

# OCT & OPTIC NERVE

Pr. Jean-Philippe Nordmann

Glaucoma Centre - Hôpital des Quinze-Vingts, Paris





## Edition

Published by:  
Laboratoire Théa  
12, rue Louis Blériot  
63000 Clermont-Ferrand  
Tel: 04 73 98 14 36

Carl Zeiss Meditec France SAS  
100 Route de Versailles  
78160 Marly-le-Roi  
Tel: 01 34 80 21 00

The content of this book presents the viewpoint of the author and do not necessarily reflect the opinions of Laboratoire Théa and Carl Zeiss.

Design - Production: Elwood

All rights of translation, adaptation and reproduction by any means are reserved for all countries.

Any reproduction, in whole or part, by any means whatsoever, of the pages published in this book, is prohibited and unlawful and constitutes forgery without the prior written consent of the publisher. The only reproductions allowed are, on the one hand, those strictly reserved for private use and not intended for collective use and, on the other hand, short analyses and quotations justified by the scientific or informational nature of the work into which they are incorporated (Law of 11 March 1957, art. 40 and 41, and Penal Code art. 425).



**Pr. Jean-Philippe Nordmann**

Centre Hospitalier National d'Ophtalmologie des Quinze-Vingts  
28, rue de Charenton  
75012 Paris - France

[j.p.nordmann@quinze-vingts.fr](mailto:j.p.nordmann@quinze-vingts.fr)



## Preface

Like many complementary examinations in ophthalmology, OCT was designed as a collaboration between ophthalmologists and orthoptists. This book is also based on such a collaboration. I want to thank the orthoptics team of Quinze-Vingts Hospital, especially Mrs. Frédérique Brion, Audrey Payeras, Cybelle Blatrix and Mr. Meddy Metref. Thanks to their energy, most diseases of the optic nerve have been presented here and OCTs have been compared with other complementary examinations, in particular visual fields and photographs of the optic nerve. I would also like to thank Prof. Philippe Denis, President of the French Society of Ophthalmology for his help and in particular the provision of interesting examples.

Knowledge has no meaning unless shared. Laboratoires Théa and Carl Zeiss have agreed to write, publish and distribute this book free of charge. I am very grateful to them.

<b>Introduction</b>	<b>Page 13</b>
<b>Principles of OCT</b>	<b>Page 16</b>
<b>General principles</b>	<b>Page 18</b>
<b>What does OCT really show?</b>	<b>Page 20</b>
<b>Analysis methods of ocular structures with OCT</b>	<b>Page 22</b>
- Optic nerve	Page 22
- Optical fibres around the papilla	Page 23
- Complex of macular ganglion cells	Page 24
<b>Error sources with OCT</b>	<b>Page 26</b>
- Signal receiving errors	Page 26
- Errors related to the positioning of the head	Page 26
- Errors related to the optics of the eye	Page 29
- Errors related to ghost images	Page 30
<b>Presentation of the results in OCT</b>	<b>Page 32</b>
<b>Cirrus™ HD-OCT (Carl Zeiss)</b>	<b>Page 34</b>
- Presentation “head of optic nerve and retinal nerve fibre analysis” (RNFL and ONH: Optic Disc Cube)	Page 34
- Presentation “Analysis of macular ganglion cells: Macular Cube”	Page 37
<b>OCT Optovue (RTVue)</b>	<b>Page 38</b>
- Presentation “Layer of parapapillary retinal nerve fibres and optic nerve”	Page 38
- General presentation “Macular ganglion cells and layer of retinal parapapillary nerve fibres”	Page 39
<b>Glaucoma</b>	<b>Page 40</b>
<b>The three structures to be analysed by OCT in glaucoma</b>	<b>Page 42</b>
- Optic nerve	Page 42
- Retinal nerve fibres (RNFL)	Page 42
- Complex of macular ganglion cells	Page 44
- Optic nerve or retinal nerve fibres: that look first in glaucoma?	Page 45
- What if there is an isolated optic nerve damage?	Page 46
<b>Preperimetric glaucoma</b>	<b>Page 48</b>
- Preperimetric glaucoma: impairment isolated from the OCT	Page 48
- Preperimetric glaucoma: impairment of the RNFL layer and the FDT Matrix visual field	Page 50
- Preperimetric glaucoma: impairment of the RNFL layer, macula and the FDT Matrix visual field	Page 52
- Preperimetric glaucoma: impairment of the FDT Matrix, OCT at the limit of normal	Page 54



<b>Early open-angle glaucoma</b>	<b>Page 56</b>
- Glaucoma with incipient open angle: location of the impairment matches between OCT and the visual field	Page 56
- Early open-angle glaucoma: depth of the impairment matches between OCT and the visual field	Page 58
- Early open-angle glaucoma: primary impairment in the OCT	Page 60
- Early open-angle glaucoma: primary impairment of the optic nerve without impairment in the optical fibres	Page 62
- Early open-angle glaucoma: comparison between OCT “Time Domain” and “Spectral Domain”	Page 64
<b>Moderate open-angle glaucoma moderate</b>	<b>Page 66</b>
- Glaucoma with moderate open angle: impairment matches in the OCT and the visual field	Page 66
- Moderate open-angle glaucoma: primary disease in the OCT	Page 68
<b>Advanced open-angle glaucoma</b>	<b>Page 70</b>
- Glaucoma with advanced open angle: impairment matches in the OCT and the visual field	Page 70
- Advanced open-angle glaucoma: primary impairment in the visual field	Page 72
- Advanced open-angle glaucoma: impairment does not match between OCT and the visual field	Page 74
<b>Normal pressure glaucoma</b>	<b>Page 76</b>
- Normal-pressure glaucoma: isolated fascicular deficit	Page 76
- Early normal pressure glaucoma	Page 78
- Moderate normal pressure glaucoma	Page 80
<b>Angle-closure glaucoma or sequelae of acute hypertension</b>	<b>Page 82</b>
<b>Follow-up of open-angle glaucoma</b>	<b>Page 84</b>
- Can OCT improve in glaucoma?	Page 87
- Comparison between “Spectral Domain” OCTs in glaucoma	Page 87
- OCT and analysis of the cribriform lamina	Page 87
<b>Non-glaucomatous optic neuropathies</b>	<b>Page 88</b>
<b>Multiple sclerosis</b>	<b>Page 91</b>
- Acute neuropathy and MS	Page 91
- Correlation between OCT and visual field in MS	Page 92
- Location of impairment by OCT in MS	Page 93
- Major sequela of neuropathy in MS	Page 94
- Can we detect subclinical MS neuropathy through OCT?	Page 96
<b>Acute optic neuropathy unrelated to MS</b>	<b>Page 98</b>
<b>Toxic optic neuropathy</b>	<b>Page 100</b>
- Toxic optic neuropathy without apparent papillary impairment	Page 100
- Toxic optic neuropathy with papillary and macular impairment	Page 102
<b>Anterior ischemic neuropathy</b>	<b>Page 104</b>

Optic neuropathy and uveo-papillitis	Page 106
Papillary oedema	Page 107
- Isolated oedema of the papilla without retinal diffusion	Page 108
- Oedema of the optic disc with subretinal oedema	Page 110
Compression of the optic nerve	Page 112
Chiasma impairment	Page 114
Amblyopia	Page 116
Perinatal impairment of the central nervous system	Page 118
Impairment of the central nervous system in adults	Page 120
Determination of the organic character of visual impairment	Page 122
Non ophthalmological neurodegenerative pathologies	Page 124
<b>Atypical appearances of the optic nerve that may show optic neuropathy in OCT</b>	Page 126
Myopia	Page 128
Dysversion the optic disc	Page 130
Physiological excavation	Page 132
Papillary coloboma	Page 134
<b>Atypical appearances of the retina that may show optic neuropathy in OCT</b>	Page 136
Vein occlusion sequelae	Page 138
Pigmentary retinopathy	Page 140
<b>Conclusion</b>	Page 143
<b>References</b>	Page 145

OCT (Optical Coherence Tomography for) is a relatively new technique that allows images of biological tissue to be obtained by measuring the reflection of light from the structure in question. Depending on the wavelength used, the discernible details are in the range of 1 to 15  $\mu\text{m}$ , i.e. at least twice as thin as is possible with the highest-performance conventional methods such as MRI or high-resolution ultrasound echography. Its main limitation is the need to analyse structures allowing sufficient light to pass through to obtain a reflected image.

The eye is clearly an “ideal” organ in this sense, because a very large number of ocular structures are mainly or partially transparent: cornea, lens, vitreous humour, neurosensory retina, as well as the front layers of the iris. Other highly reflective surface structures such as the pigment epithelium of the retina can be studied.

In 10 years, OCT has developed a key role in the diagnosis and follow-up of retinal and particularly macular impairments. This is due to the very descriptive nature of OCT images that seem to reproduce an almost histological appearance of the lesions observed. The latest generations of OCT, by multiplying the measurements, can not only reproduce this descriptive aspect, but can also perform a quantitative analysis of structures: thickness of the retina and each of its components such as the ganglion cell layer, analysis of the neuroretinal rim, etc.

Retinal imaging by OCT has thus emerged as a crucial element for the analysis of glaucomatous disease, since it is now possible to quantify the thickness of the nerve fibre layer (called either optical fibre layer or retinal nerve fibre layer, RNFL), a structure that is predominantly affected by this impairment. The optic nerve has also benefited from this quantification (surface of the neuroretinal rim, cavity volume, etc.), so that all parts of the eye that are potentially altered in glaucoma have become accessible with OCT. Obtaining quantitative values and comparing them with the standards allows us to determine the existence and severity of glaucomatous disease and allows for follow-up.

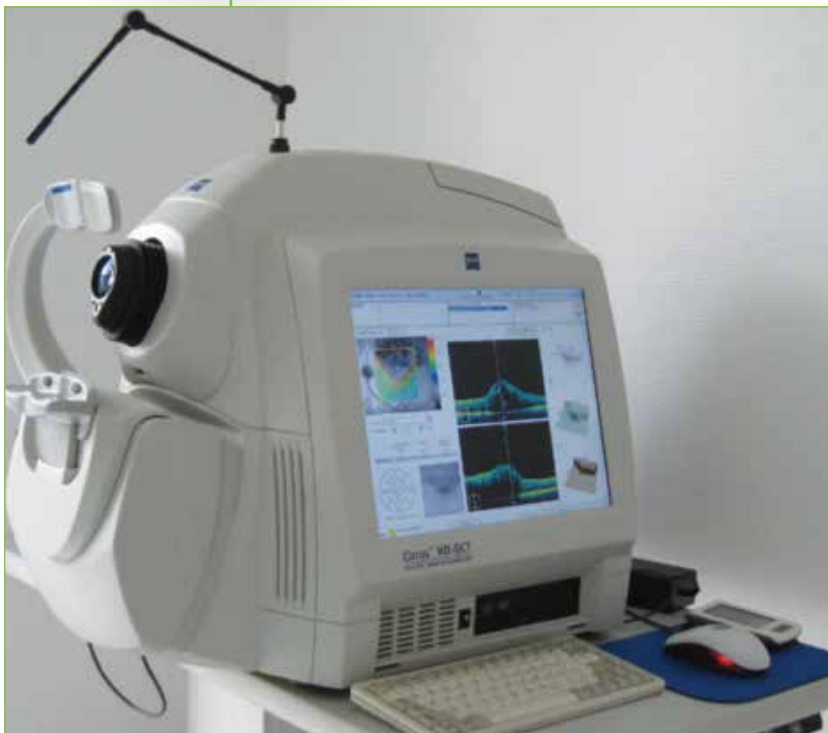It is also possible to analyse the iridocorneal angle, but in a less precise way, especially because what happens at the back of the pigment epithelium of the iris remains inaccessible to OCT.

Glaucoma is one of a range of optic neuropathies, and OCT also appears useful in the analysis of all diseases of the optic nerve and, to some extent, the central nervous system when ocular impacts are present.

However, as with any new technology, analysis of the results of OCT requires careful interpretation because the method of data acquisition is complex and does not involve simple photography of the structures studied. It is always desirable to examine the quality of the results, not only in an overview, but also in closer detail when a zone appears suspect.

Once these pitfalls have been avoided, a new field of exploration and in particular investigations opens up. What is the clinical meaning of one impairment or another? How should a worsening of the impairment of the optical fibres be interpreted if all other exams are stable? How can we explain, on the contrary, that a particular structure is no longer changing in the OCT when the glaucoma is indisputably worsening?

OCT is advancing so quickly that it is impossible to clearly define its use profile, and any document is certain to become obsolete quite quickly. Currently indispensable for analysing the retina, it is becoming so for glaucoma and other optic neuropathies. This little book aims to simply give an update on OCT in glaucoma and pathologies of the optic nerve. The first chapter concerns the principles and interpretation of OCT and has a purely practical function, to help the reader understand the results. Glaucoma is obviously an important part of this book, but one part is devoted to other eye diseases and especially neuro-ophthalmological diseases, because they can mimic glaucoma or be a source of confusion if they are also present. Regardless of this facet of differential diagnosis, OCT has acquired its place in the evaluation of the optic nerve in general.



*Cirrus™ HD-OCT (Carl Zeiss)*





# Principles of OCT

OCT works by analysing the light reflected by zones crossed by an incident light generated by a laser with a wavelength in the infrared range around 840 nm. Logically, when a beam of light passes through a structure, one part of the light will continue its path (especially if the structure is quite transparent), one part will be absorbed by the structure, one part will be reflected in all directions and the final part will be reflected towards the emission zone.

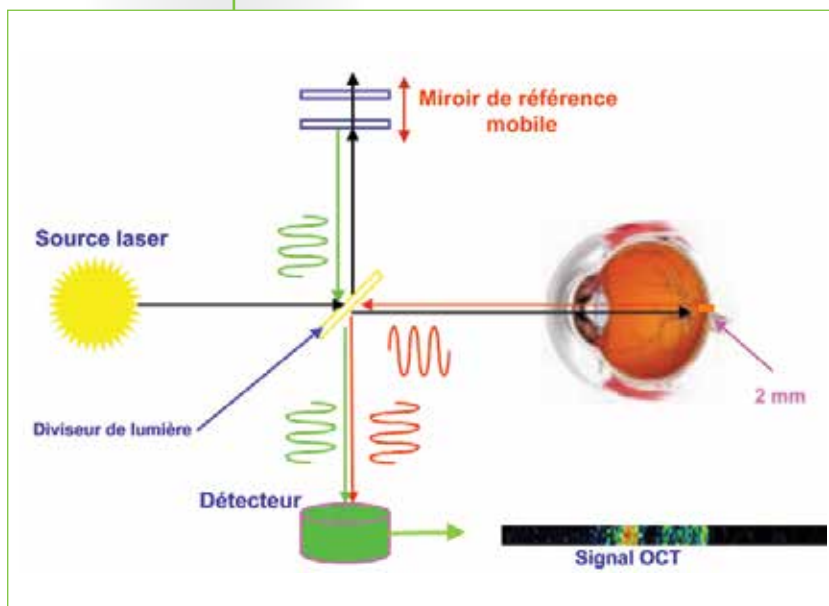
It is this last part of the light that is analysed in OCT. It corresponds to between one-billionth and one-millionth of the incident light, so it is very weak.

## General principles

Sound waves propagate relatively slowly (300m/sec in air) and it is possible to record the return time of this wave directly, as with UBM. However, the high propagation speed of light waves (300,000 km/sec) does not allow this time to be recorded, which is in the order of 30 femtoseconds ( $30 \times 10^{-15}$  sec).

OCT uses the principle of interferometry to analyse this delay. An incident wave is divided into two, one part being projected onto a plane mirror and the other onto the eye. The two waves thus created are reflected; the wave sent to the mirror returns as a single echo; the wave sent to the eye returns as multiple echoes depending on the structure it has passed through. These waves are compared by an interferometer which measures the coherence between them (hence the term OCT, Optical Coherence Tomography). This allows us to deduce the thickness of the structure passed through by the wave sent to the eye.

This simple measurement at a given point and a given depth is called an A-scan. With “Time Domain” technology, the mirror moves repeatedly at different depths to analyse the different layers of the retina.



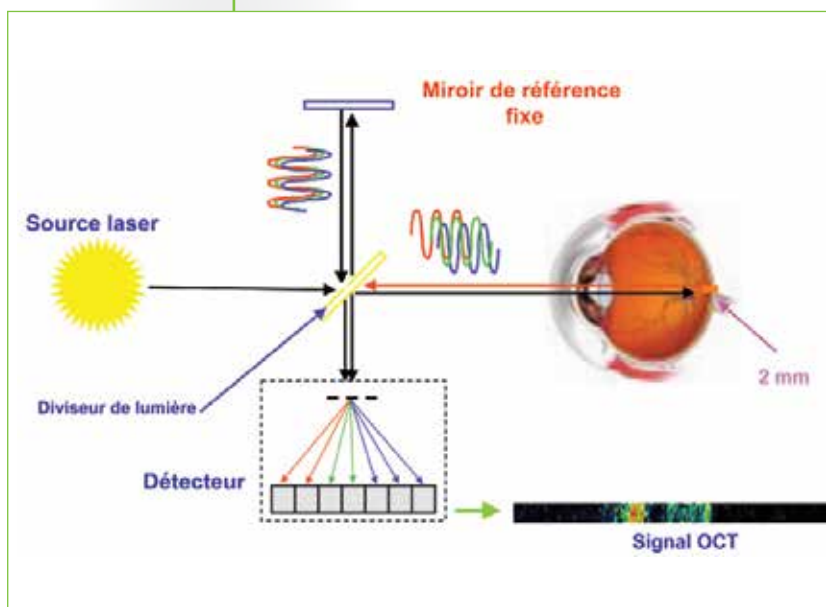
### *Acquisition of an A-scan: Time Domain*

*“Time Domain” OCT technology:  
a reference mirror moves to  
successively study the different  
depths of the retina.*



The fastest devices in Time Domain allow the measurement of 17,000 A-scans per second. These measurements in one dimension are then reassembled into 2 dimensions to obtain a slice of the retina at a given place (B-scan). Time Domain technology is limited by these movement of the mirrors, since an examination cannot reasonably take more than a few seconds when it is necessary for the eye to remain relatively fixed.

A very different technology that has led to a dramatic improvement in the quality of OCT images is “Spectral Domain” technology. Instead of using the coherence between two waves, it uses the interference spectrum between the two reflected beams of broad-spectrum waves. This interference is studied by mathematical analysis using the Fourier transform. The great advantage of this “Spectral/Fourier Domain” technology is that it is possible to analyse the reflected ray not successively at each depth, but at the same time. The reference mirror therefore no longer has to move and this allows the process to become 50 to 100 times faster.



*Acquisition of an A-scan:  
Spectral Domain*

*“Spectral Domain”  
OCT technology: the reference  
mirror is fixed and the different  
depths of the retina are analysed  
at the same time.*

It is thus possible to make much more precise measurements (around  $2\ \mu\text{m}$ ) during a reasonable examination time. Nevertheless, the examination itself is not instantaneous like a single photograph, and the quality of the results may be affected by an eye movement. It is not instantaneous because if the different depths of the retina can be studied at the same time, it is necessary for the laser beam to successively scan the different regions of this retina.

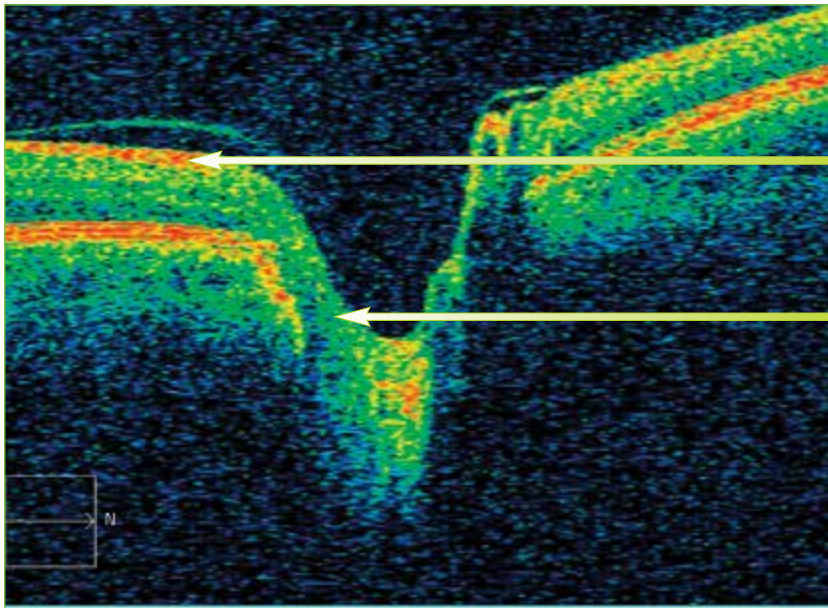
## What does OCT really show?

OCT shows the reflection of light in different eye structures. This reflection is particularly strong when there are sharp edges between two media having different refractive indices. This is particularly the case in the cornea, which is perfectly imaged in OCT. In addition, these reflections are sharper when the structure crossed is perpendicular to the incident light, rather a glass that partially reflects light. In general, reflection of light (only a part of which occurs towards the incident source) is a property of inhomogeneous structures responsible for microchanges in the refractive index, such as cell membranes, nuclei, cytoplasm, axons of cells, etc. The most reflective structures of the retina are the retinal nerve fibre layer (RNFL or optical fibres), the pigment epithelium and the interplexiform layers. The more reflective a structure is, the more red it appears, due to the colour code used in OCT.

Some structures contain melanin, which absorbs light strongly. At this level, reflection and absorption are responsible for an exponential reduction in the power of the incident beam, preventing it from exploring more distant areas. That is why OCT does not allow the precise study of structures beyond the pigment epithelium of the retina, which has the dual property of being highly reflective in the part first hit by light, and highly absorbent in the most basal area.

From this light reflection data, OCT measures the thickness of the layer studied in a calculation that considers the time that the incident beam takes to return and the known refractive index of the structure crossed.

It is therefore very important to note that OCT images are not direct images of the retina, but rather a reconstruction based on mathematical calculations transposed subsequently into images of the ocular fundus. You can understand this quite easily by looking for example at the changes in the appearance of the optical fibres in the optic nerve when these fibres change direction to exit the eye. The reflection of light on the layer of the optical fibres appears in red. When these fibres change direction when moving towards the optic nerve, this colour changes. OCT is therefore not an anatomical slice of the retina.



*Strong reflection because the layer of optical fibres is perpendicular to the light.*

*Weak reflection because the layer of optical fibres becomes parallel to the light.*

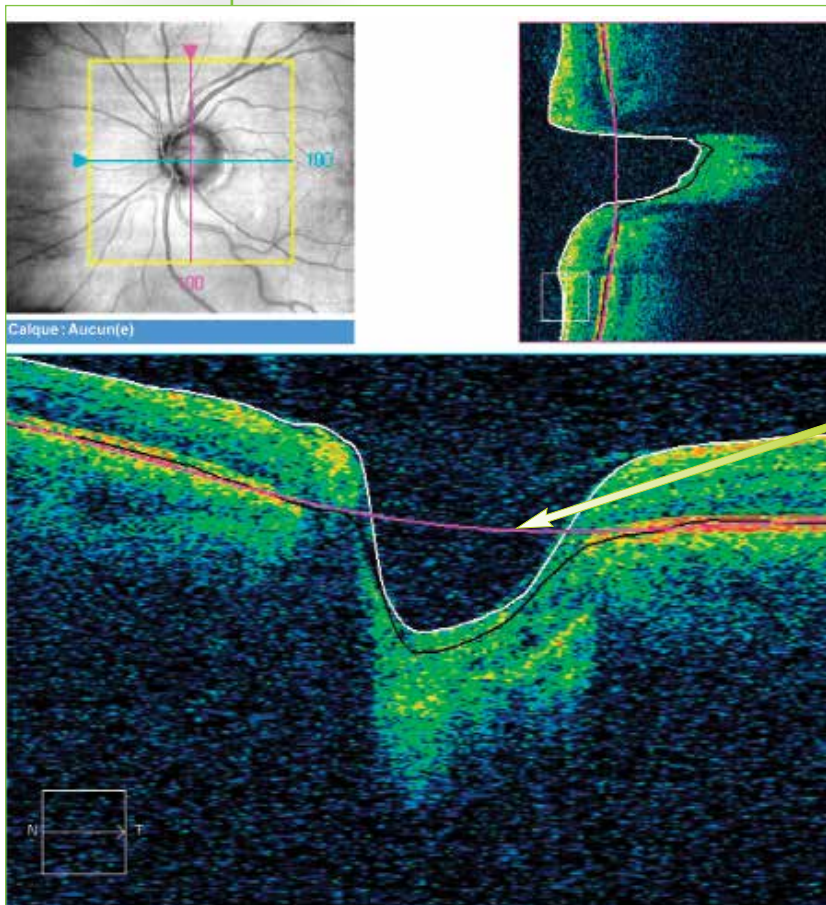
These simple remark allow us, in case of doubt about a result, to view the images obtained and get an idea about whether the impairment exists or not.

When OCT analyses a layer of cells (for example, the ganglion cell layer of the macula), it must be remembered that the measurement corresponds to the entire layer (ganglion cells, support cells, interstitial fluid, etc.) This explains why, when glaucoma is very advanced or even passed, the layer in question does not completely disappear, because some support cells remain.

In this brief chapter we review only those structures liable to be modified in glaucoma and optic nerve pathologies, namely the optic nerve head, the parapapillary optical fibre layer and the macular ganglion cell complex.

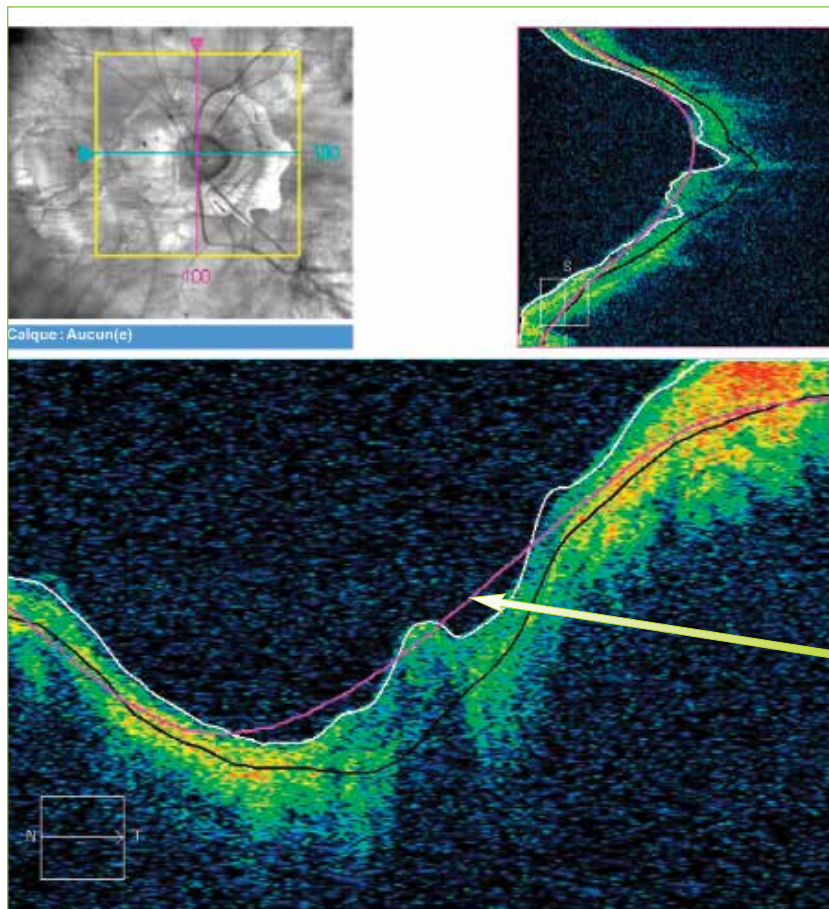
## Optic nerve

The initial problem of analysis of the optic nerve is how to define the contours of the optic nerve and what can be considered the start of the cavity. It was chosen to define a reference plane arbitrarily set at 150  $\mu\text{m}$  above the level of the peripapillary pigment epithelium. Based on this level, everything below it is considered to correspond to an cavity, whether physiological or not. It is then possible to measure the papillary parameters: width and surface of the neuroretinal rim on the different meridians, size of the disc and cavity, C/D ratio, etc. It is important to understand these points because when the disc is irregular, the measurements may be distorted by erroneous identification of this plane.



*The papillary region is regular, the pink line clearly determines the boundary between the retina and the cavity.*

*Eye with normal configuration*

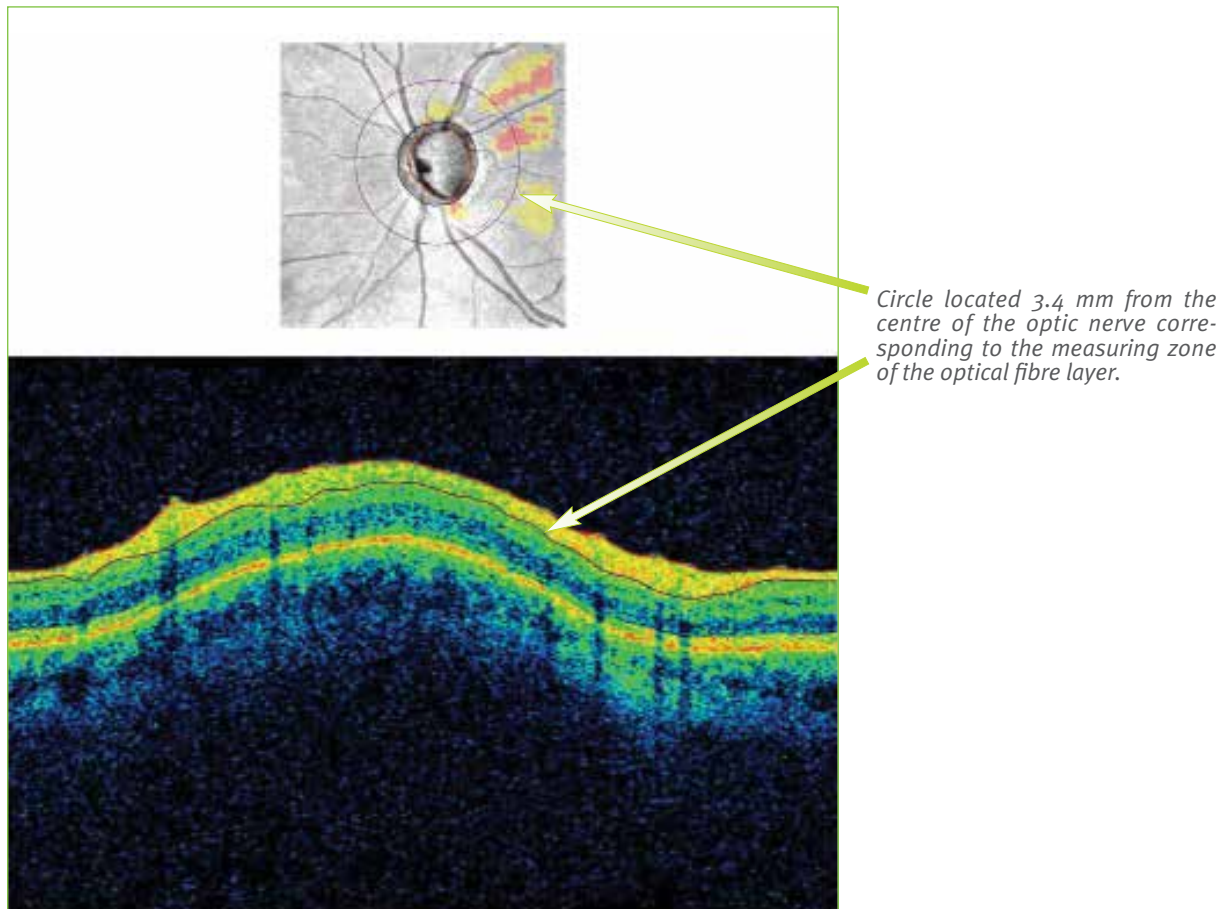


*The papillary region is irregular; the pink line does not readily demarcate the boundary between the retina and the cavity.*

*Strong myopia*

### Optical fibres around the optic disc

The device's program first identifies the two most refractive zones of the retina, which are the front of the optical fibre layer and the pigment epithelium. It then evaluates the location where the reflection of the optical fibre layer decreases sharply, thus allowing its thickness to be measured. The speed of the "Spectral Domain" OCT examination allows the measuring of a cube around the optic nerve, but it is necessary to choose what zone is to be detailed. In fact, the thickness of the optical fibres is measured at 3.4 mm from the centre of the optic disc. This distance was chosen because it is the best compromise "Thickness of optical fibre layer/interindividual variability". In fact, the closer you get to the disc, the thicker the layer is, and we could therefore be expected to be able to detect small changes in it. However, close to the optic disc, the results vary from one person to the next, and depending on the location of the vessels and the shape of the disc. Conversely, if the measurement is done a long way from the disc, the results are more consistent between people, but the fibre layer narrows quickly and small changes become less detectable. In practice, it was therefore decided to measure the fibre layer at 3.4 mm from the centre of the disc.



However, it is not always at this level where the first disease signs are found or where follow-up will be done best. In the follow-up, the zones closest to the disc would be likely to allow a better analysis of progression.

### Complex of macular ganglion cells

Thanks to “Spectral Domain” technology, it is possible to measure the thickness of each layer of the retina and in particular the ganglion cell layer in the macular region.

This zone is particularly interesting because the cells in this region correspond to around 30% of the entire thickness of the structure. The foveal region is not of interest because, conversely, it is endowed with too few ganglion cells.

Most devices measure a range including “internal interplexiform layer - bodies of ganglion cells - axons of ganglion cells passing above them”.

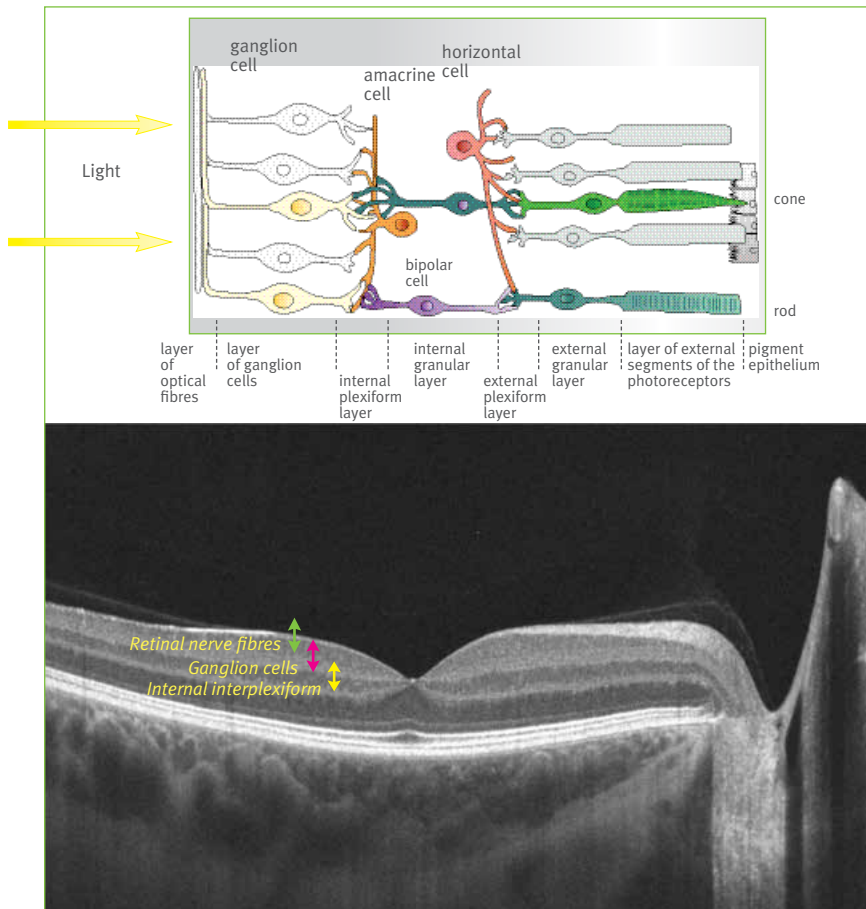


Diagram of the retina

The three layers studied in the complex of ganglion cells.

It is possible to refine this measurement to better locate the impairment by eliminating the axons of ganglion cells that correspond to cell bodies located at a distance. This is offered by some devices (e.g. the Cirrus™ HD-OCT (Carl Zeiss)), which eliminates the axon layer and thus measures only the “internal interplexiform - ganglion cell bodies” layer.

OCT appears as an objective examination, so it is less prone to patient-related errors. However, many errors can occur, related either to the imaging or to the structure of the eye.

### Signal receiving errors

The quality of imaging is crucial and is not straightforward, since only less than one-millionth of the incident light sent by the laser is reflected towards the sensor. This quality is expressed in the results by the expression “Signal Strength” and must be greater than 6/10 with the Cirrus™ HD-OCT (Carl Zeiss) or 50 with the Optovue (RTVue). A poor signal is often responsible for an underestimation of the thickness of the optical fibres.

### Errors related to head positioning

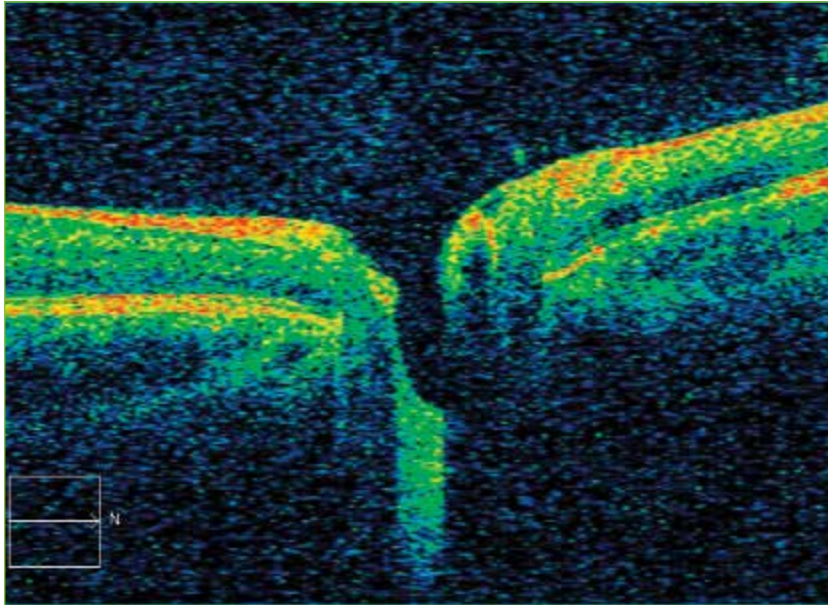
The measuring principle of OCT is based on reflection of incident light, which depends on two key things: microchanges in the refractive index of the medium crossed, and the orientation of the structure crossed; the more the latter is perpendicular to the incident beam, the stronger the reflection. Head positioning errors lead to changes in the axis of the eye and are therefore responsible for variations in the results.

This can easily be seen in the example below, remembering that the colour code in OCT indicates that the redder the colour is, the more reflective it is. If the presentation is well done, the parapapillary optical fibre layer is thick.

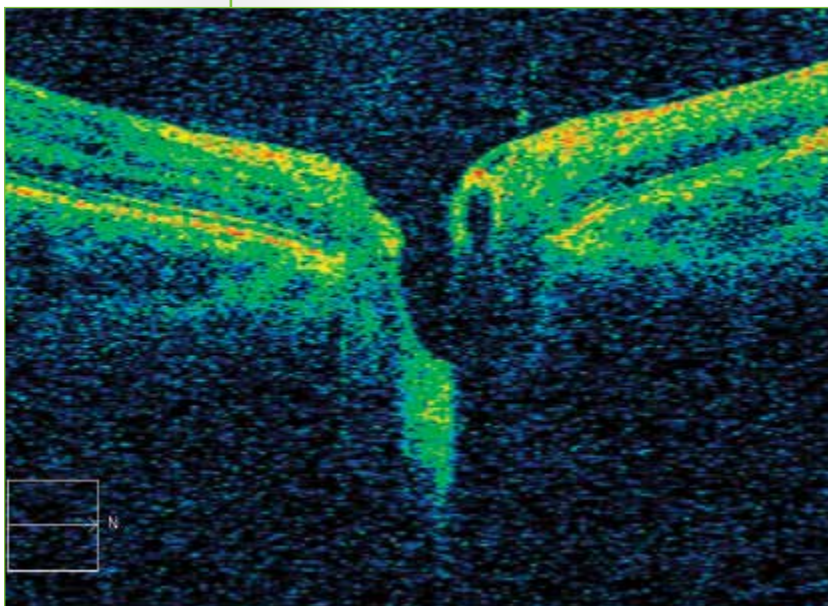
When the depth setting is incorrect (for example, too distant), this layer seems to decrease strongly, or when the head is tilted back.

This does not always result in insufficient signal quality, and therefore it cannot be detected easily.

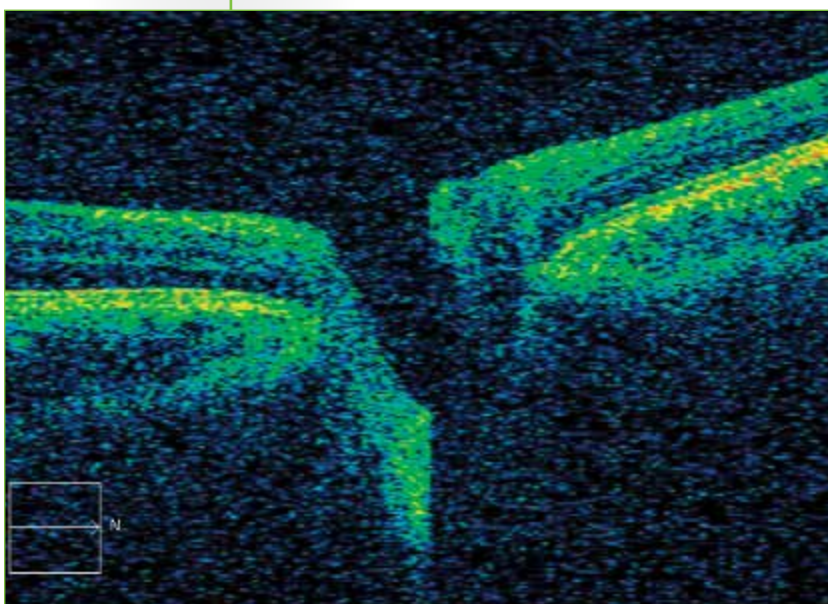




Correct head position. The optical fibre layer (red) is normal.

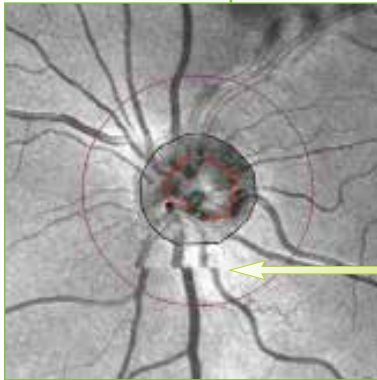


Head tilted back. The optical fibre layer is reduced. Same eye as in the previous patient.



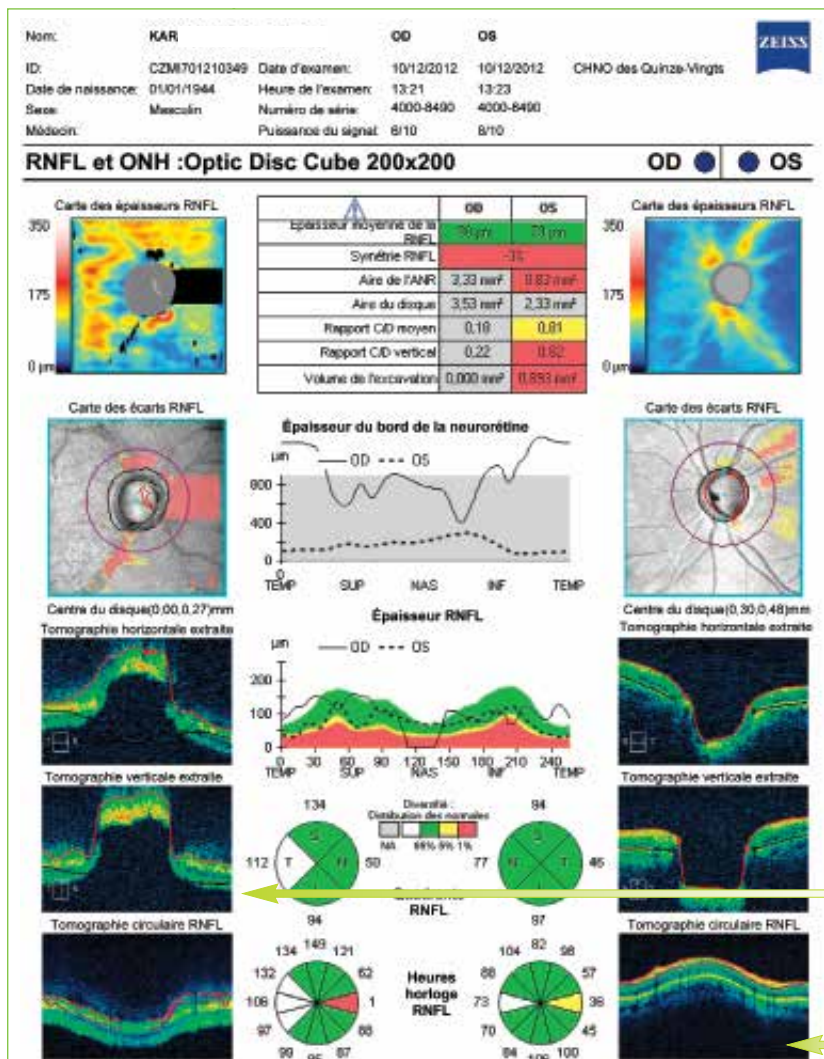
Poor adjustment in myopia. The optical fibre layer is reduced. Same eye as in the previous patient.

Another factor responsible for poor quality is the artefact related to eye movements because the examination time is around 1.5 sec. OCT offers programs to correct these artefacts, or even eye tracking during the examination. Nevertheless, it should be ensured that there are no discontinuities in the results.



*Shifting of the image  
Discontinuity of the image  
during an examination due to an  
eye movement. This is responsible  
for errors in the calculation of the  
RNFL parameters.*

With OCT in the “Spectral Domain”, artefact phenomena in the mirror may occur when the eye is incorrectly positioned or when significant depth variations of the retina are present in severe myopia. The upper limit of the OCT images corresponds to immediate reflection (no delay in reflection) and therefore nothing can be weaker. If the eye is not positioned correctly, an even closer image will be detected in the mirror and therefore completely inverted, with the outer part of the eye appearing at the top and the inner part at the bottom. In addition to the optic nerve, the retinal layers are therefore also completely inverted.

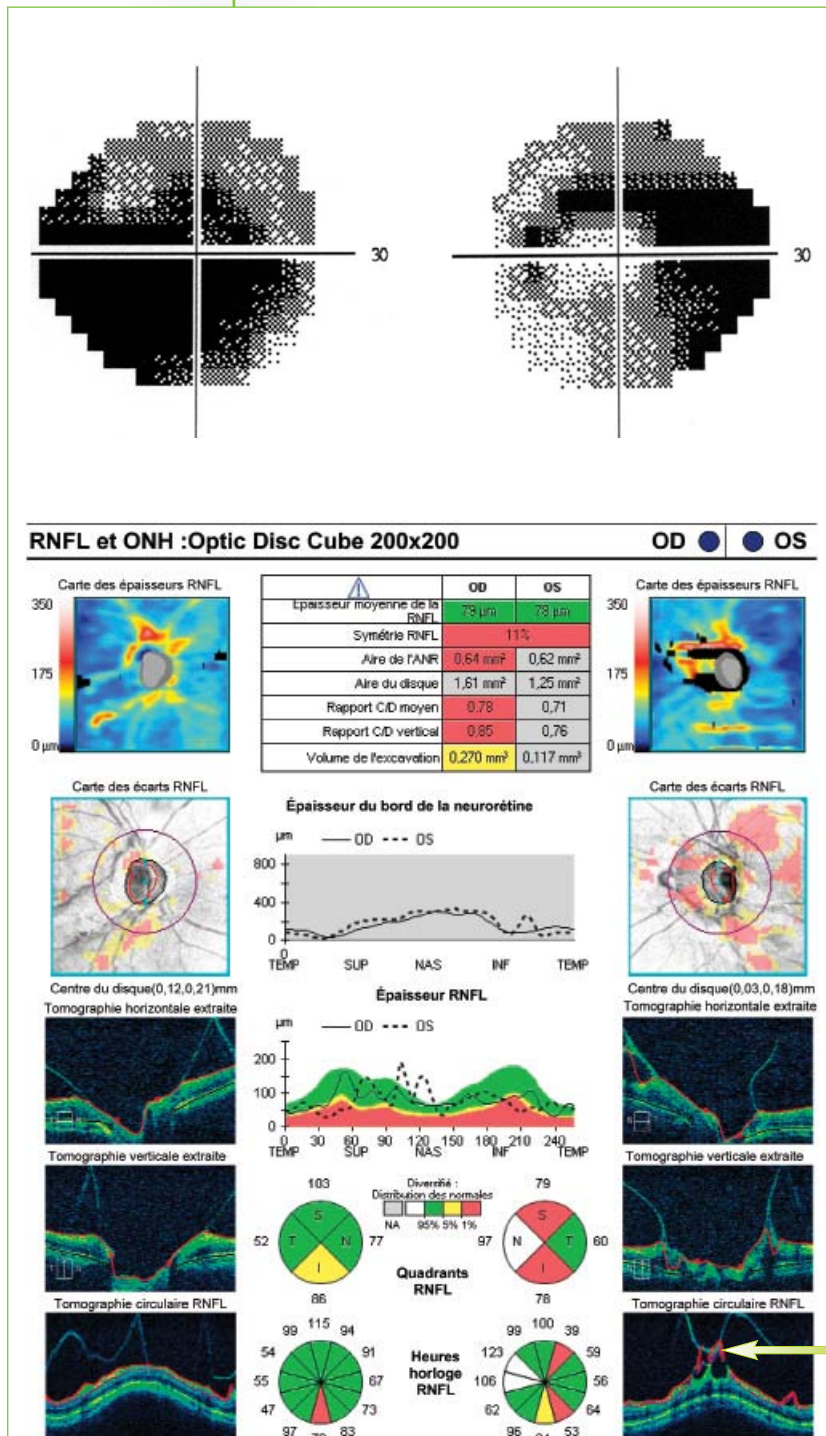


## Errors related to the optics of the eye

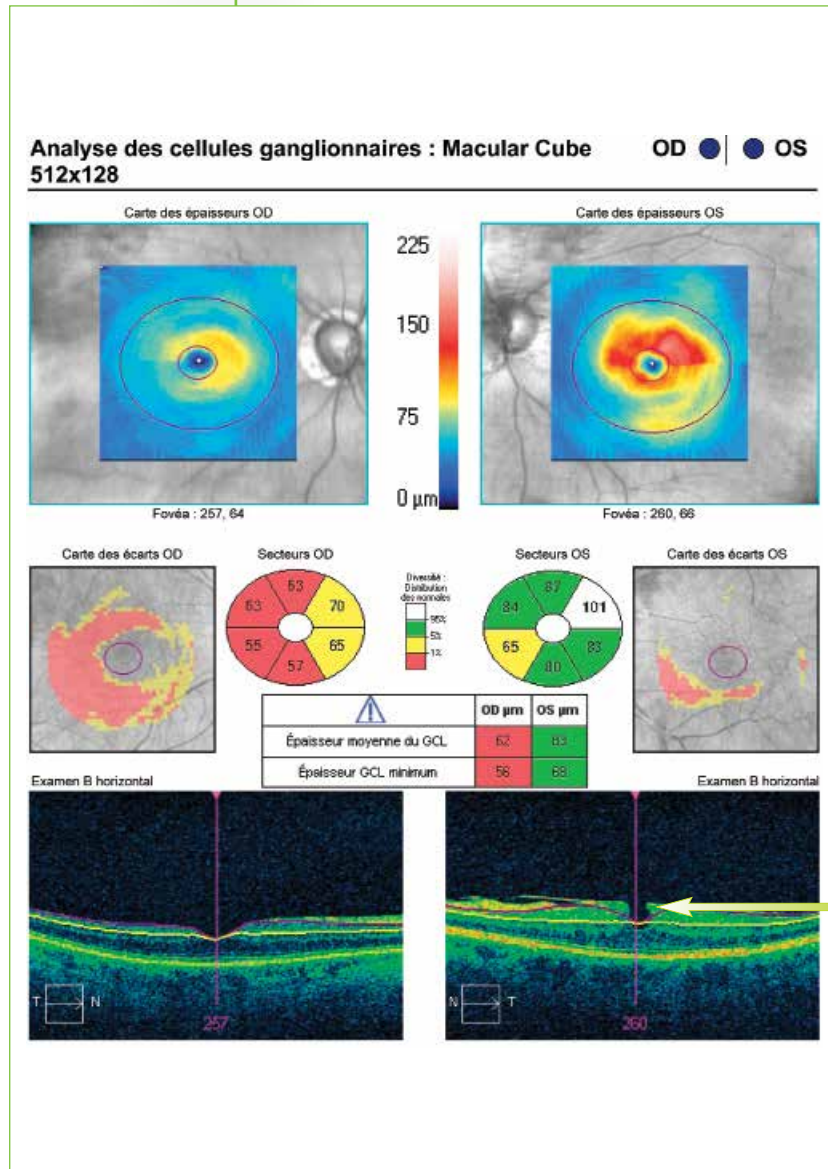
The optics of the eye may also impact the result quality. Opacification of the posterior capsule tends to reduce the evaluation of the optical fibre layer <sup>1</sup>. Conversely, wearing multifocal lenses does not change the results at both the macula and parapapillary levels <sup>2</sup>. The size of the optic disc does not influence the thickness of the optical fibres, except in the case of very small size where false disease signs seem to exist <sup>3</sup>. Conversely, myopia is a source of artificial reduction of this thickness due to measurement problems when the axial length of the eye is too high. The “bigger” an eye is, the bigger the circumference located 3.4 mm from the centre of the optic nerve. The optical fibres are more spread out than in a normal eye, and this therefore leads to a reduction in thickness, without however the number of optical fibres being fewer than normal <sup>4</sup>. This phenomenon is not significant in the macular ganglion cells and we can therefore prefer to analyse this region in high myopic patients <sup>5</sup>.

## Errors related to ghost images

OCT can sometimes confuse highly reflective structures that lie close to each other. This is the case, for example, in the posterior hyaloid and the internal boundary of the retina.



In most diseases of the optic nerve, a thinning of the optical fibre layer is observed. However, the OCT images should be consulted in case of doubt, because this thinning may be hidden by oedema in the structure having a different origin. This is the case when traction phenomena are noted.



*Bilateral glaucoma patient with impairment of visual field touching the central 10°. On the right, we note an impairment of the ganglion cell complex. On the left, there is a macular hole. Traction at this level and the oedema that follows mask the thinning of this layer, which seems to be normal.*



# Presentation of results in OCT

Many different devices currently exist. In the United States, more than 30 devices have obtained a marketing authorisation. It is therefore not possible to give a detailed presentation of all available OCTs. In France, the most common devices are the Stratus and Cirrus™ HD-OCT (Carl Zeiss) and the Optovue (RTVue). Most of the examples provided were produced with these two devices. Insofar as the two most important areas in glaucoma are the papillary and parapapillary regions, on the one hand, and the macular ganglion cell complex on the other hand, these results are subject to detailed interpretation.

### Presentation “head of optic nerve and retinal nerve fibre analysis” (RNFL and ONH: Optic Disc Cube)

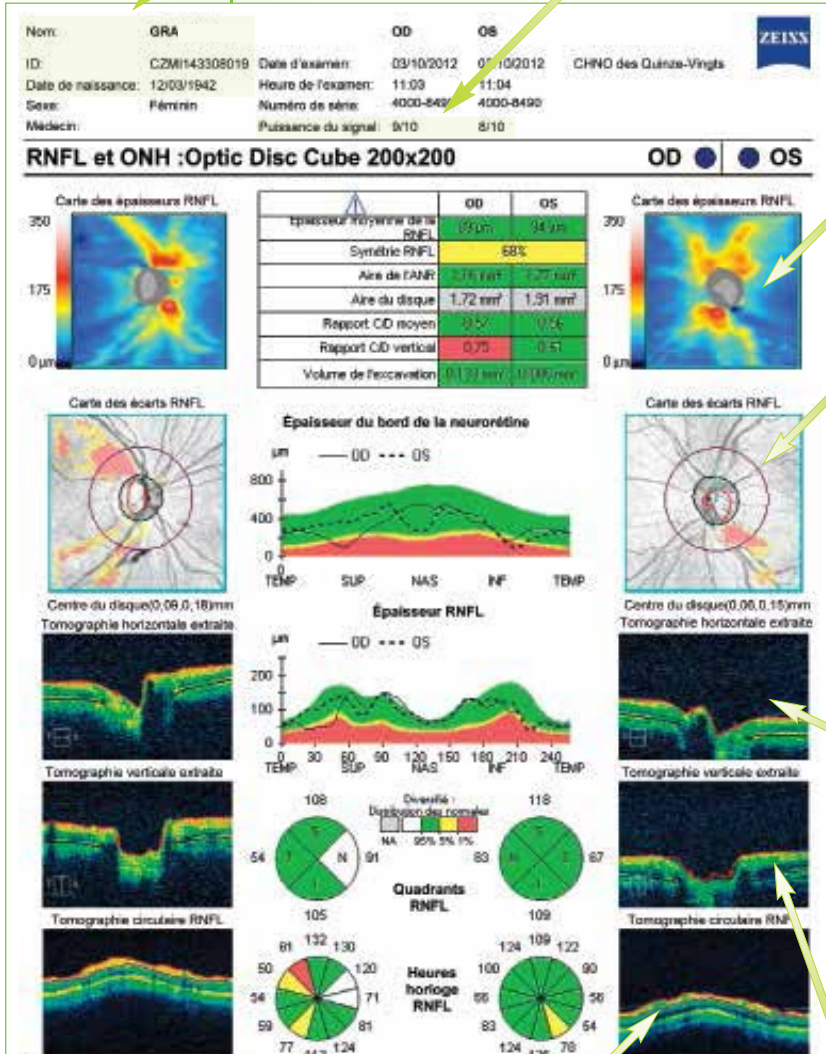
The examination shows, on a single page, both eyes (OU), with the right eye (OD) located on the left and the left eye (OS) on the right. In all of the statistical presentations, the colour yellow indicates an anomaly at  $p < 5\%$  and red indicates an anomaly at  $p < 1\%$ . Some patterns are small and difficult to analyse, but it is possible to enlarge them on a separate page.

The values obtained are compared to a patient of the same age with an optic disc of the same size. The size limits of the optic disc range from  $1.3 \text{ mm}^2$  to  $2.5 \text{ mm}^2$ . Outside of these limits, all measured parameters are shown in grey, because they are not compared to a standard. For each value, this number appears on a white background if it corresponds to 5% of the best values, and on a green background for 90% of cases. The colour yellow indicates an anomaly at  $p < 5\%$  and the colour red indicates an anomaly at  $p < 1\%$ .



Full name of the patient. It must be spelled correctly in order to guarantee follow-up. The patient's date of birth is important because the results are compared to age-dependent norms.

Signal strength. This lets you know if the results have been correctly acquired. Values higher than 6/10 are required. Even if the signal is strong, the results may be inaccurate if the eye is incorrectly positioned.



Thickness of the optical fibre layer. The thicker this layer is, the warmer the colour. Given the physiology of optical fibres, a "watch hands" appearance centred on the disc is normal.

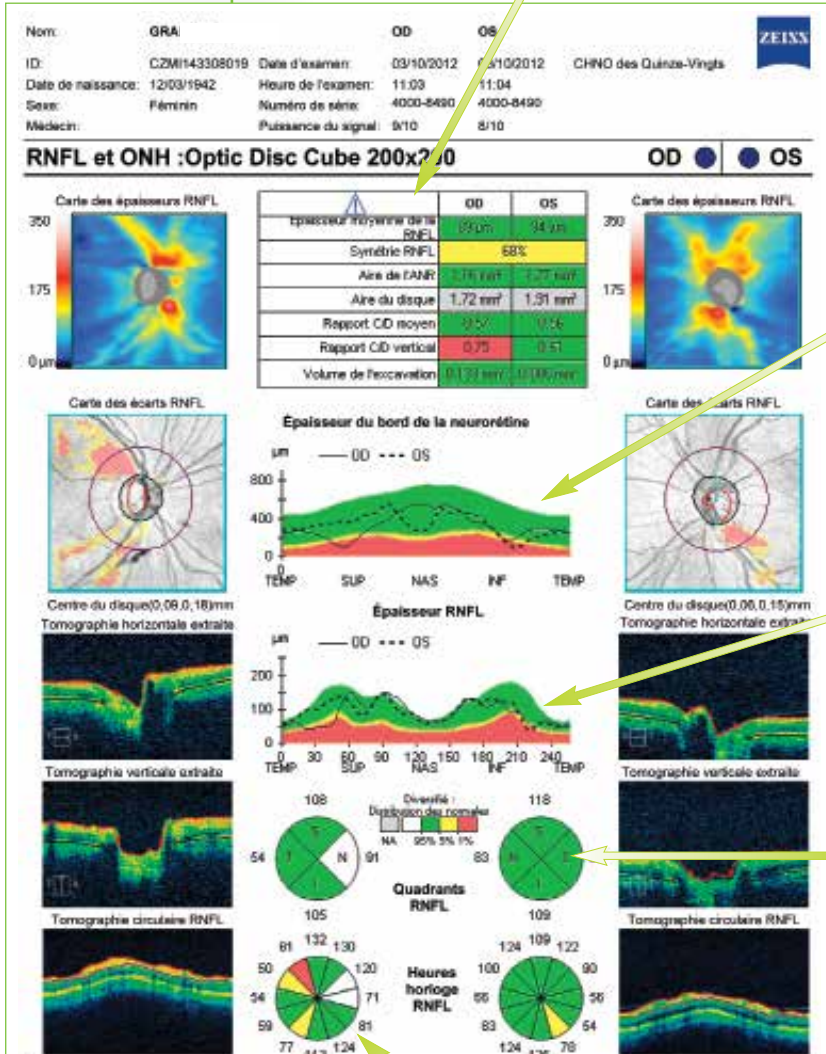
Image of the ocular fundus in which the statistical values of anomalies in the optical fibre layer are coloured. The optic disc is delimited, as well as the zone 3.4 mm from the centre of the disc where the thickness of the parapapillary nerve fibres is measured. It is important that this circle is not located in a zone of peripapillary atrophy because the reflectance of the pigment epithelium would be evaluated incorrectly and the results could be distorted.

Horizontal section of the posterior pole. It is important to ensure that the retina does not touch the upper part of the square, as this would distort the results. The reflectance of the different layers appear, as well as the boundaries of the retina and Bruch's membrane. Two small dots indicate a zone 150 µm above Bruch's membrane that defines the start of the cavity.

Vertical section of the posterior pole. Imaged elements identical to the previous presentation.

Position of the retina at 3.4 mm from the optical centre, corresponding to the region where the retinal nerve fibres are studied.

Average thickness of the optical fibre layer (RNFL).  
 Symmetry of this layer between the 2 eyes (RNFL Symmetry).  
 Surface of the neuroretinal rim (ANR area).  
 Area of the optical disc.  
 Average C/D ratio.  
 Average vertical C/D ratio.  
 Cavity volume.



Thickness of the neuroretinal rim in the different regions (temporal, superior, nasal, inferior, TSNIT); the right eye is shown as a continuous line, the left eye as a dotted line, the normal zones in green, abnormal zones in yellow and then red. This makes it easy to locate a notch.

Thickness of the optical fibre layer in different regions (temporal, superior, nasal, inferior) at 3.4 mm from the centre of the optic nerve; the right eye is shown as a continuous line, the left eye as a dotted line, normal zones in green, abnormal zones in yellow and then red.

Representation for each eye of the thickness of the optical fibres, by sections 6 hr wide. In glaucoma, the most affected zones are the upper and lower zones.

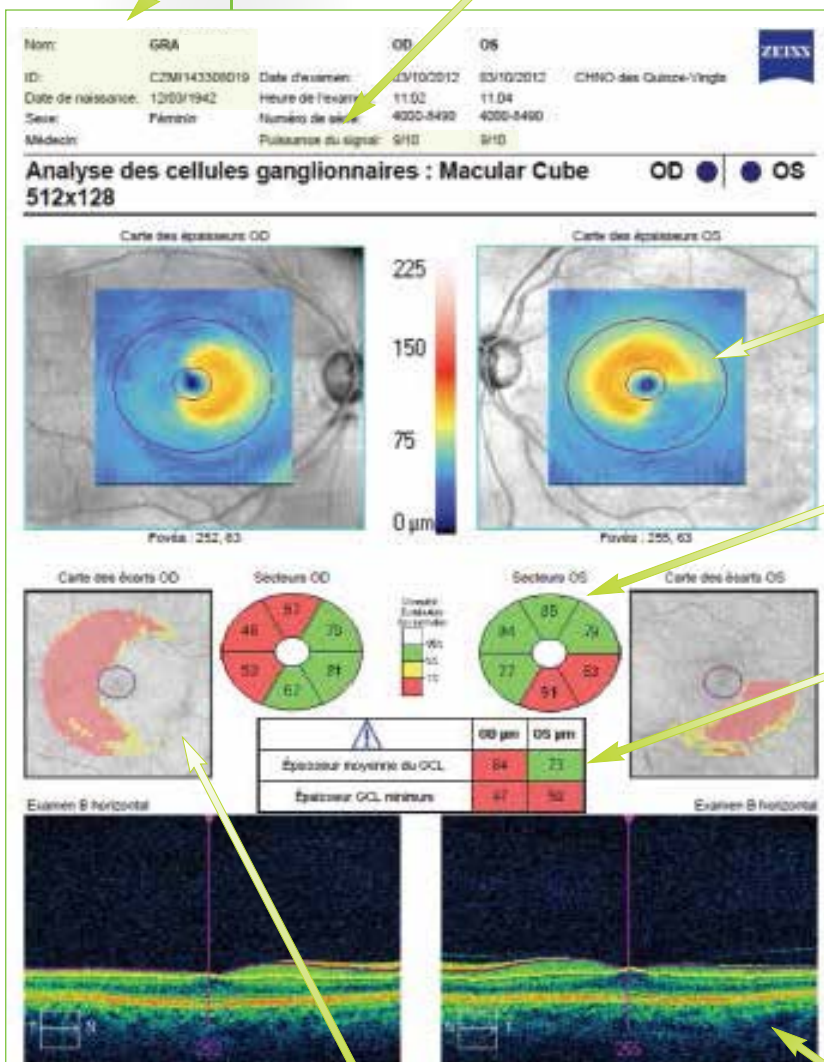
Representations for each eye of the thickness of the optical fibres, by sections 2 hr wide. In glaucoma, the most affected areas are located at 7 hr for the right eye and 5 hr for the left eye.

## Presentation “Analysis of ganglion cells: Macular Cube” (Ganglion Cell OU Analysis)

The examination shows, on a single page, both eyes (OU), with the right eye (OD) located on the left and the left eye (OS) on the right. For each value, this number appears on a white background if it corresponds to 5% of the best values, and on a green background for 90% of cases. The colour yellow indicates an anomaly at  $p < 5\%$  and the colour red indicates an anomaly at  $p < 1\%$ .

Full name of the patient. It must be spelled correctly in order to guarantee follow-up.

Signal strength. This lets you know if the results have been correctly acquired. Values higher than 6/10 are required.



Thickness of the layer of the ganglion cell complex. The thicker this layer is, the warmer the colour.

Presentation in the sector of the macular region, without studying the fovea, with the average thickness value in each zone.

Table of average and minimum values of the thickness of the layer “ganglion cells + internal interplexiform”, without the layer of ganglion cell fibres. The minimum value corresponds to the thinnest sector of 1° width.

Statistical values of anomalies in this layer. The colour yellow indicates an anomaly at  $p < 5\%$  and the colour red indicates an anomaly at  $p < 1\%$ .

Horizontal scan of the macula passing through the fovea.

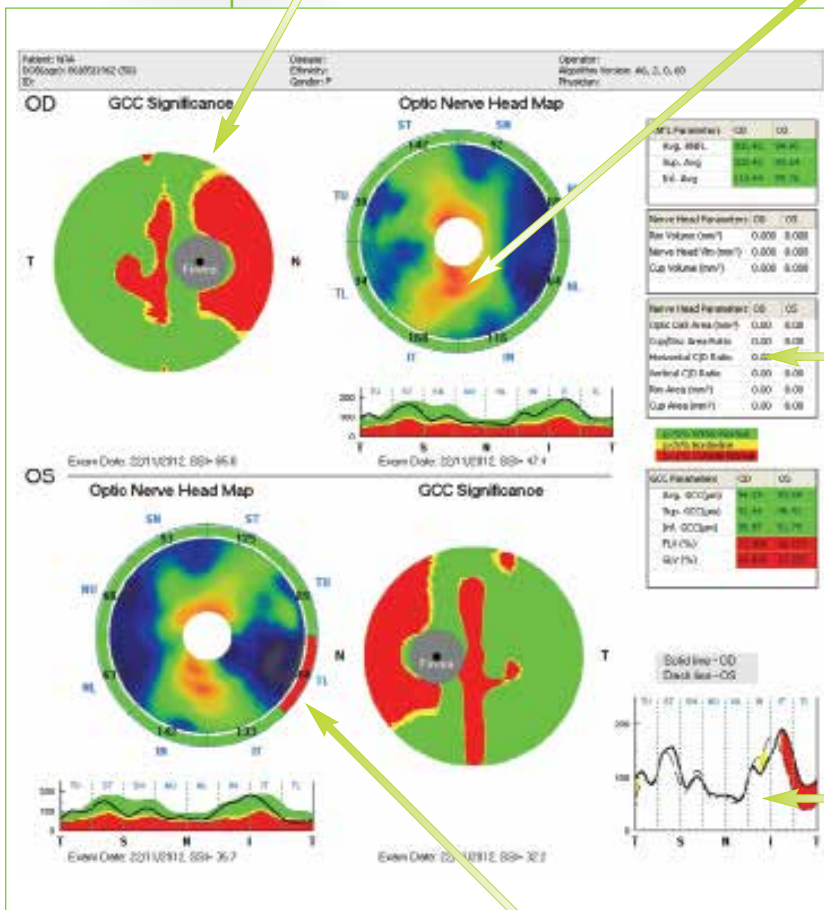


## General presentation “Macular ganglion cells and layer of parapapillary retinal nerve fibres”

A single page shows all of the results without adding a direct OCT image. Many elements described in the previous results are repeated here.

Complex of macular ganglion cells “layers of optical fibre axons + ganglion cells + internal interplexiform”. Statistical representation.

Thickness of the optical fibre layer in the different regions. The warmer the colour, the greater the thickness.



Parameters of the optic nerve head.

Interocular differences, layer of parapapillary fibres.

Thickness by region of the optical fibre layer with statistical values. Normal zones are green, abnormal zones are yellow and then red.



# Glaucoma

Glaucoma is a slowly progressive optic neuropathy that is most often associated with ocular hypertension. The progressive deformation of the head of the optic nerve caused by this hypertension leads to a cavity and destruction of the retinal nerve fibres passing through the cribriform lamina. This destruction is responsible for visual field impairment. This succession of “structural impairment inducing functional impairment” allows us to estimate that, in theory at least, the analysis of the structure should detect an initial impairment before the impairment of the visual field<sup>6</sup>. For a long time, the methods available to study the structure did not allow this approach to be confirmed.

With the new-generation “Spectral Domain” OCT, the structural changes can often be detected before they have impaired the visual field. However, in some cases, we note that the visual field is impaired before we can detect any structural impairment. Each eye has between 800,000 and 1.2 million optical fibres. If the “starting point“ is close to the upper limit, significant impairment can occur while the subject remains within the statistical standards. On the other hand, if the initial structure of the eye is more normal, destruction of fibres by glaucoma is more quickly visible.

### Optic nerve

At the head of optic nerve, the parameters affected firstly in OCT are, in order:

- the vertical thickness of the neuroretinal rim (not shown in the results),
- the overall surface of this rim (Area of the ANR),
- the vertical C/D ratio.

Although these parameters detect glaucoma well, they are not very effective in differentiating early glaucoma from moderate glaucoma<sup>7</sup>.

### Retinal nerve fibres (RNFL)

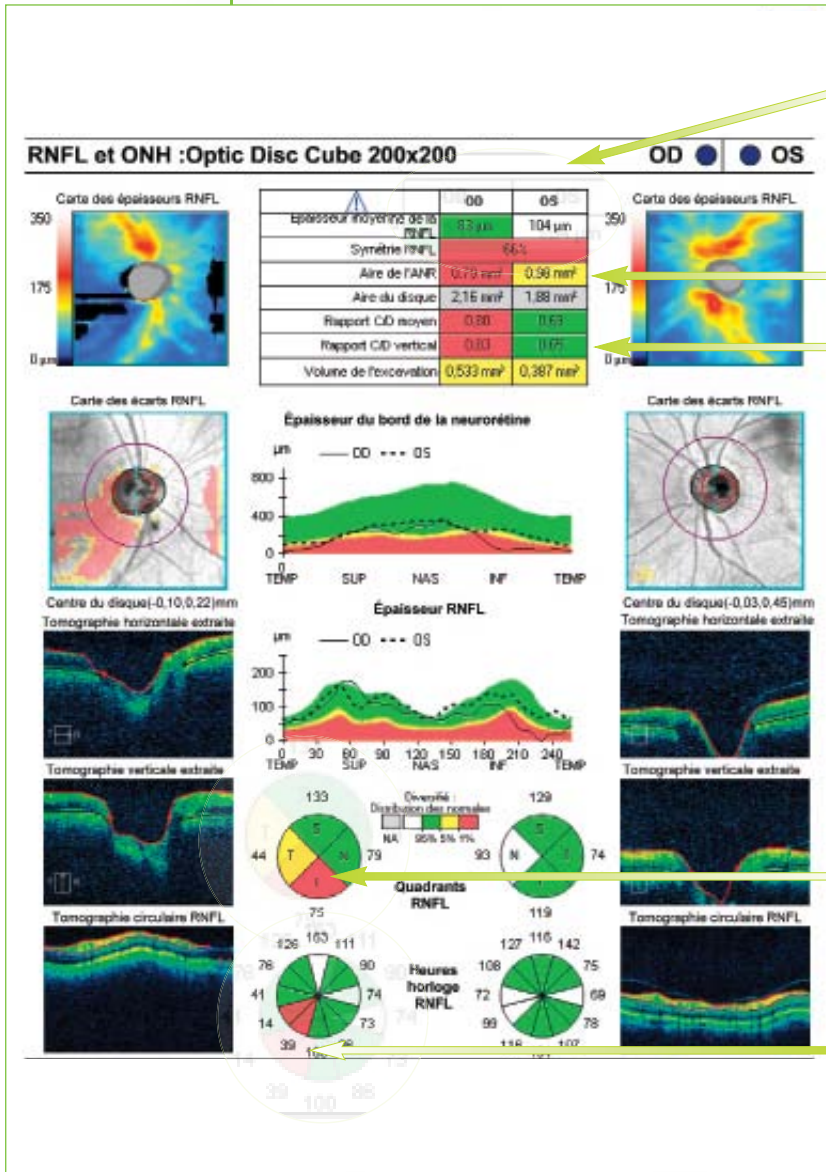
The parameters that best differentiate normal subjects and early glaucoma subjects are, in order:

- the thickness of the retinal nerve fibres in the lower temporal zone,
- the thickness of the retinal nerve fibres in the lower quadrant,
- the average thickness of retinal nerve fibres.

Some studies seem to show that the upper temporal sector would be just as differentiating as the lower temporal quadrant<sup>8</sup>.



Main criteria of a glaucomatous disease in OCT



Retinal nerve fibres  
- Average RNFL thickness.

Optic nerve  
- Vertical thickness of the neuroretinal rim,  
- Overall surface of the neuroretinal rim.

- Vertical C/D ratio.

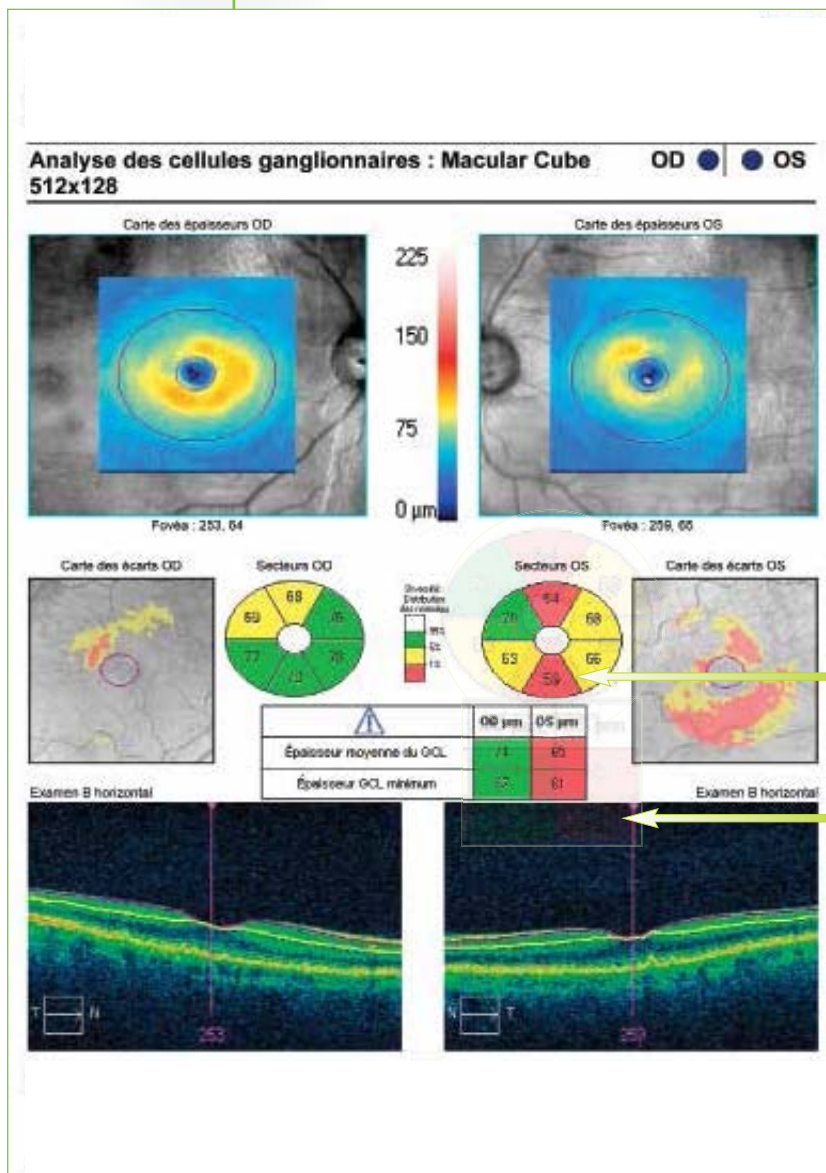
Retinal nerve fibres  
- RNFL thickness in the lower quadrant.

Retinal nerve fibres  
- RNFL thickness in the lower temporal zone.

## Complex of macular ganglion cells

The study of macular ganglion cells is more recent because it is only available in "Spectral Domain" OCT. The parameters most suggestive of early glaucoma are the average minimum thickness and the lower temporal thickness.

The macula is divided into 360 sectors each one degree wide. The average minimum thickness is that of the thinnest sector (Minimum GCL thickness).



*First elements changed in glaucoma*  
- Lower temporal thickness

*First elements changed in glaucoma*  
- Average minimum thickness

## Optic nerve or retinal nerve fibres: which should be examined first in glaucoma?

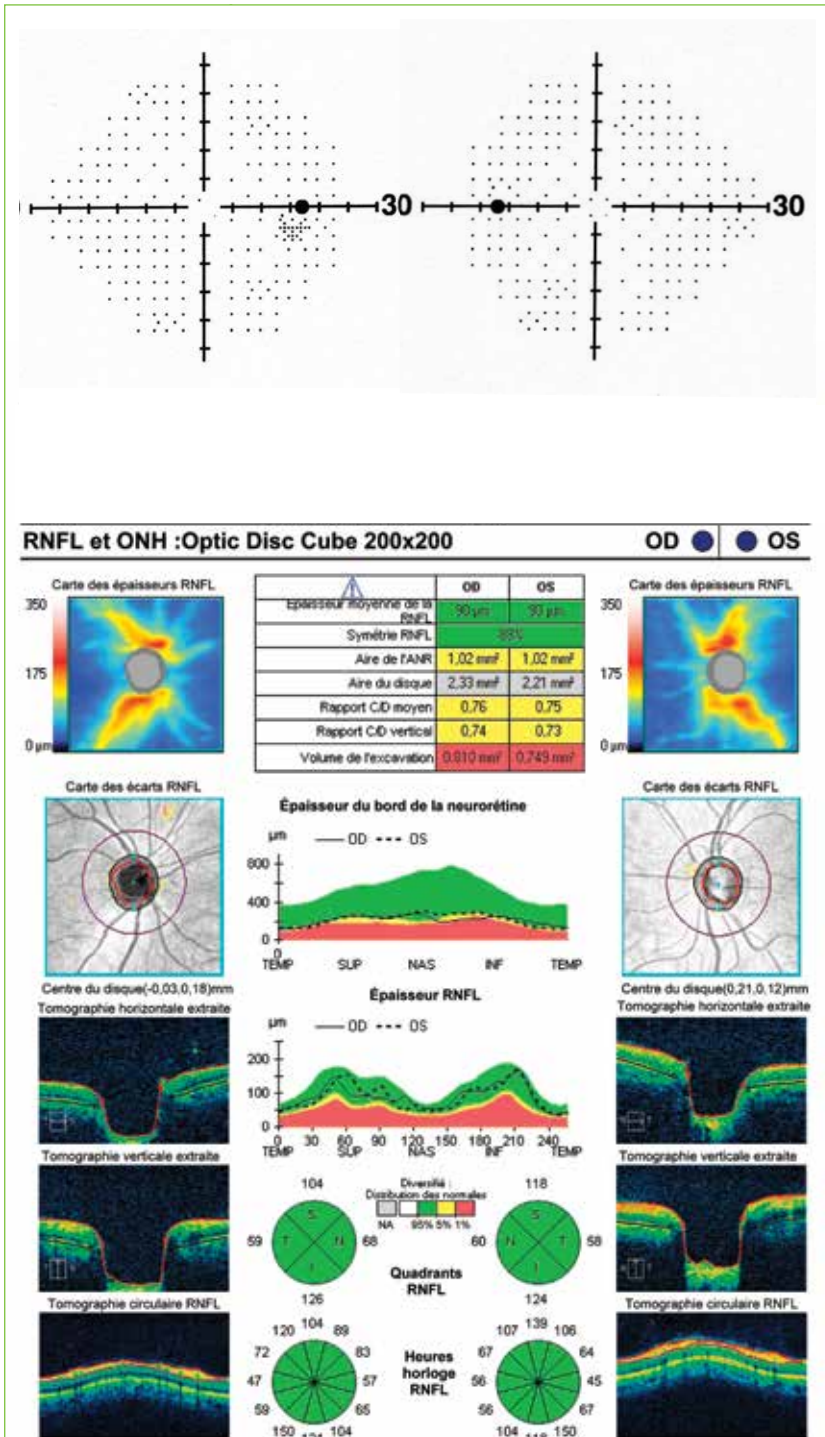
The information provided by OCT is diverse and raises the question of what parameters are most reliable for early detection of glaucoma and, in particular, whether it is better to analyse the optic nerve head or the parapapillary ganglion fibres. In fact, we can imagine that, when there is a large number of optical fibres, it is easy to analyse them and, when this thickness tends to reduce, the posterior edge of this layer is more difficult to differentiate from adjacent structures and therefore gives more variable measurements. By contrast, it would be easier to determine the parameters of the optic nerve, since only the vitreous body is facing these fibres and the determination of the optic nerve head by analysis of the end of Bruch's membrane is performed well by OCT.

However, the appearance of the optic nerve itself varies greatly from one person to another, and statistical comparisons are difficult. This is particularly the case when the optic nerve is irregular (myopia, dysversion, etc.).

In general, it is easier to detect preperimetric glaucoma in the retinal nerve fibres (RNFL). More rarely, analysis of the optic nerve is preferred. In some patients, analysis of the macular ganglion fibres would be as good as analysis of the RNFL layer 9.

### What about a case of isolated impairment of the optic nerve?

Generally, the analysis of the optic nerve in OCT is more subject to discussion than the analysis of optical fibres due to the diversity of appearances of the optic nerve from one person to another; this diversity is not perfectly covered by the standards databases of the devices. The result is that we sometimes find an isolated optic nerve impairment when the retinal nerve fibres appear normal, both at the parapapillary level and at the level of the macular ganglion cells when the visual field is also normal. In this situation, we must favour the analysis of optical fibres. However, it is desirable to analyse the progression of the parameters of the optic nerve since the comparison is then done on the patient himself.

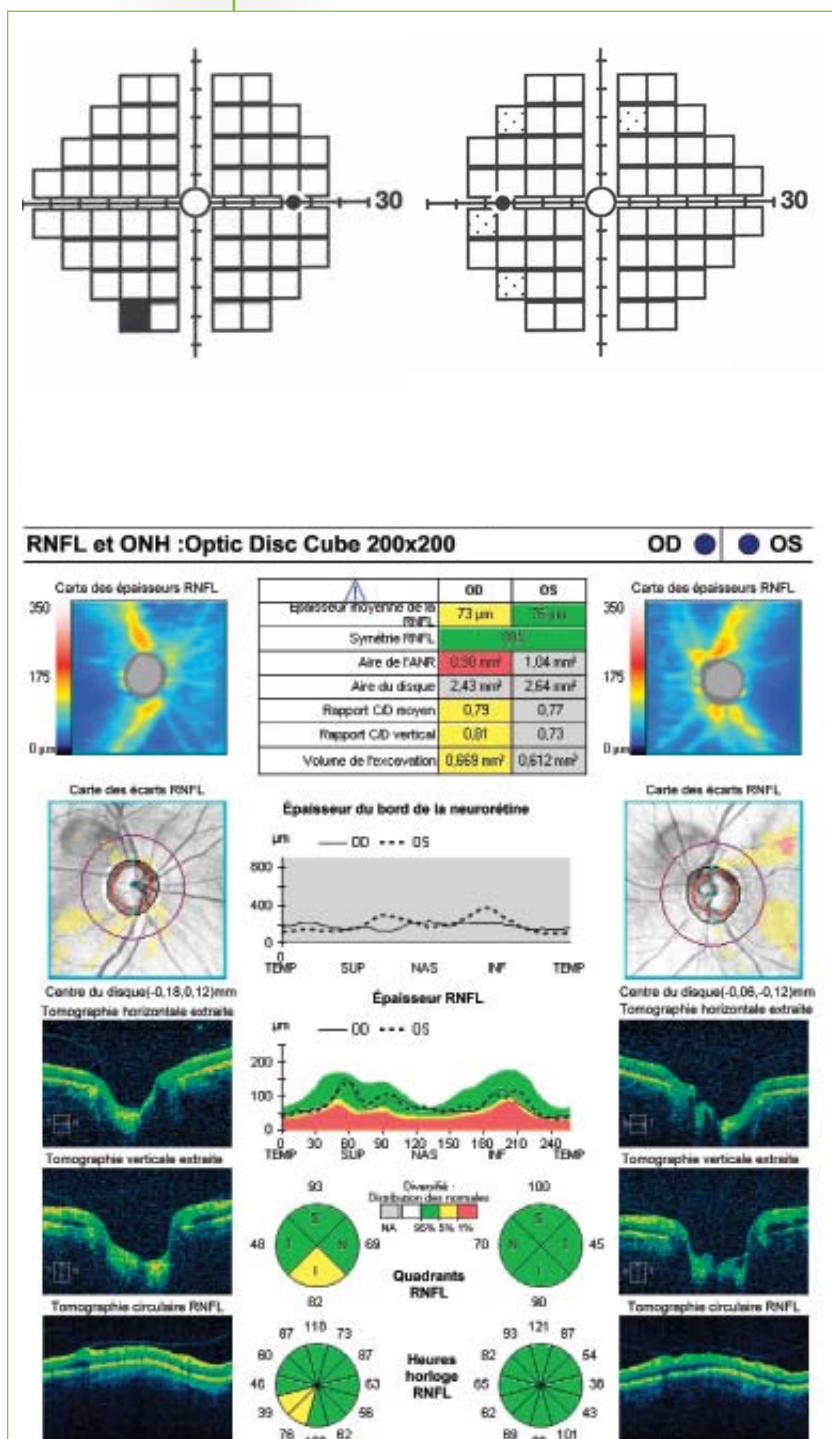


Patient with an appearance suggesting a physiological cavity. The entire results are normal, apart from an abnormal cavity volume for each eye. Glaucoma is not established. Simple monitoring should be proposed.

# Preperimetric glaucoma

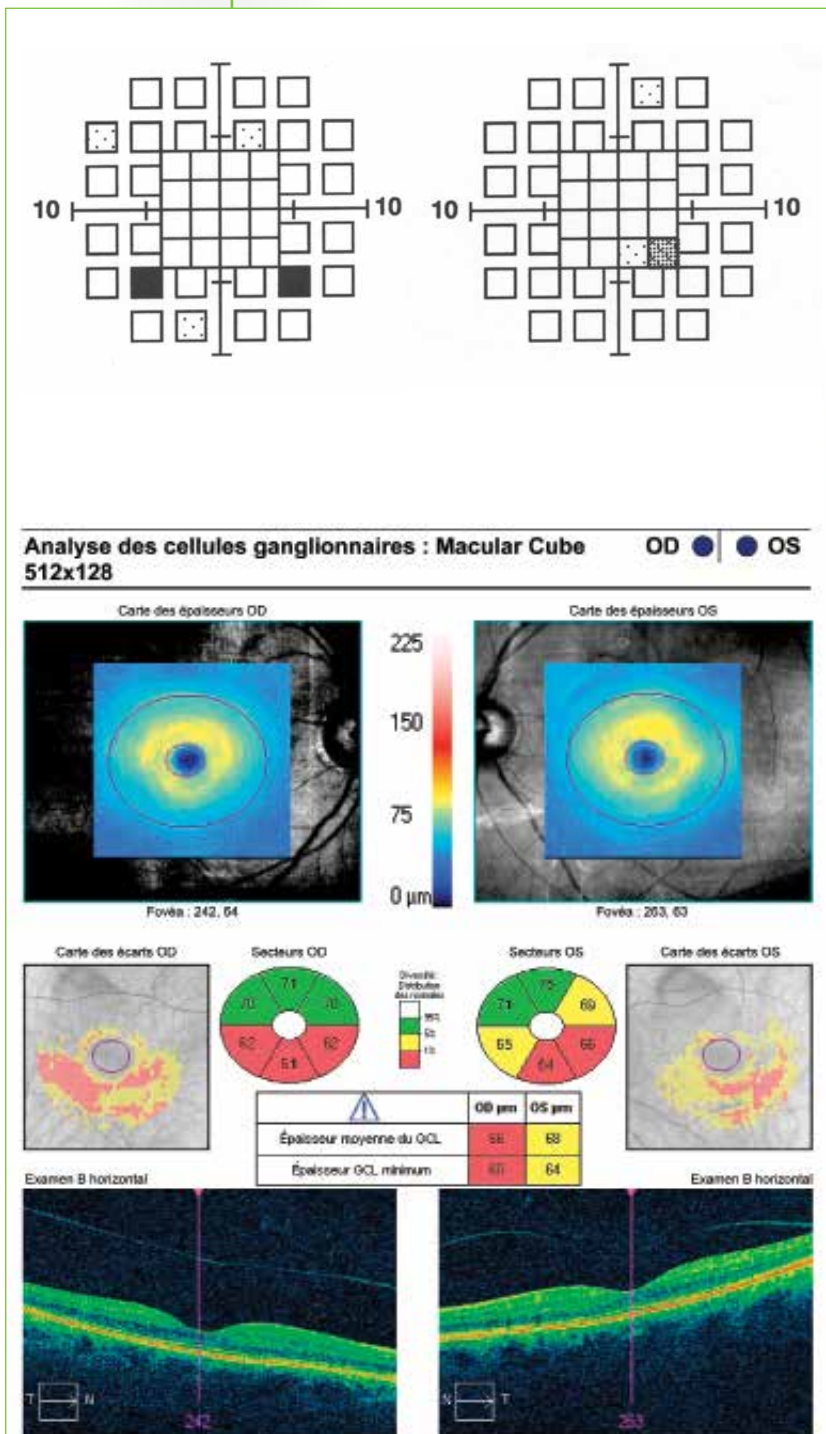
In general, the term “preperimetric glaucoma” is used for a glaucoma that is detected by an impairment of the structure or by an alteration of the early detection tests in the visual field, such as the blue-yellow visual field or the FDT Matrix, while the conventional visual field, i.e. the Humphrey-type automated perimetry or Octopus is normal.

## Preperimetric glaucoma: isolated impairment in OCT



60-year-old patient with hypertension at 23 mmHg. The FDT Matrix and OCT of the optic nerve are at the limit of normal.

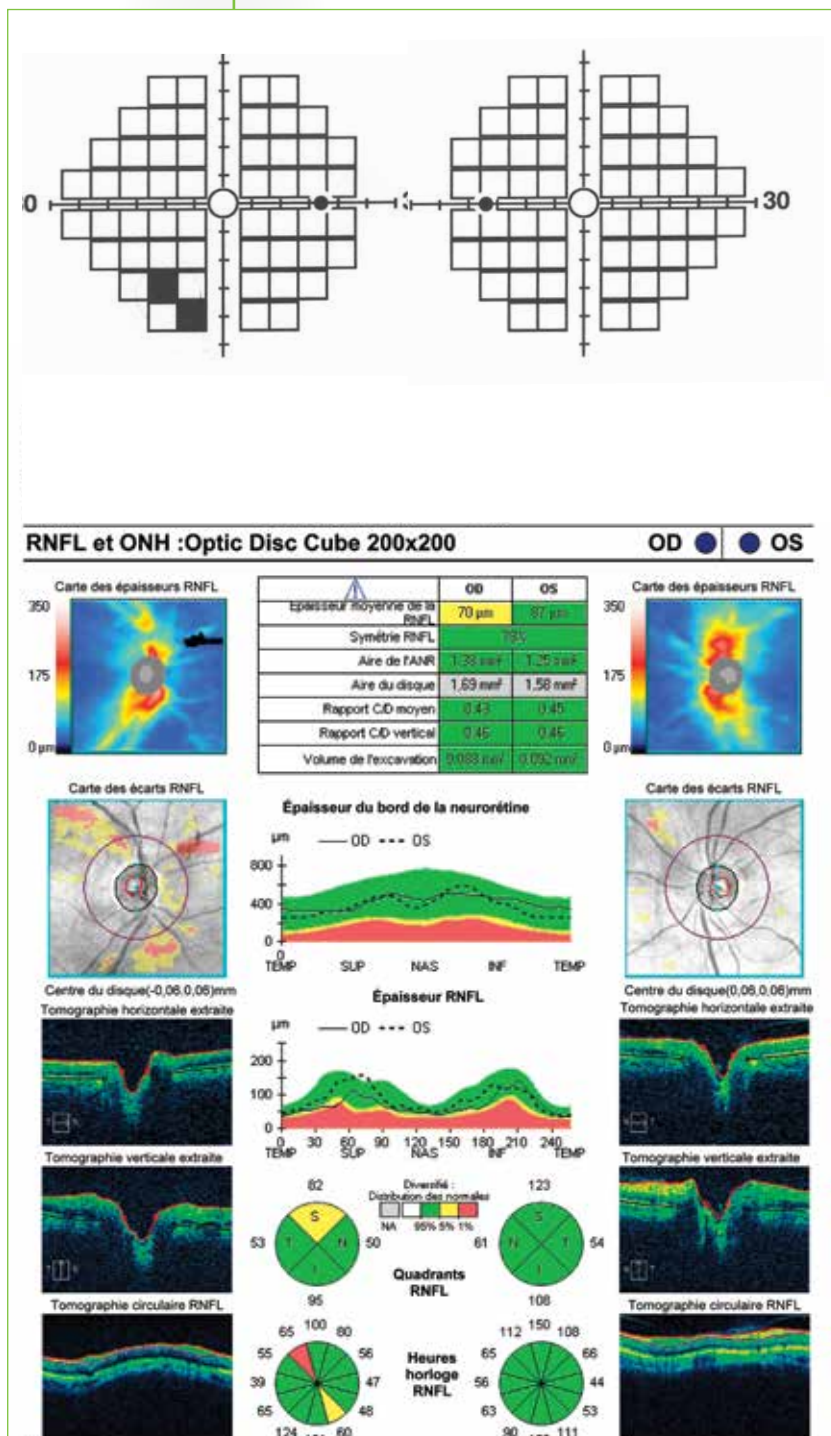
The OCT can be the only modified examination in preperimetric glaucoma. In general, in this situation, simple monitoring is sufficient, but treatment is a viable alternative, especially if the deficit in the OCT is large.



Same patient as on the previous page. The macular OCT shows a clear and well systematised impairment in the right eye. The 10° Matrix test is irregular.

## Preperimetric glaucoma: impairment of the RNFL layer and the FDT Matrix visual field

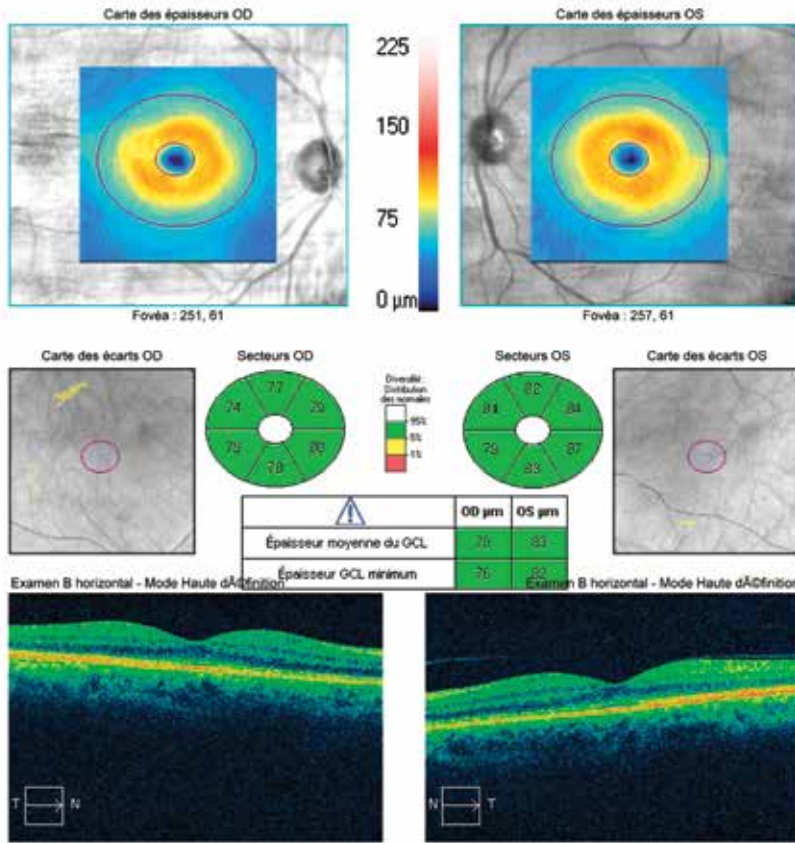
The start of impairment of the visual field by FDT Matrix and OCT corresponds to the beginning of glaucoma, especially if the deficits are consistent. These deficits may precede the appearance of a conventional perimetry deficit by 5 years.



74-year-old patient, ocular hypertension at 24 mmHg. Normal optic nerve. The OCT and FDT Matrix show matching impairment of the right eye.



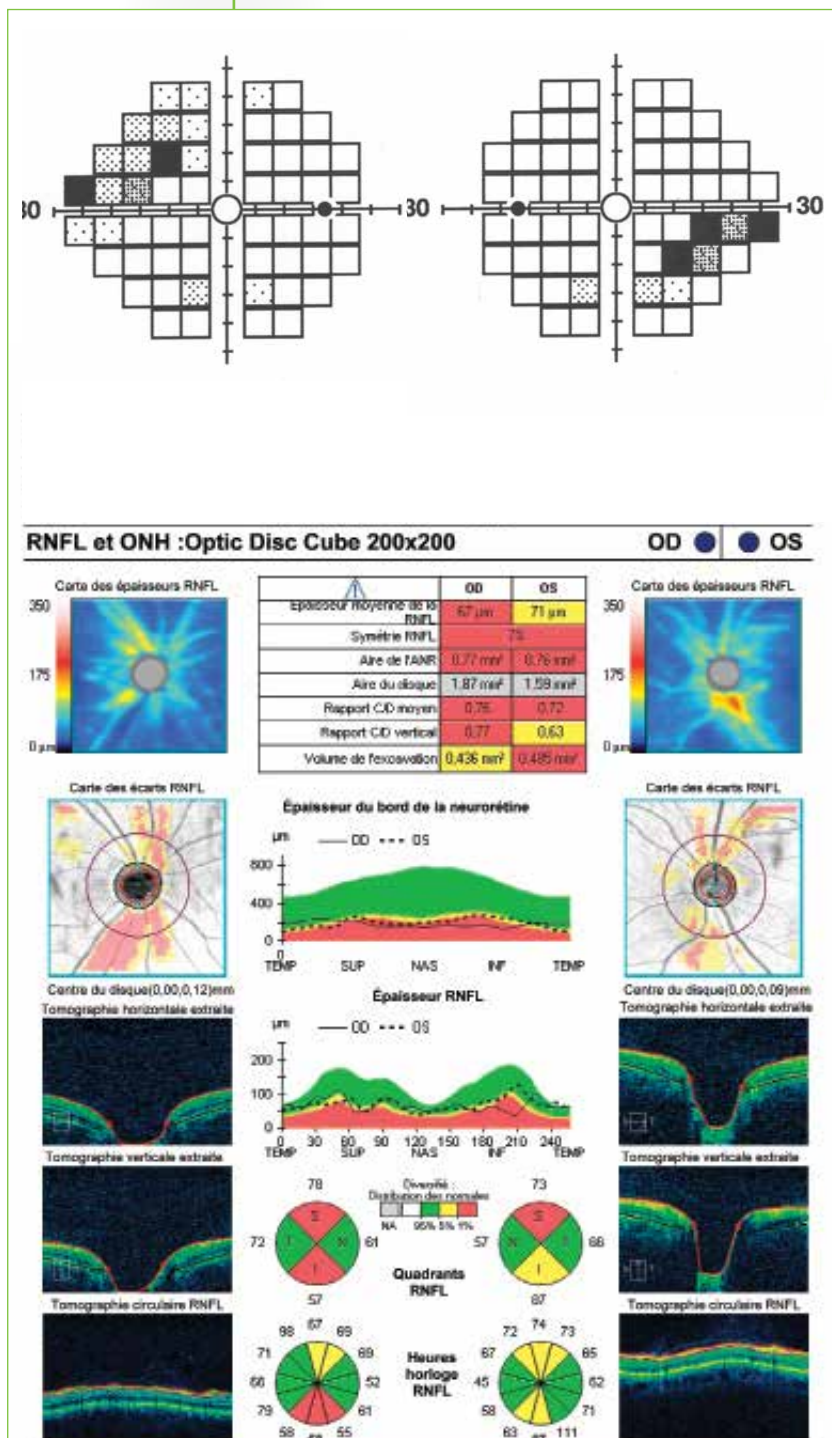
Analyse des cellules ganglionnaires : Macular Cube 512x128 OD ● | ● OS



Same patient as on the previous page. There is no central impairment.

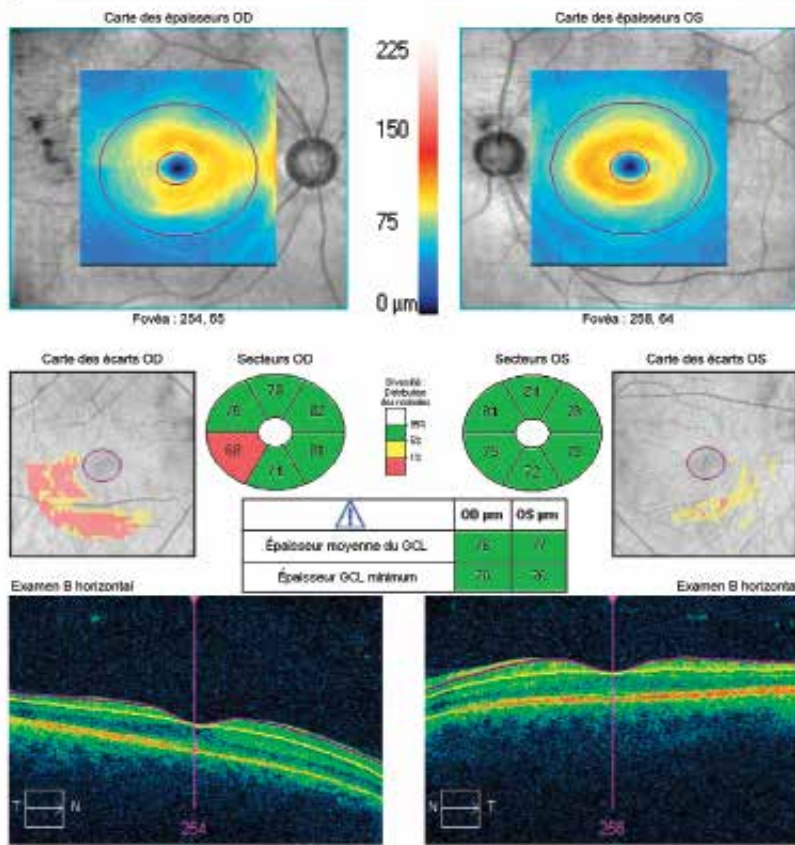
## Preperimetric glaucoma: impairment of the RNFL layer, the macula and the FDT Matrix visual field

There is often an impairment of both the RNFL layer and the macular ganglion cell complex in OCT. If the deficit is more present in the parapapillary region, we can assume that hypertension likely plays a major role. Otherwise, we will consider more vascular problems.



55-year-old patient with ocular hypertension at 26 mmHg. The automated perimetry is normal, but the Matrix shows a bilateral alteration. The OCT confirms the impairment, both in the optic nerve and the RNFL layer.

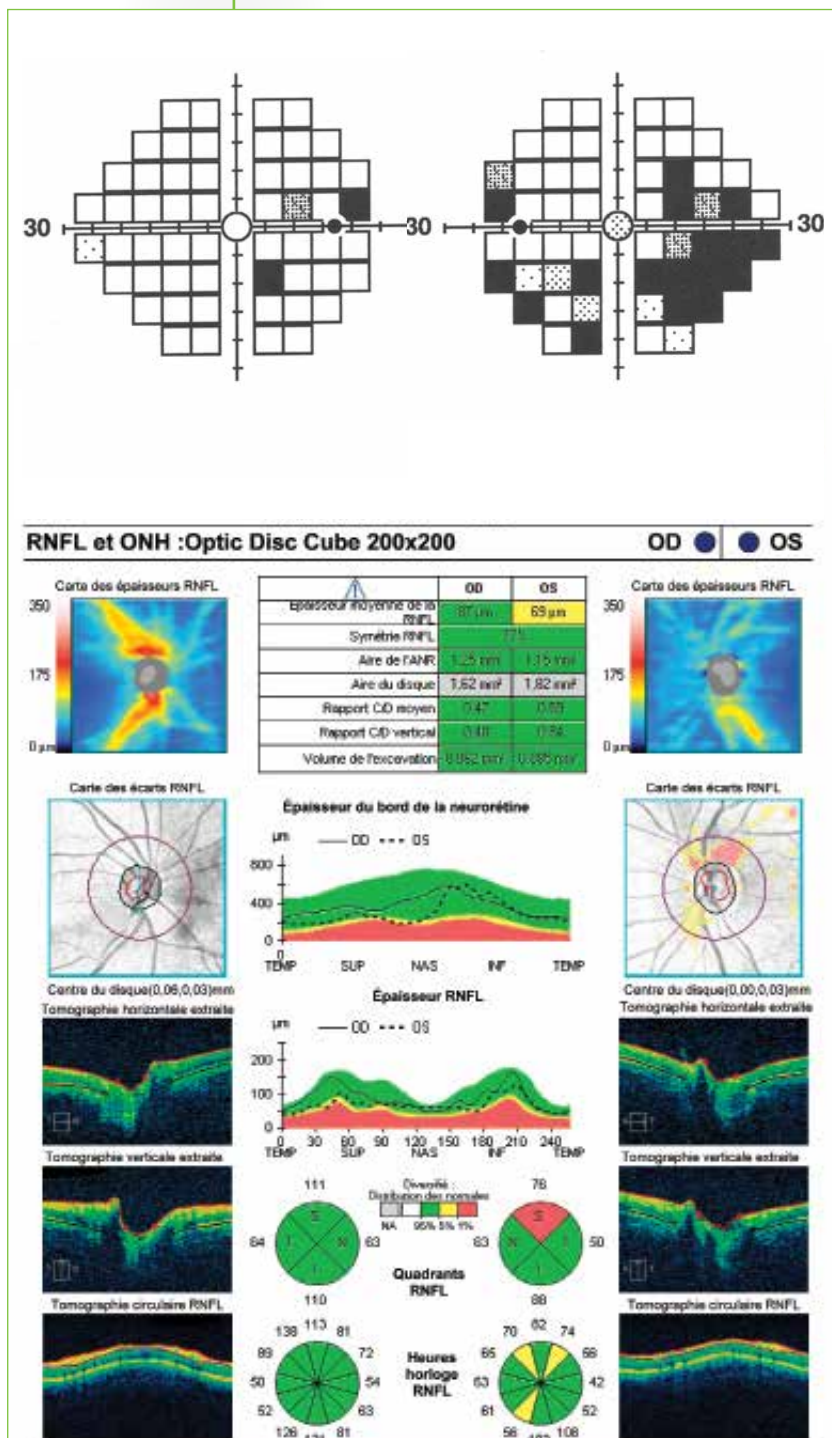
Analyse des cellules ganglionnaires : Macular Cube 512x128 OD ● | ● OS



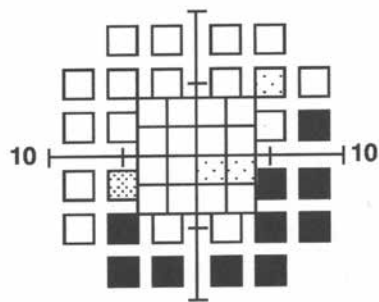
Same patient as the previous page. There is little macular impairment at the right and a normal result on the left. This profile seems to suggest early hypertension glaucoma.

## Preperimetric glaucoma: impairment of the FDT Matrix, OCT at the limit of normal

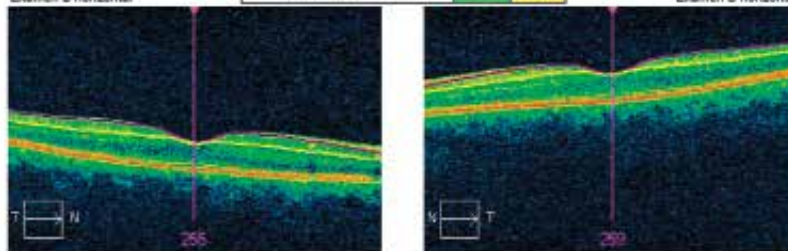
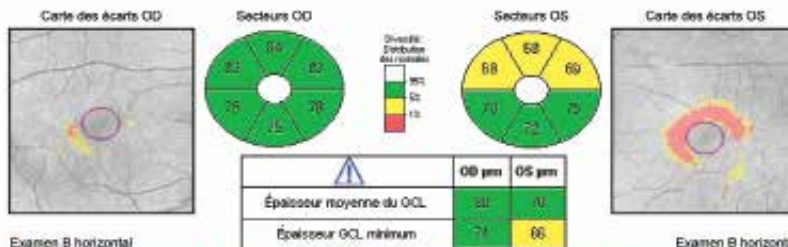
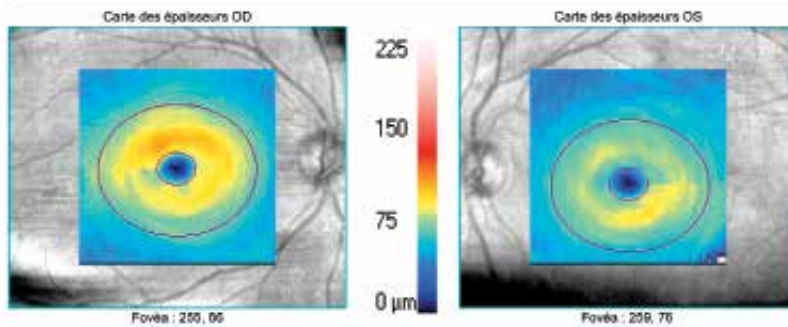
It is rare to note a normal OCT in a patient who already has perimetric impairment. However, such cases can hypothetically occur in glaucoma. However, it should then suggest a more central impairment and lead to the performance of other tests with less doubt.



60-year-old patient with ocular hypertension at 24 mmHg. The Matrix visual field shows a marked impairment on the left, while the OCT is only slightly impaired.



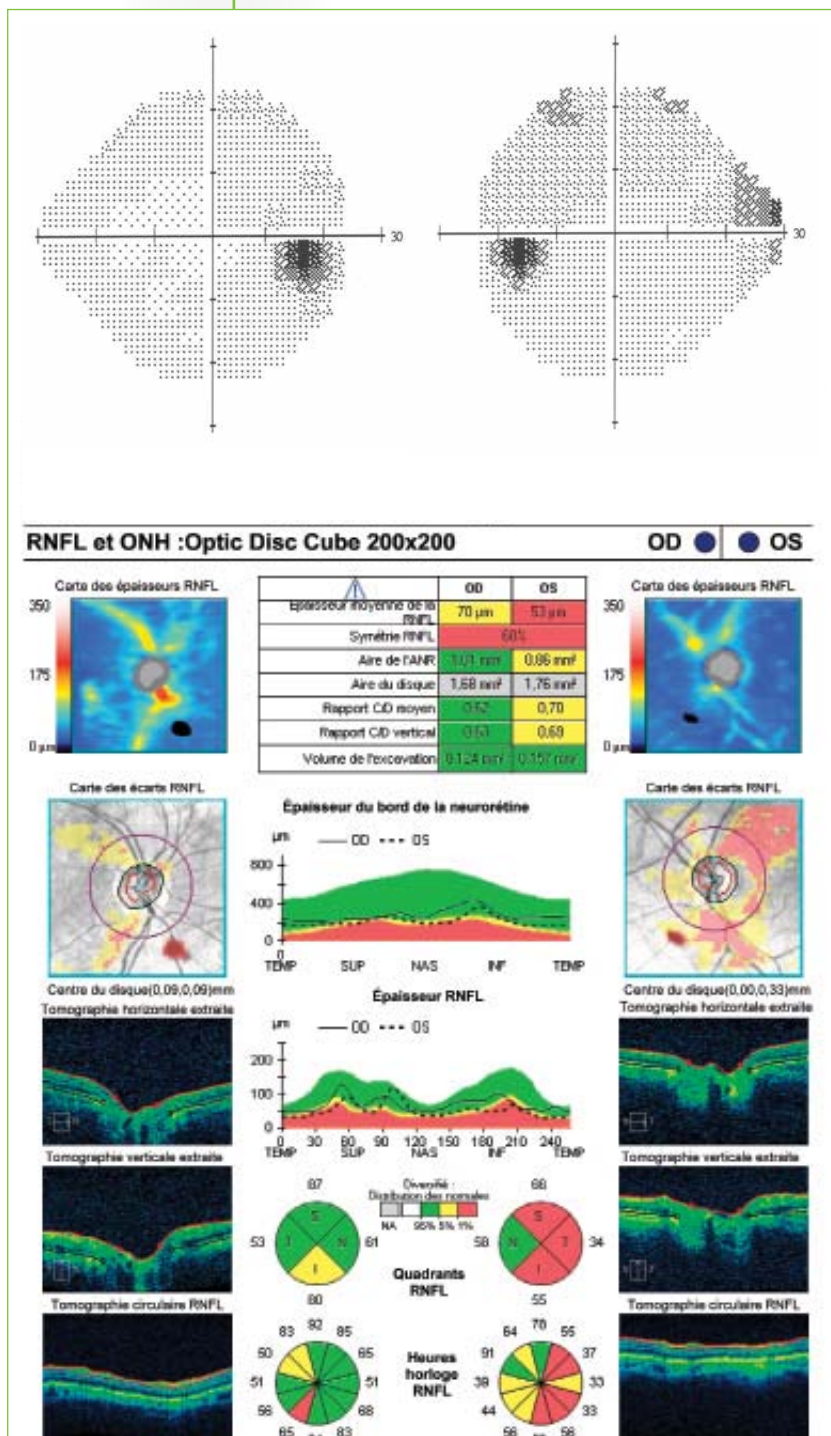
Analyse des cellules ganglionnaires : Macular Cube 512x128 OD OS



Same patient as on the previous page. OCT and central 10° visual fields. The macular ganglion cell complex is normal on the right and at the limit of normal on the left, while the Matrix 10° central test is pathological.

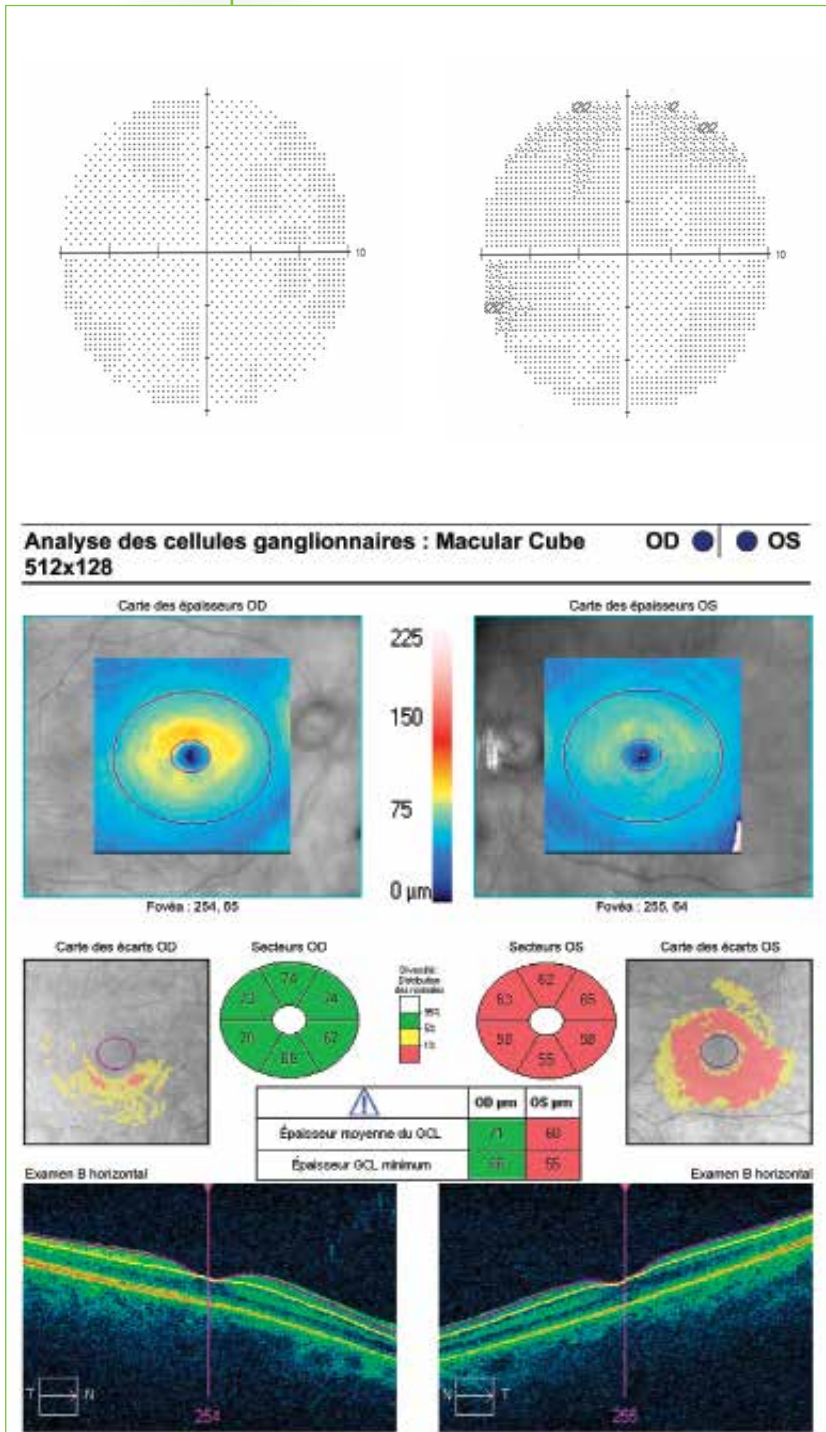
## Early open-angle glaucoma: location of the matching impairment between the OCT and the visual field

The OCT is often consistent with the visual field in early and moderate glaucomas, except in young patients where the OCT impairment is greater than the impairment of the visual field.



79-year-old patient with ocular tonus at 22mmHg at the right and 26 mmHg at the left. At the right, the visual field is normal and the OCT shows a lower temporal deficit typical of early glaucoma. On the left, the impairment is more marked and extensive.

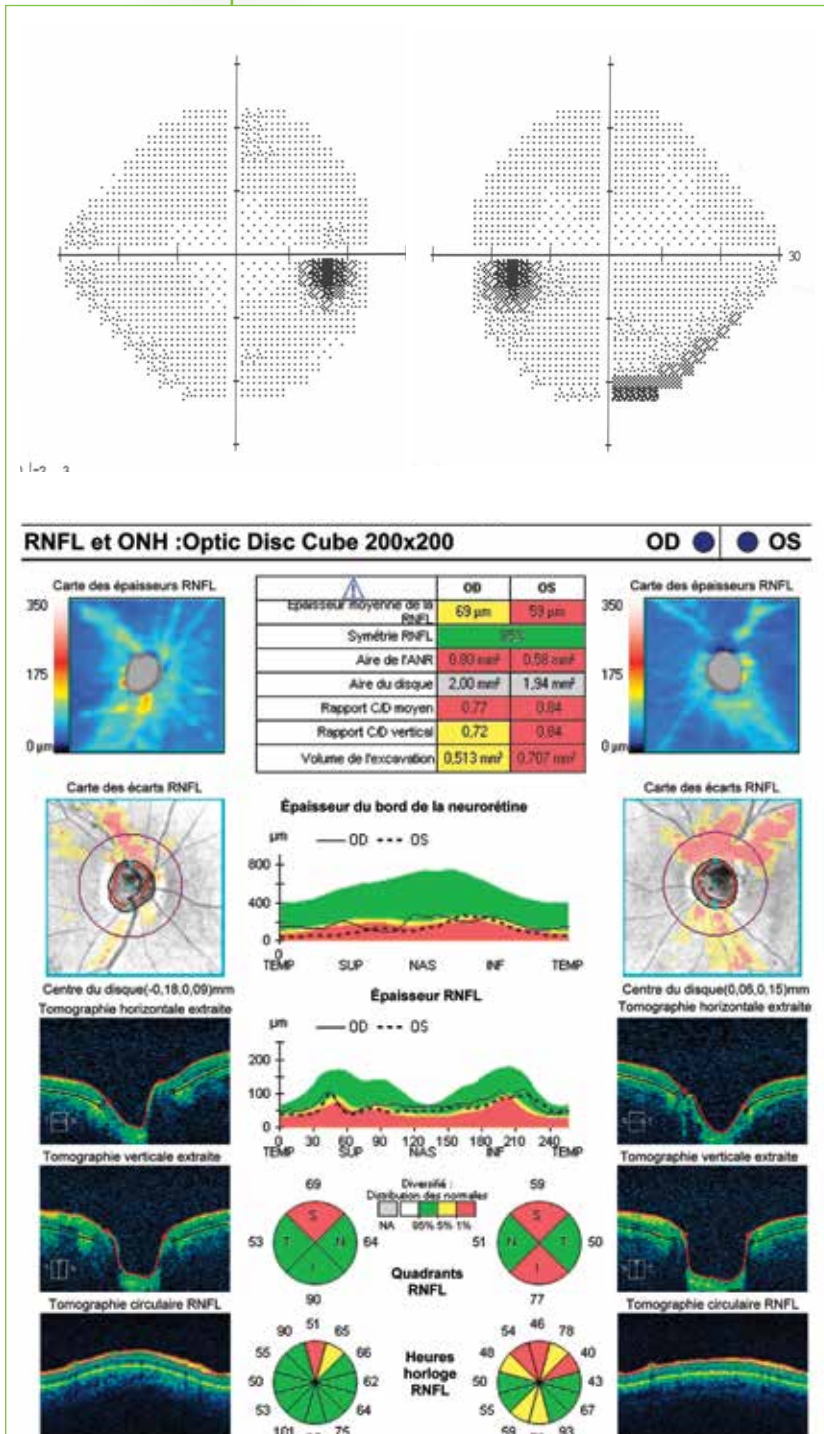
In OCT, a more significant impairment in the macular region than the peripapillary region is not a severity factor if the deficit remains moderate.



Same patient as on the previous page. OCT and central visual fields of 10°. Impairment of the macular region of the left eye is observed. The average and minimum thickness parameters are abnormal. The central visual fields of 10° are normal.

## Early open-angle glaucoma: depth of the impairment matches between the OCT and the visual field

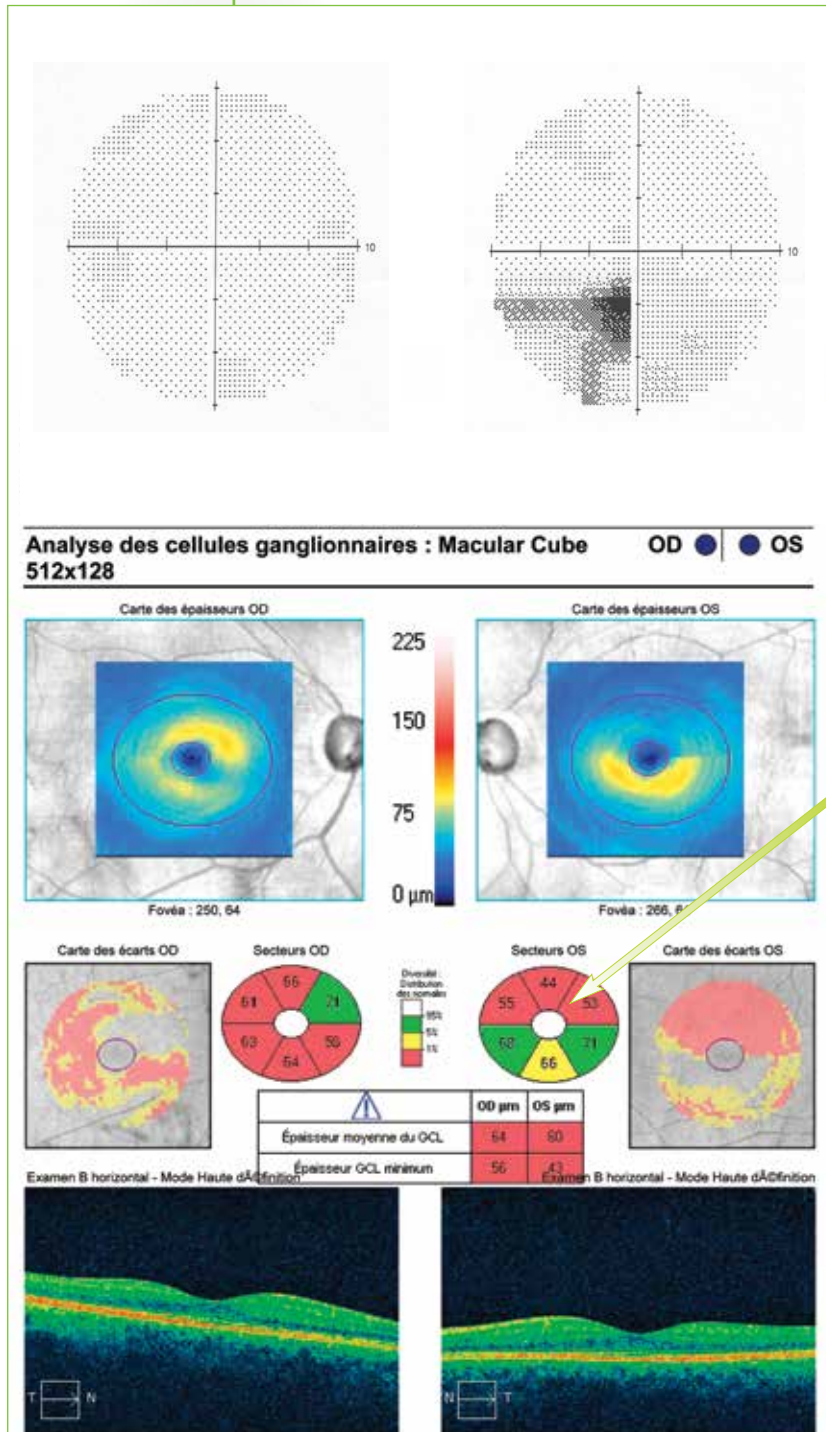
The impact on the visual field of a reduction in the thickness of the fibres depends on the severity of the impairment. It is therefore necessary to analyse the thickness precisely in the different sectors.



70-year-old patient affected by open-angle glaucoma since the age of 8. The impairment is almost concordant between the visual field and the OCT, with more marked changes on the left both at the level of the retinal nerve fibre and the level of the cavity.



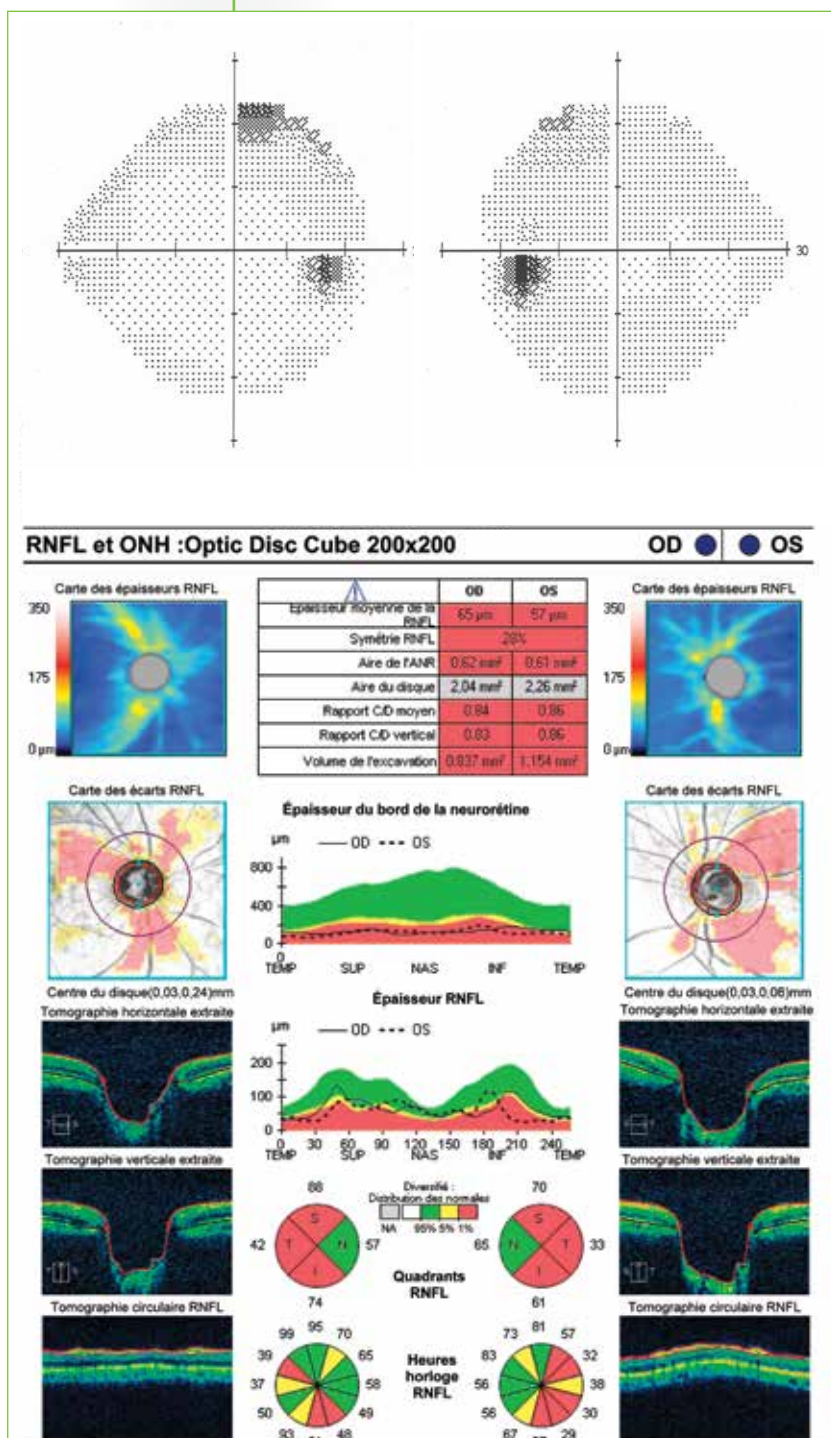
This may explain why an impairment may not be noticeable in the visual field in the central region if the most deficient point remains relatively normal. For this reason, the minimum thickness is presented in the macular OCT, in addition to the average thickness.



Same patient as on the previous page. OCT and central visual fields of 10°. Significant macular impairment of both sides, without notable impact on the right visual field. This is due to the fact that, in the corresponding zone, the macular ganglion complex retains a high thickness of more than 60  $\mu\text{m}$ . On the left, the thickness in the upper sector is reduced to 44  $\mu\text{m}$  and causes a deep lower paracentral scotoma.

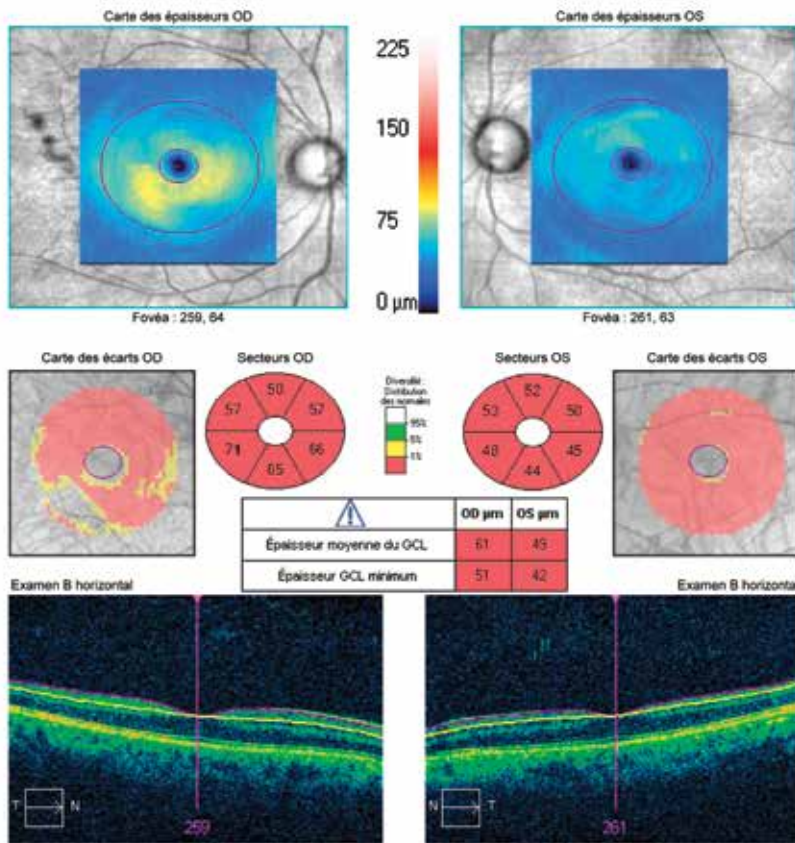
## Early open-angle glaucoma : OCT predominant impairment

The younger the patient, the more the OCT is disrupted before the visual field shows any changes. This is due to the redundancy of receptor fields in the ganglion cells. For each region of the visual field, several ganglion cells are present and process the same zone. This phenomenon decreases with age.



31-year-old patient affected by open-angle glaucoma since the age of 4. Significant and almost isolated impairment of the OCT. All parameters for the optic nerve are abnormal, as well as most of the elements regarding the retinal nerve fibre layer.

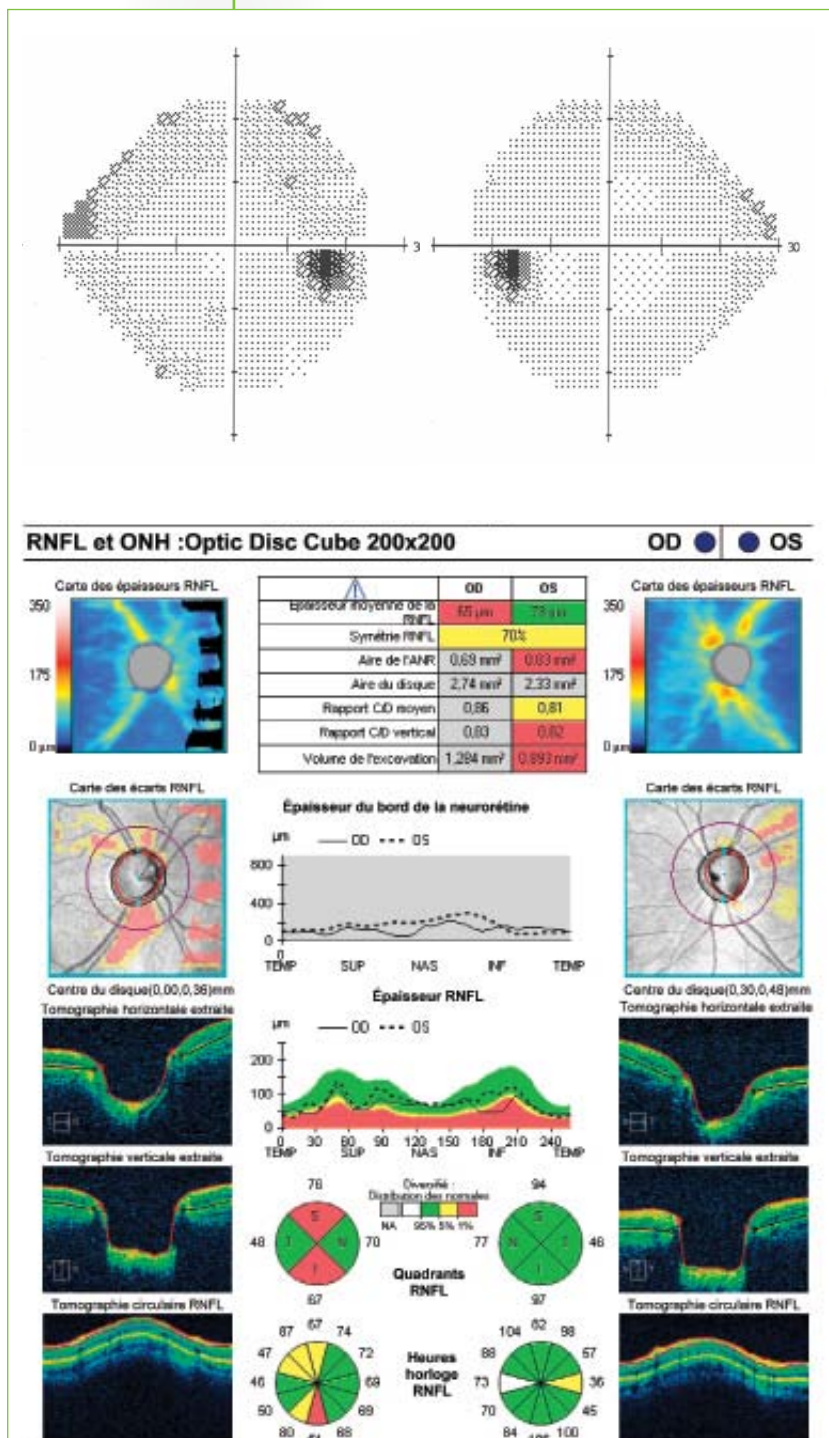
Analyse des cellules ganglionnaires : Macular Cube 512x128 OD ● | ● OS



Same patient as on the previous page. Significant macular impairment without loss of visual acuity or central visual field.

## Early open-angle glaucoma: primary impairment of the optic nerve without impairment of the optical fibres

The absence of impairment of the RNFL layer does not allow glaucoma to be ruled out. If there is a cavity noted clinically or in the OCT and it is associated with a small impairment of the visual field, you should hold back on diagnosing glaucoma proper.

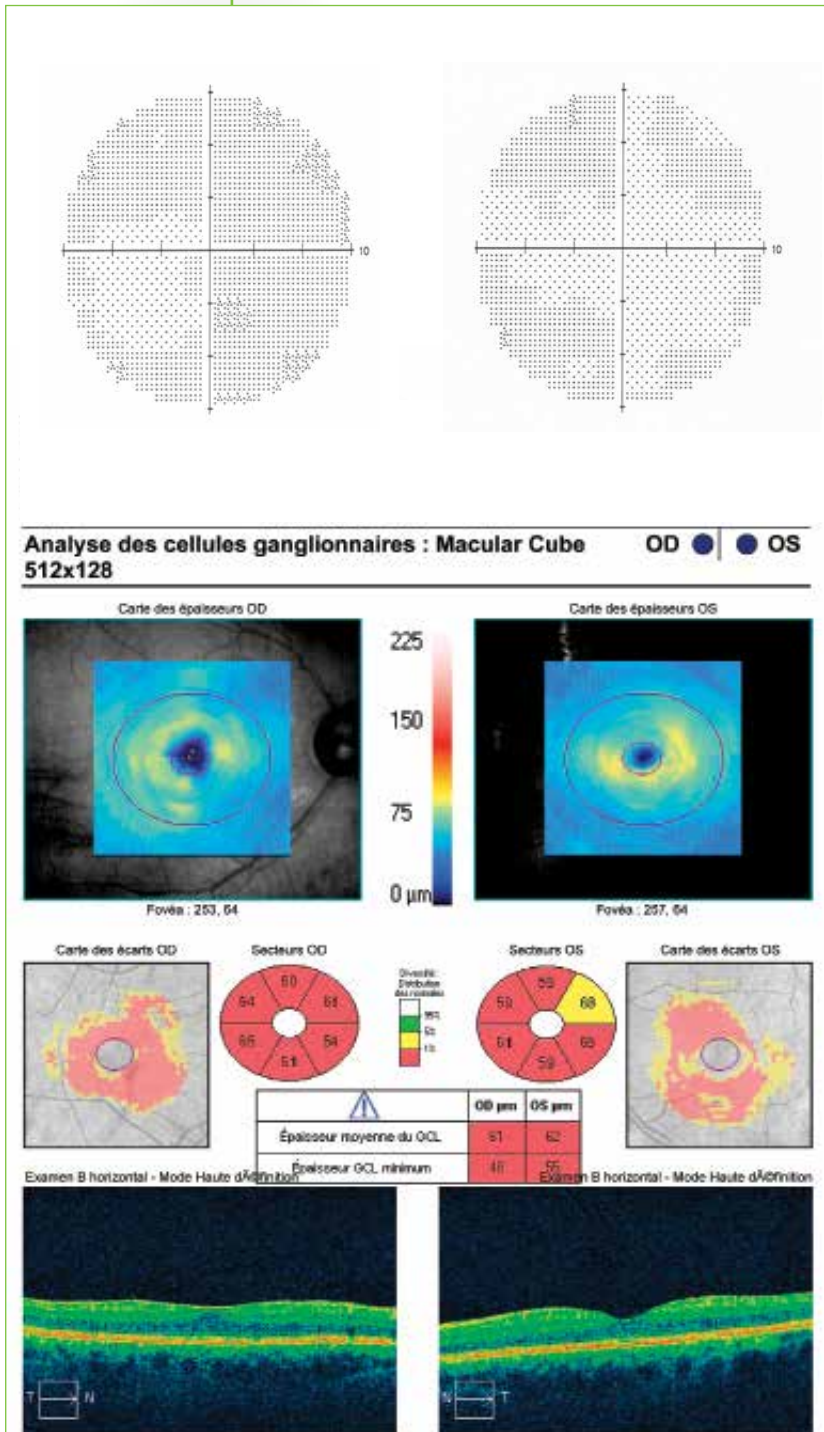


68-year-old patient with ocular hypertension.

On the right, the diagnosis of glaucoma is in no doubt, both at the level of the RNFL layer and in the macular region.

On the left, we note that the retinal nerve fibre layer (RNFL) is not affected but the OCT parameters of the optical nerve are abnormal. The glaucoma is indeed bilateral. The slightly abnormal visual fields support the diagnosis.

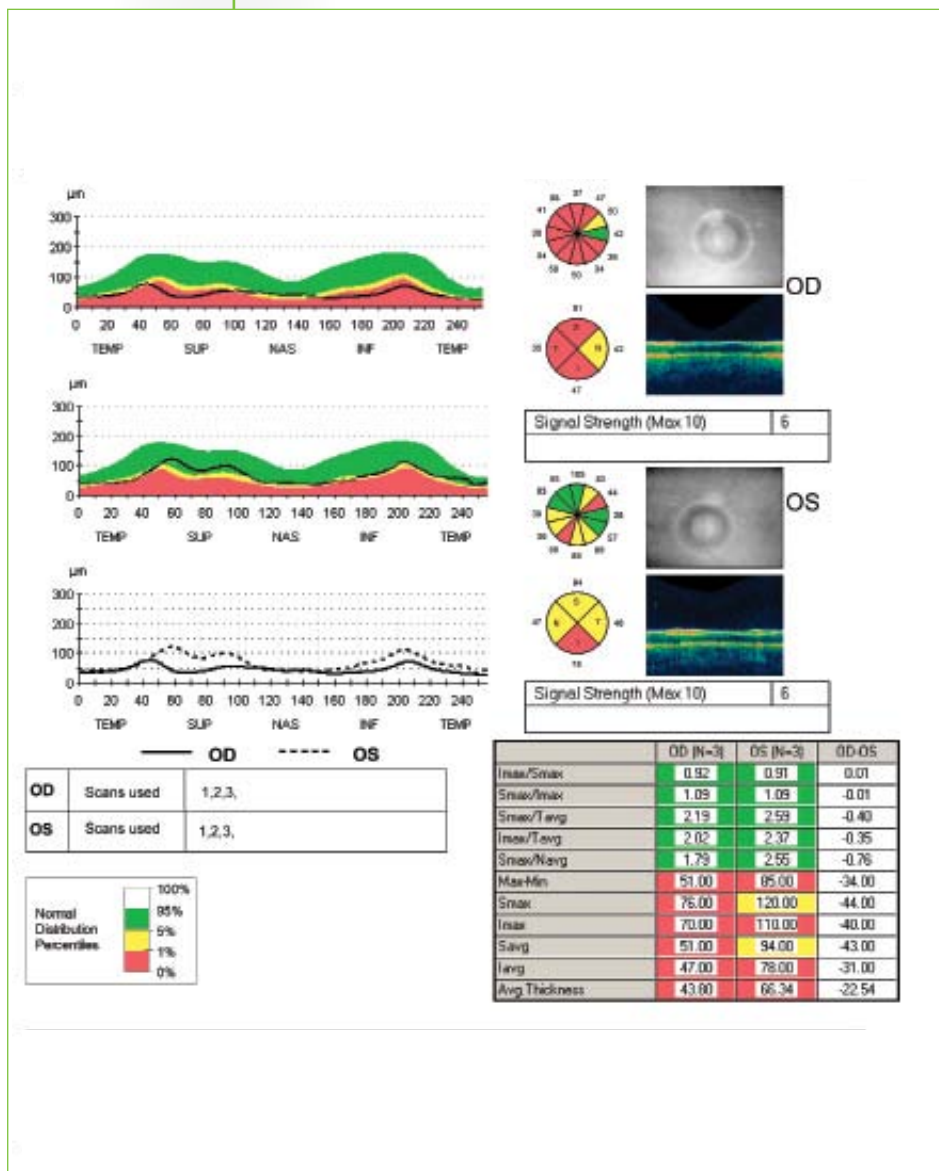
When the RNFL layer is normal, the analysis of the macular ganglion cells allows us to differentiate isolated hypertension and early impairment of optical fibres.



Same patient. OCT and central visual fields of 10°. Bilateral impairment of the macular ganglion cell layer. The central visual field is normal.

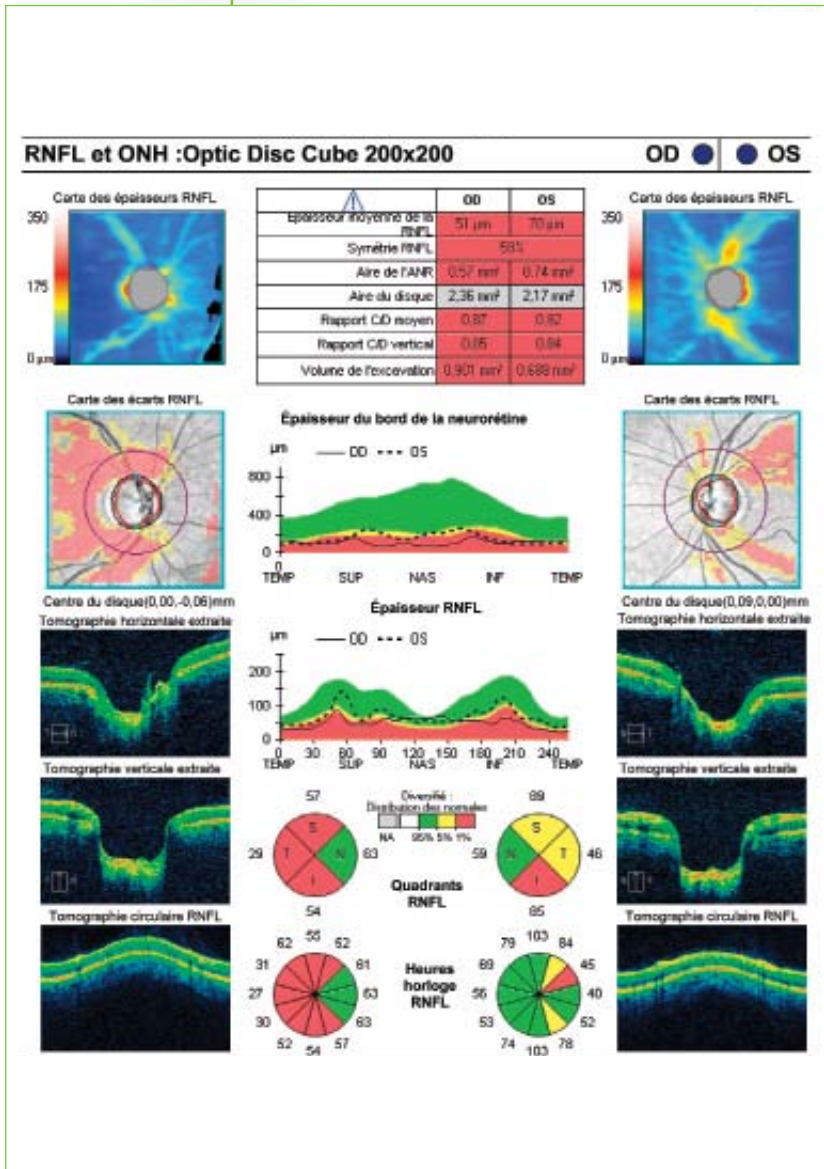
## Glaucoma with incipient open angle: comparison between OCT “Time Domain” and “Spectral Domain”

Comparison of OCT Time Domain (Stratus OCT, Carl Zeiss) and Spectral Domain (Cirrus™ HD-OCT, Carl Zeiss) shows that these two methods have the same detection capacity as regards incipient glaucoma. The main difference resides in the fact that Spectral Domain OCT is more reproducible and therefore allows better monitoring than Time Domain<sup>10</sup>.



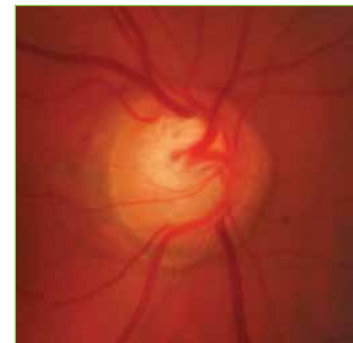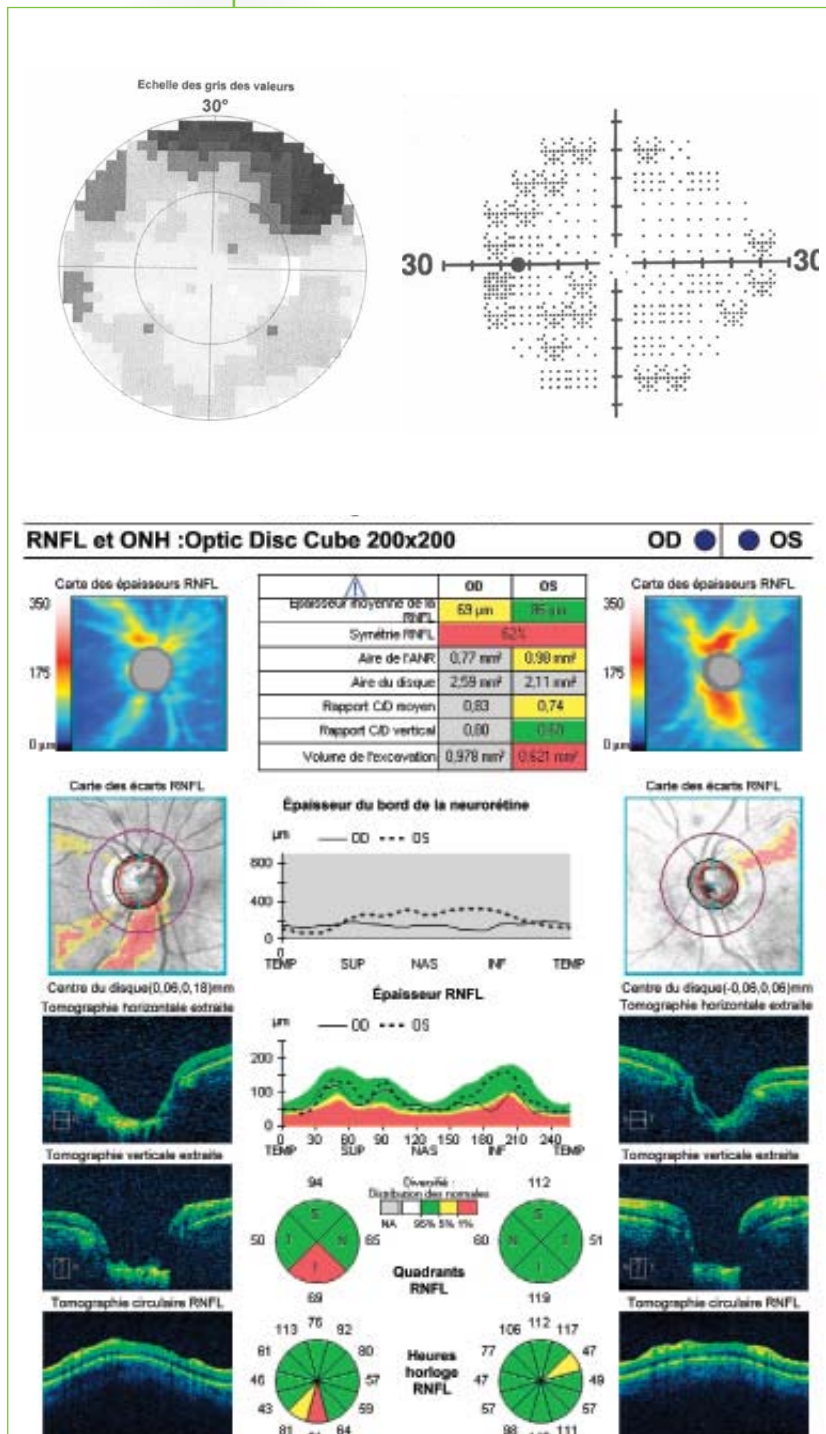
Glaucoma. OCT Time Domain

The results obtained through Time Domain and Spectral Domain OCT are not identical. In severe glaucoma in particular, we note a 10 to 20% variation in the results. The “colour codes” of Stratus OCT and Cirrus™ HD-OCT are not interchangeable. In general, the thickness of RNFL is smaller with Cirrus than with Stratus.

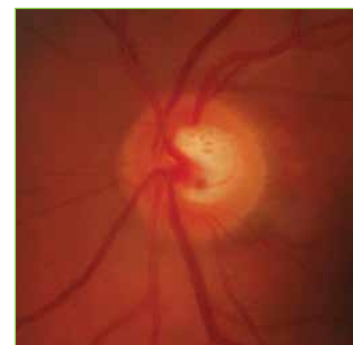

## Glaucoma with moderate open angle: concordant impairment with OCT and visual field testing

Perfect concordance between OCT and visual field testing is rare, as OCT often allows detection of slightly more serious impairment than perimetry testing.



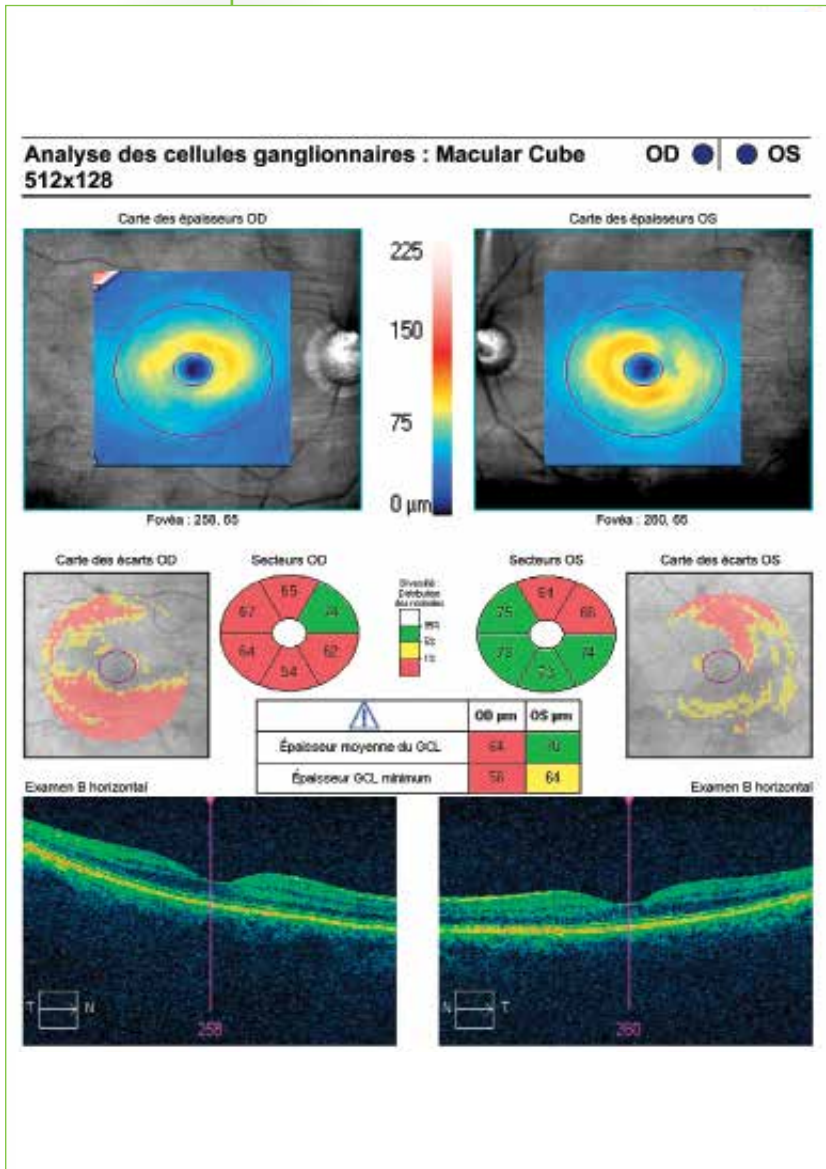
Right eye



Left eye

Moderate glaucoma on the right. Visual field testing highlights a higher deficit. The optical fibres are only affected in the lower concordant region.

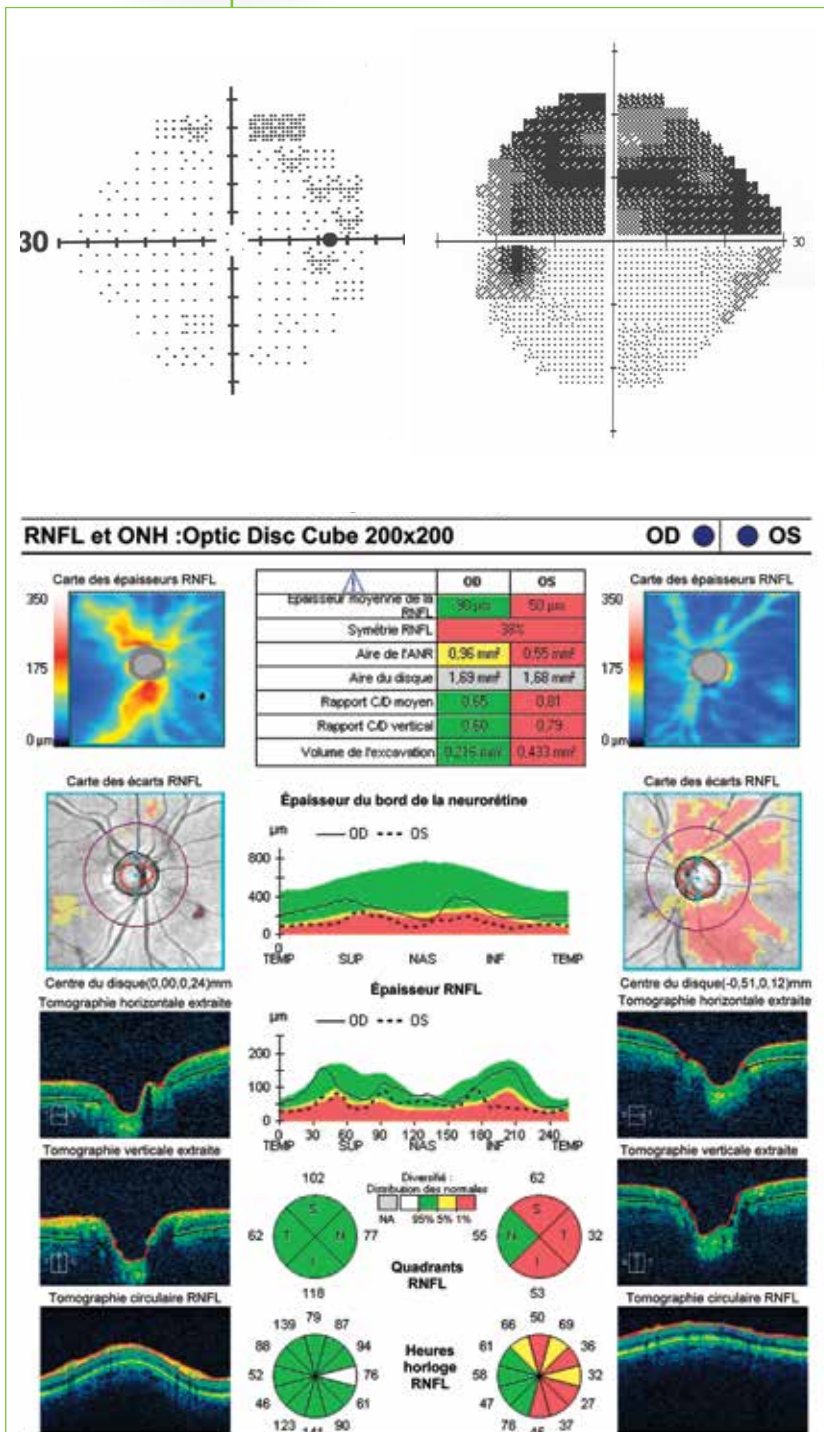




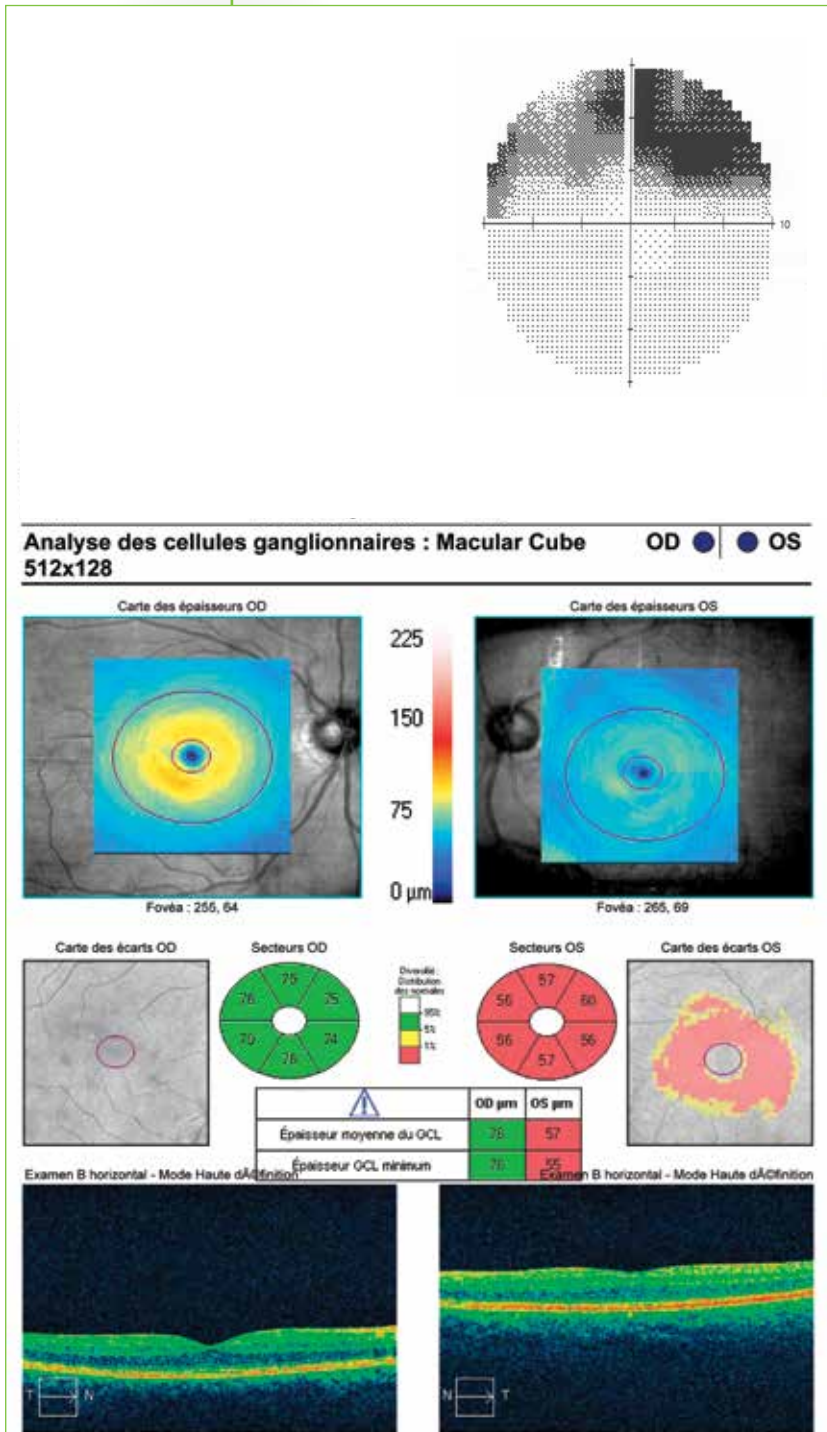
Same patient as on the previous page. The analysis of macular ganglion cells confirms this impairment, which is concordant with visual field testing, but also shows a subclinical impairment in the upper region and in the other eye.

## Glaucoma with moderate open angle: OCT predominant impairment

OCT impairment in moderate glaucoma is sometimes more important than visual field testing can predict. Thus, OCT appears to be very useful not only for confirming perimetric deficit but also for analysing other regions appearing normal in visual field testing.



*Moderate glaucoma. Visual field testing highlights an essentially higher deficit. The optical fibres are affected in the lower concordant region, but also the upper region. The right eye is normal in Matrix visual field testing and OCT.*



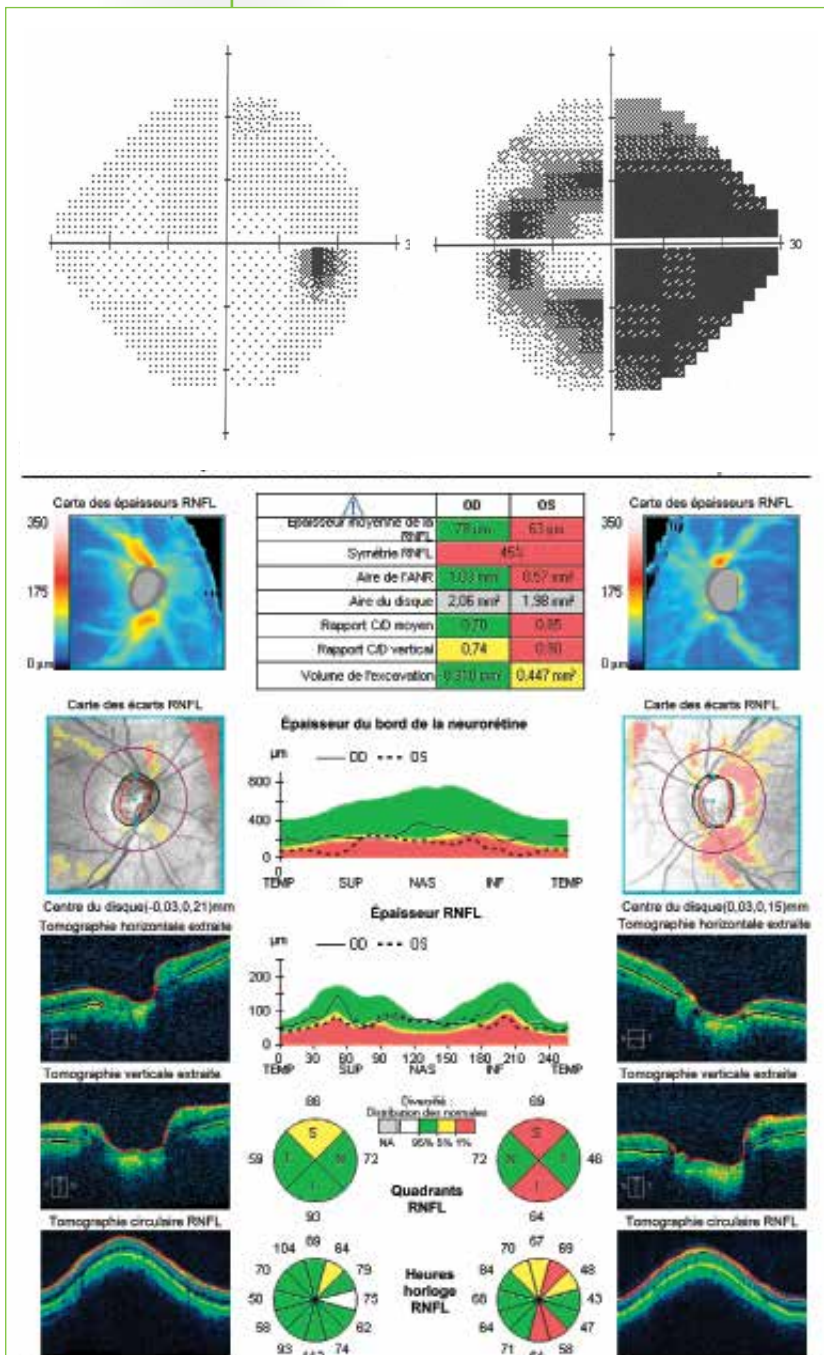
Same patient as on the previous page. OCT and central 10° visual fields. The analysis of macular ganglion cells confirms that impairment is concordant with visual field testing, but also shows subclinical impairment in the upper region. The right eye is entirely normal.

# Glaucoma with advanced open angle

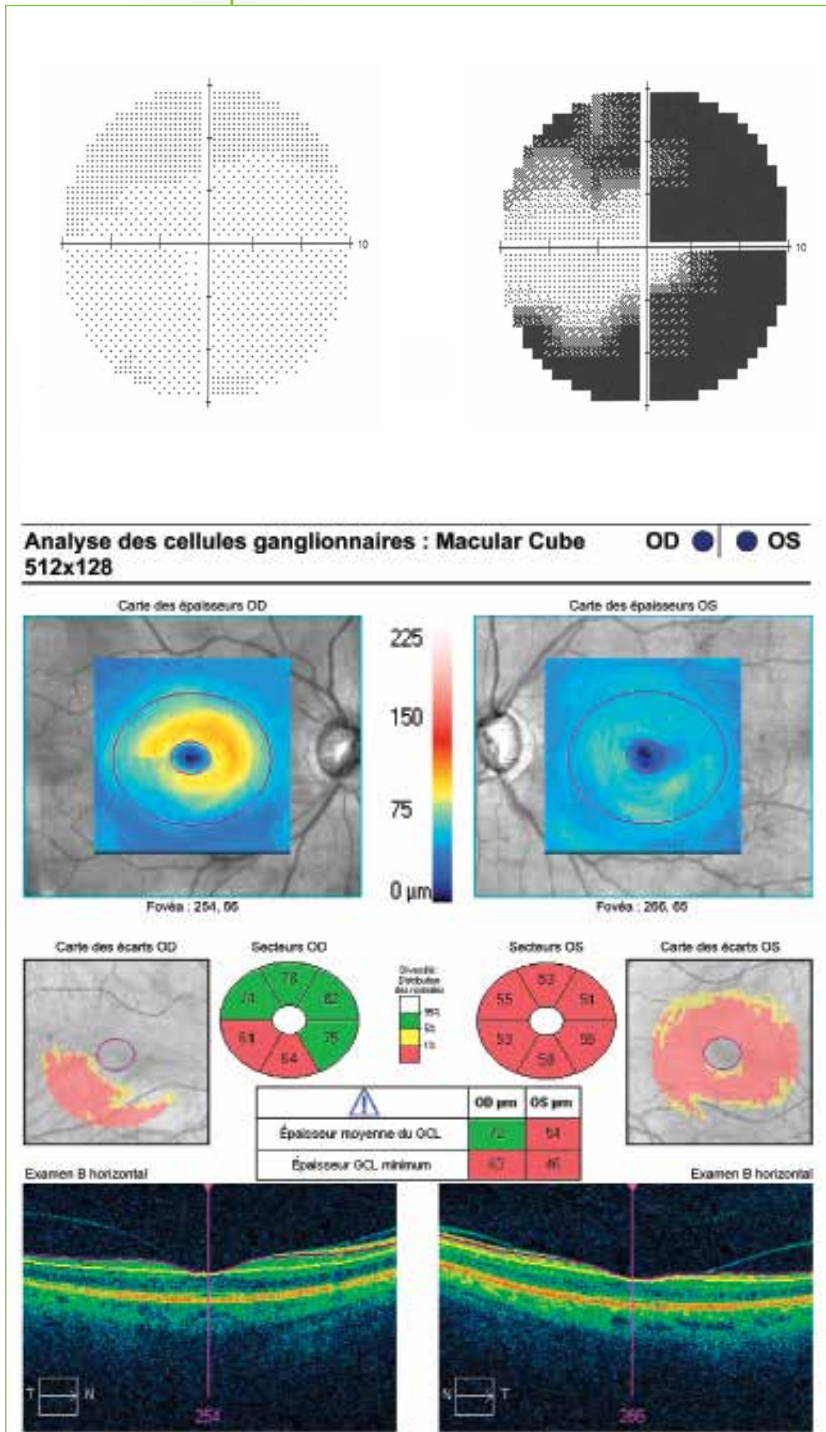
In advanced glaucoma, OCT confirms the impairment but visual field testing keeps its predominant position. In fact, other than certain seriousness, the thickness of optical fibre layers or that of macular ganglion cells is not reduced because of the presence, despite optical atrophy, of support structures accounting for the residual thickness of the RNFL.

## Glaucoma with advanced open angle: impairment concordant with OCT and visual field testing

In advanced glaucoma, a thickness of about 50  $\mu\text{m}$  corresponds to the absolute deficit regions of visual field testing.



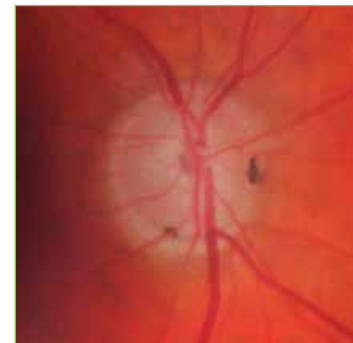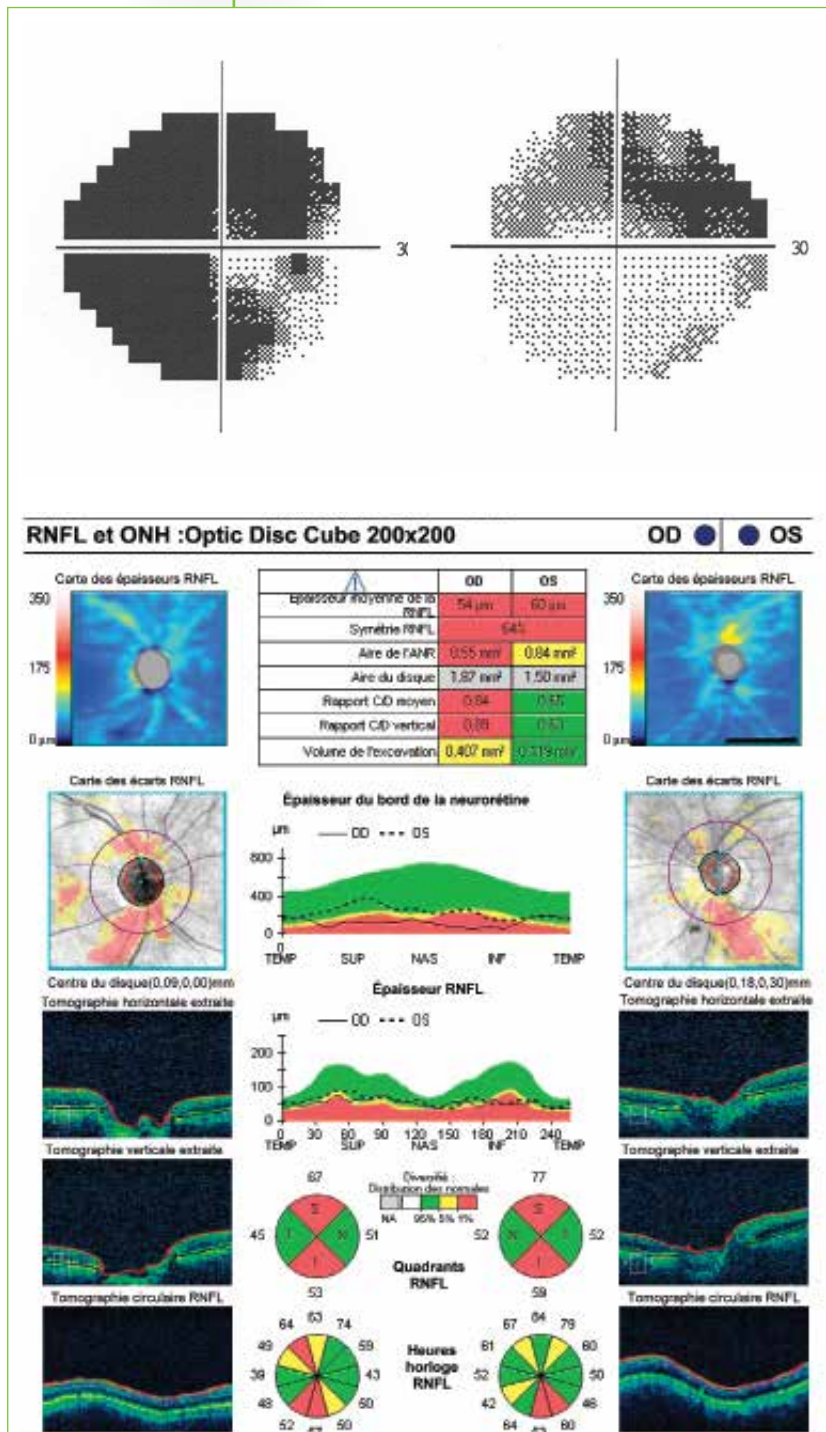
61-year-old patient with predominant glaucoma, left. The OCT profile preserves a preferential impairment in the upper and lower sectors with relative preservation of the temporal fasciculus.



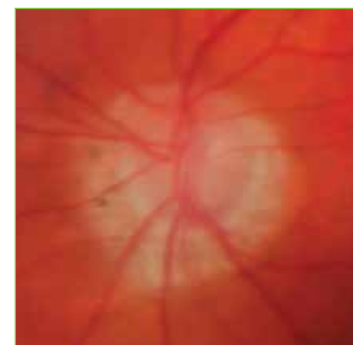
Same patient as on the previous page. OCT and central 10° visual fields. Moderate impairment present, right. All macular regions are affected, left. Note that a simple difference of 15 µm to 20 µm separates incipient deficit (right eye) and absolute deficit zones (left eye).

## Glaucoma with advanced open angle: predominant impairment of visual field testing

In the most advanced stages of glaucoma, it is difficult to rely on the thickness of the optical fibres, both at the papillary and the macular level. This thickness is only slightly reduced in this situation.

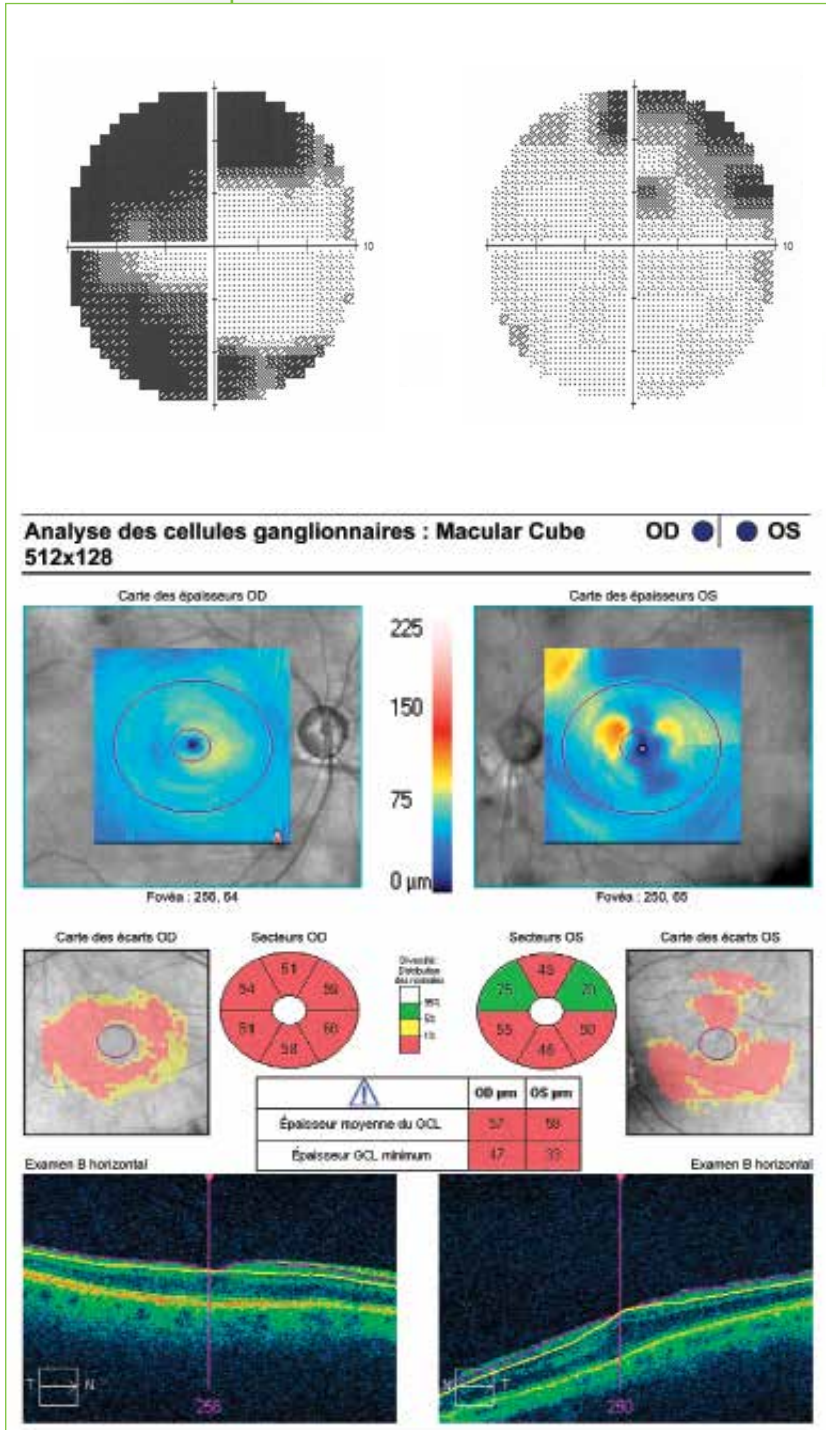


Right eye



Left eye

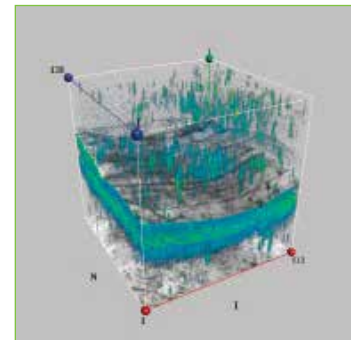
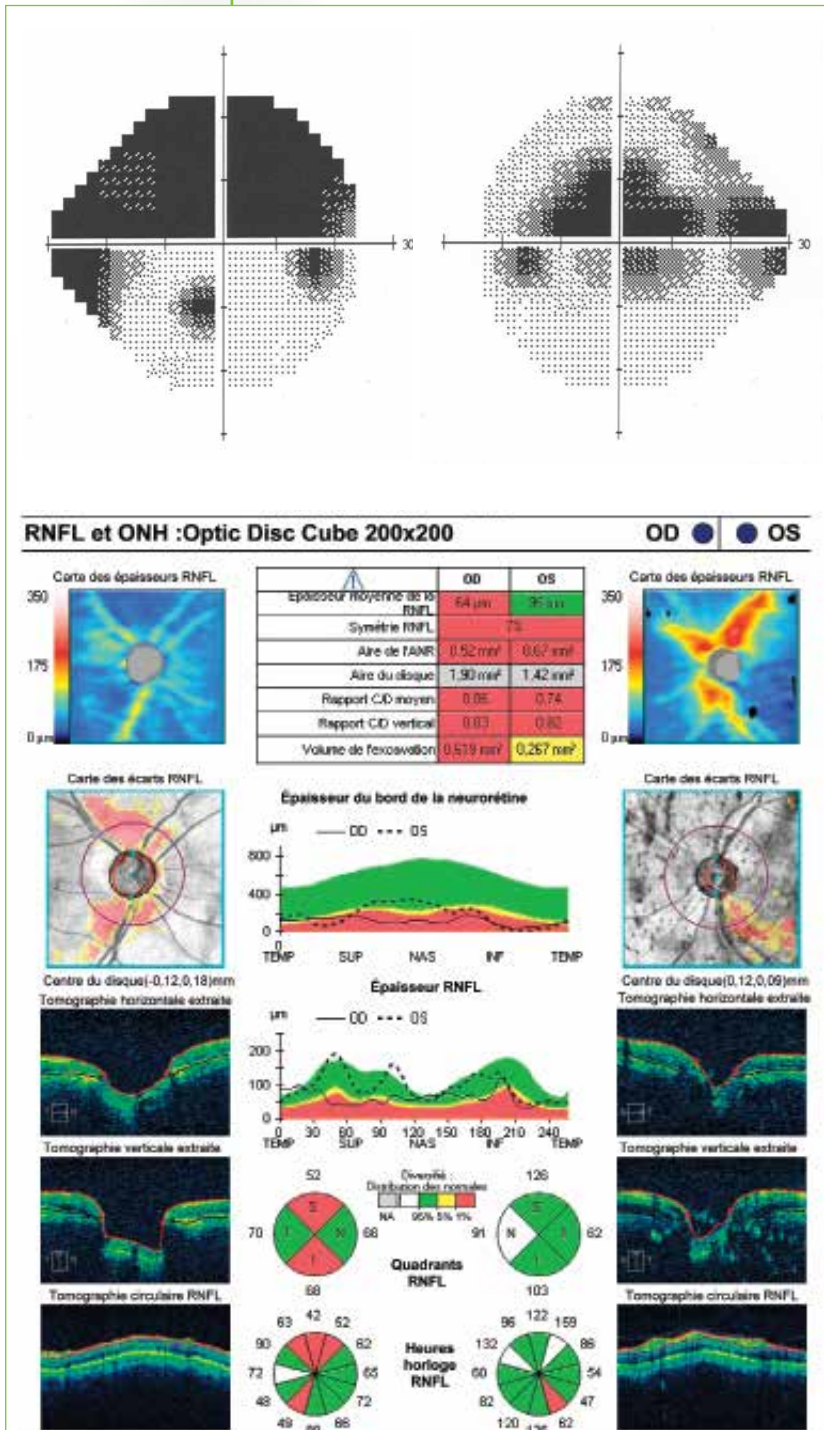
84-year-old patient with advanced glaucoma and reduced visual acuity, right. On this side, the visual field MD is -26dB. It is -11dB on the left. In OCT, this difference is less pronounced, the average thickness of the RNFL being 54 µm on the right against 60 µm on the left.



Same patient as on the previous page. OCT and central 10° visual fields. The same is noted as regards the absence of a clear correlation between VF deficit and thickness of the ganglion cell complex. The MD is -20dB right and -9dB left. The average thicknesses of the macular fibres are 57 µm right and 58 µm left.

## Glaucoma with advanced open angle: discordant impairment between OCT and visual field testing

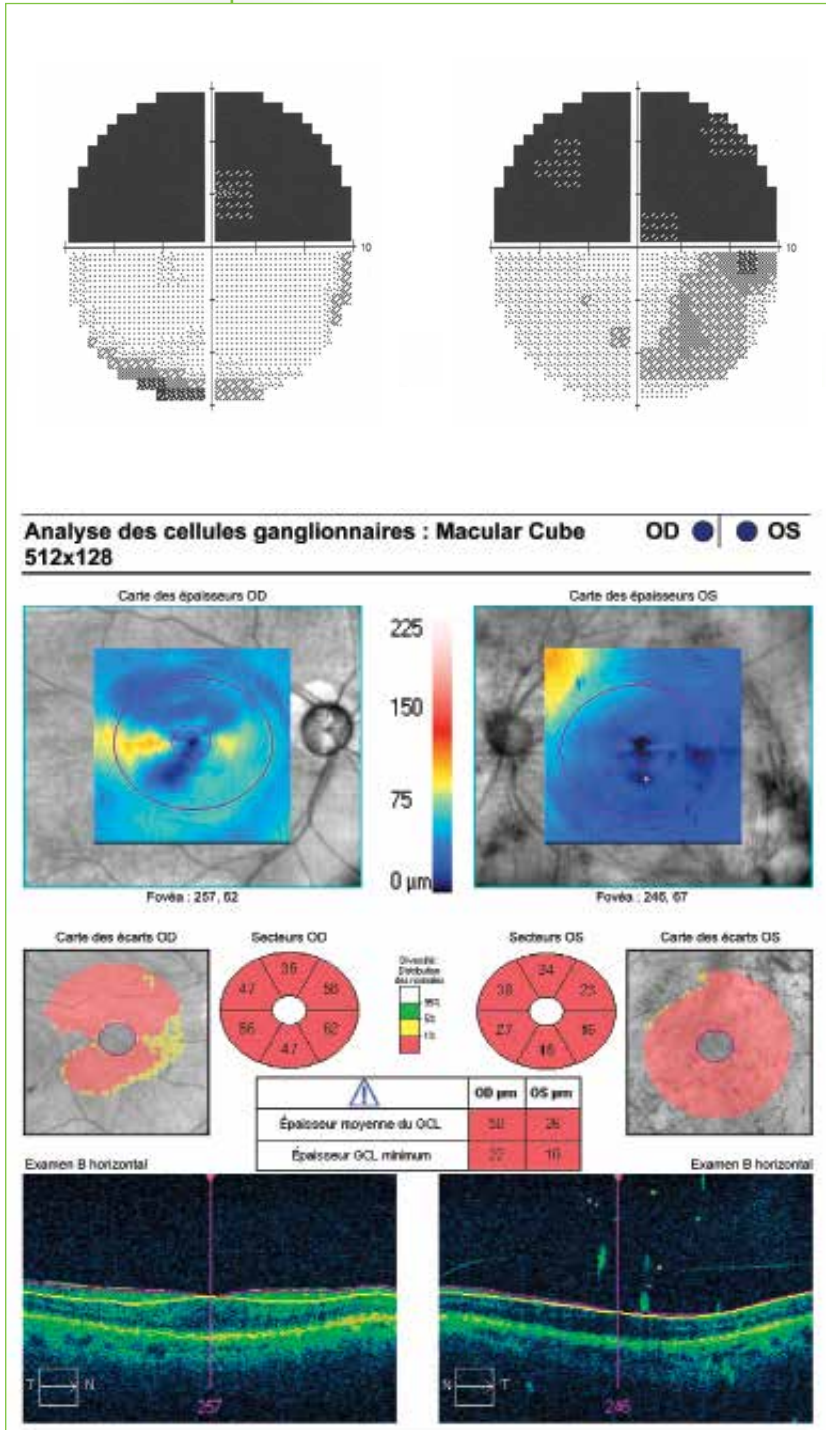
Sometimes, OCT only shows moderate impairment despite an obviously abnormal visual field. This could be due to measurement errors or real discordance.



“Drop” aspect associated with vitreous opacities of the left eye.

65-year-old female patient with more or less symmetrical bilateral glaucoma. Nevertheless, the RNFL only appears to be really abnormal on the right. This could be due to measurement errors associated with serious sparkling synchysis of the left eye, well visualised in OCT and responsible for mediocre signal quality.





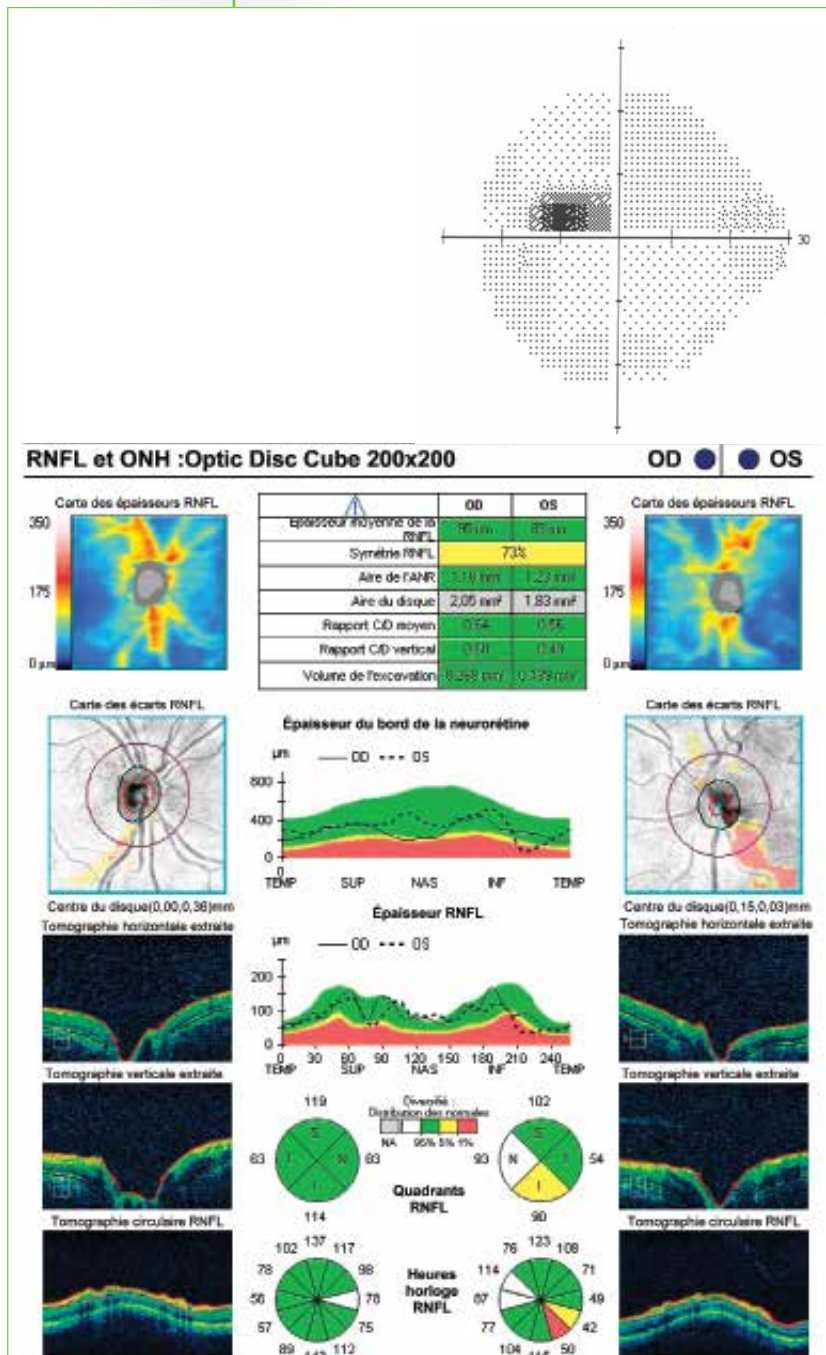
Same patient as on the previous page. OCT and central 10° visual fields. Macular OCT affected on both sides.

# Normal pressure glaucoma

In normal pressure glaucoma, we often observe central 10° visual field impairment. Due to the high number of ganglion cells in this central region, this is expressed by considerable reduction of the retina surface and, therefore, important excavation at the advanced stage. OCT also tends to find identical characteristics. Often, an isolated or predominant impairment of the macular region is found.

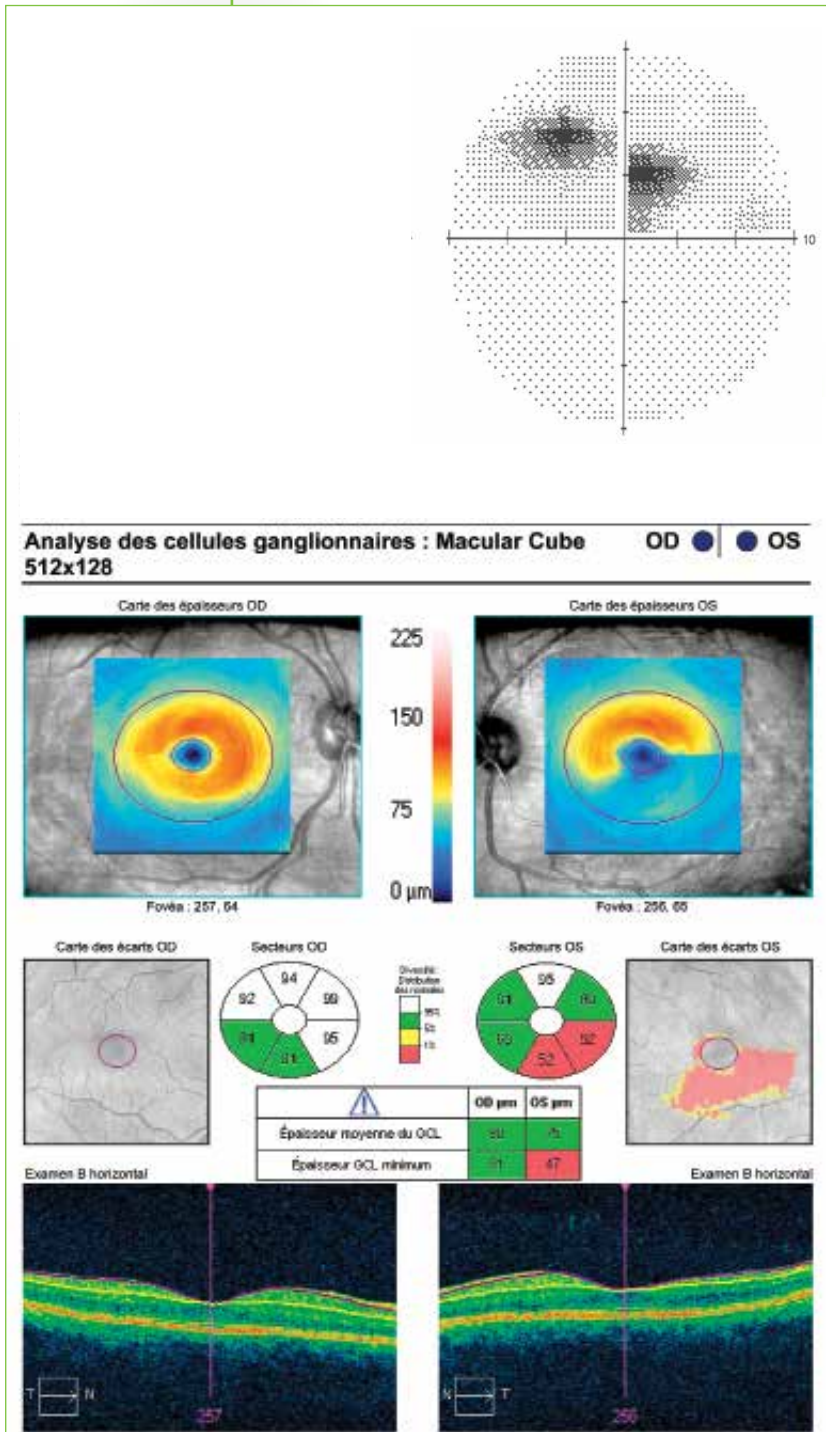
## Normal-pressure glaucoma: isolated fascicular deficit

An isolated deficit can be found in normal-pressure glaucoma, expressed by a notch in the optical nerve head and the RNFL.



60-year-old female patient, ocular pressure of 15 mm Hg without treatment. The results on the right are normal. A slight fasciculate deficit is observed on the left, both in the optical nerve and the parapapillary fibres. The optical nerve parameters are normal.

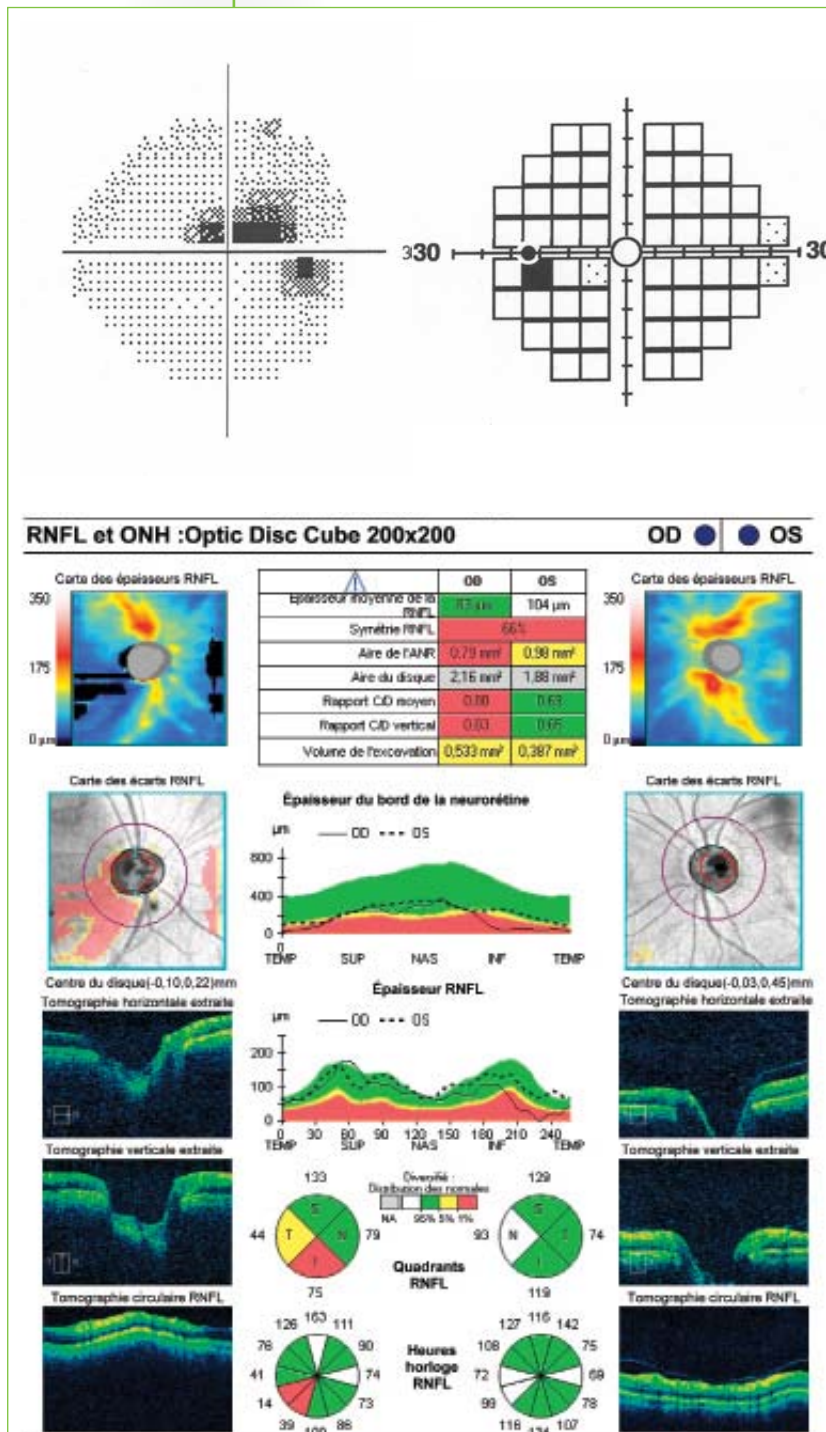
In OCT, the characteristics of normal-pressure glaucoma are, at the early stage, predominant or isolated impairment of the macular region.



Same patient as on the previous page. OCT and central 10° visual fields. Very localised impairment of the left macular ganglion cell complex.

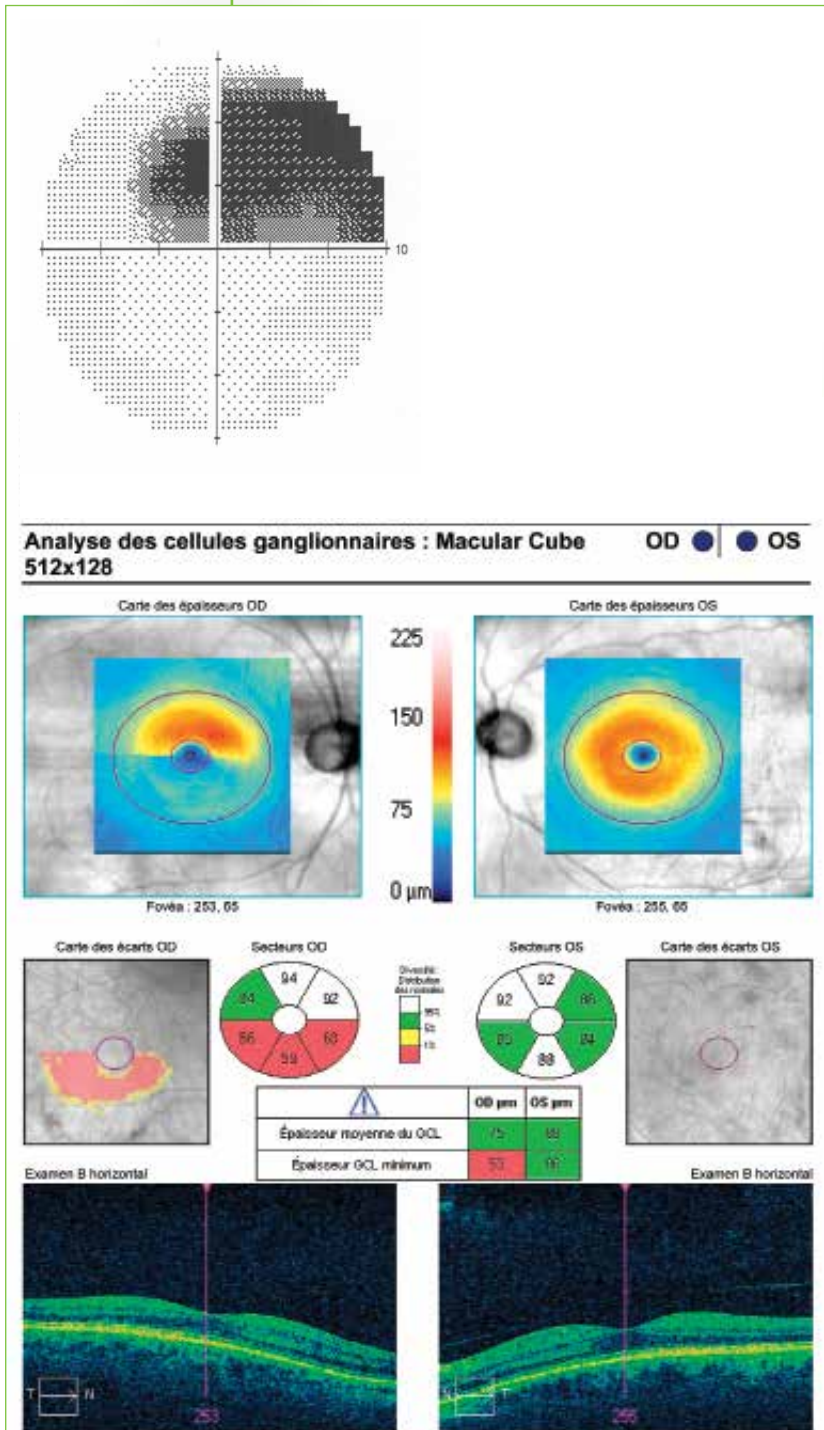
## Incipient normal-pressure glaucoma

In the initial phases, average RNFL is less affected in normal-pressure glaucoma than in hypertonic glaucoma, which is logical because the affected fasciculi are finer<sup>12</sup>.



68-year-old female patient, ocular pressure of 16 mmHg without treatment. OCT shows localised impairment, right. Average RNFL thickness is not affected but the optical nerve parameters are affected, right.

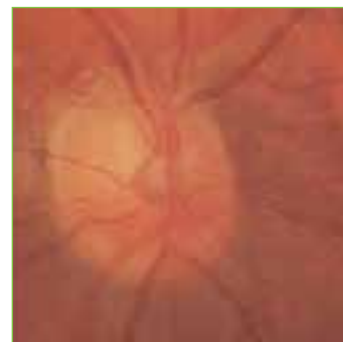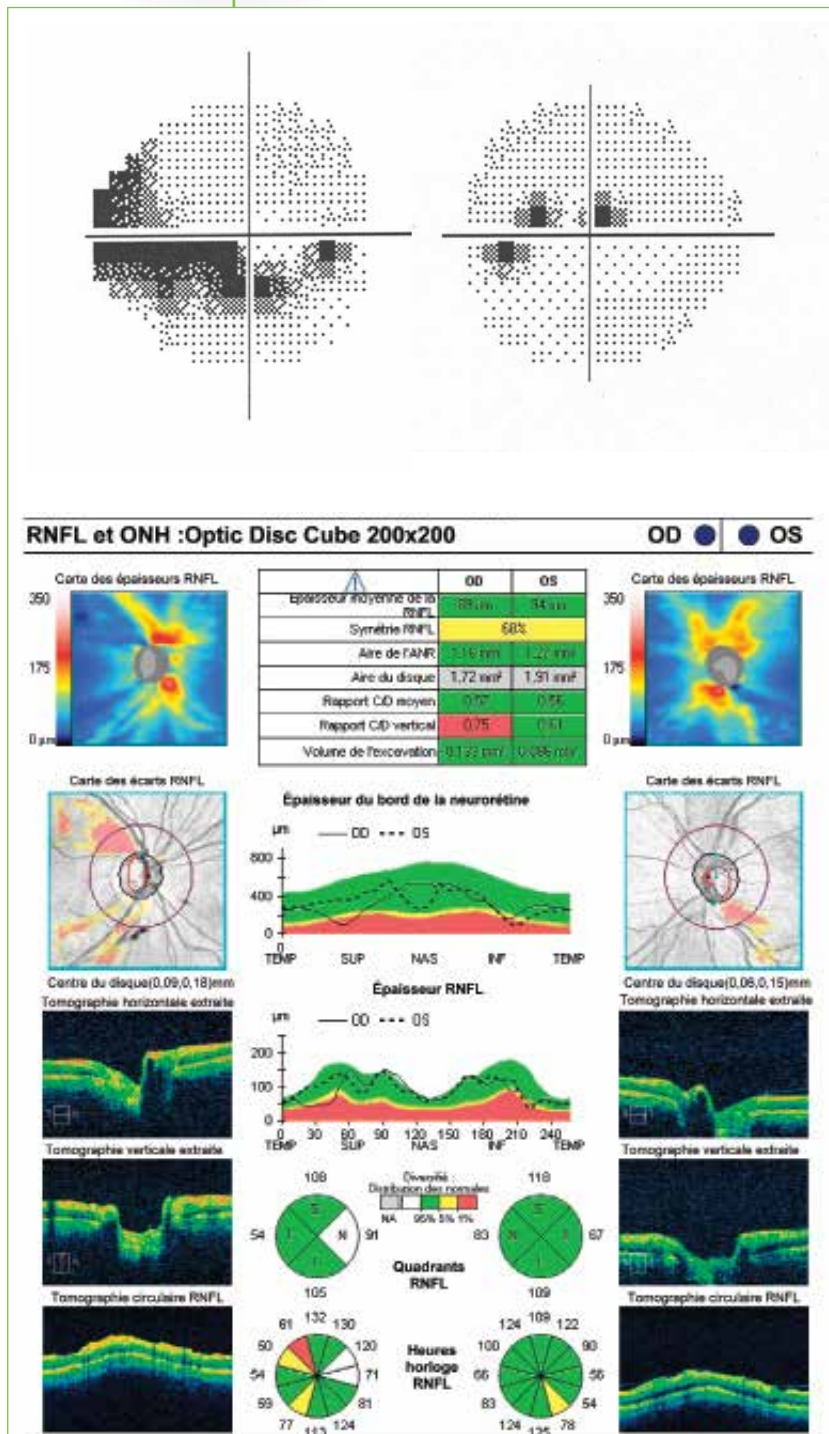
In GPN, the paracentral scotomas are deep and absolute, and only briefly pass through a relative scotoma phase. In contrast, OCT allows quantification of the optical fibre layer of the macular region, which can reduce gradually while no functional indication is present.



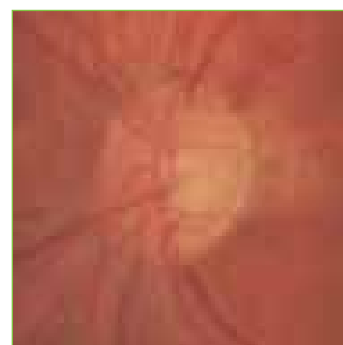
Same patient as on the previous page. OCT and central 10° visual fields. Using OCT, very localised lower macular impairment is observed, which is concordant with the perimetric deficit.

## Moderate normal-pressure glaucoma

Using OCT, the distinction between normal-pressure glaucoma and high-pressure glaucoma is found, essentially, in the initial phases of the disease. When glaucoma is more advanced and the visual field is affected more specifically, this difference between normal-pressure glaucoma and hyper-tonic glaucoma disappears gradually.



Right eye

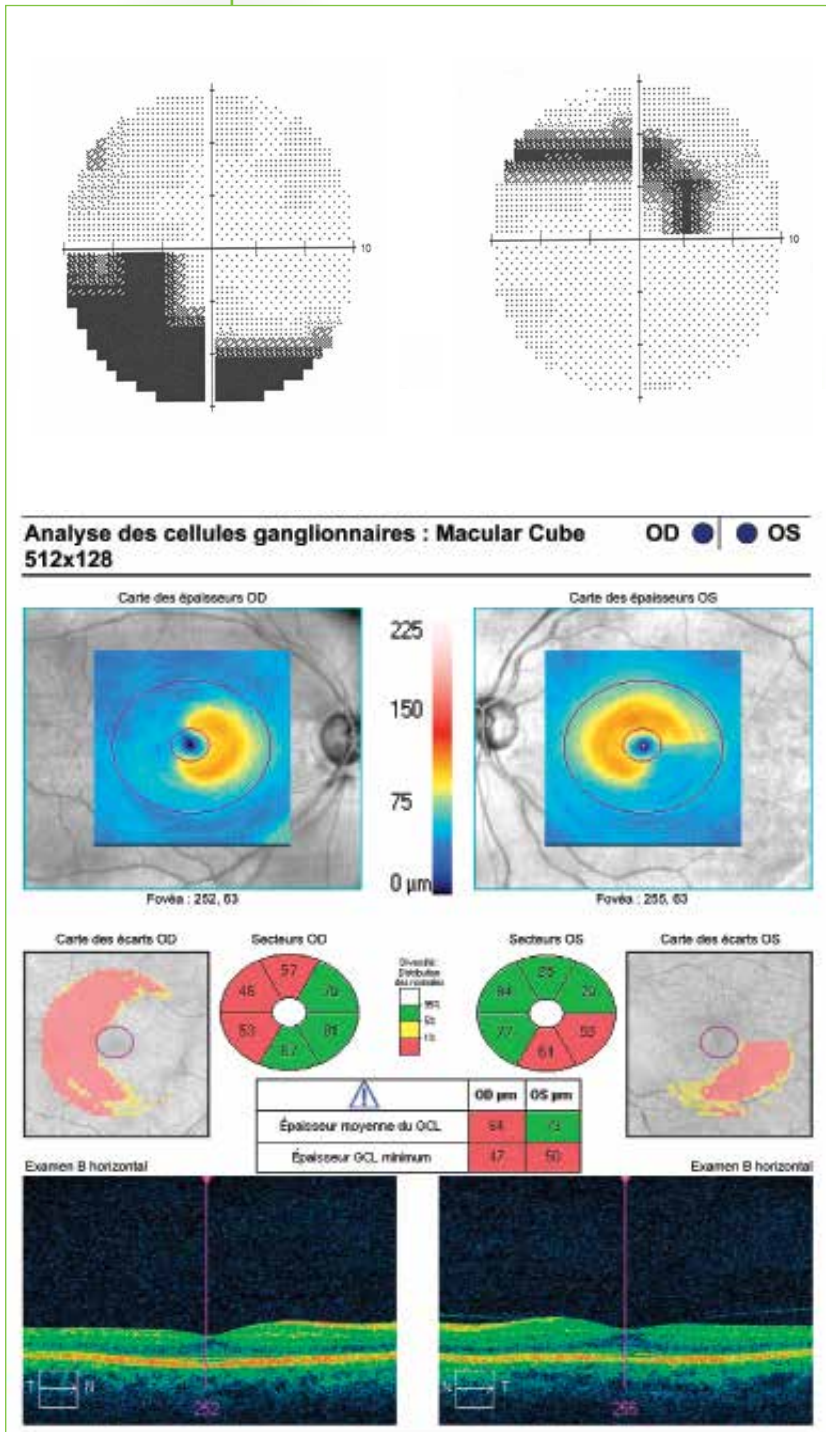


Left eye

60-year-old female patient affected by normal-pressure glaucoma. The right eye associates the usual indications of open-angle glaucoma with a nasal jump and arched scotoma. The RNFL remains relatively undisturbed.

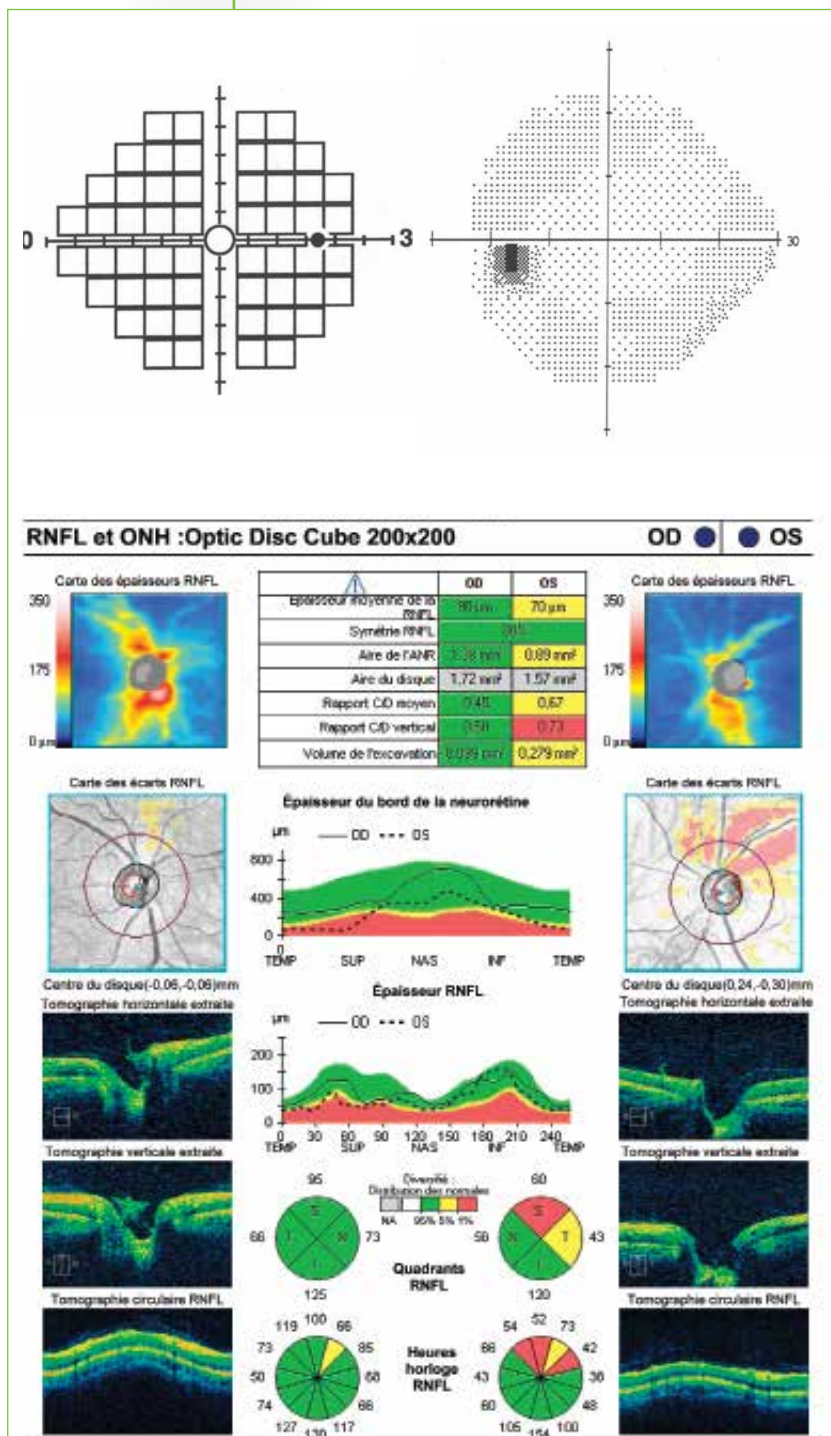
A small paracentral scotoma appears on the left, which only slightly alters the thickness of the optical fibre layer.

The analysis of the macular ganglion cell complex available in “Spectral Domain” OCT allows to detect the beginning of impairment, which is expressed by highly localised reduction of the fibres, with less global macular impairment than in GPAO.



Same patient as on the previous page. OCT and central 10° visual fields. The central 10° test and OCT are concordant. Contrary to what one often observes in hypertonic glaucoma, not all the macular sectors are damaged.

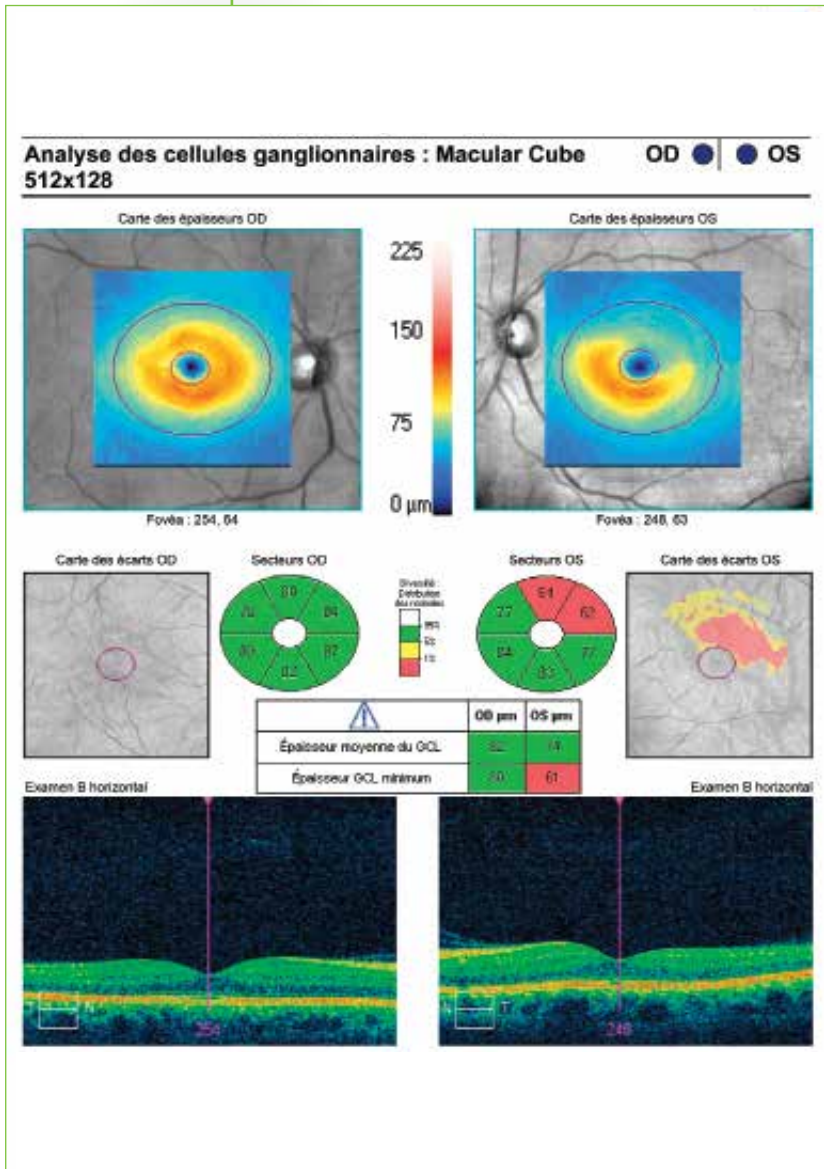
Immediately after a glaucoma crisis by reducing the angle, OCT does not change significantly. Nevertheless, 3 to 9 months later, the optical fibre layer is reduced both locally in the upper and lower regions and globally, while the perimeter remains unchanged in most cases. It might thus be interesting to compare OCT directly and some time after the acute crisis in order to establish the occurrence of impairment sequelae<sup>13</sup>.



58-year-old male patient who underwent a closed-angle glaucoma crisis in the left eye a year earlier, resolved under medical treatment and iridectomy. Pressure is 16 mmHg on each side. Matrix and OCT normal on the right. On the left, the visual field appears normal but in OCT upper impairment is shown. The optical nerve parameters show slightly abnormal results on the left.



Even in the absence of an acute crisis and if pressure is normal, the thickness of the optical fibres in the low temporal region is sometimes smaller in patients with narrow angles, Asians in particular<sup>14</sup>. This suggests repercussions of nocturnal pressure outbursts.



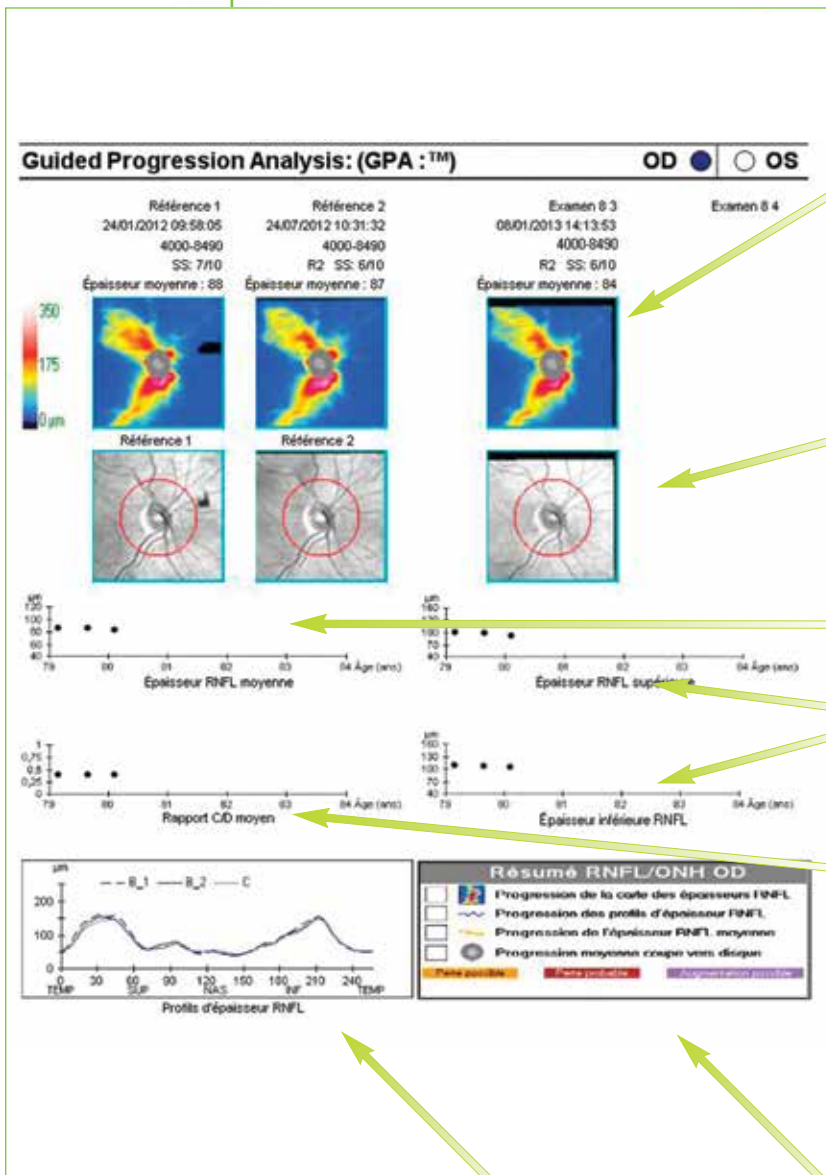
Same patient. Impairment of the macular region of the left eye is observed. The minimum average thickness parameter is abnormal.

### Open-angle glaucoma monitoring

OCT allows detection and monitoring of glaucoma evolution. “Spectral Domain” OCT being recent, it is difficult to find long-term longitudinal studies; the most recent being a 4-year monitoring of patients<sup>15</sup>. Several types of evolution are possible. The most frequent is an expansion of the deficit surface, with a tendency to approach the macula. Less frequently, one observes a deepening of the impairment or the appearance of impairment in a different region. In order to detect this aggravation, the zone selected usually, 3.4 mm from the centre of the optical nerve, is too peripheral; a region at 2mm being more differentiating. In more than 50% of the cases, this aggravation in OCT is not confirmed by automated perimetry testing, thus underlining the low correlation between these two examinations, at least during a short evolution period. On the contrary, in 20% of the cases, isolated aggravation in the perimeter is confirmed without OCT evolution.

Cirrus HD-OCT proposes a glaucoma monitoring programme and an analysis of event evolution (GPA Report).

GPA monitoring parameters



Optical fibre thickness.

Changes in the thickness of the optical fibres between examinations, when a first change is detected, are drawn in yellow, if confirmed during the next examination, they appear in red.

Changes, through time, of the average thickness of the RNFL globally, in the upper region and the lower region (3 tracings).

Average C/D ratio evolution.

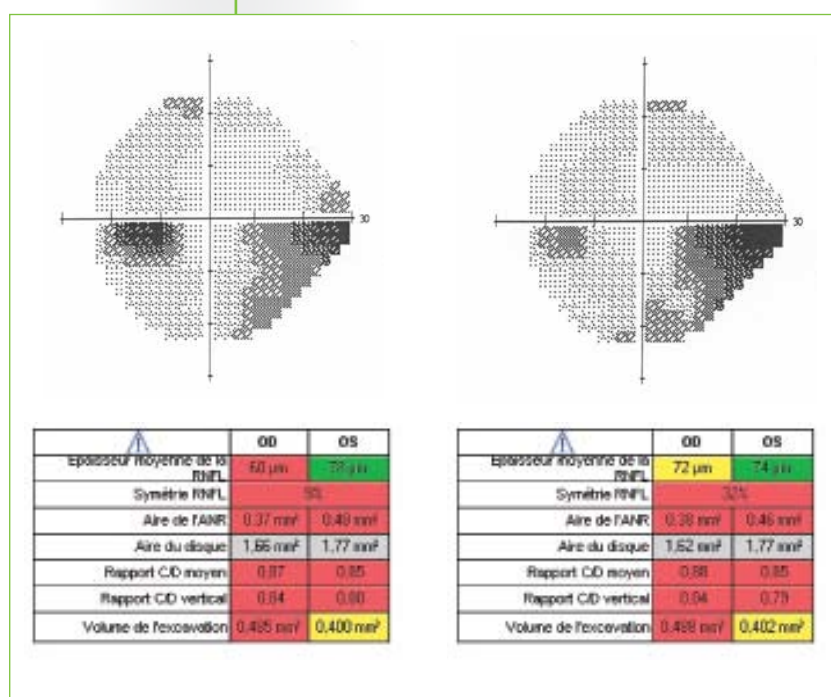
Fibre thickness profile in the various regions (TSNIT), using the same colour code in the case of aggravation.

Synthesis of the probability of stability or aggravation for three key parameters, fibre thickness and TSNIT (focal progression) and average thickness (diffused progression), as well as average C/D.

This GPA programme allows, like in perimetry testing, to detect significant evolution<sup>16</sup>. Nevertheless, important limits persist because evolution is considered real in patients with glaucoma if the new examination is outside the variability limits as determined in healthy individuals. We do not know whether this variability is smaller in reality or greater in patients with glaucoma. In the study by Leung et col<sup>17</sup>, an increase in the volume of the optical fibre layer is even found in 13% of the cases, which is difficult to accept because that would signify an improvement of glaucoma. Undoubtedly, this result corresponds to initial measurement errors. The same team had carried out a similar study 3 years earlier using OCT Stratus. This study shows a minimal capacity to detect progression with previous generation OCT.

Aggravation of structural impairment and functional impairment do not evolve in parallel. These works thus clearly show that it is not possible to avoid automated perimetry testing, when this examination is abnormal, in the monitoring of glaucoma, but that OCT also appears to be very useful, at least in the incipient and moderate glaucoma phases.

When evaluating the aggravation of glaucoma through the reduction of optical fibre thickness, one should consider the glaucoma stage. In fact, the relationship between optical fibre loss and visual field aggravation is not linear<sup>18</sup>. In the initial phases of glaucoma, an optical fibre loss can increase without an important change in the visual field. At a more advanced stage, a moderate change in optical fibre thickness is expressed by an important aggravation of the visual field. Finally, in the later stages, the optical fibre thickness does not change practically, while the visual field continues to worsen. The persistence of a certain optical fibre layer thickness does not mean that a significant number of ganglion cells are present, but rather that cells supporting this layer are still present.



*Simultaneous aggravation of visual field testing and OCT in 6 months. A 3 micron decrease of the average thickness of the RNFL is considered significant. Here, in the left eye, it changes from 78 µm to 74 µm.*

## Can OCT improve in glaucoma?

In practice, OCT does not improve in glaucoma. Nevertheless, after an important reduction in ocular pressure through surgery, OCT can show an increase in the thickness of optical fibre layers, but this phenomenon is temporary and only lasts about 3 months<sup>19</sup>. Most often, OCT improvement is the consequence of better images that were not optimal during the first measurements.

## Comparison between “Spectral Domain” OCT in glaucoma

Except for 1<sup>st</sup> generation OCT (Time Domain), there are several Spectral Domain OCT devices: Cirrus™ HD-OCT (Carl Zeiss), 100RTVue (Optovue), Spectralis (Heidelberg)... These devices use the same operating principle but vary as regards acquisition speed, the existence of a system that monitors view and the retinal layers segmentation method.

It is not possible to use the gross values of Spectral Domain OCT and transpose them to another. The results with these devices are very close but different, e.g. Cirrus HD-OCT gives lower RNFL values than RTVue<sup>20</sup>. In particular, this is associated with the measurement zone, which differs slightly from one device to another.

## OCT and cribriform plate analysis

OCT is in constant development. OCT allows analysing practically all structures that can be illuminated. Apart from optical fibre impairment, we know that glaucoma leads to deformation of the cribriform plate. Thanks to a specific programme (Enhanced Depth Imaging-Optical Coherence Tomography (EDI-OCT)), in glaucoma, one can visualise the cribriform plate deforming towards the back, but also shifting backwards in relation to the sclera in certain meridians<sup>21</sup>. We do not know whether this corresponds to a cause or a consequence of impairment of this structure, but it appears that after surgical reduction of ocular pressure, the cribriform plate gains anterior adherence and thickens again<sup>22</sup>. Thus, this analysis appears to be an important line of development not as regards the content (optical fibres) but the crossed structure (position of the cribriform plate, sectoral thinning, form of pores)<sup>23</sup>. In contrast, there does not appear to be a great interest in measuring the thickness of the choroids, which is only slightly changed by glaucoma<sup>24</sup>. Nevertheless, in case of peripapillary atrophy, this thickness is not reduced<sup>25</sup>.



# Neuropathies - optic non glaucomatous

In essence, optic neuropathies are responsible for the deterioration of optical fibre axons and cause OCT modification. This impairment affects both the parapapillary and the macular fibres. OCT has thus become a very important diagnosis tool in neuro-ophthalmology<sup>26</sup>. In many cases, the OCT profile helps diagnosis and evaluation of the importance of optic neuropathy. However, the OCT “profile” of certain diseases resembles that of glaucoma. It thus appears important to know the OCT semeiology of these different neuropathies.





In multiple sclerosis, the analysis of the retinal ganglion fibre layer is of great interest because it is better correlated with the functional symptomatology of the patients (lower acuity or reduced visual field) than in other supplementary examinations, such as MRI<sup>27</sup>.

### Acute neuropathy and MS

During the acute phase of MS optic neuropathy, the RNFL is sometimes more voluminous than normal. This provides evidence of slight papillary oedema, which is not clinically perceptible. This oedema is present even if the demyelinating plaque is quite posterior.

Thinning of the optical fibres layer occurs between the 1<sup>st</sup> and 3<sup>rd</sup> month after the acute crisis and stabilises around the 6<sup>th</sup> month. In the absence of a new crisis, there is no aggravation after 6 to 8 months.

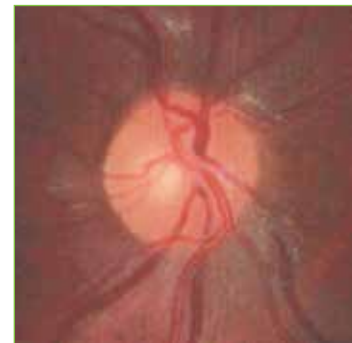
The most damaged site is the macular area where about 34% of the retinal volume is composed of the ganglion cell layer. In this pathology, an eye affected by optic neuropathy presents a reduction of about 35 to 45% in macular optical fibre thickness i.e. 20 µm to 40 µm, for a normal thickness of 110 µm to 120 µm<sup>28</sup>. The contralateral eye is also affected in most cases, but to a lesser degree (20% reduction in thickness). In order for impairment to appear in perimetry testing, a 75 µm reduction approximately is necessary.

It is thus very important to analyse OCT in relation with neuropathy dynamics<sup>29</sup>. In the acute phase, the absence of layer thinning is falsely reassuring. In fact, impairment is delayed.

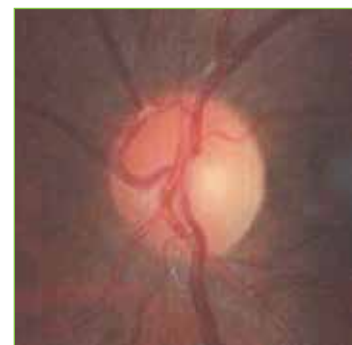The papilla and macula are affected by MS. In the initial phases, the RNFL can be artificially enlarged by papillary oedema, which is not the case for macular ganglion cells. In the long-term, the two structures develop in parallel<sup>30</sup>.

## Correlation between OCT and visual field testing in MS

When OCT impairment is minimal, the visual field and visual acuity remain normal in general after an acute crisis. In contrast, if a residual thickness threshold of 75  $\mu\text{m}$  is affected in the peripapillary area, the field is disturbed.

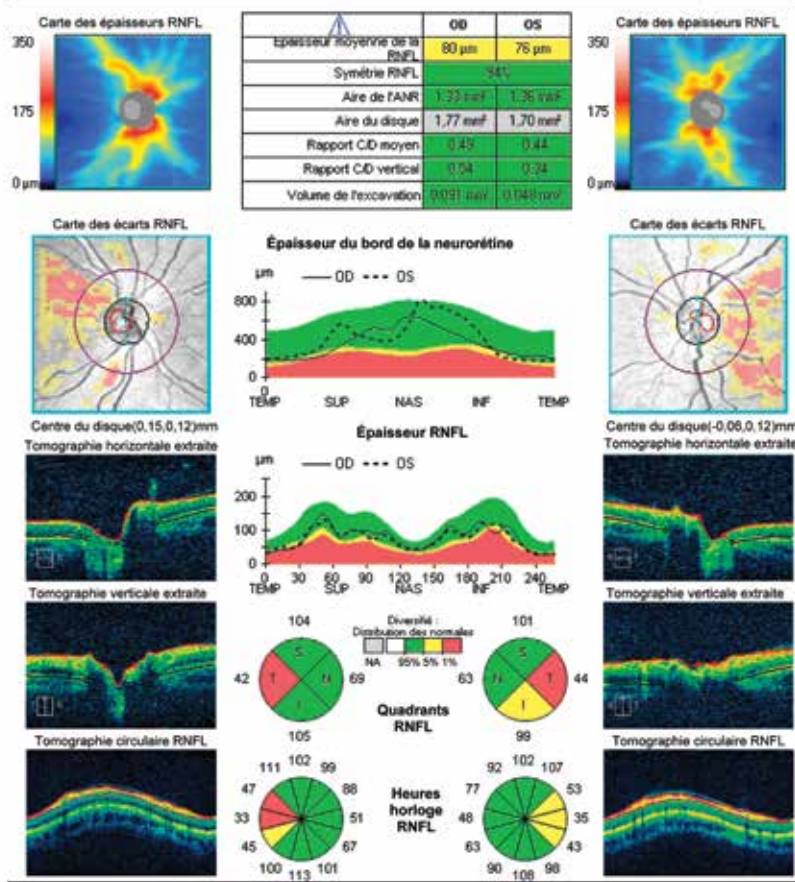


Right eye



Left eye

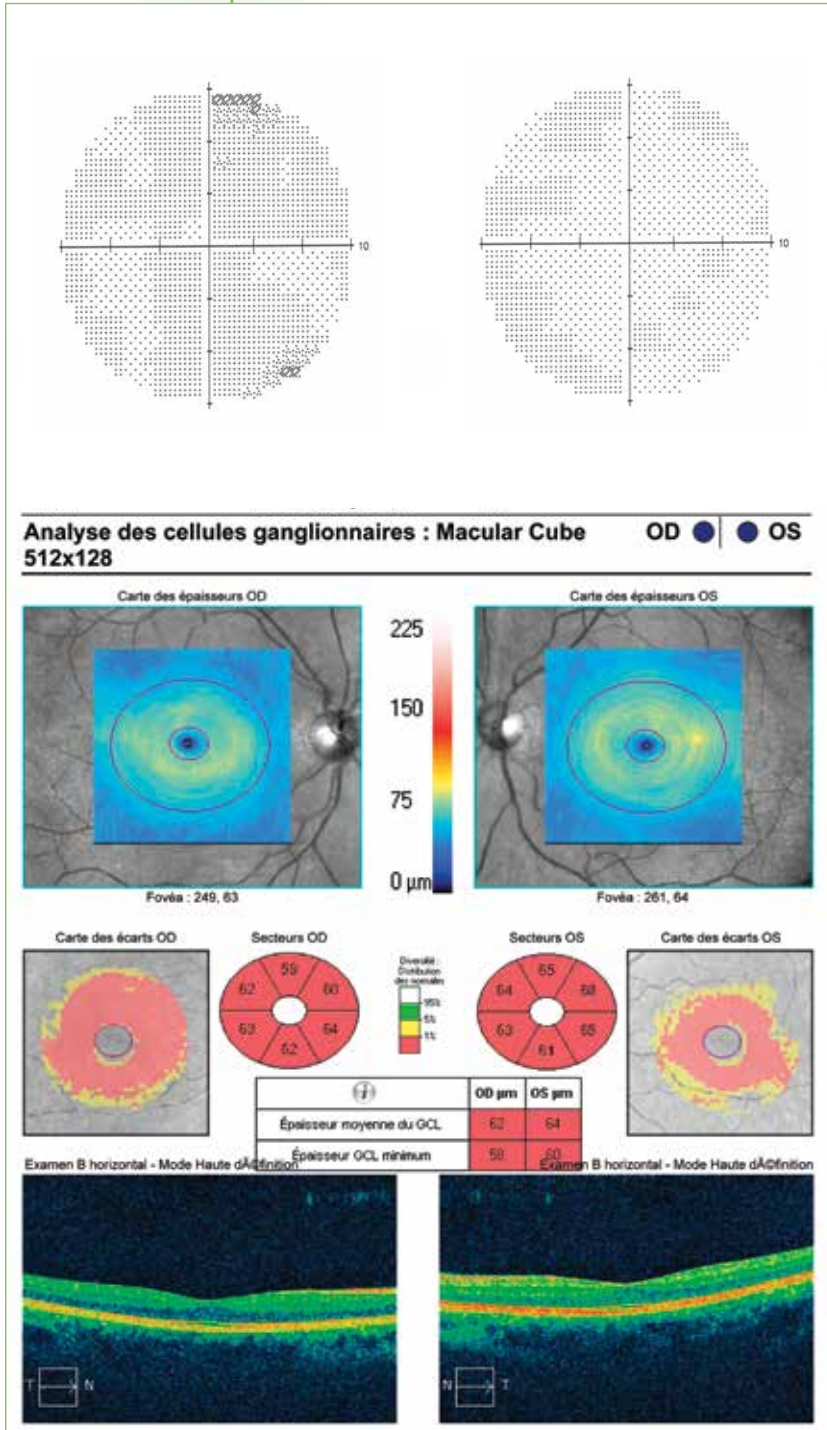
### RNFL et ONH :Optic Disc Cube 200x200



Multiple sclerosis after an outburst. The optic nerves are normal. OCT shows predominant impairment in the temporal sectors of each eye. This deficit does not appear in Goldmann's kinetic perimetry testing. Temporal impairment is typical of non glaucomatous neuropathies.

## Localisation of OCT impairment in MS

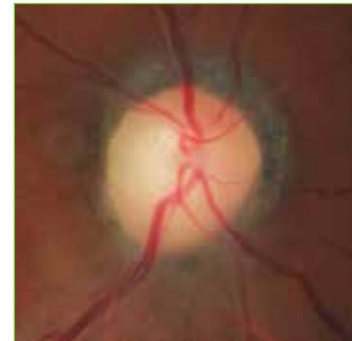
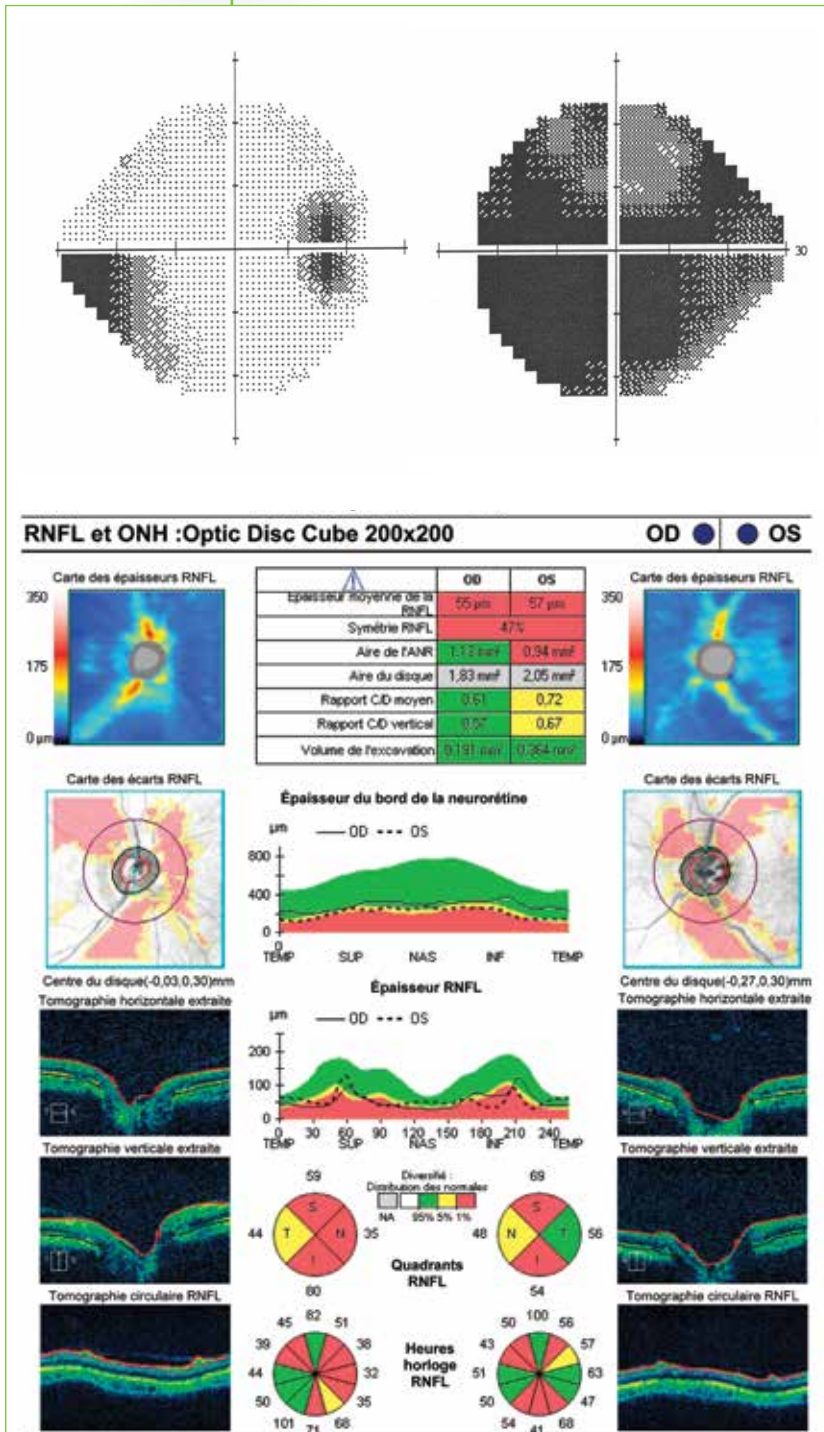
The temporal quadrant is the most frequent location. This allows distinguishing it from glaucoma where impairment is rather superior or inferior.



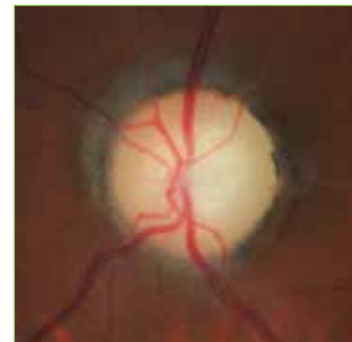
Same patient as on the previous page. OCT and central 10° visual fields. Impairment of macular ganglion cells is major in each eye, despite a very slightly affected central visual field. This type of diffused impairment is found frequently.

## Important sequelae of MS neuropathy

When multiple sclerosis evolves, visual field and OCT deteriorate. This evolution is not always parallel, OCT being able to appear more affected than the visual field.



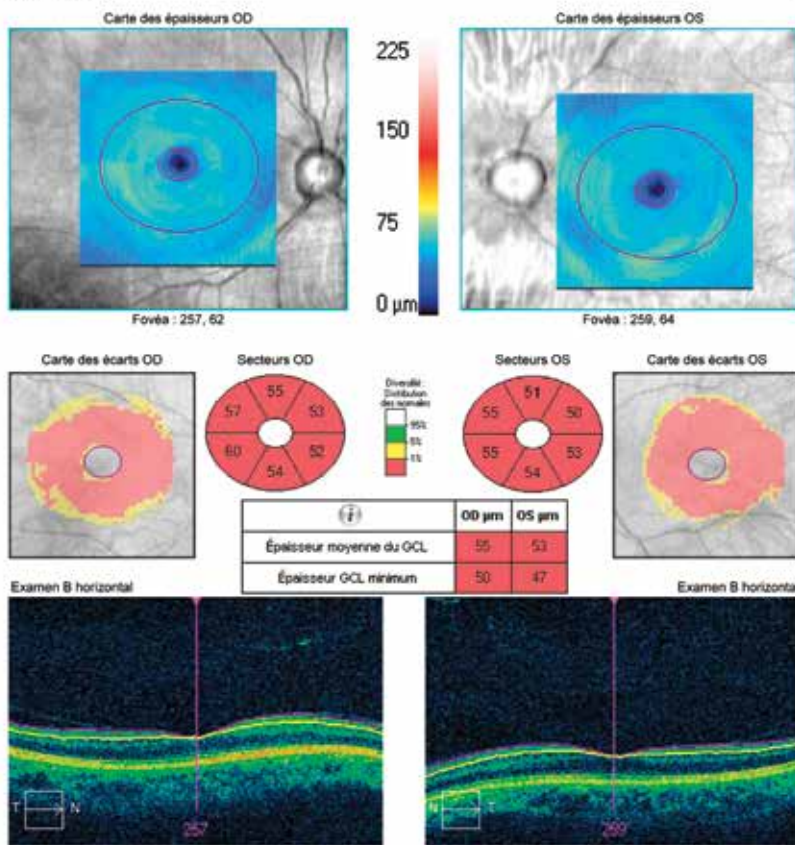
Right eye



Left eye

Female patient affected by MS, with several optic neuropathy outbursts. The visual field of the left eye is highly affected. OCT confirms this impairment and also reveals a practically identical change in the right eye. The optic nerves show predominant bilateral optical atrophy on the left. There is no pathological excavation.

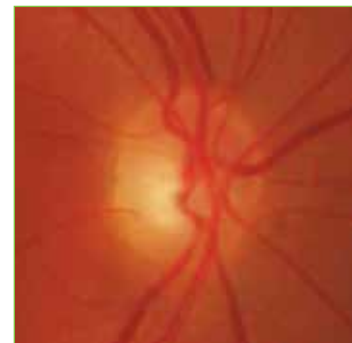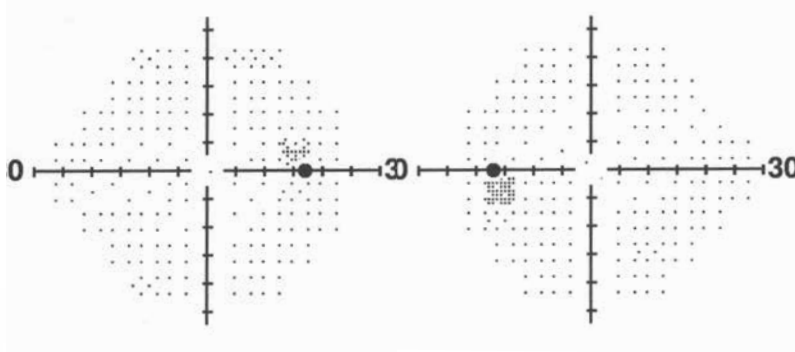
Analyse des cellules ganglionnaires : Macular Cube 512x128 OD ● | ● OS



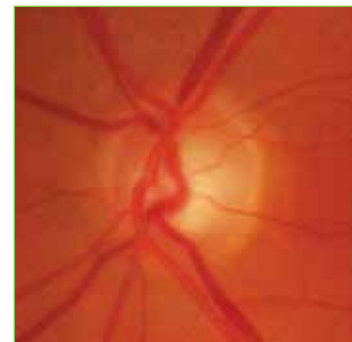Same patient as on the previous page. Impairment of ganglion cells is major on both sides.

## Is it possible to detect subclinical MS neuropathy using OCT?

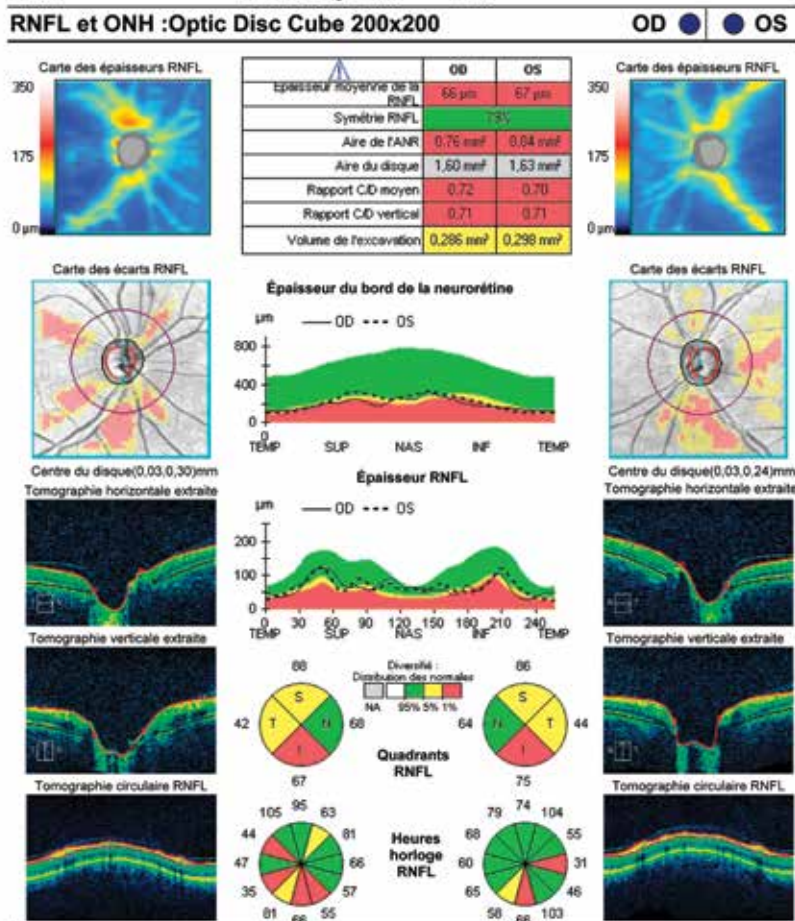
OCT is very useful for analysing the contralateral eye of the eye affected by acute neuropathy and in the absence of ocular impairment in patients with known MS. In fact, it allows detection of subclinical impairment and also monitoring of the neurological state of patients, because impairment of the visual pathways is almost always present in this disease <sup>31</sup>.



Right eye

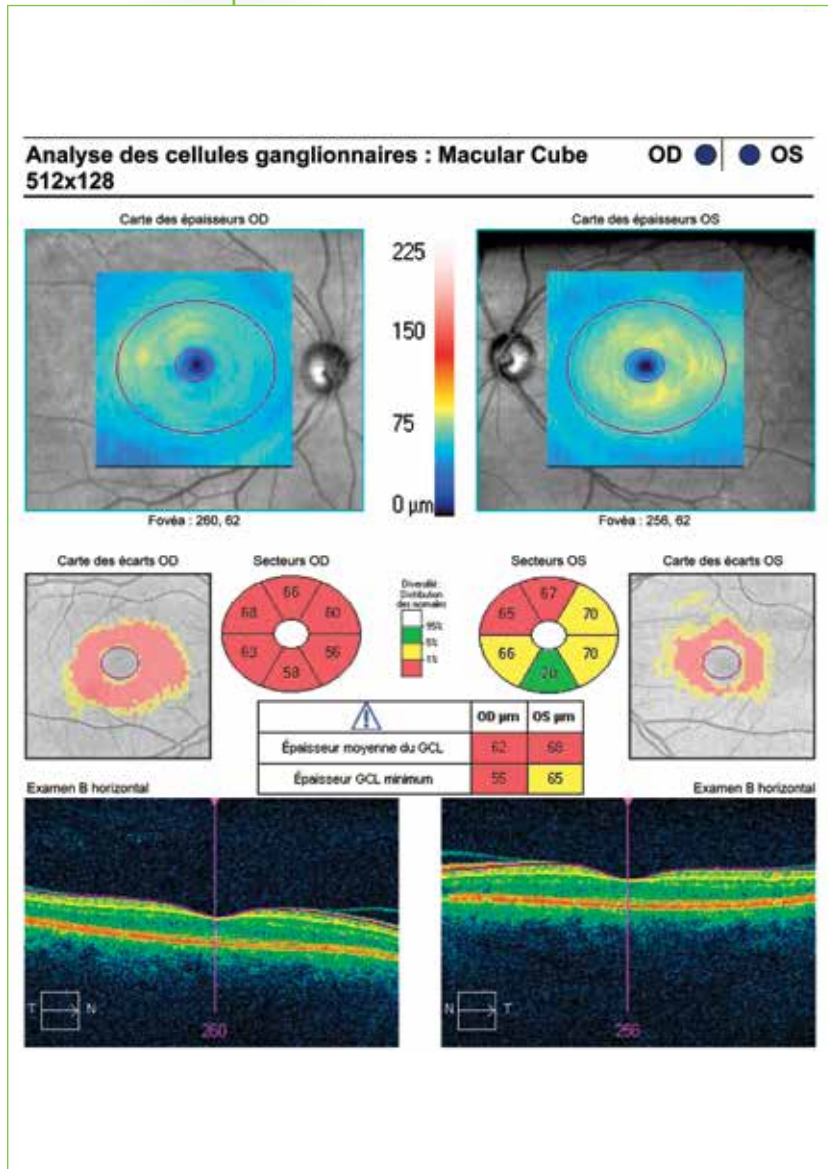


Left eye



Female patient affected by MS without known optic neuropathy episodes. OCT shows irregular impairment in the various sectors, while the visual field is normal.

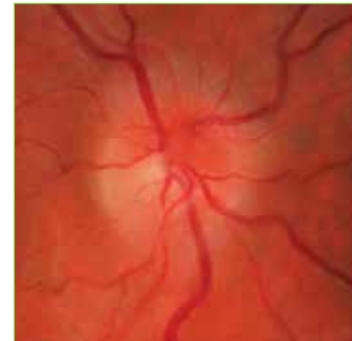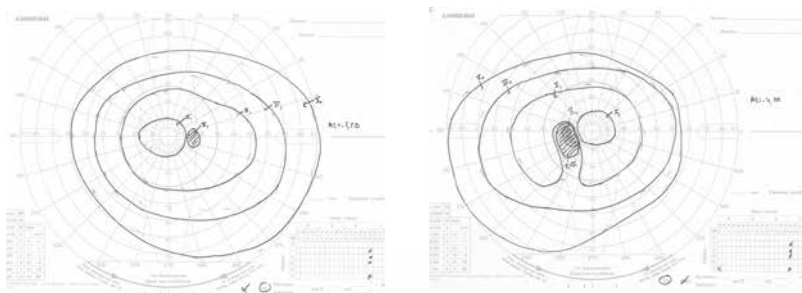
We could even perform OCT in order to monitor the evolution of treatments administered in general, in the absence of a visual history. This examination could thus provide a general evaluation of MS.



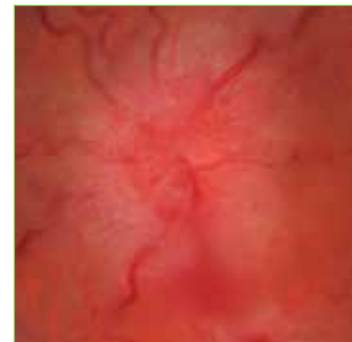Same patient as on the previous page. Diffused impairment visible. Normal visual acuity.

## Acute optic neuropathy not associated with MS.

Ophthalmologists are often confronted with acute optic neuropathy of unknown origin, demyelinating or not. Does OCT help to distinguish demyelinating optic neuropathy, whether lone or associated with other types of pathology? The clinical context is essential. In favour of demyelinating aetiology: occurring between the age of 20 and 50; ocular pain during eye movement in particular; strictly unilateral character; progressive aggravation in about a week; start of recuperation after one month.

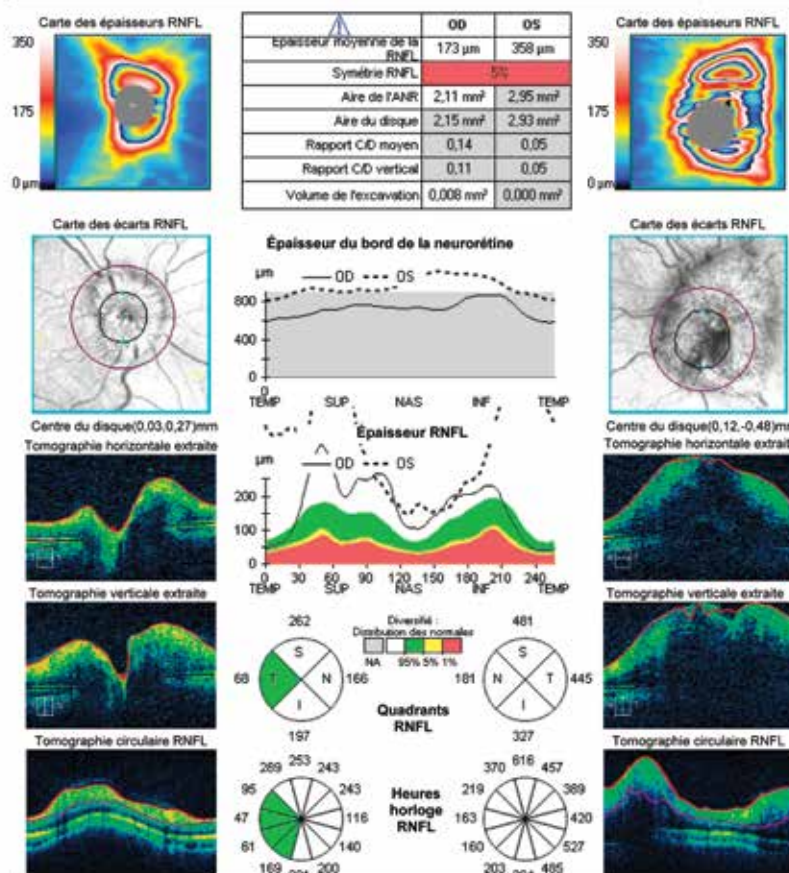


Right eye



Left eye

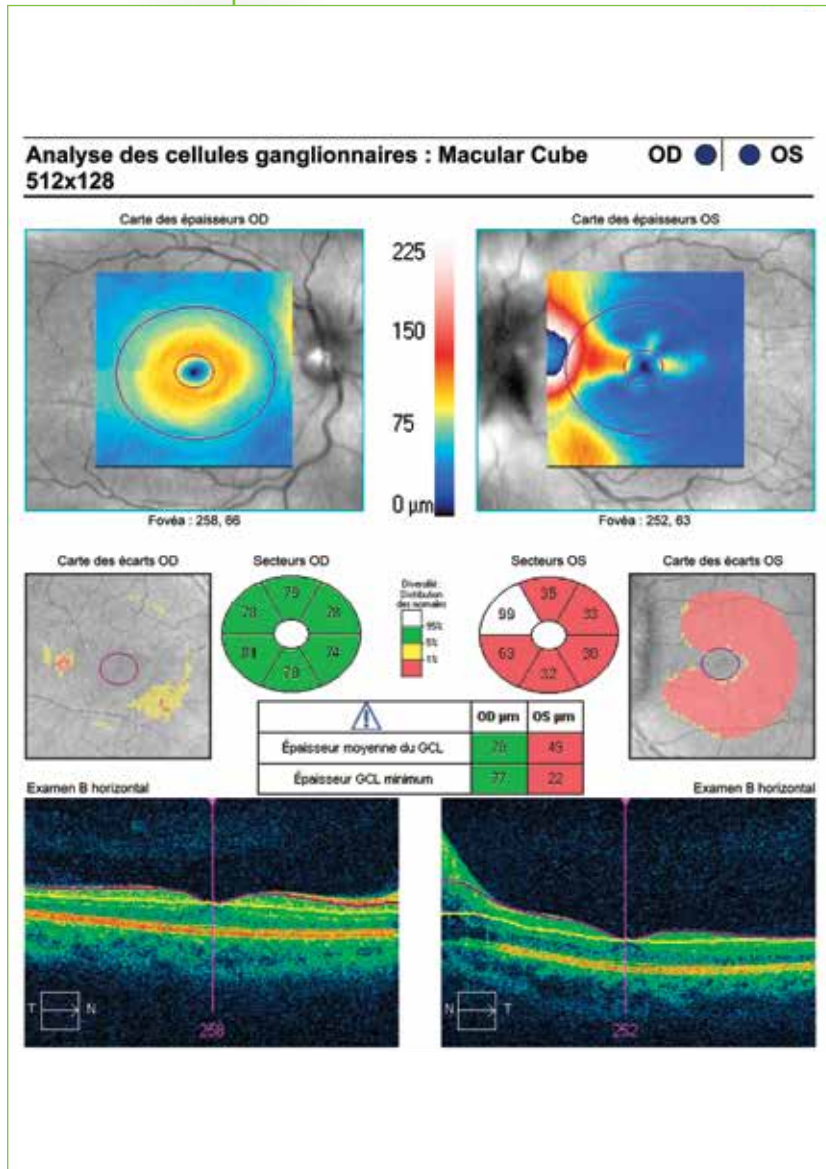
### RNFL et ONH :Optic Disc Cube 200x200



30-year-old female patient with bilateral blurred vision, without reduced acuity. The MRI results do not indicate MS. The ocular fundus reveals more significant papillary oedema on the left than on the right. OCT confirms this result through a major increase in parapapillary optical fibre thickness on both sides. This result does not indicate that the optical fibres are healthy.



Unfortunately, the OCT profile does not allow differentiation of such impairment, which is expressed by initial increase in fibre thickness in the case of oedema, and then further reduction of the RNFL.



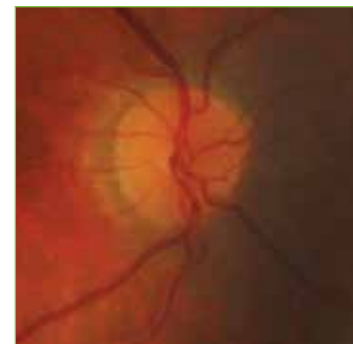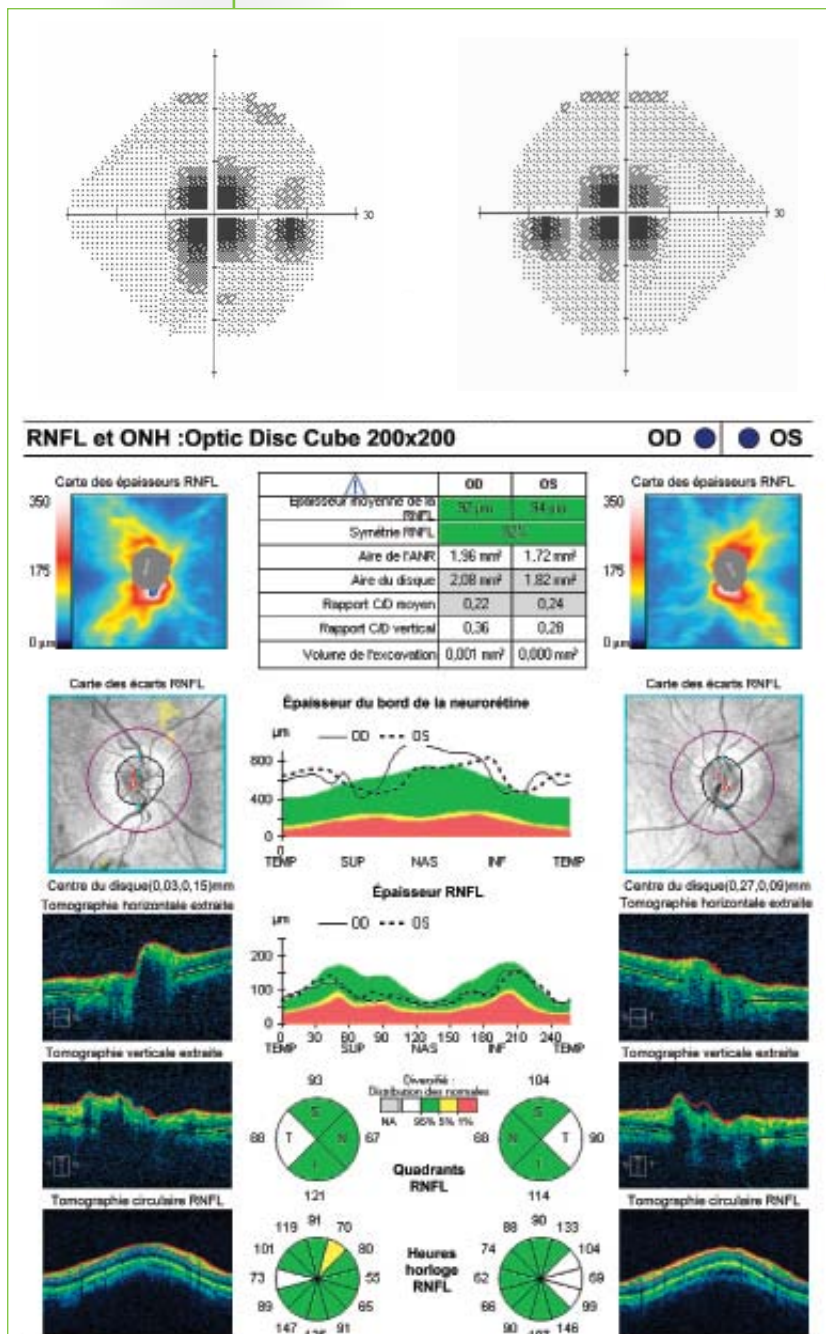
Same patient as on the previous page. The analysis of ganglion cells shows important impairment on the left, while visual acuity is 10/10<sup>th</sup>. Observation of the macula, far from the papilla, allows precise monitoring of the repercussions of optic neuropathy.

# Toxic optic neuropathy

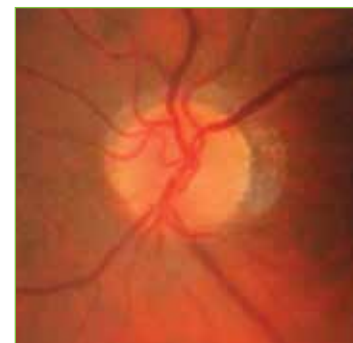
Toxic or nutritional optic neuropathies are suggested in the case of impairment, which is often bilateral, symmetrical and painless, classically associated with centrocaecal scotoma. OCT often reveals bilateral and gradual impairment of the RNFL <sup>32</sup>. As regards the peripapillary optical fibres, we note a purely temporal deficit with relative preservation of the upper and lower sectors.

## Apparent toxic optic neuropathy without papillary impairment

In the presence of associated papillary oedema, the aspect of the parapapillary fibres can appear normal because layer thickness is artificially increased by the oedema.



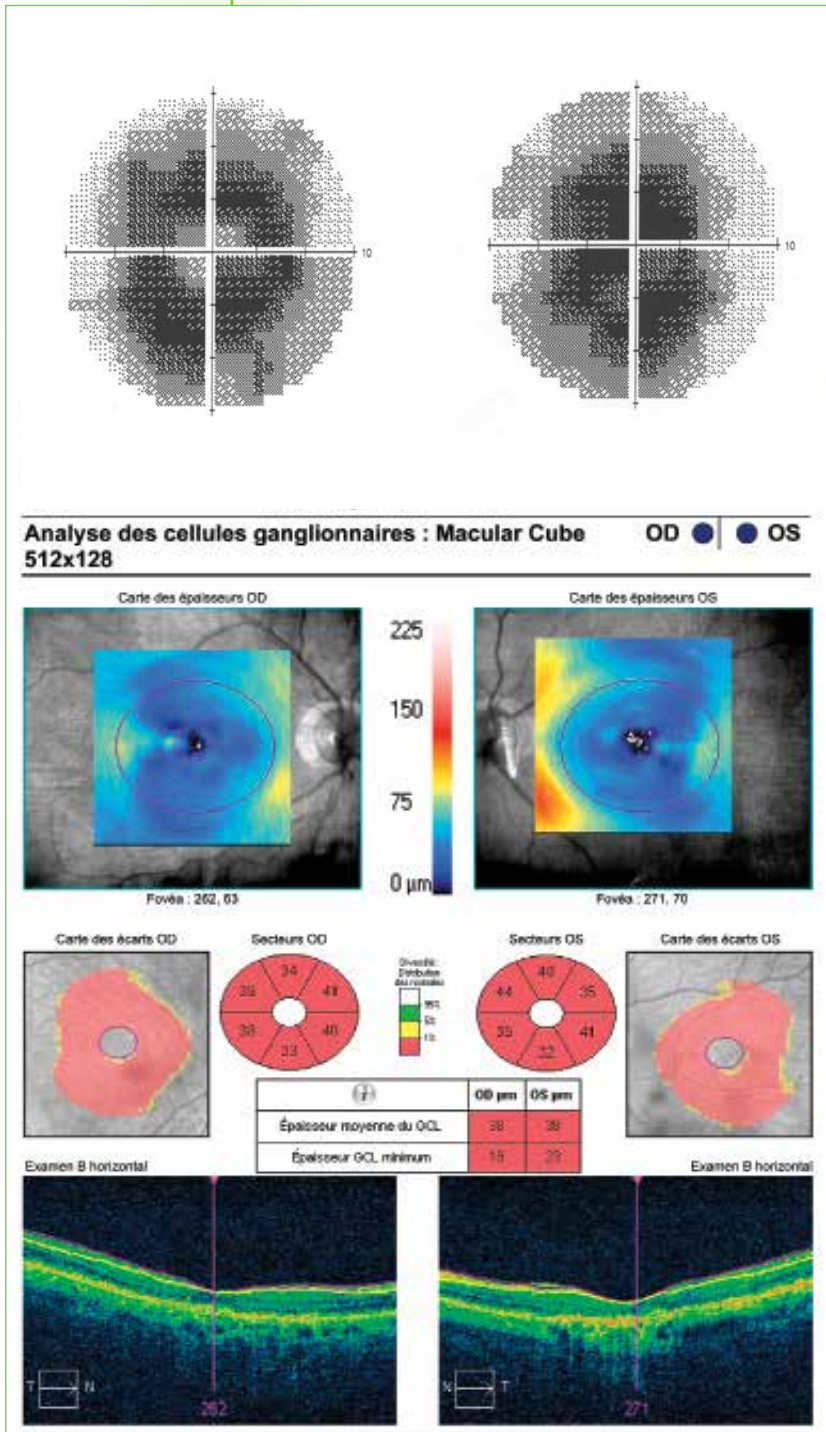
Right eye



Left eye

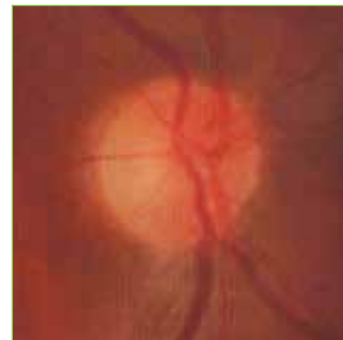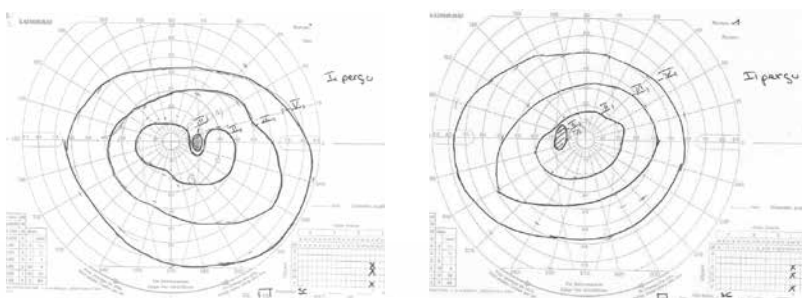
61-year-old male patient affected by optic neuropathy, undoubtedly associated with alcohol/nicotine. The optic nerves appear normal. The visual fields show bilateral centrocaecal deficit. OCT reveals papillary oedema. The RNFL appears normal because it is artificially increased due to oedema.

In the presence of associated papillary oedema, we find a contrast between two normal parapapillary optical fibres and major impairment of the ganglion cell complex.

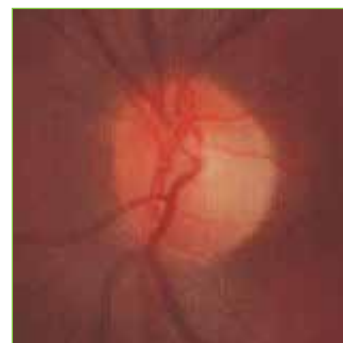

Same patient as on the previous page. OCT and central 10° visual fields. The central 10° visual field confirms central impairment. Macular OCT shows significant bilateral, symmetrical and homogeneous impairment.

## Toxic optic neuropathy with papillary and macular impairment

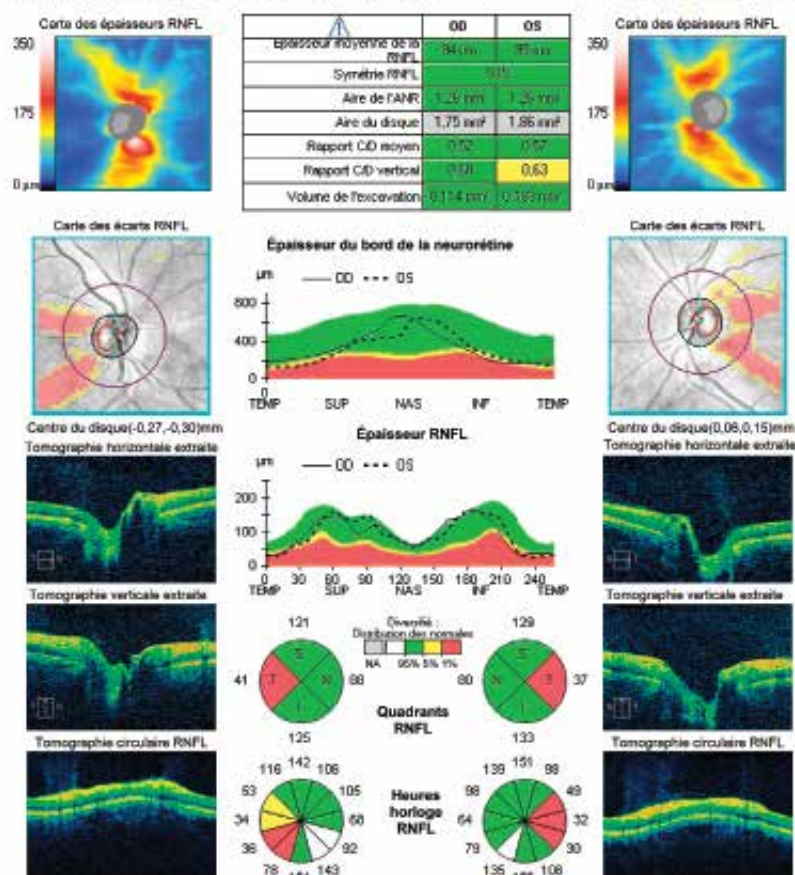


Right eye



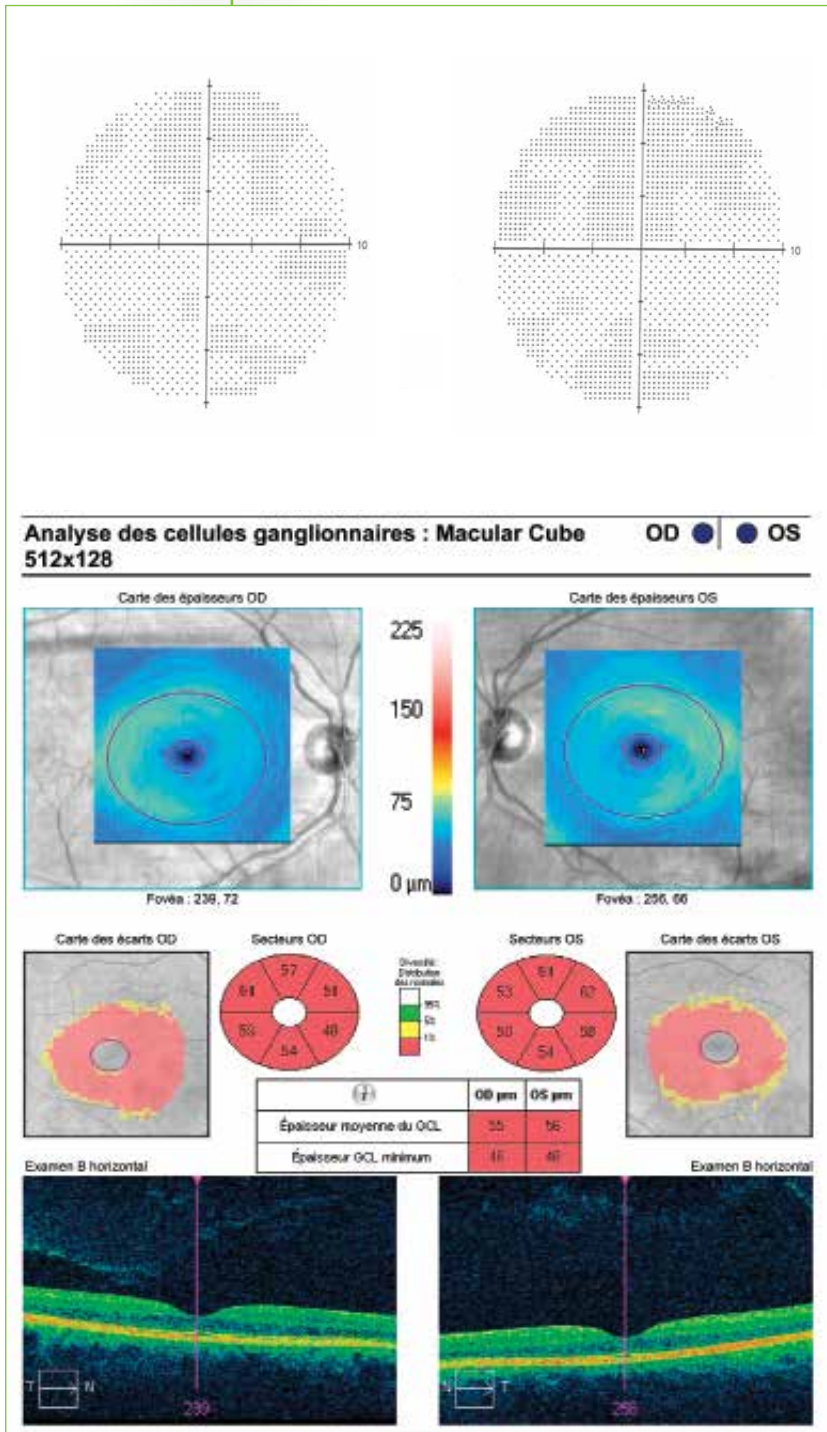
Left eye

### RNFL et ONH :Optic Disc Cube 200x200



42-year-old male patient affected by optic neuropathy, associated with alcohol/nicotine. The optic nerves are normal. Goldmann's visual fields show distortion of the blind spot on the right and a normal result on the left. OCT reveals typical impairment after bitemporal impairment. The upper and lower sectors are not affected. There is no pathological excavation.

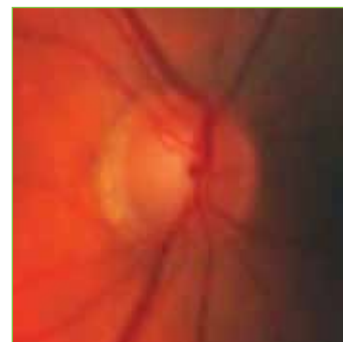
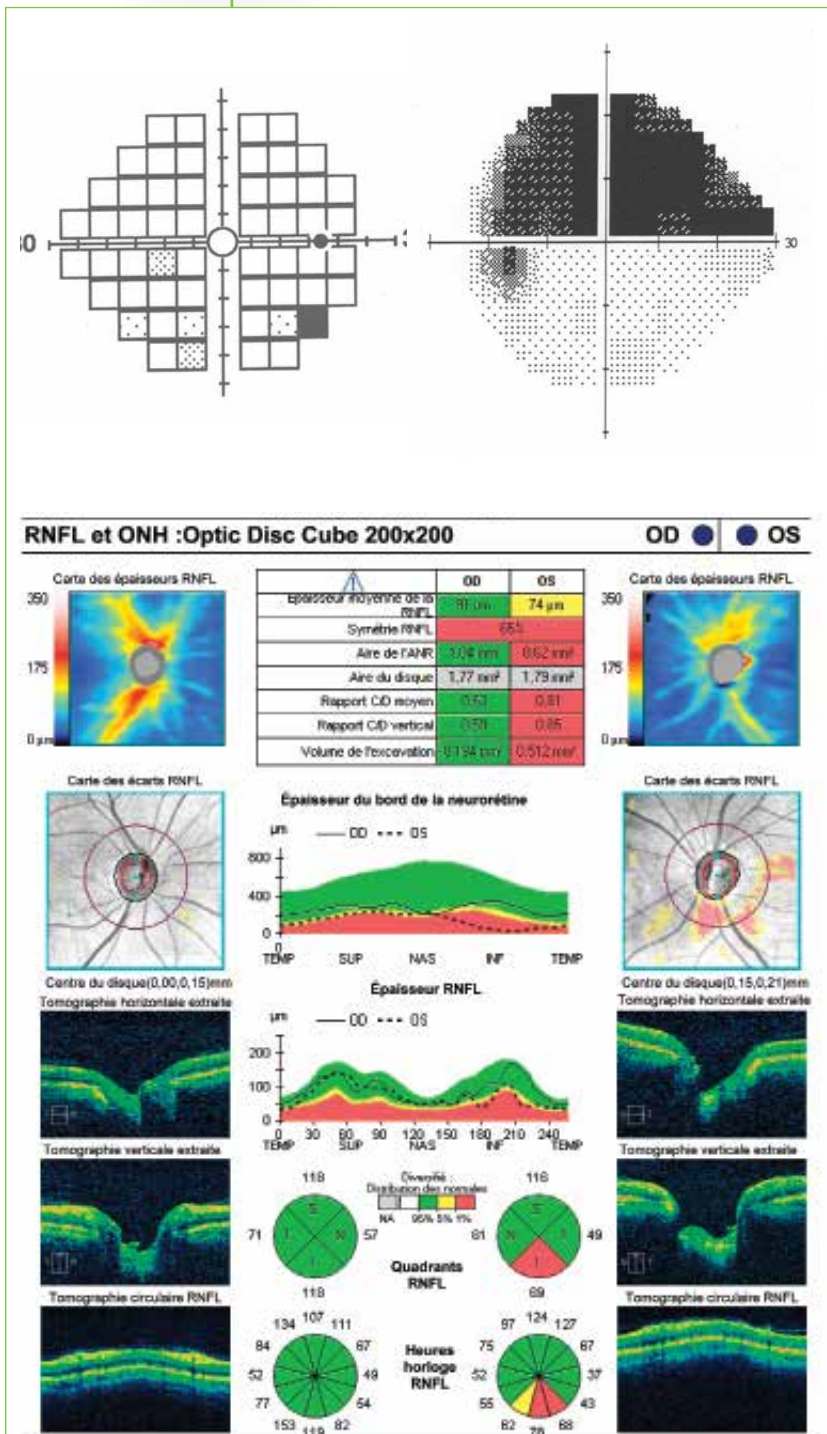
In incipient toxic optic neuropathies, impairment can be more evident in the macular ganglion cells, even in the case of preserved visual acuity. In general, it is diffuse and symmetrical.



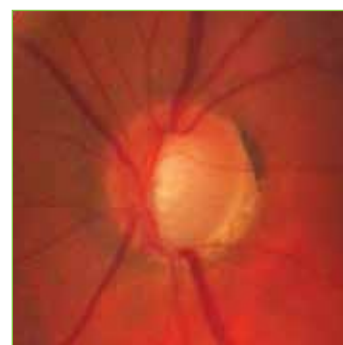Same patient as on the previous page. OCT and central 10° visual fields. Slight diffused deficit of the central 10° visual field present on both sides. Macular OCT shows significant bilateral, symmetrical and homogeneous impairment. This aspect suggests toxic NORB.

# Anterior ischaemic neuropathy

It is sometimes difficult to distinguish remote sequelae of anterior ischaemic optic neuropathy (AION) and glaucoma using OCT. Impairment of the RNFL is temporal in both cases<sup>33</sup>. The OCT deficit in AION is more altitudinal than in glaucoma, affecting not only the lower temporal sector (7hr for the right eye, 5hr for the left eye), but describing more extensive impairment<sup>34</sup>. One can also expect that the excavation volume is smaller in AION<sup>35</sup>.



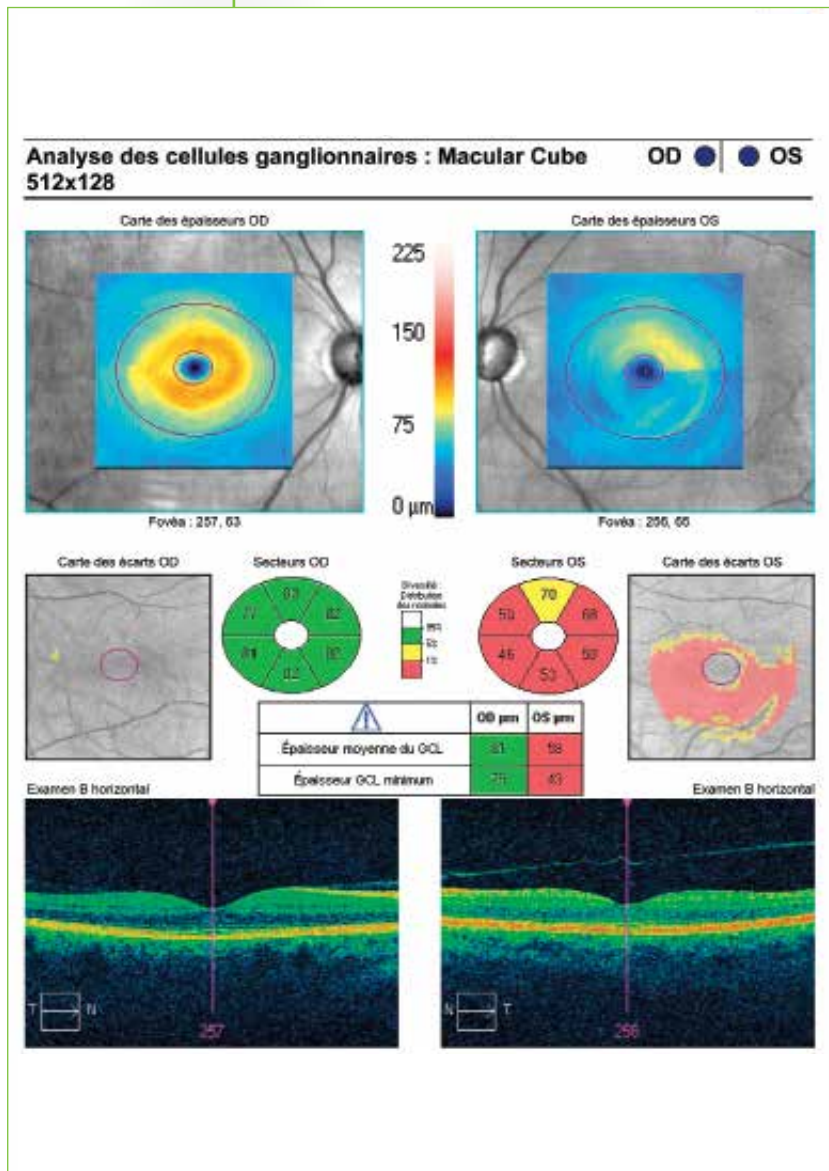
Right eye



Left eye

63-year-old female patient, hypermetropic, affected 1 year earlier by anterior ischaemic neuropathy in the left eye. The visual field of the right eye is normal, while that of the left eye shows superior altitudinal deficit, which is characteristic of this pathology. OCT is coherent with this unilateral impairment and also shows secondary excavation on the left.

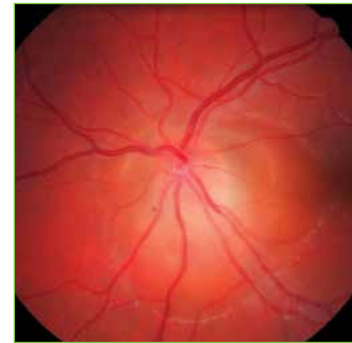
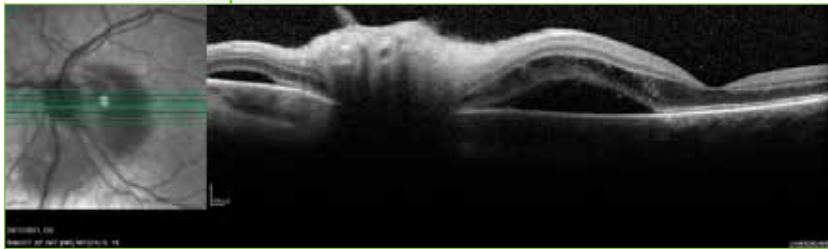During an acute phase of AION, initial papillary oedema causes spectacular increase of parapapillary optical fibre thickness, while the ganglion cell layer is not altered.



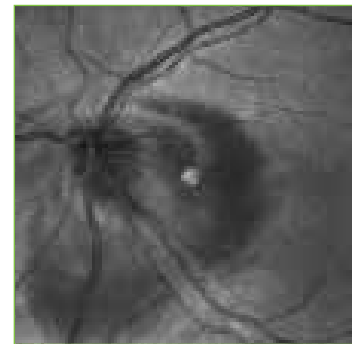
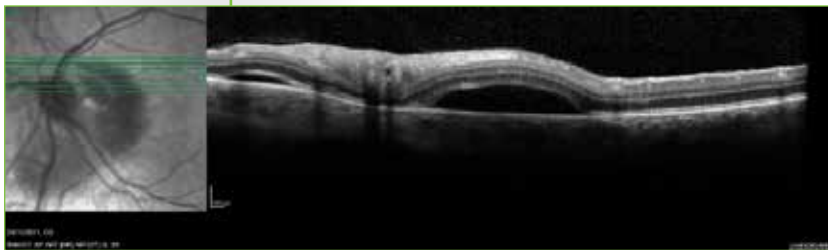
Same patient as on the previous page. Macular OCT shows global impairment of the left eye. This aspect could not be more typical because one would expect a more altitudinal deficit here.

## Optic neuropathy and uveopapillitis

Inflammatory optic neuropathies within the framework of uveopapillitis initially cause significant increase of the optical fibre layer, prior to secondary atrophy in half of the cases<sup>36</sup>. OCT allows detection of the oedema and intra and subretinal localisation.



Right eye



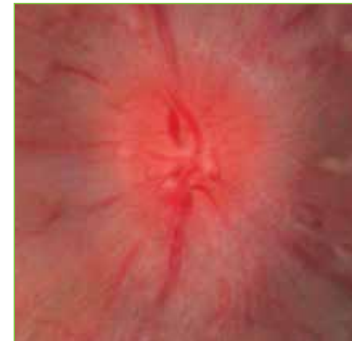
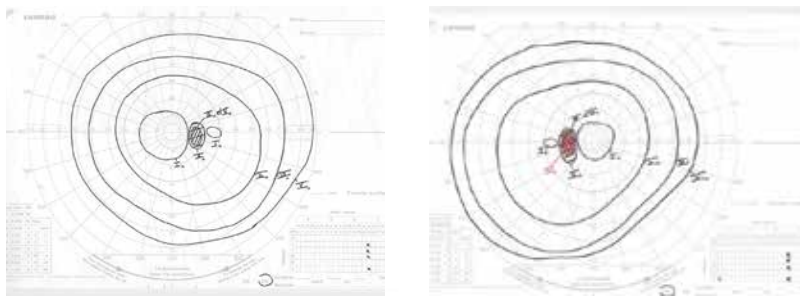
Left eye

*Left unilateral uveopapillitis, of toxoplasmic origin probably, in a 19-year-old woman. In the best case, OCT allows determination of the importance of papillary oedema and clarifies the importance of associated subretinal oedema and its proximity in relation to the fovea.*

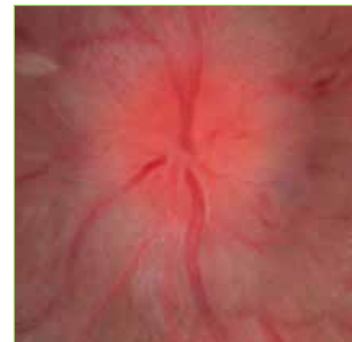

# Papilla oedema

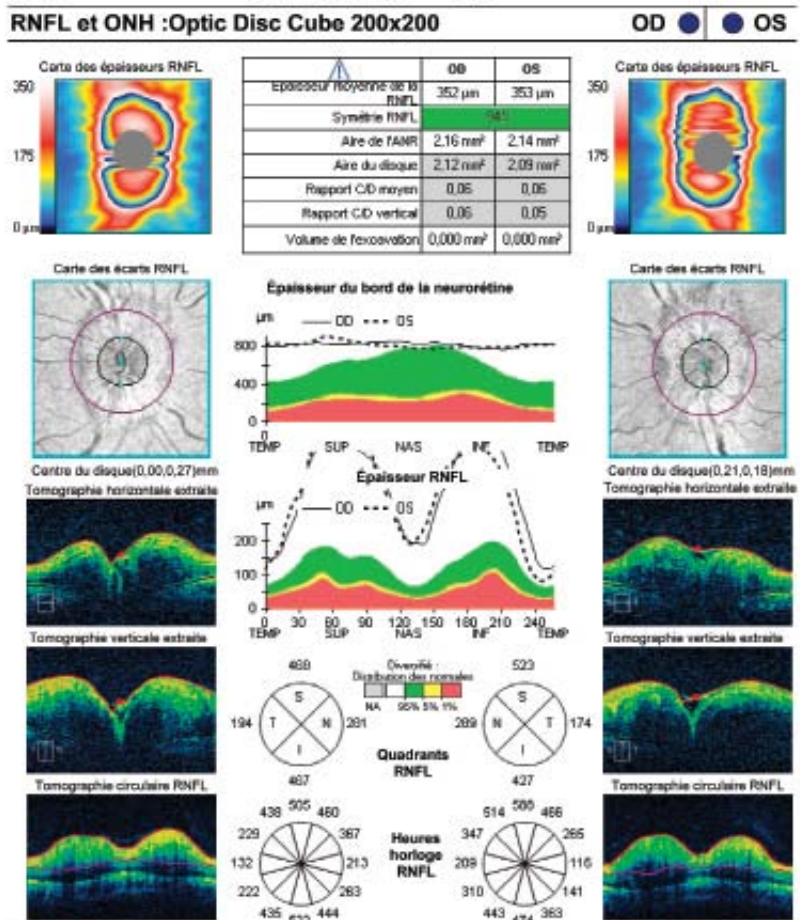
Papillary oedema, whatever the cause may be, is responsible for spectacular increase of the optical fibre layer because OCT measures this layer in a non specific way. During regression of oedema, the RNFL will appear reduced, indicating the sequelae of the papillary oedema. The kinetics of the impairment is therefore essential. The speed of appearance of sequelar deficits depends on the aetiology of the oedema.



Right eye



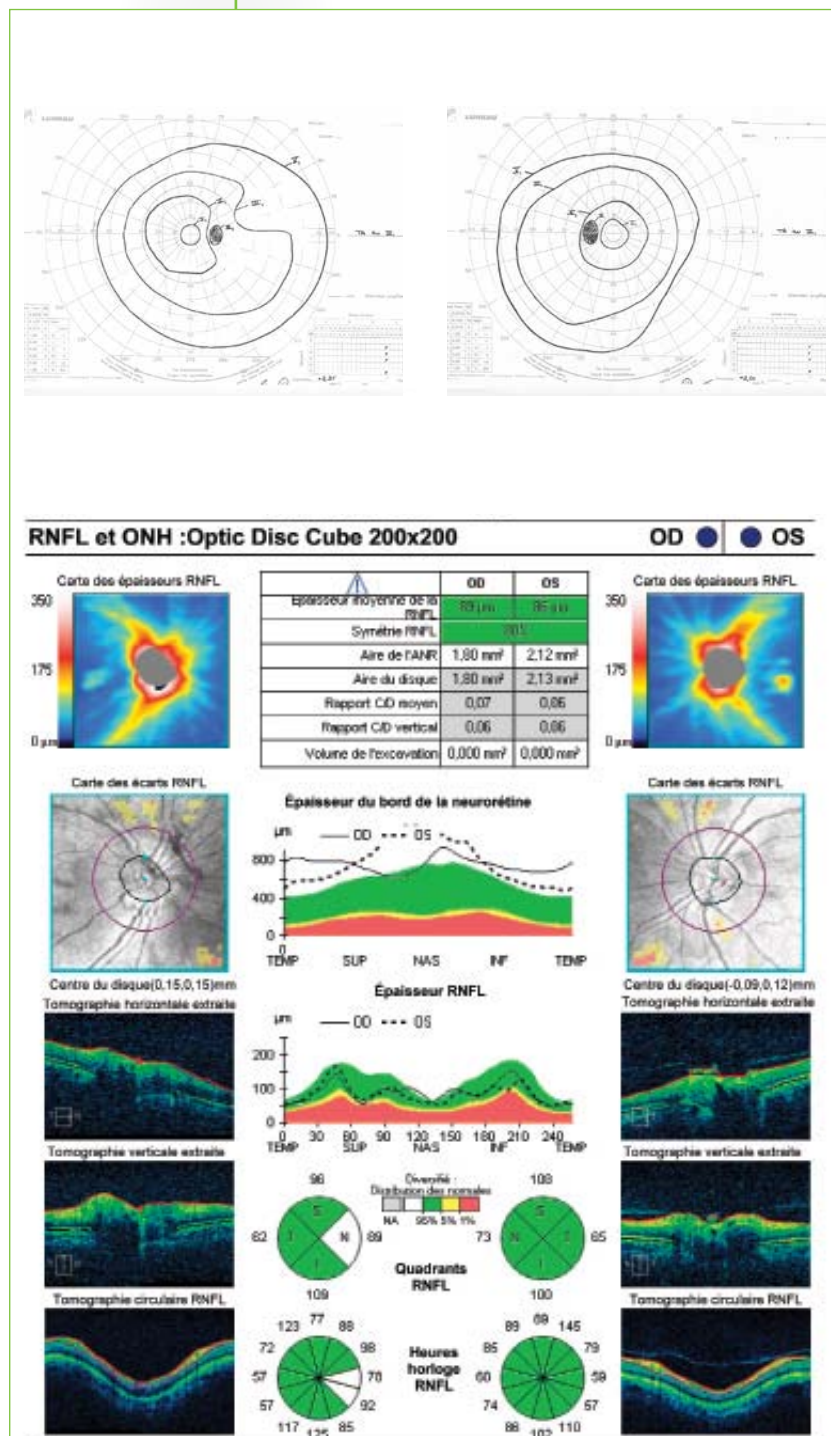
Left eye



20-year-old male patient with intracranial hypertension due to an expansive intracranial process. OCT reveals an increase in volume of the optic nerve and RNFL thickness. Monitoring of the parameters of this layer allows measuring the evolution of this oedema.

## Lone oedema of the papilla, without retinal diffusion

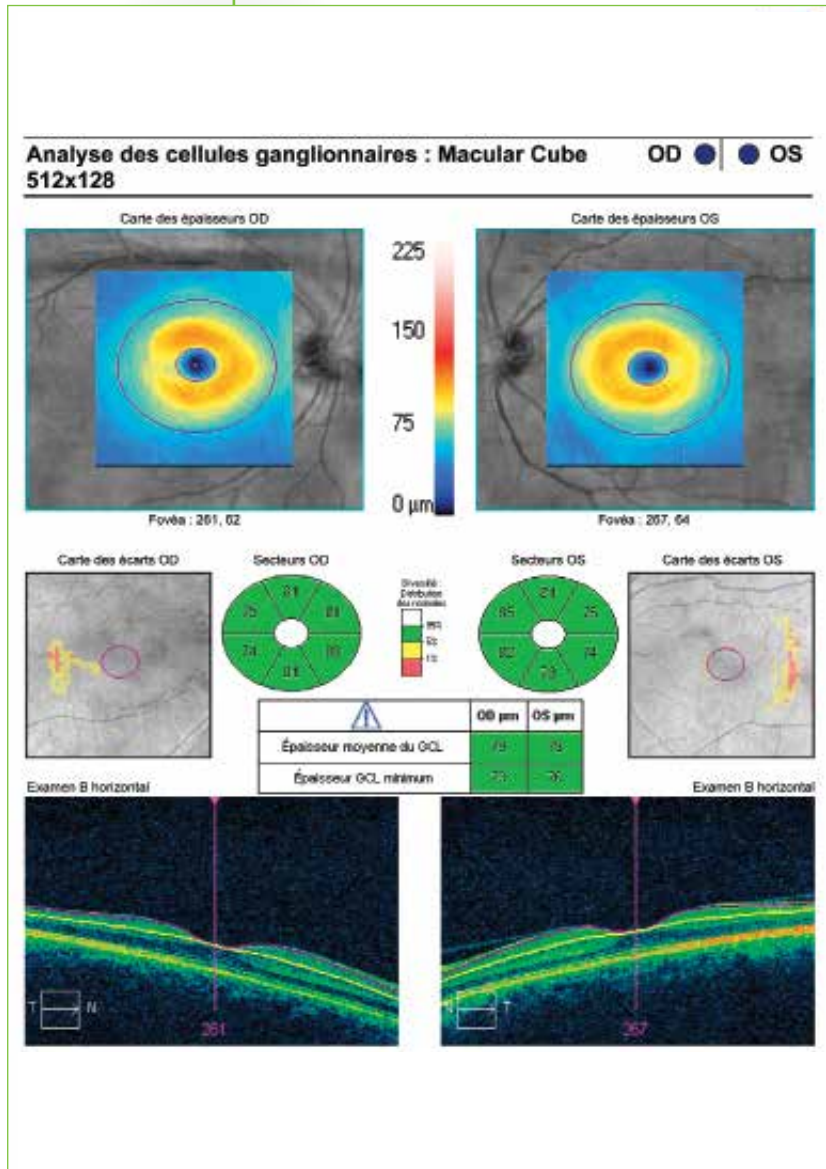
In cases of lone oedema, the optic nerve parameters describe an increase of the volume of the optic nerve, while the RNFL is normal. Nevertheless, a normal thickness can be the consequence of oedema associated with incipient optic atrophy. Long term assessment is necessary.



54-year-old female patient with intracranial hypertension

OCT reveals an increase in the volumes of the optical nerve without associated retinal impairment.

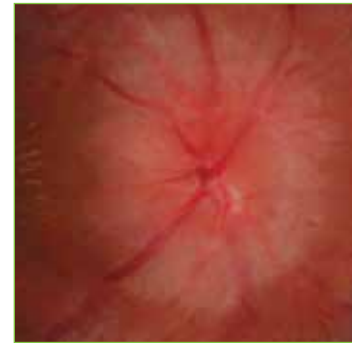
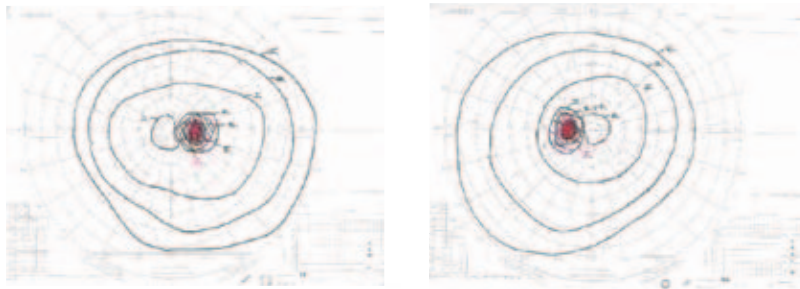
The absence of optic fibre impairment is rather a good prognosis in the case of macular oedema. A new assessment of the acute episode will allow confirming the stability of the results.



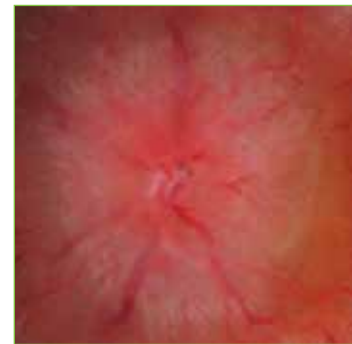
Same patient as on the previous page. Macular OCT is normal.

## Papillary oedema with subretinal oedema

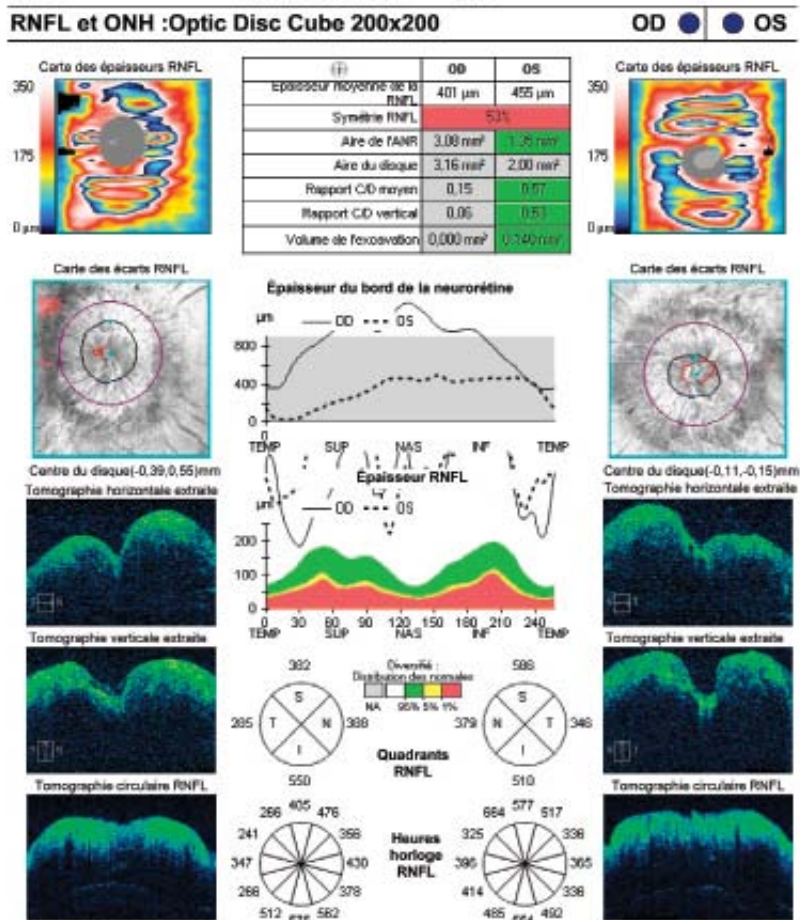
It is important to note that there is no associated subretinal oedema because, in this case, we can predict improvement of the visual function during regression. If the oedema is not subretinal, recuperation will be weaker. OCT allows distinguishing intra and subretinal oedema in the parapapillary region easily.



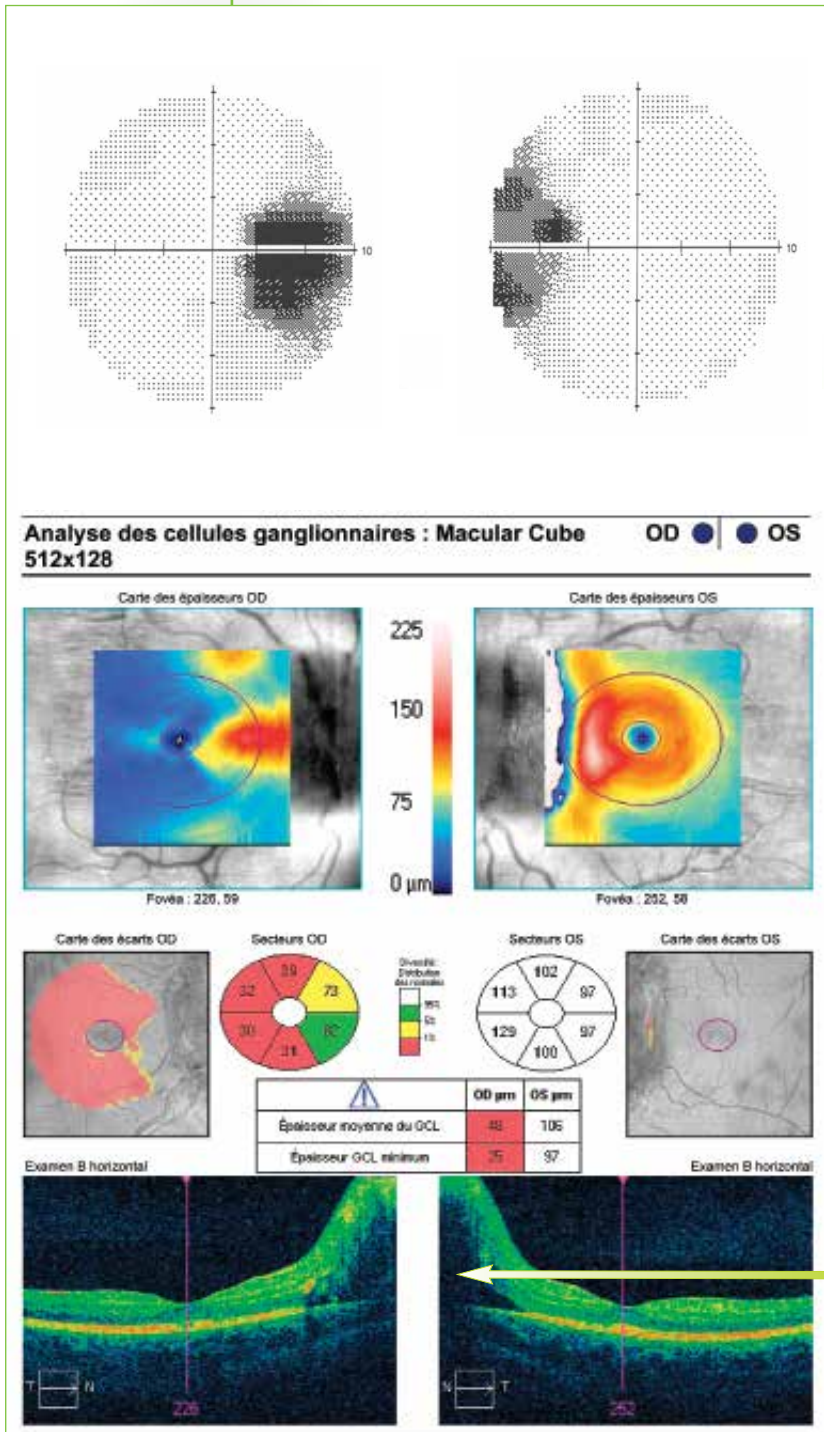
Right eye



Left eye



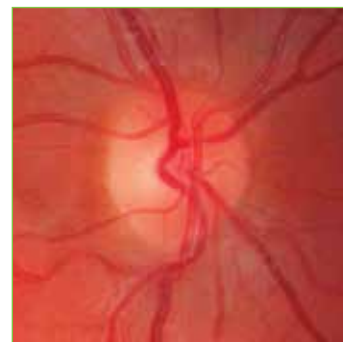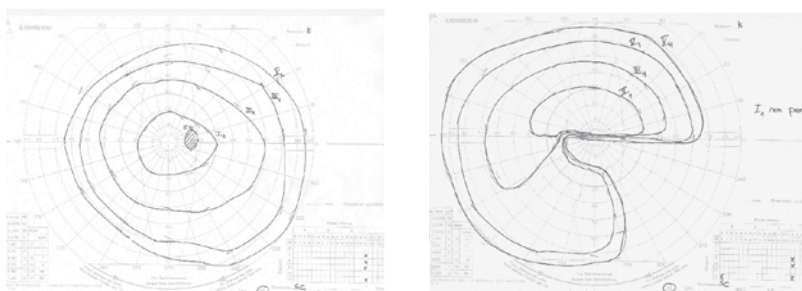
23-year-old female patient with discreet reduction of visual acuity of unexplained origin. The ocular fundus reveals bilateral papillary oedema and the visual fields reveal enlargement of the blind spot on both sides. OCT reveals an increase of RNFL thickness. The absence of optical fibre impairment is associated with this oedema.



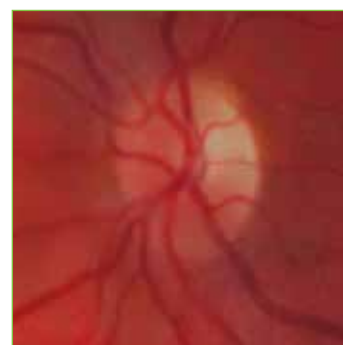Same patient as on the previous page. OCT and central 10° visual fields. In the macular region, the ganglion cell complex is already altered on the right. On the left, this impairment is hidden by oedema. We note the absence of good prognosis of subretinal oedema.

# Optic nerve compression

In the case of optic nerve compression, purely unilateral compression is present. The optic nerve is sometimes difficult to examine because optic atrophy can be accompanied by secondary excavation. Therefore, a glaucomatous hypothesis is sometimes mentioned.

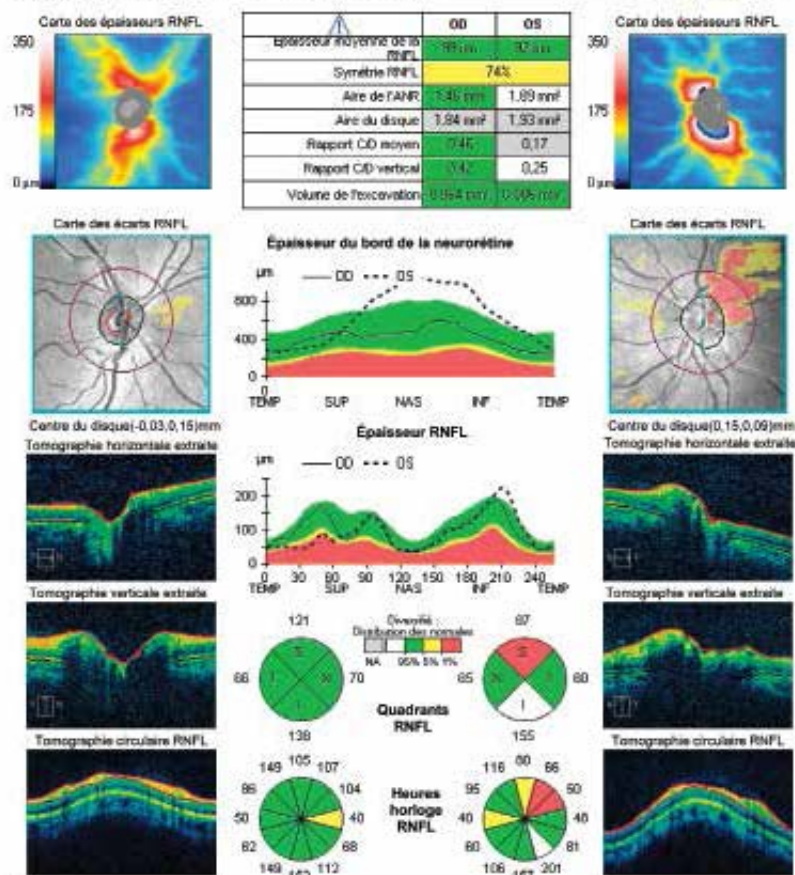


Right eye



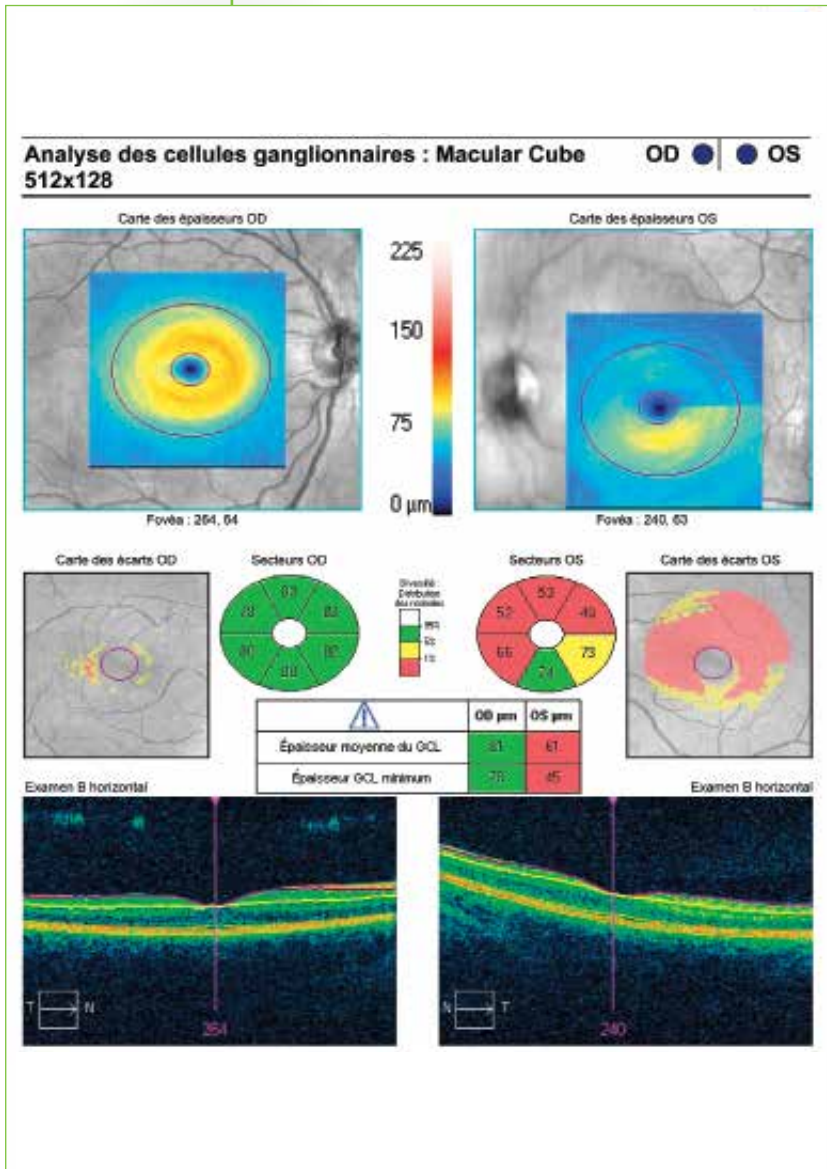
Left eye

## RNFL et ONH :Optic Disc Cube 200x200



23-year-old female patient affected by glioma in the left optic nerve. Impairment is purely unilateral, underlining the absence of compression in the other eye. Although the optic nerve gives the impression of excavation, this is not confirmed by OCT.

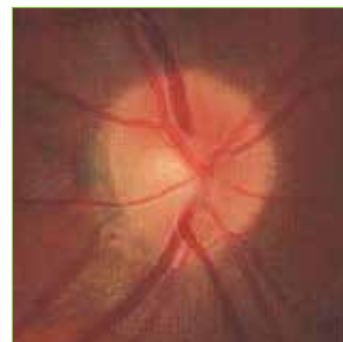

In the case of optic nerve compression, the normality of the contralateral eye allows to define the purely localised repercussion of this compression.



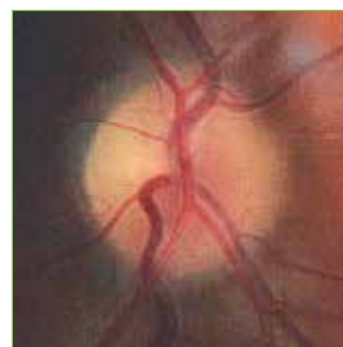
Same patient as on the previous page. Diffused and lone macular impairment of the left eye is observed.

# Chiasma impairment

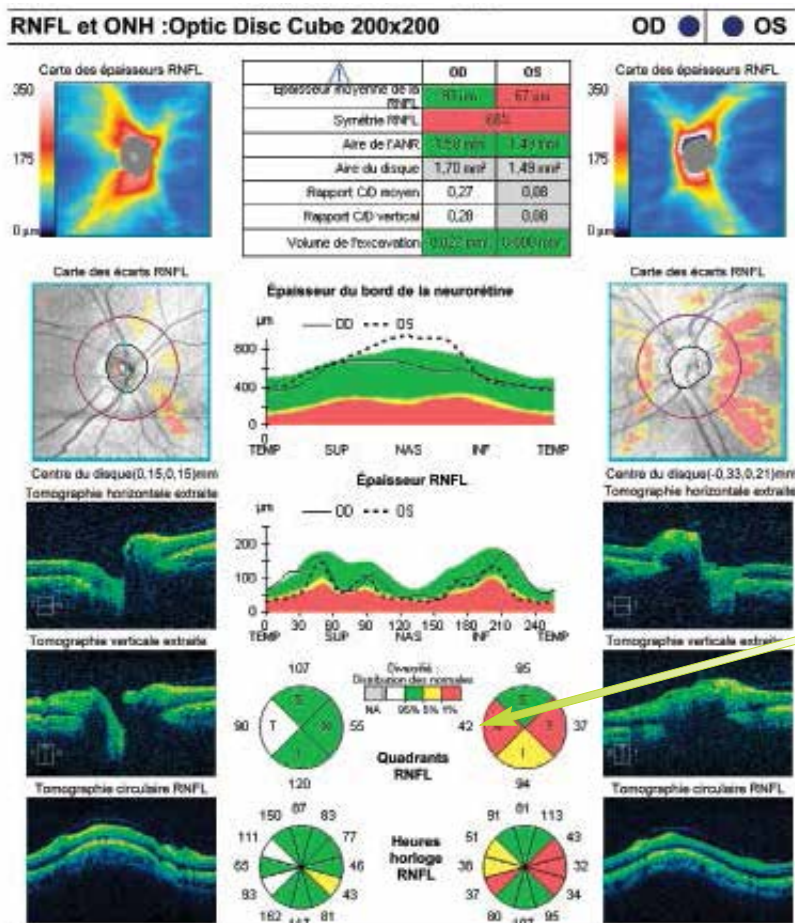
In the case of chiasma impairment, visual field and OCT lesions are present. After surgery, a favourable functional recuperation factor is the fact that, in the affected zone, the RNFL thickness of at least 80  $\mu\text{m}$  <sup>37</sup> is maintained. Even if the thickness is smaller, in general, improvement is observed after the operation. In compressive neuropathies, the volume of the optical fibre layer is thus an indicator of the probability of regression of the clinical indications after surgery. The greater the thickness of the fibres prior to treatment, the better recuperation will be.



Right eye



Left eye

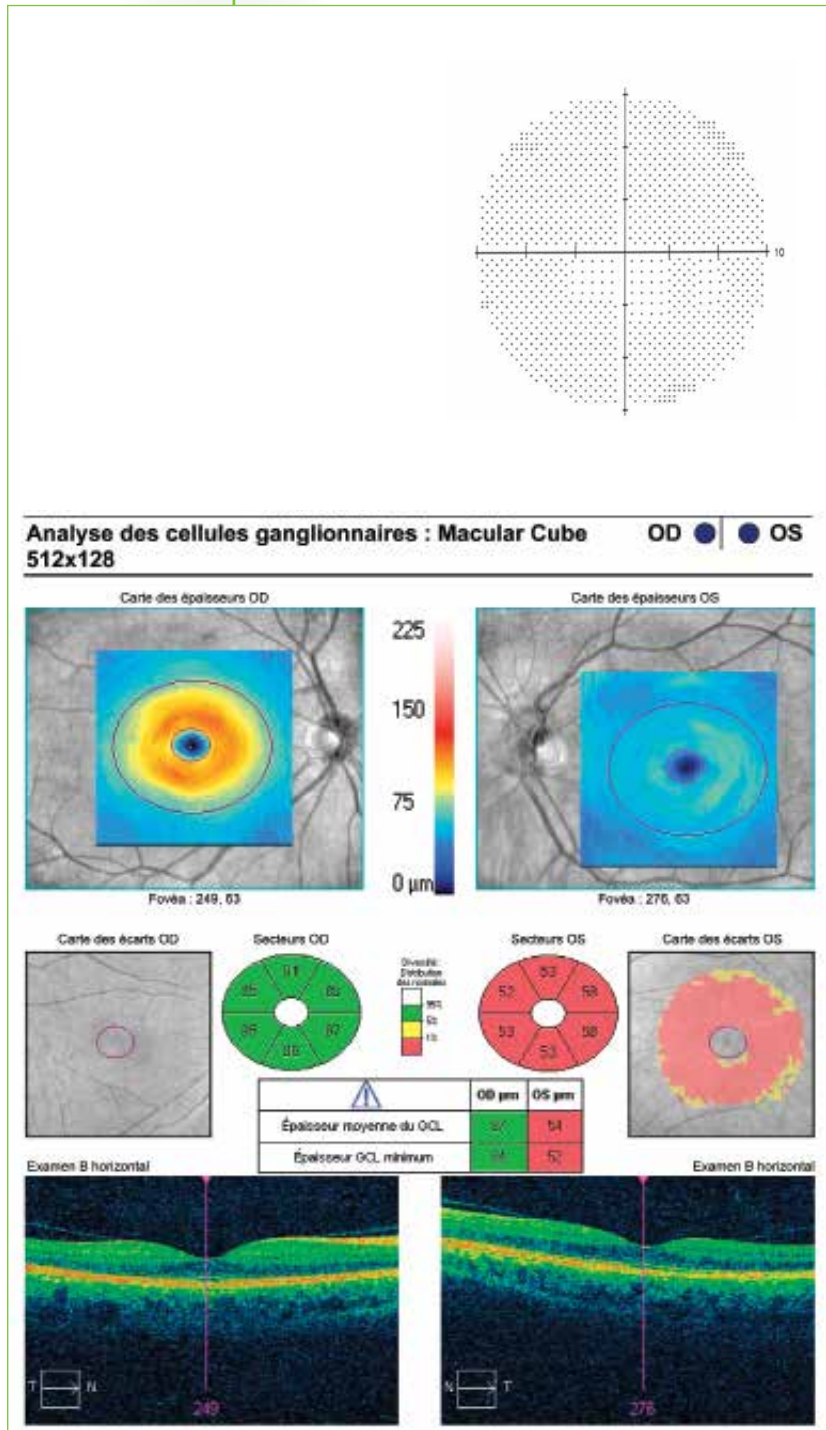


Female patient affected by prechiasmatic meningioma compressing the left optic nerve mainly. Acuity on the right is normal and on the left lower than 1/20<sup>th</sup>. The optic nerve is normal on the right and slightly pale on the left. OCT of the optic nerve head shows nasal and temporal impairment with very small fibre thickness (42  $\mu\text{m}$  and 37  $\mu\text{m}$ ). There is no excavation.

While Goldmann's visual field testing appears to show the beginning of impairment on the right, OCT remains normal.



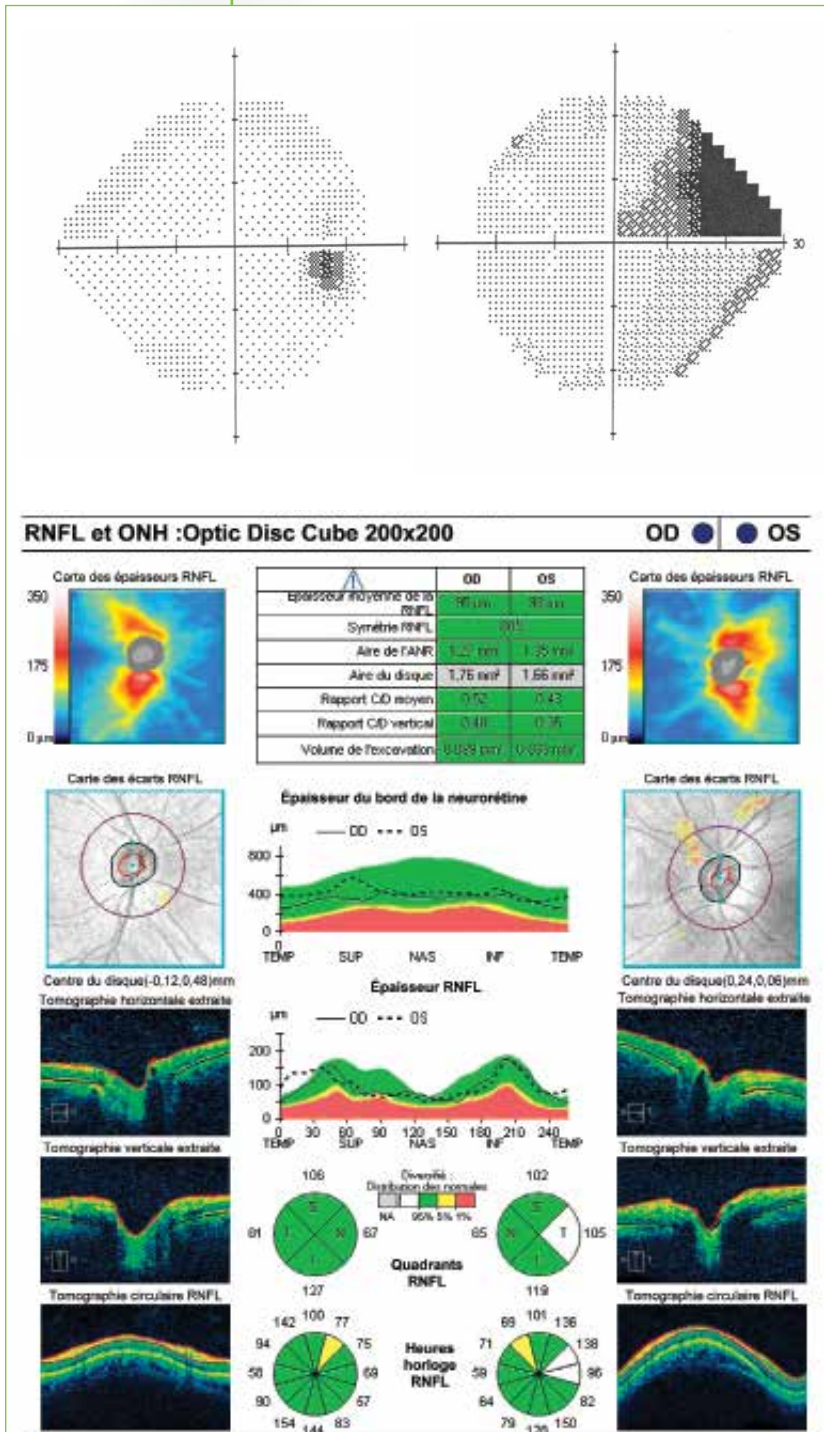
The RNFL is not always affected at an early stage in optic nerve or chiasma compression, an alteration of the visual field sometimes being the first sign of impairment. This constitutes one of the rare cases where the absence of fibre impairment does not indicate a healthy situation.




Same patient as on the previous page. Diffused and lone macular impairment of the left eye is observed. In the case of compression, this diffused character is usually observed.

# Amblyopia

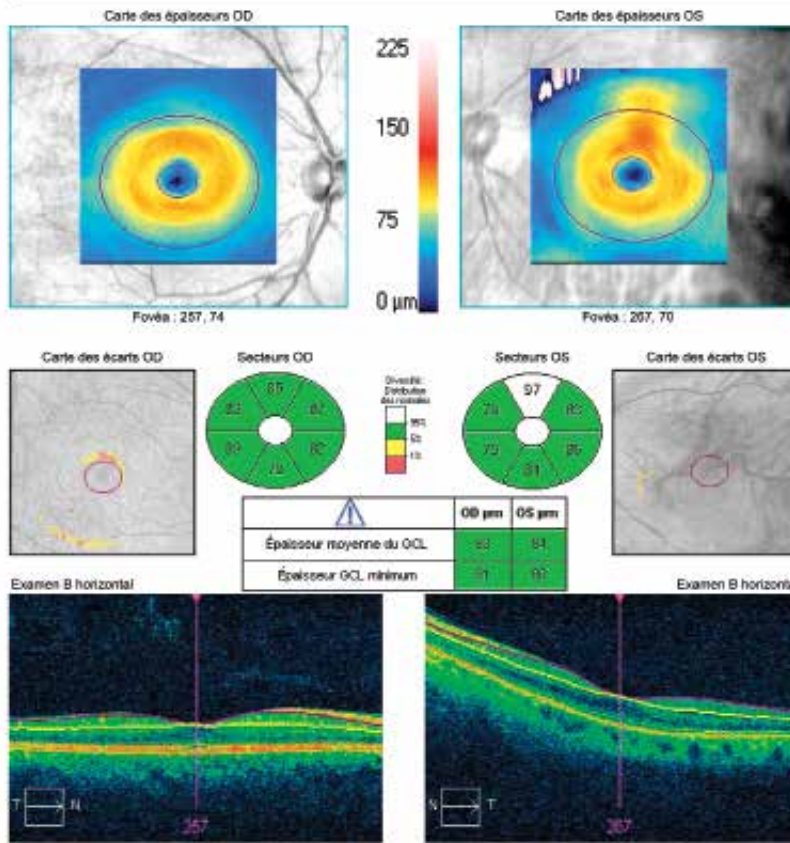
Amblyopia is expressed by a lowering of visual acuity in the relevant eye. The ganglion cells are not functional from a morphoscopic point of view, but they are still present. OCT only appears slightly modified in this situation.



48-year-old female patient with amblyopia in the left eye (visual acuity 2/10<sup>th</sup>). Visual field testing shows nasal deficit of inexplicable origin. Peripapillary OCT is normal, as are the optic nerve parameters.

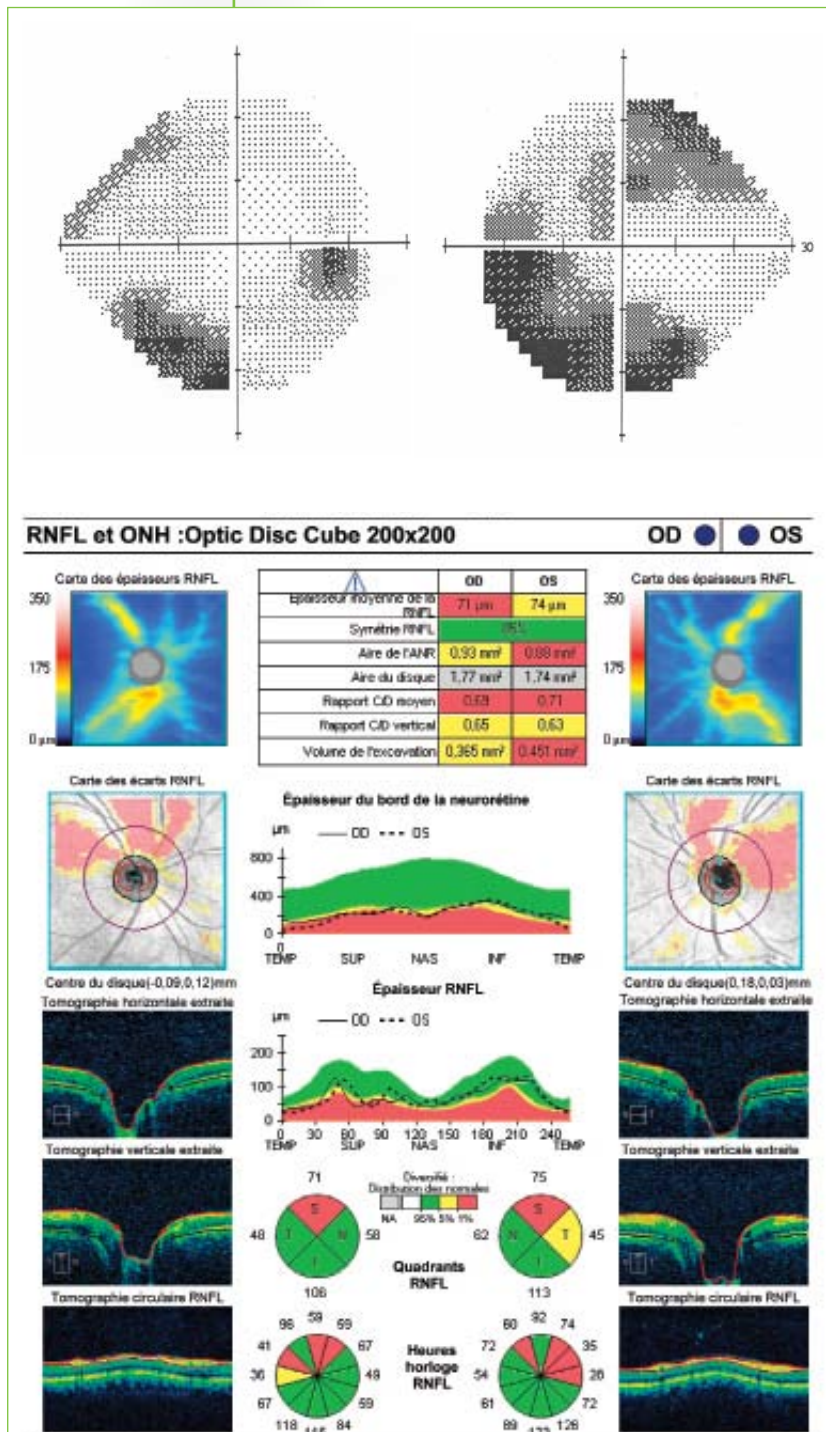


**Analyse des cellules ganglionnaires : Macular Cube 512x128**      OD ● | ● OS

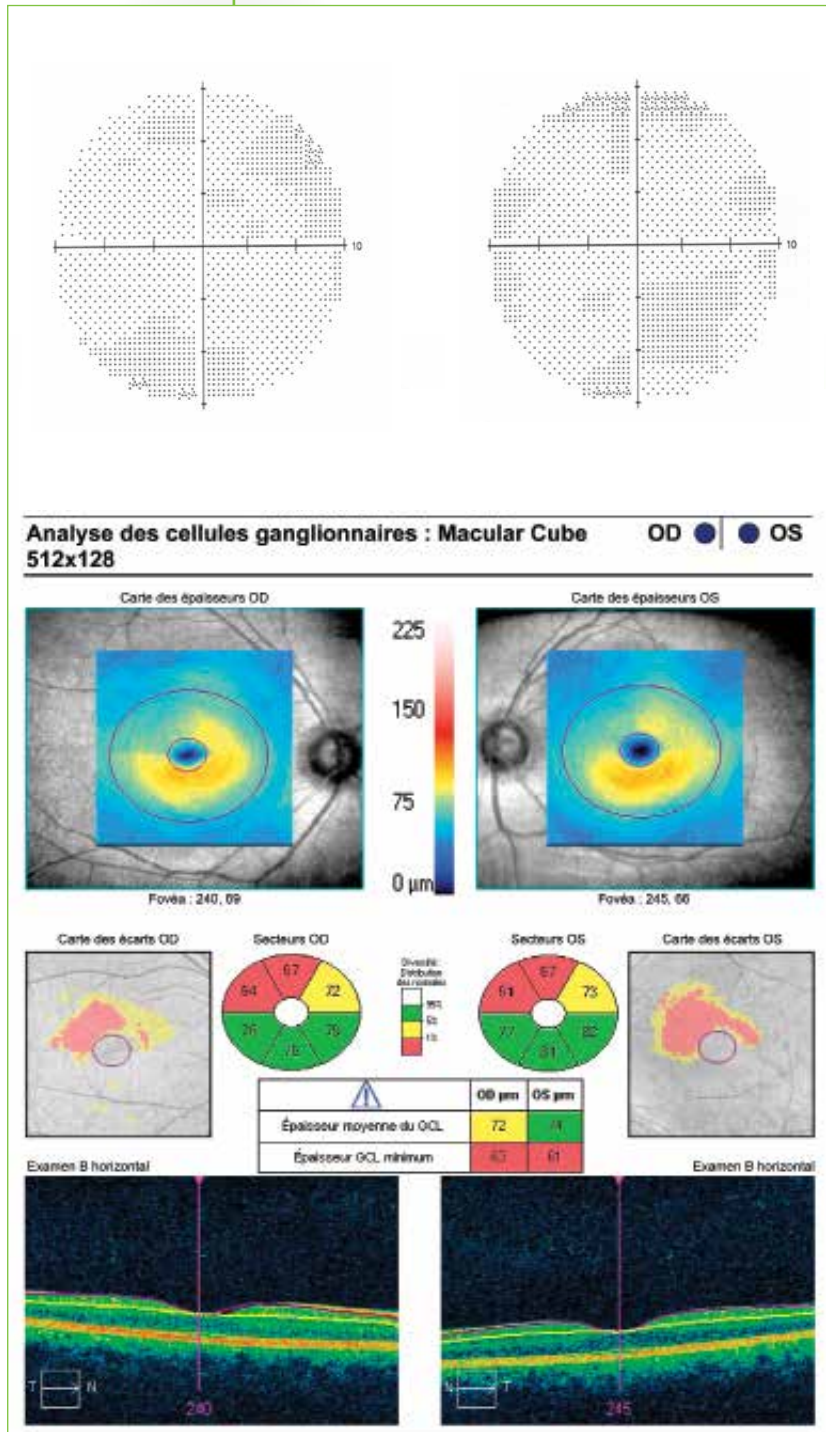


Same patient as on the previous page. OCT and central 10° visual fields. The central visual field of the left eye shows diffused deficit consistent with 2/10<sup>th</sup> acuity. OCT is normal.

One would think that reduction of the optic fibre layer can only be found in the case of direct impairment of such cells, in the cell body or the axon. It appears that even a lone occipital cortex lesion can be expressed by homonymous lateral reduction of optical fibres in OCT. This was initially evidenced for congenital or perinatal pathologies. It is not certain whether this is the case for acquired lesions.

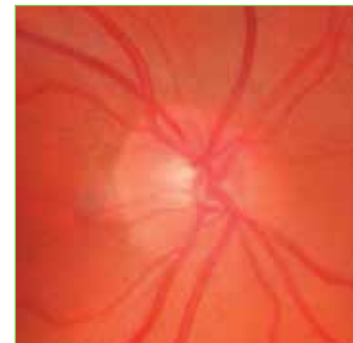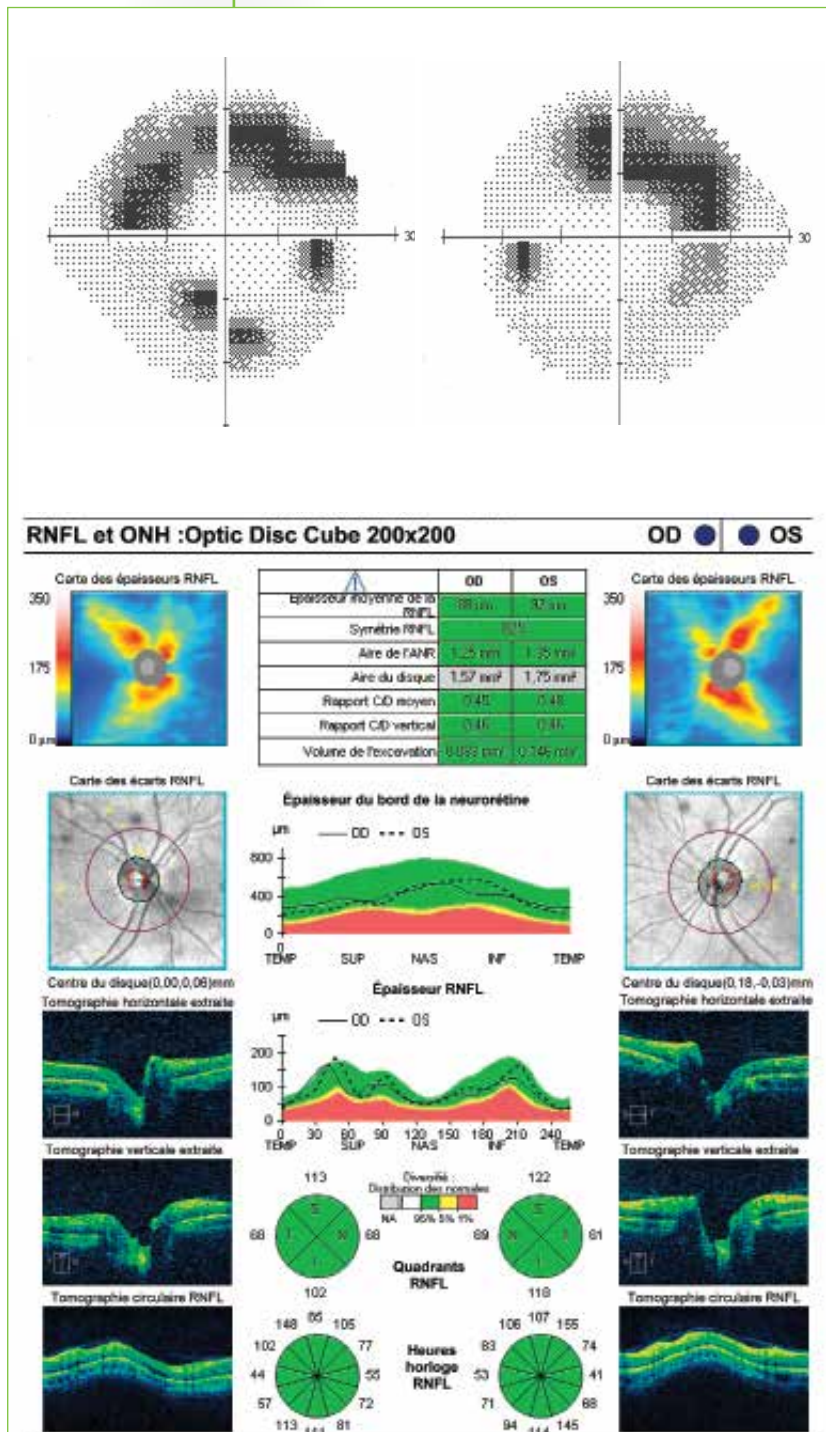


42-year-old female patient with sequelae of epilepsy and slight mental retardation associated with perinatal injury. The visual field is irregular with lower homonymous lateral deficit. The optic nerves are normal. Although this is central pathology, the OCT of the optical fibres is affected.

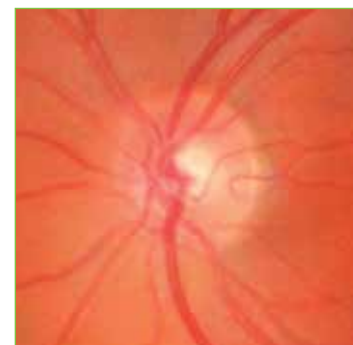

Same patient as on the previous page. OCT and central 10° visual fields. The central visual field is irregular and macular OCT shows bilateral impairment.

Visual repercussions of lone impairment of the central nervous system in adults is expressed by much more important alteration of the visual field than OCT. Nevertheless, the OCT might be affected by transsynaptic degeneration from the occipital lobe to the optic nerve<sup>38</sup>.



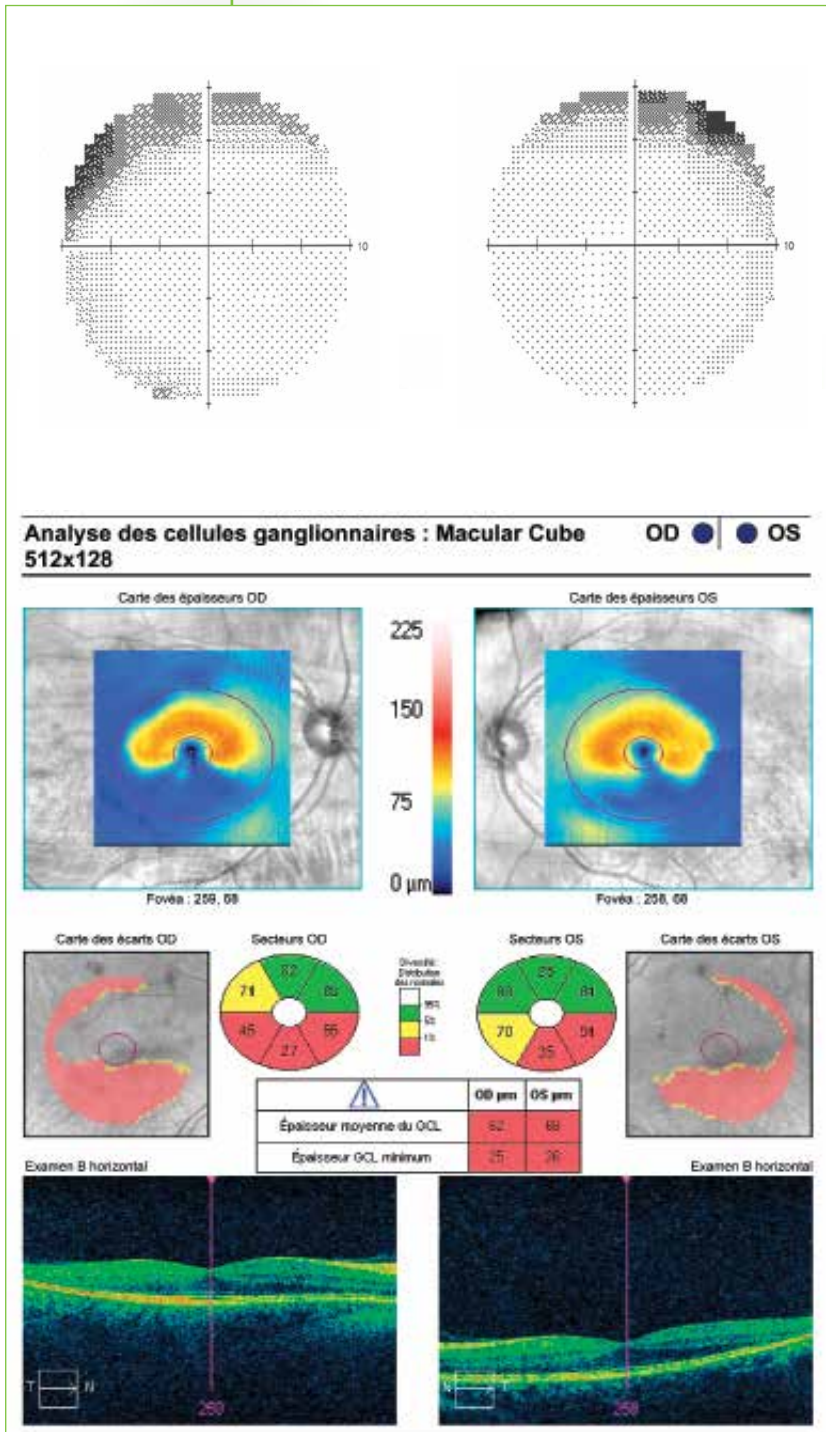
Right eye



Left eye

49-year-old female patient. The visual fields show inexplicable and relatively symmetrical bilateral deficit in the upper field. OCT is normal. The optic nerves also appear clinically normal.

OCT is thus very helpful when it is normal. With a lowering of visual acuity or impairment of the visual field, confirmation of the absence of retina destructuring in OCT allows confirming a neuro-ophthalmological cause for the symptoms.

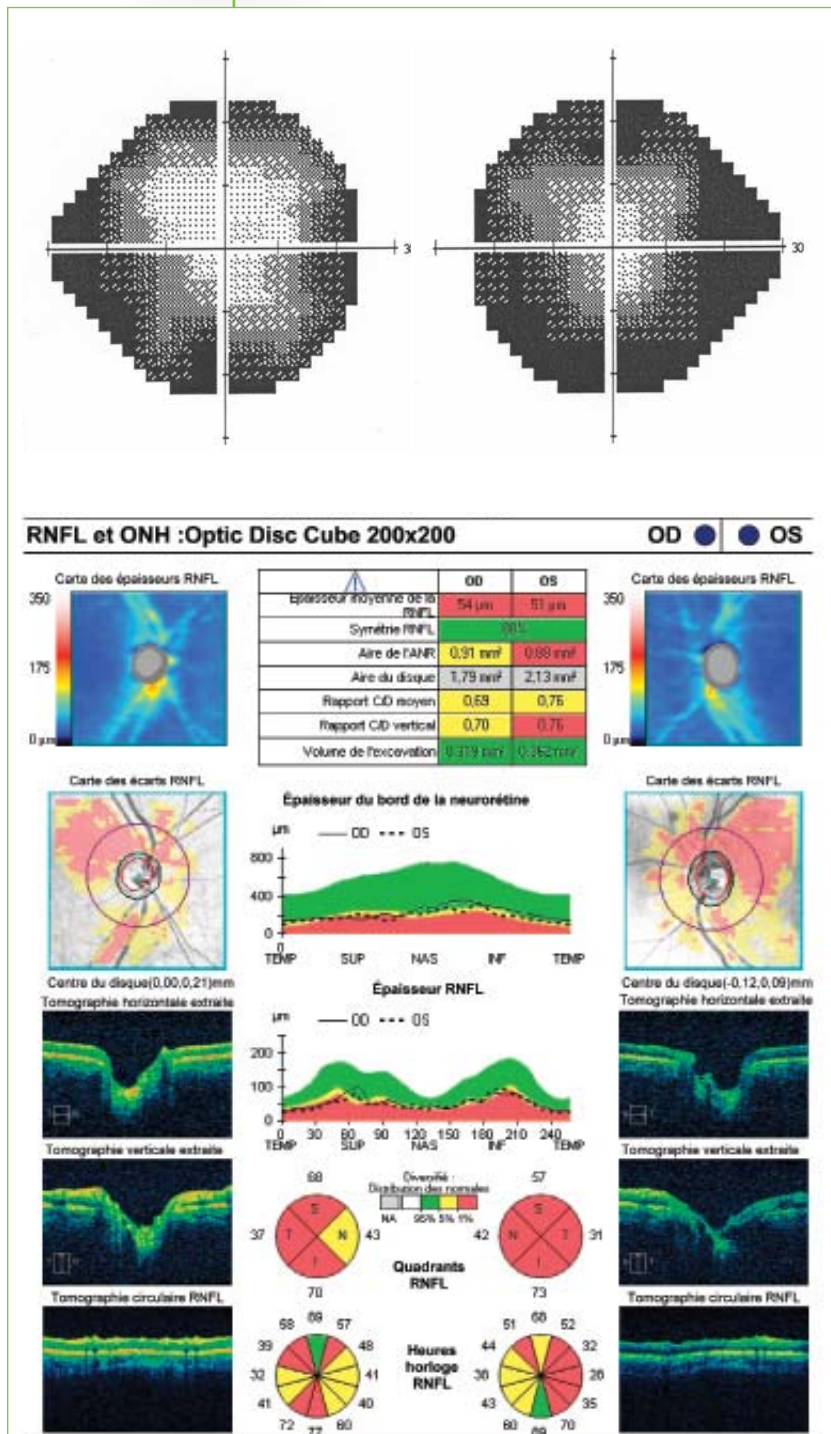


Same patient as on the previous page. OCT and central 10° visual fields.

Minor impairment of the ganglion cell complex is in contrast with the importance of the perimetric deficit. A central origin remains the most probable aetiology.

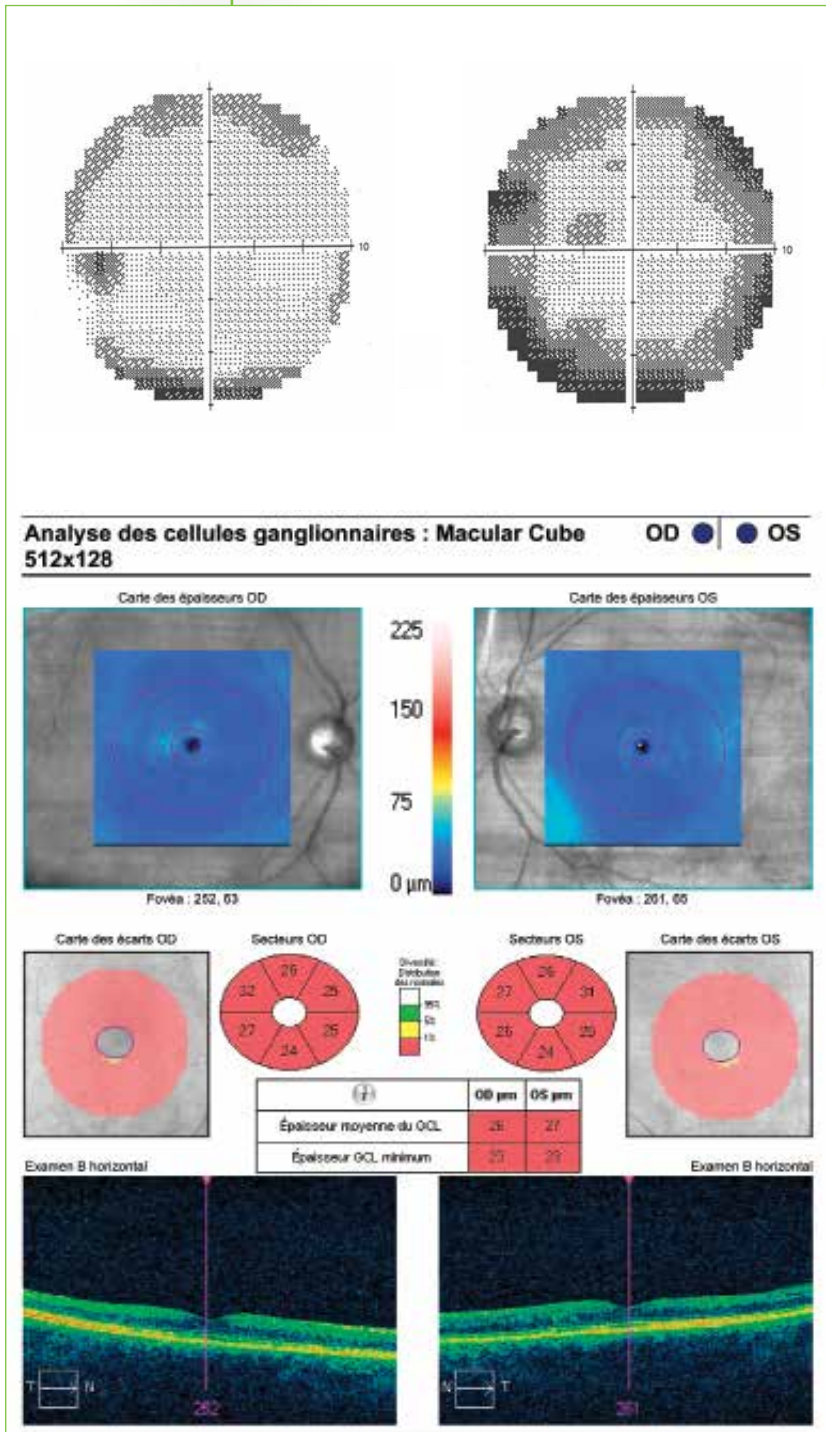
In many situations it is difficult to establish the organic origin of important functional symptoms. This is the case for post cranial trauma, perimetric deficit of hysteric origin or ill-defined pathologies.

OCT allows definition of the organic or non organic character of this functional complaint.



60-year-old male patient complaining about 6/10<sup>th</sup> reduction of visual acuity after general anaesthesia. The visual fields show inexplicable bilateral centro-caecal deficit. Neuropathy due to low choroidal debit is mentioned. OCT allows revealing major diffuse impairment of the RNFL, with-out excavation. The optic nerves appear clinically normal.





Same patient as on the previous page. OCT and central 10° visual fields. The ganglion cell complex is impaired significantly, thus confirming the organic character of the patient's complaint.

In more general pathologies such as Alzheimer's disease or Parkinson, we also observe a reduction of optical fibres in OCT. In certain cases, this reduction is diffuse and sometimes located in the superior region<sup>39</sup>.

In Alzheimer's disease, a reduction of the RNFL and the macular ganglion cell layer is observed, but this is not directly related with the level of cognitive functions.

In Parkinson's disease, a certain relationship between reduction of the optical fibre layer and the functional repercussions of Parkinson's disease has been found.



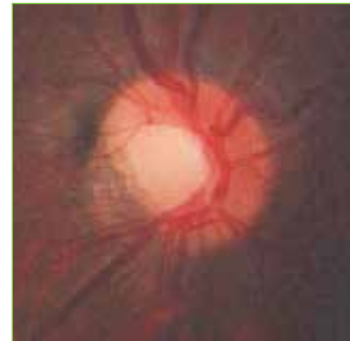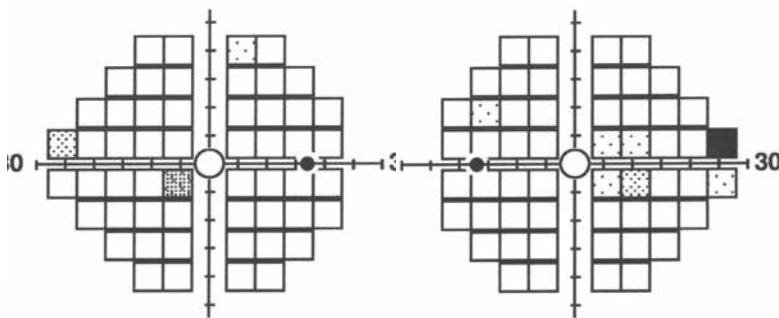


# Atypical aspects of the optic nerve that can suggest optic neuropathy in OCT

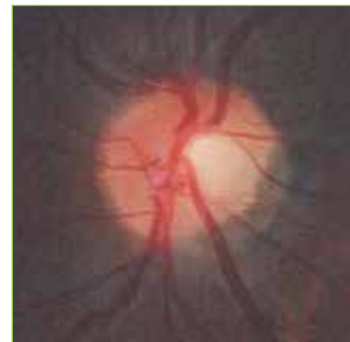Numerous atypical aspects of the optic nerve are responsible for the changes of papilla OCT. They can consider the default measurement methods and produce a wrong pathology result. OCT measures excavation in relation to a reference plane, arbitrarily set at 150  $\mu\text{m}$  below the level of the peripapillary pigment epithelium. If OCT cannot evaluate correctly the pigment epithelium, all the results can be wrong. This is why, papilla sections, indicating with a red point the theoretical start of excavation, are printed. Ophthalmologists can thus determine whether the points are placed in a consistent way.

# Myopia

Moderate myopia does not cause OCT modification. In the case of peripapillary atrophy, it should be ensured that the measurement made at 3.4 mm from the centre of the optic nerve is located outside this atrophy, in order to obtain good quality measurements.

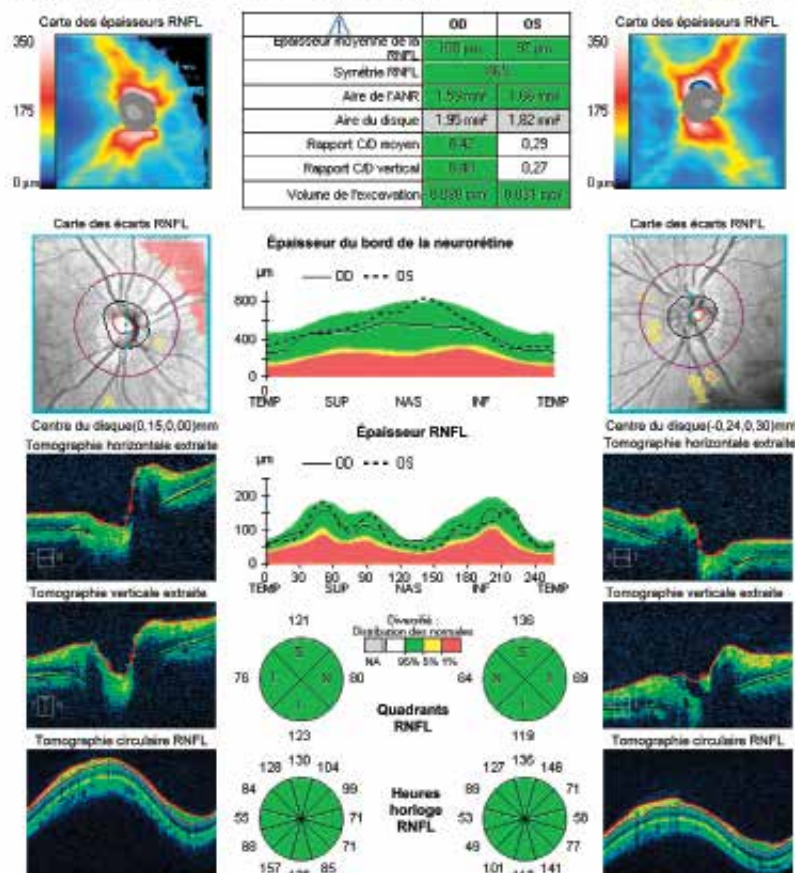


Right eye



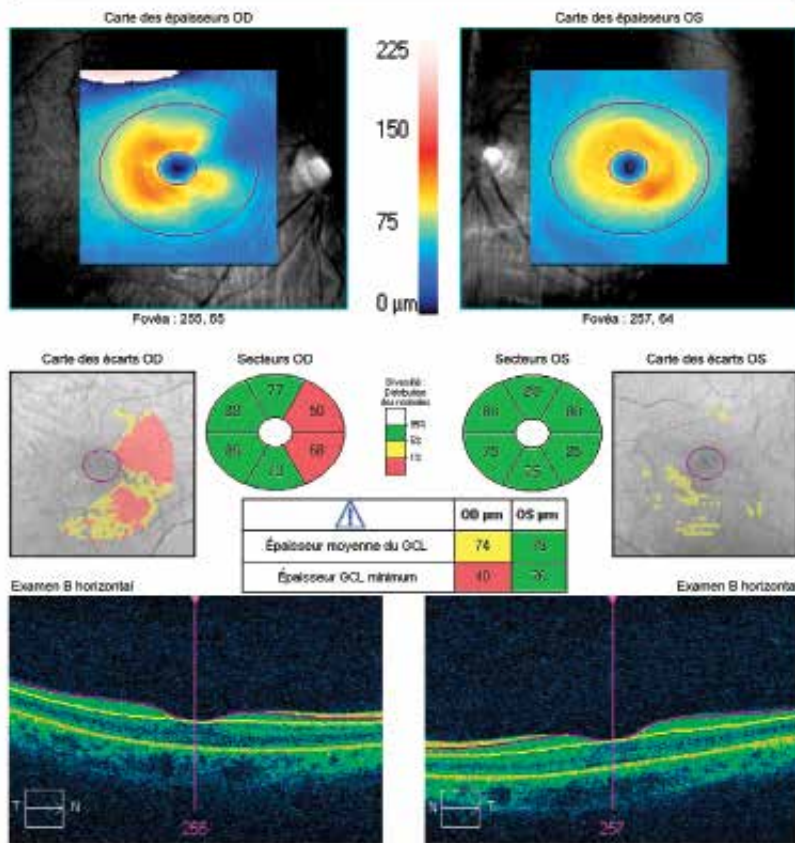
Left eye

## RNFL et ONH :Optic Disc Cube 200x200



Female patient with myopia of 6 dioptres and slight lower temporal dysversion. Matrix visual field testing shows irregularities, OCT is normal.

Analyse des cellules ganglionnaires : Macular Cube 512x128 OD ● | ● OS



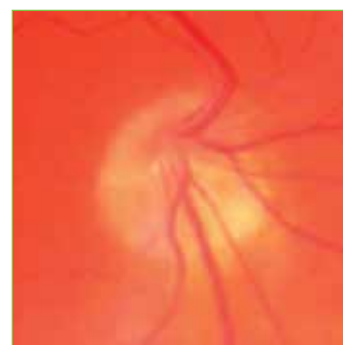
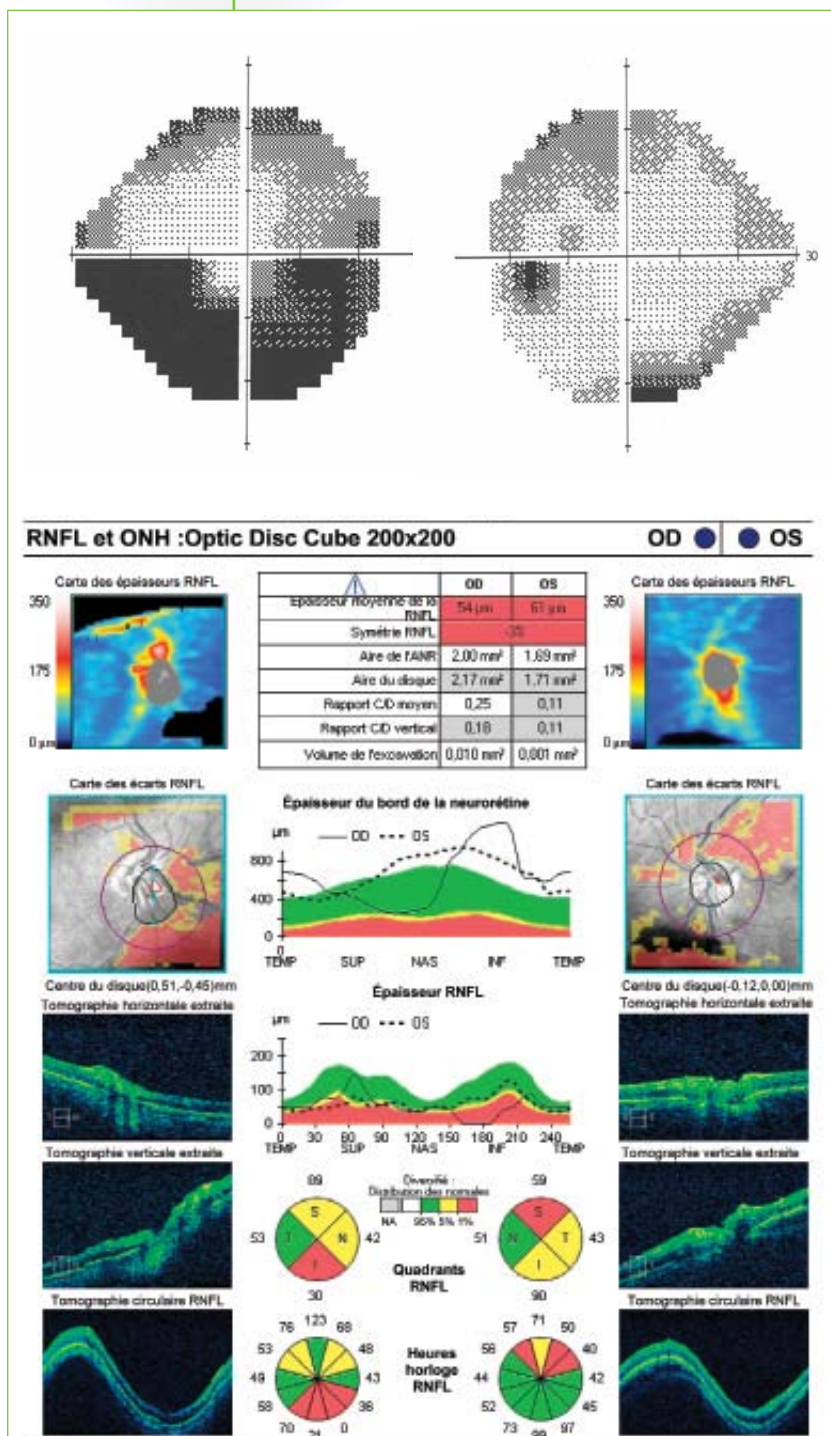
Same patient as on the previous page. Ganglion cell complex irregularities on the right. This result only indicates that a pathological process is evolving.

# Papillary dysversion

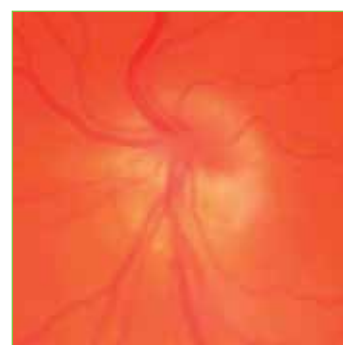Moderate dysversion of the papilla does not lead to OCT modifications, especially if it concerns the temporal axis. Nevertheless, in such cases we sometimes observe slight nasal deficit, an aspect that does not suggest glaucoma.

In contrast, if impairment is more important and especially if its axis is nasal, important alterations occur and can be sources of confusion.

The macular ganglion cell complex is simpler to evaluate in dysversion as it is located at a distance from the optic nerve. It allows revealing the existence of macular impairment.



Right eye

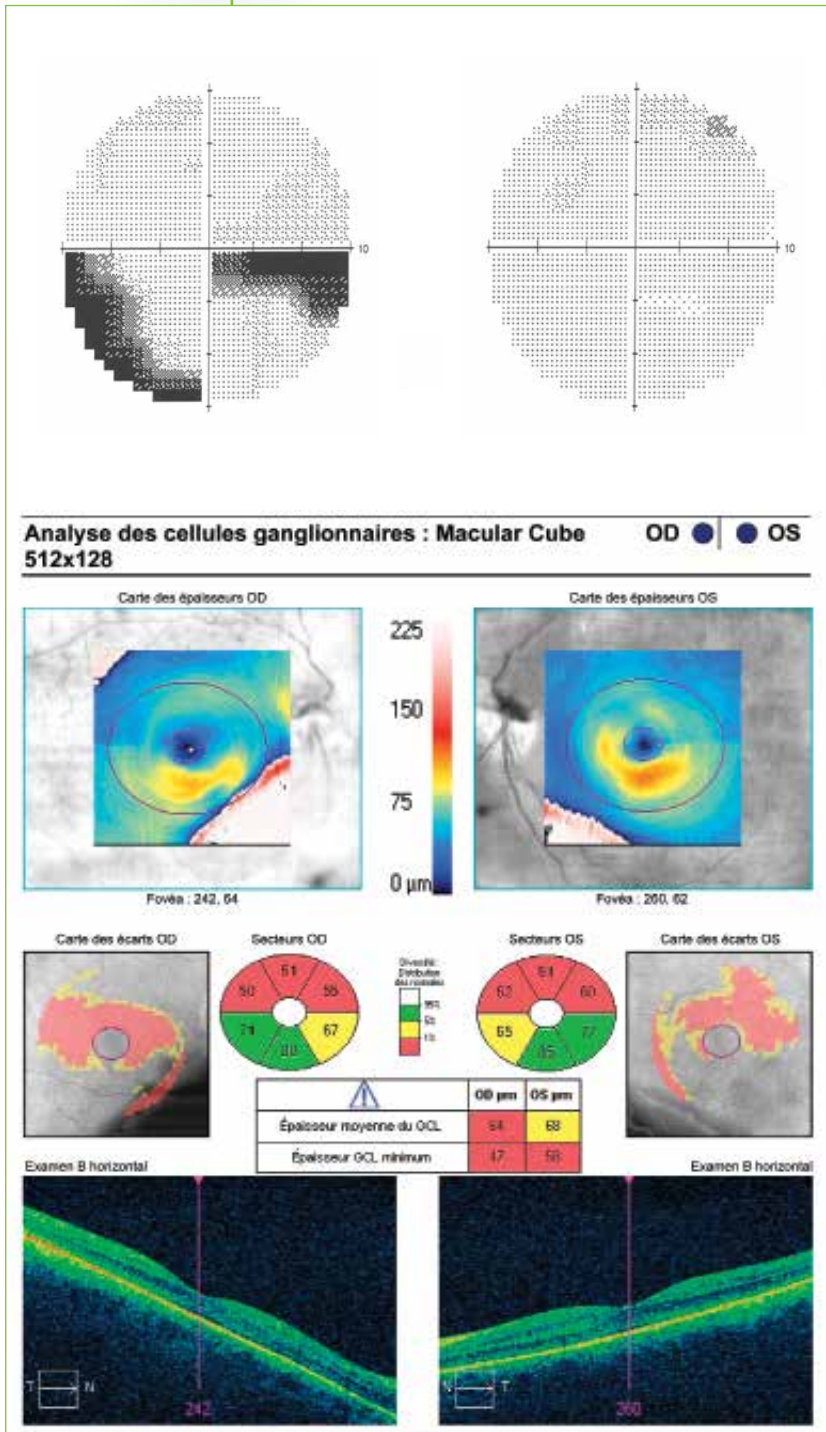


Left eye

Female patient with bilateral dysversion. The visual field is affected on the right mainly, with alteration of the RNFL suggesting glaucoma. There is no excavation using OCT.



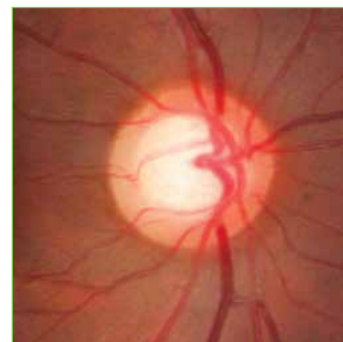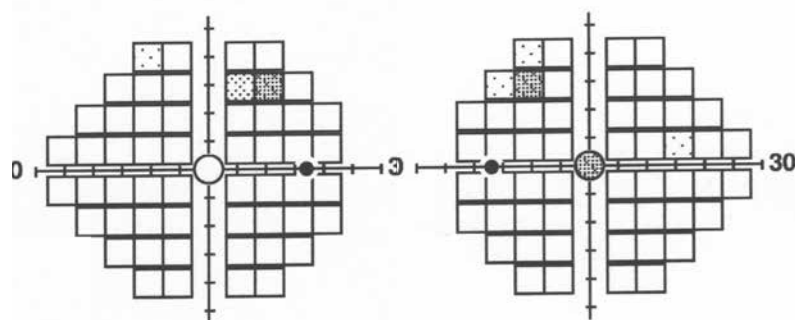
The macular ganglion cell complex is simpler to evaluate in dysversion as it is located at a distance from the optic nerve. It allows revealing the normality or the existence of optical fibre impairment.



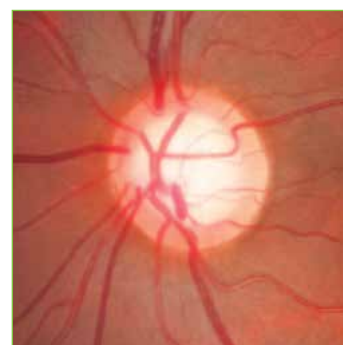Same patient as on the previous page. OCT and central 10° visual fields. An analysis of the central region confirms the repercussions of dysversion using both perimetry testing and OCT.

# Physiological excavation

Using OCT, the large papilla, which are responsible for physiological excavations, are expressed as a preservation of the RNFL and the macular ganglion cell complex. The optic nerve parameters are not often compared with a normative value because the data bases do not in general include physiological excavation.

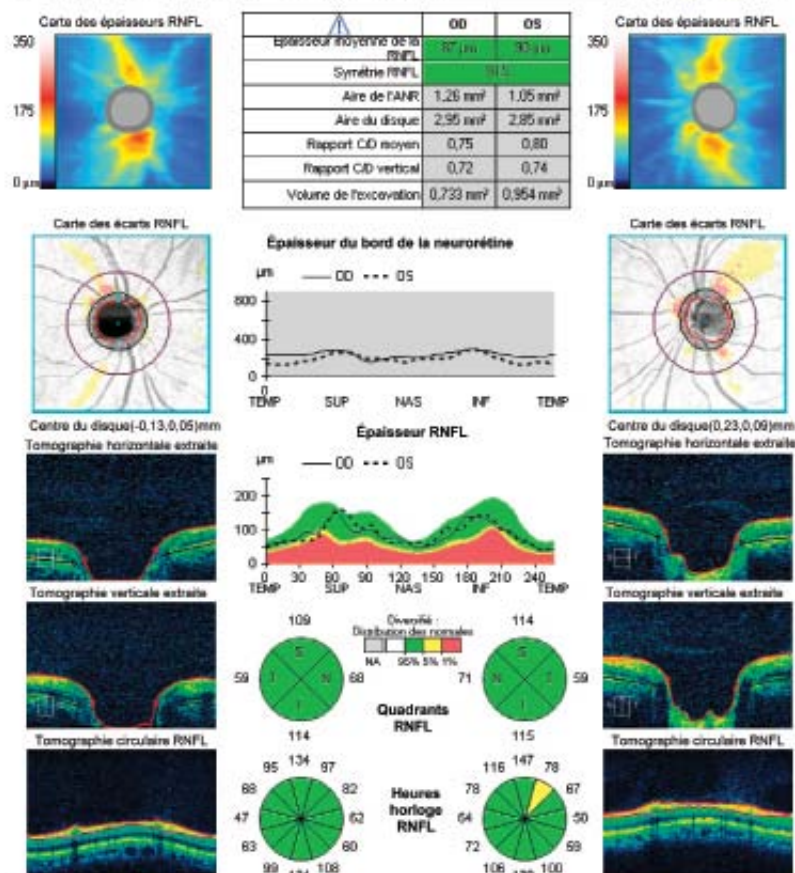


Right eye



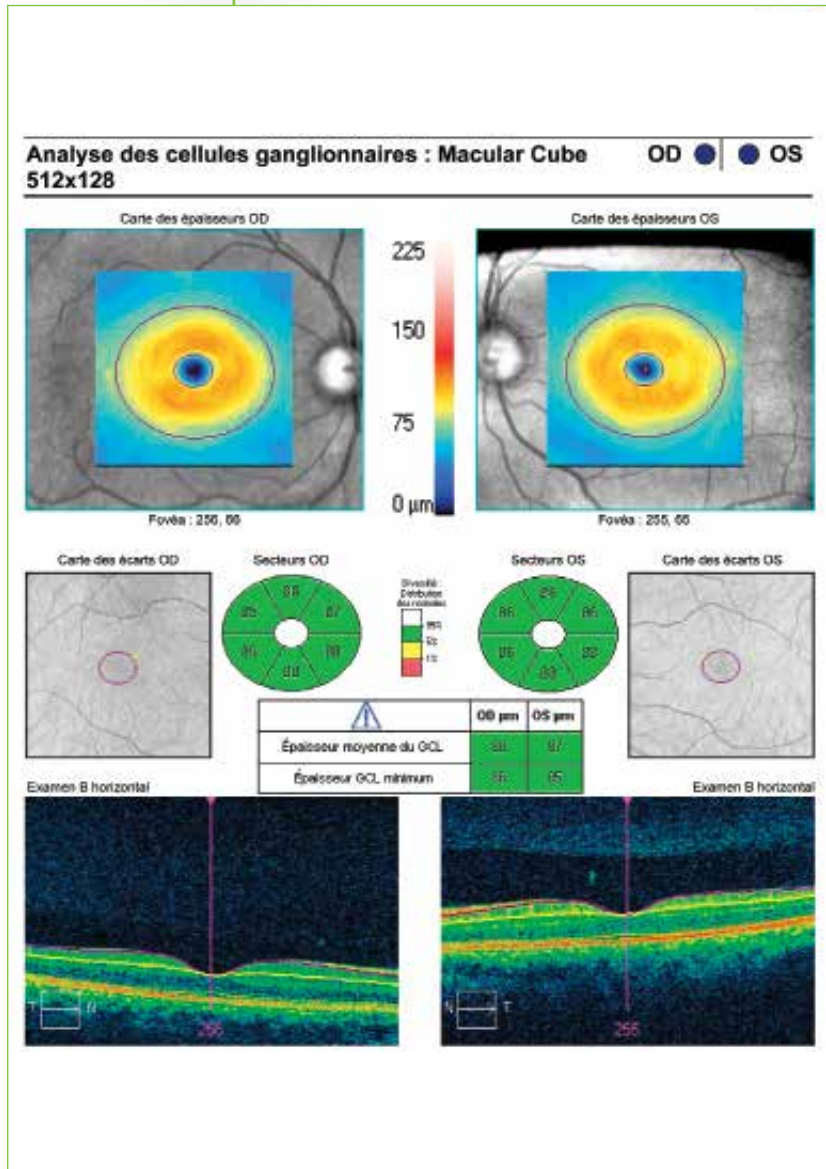
Left eye

## RNFL et ONH :Optic Disc Cube 200x200



Bilateral physiological excavation. The RNFL is normal. The optic nerve parameters are in grey (not statistically analysed), as the device does not have such large disc surfaces in its data base.

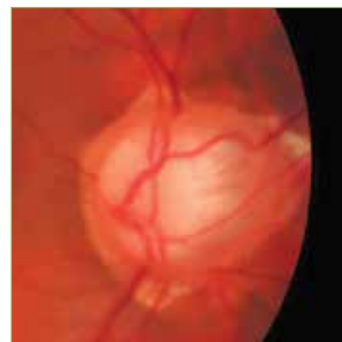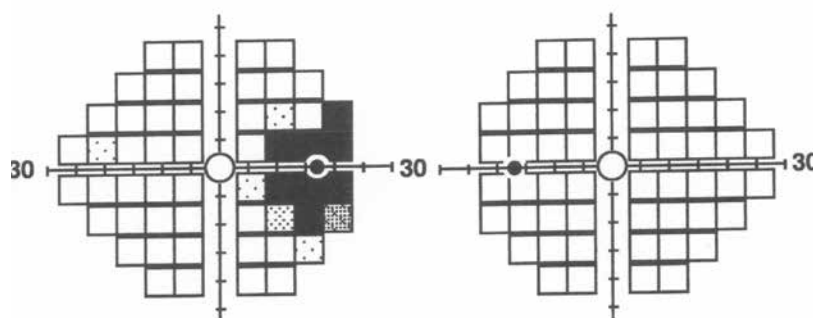
In the case of important and possibly physiological excavation, the optical fibre parameters should be analysed and those of the optic nerve should be considered to a lesser degree.



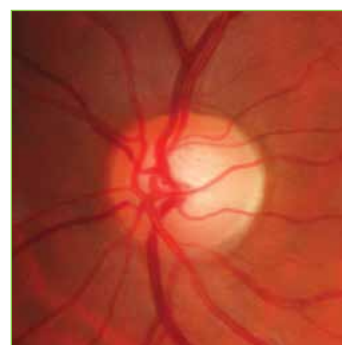
Same patient as on the previous page. The ganglion cell complex is normal. Bilateral physiological excavation.

# Papillary coloboma

Localisation of the coloboma is responsible for the opposite OCT. The sectors that are usually affected in glaucoma, the lower temporal region in particular, are not affected if this region is the seat of the coloboma.

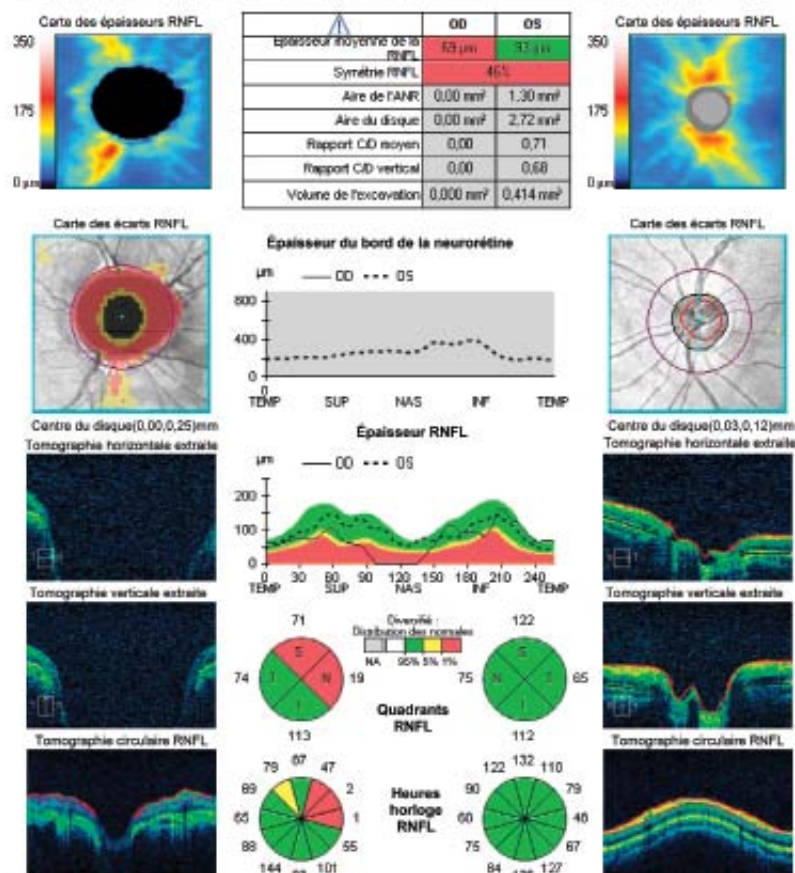


Right eye

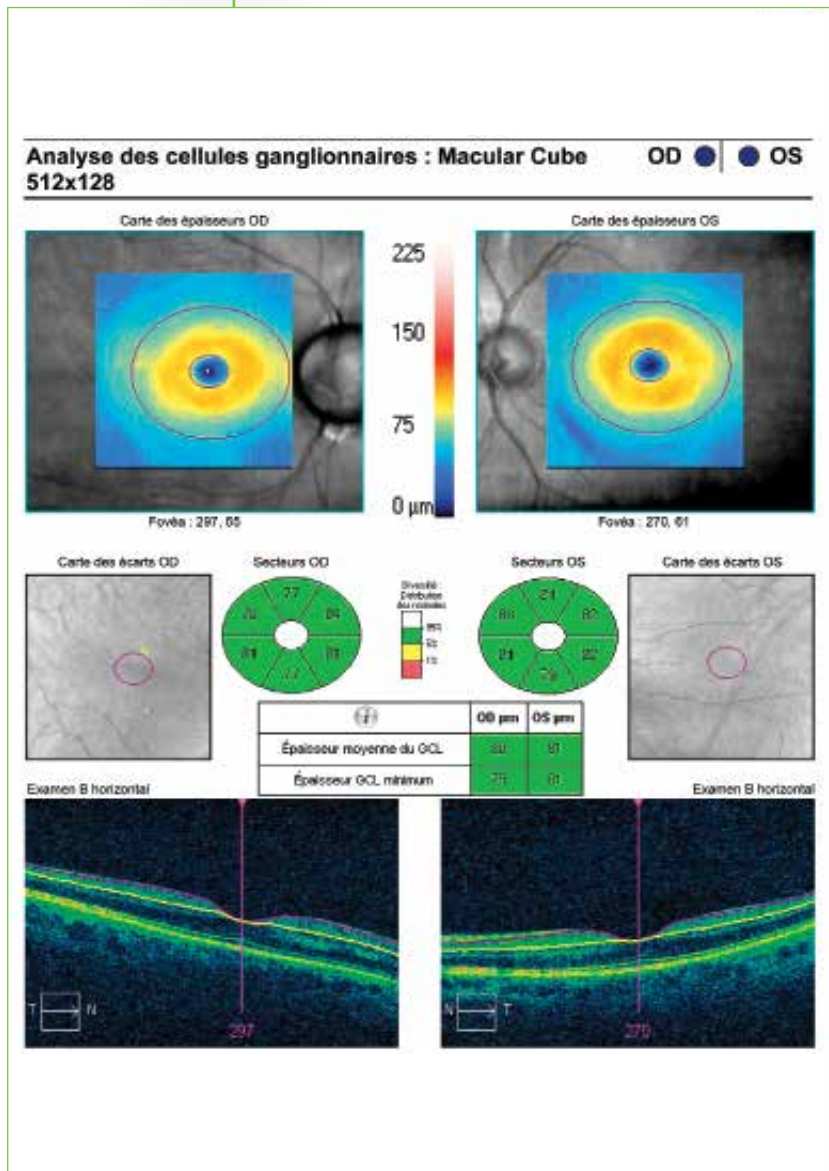


Left eye

## RNFL et ONH :Optic Disc Cube 200x200



Nasal coloboma of the right papilla. OCT impairment is opposite the abnormal region.



*Nasal coloboma of the right papilla. Same patient as on the previous page. The ganglion cell complex is normal.*

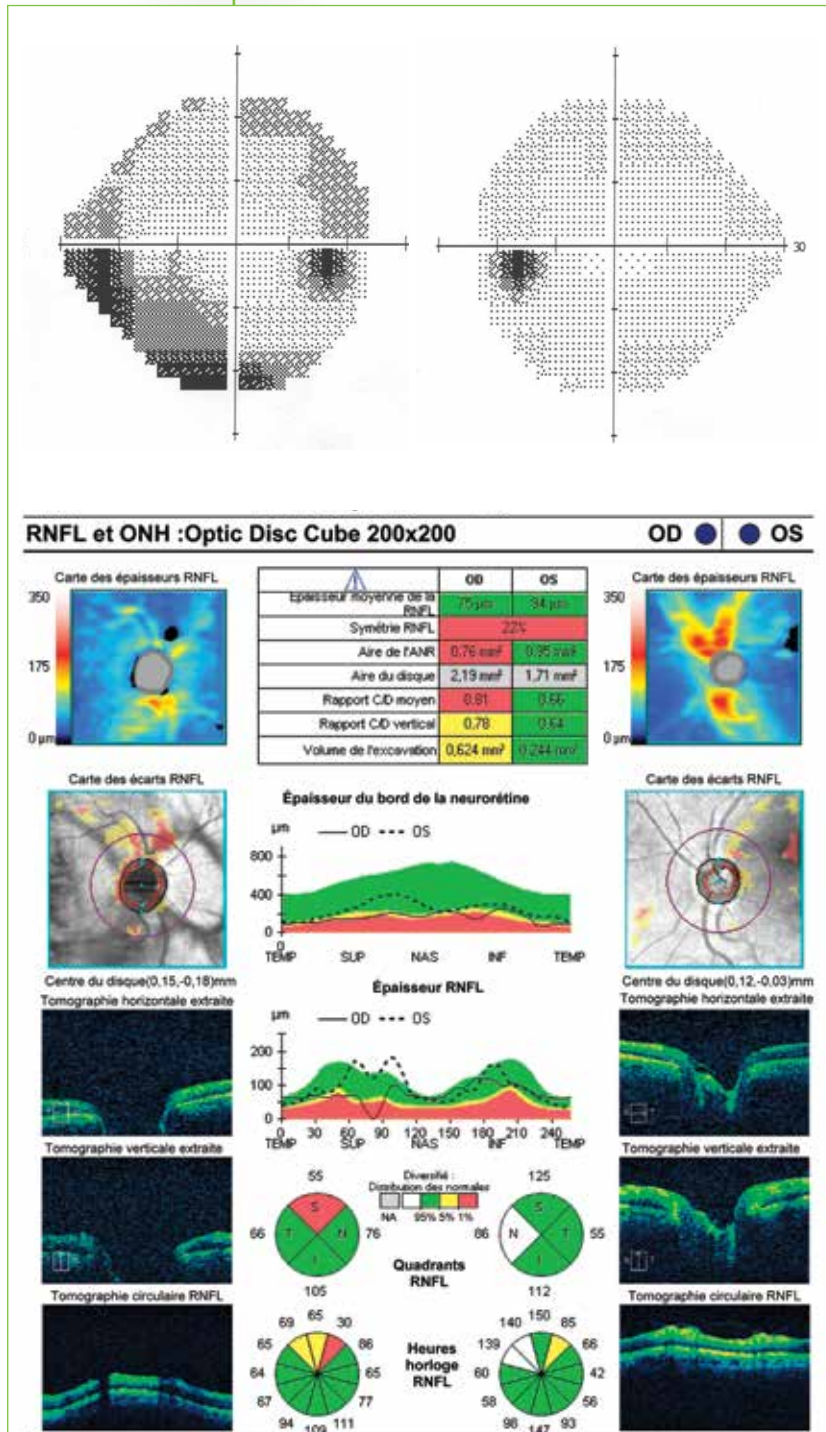


# Atypical aspects of the retina possibly suggesting optical neuropathy using OCT

Certain macular or retinal pathologies can alter the optical fibre layer, at the macular level, but also at the peripapillary level. Therefore, a change in these regions does not necessarily indicate direct impairment of the optic nerve. If initial retinal impairment is mainly macular, we frequently only observe a change in the macular ganglion cell complex. If impairment is more important, all the structures can be altered. Two examples are shown here, but they are not exhaustive as regards retinal pathologies possibly suggesting optic neuropathy.

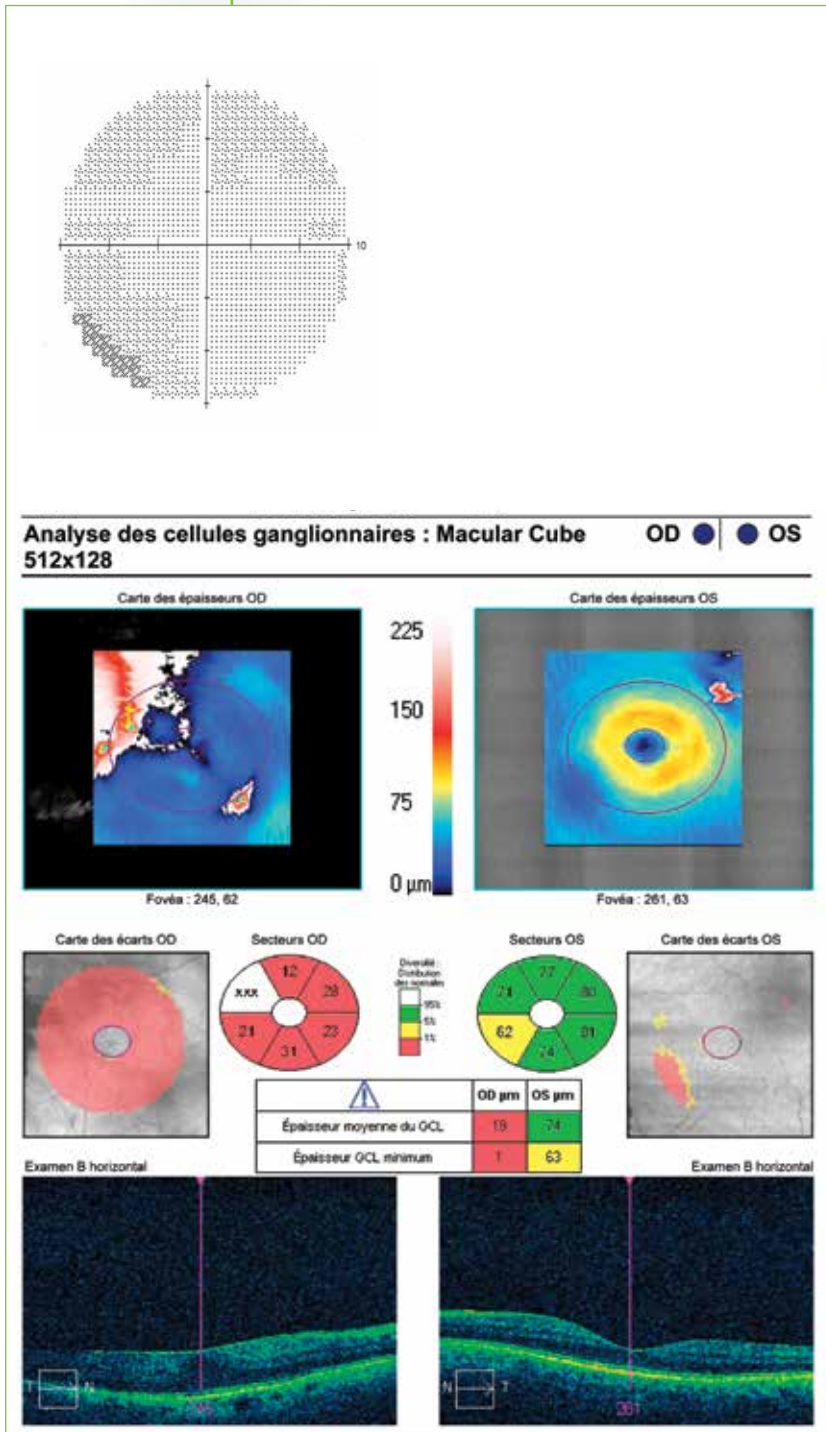
# Vein occlusion sequelae

Vein occlusion is responsible for the destruction of the ganglion cell layer in the same way as impairment of the optic nerve. The context allows an understanding of the OCT aspect.



72-year-old male patient affected 3 years earlier by upper temporal branch occlusion in the right eye. Both OCT and visual field testing detect the corresponding impairment.

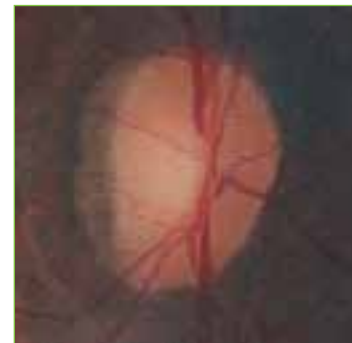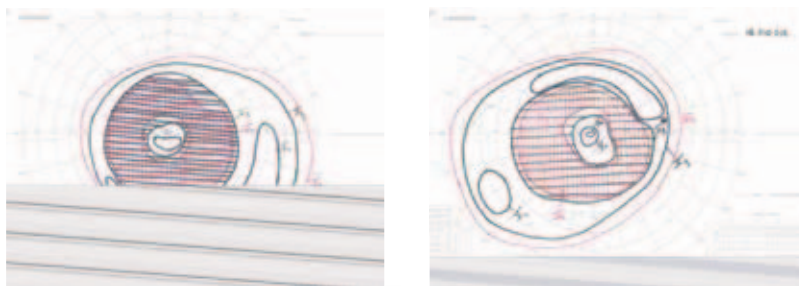




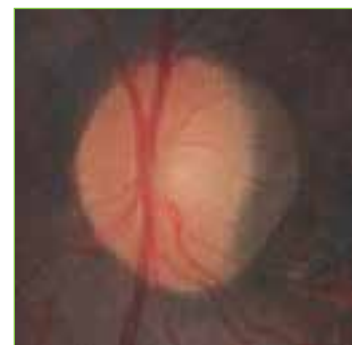Same patient as on the previous page. OCT and central 10° visual fields. We observe diffuse and unilateral impairment of the macular ganglion cell complex.

# Pigmentary retinopathy

Impairment of the macular ganglion cell complex is very frequent in retinal pathologies. It is even encountered when initial impairment is not located in the optical fibre layer, such as pigmentary retinopathy.

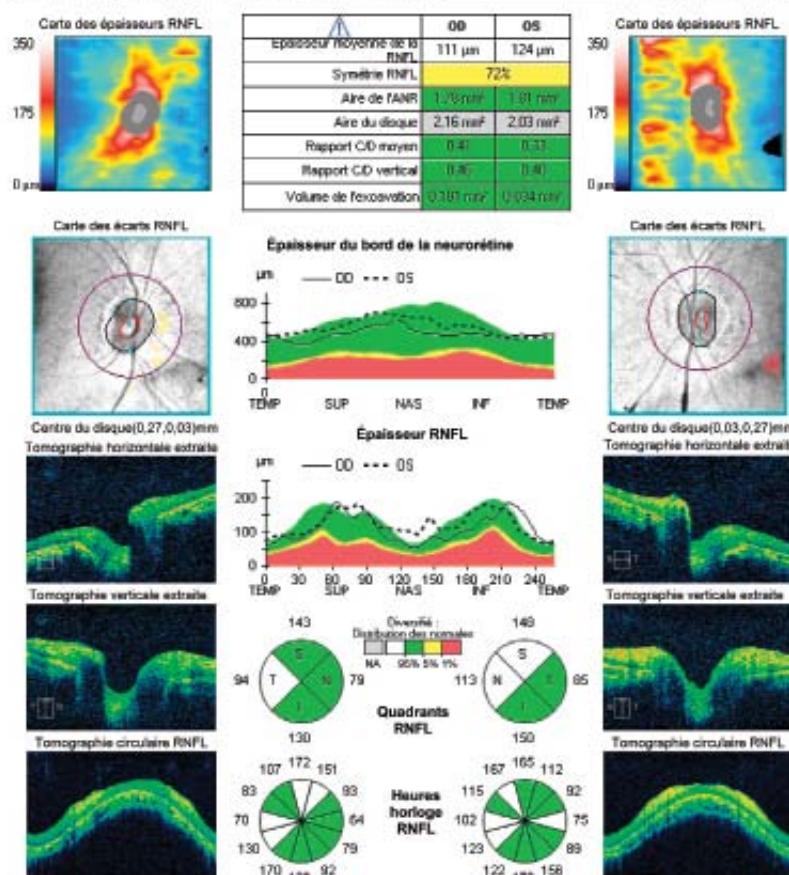


Right eye



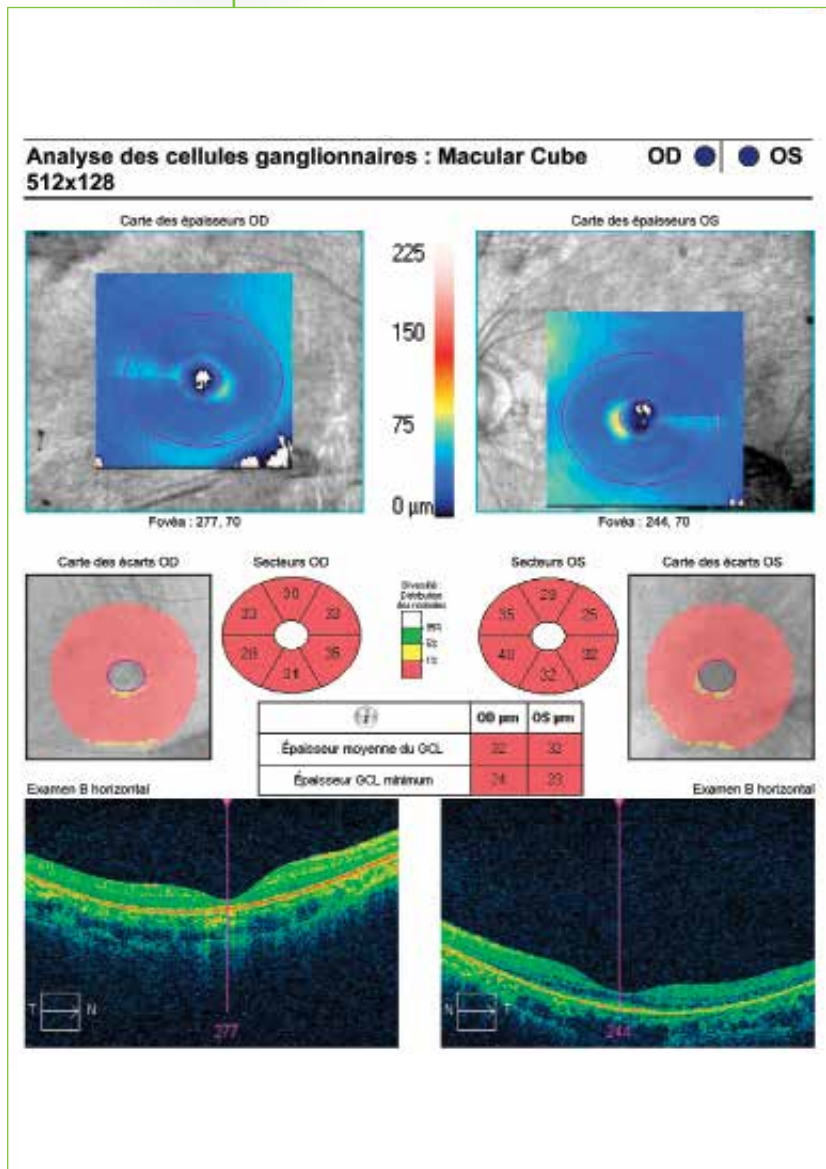
Left eye

## RNFL et ONH :Optic Disc Cube 200x200



23-year-old male patient with pigmentary retinopathy. Goldmann's visual field testing shows important bilateral pericentral impairment. The peripapillary optical fibre layer remains within normal limits.

The example given here corresponds to pigmentary retinopathy. All the other sources of macular injury can lead to impairment of the macular ganglion cell complex: epiretinal membrane, DMLA, macular oedema of any origin, maculopathies acquired or constitutional...



Same patient as on the previous page. We observe diffuse and bilateral impairment of the macular ganglion cell complex.



Optic nerve imaging using OCT is developing constantly. Most of the references of this publication are recent because earlier ones do not concern the “Spectral Domain”. In the last year, more than 300 articles on “Optic nerve and OCT” have been published in international journals, underlining the innovative character of this technology.

Many questions arise in view of these spectacular results: should OCT be considered a fundamental examination in the context of glaucoma monitoring or is it just supplementary to visual field testing and ocular pressure measurement? Can we ignore visual field testing, a limiting examination that is not well accepted by a large number of patients? What should one do if the OCT worsens significantly without an alteration in the visual field? On the contrary, what should one think of a visual field that is degrading without confirmation of change using OCT?

At the moment, it is reasonable to consider on the one hand that OCT has become a key examination for glaucoma and on the other hand that it cannot replace visual field testing.

The same type of questions are posed for other optic neuropathies. Should OCT eventually replace visual field testing? What should one think of OCT impairment in the absence of clinical optic nerve impairment?

OCT is still developing in terms of image precision and quality. New structures are being studied and measured, such as the cribriform plate. Other developments are possible, in particular the capacity to analyse not only layer thickness but also layer content. This would be very useful for counting e.g. the number of residual ganglion cells in optic nerve diseases without integrating the support cells that are responsible for the persistence of this layer, even after total destruction of the visual fibres.

The use of large wavelength laser beams (1000 nm or more, such as SWEPT-OCT) also allows studying structures beyond the pigmentary epithelium of the retina, but at the cost of lower image quality. The choroid and the region beyond the cribriform plate of the papilla also become visible. In the future, these technologies will allow an understanding of certain complex pathologies involving the modification of peripapillary cladding structures and cribriform plate impairment.

OCT has thus become a basic examination for the evaluation of optic neuropathies, without however totally replacing visual function analysis, and automated perimetry testing in particular.



- 1 Kara N, Altinkaynak H, Yuksel K, Kurt T, Demirok A. Effects of posterior capsular opacification on the evaluation of retinal nerve fiber layer as measured by stratus optical coherence tomography. *Can J Ophthalmol*, 47, 176-180, 2012.
- 2 Madrid-Costa D, Isla Paradelo., Ruiz J. Effect of multizone refractive multifocal contact lenses on the Cirrus HD OCT retinal measurements. *Clin Exp Optom*, 54, 212-216, 2012.
- 3 Kim NR, Lim H, Kim JH, Rho SS, Seong GJ, Kim CY. Factors associated with false positives in retinal nerve fiber layer color codes from spectral-domain optical coherence tomography. *Ophthalmology*, 118, 1774-1778, 2011.
- 4 Huang D, Chopra V, Lu AT, Tan O, Francis B, Varma R. Advanced Imaging for Glaucoma Study-AIGS Group. Does optic nerve head size variation affect circumpapillary retinal nerve fiber layer thickness measurement by optical coherence tomography? *Invest Ophthalmol Vis Sci*, 53, 4990-4997, 2012.
- 5 Shoji T, Nagaoka Y, Sato H, Chihara E. Impact of high myopia on the performance of SD-OCT parameters to detect glaucoma. *Graefes Arch Clin Exp Ophthalmol*, 136, 1843-1849, 2012.
- 6 Klamann MK, Grünert A, Maier AK, Gonnermann J, Joussem AM, Huber KK. Comparison of functional and morphological diagnostics in glaucoma patients and healthy subjects. *Ophthalmic Res*, 49, 192-198, 2013.
- 7 Mwanza JC, Oakley JD, Budenz DL, Anderson DR. Ability of Cirrus HD-OCT Optic nerve head parameters to discriminate normal from glaucomatous eyes. *Ophthalmology*, 118, 241-248, 2011.
- 8 Lisboa R, Leite MT, Zangwill LM, Tafreshi A, Weinreb RN, Medeiros FA. Diagnosing preperimetric glaucoma with Spectral Domain OCT. *Ophthalmology*, 119, 2161-2269, 2012.
- 9 Mwanza JC, Sayyad FR, Budenz DL. Choroidal Thickness in Unilateral Advanced Glaucoma. *Ophthalmol Vis Sci*, 53, 5880-5892, 2012.
- 10 Chang RT, Knight OJ, Budenz D. Sensitivity and specificity of time domain *versus* Spectral Domain OCT in diagnosing early to moderate glaucoma. *Ophthalmology*, 116, 2294-2299, 2009.
- 11 Kim CY, Jung JW, Lee SY, Kim NR. Agreement of retinal nerve fiber layer color codes between Stratus and Cirrus OCT according to glaucoma severity. *Invest Ophthalmol Vis Sci*, 53, 3193-3200, 2012.
- 12 Firat PG, Doganay S, Demirel EE, Colak C. Comparison of ganglion cell and retinal nerve fiber layer thickness in primary open angle glaucoma and normal tension glaucoma with Spectral Domain OCT. *Graefes Arch Clin Exp Ophthalmol*, 8, 225-228, 2012.
- 13 Lee JW, Lai JS, Yick DW, Yuen CY. Prospective study on retinal nerve fibre layer changes after acute episode of phacomorphic angle closure. *Int. Ophthalmol*, 32, 577-582, 2012.
- 14 Chen YC, Huang G, Kasuga T, Porco T, Hung PT, Lee R, Lin SC. Comparison of optic nerve head topography and retinal nerve fiber layer in eyes with narrow angles *versus* eyes from a normal open angle cohort - a pilot study. *Curr Eye Res*, 37, 592-598, 2012.
- 15 Leung CLS, Yu M, Weinreb R, Lai G. *et al*, Retinal nerve fiber layer imaging with Spectral Domain OCT. *Ophthalmology*, 119, 1858-1866, 2012.
- 16 Leung CK, Cheung CY, Weinreb RN, Qiu K, Liu S, Li H, Xu G, Fan N, Pang CP, Tse KK, Lam DS. Evaluation of retinal nerve fiber layer progression in glaucoma: a study on optical coherence tomography guided progression analysis. *Invest Ophthalmol Vis Sci*, 51:217-222, 2010.
- 17 Leung CLS, Yu M, Weinreb R, Lai G. *et al*, Retinal Nerve fiber layer imaging with Spectral Domain OCT. *Ophthalmology*, 119, 1858-1866, 2012.
- 18 Meideros FA, Zangwill L, Alencar LM, Bowd, C, Sample P, Suzanna R, Weinreb R. Detection of glaucoma progression with Stratus OCT retinal nerve fiber layer, optic nerve head and macular thickness measurements. *Invest Ophthalmol Vis Sci*, 50, 5741-5748, 2009.
- 19 Raghu N, Pandav SS, Kaushik S, Ichhpujani P, Gupta A. Effect of trabeculectomy on RNFL thickness and optic disc parameters using optical coherence tomography. *Eye (Lond)*, 26, 1131-1137, 2012.
- 20 Kanamori A, Nakamura M, Tomioka M, *et al*. Agreement among three types of Spectral Domain OCT instruments in measuring parapapillary retinal nerve fiber layer thickness. *Br J Ophthalmol*, 96, 832-837, 2012.
- 21 Park SC, Kiumer S, Teng CC, Tello C, Liebmann JM, Ritch R. Horizontal central ridge of the lamina cribrosa and regional differences in laminar insertion in healthy subjects. *Invest Ophthalmol Visc Sic*, 53, 1610-1616, 2012.
- 22 Reiss AS, O'Leary N, Stanfield MJ, Shuba LM, Nicoleta MT, Chauhan BC. Laminar displacement and prelaminar tissue thickness change after glaucoma surgery imaged with optical coherence tomography. *Invest Ophthalmol Vis Sci*, 53, 5819-5826, 2012.
- 23 Park SC, de Moraes CG, Teng CC, Tello C, Liebmann JM, Ritch R. EDI-OCT of deep optic nerve complex structures in glaucoma. *Ophthalmology* 119, 3-9, 2012.
- 24 Mwanza JC, Sayyad FR, Budenz DL. Choroidal Thickness in Unilateral Advanced Glaucoma. *Ophthalmol Vis Sci*, 53, 5880-5892, 2012.
- 25 Fénolland JR, Giraud JM, May F, Mouinga A, Seck S, Renard JP. EDI-OCT et glaucome à angle ouvert : une étude préliminaire. *J Fr Ophtalmol*, 34, 313-317, 2011.
- 26 Garcia T, Tourbah A, Setrouk E, Ducasse A, Arndt C. OCT en neuro-ophtalmologie. *J. Fr Ophtalmol* 35, 454-466, 2012.

- 27 Galetta KM, Calabresi PA, Frohman E, Balcer LJ. Optical Coherence Tomography (OCT): Imaging the visual pathway as a model for neurodegeneration. *Neurotherapeutics*, 8, 117-132, 2011.
- 28 Trip SA, Schlottmann PG, Jones SJ *et al.* Retinal nerve fiber layer axonal loss and visual dysfunction in optic neuritis. *Ann Neurol* 58, 383-391, 2005.
- 29 Lamirel C, Newman NJ, Bioussé V. OCT in optic neuritis and multiple sclerosis. *Rev Neurol (Paris)*, 166, 978-986, 2010.
- 30 Burkholder BM, Osborne B, Loguidice MJ *et al.* Macular volume determined by OCT as a measure of neuronal loss in multiple sclerosis. *Arch Neurol*, 66, 1366-1372, 2009.
- 31 Oberwahrenbrock T, Schippling S, Ringelstein M. *et al.* Retinal damage in multiple sclerosis disease subtypes measured by high resolution OCT. *Mult Scler Int*, 5305, 2012.
- 32 Pineles SL, Wilson CA, Balcer LJ *et al.* Combined optic neuropathy and myelopathy secondary to copper deficiency. *Surv Ophthalmol* 55, 386-392, 2010.
- 33 Pasol J. Neuro-ophthalmic disease and optical coherence tomography: glaucoma look-alikes. *Curr Opin Ophthalmol* 22:124-32, 2011.
- 34 Aggarwal D, Tan O, Huang D, Sadun AA. Patterns of ganglion cell complex and nerve fiber layer loss in nonarteritic ischemic optic neuropathy by Fourier-domain optical coherence tomography. *Invest Ophthalmol Vis Sci*, 53, 4539-4545, 2012.
- 35 Suh MH, Kim SH, Park KH, Kim SJ, Kim TW, Hwang SS, Kim DM. Comparison of the correlations between optic disc rim area and retinal nerve fiber layer thickness in glaucoma and nonarteritic anterior ischemic optic neuropathy. *Am J Ophthalmol*, 151, 277-286, 2011.
- 36 Contreras I, Noval S, Rebolleda G. *et al.* Follow-up of non arteritic anterior ischemic optic neuropathy with OCT. *Ophthalmology*, 114, 2338-2344, 2007.
- 37 Moura FC, Costa-Cunha LV, Malta RF, Monteiro ML. Relationship between field sensitivity loss and quadrant macular thickness measured with Stratus OCT in patients with chiasmal syndrome. *Arq Bras Oftalmol*, 73, 409-413, 2010.
- 38 Jindahra P, Petrie A, Plant GT. The time course of retrograde tans-synaptic degeneration following occipital lobe damage in humans. *Brain*, 135, 534-541, 2012.
- 39 Iseri PK, Atlina O, Tokay T, Yüsel N. Relationship between cognitive impairment and retinal morphological and visual function abnormalities in Alzheimer disease. *J Neuro-Ophthalmol*, 26, 18-24, 2006.





## Edition

Published by:  
Laboratoire Théa  
12, rue Louis Blériot  
63000 Clermont-Ferrand  
Tel: 04 73 98 14 36

Carl Zeiss Meditec France SAS  
100 Route de Versailles  
78160 Marly-le-Roi  
Tel: 01 34 80 21 00