

SYMPTOMS OF RESPIRATORY
DISEASES ON THE BASIS OF
QUESTIONING THE PATIENT,
PALPATION, PERCUSSION OF THE
CHEST, AUSCULTATION OF LUNGS

Odessa National Medical University

Department of propaedeutics of internal
diseases

This is the objective method of examination based on visual evaluation of condition and pathological changes in thorax

Static inspection – based on revelation of thorax features without taking into the act of breathing

Dynamic inspection - based on revelation of thorax features with taking into the act of breathing

INSPECTION OF THE CHEST (INSPECTIO THORACIS)

Physiological shapes :

- Normosthenic,
- Hypersthenic,
- Asthenic

The asymmetry of the chest
(enlarged volume of the half
of the chest, decreased
volume of the one part of the
chest)

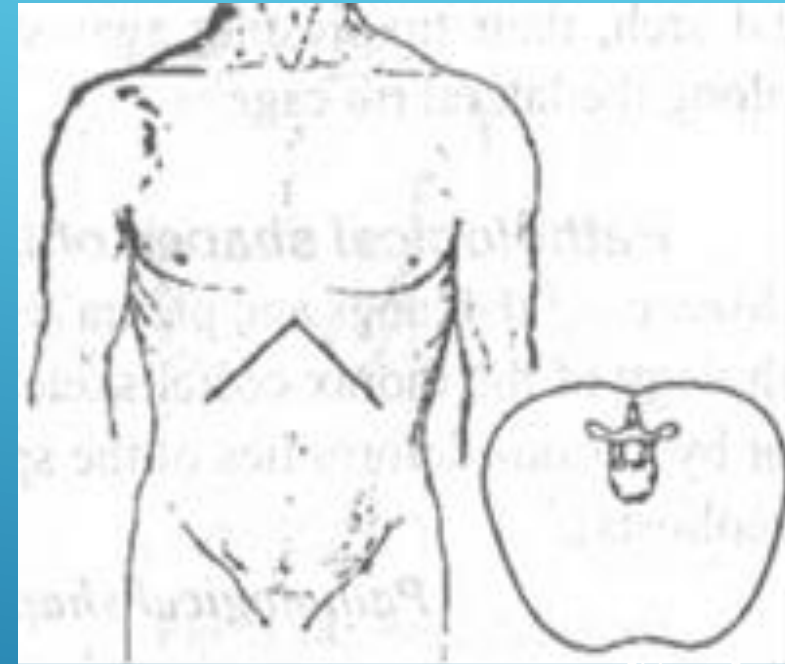
Pathological shapes :

- emphysematous (barrel)
- paralytic
- rachitic or pigeon
- funnel
- foveated
- scoliotic
- kyphotic
- kyphoscoliotic

STATIC INSPECTION

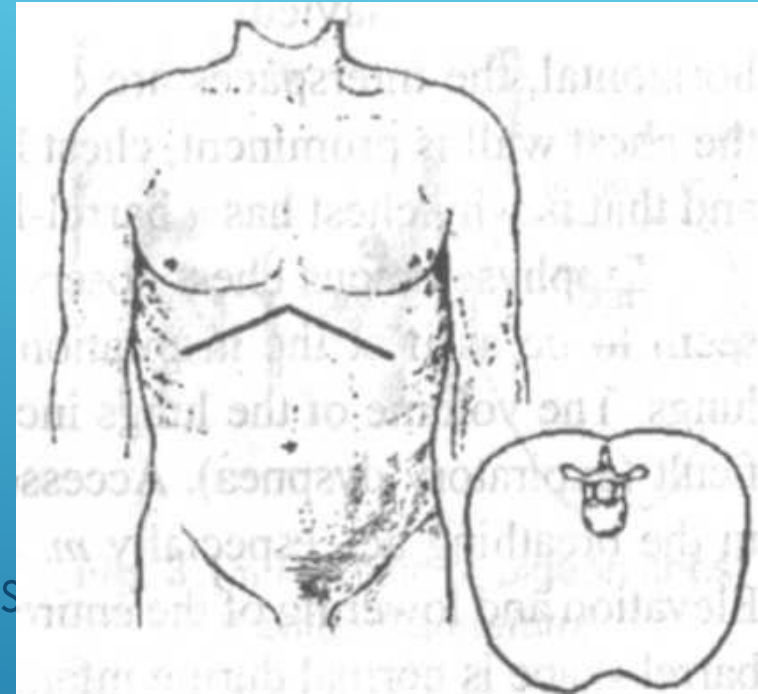
NORMOSTHENIC CHEST:

- The shoulders are under the right angle to the neck
- Supra- and infraclavicular fossae feebly expressed
- The ribs are moderately inclined
- The interspaces are visible, but moderate expressed
- Epigastric angle is near 90 degree
- The lateral diameter is larger than anteroposterior
- Scapulae closely fits to the chest and are on the same level



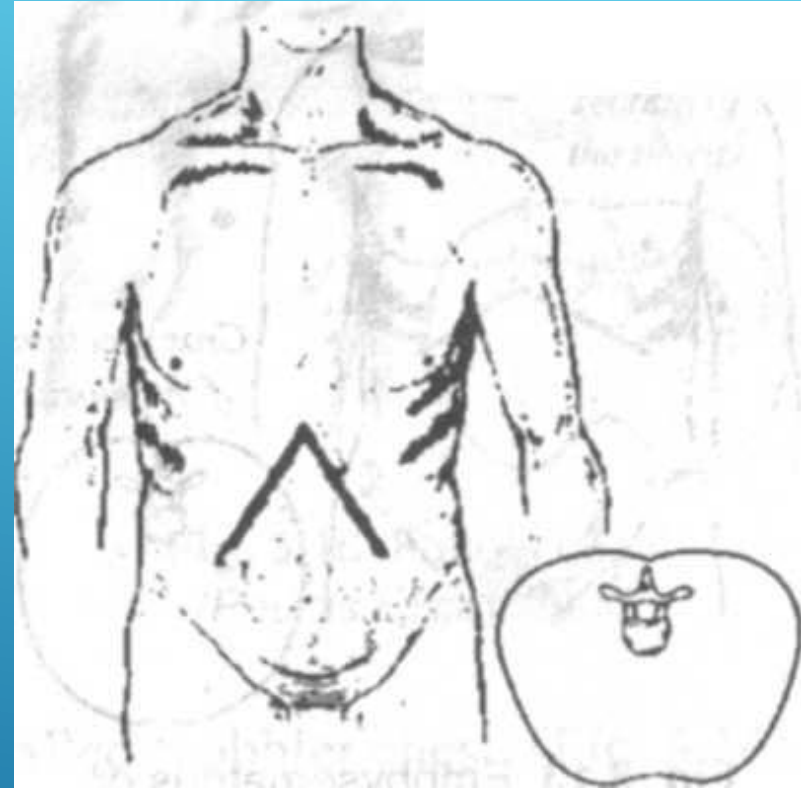
HYPERSTENIC CHEST

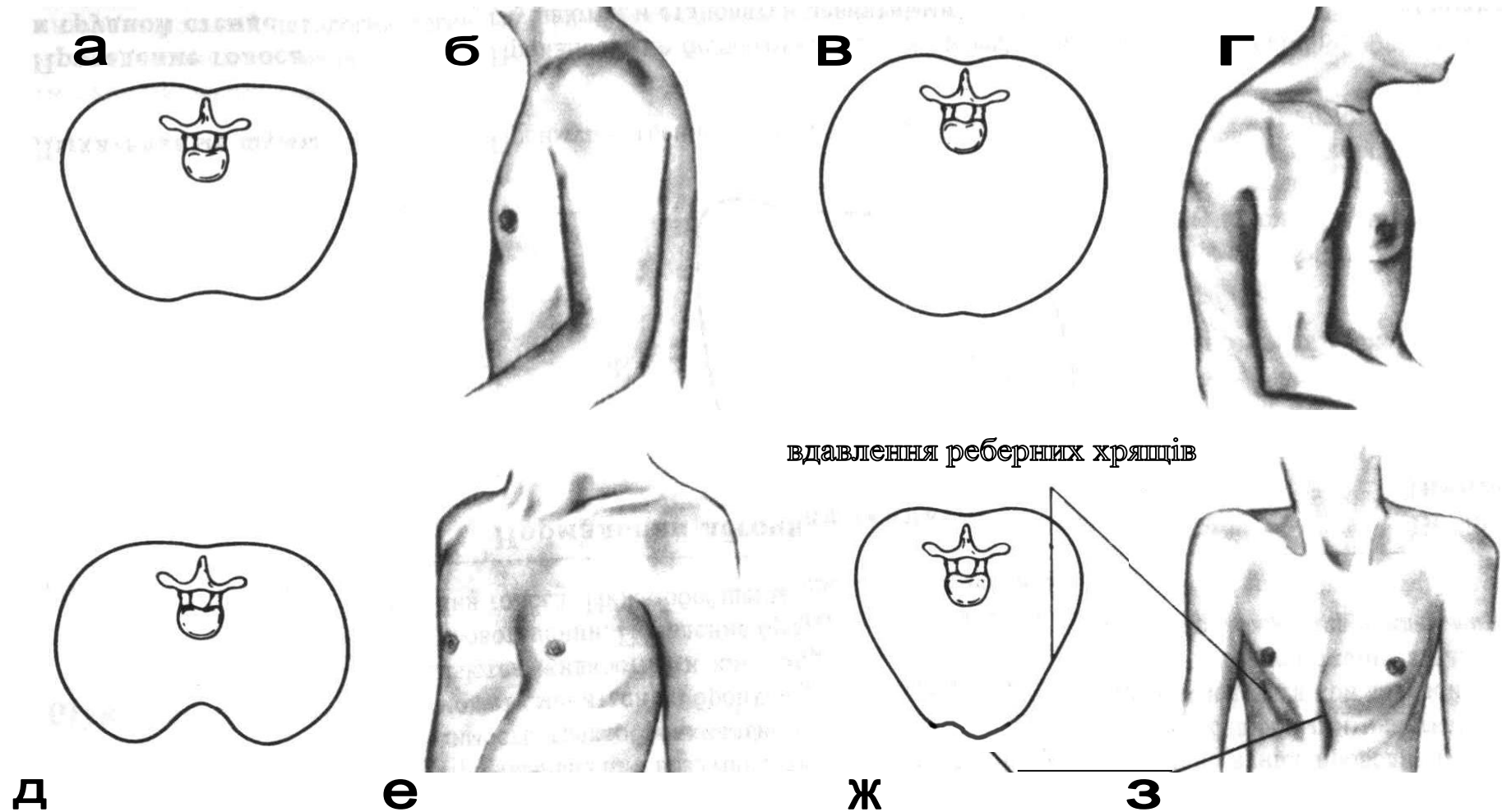
- The shoulders are wide and the neck is short
- Supra- and infraclavicular fossae are absent (level with the chest)
- Direction of the ribs are nearly horizontal
- The interspaces are narrow and slightly expressed
- Epigastric angle exceeds 90 degree
- The lateral diameter is about the same as anteroposterior
- The chest has form of a cylinder
- Scapulae closely fit to the chest



ASTHENIC CHEST

- The shoulders are sloping and are under the dull angle to the neck
- Clavicles are well visible
- Supra- and infraclavicular fossae are distinctly pronounced
- The ribs more vertical, direct downward
- The interspaces are wide and pronounced
- Epigastric angle is less than 90 degree
- Both lateral and anteroposterior diameter are smaller than normal





(cross - section and appearance)

а,б – thorax of healthy adult; в,г – thorax.

д,е – thorax; ж,з – rachitic thorax.

DYNAMIC INSPECTION

Participation of the accessory muscles in act of breathing (bronchial asthma, respiratory insufficiency or heart failure)

Participation parts of the chest in breathing act (pleuritis, pleural commissure, complications after surgical operations on the lung, lung tumors)

Type of respiration :

- thoracic (costal)
- abdominal (diaphragmal)
- mixed

Respiration rate:

- Normal at rest 16-20 per 1 min.
- Frequent (more than 20 per 1 min.) – tachypnoë
- Slow (less than 16 per 1 min.) – bradypnoë

Respiration depth:

- moderate
- deep
- superficial

Respiration rhythm:

- regular, irregular

Palpation

This is the objective method of examination based on evaluation of condition and pathological changes in thorax during its feelings

Identification of tender areas (widespread or local, in Valle points)

Thorax resistance (normal, increased, decreased)

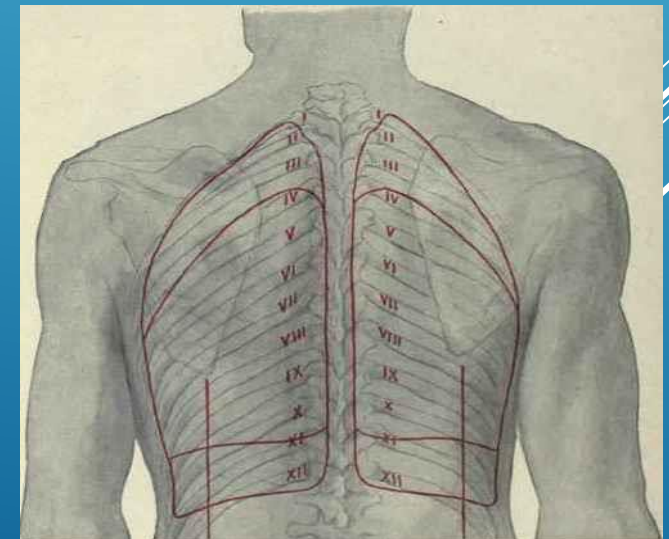
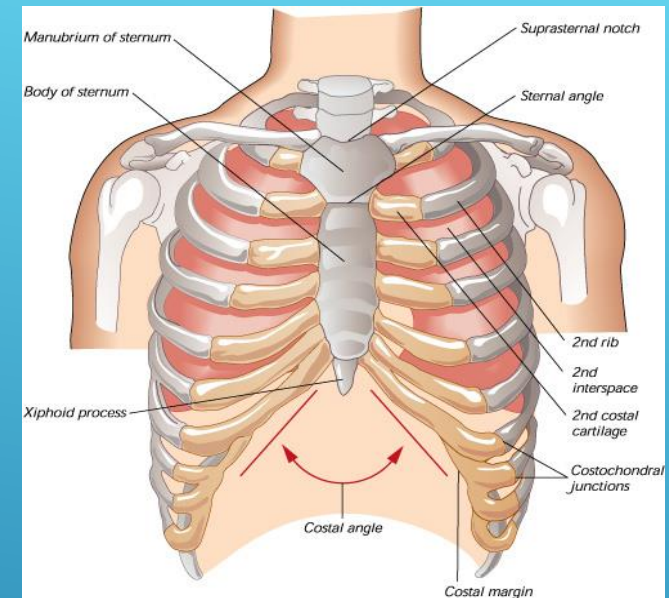
Tactile vocal fremitus (normal, increased, decreased)

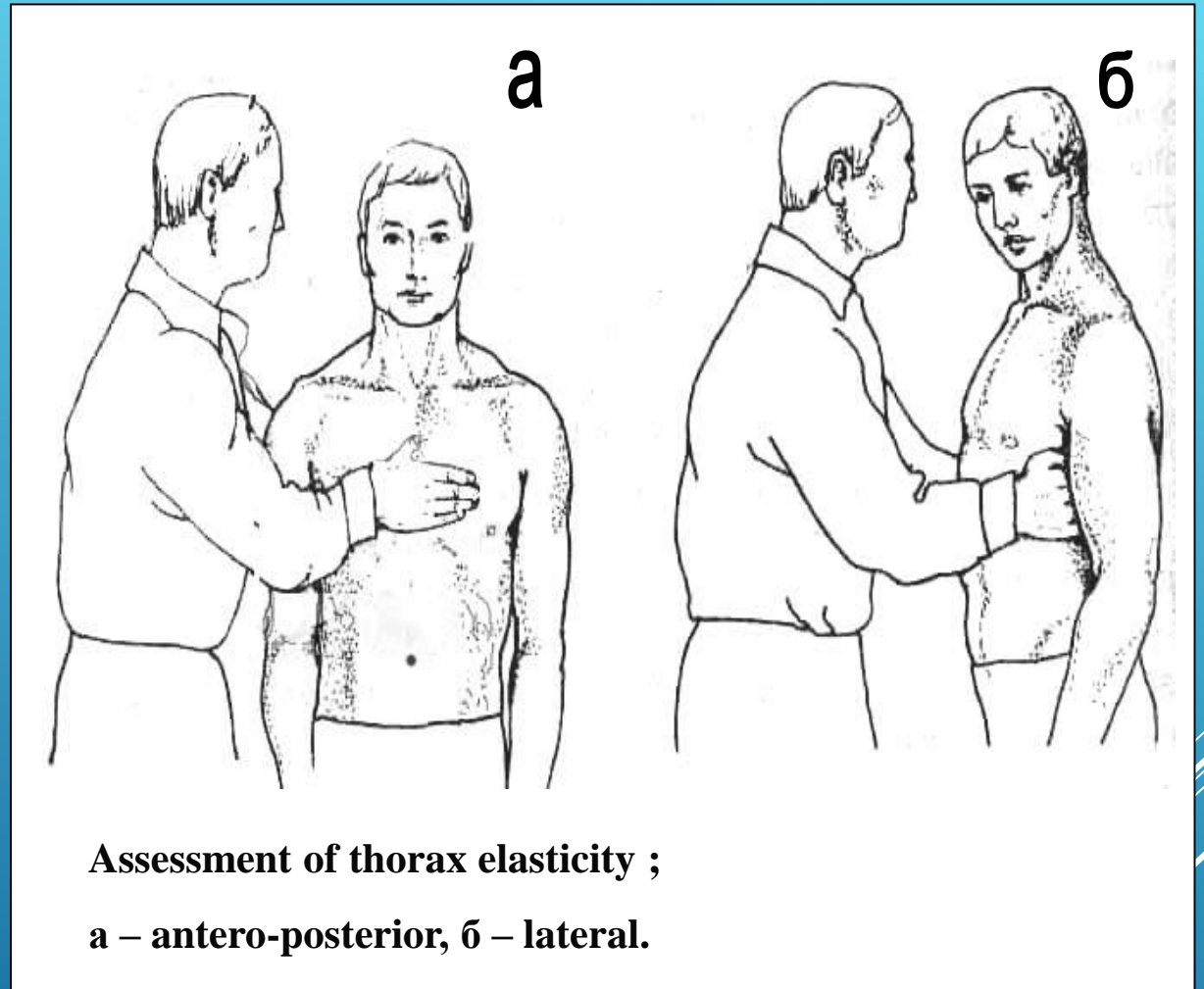
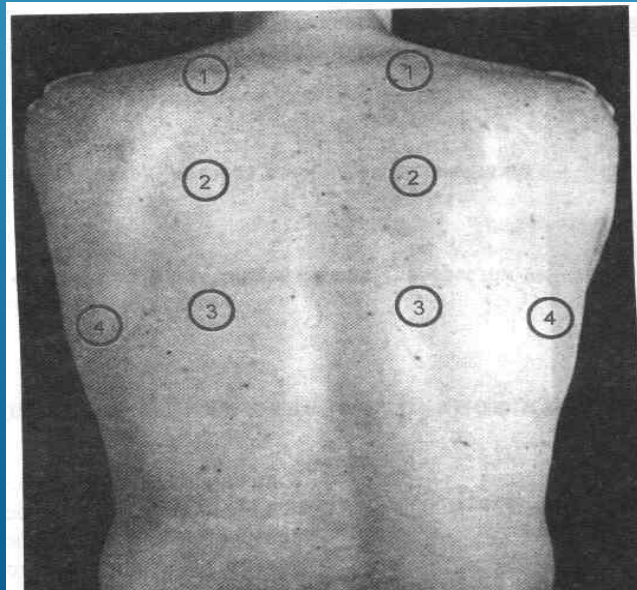
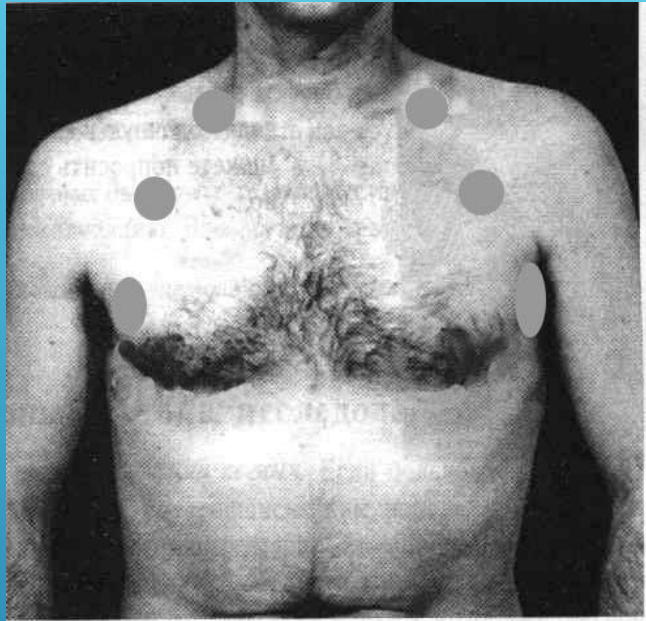
Chest expansion (in addition to inspection)

Assessment of epigastrical angle (in addition to inspection)

TOPOGRAPHIC REGIONS OF THE CHEST

- Supraclavicular region – above clavicles
- Infraclavicular region – below clavicles
- Suprascapular region – above scapulae
- Interscapular region – between the scapulae
- Infrascapular region – below scapular

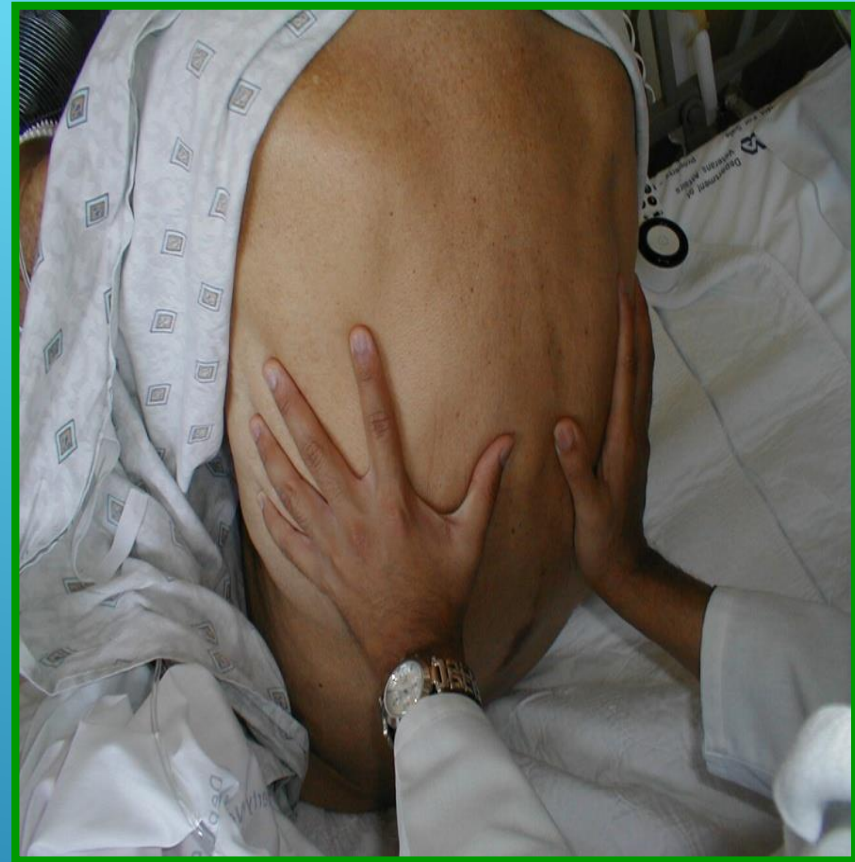



**Assessment of thorax elasticity ;
a – antero-posterior, б – lateral.**

TACTILE VOCAL FREMITUS:

palpable vibrations transmitted through the bronchopulmonary tree to the chest wall when the patients speaks

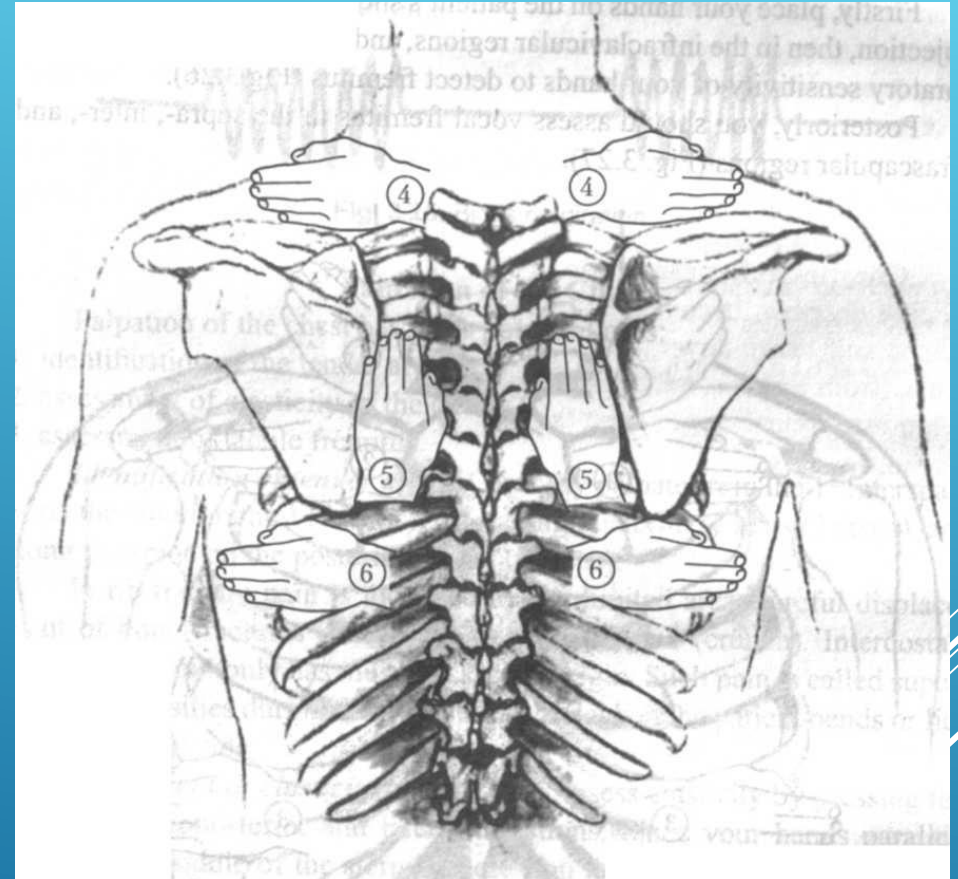
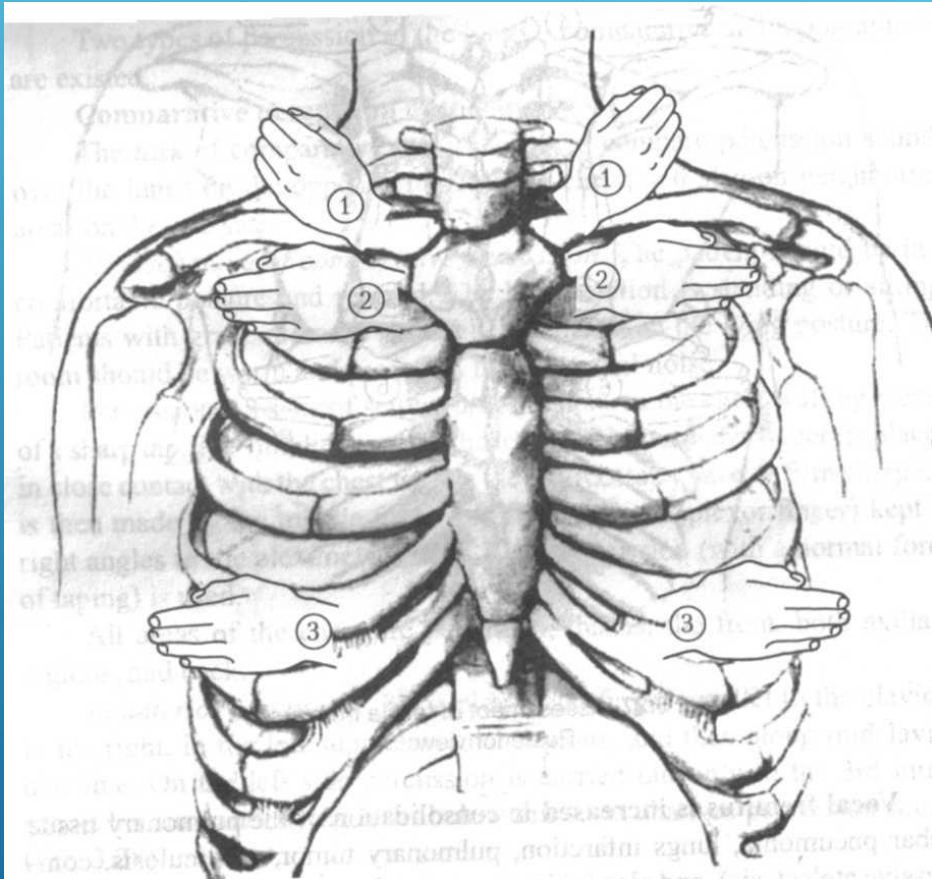


Anteriorly - midclavicular line

Laterally - midaxillary line

Posteriorly - above scapula , parascapular
“paraspinal”, below scapula

TACTILE VOCAL FREMITUS:

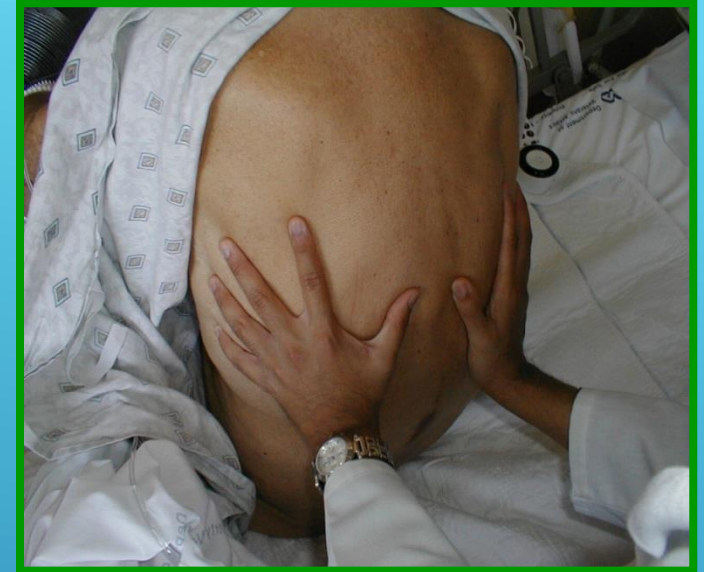

Increased TVF

- Thin chest wall
- Lobar pneumonia
- Lung infarction
- Pulmonary tumor
- Tuberculosis
- Compressive atelectasis
- Air cavity communicated with bronchus

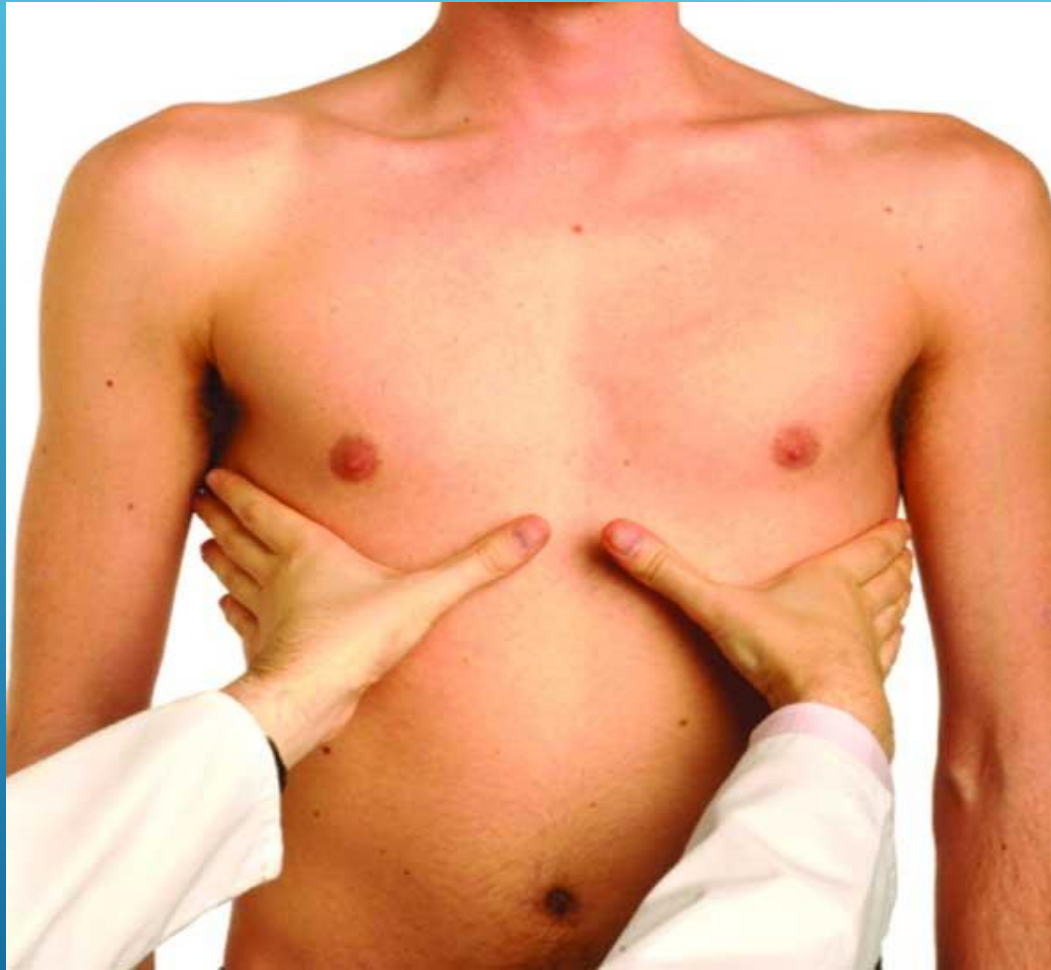Decreased TVF

- Pleural effusion
- Pleural fibrosis
- Pneumothorax
- Thick chest wall (edema, subcutaneous fat)

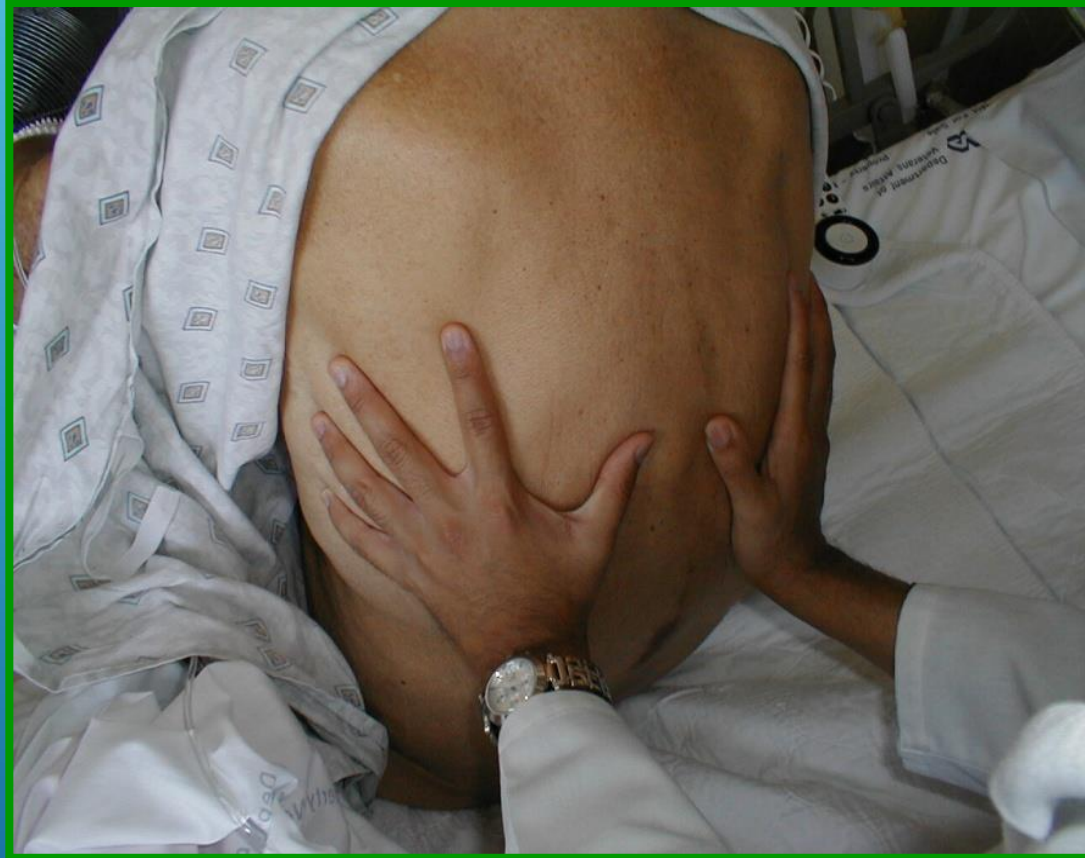

Vocal fremitus can be absent when significant amount of fluid or air are accumulated in the pleural cavity

Palpation of the chest



Palpation of the chest






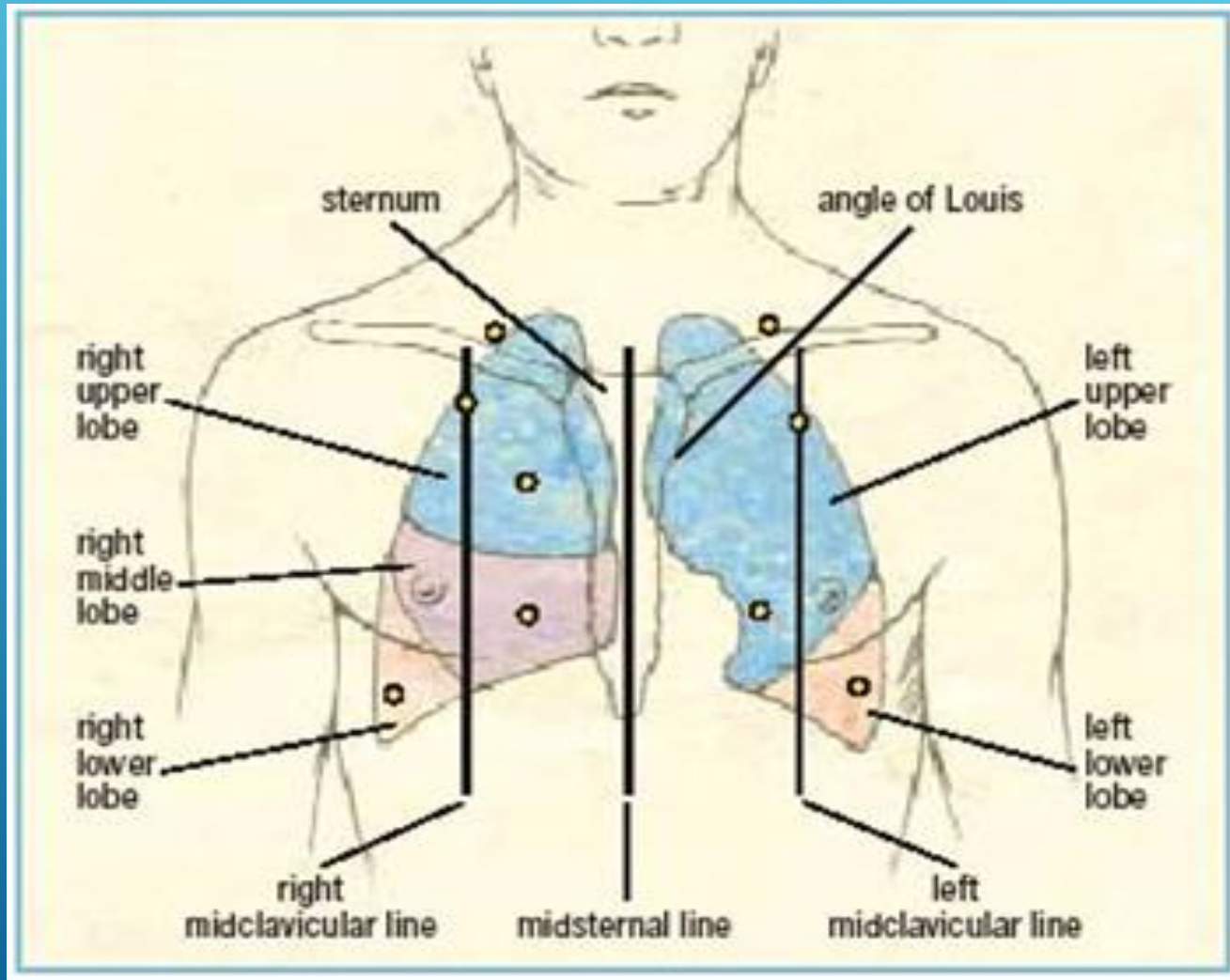
(Jean Nicholas Corvisart, 1755-1821)



(L.Auenbrugger, 1722-1809)

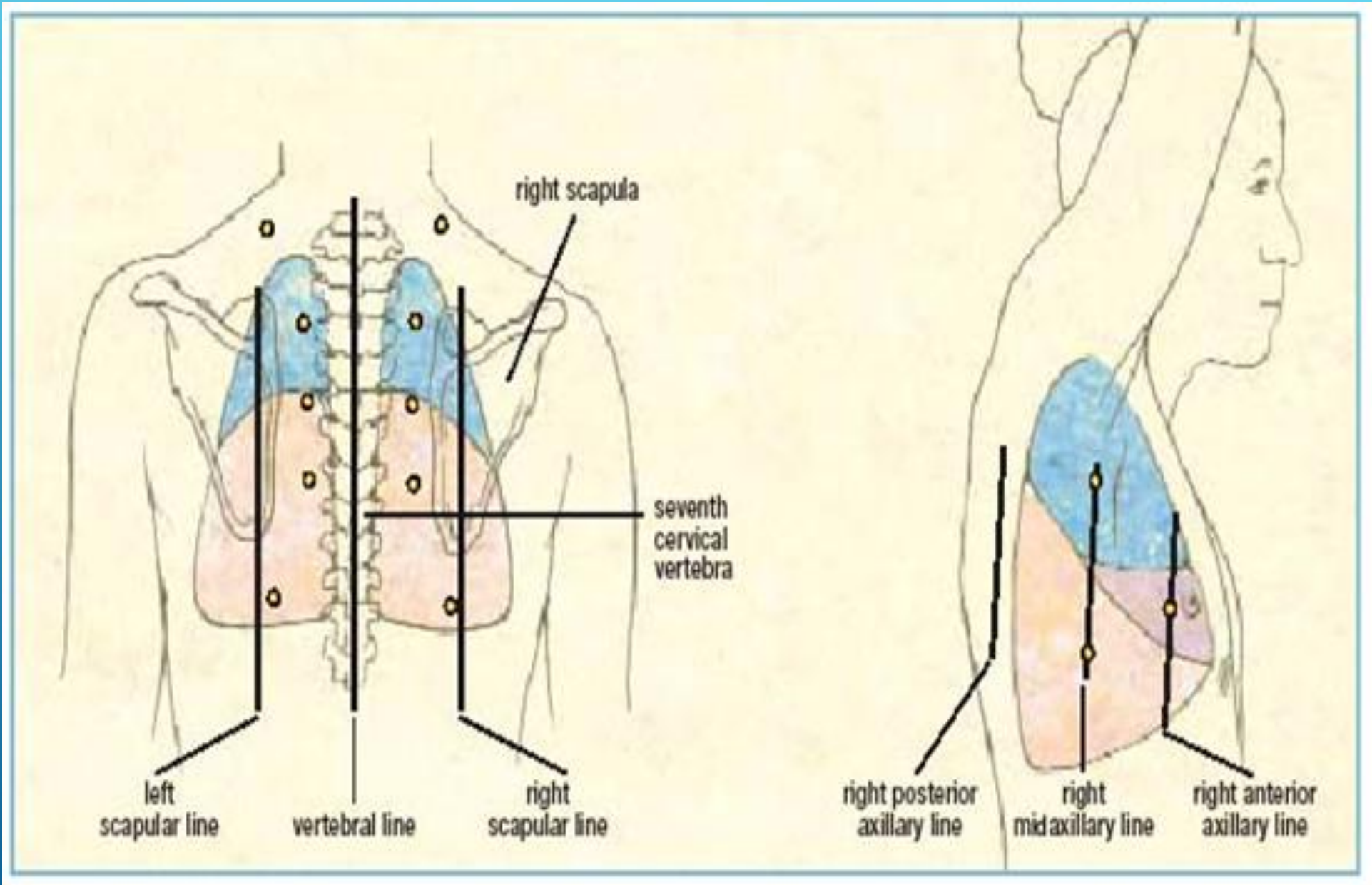


Topographic regions and lines of the chest

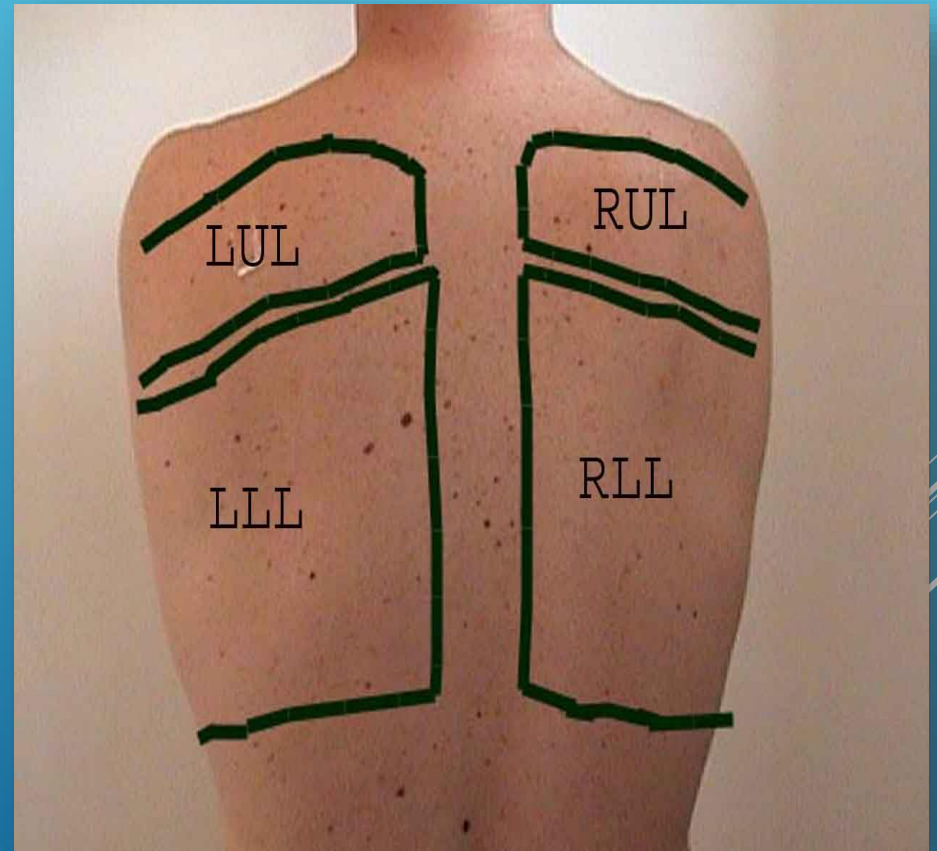
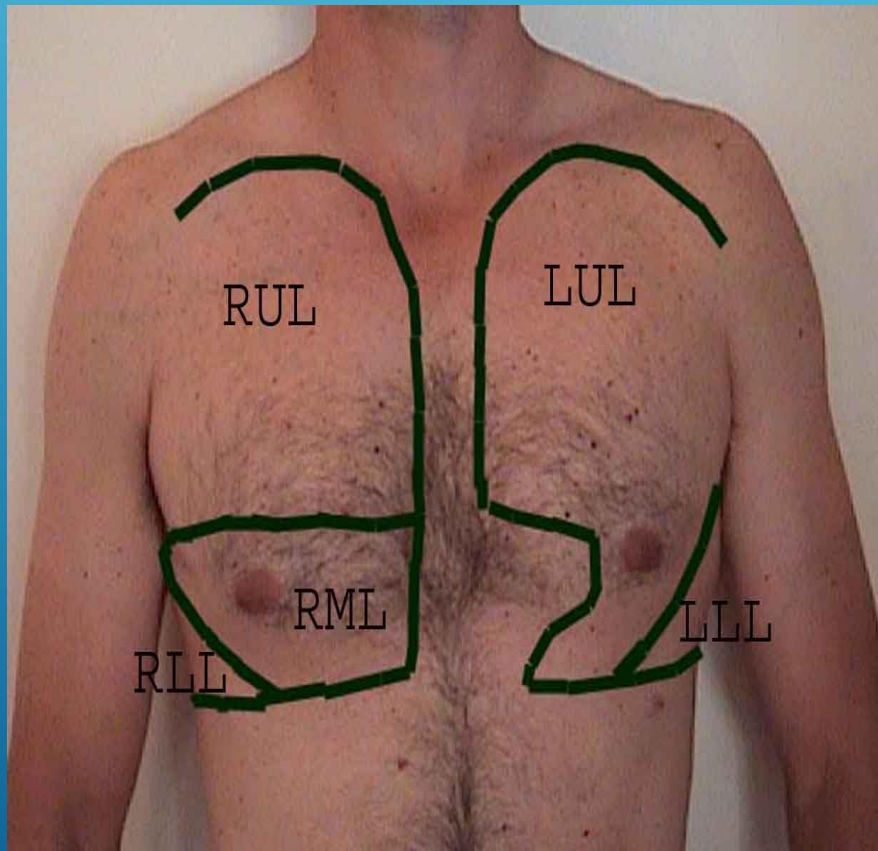


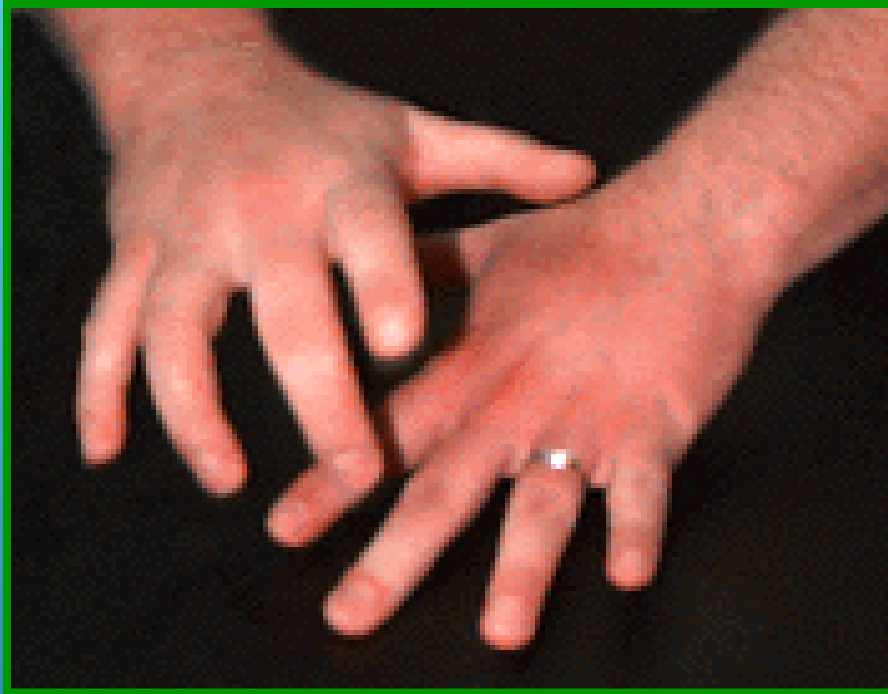Topographic regions and lines of the chest

- The left and right midaxillary lines – **linea axillaris media dextra and sinistra**
- The left and right posterior axillary lines – **linea axillaris posterior dextra and sinistra**
- The scapular left and right lines – **linea scapularis dextra and sinistra**
- The paraspinal lines dextra and sinistra – **linea paravertebralis dextra and sinistra**
- The vertebral line – **linea vertebralis – linea mediana posterior**



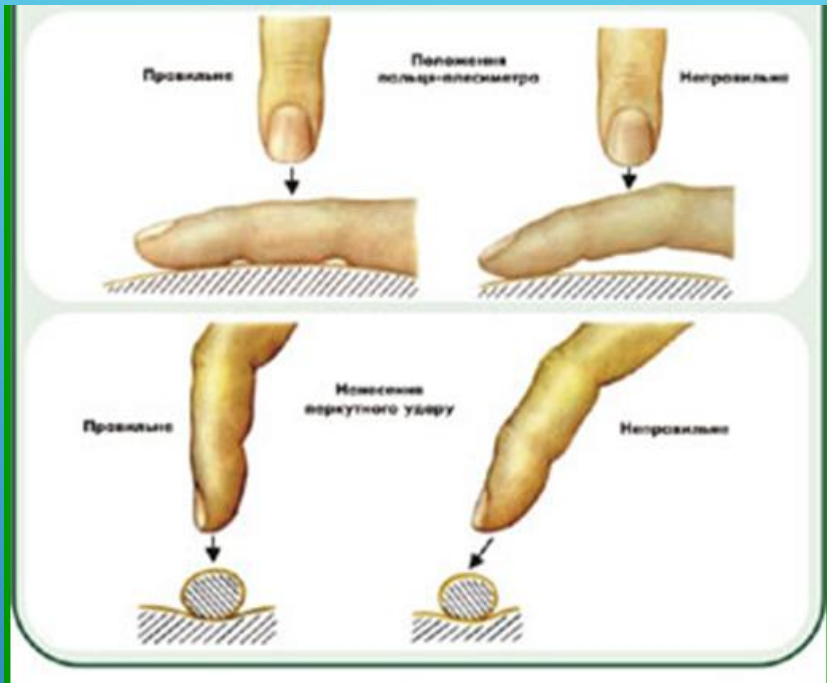
Topographic regions and lines of the chest





Percussion

Press The last 2 phalanges of your left middle finger firmly on on the area to be percussed and raise the second and fourth fingers off the chest surface; otherwise, both sound and tactile vibrations will be blunted



Use a two quick, sharp wrist motion

The best percussion site is between the proximal and distal interphalangeal joints.

Percussion of the chest

THIS IS THE OBJECTIVE METHOD OF EXAMINATION BASED ON EVALUATION OF SOUND TYPES DURING THE KNOCKING OF THE THORAX

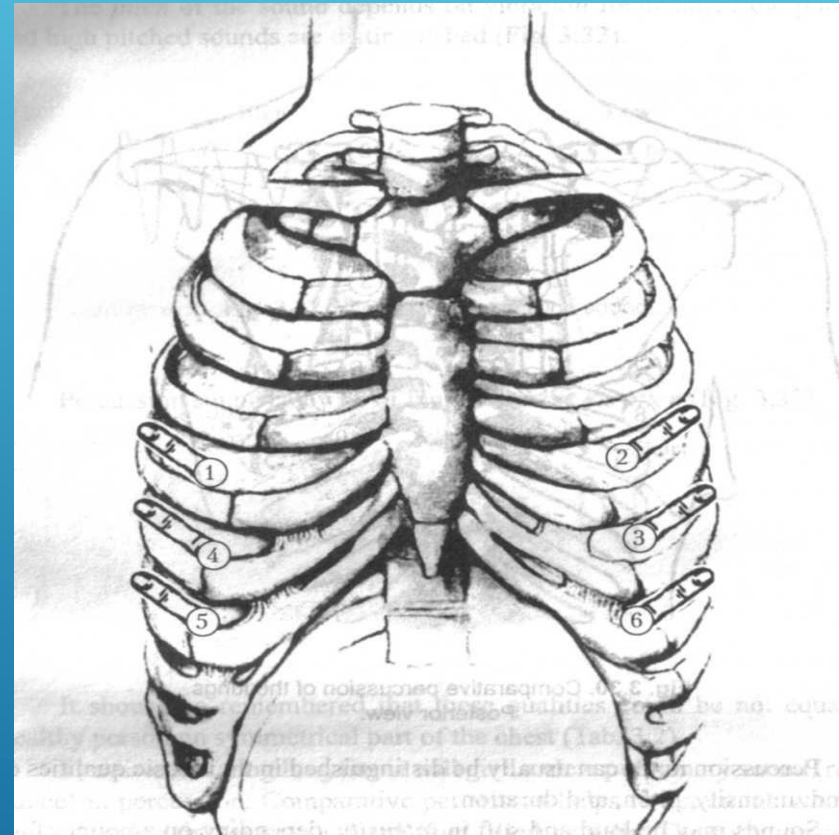
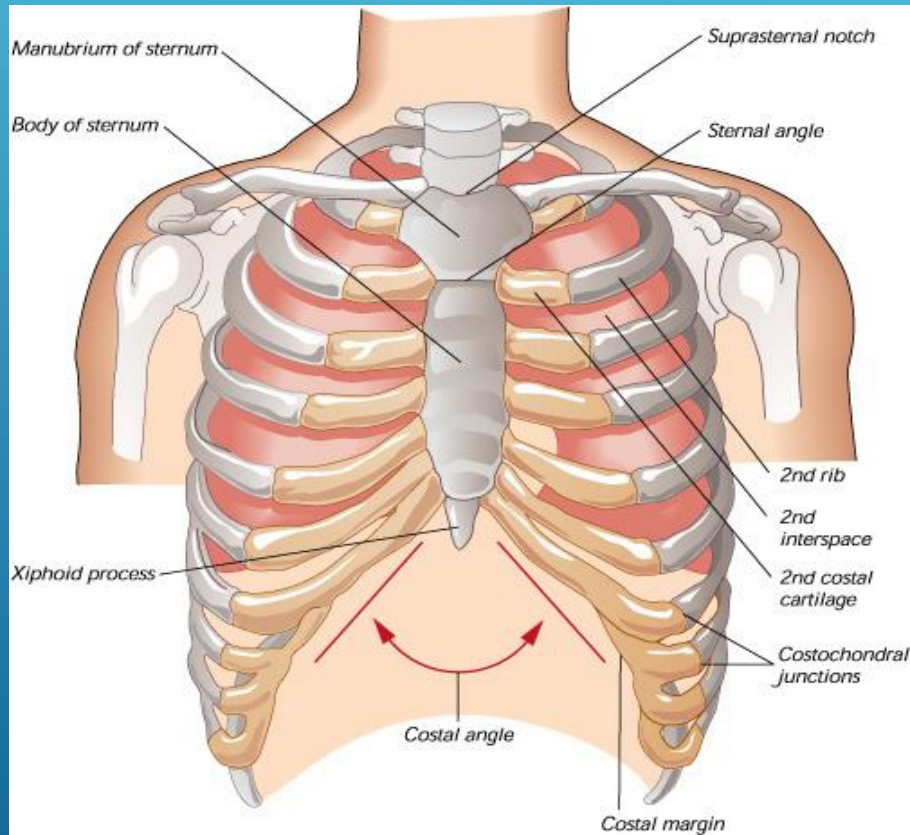
Comparative – revealing of percussion sound features on symmetrical areas of the chest:

- Supraclavicularis
- Clavicularis
- Subclavicularis
- Axillaris
- Suprascapularis
- Interscapularis
- Subscapularis

Topographic - aimed to determining :

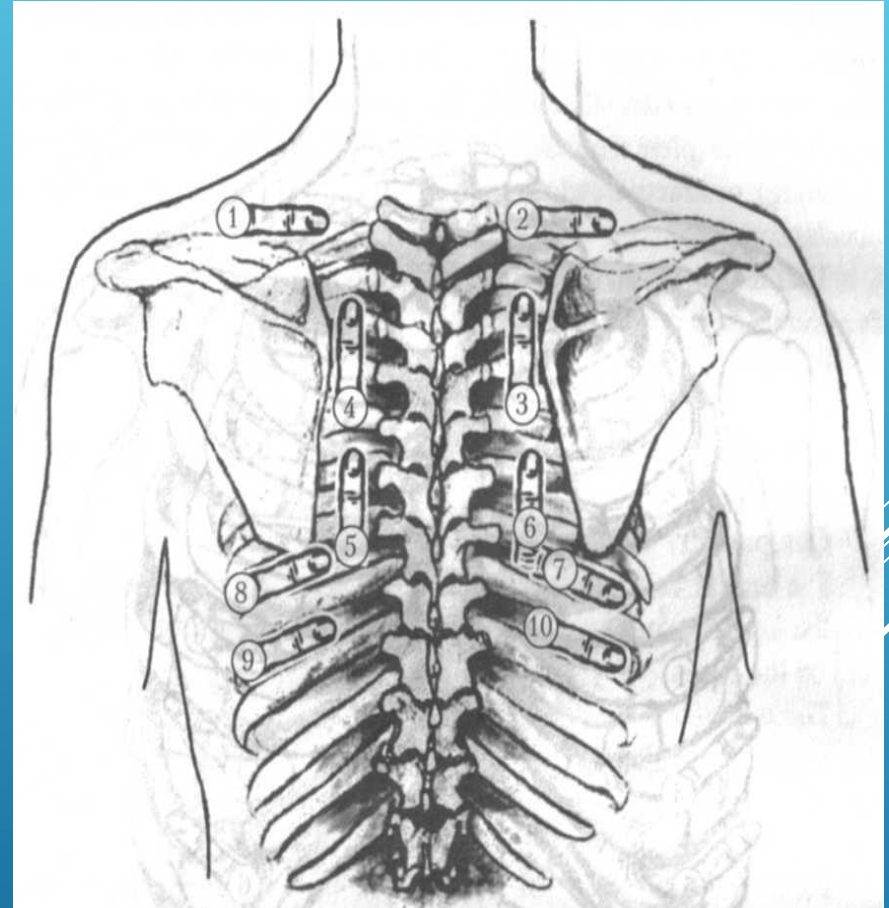
- lower borders of the lungs
- upper borders of the lungs
- the width of Crenig's area
- active and passive mobility of lower borders of the lungs
- width of Traube's area

Comparative percussion



Comparative percussion

- **Resonant** - *Clear pulmonary*
- **Intermediate** - *pulmonary sound becomes duller*
- **Dull**
- **Hyperresonant** – *Tympanic*
- **Bandbox sound** - *over the hyper inflated lungs of emphysema*



THE MAIN SYMPTOMS BASED ON COMPARATIVE PERCUSSION

Percussion sound on the symmetric areas :

Clear pulmonary (in healthy persons)

Dullness (dulling)

- Infiltration of lung tissue (tuberculosis, pneumonia, pneumosclerosis, lung cancer, abscess, lung gangrene)
- Accumulation of liquid in pleural cavity *Stony dull* – large pleural effusion
- **pleural thickening**

Tympanic

- Increasing the air capacity of lung tissue (bronchial asthma, lung emphysema)
- Formation the cavity with air in lung parenchyma (released form contents caverns, abscess, bronchoectasis)
- Accumulation of air in pleural cavity (pneumothorax)

THE MAIN SYMPTOMS BASED ON TOPOGRAPHIC PERCUSSION

1. Lower borders:

Removal down (lung emphysema, bronchial asthma, lower standing of diaphragm)

Removal upper (atelectasis, surgical ablation the part of lung, higher standing of diaphragm, subdiaphragmal abscess)

2. Upper borders:

Removal down (tuberculosis of lung apexes, pneumosclerosis, atelectasis of lung apexes)

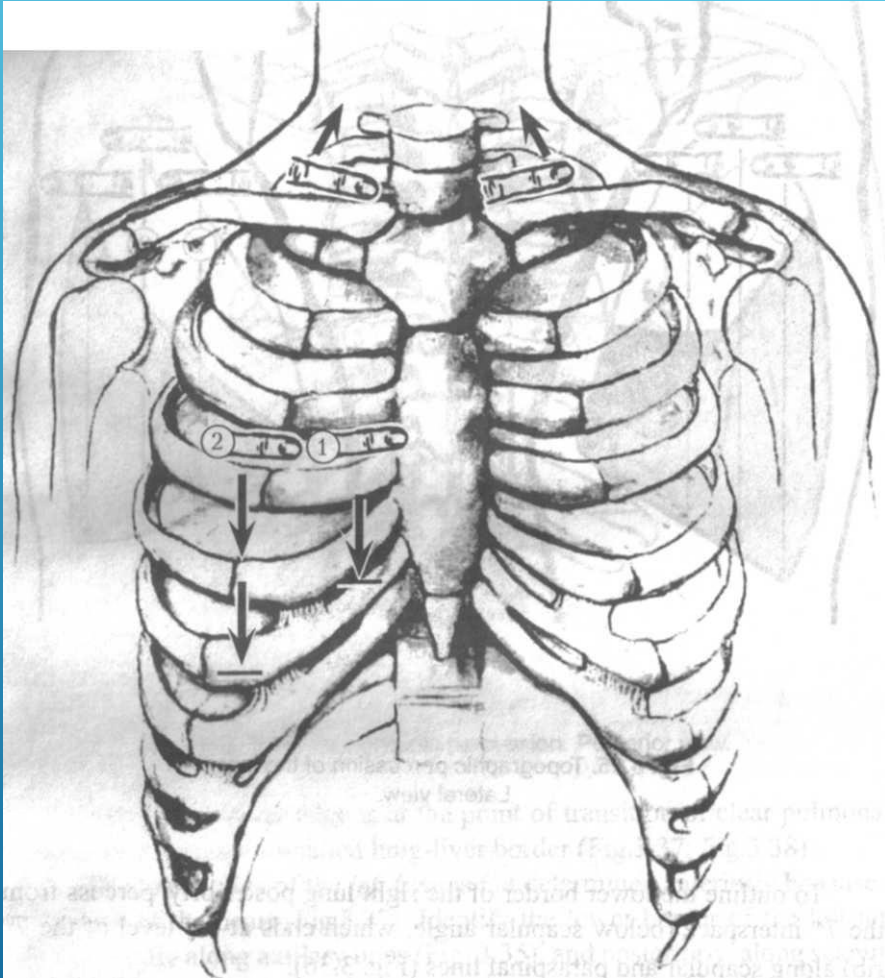
Removal upper (lung emphysema, bronchial asthma)

3. Width of Traube's area:

Increasing more than 6 sm - lung emphysema, bronchial asthma

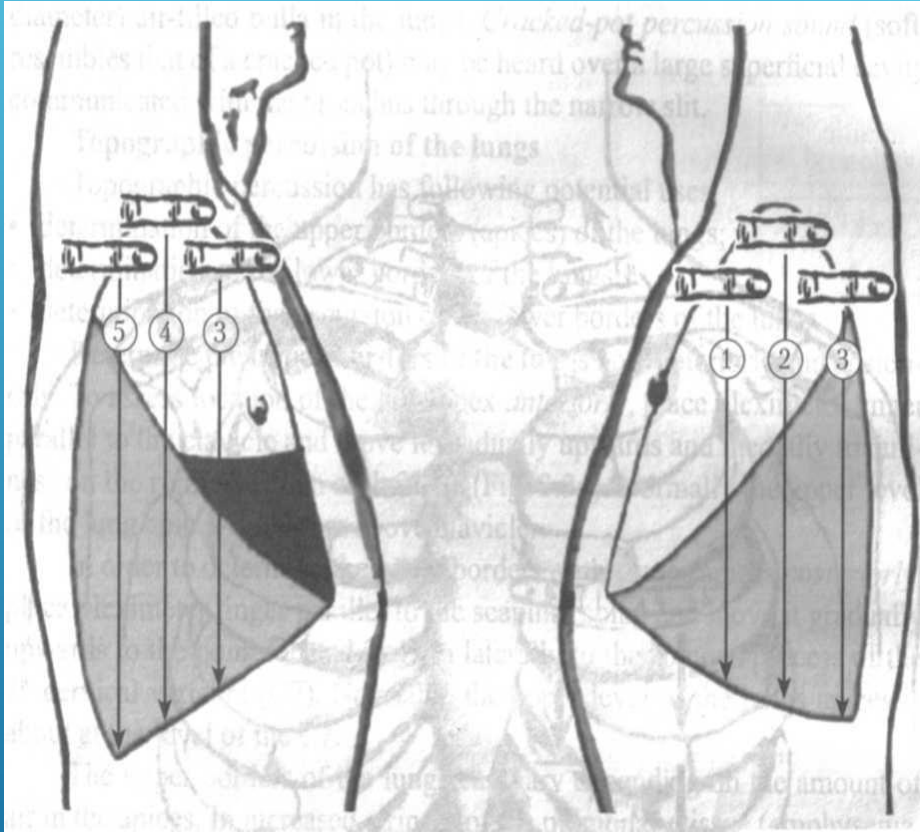
Decreasing less than 4 sm - tuberculosis of lung apexes, pneumosclerosis, atelectasis of lung apexes

Topographic percussion

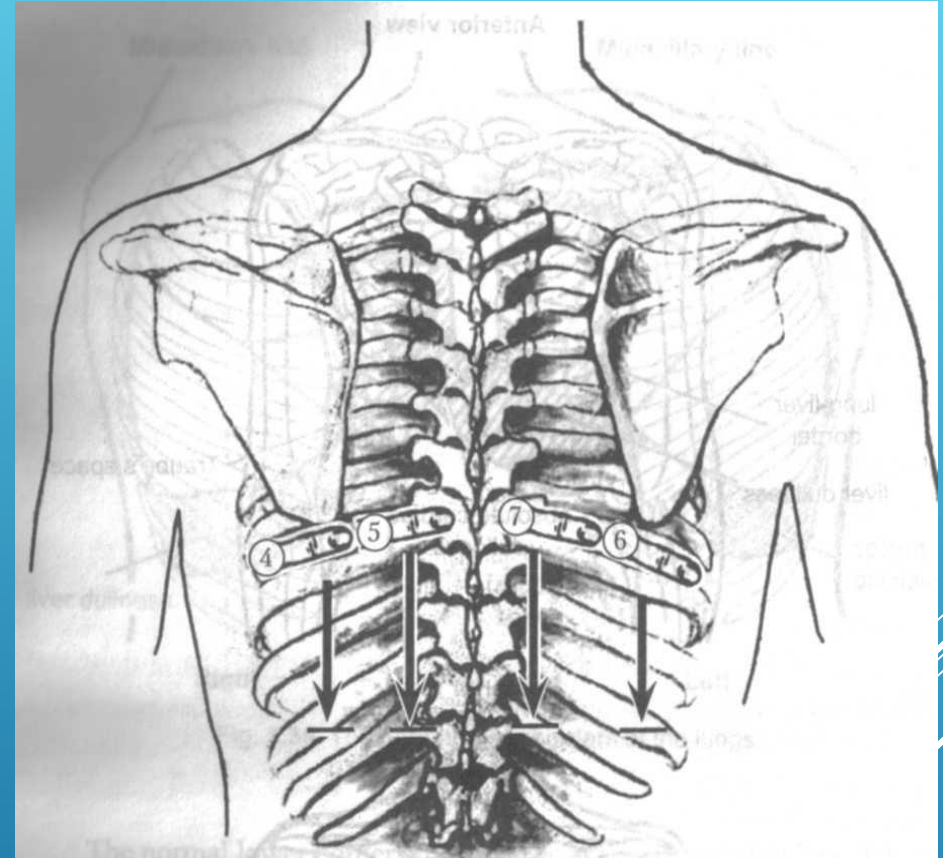


Topographic percussion of the lungs. Anterior view.

Topographic percussion



Topographic percussion of the lungs. Lateral view.



Topographic percussion. Posterior view.

Topographic percussion


lower borders of the lung

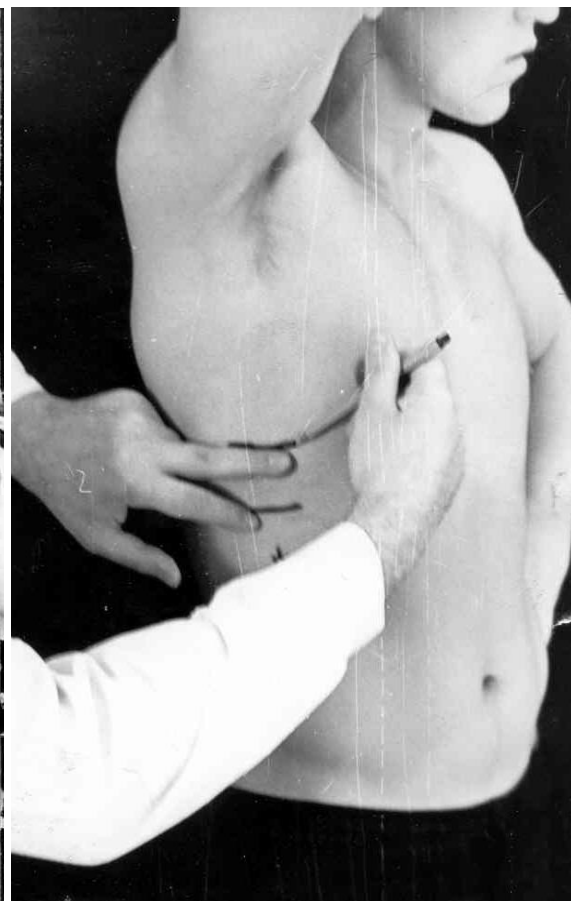
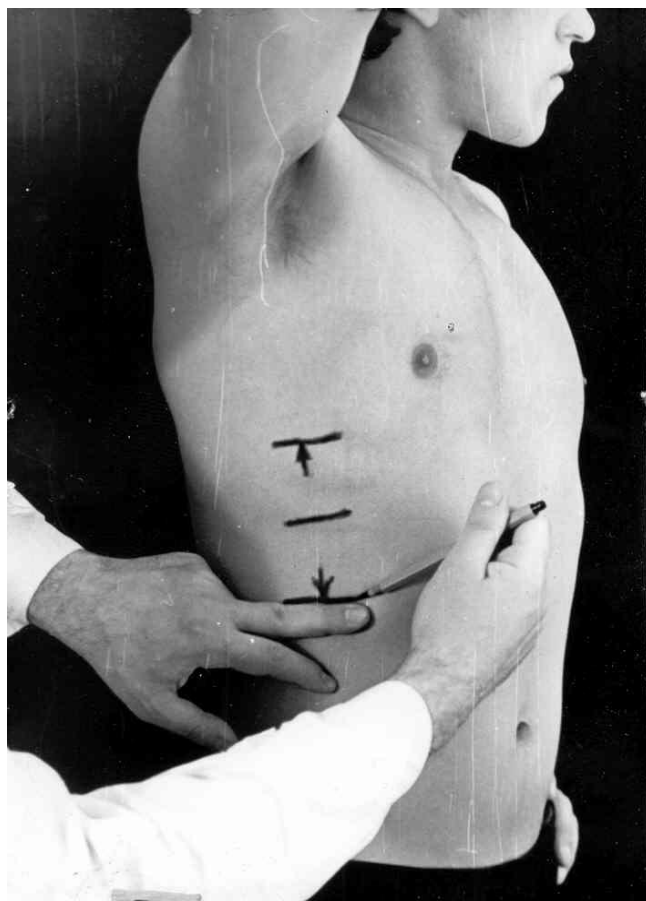
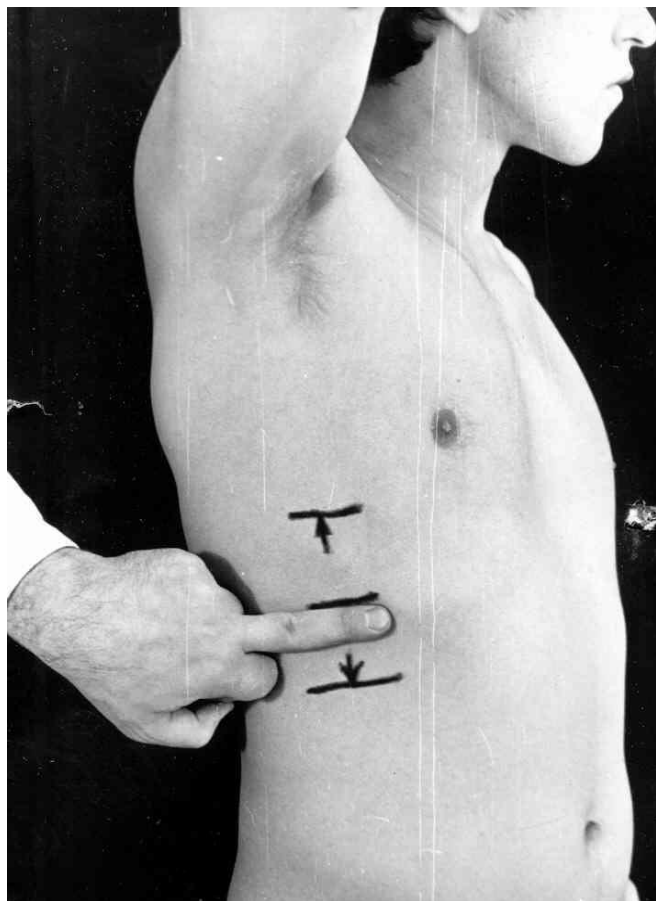
Topographic lines	Right lung	Left lung
Parasternal	5th interspace	-
Midclavicular	6th interspace	-
Anterior axillary	7th interspace	7* interspace
Midaxillary	8th interspace	8th interspace
Posterior axillary	9th interspace	9th interspace
Scapular	10th interspace	10th interspace
Paraspinal	Spinous process of T11	Spinous process of T11

4. *Active and passive mobility of the lungs* – the significance of lung tissue elasticity state and the possible mobility of lower lung border:

- *Enough* (6-8 sm) by linea axillaris media, scapularis – normal
- *Decreased* (less than 6 sm) by linea scapularis - lung emphysema, bronchial asthma, pneumosclerosis, pleural commissural, sweating pleuritis

5. *The Traube's area* – the area of tympanic sound under the left ribs arch. Diagnostically impotence –decreasing of area width:

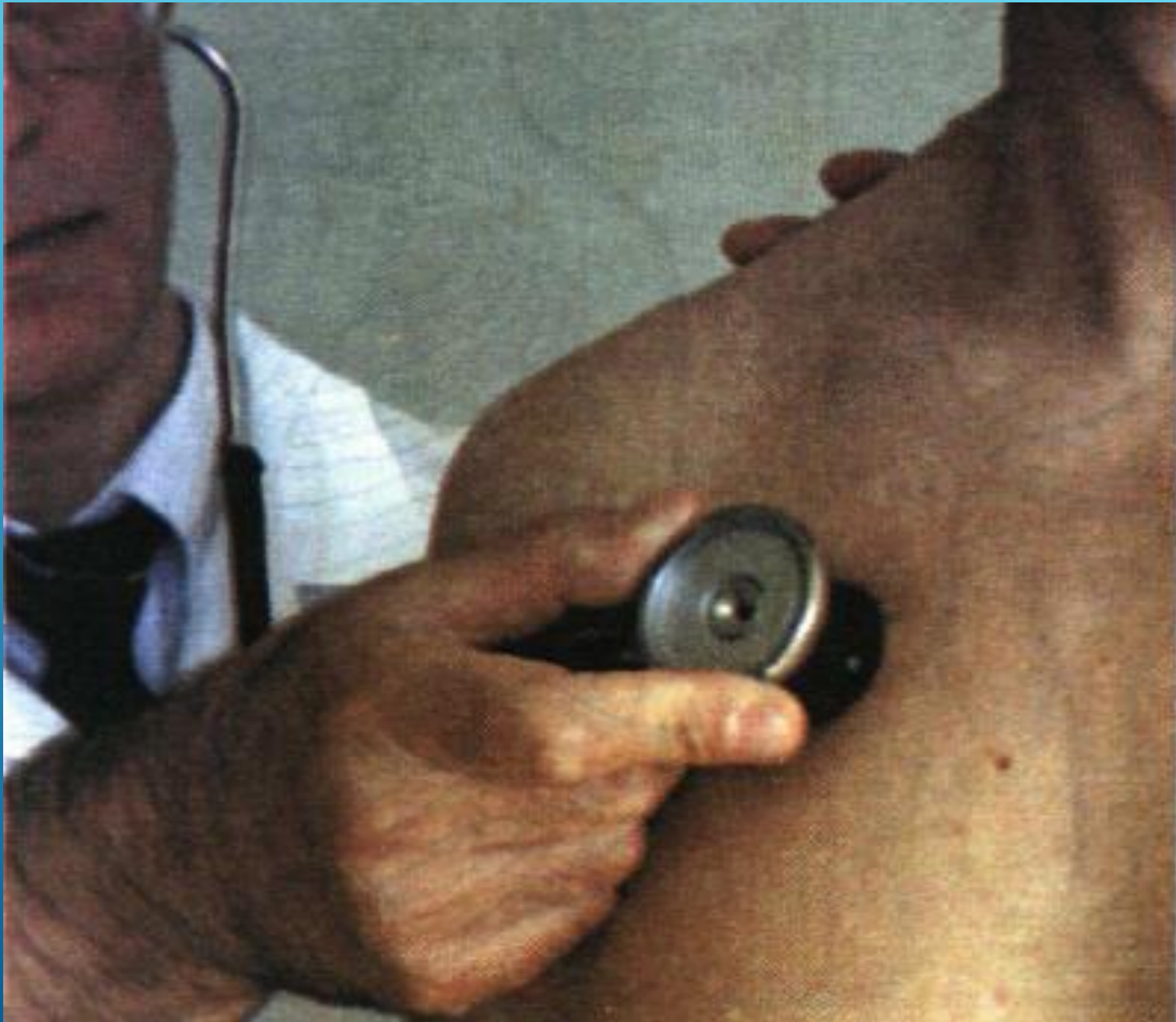
- Cancer of cardial part of stomach
 - Increasing of the liver
 - Increasing of the spleen
 - Left side sweating pleuritis
- 



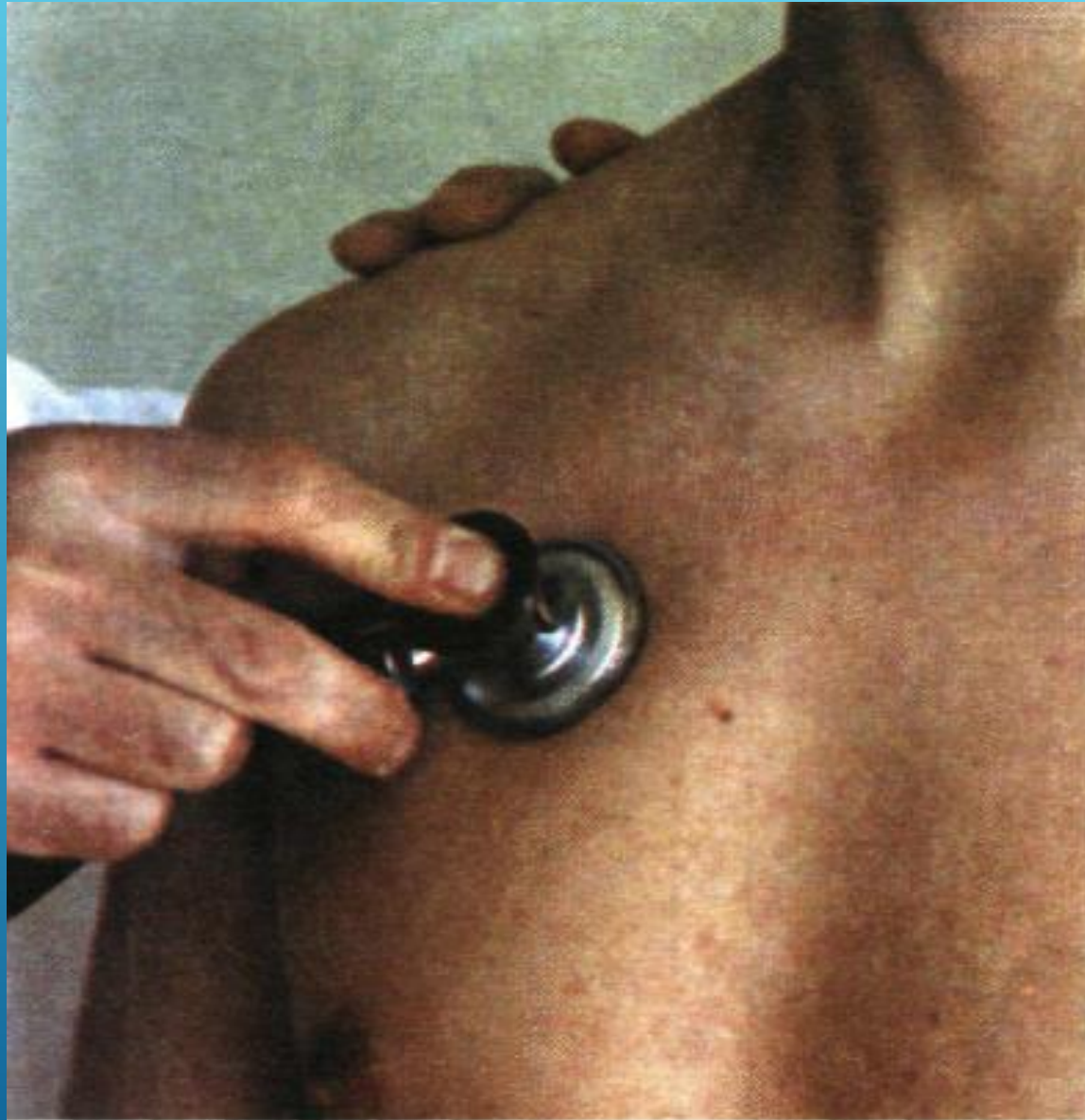
Active and passive mobility of the lungs

Topographic lines	Right lung			Left lung		
	Inspira- tion	Expiration	Total	Inspira- tion	Expiration	Total
Midclavi- cular	2-3	2-3	4-6	-		-
Midaxillary	3-4	3-4	6-8	3-4	3-4	6-8
Scapular	2-3	2-3	4-6		2-3	4-6

AUSCULTATION WITH STETHOSCOPE



AUSCULTATION WITH PHONENDOSCOPE



*Рис. 2. 73.
Техника выслушивания легких с помощью стетоскопа (а)
и фонендоскопа (б).*

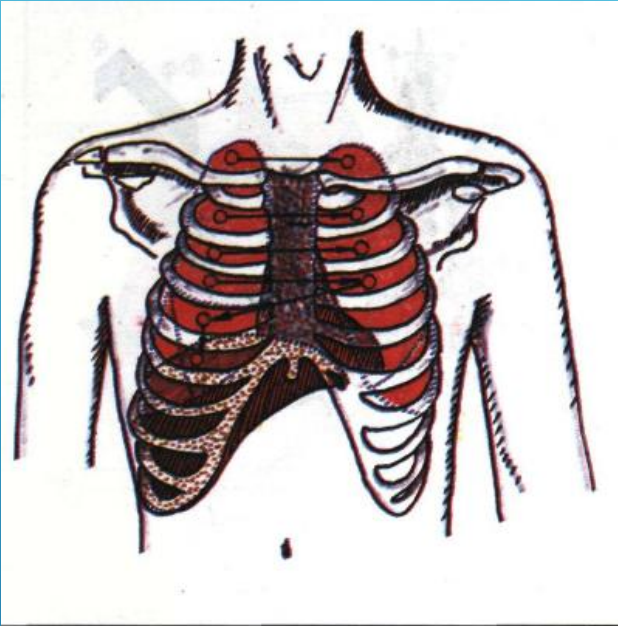
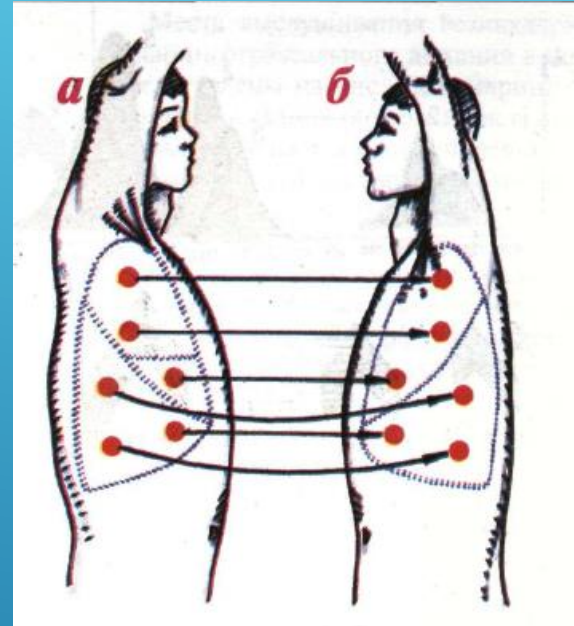


Рис.2.74. Последовательность выслушивания легких спереди. Схема.



Последовательность выслушивания боковых поверхностей легких справа (а)

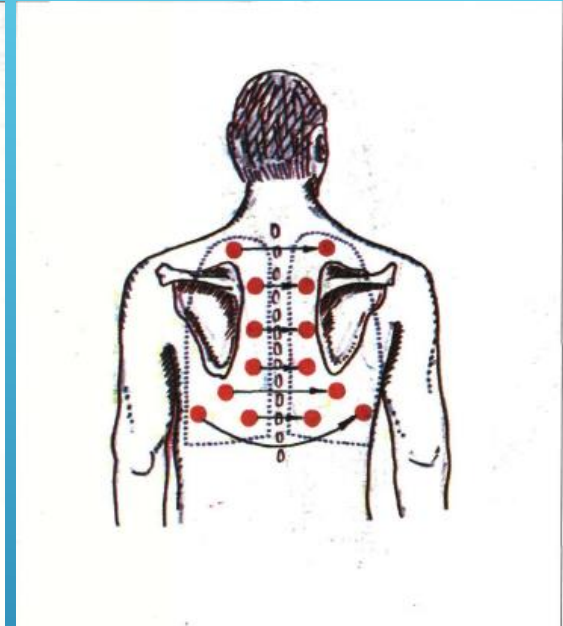
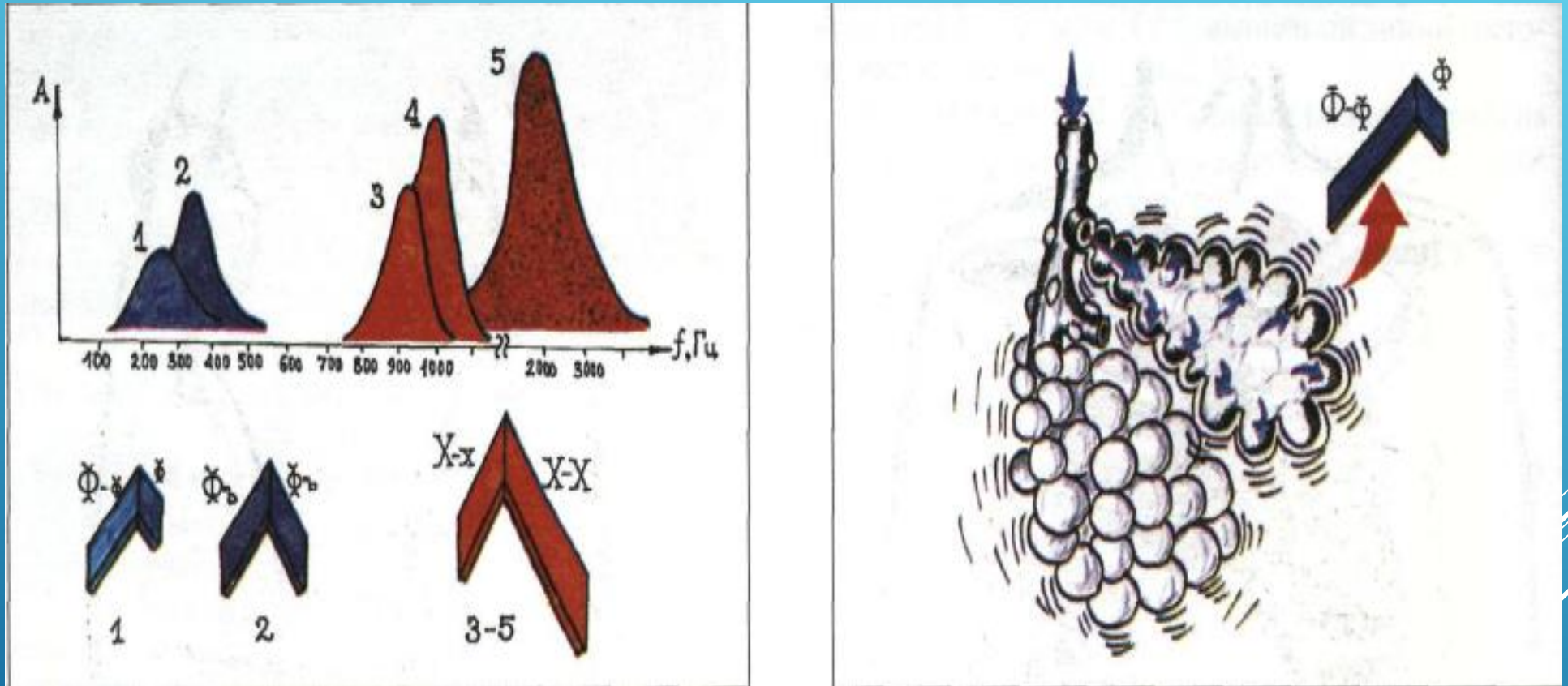


Рис.2.76. Последовательность аускультации легких сзади. Схема./

POINTS OF AUSCULTATION

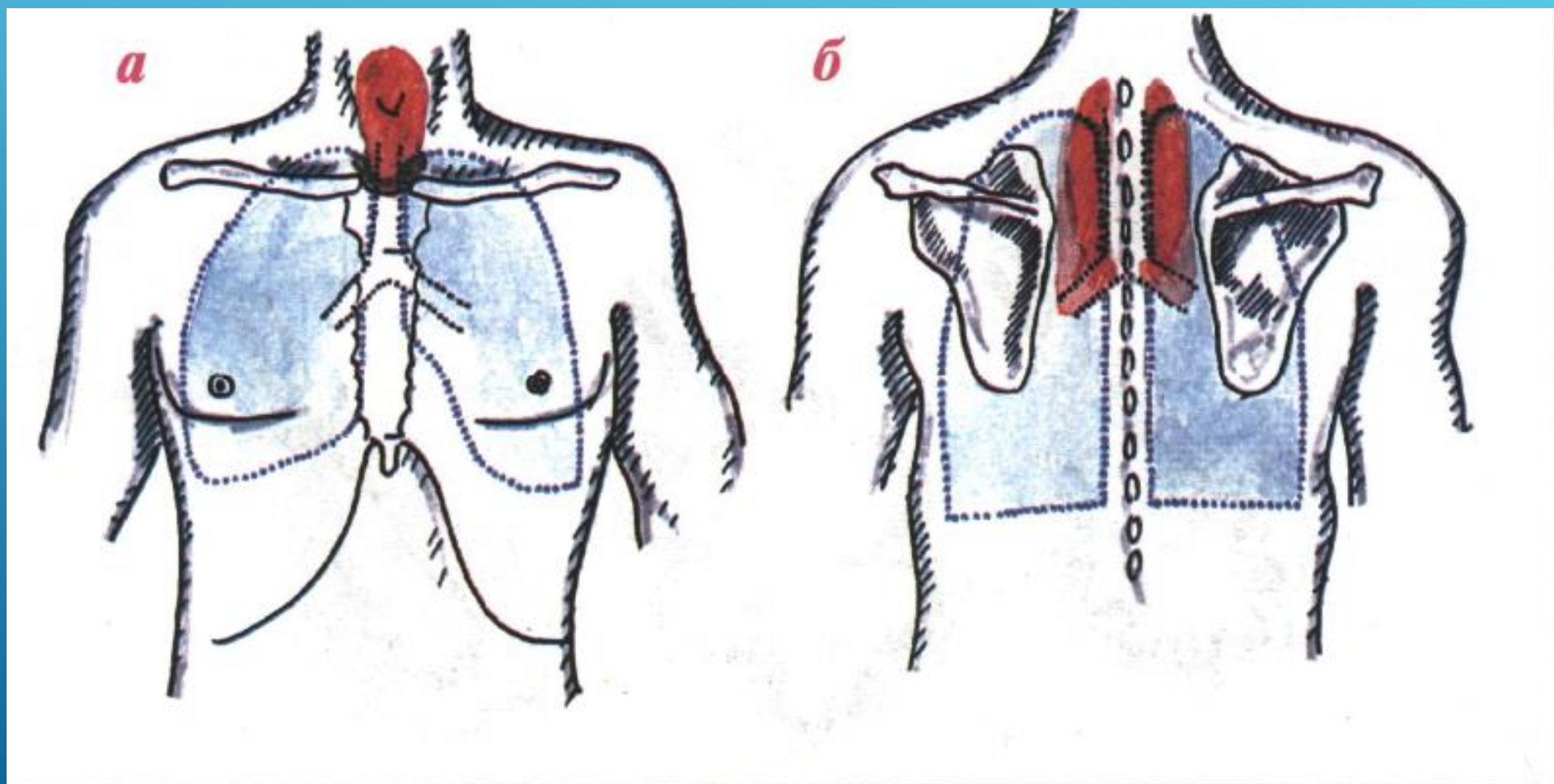
TYPES OF RESPIRATORY SOUNDS



- ▶ Vesicular breathing
- ▶ Harsh breathing
- ▶ Puerile breathing
- ▶ Bronchial breathing
- ▶ Amphoric breathing
- ▶ Cogwheel respiration
- ▶ Metallic respiration (pneumothorax)
- ▶ Stenotic respiration
- ▶ Bronchi-vesicular respiration (lobar pneumonia, infiltrative TB)

RESPIRATORY SOUNDS





2.81. Места выслушивания везикулярного и ларинготрахеального дыхания в норме; а - спереди; б - сзади.

CHANGES OF VESICULAR BREATHING

Character of breathing changes	The mechanism	Syndromes or diseases
weakening	1. Syndromes of “bar»	-hydrothorax -pneumothorax -fibrothorsx
	2. Decrease Elasticity of Alveoluses.	-emphysema of lungs -early stages of pulmonary tissue inflammation -interstitial edema of lungs
	3. Obturation of large bronchial tubes	- obturative atelectasis
intensification	1. Fever 2. Hyperthyroidism 3. Physical activity	- Not changed pulmonary tissue in the conditions of the hyperventilation
harsh	Narrowing of bronchial tubes due to edema of mucous, exudates in a lumen of bronchial tubes, a spasm smooth muscles of small bronchial tubes	Bronchitis
sakkodative	Non-uniform narrowing of the most small bronchial tubes	-Tubercular bronciolitis -Infringements of breath because of a trauma of a thorax or a pathology of respiratory muscles and their regulation

Difference	adventitious respiratory sounds			
	Dry rales	Moist rales	Crepitation	Friction sound of pleura
Connection with respiration	During inspiration and expiration	During inspiration and expiration	On the top of inspiration	During inspiration and expiration
After cough	Change	Change	Not Change	Not change
Acoustic character	More often different sounds	More often different sounds	Monotonous sounds	different sounds
At pressure of stethoscope	Not increase	Not increase	Not increase	Increase