

Michael Miloro
Editor

Trigeminal Nerve Injuries



Trigeminal Nerve Injuries

Michael Miloro
Editor

Trigeminal Nerve Injuries

 Springer

Editor

Michael Miloro, DMD, MD, FACS
Department of Oral and
Maxillofacial Surgery
University of Illinois
Chicago, Illinois
USA

ISBN 978-3-642-35538-7 ISBN 978-3-642-35539-4 (eBook)
DOI 10.1007/978-3-642-35539-4
Springer Heidelberg New York Dordrecht London

Library of Congress Control Number: 2013938301

© Springer-Verlag Berlin Heidelberg 2013

This work is subject to copyright. All rights are reserved by the Publisher, whether the whole or part of the material is concerned, specifically the rights of translation, reprinting, reuse of illustrations, recitation, broadcasting, reproduction on microfilms or in any other physical way, and transmission or information storage and retrieval, electronic adaptation, computer software, or by similar or dissimilar methodology now known or hereafter developed. Exempted from this legal reservation are brief excerpts in connection with reviews or scholarly analysis or material supplied specifically for the purpose of being entered and executed on a computer system, for exclusive use by the purchaser of the work. Duplication of this publication or parts thereof is permitted only under the provisions of the Copyright Law of the Publisher's location, in its current version, and permission for use must always be obtained from Springer. Permissions for use may be obtained through RightsLink at the Copyright Clearance Center. Violations are liable to prosecution under the respective Copyright Law.

The use of general descriptive names, registered names, trademarks, service marks, etc. in this publication does not imply, even in the absence of a specific statement, that such names are exempt from the relevant protective laws and regulations and therefore free for general use.

While the advice and information in this book are believed to be true and accurate at the date of publication, neither the authors nor the editors nor the publisher can accept any legal responsibility for any errors or omissions that may be made. The publisher makes no warranty, express or implied, with respect to the material contained herein.

Printed on acid-free paper

Springer is part of Springer Science+Business Media (www.springer.com)

To Beth and Macy, for your endless love and support.

To Joseph Foote, DMD, MD (1949–2010), my teacher and mentor at the University of Pennsylvania, for inspiring and supporting my initial interests in the diagnosis and management of trigeminal nerve injuries.

To Arden K. Hegtvedt, DDS, MS (1958–1993), a man who I never met at The Ohio State University, but who, in 1993, was a rising star in our specialty, with a passion for teaching, whose life was ended far too soon for the magnitude of his enthusiasm, and all the potential that he had to offer to the field of microneurosurgery of the trigeminal nerve.

Preface

We live in a society exquisitely dependent on science and technology, in which hardly anyone knows anything about science and technology.

Carl Sagan

Microneurosurgery of the trigeminal nerve is still in its infancy, and we continue to develop more experience and knowledge, as well as technological advancements, in managing these complex clinical dilemmas. In fact, trigeminal nerve injury management should be considered a subspecialty of oral and maxillofacial surgery since this area of surgery requires additional training, knowledge, clinical skills, and experience in order to properly diagnose and care for the patient who sustains an injury to one of the terminal branches of the trigeminal nerve. Perhaps some of the earliest publications in the English literature regarding the lingual and inferior alveolar nerve for reporting data on information other than local anesthesia were those published in the *British Dental Journal* by Cowan in 1946 who described pressure on the lingual nerve from an impacted third molar and Beauchamp in 1947 who described a case of severance of the inferior alveolar nerve during a tooth extraction. Simpson in 1958 published an article on “injuries to the inferior dental and mental nerves” in the *Journal of Oral Surgery*, but the interest in this specialty area only began to emerge in the 1960s for oral and maxillofacial surgeons, with sparse publications, including only a few case reports by Ralph Merrill, relating to decompression for inferior alveolar nerve injury published in the *Journal of Oral Surgery*. In the 1970s, microsurgery hands-on training courses were offered in the USA for those surgeons interested in pursuing advanced specialty training in the principles, and techniques of microsurgery and courses were held in various locations throughout the United States, including the University of Washington. Surgeons such as Chuck Alling, Nick Choukas, Ralph Merrill, JE Hausamen, Roger Meyer, Lenny Kaban, George Upton, Bob Campbell, Joe Van Sickels, Peter Mozsary, Larry Wolford, John Gregg, Arden Hegtvedt, Barry Eppley, Bruce Donoff, John Kiesselbach, Jim Hayward, Lee Dellon, Sue Mackinnon, Leon Davis, Ray Dionne, Bruce Epker, PP Robinson, John Zuniga, and John LaBanc were among the first to publish in the area of trigeminal nerve injuries in the 1970s and 1980s. Throughout the 1990s, there were many publications on trigeminal nerve injury; however, most of these were case reports and descriptions of specific surgical techniques based upon individual surgeon experience with little evidence-based data.

Into the new millennium, those surgeons with the most experience in this area have begun to report the results of their personal experience over many years with a reasonable number of patients, but a well-controlled multicenter clinical trial has yet to be performed in this area, although there has been interest in such a study among those individuals who are routinely evaluating

and treating the nerve-injured patient. Perhaps the only retrospective multi-center study we have available to date is that reported by LaBanc and Gregg in the 1992 *Oral and Maxillofacial Clinics of North America*. This Clinics of North America publication entitled *Trigeminal Nerve Injury: Diagnosis and Management*, edited by John LaBanc and John Zuniga, was the first attempt to bring the subject of trigeminal nerve injuries to the forefront of clinical practice for oral and maxillofacial surgeons. This issue was followed nearly a decade later by a second *Oral and Maxillofacial Surgery Clinics of North America* devoted to *Clinical Trials in Orofacial Neurotrauma*, edited by John Zuniga and John Gregg. These two clinics were focused efforts to heighten awareness and increase access to care for patients who sustain trigeminal nerve injuries. In addition, two *Atlases of the Oral and Maxillofacial Surgery Clinics of North America* were published in 2001 and 2011, with illustrated chapters demonstrating specific microneurosurgical techniques. The paucity of an organized and comprehensive treatise on trigeminal nerve injury has been the impetus for this textbook on *Trigeminal Nerve Injuries*. The Table of Contents of this textbook is organized to include the requisite information about our current understanding regarding the specialty of microneurosurgery of the trigeminal nerve, authored by the recognized experts in the field, including an impressive international group of surgeons with arguably the most clinical experience and expertise in this area. While most of these trigeminal nerve injury experts are well beyond their “textbook chapter writing days,” they were uniformly highly motivated to participate in this important project. There was a consensus that a reference textbook was essential for the practicing clinician, including dentists, dental specialists, and oral and maxillofacial surgeons, and other medical and dental professionals, to allow appropriate assessment of patients who sustain nerve injuries, in order to gain an understanding of the short- and long-term treatment options and, also importantly, to determine at what point in time to make the appropriate referral for care, and to whom, either a microneurosurgeon or neurologist or other medical professional, and to make the patient referral. In many cases, it is appropriate to obtain a neurology consultation to assist with pharmacologic management; however, it may not be as simple to find an experienced microneurosurgeon of the trigeminal nerve. The *American Association of Oral and Maxillofacial Surgeons* provides assistance to those dentists and surgeons who wish to locate a regional microneurosurgical expert, but this information should be made readily available to all practitioners. In fact, regional referral centers should be established that have the necessary experience to most appropriately manage the nerve-injured patient. Since the majority of regional experts in the USA are either full-time or part-time academicians, accredited oral and maxillofacial surgery training programs may fulfill the need of the clinician for initial patient referral and triage. As more residents in oral and maxillofacial surgery are trained in the techniques of assessment and management of nerve-injured patients, more microneurosurgeons will be available throughout the country and throughout the world, to improve access to care for the trigeminal nerve-injured patient.

While we have learned a great deal about nerve injuries and repair and we have had many reports in the literature over the past few decades and while much has changed, at the same time, very little has changed in the diagnosis and management of trigeminal nerve injuries. Certainly, we have learned a great deal since John C. Warren published his experience in *The Boston Medical and Surgical Journal* I: 1; 1, February 19, 1928 entitled “Cases of neuralgia, or painful affections of nerves.” Dr. Warren describes cases of trigeminal neuralgia that had failed pharmacologic treatment that he managed with surgical transection of the terminal branches of the nerve, with immediate recurrence of the painful trigeminal neuralgia symptoms. During an abstract presentation at the 73rd AAOMS Annual Meeting and Scientific Sessions in Chicago, Illinois, on September 25, 1991 by Roger Meyer, he indicated that microneurosurgery delayed for more than 1 year had a significantly negative impact on long-term neurosensory recovery, and, in his 2012 publication, he has maintained his opinion based upon a retrospective review of 167 patients over nearly 20 years. On the other hand, what has changed in clinical assessment and management of trigeminal nerve injuries includes the use of cone-beam 3D imaging for IAN injury risk assessment for third molar surgery, endoscopic-assisted surgery to access difficult sites, the use of nerve growth factors and other cytokines, suture laser welding of neural anastomosis sites, the use of allogeneic cadaveric nerve tissue for nerve grafting, and, certainly, surgeon experience continues to improve. It is interesting to note that according to several publications (including Pogrel and Robinson, as well as the experience of others), the number of surgical cases is less than 10 % of all patient consultations for nerve injury. As a result, the microneurosurgeon and residents in training working with these surgeons are exposed to a large number of patients that allow the development of diagnostic skills for nerve injury assessment.

At the present time, there is certainly a lack of available data to allow for evidence-based treatment decisions with regard to patient evaluation, surgical indications, degree of acceptable paresthesia, proper timing for exploration and repair, and expected outcomes and following trigeminal nerve repair surgery. When the patient symptomatology includes unpleasant or painful sensations, what is the most appropriate pharmacologic regimen to use, should medications be applied locally and/or systemically, and what is the role of behavioral therapy, vitamin B therapy, low-level laser therapy, psychotherapy, as well as microneurosurgical management of neuropathic pain? Therefore, and since the majority of existing data is retrospective in nature, a multicenter trial is essential in order to most appropriately answer these questions. This should be a well-designed controlled multicenter clinical trial with experienced microneurosurgeons using standardized data acquisition (e.g., Sunderland grading system) and examination reporting parameters (e.g., MRSC grading scale of functional neurosensory recovery). An attempt at standardization was performed in 1998 by Zuniga et al., which established the validity of the Sunderland grading system for IAN and LN injuries. A great deal of credit must be given to those surgeons who have continued to evaluate their individual experience and publish in this area of the past

20 years, and the majority of those individuals are contributing authors in this textbook due to their expertise in this specialty area. Also, since the literature has shown that existing surgical treatment modalities have not been shown to predictably result in functional neurosensory recovery even in the hands of experienced surgeons (with reported success rates of less than 50 %, although more recent studies showing a success rate in the 80–90 % range), other management options must be explored, including nonsurgical options and other innovative techniques possibly utilizing neural growth factors and possibly vitamin enhancement at the site of injury. Also, improved noninvasive imaging resolution of fascicular disruption patterns in individual patients must be developed with the continued technological advancements in radiology. In addition, multimodality treatment of painful neuropathies is essential to prevent progression to complex regional pain syndromes, and clinical and experimental research in this area continues today.

Finally, when I initially contacted potential authors about the idea of a textbook on *trigeminal nerve injuries*, the overwhelming response was extremely positive and the general sentiment was that this project was essential and long overdue. In fact, the known “experts” in this area are represented in this textbook, and even a chapter on the management of Facial Nerve Injuries is also included. This project was completed within a very short time frame from conception of the idea between Sverre Klemp with Springer-Verlag and me at the 93rd Annual AAOMS meeting on September 17, 2011 in Philadelphia. I want to thank all of the contributing experts for collaborating to make this textbook a significant contribution to the literature in the area of trigeminal nerve injuries. I must personally thank each of the authors in this textbook for their expertise in providing a contribution to this definitive textbook on *trigeminal nerve injuries*. I am very pleased that we have amassed an international authorship so that we could develop a universal consensus on patient diagnosis and management and, also, that we could consider organizing an international multicenter trial for patient diagnosis and management and perhaps determine a consensus for new recommendations and guidelines for improved care of the patient who sustains a trigeminal nerve injury, since, ultimately, this is the goal of this book.

Chicago, Illinois, USA

Michael Miloro

Contents

| | | |
|-----------|--|------------|
| 1 | Historical Perspectives on Trigeminal Nerve Injuries | 1 |
| | John M. Gregg | |
| 2 | Classification of Nerve Injuries | 17 |
| | John R. Zuniga and Alaaldin M. Radwan | |
| 3 | Etiology and Prevention of Nerve Injuries | 27 |
| | Roger A. Meyer and Shahrokh C. Bagheri | |
| 4 | Injection Injuries of the Trigeminal Nerve | 63 |
| | Søren Hillerup | |
| 5 | Third Molar Injuries of the Trigeminal Nerve | 73 |
| | Eduard Valmaseda-Castellón and Cosme Gay-Escoda | |
| 6 | Dental Implant-Related Injuries of the Trigeminal Nerve | 87 |
| | Shahrokh C. Bagheri and Roger A. Meyer | |
| 7 | Nerve Repositioning Injuries of the Trigeminal Nerve | 109 |
| | Ali Hassani and Sarang Saadat | |
| 8 | Orthognathic Injuries of the Trigeminal Nerve | 137 |
| | Anders Westermark | |
| 9 | Nerve Injury and Regeneration | 149 |
| | Martin B. Steed | |
| 10 | Clinical Evaluation of Nerve Injuries | 167 |
| | Roger A. Meyer and Shahrokh C. Bagheri | |
| 11 | Imaging of the Trigeminal Nerve | 199 |
| | Michael Miloro and Antonia Kolokythas | |
| 12 | Nonsurgical Management of Trigeminal Nerve Injuries | 213 |
| | Tara Renton | |
| 13 | Surgical Management of Lingual Nerve Injuries | 229 |
| | Vincent B. Ziccardi and Rabie M. Shanti | |
| 14 | Surgical Management of Inferior Alveolar Nerve Injuries | 239 |
| | M. Anthony Pogrel | |

| | |
|---|-----|
| 15 Surgical Management of Facial Nerve Injuries | 253 |
| Alison Snyder-Warwick, Thomas H. Tung, and Susan E. Mackinnon | |
| 16 Nerve Grafts and Conduits | 271 |
| Larry M. Wolford and Daniel B. Rodrigues | |
| 17 Complications of Trigeminal Nerve Repair | 291 |
| Michael Miloro, Thomas Schlieve, and Antonia Kolokythas | |
| 18 Neurosensory Rehabilitation | 301 |
| Greg K. Essick, George Blakey III, and Ceib Phillips | |
| 19 Outcomes of Trigeminal Nerve Repair | 317 |
| Peter P. Robinson, Keith G. Smith, and Søren Hillerup | |
| 20 Guidelines for Diagnosis and Treatment of Trigeminal Nerve Injuries | 343 |
| Salvatore L. Ruggiero and Michael Proothi | |
| Glossary | 361 |
| Index | 363 |

Historical Perspectives on Trigeminal Nerve Injuries

1

John M. Gregg

Understanding and treating the effects of human neurotrauma was hampered for centuries by ancient misunderstandings of the primary loci of sensory perception. However, elegant descriptions were made of the clinical effects of nerve injuries suffered by Civil War survivors, and research following the World Wars explained many of the underlying neural mechanisms. In the nineteenth century, nerve injuries had been treated unsuccessfully by secondary neural ablations, and fortunately, in the twentieth century, this led to therapies designed to repair nerves and enhance regeneration, enabled by studies of animal injury models, the introduction of the operating microscope, and proof that microsurgical techniques used for repair of hand nerve injuries could be successfully adapted to epineurial trigeminal nerve repairs.

The modern era has demonstrated that direct end-to-end trigeminal nerve repairs can result in high levels of useful functional sensory recovery even following long intervals after partial trigeminal injury. Historically, entubulation repairs of larger nerve gaps have been largely unsuccessful in the trigeminal system, although interpositional nerve grafting has proven useful and has been enhanced recently by the development of processed

cadaveric allografts and promising research with stem cell tissue engineering. Reversal of neuropathic pain through peripheral nerve surgery, however, has continued to be disappointing, as well as the failure to incorporate knowledge of nerve injury and neuropathic pain mechanisms into the medical and dental curriculum.

Injuries to the nerves of the jaws and face have surely been a part of life since the dawn of mankind. Yet, it has only been in the last three centuries that the devastating effects of peripheral nerve injuries have begun to be appreciated, and a scientific basis for effective treatments has emerged.

This opening chapter will plot the beginnings of published knowledge regarding neurotrauma. It will review what has been learned in the last two centuries, especially about early descriptions of the clinical effects of nerve injuries resulting from the American Civil and World Wars. It will summarize the main findings that underlie understanding of the effects of neurotrauma and recognize the roles that outstanding neuroscientists and clinicians have contributed along the way. It will focus especially on the foundations of microsurgery that led to modern techniques for treating trigeminal nerve injuries, noting the progress that has been made in the last few decades toward finding more useful diagnostic methods and implementing more effective surgical and nonsurgical treatment modalities.

Finally, because a prime purpose of historical knowledge is the impact that it may have on directing the future, this chapter will end with a section on “Unfinished Business” that will highlight the current challenges and offer a “wish list”

J.M. Gregg, DDS, MS, PhD
Department of Oral and Maxillofacial Surgery,
Virginia Commonwealth University, Medical
College of Virginia, Richmond, VA, USA

Virginia Tech Carilion School of Medicine,
Roanoke, VA, USA
e-mail: jgregg@vt.edu

that could lead to a deeper understanding of nerve injury effects, more accurate clinical diagnoses, more appropriate treatment regimens, and enhanced professional education that will facilitate healthcare access and delivery for patients who sustain nerve injuries.

1.1 The Beginnings of Knowledge

Ancient understandings of peripheral nerve injury effects were hampered for many centuries by devotion to the philosophies of Aristotle and Hippocrates (460–370 B.C.) that placed functions of the “five senses” and “soul” in the heart, rather than the nervous system [1]. Galen (A.D. 131–200) however doubted the Aristotelian views. Galen’s experiments included the sectioning of the recurrent laryngeal nerves of newborn pigs and supported his conclusions that the peripheral nerves and the brain are the mediators of sensation [82]. In support of Galen’s theories, Rene Descartes speculated in the year 1664 that sensations were mediated through “fast moving particles of fire...(that) pass(es) through the nerve filament until it reaches the brain” [25]. He also observed that “suffering may follow amputation.”

Considering the early confusion regarding the functional role of peripheral nerves, there are remarkable early reports of injured nerve treatments. In the thirteenth century, William of Salicito (Bologna) reportedly rejoined the ulnar nerve of an Italian soldier, and a detailed description of suture repair was made by Gabriele Ferrara in 1608 [6, 38]. In 1847, Sir James Paget sutured the median nerve of an 11-year-old boy, reportedly achieving “complete recovery” [144]. In an experimental milestone, Augustus Waller [137] created glossopharyngeal (IX) and vagus (X) nerve injuries in frogs and described gross degeneration distal to the site of injury, regeneration of axons in proximal segments, and greater preservation of nerves in younger compared to older frogs [137].

Better understanding of the anatomic effects of nerve injuries, however, depended upon the development and use of the light microscope by Anton van Leeuwenhoek (1632–1677). Additionally, Ramon y Cajal from Spain, the father of neuroanatomy and winner of the 1906

Nobel Prize shared with Camillo Golgi, used silver staining to demonstrate nerve microstructure, degeneration of fibers distal to nerve injury sites, and Schwann cell guidance of regeneration cones [118]. Cajal’s work also predicted the presence of “synapses,” a term coined by Sherrington (1857–1952) to designate the connections between nerves [130].

The physiologic effects of nerve injury were also being revealed by the mid-eighteenth century. Galvani (1737–1798) had demonstrated that nerve fibers respond to electrical stimuli [84]. Electrical “action potentials” were described in peripheral nerve fibers by von Helmholtz (1821–1894) and Duchenne, who measured conduction velocities in human nerves [33]. This information laid the groundwork for the 1948 Nobel Prize work by Erlanger and Gasser, who demonstrated nerve action potentials in teased single nerve fibers. This revealed that nerves contain a spectrum of fibers from fine tactile A-fibers to C-fiber nociceptors that would later become the primary targets for neurophysiologic testing of patients with nerve injuries [34].

1.2 The Clinical Features of Nerve Injuries: Lessons from the Historic Wars

The major wars of the past two centuries were followed by spurts of knowledge concerning the clinical effects of nerve injuries. The greatest impetus came from the American Civil War with the pioneering observations of Silas Weir Mitchell (1864–1906) [101, 102]. As Senior Acting Assistant Surgeon in the Union Army at the 400-bed Turners Street Philadelphia Hospital, he treated hundreds of nerve-injured patients, mostly survivors from Gettysburg, and, assisted by his son, followed their courses for 40 years. Through his remarkable observations and publications, he revealed many of the prime clinical features of traumatic neuropathies that have been verified by subsequent clinicians and neuroscientists. Some key nerve injury features credited to SW Mitchell include:

1. Phantom phenomena, referred pain, and daily pain cycles

I am more sure of (sensing) the leg which ain’t than the one which are [101].

2. Burning pain (causalgia) (an intractable post-traumatic collision effect of autonomic and somatosensory functions linking temperature, environmental, and psychiatric factors)
A 24-year-old member of the 26th Pennsylvania Volunteers was shot at Chancellorsville through the leg. He lay in the field for 28 h before wet compresses were put on his leg. At that time, he began to complain of severe burning in his heel and showed (minimal) sensory loss.
3. Touch-evoked pain (as a common effect of nerve trauma)
Agents usually felt as touch only becoming painful is sufficiently common after many forms of injury.
4. Psychogenic impact of nerve injury (describing “traumatic neurosis” and anticipating WWI descriptions of “battlefield fatigue” and the modern diagnosis of post-traumatic stress disorder (PTSD))
Perhaps few persons who are not physicians can realize the influence which long continued and unendurable pain can have on the body. When terrible pain has lasted a few days or weeks, the whole surface becomes hyperesthetic, with every vibration, and changes of light, brings on new agony. Under such torments, the temper changes, the most amiable grow irritable, the soldier becomes a coward, and the strongest man is scarcely less nervous than the most hysterical girl.
5. Gender differences in chronic pain
Moreover, the greatest number of such cases was women, and the hysterical element comes largely into view as the disorders progress.
6. Intractability of nerve injury impaired functions
Entire restoration of function-sensation after nerve injury was extremely rare.
7. Dysesthesias greater with partial than with complete nerve injuries
The greatest symptoms were due to wounds of small filaments; few instances of like symptoms have followed those of the great trunks.
8. Centralization of traumatic neuropathies and neuralgias
It is quite rare for a patient with neuralgia to arouse from sleep with pain. Those who suffer with causalgia find pain immediately on awakening.

9. Neuroviral lesion exacerbations with nerve injuries

At some time in the history of a nerve injury, it is common to see active forms of eruptions, ulcers, or herpetic vesicles or in the shape of bullae.

10. Trigeminal injury features

John Schultz, a 23-year-old German who joined the Wisconsin Volunteers was injured on July 3, 1863, while marching in an assault line at Gettysburg. The injury, which was deduced to be from a picket sniper above the victim, resulted from a Minie ball which avulsed his ear lobe, entered his right cheek beneath the malar bone, passed through the ascending ramus of the mandible and exited through the submandibular space, reentered and fractured the clavicle, and came to rest in the trapezius muscle. The Minie ball, much deformed, was removed two weeks after the injury by Dr. Keen. Patient displayed initial anesthesia over the mental nerve distribution, accompanied by eventual “tingling pain” from moving the lip.

Considered a primary founder of the specialty of neurology, SW Mitchell is also viewed among the most versatile Americans since Benjamin Franklin. The first half of his life was devoted to scientific achievements, and the second half to a literary career. He wrote 19 novels including one published when he was 84, seven books on poetry, a historical book on Washington, and a story of “Kris Kringle” which sometimes gets credit for initiating the idea of Santa Claus.

Early investigators from this era including SW Mitchell, Henry Head, and James Sherren heroically experimented with self-imposed nerve injuries. Mitchell froze his own ulnar nerve to study the effects on hand sensation, describing the overlap of cutaneous nerves adjacent to injured nerves. Henry Head damaged his own radial nerve and described the phenomena of first (A-delta fiber) pain and second (C-fiber) pain that he labeled “protopathic and epicritic” [58]. Mitchell also championed the use of animal experimentation in medical research in an era when the use of dogs for scientific purposes was vigorously opposed (as it is presently) (“Vivisection: A Statement in

Behalf of Science, 1888”). He argued that only scientists should decide whether, when, and in what way animals should be used, “(o)therwise in a matter involving the interest of the community, those who know would be directed by those who do not know.”

1.3 Treating Nerve Injuries in the Early Twentieth Century: Neural Ablation

In the aftermath of the Civil War, early twentieth-century treatments for patients with painful trigeminal nerve injuries centered on destructive peripheral nerve lesioning techniques. Harvey Cushing used extirpation of the entire Gasserian ganglion frequently [20]. Peripheral neurectomy of the trigeminal nerve branches, particularly infraorbital and mental branches, were widely used in the early decades by neurosurgeons and some oral and maxillofacial surgeons, often applied after local anesthetic blockade had demonstrated acute pain relief. Although useful for patients with short life expectancies and classic trigeminal neuralgia, neurectomy proved unsuitable for long-term symptom resolution, instead producing cases of “anesthesia dolorosa” in the deafferented nerve distributions [49, 68].

It had also been observed that surgical resections of traumatic neuromas, even cauterizing or capping the resected nerve ends with epineurial sutures, failed to prevent reformation of painful neuromata [141]. This experience led White to speculate that “(t)he surest way to prevent recurrence of traumatic neuroma-in-continuity is to resect the scarred area and do end-to-end anastomosis of healthy ends of the nerve.”

Nevertheless by the mid-twentieth century, other forms of neuro-destructive lesions were in widespread use and also included varying concentrations of alcohol injections, phenols (glycerol), formalin, and even hot boiling water [21, 142]. Unfortunately, these procedures often led to secondary inflammatory neuritis, exacerbated neurosensory functional impairments and dysesthesias, and largely fell out of routine clinical use.

There are surviving legacies of these early neuroablative procedures extending into the modern era, however, which employ more selective treatments of damaged and painful injured trigeminal nerves. Partial and reversible neurolysis using radiofrequency thermal neurolysis at 65–75 °C have been shown to depress pain from C-fiber and A-delta fiber pain hyperfunctioning while retaining the potential for eventual recovery of tactile functions [52]. More recently, radiosurgical (“gamma knife”) lesioning of trigeminal sensory roots has shown promise for mitigating traumatic trigeminal neuralgias while preserving some touch and proprioceptive functions [72].

1.4 The Emergence of Balanced and Multidisciplinary Nerve Treatments

Dr. John Bonica, Professor of Anesthesiology at the University of Washington, had studied patient responses to injuries on the WW II beaches of Anzio, Italy, and returned to establish a first-of-its-kind multidisciplinary clinic in Seattle for treating patients with chronic post-traumatic pain [12]. Bonica argued that future scientific and patient care progress would benefit from multidisciplinary collaborations of clinicians and researchers. Bonica’s vision led to the establishment of the International Association for the Study of Pain (IASP) and the current journal known as *Pain*.

Bonica’s multidisciplinary approach also recognized the need for balanced surgical and non-surgical therapies and less-destructive approaches for the treatment of painful nerve injuries. Two promising nonsurgical approaches that came to the forefront during the last century are neural blockade and neural stimulation.

1.4.1 Neural Blockade

The early twentieth century witnessed a “Golden Age of Regional Neural Blockade” for the treatment of injured and painful nerve distributions [13]. Local anesthetics were shown to provide remissions that far outlasted the expected

drug effects and often lead to overall improvements in both clinical symptoms and neural functions. Even in the modern era, neural blockade remains an important modality for managing chronic dysesthesias using serial nerve trunk blockade with long-acting anesthetic agents, often combined with adrenocorticosteroids [119].

Recent extensions of the neural blockade concept have led to the development of low-risk topical multimodal compounds containing agents such as ketamine, tricyclic antidepressants, alpha-antagonists, pre-gabalins, and lidocaine that can be applied peripherally to injured trigeminal nerve distributions [39, 59, 73, 107]. And, in a return to the early twentieth-century experience with neural blockade, there have been recent promising reports of the use of botulinum toxin A for the management of intractable trigeminal neuralgias, although its mechanism of action is not presently fully understood [81, 148].

1.4.2 Neural Stimulation

The approach to treating neuropathic conditions through physiologic counter-stimulations is as old as recorded history [71]. Egyptian tombs from the year 2750 B.C. contained pictures of electric Nile catfish being used to treat human afflictions. Aristotle and Galen both advocated attaching electric torpedo ray fish to the face and head for treating headaches. The Chinese, of course, are known to have treated painful injuries using electrical and thermal acupuncture stimulation applied at key peripheral neuroanatomic “meridians” for over 4,000 years. And, although classical acupuncture remains very popular internationally for a wide range of painful conditions, acupuncture in any form has not been proven superior to placebo for neurotraumatic dysesthesias in reviews of controlled studies [35]. Even in the nineteenth century, “electrogalvanism” was briefly considered as a surgical analgesic for the extraction of teeth [41]. More recently, electrotherapy has proven useful for the management of nerve injury pain [79].

Interestingly, the electrophysical characteristics of the torpedo fish, with voltage ranges of 40–50 V, are similar to energy ranges used in a variety of

artificial electrotherapy analgesia techniques developed in recent decades to treat nerve injury pain: notably transcutaneous electrical nerve stimulation (TENS), implanted stimulation electrodes, and intracerebral brain stimulation therapies [69].

TENS, as a form of low-level electrical stimulation analgesia, came into widespread use in the 1970s, triggered by Melzack and Wall’s 1965 “Gate Control Theory of Pain” [86]. This theory predicted that stimulation of intact large fibers in peripheral nerves could inhibit the pain-producing small C-fibers known to be found in excess following peripheral injury [11]. Unfortunately, TENS therapy has not had a wide application for trigeminal nerve injuries despite its early clinical promise [77].

More aggressive electrical impulse therapies delivered through implanted paraneural electrodes have been effective for spinal nerve injury pain management and show promise for treatment of trigeminal traumatic neuralgias [64, 129].

Intracerebral stimulation therapies (ICS), developed in the 1970s for control of Parkinsonian tremors, known as deep-brain stimulation (DBS) have also proven useful for relief of neuropathic pain [53]. More recently, motor cortex stimulation (MCS) systems have proven of benefit to patients with intractable nerve injury pain, including those with extreme deafferentation dysesthesias [105, 117].

A recently introduced benign form of stimulation therapy that appears to support recovery after nerve injury is laser therapy. “Low-level laser” (LLL) or “cold laser” or “soft laser” photoradiation stimulations applied to nerve distributions using the 650–850 nm portion of the visual spectrum have shown promise in published case series, although its efficacy beyond placebo has been questioned [4, 92, 98].

1.5 Legacies of WW II and Beyond: Understanding Mitchell’s Observations

Much like the Civil War, World War II was followed by expanding knowledge regarding nerve injuries. Sir Henry Seddon is credited with

providing the scientific foundations for peripheral nerve surgeries, including suggestions that nerve grafts might be used for this purpose. He also posed a nerve injury classification system based upon progressive anatomic derangements, coining the terms “neurapraxia, axonotmesis, and neurotmesis” [127]. Sunderland later further subdivided the scope of nerve injuries into five types (grades I–V) and then further modified by Mackinnon and Dellon to include a sixth type of mixed nerve injury (grade VI) [80, 132].

A sensory functional classification of nerve injury recovery also emerged from British WWII experiences. The Hight classification has a starting point of no sensory detection (anesthesia) and progresses through the attainment of noxious and crude touch detections, and finally fine touch abilities, with or without hyperesthesia. This system has subsequently led to a consideration that intermediate crude touch levels can be considered “useful sensory recovery” by the British Medical Research Council Scale (MRCS) [10].

In the decades following WW II, many of the neural mechanisms underlying Mitchell’s seminal clinical observations regarding nerve injuries have been clarified, including the following:

1. Burning pain

He lay in the field for 28 h before wet (cold) compresses were put on his leg. At that time he began to complain of severe burning in his heel and showed sensory loss.

It was theorized in 1944 that “cross innervations” may form between damaged somatosensory nerve fibers and adjacent sympathetic nerve fibers [31, 46]. Subsequent researchers verified that upregulated sympathetic postganglionic nerve “baskets” may form around damaged sensory ganglia and also sprout to form hyperactive couplings with sensory fibers, termed “ephapses” within traumatic neuromas [26, 42, 85, 126]. Trauma may also induce chemically mediated non-synaptic excitation in sensory ganglia after peripheral nerve injury [3].

The experience of many trauma patients complaining of burning pain aggravated by cold temperatures or stimuli (cold hyperalgesia) has been further attributed to ectopic impulses generated by C-fiber nociceptors [120] as well as

coupling with autonomic fibers [43]. For patients with this form of “sympathetic-mediated pain” mechanism, stellate ganglion anesthetic blocks are often effective for chronic pain management [13, 115].

In 1959, Noordenbos, using nerve fiber spectrum analysis, showed that early regenerated nerves have a paucity of myelinated large A-beta fibers and an excess of regenerated smaller nerve fibers [104]; clinical neurosensory studies have verified that A-fiber fine tactile mechanoreceptive functions are the last to recover after nerve injury (“first to be lost and last to recover”). Patient complaints of chronic constant paresthesias (“numbness”) and painful dysesthesias (“aching, burning”) after nerve injury have been shown to be due to involvement of hyperactive small C-fibers [19].

2. Tingling paresthesias and pain

Patient displayed initial anesthesia over the mental nerve distribution, accompanied by eventual “tingling pain” from moving the lip.

Scientific explanations of clinical “triggering” of painful and non-painful paresthesias began to emerge with the work of Hoffman and Tinel in 1915 [16]. They described the clinical phenomenon of tingling and shock-like sensations that are elicited by digital tapping over distal portions of regenerating nerves. These clinical signs were felt to represent “the presence of young axons in the process of growing.” Subsequent experiences, however, have shown that the “Tinel’s sign” may be easily misinterpreted, and, rather than a positive sign of spontaneous neural regeneration, it may also represent a poor sign of chronic peripheral neuropathy with neuroma formation.

Foerster had demonstrated painful responses to percussion over previously damaged nerve trunks with or without Tinel’s sign, and he coined the term “hyperpathia” [40]. Modern studies have verified that hyperpathic clinical signs can represent sites of sensitized neuromain-continuity, as well as chronically sensitized amputation-type neuromas. Considerable variability in traumatic trigeminal neuromas has been seen under operating microscopes, and mechanisms of peripheral sensitization within

neuromas have been clarified [50, 51]. Painful neuromas have been shown to contain chronic inflammatory cells, as well as cannabinoid and heat-sensitive vanilloid 1 (proinflammatory) receptors [5, 9].

3. Partial vs. complete nerve injuries

The greatest symptoms were due to wounds of the small filaments; few instances of the symptoms have followed those of the great trunks.

Research with both nerve-lesioned animals and patients with known types of nerve injuries has led to the conclusion that neuropathic pain is often inversely related to the degree of nerve damage [62, 149]. Quantitative neurosensory testing of patients with trigeminal nerve injuries has verified that higher retention of A-beta fibers is correlated with early triggered forms of pain, whereas delayed and disturbing paresthesia, often accompanied by dull aching and burning pain, is correlated with excess regeneration of C-fibers in more completely damaged nerve distributions [19, 63].

4. Pain elicited by touch

Agents usually felt as touch only become painful if sufficiently common after many forms of injury.

Mitchell had observed that some nerve-injured patients displayed a paradoxical syndrome that combines loss of sensation (“numbness”) with an explosive hyperphenomena, manifesting as triggered paresthesias and pain. Over the years, accumulating literature has attributed touch-evoked pain (allodynia) and heightened responses to painful stimuli (hyperalgesia) to both peripheral and central neural “sensitization” [136, 145]. Research has shown that uninjured large myelinated A-beta fibers contained within the trunks of traumatized nerves become upregulated with inflammatory vanilloid receptors and display ectopic and low-threshold activities that partially explain the resultant allodynia [15]. These mechanisms also explain how immediate-onset pain and allodynia may occur within 1–3 days after partial nerve injury. In contrast, delayed-onset pain and hyperalgesia developing 3–4 weeks after nerve injury are attributed to the regeneration of excessive C-fibers as well as central sensitization [27, 45].

5. Centralization after peripheral nerve injury

It is quite rare for a patient with neuralgia to arouse from sleep with pain.

Mid-1970s research with vital staining of sensory root and spinal subnuclei after experimental trigeminal (V) nerve transections confirmed that peripheral injuries can induce “plastic” central degeneration [47, 48]. These studies established an important link explaining clinical nerve injuries and central nerve derangements [66]. Histochemical studies have now shown that the deafferented neurons of the central trigeminal complex become chronically “sensitized” by glial cells that stimulate NMDA (N-methyl-D-aspartate) receptor excitotoxicity [124, 125, 147]. Similar neuroexcitation may also occur at higher ascending levels and combine with loss of descending inhibition to further magnify “central sensitization,” contributing to clinical hyperalgesia and allodynia [32, 108, 145].

The realization that the CNS undergoes “plastic” responses to peripheral nerve injury has also led to modern rehabilitation therapies that seek to induce central nervous “recovery.” Dellon has advocated “sensory reeducation” exercise techniques that can induce “reverse plasticity” effects in thalamic and cortical perceptual regions following injured and repaired peripheral nerves [23]. Recent studies have verified that sensory reeducation techniques can be effectively applied to trigeminal nerve injury conditions generated by mandibular sagittal split osteotomies [90, 109].

6. Phantom paresthesia sensations

I am more sure of sensing the leg which ain't than the one which are.

Patients with chronic trigeminal injuries often complain of impaired oral-facial functions and disturbing paresthesias that include perceived movement “phantoms” and tingling “afterimages” [54]. Livingstone theorized that phantom phenomena could be due to hyperactivity in traumatic neuromas, a concept that has been supported by modern demonstration of ectopic spiking activity in experimental and human neuromas [76, 120]. Phantom paresthesias have also been attributed to anatomic and physiologic responses at many other levels of the CNS resulting from sensory deafferentation [78].

A central nervous basis of phantom phenomena was revealed in a landmark 1984 experiment in which selected digits in monkeys were amputated, resulting in major anatomic derangements in their somatosensory cortical maps [88]. More recent f-MRI (functional MRI) imaging has exposed central demyelination lesions in human thalamic and cortical regions in response to repetitive injury and chronic neuropathy [83, 134].

7. Intractability of impaired functions

Entire restoration of function-sensation after nerve injury was extremely rare.

Mitchell's frustration in 1860 with the intractability of nerve injury functional impairments unfortunately would still have persisted 100 years later, awaiting new biologic and technical means of restoring neural function.

1.6 The Push Toward Nerve Repairs

By the mid-twentieth century, two particular events were to profoundly influence the science and treatment of neurotrauma: the development of experimental nerve injury animal models and the introduction of the operating microscope.

Experimental animal nerve injury models were developed in the mid-twentieth century that became important for both research into mechanisms of traumatic neuropathies and for use in training clinicians in microneurosurgical repair. The chronic constriction injury (CCI) model of sciatic nerve injury developed by Bennett and Xie has become a universally accepted model for investigating neurotrauma mechanisms and pain therapies [8]. The CCI reliably and rapidly induces behavioral changes in the lesioned animals that appear to mimic the human injury condition of measurable sensory loss and touch-evoked pain. Comparable CCI animal models have also been developed for studying trigeminal nerve injuries using infraorbital nerve constriction preparations [135].

A standardized rodent sciatic nerve injury developed at mid-century and popularized by Daniel and Terzis also became the primary model for laboratory training of surgeons in

microsurgical techniques and currently is employed by many surgical specialties employing microsurgery practice [22].

In the early World War II years, surgeons had already been attempting to repair gap nerve injuries and experimenting with autogenous tubes and sutureless repairs [14, 111, 139]. It was the development and mass production of the modern operating microscope by Carl Zeiss in 1953, however, that gave new momentum to repairing damaged peripheral nerves rather than attempting to control symptoms through nerve ablation procedures. Hanno Millesi, a Viennese plastic and reconstructive surgeon, developed the early techniques for repair of hand nerve injuries [93]. He emphasized the importance of "fascicular" repair by suturing at the perineurial tissue level in order to match up "correct endoneurial tubes" (coaptation) [94]. His techniques were subsequently adopted in Europe, Japan, and North America and were instrumental in setting the standards for successful nerve repairs during the 1970s and 1980s [22, 80].

The direct application of Millesi's techniques to the repair of damaged trigeminal nerves was somewhat limited, however, because of difficulties with surgical access and the fact that trigeminal nerves are predominantly polyfascicular, with smaller fascicles lacking thickened perineurium layers as compared to spinal nerves [114]. For these main reasons, modern trigeminal end-to-end microrepairs have come to be accomplished primarily through epineurial, rather than perineurial, suture techniques.

Nevertheless, plastic and reconstructive surgeons and oral and maxillofacial surgeons from Germany, guided by Millesi's teachings, were among the first to demonstrate that successful microrepairs of trigeminal nerves are possible [55, 56]. A major turning point in application of microsurgical repair of trigeminal injuries in the United States occurred in 1979. Drs. Hausamen and Reuter were sponsored by Dr. Phillip Worthington at the University of Washington in Seattle, Washington, to conduct a 1-week course in microsurgery and lead group discussions on trigeminal nerve applications [146]. American oral and maxillofacial surgeons invited to attend this course included early contributor Ralph Merrill

and a number of individuals who were to become leaders in advancing the field of trigeminal microsurgery over the succeeding decades [87]. This also led to many spin-off symposia and courses held at teaching centers and led by influential clinician researchers including Drs. CC Alling (Alabama), RB Donoff and Kaban LB (Harvard), A Pogrel (San Francisco), L Davis (Nebraska), BN Epker and LM Wolford (Texas), LA Assael (Oregon), RA Meyer (Atlanta), JM Gregg and JR Zuniga (North Carolina), VB Ziccardi (New Jersey), and PP Robinson (Sheffield, UK).

Finally, in the last decades of the twentieth century, a flurry of clinical publications on trigeminal injuries appeared in the oral and maxillofacial surgery literature, building a base for the upcoming new millennium [2, 30, 50, 51, 57, 60, 65, 74, 95, 103, 113, 123, 131, 151].

1.7 Twenty-First-Century Consensus: “The Triumphant Trigeminal”

The first decade of the twenty-first century has been characterized by a number of tentative “state-of-the-art and science” conclusions regarding traumatic trigeminal neuropathies:

1.7.1 Lingual Nerve Injuries

Although occurring less frequently than inferior alveolar nerve (IAN) injuries, lingual nerve (LN) damage results in more significant patient disability compared to the remarkable spontaneous functional recovery seen following IAN injuries [57]. Fortunately, the damaged LN has proven to be responsive to surgical repairs at encouragingly high levels (60–90 %) of functional improvement [7, 121].

1.7.2 Surgical Repair

Nerve repairs using direct microsurgical interventions have proven effective in improving “useful sensory functions” even for severely damaged trigeminal nerves [133]. The management of traumatic

neuropathic pain through surgical repairs, however, has been less encouraging clinically, and significant pain outcomes data are still not yet available.

1.7.3 Timing of Nerve Repairs

Although repairs of mechanical trigeminal injuries have generally been shown to be more successful when done within weeks to a few months after initial mechanical injury, parallel experimental and clinical evidence has shown that selected cases of partial nerve injuries may be successfully managed months to years after injury [89, 121, 150].

1.7.4 Microsurgical Nerve Repair

Direct end-to-end anastomoses (neurorrhaphy) of traumatized trigeminal nerves have proven to be the most effective procedure for improving sensory functions after major mechanical nerve injuries [91, 112, 131]. Nerve gaps that cannot be bridged directly by direct neurorrhaphy can be managed through graft-assisted indirect neurorrhaphy techniques. The “gold standard” donor source for nerve grafts for large trigeminal gaps has historically been the autologous sural nerve and less frequently the greater auricular and antebrachial cutaneous nerves. All donor nerve options have shown undesirable donor site complications, anatomic incompatibilities, and lessened sensory recovery outcomes compared to direct repairs [29] although it seems as if the sural nerve donor site deficit is better tolerated in long-term follow-up [99]. A promising, yet unproven, alternative has been the recently introduced allogeneic homologous (cadaver) grafts that are processed with enzymatic denaturation, gamma irradiation, and lyophilization (freeze-drying) [128, 143].

1.7.5 Entubulation

There has been continuing interest dating back to the early 1900s in identifying nerve repair techniques that utilize tubular conduits to enhance neural regeneration [111, 140]. More recently, it

has been shown that tubes made of bioabsorbable polyglycolic acid and collagen can be effective for bridging trigeminal nerve gaps of less than 10 mm [17, 18, 37]. Attempts at using cylinders of veins, arteries, muscles, and a variety of alloplastic materials including expanded polytetrafluorethylene (GORE-TEX), however, have not proven effective for larger gap repairs [96, 110, 116]. Entubulation, however, has shown considerable utility when used as “wrap protectors” on nerves that have been decompressed or suture-repaired. Currently, the most widely used wraps are either bovine collagen or porcine-based products, as well as the recently introduced extracellular matrix nerve protector and connector (AxoGuard, Axogen®, Alachua, FL). Recent experimental research has also demonstrated the exciting possibility of enhancing neural regeneration by combining entubulation with tissue engineering using stem cells [28, 138].

1.7.6 Diagnostic Assessment

In the last few decades, clinical protocols for the objective clinical assessment of trigeminal nerve injury status have progressed from historic rapid “bedside screening” to the use of detailed serial quantitative sensory testing (QST) modalities [36, 63, 122, 152]. Although QST has led to improvements in treatment planning for patients with traumatized trigeminal nerves, no specific QST protocol has been nationally or internationally adopted by any sanctioning organization.

Improvements in diagnostic imaging have led to more accurate MRI-assisted LN localization and intrabony localization of the IAN [75, 97]. Less progress has been made, however, toward developing imaging techniques that reveal detailed internal structural features of the injured nerve itself [24].

1.7.7 Trigeminal Injury Epidemiology

Increased frequency of iatrogenic trigeminal injuries of two types has been noted in the past decade; these include dental implant-related injuries and local anesthetic injuries. The dramatic increase in

placement of posterior mandibular endosseous implants, especially in North America, has led to a corresponding increase in IAN injuries [67, 100].

There also appears to have been an increase in trigeminal sensory neuropathies following local anesthetic nerve blocks using nerve blocks with higher concentration anesthetic agents (articaine 4 %) introduced in the USA in 2000 [44, 70]. These neuropathies appear most likely due to chemoneurotoxic effects rather than mechanical injection damages [61]. The prognosis for recovery of both types of injuries is guarded, with a tendency to develop neuropathic pain [114].

1.8 Unfinished Business

Significant challenges remain in the twenty-first century regarding understanding trigeminal nerve injuries and delivering more evidence-based successful patient care. There are six particular prerequisites, or “wish lists initiatives” for addressing these challenges, including the following:

1.8.1 Epidemiology

Accurate statistics that reflect the incidence, causation, clinical features, and natural recovery courses following trigeminal nerve injuries are lacking; yet these data are essential for effective patient counseling, useful actuarial analyses, allocation of research resources, and planning appropriate treatment strategies.

Prerequisites: An effective national and/or internationally based trigeminal *nerve injury registry* with built-in reporting incentive mandates is needed. Support for such a registry could potentially be coordinated through agencies such as AAOMS and IAOMS using the current electronic medical record (EMR) systems for data acquisition and retrieval for useful bioinformatics.

1.8.2 Clinical Diagnostic Methods

There are two particular diagnostic needs regarding trigeminal nerve injuries: soft tissue imaging

and improved armamentarium for quantitative sensory testing (QST).

Prerequisites: Develop *soft tissue imaging* techniques that display the microanatomy of damaged nerves, including the presence and type of traumatic neuroma and the Sunderland degree of injury prior to surgical repair. Also, make available a standardized and clinically practical armamentarium for *quantitative sensory testing (QST)*, a system that measures the full spectrum of nerve fiber function loss and also quantifies neuropathic hyperphenomena (allodynia and hyperalgesia). Affordable technology is needed that measures noxious thermal stimulus response thresholds and sensory nerve conduction velocities, detects ectopic action potentials, and localizes the exact sites of previous nerve injury.

1.8.3 Traumatic Trigeminal Neuralgia

Despite over 50 years of concentrated research, there are no universally effective surgical or non-surgical treatments for managing traumatic neuropathic pain, currently considered by some to be an incurable disease [106].

Prerequisites: Develop and evaluate *nonsurgical therapies* for patients with traumatic neuralgias that both palliate neuropathic pain and also enhance recovery from injuries. These therapies could include topical multimodal compounds that bypass systemic side effects. Other promising therapies need to be evaluated specifically among trigeminal nerve-injured patients. These include advanced behavioral sensory rejuvenation techniques, electrostimulation analgesia, botulinum toxin A neurolysis, graded radiosurgery (gamma knife), and low-level laser (LLL) treatments.

1.8.4 New Surgical Options

Currently available surgical procedures for improving function and ameliorating symptoms among nerve-injured patients are difficult to perform technically even for the well-prepared oral and maxillofacial surgeon due to problems with nerve access as well as the complexity of current microsurgical techniques.

Prerequisites: Improve techniques for treating in-office or operating room observed *acute nerve injuries*. These could include the development of sutureless “glues,” stapling techniques, or laser welding of nerve ends and, at the same time, improving cost containment and availability of these materials as well as nerve wrap protective barriers. In addition, laboratory protocols and operating room techniques must be developed that enhance nerve regeneration by combining stem cell tissue engineering with trigeminal entubulation delivery systems.

1.8.5 Professional Education

Little consistent education is currently included at any level of medical or dental education regarding the incidence, nature, prevention, and treatment of trigeminal nerve injuries, and few, if any, microsurgical training programs exist for interested surgeons.

Prerequisites: Introduce *curriculum changes* and opportunities for case-based clinical exposure to patients with traumatic neuropathies at undergraduate dental, medical, nursing, dental hygiene, and pharmacy education levels. Encourage integration of didactic, training laboratory, and clinical experiences in graduate specialty training, especially in oral and maxillofacial surgery residency training programs. Also, consideration should be given toward the establishment of trigeminal nerve injury management fellowship programs. This may require a coordinated, multi-institutional program to assure adequate numbers of patient contacts and appropriate exposure to alternative management strategies. Additionally, there must be increased case-based *Continuing Medical/Dental Education (CME/CDE) programs* and symposia related to trigeminal nerve injuries for practicing clinicians and academic faculty members in order to appropriately train oral and maxillofacial surgery residents (Miloro M, Diagnosis and Management of Trigeminal Nerve Disorders, AAOMS Annual Meeting).

1.8.6 Healthcare Delivery

Current health care for patients who have sustained trigeminal nerve injuries is largely delivered by

individual practitioners of medicine and dentistry acting in isolation or using serial referral systems. Third-party insurance or disability reimbursements continue to primarily reward time-limited and procedure-based interventions which may not fit the chronic needs of many nerve-injured patients, especially those with neuropathic pain.

Prerequisites: Multidisciplinary team treatments utilizing a spectrum of healthcare professional consultants have been proven to be more effective than isolated therapists struggling with complex chronic neuropathic syndromes.

Although ideally suited to academic center teaching environments, private sector ad hoc teams could be organized that cross disciplines such as oral and maxillofacial surgery, prosthetic dentistry, physical therapy, neurology, psychiatry, clinical psychology rehabilitative medicine, anesthesiology, and pain management consultants.

Conclusions

The scientific basis for understanding the effects of peripheral nerve trauma as a basis for improving patient care has a long and storied history. Special attention to diagnosis and treatment of trigeminal injuries, although a relative latecomer to these efforts, holds great promise based upon progress made in the most recent decades.

References

- Adams F (1849) *The genuine works of Hippocrates*. William & Wood, New York
- Alling CC (1986) Dysesthesia of the lingual and inferior alveolar nerves following third molar surgery. *J Oral Maxillofac Surg* 44:454–457
- Amir R, Devor M (2000) Functional cross-excitation between afferent A- and C- neurons in dorsal root ganglia. *Neuroscience* 95:189–195
- Anders S (2004) Phototherapy promotes regeneration and functional recovery of injured peripheral nerve. *Neurol Res* 26:233
- Anand U, Otto WR, Sanchez-Herrera D et al (2008) Cannabinoid receptor CB2 localisation and agonist-mediated inhibition of capsaicin responses in human sensory neurons. *Pain* 138:667–680
- Artico M, Cervoni L, Nucci F et al (1996) Birthday of peripheral nervous system surgery: the contributions of Gabriele Ferrara (1543–1627). *Neurosurgery* 39:380–382
- Bagheri SC, Meyer RA, Khan HA et al (2010) Retrospective review of microneurosurgical repair of 222 lingual nerve injuries. *J Oral Maxillofac Surg* 68:715–723
- Bennett GJ, Xie YK (1988) A peripheral mononeuropathy in rat that produces disorders in pain sensation like those seen in man. *Pain* 33:87–107
- Biggs JE, Yates JM, Loescher AR et al (2007) Vanilloid receptor 1 (TRPV1) expression in lingual nerve neuromas from patients with or without symptoms of burning pain. *Brain Res* 1127:59–65
- Birch R, Bonney G, Wynn Perry CB (1998) *Surgical disorders of the peripheral nerves*. Churchill Livingstone, Philadelphia
- Bohm E (1978) Transcutaneous electrical nerve stimulation in the chronic pain patient after peripheral nerve injury. *Acta Neurochir* 40:277
- Bonica JJ (1953) *The management of pain*. Lea & Febiger, Philadelphia
- Bonica JJ (1953) *The management of pain*. With special emphasis on the use of analgesic block in diagnosis, prognosis and therapy. Lea & Febiger, Philadelphia
- Campbell JB, Bassett CA, Girado JM et al (1956) Application of monomolecular filter tubes in bridging gaps in peripheral nerves and for prevention of neuroma formation. A preliminary report. *J Neurosurg* 13:635
- Campbell JN, Raja SN, Meyer RA et al (1988) Myelinated afferents signal the hyperalgesia associated with nerve injury. *Pain* 32:89–94
- Clark D (1983) Jules Tinel and Tinel's sign. *Clin Plast Surg* 4(10):627–628
- Colin W, Donoff RB (1984) Nerve regeneration through collagen tubes. *J Dent Res* 63:987
- Crawley WA, Dellon AL (1992) Inferior alveolar nerve reconstruction with a bioabsorbable nerve conduit. *Plast Reconstr Surg* 90:300–302
- Cruccu C, Leandri M, Iannetti GD et al (2001) Small-fiber dysfunction in trigeminal neuralgia. *Neurology* 56:1722–1726
- Cushing H (1900) A method of total extirpation of the Gasserian ganglion for trigeminal neuralgia. *JAMA* 34:1035–1041
- Cushing H (1920) The role of deep alcohol injections in the treatment of trigeminal neuralgia. *JAMA* 75:441–443
- Daniel RK, Terzis JK (1977) *Reconstructive microsurgery*. Little Brown, Boston
- Dellon AL (1988) Evaluation of sensibility and reeducation of sensation in the hand. J.D. Lucas, Baltimore
- Deng W, Chen SL, Zhang ZW et al (2008) High-resolution magnetic resonance imaging of the inferior alveolar nerve using 3-dimensional magnetization-prepared rapid gradient-echo sequence at 3.0T. *J Oral Maxillofac Surg* 66:2621–2626
- Descartes R (1664) *Meditations, L'Homme*. E. Angot, Paris

26. Devor M (1983) Nerve pathophysiology and the mechanisms of pain in causalgia. *J Auton Nerv Syst* 7:371–384
27. Devor M (1994) The pathophysiology of damaged peripheral nerves. In: Wall PD, Melzack R (eds) *Textbook of pain*. Churchill Livingstone, New York
28. Di Summa PG, Kingham PJ, Raffoul W (2010) Adipose-derived stem cells enhance peripheral nerve regeneration. *J Plast Reconstr Aesthet Surg* 63:1544–1552
29. Dodson TB, Kaban LB (1997) Recommendations for management of trigeminal nerve defects based on a critical appraisal of the literature. *J Oral Maxillofac Surg* 55:1380–1386
30. Donoff RB, Guralnick W (1982) The application of microneurosurgery to oral-neurologic problems. *J Oral Maxillofac Surg* 40:156–159
31. Doupe J, Cullen CH, Chance GQ (1944) Post-traumatic pain and the causalgic syndrome. *Neurol Neurosurg Psychiatry* 7:33–748
32. Dubner R, Ren K (2004) Brainstem mechanisms of persistent pain following injury. *J Orofac Pain* 18(4): 299–305
33. Duchenne GB (1872) *De l'électrisation localisée et de son application à la pathologie et à la thérapeutique*. Baillie, Paris
34. Erlanger J, Gasser HS (1924) The compound nature of the action current of nerve as disclosed by the cathode ray oscilloscope. *Am J Physiol* 70:624–666
35. Ernst E, Lee TY (2011) Acupuncture: does it alleviate pain and are there serious risks? A review of reviews. *Pain* 152:755–764
36. Essick G (1992) Comprehensive clinical evaluation of perioral sensory function. *Oral Maxillofac Surg Clin North Am* 4:503–526
37. Farole A, Jamal BT (2008) A bioabsorbable collagen nerve cuff (Neuragen) for repair of lingual and inferior alveolar nerve injuries. *J Oral Maxillofac Surg* 66:2058–2062
38. Ferrara G (1608) *Nuova Selva di Chirurgia Divisa in tre Parti*. S Combi, Venice
39. Finch PM, Knudsen L, Drummond PD (2009) Reduction of allodynia in patients with complex pain syndrome: a double blind placebo-controlled trial of topical ketamine. *Pain* 146:18–25
40. Foerster O (1927) *Die Leitungsbahnen des Schmerzgeföhls und die chirurgische Behandlung der Schmerzzustände*. Urban & Schwarzenberg, Berlin
41. Francis JB (1858) Extracting teeth by galvanism. *Dent Rep* 1:65
42. Fried K, Govrin-Lippman R, Devor M (1993) Close apposition among neighbouring axonal endings in a neuroma. *J Neurocytol* 22:663–681
43. Frost SA, Raja SN, Campbell JN et al (1988) Does hyperalgesia to cooling stimuli characterize patients with sympathetically maintained pain? In: Dubner R, Gebhart GF, Bond MR (eds) *Pain research and clinical management*, vol 3. Elsevier, Amsterdam
44. Garisto GA, Gaffen AS, Lawrence HP et al (2010) Occurrence of paresthesia after dental local anesthetic administration in the United States. *J Am Dent Assoc* 141:836–844
45. Gracely RH, Lynch SA, Bennett GJ (1992) Painful neuropathy: altered central processing maintained dynamically by peripheral input. *Pain* 51:175–194
46. Granit R, Leksell L, Skoglund CR (1944) Fibre interaction in injured or compressed region of a nerve. *Brain* 67:125–140
47. Grant G, Arvidsson J (1975) Transganglionic degeneration in trigeminal primary sensory neurons. *Brain Res* 95:265–279
48. Gregg JM (1972) Post-traumatic pain: experimental trigeminal neuropathy. *J Oral Surg* 29:260–267
49. Gregg JM (1984) Neurologic disorders of the maxillofacial region. In: Kruger GO (ed) *Textbook of oral and maxillofacial surgery*, 6th edn. Mosby, St. Louis
50. Gregg JM (1990) Studies of traumatic neuralgias in the maxillofacial region: symptom complexes and response to microsurgery. *J Oral Maxillofac Surg* 48: 135–214
51. Gregg JM (1990) Studies of traumatic neuralgias in the maxillofacial region: surgical pathology and neural mechanisms. *J Oral Maxillofac Surg* 48:228–237
52. Gregg JM, Small EW (1986) Surgical management of trigeminal pain with radiofrequency lesions of the peripheral nerves. *J Oral Maxillofac Surg* 44: 1222–1225
53. Hamani C, Schwalb JM, Rezai AR et al (2006) Deep brain stimulation for chronic neuropathic pain: long-term outcome and the incidence of insertional effect. *Pain* 125:188–196
54. Hanowell ST, Kennedy SF (1979) Phantom tongue pain and causalgia: case presentation and treatment. *Anesth Analg* 58:436
55. Hausamen JE, Samii M, Schmidseider R (1973) Restoring sensation to the cut inferior alveolar nerve by direct anastomosis or by free autologous nerve grafting. *Plast Reconstr Surg* 54(1):83–87
56. Hausamen JE, Samii M, Schmidseider R (1974) Indication and technique for the reconstruction of nerve defects in head and neck. *J Maxillofac Surg* 2: 159–167
57. Hayward JR (1986) The triumphant trigeminal nerve. *J Oral Maxillofac Surg* 44(1):2
58. Head H, Rivers WHR, Sherren J (1905) The consequences of injury to the peripheral nerves in man. *Brain* 28:99–115
59. Heir G, Karolchek C, Kalladka M (2008) Use of topical medication in orofacial neuropathic pain: a retrospective study. *Oral Surg Oral Med Oral Pathol Oral Radiol Endod* 105:466–469
60. Hillerup S, Hjorting-Hansen E, Reumert T (1994) Repair of the lingual nerve after iatrogenic injury: a follow-up study of return of sensation and taste. *J Oral Maxillofac Surg* 52:1028–1031
61. Hillerup S, Jensen RH, Ersboll BK (2011) Trigeminal nerve injury associated with injection of local anesthesia. *J Am Dent Assoc* 142(5):531–539
62. Jaaskelainen SK, Teerijoki-Oksa T, Virtanen A et al (2004) Sensory regeneration following intraoperatively verified trigeminal nerve injury. *Neurology* 62: 1951–1957

63. Jaaskelainen SK, Teerijoki-Oksa T, Forssell H (2005) Neurophysiologic and quantitative sensory testing in the diagnosis of trigeminal neuropathy and neuro-pathic pain. *Pain* 117:349–357
64. Johnson MD, Burchiel KJ (2004) Peripheral stimulation for treatment of trigeminal postherpetic neuralgia and trigeminal posttraumatic neuropathic pain: a pilot study. *Neurosurgery* 55(1):135–141
65. Jones RHB (1992) Microsurgical repair of nerves injured during third molar surgery. *Aust Dent J* 37(4): 253–261
66. Juhl GI, Jensen TS et al (2008) Central sensitization phenomena after third molar surgery: a quantitative sensory testing study. *Eur J Pain* 12(1):116–127
67. Juodzbalys G, Wang HL, Sabalys G (2011) Injury of the inferior alveolar nerve during implant placement: a literature review. *J Oral Maxillofac Res* 2(1):e1
68. Juretic CR, Gobic MB (2009) Neurectomy of the trigeminal nerve branches: clinical evaluation of an “obsolete” treatment. *J Craniomaxillofac Surg* 37(7): 388–391
69. Kane K, Taub A (1975) A history of local electrical analgesia. *Pain* 1:125
70. Katyal V (2010) The efficacy and safety of articaine versus lignocaine in dental treatments: a meta-analysis. *J Dent* 38:307–317
71. Kellaway P (1946) The part played by electric fish in the early history of bioelectricity and electrotherapy. *Bull Hist Med* 20:112
72. Kondziolka D, Zorro O, Lobato-Polo J et al (2010) Gamma Knife stereotactic radiosurgery for idiopathic trigeminal neuralgia. *J Neurosurg* 112(4):758–765
73. Krumova EK, Zeller M, Westermann A et al (2012) Lidocaine patch (5%) produces a selective, but incomplete block of A delta and C fibers. *Pain* 153:273–280
74. LaBanc JP, Gregg JM (eds) (1992) Trigeminal nerve injury: diagnosis and management. *Oral Maxillofac Surg Clin North Am* 4(2):277–283
75. Levine MH, Goddard AL, Dodson TB (2007) Inferior alveolar nerve canal position: a clinical and radiographic study. *J Oral Maxillofac Surg* 65:470–474
76. Livingstone WK (1945) The phantom limb syndrome. A discussion of the role of major peripheral neuro-mas. *J Neurosurg* 2:251–255
77. Loeser JD, Black RG, Christman A (1975) Relief of pain by transcutaneous stimulation. *J Neurosurg* 42:308
78. Loeser JD (1990) Pain after amputation: phantom limb and stump pain. In: Bonica JJ (ed) *The management of pain*, 2nd edn. Lea and Febiger, Philadelphia
79. Long DM (1973) Electrical stimulation for relief of pain from chronic nerve injury. *J Neurosurg* 39:718
80. Mackinnon SL, Dellon AL (1988) *Surgery of the peripheral nerve*. Thieme, New York
81. Magid OW (2010) Clinical use of botulinum toxins in oral and maxillofacial surgery. *Int J Oral Maxillofac Surg* 39(3):197–207
82. Majno G (1975) *The healing hand of man and wound in the ancient world*. Harvard University Press, Cambridge
83. May A (2008) Chronic pain may change the structure of the brain. *Pain* 137:7–15
84. McComas A (2012) *Galvani’s Spark: the story of the nerve impulse*. Oxford University Press, New York
85. McLachlan EM, Janig W, Devor M et al (1993) Peripheral nerve injury triggers noradrenergic sprouting within dorsal root ganglia. *Nature* 363:543–546
86. Melzack R, Wall PD (1965) Pain mechanisms: a new theory. *Science* 150:961–979
87. Merrill RG (1964) Decompression for inferior alveolar nerve injury. *J Oral Surg* 22:291
88. Merzenich MM, Nelson RJ, Stryker MP et al (1984) Somatosensory cortical map changes following digit amputation in adult monkeys. *J Comp Neurol* 224: 591–605
89. Meyer RA (1992) Applications of microneurosurgery to the repair of trigeminal nerve injuries. *Oral Maxillofac Surg Clin North Am* 4(2):405–416
90. Meyer RA, Rath EM (2001) Sensory rehabilitation after trigeminal nerve injury or nerve repair. *J Oral Maxillofac Surg Clin North Am* 13(2):365–375
91. Meyer RA, Bagheri SC (2011) Nerve injuries from mandibular third molar removal. *Atlas Oral Maxillofac Surg Clin North Am* 19:63
92. Midamba ED, Haanes HR (1993) Low reactive level 830 nm GaAlAs diode laser therapy (LLLT) successfully accelerates regeneration of peripheral nerves in human. *Laser Ther* 5:125–129
93. Millesi H (1973) Microsurgery of peripheral nerves. *Hand* 5:157–160
94. Millesi H (1984) Nerve grafting. *Clin Plast Surg* 11: 105–113
95. Miloro M (1995) Surgical access for inferior alveolar nerve repair. *J Oral Maxillofac Surg* 53:1224–1225
96. Miloro M (2001) The use of autogenous vein grafts for inferior alveolar and lingual nerve reconstruction: discussion. *J Oral Maxillofac Surg* 59:988–993
97. Miloro M, Halkias LE, Slone HW et al (1997) Assessment of the lingual nerve in the third molar region using magnetic resonance imaging. *J Oral Maxillofac Surg* 55:134–137
98. Miloro M, Rapasky R (2000) Low-level laser effect on neurosensory recovery after sagittal ramus osteotomy. *Oral Surg Oral Med Oral Pathol Oral Radiol Endod* 89:12–18
99. Miloro M, Stoner JA (2005) Subjective outcomes following sural nerve harvest. *J Oral Maxillofac Surg* 63:1150–1154
100. Misch CE, Resnik R (2010) Mandibular nerve neurosensory impairment after dental implant surgery: management and protocol. *Implant Dent* 19(5):378–384
101. Mitchell SW (1872) *Injuries of nerves and their consequences*. Lippincott, Philadelphia
102. Mitchell SW, Morehouse GR, Keen WW Jr (1864) *Gunshot wounds and other injuries*. Lippincott, Philadelphia
103. Mozsary PG, Syers CS (1985) Microsurgical correction of the injured inferior alveolar nerve. *J Oral Maxillofac Surg* 43:353–358
104. Noordenbos W (1959) *Problems pertaining to the transmission of nerve impulses which give rise to pain*. Elsevier, Amsterdam

105. Nuti C, Mertens P, Peyron R et al (2005) Motor cortex stimulation for refractory neuropathic pain: four years outcome and predictors of efficacy. *Pain* 118: 43–52
106. O'Connor AB, Dworkin RH (2009) Treatment of neuropathic pain: an overview of recent guidelines. *Am J Med* 122:522–532
107. Padilla M, Clark GT, Merrill RL (2000) Topical medications for orofacial neuropathic pain: a review of the literature. *J Am Dent Assoc* 131(2):184–195
108. Piao ZG, Cho IH, Park CK et al (2006) Activation of glia and microglia p38MAPK in medullary dorsal horn contributes to tactile hypersensitivity following trigeminal sensory nerve injury. *Pain* 121:219–231
109. Phillips C, Essick G, Preisser JS et al (2007) Sensory retraining after orthognathic surgery: effect on patients' perception of altered perception. *J Oral Maxillofac Surg* 65:1162–1173
110. Pitta MC, Wolford LM, Mehra P et al (2001) Use of Gore-Tex tubing as a conduit for inferior alveolar and lingual nerve repair: experience with 6 cases. *J Oral Maxillofac Surg* 59:493–499
111. Platt H (1919) On the results of bridging gaps in injured nerve trunks by autogenous fascial tubulization and autogenous nerve grafts. *Br J Surg* 7:384–389
112. Pogrel MA (2002) The results of microneurosurgery of the inferior alveolar and lingual nerve. *J Oral Maxillofac Surg* 60:485–489
113. Pogrel MA, Kaban LB (1993) Injuries to the inferior alveolar and lingual nerves. *J Calif Dent Assoc* 21(1):50–54
114. Pogrel MA, Schmidt BL, Sambajon V et al (2003) Lingual nerve damage due to inferior alveolar nerve blocks: a possible explanation. *J Am Dent Assoc* 134:195–199
115. Price DD, Bennett GJ, Rafii A (1989) Psychophysical observations on patients with neuropathic pain relieved by sympathetic block. *Pain* 36:273–288
116. Rath EM (2002) Skeletal muscle autograft for repair of the human inferior alveolar nerve: a case report. *J Oral Maxillofac Surg* 60(3):330–334
117. Rainov NG, Heidecke V (2003) Motor cortex stimulation for neuropathic facial pain. *Neurol Res* 25: 157–161
118. Ramon Y, Cajal SR (1905) Mecanismo de la degeneracion y regeneracion de nervios. *Trab Lab Inbest Biol* 9:119
119. Ranson MT, Pope JE (eds) (2012) Reducing risks and complications of interventional pain procedures. Elsevier/Saunders, Philadelphia
120. Robinson PP, Boissonade FM, Loescher AR et al (2004) Peripheral mechanisms for the initiation of pain following trigeminal nerve injury. *J Orofac Pain* 18:287–292
121. Robinson PP, Loescher AR, Smith KG (2000) A prospective, quantitative study on the clinical outcome of lingual nerve repair. *Br J Oral Maxillofac Surg* 38:255–263
122. Rolke R, Baron R, Maier C et al (2006) Quantitative sensory testing in the German Research Network on Neuropathic Pain (DFNS): standardized protocol and reference values. *Pain* 123:231–243
123. Ruggiero SL (ed) (2001) Microsurgery of the trigeminal nerve. *Atlas Oral Maxillofac Surg Clinics North Am* 9(2):13–21
124. Sabino MAC, Honore P, Rogers SD et al (2002) Tooth extraction-induced internalization of the substance P receptor in trigeminal nucleus and spinal cord neurons: imaging the neurochemistry of dental pain. *Pain* 95:175–186
125. Salter MW (2004) Cellular neuroplasticity mechanisms mediating pain persistence. *J Orofac Pain* 18(4):318–324
126. Sato J, Perl ER (1991) Adrenergic excitation of cutaneous pain receptors induced by peripheral nerve injury. *Science* 251:1608–1610
127. Seddon HJ (1943) Three types of nerve injury. *Brain* 66:237
128. Shanti RM, Ziccardi VB (2011) Use of decellularized nerve allograft for inferior alveolar nerve reconstruction: a case report. *J Oral Maxillofac Surg* 69:550–553
129. Sheldon CH, Pudenz RH, Doyle J (1967) Electrical control of facial pain. *Am J Surg* 114:209
130. Sherrington CS (1906) The integrative action of the nervous system. Yale University Press, New Haven
131. Smith KG, Robinson PP (1995) An experimental study of three methods of lingual nerve defect repair. *J Oral Maxillofac Surg* 53:1052–1062
132. Sunderland S (1951) A classification of peripheral nerve injuries produced by loss of function. *Brain* 74:491
133. Susarla SM, Kaban LB, Donoff RB et al (2007) Functional sensory recovery after trigeminal nerve repair. *J Oral Maxillofac Surg* 65:60–65
134. Teutsch S, Herken W et al (2008) Changes in brain gray matter due to repetitive painful stimulation. *Neuroimage* 42:845–849
135. Vos BP, Strassman AM, Maciewicz RJ (1994) Behavioral evidence of trigeminal neuropathic pain following chronic constriction injury to the rat's infraorbital nerve. *J Neurosci* 14:2708–2723
136. Wall PD, Gutnick M (1974) Ongoing activity in peripheral nerves: the physiology and pharmacology of impulses originating in a neuroma. *Exp Neurol* 43:580
137. Waller A (1850) Experiments on the section of glossopharyngeal nerves of the frog and observations of the alterations produced thereby in the structure of their primitive fibers. *Philos Trans R Soc Lond* 140:423
138. Wang X, Luo E, Li Y, Hu J (2011) Schwann-like mesenchymal stem cells within vein graft facilitate facial nerve regeneration and remyelination. *Brain Res* 1383:71–80
139. Weiss P (1944) Sutureless reunion of severed nerves with cuffs of tantalum. *J Neurosurg* 1:219
140. Weiss P, Taylor AC (1946) Guides for nerve regeneration across gaps. *J Neurosurg* 27:401
141. White JC (1946) Painful injuries of nerves and their surgical management. *Am J Surg* 72:468–488
142. White JC, Sweet WH (1969) Pain and the neurosurgeon. CC Thomas, Springfield

143. Whitlock EL, Tuffaha SH, Luciano JP et al (2009) Processed allografts and type I collagen conduits for repair of peripheral nerve gaps. *Muscle Nerve* 39:787–799
144. Wilgis EFS (1982) Nerve repair and grafting. In: Green DP (ed) *Operative hand surgery*. Churchill Livingstone, New York
145. Woolf CJ, Salter MW (2000) Neuronal plasticity: increasing the gain in pain. *Science* 288:1765–1768
146. Worthington P (1979) *Course in microsurgery for oral and maxillofacial surgeons*. University of Washington, Seattle
147. Xie YF, Zhang S, Chiang CY et al (2007) Involvement of glia in central sensitization in trigeminal subnucleus caudalis (medullary dorsal horn). *Brain Behav Immun* 21(5):634–641
148. Yoon SH, Merrill RL (2010) Use of botulinum toxin type A after trigeminal nerve injury. *Pain Med* 4:107
149. Yoon YW, Dong H, Arends JJ et al (2004) Mechanical and cold allodynia in a rat spinal cord contusion model. *Somatosens Mot Res* 21:25–31
150. Ziccardi VB, Steinberg MJ (2007) Timing of trigeminal nerve microsurgery: a review of the literature. *J Oral Maxillofac Surg* 65:1341–1345
151. Zuniga JR, Gregg JM (eds) (2001) *Clinical trials in orofacial neurotrauma*. *Oral Maxillofac Surg Clin North Am* 13(2):377–381
152. Zuniga JR, Meyer RA, Gregg JM et al (1998) The accuracy of clinical neurosensory testing for nerve injury diagnosis. *J Oral Maxillofac Surg* 56:2–8

John R. Zuniga and Alaaldin M. Radwan

2.1 Introduction

As oral and maxillofacial surgeons perform broad scope orofacial surgical procedures, most may expect to experience nerve injuries during their practice lifetime. Worldwide, the incidence of injury to the inferior alveolar nerve (IAN) has been reported to be from 0.26 to 8.4 %, whereas lingual nerve (LN) deficits range from 0.1 to 22 % [1–3]. Temporary or permanent sensory nerve disturbances are not uncommon; however, sensory deficits lasting longer than 1 year are more likely to be permanent, and attempts at microneurosurgical repair are often unsuccessful in these long-standing injuries [4].

Numerous studies have shown that dentoalveolar surgery is a major cause of trigeminal nerve injuries. Other causes of nerve dysfunction include root canal therapy with canal over-instrumentation, and extravasation of endodontic

filling material beyond the root apex has been noted in the literature [5, 6]. As the number of dental implant procedures increases, so do the complications associated with the mandibular division of the trigeminal nerve. As an oral and maxillofacial surgeon, one must have knowledge of this complication and provide informed consent to their patients [7, 8]. The symptomology is different from patient to patient and varies greatly from slight paresthesia to complete anesthesia, with or without pain [9].

This chapter will review classification systems for nerve injury, with the goals of providing this information to:

1. Assist clinicians in distinguishing the common symptoms and signs of nerve injury.
2. Provide a diagnosis and distinguish the degrees of damage for the different types of injury.
3. Provide a prognosis for recovery to help differentiate when the specific injury or patient characteristics will recover spontaneously as opposed to those requiring different treatment interventions, including surgery.
4. Provide guidance and direction regarding treatment options and provide prognosis for treatment outcome based upon the specific sensory deficit(s).

Classification systems are an important method for clinicians and clinical scientists to define common grounds for understanding etiology, differentiating symptom complexes, and predicting outcome in the present and in the future. A satisfactory classification system would

J.R. Zuniga, DMD, MS, PhD (✉)
Division of Oral and Maxillofacial Surgery,
Department of Surgery, University of Texas
Southwestern Medical Center at Dallas,
5323 Harry Hines Blvd., Dallas, TX 75390-9109, USA
e-mail: john.zuniga@utsouthwestern.edu

A.M. Radwan, DDS
Division of Oral and Maxillofacial Surgery,
Department of Surgery, Parkland Hospital and
Health Services, University of Texas
Southwestern Medical Center at Dallas,
5323 Harry Hines Blvd., Dallas, TX 75390-9109, USA
e-mail: dr.aradwan@gmail.com

provide a clinically acceptable system for diagnosis, prognosis, and treatment selection based upon statistically validated measurements. A clinically viable diagnostic test system would be used to apply and distinguish the different classification and staging systems, classes, and categories in order to provide sensitivity, specificity, positive and negative predictive values, and test accuracy and predilection. In other words, distinguishing normal from abnormal in the clinical setting (i.e., determination of false positive and negative from true positive (nerve injury present) and negative (normal, no nerve injury present)).

The classification system serves as the “gold standard system” for diagnostic testing. This chapter will present the current systems used for nerve injury classification.

2.2 Historical Perspectives

Peripheral nerve injuries were first studied systematically during the American Civil War by neurologist S. Weir Mitchell. Many of the advances in knowledge about peripheral nerve injuries have occurred during wartime, including World War I and II, from physicians on both sides of the front [10]. These nerve injuries were addressed under much less than ideal conditions in the field, but much information was learned from their management.

2.3 Nerve Injury Classification via Semiquantitative Value

2.3.1 Histology

In 1942, Sir Herbert Seddon introduced the three basic classifications based on severity of nerve injury determined by histology that is correlated to motor function that is used today in sensory and motor nerve injury classification (Fig. 2.1). These include neurapraxia, axonotmesis, and neurotmesis [11].

2.3.1.1 Neurapraxia

Neurapraxia is seen as motor paralysis, and it is the mildest injury type that is transient. There is no effect on nerve continuity. The transient nature of this injury is believed to be caused by a temporary disturbance in the conduction pathway that blocks neural transmission but does not damage the axon. Symptoms include motor paralysis (for motor nerves), numbness, tingling, and loss of vibration and postural sensation. All of these effects resemble the common effects of local anesthesia.

2.3.1.2 Axonotmesis

Axonotmesis occurs when there is complete interruption of the nerve fibers, but the connective tissues (endoneurium, perineurium, and epineurium) remain intact. It is a disturbance of nerve cell axon, with Wallerian degeneration occurring near the site of injury. This type of nerve injury is caused by a crush or pressure damage. Spontaneous regeneration is likely to

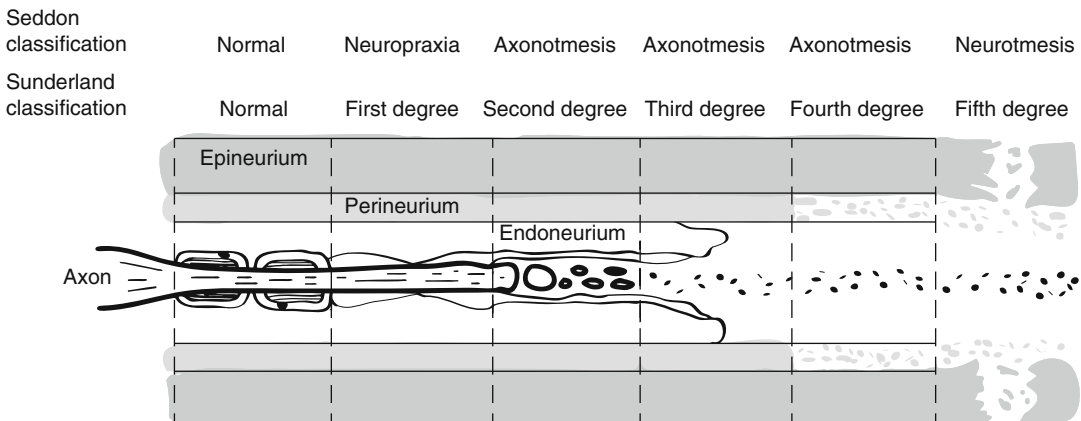


Fig. 2.1 Seddon and Sunderland classification of nerve injury based upon histological neural changes

Table 2.1 Neurosensory recovery based upon Sunderland classification

| Sunderland | Recovery pattern | Rate of recovery | Need for surgery |
|------------|------------------|---------------------|------------------|
| 1st degree | Complete | Fast (days-weeks) | – |
| 2nd degree | Complete | Slow (weeks) | – |
| 3rd degree | Variable | Slow (weeks-months) | –/+ |
| 4th degree | Poor | Little/none | + |
| 5th degree | None | None | ++ |

occur following this type of injury [12]. The nerve as a mass is still in continuity [11].

2.3.1.3 Neurotmesis

Neurotmesis involves complete severance of the nerve. Functional loss is complete and recovery without surgical intervention is unlikely. There is a complete loss of motor and sensory function. If there is recovery, it is usually incomplete. It is important to note that clinically, there may no difference between axonotmesis and neurotmesis. Discerning the differences between the two entities includes:

1. Prognosis: Axonotmesis may be expected to be followed by spontaneous regeneration, while in neurotmesis, signs of recovery fail to appear or may occur only following surgical repair [11] (Table 2.1).
2. Time: The specific time frame for recovery differentiates between axonotmesis and neurotmesis. Axonotmesis may be followed by spontaneous recovery while neurotmesis is not. The drawback is that once a time limit, generally accepted as 90 days, has passed, the likelihood of spontaneous regeneration decreases significantly (9.3–62.9 %) [13].
3. Exploration: The only precise and predictive method to differentiate between axonotmesis and neurotmesis. If performed in a conservative manner, exploration is the gold standard for distinguishing between the three basic classifications of nerve injury [11].
4. Histology: It is important to emphasize that histological analysis is very reliable, however, clinically not useful.

In 1951, Sir Sydney Sunderland further stratified the three nerve injury types described

Table 2.2 Modified MRCS (Medical Research Council Scale)

| Grade | Description |
|-------|---|
| S0 | No sensation |
| S1 | Deep cutaneous pain in autonomous zone |
| S2 | Some superficial pain and touch |
| S2+ | Superficial pain and touch plus hyperesthesia |
| S3 | Superficial pain and touch without hyperesthesia and static 2-point discrimination >15 mm Indicates USF (useful sensory function) ^a |
| S3+ | Same as S3 with good stimulus localization and static 2-point discrimination of 7–15 mm Indicates USF ^a |
| S4 | Same as S3 and static 2-point discrimination of 2–6 mm Indicates CSR (complete sensory recovery) ^a |

^aGrades S3, S3+, and S4 indicates FSR (functional sensory recovery)

by Seddon into five categories according to Wallerian axon degeneration and disruption of the endoneurial, perineurial, and epineurial tissues again based upon histological findings [14].

A first-degree injury is equivalent to Seddon's neurapraxia and a second-degree injury is equal to axonotmesis. Third-degree nerve injury can be described as axonotmesis with endoneurial involvement. This category fits between Seddon's pure axonotmesis and neurotmesis. Dependent upon the extent of the endoneurial damage, functional recovery may be possible. Sunderland further divides Seddon's neurotmesis into fourth- and fifth-degree injuries. In a fourth-degree injury, all portions but the epineurium of the nerve are disrupted and surgery is necessary for treatment. Fifth-degree injury, similar to the classic neurotmesis, involves complete severance of the nerve including the epineurium [14].

In 1988, Mackinnon introduced a new injury pattern deemed useful to further classify nerve injuries. This classification scheme combines multiple types of nerve injuries seen in the Sunderland classification. It is in other words a mixed scheme where many types of nerve injury are combined and therefore there are variable degrees of recovery witnessed by the examiner and experienced by the patient. Electrodiagnostic tests are used to differentiate between first degree and other degrees of nerve injury; however, they will not differentiate between the recovery potential associated with each injury [15] (Table 2.2).

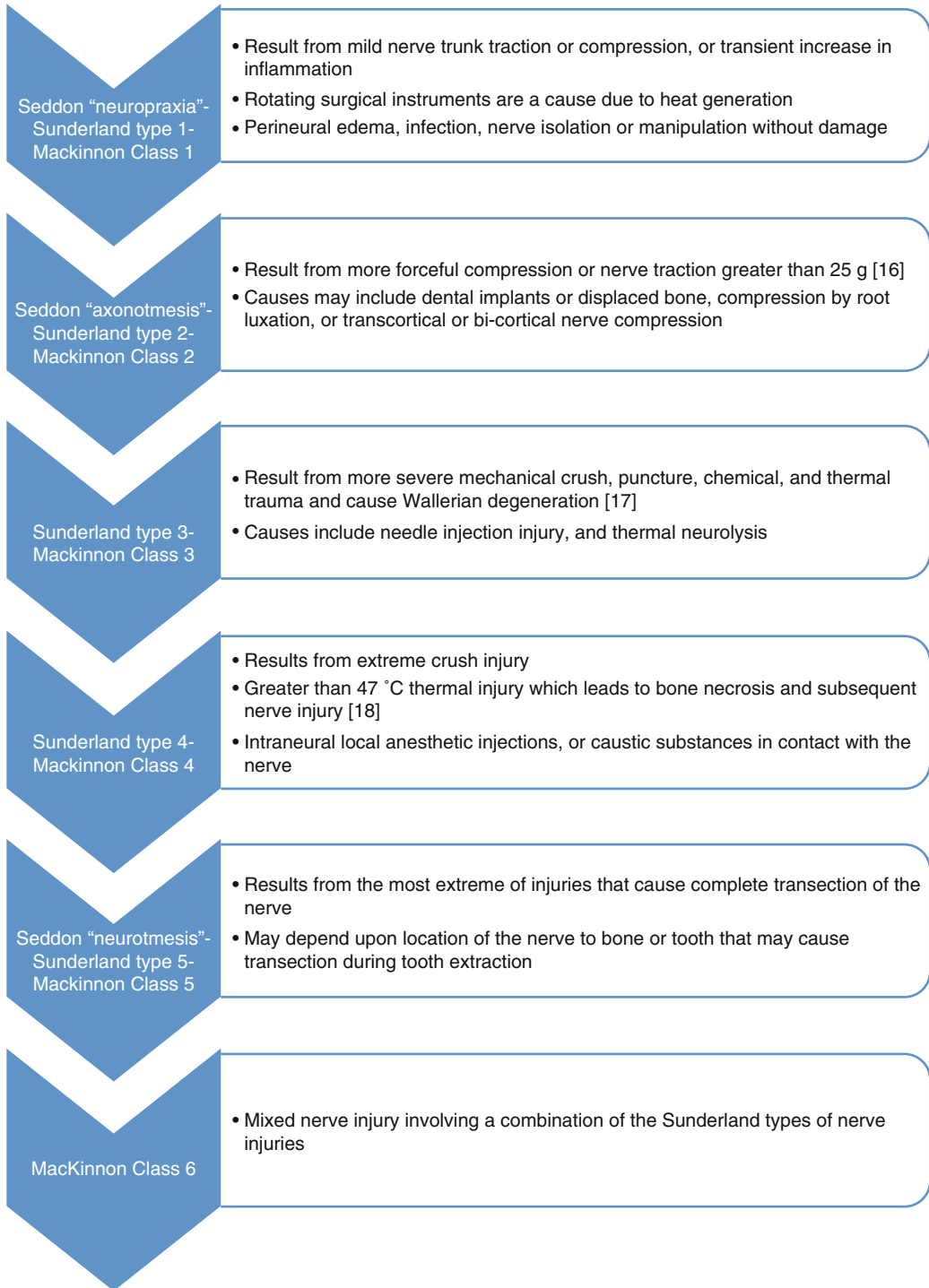

Fig. 2.2 Characteristics of the different types of nerve injuries based upon Seddon [11], Sunderland [14] and Mackinnon [15] classification schemes

More recently, the modified Medical Research Council Scale (MRCS) has been applied to the classification schemes for trigeminal nerve injury (Fig. 2.2). The grading system provides a useful method to document and monitor neurosensory recovery, either spontaneously or following surgical repair.

2.4 Nerve Injury Classification via Independent Classification

Nerve injuries as discussed previously can be created by a myriad of causes, most notably, mechanical injuries such as that produced during third molar extractions, root canal instrumentation, dental implant placement, and osteotomy procedures.

Systemic processes may also influence nerve injury responses. These include chemical injury, infection, metabolic, genetic, and disease-related causes. These other mechanisms of nerve injury may be referred to as nerve classification independent.

2.4.1 Chemical Injuries

Nerve injury by chemicals has been noted in the literature from nerve agents used as chemical weapons to the common household bleach. Any chemical that can disrupt the conduction mechanism of the nerve can cause chemical nerve injury [19]. This discussion will be limited to chemicals that are used in dental and surgical settings.

Local anesthetics are commonly used in dentistry and oral and maxillofacial surgery, and it is generally considered a safe chemical to use in a healthy individual. Unfortunately, injection-related trigeminal nerve injury that can cause neurosensory disturbances (NSD) is a rare but present complication. The signs and symptoms associated with NSD are associated with a range including anesthesia, hypoesthesia, dysesthesia, allodynia, gustatory abnormalities, and spontaneous pain [20]. Estimates of the incidence of local anesthetic related NSD (temporary or permanent) in dental practice vary greatly, ranging

from as high as 1:42 to as low as 1:750,000 disturbances per injection [20]. However, the true incidence remains elusive due the unknown number of unreported cases. Symptom resolution has been suggested to occur within 8 weeks; however, more longitudinal studies are still needed [21, 22]. The four major local anesthetics that were associated with the highest incidence of NSD were articaine 4 %, lidocaine 2 %, mepivacaine 3 %, and prilocaine 3 %, with articaine having the highest share of cases reported [20].

Other common chemicals that have been associated with chemical nerve injury are those used in root canal therapy during cleaning or sealing. Bleach, or sodium hypochlorite, is the most commonly used irrigant in endodontics due to its dual action as a powerful antimicrobial agent and its ability to dissolve organic soft tissue in the root canal system [23]. Bleach extravasation beyond the root canal apex into the surrounding tissue can cause a plethora of signs and symptoms ranging from weakness and paresthesia to neuropathic pain and tissue necrosis. The onset of these signs and symptoms can range from immediate onset to late onset [23]. All root canal sealants are neurotoxic to some degree depending upon the level of penetration of the epineurium. Unfortunately, dysesthesia can be the main NSD noted from sealant damage with a rate of 30 % [5].

2.4.2 Infection

A variety of bacteria and viruses can cause neural damage resulting in a condition known as peripheral neuropathy. The most notable virus to be discussed is herpes zoster virus causing postherpetic neuralgia (PHN) and Ramsey Hunt syndrome II (herpes zoster oticus). Herpes zoster has the highest incidence of all neurologic diseases. It occurs in approximately a half million individuals in the USA and has a lifetime occurrence of 20 % [24, 25]. After initial infection, the varicella-zoster virus establishes latency in the spinal and cranial nerve ganglia. After reactivation and replication, the viruses spread from the sensory nerve fibers in the ganglion to the involved dermatomes. Other

than the dermatologic manifestations of the infection, there are a multitude of neurologic manifestations ranging from neuropathic pain to paresthesia [26]. The rash disappears within 2–4 weeks, but the most distressing symptom that may persist after resolution of the acute infection is pain, predominately allodynia. Pain that persists beyond 3 months is termed postherpetic neuralgia [27]. It is a pain that has been described using words such as stabbing, burning, gnawing, and shooting. The destruction of primary afferent C-fibers and resulting central hyperactivity is thought to be the cause of pain in PHN [28, 29].

Ramsey Hunt syndrome was introduced in the beginning of 1900s [26]. Malin defined the syndrome as consisting of multiple signs and symptoms:

1. Zoster oticus (a lesion that is rarely also on ipsilateral soft palate)
2. Peripheral facial nerve paresis with gustatory disturbances and reduction of lacrimation (rarely contralateral or bilateral cranial nerve VII paresis)
3. Sensory disturbances in the areas innervated by branches V1 and V3 of the trigeminal nerve
4. Sensory disturbances in the cervical dermatomes (frequently C2 to C4)
5. Lesion of cranial nerve VIII (causing decreased audition) [30].

2.4.3 Metabolic Disorders

These are disorders caused by a disruption of the chemical processes in the body. In some instances, nerve damage is caused by poor energy utilization by the body. In others, the accumulation of harmful substances (toxins) in the body may lead to nerve damage. Some metabolic disorders are inherited, and other etiologies are multifactorial. Diabetic sensorimotor polyneuropathy (DSPN) develops as a consequence of chronic hyperglycemia. This results in chronic metabolic derangements, including oxidative stress, excessive advanced glycation end products (AGE), and polyol pathway flux. Microscopic vessel damage and nerve injury are the end result. In DSPN, the

longest sensory axons are affected first, resulting in peripheral neuropathy of the feet and hands. Large nerve fiber damage occurs early, predominately affecting vibration. However, it may also result in loss of proprioception, muscle strength, and two-point discrimination. Polyradiculopathy can also be seen as a result of DSPN. Clinically, this is commonly seen affecting the lumbar nerve root distribution [31]. At this point, there have been no reports of metabolic disorders that cause trigeminal nerve injury.

2.4.4 Genetic Disorders

The inherited peripheral neuropathies are a complex group of disorders caused by mutations in more than 50 genes. They are caused by nascent mistakes in the genetic code or by new genetic mutations. Some genetic mutations lead to mild neuropathies with symptoms that appear in early adulthood and result in little, if any, significant neurosensory impairment. More severe hereditary neuropathies may appear in early childhood or even in infancy. The most common inherited neuropathies are a group of disorders collectively referred to as Charcot-Marie-Tooth (CMT) disease, after the three men who first described them in 1886. These neuropathies result from errors in genes responsible for manufacturing neurons or the myelin sheath. Hallmarks of typical Charcot-Marie-Tooth disease include extreme weakening and wasting of muscles in the lower legs and feet, gait abnormalities, loss of tendon reflexes, and numbness in the lower limbs. CMT disease can also lead to severe pain in the extremities [32]. At this point in time, there have been no reports of genetic disorders that cause trigeminal nerve injury.

2.4.5 Multiple Sclerosis

During periods of multiple sclerosis (MS) activity, white blood cells are drawn to regions of the white matter. These initiate and participate in the inflammatory response. During the inflammatory phase, the myelin surrounding the axons is destroyed in a process known as demyelination.

There are a significant number of MS patients who actually suffer from painful conditions such as central and peripheral neuropathy, migraine headaches, trigeminal neuralgia, painful tonic spasms or Lhermitte's sign, complex regional pain syndrome (CRPS), glossopharyngeal neuralgia, and transverse myelitis. In addition, MS relapses are usually accompanied by pain with many patients complaining of paroxysmal dystonia and neuropathic pain during these episodes [33]. It is important to note that approximately 2 % of patients with MS also have symptoms of trigeminal neuralgia [34].

2.5 Nerve Injury Classification via Subjective Reporting

Complete versus partial nerve avulsions and injuries produce different responses with regard to the effects on sensory perception and type of dysesthesia that result. Ironically, lesser neurotrauma, as seen with Sunderland type 2 and 3 injuries and partial or puncture injuries, is more likely to be associated with early hyperesthesia. Severe type 4 internal nerve damage and type 5 complete lac-

eration or avulsion injuries, by contrast, are often initially less painful but eventually lead to the formation of dysfunctional chronic neuroma-incontinuity and amputation neuromas. These initially anesthetic lesions are more often associated with poor orofacial function, referred and radiating forms of unpleasant paresthesia, and spontaneous pain [35, 36]. Other such terminologies of altered function that clinicians define as altered are found in Table 2.3.

In trying to obtain subjective reporting from patients, it is beneficial to provide them with a list of *verbal descriptors* that helps illicit qualitative information about their neuropathy; it is also helpful in revealing the causal mechanisms of sensory irregularity, pain, and dysfunction. Important to note is that when the vast majority of English-speaking patients were asked about their neuropathy they used the term “numbness” [35, 37]. However, quantitative sensory testing (QST) reveals that patients' objective reporting varied widely, with some patients testing completely anesthetic, while others had near normal stimulus responses.

The majority of patients tend to report their symptoms mainly using three words for each of

Table 2.3 Pain terms adapted from the definitions of the International Association for the Study of Pain (www.iasp-pain.org)

| | |
|---------------|---|
| Paresthesia | Abnormal sensation whether spontaneous or evoked and is not unpleasant |
| Dysesthesia | An unpleasant abnormal sensation, whether spontaneous or evoked. Special cases of dysesthesia include hyperalgesia and allodynia |
| Anesthesia | It is a pharmacologically induced and reversible state of amnesia, analgesia, loss of responsiveness, loss of skeletal muscle reflexes or decreased stress response, or all simultaneously |
| Hyperesthesia | Increased sensitivity to stimulation, excluding the special senses. The stimulus and locus should be specified. <i>Hyperesthesia</i> may refer to various modes of cutaneous sensibility including touch and thermal sensation without pain, as well as to pain. The word is used to indicate both diminished threshold to any stimulus and an increased response to stimuli that are normally recognized |
| Hypoesthesia | Decreased sensitivity to stimulation, excluding the special senses. Stimulation and locus to be specified |
| Synesthesia | A neurological condition in which stimulation of one sensory or cognitive pathway leads to automatic, involuntary experiences in a second sensory or cognitive pathway |
| Allodynia | Pain due to a stimulus that does not normally provoke pain. The stimulus leads to an unexpectedly painful response. This is a clinical term that does not imply a mechanism. Allodynia may be seen after different types of somatosensory stimuli applied to many different tissues |
| Sensitization | Increased responsiveness of nociceptive neurons to their normal input, and/or recruitment of a response to normally subthreshold inputs. Sensitization can include a drop in threshold and an increase in suprathreshold response. Spontaneous discharges and increases in receptive field size may also occur |

Table 2.4 Qualitative descriptors used by patients to describe hypoesthesia, paresthesia, and dysesthesia [38]

| | |
|--------------|---------------------------------|
| Hypoesthesia | Numb Rubbery Swollen |
| Paresthesia | Tingling Tickling Itching |
| Dysesthesia | Tender Pricking Burning |

the following categories: hypoesthesia, paresthesia, and dysesthesia.

As compared to hypoesthesia and paresthesia categories, the three most commonly chosen words by patients to describe their symptoms were less useful in describing dysesthesia [38] (Table 2.4).

Nerve classification is an essential part of diagnosing and managing nerve injuries since it allows the establishment of specifically structured treatments based upon individual categories of injury. It provides the means of obtaining a prognosis based upon the type of nerve injury, the etiologic factor that caused that injury, and the length of time since the injury. One must also take into consideration the importance of subjective data in addressing the specific needs of the patient. This includes obtaining a thorough history of present illness and allowing the patient to describe their injury in their own words.

References

- Gulich D, Gerlach KL (2001) Sensory impairment of the lingual and inferior alveolar nerves following removal of impacted mandibular third molars. *Int J Oral Maxillofac Surg* 30(4):306–312
- Jerjes W et al (2010) Risk factors associated with injury to the inferior alveolar and lingual nerves following third molar surgery-revisited. *Oral Surg Oral Med Oral Pathol Oral Radiol Endod* 109(3):335–345
- Leung YY, Cheung LK (2011) Risk factors of neurosensory deficits in lower third molar surgery: an literature review of prospective studies. *Int J Oral Maxillofac Surg* 40(1):1–10
- Loescher AR, Smith KG, Robinson PP (2003) Nerve damage and third molar removal. *Dent Update* 30(7):375–380, 382
- Pogrel MA (2007) Damage to the inferior alveolar nerve as the result of root canal therapy. *J Am Dent Assoc* 138(1):65–69
- Neaverth EJ, Swindle R (1990) A serious complication following the inadvertent injection of sodium hypochlorite outside the root canal system. *Compendium* 11(8):474, 476, 478–81
- Ziccardi VB, Assael LA (2001) Mechanisms of trigeminal nerve injuries. *Atlas Oral Maxillofac Surg Clin North Am* 9(2):1–11
- Ziccardi VB, Rivera L, Gomes J (2009) Comparison of lingual and inferior alveolar nerve microsurgery outcomes. *Quintessence Int* 40(4):295–301
- Alhassani AA, AlGhamdi AS (2010) Inferior alveolar nerve injury in implant dentistry: diagnosis, causes, prevention, and management. *J Oral Implantol* 36(5):401–407
- Maricevic A, Erceg M (1997) War injuries to the extremities. *Mil Med* 162(12):808–811
- Seddon HJ (1943) Three types of nerve injury. *Brain* 66:237–288
- Payton OD, Jackson O, Di Fabio RP (1989) *Manual of physical therapy*. Churchill Livingstone, New York
- Susarla SM, Blaeser BF, Magalnick D (2003) Third molar surgery and associated complication. *Oral Maxillofac Surg Clin North Am* 15:177
- Sunderland S (1951) A classification of peripheral nerve injury producing loss of function. *Brain* 74:491–516
- Mackinnon SE (1989) New directions in peripheral nerve surgery. *Ann Plast Surg* 22(3):257–273
- Terzis J, Faibisoff B, Williams HB (1975) The nerve gap: suture under tension versus graft. *Plast Reconstr Surg* 56:166
- Erikson L et al (2006) Traumatic changes of the inferior alveolar nerve and Gasserian ganglion after removal of a mandibular third molar: report of a case. *J Oral Maxillofac Surg* 64:1821
- Juodzbaly G et al (2013) Inferior alveolar nerve injury associated with implant surgery. *Clin Oral Implants Res* 24:183–190
- Sidell FR, Takafuji ET, Franz DR (1997) *Medical aspects of chemical and biological warfare*. Borden Institute, Walter Reed Army Medical Center, Washington, D.C., pp 131–139
- Hillerup S, Jensen RH, Ersbøll BK (2011) Trigeminal nerve injury associated with injection of local anesthetics: needle lesion or neurotoxicity? *J Am Dent Assoc* 142(5):531–539
- Pogrel MA, Thamby S (2000) Permanent nerve involvement resulting from inferior alveolar nerve blocks. *J Am Dent Assoc* 131(7):901–907 (published correction appears in *JADA* 2000;131[10]:1418)
- Haas DA (2002) An update on local anesthetics in dentistry. *J Can Dent Assoc* 68(9):546–551

23. Chaudhry H et al (2011) Before you reach for the bleach. *Br Dent J* 210(4):157–160
24. Kurtzke JF (1984) Neuroepidemiology. *Ann Neurol* 16:265–277
25. Donohue RH et al (1995) The incidence of herpes zoster. *Arch Intern Med* 155:1605–1609
26. Wagner G et al (2012) Ramsay hunt syndrome. *J Dtsch Dermatol Ges* 10(4):238–244
27. Dworkin RH et al (2000) Prospects for the prevention of postherpetic neuralgia in herpes zoster patients. *Clin J Pain* 16(2 Suppl):S90–S100
28. Rowbotham MC et al (1996) Cutaneous innervation density in the allodynic form of postherpetic neuralgia. *Neurobiol Dis* 3(3):205–214
29. Oaklander AL et al (1998) Unilateral postherpetic neuralgia is associated with bilateral sensory neuron damage. *Ann Neurol* 44(5):789–795
30. Malin JP, Weissenborn K, Heinze HJ (1985) Das Ramsay-hunt-syndrom. *Verhandl dtsch Ges Neurol* 3:658–661
31. Morales-Vidal S, Morgan C, McCoyd M, Hornik A (2012) Diabetic peripheral neuropathy and the management of diabetic peripheral neuropathic pain. *Postgrad Med* 124(4):145–153
32. Patzko A, Shy ME (2012) Charcot-Marie-tooth disease and related genetic neuropathies. *Continuum Lifelong Learn Neurol* 18(1):39–59
33. Kenner M, Menon U, Elliott DG (2007) Multiple sclerosis as a painful disease. *Int Rev Neurobiol* 79:303–321
34. Solaro C, Bricchetto G, Amato MP et al (2004) The prevalence of pain in multiple sclerosis: a multicenter cross-sectional study. *Neurology* 63:919
35. Jaaskelainen SK, Teerjoke-Oske T, Forsell H (2005) Neurophysiologic and quantitative sensory testing in the diagnosis of trigeminal neuropathy and neuropathic pain. *Pain* 117(3):349
36. Rasmussen PV et al (2004) Symptoms and signs in patients with suspected neuropathic pain. *Pain* 110:461
37. Gregg JM (1992) Abnormal responses to trigeminal nerve injury. *Oral Maxillofac Surg Clin North Am* 4:339
38. Phillips C, Essick G, Zuniga J, Tucker M, Blakey G III (2006) Qualitative descriptors used by patients following orthognathic surgery to portray altered sensation. *J Oral Maxillofac Surg* 64(12):1751–1760

Roger A. Meyer and Shahrokh C. Bagheri

3.1 Introduction

Dental treatment, surgical operations, and traumatic injuries to the oral cavity and maxillofacial region occur in close proximity to peripheral

R.A. Meyer, DDS, MS, MD, FACS (✉)
Department of Surgery, Northside Hospital,
Atlanta, GA, USA

Georgia Oral and Facial Surgery,
1880 West Oak Parkway, Suite 215,
Marietta, GA 30062, USA

Department of Oral and Maxillofacial Surgery,
Georgia Health Sciences University,
Augusta, GA, USA

Medicolegal Services, Maxillofacial Consultants, Ltd.,
1021 Holt's Ferry, Greensboro, GA 30642, USA
e-mail: rameyer@aol.com

S.C. Bagheri, DMD, MD, FACS
Department of Surgery, Northside Hospital,
Atlanta, GA, USA

Georgia Oral and Facial Surgery,
1880 West Oak Parkway, Suite 215,
Marietta, GA 30062, USA

Eastern Surgical Associates and Consultants,
2795 Peachtree Rd, Suite 2008,
Atlanta, GA 30303, USA

Department of Oral and Maxillofacial Surgery,
Georgia Health Sciences University,
Augusta, GA, USA

Department of Surgery, Emory University,
School of Medicine,
Atlanta, GA, USA
e-mail: sbagher@hotmail.com

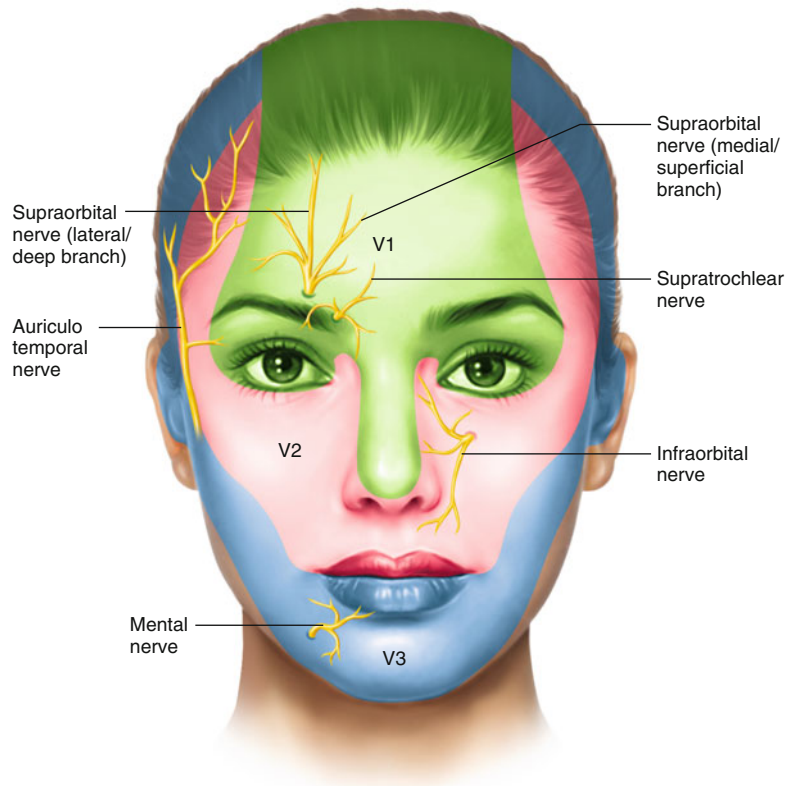
branches of the three major divisions of the fifth cranial (trigeminal) nerve (TN5), the main sensory innervation to several important structures in the head and neck. Despite detailed knowledge of the regional anatomy and the application of skillful surgical technique, injuries to the TN5 are not always avoidable [79]. In this chapter, situations in which TN5 injuries are known to occur, the mechanism of injury (if known), the local neuroanatomy, and measures or technical modifications that might reduce the risk of trauma to adjacent TN5 branches will be presented.

3.2 Neuroanatomy

The anatomy of the TN5 is complex, and an additional review will be helpful to clinicians [31, 106, 114]. All three divisions of the TN5 are at risk for injury. Those peripheral branches which are most often involved in cases of nerve injury include the supraorbital nerve (SON) and the supratrochlear nerve (STN) from the ophthalmic (first, V1) division of TN5, the infraorbital nerve (IFN) from the maxillary (second, V2) division, and the inferior alveolar (IAN), lingual (LN), mental (MN), and long buccal (LBN) nerves from the mandibular (third, V3) division (Figs. 3.1 and 3.2).

Rarely do injuries occur to the other branches of the TN5, such as the anterior, middle, and posterior superior alveolar, nasopalatine, and greater palatine nerves of V2 and the mylohyoid, auriculotemporal, and incisive nerves of V3, perhaps because

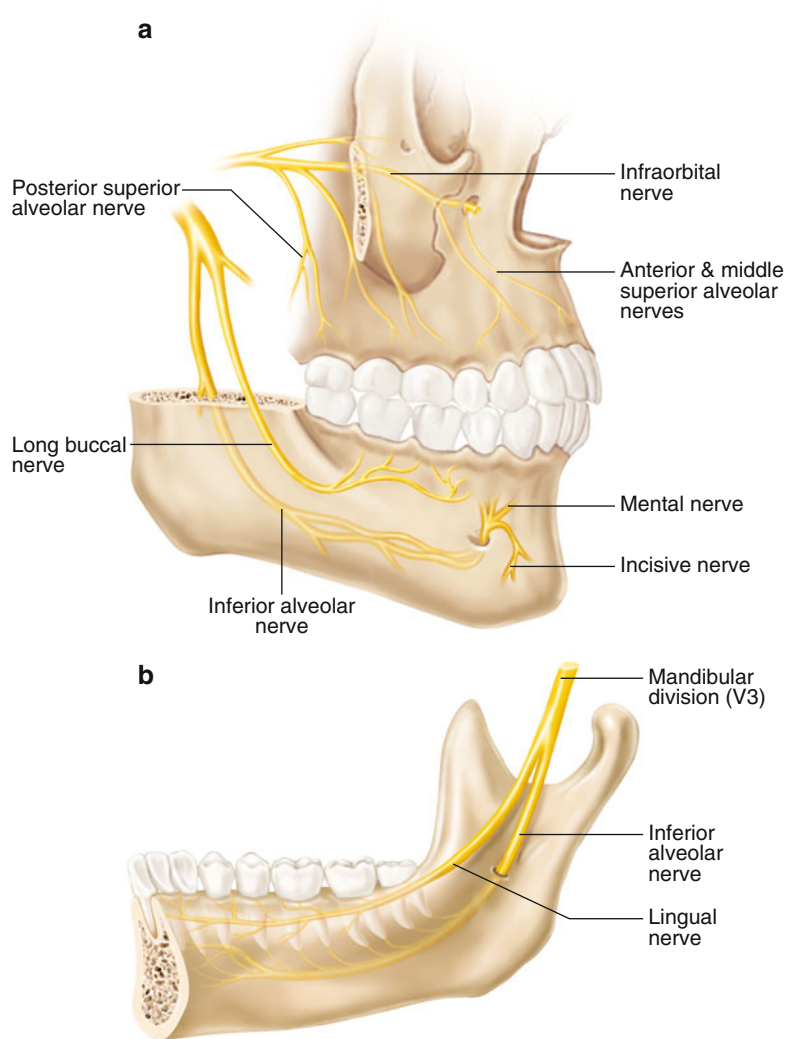
Fig. 3.1 Sensory innervation of the face via branches of the three major divisions of the trigeminal nerve. V1 ophthalmic division, V2 maxillary division, V3 mandibular division



alteration of sensation in the affected areas is not readily perceived by patients and does not seriously interfere with orofacial functions, or merely that the paresthesia resolves rapidly [76]. For example, temporary, but sometimes prolonged, numbness of the palate is common after a LeFort I maxillary osteotomy because of involvement of the nasopalatine and greater palatine nerves. However, it is seldom a long-term patient complaint and does not seem to interfere with speech, mastication, or drinking or swallowing liquids [69]. The buccal and labial gingivae are routinely anesthetic following a LeFort I osteotomy because the terminal fibers of the middle and anterior superior alveolar nerves are severed by the usual circumvestibular incision. Recovery of this sensation occurs within a few weeks or months, and the interval of gingival insensitivity has little or no effect on oral function. The mylohyoid nerve which branches from the IAN in the pterygomandibular fossa provides motor innervation to the mylohyoid muscle and the anterior belly of the digastric muscle. In some patients, it has

a sensory component that supplies a small area of skin in the submental area where loss of sensation is not often perceived by the patient. Likewise, the auriculotemporal nerve (ATN) is frequently injured during temporomandibular joint surgery, parotid gland surgery, or rhytidectomy, but the alteration of sensation in the periauricular region generally resolves within a few months and is seldom a problem for the patient. Occasionally, however, injury to the ATN is associated with the development of Frey's syndrome (gustatory sweating, see Sect. 3.5.7) that can be a significant aggravation for the afflicted patient [132]. Also, the incisive nerve is often intentionally sectioned to allow for maximal lateralization or advancement of the IAN during nerve repair surgery after injury or to allow for lateral repositioning for dental implant placement. The resulting loss of sensation in the mandibular labial gingiva and anterior teeth does not present a problem for most patients, although the lack of tactile proprioception in the incisors may be frustrating for some patients. In addition, however, an amputation

Fig. 3.2 Important sensory branches of the trigeminal nerve in the oral cavity: (a) labio-buccal aspect of maxilla and mandible; (b) lingual area of mandible



neuroma may develop rarely on the proximal stump of a transected incisive nerve possibly leading to painful neuropathies [14].

3.2.1 Supraorbital and Supratrochlear Nerves

The supraorbital nerve (SON) traverses along the superior orbital fissure above the bony orbit and exits through the supraorbital foramen, or notch, in the superior orbital rim of the frontal bone. From this point, the SON and its branches proceed medially, laterally, and cephalad to supply

sensation to the eyebrow, forehead, and anterior scalp. The SON has a “superficial” (lateral) division and a “deep” (medial) division. The superficial division courses superficially over the frontalis muscle and supplies sensation to the skin of the forehead, while the deep division proceeds more cephalad beneath the galea aponeurotica to innervate the frontoparietal region of the scalp [65]. This deep (medial) division has implications in the surgical dissection utilized for a forehead or brow-lift procedure (see Sect. 3.5.9). The supratrochlear nerve (STN) exits from beneath the superior orbital rim about 1 cm medial to the supraorbital foramen and provides branches to

the upper eyelid and lower midportion of the forehead. The patient seldom notices the loss of sensation from the STN alone following forehead injury or surgical procedures.

3.2.2 Infraorbital Nerve

The infraorbital nerve (IFN), the most important branch of V2, traverses the inferior orbital canal below the floor of the orbit and exits via the infraorbital foramen inferior to the inferior orbital rim. From there it divides into several branches as it proceeds peripherally. Its locations within the inferior orbital canal and following its exit from bone make it susceptible to injury from trauma or various surgical procedures. The injured IFN may produce symptomatic neurosensory dysfunction in the upper lip and middle third of the face (see Sects. 3.5.3 and 3.5.4).

3.2.3 Inferior Alveolar Nerve

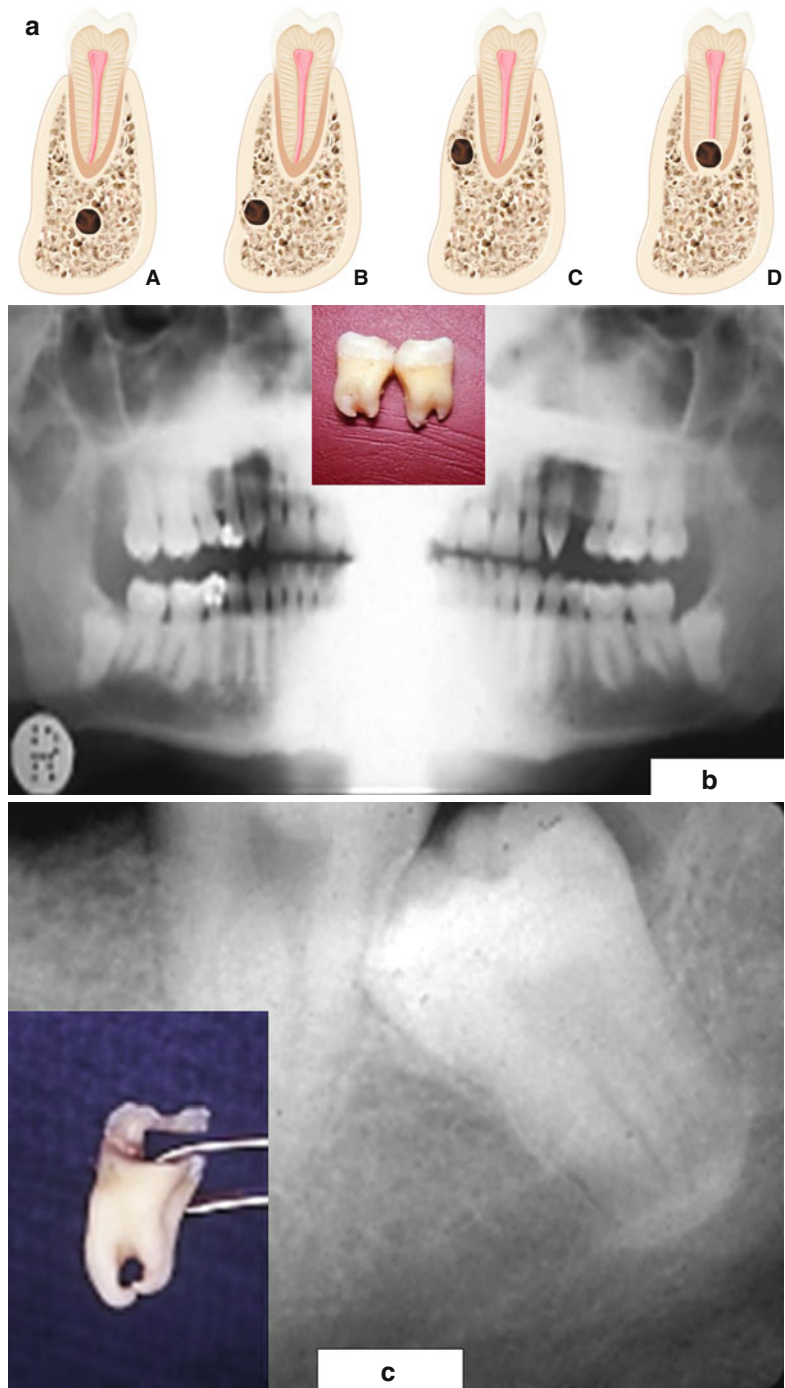
The inferior alveolar nerve (IAN) leaves V3 in the pterygomandibular space and courses anterolaterally to the medial surface of the mandible into which it enters at the mandibular foramen. From here, its location within the inferior alveolar canal (IAC) can be highly variable, superoinferiorly, between the molar and premolar teeth and the mandibular inferior border and, mediolaterally, between the lateral and medial mandibular cortices (Fig. 3.3). Recognition of this variability of position of the IAN is important in planning a surgical procedure for the removal of mandibular third molars (M3s), correction of mandibular developmental deformities with orthognathic surgery, repair of mandibular fractures, placement of dental implants, and endodontic periapical surgery (see Sects. 3.5.2, 3.5.3, 3.5.4, 3.5.5, and 3.5.7). This location can usually be determined from plain radiographs in most patients [39, 56]; however, in those patients who are suspected of having an intimate relationship between the IAN and an approximating tooth, implant, or other object or structure (based upon plain-film assessment), the availability of newer imaging tech-

niques (computed tomography (CT), cone-beam computed tomography (CBCT)) has made possible the precise and accurate determination of the position of the IAN within the mandible (see Chaps. 5 and 11).

3.2.4 Mental Nerve

The mental nerve (MN) arises from the IAN in the inferior alveolar canal in the premolar region. The MN then courses superiorly and posteriorly to exit the lateral surface of the mandible through the mental foramen (MFN), generally located between and slightly inferior to the apices of the mandibular first and second premolar roots. Vertical or horizontal incisions and submucosal dissections in the mandibular buccal vestibule should be performed with great caution in this area. The level of exit of the MN is generally several millimeters superior to the level of the inferior alveolar canal, a relationship that impacts upon the placement of a horizontal osteotomy for mandibular symphysis repositioning or genioplasty (see Sect. 3.5.9). As it exits the MFN, the MN usually divides into three distinct branches that pass inferior, lateral, and anterior (lower labial branches, LLBs) to supply the lower labial mucosa and skin of the lower lip. Occasionally, there is an anatomic variation in which the MN exits the mandible as two separate branches via two bony mental foramina (Fig. 3.4). Knowledge of the position of the LLBs of the MN [1] aids the clinician in determining appropriate incision designs in the lower labial mucosa for various procedures (such as biopsy of minor salivary glands, excision of submucosal masses, and mandibular symphysis procedures) while minimizing the risk of injury to the MN. In general, the LLBs of the MN proceed in an anteromedial direction at an angle of about 36 % to the horizontal plane of the lower lip, so an incision in the lower labial mucosa for removal of a submucosal mass should parallel the direction of these branches. A U-shaped incision with its lateral aspects parallel to the LLBs should be made to expose the mandibular symphysis (Fig. 3.5). When the patient has lost posterior mandibular teeth and there is

Fig. 3.3 Variable locations (left, **a**) of the inferior alveolar canal (IAC) in the mandible molar region (seen in cross section) which can be determined from preoperative imaging studies: (A) the IAC lies several millimeters inferior to the tooth root apex, a favorable position during M3 removal; (B) the IAC, situated inferiorly, is grooving the lateral cortical bone, placing it at risk during the mandibular sagittal split ramus osteotomy (MSSRO); (C) the IAC, located superiorly, again is grooving the lateral cortical bone, placing it at risk when performing the MSSRO or inserting superior border monocortical internal fixation screws; (D) the IAC lies within a groove in the root apex, posing a risk of injury during the removal of the tooth. Bilateral impacted mandibular third molars (M3) in which the roots are straddling the IAC (middle, **b**). An M3 whose roots were perforated by the IAC (right, **c**). The IAN was severed during M3 removal and was later successfully repaired with microsurgery



alveolar bone atrophy in the mandibular body region, the MFN and/or the IAC may be located at, or near, the alveolar crest, placing the MN or the IAN at risk from incisions or other surgical manipulations in this area [55, 77, 78] (Fig. 3.6).

3.2.5 Lingual Nerve

The lingual nerve (LN), after it leaves V3 in the pterygomandibular space, proceeds anteriorly where it assumes a variable relationship to the

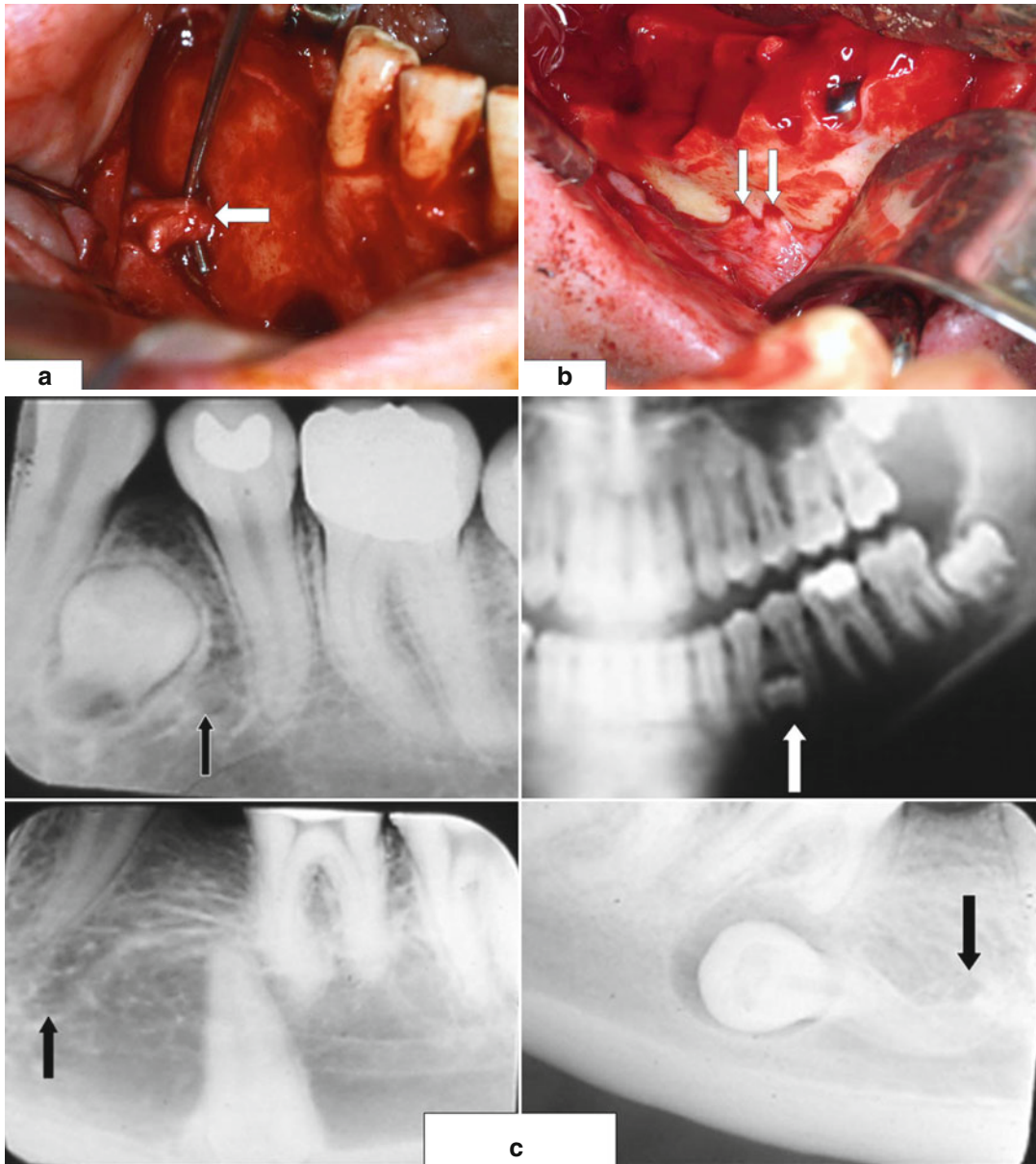


Fig. 3.4 Mental nerve (MN, indicated by *white arrow*) usually (a) exits the buccal surface of the mandible inferior to the root apices of the two premolar teeth; (b) a view of patient with two right mental foramina, each with a

MN; (c) radiographic views of impacted mandibular premolar teeth, each of which is in close proximity to its adjacent mental foramen (*arrows*), posing a risk of MN injury during their removal

medial surface of the mandible in the third molar (M3) area. Cadaveric dissections and clinical experience have shown that the LN in the M3 area may be located in intimate contact with the medial mandibular periosteum at, or above, the level of lingual crest of bone (Fig. 3.7) or one to

several millimeters below the alveolar crest at various distances (from 0 to several millimeters) medial to the lingual mandibular periosteum [20, 63, 86]. It has been noted that these nerve-bone relationships may not necessarily change in patients who subsequently lose their teeth and

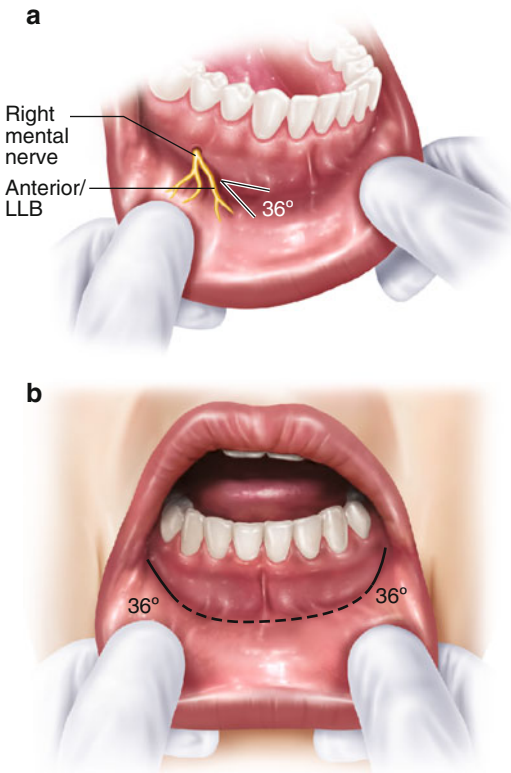


Fig. 3.5 (a) MN gives off its anterior/lower labial branches (LLB) which course anteriorly at an angle of about 36° with the horizontal plane of the lower lip. An incision in this area should parallel the LLB; (b) a labial vestibular incision for access to the mandibular symphysis has its lateral wings (*solid black lines*) parallel to the LLB. Remainder of the incision is a *dotted line*

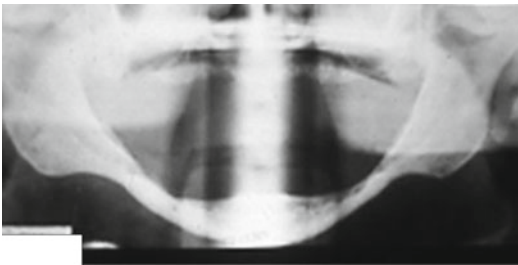


Fig. 3.6 Severe atrophy of the mandible. IAC and MF are at or near the crest of the residual alveolar ridge

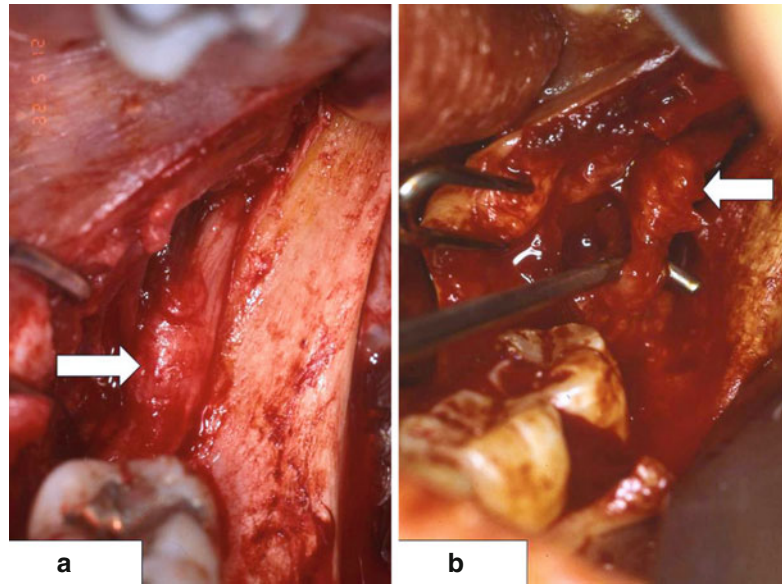
undergo mandibular atrophy [55]. The position of the LN on one side of a bilateral cadaver dissection [103] and as seen in clinical experience is not a reliable predictor of its position on the contralateral side. The frequently noted intimacy of

the LN and the mandible in the third molar region increases the risk of LN injury from removal of M3s or other surgical procedures in the retromolar pad area (see Sects. 3.5.2, 3.5.3, 3.5.4, and 3.5.5). As the LN courses anteriorly from the M3 region, it again may assume a variable relationship with the submandibular salivary duct and the submandibular salivary gland. In some patients, the LN runs medially inferior to the submandibular duct and then into the floor of the mouth and tongue musculature. In other patients, the LN runs through or inferior to the submandibular gland to reach the body of the tongue muscle [88, 89]. In these latter two relationships, the LN might be in jeopardy during surgical procedures of the sublingual salivary gland, submandibular gland, or Wharton's duct. As the LN proceeds anteriorly from the M3 area and into the floor of the mouth, it assumes a more tortuous course. This has implications for the surgical repair of LN injuries in that dissection and mobilization of the distal portion of a severed nerve often allows it to be advanced without tension to approximation with the proximal nerve stump. The nerve gap is eliminated and a direct neuroorrhaphy, rather than an indirect reconstruction with a nerve graft or conduit, may be performed [12, 13].

3.2.6 Long Buccal Nerve

The long buccal nerve (LBN) leaves V3 in the pterygomandibular space and crosses lateroinferiorly in a supraperiosteal location over the deepest concavity of the external oblique ridge of the mandibular ramus, or up to 12 mm inferior to this point. There the LBN may separate into several smaller branches or continue as a single structure into the mandibular buccal vestibule in the molar area where it then sends multiple smaller branches medially, laterally, and anteriorly to supply the buccal molar gingiva, buccal mucosa, and mandibular vestibule, respectively [52]. While the main trunk of the LBN as it crosses the external oblique ridge is often 1 mm in diameter, it is seldom noted in surgical dissections in the retromolar pad or vestibule of the posterior mandible unless it is the subject of exploration

Fig. 3.7 (a) Intact left lingual nerve (LN, *arrow*), exposed during a mandibular ramus surgical procedure, is located at level of alveolar crest in mandibular retromolar area; (b) left LN injured during mandibular third molar removal several months previously has developed a neuroma-incontinuity (*arrow*)



and repair. When the LBN crosses below the greatest concavity of the external oblique ridge, it may be at risk of injury from incisions in the posterior mandibular buccal vestibule, such as those performed for M3 removal, mandibular ramus osteotomies, or open reduction of posterior mandibular body, angle, ramus, or condylar fractures. In the majority of patients, transection of the main trunk of the LBN, or one or more of its branches, is associated with little, if any, perceived sensory aberration [76], possibly due to a high mechanosensory threshold of this nerve [51]. However, in some patients, a LBN injury results in significant sensory dysfunction, especially if a painful neuroma develops on the proximal stump of a severed LBN [11] (Fig. 3.8).

3.3 Types of Nerve Injury

3.3.1 Clinical Categories of Nerve Injury

Clinically, peripheral nerve injuries are divided into two categories: *closed* and *open injuries*. The vast majority of TN5 injuries occurring during elective surgery, except those nerve resections which are planned as part of ablative surgery, are unobserved or are unsuspected by the surgeon at

the time of operation [110]. Only in retrospect, when the patient returns with a complaint of sensory dysfunction, is the diagnosis established and the surgeon obliged to evaluate the situation further. Such an injury, not directly observed by the surgeon at the time of its occurrence, is termed a *closed (or unobserved) injury*. When a nerve injury is noticed at the time of surgery, whether it is produced intentionally, such as during surgical excision of a malignant tumor in which the nerve is involved, or unintentionally, such as during an elective, non-ablative operation, this is called an *open (or observed) injury*. An open injury is documented in the surgeon's notes or operative report, and if the nerve is not to be repaired at the time it occurs, the injured area of the nerve may be tagged with fine, nonabsorbable, nonreactive sutures (such as 8-0 monofilament nylon) to assist the surgeon who does the subsequent microsurgical repair in identifying the proximal and distal nerve stumps.

3.3.2 Mechanisms of Nerve Injury

There are many aspects of surgical manipulation that can lead to TN5 injury (Table 3.1). Some of these might be recognized clinically, if the nerve is exposed, and repaired at that time or within a

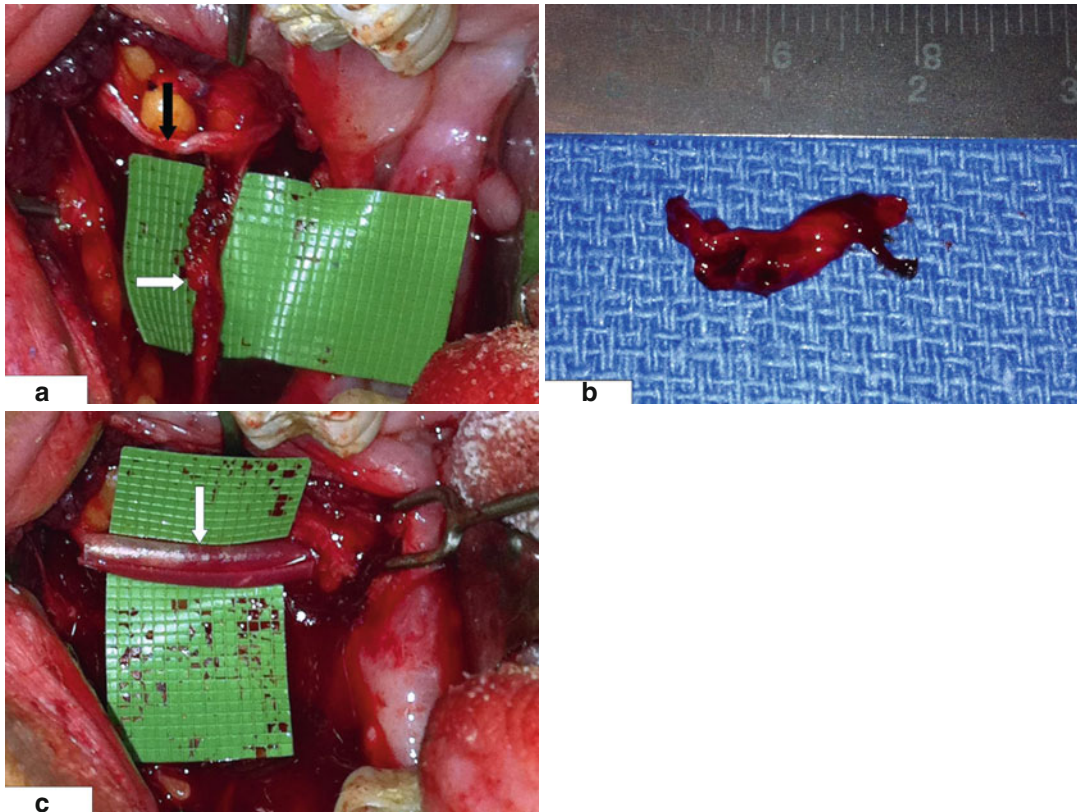


Fig. 3.8 Right long buccal nerve (LBN) is shown, (a) with its normal-appearing main branch (*black arrow*) traversing laterally into the cheek mucosa and an abnormal anterior branch with neuroma (indicated by *white arrow*). The patient developed stimulus-evoked pain in the right

buccal vestibule following removal of the right third molar tooth. The pain resolved (b) after resection of the anterior branch and its neuroma; (c) main branch of the LBN is surrounded by membrane sheath (indicated by *white arrow*) to facilitate healing after resection of anterior branch

short time after injury (as in a delayed primary repair at 3 weeks) [99]. However, within several weeks, the healing process has begun and scar tissue has formed, and although these events may render the surgical repair technically less difficult [79], they alter the appearance of the injured nerve, and frequently make the mechanism of injury difficult to determine clinically or histologically. From direct clinical observation and other considerations [97], it has been proposed that the TN5 may be injured via the following: (1) sharp incision (as from a scalpel or an anesthetic needle) that may cause a partial (one or more fascicles) or total (all fascicles) nerve transection; (2) blunt trauma associated with maxillofacial injuries or from instrumentation such as elevation of a mucoperiosteal flap; (3)

stretching, compression, or laceration from displaced bone fragments in facial bone fractures; (4) manipulations during reduction of fractured bone fragments or osteotomized bone segments that produce nerve compression or crushing; (5) a high-speed rotating bur during bone removal or a slower-speed drill preparing dental implant sites or bone holes for internal fixation screws that causes ragged and irregular nerve shredding; (6) impaling the nerve with an internal fixation screw; (7) prolonged or excessive retraction of the nerve that induces ischemia and a stretching (or neurapraxic) injury; or (8) contact with a toxic root canal medicament or sealer or other chemical medications (such as tetracycline placed into a tooth-extraction socket) that generate a chemical burn of the nerve.

Table 3.1 Etiology of TN5 injuries

| Procedure | Nerves affected | Mechanism of injury |
|--|-------------------|---|
| Local anesthetic injection | IAN, LN | Direct needle trauma Toxic effect of anesthetic Bleeding, hematoma |
| M3 removal | IAN, LN, LBN | Incision Flap retraction Rotating bur, osteotome Compression (bone, root) Suturing Socket medication |
| Orthognathic surgery: Lefort I, MSSRO, MIVRO | IFN, IAN, LN | Drill, osteotome, saw Internal fixation Nerve retraction Nerve compression |
| Maxillofacial trauma: Fracture, laceration, GSW | SON, IFN, IAN, MN | Compression Severance Avulsion Internal fixation |
| Preprosthetic surgery: Ridge augmentation Vestibuloplasty Dental implants | IAN, LN, MN | Chemical burn Compression, suture Compartment syndrome Rotating bur |
| Endodontic treatment: Root canal filling Periapical surgery | IAN, MN | Overinstrumentation Compression Chemical burn |
| Salivary gland surgery: Submandibular, sublingual | LN | Dissection |
| Ablative surgery: Benign cysts/tumors Malignant tumors | IAN, MN, LN | Unintentional injury Intentional nerve resection |
| Cosmetic facial surgery: Genioplasty, facelift, forehead/brow lift | SON, MN, ATN | Dissection Compression Rotating bur, saw |

TN5 trigeminal nerve, *IAN* inferior alveolar nerve, *LN* lingual nerve, *M3* mandibular third molar, *LBN* long buccal nerve, *IFN* infraorbital nerve, *MSSRO* mandibular sagittal split ramus osteotomy, *LeFort I* maxillary horizontal osteotomy, *Fx* fractured facial bone, *SON* supraorbital nerve, *MN* mental nerve, *GSW* gunshot wound/missile injury, *ATN* auriculotemporal nerve

3.4 Incidence of Nerve Injuries

Reliable statistics about the frequency of TN5 injuries are hard to obtain since so much of the activity (dental treatment, intraoral surgery, and cosmetic procedures) associated with these injuries is performed in private practice offices where either thorough documentation is incomplete or the databases lack the capability for retrieval of pertinent information on nerve-injured patients.

Even in hospitals, recognition of the event of a nerve injury may not take place until after the patient has been discharged, rendering a retrospective database search futile or misleading in many cases, even with the most sophisticated electronic medical record computer systems; without the data input, there can be no data retrieval. In the absence of national or international registries for the accumulation of nerve injury data, most of the current information concerning the causes and frequency of TN5 injuries has come from group

Table 3.2 Incidence of TN5 injury based on procedure

| Procedure | Posttraumatic NSD ^a (%) | Postoperative NSD ^b (%) | Permanent NSD ^c (%) ^d |
|----------------------------|------------------------------------|------------------------------------|---|
| Local anesthetic injection | N/A ^e | 0.0033–3.3 | 0.54 |
| M3 removal | N/A ^e | 0.10–0.40 | 0.001–0.040 |
| Genioplasty | N/A ^e | 100 | 3.33–10.0 |
| Mandibular SSRO | N/A ^e | 63.3–83.0 | 12.8–39.0 |
| SSRO+ genioplasty | N/A ^e | 100 | 66.6 |
| Mandibular IVRO | N/A ^e | 18.0 | 0.01 |
| Mandibular DO | N/A ^e | 46.7 | <5.0 |
| Mandible fracture | 46.0–58.5 | 76.1–91.3 | 38.8 |
| ZMC fracture | 52.0–100 | 7.7–55.0 | 37.0 |
| Mandibular vestibuloplasty | N/A ^e | 100 | 50–100 |
| Dental implant | N/A ^e | 1.7–43.5 | 0–15 |

TN5 trigeminal nerve, M3 mandibular third molar tooth, SSRO sagittal split ramus osteotomy, IVRO intraoral vertical ramus osteotomy, DO distraction osteogenesis

^aParesthesia of TN5 branch present after injury, but before surgical intervention

^bPostoperative sensory dysfunction=paresthesia present after operation that resolves by 3 months post-injury and/or is acceptable to the patient

^cPermanent sensory dysfunction=sensory aberration (moderate hypoesthesia to anesthesia ± hyperesthesia) that persists beyond 3 months post-injury. This may or may not be acceptable to the patient and require surgical intervention

^dPermanent sensory dysfunction may be better tolerated by patient when this was either an expected sequel as disclosed during the preoperative consent process or due to a traumatic injury in which the patient's expectations for sensory recovery were modest or had low priority when there were coexisting life-threatening injuries

^eN/A=applies only to mandibular fracture and ZMC complex fracture

surveys, reports of individual experience in the performance of certain procedures, or retrospective or prospective case reports or case series of the results of microsurgical repair of TN5 injuries in the literature. There is little doubt that the incidence of TN5 injuries from all etiologies, but especially those resulting from local anesthetic injections, is underreported [100]. This information is summarized in Table 3.2, and it is discussed further below in relation to the individual causes or mechanisms of TN5 injuries.

Perhaps of equal importance to the “clinical outcome” of peripheral TN5 injuries is the patient's perception of his or her neurosensory status and their ability to carry out the usual oral and facial functions that depend upon sensory input. Some patients who achieve a level of “functional sensory recovery” based upon clinical testing may still continue to experience adverse symptoms or interference with function and activities of daily living, while others will tolerate compromised oral or facial sensation without significant difficulty. In general, however, most patients who experience greater neurosensory improvement after surgical repair of TN5 injuries report lower frequencies of related oral/

facial dysfunction [119]. Assessment of the degree of recovery of sensory function and its long-term effects on quality of life (i.e., “patient-centered research”) deserve more attention of clinicians and researchers, since the care of the nerve-injured patient [68, 105] and, indeed, all types of patients [16] will continue to evolve in the future.

3.5 Causes of Nerve Injury

3.5.1 Local Anesthetic Injections

Injection of local anesthetics for dental treatment or oral and maxillofacial surgery is by far the procedure most frequently performed in proximity to peripheral branches of the TN5. It is estimated that the average general dental practitioner administers between 3 and 10 mandibular nerve blocks per day, or 20–25 per week, and he/she sees some type of IAN or LN involvement (either paresthesia at the time of the injection and/or subsequent sensory dysfunction) as a result of the injection about once every 2–8 weeks. This data would imply an incidence of nerve injury of between 1:30 (3.3 %)

and 1:300 (0.003 %) [47, 100] (Table 3.2). Given that it is essentially a blind (albeit trained and practiced) maneuver within the pterygomandibular space, it seems curious that the incidence of injection-associated IAN and LN injuries is not greater. Is this a case of underreporting or a testament to the skill of the average dentist or merely luck? Of course, the goal of the injection is to deposit the anesthetic solution *in close proximity* to the nerves being anesthetized and to avoid actual contact with the nerve. If this is achieved and apparently it is in the vast majority of injections, then the happenstance of needle contact with the nerve and the possible sudden dysesthesia (“electric shock,” the possibility of which is always a patient’s fear) is avoided in most cases, or it may be that contact between the needle and the nerve may not result in any significant neurosensory dysfunction. The dysesthesia resulting from needle contact with the nerve is not a reliable indicator of subsequent significant, prolonged or permanent, sensory dysfunction, however. “Needle shock” does not always occur in patients who subsequently fail to regain sensation in the usual time frame, and in many patients who experience the sudden pain of needle to nerve contact, there is no subsequent sensory dysfunction [100]. In those patients who are under intravenous sedation or general anesthesia before the injection of local anesthetic is performed, there will be no recollection of needle contact with the nerve [82].

There are three proposed mechanisms of nerve injury resulting from a local anesthetic injection [101]. These include the following: (1) *direct trauma*, the needle may pierce the nerve, injuring one or more fascicles, and (2) *chemical toxicity*, the anesthetic solution may have a neurotoxic effect. All local anesthetic solutions have to meet FDA specifications and are thought to be nontoxic in the concentrations used to produce local anesthesia in human patients. Recently, however, mention has been made of the potential toxicity of a 4 % solution of articaine hydrochloride when used for local anesthetic nerve blocks for dental procedures [54] (see Chap. 5 on Injection Injuries). Also, there is the possibility that a cartridge containing any of the commonly used local anesthetics (i.e., lidocaine, mepivacaine, bupivacaine) could have a leak, and

when placed into storage in a sterilizing solution (alcohol or other chemical that is neurotoxic), that cartridge might become contaminated. Upon injection of the contents of the cartridge to produce local anesthesia, the toxic sterilizing solution could be carried into contact with the nerve. The use of a disclosing agent (such as methylene blue) in the sterilizing solutions where anesthetic cartridges are stored in professional offices and clinics could eliminate this iatrogenic nerve injury; (3) *bleeding and hematoma formation*: the injection needle pierces or tears a blood vessel in the mesoneurium or epineurium of the nerve, causing localized bleeding and formation of a hematoma around or within the internal structure of the nerve thereby producing a compression effect on the nerve. In some patients, the hematoma is rapidly resorbed, and any effect on sensory function is transient. In others, the hematoma organizes and is replaced by scar tissue that exerts a continued compression on the nerve, and neurosensory dysfunction persists. Which specific one of these effects, a combination of several effects, or other mechanisms as yet unknown occurs in a given patient remains an unresolved question at this time [100].

Following a protocol for the administration and documentation of local anesthetic injections might minimize the risk of nerve injury and provide an impetus for proper follow-up evaluation, which increases the likelihood that a nerve injury is recognized and that rapport with the patient is maintained [82]. When the patient is fully conscious, the clinician proceeds to insert the local anesthetic needle into the proper location (i.e., pterygomandibular space). In the absence of the patient’s complaint of sudden pain or shocking sensation (dysesthesia, which may radiate to the lower teeth, lower lip, mandible, or tongue), the syringe is aspirated. If the aspirate is free of blood, the local anesthetic is administered with the needle position unchanged. If there is a bloody aspirate, the needle is withdrawn 2–3 mm and aspiration is repeated. If the aspirate is then clear, the local anesthetic is injected with the needle in the new position. If the patient complains of sudden pain or shocking sensation, the needle is withdrawn 2–3 mm. Following a clear aspiration, the anesthetic is injected in this new position. If

there is either a bloody aspirate or a dysesthesia associated with the injection, the incident is noted in the patient's record, and a follow-up evaluation of sensory function is done at the patient's next visit (see Chap. 10). When the patient is under general anesthesia or intravenous sedation, the patient will not be able to react to a dysesthesia. Therefore, aspirate before injecting and proceed as described above.

While the IAN and the LN are the TN5 nerves most frequently injured by local anesthetic injections [101, 102], injuries to other branches including the LBN, nasopalatine, mental, and IFN have been seen by the authors.

For further discussion of this topic, the reader is referred to Chap. 4.

3.5.2 Mandibular Third Molar Removal

Removal of third molar teeth is the most frequently performed surgical procedure in oral surgery practice [95]. It has been estimated that some oral and maxillofacial surgeons (OMFS) remove as many as 25 or more M3s per week in their office practices. During the latter half of the twentieth century, a number of reports (from Europe, the United Kingdom, New Zealand, and the United States) indicated that an injury to the IAN or LN during M3 removal occurred in 1.0–6.0 % of patients, with 0.1–1.0 % of these injuries failing to resolve within a few months and becoming permanent in the absence of surgical intervention [3, 23, 24, 27, 46, 53, 64, 129].

More recently, a prospective study conducted by the American Association of Oral and Maxillofacial Surgeons (AAOMS) of a selected group of 63 American oral and maxillofacial surgeons who removed 8,333 M3s from 3,760 patients over a 1-year period (January–December 2001) found an incidence of IAN injury of 1.1 % on the left side versus 1.7 % on the right side, while the LN was involved in 0.3 % (equal on both sides). These figures were for the immediate postoperative period only, so there was no indication of whether any of these injuries failed to resolve spontaneously [49]. A retrospective sur-

vey of California OMFS showed that in 95 % of practices surveyed ($n=535$), over a 1-year period, 94.5 % experienced one or more IAN injuries, and 53 % had one or more LN injuries. Over their practice lifetimes, 78 % of these OMFS reported one or more cases of “permanent” IAN injury, while 46 % indicated one or more instances of “permanent” LN injury. The mean rate for any IAN involvement (temporary or prolonged) was 4/1,000 (0.4 %), and the permanent IAN injury mean rate was 0.4/1,000 (0.04 %). For the LN, the mean rate for any involvement was 1/1,000 (0.1 %), while that of permanent LN injury was 0.1/10,000 (0.01 %). In most cases of IAN injury, the surgeon was aware of the cause of the injury, probably due to the surgeon's knowledge of the relationship of the M3 to the inferior alveolar canal as seen on the preoperative panoramic radiograph. However, in most LN injuries, the surgeon did not know the cause, which may be because the LN was not imaged preoperatively and not directly visualized during the procedure. Nerve injury rates varied inversely with the numbers of M3s removed per year by each surgeon and his/her total years of surgical practice, emphasizing the importance of experience in the reduction of M3 surgical complications [110].

Removal of an impacted mandibular third molar (M3) presents unique surgical requirements, especially with regard to avoidance of nerve injuries. Even in an operation that is conducted according to the existing standards of care by a well-trained and experienced OMFS, it is accepted and expected that complications may occur. Mechanisms of TN5 injury while removing M3s can occur during local anesthetic injection (see above), incision placement, soft tissue flap retraction, removal of bone, sectioning of teeth, elevation of teeth, suturing, and placement of socket medications. Delayed injury of the IAN may occur when the IAC is disrupted during M3 root elevation or removal [25]. During the osseous healing process, bone proliferation may have the effect of narrowing the diameter of the IAC and compressing the IAN, a “closed box” effect similar to the sequelae of increased intracranial pressure on the intracranial contents as a result of a closed head injury. Discussed below are

suggestions for minimizing the risk of TN5 nerve injury during the removal of M3s.

Imaging studies are indispensable in the pre-operative planning for M3 removal. An acceptable radiograph displays the entire tooth, the surrounding alveolar bone, the periapical area, and the inferior alveolar canal (IAC). A plain panoramic view is most often the basic imaging study for M3 evaluation. Although the depth of the tooth within the mandible (soft tissue, partial bone, or complete bone impaction) and the angulation of the tooth (vertical, horizontal, mesioangular, distoangular) are certainly important to the surgeon, perhaps most critical to the prevention of IAN injury is the relationship of the M3 roots to the IAC [56]. Several conditions seen on a plain films may indicate the likelihood of exposure of the IAN during M3 removal including (1) darkening (decreased radiodensity) of the tooth root where it is crossed by the IAC, (2) narrowing of the IAC where it crosses the M3 root, (3) interruption of the white lines (cortical walls) of the IAC, (4) diversion of the IAC, and (5) narrowing of the M3 roots [115]. When a plain radiograph suggests a possible intimate relationship between an M3 and the IAC, this situation may be clarified with advanced radiographic technology [118]. Computed tomography (CT) provides a three-dimensional view of soft tissue and bony anatomy. Although the CT scan was available only in the hospital setting, the introduction (in the 1990s) of cone-beam computed tomography (CBCT) brought this important imaging technology to office surgical practice. In the evaluation and treatment planning for M3 removal, CBCT is invaluable in determining the relationship of M3 roots to the IAC [109]. For more information on this topic, see Chap. 5.

The *location* of the *soft tissue incision* is important in avoiding injury to the LN. The posterolateral extension of the buccal incision from the mesiobuccal corner of the mandibular second molar often encounters the LBN, but injury to this nerve is only rarely symptomatic. Far more important is that the incision is not carried directly posteriorly or even posteromedially where it may cross the path of the LN, which may be located in the soft tissues overlying the impacted M3 [63].

Soft tissue flap retraction, while allowing access and visualization of the operative site, also provides protection to important neighboring structures such as the LN. Lingual flap retraction, a mainstay of the split-bone technique for M3 removal [111], might be followed by a temporary paresthesia due to mild compression of the LN, but the incidence of permanent paresthesia is not increased [94]. The LN retracting instrument protects the nerve from more severe, possibly permanent, injury in case an errant osteotome, elevator, or high-speed rotating bur penetrates the lingual cortical bone [43].

Removing soft tissue pathology from around the crown of an M3 (e.g., granulation tissue, enlarged follicular sac, dentigerous cyst) should be performed with care. If the lingual bone has been eroded or perforated, the pathologic tissue, mandibular lingual periosteum, and LN may be adherent to one another and inadvertently removed en masse, causing an avulsion injury to the LN. Periapical pathology may be located adjacent to the IAC, and curettage of the socket should be performed gently to avoid encroachment on the IAC.

During *removal of bone* or *sectioning of the tooth*, great care is taken regarding the positions of the LN and the IAN [56, 76]. Placement of a lingual retractor (see above) protects the LN if it is necessary to remove lingual bone with the high-speed drill or osteotomes in order to expose, section, or deliver the M3 [108]. When sectioning the tooth with the high-speed drill, the rotating bur should section only three-fourths of the way through the M3, thus avoiding direct trauma to an adjacent LN or IAN. Completion of the separation of the tooth fragments is performed with an elevator. Vectors of force created when *elevating teeth* should be appreciated; for example, upward and posterior elevation of the crown of a mesioangular M3 may cause a reciprocal antero-inferior rotation of the root apex and possibly adjacent bone into the IAC, causing compression of the IAN, and this would be a situation that would undoubtedly go unnoticed during the procedure. Application of excessive force during tooth elevation, especially in a patient with extensive bone resorption, or where a large amount of

bone has been removed to expose the tooth, may cause a fracture of the mandible, and fracture displacement may cause significant IAN injury.

Partial odontectomy [40] or *coronectomy* [104] can be considered as an alternative treatment to M3 removal in certain instances, including when the roots of an M3 reside in close approximation to the IAC, when there is an atrophic mandible containing a deeply impacted M3 and there is risk of pathologic fracture of the mandible, and in cases of advanced patient age. After the crown of the tooth is removed, the roots are left in situ. Subsequent development of infection or other complications such as root migration or even IAN paresthesia may occur rarely. The root migration in an occlusal direction in some patients away from the IAC may allow their subsequent removal with less chance of IAN involvement.

In general, if either the LN or the IAC contents were directly visualized during M3 removal, it is not advisable to *medicate the socket* with antibiotics (cones, powder, etc.) at the conclusion of the operation or to place analgesic liquids or pastes into the socket afflicted with alveolar osteitis several days following the extraction. If such substances (e.g., eugenol, tetracycline, Surgicel) come into direct contact with the LN or IAN, they have the potential to cause a chemical burn with long-term paresthesia, including unpleasant dysesthesia [33].

When lingual bone in the M3 area has been eroded by pathology, fractured off during removal of an ankylosed tooth, or removed surgically with a bur or osteotome, the LN may be exposed and vulnerable during *suturing* of the lingual soft tissue flap. This may cause a compressive injury to the LN, but long-term paresthesia is unlikely via this mechanism of injury.

For further discussion, the reader is referred to Chap. 5.

3.5.3 Orthognathic Surgery

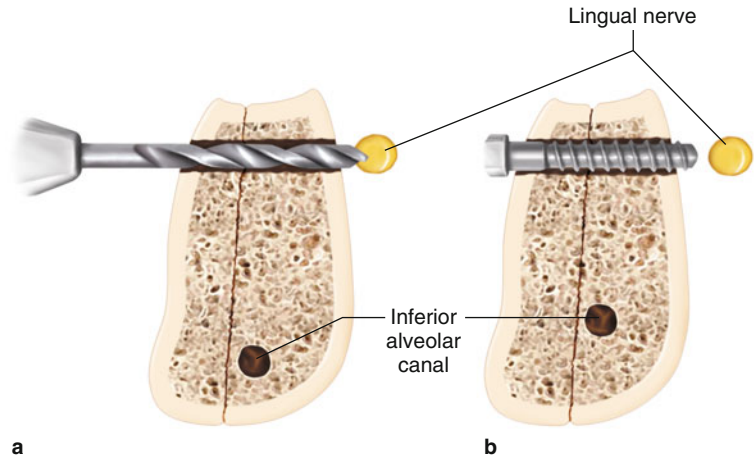
The most common surgical procedures to correct developmental facial deformities associated with dental malocclusions in the upper jaw are the

LeFort osteotomies (LeFort I, or horizontal maxillary osteotomy; LeFort II, or pyramidal osteotomy; and LeFort III, or transverse facial osteotomy) and, in the lower jaw, the mandibular sagittal split ramus osteotomy (MSSRO), the mandibular intraoral vertical ramus osteotomy (MIVRO), and mandibular distraction osteogenesis (MDO). Of these, the LeFort I and MSSRO pose the greatest risk of significant TN5 injury (to the IFN in the maxilla and to the IAN in the mandible) [38].

Injury to the IAN during MSSRO has been studied extensively [32], and it is well known that sensory dysfunction of the IAN following MSSRO is nearly universal (~100 %) among patients in the immediate postoperative period, being reported in 63.3–83.0 % of patients. When patients are followed for more than 1 year, the incidence of prolonged or permanent IAN injury varies from 12.8 to 39.0 %. In both the immediate postoperative evaluation and in the longer follow-up periods, both objective and subjective methods of sensory assessment were used; however, following MSSRO many patients are satisfied with their neurological status and do not request further treatment for residual IAN sensory dysfunction [41, 133]. See Table 3.2. Factors which have been found to increase the risk of IAN injury during MRSSO include the *position of the IAC* [131], especially when it is located just medial to or within the lateral cortical plate of the mandible [130, 134]; *patient age*, especially greater than 40 years [2, 5]; *type of fixation*, whether wire osteosynthesis or mono- or bicortical screws [42, 70, 80]; *magnitude of mandibular advancement*, and whether or not there was *manipulation of the IAN* [133], whether an *additional osteotomy* (such as for genioplasty) was performed [124], and also the *duration of the operation* [120].

The MSSRO is a technically demanding surgical procedure, and although the steps, techniques, instruments, and internal fixation systems utilized may differ among surgeons and are influenced by anatomic variations among patients, the following suggestions for modifications are intended to reduce, in so far as is reasonable, the risk of injury to the IAN [13, 83]: (1) Determine the exact location of the IAN preoperatively by appropriate

Fig. 3.9 Possible mechanisms of LN injury while placing internal fixation during a MSSRO: (a) allowing rotating drill bit to extend medially beyond cortical bone; (b) excessively long screw penetrates LN



imaging studies; (2) identify and protect the IAN with suitable retractors in the pterygomandibular space and where it enters the medial surface of the mandible at the mandibular foramen before proceeding with the horizontal osteotomy; (3) extend the vertical anterior osteotomy *just barely* through the buccal mandibular cortical bone, using a light touch with the bur or saw, as the IAN may rest just medial to the cortex; (4) begin initial separation of the osteotomy segments with anteroinferior and superior border “spreaders” until the IAN can be visualized within the separation. If necessary, when the IAN is found to be in the proximal (posterior, condyle-containing) mandibular segment, it is carefully dissected free (under magnification, as needed). After the IAN is safely contained or repositioned into the distal (anterior, tooth-bearing) mandibular segment and protected with a retractor, osteotomes can be placed to complete the osteotomy and mobilize the segments; (5) irregular bone is removed from the medial surface of the proximal segment with rasps, files, or rotating burs to provide room for the IAN and prevent its compression when the two mandibular segments are fixated together. If additional room for the IAN is needed, bone grafts (autogenous or allogeneic) are inserted between the two segments before clamping them together and placing internal fixation; (6) bicortical fixation screws are placed only through the superior aspect of the mandible, above the level of the IAC and posterior to the last tooth. Although more stable than the linear configuration of three bicortical screws at the superior border, the L

configuration of bicortical screws with two at the superior border and one near the inferior border places the IAN at risk for iatrogenic injury. If preferred, monocortical screws of no longer than 5 mm are used with monocortical plates to avoid entering the IAC. A fine tactile sense is required when drilling monocortical holes so that it can be immediately appreciated when the drill has completely penetrated through the cortical bone and drilling can be terminated.

Less common is the risk of iatrogenic injury to the LN during MSSRO [60]. The LN, as it lies adjacent to the superior border of the mandible in the retromolar area (see above, Fig. 3.7), is susceptible to injury with the incision, retraction of the lingual soft tissue flap, or placement of internal fixation. This situation can be alleviated with careful attention to surgical technique [12, 77]. First, the incision is not carried to the lingual aspect of the retromolar area. Dissection and retraction of the lingual mandibular periosteum are done carefully with blunt instruments. During placement of drill holes for bicortical superior border internal fixation, either the lingual flap (containing the underlying LN) is protected with a suitable retractor (Henahan or Freer, if access allows) or the drill is not allowed to penetrate medially beyond the mandibular lingual cortical bone. A light touch and manual tactile sense are indispensable in this regard. When bicortical screws are inserted, the appropriate length is chosen to prevent “skewering” of the LN by an overly long screw (Fig. 3.9).

The MIVRO is associated with sensory dysfunction of the IAN in up to 18.0 % of patients in the early postoperative period. Long-term follow-up shows that permanent sensory aberration is extremely rare (0.01 %) [61, 135]. The key consideration in reducing risk of IAN is placement of the vertical osteotomy posterior to the location of the IAN as it enters the IAC at the mandibular foramen. This relationship can be easily determined from preoperative imaging studies [6]. At surgery, a vertical osteotomy placed 5 mm posterior to the antilingula on the lateral surface of the mandibular ramus should avoid injury to the underlying neurovascular bundle [7], although the validity of using the antilingula to determine the location of lingual has been questioned in anatomic studies.

The incidence of long-standing or permanent dysfunction of the IAN as a result of mandibular distraction osteogenesis (MDO) is small [71, 125, 127]. Distraction at a rate of no greater than 1 mm/day is tolerated well by the IAN [57]. Temporary paresthesia is expected in a majority of patients in the early postoperative period during the distraction phase that places gentle intermittent traction on the nerve. However, if direct trauma to the IAN is avoided during the corticotomy procedure, preparatory through-and-through osteotomy [74], or the sagittal split osteotomy [126] and the IAN is not injured during drilling or placement of monocortical screws for fixation of the distraction device [81], long-term recovery of sensory function is excellent with few, if any, patients experiencing bothersome residual sensory aberrations.

Altered sensory function following the LeFort I maxillary osteotomy in the upper lip, maxillary gingiva and teeth, and palatal mucosa is likely due to the severance of the terminal branches of the superior alveolar nerves with the standard maxillary circumvestibular incision and involvement of the nasopalatine nerve during the down fracture. This sensory dysfunction is common in the early postoperative period, seen in 34 of 62 (54.8 %) patients in two reported studies [61, 113], and persistent altered sensation beyond 3 months was seen in only 1 of these patients (1/62, 1.6 %). Apparently, these minor branches of V2 either heal rapidly, the lost sensation is not readily perceived by the patient, or it does not interfere with

normal oral function. Permanent injury to the IFN itself during maxillary orthognathic procedures is a rare event, easily avoided by protecting the nerve as it exits the infraorbital foramen with a suitable retractor, placing LeFort II osteotomies at a safe distance medial to the infraorbital foramen or inferior orbital canal, and careful drilling and placement of internal fixation screws and plates to avoid IFN encroachment.

The anterior sliding horizontal mandibular osteotomy, employed in chin-reshaping procedures, and implants to augment chin contour place the MN at risk for injury. These genioplasty procedures are discussed under Sect. 3.5.9 below.

For further discussion of this topic, the reader is referred to Chap. 8.

3.5.4 Maxillofacial Trauma

The causes of traumatic injuries to the oral and maxillofacial region include interpersonal violence, motor vehicle accidents (MVA, or road traffic accidents, RTA), missile injuries, military combat, athletic events, and individual accidents. The prevalence of these has varied throughout history with MVA being the current most frequent cause in industrialized western societies [90]. Control of vehicle speed on highways, the installation of air bags, the wearing of seat belts by occupants in automobiles and of helmets by motorcyclists, special types of facial armor on military combatants, and the use of mouth guards and facial protection bars on football and hockey helmets have all had the effect of reducing the incidence of facial injuries in the affected populations. In the past, little attention was given to TN5 injuries that were associated with facial injuries. Emphasis was placed on anatomic reduction and stable fixation of facial bone fractures to reestablish normal facial contour, dental occlusion, and chewing function and on repair of soft tissue injuries with restoration of the integrity of the facial (seventh cranial, FN7) nerve and its control of facial movements and especially eyelid closure. In some cases, of course, in a patient in critical condition with severe multisystem injuries, definitive treatment of severe

maxillofacial injuries was deferred necessarily, while exploration and surgical treatment of primary survey life-threatening intracranial, thoracic, and abdominal injuries were performed. Many of these patients remained unconscious for long periods of time, during which they were unresponsive to sensory testing and of inadequate physical status to tolerate additional surgery on the maxillofacial region.

The mechanisms of injury to the TN5 subjected to trauma include laceration, severance or avulsion from penetrating missiles or weapons, stretching or tearing from fracture displacement, compression or crush from direct contusion of nerve branches within soft tissue (i.e., LN, MN, SON, STN, or extraosseous branches of IFN), or indirect pressure of mobile fracture fragments on nerves contained in bone (i.e., IAN or IFN) (Fig. 3.10). During the healing phase of a fracture that crosses a nerve-containing canal (i.e., IFN or IAN), exuberant bone proliferation in the area might cause a narrowing of the canal diameter producing direct compression of the nerve [25]. Such effect would be seen clinically in a delayed onset (one to several months after the injury) of neurosensory dysfunction (NSD) in the distribution of that nerve. When it occurs, this effect would impact on the incidence of long-term or permanent NSD after treatment of fractures involving the IAN or IFN (see below). The authors, in fact, have seen this effect of delayed onset of NSD in several patients with IFN injuries. In such patients, nondisplaced midfacial fractures that passed through the inferior orbital canal or infraorbital rim and were not surgically treated quickly recovered normal IFN sensation. One or more months later, onset of numbness and/or pain in the IFN distribution caused the patients to seek treatment for this paresthesia.

More recently, improved treatment protocols of trauma centers have greatly enhanced survival potential of the multiply injured patient, and facial repair and reconstruction have become an integral part of the overall treatment [8, 9, 21]. Dedicated research in TN5 injuries and patients' desires to regain control of oral and facial functions dependent on intact sensory input have stimulated OMFS interest in the evaluation and

surgical repair of TN5 injuries associated with maxillofacial trauma [10]. Current information on the incidence of trauma-related injuries of the TN5 comes from a compilation of available studies, many of which are poorly documented and lack standards for nerve evaluation, grading of sensory function, or adequate follow-up periods [121]. Data summarizing TN5 injury incidence are presented in Table 3.2. Collated data from reports of maxillofacial trauma with appropriate information regarding diagnosis, neurosensory testing, and adequate length of follow-up shows that in fractures of the mandibular body and angle that involve the IAN, the incidence of posttraumatic/pre-treatment NSD was 46.0–58.5 %. Risk factors for posttraumatic/pre-treatment NSD included patient age (risk increased with age), gender (females have higher risk), fracture displacement, and missile trauma which frequently causes nerve severance or avulsion. Immediately after these fractures had been reduced and fixated (i.e., post-treatment), this incidence *increased* to a range of 76.1–91.3 %. That the incidence of NSD increased after surgical treatment of the fracture was most likely due to the manipulation required to expose, reduce, and fixate the fracture segments that might cause additional compression or stretching injury to the nerve. This increase was not found with injury to the IFN (see below). Combining the patients from four studies, long-term follow-up found permanent NSD of the IAN in 92 of 237 patients (38.8 %). Factors that increased the incidence of permanent NSD of the IAN after mandibular fracture repair included fracture segment manipulation, open reduction, and internal fixation.

In a 10-year retrospective review from Edinburgh of 2,067 patients with 2,160 zygomaticomaxillary complex (ZMC) fractures, the incidence of NSD in the distribution of the IFN varied from 52 to 80 %, depending upon the type of fracture (nondisplaced, 52 %; blowout of orbital floor, 60 %; orbital rim, 71 %; zygomaticoorbital [ZO] with non-distracted frontozygomatic suture [FZS], 74 %; ZO with distracted FZS, 80 %) [37]. Unfortunately, there was no long-term follow-up to provide information on recovery of IFN function in affected patients.

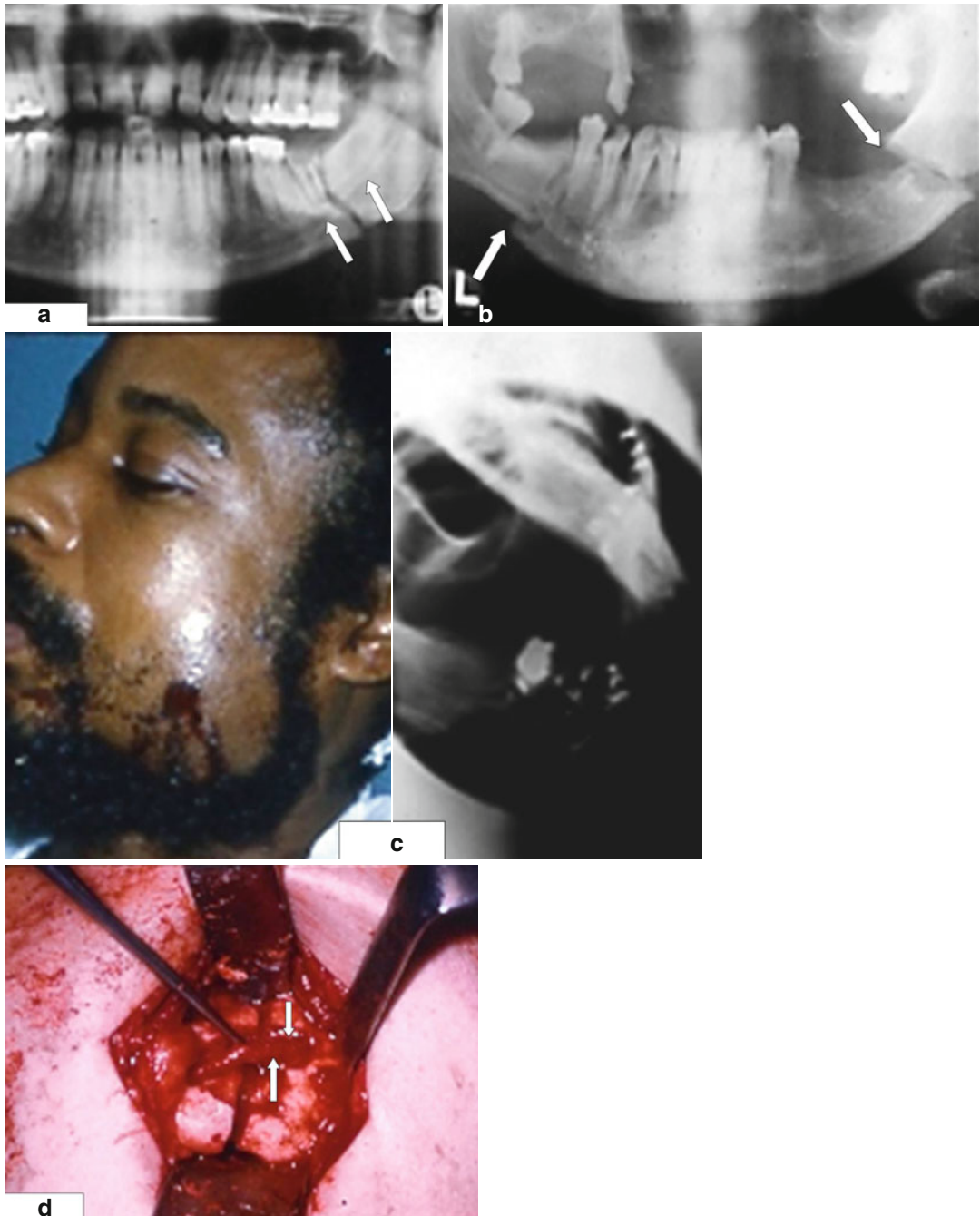
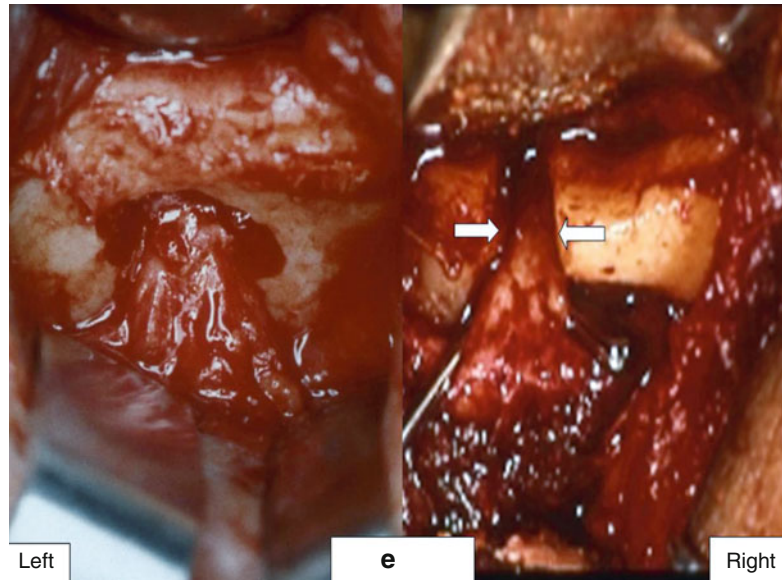


Fig. 3.10 Examples of fractures involving branches of the trigeminal nerve: (a) fracture of posterior body of left mandible has minimum offset of inferior alveolar canal (IAC, *arrows*) and low risk of permanent IAN injury; (b) grossly displaced fractures of right and left mandible through IACs (*arrows*) may cause stretching or severance injury of IAN; (c) gunshot wound of left mandible (*left*) with missile penetration of the IAC resulting in avulsion

of a segment of IAN (*right*); (d) malunion of left mandibular angle fracture treated by osteotomy and decompression of IAN (*arrows*); (e) *left*, healed untreated orbital floor and inferior orbital rim fractures causing entrapment, compression, and scarring of infraorbital nerve (IFN); *right*, infraorbital foramen and inferior orbital canal unroofed (*arrows*) for decompression of IFN

Fig. 3.10 (continued)

Data combined from several studies included 462 patients who had ZMC fractures [121]. In these patients, 65–100 % had posttraumatic/pretreatment NSD of the IFN. After fracture treatment, these numbers had decreased to 7.7–55 %. Long-term follow-up indicated that 171 (37 %) of these 462 patients had permanent NSD of the IFN.

The final outcomes of many of these patients who in the past sustained maxillofacial trauma and were left with permanent NSD of the IAN or ION are certainly less than ideal. The reasons might include needful delay in assessing and treating the facial and associated peripheral nerve injuries because of the priorities in stabilizing the patient and treating life-threatening conditions first, lack of training of surgeons in management of peripheral nerve injuries associated with maxillofacial injuries or lack of ready availability of such expertise locally, or patients' satisfaction with their final status of recovery from what might have been life-threatening injuries. Some surgeons contend that reducing the fracture into anatomic alignment also restored a natural conduit (IAC for the IAN, inferior orbital canal for the IFN) that serves as a guide for nerve regeneration, and this was considered adequate treatment. However, restoration of neurological function has now become a specific treatment goal in the care of patients with maxillofacial fractures, according to AAOMS [48]. More

patients have begun to seek treatment for the residual sensory dysfunction that is often a continuing reminder of their facial injuries, now they are aware that something can be done. A recent retrospective study reviewed 42 patients who had undergone microsurgical repair of TN5 nerves (IAN, 21; MN, 12; IFN, 7; LN and LBN, 1 each) injured as a result of maxillofacial trauma [10]. After a follow-up of at least 1 year, neurosensory testing showed that, according to the Medical Research Council Scale (MRC) [22], 23 nerves (55 %) had regained “useful” sensory function, 13 nerves showed full sensory recovery, and 6 nerves (14 %) showed little or no sign of recovery, for an overall success rate of 86 %. These results compare favorably with those of microsurgical repair of TN5 injuries from other causes [11–14], and they establish this type of microneurosurgical intervention as an acceptable treatment modality in selected patients.

Timing is critical in successful microsurgical repair of all peripheral nerve injuries. In most clinical studies, the best results are achieved when the nerve is repaired within 6 months of injury [10, 12–14, 36, 79, 96, 112, 117, 136]. Although repair of an observed or suspected nerve injury is not routinely delayed that long, there may be valid reasons or extenuating circumstances for postponing nerve repair in a patient who has sustained multiple injuries.

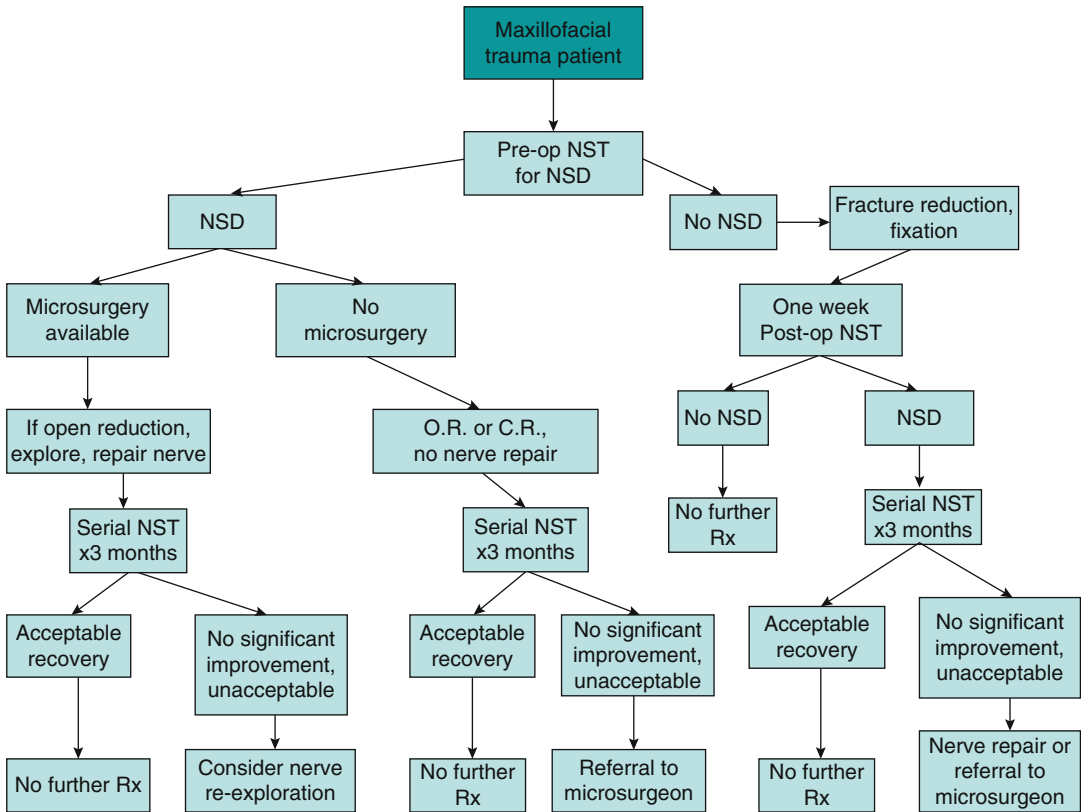


Fig. 3.11 Method of evaluation and treatment for maxillofacial trauma patients with peripheral trigeminal nerve injuries. See text for discussion. *NSD* significant neurosensory deficit (i.e., moderate hypoesthesia to anesthesia),

NST neurosensory testing, including responses to pain, static light touch, and two-point discrimination, *O.R.* open reduction of fracture, *C.R.* closed reduction of fracture, *Rx* treatment

These include (1) gross contamination of the wound (especially prevalent in combat injuries), (2) poor patient physical status due to multiple system injuries making him/her a poor risk for additional anesthesia and surgery after life-threatening conditions are stabilized, and/or (3) the surgeon in charge of management of the maxillofacial injuries does not have microsurgical training or it is not readily available. In such cases, the microneurosurgery is delayed until the wound is free of infection, the patient's physical status has improved, and a surgeon trained in microsurgery becomes available. Such delays are acceptable and usually amount to only days or weeks [79]. Longer delay in repairing nerve injuries may occur if the injury is not suspected or recognized, the patient desires no further treatment for NSD that is judged "acceptable," or the patient is lost to follow-up.

The algorithm shown in Fig. 3.11 will assist the clinician who manages maxillofacial trauma in the evaluation and treatment of associated TN5 injuries. Patients who have sustained maxillofacial injuries and are conscious and able to cooperate should undergo a cranial nerve screening, including neurosensory testing (NST) of the TN5 (see Chap. 10). If *no* NSD of the major branches of the TN5 (IAN, IFN, SON) is found, the facial fractures are reduced and fixated as needed. Follow-up NST is done within 1 week postoperatively. If *no* TN5 NSD is present at 1 week after fracture repair, no additional nerve follow-up is necessary at that time. The patient is advised, however, that if a sensory aberration develops within the next several months, another evaluation is advised *at that time* (see delayed onset of NSD, discussed in this section above). If the patient has significant NSD at 1 week postoperatively,

follow-up NST is done serially for 3 months. If the patient's sensory function has recovered within that time frame, no treatment is needed. If, however, acceptable recovery of NSD has not occurred by 3 months following fracture repair, exploration and microsurgical repair of the injured nerve, or referral to a microsurgeon, should be considered.

If the patient *has* a significant TN5 sensory deficit following his facial injuries, the fractures are repaired. When *microsurgical repair is not readily available*, closed or open reductions of the fractures are performed as indicated. If the surgeon observes a nerve injury (crush, severance, or avulsion) during the fracture repair, the area of the nerve injury should be marked with one or two fine (6-0 or 8-0) nylon sutures, the nerve placed in as normal alignment as possible, and mention made in the operative report of the location and nature of the injury. The patient is followed postoperatively for 3 months with serial NST. If the NSD has resolved or is acceptable to the patient, no further treatment is necessary. If the NSD has not recovered to an acceptable level at 3 months post-injury, the patient is referred to a microsurgeon for further evaluation, and a decision is made regarding the necessity for another operation to repair the nerve. When the patient's maxillofacial fractures are being evaluated and treated by *a surgeon with microsurgical skills*, the fractures are also treated as indicated. If an open reduction is performed, the nerve is exposed, its nerve canal enlarged to compensate for post-injury osseous proliferation, and repaired as indicated. If a closed reduction is performed, the nerve will not be directly observed in most cases. In either situation, this patient is followed with serial NST for 3 months. If the patient has recovered acceptable sensory function, no further treatment is indicated. On the other hand, if the NSD is unacceptable after 3 months, re-exploration of the nerve should be considered. Adherence to these recommendations will more likely afford patients with significant TN5 NSD the greatest likelihood of regaining "useful sensory function" [10, 84].

Methods of fracture repair are modified when they encroach upon adjacent nerves, in order to minimize or avoid iatrogenic injury. Manipulation

for satisfactory reduction of fracture segments should be done carefully to avoid excessive stretching or compression of involved nerves. Decompression by removing adjacent bone or enlarging the nerve canal may prevent a "closed box" phenomenon by creating additional space for temporary posttraumatic/postoperative edema of the nerve. Also, this may compensate for the delayed effect of osseous proliferation and canal narrowing that may occur during postoperative fracture healing (see above). Using monocortical, rather than bicortical, fixation screws and not placing them adjacent to, or into, bony nerve canals are always desirable considerations in fracture management. Internal fixation plates are placed so as not to encroach on nerves exiting from bone (i.e., the SON, IFN, MN). Nerve repair that is not performed at the time of fracture treatment is delayed for 6 weeks (for a ZMC fracture) to 6 weeks (for a mandibular fracture). This amount of time allows the fracture to become clinically stable and the inflammatory response to have resolved. Bleeding is less troublesome, and epineurial tissue will have thickened and lost its friability, making visualization, debridement, and suturing much easier. This time delay allows the zone of neural damage to declare itself so that adequate resection of neuromatous tissue can be performed by visual inspection under magnification. The recovery of neurosensory function will not be compromised by this prudent delay and, in fact, may be improved when compared to recovery after immediate repair [59, 79].

Although the SON and the STN must necessarily be involved when the supraorbital region is injured in military combat and other missile actions, MVA, interpersonal violence, or household accidents, this type of paresthesia has been mentioned rarely in published studies. NSD in the forehead region may be omitted on initial evaluation because of immediate concern for life-threatening injuries, it may resolve spontaneously, the patient may not be afflicted with significant symptoms, and/or the deficit does not interfere with normal facial functions, or it is simply underreported. In any case, SON injuries due to maxillofacial trauma, though seldom reported, do occur (Fig. 3.12).

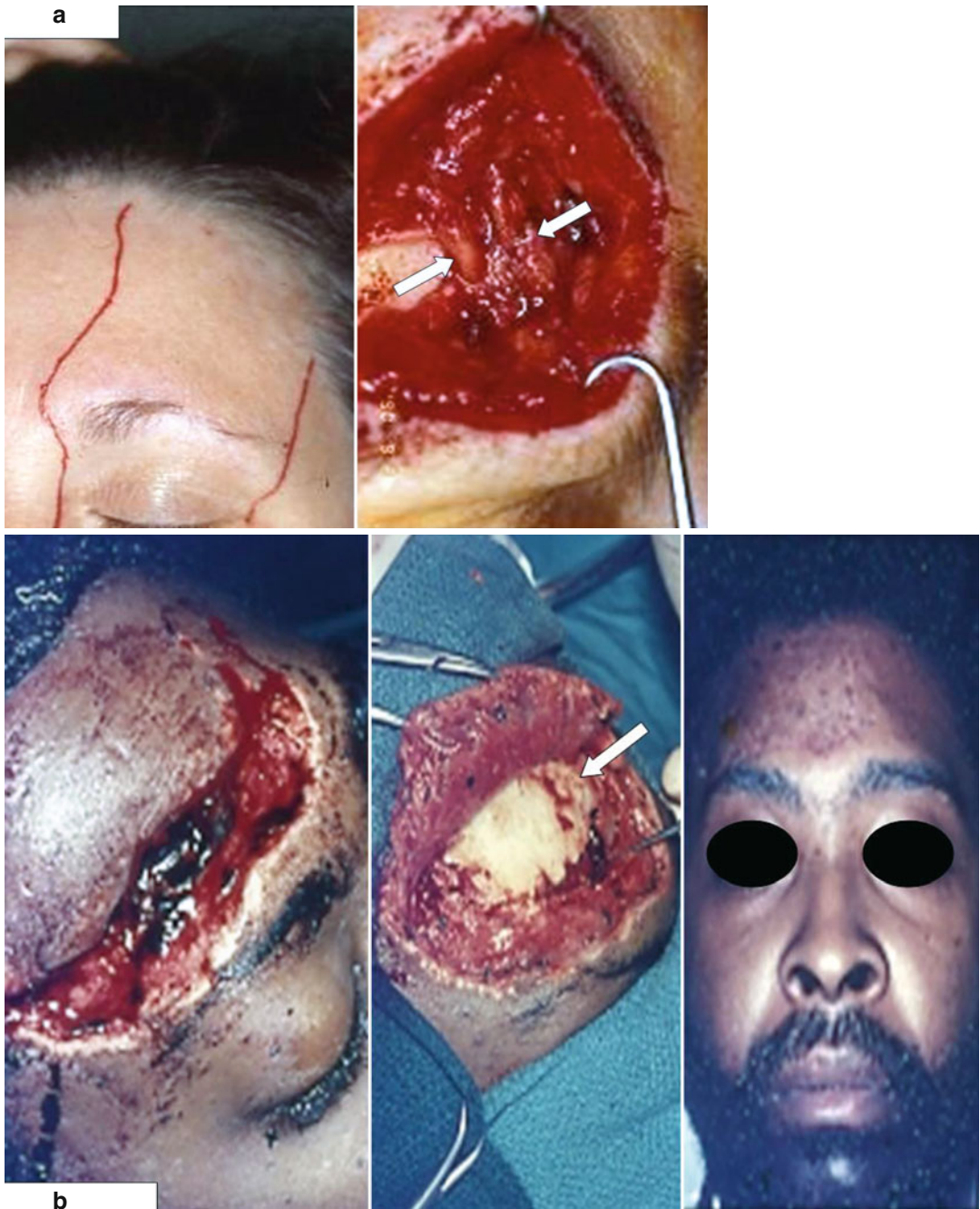

Fig. 3.12 Injuries to supraorbital nerve (SON): (a) patient sustained blunt trauma to left forehead (*left*). She developed pain, numbness, and hyperesthesia in the area outlined. *Right*, exploration revealed injured branches of the left supraorbital nerve, each with a neuroma-in-continuity (*arrows*). Repair was done by excision of neuromas and reconstruction of each branch with autogenous great

auricular nerve graft; (b) unrestrained passenger in motor vehicle accident struck forehead on dashboard. Laceration transected right supraorbital (SON) and supratrochlear (STN) nerves (*left*); depressed frontal fracture (*arrow*) required surgical reduction (*middle*); patient satisfied with postoperative status and refused exploration/repair for SON/STN sensory loss (*right*)

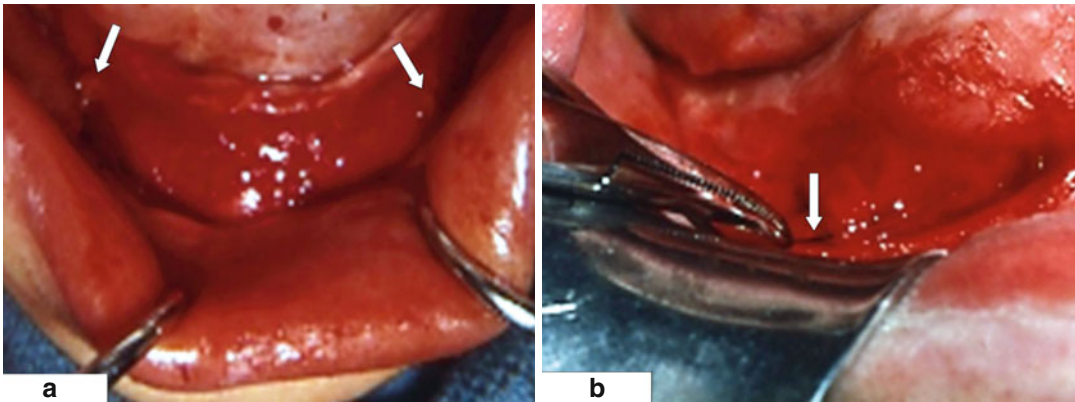


Fig. 3.13 Mandibular vestibuloplasty (MVest): (a) exposure of both mental nerves (MNs) (indicated by *white arrows*) during suprapariosteal dissection prior to placing split-thickness skin graft; (b) patient who developed persistent

numbness after MVest was found on re-exploration to have a retained nylon suture (indicated by *white arrow*) around right MN. Removal of suture was followed by recovery of MN sensation

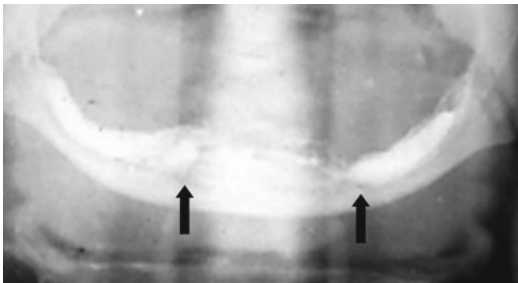


Fig. 3.14 Severely atrophic mandibular ridge was augmented with calcium hydroxyapatite (CHA). CHA was in direct contact with both mental nerves (*arrows*), producing anesthesia and constant pain in MN distribution. Both MNs were explored and found to have pathologic changes consistent with a chemical burn

an osteotomy with placement of a bone graft or alloplastic material, the IAN or MN might be at risk for injury [15]. While calcium hydroxyapatite (CHA) has been placed safely around the MN in ridge augmentation procedures [62], in the senior author's experience, CHA was found to produce a chemical burn in some patients when it was placed in contact with the MN (Fig. 3.14). This untoward outcome sometimes improved spontaneously over time, but in some unfortunate patients, it was prolonged or permanent, often associated with pain or hyperesthesia, and it served as a deterrent to many prospective patients needing preprosthetic surgery. With the current dental implant options, these procedures are seldom performed today.

3.5.5 Dental Implants and Preprosthetic Surgery

In the past, “preprosthetic” operations to alter interfering soft tissue attachments, deepen the vestibule of an edentulous ridge, or augment the residual alveolar ridge that had undergone excessive resorption following the loss of teeth were the only surgical options available to improve conditions of retention and stability for dental prostheses [45, 50, 75, 116]. In the mandible, performance of a vestibuloplasty procedure necessarily required suprapariosteal soft tissue dissection with risk of injury to the MN (Fig. 3.13). If a ridge augmentation were required utilizing

The development and introduction of dental implants [26] has revolutionized the replacement of individual missing teeth and restoration of lost dentition in free-end saddles and totally edentulous dental arches. Despite the availability of improved imaging studies, careful treatment planning, modified surgical techniques, special instrumentation, and the application of surgical skills, injuries to the IAN and the MN can, and do, occur during osseous drilling and implant fixture placement [18, 66, 78]. The incidence of temporary nerve injury has been reported in several case studies varying between 1.7 and 43.5 %. Long-term or permanent (greater than 1 year) NSD was found in 0–15 % of patients. The larger the number of patients, the

lower the rate of nerve injury reported, perhaps indicating the value of surgical experience in reducing the potential for nerve injury. There are many theories regarding IAN injury from dental implant placement other than direct injury due to imprecise determination of the amount of available bone above the canal. One explanation is that intracanal bleeding from an inferior alveolar vein or artery injured during bone preparation may create a “compartment syndrome” within the inferior alveolar canal which compresses the IAN. This would explain the fact that many of these implant-related nerve injuries result in unpleasant dysesthesia rather than solely hypoesthesia or anesthesia. For a complete discussion of this topic, the reader is referred to Chap. 6.

3.5.6 Endodontic Treatment

The onset of persistent numbness or pain following completion of root canal treatment of a mandibular molar or premolar tooth is especially distressing to the patient who expected salvage of that tooth as the primary outcome. The instrumentation necessary to remove necrotic tissue from the pulp canal of a non-vital posterior mandibular tooth and smooth or enlarge its walls and the substances used to medicate and fill the canal can injure the underlying IAN [17, 67, 87, 91, 98]. The incidence of IAN injury associated with endodontic treatment has not been determined, since the only reports in the literature are single case reports or small series of fewer than ten patients. Many of these patients had their root canals filled with Sargenti (N2) paste, a substance that contains paraformaldehyde which has been shown to be toxic to nerve tissue. When N2 paste is injected into the prepared canal under pressure, it has the potential to flow beyond the root apex in the periapical area and thence, particularly if the root canal has been overinstrumented, come into contact with the IAN.

The mechanisms of nerve injury that might result in NSD of the IAN from endodontic treatment include (1) *direct trauma* from overinstrumentation, (2) *compression* from overfilling of the root canal with extrusion of inert filling material

into the IAC, and (3) *chemical injury* [33]. This is particularly prone to occur, if the IAC is in close proximity to the root apex. Endodontic broaches or files passed beyond the apex might enter the IAC and pierce the IAN, causing its internal disruption and partial or complete severance. Some medicaments and materials used to irrigate, sterilize, and fill the canal might be inert (e.g., normal saline) when in contact with nerve tissue and/or only produce compression (e.g., gutta-percha, zinc oxide), if allowed to enter the IAC. On the other hand, many root canal cements contain derivatives of phenol (such as eugenol) or other substances (e.g., calcium hydroxide, paraformaldehyde), and sterilizing solutions may consist of parachlorophenols, paraldehydes, or other agents such as sodium hypochlorite and antibiotics, all of which may be toxic to nerve tissue and capable of producing a chemical burn if allowed to make contact with a nerve.

The patient who has sustained an IAN injury during endodontic treatment may experience immediate onset of pain and/or loss of sensation. In such a case, it may be concluded that direct contact with the nerve was made during the procedure by overinstrumentation and/or extrusion of root canal filling cement or filling material beyond the confines of the root canal into the periapical region and thence into the IAC. If there is pain, it is often intense, prostrating, and difficult to control with opioid analgesics. In some patients, addition of a neurotropic medication (e.g., clonazepam 0.5–2.0 mg. every 8 h) will provide adequate pain relief until surgical intervention is begun. In other instances, after the effect of local anesthesia administered for the procedure has worn off, there may be a return of normal sensation (the so-called lucid interval), and only in one to several days later does the patient experience the onset of pain and altered sensation [98]. This is thought to be due to delayed percolation of toxic materials into the IAC that have leaked out the root apex of an overinstrumented canal. In either situation, the symptomatic patient requires immediate attention (Fig. 3.15). Imaging studies (plain films or CBCT) will demonstrate whether filling material has extruded beyond the confines of the root canal and if there is involvement of the

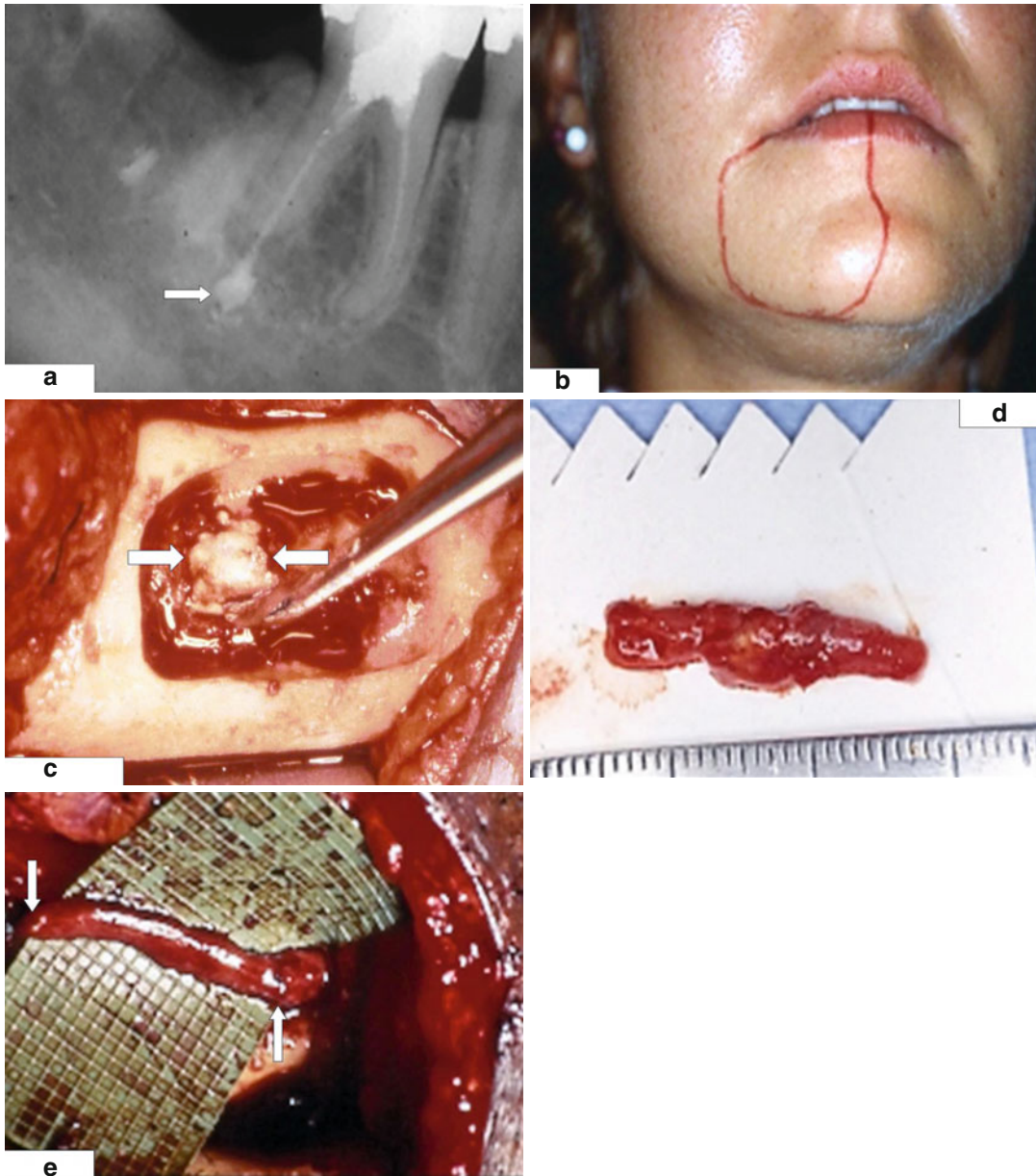


Fig. 3.15 Inferior alveolar nerve (IAN) injury associated with root canal (RC) treatment: (a) overfilled mandibular right first molar with radiopaque material (arrow) extruded into inferior alveolar canal; (b) the patient presents with pain and numbness in the distribution of the right IAN

(outlined in red); (c) surgical exploration shows extruded filling material (arrows) in contact with IAN; (d) resected 2.5 cm segment of IAN had sustained chemical burn from contact with extruded RC material; (e) the IAN was reconstructed with autogenous sural nerve graft (arrows)

IAC. If so, the patient should be scheduled as soon as possible in the hospital operating room under general anesthesia for microsurgical exploration and debridement of the IAC and repair of the IAN as indicated by surgical findings. The IAC is approached either transorally or through a

submandibular cutaneous incision, depending on the ease of exposure, as dictated by the location of involvement of the IAN. In some patients, the IAN will be found to be compressed by impinging root canal filling material. All extruded material surrounding the IAN is removed. If it appears

that material has breached the nerve itself, the epineurium is entered through an axial incision. Under magnification, the fascicles are identified, and a thorough intraneural debridement is done, often a tedious task with the potential for intraneuronal scarring limiting full neurosensory recovery, followed by copious saline irrigation. If the nerve has sustained a chemical burn, the epineurium may appear thickened and chalky white, rather than with its normal translucent sheen appearance. If a segment of the nerve appears to have sustained a chemical burn, it is important to accurately determine the line of demarcation between necrotic and viable tissue [79], and this may not be apparent for several days to weeks following the injury. Then, the damaged nerve tissue is resected so that normal fascicular tissue is present in the proximal and distal nerve stumps and the IAN is then reconstructed in the usual manner (see Chap. 14).

A nerve injury from endodontic treatment can be a serious emergency for the patient whose principal symptom is pain. Every effort should be made to avoid or minimize the occurrence of this complication. The practitioner is advised to ascertain an accurate estimate of the root length from a standardized radiograph. Instruments should be armed with stops at the determined distance to avoid overinstrumentation beyond the root apex. Root canal filling materials should not be inserted or injected under pressure. A radiograph should be taken immediately upon completion of treatment to assess the location of filling material. If there is evidence of overfilling of material with encroachment on the IAC, the patient should be referred immediately for microsurgical consultation. When performing apical surgery on a mandibular premolar or molar tooth, the location of the mental foramen and the IAC should be determined and care taken to avoid these areas or use suitable gentle retraction of any nerve branches in the area of the procedure on the root apex.

The development of the dental specialty of endodontics [58], closer scrutiny of the toxicity of root canal filling materials [4], the modification of techniques, and the introduction of magnification to endodontic treatment have greatly diminished the case load of endodontically associated TN5 injuries in microsurgical practice.

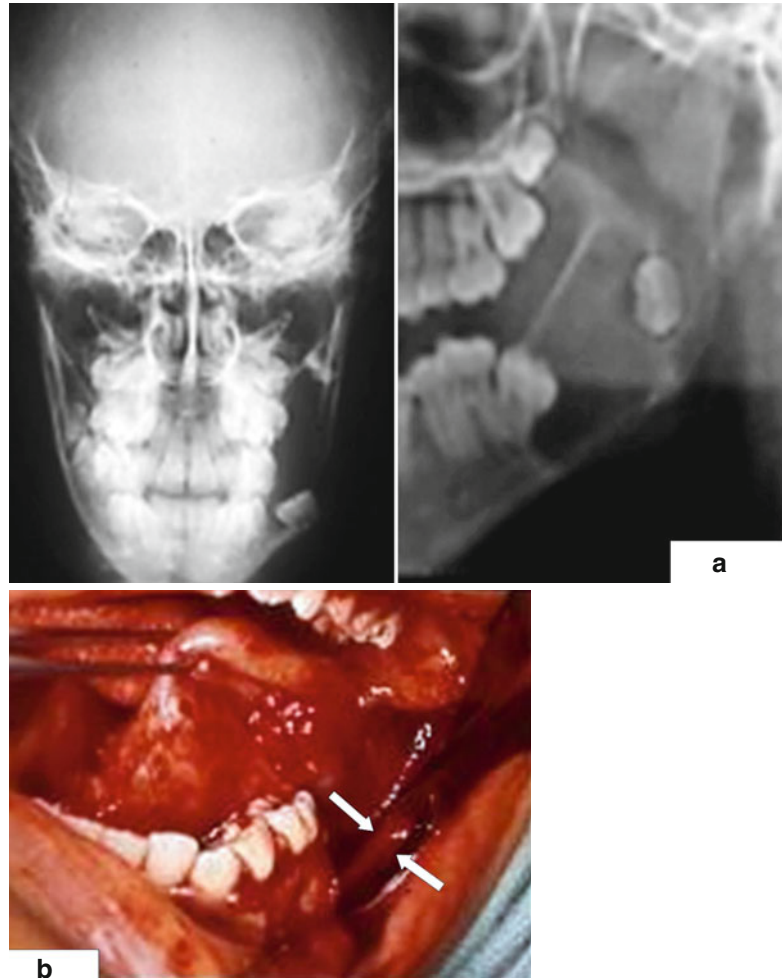
3.5.7 Salivary Gland Surgery

Surgical operations on the submandibular salivary duct and the submandibular and sublingual salivary glands are frequently required to treat tumors, ranulas, sialolithiasis, obstruction, acute and chronic infections, and end-stage salivary gland dysfunction [28, 29]. Such operations, whether they are performed through transoral or submandibular cutaneous approaches, will often involve the LN as it courses medial to or even through the submandibular gland and in close proximity to the sublingual gland and submandibular salivary duct in the floor of the mouth (see Sect. 3.2, above). Although the incidence of NSD of the LN following salivary gland surgery is not known, occasional cases are seen. Patients present with varying complaints of tongue numbness, pain or hypersensitivity, and altered taste sensation, all of which are often quite distressing and interfere with normal oral functions.

In order to minimize the risk of LN injury during surgery on salivary structures, the surgeon should be proactive. When the sublingual or submandibular gland is to be excised, a maneuver that is helpful in identifying the facial nerve during parotid gland surgery can be employed. At the beginning of the operation, the submandibular salivary duct is dilated, cannulated, and injected with 1–2 mL of an inert dye such as methylene blue. When the salivary gland (sublingual or submandibular) to be operated upon is exposed, it will be stained an intense blue color. This technique makes it easy to locate the LN, which will retain its usual translucent opalescent appearance in contrast to the stained blue color of the gland. In operations upon the submandibular duct, one is advised to maintain a cannula in the duct while opening or dissecting within it in order to maintain perspective with the rest of the floor of the mouth. Confining instruments to within the duct while removing a stone will avoid their contact with the nearby LN.

As mentioned above (see Sect. 3.2), the ATN is at risk during parotidectomy. The development of Frey's syndrome (syndrome of gustatory sweating) with preauricular flushing and sweating during mastication of food is thought to be due to abnormal reconnections of postganglionic parasympathetic fibers of the ATN which supply

Fig. 3.16 Large dentigerous cyst of left mandible: (a) preoperative radiographic views; (b) cyst and associated teeth have been successfully dissected away from the left inferior alveolar nerve which is seen to be intact (*arrows*)



the parotid gland with severed sympathetic nerve branches that stimulate subcutaneous sweat glands. The incidence is unpredictable and is reported to range from 2.6 to 97.6 % in various studies. This complication can be prevented by interposition of various types of soft tissue (fat, temporalis fascia, fascia lata femoris, dermis, and myocutaneous flaps) beneath the skin flap, and the problem can also be treated with injections of botulinum toxin [44].

3.5.8 Ablative/Oncologic Surgery

Large cysts and benign tumors of the mandible often involve the IAN, and the surgeon is then faced with a decision regarding surgical management of the nerve as well as the lesion. In the case of dentigerous, or other types of odontogenic

cysts, without malignant or invasive potential, generally the cyst can be carefully dissected away from the IAC contents, sometimes aided by magnification and microsurgical instruments (Fig. 3.16). Such careful technique may result in immediate temporary paresthesia of the IAN in the early postoperative period, but this often resolves over the course of several months. Occasionally, the nerve is *unintentionally* partially or completely transected during removal of the cyst. If this is observed by the surgeon at the time of its occurrence and the surgeon has microsurgical expertise, the nerve can be surgically repaired at that time. If not, the nerve ends are tagged with fine, nonreactive sutures (i.e., 6-0 or 8-0 nylon), the nerve ends are placed in as close approximation as possible, and a note describing the nature and location of the nerve is included in the operative report. Subsequently, the patient

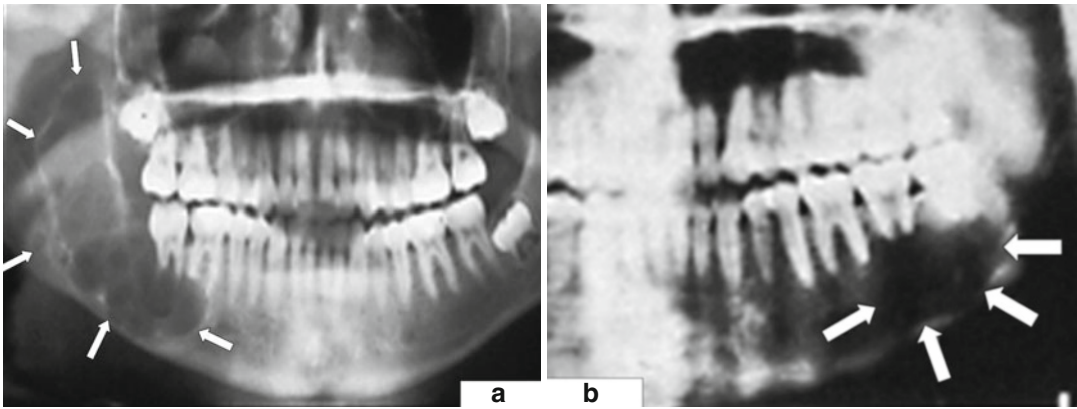


Fig. 3.17 Locally aggressive tumors can involve the inferior alveolar nerve, necessitating its resection along with the tumor: (a) large, multiloculated ameloblastoma

of right mandible (indicated by *white arrows*); (b) myxoma of left mandible (indicated by *white arrows*)

is given a *timely* referral to a microsurgeon for follow-up and possible delayed primary nerve repair, typically 3 weeks following the injury.

Locally aggressive benign tumors of the mandible, such as the ameloblastoma and myxoma, have a high rate of recurrence if not excised with adequate margins [128] (Fig. 3.17). Since there is a question whether such tumors actually invade an adjacent nerve, some clinicians have advocated preservation of the IAN when excising these tumors [19, 122]. However, in an effort to maximize the likelihood of a curative result without recurrence due to inadequate removal, an *intentional* resection of the IAN is included with the surgical specimen in most surgeons' hands. Following mandibular resection (including sacrifice of the IAN) in patients younger than 16 years, spontaneous return of partial IAN sensation to which the patients adapt well has been noted [30]. However, the IAN is often reconstructed immediately with good return of sensation in many patients [93]. Similarly, excision of nerve tumors such as the neurilemmoma (schwannoma) requires resection of the involved nerve and its reconstruction with a nerve graft.

Altered sensation (pain, numbness, loss of sensation to neurosensory testing) is an important clinical symptom and sign of malignancy in a tumor that approximates a sensory nerve such as the TN5. Malignant tumors are well known for their propensity to invade nerves (neurotropism) and use them as a route for spread of malignant cells [72]. Therefore, the IAN is *always* intentionally sacrificed when the mandible is resected for treatment of malignancy.

3.5.9 Cosmetic Surgery

Operations to improve appearance of the chin (the genioplasty) are among the most frequent in facial cosmetic surgery. In the past, contour deficiency corrected by insertion of an alloplastic implant was the favored esthetic operation on the chin [85], and it still is in many situations [35]. However, the development and addition of the anterior horizontal sliding mandibular osteotomy to the orthognathic and facial cosmetic surgeon's repertoire provided a versatile operation that could be utilized in the correction of deficiency of chin contour, objectionable chin prominence, excessive or inadequate chin height, and asymmetry, especially in combination with operations to correct developmental facial bone deformities and concomitant dental malocclusion [73].

Various studies have reported on involvement of the IAN or MN and postoperative NSD in the lower lip and chin following horizontal mandibular osteotomy for genioplasty [38, 92, 107, 124]. Immediately following surgery, most patients experience decreased or absent responses to pain, static light touch, and/or two-point discrimination. When done as a solitary procedure, patients usually regain most or all of their sensory function in the lower lip and chin (Table 3.2). When the genioplasty is done in conjunction with the MSSRO (see Sect. 3.5.3, above), however, there seems to be an exponential additional effect on NSD. For instance, in one series of 115 adolescent patients who underwent surgical correction of dentofacial deformities, the incidence of long-

term NSD in the IAN and/or MN was 10 % for patients having a genioplasty only, 20 % following bilateral MSSROs, and 67 % for those having *both* MSSROs and genioplasty [107]. This has been described as the “double crush syndrome” and indicates that, at least in some instances, the patient who undergoes MSSROs *and* genioplasty at the same operation will have greater loss of sensory function in the IAN and MN distribution than in patients that have either procedure alone [38, 107, 123, 124].

The MN is at risk during the creation of a pocket for insertion of an alloplastic implant through a submental skin incision because the surgeon seldom can visualize the nerve directly or very well at all. The location of the mental foramen can be determined preoperatively from a panoramic radiograph of the mandible, and the

surgeon can plan to avoid this area when creating the soft tissue pocket. An implant size is selected which does not impinge upon the mental foramen when seated into place. When raising a mucoperiosteal flap to expose the facial aspect of the mandibular symphysis for a horizontal osteotomy, the dissection is done carefully until the MN is identified on each side. The exit of the MN from the mandible is at a level several millimeters superior to that of the IAC (see Sect. 3.2, above). This vertical distance is variable and is determined from preoperative imaging studies. The horizontal osteotomy must be made sufficiently inferior to the anatomic mental foramen to avoid contact with the anterior loop, or genu, of the IAN (Fig. 3.18).

Additional cosmetic facial operations that might affect branches of the TN5 include the

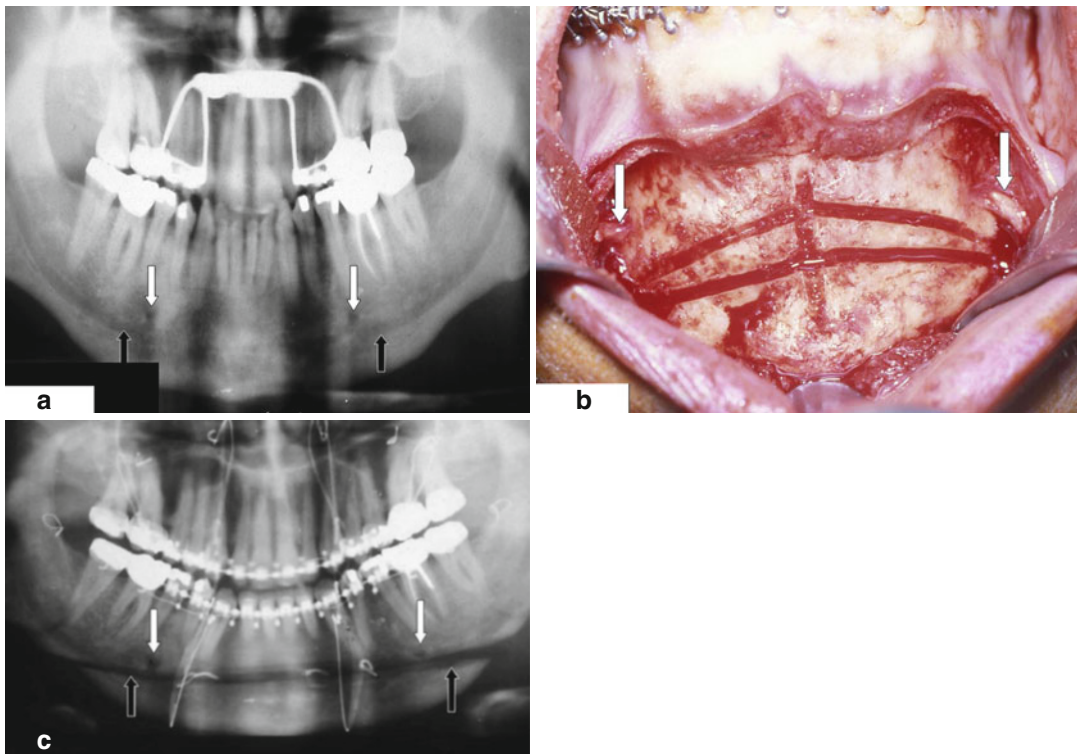


Fig. 3.18 Relationship of mental foramen (MFN) to inferior alveolar canal (IAC): (a) preoperative x-ray shows MFNs (*white arrows*) are several millimeters superior to IACs (*black arrows*); (b) osseous markings made for osteotomies for reduction of chin height and chin advancement are located inferior to mental nerves (*white arrows*);

(c) postoperative film shows that horizontal sliding osteotomy, although located inferior to both MFNs (*white arrows*), has traversed through both IACs. Both inferior alveolar nerves (*black arrows*) were transected. They were successfully repaired microscopically 3 months after injury

facelift (rhytidectomy) and the brow/forehead lift. The facelift procedure commonly involves the auriculotemporal nerve (ATN), a branch of the V3 of TN5. Seldom is sensory loss in the preauricular or temporal areas permanent or mentioned as a problem by the patient [35]. Of more concern is the risk of injury to the FN7 with weakness or paralysis of facial and/or eyelid musculature, a subject not within the scope of this discussion on trigeminal nerve injuries. When planning an open forehead and brow lift, the surgeon should place skin incisions well into the hair-bearing scalp to avoid the superficial branches of the SON and thereby maintain forehead sensation and to preserve the deep division of this nerve and scalp sensation by not carrying the incision through the galea aponeurotica [65]. The introduction of endoscopic procedures has undoubtedly lessened the incidence of permanent forehead or scalp numbness or other undesirable sensory aberrations in patients undergoing eyebrow and forehead lifts [34].

3.6 Summary

Surgical procedures, routine dental treatments, and traumatic injuries in the face and oral cavity occur in close proximity to peripheral branches of the trigeminal (fifth) cranial nerve, the major sensory supply to this important area. Despite the best of care, trigeminal nerve injuries are recognized and accepted risks of surgical operations, dental treatment, and injuries in the oral and maxillofacial regions. However, lost or altered sensation resulting in numbness, pain, or hypersensitivity seriously interferes with common orofacial functions and, if persistent, is often distressing and unacceptable to patients so afflicted. The incidents associated with peripheral trigeminal nerve injuries, the likelihood (incidence) of their occurrence, and the potential mechanisms causing them have been presented, and suggestions have been proposed for reducing the risk of injury associated with specific situations. In the chapters to follow, the treatment of trigeminal nerve injuries will be thoroughly presented.

References

1. Alantar A, Roch Y, Maman L et al (2000) The lower labial branches of the mental nerve: anatomic variations and surgical relevance. *J Oral Maxillofac Surg* 58:415–418
2. Al-Bishri A, Rosenquist J, Sunzel B (2004) On neurosensory disturbance after sagittal split osteotomy. *J Oral Maxillofac Surg* 62:1472–1476
3. Alling CC (1986) Dysesthesia of the lingual and inferior alveolar nerves following third molar surgery. *J Oral Maxillofac Surg* 44:454–457
4. American Dental Association (1991) News: ADA calls for studies on Sargenti paste. *J Am Dent Assoc* 122:18
5. August M, Marchena J, Donady J et al (1998) Neurosensory deficit and function impairment after sagittal ramus osteotomy: a long-term follow-up study. *J Oral Maxillofac Surg* 56:1231–1235
6. Aziz SR, Roser SM (2012) Mandibular orthognathic surgery: vertical ramus osteotomy vs. sagittal split osteotomy. In: Bagheri SC, Bell RB, Ali Khan H (eds) *Current therapy in oral and maxillofacial surgery*. Elsevier/Saunders, St Louis
7. Aziz SR, Dorfman BJ, Ziccardi VB et al (2007) Accuracy of using the antilingula as a sole determinant of vertical ramus osteotomy position. *J Oral Maxillofac Surg* 65:859–862
8. Bagheri SC, Dierks EJ, Kademani D et al (2006) Application of a facial injury severity scale in craniomaxillofacial trauma. *J Oral Maxillofac Surg* 64:408–414
9. Bagheri SC, Dimassi M, Shahriari A et al (2008) Facial trauma coverage among level-I trauma centers of the United States. *J Oral Maxillofac Surg* 66:963–967
10. Bagheri SC, Meyer RA, Ali Khan H et al (2009) Microsurgical repair of peripheral trigeminal nerve injuries from maxillofacial trauma. *J Oral Maxillofac Surg* 67:1791–1799
11. Bagheri SC, Meyer RA, Etezadi H et al (2010) A retrospective review of microsurgical repair of long buccal nerve injuries. *J Oral Maxillofac Surg* 68(Suppl 1):85–86
12. Bagheri SC, Meyer RA, Ali Khan H et al (2010) Retrospective review of microsurgical repair of 222 lingual nerve injuries. *J Oral Maxillofac Surg* 68:715–723
13. Bagheri SC, Meyer RA, Ali Khan H et al (2010) Microsurgical repair of the peripheral trigeminal nerve after mandibular sagittal split ramus osteotomy. *J Oral Maxillofac Surg* 68:2770–2782
14. Bagheri SC, Meyer RA, Cho SH et al (2012) Microsurgical repair of the inferior alveolar nerve: success rate and factors which adversely affect outcome. *J Oral Maxillofac Surg* 70:1978–1990
15. Bailey PH, Bays RA (1984) Evaluation of long-term sensory changes following mandibular augmentation procedures. *J Oral Maxillofac Surg* 42:722–727
16. Bardes CL (2012) Defining “patient-centered medicine”. *N Engl J Med* 366:782–783
17. Barkhordar RA, Nguyen NT (1985) Paresthesia of the mental nerve after overextension with AH26 and gutta

- percha: report of case. *J Am Dent Assoc* 110: 202–203
18. Bartling R, Freeman K, Kraut RA (1999) The incidence of altered sensation of the mental nerve after mandibular implant placement. *J Oral Maxillofac Surg* 57:1408–1410
 19. Becker R (1970) Continuity resection of the mandible with preservation of the mandibular nerve. *Br J Oral Surg* 8:45–49
 20. Behnia H, Kheradvar A, Shahrokh M (2000) An anatomic study of the lingual nerve in the third molar region. *J Oral Maxillofac Surg* 58:649–651
 21. Bell RB (2007) The role of oral and maxillofacial surgery in the trauma care center. *J Oral Maxillofac Surg* 65:2544–2553
 22. Birch R, Bonney G, Wynn Parry CB (1998) Surgical disorders of the peripheral nerves. Churchill-Livingstone, Edinburgh
 23. Black CG (1997) Sensory impairment following lower third molar surgery: a prospective study in New Zealand. *N Z Dent J* 93:68–72
 24. Blackburn CW, Bramley PA (1989) Lingual nerve damage associated with the removal of lower third molars. *Br Dent J* 167:103–107
 25. Boyne PJ (1982) Postexodontia osseous repair involving the mandibular canal. *J Oral Maxillofac Surg* 40:69–73
 26. Branemark P-I (1983) Osseointegration and its experimental background. *J Prosthet Dent* 50:399–410
 27. Carmichael FA, McGowan DA (1992) Incidence of nerve damage following third molar removal. A West of Scotland Oral Surgery Research Group Study. *Br J Oral Maxillofac Surg* 30:78–82
 28. Catone GA, Merrill RG, Henny FA (1969) Sublingual gland mucus-escape phenomenon – treatment by excision of sublingual gland. *J Oral Surg* 27:774
 29. Chidzonga MM, Mahomva L (2007) Ranula: experience with 83 cases in Zimbabwe. *J Oral Maxillofac Surg* 65:79–82
 30. Chow H-T, Teh L-Y (2000) Sensory impairment after resection of the mandible: a case report of 10 cases. *J Oral Maxillofac Surg* 58:629–635
 31. Cobb WM (1972) Facial mimetics as cranial nerve mnemonics. *J Natl Med Assoc* 64:385–396
 32. Colella G, Cannavale R, Vicidomini A et al (2007) Neurosensory disturbance of the inferior alveolar nerve after bilateral sagittal split osteotomy. *J Oral Maxillofac Surg* 65:1707–1715
 33. Conrad SM (2001) Neurosensory disturbances as a result of chemical injury to the inferior alveolar nerve. *Oral Maxillofac Surg Clin North Am* 13:255–263
 34. Cuzalina A, Coptly TV (2012) Forehead, eyebrow, and upper eyelid lifting. In: Bagheri SC, Bell RB, Ali Khan H (eds) *Current therapy in oral and maxillofacial surgery*. Elsevier/Saunders, St Louis
 35. Cuzalina A, Coptly TV, Ali Khan H (2012) Rhytidectomy (face-lifting). In: Bagheri SC, Bell RB, Ali Khan H (eds) *Current therapy in oral and maxillofacial surgery*. Elsevier/Saunders, St Louis
 36. Donoff RB (1995) Surgical management of inferior alveolar nerve injuries. Part I: the case for early repair. *J Oral Maxillofac Surg* 53:1327–1329
 37. Ellis E, El-Attar A, Moos KJ (1985) An analysis of 2,067 cases of zygomatico-orbital fracture. *J Oral Maxillofac Surg* 43:417
 38. Essick GK, Austin S, Phillips C et al (2001) Short-term sensory impairment after orthognathic surgery. *Oral Maxillofac Surg Clin North Am* 13:295–313
 39. Fox NA (1989) The position of the inferior dental canal and its relation to the mandibular second molar. *Br Dent J* 167:19–21
 40. Freedman GL (1997) Intentional partial odontectomy: review of cases. *J Oral Maxillofac Surg* 55: 524–526
 41. Fridrich KL, Holton TJ, Pansegrau KJ et al (1995) Neurosensory recovery following the mandibular bilateral sagittal split osteotomy. *J Oral Maxillofac Surg* 53:1300–1306
 42. Fujioka M, Hirano A, Fujii T (1998) Comparative study of inferior alveolar disturbance restoration after sagittal split osteotomy by means of bicortical versus monocortical osteosynthesis. *Plast Reconstr Surg* 102:37–43
 43. Gomes ACM, Vasconcelos BCE, Silva EDO et al (2005) Lingual nerve damage after mandibular third molar surgery: a randomized clinical trial. *J Oral Maxillofac Surg* 63:1443–1446
 44. Gregoire C (2012) Salivary gland tumors: the parotid gland. In: Bagheri SC, Bell RB, Ali Khan H (eds) *Current therapy in oral and maxillofacial surgery*. Elsevier/Saunders, St Louis
 45. Guernsey LH (1984) Preprosthetic surgery. In: Kruger GO (ed) *Textbook of oral and maxillofacial surgery*, 6th edn. CV Mosby, St. Louis
 46. Gulicher D, Gerlach KL (2001) Sensory impairment of the lingual and inferior alveolar nerves following removal of impacted mandibular third molars. *Int J Oral Maxillofac Surg* 30:306–312
 47. Harn SD, Durham TM (1990) Incidence of lingual nerve trauma and postinjection complications in conventional mandibular block anesthesia. *J Am Dent Assoc* 121:519–523
 48. Haug RH, Dodson TB, Morgan JP (2001) Trauma surgery. In: Haug RH (ed) *Parameters and pathways: clinical practice guidelines for oral and maxillofacial surgery (AAOMS ParPath 01)*, version 3.0. AAOMS, Chicago
 49. Haug RH, Perrott DH, Gonzales ML et al (2005) The American Association of Oral and Maxillofacial Surgeons age-related third molar study. *J Oral Maxillofac Surg* 63:1106–1114
 50. Helfrick JF, Waite DE (1987) Reconstructive preprosthetic surgery. In: Waite DE (ed) *Textbook of practical oral and maxillofacial surgery*, 3rd edn. Lea & Febiger, Philadelphia
 51. HENDY CW, Robinson PP (1994) The sensory distribution of the buccal nerve. *Br J Oral Maxillofac Surg* 32:384–386

52. Hendy CW, Smith KG, Robinson PP (1996) Surgical anatomy of the buccal nerve. *Br J Oral Maxillofac Surg* 34:457–460
53. Hill CM, Mostafa P, Thomas DW et al (2001) Nerve morbidity following wisdom tooth removal under local and general anesthesia. *Br J Oral Maxillofac Surg* 39:419–422
54. Hillerup S (2011) Update on injuries related to injection of local anesthetics. In: Symposium: update on nerve injury, diagnosis and repair. In: American Association of Oral and Maxillofacial Surgeons 93rd annual meeting, Philadelphia, 16 Sept
55. Holzle FW, Wolff KD (2001) Anatomic position of the lingual nerve in the mandibular third molar region with special consideration of an atrophied mandibular crest: an anatomical study. *Int J Oral Maxillofac Surg* 30:333–338
56. Hooley JR, Whitacre RJ (1983) Assessment and surgery for impacted third molars: a self-instructional guide, 3rd edn. Stoma Press, Inc., Seattle
57. Hu J, Tang Z, Wang D et al (2001) Changes in the inferior alveolar nerve after mandibular lengthening with different rates of distraction. *J Oral Maxillofac Surg* 59:1041–1045
58. Ingle JI, Slavkin HC (2008) Modern endodontic therapy: past, present and future. In: Ingle JI, Bakland LK, Baumgartner JC (eds) *Ingle's endodontics*, 6th edn. BC Decker, Hamilton
59. Jabaley ME (1981) Current principles of nerve repair. *Clin Plast Surg* 8:33–44
60. Jacks SC, Zuniga JR, Turvey TA et al (1998) A retrospective analysis of lingual nerve sensory changes after mandibular bilateral sagittal split osteotomy. *J Oral Maxillofac Surg* 56:700–704
61. Karas ND, Boyd SB, Sinn DP (1990) Recovery of neurosensory function following orthognathic surgery. *J Oral Maxillofac Surg* 48:124–134
62. Kent JN, Finger IM, Quinn JH et al (1986) Hydroxylapatite alveolar ridge construction: clinical experiences, complications, and technical modifications. *J Oral Maxillofac Surg* 44:37–49
63. Kiesselbach JE, Chamberlain JG (1984) Clinical and anatomic observation on the relationship of the lingual nerve to the mandibular third molar region. *J Oral Maxillofac Surg* 42:565–567
64. Kipp DP, Goldstein BH, Weiss WW (1980) Dysesthesia after mandibular third molar surgery: a retrospective study and analysis of 1,377 surgical operations. *J Am Dent Assoc* 100:185–192
65. Knize DM (1995) A study of the supraorbital nerve. *Plast Reconstr Surg* 96:564–569
66. Kraut RA, Chahal O (2002) Management of patients with trigeminal nerve injuries after mandibular implant placement. *J Am Dent Assoc* 133:1351–1354
67. LaBanc JP, Epker BN (1984) Serious inferior alveolar dysesthesia after endodontic procedure: report of three cases. *J Am Dent Assoc* 108:605–607
68. Lam NP, Donoff RB, Kaban LB et al (2003) Patient satisfaction after trigeminal nerve repair. *Oral Surg Oral Med Oral Pathol Oral Radiol Endod* 95:535–540
69. Langford RJ (1989) The contribution of the nasopalatine nerve to sensation of the hard palate. *Br J Oral Maxillofac Surg* 27:379–386
70. Lemke RR, Rugh JD, Van Sickels J et al (2000) Neurosensory differences after wire and rigid fixation in patients with mandibular advancement. *J Oral Maxillofac Surg* 58:1354–1359
71. Li KK, Powell NB, Riley RW et al (2002) Distraction osteogenesis in adult obstructive sleep apnea: a preliminary report. *J Oral Maxillofac Surg* 60:6–10
72. Lydiatt DD, Lydiatt WM (1997) Advances in the surgical management of carcinoma of the oral cavity. *Oral Maxillofac Surg Clin North Am* 3:375–383
73. McBride KL, Bell WH (1980) Chin surgery. In: Bell WH, Proffit WR, White RP (eds) *Surgical correction of dento-facial deformities*, vol II. W B Saunders, Philadelphia
74. McCarthy JG, Schreiber J, Karp W et al (1992) Lengthening the human mandible by gradual distraction. *Plast Reconstr Surg* 89:1–8
75. McIntosh RB, Obwegeser HL (1967) Preprosthetic surgery: a scheme for its effective employment. *J Oral Surg* 25:397–405
76. Merrill RG (1979) Prevention, treatment, and prognosis for nerve injury related to the difficult impaction. *Dent Clin North Am* 23:471–488
77. Meyer RA (1990) Protection of the lingual nerve during placement of rigid fixation after sagittal split osteotomy. *J Oral Maxillofac Surg* 48:1135–1136
78. Meyer RA (1990) Nerve injuries associated with dental implants. In: Fagan MJ Jr (ed) *Implant prosthodontics*. Year Book Medical Publishers, Chicago
79. Meyer RA (1992) Applications of microneurosurgery to the repair of trigeminal nerve injuries. *Oral Maxillofac Surg Clin North Am* 4:405–424
80. Meyer RA (1999) Bicortical versus monocortical osteosynthesis (letter). *Plast Reconstr Surg* 103:1538–1539
81. Meyer RA (2007) Surgical treatment of inferior alveolar nerve injuries associated with orthognathic surgery in the mandibular ramus. In: Bell WH, Guerrero CA (eds) *Distraction osteogenesis of the facial skeleton*. BC Becker Inc., Hamilton
82. Meyer RA, Bagheri SC (2011) Nerve injuries from mandibular third molar removal. *Atlas Oral Maxillofac Surg Clin North Am* 19:63–78
83. Meyer RA, Bagheri SC (2011) Reducing risk of IAN injury during SSRO (letter). *J Oral Maxillofac Surg* 69:1538–1539
84. Meyer RA, Rath EM (2001) Sensory rehabilitation after trigeminal nerve injury or nerve repair. *Oral Maxillofac Surg Clin North Am* 13:365–376
85. Meyer RA, Gehrig JD, Funk EC et al (1967) Restoring facial contour with implanted silicone rubber. *Oral Surg Oral Med Oral Pathol* 24:598–603
86. Miloro M, Halkias LE, Chakeres DW, Slone W (1997) Assessment of the lingual nerve in the third molar region using magnetic resonance imaging. *J Oral Maxillofac Surg* 55:134–137

87. Morse DR (1997) Endodontic-related inferior alveolar nerve and mental foramen paresthesia. *Compendium* 18:963–983
88. Moszary PG, Middleton RA (1984) Microsurgical reconstruction of the lingual nerve. *J Oral Maxillofac Surg* 42:415–420
89. Moszary PG, Middleton RA, Szabo Z et al (1982) Experimental evaluation of microsurgical repair of the lingual nerve. *J Oral Maxillofac Surg* 40:329–331
90. Motamedi MH (2003) An assessment of maxillofacial fractures: a 5-year study of 237 patients. *J Oral Maxillofac Surg* 61:61–64
91. Neaverth EJ (1989) Disabling complications following inadvertent overextension of a root canal filling material. *J Endod* 15:135–139
92. Nishioka GJ, Mason M, Van Sickels JE (1988) Neurosensory disturbance associated with the anterior mandibular horizontal osteotomy. *J Oral Maxillofac Surg* 46:107–110
93. Noma H, Kakizawa T, Yamane G et al (1986) Repair of the mandibular nerve by autogenous grafting after partial resection of the mandible. *J Oral Maxillofac Surg* 44:30–36
94. Pichler JW, Bierne OR (2001) Lingual flap retraction and prevention of lingual nerve damage associated with third molar surgery: a systematic review of the literature. *Oral Surg Oral Med Oral Pathol Oral Radiol Endod* 91:395–401
95. Pogrel MA (1990) Complications of third molar surgery. *Oral Maxillofac Surg Clin North Am* 2:441–451
96. Pogrel MA (2002) The results of microneurosurgery of the inferior alveolar nerve and lingual nerve. *J Oral Maxillofac Surg* 60:485–489
97. Pogrel MA (2006) Etiology of LN injuries in the 3rd molar region. *J Oral Maxillofac Surg* 64:1790
98. Pogrel MA (2007) Damage to the inferior alveolar nerve as the result of root canal therapy. *J Am Dent Assoc* 138:65–69
99. Pogrel MA, Hung L (2006) Etiology of lingual nerve injuries in the third molar region: a cadaver and histologic study. *J Oral Maxillofac Surg* 64:1790–1794
100. Pogrel MA, Schmidt BL (2001) Trigeminal nerve chemical neurotrauma from injectable materials. *Oral Maxillofac Surg Clin North Am* 13:247–253
101. Pogrel MA, Thamby S (2000) Permanent nerve involvement from inferior alveolar nerve blocks. *J Am Dent Assoc* 131:901–907
102. Pogrel MA, Bryan J, Regezi J (1995) Nerve damage associated with inferior alveolar nerve blocks. *J Am Dent Assoc* 126:1150–1155
103. Pogrel MA, Renaut A, Schmidt B et al (1995) The relationship of the lingual nerve to the mandibular third molar region: an anatomic study. *J Oral Maxillofac Surg* 53:1178–1181
104. Pogrel MA, Lee JD, Muff DF (2004) Coronectomy: a technique to protect the inferior alveolar nerve. *J Oral Maxillofac Surg* 62:1447–1453
105. Pogrel MA, Jergensen R, Burgon E et al (2011) Long-term outcome of trigeminal nerve injuries related to dental treatment. *J Oral Maxillofac Surg* 69:2284–2288
106. Posnick JC, Zimble AG, Grossman JAI (1990) Normal cutaneous sensibility of the face. *Plast Reconstr Surg* 86:429–433
107. Posnick JC, Al-Qattan MM, Stepner NM (1996) Alteration in facial sensibility in adolescents following sagittal split and chin osteotomies of the mandible. *Plast Reconstr Surg* 97:920–927
108. Queral-Godoy E, Figueiredo R, Valmaseda-Castellon E et al (2006) Frequency and evolution of lingual nerve lesions following lower third molar extraction. *J Oral Maxillofac Surg* 64:402–407
109. Queresby FA, Savell TA, Palomo JM (2008) Applications of cone beam computed tomography in the practice of oral and maxillofacial surgery. *J Oral Maxillofac Surg* 66:791–796
110. Robert RC, Bacchetti P, Pogrel MA (2005) Frequency of trigeminal nerve injuries following third molar removal. *J Oral Maxillofac Surg* 63:732
111. Rud J (1970) The split-bone technic for removal of impacted mandibular third molars. *J Oral Surg* 28:416–421
112. Rutner TW, Ziccardi VB, Janal MN (2005) Long-term outcome assessment for lingual nerve microsurgery. *J Oral Maxillofac Surg* 63:1145–1149
113. Schultze-Mosgau S, Krems H, Ott R et al (2001) A prospective electromyographic and computer-aided thermal sensitivity assessment of nerve lesions after sagittal split osteotomy and Le Fort I osteotomy. *J Oral Maxillofac Surg* 59:128–139
114. Seckel BR (1990) Normal cutaneous sensibility of the face (discussion). *Plast Reconstr Surg* 86:434–435
115. Sedaghatfar M, August MA, Dodson TB (2005) Panoramic radiographic findings as predictors of inferior alveolar nerve exposure during third molar extraction. *J Oral Maxillofac Surg* 63:3–7
116. Steinhäuser EW (1971) Vestibuloplasty – skin grafts. *J Oral Surg* 29:277–282
117. Strauss ER, Ziccardi VB, Janal MN (2006) Outcome assessment of inferior alveolar nerve microsurgery: a retrospective review. *J Oral Maxillofac Surg* 64:1767–1770
118. Susarla SM, Dodson TB (2007) Preoperative computed tomography imaging in the management of impacted mandibular third molars. *J Oral Maxillofac Surg* 65:83–88
119. Susarla SM, Lam NP, Donoff RB et al (2005) A comparison of patient satisfaction and objective assessment of neurosensory function after trigeminal nerve repair. *J Oral Maxillofac Surg* 63:1138–1144
120. Teerijoki-Oksa T, Jaaskelainen SK, Forssell K et al (2002) Risk factors of nerve injury during mandibular sagittal split osteotomy. *Int J Oral Maxillofac Surg* 31:33–39
121. Thurmüller P, Dodson TB, Kaban LB (2001) Nerve injuries associated with facial trauma. *Oral Maxillofac Surg Clin North Am* 13:283–293
122. Tung-Yiu W, Jehn-Shyun H, Ching-Hung C (2000) Epineural dissection to preserve the inferior alveolar

- nerve in excision of an ameloblastoma of mandible: case report. *J Oral Maxillofac Surg* 58:1159–1161
123. Upton ARM, McComas AJ (1973) The double crush in nerve entrapment syndromes. *Lancet* 2:359–363
 124. Van Sickels JE, Hatch JP, Dolce C et al (2002) Effects of age, amount of advancement, and genioplasty on neurosensory disturbance after a bilateral sagittal split osteotomy. *J Oral Maxillofac Surg* 60:1012–1017
 125. Wang X-X, Wang X, Li Z-L (2002) Effects of mandibular distraction osteogenesis on the inferior alveolar nerve: an experimental study in monkeys. *Plast Reconstr Surg* 109:2373–2383
 126. Whitesides LM, Meyer RA (2004) Effects of distraction osteogenesis on the severely hypoplastic mandible and inferior alveolar nerve function. *J Oral Maxillofac Surg* 62:292–297
 127. Wijbenga JG, Verlinden CRA, Jansma J et al (2009) Long-lasting neurosensory disturbance following advancement of the retrognathic mandible: distraction osteogenesis versus bilateral sagittal split osteotomy. *Int J Oral Maxillofac Surg* 38:718–725
 128. Williams TP (1997) Aggressive odontogenic cysts and tumors. *Oral Maxillofac Surg Clin North Am* 3:329–338
 129. Wofford DT, Miller RI (1987) Prospective study of dysesthesia following odontectomy of impacted mandibular third molars. *J Oral Maxillofac Surg* 45:15–19
 130. Yamamoto R, Nakamura A, Ohno K et al (2002) Relationship of the mandibular canal to the lateral cortex of the mandibular ramus as a factor in the development of neurosensory disturbance after bilateral sagittal split osteotomy. *J Oral Maxillofac Surg* 60:490–495
 131. Yamauchi K, Takahashi T, Kaneuji T et al (2012) Risk factors for neurosensory disturbance after bilateral sagittal split osteotomy based on position of mandibular canal and morphology of mandibular angle. *J Oral Maxillofac Surg* 70:401–406
 132. Ye WM, Zhu HG, Zheng JW et al (2008) Use of allogeneic acellular dermal matrix in prevention of Frey's syndrome after parotidectomy. *Br J Oral Maxillofac Surg* 46:649–652
 133. Ylikontiola L, Kinnunen J, Oikarinen K (2000) Factors affecting neurosensory disturbance after mandibular bilateral sagittal split osteotomy. *J Oral Maxillofac Surg* 58:1234–1239
 134. Yoshioka I, Tanaka T, Khanal A et al (2010) Relationship between inferior alveolar nerve canal position at mandibular second molar in patients with prognathism and possible occurrence of neurosensory disturbance after sagittal split osteotomy. *J Oral Maxillofac Surg* 68:3022–3027
 135. Zaytoun HS, Phillips C, Terry BC (1986) Long-term neurosensory deficits following transoral vertical ramus and sagittal split osteotomies for mandibular prognathism. *J Oral Maxillofac Surg* 44:193–196
 136. Zuniga JR, LeBanc JP (1993) Advances in microsurgical nerve repair. *J Oral Maxillofac Surg* 51(suppl 1):62–68

Injection Injuries of the Trigeminal Nerve

4

Søren Hillerup

Patients experience painless treatment in current health care since local anesthesia (LA) makes it possible for most procedures in ambulatory dentistry and oral and maxillofacial surgery. Modern local anesthetics are extremely efficient and safe drugs, and the great majority of patients encounter neither unpleasant side effects nor lasting local or systemic complications. Vasovagal syncope is a frequent psychogenic reaction experienced upon anesthetic injection that is unrelated to the particular drug used.

Nevertheless, serious adverse drug reactions (ADRs) with LA occasionally do occur. Prolonged neurosensory disturbance (NSD) with reduced somatosensory (and gustatory) perception has become a problem for a number of patients [1–4]. A trigeminal NSD involves not only a loss of nerve conduction with reduced perception but most often also a neuropathic symptom that may present a devastating nuisance for the patient [5]. Therefore, an anesthetic injection-associated trigeminal nerve injury causing permanent NSD may have a significant impact on patients' quality

of life, and every possible step should be taken to minimize the risk of such complications.

This chapter focuses on trigeminal nerve injuries associated with the injection of local anesthetics that result in NSD in the orofacial region. For this purpose, a NSD is defined as *any abnormality in somatosensory or gustatory perception exceeding weeks or months or at least beyond the normal duration of local anesthetic action* [6].

Since LA-associated nerve injury is such an infrequent ADR, controlled clinical trials are not an option for evaluation of these complications. Consequently, other methodologies must be relied upon such as open observational studies [3, 7, 8], national registry data [6, 9–12], and animal experiments [13–17], all with due regard to the strengths and weaknesses inherent in each methodology.

4.1 History

The history and development of local anesthesia (LA) is a little more than 100 years old [18, 19]. The first ester-type formulations of LA were based on cocaine and, later, procaine. These drugs were associated with a significant potential for systemic, central nervous system, and cardiovascular malfunctions due to their toxicity, central mode of action, and rapid spread through tissues and the bloodstream [20]. Subsequent research in amino-amide formulations converged into the synthesis of lidocaine, and initial

S. Hillerup, PhD, Dr.Odont.
Department of Oral and Maxillofacial Surgery,
University of Copenhagen Rigshospitalet,
Blegdamsvej 9, DK-2100, Copenhagen Ø, Denmark

Institute of Odontology, Panum Institutet,
University of Copenhagen,
Norre Alle 20, 2200, Copenhagen, Denmark
e-mail: shil@sund.ku.dk, soeren@hillerup.net

experience with this new drug launched in 1948 set a new standard in LA [21]. The formulation of lidocaine 2 % with adrenaline (5–12.5 µg/ml) proved to be safe and efficient, and it became the drug of choice for dental LA through several decades. For amide-based LA, systemic complications were minimized, and local complications were few.

Mepivacaine, with or without vasoconstrictor, as well as prilocaine, with an alternative vasoconstrictor with no cardiac stimulation (felypressin), gained considerable popularity in Europe, either as a successor of lidocaine or as an alternative for treatment of a selected group of patients. Finally, articaine-based local anesthetics entered the European and North American market between 1976 and 2000 in a 4 % formulation that conquered a substantial market share in central Europe, with less in the USA, UK, and Scandinavia.

Complications with amide-based local anesthetics in current use include primarily hematoma at the injection site, local tenderness, trismus, and unintended effect on nerves other than the terminal branches of the trigeminal nerve. Most of these complications are harmless and transient, in contrast to nerve injury that may cause loss of function and neurosensory (neuropathic) disturbance of all kinds, including chronic pain [22]. Thus, LA-associated nerve injury causing NSD may be permanent and severely incapacitating [3, 6].

4.2 Incidence of Injection Injuries

A review of 441 cases of iatrogenic injuries to the oral branches of the trigeminal nerve referred to a tertiary oral and maxillofacial surgery unit showed that 17 % were associated with the injection of local anesthetics in nonsurgical cases [5]. The lingual nerve (LN) seems to be the most frequently affected trigeminal branch followed by the inferior alveolar nerve (IAN) [3, 7, 11, 12], and more than nine out of ten cases of LA-induced NSD are associated with mandibular blocks [6, 11, 12].

Valid information regarding the incidence of injection injuries of the trigeminal nerve is

lacking due to poor recognition and probable underreporting of the problem [23]. Estimates of the incidence range between the extremes of 1:42 and more than 1:1 million LA injections [1, 9, 24–26]. Several difficulties in the precise determination of the true incidence include the subjective and anecdotal nature of data acquisition, missing or absent follow-up, and the oversimplified terminology of paresthesia accounting for all types of NSD. Moreover, only few authors determine a clear distinction between temporary and permanent nerve injuries [1, 6, 24] and potentially surgical and nonsurgical injuries [1], and even fewer perform a standard clinical neurosensory test on their patients to assess loss of conductive function [3, 6, 8].

The true incidence of local anesthetic-related trigeminal nerve injuries is basically unknown, and due to probable underreporting, registry data from medical agencies and the FDA most likely do not provide a valid estimate. A systematic review comprising 37 numerical estimates of underreporting of ADRs (others than those associated with LA), from private practice and hospital settings from 12 different countries, showed a median rate of underreporting of 94 % [23]. Therefore, provided that there is an equal underreporting rate for all local anesthetics, and knowing the market share of each drug, a relative incidence of injection injury may be calculated. The relative incidence forms the basis for risk assessment of LAs in current clinical usage.

Several studies [6, 9, 11, 12] have found an increased incidence/risk of ADRs, in particular trigeminal NSD, with increasing concentrations of the local anesthetic solution. Our findings were based upon clinical data from a tertiary oral and maxillofacial unit receiving referrals from the country of Denmark [3], and they were in accordance with the registry data from the Danish Medicines Agency covering 12 years (2005–2007) [6] (Fig. 4.1). Articaine-based LA were launched late in the year 2000 in Denmark, and a dramatic increase in LA-associated ADR was observed thereafter, the majority being associated with articaine-based LA. The distribution of ADRs based upon neurosensory trigeminal

Fig. 4.1 Reports to the Danish Medicines Agency of ADRs associated with LA sold in cartridges, 1995–2007. Reports from 2005 may be influenced by peaking sales figures through 2003 and 2004. Decline of reports from 2006 and 2007 probably reflecting change in application pattern (avoidance of articaine for IAN blocks) [6] (Source: Danish Medicines Agency)

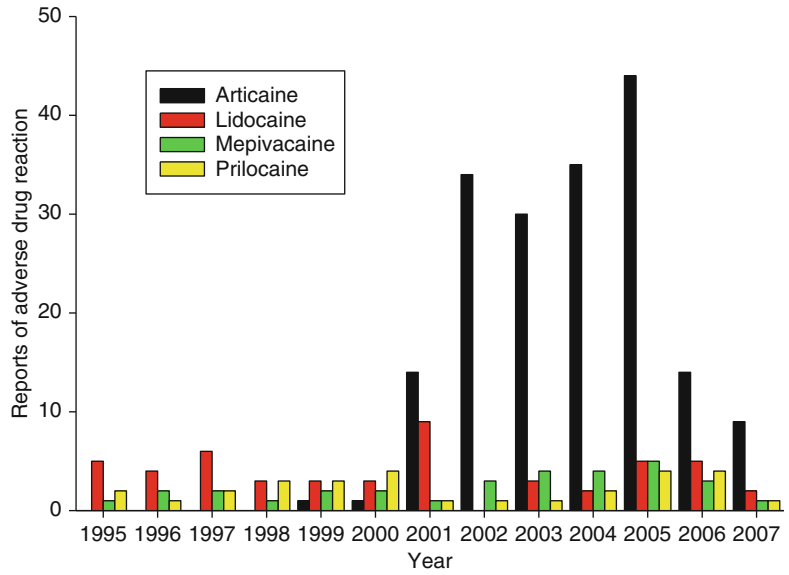
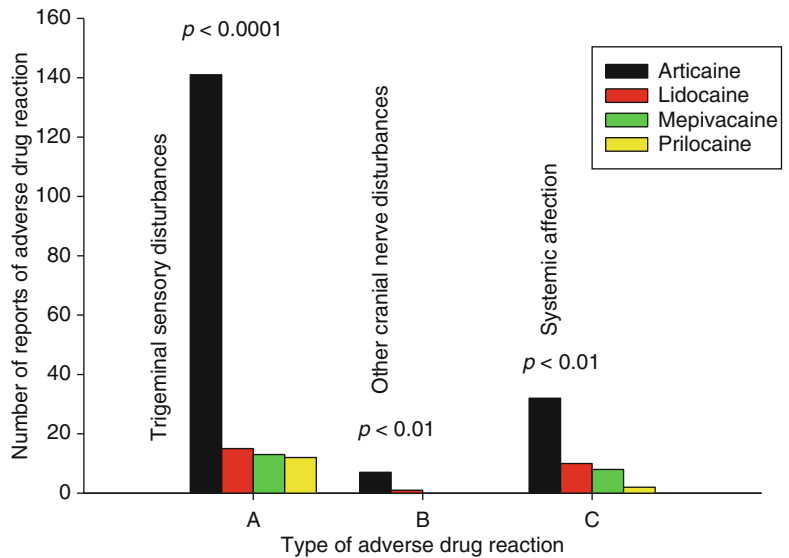


Fig. 4.2 Reports of ADRs associated with LA sold in cartridges in Denmark 2001–2007 distributed based upon type of symptom. Group A shows trigeminal and gustatory sensory disturbances, group B shows other facial nerve affections, and group C illustrates systemic and local non-neurologic ADRs. Significant overrepresentation of articaine was identified in all groups [6] (Source: Danish Medicines Agency)



disturbance, other facial nerve involvement, and systemic and non-neurologic local reactions is illustrated in Fig. 4.2, showing overrepresentation of articaine-based LA in all three groups. Interestingly, a similar distribution of 168 nervous system disorders associated with articaine was found by the European Medicines Agency based upon reports from 19 countries. Unfortunately, the impact of underreporting was not addressed, and sales data were omitted (Fig. 4.3).

Comparative data from 2001 to 2007 showed that reports of NSD associated with 4 % articaine-based formulations were significantly more frequent than those of other LAs, and articaine-related NSDs were significantly more numerous than would be expected from the proportion of its market share (Table 4.1). NSDs with lidocaine and prilocaine were equally underrepresented, whereas mepivacaine-related NSDs closely followed the market share. These data show a remarkable

Fig. 4.3 Nervous system disorders associated with articaine, $n = 168$ (Source: Periodic Safety Update Report, European Medicines Agency 2006–2009 [36])

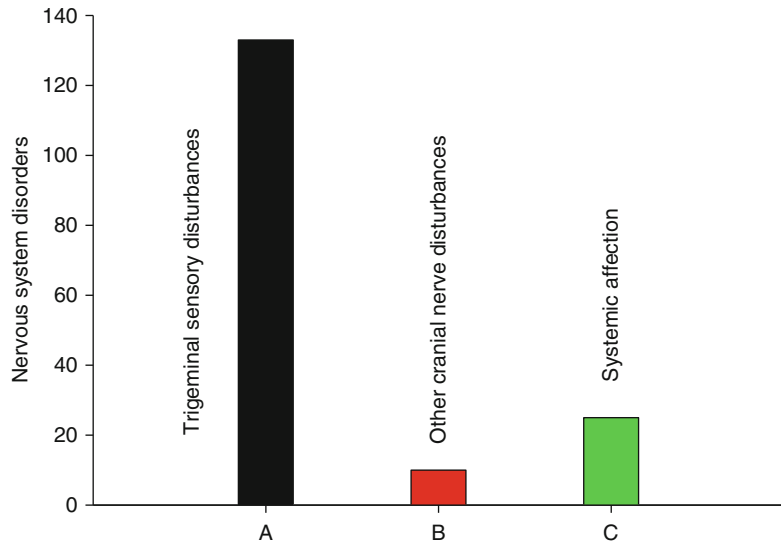


Table 4.1 Reports to the Danish Medicines Agency of trigeminal neurosensory disturbances (NSD) associated with local anesthetics sold in cartridges, 2001–2007 [6]

| Local anesthetic | Number of reports (%) | Market share of drug (%) | <i>P</i> value | Sales volume (l) | Ratio NSD to liters | Relative risk for articaine | |
|-------------------|-----------------------|--------------------------|---------------------|------------------|---------------------|-----------------------------|------------------|
| Articaine 4 % | 141 (77.9) | 41.2 | <0.001 ^a | 12,660 | 1:90 | Versus each drug | Versus all drugs |
| Mepivacaine 2–3 % | 13 (7.2) | 11.8 | =0.06 | 3,631 | 1:279 | 3.1 | 5.0 |
| Prilocaine 3 % | 12 (6.6) | 19.4 | <0.001 ^b | 5,957 | 1:496 | 5.5 | |
| Lidocaine 2 % | 15 (8.3) | 27.7 | <0.001 ^b | 8,512 | 1:568 | 6.3 | |

^aOverrepresentation (more than expected related to market share)

^bUnderrepresentation (less than expected related to market share)

similarity with the data of Garisto et al. [12] and Gaffen et al. [11]. Differences in the rate of prilocaine-associated NSD between North America and Europe [12] may be explained by the fact that prilocaine-based formulations in North America are 4 % and the vasoconstrictor is adrenaline, whereas the concentration of prilocaine in Europe is 3 % and the vasoconstrictor is felypressin.

4.3 Clinical Features and Nerve Involvement

A number of studies indicate that the LN is by far the most frequently involved trigeminal branch in LA-associated injuries followed by the IAN [5–7, 9]. This may be explained by the fact

that the LN is more superficial in the pterygo-mandibular space than the IAN, and upon mouth opening, the LN is stretched towards the surface mucosa, making it more vulnerable to injury (mechanic and/or chemical). Upon initial injection of LA, the LN may become anesthetized first, and if multiple needle passes are made, a shock-like sensation may not be experienced if the needle comes into contact with the LN itself. It has also been well documented that females are affected much more often than males [6, 7, 12], and this may be due to a gender difference in the ability to resolve spontaneously following neural trauma.

The specific individual NSD may be temporary, of short or longer duration, or permanent. A limited number of studies describe temporary NSD [1, 8, 11] with an estimated rate of

spontaneous recovery in 80–85 % of affected patients. Of the remaining 15–20 % of patients, less than one-third of these patients experience complete neurosensory recovery. Conversely, in our on clinical sample of 131 patients, only 7 % were temporary, while 20 % were potentially permanent, i.e., non-resolving less than 1 year after injury, and 73 % were permanent, i.e., persisting at 1 year after the injection or later [6].

The clinical symptoms may consist of any alteration of cortical perception of trigeminal afferent input, including gustatory perception transferred through the chorda tympani branch of the facial (VII) nerve. Most cases of NSD associated with local anesthetics are characterized as “paresthesia” in the literature [11, 12, 27]. “Numbness” is another popular term that may cover any sensation between mild paresthesia and complete anesthesia. Chronic pain is frequent in patients with LA-associated NSD [3, 4]. In fact, an array of neurologic discomfort may be perceived by the patients, each characterized by a specific neurological term such as hypesthesia, anesthesia, dysesthesia, allodynia, pain, and abnormalities related to gustation, (hypo-, dys-, or ageusia) [3, 6, 22]. Again, since there is a lack of consistency in the literature regarding standardization of terminology to classify the specific ADRs, it is difficult to determine the exact incidence or to determine spontaneous resolution of NSD.

Among our 42 patients with LN injection injuries in nonsurgical cases [3], 18 (43 %) complained of paresthesia, 9 (21 %) had dysesthesia expressed as burning pain, and 3 (7 %) suffered from mechanical allodynia. Only three patients (7 %) had no neuropathic complaint in addition to their functional loss. Thirty-three patients (79 %) had an altered gustatory perception, partial or total loss of gustatory function, or dysgeusia with an unpleasant taste (metallic, electric shock, etc.). Functional neurosensory loss in patients with LN affections was more disturbing than it was in patients with IAN lesions that concurred with clinical records of nerve function (tactile, thermal, and position sensations).

4.4 Etiology: Needle Lesion or Neurotoxicity?

The pathophysiological mechanisms behind these injuries and NSD may be multifactorial, but two different main causes, mechanical lesion and/or neurotoxic reaction, have been the focus of interest [28]. Methodological obstacles have hindered the search for the etiology of LA-associated trigeminal injury, such as randomized controlled trials (RCTs) being not feasible due to the rarity of these injuries, ethical issues, underreporting, marketing issues including commercial interests’ denial, and conflicts of interest. These barriers have precluded a simple explanation of the precise etiology of these injuries. Likewise, lack of proof of the significance of the needle injury, attitudes towards neurotoxicity as a causative mechanism based on emotional or commercial bindings, and denial beyond measurable evidence have confounded the issues, as well [26, 28–31]. Given the assumption of an equal safety profile for all LAs in current use, a distribution of ADRs including NSD would be expected to mirror the market share of each anesthetic, and such a distribution would be suggestive of needle lesion etiology, whereas a distribution disproportionate to market shares would indicate differences in safety profile (neurotoxicity) [6].

Needle Lesion—Theoretically, direct mechanical needle lesion may cause severance of axons, maybe even some of the fascicles within the nerve itself. Such a lesion would expectedly be reflected in a patchy pattern of NSD affecting the area of innervation of each affected neuron/fascicle, not the distribution of the entire nerve branch. Furthermore, mechanical injury to the *vasa nervorum* may cause hypoxic nerve damage or reactions associated with intraneural hematoma formation, organization with granulation and scar tissue, or toxic blood decay. Local anesthetic-associated NSD in general affects the entire distribution of the affected nerve branch. Pogrel and colleagues [8] wondered how a needle with a diameter of less than ½ mm could produce “such profound damage to the entire nerve.” Direct needle contact with a nerve may be the cause of a painful “electric shock” experience; however, for

the reasons mentioned above, this phenomenon may not be commonly experienced by patients. Harn and Durham [1] considered such a “traumatic episode” the main focus of the mechanism of injury. Conversely, Krafft and Hickel [24] in a prospective study observed an electric shock reaction in only 7 % of more than 12,000 patients upon injection of LA; none of these patients affected complained of subsequent NSD. Hillerup and Jensen [3] reported electric shock reactions in 32 % of patients with LA-induced lingual NSD and 33 % related to IAN injury. Interestingly, the severity of NSD did not differ between those patients that experienced an electric shock and those who did not.

Neither studies in humans nor animals [15, 17, 32] support the idea of physical lesion to be a the mechanism of LA-induced NSD; in fact, surgical exploration of four LNs in patients with nonsurgical paresthesia showed no evidence of physical damage to the nerve caused by the needle [7].

Neurotoxicity—Haas and Lennon [9] noted an increase in reported paresthesia rates after the launch of 4 % formulations of articaine and prilocaine in Canada in 1984 and a significant overrepresentation of these drugs in reports of ADRs. Recent studies from North America and Denmark demonstrate that the distribution of NSDs is disproportionate to the market share of commonly used drugs in both national registry data [11, 12] and clinical data [6]. There is a highly significant overrepresentation of NSD associated with 4 % formulations of articaine and prilocaine in accordance with a previous Canadian study [9], with a corresponding underrepresentation of NSDs due to lidocaine.

The concentration issue of neurotoxicity has been confirmed in several experimental studies [13, 14, 16, 17]. Similarly, the physical trauma of needle penetration with the injection of saline solution did not produce a significant reduction of nerve conduction as reflected in measured amplitudes on stimulation in two animal experiments [16, 17]. Additionally, it has also been shown experimentally in the cadaver model that needle penetration of the trigeminal nerve (both the LN and IAN) is likely to result in the needle passing through the interfascicular space, rather than result in direct fascicular damage [8].

It may be concluded that among the etiologic factors in question, direct needle trauma is of minor importance.

Neurotoxicity appears to be the most significant causative factor considering the disproportionate distribution of ADRs including NSD-to-market share, the correlation of neurotoxic reactions with the concentration of the drug, and animal studies showing concentration-dependent neurotoxicity [14, 15, 17, 33]. The vasoconstrictor must also be considered since the ischemic effect may exacerbate the neural injury by impeding blood flow to heal the damaged area.

4.5 Toxicity of Local Anesthetics: Systemic and Local

Since the introduction of amide-based LA, systemic toxicity is hardly an issue in dentistry, including oral and maxillofacial surgery.

Conversely, all LAs are, in principle, neurotoxic, and local neurotoxicity is a potential hazard that deserves attention. A nerve conduction block has been explained as a “reversible toxic effect of LA” where the neurotoxicity parallels its anesthetic potency [34]. Nerve injury may result from direct toxicity to the axon or Schwann cell or may be secondary to disruption of the nerve microenvironment [35]. The mechanism is not completely understood, but factors of importance are the concentration of the LA and the duration of exposure of the neural tissue to the LA [14]. Likewise, the chemical composition, lipid solubility, and protein binding of the LA may all play a role in the toxic effects. Finally, contributing factors might be mechanical neural trauma and ischemia, both of which may be deleterious [34].

Kalichman et al. [33] used quantitative measurements of endoneurial edema, cytoplasmic lipid droplets, nerve fiber injury, and Schwann cell damage to elucidate the pathogenesis of LA-induced injury to the sciatic nerve in rats and found these data to be consistent with a direct cellular toxicity of four local anesthetic solutions. All four drugs produced a concentration-dependent increase in every measure of neural injury.

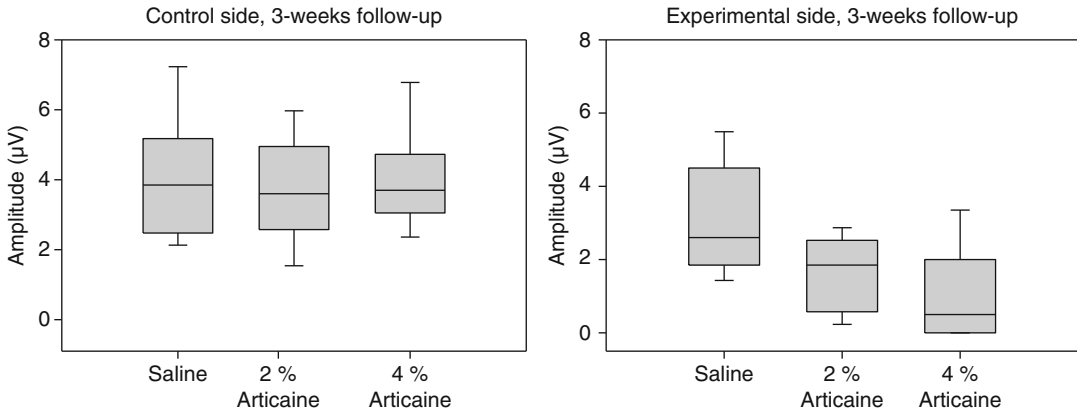


Fig. 4.4 Box plot of amplitudes (median values, inter-quartile range, extreme values) of lumbar-evoked electrospinograms at the 3-week follow-up after intraneural injection of test substance in the right sciatic nerve in rats. Control side (untreated) and experimental side showing

the three injection groups (saline, articaine 2 %, articaine 4 %) indicating significant concentration-dependent depression of amplitudes in the articaine 2 % group ($P=0.03$) and 4 % group ($P=0.0006$) [17] (Reprinted with permission from Anesthesia and Analgesia)

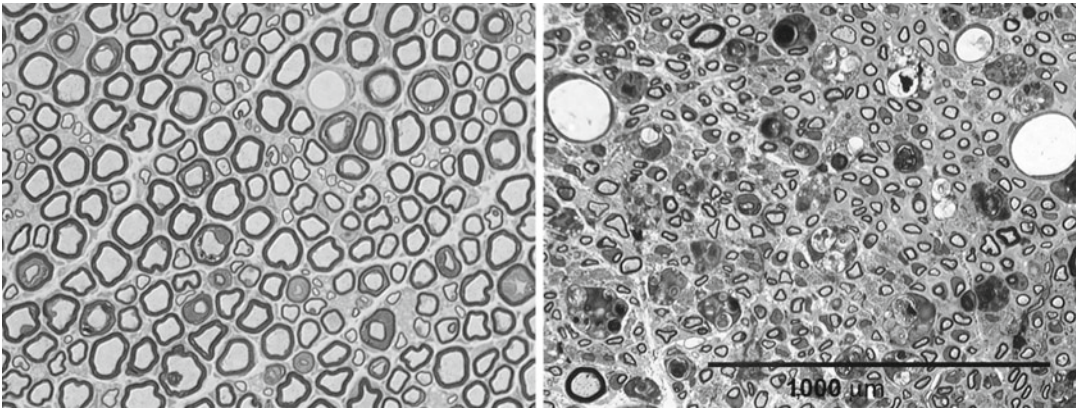


Fig. 4.5 Electron micrographs of nerve cross sections from a saline-treated rat (left) and a rat injected with articaine 4 % (right) showing obvious features of axonal and myelin degeneration 3 weeks after intraneural injection. The number of myelinated axons is the same in the two treatment groups, but in the group injected with articaine 4 %, the axons are much smaller and the endoneurial

connective tissue increased. Few remnants of degenerating nerve fibers are seen, and several of the smallest myelinated axons are surrounded by a nucleated Schwann cell, indicating regeneration. Magnification bar shown in the picture is 1,000 μm . Stain: osmium tetroxide and toluidine blue [17] (Reprinted with permission from Anesthesia and Analgesia)

Compromised nerve conduction may be reflected electrophysiologically by a lowered or extinct action potential amplitude and axonal and myelin degeneration as measurable effects of drug toxicity. A number of experimental studies have identified a clear association between neurotoxicity and the concentration of LA [13–17].

A recent study on concentration-dependent neurotoxicity of 2 and 4 % formulations of

articaine injected into the rat sciatic nerve with injection of saline as the control group [17] showed depression of lumbar-evoked spinograms as a sign of substantial neurotoxic reaction increasing with the concentration of the drug (Fig. 4.4). Electron micrographs of histological nerve cross sections from the same study showed marked axonal and myelin degeneration in nerves injected with 4 % articaine as compared to saline injected nerves (Fig. 4.5).

In accordance with previous and recent animal studies [13, 14, 16, 17], independent studies on reports to national and international registries of ADRs, in particular trigeminal NSD [6, 11, 12, 36], link these expressions of nerve injury to a significant overrepresentation of NSD associated with 4 % formulations of articaine and prilocaine. Likewise, the distribution of ADRs/NSDs was significantly disproportionate to the market share of LA drugs in current use which (indirectly) excludes needle trauma as a major contributing factor, since, had it been so, the ADRs/NSDs would mirror the market share of each anesthetic.

4.6 Treatment Options

There is no indication that surgery is helpful for LA-associated NSD. While mechanical nerve injury associated with third molar surgery may be managed with successful microsurgical repair [37–40], non-resolving chemical (neurotoxic) lesions unfortunately do not offer such potential for surgically assisted recovery. The reason for this is that the injury from the third molar surgical insult is most likely to occur in the third molar region, and surgical access is feasible via a standard transoral approach. In contrast, surgical access to the pterygomandibular space for microneurosurgical exploration of a LA-related injury is difficult or impossible from a transoral or transcervical surgical approach. Further, a chemical lesion may be impossible to visualize clinically. Likewise, curative medical treatment is not an option. Reassurance and counseling may work in less disturbing cases, and topical application of lidocaine 5 % or similar medicament may lessen the symptoms in selected severe cases [22]. Patients with severe neuropathic pain or dysesthesia may be relieved with pharmacologic treatments including gabapentin or similar anti-epileptic or antidepressant drugs [41]. However, these drugs are associated with some stressful side effects, including drowsiness, that may override a vague but distressing NSD. It may be advisable to emphasize that even serious neuropathic symptoms may decrease over time, and coping strategies may help patients come to terms

with the situation. Indeed, there is no ideal solution to this complex clinical dilemma.

4.7 Preventative Measures

In the absence of rewarding treatment options, it seems logical to focus on preventative measures and risk assessment in the choice of the ideal local anesthetic. Since more than 90 % of all LA-associated NSDs are related to inferior alveolar nerve blocks [6, 11, 12], and the majority of NSDs are linked to the injection of 4 % formulations, it might seem prudent and responsible to avoid these formulations for mandibular IAN blocks and consider the use of alternative formulations.

Another option is to report each and every incidence of LA-associated NSD and other ADRs to the relevant national registry database. Even though such action may seem to have little influence on the FDA and national and regional medicines agencies' responsive action, even in more dramatic ADRs [42], there is no other way to influence authorities, accumulate evidence, and make differences in risk profile known.

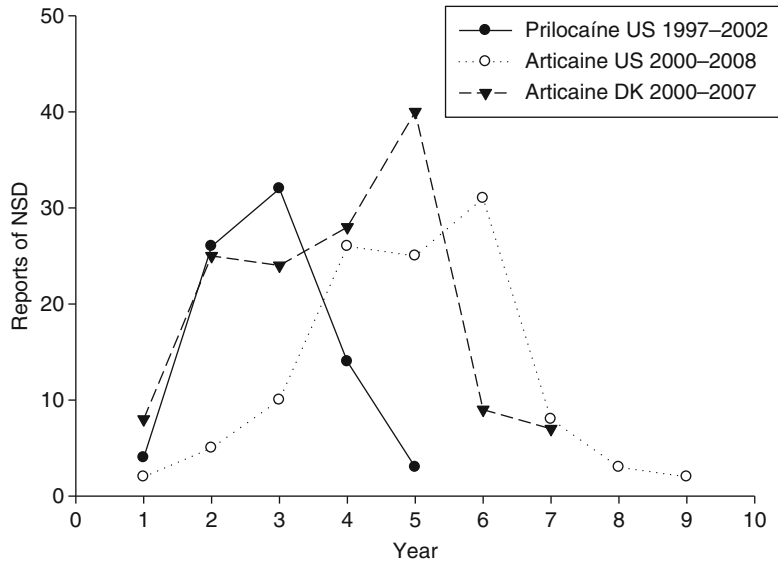
Patient education, case histories of ADRs in the press and on the internet, and similar release of information including scientific data may alert patients to demand the LA with the lowest risk in the presence of viable alternative options. It is the experience of the author that informed patients prefer the less risky formulations—for obvious reasons.

There are data to indicate that both the dental community and the patients react in an appropriate manner. Comparable studies from the USA and Europe on reported NSD show an identical pattern of rise and fall of the number of reported incidences with 4 % formulations of prilocaine and articaine per year (Fig. 4.6).

Conclusions

Primum non nocere (first, do no harm). This Hippocratic axiom still applies to all health care delivery. Medical and dental health professionals in specialties performing surgery or painful dental treatment and patients alike are in the lucky position that pain-free treatment is easily achieved through LA and harmful effects of LA are rare.

Fig. 4.6 Reports of neurosensory disturbance (NSD) associated with 4 % formulations of prilocaïne and articaine in USA, and articaine in Denmark, from time of launch and onwards showing a rise and fall in reported NSDs over time [6, 12]



The clinical efficacy of current local anesthetics does not differ significantly when administered appropriately [43, 44], and the choice of formulation may be directed by the desired duration of action [10]. Conversely, the risk profile is not equal for the four common local anesthetics used in dentistry and oral and maxillofacial surgery: lidocaine, mepivacaine, prilocaïne, and articaine. It is accepted that a higher concentration of the LA is associated with a higher risk of ADRs. More than 90 % of such iatrogenic nerve injuries, reflected in neurosensory disturbances, are related to mandibular blocks, and the vast majority of reports of trigeminal ADRs relate to 4 % formulations.

It is the responsibility of national and regional medical agencies and the FDA to approve, disprove, and regulate distribution and application patterns for maximum patient safety. The reluctance of these institutions towards responsive action to studies showing overrepresentation of neurosensory disturbance associated with 4 % formulations of articaine in Europe and 4 % formulations of articaine and prilocaïne in North America is difficult to understand. A sensible guideline would be to avoid 4 % formulations for block anesthesia in the presence of viable alternatives, and in fact, this is the current teaching in most dental

schools in the USA at the present time, and this may result in a decreased incidence of nonsurgical paresthesia in dental practice.

References

1. Harn SD, Durham TM (1990) Incidence of lingual nerve trauma and postinjection complications in conventional mandibular block anaesthesia. *J Am Dent Assoc* 121:519–523
2. Pogrel MA (2007) Permanent nerve damage from inferior alveolar nerve blocks – an update to include articaine. *J Calif Dent Assoc* 34:271–273
3. Hillerup S, Jensen R (2006) Nerve injury caused by mandibular block analgesia. *Int J Oral Maxillofac Surg* 35:437–443
4. Renton T, Adey-Viscuso D, Meechan JG, Yilmaz Z (2010) Trigeminal nerve injuries in relation to the local anaesthesia in mandibular injections. *Br Dent J* 209(9):E15
5. Hillerup S (2007) Iatrogenic injury to oral branches of the trigeminal nerve: records of 449 cases. *Clin Oral Investig* 11(2):133–142
6. Hillerup S, Jensen RH, Ersboll BK (2011) Trigeminal nerve injury associated with injection of local anesthetics: needle lesion or neurotoxicity? *J Am Dent Assoc* 142(5):531–539
7. Pogrel MA, Thamby S (2000) Permanent nerve involvement resulting from inferior alveolar nerve blocks. *J Am Dent Assoc* 131:901–907
8. Pogrel MA, Bryan J, Regezi J (1995) Nerve damage associated with inferior alveolar nerve blocks. *J Am Dent Assoc* 126(8):1150–1155

9. Haas DA, Lennon D (1995) A 21 year retrospective study of reports of paresthesia following local anaesthetic administration. *J Can Dent Assoc* 61:319–330
10. Haas DA (2002) An update on local anesthetics in dentistry. *J Can Dent Assoc* 68(9):546–551
11. Gaffen AS, Haas DA (2009) Retrospective review of voluntary reports of nonsurgical paresthesia in dentistry. *J Can Dent Assoc* 75(8):579
12. Garisto GA, Gaffen AS, Lawrence HP, Tenenbaum HC, Haas DA (2010) Occurrence of paresthesia after dental local anesthetic administration in the United States. *J Am Dent Assoc* 141(7):836–844
13. Kalichman MW, Moorhouse DF, Powell HC, Myers RR (1993) Relative neural toxicity of local anesthetics. *J Neuropathol Exp Neurol* 52(3):234–240
14. Kroin J, Penn R, Levy F, Kerns J (1986) Effect of repetitive lidocaine infusion on peripheral nerve. *Exp Neurol* 94:166–173
15. Cornelius CP (1997) Nerveninjektionsschäden durch Lokalanästhetika. Experimentelle Untersuchungen zur Neurotoxizität und Longitudinalausbreitung. Thesis ed. Tübingen
16. Cornelius CP, Roser M, Wiethölter H, Wolburg H (2000) Nerve injection injuries due to local anaesthetics. Experimental work. *J Cranio Maxillofac Surg* 28(suppl 3):134–135
17. Hillerup S, Bakke M, Larsen JO, Thomsen CE, Gerds TA (2011) Concentration-dependent neurotoxicity of articaine: an electrophysiological and stereological study of the rat sciatic nerve. *Anesth Analg* 112(6):1330–1338
18. Calatayud J, González Á (2003) History of the development and evolution of local anesthesia since the coca leaf. *Anesthesiology* 98(6):1503–1508
19. Baart JA, Brand HS editors (2009) Local anesthesia in dentistry, 2nd edn. Blackwell
20. Zink W, Graf BM (2003) Toxikologie der Lokalanästhetika. Patomechanismen – Klinik – Therapie. *Anaesthetist* 52:1102–1123
21. Bremer G, Ekmanner S (1948) Xylocaine; a new local anaesthetic. *Br Dent J* 85(12):278–281
22. Renton T, Yilmaz Z (2012) Managing iatrogenic trigeminal nerve injury: a case series and review of the literature. *Int J Oral Maxillofac Surg* 41:629–637
23. Hazell L, Shakir SA (2006) Under-reporting of adverse drug reactions: a systematic review. *Drug Saf* 29(5):385–396
24. Krafft TC, Hickel R (1994) Clinical investigation into the incidence of direct damage to the lingual nerve caused by local anaesthesia. *J Craniomaxillofac Surg* 22:294–296
25. Malamed SF, Gagnon S, Leblanc D (2001) Articaine hydrochloride: a study of the safety of a new amide local anaesthetic. *J Am Dent Assoc* 132:177–185
26. Dower JS (2007) Articaine vs. lidocaine. *J Calif Dent Assoc* 35:240–244
27. Haas DA (2006) Articaine and paraesthesia: epidemiological studies. *J Am Coll Dent* 73:5–10
28. Dower JS (2007) Anesthetic study questioned. *J Am Dent Assoc* 138:708–709
29. Malamed SF (2006) Nerve injury caused by mandibular block analgesia. *Int J Oral Maxillofac Surg* 35(9):876–877
30. Pogrel MA (2007) Permanent nerve damage from inferior alveolar nerve blocks – an update to include articaine. *J Calif Dent Assoc* 35(4):271–273
31. Malamed SF (2007) Articaine versus lidocaine: the author responds. *J Calif Dent Assoc* 35:383–385
32. Fried K, Frisen J, Mozart M (1989) De- and regeneration of axons after minor lesions in the rat sciatic nerve. Effects of microneurography electrode penetrations. *Pain* 36(1):93–102
33. Kalichman MW, Powell HC, Myers RR (1989) Quantitative histologic analysis of local anesthetic-induced injury to rat sciatic nerve. *J Pharmacol Exp Ther* 250(1):406–413
34. Selander D (1993) Neurotoxicity of local anesthetics: animal data. *Reg Anesth* 18(6 Suppl):461–468
35. Kalichman MW (1993) Physiologic mechanisms by which local anesthetics may cause injury to nerve and spinal cord. *Reg Anesth* 18(6 Suppl):448–452
36. European Medicines Agency (2009) Periodic safety update report on articaine, nervous system disorders. Source: Danish Medicines Agency 2009
37. Bagheri SC, Meyer RA, Khan HA, Kuhmichel A, Steed MB (2010) Retrospective review of microsurgical repair of 222 lingual nerve injuries. *J Oral Maxillofac Surg* 68:715–723
38. Hillerup S, Stoltze K (2007) Lingual nerve injury II. Observations on sensory recovery after micro-neurosurgical reconstruction. *Int J Oral Maxillofac Surg* 36(12):1139–1145
39. Robinson PP, Loescher AR, Smith KG (2000) A prospective, quantitative study on the clinical outcome of lingual nerve repair. *Br J Oral Maxillofac Surg* 38:255–263
40. Zuniga JR, Chen N, Philips CL (1997) Chemosensory and somatosensory regeneration after lingual nerve repair in humans. *J Oral Maxillofac Surg* 55:2–13
41. Dworkin RH, O'Connor AB, Backonja M et al (2007) Pharmacologic management of neuropathic pain: evidence-based recommendations. *Pain* 132(3):237–251
42. Moore TJ (1995) Deadly medicine, why tens of thousands of heart patients died in America's worst drug disaster. 1st edn. Simon & Schuster, New York. <http://www.medicine.ox.ac.uk/bandolier/band23/b23-8.html>
43. Kanaa MD, Whitworth JM, Meechan JG (2012) A comparison of the efficacy of 4 % articaine with 1:100,000 epinephrine and 2 % lidocaine with 1:80,000 epinephrine in achieving pulpal anesthesia in maxillary teeth with irreversible pulpitis. *J Endod* 38(3):279–282
44. Silva LC, Santos TD, Santos JA, Maia MC, Mendonça CG (2012) Articaine versus lidocaine for third molar surgery: a randomized clinical study. *Med Oral Patol Oral Cir Bucal* 17(1):140–145

Third Molar Injuries of the Trigeminal Nerve

5

Eduard Valmaseda-Castellón
and Cosme Gay-Escoda

Third molar extraction is one of the most common procedures performed in oral and maxillofacial surgery. Among the possible complications, damage to the neighboring branches of the trigeminal nerve is a most dreaded complication. Although it is transient in most cases, it can leave permanent sequelae, such as hypoesthesia or dysesthesia, with a great impact on the patient's quality of life. In the lower third molar area, the lingual nerve (LN) usually lies under the mucosa overlying the lingual cortical plate. Surgical trauma to the LN during extraction of the lower third molar is caused by inadequate handling of either the lingual cortical plate or the mucosa on the lingual aspect of the wound. Preventive measures to avoid LN injury include (1) a buccal approach without elevating or separating a lingual flap and (2) caution when removing bone or sectioning the tooth, not to perforate the lingual cortical plate. Damage to the inferior alveolar nerve (IAN) is generally related to an anatomical

proximity between the third molar roots and the mandibular canal. This close relationship can be suspected using orthopantomography or intraoral radiographs but only confirmed with computed tomography (CT). Surgical techniques that reduce excessive forces or prevent nerve impingement during lower third molar extraction and postoperative care that minimizes edema are the keys to avoiding long-term IAN injury.

5.1 Introduction

Trigeminal nerve damage is a well-known severe complication of lower third molar extraction. Indeed, lower third molar extraction is still the main cause of inferior alveolar nerve (IAN) and lingual nerve (LN) injuries [1]. Thus, IAN and LN injury must be included in the informed consent, because of both their prevalence (which can be estimated at 0.5–8.0 % for the IAN [2–10] and at 0 % to over 10 % for the LN [5, 7–15]) and their potential impact on the patient's everyday life. With pain and swelling, the most remembered possible complications explained in the informed consent are IAN and LN injuries [16]. This reflects the importance of this impairment for the patient. Besides, more than a half of the IAN injuries caused by lower third molar (L3M) extraction take several months to recover, and up to 25 % do not recover completely, leaving some degree of hypoesthesia or, in a worst case scenario, dysesthesia [17]. Thus, trigeminal nerve injury after L3M is not only disabling for a short

E. Valmaseda-Castellón, DDS, PhD (✉)
Faculty of Dentistry, IDIBELL Institute,
University of Barcelona,
Barcelona, Spain
e-mail: eduardvalmaseda@ub.edu

C. Gay-Escoda, DDS, MD, PhD
Faculty of Dentistry, IDIBELL Institute,
University of Barcelona,
Barcelona, Spain

Department of Oral and Maxillofacial Surgery,
Teknon Medical Center, Barcelona, Spain
e-mail: cgay@ub.edu

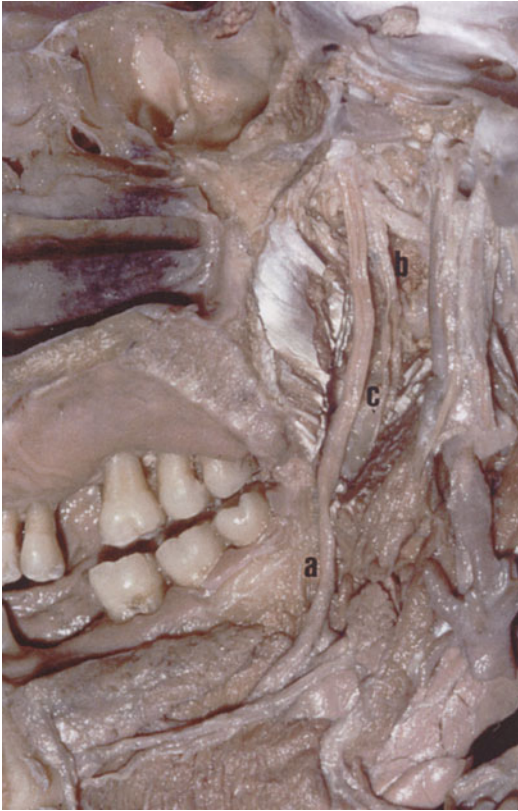

Fig. 5.1 Medial view of a sagittal section of a human cadaver (medial pterygoid muscle removed) showing the course of the lingual nerve (a), the inferior alveolar nerve (b), and the mylohyoid nerve (c) in the L3M region (Preparation of Prof. Dr. Alfonso Rodríguez, Chairman of Anatomy and Embriology of the Universitat Autònoma de Barcelona (UAB))

time, but it can become a lifelong sequelae causing a severe reduction of the patient's quality of life [18].

Although local anesthesia can itself cause LN or IAN damage [1, 19, 20], the main cause of this lesion in L3Ms is surgical trauma. IAN injury usually results from an anatomical proximity between the roots of the L3M and the mandibular canal. It is, therefore, possible to anticipate such risk using adequate imaging techniques. However, the LN in the L3M region, unlike the IAN, lies under the mucosa and is not surrounded by an osseous canal (Fig. 5.1). Therefore, it is not possible to anticipate with certainty the position of the LN using routine radiographs, such as intraoral projections or orthopantomography. At the L3M region, the LN is at 2.8 mm below the

crest (SD 1 mm) and at 2.5 mm of the lingual cortical plate (SD 0.7 mm), although it can be in contact with the cortical bone and lie over the crest [21]. Besides, the position of the LN on one side seems to be independent from the position of the opposite side [20]. Magnetic resonance imaging (MRI) can identify the position of the LN [21], but it is not a routine imaging technique, so the only way to prevent LN injury is to keep the incision away from the lingual side of the wound, to avoid instrumentation in that area, and not to damage the lingual cortical plate [22].

An important difference between LN and IAN, as mentioned above, is that the latter has an intraosseous course, which protects it against damage and in case of sectioning, provides a scaffold for nerve regeneration. Unfortunately, in case of compression, the stiffness of the mandibular canal can foster nerve damage, especially in case of swelling or bleeding within the canal. As the LN lies within soft tissue, close to the lingual cortical plate, it is more exposed to compression, and scratching or catching can occur more easily as a result of the use of retractors, burs, or other surgical instruments.

There are other nerves that can be also damaged as a result of L3M extraction. The mylohyoid nerve, a branch of the IAN, innervates the mylohyoid muscle, the anterior belly of the digastric muscle, the skin of the inferior part of the chin, the submandibular and sublingual glands, and, in approximately half of the cases, the lower incisors [23, 24]. Its impairment is much more infrequent and less noticeable by the patient than that of the IAN, since it affects only a small skin area in the lower part of the chin, close to the midline. However, the etiology and pathogenesis of neural damage is quite similar to the injury of the LN.

Finally, the buccal nerve can also be damaged as a result of L3M extraction. This nerve, which must be anesthetized to extract the L3M, is formed by sensory fibers carrying input from the buccal mucosa, the buccal gingiva and mucosa of the lower molars (and eventually premolars), and the skin. It can be damaged as a result of excessive reflection of the buccal flap or in the rare cases of an intraosseous course of the buccal nerve, but this injury seems to be very uncommon.

5.2 Etiology and Prevention of Damage to the Lingual Nerve

There is a great variation in the dental literature regarding the prevalence of LN injury after L3M extraction. This fact reflects important differences in the management of the soft and hard tissues on the lingual side of the L3M.

5.2.1 Buccal Versus Lingual Approach for L3M Removal

The L3M usually lies closer to the lingual cortical plate, which is considerably thinner than the buccal plate. This anatomic difference is the rationale for the so-called lingual split technique, which consists of removing the thin lingual cortical plate using a chisel or a bur and extracting the L3M through the resulting lingual opening. The lingual split is performed quickly and simply, but manipulation on the lingual side of the L3M renders an unacceptably high prevalence of LN injuries [11]. Despite the claim that these injuries are transient in nature, it must be taken into account that any nerve compression or scratching can cause axonal degeneration. Thus, the ideal situation is to avoid all types of nerve manipulation and possible injury, even mild traction on the nerve. Indeed, a systematic review has confirmed that the lingual approach causes significantly more LN injuries than the standard buccal approach [25].

In uncommon cases, the LN can lie over the crest distal to the lower second molar covering the impacted L3M. This situation places it at risk in case of surgical L3M extraction, since the incision can section or scratch the nerve [21, 22]. Thus, it is advisable to stay away from the crest distal to the second molar and to place the incision slightly towards the buccal mucosa in a distobuccal extension (Fig. 5.2). The buccal approach requires a greater amount of bone removal than the lingual approach, but it is safer for the LN. However, the non-raised soft tissues of the lingual side of the wound often limit the surgeon's vision. To facilitate it and to "protect" the lingual soft tissues and the lingual cortical plate during bone removal or tooth sectioning,

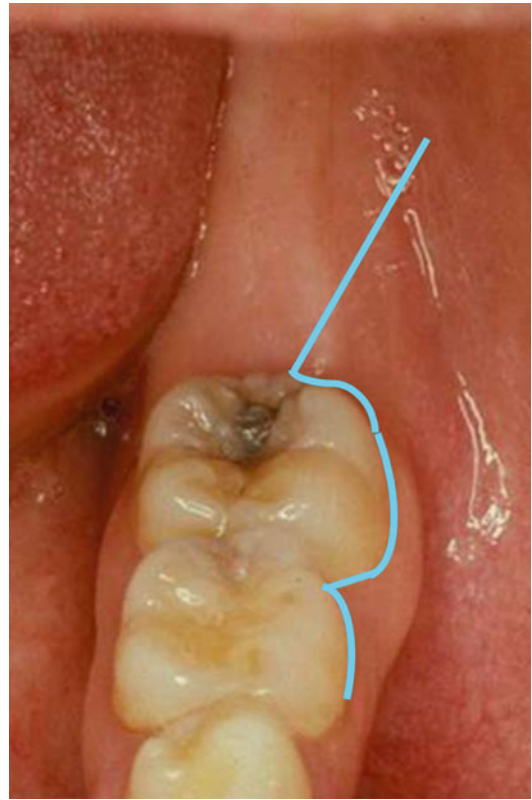


Fig. 5.2 Design of an envelope flap for L3M extraction (blue line). The incision over the impacted L3M should be slightly buccal to the crest, from the distobuccal aspect of the adjacent lower second molar towards the external oblique ridge. Avoiding the crestal bone over the L3M eliminates the possibility of LN section if the LN is over the crest

different separators have been proposed [26, 27]. In the past, some authors thought that the wider the retractor on the lingual side of the flap, the better, because it increased the risk of transient LN injury but decreased the risk of a permanent damage. However, as lingual retraction itself has been recognized as a major risk factor of LN damage, as reported in the next section, the use of retractors has been progressively abandoned.

5.2.2 Use of Separators to Retract the Lingual Flap

As mentioned above, different types of separators have been advocated to retract the lingual flap during L3M extraction. They are inserted between the lingual cortical plate and the mucosa of the

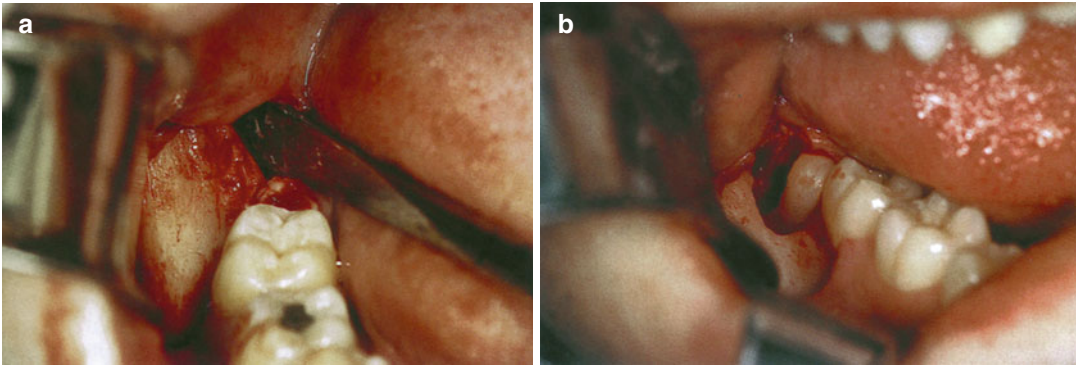


Fig. 5.3 (a) Insertion of a separator (Freer periosteal) gives better vision of the bone distal to the lower second molar and prevents accidental impingement of the bur in the lingual flap. However, it traumatizes the soft tissues of the lingual side of the wound and causes an increase in LN

injuries. (b) It is advisable to use only a buccal approach, without separating the soft tissues on the lingual side of the wound. The flap yields a good vision and does not put the LN at risk (Images reprinted with permission from Gargallo-Albiol et al. [32])

lingual side of the flap (Fig. 5.3) in order to better visualize the bone that covers the L3M and to “protect” the lingual flap from any elevator or bur trauma. This “protection,” sometimes performed with quite wide instruments to cover a larger area, has been traditionally recommended [12]. Failure to prove that the lingual flap was retracted has even resulted in medicolegal problems [28].

However, many publications have shown that reflecting the lingual tissues during L3M extraction does not avoid, and even favors, the occurrence of LN injuries [5, 12, 29–31]. A systematic review has demonstrated that the buccal approach, without any lingual tissue retraction, causes approximately nine times less transient injuries than the same approach with retraction of the lingual soft tissues [25]. On the other hand, a randomized controlled trial (RCT) at our institution demonstrated three times more LN injury when the lingual flap was retracted, although this difference was not significant due to small sample size and low prevalence of LN damage [32]. The major role played by lingual flap retraction in the etiology of LN injuries was confirmed after a report showed how lingual flap retraction was associated with transient LN injuries [31]. As a result, the surgical technique was modified to avoid lingual flap tissue manipulation, and then the number of transient LN injuries was divided by four [33]. An RCT has confirmed that lingual

flap retraction significantly increases transient LN damage [34]. Therefore, current evidence suggests not only that the buccal approach is safer for the LN than the lingual approach, but the buccal approach should be performed without any retraction of the lingual tissues, if possible.

5.2.3 Use of Burs or Chisels

Currently the preferred method for bone removal in L3M extractions is with the use of a bur and a handpiece. However, especially when using the lingual split technique, bone removal can be accomplished with a chisel. Although some reports have concluded that chisels are safer and associated with less IAN injuries [5], this is not valid since burs are easy to control and allow very precise bone removal as opposed to chisels.

Today there are several other instruments that can be used to remove bone. Er:YAG or Er,Cr:YSGG lasers can perform very controlled bone removal and even tooth sectioning (Fig. 5.4) [35]. However, although some lasers are very precise and gentle tools for bone removal, tooth sectioning is usually performed using a rotating bur, which is considerably faster and allows better tactile control of deep tooth sectioning. Also piezosurgery can be used to remove bone during L3M extraction [36]. Although the postoperative

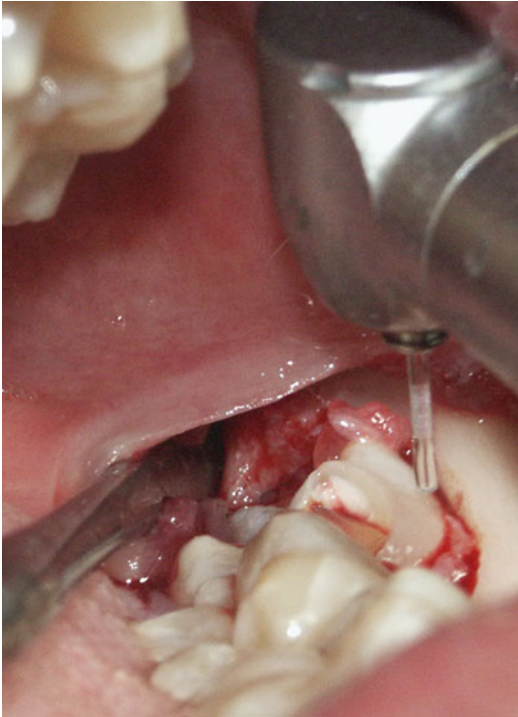


Fig. 5.4 Extraction of a L3M using Er,Cr:YSGG laser. The optic fiber tip allows a precise and effective bone removal. Tooth sectioning can also be performed using the same technology, but for practical reasons a hand-piece is often used (Courtesy of Dr. Josep Arnabat-Domínguez, Professor of Oral Surgery of the University of Barcelona and Codirector of the EMDOLA Master Degree. Barcelona, Spain)

course seems to be comparable to the conventional osteotomy using burs, the piezosurgery instrument, unlike the bur, does not cause harm if it contacts the IAN or LN. But, piezosurgery is slower to perform, and there is limited evidence on its potential beneficial effects in L3M removal.

5.2.4 Integrity of the Lingual Cortical Plate

During bone removal, and especially tooth sectioning, care must be taken so that the lingual cortical plate is not perforated. An attempt to complete the extraction in the minimal possible time can

lead to careless grinding of the bone beyond the L3M tooth. As the roots usually lie very close to the lingual cortical plate, or even perforate it occasionally, there is a risk of penetration through this thin cortical into the soft tissues on the lingual side. Perforation of the periosteum can directly damage the LN or cause fibrosis that can compress the nerve during healing.

It is of utmost importance to maintain the lingual cortical plate in an undamaged condition since it is functioning to protect the LN. Allowing adequate time to plan and perform any root or tooth sectioning of the L3M, avoiding excessive stretching of the lingual soft tissues, and maintaining an undisturbed visualization of the surgical field are the keys to avoid placing the lingual cortical plate, and thus, the LN, at risk for iatrogenic injury.

5.2.5 Wound Cleaning and Suture

Suture placement has not been identified as a significant risk factor of LN injuries in L3M extraction. However, in surgical L3M extractions, the surgeon should consider the possibility of a close relationship of the LN and the crestal bone distal to the adjacent second molar and avoid placing the sutures too inferior on the lingual side.

After the removal of partially erupted L3M, any fibrotic, cystic, or inflammatory tissue should be carefully removed to facilitate primary wound closure and prevent degeneration of those tissues into cysts or tumors. However, caution should be applied when removing soft tissue after the extraction, such as fibrous tissue or remnants of the dental follicle since the IAN may be exposed in the socket. Good vision of the lingual side of the wound and avoiding excessive stretching of the tissues are important to avoid damaging the LN, in case it lies close to the distal bone of the second molar. Excessive stretching or tissue removal must be avoided, and it is better not to obtain primary closure of the wound rather than risking an LN damage. In case of an iatrogenic LN injury from suturing, the cause can be the

wound caused by the needle or compression due to the suture thread. Any transient LN paresthesia is likely from a compressive injury to the LN from the suture, and this will likely resolve spontaneously.

5.2.6 Experience of the Surgeon

Some reports have shown that senior surgeons seem to cause significantly more LN injuries during L3M extraction [11, 29]. This fact could be related to a selection bias (senior surgeons tend to operate the deepest or more difficult L3Ms) or due to the use of a more aggressive technique. In fact, the prevalence of LN injuries in these reports is very high (from 11.5 to 36.0 % for senior surgeons). Moreover, in one of these reports [29], the correlation between depth of impaction and LN injury was only appreciated in L3M operated by senior surgeons under general anesthesia, which supports the probable explanation of a more aggressive technique.

Indeed, at least for buccal approaches to L3M extraction, surgical inexperience seems to be associated to LN injuries only when the lingual soft tissues are elevated to place a separator, since lingual flap retraction is the most relevant cause of LN injury as discussed above [31]. Indeed, the opposite has also been found, and there are certainly other reports that indicate that resident surgeons in training have a higher incidence of IAN and LN injuries than faculty surgeons and that the surgical time is increased for the more inexperienced surgeons.

5.2.7 Age

Although some reports suggest that the prevalence of trigeminal nerve injuries could slightly increase with age [10, 37], prevalence of LN injury after L3M extraction does not seem to depend on age [31, 33], as much as it does with IAN injury [38, 39]. Other reports do show a clear association between postoperative L3M extraction and paresthesia, as well as other complications, in the older patient population.

5.3 Etiology and Prevention of Damage to the Inferior Alveolar Nerve

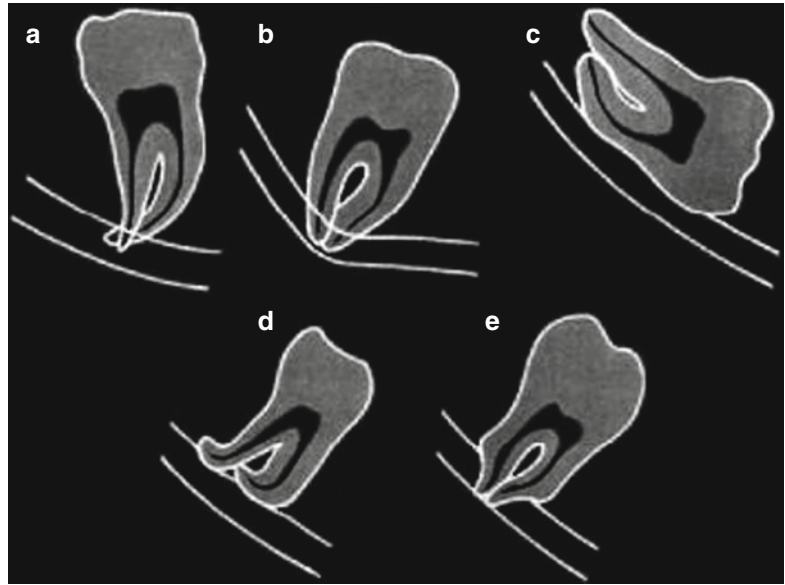
The most important risk factor for IAN injuries caused by L3M extraction is the anatomical proximity between the roots of the third molar and the mandibular canal. Thus, prevalence of IAN injuries is not only technique-dependent, but, instead, it depends upon preoperative factors that can be identified with a thorough clinical and radiological examination. As a result, the range of prevalence of IAN injury caused by L3M extraction is not as broad as in the case of LN injuries.

5.3.1 Germenectomy Versus Delayed Extraction

Germenectomies, or surgical extractions of L3M whose roots have not developed or have less than two thirds of root formation, have a significantly lower risk of IAN injury, with the percentage of IAN impairment being 0–0.3 % [40, 41]. This is probably due to several factors including (1) the root is separated from the mandibular canal and it usually gets closer to it as the root grows, (2) the bone is more flexible in teenagers than in adults, and (3) the force that must be applied to luxate and elevate the tooth is considerably lower than for L3M with formed roots.

On the other hand, germenectomy is usually performed without a clear indication for extraction. In fact, the guidelines for extraction promulgated by SIGN (Scottish Intercollegiate Guidelines Network) and NICE (National Institute for Health and Clinical Excellence) do not support extraction of asymptomatic third molars, which is generally the case with germenectomies, with some exceptions (for instance, difficulty in obtaining dental care in certain remote areas) [42, 43]. Thus, it must be taken into account that although the risk of IAN damage is lower, germenectomy could have an unfavorable risk–benefit ratio. Nevertheless, asymptomatic third molars may not be disease-free if affected by periodontal disease, for instance. Other guidelines, such as the AAOMS Clinical Practice Guidelines for Oral

Fig. 5.5 Examples of radiographic predictors of potential nerve injury, including (a) darkening of the root, (b) deviation of the mandibular canal, (c) interruption of the white lines of the mandibular canal, (d) deflection of the root, and (e) narrowing of the root



and Maxillofacial Surgeons, are not so restrictive as the NICE or SIGN guidelines [44].

5.3.2 Radiological “Alert” Signs

Superposition of the mandibular canal and the roots of the L3M in the panoramic radiograph can be the result of a true anatomical relationship such that the mandibular canal is in close proximity to the tooth roots, or merely a projection artifact, where the mandibular canal lies in a buccal or lingual position and it is physically separated from the L3M. To distinguish cases where there is a true anatomical contact between the mandibular canal and the L3M, seven “warning” signs have been described including [45] (Fig. 5.5) the following: darkening of the root, deflection of the root, narrowing of the root, deviation of the mandibular canal, narrowing of the mandibular canal, interruption of the white lines of the mandibular canal, and a dark and bifid root. It seems that interruption of the white line, darkening of the root, and deviation of the mandibular canal are consistently associated with a greater risk of IAN surgical exposure or damage [17, 38, 39, 45–47]. The absence of any of these signs, and, of course the lack of superposition of the mandibular canal and the L3M roots, seems to rule out the possibility of IAN damage if proper

surgical technique is used. Indeed, radiological signs have proved to be very specific in ruling out IAN exposure during surgery with a negative predictive value of the surgeon’s evaluation of radiological signs of approximately 99 % [48]. However, the existence of several “warning” signs in the panoramic radiograph has a low sensitivity for detection of IAN exposure (approximately 25 %). Also, these signs have also a low positive predictive value of IAN damage; the presence of several signs indicates a risk of IAN damage between 10 and 20 % [17], which is approximately the prevalence of IAN paresthesia when a CT scan shows that the cortical outline of the mandibular canal is disrupted by the L3M [49].

5.3.3 Conventional Radiography Versus Computed Tomography

Two-dimensional radiographs provide only an approximation of the relationship between the roots of the L3M and the mandibular canal (Fig. 5.6). The existence of a true anatomical relationship can only be detected using tomographic techniques. However, due to the high prevalence of superposition of the L3M roots and the mandibular canal, the low positive predictive value for nerve injury of the computed

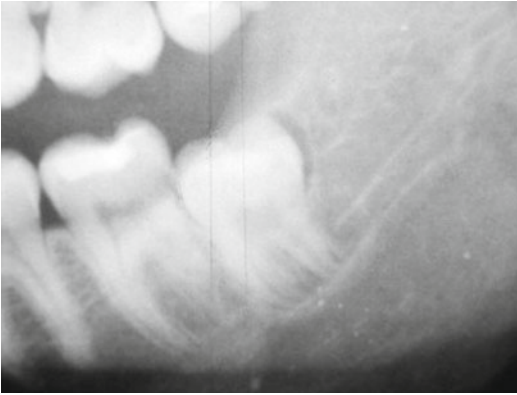


Fig. 5.6 Portion of a panoramic radiograph showing signs of root proximity to the inferior alveolar canal

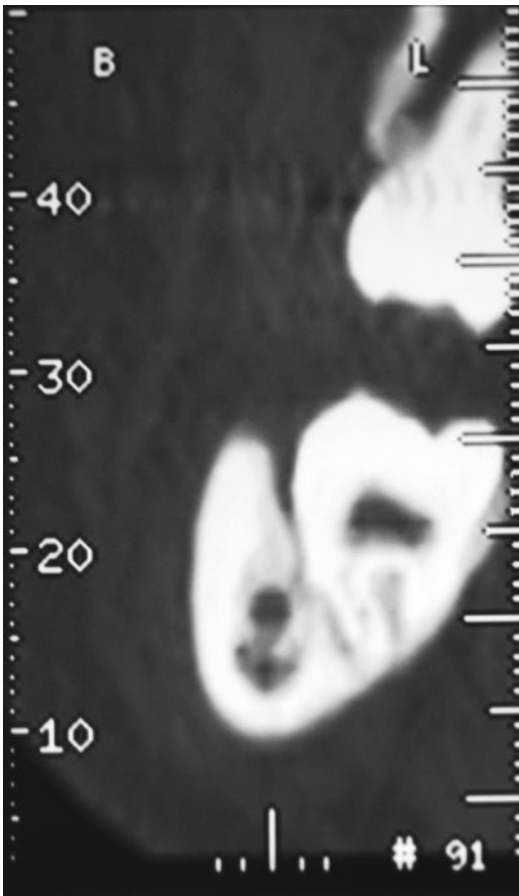


Fig. 5.7 CT of a L3M depicts a mandibular canal close to the buccal CEJ. Removal of the buccal bone should be performed with extreme caution, as it can decorticate and eventually injure the mandibular canal, although it is not in contact with the tooth. In this case CT offers important information to plan the operation

tomography (CT) (similar to the orthopantomography), and the increased cost and radiation exposure of this technique, its systematic use does not seem to be justified for routine evaluation.

CT is especially useful to evaluate the risk-benefit ratio of an L3M extraction, and it helps selecting the surgical strategy when the mandibular canal is close to the cementoenamel junction (Fig. 5.7) or when it is suspected to perforate an L3M root. In the first case, ostectomy can help to avoid the risky areas, buccal or lingual to the L3M, and in the second example, tooth sectioning can avoid a traction injury or avulsion of the IAN.

Nevertheless, CT does not seem to modify the surgical technique in most cases, and the prevalence of IAN injury seems to be approximately the same with or without a preoperative CT [17]. Therefore, it is questionable whether a CT is required in other situations than those described above although it is undeniable that it provides valuable information (Fig. 5.8).

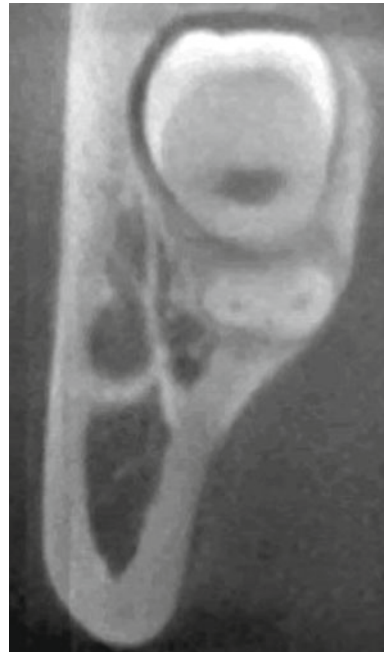


Fig. 5.8 CT section displaying the roots of a L3M close to the lingual cortical plate. This should alert the clinician of two dangers: (1) accidental displacement of the roots to the submandibular space during luxation and (2) risk of laceration of the lingual periosteum that could cause fibrosis near the LN

The spread of cone-beam computed tomography (CBCT) has made 3-D techniques available in dental offices. This technique, despite being less precise than conventional CT because of patient movement, is less expensive and delivers a low radiation dose.

5.3.4 Ostectomy and Tooth Sectioning (Burs, Chisels, Piezosurgery, and Laser)

Ostectomy and tooth sectioning can reduce the amount of strength that must be applied to the roots of the L3M during extraction. If the L3M are in close proximity to the mandibular canal, this action is clearly beneficial, as it reduces the chances of IAN compression. However, if ostectomy is made without caution, it can cause direct damage to the IAN, or increase wound bleeding, which in turn can cause an IAN injury by compression. Ostectomy must be controlled and thoroughly oriented to facilitate luxation and avoid IAN or LN impingement.

Piezosurgery reduces the chances of nerve damage due to impingement of the burs or chisels into the mandibular canal and also reduces vibration or strength required to perform ostectomy or tooth sectioning. However, there is lack of data on IAN damage comparing piezosurgery with the conventional buccal approach with burs, which is the most common technique used for L3M extraction.

Different laser types have also been used for L3M extraction. Although some lasers, such as Er:YAG or Er,Cr:YSGG laser, can be safely used for this indication and compare favorably with the conventional buccal approach with rotating burs [35], some laser light wavelengths and power settings can directly damage the IAN. Moreover, although ostectomy can be easily and safely performed using lasers, tooth sectioning is usually carried out with rotating instruments for practical reasons. Finally, there is no clear evidence that laser surgery reduces IAN injuries.

5.3.5 Drainage and Postoperative Dressings

Placing antiseptic, antibiotic, or caustic substances into the empty socket after L3M extraction has been recommended for the open treatment of the wound to prevent alveolar osteitis or as a complement to cyst removal [50]. However, in case of nerve exposure, it is advisable to not use intra-alveolar tetracycline because of its documented neurotoxicity [51, 52]. In the case of Carnoy's solution for complementary surgical treatment of keratocystic odontogenic tumors, although it has been shown to damage peripheral nerves when left in contact for several minutes [53], it seems to be safe [54]. Carnoy's solution should not be in potential contact with the IAN over 3 min, and special care should apply if the epineurium is not intact [53].

The wound resulting from extraction of the L3M can be closed tightly with sutures and left open to heal secondarily, or a drainage tube or gauze can be inserted to facilitate drainage. It seems that secondary closure (i.e. not covering the socket completely with mucosa) causes less postoperative swelling and pain [55], which could have a beneficial effect on the recovery of the IAN and LN. The insertion of a drainage tube could also prevent swelling [56], with an effect comparable to using a systemic corticosteroid medication [57].

5.3.6 Age

Age is a risk factor for IAN nerve injury caused by L3M extraction [10, 38] and is also a risk factor for poor recovery and wound healing. Age decreases the chances of spontaneous neurosensory recovery and the recovery rate is slower [39]. The explanation for this phenomenon remains speculative, and mechanisms include a reduced neuronal plasticity, a slower recovery rate, or a greater surgical trauma. Indeed, it is well known that age plays an important role in peripheral nerve regeneration, since younger patients recover more easily than older patients [58–61].

5.3.7 Anti-inflammatory Treatment

Although data are limited to a preliminary RCT with a small sample size and thus must be considered with caution, dexamethasone seems to reduce IAN hypersensitivity after L3M extraction [62]. As corticosteroids effectively control swelling after L3M extraction [63–65], the mechanism for reduction of IAN damage is probably a reduction in swelling, which minimizes the chance of nerve compression.

5.3.8 Coronectomy

Coronectomy consists of intentionally removing the crown of a tooth and leaving its root in place. The technique was described in France by Yves Commisionat as an alternative to L3M when there are radiological signs of proximity between the mandibular canal and the roots of the L3M [66, 67]. However, coronectomy became more popular after the appearance of short case series in the UK and the USA [68, 69]. Although the long-term effects of coronectomy are yet to be investigated, RCTs have shown that it significantly reduces the occurrence of IAN injury in cases estimated of high risk [70, 71]. Coronectomy minimizes the risk of IAN injury and shows good results after 1–3 years [72–74]. Additionally, there are no signs of apical pathology of the roots left in situ [72]. However, coronectomy does not completely avoid the risk of IAN injury, since some L3M are indeed loosened when trying to separate the crown and must be removed. RCTs have considered these failed coronectomies as extractions, or excluded them, which is against intention-to-treat analysis; failed coronectomies have to be considered as coronectomies, not as extractions. Thus, coronectomy can also cause IAN injury, although it is less frequent than with extraction. As coronectomy has expanded as an alternative to extraction, the technique has been refined and less unintentional root loosening is observed [73].

During coronectomies, the roots of the L3M are left in place and can migrate and eventually erupt, which separates them from the mandibular

canal and reduces the chances of IAN damage. This migration is usually around 3.0 mm in the first year, with an SD around 1.5 mm [71].

Coronectomy can also be performed in a partial fashion. In this case, normally a second-stage surgery is needed, to remove the roots and the remainder of the L3M, once they have migrated and separated from the mandibular canal [75, 76].

On the other hand, the remaining roots after coronectomy, if the tooth is covered by mucosa when suturing, do not seem to require endodontic treatment [77], and the pulpal tissues can remain vital [71].

Thus, there is increasing evidence that coronectomy reduces the chances of IAN damage when extracting L3M close to the mandibular canal, while it does not significantly increase the occurrence of infection or other postoperative complications.

5.3.9 Pericoronal Ostectomy

Pericoronal ostectomy of deeply impacted L3M facilitates their partial eruption, which separates the roots of the L3M from the mandibular canal, thus minimizing the risk of IAN damage [78]. However, there are only short case series reported in the literature, and the prevalence of IAN injury seems to be approximately 10–15 % [79].

5.3.10 Orthodontic Extrusion

The L3M may be extruded using orthodontic appliances, in order to separate its root from the mandibular canal [80–82]. However, this treatment option requires orthodontic appliances, a retention phase, and can be difficult or even impossible depending upon the occlusion or the position of the L3M. An advantage of the “orthodontic extraction” method is the protection of the periodontal tissues of the adjacent second molar [80]. On the other hand, only a few cases have been described, and thus, there is limited evidence to support this approach.

5.4 Evolution of LN and IAN Injury Caused by L3M Extraction

After L3M extraction, there is a reduction in touch sensibility of the ipsilateral side of the tongue when compared to the contralateral side. Conversely, the taste function seems to remain largely unaffected [83]. Despite being present, changes in the touch threshold seem not to be noticed by patients, suggesting that minor alterations of LN function after L3M are common but of no clinical importance. Although almost half of the patients complain of changes in taste after L3M extraction, this fact seems related to the difficulty of oral hygiene or the use of antiseptic mouth rinse and not to LN impairment [18].

The majority of LN injuries caused by L3M extraction are indeed mild (neurapraxia or Sunderland I or II injuries) [33]. Figure 5.9 shows the evolution of LN injuries caused by L3M extraction and compares it with IAN injuries. One of the most striking differences is that while most LN injuries fully recover in the first 3 months without any noticeable sensory deficit, IAN injuries take considerably longer, and a significant proportion (up to 25 %) have some degree of permanent impairment. On the other hand, while most LN injuries seem to recover most in the first few months, IAN injuries show a bimodal distribution, with peaks in the first 3 months and after 9 months. This suggests that there are two patterns of IAN injury: some patients recover very quickly, in the first 3 months, but patients whose impairments last longer usually take more than 9 months to fully recover, or even remain with some permanent alteration.

Conclusions

In conclusion, L3M removal accounts for the majority of cases of LN and IAN injuries, and there are many possible risk factors for paresthesia, including surgical technique, patient age, radiographic predictors or root-to-nerve proximity, surgeon experience, patient gender, and the use of intra-socket medications. Although there are several possible methods that can be used to decrease the incidence of

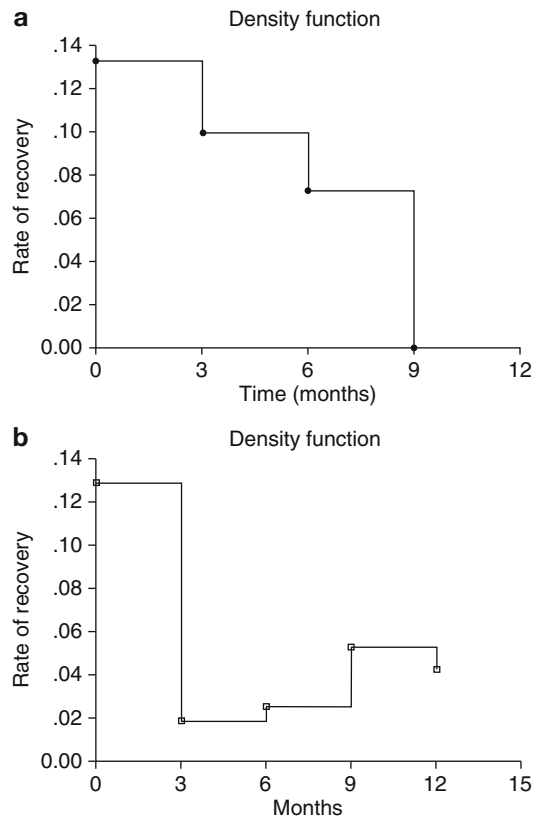


Fig. 5.9 Graphs show the recovery rate of LN (a) and IAN injuries (b) caused by L3M extraction. The *horizontal axis* represents months and the *vertical axis* represents the recovery rate (percentage of recoveries per month). While LN injuries are usually transient and disappear in the first 3 months, suggesting a mild damage, IAN injuries that do not recover after 3 months are mostly severe, can persist for more than 9 months, and even leave some permanent impairment (Graphs reprinted with permission from Queral-Godoy et al. [33, 39])

LN and IAN injuries from L3M removal, these nerve injuries remain a known risk and complication of the surgical procedure.

References

- Hillerup S (2007) Iatrogenic injury to oral branches of the trigeminal nerve: records of 449 cases. *Clin Oral Investig* 11(2):133–142
- Sisk AL, Hammer WB, Shelton DW, Joy ED Jr (1986) Complications following removal of impacted third molars: the role of the experience of the surgeon. *J Oral Maxillofac Surg* 44(11):855–859

3. Blondeau F (1994) Paresthesia: incidence following the extraction of 455 mandibular impacted third molars. *J Can Dent Assoc* 60(11):991–994
4. Blondeau F, Daniel NG (2007) Extraction of impacted mandibular third molars: postoperative complications and their risk factors. *J Can Dent Assoc* 73(4):325
5. Rood JP (1992) Permanent damage to inferior alveolar and lingual nerves during the removal of impacted mandibular third molars. Comparison of two methods of bone removal. *Br Dent J* 172(3):108–110
6. Rood JP (1983) Lingual split technique. Damage to inferior alveolar and lingual nerves during removal of impacted mandibular third molars. *Br Dent J* 154(12):402–403
7. Jerjes W, Swinson B, Moles DR, El-Maaytah M, Banu B, Upile T et al (2006) Permanent sensory nerve impairment following third molar surgery: a prospective study. *Oral Surg Oral Med Oral Pathol Oral Radiol Endod* 102(4):e1–e7
8. Bataineh AB (2001) Sensory nerve impairment following mandibular third molar surgery. *J Oral Maxillofac Surg* 59(9):1012–1017; discussion 1017
9. Robert RC, Bacchetti P, Pogrel MA (2005) Frequency of trigeminal nerve injuries following third molar removal. *J Oral Maxillofac Surg* 63(6):732–735; discussion 736
10. Bruce RA, Frederickson GC, Small GS (1980) Age of patients and morbidity associated with mandibular third molar surgery. *J Am Dent Assoc* 101(2):240–245
11. Mason DA (1988) Lingual nerve damage following lower third molar surgery. *Int J Oral Maxillofac Surg* 17(5):290–294
12. Robinson PP, Smith KG (1996) Lingual nerve damage during lower third molar removal: a comparison of two surgical methods. *Br Dent J* 180(12):456–461
13. Wofford DT, Miller RI (1987) Prospective study of dysesthesia following odontectomy of impacted mandibular third molars. *J Oral Maxillofac Surg* 45(1):15–19
14. Brann CR, Brickley MR, Shepherd JP (1999) Factors influencing nerve damage during lower third molar surgery. *Br Dent J* 186(10):514–516
15. Schultze-Mosgau S, Reich RH (1993) Assessment of inferior alveolar and lingual nerve disturbances after dentoalveolar surgery, and of recovery of sensitivity. *Int J Oral Maxillofac Surg* 22(4):214–217
16. Ferrus-Torres E, Valmaseda-Castellon E, Berini-Aytes L, Gay-Escoda C (2011) Informed consent in oral surgery: the value of written information. *J Oral Maxillofac Surg* 69(1):54–58
17. Sanmarti-Garcia G, Valmaseda-Castellon E, Gay-Escoda C (2012) Does computed tomography prevent inferior alveolar nerve injuries caused by lower third molar removal? *J Oral Maxillofac Surg* 70(1):5–11
18. Colorado-Bonnin M, Valmaseda-Castellon E, Berini-Aytes L, Gay-Escoda C (2006) Quality of life following lower third molar removal. *Int J Oral Maxillofac Surg* 35(4):343–347
19. Ehrenfeld M, Cornelius CP, Altenmuller E, Riediger D, Sahl W (1992) Nerve injuries following nerve blocking in the pterygomandibular space. *Dtsch Zahnarztl Z* 47(1):36–39
20. Pogrel MA, Renaut A, Schmidt B, Ammar A (1995) The relationship of the lingual nerve to the mandibular third molar region: an anatomic study. *J Oral Maxillofac Surg* 53(10):1178–1181
21. Miloro M, Halkias LE, Slone HW, Chakeres DW (1997) Assessment of the lingual nerve in the third molar region using magnetic resonance imaging. *J Oral Maxillofac Surg* 55(2):134–137
22. Behnia H, Kheradvar A, Shahrokhi M (2000) An anatomic study of the lingual nerve in the third molar region. *J Oral Maxillofac Surg* 58(6):649–651; discussion 652–653
23. Madeira MC, Percinoto C, das Gracias M, Silva M (1978) Clinical significance of supplementary innervation of the lower incisor teeth: a dissection study of the mylohyoid nerve. *Oral Surg Oral Med Oral Pathol* 46(5):608–614
24. Racz L, Maros T, Seres-Sturm L (1981) Anatomical variations of the nervus alveolaris inferior and their importance for the practice (author's transl). *Anat Anz* 149(4):329–332
25. Pichler JW, Beirne OR (2001) Lingual flap retraction and prevention of lingual nerve damage associated with third molar surgery: a systematic review of the literature. *Oral Surg Oral Med Oral Pathol Oral Radiol Endod* 91(4):395–401
26. To EW, Chan FF (1994) Lingual nerve retractor. *Br J Oral Maxillofac Surg* 32(2):125–126
27. Greenwood M, Langton SG, Rood JP (1994) A comparison of broad and narrow retractors for lingual nerve protection during lower third molar surgery. *Br J Oral Maxillofac Surg* 32(2):114–117
28. Brahams D (1992) Retractor design and the lingual nerve. *Lancet* 339(8796):801
29. Blackburn CW, Bramley PA (1989) Lingual nerve damage associated with the removal of lower third molars. *Br Dent J* 167(3):103–107
30. Carmichael FA, McGowan DA (1992) Incidence of nerve damage following third molar removal: a West of Scotland Oral Surgery Research Group study. *Br J Oral Maxillofac Surg* 30(2):78–82
31. Valmaseda-Castellon E, Berini-Aytes L, Gay-Escoda C (2000) Lingual nerve damage after third lower molar surgical extraction. *Oral Surg Oral Med Oral Pathol Oral Radiol Endod* 90(5):567–573
32. Gargallo-Albiol J, Buenechea-Imaz R, Gay-Escoda C (2000) Lingual nerve protection during surgical removal of lower third molars. A prospective randomised study. *J Oral Maxillofac Surg* 29(4):268–271
33. Queral-Godoy E, Figueiredo R, Valmaseda-Castellon E, Berini-Aytes L, Gay-Escoda C (2006) Frequency and evolution of lingual nerve lesions following lower third molar extraction. *J Oral Maxillofac Surg* 64(3):402–407
34. Gomes AC, Vasconcelos BC, de Oliveira e Silva ED, da Silva LC (2005) Lingual nerve damage after man-

- dibular third molar surgery: a randomized clinical trial. *J Oral Maxillofac Surg* 63(10):1443–1446
35. Abu-Serriah M, Critchlow H, Whitters CJ, Ayoub A (2004) Removal of partially erupted third molars using an Erbium (Er):YAG laser: a randomised controlled clinical trial. *Br J Oral Maxillofac Surg* 42(3):203–208
 36. Sivoilella S, Berengo M, Bressan E, Di Fiore A, Stellini E (2011) Osteotomy for lower third molar germectomy: randomized prospective crossover clinical study comparing piezosurgery and conventional rotatory osteotomy. *J Oral Maxillofac Surg* 69(6):e15–e23
 37. Renton T, McGurk M (2001) Evaluation of factors predictive of lingual nerve injury in third molar surgery. *Br J Oral Maxillofac Surg* 39(6):423–428
 38. Valmaseda-Castellon E, Berini-Aytes L, Gay-Escoda C (2001) Inferior alveolar nerve damage after lower third molar surgical extraction: a prospective study of 1117 surgical extractions. *Oral Surg Oral Med Oral Pathol Oral Radiol Endod* 92(4):377–383
 39. Queral-Godoy E, Valmaseda-Castellon E, Berini-Aytes L, Gay-Escoda C (2005) Incidence and evolution of inferior alveolar nerve lesions following lower third molar extraction. *Oral Surg Oral Med Oral Pathol Oral Radiol Endod* 99(3):259–264
 40. Chiapasco M, Crescentini M, Romanoni G (1995) Germectomy or delayed removal of mandibular impacted third molars: the relationship between age and incidence of complications. *J Oral Maxillofac Surg* 53(4):418–422; discussion 422–423
 41. Chaparro-Avendano AV, Perez-Garcia S, Valmaseda-Castellon E, Berini-Aytes L, Gay-Escoda C (2005) Morbidity of third molar extraction in patients between 12 and 18 years of age. *Med Oral Patol Oral Cir Bucal* 10(5):422–431
 42. Scottish Intercollegiate Group Network (2000) Management of unerupted and impacted third molar teeth. SIGN Publication n. 43. <http://www.sign.ac.uk/guidelines/fulltext/43/index.html>. Accessed 13 May 2012
 43. National Institute for Clinical Excellence (NICE) (2010) Guidance on the extraction of wisdom teeth. <http://www.nice.org.uk/nicemedia/live/11385/31993/31993.pdf>. Accessed 30 Mar 2012
 44. Haug RH, Perrott DH, Gonzalez ML, Talwar RM (2005) The American Association of Oral and Maxillofacial Surgeons age-related third molar study. *J Oral Maxillofac Surg* 63(8):1106–1114
 45. Rood JP, Shehab BA (1990) The radiological prediction of inferior alveolar nerve injury during third molar surgery. *Br J Oral Maxillofac Surg* 28(1):20–25
 46. Monaco G, Montevecchi M, Bonetti GA, Gatto MR, Checchi L (2004) Reliability of panoramic radiography in evaluating the topographic relationship between the mandibular canal and impacted third molars. *J Am Dent Assoc* 135(3):312–318
 47. Leung YY, Cheung LK (2011) Correlation of radiographic signs, inferior dental nerve exposure, and deficit in third molar surgery. *J Oral Maxillofac Surg* 69(7):1873–1879
 48. Sedaghatfar M, August MA, Dodson TB (2005) Panoramic radiographic findings as predictors of inferior alveolar nerve exposure following third molar extraction. *J Oral Maxillofac Surg* 63(1):3–7
 49. Park W, Choi JW, Kim JY, Kim BC, Kim HJ, Lee SH (2010) Cortical integrity of the inferior alveolar canal as a predictor of paresthesia after third-molar extraction. *J Am Dent Assoc* 141(3):271–278
 50. Holland CS, Hindle MO (1984) The influence of closure or dressing of third molar sockets on post-operative swelling and pain. *Br J Oral Maxillofac Surg* 22(1):65–71
 51. Leist JC, Zuniga JR, Chen N, Gollehon S (1995) Experimental topical tetracycline-induced neuritis in the rat. *J Oral Maxillofac Surg* 53(4):427–434
 52. Zuniga JR, Leist JC (1995) Topical tetracycline-induced neuritis: a case report. *J Oral Maxillofac Surg* 53(2):196–199
 53. Frerich B, Cornelius CP, Wietholter H (1994) Critical time of exposure of the rabbit inferior alveolar nerve to Carnoy's solution. *J Oral Maxillofac Surg* 52(6):599–606
 54. Gosau M, Draenert FG, Muller S, Frerich B, Burgers R, Reichert TE et al (2010) Two modifications in the treatment of keratocystic odontogenic tumors (KCOT) and the use of Carnoy's solution (CS) – a retrospective study lasting between 2 and 10 years. *Clin Oral Investig* 14(1):27–34
 55. Pasqualini D, Cocero N, Castella A, Mela L, Bracco P (2005) Primary and secondary closure of the surgical wound after removal of impacted mandibular third molars: a comparative study. *Int J Oral Maxillofac Surg* 34(1):52–57
 56. Cerqueira PR, Vasconcelos BC, Bessa-Nogueira RV (2004) Comparative study of the effect of a tube drain in impacted lower third molar surgery. *J Oral Maxillofac Surg* 62(1):57–61
 57. Ordulu M, Aktas I, Yalcin S, Azak AN, Evlioglu G, Disci R et al (2006) Comparative study of the effect of tube drainage versus methylprednisolone after third molar surgery. *Oral Surg Oral Med Oral Pathol Oral Radiol Endod* 101(6):e96–e100
 58. Kalomiri DE, Soucacos PN, Beris AE (1995) Management of ulnar nerve injuries. *Acta Orthop Scand Suppl* 264:41–44
 59. Marsh D (1990) The validation of measures of outcome following suture of divided peripheral nerves supplying the hand. *J Hand Surg [Br]* 15(1):25–34
 60. Tajima T, Imai H (1989) Results of median nerve repair in children. *Microsurgery* 10(2):145–146
 61. Poppen NK, McCarroll HR Jr, Doyle JR, Niebauer JJ (1979) Recovery of sensibility after suture of digital nerves. *J Hand Surg [Am]* 4(3):212–225
 62. Barron RP, Benoliel R, Zeltser R, Eliav E, Nahlieli O, Gracely RH (2004) Effect of dexamethasone and dipyrrone on lingual and inferior alveolar nerve hypersensitivity following third molar extractions: preliminary report. *J Orofac Pain* 18(1):62–68
 63. Vegas-Bustamante E, Mico-Llorens J, Gargallo-Albiol J, Satorres-Nieto M, Berini-Aytes L, Gay-Escoda C

- (2008) Efficacy of methylprednisolone injected into the masseter muscle following the surgical extraction of impacted lower third molars. *Int J Oral Maxillofac Surg* 37(3):260–263
64. Mico-Llorens JM, Satorres-Nieto M, Gargallo-Albiol J, Arnabat-Dominguez J, Berini-Ayres L, Gay-Escoda C (2006) Efficacy of methylprednisolone in controlling complications after impacted lower third molar surgical extraction. *Eur J Clin Pharmacol* 62(9):693–698
 65. Grossi GB, Maiorana C, Garramone RA, Borgonovo A, Beretta M, Farronato D et al (2007) Effect of sub-mucosal injection of dexamethasone on postoperative discomfort after third molar surgery: a prospective study. *J Oral Maxillofac Surg* 65(11):2218–2226
 66. Alantar A, Roisin-Chausson MH, Commissionat Y, Aaron C, Barda L, Debien J et al (1995) Retention of third molar roots to prevent damage to the inferior alveolar nerve. *Oral Surg Oral Med Oral Pathol Oral Radiol Endod* 80(2):126
 67. Commissionat Y, Roisin-Chausson MH (1995) Lesions of the inferior alveolar nerve during extraction of the wisdom teeth. Consequences – prevention. *Rev Stomatol Chir Maxillofac* 96(6):385–391
 68. O’Riordan BC (2004) Coronectomy (intentional partial odontectomy of lower third molars). *Oral Surg Oral Med Oral Pathol Oral Radiol Endod* 98(3):274–280
 69. Pogrel MA, Lee JS, Muff DF (2004) Coronectomy: a technique to protect the inferior alveolar nerve. *J Oral Maxillofac Surg* 62(12):1447–1452
 70. Renton T, Hankins M, Sproate C, McGurk M (2005) A randomised controlled clinical trial to compare the incidence of injury to the inferior alveolar nerve as a result of coronectomy and removal of mandibular third molars. *Br J Oral Maxillofac Surg* 43(1):7–12
 71. Leung YY, Cheung LK (2009) Safety of coronectomy versus excision of wisdom teeth: a randomized controlled trial. *Oral Surg Oral Med Oral Pathol Oral Radiol Endod* 108(6):821–827
 72. Goto S, Kurita K, Kuroiwa Y, Hatano Y, Kohara K, Izumi M et al (2012) Clinical and dental computed tomographic evaluation 1 year after coronectomy. *J Oral Maxillofac Surg* 70(5):1023–1029
 73. Cilasun U, Yildirim T, Guzeldemir E, Pektas ZO (2011) Coronectomy in patients with high risk of inferior alveolar nerve injury diagnosed by computed tomography. *J Oral Maxillofac Surg* 69(6):1557–1561
 74. Leung YY, Cheung LK (2012) Coronectomy of the lower third molar is safe within the first 3 years. *J Oral Maxillofac Surg* 70(7):1515–1522
 75. Landi L, Manicone PF, Piccinelli S, Raia A, Raia R (2010) A novel surgical approach to impacted mandibular third molars to reduce the risk of paresthesia: a case series. *J Oral Maxillofac Surg* 68(5):969–974
 76. Landi L, Manicone PF, Piccinelli S, Raia A, Raia R (2010) Staged removal of horizontally impacted third molars to reduce risk of inferior alveolar nerve injury. *J Oral Maxillofac Surg* 68(2):442–446
 77. Sencimen M, Ortakoglu K, Aydin C, Aydintug YS, Ozyigit A, Ozen T et al (2010) Is endodontic treatment necessary during coronectomy procedure? *J Oral Maxillofac Surg* 68(10):2385–2390
 78. Tolstunov L (2010) Pericoronary ostectomy as alternative treatment option for extraction of impacted mandibular third molars in proximity to inferior alveolar nerve. *J Oral Maxillofac Surg* 68(1):231–232
 79. Tolstunov L, Javid B, Keyes L, Nattestad A (2011) Pericoronary ostectomy: an alternative surgical technique for management of mandibular third molars in close proximity to the inferior alveolar nerve. *J Oral Maxillofac Surg* 69(7):1858–1866
 80. Hirsch A, Shteyman S, Boyan BD, Schwartz Z (2003) Use of orthodontic treatment as an aid to third molar extraction: a method for prevention of mandibular nerve injury and improved periodontal status. *J Periodontol* 74(6):887–892
 81. Checchi L, Alessandri Bonetti G, Pelliccioni GA (1996) Removing high-risk impacted mandibular third molars: a surgical-orthodontic approach. *J Am Dent Assoc* 127(8):1214–1217
 82. Bonetti GA, Parenti SI, Checchi L (2008) Orthodontic extraction of mandibular third molar to avoid nerve injury and promote periodontal healing. *J Clin Periodontol* 35(8):719–723
 83. Ridaura-Ruiz L, Figueiredo R, Valmaseda-Castellón E, Berini-Ayres L, Gay-Escoda C (2012) Sensibility and taste alterations after impacted lower third molar extractions. A prospective cohort study. *Med Oral Patol Oral Cir Bucal* 17(5):e759–e764

Dental Implant-Related Injuries of the Trigeminal Nerve

6

Shahrokh C. Bagheri and Roger A. Meyer

Placement of dental implants has become the standard of care for replacement of missing teeth when indicated. Implant surgery is now performed by several of the dental specialties, including oral and maxillofacial surgery. Injuries

to the inferior alveolar nerve (IAN) and the mental nerve (MN) are known risks for the placement of dental implants in the mandible. Upon diagnosis of a nerve injury, prompt evaluation of the patient's sensory function, assessment of the position of the implant with relation to the inferior alveolar canal, and timely decisions regarding the fate of the implant and management of the nerve injury will maximize the likelihood of a favorable outcome.

S.C. Bagheri, DMD, MD, FACS, FICD (✉)
Division of Oral and Maxillofacial Surgery,
Department of Surgery,
Northside Hospital, Atlanta, GA, USA

Georgia Oral and Facial Surgery,
1880 West Oak Parkway, Suite 215,
Marietta, GA 30062, USA

Eastern Surgical Associates and Consultants,
2795 Peachtree Rd, Suite 2008,
Atlanta, GA 30303, USA

Department of Oral and Maxillofacial Surgery,
Georgia Health Sciences University,
Augusta, GA, USA

Department of Surgery, Emory University,
Atlanta, GA, USA
e-mail: sbagher@hotmail.com

R.A. Meyer, DDS, MS, MD, FACS
Division of Oral and Maxillofacial Surgery,
Department of Surgery, Northside Hospital,
Atlanta, GA, USA

Georgia Oral and Facial Surgery,
1880 West Oak Parkway, Suite 215,
Marietta, GA 30062, USA

Department of Oral and Maxillofacial Surgery,
Georgia Health Sciences University,
Augusta, GA, USA

Maxillofacial Consultants, Ltd.,
1021 Holt's Ferry, 30642 Greensboro, GA, USA
e-mail: rameyer@aol.com

6.1 Background

Since the introduction of dental implants in the 1980s in the USA, the last three decades have seen an exponential increase in the number of implants placed, with many choices of implant type. Many dental professionals, including several specialists, provide this service, and although there have been groundbreaking advances in materials science, bone grafting, tissue management, imaging, and treatment planning, the basic concept of osseointegration [9] remains pivotal for the success of modern implantology. Expertise in the regional soft and hard tissue anatomy of the maxillomandibular region is a prerequisite for the minimization of risk of untoward sequelae from dental implant placement. Prompt recognition and management of acute and chronic complications of surgery is paramount for optimal patient outcome [19, 22, 36].

The risks of injury to the inferior alveolar nerve (IAN), lingual nerve (LN), mental nerve

(MN), and long buccal nerve (LBN) are uncommon, but known, complications of implant restoration of the mandible and demand specialized attention [2]. Although not routine, the preoperative use of advanced imaging modalities such as cone-beam computerized tomography (CBCT) scans can assist in localization of the inferior alveolar canal (IAC) and the position of the mental foramen in preparation for implant surgery [30]. With careful planning, the possibility of nerve injury is significantly reduced, although not eliminated completely, even with the best of planning and treatment. Sensory dysfunction of the IAN, especially if persistent or painful, can be distressing to both the patient and the clinician. Most of these injuries resolve spontaneously [7]; however, surgical intervention to repair the nerve is of benefit to selected patients whose sensory dysfunction is persistent and unacceptable [15]. Altered sensation after implant surgery continues to bear medicolegal implications that further warrant the attention of the implantologist [10]. The occurrence of neurosensory dysfunction associated with implant surgery does not necessarily imply a breach of the standard of care. In essence, a nerve injury can result from surgeon-related factors (e.g., diagnosis, surgical technique), patient-related factors (e.g., anatomic variations, undisclosed or uncontrolled medical conditions such as diabetes mellitus), factors not known at the time of the procedure, or combinations of these factors. This differentiation of cause and effect is not always easily discerned from a retrospective review of any given clinical situation.

In the treatment of IAN injuries associated with dental implant surgery, it is most important that there be prompt recognition and acknowledgment of the patient's sensory complaints and timely decisions regarding management in order to maximize the recovery of nerve function. The clinician will be faced with several issues including treatment of the neurosensory disturbance (NSD) of the affected region, how best to proceed with dental restoration of the affected area, management of a distressed and disappointed patient, and communication with other involved dental professionals. The patient's concerns are best addressed by a continuing supportive relationship

with the patient and appropriate recommendations for further treatment in conjunction with the restorative dentist.

This chapter will cover the etiology, diagnosis, and current management of injuries to the mandibular division (MdN) of the trigeminal nerve from dental implant surgery.

6.2 Etiology of Implant-Related Nerve Injury

The etiology and location of mandibular nerve (MdN) injury from dental implant surgery may be obvious in some clinical situations. However, it is imperative that when planning any microsurgical intervention the site of nerve injury must be identified preoperatively, if at all possible, in order to minimize manipulation of the nerve during surgical intervention. Consideration should be given to the possible anatomic locations of the injury site other than the site of implant placement. This would include the site of local anesthetic injection, incision design, and possible retraction (i.e., stretch) injury at a site distant from the implant location.

Anatomic variations aside, the five most frequent possible causes of injury to the mandibular nerve (MdN) related to dental implant surgery are (1) preoperative errors in evaluation, diagnosis, and treatment planning; (2) local anesthetic injection; (3) excessive implant osteotomy preparation (drilling) or overheating due to drilling; (4) impingement of the implant on the inferior alveolar canal and neurovascular bundle; and (5) other causes such as inadvertent transection of the mental, lingual, or long buccal nerve during incision and/or soft tissue flap retraction.

6.2.1 Errors in Diagnosis and Treatment Planning

The radiographic planning identifies the position of the inferior alveolar canal, which coincides with the anatomic boundaries of the inferior alveolar neurovascular bundle. Anatomical analysis of the neurovascular bundle demonstrates

that the IAN is the dominant structure occupying over 80 % of the cross-sectional area, while the remaining 20 % contains the inferior alveolar artery and vein. The location of the vascular structures in relation to the nerve is unpredictable with individual variability.

The panoramic radiograph is useful as the primary imaging study to assess the vertical distance from the crest of the mandibular alveolar ridge to the superior aspect of the inferior alveolar canal (IAC). The panoramic machine should be calibrated for distortion or magnification to allow for accurate determination of dimensions from each panoramic film. There is generally a magnification factor varying between 10 and 40 % on the panoramic radiograph with more magnification in the areas where the imaged bone falls out of the focal trough of the beam. Typically, 20–30 % magnification should be expected in the mandible, and this must be accounted for in the planning. Many implant companies provide radiographic guides with varying percentages of magnification that are helpful in the treatment planning process. If the panoramic film shows inadequate distance from the alveolar crest to the IAC to support an implant, the mediolateral position of the IAC will need to be determined in order to decide whether an implant can be placed without repositioning of the IAN or MN (see below). In such patients, a computed tomographic (CT) or cone-beam scan (CBCT) will be a necessary part of the evaluation process.

Regardless of the radiographic modality (CT or panorex) used for implant planning, errors in interpretation and application of the radiograph can lead to errors in implant positioning. The CT scans have improved resolution and allow visualization of the nerve in three dimensions; however, errors in software planning can be transferred into the surgical procedure. With respect to surgical guides, attention should be given to the accuracy of the guides and the stability of seating onto the alveolar ridge. Placement of the surgical guide on a totally edentulous mandible will have a significant inherent margin of error related to the soft tissue despite correct 3D planning. It is important to allow an additional reasonable distance (i.e., 2–3 mm) from the superior aspect of

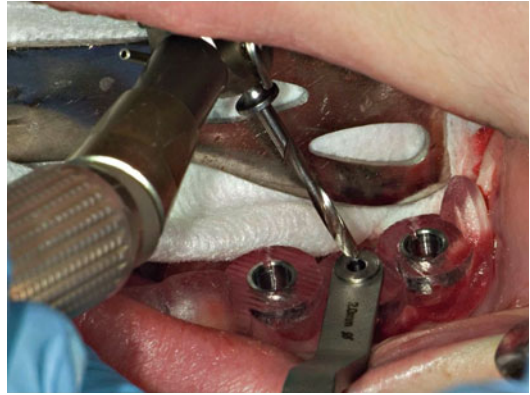


Fig. 6.1 Flapless surgery for implant placement using navigation guides. Both the depth and the position of the implant osteotomy are determined by the guide

the IAC during CT planning to accommodate for this margin of error. Although the use of *flapless* surgery with a mucosal-borne surgical guide (Fig. 6.1) for implant placement is popular, the surgeon should not hesitate to raise a mucoperiosteal flap to better visualize and confirm anatomic landmarks as needed. It is accepted that there is more accuracy with bone-borne (and tooth-borne) surgical guides than with mucosal-borne guides due to the inherent mobility of the soft tissues and lack of fixed landmarks, despite the use of stabilization screws.

6.2.2 Local Anesthetic Injection

The IAN or LN can be injured by needle contact secondary to the injection of a local anesthetic into the pterygomandibular space [27, 28] or the MN when injecting in the area of the mental foramen. Although the exact pathophysiology of this injury remains unknown, there are three possible causes: (1) direct intraneural injection with mechanical injury to the nerve (i.e., severance of axons, partial or total, scar tissue or neuroma formation, Wallerian degeneration), (2) interruption of vessels of the mesoneurium with peri- and intraneural hemorrhage and secondary scar formation, and (3) chemical toxicity of the anesthetic solution, or from a contaminant (sterilizing solution in a storage container) that is able to enter into a leaky anesthetic cartridge [13]. Regardless

of the cause, it is recommended that aspiration be performed prior to all local anesthetic injections. If there is a bloody aspirate, or the patient complains of a paresthesia (typically, an “electric shock-like” sensation), the needle is withdrawn a few millimeters and aspiration is repeated. If there is now no bloody aspirate, it can be assumed that the needle tip is no longer in contact with a blood vessel or nerve, and the injection is completed. A note of such an occurrence should be routinely entered in the patient’s chart. This technique may prevent direct injection into a vascular space, but does not necessarily prevent deposition of the anesthetic within the epineurium (the diameter of the IAN is four to five times greater than the associated inferior alveolar artery or vein). Nerve injury secondary to local anesthetic injection, although uncommon, has a reported incidence of 1:26,762 to 1:160,571. It can be difficult to differentiate from injury related to the placement of the dental implants, especially if sedation or general anesthesia was used and, therefore, the patient was unable to report a paresthesia at the time of the injection(s). Without obvious clinical or radiographic signs of injury to the nerve from the dental implant procedure itself, the possibility of needle injection injury cannot be eliminated. Unfortunately, a small number of patients who have suffered an injection-related injury can be misdiagnosed with injury related to the dental implant surgery and subsequently undergo either inappropriate removal of the implant or fruitless exploratory surgical procedures that reveal no visible nerve injury at the implant location.

6.2.3 Osteotomy Preparation

Injury to the IAN as a consequence of bone preparation or implant placement can be due to errors in radiographic planning, drilling, or direct contact of the implant with the nerve. Drilling injuries to the IAN can be difficult to diagnose. Despite correct position of the implant vis-a-vis the IAC on the postoperative radiograph appearance of the implant, osseous preparation with the drill may have been performed beyond the

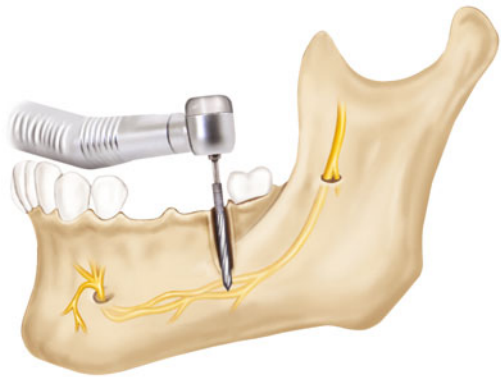


Fig. 6.2 Diagram of a direct injury to the IAN by drilling beyond the planned osteotomy through the superior aspect of the IAC

planned implant depth causing injury to the nerve (Fig. 6.2). In addition to the possibility that one of the implant drills entered the IAC and injured the IAN, it is also possible that the drill caused vascular trauma to the inferior alveolar artery (IAA) or inferior alveolar vein (IAV) and resulted in intra-canal bleeding. This bleeding may be noted during the osteotomy preparation by visualization of oozing that is more significant than normal marrow oozing. Once the implant is placed, the bleeding is tamponaded with resultant pressure placed upon the IAN, resulting in paresthesia, and even dysesthesia. This error can be prevented by measurement from correctly calibrated radiographs of the distance from the alveolar ridge crest to the superior aspect of the IAC, the use of drilling equipment with predetermined depth stops, and careful technique to prevent drilling beyond the planned depth. Irrigation with adequate coolant to dispel heat generated by bone drilling may also prevent a thermal injury in the absence of direct contact with the nerve. Frequent intraoperative reverification of the drill dimensions (diameter and length) is also helpful.

6.2.4 Direct Implant Placement Injury

In addition to injury caused by drilling, the extent of injury to the IAN due to the implant itself is

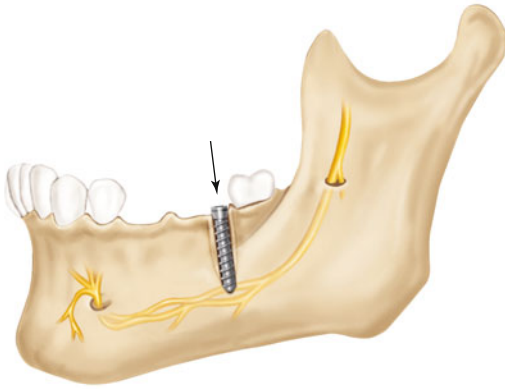


Fig. 6.3 Diagram showing the placement of an implant into the confines of the IAC with increased intra-canal pressure

related to the degree of encroachment of the implant into the IAC or its direct contact with the IAN (Fig. 6.3). Nerve injury due to implant placement may occur despite proper osseous preparation, when the implant is inserted beyond the vertical confines of the prepared bone, compressing or breaching the superior wall of the IAC and forcing bone into the canal (Fig. 6.4a). Alternately, extension of drilling into the IAC may facilitate overinsertion of the implant beyond its intended depth and into the IAC, making direct contact between the implant and the IAN (Fig. 6.4b, c). Finally, delayed osseous healing and remodeling from localized injury can cause excessive bone formation during the healing phases and compromise the IAC cross-sectional diameter resulting in nerve compression (Fig. 6.4d) [8].

6.2.5 Other Causes of Injury

The mental nerve (MN) lies in the mandibular buccal soft tissues and is at risk for iatrogenic injury during a vestibular incision. Recognition of the changing anatomy of the edentulous mandible is particularly helpful in minimizing the risk of injury to the MN. As the patient ages, the alveolar bone in an edentulous area resorbs, and the position of the mental foramen becomes closer to the crest of the alveolar ridge (Fig. 6.5a). In some

patients there is actual dehiscence of the IAC, and the IAN and the MN come to lie on the alveolar ridge crest (Fig. 6.5b). Placement of an incision must, therefore, take these anatomic changes into consideration. During the retraction of a mucoperiosteal flap, it is possible to exert continuous, undue pressure on the underlying MN. Gentle soft tissue retraction with frequent brief relaxation of retraction pressure is suggested (Fig. 6.5c).

Less common causes of nerve injury are related to placement of bone grafts (autologous, allogeneic, xenogeneic) during simultaneous implant placement. In cases of complex implant reconstruction, the bone graft material may be placed into the donor site with excessive force, thus severely compressing or even crushing the IAN. It is also possible that particulate bone materials placed in the vicinity of the mental foramen may migrate or become dislodged to impinge upon the MN as it exits the foramen, and this may cause significant scarring around the nerve and resultant paresthesia, including dysesthesia.

6.3 Evaluation of Implant-Related Nerve Injury

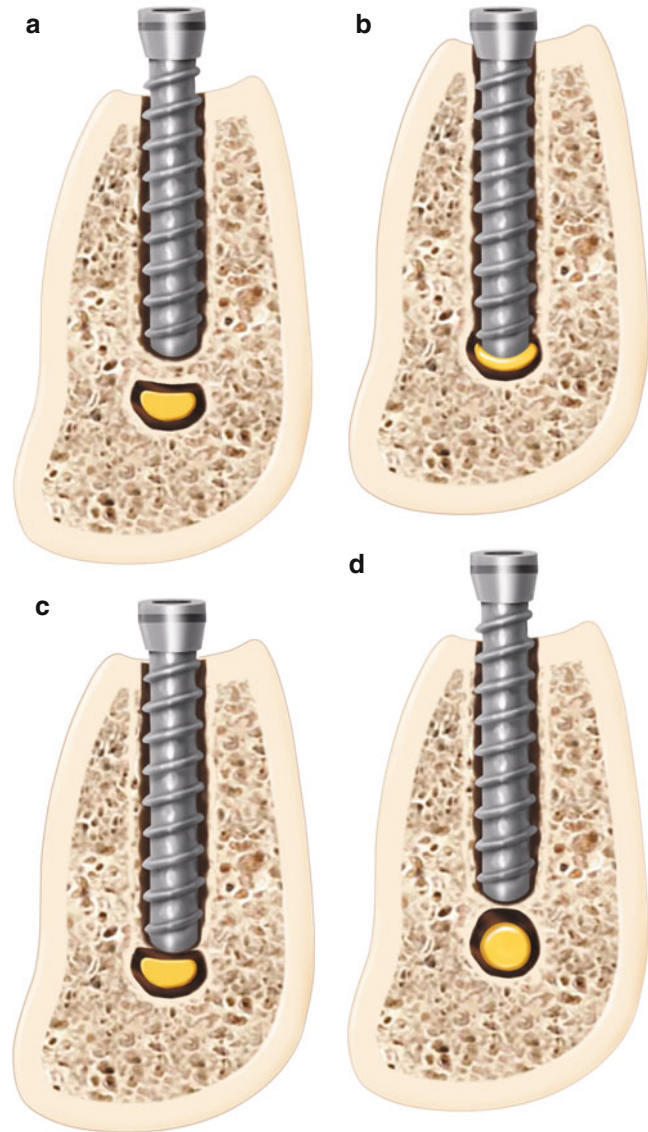
6.3.1 Evaluation of Nerve Injuries

Neurosensory disturbances are evaluated and documented in a standard fashion using the Medical Research Council Scale (MRCS) guidelines, as modified for the oral and maxillofacial regions, regardless of the etiology of the sensory nerve injury. The evaluation of nerve injuries is discussed in Chap. 10. Since many of these implant-related injuries result in dysesthesia, specific attention should be directed towards the time frame of the injury and the likelihood that pharmacologic management may be indicated.

6.3.2 Treatment

Timely repair of peripheral nerve injuries has always been the sine qua non for successful recovery of nerve function, especially since

Fig. 6.4 (a) Collapse of the superior aspect of the IAC due to implant placement beyond the planned osteotomy causing injury to the nerve (compartment syndrome). (b) Direct injury to the IAN by implant contact. (c) Direct injury to the cortical rim of the IAC with deformation of the neurovascular bundle. (d) Remodeling of the IAC cortical rim causing narrowing of canal



Seddon's extensive experience with treatment of missile injuries to extremities during and following WWII. His comment [31], "(i)f a purely expectant policy is pursued, the most favorable time for operative intervention will always be missed..." is as pertinent today as it was more than 60 years ago. As in all other causes of nerve injury, treatment of the patient with a dental implant-associated nerve injury is dependent upon the correct diagnosis of the injury and its *timely* management.

The perioperative administration of supportive medications has been advocated for patients undergoing procedures such as dental implants, mandibular osteotomies, and lower third molar removal that are associated with a significant risk of nerve injury. There is conflict in the literature between those who recommend beginning corticosteroids preoperatively [1] and others who advise waiting postoperatively for several days before initiating administration to allow for edema resolution and tissue perfusion of the medication

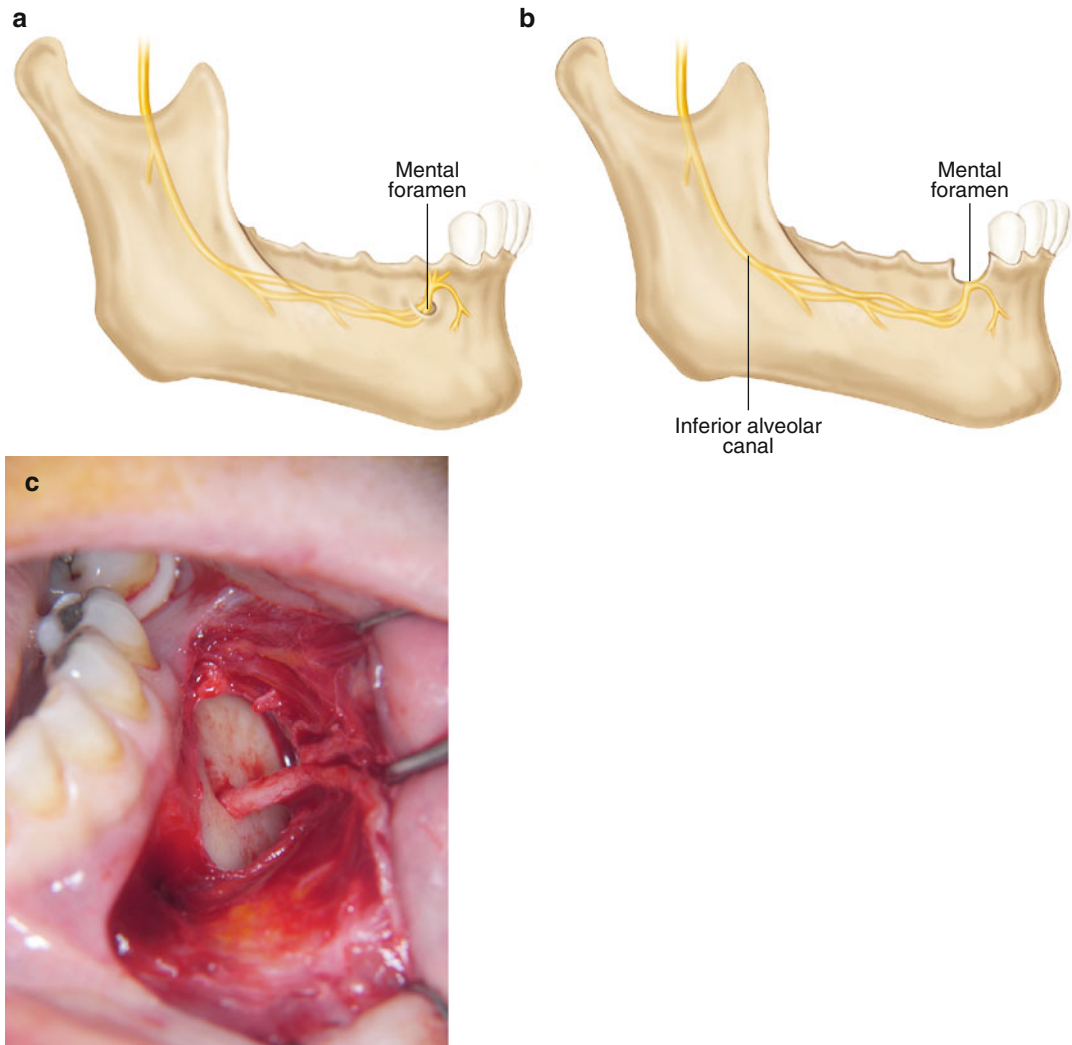


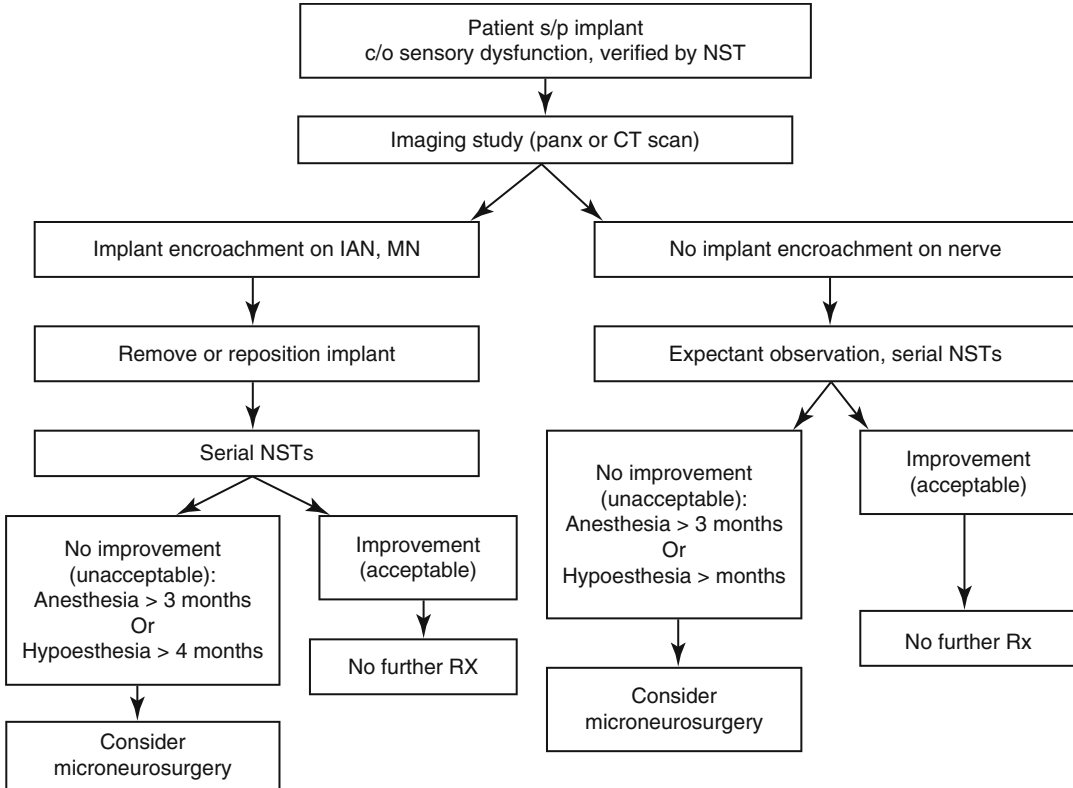
Fig. 6.5 (a) Superior position of the mental foramen due to resorption of the alveolar bone in the partially edentulous mandible. (b) Dehiscence of the IAC, where the IAN

and the MN come to lie on the alveolar ridge crest. (c) Exposure of the MN with gentle traction and frequent relaxation minimizes the chance of nerve injury

[32]. Many surgeons routinely administer a single preoperative intravenous dose of a steroid (dexamethasone or hydrocortisone). Whether or not it is beneficial to initiate corticosteroid or anti-inflammatory (NSAID) medications *after* a nerve injury has occurred is questionable. Previous studies have documented the lack of benefit of corticosteroids administered to reduce cerebral edema in patients who have sustained closed head injuries. That the IAN, in a similar “closed box” situation, confined within the IAC,

could benefit from a retroactively administered corticosteroid seems unlikely as well, although that data is conflicting.

An algorithm for the management of nerve injuries from dental implant surgery is shown in Table 6.1. The patient who complains of decreased or painful sensation following placement of dental implants should be requested to return to the office for evaluation. In some patients a nerve injury might have been suspected, if the patient complained of a

Table 6.1 Algorithm for the management of nerve injuries from dental implant surgery

NST neurosensory testing, *MN* mental nerve, *IAN* inferior alveolar nerve, *Panx* panoramic radiograph, *CT* computerized tomography, *Rx* treatment

paresthesia during local anesthetic injection or during the bone drilling preparation for implant placement. In most cases, however, the patient may be under intravenous sedation, and there is typically no indication during the procedure of a nerve injury. It is recommended that the patient be seen as soon as possible and convenient for the patient, preferably within 24 h, or the same day, if painful sensation is the chief complaint, so that adequate pain control can be established and rapport with the patient maintained. The exact nature of the complaint(s) should be ascertained. A general oral exam is performed to assess the healing status of the surgical site. Neurosensory testing (NST) is done to establish an objective baseline determination of the level of sensory dysfunction for further follow-up, as indicated.

A panoramic radiograph is obtained to determine the position of the implant(s) in relation to

the IAN. If there is no close relationship of the implant and the IAC on the panoramic film, *no repositioning or removal of the implant is indicated and should be done*. The patient is followed *expectantly* with frequent repeat NST to assess progress of recovery of sensation. Those patients who go on to *acceptable* (to the patient) spontaneous recovery require no further active treatment. Patients who fail to regain acceptable sensory function within 3 (anesthesia) or 4 (hypoesthesia \pm pain) months are referred to a microneurosurgeon for possible nerve exploration and repair. On the other hand, if there is *superimposition* of the implant over the IAC on the panoramic film, a CT or CBCT scan is obtained to determine whether this represents an *encroachment* upon the IAN or IAC, or simply a two-dimensional radiographic *overlap* that cannot be distinguished on the panoramic radiograph. If the CT demonstrates that the implant is not in contact with the IAC, the

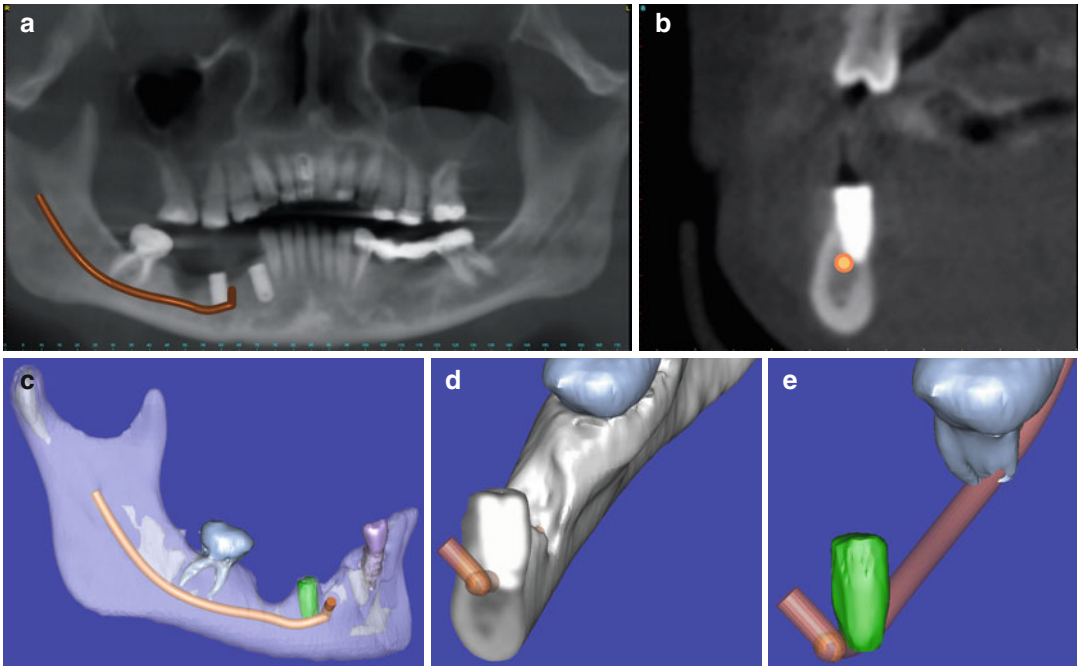


Fig. 6.6 (a) CT-generated panoramic radiograph demonstrating the position of the implant #29 to the IAC in a patient with severe dysesthesia of the IAN following implant placement. (b) Cross-sectional view (coronal) of the same patient demonstrating impingement of the

implant on the IAN within the IAC. (c) 3D reconstruction image with transparency of the osseous structures showing the IAC and the implant. (d) 3D reconstruction in cross-section. (e) 3D reconstruction in cross-section with digital removal of the osseous structures

implant can be maintained and the patient is followed *expectantly* with serial NST to determine if spontaneous recovery occurs (see above) (Fig. 6.6a–e).

On the contrary, if the implant is in direct contact with the IAC, then the implant should be repositioned *immediately* (prior to osseointegration) to create at least a 2-mm separation between the apical aspect of the implant and the IAC. If this implant repositioning encroaches unacceptably on the interocclusal clearance, then the implant should be removed and replaced with a shorter implant. This may allow the patient to maintain the implant despite the outcome of nerve injury. If the implant cannot be repositioned without compromising its stability, then it should be removed; consideration could be given towards the use of a shorter implant with a wider diameter to engage the bone for primary implant stability. The patient should be reevaluated with NST within 1 week. If there are signs of neurosensory recovery, no further treatment may be necessary, except for interval NST to

document progress to satisfactory return of sensation (“useful sensory function,” or better). The implant can be restored if it has adequate stability and meets acceptable prosthodontic criteria for restoration. It should be remembered that if the implant was close to the IAC, that once the implant is restored and placed into function that neurosensory symptoms may occur during mastication whereby pressure is placed within the closed environment of the IAC. In this case either occlusal adjustment of the implant restoration or removal or “sleeping” the implant may be necessary depending upon the individual patient and clinical symptoms.

If, upon removal or repositioning of the implant, the patient does not show *acceptable* signs of recovery within 3 (anesthesia) or 4 (hypoesthesia/pain) months by serial NST, microsurgical consultation is indicated. Since the IAN lies within a bony canal, spontaneous recovery might occur due to “guided regeneration” of the nerve provided by the confines of the canal. In such a case, recovery of sensory function should

begin (onset of symptoms, responses to NST) within 3 months after nerve injury. Microsurgical consultation can be considered earlier if there is a diagnosis of nerve transection (i.e., by direct visualization at the time of surgery). The so-called 12-week rule for the anesthetic patient has subsequently come to be recognized by many of those surgeons who care for nerve injuries as the standard for timely decision-making for the nerve injury patient who has an unacceptable persistent total loss of sensory function [3–6]. The patient who still has partial, but unacceptable, recovery of sensation at 3 months after nerve injury can be followed at regular (1-month) intervals as long as there is progressive improvement in subjective symptoms and NST at each visit. Once improvement ceases, it will typically not resume at some indeterminate time in the future, and a treatment decision is made at that time, depending upon the level of the sensory deficit according to the NST, the patient's subjective assessment of his status, and any associated functional impairment.

shows various microneurosurgical operations (note: these should include only nerve repairs secondary to dental implant-associated injuries). Although it is beyond the scope of this chapter to discuss all the techniques listed in Table 6.2, in a review of 167 IAN injuries [6], the most commonly performed operation was autogenous (sural or great auricular) nerve grafts ($n=71$, 38.2 %) for reconstruction of a nerve gap, followed by internal neurolysis ($n=60$, 32.3 %) when the nerve was not discontinuous. The need for reconstruction of a nerve gap was much more frequent with the IAN than that of the LN [4]. This has to do with the greater ease with which the proximal and distal stumps of the LN, contained within soft tissue, are able to be mobilized and brought into approximation for suturing without tension, than is the case with the IAN contained within a bony canal. This certainly has implications for the dental implant patient with a nerve injury, the majority of which are related to the IAN, and not the LN.

6.4 Surgical Procedures for IAN Injuries from Dental Implants

A list of *microneurosurgical* procedures that can provide surgical management of IAN injuries from dental implants is provided in Table 6.2. Figure 6.7

6.4.1 Nerve Exploration

High-resolution CT imaging can provide extensive detail of the bony anatomy, including the IAC. Although high-resolution magnetic resonance imaging (MRI) may be able to provide adequate visualization of the LN or MN [23], the

Table 6.2 Nerve procedures for dental implant-related nerve injuries

| Nerve procedure | Goals |
|---|---|
| External neurolysis (decompression) | Removal of surrounding bony, soft tissue, and/or foreign material around the nerve |
| Internal neurolysis | Opening of the epineurium to inspect and decompress the nerve fascicles |
| Excision of neuroma | Removal of a neuroma (disorganized nerve scar tissue) associated with a nerve |
| Neurorrhaphy | Microsurgical anastomosis of a transected nerve or two nerve stumps |
| Nerve graft | Placement of an interpositional nerve (allogeneic or autogenous) between two ends of a nerve |
| Nerve sharing | Microsurgical anastomosis of a distal nerve to a different proximal nerve via an interpositional nerve graft |
| Entubulization or “guided” nerve regeneration | Use of an interpositional conduit to guide axonal sprouting and regeneration across a nerve gap from the proximal to distal nerve |
| Neurectomy | Microsurgical transection and removal of a segment of a peripheral nerve |
| Nerve capping | Covering the proximal stump of a transected nerve with its own epineurium to prevent neuroma formation |
| Nerve redirection | Rerouting of the sensory innervation of a nerve to a different anatomic location (usually adjacent muscle); usually done to prevent deafferentation |

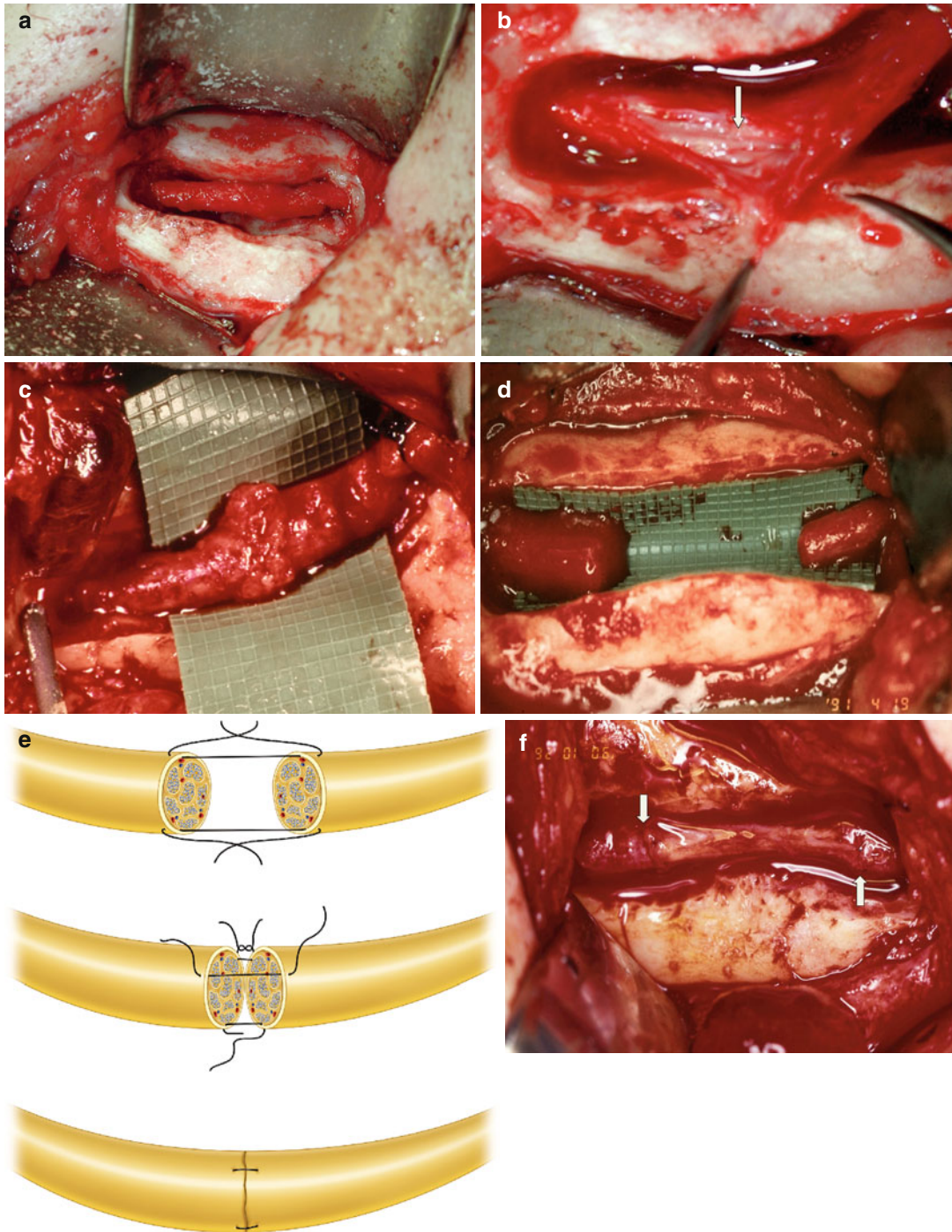


Fig. 6.7 Microneurosurgical procedures: (a) External decompression of the IAN. (b) Internal neurolysis of IAN. *Arrow* shows intact fascicles. (c) Neuroma-in-continuity of the IAN. (d) IAN after excision of a neuroma-in-continuity. (e) Diagram of a direct neurorrhaphy. (f) Sural nerve graft for IAN reconstruction. Areas of microanastomosis

(arrows). (g) Decellularized human nerve graft (Axogen Avance, Alachua, FL) for IAN reconstruction. (h) Diagram of guided tissue regeneration with conduit repair (entubulation). (i) Neurectomy and epineurial nerve capping. (j) Nerve redirection procedure

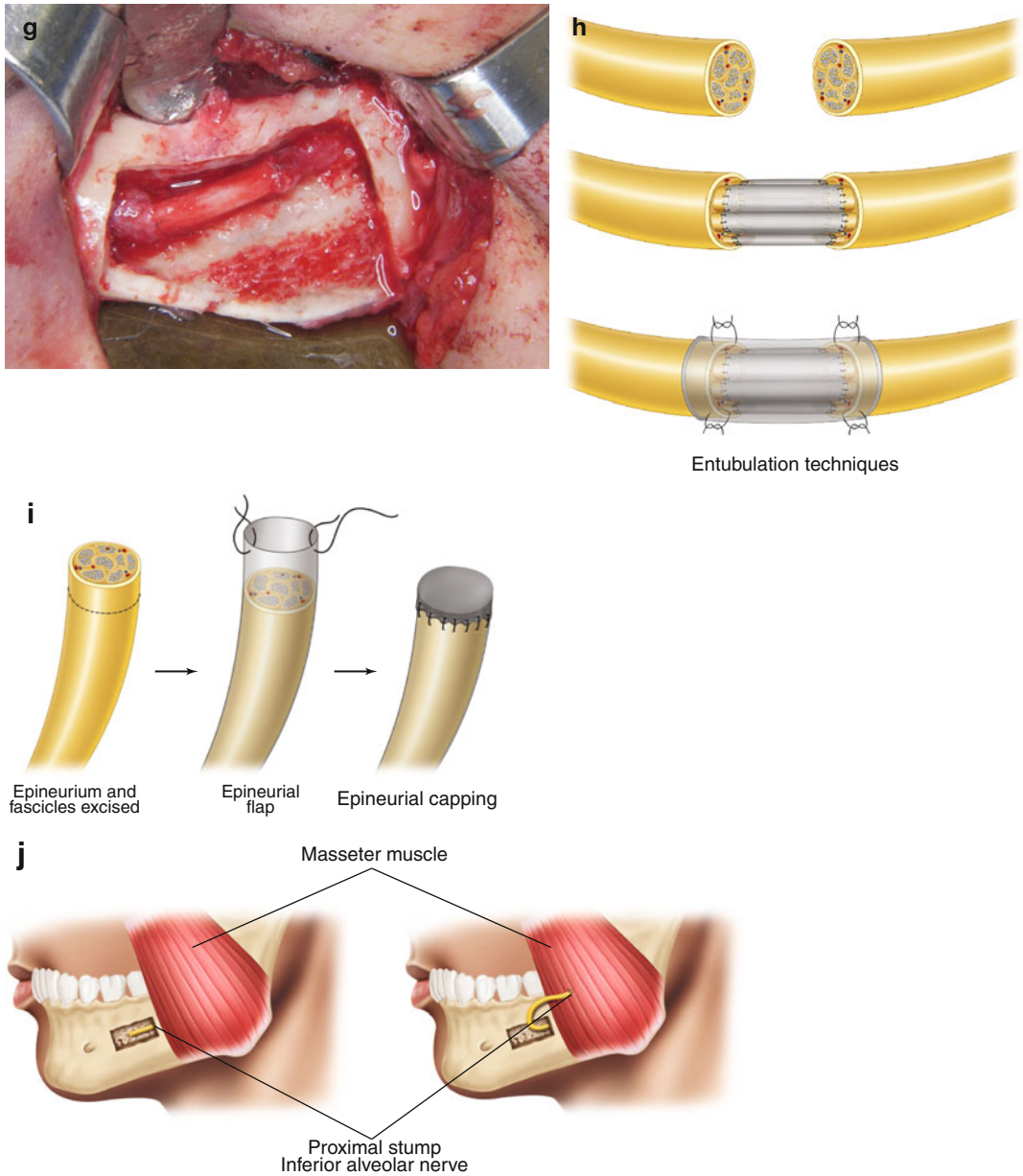


Fig. 6.7 (continued)

ultimate view of the injured nerve requires visualization provided only by surgical exploration. Exploration of the IAN will reveal any gross anatomic abnormalities, the presence of bony fragments or foreign bodies (e.g., bone graft materials) that may be impinging upon the nerve, any contact of the nerve with the implant (Fig. 6.8), or the formation of scar tissue associated with the nerve (Fig. 6.9).

6.4.2 Dental Implant Removal

The technique of implant removal will depend upon whether the implant has achieved osseointegration. If the implant is fully osseointegrated, it is best removed using a trephine bur that cuts circumferentially around the implant allowing implant removal with minimal sacrifice of surrounding bone. A recently placed implant

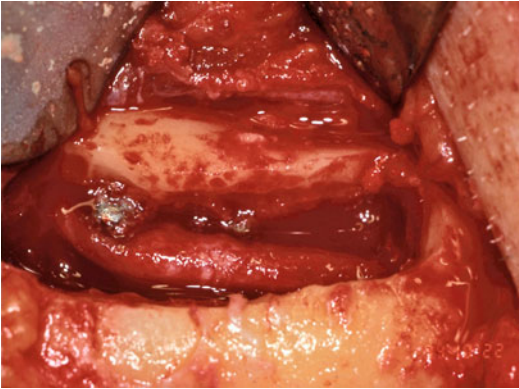


Fig. 6.8 Exploration of the IAN via a transfacial approach and removal of the buccal cortex, showing a mandibular implant impinging and deforming the integrity of the IAN

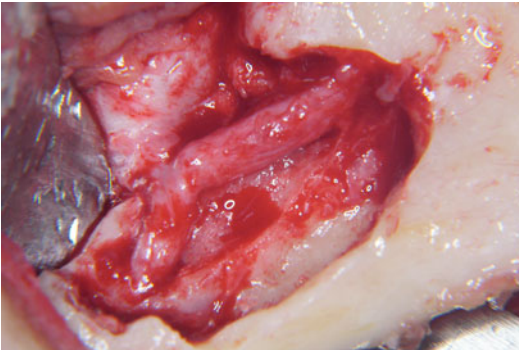


Fig. 6.9 Exploration of the IAN revealing extensive scar tissue formation compromising the integrity of the nerve secondary to a direct implant drill injury, in a patient with pain and anesthesia of the right lower lip and gingiva

that has not osseointegrated can be removed using a torque wrench or handpiece. Appropriate bone preservation techniques should be used for possible future implant replacement. However, care must be taken not to further injure the nerve by compressing bone graft material onto the exposed nerve through the superior aspect of the IAC as described above. Additionally, it may be preferred to remove the involved implant and replace it immediately with a shorter implant. In the event that there is not adequate primary implant stability of the same diameter but shorter implant, a wider diameter and shorter implant can be used for immediate replacement.

6.4.3 Nerve Repositioning

CT imaging and navigation-guided implant placement have provided some protection against IAN injury since there is no magnification error associated with these imaging techniques, but proper planning is still essential. However, when preoperative imaging studies indicate an unfavorable location of the IAC either inferosuperiorly or mediolaterally, the implants cannot be placed without a high risk of injury to the IAN. It may be possible to place the implant in a position buccal or lingual to the IAC, but this may place the IAN at further risk for injury. Additionally, in such cases a *nerve repositioning procedure* may be indicated [11, 14, 18]. In this procedure the lateral cortex of the mandible is removed at the desired location for implant placement. The mental nerve can be freed from the foramen if the implants are planned in close proximity to this area. If necessary, the incisive nerve is transected at its junction with the mental nerve to allow lateralization of the IAN. The nerve is carefully lateralized from the canal to allow placement of the implant(s) medial to the lateralized IAN as needed (Fig. 6.10). An autogenous bone graft, either from the bone removed to unroof the IAC, or elsewhere, or freeze-dried bone allograft, is *always* placed between the repositioned nerve and the associated implants in order to prevent direct contact of the IAN and thermal transmission with the implant(s). Also, *artificial material*, such as calcium hydroxyapatite, should *never* be placed in direct contact with the nerve. A severe inflammatory reaction in the nerve, similar to a chemical burn with dense scarring, accompanied by considerable pain, is often the unfortunate result. Surgical treatment of such injuries is problematic. For further discussion of nerve repositioning, see Chap. 7.

6.4.4 Excision of Neuroma

Neuroma formation can be the result of direct drill injury, or direct or indirect implant injury to the IAN (Fig. 6.11a). A *neuroma-in-continuity* usually represents a partial nerve transection

with subsequent healing predominated by scar formation and the presence of nonconducting nerve tissue. The vast majority of these injuries are repaired using nerve grafts (see next sec-

tion) to restore the continuity of the defect following neuroma excision to healthy nerve tissue proximally and distally from the site of injury (Fig. 6.11b).

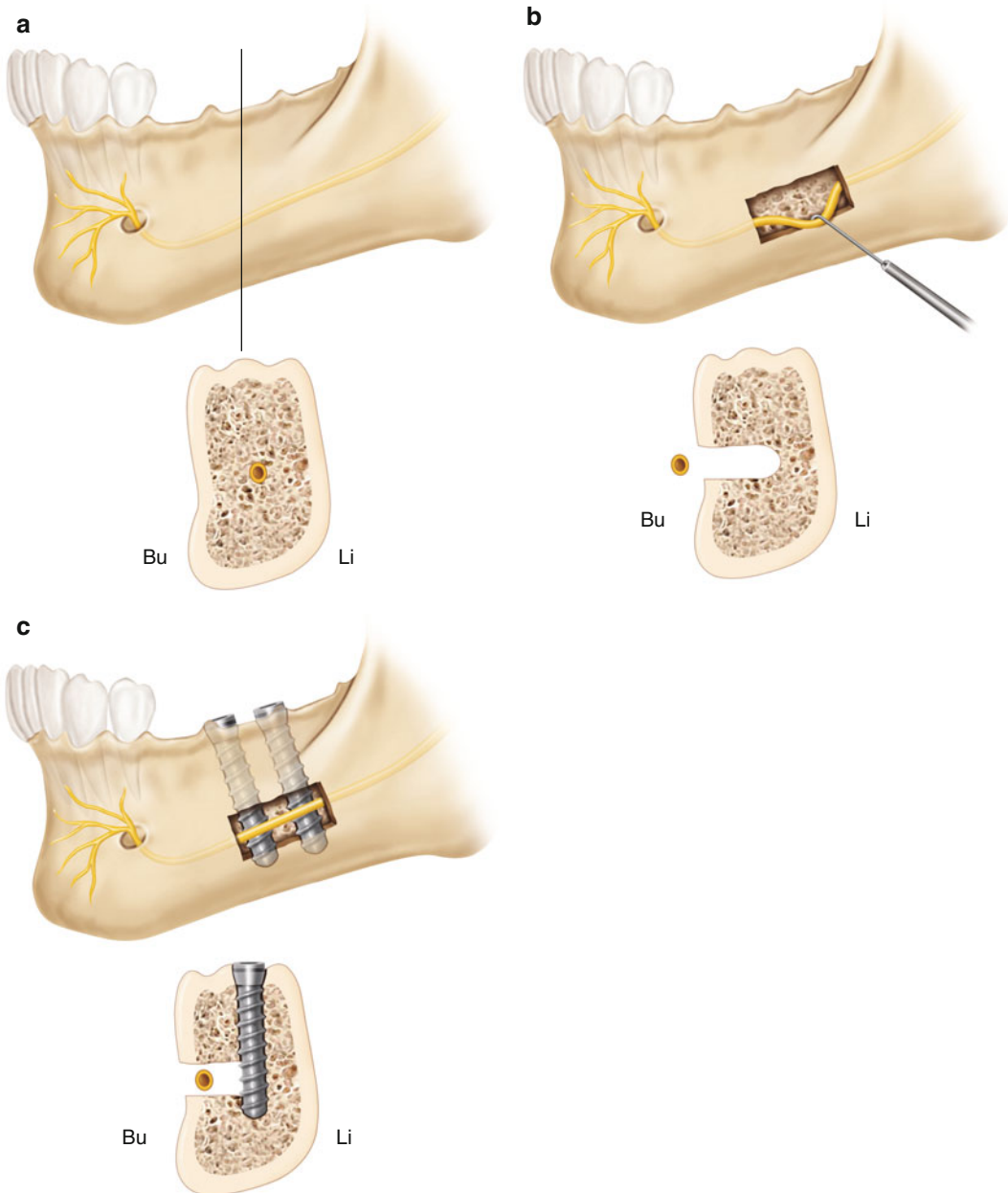


Fig. 6.10 (a) Schematic representation of anticipated implant placement in the posterior right mandible. (b) IAN lateralization. (c) Placement of two dental implants beyond the IAC after nerve lateralization. (d) Preoperative panoramic radiograph

of failing dental fixed prosthesis and edentulous posterior mandible. (e) Placement of two dental implants lingual to the IAC after nerve lateralization. *Bu* Buccal; *Li* Lingual

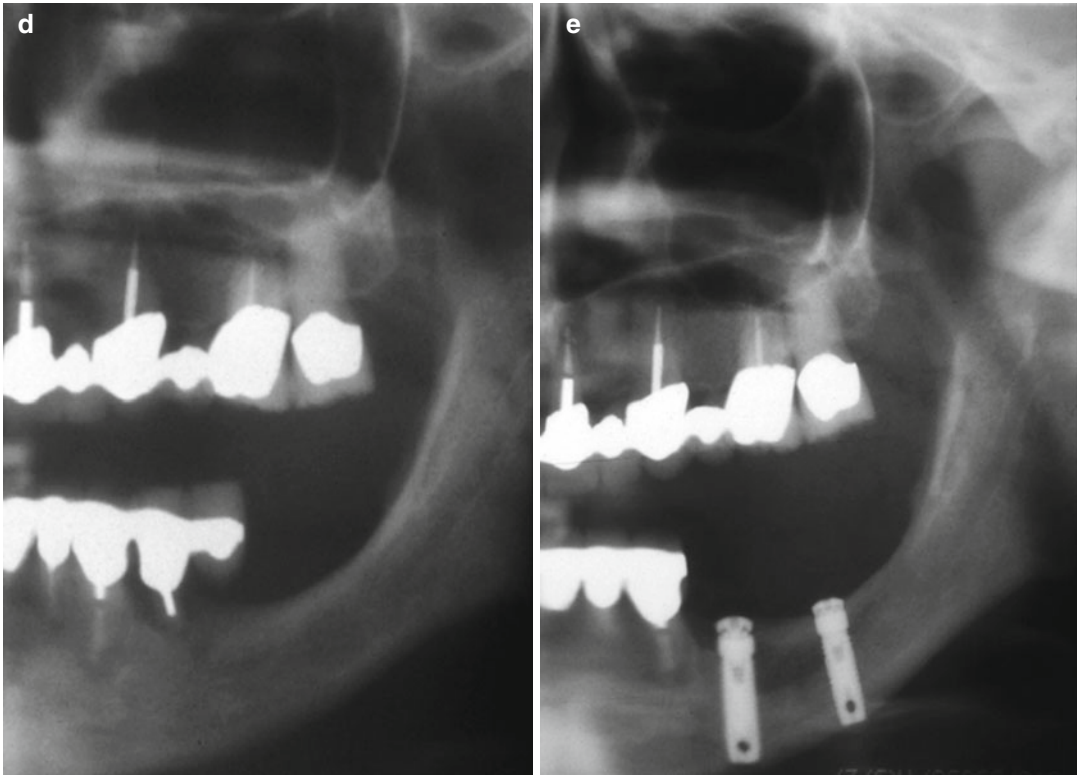


Fig. 6.10 (continued)

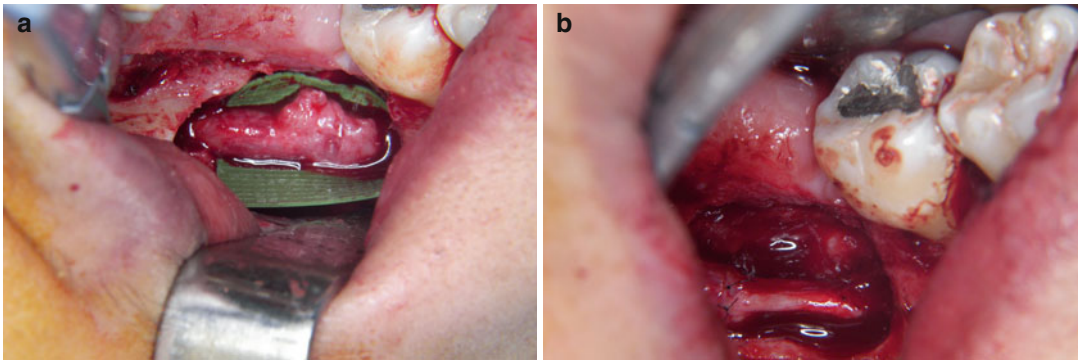


Fig. 6.11 (a) Intraoral exposure of the IAN with a neuroma-in-continuity secondary to implant placement in the area of the second molar. (b) Microsurgical repair using an autogenous nerve graft

6.4.5 External Neurolysis (Decompression) and Internal Neurolysis

Compression of the IAN can be seen with collapse of the IAC, or impingement on the nerve by the implant or other foreign bodies (e.g., bone

graft material). External neurolysis, or decompression, is the removal of surrounding bone, soft tissue structures, and/or foreign material around the nerve (Fig. 6.7a). In cases where the implant is found to compress the nerve (Fig. 6.8), repositioning of the nerve is an option for decompression (see previous section). Internal

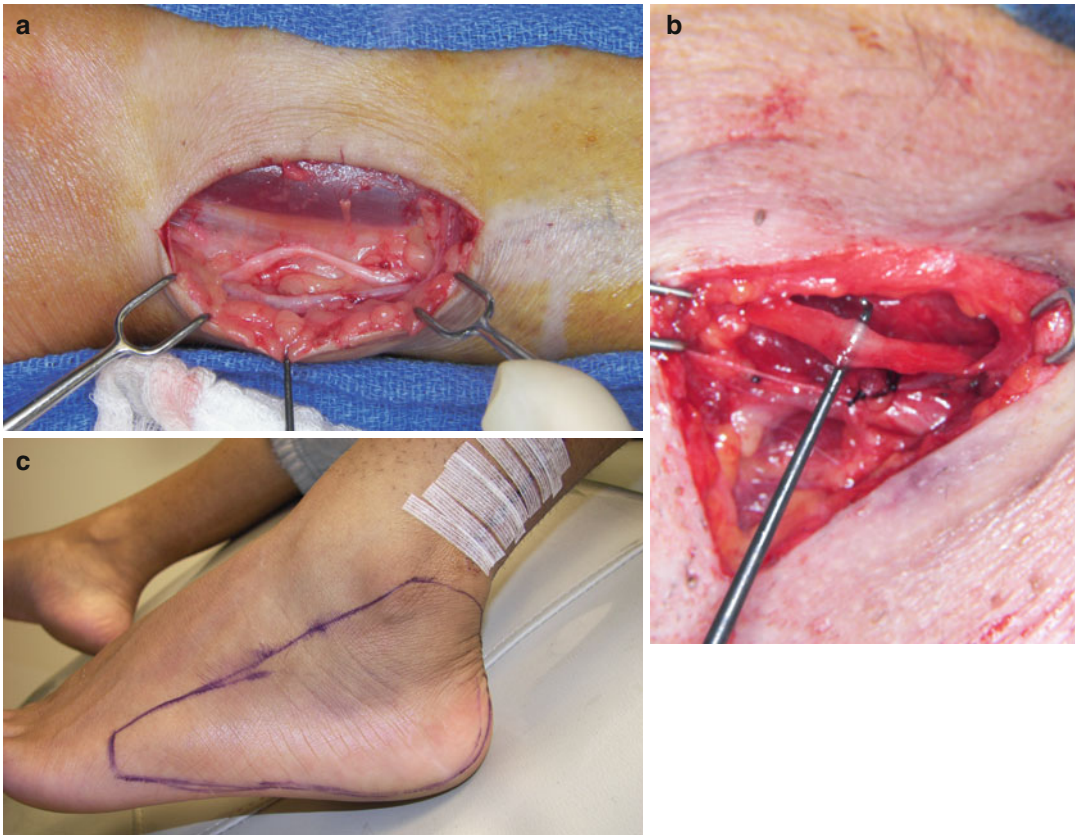


Fig. 6.12 (a) Sural nerve graft harvest. (b) Greater auricular nerve harvest. (c) Resulting area of anesthesia following sural nerve harvest

neurolysis is the opening of the epineurium to inspect the internal neural structures and decompress the individual nerve fascicles (Fig. 6.7b). If there is a continuity defect of one or more of the fascicles, then neurorrhaphy or nerve graft reconstruction is indicated. If the nerve is found to be intact, an external decompression and internal neurolysis are sufficient. Extensive or aggressive attempts at internal neurolysis carry the risk of scar formation and iatrogenic injury to the fascicles, so this technique must be performed with great care and precision.

6.4.6 Neurorrhaphy

Unlike the lingual nerve, injuries to the IAN are difficult to repair by direct neurorrhaphy due to the relative inability to mobilize and advance the IAN into approximation across a nerve gap without tension, unless the incisive nerve (IN) is

transected to allow increased mobility of the nerve stumps. However, release of the IN leaves the patient with sensory loss in the lower incisor teeth and the mandibular labial gingiva. The stump of the transected IN may develop a stump neuroma, with the potential for neuropathic pain. These disadvantages should be weighed against considerations to attempt tension-free approximation of the IAN without interposition of an autogenous nerve graft.

6.4.7 Nerve Grafts

The *sine qua non* of a successful neurorrhaphy is to bring the proximal and distal stumps of a transected nerve together and suture them in this position *without tension*. When the surgeon is unable to accomplish this, reconstruction of the space between the two nerve stumps (the *nerve gap*) can be performed with an interpositional

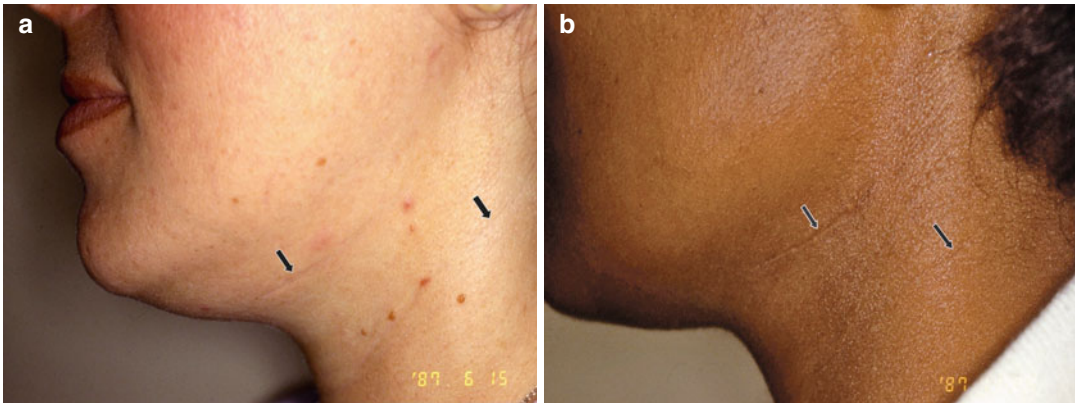


Fig. 6.13 (a) One-year postoperative view of a healed Risdon incision in an 18-year-old female demonstrating minimal scar visibility. (b) Surgical scars (*arrows*) from

submandibular incision to expose the IAN and neck incision to harvest a great auricular nerve graft in a 21-year-old African-American female 1 year after the operation

nerve graft [20]. Both autologous and allogeneic nerve grafts can be utilized. The sural (SN) and greater auricular nerve (GAN) are the most commonly used autogenous grafts for maxillofacial nerve repairs (Fig. 6.12a, b). The SN provides a better size match and longer length than the GAN. The disadvantages of this graft are the vertical scar just posterior and superior to the lateral malleolus of the ankle, although a transverse incision could be used [24]; the added operative time to reposition the patient and access a distant surgical site; and the associated donor site morbidity (anesthesia of the lateral foot, temporary gait disturbance, pain) (Fig. 6.12c). The GAN is easily harvested along its superficial course lateral to the sternocleidomastoid muscle approximately 6 cm inferior to the ear lobe. The main disadvantages of the GAN are the neck scar, ear lobe anesthesia, and its smaller (than the recipient IAN or LN) diameter. The incision for harvesting the GAN is usually made in a natural skin crease in the lateral neck, and a careful closure usually results in an inconspicuous scar (Fig. 6.13). Loss of sensation in the lower part of the earlobe is seldom a concern to patients. When the diameter of the GAN is smaller than that of the recipient nerve, a *cable graft* (using multiple strands of GAN) can correct this discrepancy.

In addition, decellularized human nerve allografts (Axogen Avance, Alachua, Florida) are readily available for trigeminal nerve reconstruction (Fig. 6.7g). Ongoing studies to determine the success of this nerve in the maxillofacial area is pending, although the initial results are

promising. It is another option to avoid donor site morbidity of autogenous nerve grafting.

6.5 Complications of Surgical Treatment

The main complications associated with microsurgical repair of nerve injuries from dental implants are related to the specific surgical procedure, expected sensory outcomes, timing of surgery, patient age and medical status, and risks of general anesthesia.

6.5.1 Specific Surgical Procedures

Surgical access to the IAN is dependent upon the location of the nerve injury, the planned procedure, and the surgeon's preference. The IAN has a long course, branching from the mandibular nerve in the pterygomandibular space, traveling anteriorly until it enters the mandibular foramen on the medial mandible, continuing within the IAC, and, just before exiting at the mental foramen, dividing into its two terminal branches, the IN and the MN. Injuries to the IAN in the IAC and more proximally in the pterygomandibular space (needle injuries) are difficult to visualize and repair without performing a mandibular ramus osteotomy for additional access. Such operations are seldom done for nerve repair unless as part of tumor resection. However, when

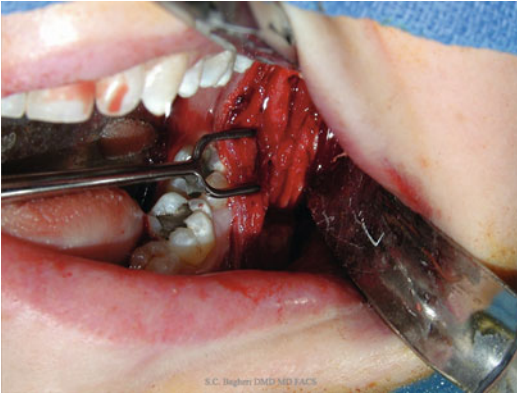

Fig. 6.14 Exposure of the IAN via an intraoral access

the proximal IAN is not accessible, or otherwise unreparable, a *nerve-sharing procedure* can be done without the requirement of a mandibular ramus osteotomy [16]. In this operation, an autogenous sural nerve graft is used to connect the proximal great auricular nerve to the distal IAN. The IAN in the area of the third molar can be accessed via both transoral and transcutaneous incisions. The standard Risdon incision allows excellent access to the entire nerve from the area of the mandibular canal to the mental foramen. The main disadvantage of this access is the small possibility of permanent injury to the marginal mandibular branch of the facial nerve (less than 1 %) and the facial neck scar (especially in younger individuals that do not have a naturally visible neck crease). However, placement of the incision along the relaxed skin tension lines (RSTL), meticulous attention to closure, continued support of the healing incision with adhesive strips, proper skin care, and protection with sunscreens for up to 1 year after operation will enhance the likelihood of an inconspicuous scar (Fig. 6.13a). In African-Americans, the injection of the incision margins with a corticosteroid (e.g., triamcinolone) before closure, and on a monthly basis thereafter as indicated, reduces the risk of formation of a hypertrophic scar or keloid (Fig. 6.13b).

The IAN can also be exposed transorally via a variety of techniques including a modified sagittal split ramus osteotomy or by decortication (removal of the lateral cortex to create a window

of exposure) (Fig. 6.14). The main disadvantage of the transoral approach is the reduced visibility and access, mainly posterior to the mandibular first molar. Although technically more difficult, successful nerve repairs, including interpositional grafting, may be accomplished via this approach.

6.5.2 Expected Sensory Outcomes

The fact that microsurgical repair of injured peripheral nerves achieves some degree of successful improvement in sensory function and reduction of pain in some patients has been established [12, 17, 29]. However, as in all operations on sensory nerves, the failure to improve sensation or relieve dysesthesia does occur in some patients. In our study of 167 patients who underwent IAN repair and returned for at least 1-year follow-up, the majority of patients complained preoperatively of numbness ($n=62$, 33.3 %) or numbness with pain ($n=91$, 48.9 %). Recovery from neurosensory dysfunction of the IAN (defined by the MRSC as ranging from “useful sensory function” to “complete return of sensation”) was achieved in 152 IANs (81.7 % with complete recovery or recovery to “useful sensory function”), while 18.3 % of nerves showed no or inadequate improvement [6].

6.5.3 Timing of Surgery and Age of Patient

The results of microsurgical intervention are related statistically to the length of time between nerve injury and microsurgical repair, as shown in previous studies. In our report of 222 repaired LN injuries, using the logistic regression model, the shorter the duration of time (in months) between nerve injury and repair, the higher the odds of improvement. This work is in agreement with that of Susarla who found a relationship between early repair of LN injuries and a more favorable outcome as judged by the patient [33]. In our series of 167 IAN repairs, the likelihood of functional sensory recovery decreased with increasing duration from nerve injury to its repair, and favorable surgical outcome was decreased with

increased age of the patient [6]. It should be remembered that some studies have shown that time from injury to repair is not a significant factor, however. The significance of age and length of time from nerve injury to its repair is especially pertinent to the dental implant patient. Most of the patients who sustain dental implant-associated nerve injuries that failed to improve or resolve spontaneously and are referred for evaluation and treatment are greater than 50 years of age and had suffered their nerve injury more than 9 months prior to the initial consultation. These factors all potentially impact negatively on neurosensory recovery following any form of treatment.

6.5.4 Patient's Medical Status and Risk of General Anesthesia

Preoperative evaluation of the patient's medical status and risk assessment for general anesthesia for a microneurosurgical operation is performed as needed in consultation with other medical specialties. The risks of general anesthesia for a prolonged procedure include deep vein thrombosis with potential for embolization, pulmonary atelectasis with development of pneumonitis, and urinary tract infection from catheterization. These risks may be greater in the older patient population that most often presents for treatment of dental implant-associated nerve injuries. Measures to prevent these risks should be part of the routine care of the patient.

6.6 Postoperative Rehabilitation

Care of the nerve-injured patient does not end with the operation, provision of the usual pain relief, attention to incision care, and recommendations for resumption of normal activities and diet. Measures to enhance sensation and restore related orofacial functions must be included in the rehabilitation of the nerve-injured patient to achieve optimal results.

Younger individuals have better functional recovery after peripheral nerve injury than mature adults (those most likely to have dental implants

and, therefore, more at risk of associated nerve injuries). Observations in the human patient are limited, but clinical experience indicates that the efficiency of neural regeneration is less in later life [26, 34]. Neuropsychological factors also influence the ability of the patient to recover successfully from a peripheral nerve injury following surgical repair. There is the need to learn new axonal connections with referral of sensory input to different areas of the CNS. Early in the recovery process, axons exhibit slower conduction time making interpretation more difficult for the CNS until accommodations can be achieved; this is a situation analogous to a baseball batter having to adjust to a change-up (dramatically slower speed) pitch. Although the older patient is slower to adapt to these changes imposed by recovery from a peripheral nerve injury, *neuroplasticity* (the ability of the brain to adapt) is still viable even into advanced age.

The concept of "sensory reeducation," first developed by Wynn Parry [35] for rehabilitation of hand and upper extremity injuries, has been modified for the maxillofacial regions and shown to be successful in improving sensory function, once responses to pain and static light touch have returned [21, 25]. The goals of sensory reeducation for peripheral trigeminal nerve injuries are to improve or resolve *synesthesia* (failure to recognize the location of a stimulus), decrease hyperesthesia, improve recognition of the character and amplitude of stimuli (e.g., moving or stationary, sharp or dull, light or forceful application, size of area of contact), and decrease subjective differences (e.g., numbness) between the affected area and the corresponding normal contralateral area. Following microneurosurgery, sensory reeducation exercises are begun as soon as the area supplied by the repaired nerve begins to respond to painful stimuli and static light touch (usually within 3–6 months after surgery). The exercises are performed by the patient several times daily for a minimum of 12 months, or longer as needed. During this time the patient is monitored with NST to assess progress. Sensory reeducation can contribute to the nerve-injured patient's ability to improve his level of sensory function and associated orofacial activities.

Conclusions

Treatment of the patient who has sustained a nerve injury from dental implant procedures involves prompt recognition of this complication, evaluation of sensory dysfunction and the position of the implant, and timely management of the injured nerve. In some patients, removal or repositioning of the implant, or replacement with a shorter implant, and surgical exploration and repair of the injured nerve will maximize the implant patient's potential for a successful recovery from nerve injury.

Suggested Reading

- Al-Bishri A, Dahlin L, Sunzel B et al (2005) Systemic betamethasone accelerates functional recovery after a crush injury to rat sciatic nerve. *J Oral Maxillofac Surg* 63:973
- Bagheri SC, Meyer RA (2011) Microsurgical repair of injuries to the inferior alveolar nerve associated with dental implants. In: Steed MB (ed) *Atlas of the oral and maxillofacial surgery clinics of North America*
- Bagheri SC, Meyer RA, Khan HA et al (2009) Microsurgical repair of peripheral trigeminal nerve injuries from maxillofacial trauma. *J Oral Maxillofac Surg* 67:1791
- Bagheri SC, Meyer RA, Khan HA et al (2010) Retrospective review of microsurgical repair of 222 lingual nerve injuries. *J Oral Maxillofac Surg* 68(4): 715–723
- Bagheri SC, Meyer RA, Ali Khan H et al (2010) Microsurgical repair of the peripheral trigeminal nerve after mandibular sagittal split ramus osteotomy. *J Oral Maxillofac Surg* 68:2770–2782
- Bagheri SC, Meyer RA, Cho SH et al (2012) Microsurgical repair of the inferior alveolar nerve: success rate and factors which adversely affect outcome. *J Oral Maxillofac Surg* 70(8):1978–1990
- Bartling R, Freeman K, Kraut R (1999) The incidence of altered sensation of the mental nerve after mandibular implant placement. *J Oral Maxillofac Surg* 57: 1408–1410
- Boyne PJ (1982) Postexodontia osseous repair involving the mandibular canal. *J Oral Maxillofac Surg* 40: 69–77
- Branemark P-I (1983) Osseointegration and its experimental background. *J Prosthet Dent* 50:399–410
- Chaushu G, Taicher S, Haiamish-Shani T, Givol N (2002) Medicolegal aspects of altered sensation following implant placement in the mandible. *Int J Oral Maxillofac Implants* 17:413–415
- Dario LJ, English R (1994) Achieving implant reconstruction through bilateral mandibular nerve reposition. *J Am Dent Assoc* 123:305–309
- Gregg JM, Zuniga JR (2001) An outcome analysis of clinical trials of the surgical treatment of traumatic trigeminal sensory neuropathy. *Oral Maxillofac Surg Clin North Am* 13:377
- Hillerup S (2011) Update on injuries related to injection of local anesthetics. In: *Symposium: update on nerve injury, diagnosis and repair. Amer Assoc Oral Maxillofac Surg, 93rd annual meeting, Philadelphia, 19 Sept*
- Jensen O, Nock D (1987) Inferior alveolar nerve repositioning in conjunction with placement of osseointegrated implants: a case report. *Oral Surg Oral Med Oral Pathol* 63:263–266
- Kraut RA, Chanal O (2002) Management of patients with trigeminal nerve injuries after mandibular implant placement. *J Am Dent Assoc* 133:1352–1354
- LaBanc JP, Epker BN (1992) Trigeminal nerve reconstruction surgery using the great auricular nerve transfer technique. *Oral Maxillofac Surg Clin North Am* 4: 459–463
- LaBanc JP, Van Boven RW (1992) Surgical management of inferior alveolar nerve injuries. *Oral Maxillofac Surg Clin North Am* 4:425
- Louis PJ (2001) Inferior alveolar nerve repositioning. *Atlas Oral Maxillofac Surg Clin North Am* 9:93–128
- Meyer RA (1992) Applications of microneurosurgery to the repair of trigeminal nerve injuries. *Oral Maxillofac Surg Clin North Am* 4:405
- Meyer RA (2001) Nerve harvesting procedures. *Atlas Oral Maxillofac Surg Clin North Am* 9:77–91
- Meyer RA, Rath EM (2001) Sensory rehabilitation after trigeminal nerve injury or nerve repair. *Clin North Am* 13:365
- Meyer RA, Ruggiero SL (2001) Guidelines for diagnosis and treatment of peripheral trigeminal nerve injuries. *Oral Maxillofac Surg Clin North Am* 13:383
- Miloro M, Halkias LE, Chakeres DW, Slone W (1997) Assessment of the lingual nerve in the third molar region using magnetic resonance imaging. *J Oral Maxillofac Surg* 55:134–137
- Miloro M, Stoner JA (2005) Subjective outcomes following sural nerve harvest. *J Oral Maxillofac Surg* 63:1150–1154
- Phillips C, Blakey G, Essick GK (2011) Sensory retraining: a cognitive behavioral therapy for altered sensation. *Atlas Oral Maxillofac Surg Clin North Am* 19:909
- Pola R, Aprahamian TR, Bosch-Marce M, Curry C, Gaetani E, Flex A, Smith RC, Isner JM, Losordo DW (2004) Age-dependent VEGF expression and intraneural neovascularization during regeneration of peripheral nerves. *Neurobiol Aging* 25:1361
- Pogrel MA, Bryan J, Regezi J (1995) Nerve damage associated with inferior alveolar nerve blocks. *J Am Dent Assoc* 126(8):1150–1155
- Pogrel MA, Thamby S (2000) Permanent nerve involvement resulting from inferior alveolar nerve blocks. *J Am Dent Assoc* 131(7):901–907

29. Pogrel MA (2002) The results of microneurosurgery of the inferior alveolar and lingual nerve. *J Oral Maxillofac Surg* 60:485
30. Queresby FA, Savell TA, Palomo JM (2008) Applications of cone beam computed tomography in the practice of oral and maxillofacial surgery. *J Oral Maxillofac Surg* 66:791–796
31. Seddon HJ (1947) Nerve lesions complicating certain closed bone injuries. *J Am Med Assoc* 135:691
32. Seo K, Tanaka Y, Terumitsu M et al (2004) Efficacy of steroid treatment for sensory impairment after orthognathic surgery. *J Oral Maxillofac Surg* 62:1193
33. Susarla S, Kaban L, Donoff RB, Dodson T (2007) Does early repair of lingual nerve injuries improve functional sensory recovery? *J Oral Maxillofac Surg* 65:1070–1076
34. Verdu E, Ceballos D, Vilches JJ, Navarro X (2000) Influence of aging on peripheral nerve function and regeneration. *J Peripher Nerv Syst* 5:191
35. Wynn Parry CB (1984) Brachial plexus injuries. *Br J Hosp Med* 32(3):130–132, 134–139
36. Ziccardi V, Steinberg M (2007) Timing of trigeminal nerve microsurgery: a review of the literature. *J Oral Maxillofac Surg* 65:1341–1345

Ali Hassani and Sarang Saadat

7.1 History and Terminology

Nerve repositioning is the subject of discussion in this chapter. In brief, in this procedure an osteotomy of the lateral mandibular cortex is performed, the inferior alveolar nerve (IAN) is lateralized outside of the inferior alveolar canal (IAC), then dental implants are placed under direct visualization with protection of the IAN as inferior as the basal bone, and may even engage the inferior cortex of mandible. Eventually the IAN is passively positioned aside the implants with or without an interpositional graft material. In this method, implants of greater length may be placed and even bicortical mandibular anchorage is possible. Treatment duration is shortened compared to other techniques utilizing bone grafting. However, this technique temporarily weakens the mandible and may predispose it to mandibular fracture [1–3]. Anatomic reconstruction of the lost alveolar bone cannot be achieved by this method [1, 2]. But, by using longer implants after nerve repositioning, resistance to occlusal forces increases and compatibility between the implant and the prosthesis improves

[2]. Postoperative sensory disturbances are among the most important complications and considerations with this technique.

From a historical perspective, Becker first described the protection of the IAN during resection of the mandible by way of lateralization technique in 1970 [4]. The first case of IAN repositioning for prosthetic rehabilitation was reported by Alling in 1977 to rehabilitate patients with severe atrophy for dentures [5]. Jenson and Nock in 1987 carried out IAN repositioning for placement of dental implants in posterior mandibular regions [6]. Subsequently, Kahnberg and Ridell used nerve repositioning of the IAN in orthognathic surgery in 1987 [7]. Regarding IAN repositioning for dental implant placement, in 1992, Rosenquist reported the first case series on 10 patients using 26 implants. He reported an implant survival rate of 96 % for this procedure [8]. Later he reported on 114 patients who underwent repositioning of the IAN to facilitate implant placement in 1995 [9], and therefore, this technique was accepted as a treatment modality for reconstruction of the dentoalveolar system with dental implants in the posterior mandible. Consequently, research studies began to evaluate various surgical techniques developed for this procedure, in terms of advantages, disadvantages, pitfalls, and methods for preventing or decreasing complications. As a result, this technique has constantly improved and changed over time. When evaluating the history of different treatment modalities and surgical techniques in various academic fields, we notice that most of them

A. Hassani, DMD (✉)
Department of Oral and Maxillofacial Surgery,
Tehran Azad University of Medical Sciences,
Dental Branch, Tehran, Iran
e-mail: drhassani.omfs@gmail.com

S. Saadat, DMD
Craniomaxillofacial Research Center,
Shariati Hospital, Tehran University of Medical Sciences,
Tehran, Iran
e-mail: ss_saadat@yahoo.com

have had limitations and complications at first but significantly improved with time and advancement of technology. Nerve repositioning is a relatively new procedure that needs further refinements in terms of technique and instrumentation to decrease the incidence of complications.

A few terms have been used to describe IAN repositioning. To interpret the literature, these terms, which many times are used interchangeably, must be defined. The first term is IAN lateralization. During this procedure the IAN is moved laterally after a portion of buccal plate of the mandible has been removed. A key factor in IAN lateralization is that the mental foramen is left undisturbed. At the completion of the procedure, the nerve is usually allowed to lie passively. When this procedure is used to facilitate implant placement, the nerve is in a more lateral position and the implants occupy the space where the nerve was once housed.

The second term is IAN transpositioning. During this procedure, the buccal cortical plate overlying the IAN, including the mental foramen, is removed. Once exposed, the incisive branch of the IAN is usually sectioned to facilitate transposing the nerve from the IAC in the area of the mental foramen for implant placement. The IAN is then removed from the IAC. In cases in which endosseous implants are planned, the nerve must be exposed at least 5 mm and up to 1 cm posterior to the most posteriorly planned implant. The mental foramen is therefore transposed to a more posterior position [10]. In some studies, the authors have used the term IAN distalization for this transpositioning procedure [11].

The last term is IAN repositioning, which is a more general term that can be used to include both IAN lateralization and IAN transpositioning (or distalization) [10].

7.2 Nerve Repositioning Techniques

Inferior alveolar nerve repositioning for implant placement is usually performed by two techniques as mentioned, including lateralization and transpositioning:

1. *Nerve lateralization*: IAN repositioning without mental nerve transpositioning or involve-

ment of mental foramen is usually employed when the edentulous area and alveolar ridge resorption do not include the premolars. This technique has been called nerve lateralization in some studies [11, 12] (Fig. 7.1).

2. *Nerve transpositioning*: In cases where the edentulous area and ridge resorption include the premolar teeth, there is a need for transpositioning of the mental neurovascular bundle and transection of the incisive nerve with transposing of the nerve distally (associated with mental nerve and mental foramen involvement). This method has been called IAN distalization in some studies [2, 11–13]

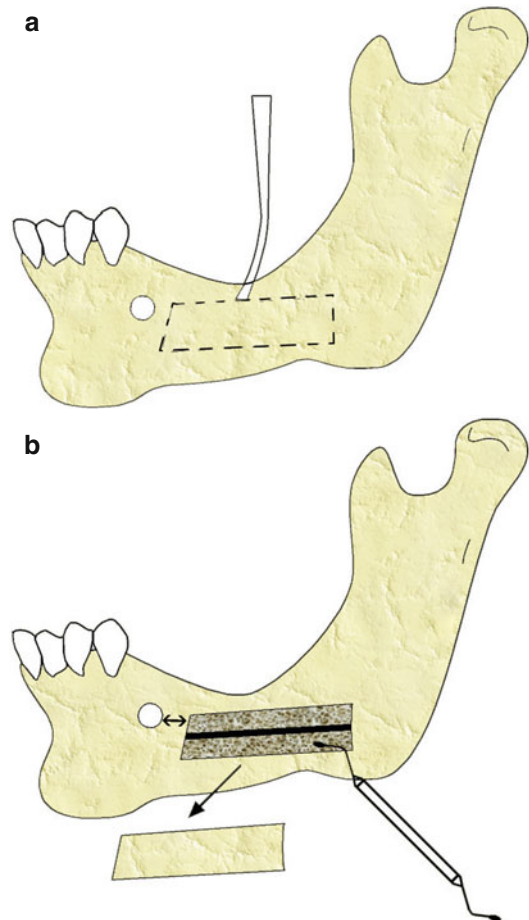


Fig. 7.1 (a) A bur is used to outline the location of bone block on mandibular buccal cortex by a distance from the inferior border of mandible and alveolar crest. The mesial incision should be made in 3–4 mm away from the mental foramen (2 sided arrow). (b) Then the buccal bone surrounding the canal is removed carefully by reciprocal motion using an osteotome

(Fig. 7.2). Another method that has been suggested is drilling the bone surrounding the canal using a handpiece and a round bur. In this technique, while the nerve is protected, minimum amount of bone is removed from the buccal cortex and the maximum amount of bone is preserved in an atrophic ridge for implant placement that results in maximum primary stability of the implant. Also, mandibular bone weakening is minimized in this method that is a great advantage of this technique. This instrument has been designed, patented, and manufactured by the author (Hassani nerve protector).

7.3 Patient Selection and Keys of Reducing Nerve Damage

Generally, IAN repositioning is used for different treatment goals. It is used for implant placement in the atrophic posterior mandibular alveolar ridge [1, 2, 10–13], orthognatic surgery [7], pain reduction in the atrophic ridge caused by a dental prosthesis pressure on the mental foramen [15, 17, 18], treatment of pathologic lesions of the posterior of mandible [19, 20], and transoral access to the IAN for microsurgery or nerve grafting [21].

In this surgery, as in other surgical operations, the process of selecting the appropriate patient is

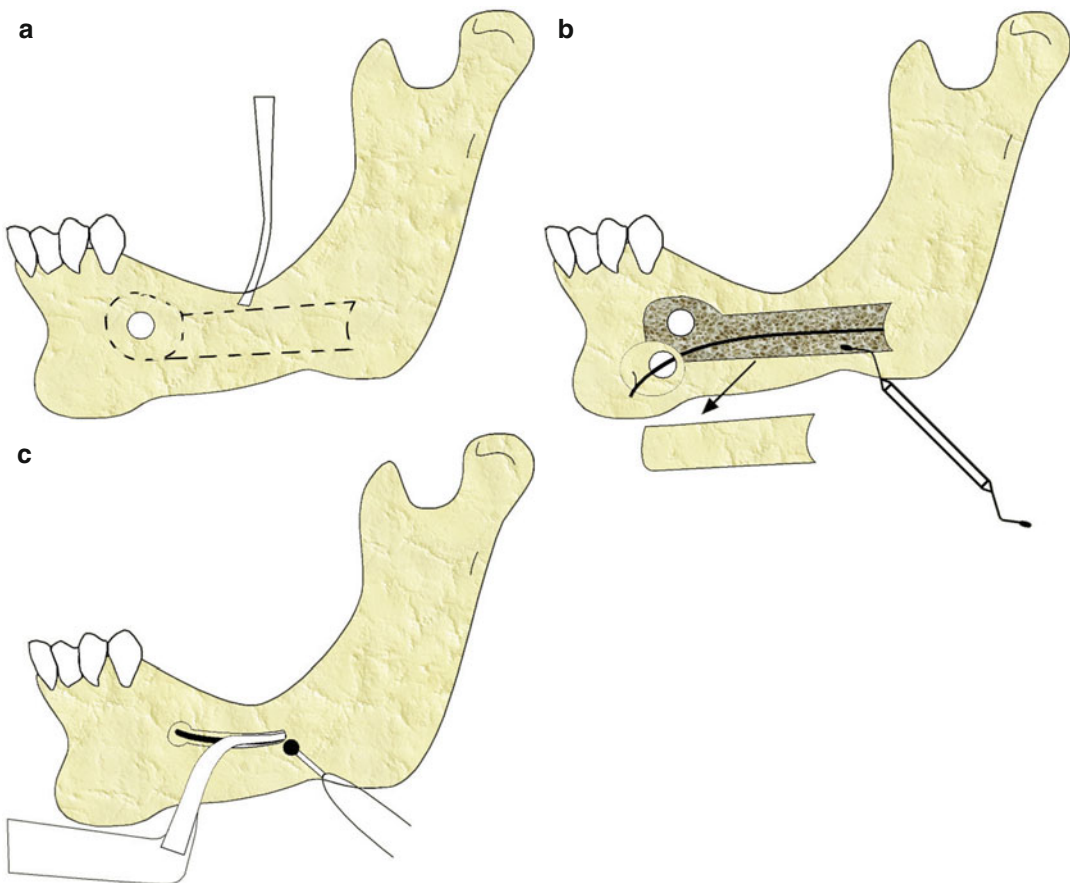


Fig. 7.2 Inferior alveolar nerve transpositioning (distalization). Different techniques of osteotomy. (a) A bur is used to outline the bone block area. An osteotome (chisel) is used to remove the bone block. (This technique that is usually performed for treatments other than dental implants) (b) The spongy bone is removed using a curette. In this technique, the preparation design includes the surround-

ings of the mental foramen. While keeping an adequate distance from mental foramen a circle is drawn with the center being the foramen using a round bur and the cortical bone is resected (c) In groove technique, while the nerve is protected by IAN protector, minimum amount of bone is removed from the buccal cortex by drilling the bone surrounding the canal using a handpiece and a round bur

the key to a successful treatment. The more eligible for surgery the selected patient is, the less postsurgical complications there will be. As the most important complication of this surgery relates to neurosensory deficit, selecting the right patient will help to minimize this problem with adequate informed consent.

7.3.1 Clinical and Radiographic Evaluation

For clinical assessment of a patient who is a candidate for dental implants and suffers from a reduced mandibular alveolar ridge height, first study casts should be prepared and then the occlusal relationship should be evaluated and recorded. The following points should also be considered:

1. The area of the edentulous atrophic alveolar ridge:

If the edentulous area extends anteriorly to the canine region, the surgeon should consider the need for mental nerve transpositioning [12].

In edentulous patients, the absence of incisor sensation following nerve distalization does not cause problems, but in patients with mandibular incisor teeth this can result in an unpleasant sensation in the anterior segment that is usually described as a sense of dullness in these teeth [7].

2. The distance between the occlusal surface of maxillary teeth and mandibular alveolar ridge:

In some cases, despite alveolar ridge resorption there is not enough clearance between the occlusal surfaces of the maxillary teeth and mandibular ridge that is required for constructing the implant prosthesis. This is usually due to the patient's preexisting occlusion (mainly in deep bite cases) or super-eruption of the corresponding maxillary posterior teeth. Vertical augmentation methods often cannot be used due to the restricted inter-occlusal space (Fig. 7.3). In such cases, the only available option seems to be nerve repositioning [22, 23].

3. Evaluation of the relationship between the mandibular alveolar ridge and maxillary alveolar ridge in the horizontal plane: The

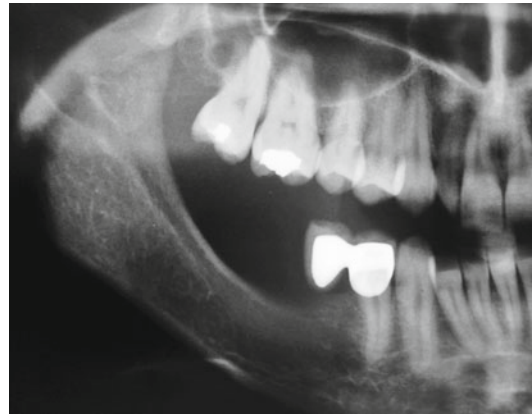


Fig. 7.3 Lack of adequate space for vertical augmentation

necessity of lateral augmentation simultaneous with nerve repositioning or vertical augmentation should also be evaluated by clinical examination and dental cast analysis.

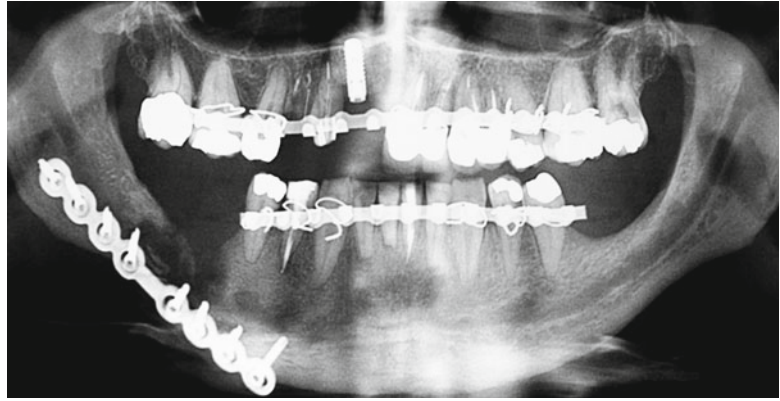
4. Radiographic evaluation: Every patient who is a candidate for nerve repositioning is required to obtain panoramic radiography and consideration should be given toward a CBCT scan. The amount of bone above the IAC, other anomalies, the distance of the IAC from the buccal cortex, and the thickness of the cortex for ostectomy are all evaluated on panoramic radiography. Exact location and precise anatomy of the mental foramen and anterior loop may also be evaluated [24].

In rare cases, the IAC may be completely attached to the medial or lateral cortex as evidenced on CBCT. In such cases, implants may be placed buccal or lingual to the IAC with no need for nerve repositioning surgery. Additionally, by analysis and reconstruction of scanned images using CAD-CAM, it is feasible to determine the entire path of the IAC and place the implants in atrophic areas with caution.

7.3.2 Indications, Contraindications, and Limitations

Babbush mentioned several indications for nerve repositioning including the following: placement of removable prosthetics, stabilizing

Fig. 7.4 Mandibular fracture in a patient with severe mandibular atrophy following nerve repositioning



the remaining anterior teeth, stabilizing the TMJ, and establishing muscular balance following reconstruction of the dentoalveolar system. He also discussed some related limitations, primarily that this procedure is technically difficult and requires adequate expertise. The surgeon should have advanced surgical experience with this technique, as well as sufficient anatomic knowledge and necessary skills to fully manage perioperative and postoperative complications if they occur. According to Babbush, the most significant risk of surgery is nerve injury due to surgical manipulation of the IAN as a result of the surgical procedure itself. Although rare, mandibular fracture should also be considered as a risk, especially in cases with severe mandibular atrophy [25] (Fig. 7.4).

Rosenquist et al. in their studies on the nerve repositioning procedure mentioned the following indications and contraindications for this operation:

Indications

1. Less than 10–11-mm bone height above the IAC.
2. When the quality of the spongy bone does not provide sufficient stability for implant placement.

Contraindications

1. Height of bone over the canal is less than 3 mm.
2. The patient has thick cortical bone buccally and thin neurovascular bundle.
3. The patient is susceptible to infection and bleeding.
4. Limitation in accessing the surgical site [1, 2, 8, 9, 26].

7.3.3 Preoperative Consultation

Before choosing nerve repositioning, the required criteria must be assessed. According to the literature, 100 % of patients who undergo nerve repositioning develop various degrees of sensory nerve dysfunction of the IAN sensory distribution [1, 27–29]. Therefore, the patient and family members should be well informed relevant to the phases of treatment, duration of surgery, and postoperative general complications, and most importantly they should be provided with knowledge about the postoperative lower lip and chin (and possibly lower incisor) paresthesia which will definitely occur and may last for up to 6 months, and in some cases, if it lasts longer or is very severe, it may require microneurosurgical exploration and repair [1, 27, 29–31].

Despite the issues mentioned above, the patient may not fully comprehend the sensation of paresthesia, and in such cases, it is recommended to perform an IAN anesthetic block for the patient using bupivacaine for long-lasting anesthesia induction so that the patient can experience anesthesia and paresthesia for up to 8–12 h. The advantages of this treatment modality should also be explained to the patient including shorter treatment duration, no need for autogenous bone grafting and no donor site morbidity, minimum use of other bone replacement materials, and avoiding the need for additional surgeries [1, 2, 7, 27, 29].

7.3.4 Important Considerations in Nerve Repositioning Surgery

1. *Patient selection:* The surgical process is complicated and occurrence of sensory disturbances is inevitable. Therefore, the surgeon should evaluate the patient's general mental condition, since some patients are under stress and oversensitive even toward the smallest surgical complications. Such patients do not have the tolerance and compatibility skills and therefore are not good candidates for nerve repositioning surgery.
2. *Informed consent:* The surgeon must provide data to the patient regarding all of the phases of surgery as well as the probable and possible complications. A thorough explanation should be provided for the patient in an understandable and comprehensible manner regarding surgical and neural complications. The sense of anesthesia that may occur should be well described for the patient, and it also should be mentioned that the anesthesia may be permanent and irreversible.
3. *Imaging:* While in the past, panoramic radiography was sufficient for evaluation, presently CBCT, when available, should be considered for the precise evaluation of IAC position and surrounding bone thickness.
4. *Perioperative medications:* Dexamethasone should be administered before the surgery in order to help decrease perineurial edema following nerve manipulation.
5. *Regional anatomy:* The surgeon must have a full knowledge regarding local and regional anatomy of the mandible, as well as a working knowledge of the pathophysiology of nerve injuries, and be able to evaluate and follow the clinical course of nerve dysfunction after the surgery and make an appropriate referral to a microneurosurgeon or neurologist, if indicated.
6. *Surgeon experience:* The surgeon's skill and expertise are very important and consideration should be given toward the use of operating magnification with the use of magnification loops.
7. *Armamentarium:* Delicate microsurgery instruments are required for this type of surgery and should be available. Also, the surgeon should have the knowledge, skills, and experience for repairing the nerve in case of IAN transection or severe axonal injury sustained during the nerve repositioning procedure.
8. *Anatomic variations:* In cases where the IAC is located in the center of the mandible buccolingually or in a lingual position based upon CBCT, the surgeon should expect a more complex surgery and the risk of neurosensory complications is increased due to the more extensive surgical manipulation of the IAN.
9. *Posterior access:* In cases where the nerve repositioning surgery extends further posteriorly and involves the first or second molar area for implant placement, the surgery can be more complicated due to the thicker cortical bone and limited access to this area.
10. *Adjunctive therapies:* Following nerve repositioning surgery, sensory reeducation exercises should be used to augment spontaneous neurosensory recovery of the IAN. In addition, the use of low-level laser after surgery reduces perineurial inflammation and has been shown to improve spontaneous neurosensory recovery.
11. *Postoperative medications:* Antibiotic therapy and administration of analgesics and NSAIDs postoperatively are similar to that following routine implant surgery, and there are no specific recommendations in this regard in the literature. Antibiotic and corticosteroid prophylaxis is recommended because of the extensiveness and duration of surgery. As mentioned, the use of corticosteroids pre- and postoperatively helps to decrease the symptoms of perineurial edema. However, there is no consensus in this regard, but since inflammation can be among the causes of nerve dysfunction, corticosteroid therapy can be beneficial.

7.4 Mechanism of Nerve Injury

IAN damage during the various stages of the nerve repositioning operation is possible. Generally nerve damage processes can be classified to five categories:

1. Flap design
2. Ostectomy to access the IAC
3. Repositioning the neurovascular bundle outside of the IAC
4. Nerve damage during IAN retraction from the canal for drilling and implant insertion
5. Repositioning the neurovascular bundle inside the canal

7.4.1 Flap Design

The incision is made on alveolar crest starting from the anterior border of the ramus forward. At the mesial surface of the mandibular canine, a releasing incision is made anteriorly and toward the vestibular sulcus in order to avoid injuring mental nerve branches. If the anterior-releasing incision is not made at the mesial of the canine, there is a chance of injuring the mental nerve branches present in the vestibular soft tissues [12, 28, 29, 32]. When retracting the mucoperiosteal flap, the mental foramen is completely exposed and the dissection is extended toward the inferior border of the mandible. Considering the radiographic and CBCT evaluations along with the fact that the IAC is usually located 2 mm below the mental foramen, it is necessary to expose the lateral surface of the body of the mandible and release the periosteum around the mental nerve [6, 12, 17] (Figs. 7.5 and 7.6).

The MN lies in the mandibular buccal soft tissues and is at risk of injury during the incision(s). Recognition of the changing anatomy of the edentulous mandible is particularly helpful in minimizing the risk of injury to the MN. As the patient ages, the alveolar bone in an edentulous area resorbs, and the position of the mental foramen becomes closer to the crest of the alveolar ridge. In some patients there is an actual dehiscence of the IAC, and the IAN and the MN come to lie on the alveolar ridge crest. Placement of an incision must, therefore, take these anatomic changes into consideration.

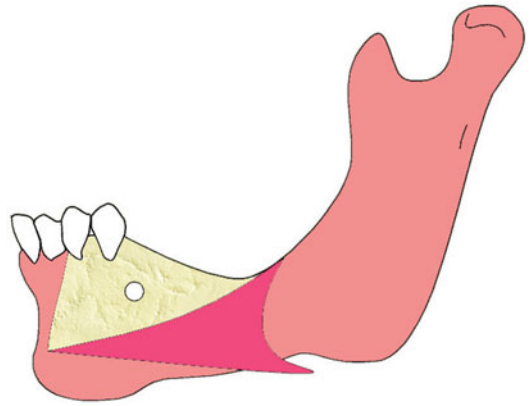


Fig. 7.5 Correct flap design: an incision is made on the alveolar crest with a releasing incision at the mesial of the mandibular canine

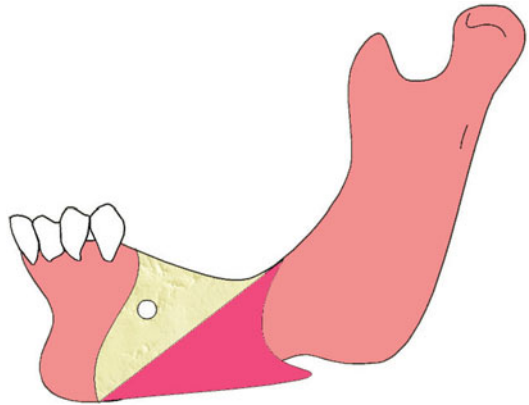


Fig. 7.6 Incorrect flap design: if the anterior-releasing incision is not made at the mesial of the canine, there is a chance of injuring the terminal mental nerve branches present in the vestibular soft tissues

During the retraction of the mucoperiosteal flap, it is possible to exert continuous undue pressure on the underlying MN with resultant neuropraxic (Sunderland grade I) injury. Gentle soft tissue retraction with frequent brief relaxations of retraction pressure is suggested [33].

7.4.2 Ostectomy to Access the IAC

Nerve injury is most likely to happen when performing the ostectomy to expose the IAC. According to the existing research, the technique

of performing the ostectomy is effective in reducing postsurgical complications. There are two general techniques to accomplish this portion of the surgery.

In the first technique, which is usually performed for treatments other than dental implants, a piece of bone is removed as a block and then the IAC is exposed. This method can be indicated for simultaneous implant surgery where there is adequate bone height over the canal. In such cases, even after resecting a bone block, a sufficient amount of bone still remains at the lateral side of implant [7]. In the second technique, the ostectomy is performed with the “groove ostectomy” method, since more bone will be saved and primary implant stability will also be improved. These techniques can be modified to accomplish either nerve lateralization or transpositioning.

7.4.2.1 Nerve Lateralization

Method of removing bone block without the involvement of mental foramen: In this technique, a bur is used to outline the location of the bone block on the mandibular buccal cortex by a distance from the inferior border of the mandible and alveolar crest. The anterior border of the ostectomy should be made in 3–4 mm anterior to the mental foramen. It is worth mentioning that maintaining a 3–4-mm distance from the distal side of the mental foramen will also help to reduce the postsurgical neurosensory problems. Generally, more involvement between the mental nerve and the mental foramen during the surgery will increase the risk of neurosensory symptoms [11, 25] (Fig. 7.7a).

7.4.2.2 Nerve Transpositioning

Removal of bone block with mental foramen involvement: Similar to the previous method, a bur is used to outline the bone block area. An osteotome (chisel) is used to remove the bone block and the spongy bone is removed using a curette. In this technique, the preparation design includes the surroundings of the mental foramen. While keeping an adequate distance from the mental foramen, a circle is drawn with the center as the mental foramen using a round bur, and then the cortical bone is resected. This results in

two bone blocks: one posterior to the mental foramen and the other one around the mental foramen through which the nerve has traversed. This mesial segment, with the nerve passing through it, is put aside with great caution, and when the operation is completed, it is returned to its original location. This technique is indicated when the edentulous atrophic area has extended to involve the premolar area, and there is a need for replacing the lost premolar teeth. This method may require incisive nerve transection in order to achieve improved nerve mobility from the IAC or when the planned implant is anterior to the mental foramen in the area of the incisive nerve. This method is also called nerve distalization [1–3, 7, 12] (Fig. 7.7b).

Groove ostectomy technique: Another method that has been described is drilling the bone surrounding the canal using a handpiece and a round bur. The surgeon carefully enters a probe (round end with no sharp edges) into the IAC through the mental foramen and determines the distal path of the IAC. Then, according to this test and after evaluating the canal path on the radiographs, the surgeon inserts the tip of the nerve protector into the canal. This instrument should be placed in between the nerve and the bone in order to protect the IAN. The buccal bone is drilled using a bur. By directing the bur distally, the nerve protector is also moved distally in between the nerve and bone to protect the nerve. The bone chips are collected by a bone collection device (suction trap) during this process. In this technique, while the IAN is protected, a minimum amount of bone is removed from the buccal cortex and the maximum amount of bone is preserved in an atrophic ridge for implant placement that results in maximum primary stability of the implant. Also, mandibular bone weakening is minimal in this method that is a great advantage of this technique to decrease the chance of mandibular fracture. This instrument has been designed, patented, and manufactured by the author (Hassani nerve protector) (Fig. 7.7c, d).

In patients with an atrophic alveolar ridge involving the premolar area or those with an edentulous mandibular ridge with alveolar crest atrophy who need implant placement and nerve

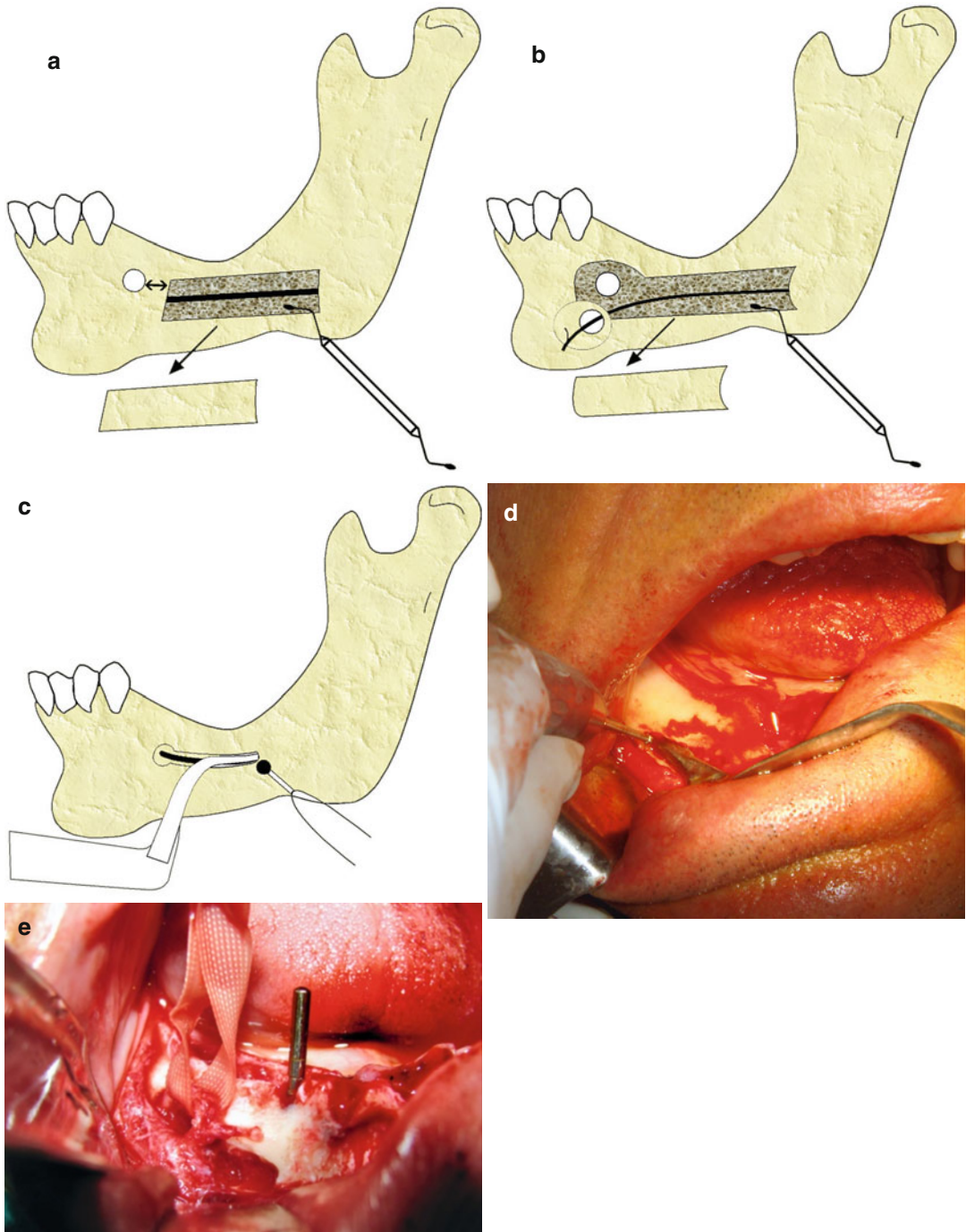


Fig. 7.7 (a) Nerve lateralization. The anterior border of osteotomy should be 3–4 mm anterior to the mental foramen (*double arrow*). Maintaining a 3–4-mm distance from the distal of the mental foramen will reduce postsurgical paresthesia. (b) Nerve transpositioning with the

block technique. Two bone segments are removed. (c, d) Nerve transpositioning with the groove technique. Nerve protector is used to protect the IAN and reduce paresthesia. (e) Transection of the incisive branch to facilitate nerve transpositioning (distalization)

transpositioning in the posterior mandible, mental nerve transpositioning is also necessary most of the time. This transpositioning is usually associated with incisive nerve transection (Fig. 7.7e). In such cases, the patients will not have any problems related to incisive nerve transection, but in cases where the patient has vital anterior mandibular teeth, incisive nerve transection may result in an unpleasant sensation in these incisor teeth. In some cases, root canal therapy may be required. However, several studies have reported that no problems related to anterior mandibular teeth were seen [1, 2, 12, 27, 29, 32]. Sectioning of the incisive branch of the IAN, and releasing the neurovascular bundle and moving it posterior in order to avoid traction is called nerve distalization [2]. It should be noted that in many cases it is possible to transpose the mental nerve without sectioning the incisive branch.

In the method of nerve repositioning without releasing the mental nerve, a great traction force is exerted on the nerve when holding it outside of the surgical implant site. According to the literature, the highest number of nerve injuries occurs during the anterior osteotomy because the nerve trunk becomes thinner at mental foramen and is therefore more susceptible to injury. This is the reason that nerve repositioning without involving the mental foramen has the least neurosensory complications and side effects. According to the literature, by preserving 3–4 mm of bone distal to the mental foramen during nerve repositioning, IAN damage can be reduced because the nerve is thinner and more susceptible to injury at this specific location [11, 29].

During osteotomy care must be taken not to injure the nerve with rotary instruments, curettes, or elevators. When removing the bone cortex over the nerve, it is recommended to use the nerve protector designed specifically for this purpose; it fits within the IAC lateral to the IAN. Direct contact of rotary or other surgical instruments with the nerve is among the most serious injuries in this type of surgery; a round diamond bur may be used to decrease the incidence of neural trauma as opposed to a round carbide bur if there is direct contact with the IAN.

7.4.3 Repositioning the Neurovascular Bundle Outside of the IAC

The portion of the surgery when the nerve is released and withdrawn from the IAC is one of the stages that may lead to nerve damage. The neurovascular bundle inside the canal is released using special curettes, and it is moved laterally using a blunt nerve hook. Bone removal in close vicinity to the neurovascular bundle should be performed patiently and thoroughly. This is usually performed using special curettes parallel to the surface of nerve bundles in an anteroposterior direction. Tiny bone spicules around the nerve should be removed. The area should be thoroughly irrigated so that the nerve bundle can be clearly seen. Spongy bone surrounding the nerve is removed using a special curved curette. The nerve is released and slowly retracted from the canal using a nerve hook. The hook should be rounded at the end and polished (Fig. 7.8). Care is taken to avoid any tension or sudden movement of the nerve, which may cause injury.

7.4.4 Nerve Damage During IAN Retraction from the Canal for Drilling and Implant Insertion

Another important stage that may cause damage to the IAN is when the nerve is outside of the canal. Some studies have suggested various techniques for protecting the nerve outside of the canal and retracting it while drilling for implant placement. Such techniques include the use of a looped suture [6], small green cloth [34], piece of a suture cover [13], half of the rubber piston of a dental cartridge [35], umbilical tape [25], vessel loops [10, 16, 32], and elastic bands (author's preference).

The important strategy for preventing nerve damage in this stage relies on increasing the contact surface in order to decrease pressure on the nerve. The more the contact surface decreases, the more the nerve damage will occur (pressure = force/area). So, avoid exerting too much traction upon the nerve when lateralizing the

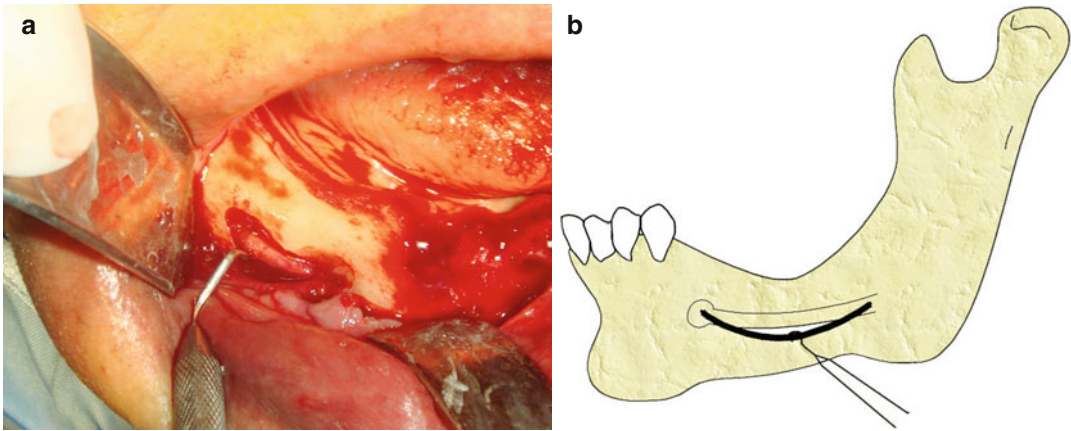


Fig. 7.8 (a) Spongy bone surrounding the nerve is removed using a special curved curette. (b) The nerve is released and slowly retracted from the canal using a nerve hook

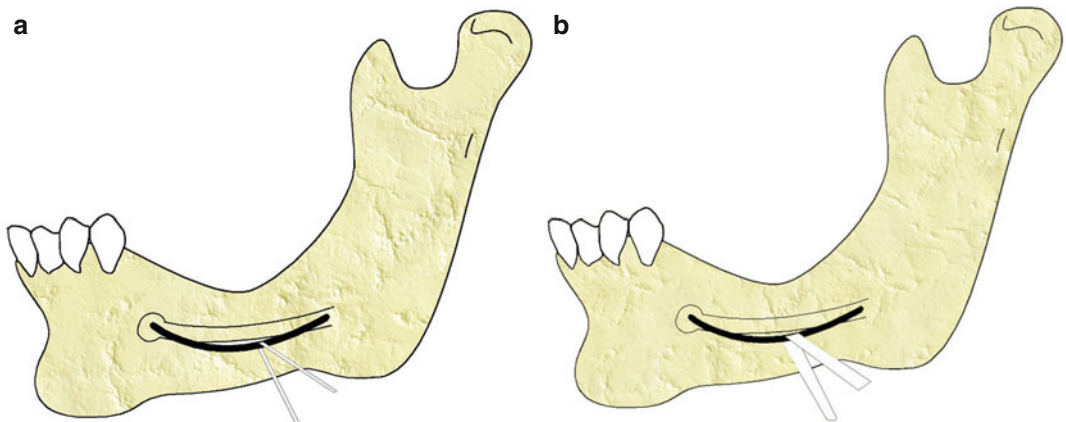


Fig. 7.9 Avoid forming a contact point (a) between the retracting tape and the IAN. Contact between these two should be in the form of a contact area (b) rather than a contact point

nerve and during nerve repositioning; attempt to transform the contact point to a contact area (Fig. 7.9). Then, a 10-mm-wide gauze cord or elastic band is passed below the IAN retracting it away from the surgical site decreasing ischemic trauma to the nerve. It also retracts the nerve away from the surgical site during the operation reducing the risk of iatrogenic nerve damage [2, 13, 30, 32] (Figs. 7.10 and 7.11). The advantage of using a wide elastic band is that it counteracts the tension of the nerve to some extent and also decreases the final pressure on the nerve due to its elasticity. Also, the retracted neurovascular bundle must be constantly moistened by normal saline.

7.4.5 Repositioning the Neurovascular Bundle Inside the Canal

Finally, the last stage of possible nerve damage refers to the process of nerve repositioning, when the nerve is replaced back into the IAC, and the contact between the nerve and the implant occurs. Prior to this phase, the surgeon should decide whether or not to place material(s) between the implant and the nerve. There is a lot of controversy in this regard and some studies have been performed on animal models in this respect. In a study by Yoshimoto et al. with rabbits, no difference was observed microscopically after placing and not placing a membrane between

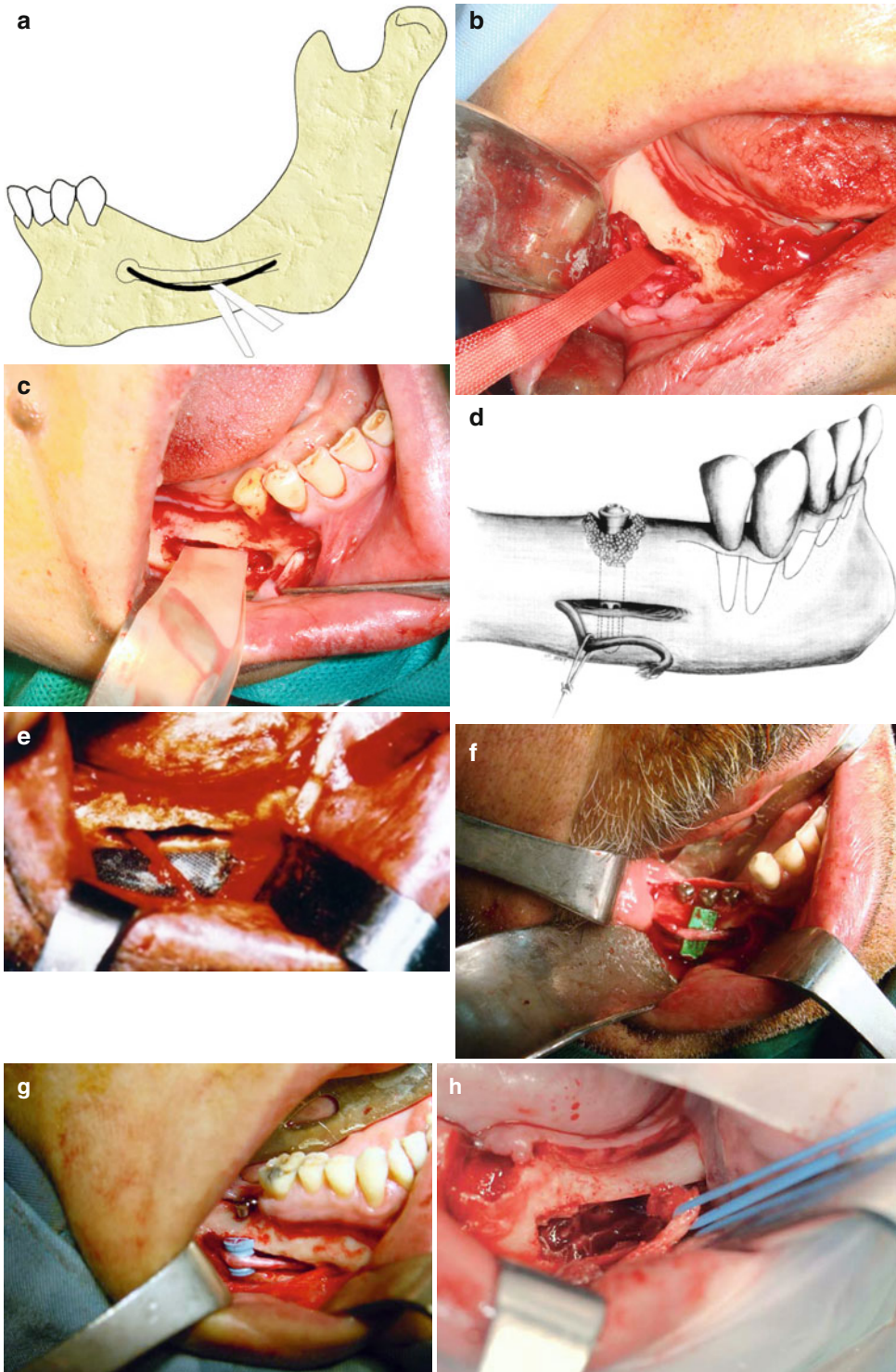


Fig. 7.10 The nerve is retracted from the site (a) using 10-mm-wide umbilical tape (b) or elastic band (c) in order to protect it from any damage during implant placement. The advantage of an elastic band is that if it is pulled during

surgery, the traction is neutralized by the band and not transferred to the nerve. Other techniques include looped suture (d), small green cloth (e), piece of a suture cover (f), half of the rubber piston of a dental cartridge (g), and vessel loop (h)

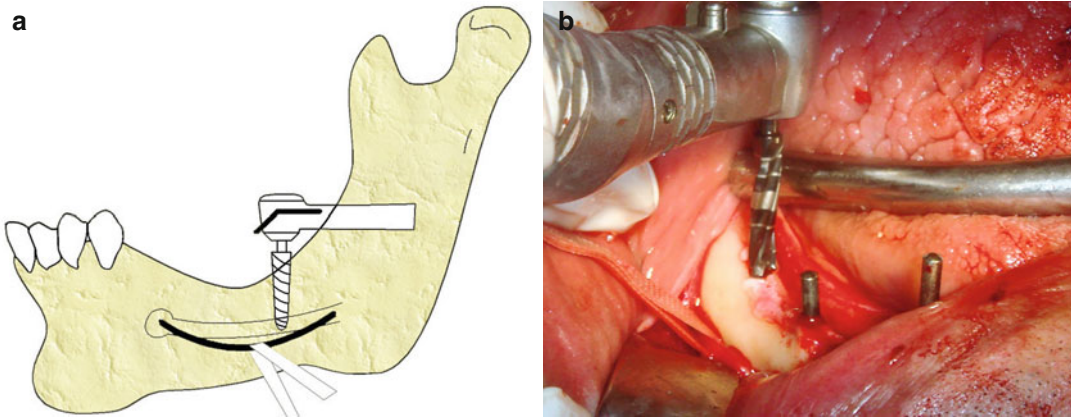


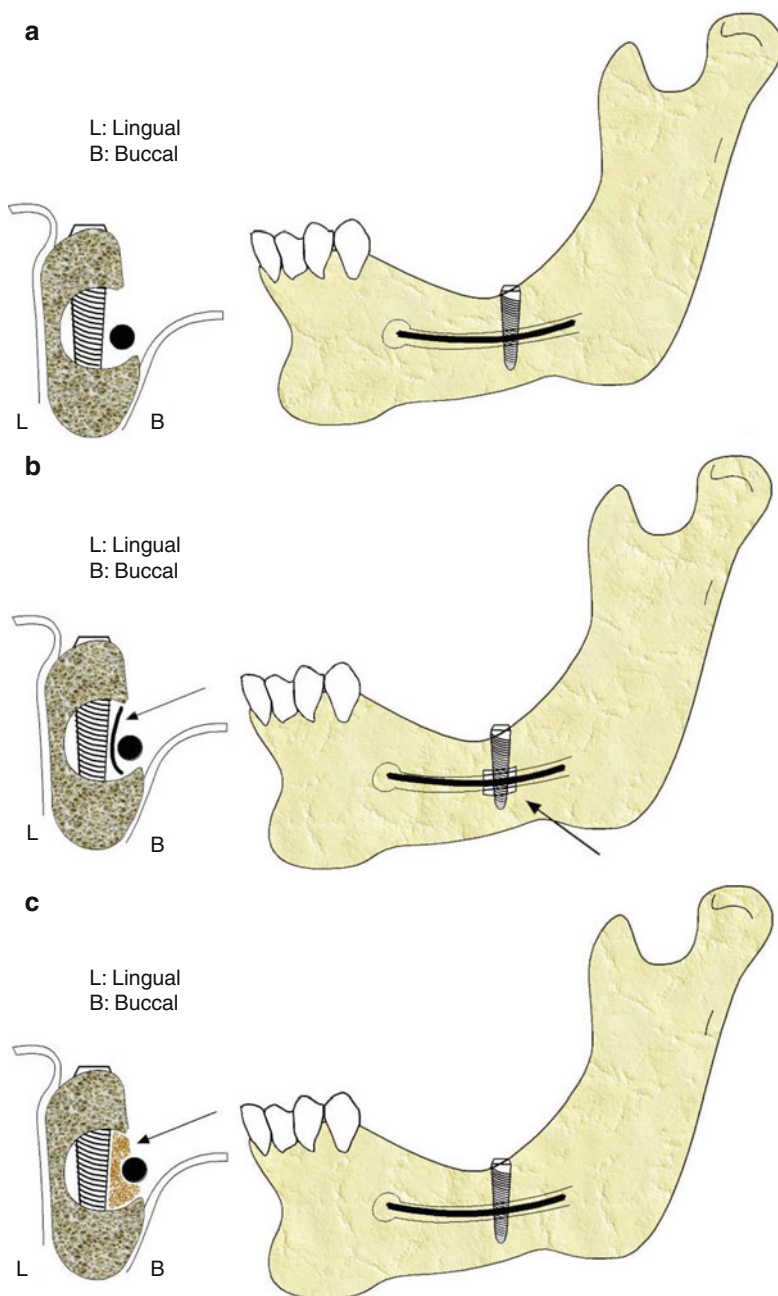
Fig. 7.11 Implant osteotomy preparation with lateral nerve retraction (**a, b**)

the implant and the nerve bundle [36]. On the other hand, in the Kahnberg et al. dog study, healing was not complete after 14 weeks, but none of the implants were exposed. Histologic examination showed that in cases where a membrane had not been placed, a small contact was present between the nerve bundle and the implant. When a membrane is used, the distance between the nerve bundle and the implant will be four to eight times greater. There is no contact between the nerve and the implant when using a membrane, but the bone is not seen around the implant either [37]. An autogenous bone graft, either from the bone removed to unroof the IAC or elsewhere, or banked bone, is always placed between the repositioned nerve and the associated implants to prevent direct contact of the IAN and thermal transmission or metallic sensitivity with the implant(s). Also, artificial material, such as calcium hydroxyapatite, should never be placed in direct contact with the nerve. A severe inflammatory reaction in the nerve, similar to a chemical burn with dense scarring, accompanied by considerable pain, is often the unfortunate result. Surgical treatment of such injuries is problematic [33]. The author's preference is to place a collagen membrane or autogenous bone graft in between the implant and IAN [10, 33]. A potential advantage of bone grafting over membrane placement is that if proper healing occurs in the area, the contact area of implant and bone will increase for osseointegration (Fig. 7.12).

Therefore, attention should be paid during and after surgery to minimize the factors responsible for ischemia and mechanical neurotrauma. Such factors in the order of most common to the least common during nerve repositioning surgery include:

1. Avoid exerting too much traction on the nerve. When lateralizing the nerve and during nerve repositioning, try to transform the contact point to a contact area.
2. During osteotomy care must be taken to not injure the nerve with rotary instruments, curettes, or elevators. Direct contact of rotary or other surgical instruments with the nerve is among the most serious injuries in this type of surgery. Consider using a nerve protector.
3. In order to lateralize the nerve, use instruments with minimal traction and prevent ischemia to the nerve. Instruments that have large contact area with the nerve and minimum thickness are preferred to be placed between the nerve and the location of drilling for implant placement.
4. The retracted IAN bundle should be constantly moistened with normal saline.
5. Prevent development of a hematoma since it places pressure on the nerve trunk.
6. After inserting the implant, bone grafting (autogenous from a suction trap or allogeneic) and possibly a collagen membrane should be placed between the implant and the nerve bundle [10, 33].

Fig. 7.12 Replacement of the IAN within the IAC. (a) Direct contact of nerve and implant (not recommended). (b) Membrane placement (arrow) between the implant and IAN. (c) Placement of a bone graft (arrow) between the repositioned IAN and implant L: Lingual, B: Buccal



7.5 Histological Findings Associated with Nerve Repositioning and Implant Placement

Yoshimoto et al. evaluated the condition of the tissues surrounding the implant 8 weeks after nerve repositioning surgery and simultaneous

implant placement; they observed that none of the implants were exposed, and all were stable. No infection or inflammation was observed at the site. In all cases bone formation between the implant and neurovascular bundle was observed, and no direct contact was seen between them (Fig. 7.13). Research demonstrates that bone formation around the implant surface sandblasted

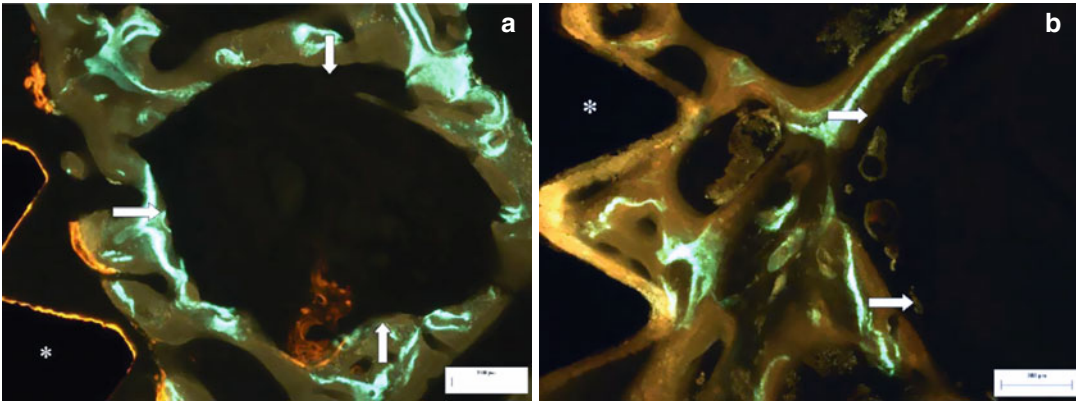
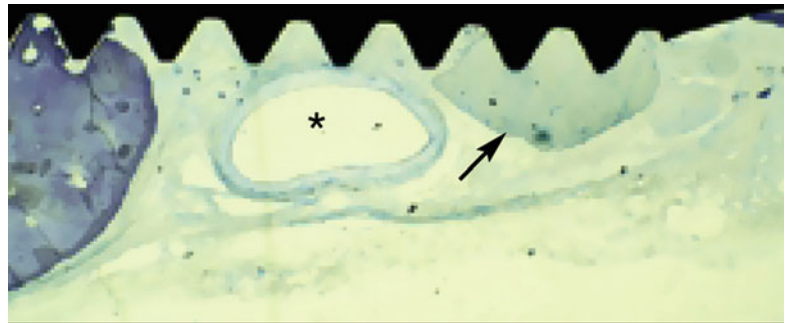


Fig. 7.13 Fluorescent microscopy showing relationship of IAN and implant following nerve repositioning surgery in a rabbit (*star* implant, *arrow* IAN). Bone formation is shown by fluorescent indicators (**a, b**) [36]

Fig. 7.14 Microscopic image of contact between implant and IAN after nerve repositioning and implant placement in a dog (*arrow* IAN, *star* artery). No membrane was used. There is physical contact between the nerve and the implant [37]



with aluminum oxide was 2.5 times greater than a smooth titanium surface. Bone formation around the neurovascular bundle prevents the implant from having direct physical contact with the bundle, and therefore the nerve structure will be protected from mechanical or thermal trauma. Microscopic sections show the formation of a vascular network in the adjacent tissues that demonstrates that there is no need for placing a barrier or any kind of graft material to separate the nerve from the implant [36].

In Kahnberg et al. study on a dog, healing was not complete after 14 weeks, but none of the implants were exposed. Histologic examination showed that in cases where a membrane had not been placed, a small contact was present between the nerve bundle and the implant (Fig. 7.14).

Plasma cells, macrophages, polymorphonuclear leukocytes, and granulocytes were alternately seen next to the membrane. Several giant

cells and macrophages were also seen. Vascular buds were seen where membrane had been placed (compared to areas where no membrane had been used). In some cases, a capsule with less than 10 μm thickness was seen in some areas between the implant and the nerve. When a membrane is used, the distance between the nerve bundle and the implant will be four to eight times greater. The mean distance between the implant and the nerve is 348.3 μm when using a membrane and 39.8 μm when not using one. There is no contact between the nerve and the implant when using a membrane, but the bone is not seen around the implant either [37] (Fig. 7.15).

Yoshimoto et al. also, evaluated the bone healing surrounding the implant 8 weeks after nerve repositioning surgery in rabbits. Light microscopy and SEM analysis of all the specimens showed bone ingrowth between the implants and the neurovascular bundle (Figs. 7.16 and 7.17).

Fig. 7.15 Microscopic image of contact between the IAN and implant after nerve repositioning and implant placement in a dog. A membrane is used between the nerve and the implant (arrow IAN). Note the distance between the nerve and the implant caused by the membrane [37]

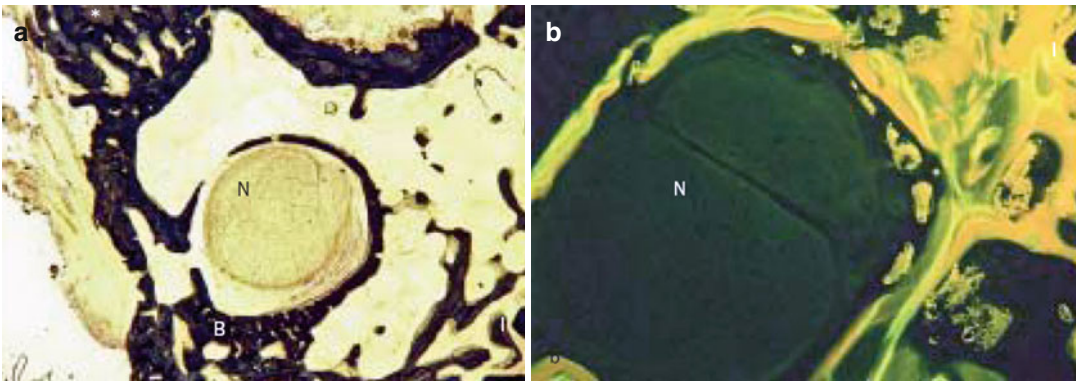
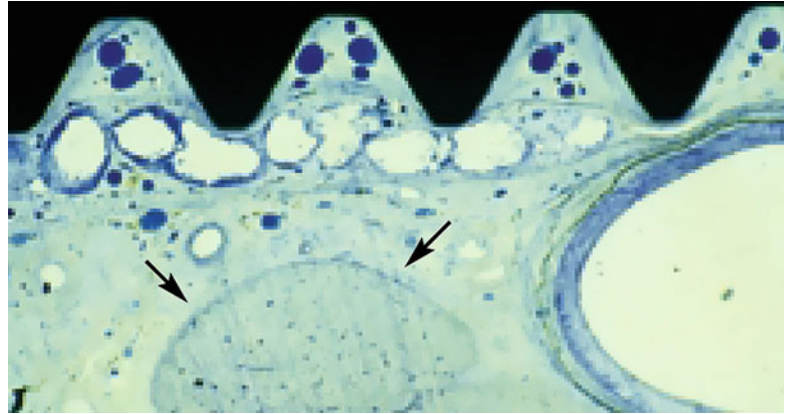

Fig. 7.16 (a) Light microscopy showing bone formation (*B*) between the implant (*I*) and the nerve (*N*) (original magnification $\times 10$). Notice bone ingrowth at the area of surgical access to the nerve bundle (*) (Masson trichrome). (b) Fluorescent microscopy imaging showing greater

label interdistance occurred between alizarin (*red*), followed by calcein (*green*) and tetracycline (*orange*) (original magnification $\times 30$). This presence of higher MAR labeling between alizarin labels reveal that bone ingrowth occurred primarily over the first weeks of healing [38]

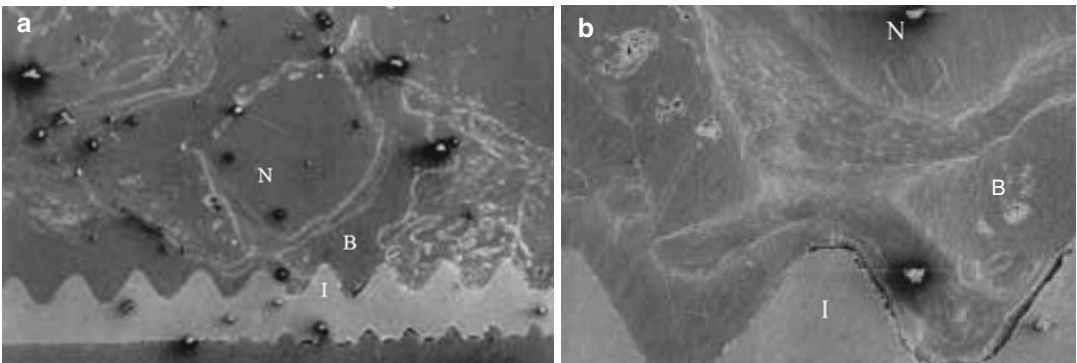


Fig. 7.17 Scanning electron micrographs showing the relationship between the IAN and the implant surface. (a) Bone (*B*) ingrowth between the IAN (*N*) and implant (*I*)

and (b) detailed micrograph showing the IAN (*N*) surrounded by new bone (*B*) [38]

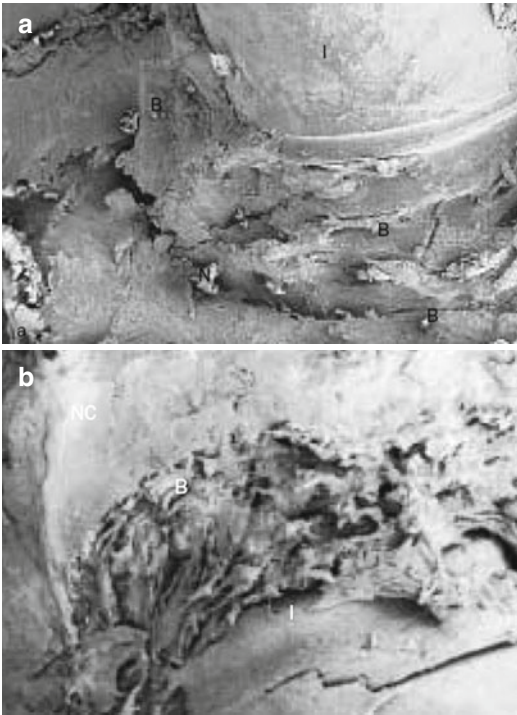


Fig. 7.18 Scanning electron micrographs obtained following cortical selective removal by means of 20 % chloridric acid solution. (a) The implant (*I*) and the lateral bone walls (*B*) of the IAN (*N*). (b) Removal of the IAN revealed the presence of a newly formed mandibular canal bone wall (*NC*) [38]

No direct contact between the nerve bundle and implant surface was observed after the 8-week healing period (Fig. 7.16a). Removal of the IAN from the bone blocks showed a newly formed mandibular canal bone wall (Fig. 7.18b). This study showed that modeling and remodeling of bone in close proximity to the direct contact between the IAN and implant surface resulted in total isolation of the nerve bundle (Figs. 7.16, 7.17, and 7.18). This shows that the wound healing process includes processes to help restore the original presurgical anatomy, avoiding long-term nerve structure contact with the implant surface. The bone tissue activity evaluated through a sequence of fluorescent labels showed that bone modeling between the IAN bundle and implant surface takes place as early as 14 days postoperatively at high bone mineral apposition rates (Fig. 7.16b). Observation of the label position suggests that the healing occurred first around

the implant surface and that bone apposition closer to the IAN followed later in vivo (calcein and tetracycline labels, Fig. 7.16b). The wound healing pattern observed through fluorescent labels suggests rapid bone formation at the implant surface soon after implantation, which is a desirable feature from several perspectives. First, mechanical stability is achieved at the mandibular posterior region shortly after implant placement. Second, rapid isolation of the IAN from the implant surface may effectively decrease any potential nerve sensitivity due to contact to the implant surface (i.e., thermal sensitivity). The remodeling observed at regions in proximity to the IAN at later implantation times (calcein and tetracycline) showed that following initial repair and modeling of the surgical site, remodeling leading to the new formation of a mandibular canal wall (Figs. 7.17 and 7.18) may further support decreases in IAN neural sensitivity [38].

Also, Yoshimoto et al. evaluated the microstructural and ultrastructural damage of the IAN damage following nerve repositioning and implant placement in rabbits after 8 weeks. Implants were placed in the right mandible, and the left side was used as a control (no surgical procedure). Light microscopy revealed a more diffuse IAN histology in experimental sites than in control sites. This dispersed arrangement was observed not only in the epineural and perineural regions but also in tissue at greater distances from the fascicles, suggesting that a repair mechanism was still ongoing at 8 weeks after surgery. The tissue organization observed in different regions of the experimental group and the connective tissue separating the fascicles suggested edema, and the histologic sections showed a less dense structural arrangement compared with the control groups (Figs. 7.19 and 7.20). The following data support the hypothesis that at 8 weeks postoperative, the experimentally manipulated IAN was still affected by the surgical procedure. TEM observations revealed a denser ultrastructure in controls (Fig. 7.21) than in experimental sites (Fig. 7.22). In addition, myelin sheath degeneration occurred in several experimental group fibers (Fig. 7.22). Although myelin degeneration along a less cohesive interfiber distance was observed,

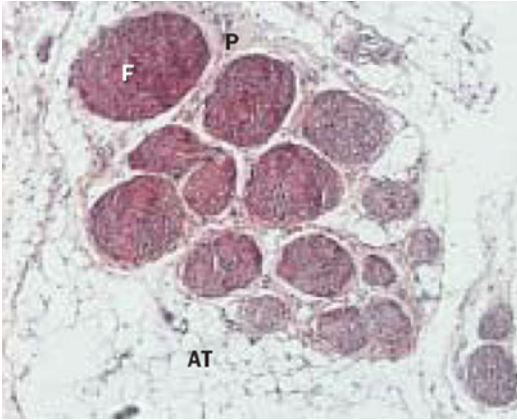

Fig. 7.19 Control tissue showing the IAN fascicles (*F*) surrounded by the perineurial capsule (*P*). Fascicles in control samples were arranged in a closely packed, cohesive fashion. Fascicles were surrounded by the epineurial membrane, consisting of dense connective tissue with thin collagen fibers, adipose tissue (*AT*), and blood vessels (hematoxylin-eosin; bar = 10 μm) [39]

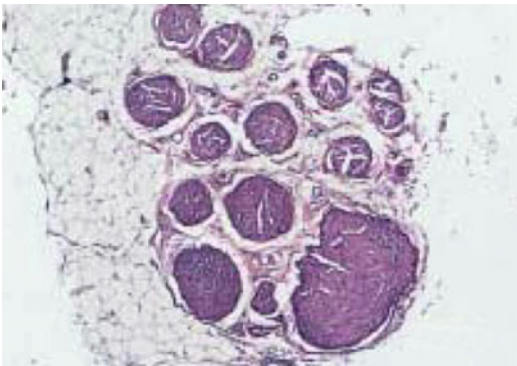

Fig. 7.20 IAN experimental groups exhibiting displaced fascicles and axonal bundles. The epineurium displays less connective tissue, fewer collagen fibers, and lower density (more spacing between arrays) compared to control groups, suggesting that edema was a factor (hematoxylin-eosin; bar = 10 μm) [39]

the number of degenerating myelin fibers was found to be substantially lower compared to the overall myelin fiber content. Thus, the results suggest that the IAN was partially damaged and was undergoing a regenerative process, which may parallel the temporary neurosensory disturbance that is frequently observed in clinical practice or potentially rationalize previous observations of decreased neural stimulus conduction speed. The insignificant difference in the number

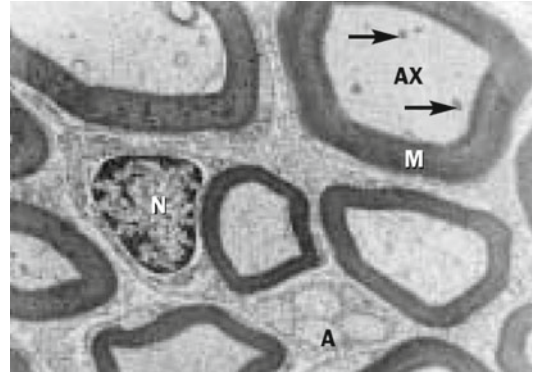


Fig. 7.21 Transmission electron micrograph of control IAN tissue. The myelin sheath (*M*), axoplasm (*AX*), and organelles (*arrows*) are present. Note the closely packed arrangement between myelinated and nonmyelinated (*N*) nerves and the presence of a Schwann cell (*N* Schwann cell nucleolus). *A* myelinated fibers. Bar = 1 μm [39]

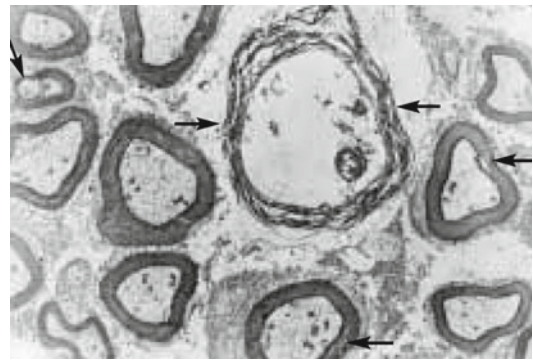


Fig. 7.22 TEM of an experimental IAN tissue. A less dense arrangement between myelin and nonmyelinated fibers is observed. In general, myelin sheaths with normal ultrastructure are seen. However, unlike control samples, degeneration of the nerve ultrastructure is observed in several locations (*arrows*). The central region of the micrograph depicts a degenerative process occurring as a result of surgical trauma. Bar = 1 μm [39]

of fascicles between control and experimental groups was likely a result of the region from which samples were collected for both groups, which was nearly the same at both sides of the mandible, even though variability in the number of fascicles has been previously reported. Such decreases in fascicular dimensions were likely a result of the edematous characteristic of the surrounding tissues, where substantial spacing existed in the connective tissue (Fig. 7.20). Such

findings support the idea that the postoperative deficiency in conduction observed by several authors is a result of tissue disorganization at both microstructural and ultrastructural levels. Should a reparative process evolve over time, allowing the tissue to reorganize itself, physiologic neural conduction may be totally reestablished [39].

7.6 Clinical Neurosensory Testing in Nerve Repositioning Patients

Clinicians should document unusual patient reactions occurring during nerve repositioning surgery (such as sharp pain or an electrical shock-like sensation). If a nerve injury is suspected, the clinician should perform a thorough neurosensory examination and document the results the day after surgery (when the effects of the local anesthetic should have worn off). The clinician also should record the patient's subjective assessment of the altered sensation [40]. The method of questionnaire should include a list of questions concerning various aspects of the symptoms and function. Answers may be provided as "yes" or

"no," via multiple-choice options, or by use of a visual analog scale (VAS) [30]. At the time of completion of the questionnaire, each patient is specifically asked if there was any difference in sensation in the lower lip or chin between the operated and unoperated sides. Also, specific questions are asked about accidental biting of the lip, drooling/food running down the chin, and burning, painful, or tingling sensations [41].

Clinical neurosensory testing is still the most popular in daily practice. Clinical neurosensory testing can be divided into two basic categories, mechanoreceptive and nociceptive testing, based upon the specific receptors stimulated through cutaneous contact. Mechanoreceptive tests include static light touch, two-point discrimination, and brushstroke direction. Pin tactile discrimination and thermal discrimination are nociceptive tests. Each test assesses specific categories of the receptors and axons [42, 43] (Table 7.1).

7.6.1 Mechanoreceptive Tests

1. Static light touch: For this test a series of nylon filaments with same length and different thickness mounted on a plastic handle are used

Table 7.1 Subjective clinical sensory testing methods IAN fiber types assessed [42–45]

| Fiber types and functions | Description of test | Name of test |
|---|---|--|
| <i>Mechanoreceptive</i> | | |
| Myelinated afferent A-beta axons | Patient is asked to tell when he/she feels light touch on the face and to point to the exact location | Static light touch detection |
| Large A-alpha and A-beta myelinated axons | Patient is asked to tell when he/she feels the brush and to determine the direction of movement | Brushstroke directional discrimination |
| Small myelinated A-delta and unmyelinated C-afferent fibers | Patient is asked to determine single and two points of touch. The examiner uses any two sharp instruments by which the patient can change the distance between them | Two-point discrimination (sharp) |
| Larger myelinated A-alpha afferent fibers | Patient is asked to determine single and two points of touch. The examiner uses any two blunt instruments by which the patient can change the distance between them | Two-point discrimination (blunt) |
| <i>Nociceptive</i> | | |
| Free nerve endings and small A-delta and C-fibers | Patient is asked to determine the feeling of a pin prick | Pin pressure nociception |
| A-delta fibers | Patient is asked if he/she feels heat | Thermal discrimination (warm) |
| C-fibers | Patient is asked if he/she feels cold | Thermal discrimination (cold) |

- (Semmes-Weinstein monofilaments or von Frey hairs). The patient closes the eyes and indicates “yes” whenever he/she feels a light touch to the face and points to the exact spot where he felt the touch.
2. Brushstroke directional discrimination. The sensory modalities for these receptors are vibration, touch, and flutter. The patient indicates if any sensation is detected and in which direction the filament or brush is moved [43]. Direction discrimination is tested with use of a cotton swab, soft brush, or Semmes-Weinstein monofilament. It is recommended to swipe a soft brush from left to right, as well as in the reverse direction, over a 1-cm area, asking the patient the direction of movement of the stimulus [30, 46].
 3. Two-point discrimination (static): In this test the distance between two points is altered. With the patient’s eyes closed, the test is initiated with the points essentially touching so that the patient is able to discriminate only one point [43]. The two points are gradually separated and the closest distance that the patient can discern two points is recorded and compared to the opposite control side.
 2. Thermal discrimination: This is an adjuvant test and may be performed using several testing devices including Minnesota thermal disks. Ice, ethyl chloride spray, acetone, and water are also used. The simplest method is to use a cotton-tipped applicator dipped into acetone or ethyl chloride [43] for suprathreshold response assessment.

In general for these tests including static light touch, brushstroke directional testing, and sharp/dull discrimination, a correct response 80 % of the time is considered to indicate normal sensibility [48]. Generally, few studies report using a control site for clinical sensory testing, although it is useful to establish a baseline threshold. The unaffected site can be used as a control site, as can the upper lip or forehead [30]. In many studies for bilateral cases, another area of the face has been used as a control for the IAN/mental nerve distribution [42], but differences in thresholds between different areas of the facial skin must be appreciated. The majority of the studies on nerve repositioning used preoperative clinical sensory data as the control. Other studies have used remote sites in bilateral cases including the skin in the distribution area of the infraorbital nerve [30, 49, 50] or frontal nerve [51], the hand [52], and the right ear lobe [53]. A grid is defined as dividing the IAN distribution into three areas on each side for clinical sensory testing. Most studies use the chin divided by the labiomental fold and lower lip or, alternatively, the lower lip, chin, and mental nerve area because these areas have different cutaneous sensibility values [30, 50, 51]. When pain is a symptom of nerve injury, diagnostic nerve blocks using local anesthesia can be very helpful in deciding whether or not microneurosurgical reconstructive surgery is indicated. It is important to start with low concentrations of anesthetic drug, and injections should be performed starting from the periphery toward the center to ease the pain. If the pain is not alleviated, there is a chance that collateral sprouts from the other side are present. If the persisting pain is aggravated by cold, is spontaneous, and of a burning type and long lasting, allodynia, hyperpathia, causalgia, and sympathetic-mediated pain should

7.6.2 Nociceptive Tests

1. Pin pressure nociception: For this test the most common instrument used is an algometer. This instrument is made from a needle and an orthodontic strain gauge. The sharp point of the needle is used to test nociception and the blunt end to test for pressure detection. The magnitude of force necessary to feel the sharpness of the unaffected area is recorded as the nociceptive threshold for the affected area. The normal values also vary greatly in this test, but 15 g is considered to be an adequate force to elicit a response [47]. An exaggerated response to pin pressure relative to an unaffected area is defined as hyperalgesia. A reduced response (touch) relative to an unaffected area is hypoalgesia. No response is defined as anesthesia [43].

be considered in the differential diagnosis. In such cases, diagnostic stellate ganglion block is helpful in differentiating the causalgia pain from the sympathetic pain from the cervical plexus [1, 30, 54].

7.7 Management of Sensory Disturbances in Nerve Repositioning Cases (Surgical and Nonsurgical Approaches)

IAN repositioning for implant placement results in sensory impairment immediately after surgery essentially in 100 % of cases [1, 28, 29]. Sensory disturbances are resolved in 84 % of cases, and in only 16 % of patients will this complication be permanent and irreversible [1, 29–31]. Generally, the management of neurosensory problems following nerve repositioning may be implemented from two points of view. First, the nonsurgical management and then, if necessary, the surgical treatment are recommended.

7.7.1 Nonsurgical Treatment Options

The important issue in the management of nerve injury is to inform and educate the patient in this respect. The patient should be educated before and after the surgery and should be well aware that neurosensory recovery may take a long time and he/she may experience paresthesia or dysesthesia for a long time. The patient may be taught to massage the area (with lanolin or a moisture-absorbing ointment). Massage should be started with mild movements and then the intensity is increased to improve the sense of touch. Massaging is indicated four to six times daily for 10–15 min each. The first sensation that usually resumes is the sense of cold followed by pain. At this time the patient still may have paresthesia in the area. After 4–5 months, the patient should be able to differentiate between cold and heat sensations and feels the sharpness of needle with 25–30-g pressure. After 6 months, touch, pain, and thermal sensations will usually resume more efficiently [55].

In some studies, the use of *low-level laser* (LLL) immediately after surgery, four times per week for ten sessions, has been suggested. The sessions usually begin on the day of surgery, although LLL can be used preoperatively to prepare the IAN for the surgical insult of nerve repositioning. The sensitive area is detected using a simple anesthesia needle and is controlled monthly. The percentage of recovery is calculated by the proportion of the primary area suffering from paresthesia to the final area after 6 months [1]. Studies suggest that using LLL as a noninvasive nonsurgical method for faster recovery from paresthesia may obviate the need for microneurosurgery in nerve injuries. The use of the gallium-aluminum-arsenide (GaAlAs) 820-nm low-level laser can ameliorate or resolve the patient's subjective and objective symptoms, since LLL increases nerve function as well as myelin and neurotrophic factor production [1, 56].

Medicament treatment with pharmacologic therapies for acute nerve injuries includes the use of corticosteroids and nonsteroidal anti-inflammatory drugs (NSAIDs). Regarding the use of anti-inflammatory drugs before and after surgery, some articles have recommended administration of corticosteroids pre- and postoperatively or high dose ibuprofen 800 mg three times daily for 3 weeks [40, 43]. Also, a course of systemic corticosteroids (e.g., dexamethasone 8–12 mg/day) can decrease the perineural inflammation in the first week following surgery [57]. The use of adrenocorticosteroids has been shown to minimize neuropathy after nerve injuries if administered in high doses within 1 week of the injury [58, 59]. In addition, adrenocorticosteroids have been shown to inhibit axonal sprouting centrally and ectopic discharges from injured axons and therefore aid in the prevention of neuroma formation [60, 61].

Cryotherapy should be applied extraorally to most implant and bone graft sites, but especially when nerve injury is suspected. The paraneural tissues should have ice applied intensely for the first 24 h postoperatively and then episodically for the first week [62]. Cryotherapy has been shown to minimize secondary nerve injury from edema-induced nerve compression, a decrease in

the metabolic degeneration rate of trigeminal ganglion cells, and slowed potential neuroma formation [63]. Ice, when applied to the tissues, has been shown to significantly improve postsurgical recovery [62].

In some complicated cases additional pharmacologic agents can be prescribed [43]. Using *vitamin B-complex* supplements, some studies have shown that B-complex and vitamin E supplementation may improve nerve function and decrease persistent neuropathy. Vitamin B family, especially B1 and B12, can prevent nerve injury and improve natural growth of the nerve by preserving and protecting the lipid-rich covering of the nerve terminals. Alcohol consumption causes vitamin B deficiency and therefore should be avoided by the nerve-injured patient [64].

7.7.2 Surgical Treatment Options

The specific course of nerve recovery and patient symptoms vary based upon the type and severity of the primary nerve injury. In most cases, only time and regular patient visits are required for continued observation of spontaneous recovery. Other cases may require pharmacologic therapy or microscopic reconstructive neural surgery.

If during the nerve repositioning surgery, a known or observed injury (including traction or compression of the nerve trunk) has occurred, the topical application of dexamethasone is suggested. One to two milliliter of the intravenous form of dexamethasone (4 mg/mL) may be topically applied for 1–2 min. The direct application of adrenocorticosteroids will reduce neural inflammation and reduce compression from swelling, which may enhance recovery from neurosensory deficits [65].

Bleeding from the IAN neurovascular bundle during nerve repositioning should be controlled with gentle temporary packing with gauze (which is removed before the wound is closed), and diathermy or electrocautery should not be used. Medicaments or hemostatic agents such as Whitehead's varnish or Surgicel (oxidized cellulose) should also be avoided since these materials can cause a chemical injury when in direct contact with the nerve [66, 67].

In cases of nerve transection, the free ends may be reapproximated without traction, but primary and simultaneous nerve grafting should never be performed. An attempt should be made to reapproximate the nerve stumps with epineurial sutures (using an 8/0 monofilament polyamide suture, Ethilon, Ethicon Ltd., UK) with the aid of loupes or an operating microscope [55, 66].

If the IAN is repaired under tension, greater fibrosis will develop at the site of repair with probable neuroma formation and failure of neurosensory recovery. In cases with nerve compression or traction, the surgeon should release the nerve and eliminate the traction or compression in order to prevent ischemia due to mechanical trauma [55]. After nerve repair, clinical testing should be performed weekly during the first month and then monthly for 5 months. It is especially important to do the test in the first month to recognize and diagnose whether neuroma or neuropathic pain develops that may indicate neuroma formation and may be amenable to early microneurosurgical repair [40]. In the presence of neuropathic pain, primary management includes nerve block with local anesthetics, use of analgesics, and nerve stimulation through the skin (30 min/day for 3 weeks). If post-traumatic neural pains do not alleviate pain after 3–4 weeks, administration of various drugs has been recommended, including Neurontin (gabapentin) [55]. In general, in most patients, the sensory loss will usually improve 6–12 months after nerve repositioning, although it may not recover fully [10, 12, 29]. In some studies, this period is even reported to be up to 18 months [17]. If any intolerable problem still exists for the patient at the end of this period (12–18 months) or even before it, microsurgical exploration may be necessary.

Surgical intervention for a patient suffering from nerve injury has two main objectives: restoration of neurosensory function and managing the pain and discomfort, if present.

Indications for explorative surgery and nerve reconstruction include the following:

1. Visible injury to the nerve
2. Presence of foreign body around the nerve
3. No change in anesthesia or hypoesthesia over time
4. Uncontrollable neuropathic pain

Contraindications for explorative surgery and nerve reconstruction include the following:

1. Signs of improved sensory function based upon quantitative sensory testing (QST), which is a method for determining the exact threshold of sensory stimulation with the use of oscillatory, touch, thermal, or painful stimuli
2. Patient admission based upon remaining dysfunction or discomfort
3. Signs of central sensitivity (e.g., regional dysesthesia, secondary hyperalgesia)
4. Presence of clinical symptoms with autonomic origin (e.g., erythema, edema, hypersensitivity, burning sensation) which are indicative of autonomic nerve dysfunction rather than sensory nerve injury
5. Advanced age with the presence of an underlying systemic or neuropathic disease
6. A long time has passed since the injury (more than 12–18 months)
7. Patient with unrealistic expectations (e.g., demands immediate full recovery or resuming of sensory function with no pain)
8. Neuropathic pain that is not alleviated by local anesthesia blocks [54]

Nerve reconstruction options include the following:

1. Decompression of the injured nerve by removal of foreign bodies and releasing the scar tissues and other tissues compressed around the nerve (external neurolysis)
2. Detection of the injured area, incision, and transection of the traumatic neuroma (internal neurolysis)
3. Repair with microscopic sutures via neurorrhaphy (direct neural anastomosis)
4. Reconstruction through an interpositional nerve graft if neurorrhaphy is not feasible due to extensive loss of nerve tissue with tension on the nerve repair [54]

7.8 Sensory Function After Nerve Repositioning Surgery

The most common sensory complications following nerve repositioning are hypoesthesia, paresthesia, and hyperesthesia. The most common causes of nerve dysfunction include the

mechanical trauma to the nerve and ischemia following extracting the neurovascular bundle from the IAC, nerve traction during surgery, edema and probable hematoma formation, and/or chronic compression after the surgery [1, 2]. According to Hirsch and Branemark, the main cause of sensory disturbances is nutritional impairment of the nerve due to injury to the microvascular circulation surrounding the nerve fibers as a result of mechanical trauma. Thermal and pain sensation nerve fibers are more resistant to compressive traumatic forces and ischemia than are the larger fibers responsible for touch sensation [12].

It is worth noting that the IAN is considered a polyfascicular nerve. The smaller the number of nerve fascicles, thicker epineurium, and abundant interfascicular tissue make the IAN more resistant to pressure and vice versa (i.e., the greater the number of fascicles and the thinner the epineurium, the less resistant the nerves are to pressure) [23, 55, 68].

The incidence of postoperative neurapraxia, permanent anesthesia, and paresthesia decreases when only the thicker parts of the neurovascular bundle are manipulated compared to manipulation of thinner parts or terminal branches of the mental nerve. Therefore, although nerve repositioning in more posterior areas such as the 2nd molar area is technically more complex, it is usually associated with smaller risk of serious and long-term injuries to the nerve because the neurovascular bundle is thicker in this region. Spontaneous regenerative processes of nerve recovery following mild compression or crush injury usually take several weeks to 6 months [1]. If recovery does not occur in this time period, the possibility of permanent paresthesia may be expected. Some researchers believe that neurosensory changes following implant placement and nerve repositioning should be considered as a normal consequence of this particular treatment and not an adverse sequelae or complication [1, 69].

According to one study [10], on the nerve repositioning side, 3 of 15 patients had persistent paresthesia of the mental region and three patients had hypoesthesia. No patient had anesthesia or dysesthesia in the mental region. The three patients with paresthesia had a two-point discrimination threshold of 7–11 mm, and only

one of these patients returned to within 2 mm of the preoperative threshold value. The patients with hypoesthesia had a two-point discrimination threshold of more than 20 mm, and all of these patients failed to return to within 2 mm of the preoperative threshold value. One patient had dysesthesia that involved the anterior mandibular gingiva. This dysesthesia was experienced only with brushing or flossing around the implant and anterior teeth. This patient did not have any paresthesia or hypoesthesia in the mental region [10]. While according to Hashemi [13], 73.6 % of patients experience anesthesia in the first week due to nerve repositioning.

Other patients show other sensory disturbances, including hypoesthesia, tickling, burning, painful, pinching sensations. During the first month, the percentage of patients with hypoesthesia increases, while the percentage of patients with anesthesia sharply decreases. After 12 months, only 2.7 % of patients reported a tickling sensation, while the others had completely recovered. It was also stated that in spite of some neurosensory complaints, 94 % of the patients were satisfied with the surgery [13].

A review of the available nerve repositioning studies (Table 7.2) shows that the probability of occurrence of postsurgical neurosensory

Table 7.2 Review of literature on neurosensory disturbances following nerve repositioning surgery

| Study | No. of nerve repositioning sites | Postoperative neurosensory disturbance (no. of patients) | No. of patients who returned to normal sensation after 6–12 months (max. 18 months) | No. of patients who did not return to normal sensation at 18 months |
|---------------------------------------|----------------------------------|--|---|---|
| Jensen and Nock (1987) [6] | 2 | 2 | 2 | – |
| Rosenquist (1992) [8] | 10 | 7 | 10 | – |
| Friberg et al. (1992) [31] | 10 | 10 | 7 | 3 |
| Smiler (1993) [32] | 5 | 5 | 5 | – |
| Sethi (1993) [70] | 1 | 1 | 1 | – |
| Rosenquist (1994) [26] | 100 | 79 | 96 | 4 |
| Jensen et al. (1994) [27] | 10 | 10 | 9 | 1 |
| Rosenquist (1995) [9] | 92 | 92 | 87 | 5 |
| Rugge et al. (1995) [20] | 1 | 1 | 1 | – |
| Hirsch and Branemark (1995) [12] | 24 | 24 | 21 | 3 |
| Sethi (1995) [71] | 14 | 14 | 14 | – |
| Kan et al. (1997) [28] | 21 | 21 | 11 | 10 |
| Louis (2001) [10] | 15 | 15 | 9 | 6 |
| Peleg et al. (2002) [29] | 10 | 10 | 10 | – |
| Morrison et al. (2002) [48] | 12 | 12 | 8 | 4 |
| Bovi (2005) [14] | 1 | 1 | 1 | – |
| Ferrigno et al. (2005) [72] | 19 | 10 | 18 | 1 |
| Proussaefs (2005) [73] | 2 | 2 | 2 | – |
| Hashemi (2006) [34] | 11 | 11 | 11 | – |
| Sakkas et al. (2008) [15] | 1 | 1 | 1 | – |
| Vasconcelos et al. (2008) [2] | 1 | 1 | 1 | – |
| Del Castillo Pardo et al. (2008) [17] | 2 | 2 | 2 | – |
| Chrcanovic and Custodio (2009) [1] | 18 | 18 | 18 | – |
| Bovi et al. (2010) [16] | 10 | 10 | 10 | – |
| Kale et al. (2010) [18] | 1 | 1 | 1 | – |
| Hashemi (2010) [13] | 110 | 110 | 107 | 3 |
| Hassani and Saadat | 85 | 85 | 80 | 5 |
| Total | 588 | 555 | 543 | 45 |

problems with this technique is 94.38 %. It is worth mentioning, however, that all but three of the studies report that some patients did not experience postsurgical neurosensory problems. Thus, it seems rational to take into consideration the possibility of postsurgical neurosensory paresthesia caused by the nerve repositioning procedure for all cases. The neurosensory problems mostly resolve within 6–12 months after surgery, although few studies have reported recovery of the neurosensory loss after 18 months following nerve repositioning surgery [17]. But it is clear that in 92.34 % of cases, neurosensory problems recover within this period of time, and only in 7.66 % of cases do they persist indefinitely (greater than 12–18 months). If the neurosensory problems persist after this period, they will most likely last forever. Depending upon the particular circumstances, in some of these cases, there may be the need for microneurosurgical exploration and repair.

The important issue in management of nerve injury is to inform and educate the patient with respect to expected paresthesia that may be permanent and unpleasant. The patient should be educated before and after the surgery and should be well aware that spontaneous neurosensory recovery may take a long time and he/she may experience paresthesia or dysesthesia for a long time, possibly permanently. Studies indicate that the chance of spontaneous recovery of the nerve is less in female compared to male patients [1]. As mentioned above, most surgeons believe that neurosensory disturbances should be considered as a normal predictable state following nerve repositioning surgery and not a complication or sequelae of this type of treatment with direct nerve manipulation [1, 29].

Conclusions

Repositioning the inferior alveolar nerve is a procedure that carries a significant risk of permanent nerve damage and resultant paresthesia. The decision to perform nerve repositioning and implant placement must be justified by the need for posterior mandibular support to stabilize the dentition and provide proper oral function. Patient selection should be done with care. It is important that only

well-experienced surgeons perform this type of surgery and he/she must be familiar with management of the nerve-injured patient and have the adequate skills for assessment, diagnosis, and treatment (both nonsurgical and surgical) of patients who have had nerve repositioning surgery.

References

1. Chrcanovic BR, Custodio AL (2009) Inferior alveolar nerve lateral transposition. *Oral Maxillofac Surg* 13(4):213–219
2. Vasconcelos Jde A, Avila GB, Ribeiro JC, Dias SC, Pereira LJ (2008) Inferior alveolar nerve transposition with involvement of the mental foramen for implant placement. *Med Oral Patol Oral Cir Bucal* 13(11):E722–E725
3. Karlis V, Bae RD, Glickman RS (2003) Mandibular fracture as a complication of inferior alveolar nerve transposition and placement of endosseous implants: a case report. *Implant Dent* 12(3):211–216
4. Becker R (1970) Continuity resection of the mandible with preservation of the mandibular nerve. *Br J Oral Surg* 8(1):45–50
5. Alling C (1977) Lateral repositioning of inferior alveolar neurovascular bundle. *J Oral Surg* 35:419
6. Jensen O, Nock D (1987) Inferior alveolar nerve repositioning in conjunction with placement of osseointegrated implants: a case report. *Oral Surg Oral Med Oral Pathol* 63(3):263–268
7. Kahnberg KE, Ridell A (1987) Transposition of the mental nerve in orthognathic surgery. *J Oral Maxillofac Surg* 45(4):315–318
8. Rosenquist B (1992) Fixture placement posterior to the mental foramen with transpositioning of the inferior alveolar nerve. *Int J Oral Maxillofac Implants* 7(1):45–50
9. Rosenquist BE (1995) Nerve transpositioning to facilitate implant placement. *Dent Econ* 85(10):92–93
10. Louis P (2001) Inferior alveolar nerve transposition for endosseous implant placement. *Oral Maxillofac Surg Clin North Am* 13(2):265–281
11. Babbush CA (1998) Transpositioning and repositioning the inferior alveolar and mental nerves in conjunction with endosteal implant reconstruction. *Periodontol* 2000 17:183–190
12. Hirsch JM, Branemark PI (1995) Fixture stability and nerve function after transposition and lateralization of the inferior alveolar nerve and fixture installation. *Br J Oral Maxillofac Surg* 33(5):276–281
13. Hashemi HM (2010) Neurosensory function following mandibular nerve lateralization for placement of implants. *Int J Oral Maxillofac Surg* 39(5):452–456
14. Bovi M (2005) Mobilization of the inferior alveolar nerve with simultaneous implant insertion: a new technique. Case report. *Int J Periodontics Restorative Dent* 25(4):375–383

15. Sakkas N, Otten JE, Gutwald R, Schmelzeisen R (2008) Transposition of the mental nerve by piezosurgery followed by postoperative neurosensory control: a case report. *Br J Oral Maxillofac Surg* 46(4):270–271
16. Bovi M, Manni A, Mavriqi L, Bianco G, Celletti R (2010) The use of piezosurgery to mobilize the mandibular alveolar nerve followed immediately by implant insertion: a case series evaluating neurosensory disturbance. *Int J Periodontics Restorative Dent* 30(1):73–81
17. Del Castillo Pardo de Vera JL, Chamorro Pons M, Cebrián Carretero JL (2008) Repositioning of the inferior alveolar nerve in cases of severe mandibular atrophy. A clinical case. *Med Oral Patol Oral Cir Bucal* 13(12):E778–E782
18. Kale TP, Patel JN, Bhutani H (2010) Mental nerve repositioning—a case report. *Int J Dent Clin* 2(3):58–60
19. Felice P, Corinaldesi G, Lizio G, Piattelli A, Iezzi G, Marchetti C (2009) Implant prosthetic rehabilitation of posterior mandible after tumor ablation with inferior alveolar nerve mobilization and inlay bone grafting: a case report. *J Oral Maxillofac Surg* 67(5):1104–1112
20. Ruge G, Lekholm U, Nevins M (1995) Osseointegration and nerve transposition after mandibular resection to treat an ameloblastoma: a case report. *Int J Periodontics Restorative Dent* 15(4):396–403
21. Zuniga JR, Zenn MR (2001) Principles of microsurgery. *Oral Maxillofac Surg Clin North Am* 13(2):331–342
22. Rocchietta I, Fontana F, Simion M (2008) Clinical outcomes of vertical bone augmentation to enable dental implant placement: a systematic review. *J Clin Periodontol* 35:203–215
23. Hupp JR, Ellis E, Tucker MR (2008) Contemporary oral and maxillofacial surgery, 5th edn. Mosby/Elsevier, Missouri, pp 281, 285, 620–622
24. Lindh C, Petersson A (1989) Radiologic examination for location of the mandibular canal: a comparison between panoramic radiography and conventional tomography. *Int J Oral Maxillofac Implants* 4(3):249–253
25. Babbush CA, Hahn JA, Krauser JT, Rosenlicht JL (2010) Dental implants: the art and science, 2nd edn. Saunders/Elsevier, London, pp 232–250
26. Rosenquist BO (1994) Implant placement in combination with nerve transpositioning: experiences with the first 100 cases. *Int J Oral Maxillofac Implants* 9(5):522–531
27. Jensen J, Reiche-Fischel O, Sindet-Pedersen S (1994) Nerve transposition and implant placement in the atrophic posterior mandibular alveolar ridge. *J Oral Maxillofac Surg* 52(7):662–668
28. Kan JY, Lozada JL, Goodacre CJ, Davis WH, Hanisch O (1997) Endosseous implant placement in conjunction with inferior alveolar nerve transposition: an evaluation of neurosensory disturbance. *Int J Oral Maxillofac Implants* 12(4):463–471
29. Peleg M, Mazor Z, Chaushu G, Garg AK (2002) Lateralization of the inferior alveolar nerve with simultaneous implant placement: a modified technique. *Int J Oral Maxillofac Implants* 17(1):101–106
30. Poort LJ, van Neck JW, van der Wal KG (2009) Sensory testing of inferior alveolar nerve injuries: a review of methods used in prospective studies. *J Oral Maxillofac Surg* 67(2):292–300
31. Friberg B, Ivanoff CJ, Lekholm U (1992) Inferior alveolar nerve transposition in combination with Branemark implant treatment. *Int J Periodontics Restorative Dent* 12(6):440–449
32. Smiler DG (1993) Repositioning the inferior alveolar nerve for placement of endosseous implants: technical note. *Int J Oral Maxillofac Implants* 8(2):145–150
33. Bagheri SC, Meyer RA (2011) Management of mandibular nerve injuries from dental implants. *Atlas Oral Maxillofac Surg Clin North Am* 19(1):47–61
34. Hashemi HM (2006) A modified technique of inferior alveolar nerve repositioning: results in 11 patients. *Acta Med Iran* 44(4):273–276
35. Hashemi HM (2006) Retraction of the inferior alveolar nerve during implant insertion using the rubber piston of a dental anaesthetic cartridge. *Asian J Oral Maxillofac Surg* 18:134–135
36. Yoshimoto M, König B Jr, Allegrini S Jr, de Carvalho Lopes C, Carbonari MJ, Liberti EA, Adami N Jr (2004) Bone healing after the inferior alveolar nerve lateralization: a histologic study in rabbits (*Oryctolagus cuniculus*). *J Oral Maxillofac Surg* 62:131–135
37. Kahnberg KE, Henry PJ, Tan AE, Johansson CB, Albrektsson T (2000) Tissue regeneration adjacent to titanium implants placed with simultaneous transposition of the inferior dental nerve: a study in dogs. *Int J Oral Maxillofac Implants* 15(1):119–124
38. Yoshimoto M, König BJ, Coelho PG, Allegrini SJ, Luiz FF (2008) A light and scanning electron microscopy study of bone healing following inferior alveolar nerve lateralization: an experimental study in rabbits. *Int J Oral Maxillofac Implants* 23(3):457–462
39. Yoshimoto M, Watanabe IS, Martins MT, Salles MB, Ten Eyck GR, Coelho PG (2009) Microstructural and ultrastructural assessment of inferior alveolar nerve damage following nerve lateralization and implant placement: an experimental study in rabbits. *Int J Oral Maxillofac Implants* 24(5):859–865
40. Kraut RA, Chahal O (2002) Management of patients with trigeminal nerve injuries after mandibular implant placement. *J Am Dent Assoc* 133(10):1351–1354
41. Beukelaer J, Smeele LE, Ginkel FC (1998) Is short-term neurosensory testing after removal of mandibular third molars efficacious? *Oral Surg Oral Med Oral Pathol Oral Radiol Endod* 85:366–370
42. Ylikontiola L, Kinnunen J, Oikarinen K (1998) Comparison of different tests assessing neurosensory disturbances after bilateral sagittal split osteotomy. *Int J Oral Maxillofac Surg* 27(6):417–421
43. Juodzbals G, Wang HL, Sabalys G (2011) Injury of the inferior alveolar nerve during implant placement: a literature review. *J Oral Maxillofac Res* 2(1):e1

44. Ylikontiola L, Kinnunen J, Laukkanen P, Oikarinen K (2000) Prediction of recovery from neurosensory deficit after bilateral sagittal split osteotomy. *Oral Surg Oral Med Oral Pathol Oral Radiol Endod* 90(3):275–281
45. Jääskeläinen SK (1995) Blink reflex with stimulation of the mental nerve. Methodology, reference values, and some clinical vignettes. *Acta Neurol Scand* 91(6):477–482
46. Essick GK (1992) Comprehensive clinical evaluation of perioral sensory function. *Oral Maxillofac Surg Clin North Am* 4:503
47. Walter JM Jr, Gregg JM (1979) Analysis of postsurgical neurologic alteration in the trigeminal nerve. *J Oral Surg* 37(6):410–414
48. Morrison A, Chiarot M, Kirby S (2002) Mental nerve function after inferior alveolar nerve transposition for placement of dental implants. *J Can Dent Assoc* 68(1):46–50
49. Essick GK, Phillips C, Turvey TA et al (2007) Facial altered sensation and sensory impairment after orthognathic surgery. *Int J Oral Maxillofac Surg* 36:577
50. Nishioka GJ, Zysset MK, Van Sickels JE (1987) Neurosensory disturbance with rigid fixation of the bilateral sagittal split osteotomy. *J Oral Maxillofac Surg* 45:20
51. Chen N, Neal CE, Lingenbrink P et al (1999) Neurosensory changes following orthognathic surgery. *Int J Adult Orthodon Orthognath Surg* 14:259
52. Geha HJ, Gleizal AM, Nimeskern NJ et al (2006) Sensitivity of the inferior lip and chin following mandibular bilateral sagittal split osteotomy using piezosurgery. *Plast Reconstr Surg* 118:1598
53. Westermarck A, Englesson L, Bongehiellm U (1999) Neurosensory function after sagittal split osteotomy of the mandible: a comparison between subjective evaluation and objective assessment. *Int J Adult Orthodon Orthognath Surg* 14:268
54. Fonseca RJ, Barber HD, Matheson JD (2009) *Oral and maxillofacial surgery*, vol 1, 2nd edn. Saunders/Elsevier, Missouri, pp 260–270, Vol.2, p.959–976
55. Yaghmaei M (2010) *Mandibular canal (clinical aspects)*, 1st edn. Karvar Publishers, Tehran
56. Khullar SM, Brodin P, Barkvoll P et al (1996) Preliminary study of low-level laser for treatment of long-standing sensory aberrations in the inferior alveolar nerve. *J Oral Maxillofac Surg* 54:2
57. Seo K et al (2004) Efficacy of steroid treatment for sensory impairment after orthognathic surgery. *Oral Maxillofac Surg* 62:1193
58. Galloway EB, Jensen RL, Dailey AT, Thompson BG, Shelton C (2000) Role of topical steroids in reducing dysfunction after nerve injury. *Laryngoscope* 110(11):1907–1910
59. Han SR, Yeo SP, Lee MK, Bae YC, Ahn DK (2010) Early dexamethasone relieves trigeminal neuropathic pain. *J Dent Res* 89(9):915–920
60. Kohnelein KE, Ocker K, Seitz HD (1980) Experimental rails to inhibit neuroma formation. *Chir Plast (Berl)* 5:207–211
61. Seo K, Tanaka Y, Terumitsu M, Someya G (2004) Efficacy of steroid treatment for sensory impairment after orthognathic surgery. *J Oral Maxillofac Surg* 62(10):1193–1197
62. Misch CE, Resnik R (2010) Mandibular nerve neurosensory impairment after dental implant surgery: management and protocol. *Implant Dent* 19(5):378–386
63. Olson JE, Stravino VD (1972) A review of cryotherapy. *Phys Ther* 52(8):840–853, Review
64. Kubilius R, Sabalys G, Juodzbaly G, Gedrimas V (2004) Traumatic damage to the inferior alveolar nerve sustained in course of dental implantation. Possibility of prevention. *Stomatologija Baltic Dent Maxillofac* 6:106–110
65. Misch CE (2008) Root form surgery in the edentulous anterior and posterior mandible: implant insertion. In: Misch CE (ed) *Contemporary implant dentistry*. Mosby/Elsevier, St. Louis, pp 221–226
66. Robinson PP, Loescher AR, Yates JM, Smith KG (2004) Current management of damage to the inferior alveolar and lingual nerves as a result of removal of third molars. *Br J Oral Maxillofac Surg* 42(4):285–292
67. Loescher AR, Robinson PP (1998) The effect of surgical medicaments on peripheral nerve function. *Br J Oral Maxillofac Surg* 36:327–332
68. Colella G, Cannavale R, Vicidomini A, Lanza A (2007) Neurosensory disturbance of the inferior alveolar nerve after bilateral sagittal split osteotomy: a systematic review. *J Oral Maxillofac Surg* 65(9):1707–1715
69. Davis H, Ohnell LO, Larson C, et al (1990) Lateralizing of the inferior alveolar nerve to allow fixture placement. *Proceedings of the UCLA Symposium on Implants in the Partially Edentulous Patient*. Los Angeles:28–31
70. Sethi A (1993) Inferior alveolar nerve repositioning in implant dentistry: clinical report. *Implant Dent* 2(3):195–197
71. Sethi A (1995) Inferior alveolar nerve repositioning in implant dentistry: a preliminary report. *Int J Periodontics Restorative Dent* 15(5):474–481
72. Ferrigno N, Laureti M, Fanali S (2005) Inferior alveolar nerve transposition in conjunction with implant placement. *Int J Oral Maxillofac Implants* 20(4):610–620
73. Proussaefs P (2005) Inferior alveolar nerve transposing in a situation with minimal bone height: a clinical report. *J Oral Implantol* 31(4):180–185

Anders Westermark

Correction of cranio-maxillofacial deformity by means of orthognathic surgery includes procedures that may cause impaired sensory nerve function in the facial skin distribution. The most common site for such disturbance is the lower lip and chin area following a sagittal split ramus osteotomy of the mandible. Most often, however, such impaired sensitivity is tolerated well by the patient, but careful preoperative information about the risk of obtaining a neurosensory impairment is of primary importance in patient management. It is generally accepted that inferior alveolar nerve injury is the most common complication of mandibular orthognathic surgery, with immediate neurosensory dysfunction occurring in nearly 100 % of patients and long-term paresthesia occurring to a variable degree.

8.1 Orthognathic Surgery

Orthognathic surgery is directed toward correction of malpositioned jaws, or parts thereof. Orthognathic surgery may be performed as mandibular procedures, maxillary procedures, or combined bimaxillary surgeries. Occasionally, the osteotomies employed in orthognathic surgery are utilized to gain access to tumors or

other pathological conditions including vascular access. In the vast majority of cases, however, they are used as elective procedures in order to improve occlusion, masticatory function, and facial esthetics. Also, the vast majority of patients treated with orthognathic surgery are young and healthy individuals. A common age for the operation is in the upper teenage years, and in general, such procedures should be done with a minimum of adverse sequelae. That, however, is not always the case. Since orthognathic surgery was established as a common treatment modality half a century ago, it also has been clear that mandibular osteotomies, more commonly than maxillary cases, may be followed by various degrees of neurosensory disturbances (NSDs).

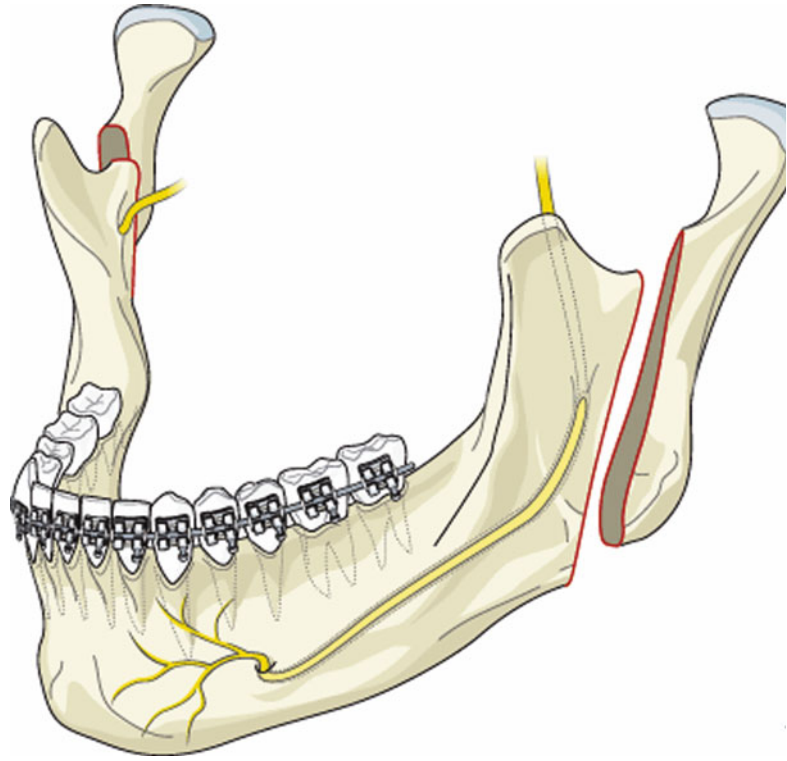
The inferior alveolar nerve (IAN) distributes sensory function to the lower lip and chin, as well as for the buccal gingiva anterior of the mental foramen. The infraorbital nerve (ION) carries the sensation for the skin of the cheek, side of the nose, upper lip, and the buccal gingiva in the anterior region of the maxilla. The somatosensory function of each of these areas is at risk as a result of orthognathic surgery.

8.2 Mandibular Osteotomies

In the mandible, three osteotomy designs and used most frequently including the vertical ramus osteotomy (VRO), sagittal split ramus osteotomy (SSRO), and genioplasty. It is beyond the scope of

A. Westermark, DDS, PhD
Department of Oral and Maxillofacial Surgery,
Åland Central Hospital, PB 1055, AX 22111,
Mariehamn, Åland, Finland
e-mail: a.h.westermark@aland.net

Fig. 8.1 Vertical ramus osteotomy is performed posterior to the mandibular foramen (lingula region) to avoid injury to the IAN



this chapter to describe these surgical procedures in detail, and it is assumed that there is a familiarity with each of these surgeries.

In short, however, the VRO cuts the mandibular ramus from the sigmoid notch inferiorly to the mandibular angle region (Fig. 8.1). The cut is carried out posterior to where the mandibular nerve enters the mandibular ramus on the medial side in the mandibular foramen at the lingula. In most cases this osteotomy is performed intraorally, but the extraoral approach is also used. The VRO requires intermaxillary fixation (IMF) for 3–6 weeks after surgery if rigid fixation is not utilized. The VRO can only be used for mandibular setback procedures.

The SSRO divides the mandible in the angular region of the ramus and body of the mandible. Between a medial horizontal cut on the ramus and a lateral vertical cut in the molar region, the

mandible is split sagittally, ideally along the inner surface of the lateral cortex (Fig. 8.2). This osteotomy can be used for mandibular setback, advancement, and rotational movements. The proximal and distal bone fragments can be fixated with osteosynthesis of various types; therefore, IMF is not needed in the postoperative period. There are many possible risk factors for nerve injury resulting from orthognathic surgery, and these are summarized in Table 8.1.

In the genioplasty procedure, the anterior part of the mandible is cut more or less horizontally below and anterior to the mental foramen, and to a point approximately 1 cm above the symphyseal base (Fig. 8.3). This chin segment of the mandible can then be mobilized and fixated in a new position. In addition, this osteotomy does not disrupt the mandibular continuity.

Fig. 8.2 Bilateral sagittal split ramus osteotomy places the IAN at risk for injury due to osteotomy design

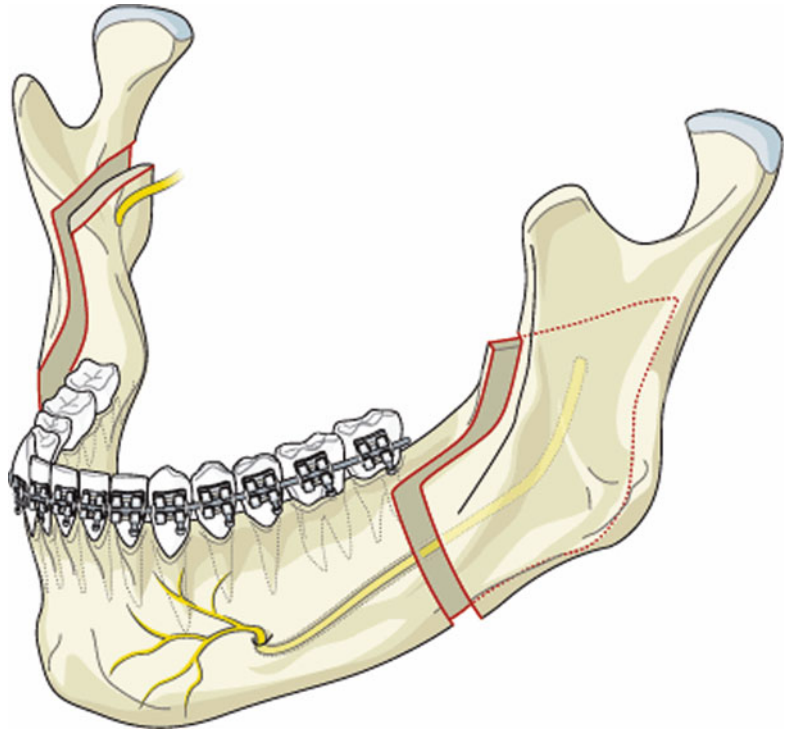


Table 8.1 Risk factors for IAN injury during SSRO

| |
|--|
| Patient age |
| Patient gender |
| Type of surgical procedure |
| Type of mandibular deformity |
| Variation in nerve anatomy |
| Surgical technique |
| Nerve manipulation |
| Instrumentation |
| Nerve position (proximal/distal segment) |
| Method of fixation |
| Duration of surgery |
| Surgeon experience |
| Inadvertent osteotomies (bad splits) |
| Presence of third molars |

Clearly, the SSRO, which splits the mandible along 2–3 cm of the mandibular body and ramus, must be considered as a high-risk procedure for the IAN coursing in the same bony structure, at least much more than the VRO and genioplasty, and this is also reflected in the literature.

8.2.1 Sagittal Split Ramus Osteotomy (SSRO)

One of the pioneers of SSRO, Hugo Obwegeser, discussed in a paper in 1964 [13] the indications for the procedure without even mentioning the risk of NSD as a result of the surgery. Later, numerous papers have indicated that SSRO might be followed by more than a minimal NSD of the lower lip and chin. Of interest is the extremely variable occurrence of NSD after SSRO reported in the literature. In his thesis [20] Westermark made a list of 35 papers published between 1974 and 1999, in which NSD of the lower lip and chin were reported from between zero and 85 % following SSRO surgery. It was not only the reported numbers that varied widely but also the method used to evaluate neurosensory function. Further, some authors reported per side NSD incidence, while others reported per patient incidence. Some authors with very low numbers of NSD performed their evaluation by testing the skin response with

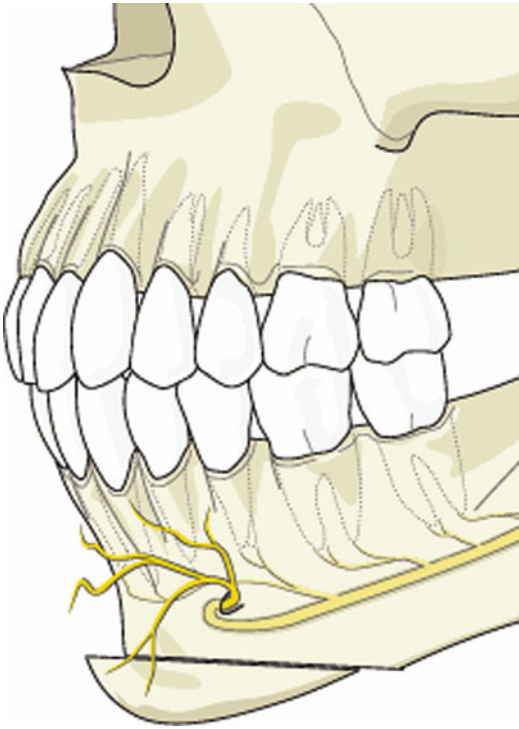


Fig. 8.3 Genioplasty procedure of the anterior mandible places the IAN and mental nerve terminal branches at risk for injury

a sharp probe only. Patients who did not respond to such a stimulus were considered to have an NSD. The more sophisticated the evaluation methods used, the more NSD could be detected. This author compared subjective evaluation and objective assessment of neurosensory function in patients who, after SSRO, had a self-reported NSD of varying degrees [23]. The examination modalities used included the visual analogue scale (VAS), light touch perception, and perception thresholds of warm and cold temperatures. The results indicated that there was a relatively good positive correlation between subjective evaluation and objective assessment of the sensitivity of the lower lip and chin after SSRO of the mandible. In another paper in the same thesis this author reported on IAN function after mandibular osteotomies [21]. For SSRO the data was based upon 548 operated sides with a minimum follow-up time of 2 years. The neurosensory function was evaluated on a 5° scale, where 5,

fully normal sensitivity; 4, almost normal sensation; 3, reduced sensation; 2, almost numb; and 1, numb. The distribution was the following: score 5, 61 %; score 4, 22 %; score 3, 14 %; score 2, 2 %; and score 1, 1 %. Interestingly, the two worst scores (scores 1 and 2), representing about 3 % of the operated sides, corresponded well with the previously mentioned reports, where NSD was considered present if the patient did not respond to sharp probing. With the low numbers in the two worst groups, these were added into group 3. Then, the figures indicated that of the operated sides 60 % had fully normal sensitivity of the lower lip and chin, 20 % had a very slightly reduced sensitivity, and 20 % had a reduced sensitivity. The difference between groups 2 and 3 was that in group 2, with a very slight neurosensory disturbance, the abnormal sensation was barely perceptible, while in group 3, the patients were subjectively aware of their NSD. The distribution of “60-20-20” fell very much in the middle of the previously mentioned list of reports and has been supported in later studies with a similar methodological approach.

What, then, is the cause of NSD after SSRO? As mentioned above, the SSRO procedure osteotomizes the mandible along a substantial part of the body, angle, and ramus regions. Therefore, it is generally thought that NSD follows direct trauma to the IAN during the actual osteotomy procedure. This author studied how NSD after SSRO correlated with intraoperative nerve encounter and other variables in 496 operations [22]. From the information contained in the surgical operative reports about nerve encounter during the splits, the nerve was described as one of the following: not exposed at all, visible in the medial fragment, free in between the fragments, dissected from the lateral fragment/superficial damage to the nerve, deep damage into the nerve trunk, and nerve transection. Other study variables included patient age, degree of mandibular movement, type of osteosynthesis used, and surgeon skill/experience. Patient age had a significant influence on the recovery of neurosensory function. The mean age of the patients in the study was 26 years, the median age was 22, and the 25 and 75 percentiles were 18 and 33 years, respectively. Both when the

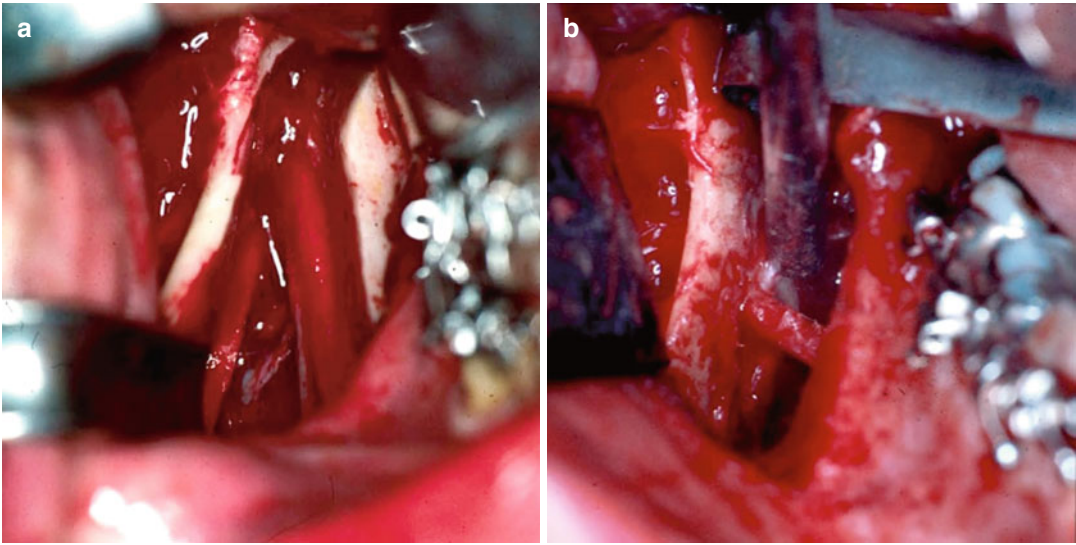


Fig. 8.4 (a) IAN is visualized between the proximal and distal segments during an SSRO procedure. (b) The IAN is entrapped in the proximal segment; this is associated with a higher incidence of NSD following SSRO surgery

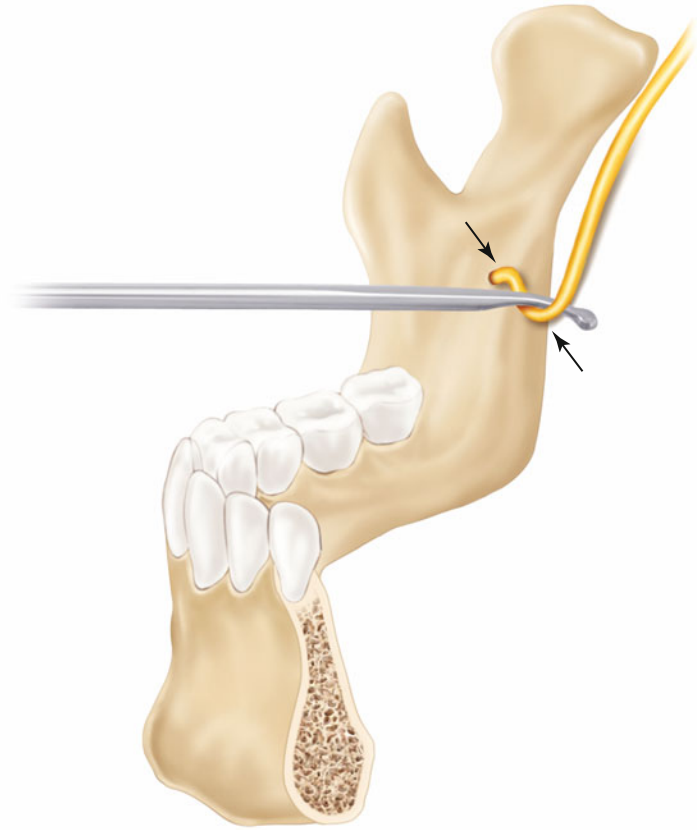
patient series was divided at the median and when the youngest and oldest quartiles were compared with the mid-half, there were significant differences in sensitivity scores. The largest differences were found between the youngest and oldest quartiles. The severity of the neurosensory disturbances was also increased with age.

Intraoperative nerve encounter, however, correlated with NSD to a much lesser degree than expected. While there were more NSD and more severe NSD among the sides where the nerve had been manipulated more extensively in the split, there were also many of those who demonstrated very good neurosensory function. Those sides where the nerves were embedded in the distal fragments did better than those with nerves embedded in the proximal segments (Fig. 8.4), but even among them, there were those with more or less severe NSD. All in all, the nerve encounter as such did not seem to be the only factor involved in the occurrence of NSD. It was suggested that the soft tissue dissection on the medial aspect of the ramus partly may compress the nerve over the lingula and under the dissecting instrument, and partly stretch the nerve between the two (Fig. 8.5). Lingual nerve injury is much less common than inferior alveolar nerve injury, but it may occur possibly from nerve manipulation

on the medial ramus or from screw overpenetration during fixation of the proximal and distal fragments [19, 25].

Both compression and stretching of a nerve may seriously harm the nerve function. Interestingly, when the results of surgeons in training were compared with those of the consultant or attending surgeon, there was a significant difference in favor of the experienced surgeon. Realizing the relative difficulty with the soft tissue dissection, it might not come as a major surprise that the inexperienced surgeon might spend a longer amount of time there, and may run a larger risk of causing nerve compression and stretching during the dissection, and during the time it takes to perform the horizontal cut. Several attempts have been made to observe such dissection trauma, for example, by means of trigeminal somatosensory-evoked potentials (TSEP). With this neurophysiological testing modality, the nerve impulses along a nerve can be observed both during the dissection phase and under resting conditions. By monitoring TSEP [8], support for the idea that the soft tissue dissection on the medial aspect of the mandibular ramus might significantly compress the nerve was obtained. It was stated, however, that TSEP in the surgical setting could be obtained “only with some difficulty.”

Fig. 8.5 Medial retraction during SSRO may cause IAN compression and contribute to postoperative NSD



Neither the type of osteosynthesis applied nor the direction or degree of mandibular movement played a significant role in the occurrence of postoperative NSD. When bicortical screws are used for the stabilization of SSRO fragments, care should be taken, of course, to avoid the course of the nerve trunk. Also, one should avoid using a lag screw technique, since this technique compresses the fragments toward each other, and there is a risk of nerve trunk compression. Also, there seems to be no difference in postoperative neurosensory function if the bone fragments after SSRO have been stabilized with metal or with biodegradable osteosynthesis [24].

The impact of age has been widely discussed in the literature. Not only the frequency but also the impact of NSD seems to be higher in advanced ages. The better outcome in the younger individuals may depend upon two

factors. Partly, the young patient may possess a better capacity of nerve regeneration as such, and partly, the adaptation to a NSD may be easier in a young than in an elderly patient. Recently Baas et al. [4] demonstrated an age-related increase in NSD after sagittal split of the mandible. In the same paper they also found that there was no significant difference in neurosensory function after mandibular advancement done by sagittal split osteotomy or by distraction osteogenesis of the mandible. In another study of subjective paresthesia following 68 SSRO procedures [12], 62 % of patients had NSD at 2 months, 38 % NSD at 6 months, 32 % NSD at 18 months, and 24 % subjective paresthesia at 30 months. The most important factors included age >30, method of fixation (lag screw worse than mini-plate worse than wire fixation), and perioperative position of the IAN

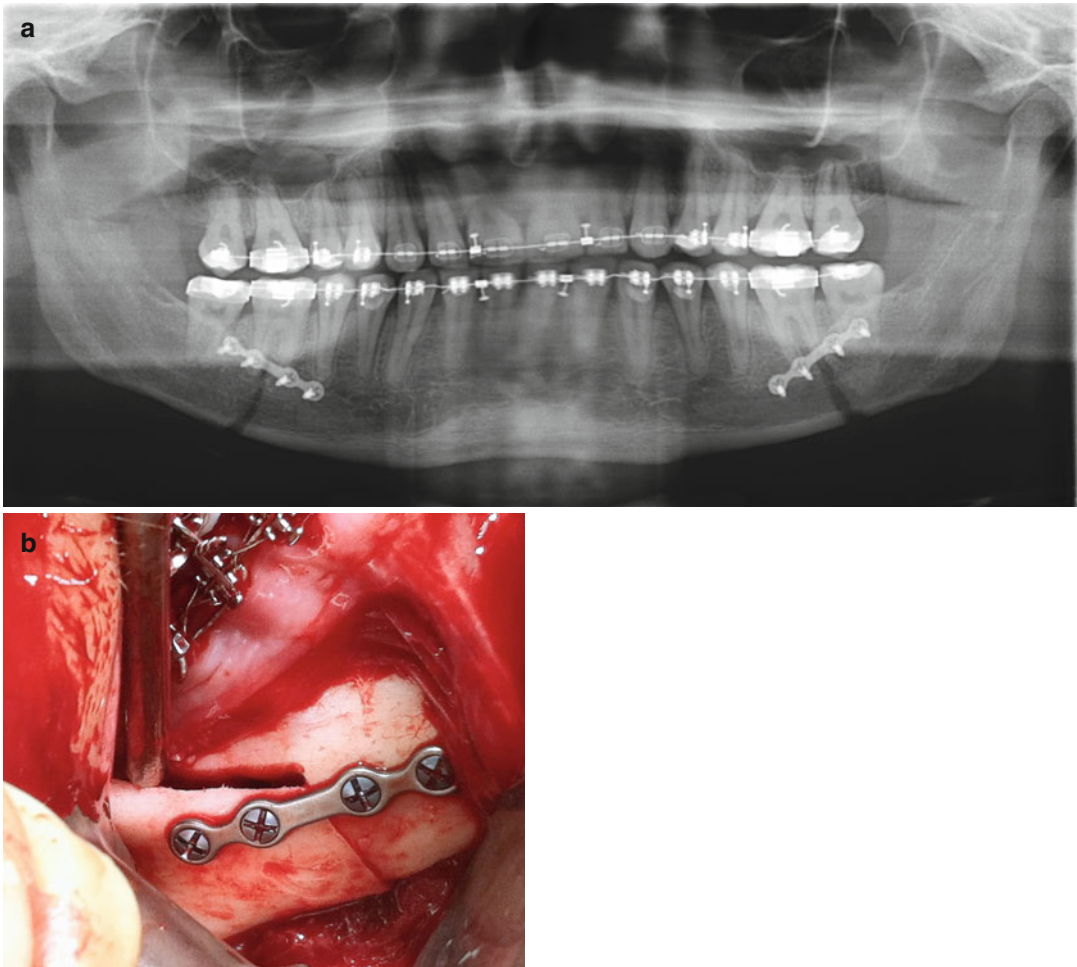


Fig. 8.6 (a) Panoramic radiograph demonstrating monocortical plate and screw fixation following SSRO surgery. (b) Intraoperative view of monocortical plate and screw

fixation of an SSRO procedure. This technique helps to prevent unnecessary compression of the IAN between the bony segments (Courtesy of Michael Miloro)

(worse if located in the proximal segment than the distal segment). In general the monocortical mini-plate permits passive contact of the proximal and distal segments without compression on the IAN (Fig. 8.6).

There are several other risk factors for IAN injury during SSRO surgery including the use of thin chisels that may cause iatrogenic injury. In addition, female gender may play a role in NSD since it has been shown that females recover slower and less fully than males following nerve injuries. The presence of third molars and concomitant removal during SSRO may increase the

incidence of NSD since there may be additional nerve contact or manipulation during the odontectomy procedure. The occurrence in advertent osteotomies, or bad splits, also increases the risk of IAN NSD. Finally, it has been shown that in class II retrognathic patients, the inferior alveolar canal may be closer to the buccal cortex and therefore at higher risk of injury during an SSRO procedure [6]. In addition, with severe mandibular deformities such as hemifacial microsomia or Treacher Collins syndrome cases, the position of the inferior alveolar canal may be extremely variable.

While the use of corticosteroids perioperatively has been shown to decrease edema as well as perineurial edema, studies have shown [2] that the difference is not statistically significant. In this questionnaire study of 43 patients more than 1 year after SSRO, 11.6 % reported long-term subjective NSD. Most of the patients reporting NSD were woman over 40 years of age at the time of SSRO. While only 15 % of patients who received perioperative steroids reported NSD and 30 % of patients without steroids reported NSD, the results were not statistically significant.

8.2.2 Vertical Ramus Osteotomy (VRO) and Genioplasty

Vertical ramus osteotomy (VRO) and genioplasty procedures are associated with less postoperative NSD than SSRO. Again, there are variations in the incidence reported, and those may depend upon how the NSD has been evaluated. An incidence below 10 % for VRO and genioplasty seems realistic [7, 20, 21]. The lower risk of NSD after VRO compared with SSRO is a reason why VRO is still used in some centers, despite the morbidity of intermaxillary fixation that follows the procedure. Many centers have abandoned VRO because of the possible threat to the airway in an edematous postoperative patient with IMF. Another limitation is that the VRO can be used only for mandibular setback movements.

Hand surgeons use a definition called double-crush injury, which relates to a situation when one nerve has crush damages at two distinct sites. Such a situation may occur in orthognathic surgery, too, if a ramus osteotomy is combined with a genioplasty. In this authors research [20, 21], there was a tendency toward a higher incidence and increased severity of the NSD when genioplasty was added to both VRO and SSRO. Those tendencies were not, however, statistically significant, but were supported by others [15] who reported more NSD after SSRO combined with genioplasty than after SSRO alone. In one study (Lindqvist and Obeid 1996) the incidence of NSD with genioplasty alone was 10 %, and it was 28.5 % in cases of genioplasty combined with SSRO surgery [9].

8.3 Maxillary Osteotomies

While disturbances in the IAN after mandibular osteotomies have been documented in numerous publications, the maxillary nerve has not attracted the same attention in the literature. A one-piece Lefort I osteotomy (LFO) can be carried out in a relatively safe distance from the infraorbital nerve (ION). Still, if one does not pay attention, the retracting instruments may create a substantial compression of the ION where it exits the bone through the infraorbital foramen. Also, the mucosa in the upper vestibule is incised and the nerves to the marginal gingiva will usually be transected. In addition, plate and screw fixation may also compromise the ION due to proximity in placement. Even so it seems to be a general assumption that LFO is not followed by sensory impairment of a degree that requires the same words of warning that surgeons claim for mandibular osteotomies. Such an assumption, however, is not correct.

Thus, in one study [14] 59 patients who were 1 year after LFO were studied, and it was found that somatosensory function in the distribution area of ION was incomplete compared with the preoperative condition. Another study [11] made 2- and 8-year follow-up examinations with both objective measurements and self-reported sensitivity evaluations. They reported changes in somatosensory function in 17–43 % of their patients, depending upon type of assessment. Another study [17] observed that 1 month after LFO, 81 % of patients demonstrated hypoesthesia in the distribution area of the ION and that 1 year after surgery, only 6 % of the patients had persistent hypoesthesia. Other investigators [16] found that somatosensory function in the skin innervated by ION was normalized 6 months after LFO, while the recovery of sensory function in the palate was incomplete. Similar findings were reported by others [3].

Recently, a study [18] investigated ION function after LFO in a prospective and more standardized fashion. The patients reported an array of sensory disturbances both in the skin and in their intraoral soft tissues. There were tooth sensitivity disturbances that obscured the patient's impression of occlusal conditions. Apart from hypo-sensations, there were also hyper-sensations

reported. In summary, these findings demonstrated subjective changes in somatosensory function of the ION in 7–60 % of the patients, depending upon the site of measurement, 1 year after LFO. Still, they noted that 100 % of their patients were satisfied with the outcome of their surgical procedures and would elect to undergo surgery again.

These observations probably reflect the previously mentioned assumption that the somatosensory disturbances of the ION after LFO are of such a low magnitude causing little subjective complaints that they are of a more academic than clinical interest. Still, however, they should not be ignored, and patients should be properly informed prior to surgery.

8.4 Allodynia

It sometimes occurs that a traumatized sensory nerve produces pain as a response to a stimulus that normally should not result in pain (e.g., light touch). This condition is called allodynia, and it can also occur in a sensory nerve with hypofunction. Thus, a patient can have an increased threshold for light touch and at the same time react with intense pain upon a stimulus that should be experienced as light touch. This is probably the worst somatosensory dysfunction of all that can follow orthognathic surgery. A bilateral loss of light touch sensitivity of the lower lip and chin with addition of intense pain upon touch is a condition that will require a great deal of tender care from the surgeon, preferably with the aid of a neurologist for pharmacologic management.

8.5 Preoperative Considerations

How should we best prepare our patients for the possibility of an NSD after SSRO? Pragmatically, it is fair to say that every patient (100 %) will have some degree of NSD directly after surgery. In the majority of patients, the sensitivity of the lower lip and chin will improve over the first several weeks following surgery, and the majority will return to a normal, or almost normal, sensitivity.

If the patient asks about a more precise prediction, it becomes more difficult to determine such

a percentage of NSD based upon a wide variation in the literature. We can accept the figures of 60-20-20, representing the percentages for fully normal sensation, almost normal sensation, and reduced sensation of the lower lip and chin per the operated side after SSRO. Then we can proceed in two different manners to describe what may result in the long term.

On the one hand we could consider NSD as a clinical condition and suggest that those with almost normal sensitivity are so close to normal that they do not have significant symptoms and therefore may be included in the normal sensitivity group. In this case, the risk of permanent NSD is 20 % per operated side, or actually slightly below 20 %, since the groups were equilibrated as described above. Then, we can inform patients in this fashion based upon solid statistical evidence.

On the other hand, we could be more academic about this matter and use the statistics to describe the complete risk of obtaining some, even the slightest, type of NSD on either, or both sides, of the lower lip and chin. If we maintain the 60-20-20 rule, the percentage for almost normal and reduced sensitivity will be 40 %. The formula for any type of NSD on either or both sides of the lower lip and chin then will be calculated as follows: $(0.4+0.4) - 0.4 \times 0.4 = 0.8 - 0.16 = 64\%$ chance of NSD following SSRO.

Thus, depending upon how we present the same material to patients, we can do it with widely varying presumptions, while remaining more or less truthful about the percentages. With increasing age and experience, this author has found it increasingly valuable to be very frank about the risk of obtaining permanent NSD after orthognathic surgery. In general, the more time that passes after the SSRO procedure, the less the significance of the NSD to the patient.

8.6 New Research on Orthognathic Nerve Injuries

When molecular biology started to find keys to a lot of growth factors that are steering and modulating tissue formation and healing, great hopes grew that one day nerve growth factors and similar substances might be used to improve recovery

of function after injuries to both sensory nerves and motor nerves, whether the injury being caused by trauma or by elective surgery. So far, however, these substances have not been introduced in everyday surgical activities.

Advances in diagnostic tools have made it easier to observe complicating inferior alveolar nerve anatomy and position, by which some traumatic nerve interferences during SSRO can be avoided [1].

Also, the mere understanding of a possible dissection trauma, where a procedure performed to protect, in fact may harm the nerve, has helped to shorten that particular process in order to reduce the impact on the nerve in SSRO.

Recent studies also have brought our attention to aspects previously hardly considered. Thus, a paper by Doucet et al. [5] indicated that if impacted third molars were removed during SSRO, rather than before, the incidence of NSD was reduced.

Even though these new research findings seem to reduce NSD after SSRO, they do not eliminate NSD. Orthognathic surgery will for a long future to come continue to produce NSDs of various degrees and severity.

Another study [10] used low-level laser (LLL) treatment perioperatively for six patients undergoing SSRO surgery. The IAN was treated at the mandibular foramen, mental foramen, and lower lip and chin region using a gallium-aluminum-arsenide (Ga-Al-Ar) laser at 820 nm. It was found that brushstroke directional discrimination was normal at 14 days and two-point discrimination thresholds were normal by 8 weeks in all patients. There were few abnormalities in thermal discrimination and pinprick nociception, but in those that did occur, they tended to last longer (>2 months). Using a VAS scale, patients reported a 50 % deficit at 2 days and only 15 % at 8 weeks. This LLL treatment shows promise in management of difficult and long-lasting nerve injuries, but may also be used, as in this study, preemptively in order to prepare the IAN for the expected surgical insult and expected paresthesia to decrease the incidence of long-term NSD.

8.7 Recommendations

In order to attempt to avoid IAN injury during SSRO surgery, there are several considerations that can be useful. The vertical osteotomy should be made in the first or second molar region to avoid the most lateral position of the IAN in the third molar region. Also, the depth of the osteotomy should be limited to 2–3 mm in the first molar region to avoid the IAN. The horizontal osteotomy should be made at a reasonable distance above the mandibular foramen on the medial aspect of the ramus to avoid the IAN as it enters the mandible. Care should be taken to avoid significant compression of the IAN during medial retraction for the horizontal osteotomy. The use of thin sharp chisels should be avoided in favor of larger chisels to initiate the osteotomy only and then the use of a spreading instrument (e.g., Smith spreader) to complete the SSRO.

The management of IAN injuries is similar to the management of IAN injuries due to other causes. Intraoperative transection of the IAN may necessitate a corticotomy to the mental foramen in order to mobilize the nerve enough for primary neuroorrhaphy (Fig. 8.7). As mentioned, persistent decreased sensation is usually well tolerated and no specific treatment is recommended. The decision to explore the IAN surgically must be weighed against the risks of additional nerve injury from the surgical exposure (or malocclusion if the approach is an SSRO approach). If allodynia or dysesthesia is the predominate symptom, then consultation with a neurologist is indicated for pharmacologic management. Again, younger patients are typically better able to tolerate nerve injuries than older patients, and, in the majority of cases, no specific treatment is recommended.

8.8 Summary

From what has been described in this chapter, it is clear that it would be of great academic value if the maxillofacial surgery community in cooperation with neurology counterparts could agree

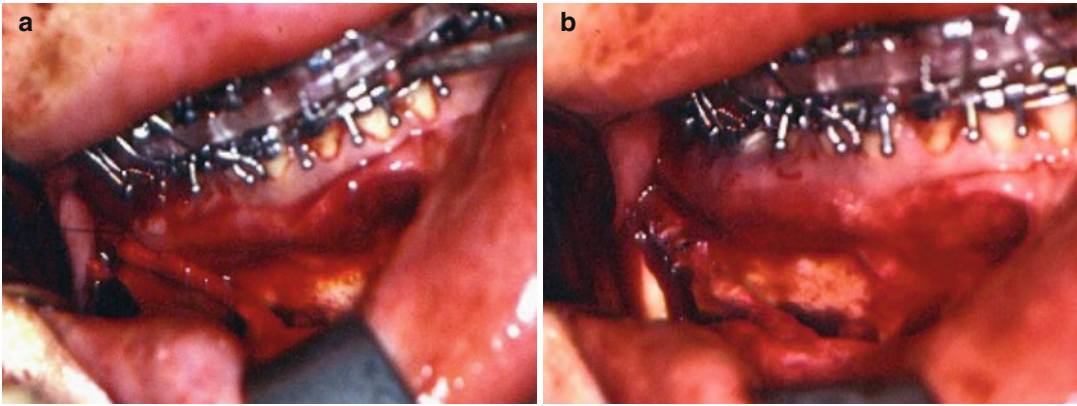


Fig. 8.7 (a) Intraoperative view of right IAN transection during SSRO mandibular advancement. Note epineurial suture placed through proximal and distal nerve stump.

(b) Decortication of the lateral mandible to the mental foramen in order to mobilize the IAN for direct repair using epineurial sutures (Courtesy of Michael Miloro)

upon a universal method to measure and evaluate somatosensory function, although from a clinical point of view it is the patient's subjective perception of sensation that is most important and should guide treatment recommendations. There are patients who do not care a great deal about NSD even when we measure severe sensitivity loss objectively and others in whom we can hardly detect a sensory loss objectively, but for whom the subjective experience can be very disturbing. Here, as in many other areas of maxillofacial surgery, preoperative information, preoperative evaluation, and patient selection are key factors to what we call treatment success. In general, patients are willing to tolerate mild NSD in order to correct a dentoskeletal discrepancy with improvement in esthetics and function. As mentioned, the younger the patient, the better they will tolerate the NSD and the better the NSD will recover quicker and to a higher level spontaneously than in the older patient. But for all patients, it is helpful to remember that, generally, the significance of the NSD decreases as the time from SSRO increases, indicating that recovery occurs in most patients almost fully, or at least their perception of the NSD improves with time.

We have come a long way from the days when discussions about SSRO did not even include considerations about neurosensory

disturbances, but still, we must remember one of the rules of all surgeons is "primum non nocere" (first, do no harm).

References

1. Aizenbud D, Ciceu C, Hazan-Molina H, Abu-El-Naj I (2012) Relationship between inferior alveolar nerve imaging and neurosensory impairment following bilateral sagittal split osteotomy in skeletal class III cases with mandibular prognathism. *Int J Oral Maxillofac Surg* 41:461–468
2. Al-Bishri A (2004) On neurosensory disturbance after sagittal split osteotomy. *J Oral Maxillofac Surg* 62:1472–1476
3. Al-Din OF, Coghlan KM, Magennis P (1996) Sensory nerve disturbance following Le Fort I osteotomy. *Int J Oral Maxillofac Surg* 25:13–19
4. Baas EM, Horsthuis RBG, de Lange J (2012) Subjective alveolar nerve function after bilateral sagittal split osteotomy or distraction osteogenesis of mandible. *J Oral Maxillofac Surg* 70:910–918
5. Doucet JC, Morrison AD, Davis BR, Gregoire CE, Goodday R, Precious DS (2012) The presence of mandibular third molars during sagittal split osteotomies does not increase the risk of complications. *J Oral Maxillofac Surg* 70(8):1935–1943
6. Hallikainen H (1992) Cross-sectional tomography in evaluation of patients undergoing sagittal split osteotomy. *J Oral Maxillofac Surg* 50:1269–1273
7. Hoenig JF (2007) Sliding osteotomy genioplasty for facial aesthetic balance: 10 years of experience. *Aesthetic Plast Surg* 31:384–391
8. Jones DL, Wolford LM, Hartog JM (1990) Comparisons to assess neurosensory alterations

- following orthognathic surgery. *Int J Adult Orthodon Orthognath Surg* 5:35–42
9. Lindqvist CC, Obeid G (1988) Complications of genioplasty done alone or in combination with sagittal split ramus osteotomy. *Oral Surg Oral Med Oral Pathol* 66:13–16
 10. Miloro M, Repasky M (2000) Low level laser effect on neurosensory recovery following sagittal ramus osteotomy. *Oral Surg Oral Med Oral Pathol* 89:12–18
 11. Nardi P, Guarducci M, Cervinio M (2002) Orthognathic surgery. Study of nerve injuries. *Minerva Stomatol* 51:461–471
 12. Nesari N (2005) Neurosensory function of the inferior alveolar nerve after bilateral sagittal split osteotomy. *Int J Oral Maxillofac Surg* 34:495–499
 13. Obwegeser H (1964) The indications for surgical correction of mandibular deformity by the sagittal splitting technique. *Br J Oral Maxillofac Surg* 7:157–171
 14. Posnick JC, Al Qattan MM, Pron G (1994) Facial sensitivity in adolescents with and without clefts 1 year after undergoing Le Fort I osteotomy. *Plast Reconstr Surg* 94:431–435
 15. Posnick JC, Al-Qattan MM, Stepner NM (1996) Alteration in facial sensibility in adolescents following sagittal split and chin osteotomies of the mandible. *Plast Reconstr Surg* 97:920–927
 16. Rosenberg A, Sailer HF (1994) A prospective study on changes in the sensitivity of the oral mucosa and the mucosa of the upper lip after Le Fort I osteotomy. *J Craniomaxillofac Surg* 22:286–293
 17. Schultze-Mosgau S, Krems H, Ott R, Neukam FW (2001) A prospective electromyographic and computer-aided thermal sensitivity assessment of nerve lesions after sagittal split osteotomy and Le Fort I osteotomy. *J Oral Maxillofac Surg* 59:128–138
 18. Thygesen TH (2008) Somatosensory function after Le Fort I osteotomy xperimental and clinical studies. Thesis, Faculty of Health Sciences, University of Aarhus, Aarhus
 19. Triplett G (1996) Lingual nerve injury due to overpenetration of bicortical screws for sagittal split osteotomy. *J Oral Maxillofac Surg* 54:1451–1453
 20. Westermark A (1999) On inferior alveolar nerve function after sagittal split osteotomy of the mandible. Thesis, Karolinska Institute, Stockholm
 21. Westermark A, Bystedt H, von Konow L (1998) Inferior alveolar nerve function after mandibular osteotomies. *Br J Oral Maxillofac Surg* 36:425–428
 22. Westermark A, Bystedt H, von Konow L (1998) Inferior alveolar nerve function after sagittal split osteotomy of the mandible: correlation with degree of intraoperative nerve encounter and other variables in 496 operations. *Br J Oral Maxillofac Surg* 36:429–433
 23. Westermark A, Englesson L, Bongehiellm U (1999) Neurosensory function after sagittal split osteotomy of the mandible – a comparison between subjective evaluation and objective assessment. *Int J Adult Orthodon Orthognath Surg* 14:268–275
 24. Yoshioka I et al (2012) Comparison of material-related complications after bilateral sagittal split mandibular setback surgery: biodegradable versus titanium miniplates. *J Oral Maxillofac Surg* 70:919–924
 25. Zuniga J (1990) Lingual nerve injury as a complication of sagittal split osteotomy. *J Oral Maxillofac Surg* 48:647–648

Martin B. Steed

9.1 Introduction

Peripheral nerve injuries vary widely in extent and severity. In the peripheral trigeminal nerve, these injuries may result from extraction of teeth, placement of dental implants, benign and malignant tumor removal, maxillofacial trauma, endodontic procedures, orthognathic procedures, and even local anesthetic injections. Each form of insult results in various extent and type of nerve fiber injury with differing abilities for the nerve to regenerate spontaneously.

The consequences of peripheral trigeminal nerve injury to the patient are almost always detrimental and can influence the patient's ability to speak clearly, eat comfortably, taste foods, handle oral secretions, and perform everyday activities such as shaving or applying makeup. Many types of lingual and inferior alveolar nerve injuries require no surgical intervention, and the patient's sensation returns to normal over time. Other injuries show incomplete or no improvement with time. In order to compare these two types of clinical

scenarios, the surgeon must first understand the response of the peripheral nerve to injury. The fate of the axons and the surrounding architecture of the nerve components after injury are critical for forecasting possible neural regeneration and recovery.

The ability of the peripheral nerve to regenerate and reinnervate target organs has been recognized for more than a century. In reality, peripheral axonal regrowth is often delayed and seldom complete. Complete functional recovery from severe injuries is rarely achieved despite advances in microsurgical techniques and improved understanding of nerve regeneration at the cellular level. Functional recovery is particularly poor for injuries that sever the nerve far from the target and those that incur a considerable delay prior to target reinnervation [14]. In nerve transection (axotomy) cases where the distal stumps are denervated for a prolonged period of time, they become nonconductive to regeneration as a result of loss of supportive cell assistance.

After a peripheral nerve is injured, a complex and finely regulated sequence of events is initiated to remove the damaged tissue and begin the regenerative process. The healing of peripheral nerve injuries is unique within the body as the process is one of cellular repair rather than cell division or mitosis. The nerve cells at the site are not increasing in number after an injury but are attempting to restore the volume and continuity of the original neurons.

M.B. Steed, DDS
Division of Oral and Maxillofacial Surgery,
Department of Surgery,
Emory University School of Medicine,
1365 Clifton Road, Suite 2300 B,
Atlanta, GA 30322, USA
e-mail: msteed@emory.edu

9.2 Anatomy

An in-depth knowledge of peripheral nerve anatomy is beneficial to understand the series of events that take place after an injury. Peripheral nerves are made up of a *stroma* (the scaffold made of connective tissue elements) and a *parenchyma* (the nerve axons and Schwann cells). The components of the peripheral nerve therefore include a large amount of connective tissue, blood vessels, and the basic unit of the peripheral nerve – an axon and its associated Schwann cells. The nerve trunk represents a composite tissue constructed for the purpose of maintaining continuity, nutrition, and protection of these basic units, which require a continuous energy supply to allow for impulse conductivity and axonal transport.

9.2.1 Connective Tissue

The connective tissue subdivisions provide the framework around and within the nerve. The resulting architecture consists of an external and internal epineurium and a perineurium surrounding each fascicle, in which are contained multiple

axons surrounded by endoneurium (Fig. 9.1). A fourth subdivision includes a mesoneurium that consists of loose areolar tissue continuous with the epineurium and the surrounding tissue bed. The mesoneurium allows the nerve to move a certain distance longitudinally within the surrounding tissue.

The outer connective tissue layer of the nerve is the external epineurium, which is a supporting and protective connective tissue made up primarily of collagen and elastic fibers (Fig. 9.2). The internal epineurium is the structure that invests the fascicles, which contain the nerve fibers themselves. Usually several fascicles are grouped together in bundles, constituting well-defined subunits of the nerve trunk. Fascicles vary in their size and quantity depending primarily on whether the region in question is at the proximal or distal site of the nerve. Both the lingual and inferior alveolar nerves are polyfascicular. The lingual nerve contains 15–18 fascicles at the region adjacent the mandibular third molar, while the inferior alveolar nerve contains 18–21 fascicles within the angle of the mandible. There may be fewer fascicles contained in the lingual nerve in the third molar region.

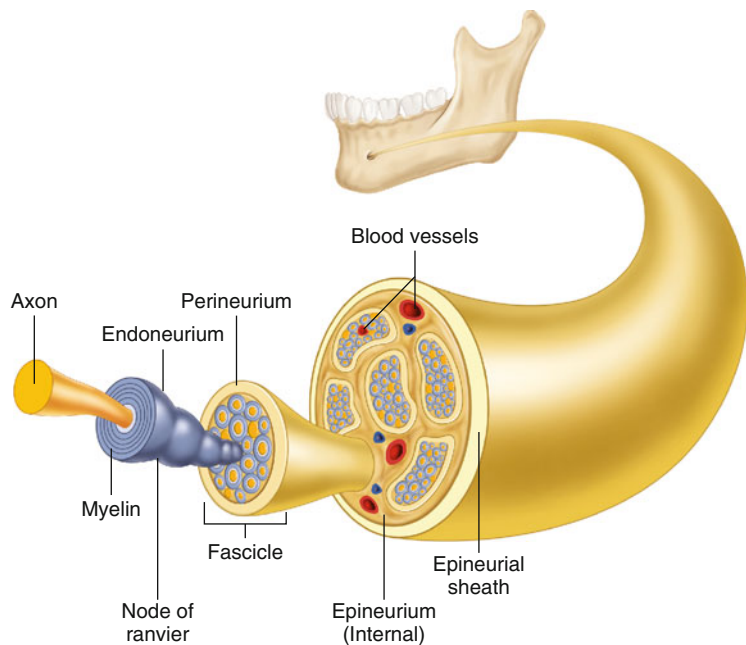


Fig. 9.1 Diagrammatic depiction of a cross-sectional view of the peripheral trigeminal nerve internal anatomy (From Steed [34]; with permission)

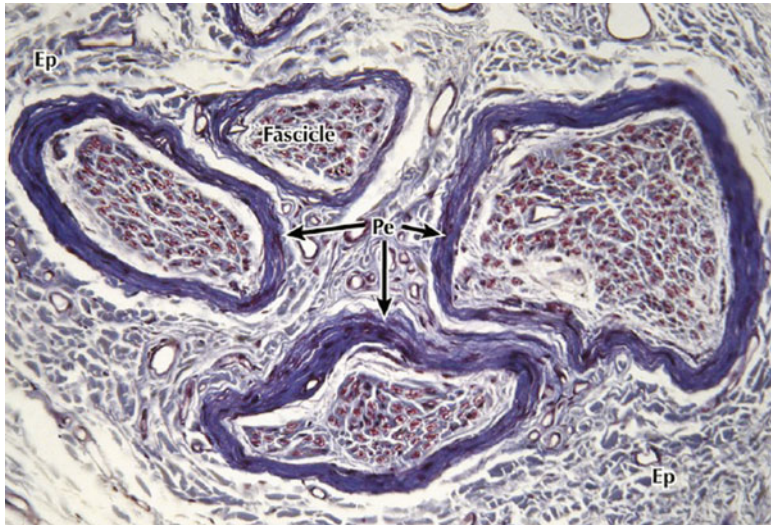
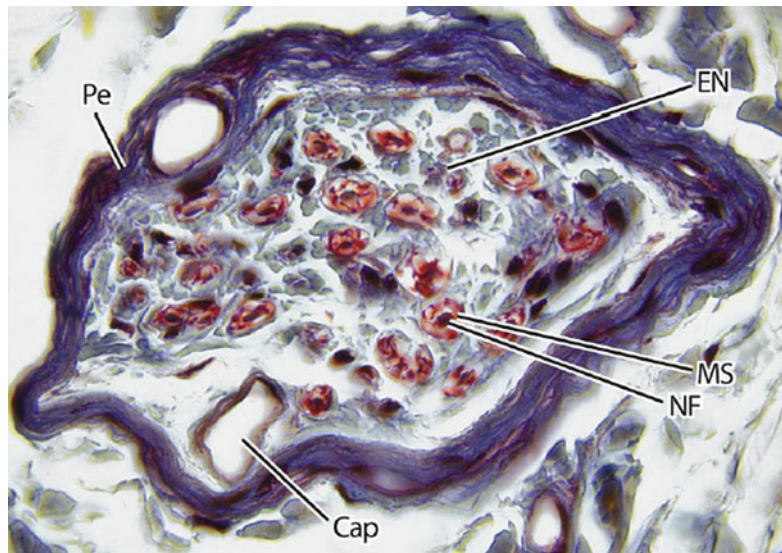


Fig. 9.2 Light micrograph of a peripheral nerve in transverse section. Several fascicles that make up this nerve are enveloped by the connective tissue of the epineurium (*Ep*) that merges imperceptibly with the surrounding loose connective tissue – the mesoneurium. A more deeply stained

perineurium (*Pe*) encloses the fascicles. Each fascicle consists of a large number of nerve fibers that are embedded in a more delicate endoneurium (not well defined at this level of magnification), 200 \times , *Masson trichrome* (From Steed [34]; with permission)

Fig. 9.3 Light micrograph of a nerve fascicle at higher magnification. Here, the perineurium (*Pe*) is dark blue and the endoneurium (*EN*) light blue. Nerve fibers (*NF*) are densely stained structures surrounded by a myelin sheath (*MS*), which is red. A capillary (*Cap*) is shown. 465 \times , *Masson trichrome* (From Steed [34]; with permission)



Each fascicle is surrounded by a perineurium, a lamellated sheath with considerable tensile mechanical strength and elasticity (Fig. 9.3). The perineurium is made up of collagen fibers dispersed among perineurial cells and acts as a diffusion barrier as a result of its selective permeability, maintaining the endoneurial space within it from

the surrounding tissues. This preserves the ionic environment within the fascicle. The nerve fibers themselves are closely packed together within endoneurial connective tissue (endoneurium) inside of each fascicle (Figs. 9.4 and 9.5). The endoneurium is composed of a loose gelatinous collagen matrix.

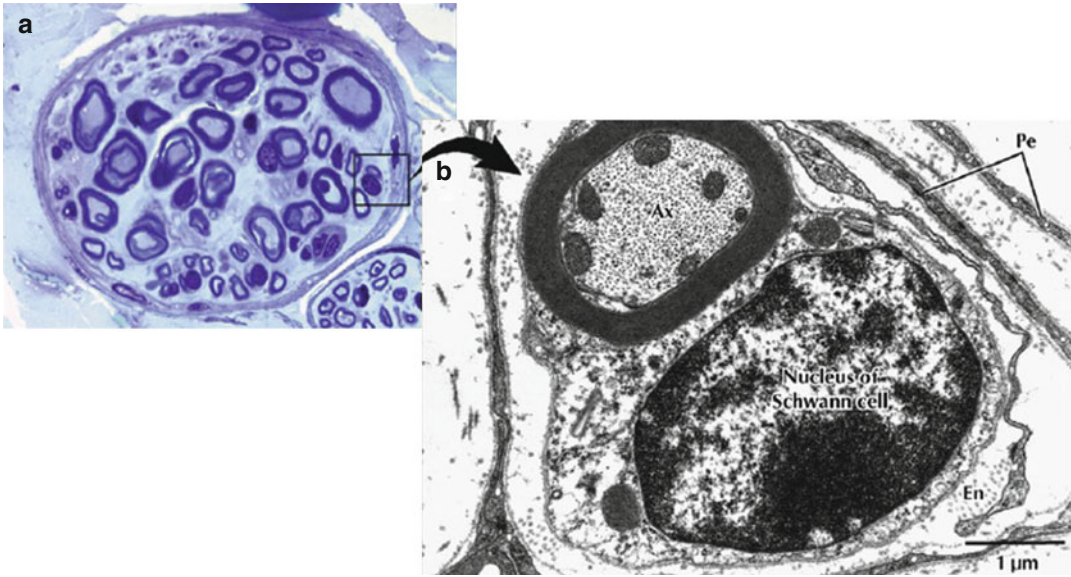


Fig. 9.4 Light micrograph of a peripheral nerve fascicle in transverse section. (a) Osmium fixation shows well-preserved myelin sheaths of nerve fibers. Nerve fibers vary in diameter and perineurium (*Pe*) surrounds the fascicle (*toluidine blue*, magnification $\times 600$; semithin plastic section). (b) Electron micrograph of a myelinated nerve fiber and its associated Schwann cell in transverse section.

The myelinated nerve fiber axoplasm (*Ax*) contains cytoskeletal elements and mitochondria that parallel its long axis. The Schwann cell, sectioned at the level of its nucleus, is enveloped by a basal lamina. Flattened perineurial cells (*Pe*) and collagen fibers of the endoneurium (*En*) are also seen (magnification $\times 16,800$) (From Steed [34]; with permission)

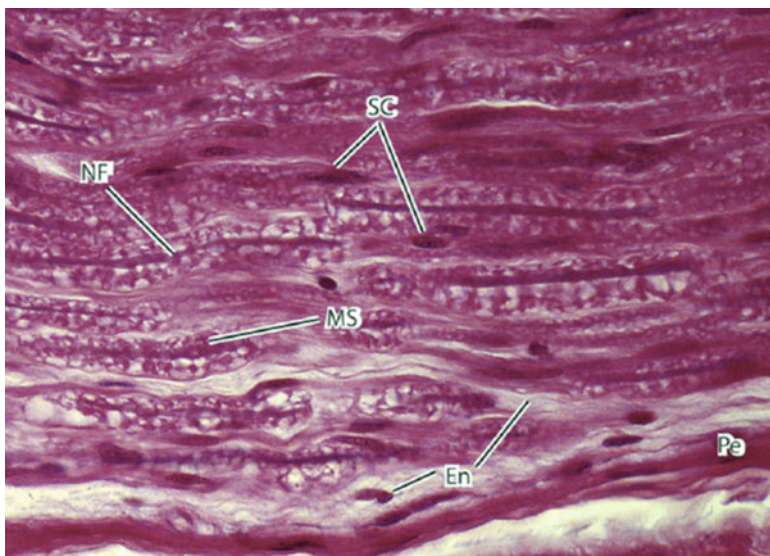


Fig. 9.5 Light micrograph of peripheral nerve in longitudinal section. Nerve fibers (*NFs*) – the slender deeply stained threads – pursue a wavy course. Myelin sheaths (*MSs*) appear vacuolated because of high lipid content and the effects of paraffin embedding on the tissue sample. Schwann cells (*SCs*) have elongated nuclei.

They are indistinguishable from nuclei of fibroblasts of the delicate endoneurium (*En*) that invests the individual nerve fibers. A deeply stained perineurium (*Pe*) surrounds the nerve fascicle externally. $700\times$. H&E (From Steed [34]; with permission)

9.2.2 Blood Supply

Each neuron's axon requires a continuous energy supply for impulse transmission and axonal transport. This is provided by an extrinsic vascular system and an intrinsic vascular system, which are interconnected. The extrinsic vessels enter

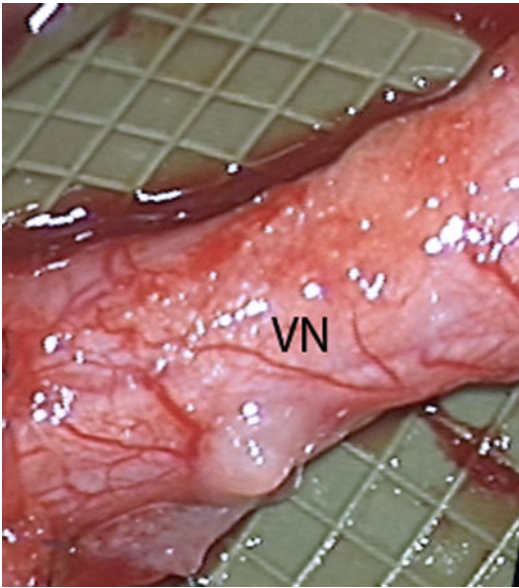


Fig. 9.6 Clinical photo of a lingual nerve under microscopic magnification demonstrating the vasa nervorum (VN). Large longitudinally oriented intrinsic epineurial arteriolar and venular vessels can be seen deep to this plexus (From Steed [34]; with permission)

the mesoneurium and communicate with the epineurial space via the vasa nervorum. A plexus develops at this level and runs longitudinally (Fig. 9.6). If the fascicles are examined closely, a large number of epineurial vascular branching is seen, supplying each fascicle in a segmental manner, so that each fascicle is vascularly analogous to a complete axon in a miniature model.

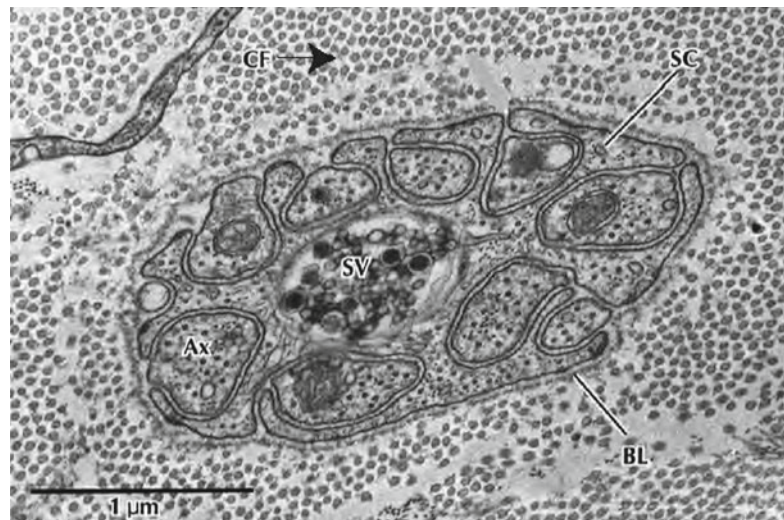
The vascular plexus enters the endoneurium through the perineurium at an oblique angle to anastomose with the intrinsic circulation that surrounds each fascicle. The oblique passage of vessels through the inner perineurial membrane is a site of potential circulatory compromise within the intrafascicular tissue.

9.2.3 Nerve Fibers

A neuron consists of a nerve cell body and its processes. There are a number of dendrites associated with the cell body and one long extension – an axon, which travels to an end organ with branches terminating in peripheral synaptic terminals. Nerve fibers can be either myelinated or unmyelinated. Sensory and motor nerves contain *both types* of fibers in a ratio of 4 unmyelinated axons to 1 myelinated axon.

Unmyelinated fibers are made up of *several* axons enclosed by a single Schwann cell (Fig. 9.7). Unmyelinated axons are small in diameter, usually

Fig. 9.7 Electron micrograph of a Schwann cell associated with several unmyelinated nerve fibers in transverse section. Nerve fibers (Ax) occupy channel-like invaginations of Schwann cell cytoplasm (SC). Most nerve fibers contain neurofibrils and microtubules; synaptic vesicles (SV); collagen fibrils (CF); basal lamina (BL) (From Steed [34]; with permission)




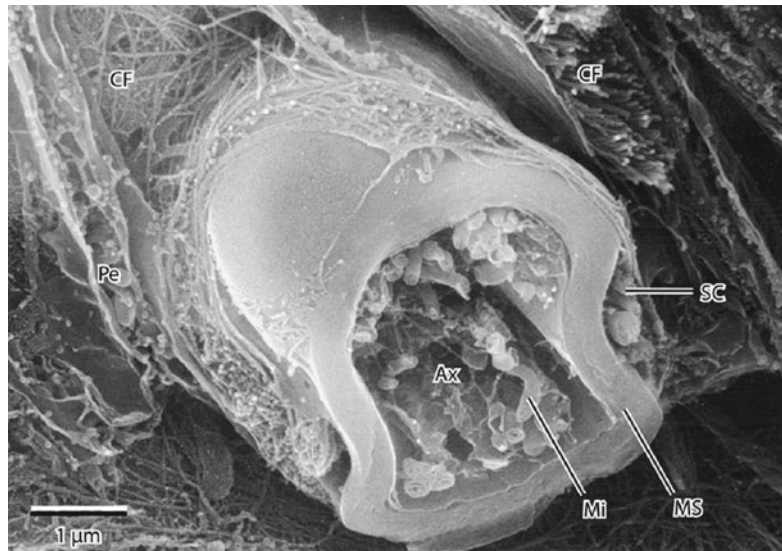


Fig. 9.8 Electron micrograph of a myelinated peripheral nerve fiber in transverse section. The axon is surrounded by a myelin sheath (MS) composed of multiple lamellae formed by the plasma membrane of a Schwann cell. A thin rim of Schwann cell cytoplasm (SC) envelops the myelin and is invested externally by a thin basal lamina

(BL). Collagen fibers (CFs) of the endoneurium and flattened perineurial cells (Pe) are in the surrounding area. The nerve axoplasm contains mitochondria (Mi), neurofilaments, and a few microtubules. 30,000 \times (From Steed [34]; with permission)

Fig. 9.9 High-resolution scanning electron micrograph of a myelinated peripheral nerve fiber fractured in the transverse plane. The axon, fractured open, reveals mitochondria (Mi) and cytoskeletal elements in the axoplasm (Ax). A peripheral rim of Schwann cell cytoplasm (SC) is outside the myelin sheath (MS). Collagen fibrils (CFs) of the surrounding endoneurium are shown well. A flattened perineurial cell (Pe) is also fractured open. 15,000 \times (From Steed [34]; with permission)



averaging 0.15–2.0 μm . The axons of a myelinated fiber are *individually* wrapped by a single Schwann cell that has laid down a laminar myelin sheath (Fig. 9.8). The center of a myelinated fiber is made up of cytoplasm (axoplasm) with associated cytoskeletal elements surrounded by a membrane

(axolemma). A concentric sheath of myelin and a Schwann cell surround this membrane (Fig. 9.9). A thin basal lamina invests the interdigitating processes of Schwann cells. At the junction between two Schwann cells, the axolemma becomes exposed at a gap called a node of Ranvier

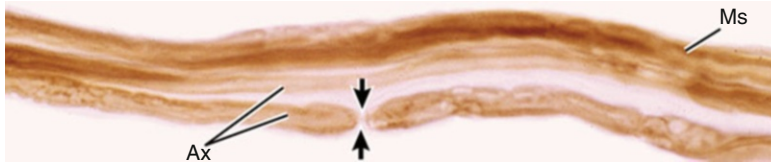


Fig. 9.10 Light micrograph of teased myelinated nerve fibers demonstrating a node of Ranvier. The axon (Ax) is the central pale region in each fiber. Myelin sheaths (Ms),

visible when fixed and stained with osmium, appear as dark linear densities. A node of Ranvier (arrows) is indicated. 500 \times . Osmium (From Steed [34]; with permission)

(Fig. 9.10). The propagation of an action potential along the axon “jumps” from node to node over the insulated areas covered with myelin in the process of saltatory conduction. This provides for more rapid propagation along the axon. As a result, myelinated fibers are able to conduct an impulse at a speed up to 150 m/s, while unmyelinated fibers propagate impulses at speeds of 2–2.5 m/s.

The cell bodies of the peripheral trigeminal nerve, including the lingual and inferior alveolar nerve, are contained within the trigeminal ganglion (also called the semilunar ganglion). The trigeminal ganglion is analogous to the dorsal root ganglia of the spinal cord, which contain the cell bodies of incoming sensory fibers from the rest of the body. These nerve cells may have axons that extend over a distance corresponding to thousands of cell body diameters. This imposes special requirements on the communication systems between the proximal and distal regions of the cell. To meet these requirements the neuron has unique systems of *anterograde* as well as *retrograde* intracellular transport. These transport mechanisms are involved in the response to an injury.

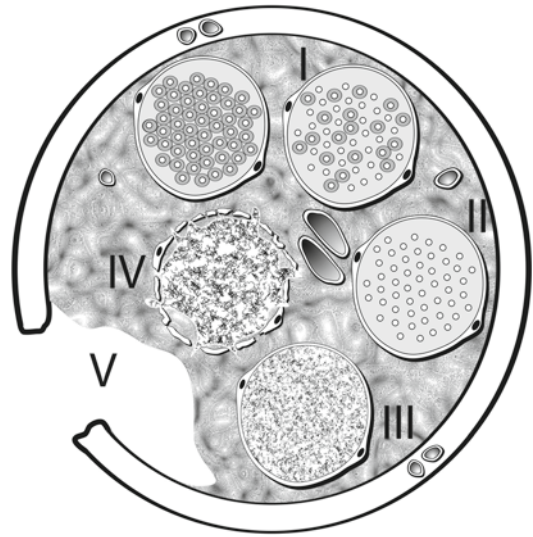


Fig. 9.11 Diagrammatic representation of Sunderland classification of distal segment nerve injury in transverse plane. A normal, uninjured fascicle with myelinated axons is represented at the *top left*. Proceeding clockwise, fascicle number *I* represents a first-degree injury with demyelination of some axons. Fascicle number *II* depicts a second-degree injury with more extensive demyelination without injury to the endoneurium. Fascicle number *III* is involved in a third-degree injury, now with disruption of the endoneurium around each axon. Fascicle number *IV* shows a fourth-degree injury with damage extending through the perineurium. Transection injury to all of the nerve components and supporting elements is reflected by the number *V* representing a fifth degree injury (Courtesy of Don Johnson, Atlanta VA Medical Center)

9.3 Basic Injury Types

Clinically useful injury grading systems have been developed that allow reflection of patient symptomatology after nerve injury and with the histological changes occurring to the nerve. Histological parameters are the far most used predictors of peripheral nerve damage and regeneration. In 1941, Cohen introduced a classification scheme to describe the injury to peripheral nerves: neuropraxia, axonotmesis, and neurotmesis [30]. In the early 1940s, Seddon

[33] examined 650 patients with peripheral injuries and popularized Cohen’s time and degree of recovery-based classification system. In 1951, Sunderland [36] expanded upon this classification system by defining five distinct degrees of nerve injury based on histological changes within the nerve [30] (Figs. 9.11 and 9.12). Within this classification scheme, first-degree injuries are

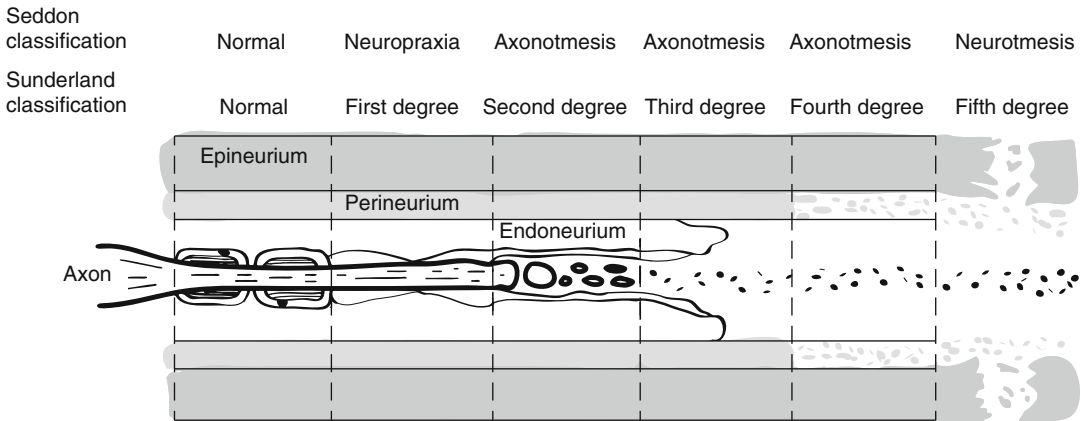


Fig. 9.12 Schematic representation of Sunderland classification of nerve injury in longitudinal plane. Sunderland classification scheme is shown in longitudinal

section demonstrating the “inside-out” histological progression of injury with a fifth-degree injury representing a neurotmesis defined as complete nerve transection

representative of a neuropraxia, while axonotmesis is divided into second-, third-, and fourth-degree injuries. Fifth-degree injuries represent a neurotmesis. In 1989, Mackinnon coined the term “Sixth-degree injury” which was defined as a mixed injury involving different combinations of the above [29].

9.3.1 First-Degree Injury, Neuropraxia

A first-degree peripheral nerve injury (neuropraxia) clinically shows recovery within the first 3 months. It represents a conduction block with good chances for complete recovery from within days to 3 months. Pathologic changes are mild (demyelination) or absent in first-degree injuries [4]. An example would be a mild nerve *stretch* injury to the lingual nerve from retraction of a lingual flap during a surgical extraction of a third molar tooth.

9.3.2 Second-Degree Injury, Axonotmesis

In second-degree injury the endoneurium and perineurium remain intact. In second-degree injuries there is little histological change at the injury site or proximal to it; however, distal to

the site of injury, a calcium-mediated process known as Wallerian degeneration occurs [2]. The general arrangement of the axonal sheaths and the remaining structures comprising the nerve are preserved [30]. The prospect of recovery is possible in such injuries because of the remaining uninjured mesenchymal latticework that provides a path for subsequent sprouting axons to reinnervate their target organ. Nerve recovery should be complete but progresses slowly at approximately 1 cm/day or 1 in./month.

9.3.3 Third-Degree Injury, Axonotmesis

The third-degree injury pattern involves endoneurium scarring and disorganization with the fascicles. Damage extends to the perineurium. The endoneurial tube (or sheath) is disrupted, resulting in misalignment of any regenerating axonal fibers. Regeneration from the proximal nerve takes place through scar tissue in the endoneurium, thereby limiting the regenerating axons ability to make contact with distal sites [30]. The rate of recovery progresses as expected for an axonotmesis (1 in./month), but the degree of return will not be complete.

9.3.4 Fourth-Degree Injury, Axonotmesis

A fourth-degree injury is in which the nerve is physically in continuity, but only the epineurium remains intact. Damage extends through the perineurium and regeneration attempts are blocked by scar tissue. After Wallerian degeneration takes place, the axonal continuity may eventually be interrupted, resulting in degeneration of the distal axonal segment and complete denervation. If recovery is to occur, then surgical intervention is necessary. These injuries are typically the result of severe stretch, traction, crush, or cautery injuries, or nerve injection injuries [30].

9.3.5 Fifth-Degree Injury, Neurotmesis

A fifth-degree injury results from the complete transection of a nerve trunk and loss of all supporting elements. Although these injuries can result from severe stretch that leads to avulsion, they are more often associated with sharp or penetrating trauma. Recovery is not possible without a surgical repair, although inferior alveolar nerve transection during third molar removal with replacement of the proximal and distal nerve stumps into the inferior alveolar canal may have a reasonable prognosis for spontaneous recovery without subsequent nerve repair. However, in most fifth-degree injuries, functional loss is complete and spontaneous recovery is unlikely.

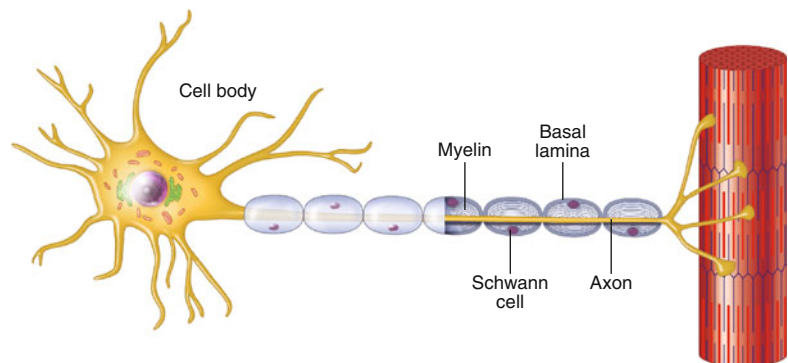
9.3.6 Sixth-Degree Injury, Neuroma in Continuity

Mackinnon used the term “Sixth-degree injury, neuroma in continuity” in 1989, to describe a mixed nerve injury [29]. She illustrated how the pattern of recovery of the whole nerve is mixed to a varying degree by fascicle (I, II, III, IV, and V) [30]. Complete recovery takes place in fascicles that have sustained a first- or second-degree injury. Partial recovery is seen in fascicles that have a third-degree injury, while no recovery is seen in fourth- or fifth-degree injury patterns.

9.4 Overview of Response to Injury

The healing of peripheral nerve injuries is quite unique within the body as it is a process of *cellular* repair rather than *tissue* repair. In other words, the nerve cells themselves do not undergo mitoses. The number of nerve cells (neurons) does not increase, but the amputated nerve cell regains its original axoplasmic volume by sending out new processes to the end organ target. Peripheral nerves do have this capacity to regrow, but functional recovery in humans is often incomplete [15]. This is because the neuron and surrounding cells cannot maintain an effective growth promoting response for long periods of time. Peripheral nerves are some of the longest and most spatially complex cells in the body. A normal, uninjured nerve is represented in Fig. 9.13. Their length makes them unable to function without the structural and metabolic support provided

Fig. 9.13 A normal myelinated axon. A schematic representation of a normal myelinated axon associated with a longitudinal chain of Schwann cells and enclosed within a continuous basal lamina (From Steed [34]; with permission)



by approximately ten times as many glial support cells [20]. A nerve injury that takes place centimeters from a neuronal cell body induces a response that involves the entire cell and its associated glial support cells. Although the number of neurons does not increase in number, the repair of each cell takes place in an environment of intense cellular proliferation. The cells that do show evidence of proliferation include Schwann cells, endothelial cells, and fibroblasts.

Peripheral nerve response to injury has been shown to be a complex yet finely regulated sequence of events. These are aimed at removing the damaged tissue and beginning the reparative process. First, the neuron itself must survive the injury and mount an effective metabolic response to initiate regeneration [14]. Second, the growth environment in the nerve stump distal to the injury must provide sufficient support for regenerating axons. Third, the successfully regenerated axon must reinnervate the proper target and the target must retain the ability to accept reinnervation and recover from denervation atrophy. These response events take place at the cell body of the neuron, distal and proximal portions of the axon, and at the site of injury.

9.4.1 Proximal Nerve Segment Response

The first prerequisite for axonal regeneration is survival of the neuron following the injury. Survival depends upon several factors, including neuron type, age, and the degree of proximity of the injury to the cell body [14]. Certain types of neurons appear to be more susceptible to injury, such as cutaneous afferent neurons [22], and spinal motoneurons are less susceptible to injury-induced cell death than cranial sensory neurons such as the peripheral trigeminal nerve. Perhaps counterintuitively, mature neurons in the adult are less susceptible than immature neurons in the young animal. Proximal injuries produce more marked neuronal loss than distal injuries [42], and neurons subjected to injury far from their cell bodies are less susceptible than those that occur close to cell bodies. Numbers quoted in the literature vary according to

the experimental animal model used, but can be substantial as 30–40 % of the small-diameter sensory neurons which contribute to a dorsal root ganglion die after nerve transection.

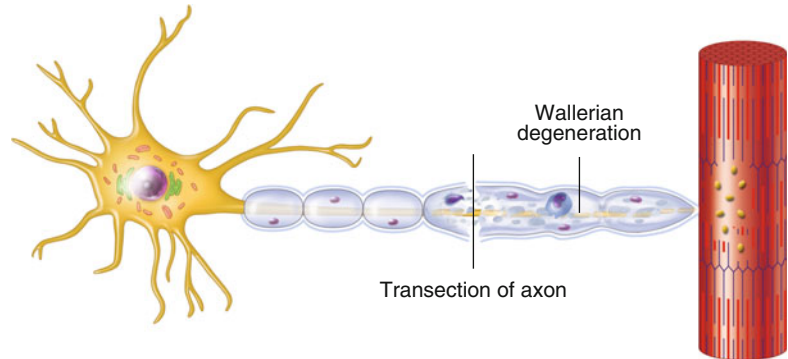
The mechanisms of injury-induced neuronal death are not yet fully understood, but it is clear that axotomized neurons die by apoptosis [26]. The neuron displays characteristic morphological changes associated with apoptosis and undergoes DNA fragmentation. This is primarily as a result of loss of target-derived neurotrophic support (neurotrophic factors) [14]. Neurotrophic factors are released by target tissues and by glial cells, fibroblasts, and macrophages in the local environment of both the neurons cell body and axon.

Changes in the neuronal cell body and in nerve fibers proximal to the site of injury depend both upon the severity of the injury and the proximity of the injury to the cell body. The nerve cell body itself reacts to axonal injury in a relatively predictable fashion. The series of morphologic changes that ensue in the cell body after injury are known as *chromatolysis*, and they entail cell body and nucleolar swelling as well as nuclear eccentricity [17]. Within 6 h of injury, the nucleus migrates to the periphery of the cell body, and Nissl granules (rough endoplasmic reticulum) break up and disperse, reflecting an increased mRNA synthesis and enhanced protein synthesis.

These changes involve a switch in the cell “machinery” from being primarily concerned with transmitting nerve impulses to fabricating structural components for regeneration and reflect an altered gene expression associated with preparedness for axonal outgrowth and regeneration. The neurons convert from “transmitting mode” to “growth mode.” More important than the morphological changes are the series of alterations involving a downregulation of molecules such as neurofilaments and neuropeptides with upregulation of regeneration-associated genes (RAGs) [41].

The protein synthesis switches from producing neurotransmitter related substances to those required for axonal reconstruction [31, 38]. Examples of these substances include actin and tubulin. Evidence of upregulation of tubulin and

Fig. 9.14 Transection injury such as could occur with a scalpel or straight fissure bur and accompanying axonal degeneration – resulting in dissolution of distal myelin sheaths, degeneration of axoplasm distally, and sealing of the tip of the proximal stump of the axon (From Steed [34]; with permission)



actin mRNA and downregulation of neurofilament proteins after axotomy [39] strongly suggests that regenerating axons recapitulate developing axons in transporting increased supplies of actin and tubulin to the injury site for axonal growth [17, 21]. Downregulation of neurofilament proteins has been suggested to increase the fluidity of the axoplasm and thereby facilitate axonal transport of the tubulin and actin [23, 39]. Simultaneously there is a significant proliferative response of perineurial glial (support) cells, most likely signaled by the process of chromatolysis.

9.4.2 Injury Site Response

Within hours of physical interruption, the ends of the axon are sealed. Anterograde axoplasmic transport continues within the proximal stump, and retrograde axonal transport continues for several days. As a consequence the ends of the sealed axons swell as they fill with organelles that are unable to progress beyond the site of the discontinuity forming end bulbs [20]. There is evidence that accumulation and release of molecules from axonal end bulbs influence several aspects of the local environment [43]. End bulbs accumulate potent vasoactive peptides such as calcitonin gene-related peptide (CGRP) and the enzyme nitric oxide synthase (NOS) that generates gradients of nitric oxide (NO). Both CGRP and NO mediate the striking rises in local blood flow that develop early at the sites of injury, perhaps synergistically [44]. End bulbs accumulate sodium channels thought to

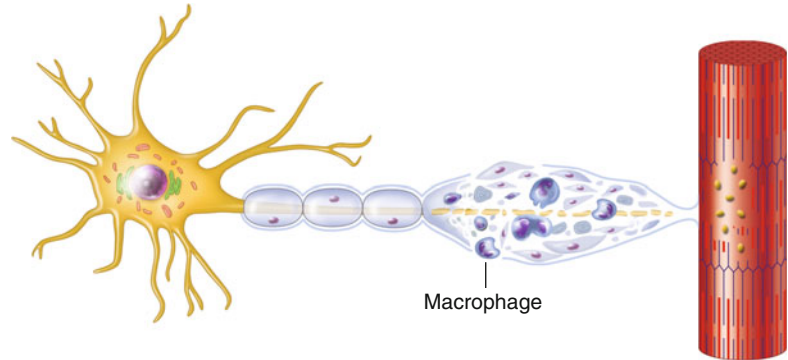
contribute to ectopic discharges that generate neuropathic pain [11].

A subsequent series of proliferative events involving the proximal nerve trunk at the site of injury takes place at day 3 following the injury with combined endothelial cell, Schwann cell, mast cell, and connective tissue proliferation [9, 45, 46]. This coincides with axon sprouting and macrophage infiltration [27]. After transection, a single axon produces multiple axonal sprouts. New axonal sprouts can emerge directly from the end bulbs, but more often arise from their proximal junction with the axon or at nodes of Ranvier. At the tip of these sprouts, a growth cone exists that has an affinity for the fibronectin and laminin of the Schwann cell basal lamina. The growth cone explores the distal environment for an appropriate physical substrate.

9.4.3 Axonal Degeneration

In the distal nerve stump, a parallel series of changes develop after injury. Distal to the injury, a series of molecular and cellular events (some simultaneous while others are consecutive) that are collectively termed *Wallerian degeneration* (Fig. 9.14) are triggered throughout the *distal* nerve stump and within a small reactive zone at the tip of the proximal stump. In Wallerian (or anterograde) degeneration the primary histological change involves physical fragmentation of both axons and myelin. Ultrastructurally, both neurotubules and neurofilaments become disarrayed. Until

Fig. 9.15 The inflammatory response. The Schwann cell tube is invaded by macrophages, which breach the basal lamina. Schwann cells distal to the injury site proliferate and axon sprouts begin to emerge from the proximal stump (From Steed [34]; with permission)



recently, it was assumed that axons degenerated because they were no longer supported by their cell bodies. More recent studies have revealed that disconnected axons *destroy themselves* through a local caspase-independent process [12, 32] that leads to cytoskeletal disintegration.

The intrinsic degeneration of detached distal axons has been identified as the key event in Wallerian degeneration, triggering a cascade of nonneuronal cellular responses that leads to clearing of the inhibitory debris and production of an environment that supports axon regrowth in the months after the injury [15]. An initial and transient calcium signal within the axon is likely the sentinel development [43].

Axon degeneration does not occur immediately. Detached axon segments remain intact for days after peripheral nerve injury and can still transmit action potentials when stimulated [15, 28, 40]. The lag between injury and axonal degeneration is 24–48 h in murine models and several days for humans [8, 15, 18]. Eventually axons bead and swell before catastrophic granular disintegration of the cytoskeleton into fine debris is completed [16].

9.4.4 The Inflammatory Response in Wallerian Degeneration

Macrophages, T cells, and neutrophils infiltrate the site of an injury within 2 days. There are two populations of macrophages in an injured peripheral nerve, resident and recruited.

Resident endoneurial macrophages constitute approximately 4 % of the endoneurial cell population and respond extremely rapidly to injury. They are joined by recruited macrophages from the vascular supply attracted by locally produced chemokines. These macrophages penetrate the tubes of the Schwann cell, degrade the myelin sheaths, and phagocytose the axonal debris that has occurred (Fig. 9.15). Schwann cells themselves may participate in the breakdown of myelin if the numbers of macrophages are depleted. Although the endoneurium and basal lamina remain essentially intact, the neural tube eventually collapses as the myelin and axonal contents are digested. The process continues until the axons neural components are completely resorbed, at which time the neural tube becomes replaced by Schwann cells and macrophages.

9.4.5 Schwann Cells

Schwann cells, the ensheathing glial cells of the peripheral nervous system, are crucial for normal nerve function and for nerve repair (Gaudet et al. 2011). Schwann cells constitute 90 % of nucleated cells within peripheral nerves [3]. They provide nutritional support for developing, mature, and regenerating axons. Basal lamina produced by Schwann cells surrounds the cell and its associated axon(s), isolating units from their neighbors and from extracellular matrix. The functional relationship between Schwann cells and their axons is normally tightly regulated by

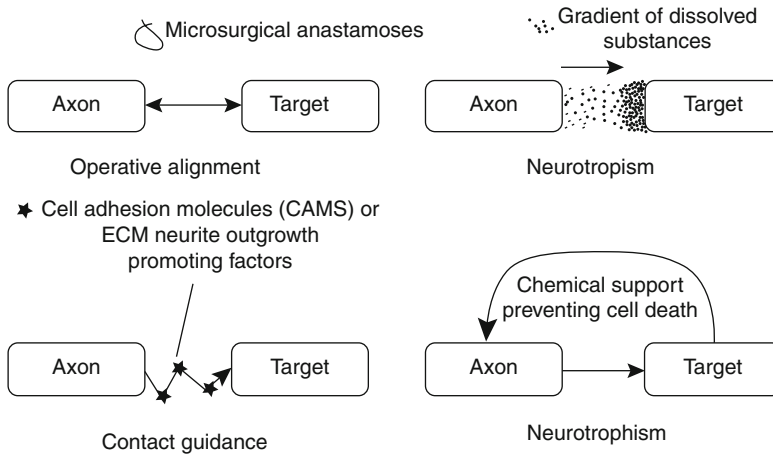


Fig. 9.16 Mechanisms of regenerative nerve guidance. With operative alignment, the axons are physically aligned with the target. In neurotropism, the growth cone follows a chemotactic gradient of neurotransmitters secreted by the distal segment. In neurotrophism, the axons follow

physical guideposts such as cell adhesion molecules (CAMs) or ECM neurite outgrowth promoting factors to reach their target. In neurotrophism, growth cones will reach a target and receive chemical support (preventing cell death) if it is the correct one

reciprocal signaling [20]. The manner in which Schwann cells respond to the loss of that relationship, whether as a result of demyelination or of axonal degeneration after crush or transection, is a critical component of the response to injury [20].

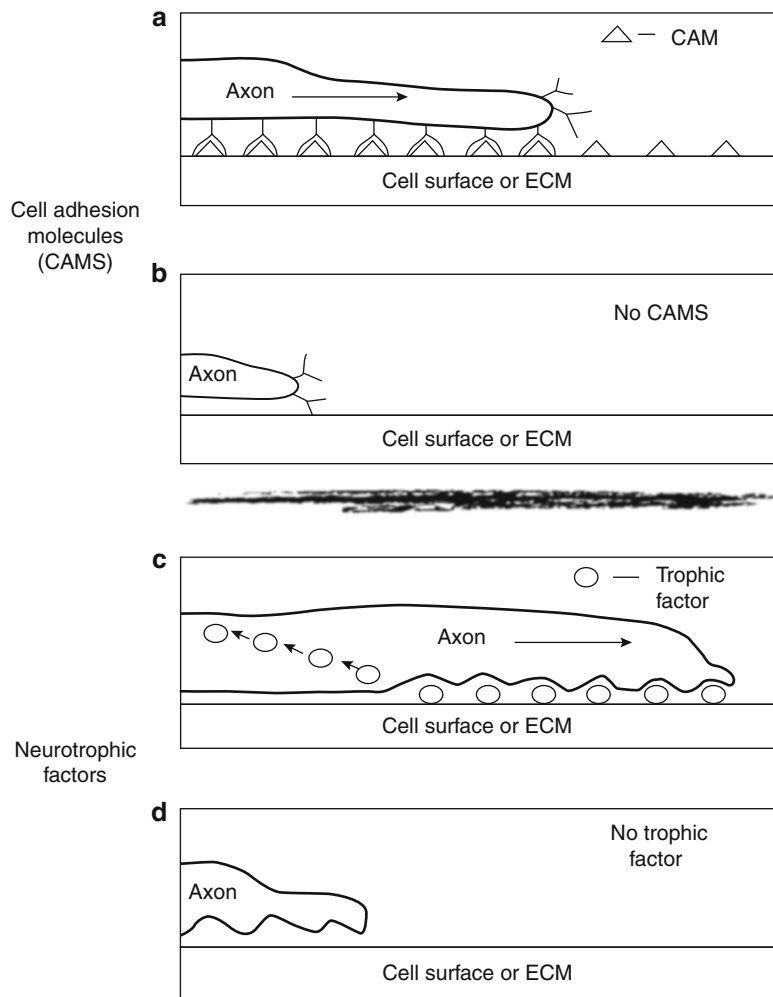
9.4.5.1 Proliferation and Support

Schwann cells in the distal stump undergo proliferation and phenotypical changes to prepare the local environment for favorable axonal regeneration. Schwann cells in the distal nerve begin to dedifferentiate soon after peripheral nerve injury, a process that is dependent on the ubiquitin–proteasome system [24]. Myelinating Schwann cells associated with detached axons respond by altering their gene expression. Within 48 h these cells stop producing myelin proteins, upregulate the synthesis of neurotrophic factors and their receptors, and begin to proliferate [20]. Proliferating Schwann cells organize themselves into columns (referred to as bands of Bungner or Schwann tubes), and the regenerating axons associate with them by growing distally between their basal membranes (Fig. 9.17). Schwann cells that are contacted by regenerating axons uncouple [6, 7], differentiate, and start to secrete myelin once again.

Schwann cells that have not been reinnervated may apoptose and disappear [37]. Cells that have been denervated for more than 6 months are morphologically and functionally different from their acutely denervated counterparts [20]. They show evidence of downregulating expression of receptors used in Schwann cell – axon signaling. Loss of these receptors may be the reason why denervated Schwann cells become progressively less able to support axonal regeneration. Interestingly, chronically denervated Schwann cells can be reactivated by treatment with TGF- β , a cytokine that is released by proliferating Schwann cells and macrophages. These reactivated Schwann cells can support axonal regeneration [35]. The weight of experimental evidence strongly suggests that there is a relatively narrow window of opportunity when transected neurons are in survival mode and denervated Schwann cells are axon responsive thus reinforcing the view that nerve repair should not be delayed when there is unequivocal evidence of the separation of nerve stumps [20].

The environment of the distal nerve directs nerve growth by means of contact attraction (contact guidance) and chemo-attraction (neurotropism) or supports nerve cell survival (neuro-

Fig. 9.17 Axon growth cone orientation, adhesiveness, and survival. **(a)** Axonal growth requires the presence of extracellular matrix proteins (present within the basement membrane produced by Schwann cells) and surface cell adhesion molecules (CAMs) (present on the Schwann cell surface). The presence of receptors (integrins) for these molecules or homophilic binding to the same molecules allows advancement of the axonal growth cone. **(b)** If these receptors or same molecules are not present, the advancement of the axonal growth cone will not occur. **(c)** Growth can only occur if neurotrophic factors are available in the growth terrain. The trophic factors are incorporated into the axon and transported to the cell body to support its survival. **(d)** If local neurotrophic factors are not present, growth will not occur and the axotomized neuron may not survive



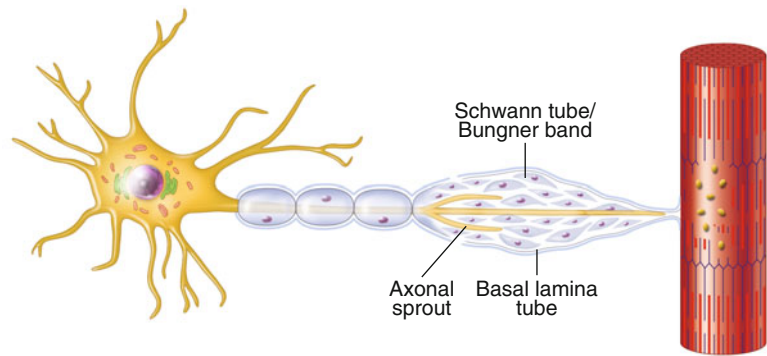
trophism) (Fig. 9.16). Each of these mechanisms involves Schwann cells. Schwann cells produce a large number of molecules that can potentially regulate axonal regeneration either directly or indirectly. The molecules can be roughly divided into three groups: cell adhesion molecules (CAMs), extracellular matrix proteins, and neurotrophic factors [14].

9.4.5.2 Cell Adhesion Molecules (CAMs) and Extracellular Matrix Proteins

Schwann cells play an indispensable role in promoting regeneration by increasing their synthesis of surface cell adhesion molecules (CAMs), such as N-CAM, L1, and N-cadherin. They also show enhanced expression of extracellular matrix

proteins such as laminin, collagen, fibronectin, and tenascin-C [14]. These molecules mediate adhesion between axon and axon, axon and Schwann cells, and axon and basal lamina and thereby regulate contact attraction axonal growth into the distal nerve stump (Fig. 9.17a). Adhesions between axons and between axons and Schwann cells are primarily mediated by homophilic binding of L1, N-CAM, and N-cadherin, although heterophilic binding of N-CAM to L1 and N-CAM or L1 to integrins (receptors) also occurs [14]. Adhesion between axons and the basal lamina is primarily accomplished by binding of extracellular matrix molecules, such as laminin and tenascin, to integrin receptors [10].

Fig. 9.18 Axonal regeneration. The proliferating Schwann cells form a tube (also known as the band of Bungner). Axon sprouts from the proximal end of the axon (From Steed [34]; with permission)



9.4.5.3 Neurotrophic Factors

Neurotrophic factors are a family of polypeptides required for survival of discrete neuronal populations [13]. The neurotrophin family includes NGF (nerve growth factor), BDNF (brain derived neurotrophic factor), NT-3 (neurotrophin 3), NT-4/5 (neurotrophin 4/5), FGFa (acidic fibroblast growth factor), PDGF (platelet derived growth factor), and GGF (glial growth factor), all of which may have autocrine and paracrine effects on neurons in addition to their effects on nonneuronal cells in the growth pathway [14]. The upregulation of neurotrophic factors in the distal nerve stumps of injured nerves and their subsequent return to normal levels after regeneration and target reinnervation have led to the natural association between these factors and regeneration [14]. Although a direct effect of these molecules on regeneration has been extensively looked for, there is increasing evidence that the neurotrophic molecules act directly to promote neuron survival and indirectly on regenerating axons via nonneuronal cells such as Schwann cells.

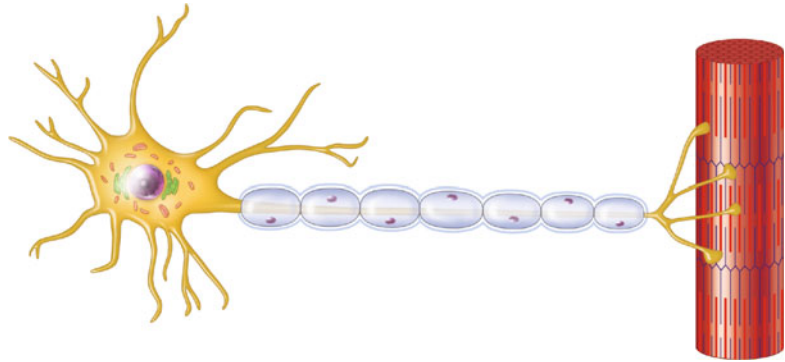
Different populations of neurons express receptors for different neurotrophins, indicating that each distinct neuronal population will respond differently to the mix of neurotrophins supplied by the Schwann cells and the target tissue [5].

9.4.6 Axonal Regeneration

The Schwann cell is therefore an intimate and essential partner to axons during early regenerative outgrowth. Three to four days after injury,

Schwann cells throughout the distal stump and at the tip of the proximal stump start to divide. Schwann cells migrate into injury sites. The proliferating Schwann cells then organize into columns and form the “bands of Bungner” which are arrays of Schwann cells within a space circumscribed by the basal lamina (“Schwann tube”) (Fig. 9.18). The spouts from the proximal stump of the axon grow towards the lesion site within the basal lamina tubes that enveloped their parent axons and enter the “bands of Bungner.” The advancement of regenerating axons into the distal segment is promoted by neurite outgrowth promoting factors such as laminin and fibronectin [1, 19, 25]. Although sprouting usually starts within several hours of injury, it may be several days before a cellular outgrowth emerges from the proximal stump, and at least 4 weeks before all regrowing axons have negotiated the interface between proximal and distal stumps, a process which has been termed “regeneration stagger” [20]. Since an excess number of sprouts invade the distal Schwann columns, the initial number of axons present in the distal nerve segment may considerably exceed the number in the same nerve proximal to the site of injury [17]. With successful elongation and in the case of minimal separation of the two ends of the damaged axon, there may be no axonal misrouting, and remyelination of the axon from the daughter Schwann cells will take place (Fig. 9.19). Regrettably, the presence of a nearby or attached distal stump does not ensure directionality of peripheral axons [43].

Fig. 9.19 Daughter Schwann cells and complete regeneration over a less than critical nerve gap. “Daughter” Schwann cells re-myelinate the regenerating axon. The new myelin sheaths are thinner and the intermodal distances are shorter than the axon’s more proximal counterparts (From Steed [34]; with permission)



9.4.7 Pathway Selection

If axons degenerate without rupture of the basal lamina that surrounds each Schwann tube (e.g., in an ischemic or compressive injury), the axon sprouts are less likely to be misrouted. This is not always the case; however, the prime example of failed directional growth or inability for the axons themselves to cross a gap is the “neuroma in continuity,” a partial nerve trunk injury in which the distal and proximal stumps remain connected, but fail to utilize this relationship [43]. The connective tissue bridge of the neuroma in continuity contains small numbers of axons or none at all. In traumatic injuries to the peripheral nerve resulting in complete disruption, the nerve ends become a swollen mass of disorganized Schwann cells, capillaries, fibroblasts, macrophages, and collagen fibers. Regenerating axons that reach the swollen bulb of the proximal stump encounter significant barriers to further regeneration. Most sprouts will remain in the endoneurium, but others may traverse into the epineurium through breaches in the damaged perineurium or may grow ectopically between the layers of the perineurium. In both situations their behavior may produce a painful neuroma (Fig. 9.20).

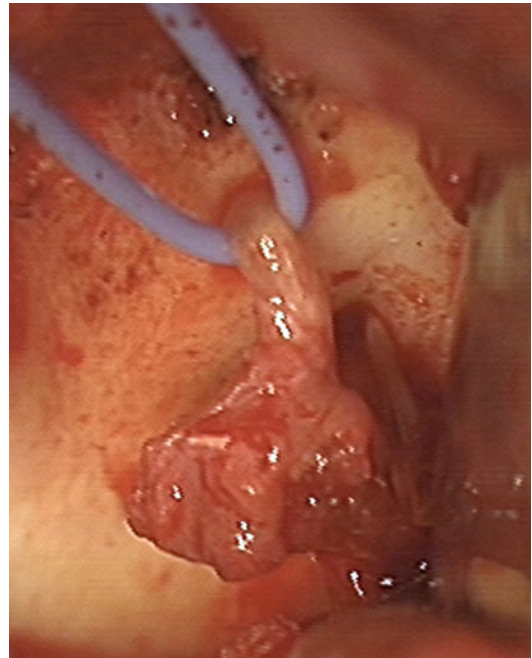


Fig. 9.20 Neuroma of the peripheral trigeminal nerve at its exit from the right mental foramen (From Steed [34]; with permission)

9.4.8 Roadblocks to Regenerative Outgrowth

The growth potential of regenerating axons has been suggested to be maximal 3 weeks after injury, based on temporal changes of the metabolic status of axotomized neurons [14].

Growth support provided by the distal nerve stump and the capacity of the axotomized neurons to regenerate axons may not be sustained indefinitely. Even if the neurons survive the injury, their capacity to regenerate may deteriorate with prolonged neurotrophic factor deprivation. As a result, axotomized axons that attempt to regenerate their axons after delayed nerve repair may fail. Even when regenerating axons gain access to the distal nerve stump after early microsurgical repair, they must regenerate

over long distances to reach their denervated targets at a rate of 1–3 mm/day.

In peripheral nerve repair, scar formation is a major clinical problem. Many axons fail to regenerate past the injury site because they become trapped in scar tissue after the repair even with primary neuroorrhaphy. In the injured human nerve, while the Schwann cell environment within the bands of Bungner is supportive of axonal growth, the fibrotic scar that forms at the site of repair represents a barrier to successful regeneration.

Examples of poor axon regeneration beyond that of a neuroma suggest a highly constrained regenerative capacity of peripheral neurons [43]. In the central nervous system (CNS), constrained regrowth is essential to the refinement of topographical circuitry. Molecular pathways to limit exuberant and inappropriate growth are needed in the CNS [43]. Similar persistent expression of growth restraining mechanisms within the peripheral system may limit regeneration when it is needed.

9.5 Summary

Surgeons caring for patients who have sustained a nerve injury to a branch of the peripheral trigeminal nerve must possess an understanding of the peripheral nerve's response to trauma. The series of events that subsequently take place are largely dependent upon the injury type and severity, but are consistent with the response of all other peripheral nerves throughout the body. Regeneration of the peripheral nerve is possible in many instances and future manipulation of the regenerative microenvironment will lead to advances in the management of these difficult injuries.

References

1. Baron-Van Evercooren A, Kleinman HK et al (1982) Nerve growth factor, laminin, and fibronectin promote neurite growth in human fetal sensory ganglia cultures. *J Neurosci Res* 8:179–183
2. Burnett MG, Zager EL (2004) Pathophysiology of peripheral nerve injury: a brief review. *Neurosurg Focus* 16:E1

3. Campana WM (2007) Schwann cells: activated peripheral glia and their role in neuropathic pain. *Brain Behav Immun* 21:522–527
4. Campbell WW (2008) Evaluation and management of peripheral nerve injury. *Clinical neurophysiology* 119:1951–1965.
5. Carlstedt T (2011) An overture to basic science aspects of nerve injuries. *J Hand Surg* 36E: 726–729
6. Chandross KJ (1998) Nerve injury and inflammatory cytokines modulate gap junctions in the peripheral nervous system. *Glia* 24:21–31
7. Chandross KJ, Kessler JA, Cohen RI et al (1996) Altered connexin expression after peripheral nerve injury. *Mol Cell Neurosci* 7:501–518
8. Chaudhry V, Comblath DR (1992) Wallerian degeneration in human nerves: serial electrophysiological studies. *Muscle Nerve* 15:687–693
9. Cheng C, Zochodne DW (2002) In vivo proliferation, migration, and phenotypic changes of Schwann cells in the presence of myelinated fibers. *Neuroscience* 115: 321–329
10. Daniloff JK, Levi G, Grumet M et al (1986) Altered expression of neuronal cell adhesion molecules induced by nerve injury and repair. *J Cell Biol* 103: 929–945
11. Devor M (1991) Neuropathic pain and the injured nerve: peripheral mechanisms. *Br Med Bull* 47: 619–630
12. Finn JT, Weil M et al (2000) Evidence that Wallerian degeneration and localized axon degeneration induced by local neurotrophin deprivation do not involve caspases. *J Neurosci* 20:1333–1341
13. Frostick SP, Kemp GJ (1998) Schwann cells, neurotrophic factors, and peripheral nerve regeneration. *Microsurgery* 18:397–405
14. Fu SY, Gordon T (1997) The cellular and molecular basis of peripheral nerve regeneration. *Mol Neurobiol* 14:67–116
15. Gaudet AD, Popovich PG, Ramer MS (2011) Wallerian degeneration: Gaining perspective in inflammatory events after peripheral nerve injury. *J Neuroinflamm* 8:110–123
16. George EB, Glass JD et al (1995) Axotomy-induced axonal degeneration is mediated by calcium influx through ion specific channels. *J Neurosci* 15: 6445–6452
17. Geuna S, Raimondo S, Ronchi G et al (2009) Histology of the peripheral nerve and changes occurring during nerve regeneration. In: Geuna S (ed) *International review of neurobiology-essays on peripheral nerve repair and regeneration*. Elsevier, New York
18. Gilliat RW, Hjorth RJ (1972) Nerve conduction during Wallerian degeneration in the baboon. *J Neurol Neurosurg Psychiatry* 35:335–341
19. Hall S (1997) Axonal regeneration through acellular muscle grafts. *J Anat* 190:57–71
20. Hall S (2005) The response to injury in the peripheral nervous system. *J Bone Joint Surg* 87 B: 1309–1319

21. Hoffman PN, Cleveland DW (1988) Neurofilament and tubulin recapitulates the developmental program during axonal regeneration: induction of a specific beta tubulin isotype. *Proc Natl Acad Sci USA* 85:4530–4533
22. Hu P, McLachlan EM (2003) Selective reactions of cutaneous and muscle afferent neurons to peripheral nerve transection in rats. *J Neurosci* 23:10559–10567
23. Kreutzberg GW (1995) Reaction of the neuronal cell body to axonal damage. In: Waxman SG (ed) *The axon: structure, function and pathophysiology*. Oxford University Press, New York/Oxford
24. Lee HK, Shin YK, Jung J et al (2007) Schwann cells: activated peripheral glia and their role in neuropathic pain. *Brain Behav Immun* 21:522–527
25. Liu HM (1996) Growth factors and extracellular matrix in peripheral nerve regeneration, studied with a nerve chamber. *J Peripher Nerv Syst* 1:97–110
26. Lo AC, Houenou LJ et al (1995) Apoptosis in the nervous system: morphological features, methods, pathology, and prevention. *Arch Histol Cytol* 58:139–149
27. Lu X, Richardson PM (1993) Responses of macrophages in rat dorsal root ganglia following peripheral nerve injury. *J Neurocytol* 22:334–341
28. Luttges MW, Kelly PT et al (1976) Degenerative changes in mouse sciatic nerves: electrophoretic and electrophysiologic characterizations. *Exp Neurol* 50:706–733
29. Mackinnon SE (1989) New directions in peripheral nerve surgery. *Ann Plast Surg* 22:257–273
30. Maggi SP, Lowe JB et al (2003) Pathophysiology of nerve injury. *Clin Plast Surg* 30:109–126
31. Muller HW, Stoll G (1998) Nerve injury and regeneration: basic insights and therapeutic interventions. *Curr Opin Neurol* 11:557–562
32. Raff MC, Whitmore AV et al (2002) Axonal self-destruction and neurodegeneration. *Science* 296:868–871
33. Seddon JJ (1943) Three types of nerve injury. *Brain* 66:237
34. Steed M (2011) Peripheral Trigeminal Nerve Injury, Repair, and Regeneration. In: Steed M (ed) *Atlas Oral Maxillofac Surg Clin North Am* 19:1–13. Elsevier/Saunders, Philadelphia
35. Sulaiman OA, Gordon T (2002) Transforming growth factor beta and forskolin attenuate the adverse effects of long term Schwann cell denervation on peripheral nerve regeneration in vivo. *Glia* 37:206–218
36. Sunderland S (1951) A classification of peripheral nerve injuries produced by loss of function. *Brain* 74:491
37. Syroid DE, Maycox PR, Burrola PG et al (1996) Cell death in the Schwann cell lineage and its regulation by neuregulin. *Proc Natl Acad Sci USA* 93:9229–9234
38. Terzis J, Smith K (1990) *The peripheral nerve. Structure, function, and reconstruction*. Raven Press, New York
39. Tetzlaff W, Bisby MA, Kreutzberg GW (1988) Changes in cytoskeletal protein in the rat facial nucleus following axotomy. *J Neurosci* 8:3181–3189
40. Tsao JW, George EB et al (1999) Temperature modulation reveals three distinct stages of Wallerian degeneration. *J Neurosci* 19:4718–4726
41. Verge VM, Gratto KA, Karchewski LA et al (1996) Neurotrophins and nerve injury in the adult. *Philos Trans R Soc Lond B Biol Sci* 351:423–430
42. Ygge J (1989) Neuronal loss in lumbar dorsal root ganglia after proximal compared to distal sciatic nerve resection: a quantitative study in the rat. *Brain Res* 478:193–195
43. Zochodne DW (2012) The challenges and beauty of peripheral nerve regrowth. *J Peripher Nerv Syst* 17:1–18
44. Zochodne DW, Levy D et al (1999) Evidence for nitric oxide and nitric oxide synthase activity in proximal stumps of transected nerves. *Neuroscience* 91:1515–1527
45. Zochodne DW, Nguyen C (1997) Angiogenesis at the site of neuroma formation in transected peripheral nerve. *J Anat* 191:23–30
46. Zochodne DW, Nguyen C et al (1994) Accumulation and degranulation of mast cells in experimental neuromas. *Neurosci Lett* 182:3–6

Roger A. Meyer and Shahrokh C. Bagheri

The foundation of proper treatment of any medical condition is establishment of an accurate diagnosis, and the diagnosis is based upon a thorough evaluation of the patient's condition. The patient with a peripheral trigeminal nerve injury

may present with a myriad of symptoms, often not conforming to a stereotypical pattern. Likewise, the responses to a neurological examination are varied and require interpretation based upon the knowledge and experience of the clinician. However, in this chapter, the evaluation of the nerve-injured patient is presented in a manner easily understood and completed by any competent practitioner, whether a specialist in nerve injuries or not. The obtainment of a proper history and completion of an essential neurosensory examination will lead to the establishment of a diagnosis regarding the extent of the sensory neurological deficit and the classification of the nerve injury. Such an undertaking will allow the clinician to consider appropriate and timely treatment, and it should be a rewarding, rather than a confounding, experience, if the clinician follows the information presented in this chapter on clinical evaluation of nerve injuries.

R.A. Meyer, DDS, MS, MD, FACS (✉)
Georgia Oral and Facial Surgery,
1880 West Oak Parkway, Suite 215,
Marietta, GA 30062, USA

Division of Oral and Maxillofacial Surgery,
Department of Surgery, Northside Hospital,
Atlanta, GA, USA

Department of Oral and Maxillofacial Surgery,
Georgia Health Sciences University,
Augusta, GA, USA

Maxillofacial Consultants, Ltd.,
1021 Holt's Ferry, Greensboro, GA 30642, USA
e-mail: rameyer@aol.com

S.C. Bagheri, DMD, MD, FACS
Georgia Oral and Facial Surgery,
1880 West Oak Parkway, Suite 215,
Marietta, GA 30062, USA

Division of Oral and Maxillofacial Surgery,
Department of Surgery, Northside Hospital,
Atlanta, GA, USA

Eastern Surgical Associates and Consultants,
2795 Peachtree Rd, Suite 2008, Atlanta,
GA 30303, USA

Department of Oral and Maxillofacial Surgery,
Georgia Health Sciences University,
Augusta, GA, USA

Division of Oral and Maxillofacial Surgery,
Department of Surgery, Emory University,
Atlanta, GA, USA
e-mail: sbagher@hotmail.com

10.1 Introduction

To the inexperienced clinician, the evaluation of a patient with a peripheral trigeminal nerve injury can be a confounding or intimidating task. The patient with a sensory nerve injury is usually complaining of lost or altered sensation, pain, or a combination of both. Such symptoms are relatively difficult to *quantify* objectively by conventional means of physical examination, such as that of inspection, palpation, percussion, and auscultation. Many advanced, sophisticated, and

technologically involved methods for peripheral nerve evaluation that utilize specialized testing equipment (such as somatosensory evoked potentials (SSEP), magnetic source imaging (MSI), conduction velocity, and current perception threshold) have been developed and used primarily in laboratory and clinical research studies [12, 35, 40, 46, 56, 65]. Such armamentarium is not necessary in order to conduct an accurate and reproducible clinical examination of the nerve-injured patient. However, the interested clinician is encouraged to peruse the references listed in the references. In this chapter, a practical, straightforward method for evaluating sensory nerve injuries that is used in clinical practice is presented [22, 43, 47, 70]. This evaluation is well within the capability of any clinician, whether a specialist in nerve injuries or not.

Although the evaluation of a sensory nerve injury depends upon patient cooperation and proper interpretation, and it is characterized as “subjective” by some investigators [65], the information obtained from the methods described in this chapter is valid, is reproducible by other examiners, and is routinely used in the diagnosis, classification, and treatment of peripheral nerve injuries in all surgical specialties [7, 49]. A standardized method for peripheral nerve injury evaluation makes it possible to compare and interpret data from multiple treatment centers, thus enhancing the validity of clinical research and uniformity in terminology and nomenclature [39].

When evaluating a patient with a sensory nerve injury of the mouth or face, the clinician’s mission is to ascertain the circumstances of the injury and its subsequent course, examine the region containing the sensory dysfunction, complete a series of diagnostic maneuvers that will accurately outline the area of sensory deficit, quantify as best as possible the magnitude and character of the deficit, and record this information in an objective format so that it can be a basis for comparison with subsequent examinations by the same clinician or others, as needed. Accurate, legible, and complete records of this evaluation are indispensable since they are needed in making decisions regarding treatment of the nerve injury. Complete medical records are imperative

in retrospective studies of patient care, and they may be crucial in cases of legal involvement.

The essential elements of the evaluation of the patient with a peripheral sensory nerve injury of the oral and maxillofacial regions include the chief complaint; the history of present illness related to the chief complaint; a general head, neck, and oral examination; clinical neurosensory testing; imaging studies; and diagnosis and classification of the injury. Each of these subjects is addressed sequentially in this chapter.

10.2 History

The patient history begins with the patient’s *chief complaint* or the reason that the patient is seeking treatment. In the case of a sensory nerve injury, such as that of one of the peripheral branches of the trigeminal nerve, it will usually concern decreased altered sensation (*paresthesia*) or painful or unpleasant sensation (*dysesthesia*). The clinician must differentiate between these two types of sensory aberration because there is a separate neurosensory examination for each scenario (see below, Sect. 10.5.2). Some patients complain of both paresthesia and dysesthesia, so both types of examination may apply to these individuals. Patients often are frustrated or have difficulty in describing their sensory symptoms [45]. The exact nature of their complaints is often better determined by having the patient complete a preprinted questionnaire before being examined by the clinician. An example of the “nerve injury history” used in clinical practice and included in Appendix 10.A.1 is referred to in the following discussion.

When the patient complains of decreased or altered sensation, the problem may be characterized as *numbness*. This, however, is a colloquial term that demands clarification in order to be meaningful in a clinical sense. The patient who complains of numbness may be attempting to describe altered sensation that falls anywhere along a continuum from minimal sensory deficit (*hypoesthesia*) to total loss of sensation (*anesthesia*). There may be some component of pain (*dysesthesia*) as well. To assist the patient in verbally characterizing the nature of the sensory dysfunction,

a list of descriptive words (partially attributed to [58]) is included on the preprinted nerve injury history form (see Appendix 10.A.1, item #3).

Patients with complaints of a painful or unpleasant sensation are questioned whether it is *constant* or *intermittent*. Constant pain is most often seen in patients with chronic (more than 3 months), well-established, dysesthesia. There may be a central nervous system (CNS) component as well as that caused by the peripheral nerve injury. For example, CNS pain may develop over time due to the loss of afferent input from the periphery, so-called *deafferentation pain*, caused by failure of impulse transmission by the injured nerve [13]. Intermittent pain may be *spontaneous* or *stimulus evoked*. Spontaneous pain may be of brief duration (seconds), longer (minutes to hours), or constant. Stimulus-evoked pain is most often brief (seconds). It is usually associated with a common, frequently performed maneuver such as applying lipstick or shaving. Such pain is usually described by the patient as “hypersensitivity.” The intensity or severity of the pain at the time of the examination may be estimated by having the patient use a visual analog scale (VAS) in which 0 is “no pain” and 10 indicates the “worst pain” the patient has ever experienced. The patient is asked whether there is anything that has relieved the pain, including medications, application of heat or cold, rest, physical exercise, acupuncture, and chiropractic manipulation. In some patients with chronic pain, there is a history of inappropriate or excessive use of medications (particularly narcotics). Such patients may request prescription narcotic, sedative, or tranquilizing medications with addictive potential for pain relief on their first visit. In most cases, this is not acceptable and such medications should not be prescribed. Consultation with the patient’s other known medical or dental practitioners and local pharmacies may reveal an extensive history of prescription medication usage for chronic pain (see Appendix 10.A.1, item #4).

The *history of the present illness* includes the incident, procedure, or operation (e.g., local anesthetic injection for dental work, root canal filling, mandibular third molar removal, placement of dental implant, maxillofacial injury, jaw defor-

mity surgery, and cyst or tumor removal) that preceded and is thought by the patient to be the cause of the onset of the sensory complaint, the date of its occurrence, the symptoms, their progress or change in the interval since onset, and any perceived impairment of orofacial functions. This information is obtained by posing the following few screening questions: (1) What happened to initiate the onset of your symptoms? (2) Who performed the procedure or operation? (3) When (date) did it happen? (4) When did your primary symptom (numbness and/or pain) begin (date)? (5) What is the progress or change in your symptom(s) since onset? (6) What is the estimated amount of impairment or interference with orofacial functions in your everyday life? (7) Does anything make the symptoms better or worse? (see Appendix 10.A.1, items #5, 6, 7).

The incident or operation associated with the onset of sensory symptoms is often helpful in localizing the site of the nerve injury. For instance, if, after the removal of the mandibular left third molar tooth, a patient complains of left tongue numbness, there has most likely been an injury to the left lingual nerve (LN) in its location on the medial surface of the left mandible adjacent to the location of the removed tooth. The patient who complains of left lower lip and chin numbness after a similar operation probably sustained an injury to the left inferior alveolar nerve (IAN) adjacent to the apical portion of the third molar socket, although this complaint could represent a local anesthetic mandibular block injury as well. If, after a facial fracture through the right inferior orbital rim, the patient complains of right midfacial and upper lip numbness, the right infraorbital nerve (IFN) may surely have been involved within the inferior orbital canal or at its exit through the infraorbital foramen. Sensory changes in the lower lip or chin following posterior mandibular dental implant placement are generally caused by direct contact of the IAN or mental nerve (MN) with a rotating dental bur or by the implant itself. If the dentist or surgeon who performed the procedure is known, he or she might be contacted to obtain copies of the patient’s records, including operative reports that may contain information about the nature and location of an observed

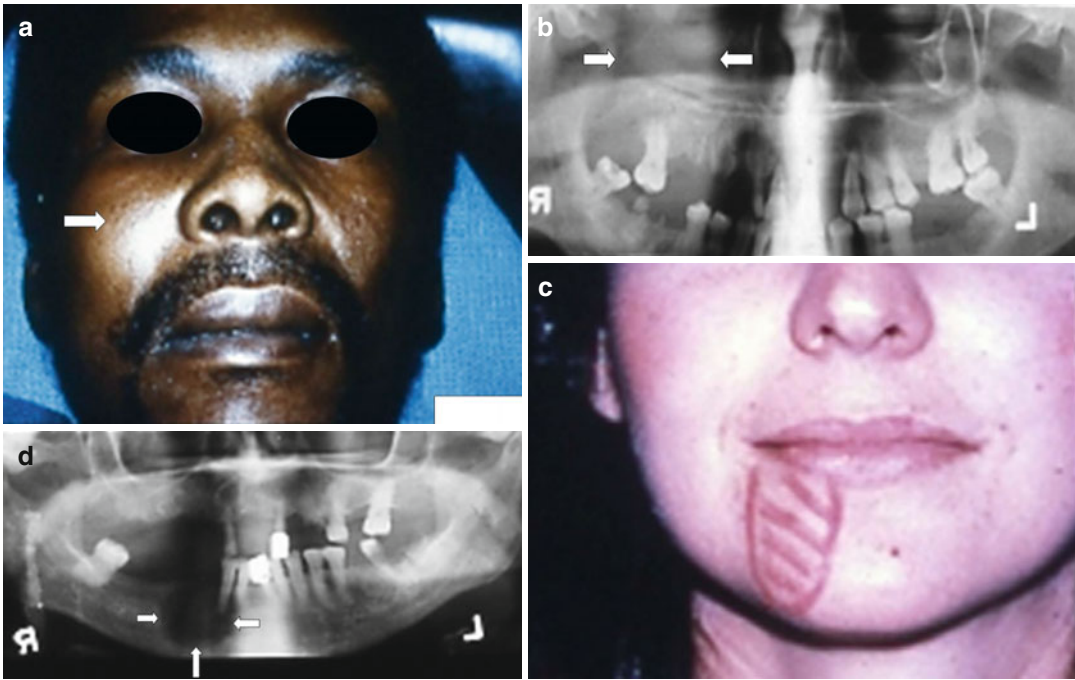


Fig. 10.1 Spontaneous numbness and pain in the facial region: (a) a 36-year-old male with right facial pain and swelling (*arrow*) and numbness of the right upper lip; (b) panorex shows lesion of right maxilla and sinus (*white arrows*). Biopsy revealed transitional cell carcinoma. Microscopic examination showed tumor invasion of the

right infraorbital nerve. (c) A 41-year-old female with right mandibular pain and numbness of right lower lip and chin (*outlined*); (d) panorex reveals lytic lesion (*white arrows*) involving right mandible and IAN. Biopsy showed metastatic adenocarcinoma, due to primary tumor in uterus

nerve injury. It is also a professional courtesy to send a report of the patient's nerve injury evaluation to that practitioner, whether or not a direct referral for care of the nerve injury was made.

Of special interest is the patient whose onset of altered sensation is without an associated incident or procedure. This patient requires the evaluation presented in this chapter to rule out the presence of pathology or a causative factor in the oral and maxillofacial regions (e.g., metastatic tumor to the mandible) (Fig. 10.1). Failing to find a cause there, it is incumbent upon the clinician to refer the patient to a neurologist for further evaluation to determine the reason for the patient's spontaneous onset of symptoms (CNS tumor, vascular anomaly, infection, metabolic disorder, etc.).

The date of the incident and/or onset of sensory changes is pertinent because there is a timetable for the pathophysiologic response of a peripheral nerve to injury (Wallerian degeneration) [7, 61]. Progressively, the axons distal to the injury location undergo necrosis and phagocytosis. As this process

is completed, repair is begun by outgrowth of axonal sprouts from the proximal nerve stump. If the distal nerve superstructure is not recannulated by new axons within a reasonable period of time, it is replaced by scar tissue and becomes incapable of repair, either spontaneously or by surgical intervention. Although there is some uncertainty regarding the timing of surgical repair of nerve injuries [64], it is generally accepted that there is a window of opportunity of about 6 months from the time of injury when surgical repair of an injured nerve provides the best chance of improvement or restoration of sensory function [2–5]. After that, the chance of successful outcome of nerve repair decreases with each passing month until a critical mass of distal nerve tissue is replaced by scar tissue that lacks the potential for restoration of nerve function; additionally, there is ganglion cell death in the trigeminal ganglion that decreases the total percentage of possible sensory recovery. In humans, this time has been estimated at 12 months or longer, depending on the age and general health of the patient and

other factors not yet fully understood [42]. In any case, it behooves the clinician who initially attends the patient with a sensory nerve injury to note the date of injury so that surgical intervention that might be indicated for non-resolving sensory dysfunction can be done within a favorable time frame.

Numbness or pain may not begin concomitantly with the incident or operation associated with the nerve injury. For example, seepage of root canal medicaments from the tooth apex following over-instrumentation during root canal preparation may take one or more days to reach the adjacent inferior alveolar canal (IAC) and cause a chemical burn of the IAN. Similarly, after bone preparation for insertion of dental implants, edema secondary to heat generated by the drill may develop slowly within the IAN, producing delayed compression of the nerve with the onset of lower lip numbness and/or pain not noticed by the patient for up to 24 h after the procedure. Also, if the IAN is not directly injured, but the bony wall of the IAC is disrupted during elevation and removal of a mandibular third molar, or during any other procedure (e.g., mandibular fracture or mandibular osteotomy), excessive bone may be regenerated during the healing process [9]. Thus, the IAC diameter is narrowed, and delayed compression of the IAN occurs one to several months later with the onset of symptoms at that time. Such instances help to explain why, although most sensory nerve injuries result in immediate onset of symptoms, in some patients sensory dysfunction might occur later and render the association between cause and effect somewhat obscure.

The progression of sensory symptoms is significant because, over an interval of days, weeks, or months after the injury, the patient might show improvement or deterioration of sensory function or undergo no change [18]. The patient is seen at regular intervals (i.e., every 2–4 weeks) for repeated evaluations to ascertain any evolution of sensory status. In patients who are improving, an *expectant* course can be taken; serial examinations are repeated as long as they continue to show documented subjective and objective improvement at each subsequent visit. A patient who fails to show improvement of neurosensory status from one evaluation to the next (especially beyond 3 months following nerve

injury) will generally not resume improvement at some future date. This patient is assumed to have reached a plateau or end point. If his or her sensory status is judged to be *unacceptable*, a decision regarding surgical intervention should be considered at that time rather than continuing to follow the patient further in the vain hope that further improvement will occur in the future. Whether or not a patient is improving is based not only upon subjective information (the patient's history) but also upon objective evidence (the examination, see below). In the course of recovery from a sensory nerve injury, new symptoms may appear. Most commonly, numbness is the patient's initial complaint. Although there may be pain at that time as well, it often develops days or weeks after the injury, and it may increase in frequency, duration, and intensity, be episodic initially and then become constant, and be spontaneous or associated with various orofacial maneuvers or daily activities.

Aside from the unpleasant sensory symptoms, many patients experience interference with normal daily activities or functions (see Appendix 10.A.1, item #7). Chewing food, drinking liquids, toothbrushing, face washing, shaving, applying lipstick and makeup, and speaking are examples of common acts that are performed almost without thinking in the person with normal orofacial sensory and motor function. Loss of sensory input adversely affects the coordination of the motor component of any activity. Therefore, accidental lip or cheek biting while chewing food, dribbling of liquids while drinking, difficulty with toothbrushing or application of lipstick, and alterations of speech are common complaints of the patient with a peripheral trigeminal nerve injury and should be duly noted [27]. In some patients, interference with speech or the ability to play wind musical instruments may impact on their capacity to earn a living. Referral to a speech pathologist or other performing consultant may be indicated in order to properly document a loss of function and arrange for appropriate corrective therapy, if indicated.

Although not a primary complaint, the patient with a lingual nerve injury is often aware of alterations of taste sensation (*parageusia*, *dysgeusia*) that may be characterized as a general

lessening or loss of taste, loss of one or more specific taste senses (sweet, sour, salty, bitter), or a foul or unpleasant taste (e.g., metallic, rotten, foul, rancid). The patient should be counseled that taste sensation may improve along with spontaneous improvement in general sensory function of the lingual nerve (LN) or as a result of the microsurgical repair of the LN [53]. However, it is further explained that taste sensation is transmitted by the chorda tympani fibers from the facial nerve (FN7) that travel with the lingual nerve but which send their impulses to the nucleus of the FN7 and have a potential for healing and recovery of function that is not as great as that of the LN. Therefore, recovery of taste may or may not occur to the same extent as that of the general sensory function of the LN, although some patients report normal or near-normal taste sensation after LN repair [6, 29, 53, 69].

As important as is the history in the evaluation of a patient's complaint, it has been shown that

neurosensory problems can be over-reported by some patients [14]. Therefore, it behooves the clinician to always complete a comprehensive neurosensory examination of the patient regardless of the alleged severity of the subjective symptoms.

10.3 Equipment

The well-equipped practitioner's office will already contain the supplies and instruments required for examination of the nerve injury patient. Sterile gloves, mouth mirror, tongue blades, cotton swabs, calipers, local anesthetic needles (27 gauge), anesthetic cartridges, and local anesthetic syringe are the basic armamentarium used for nerve testing (Fig. 10.2). A pulp tester (vitalometer) is sometimes used as method of assessing response to pain when evaluating an IAN injury (Fig. 10.3). An algometer can be another way to assess pain response. Thermal discs are utilized by some clinicians to test



Fig. 10.2 Basic equipment for NST includes (left to right) syringe, local anesthetic cartridges, calipers, 27-gauge needle, tongue blade, cotton swabs, mouth mirror, and examination gloves

sensory response to temperature change [17]. Semmes-Weinstein monofilaments [63] provide a more accurate and reproducible measure of contact detection (static light touch), although

the use of a cotton swab as demonstrated below is adequate in the typical clinical situation.

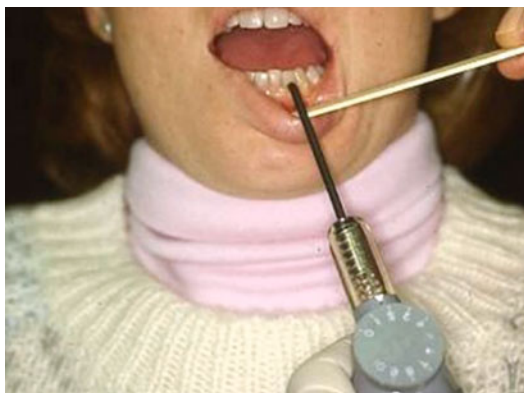

Fig. 10.3 A pulp tester can be used to assess pain response of the lower teeth in a patient with an IAN injury

10.4 Head, Neck, and Oral Examination

A regional examination is completed on all patients including the head, eyes, ears, nose, face, temporomandibular joints, neck, oral cavity, pharynx, and neck. Specific components of the screening evaluation for the nerve injury patient are shown in Fig. 10.4. Following recording of the patient's vital signs, the next step is *inspection*. If the patient is acutely injured, the examiner looks for evidence of maxillofacial trauma (missile wound, laceration, facial bone fracture, abrasion, or contusion). A nerve injury (transection, avulsion, partial tear, compression, or crushing) may be able to be directly visualized through an open wound or laceration [2]. In other patients, the examiner searches

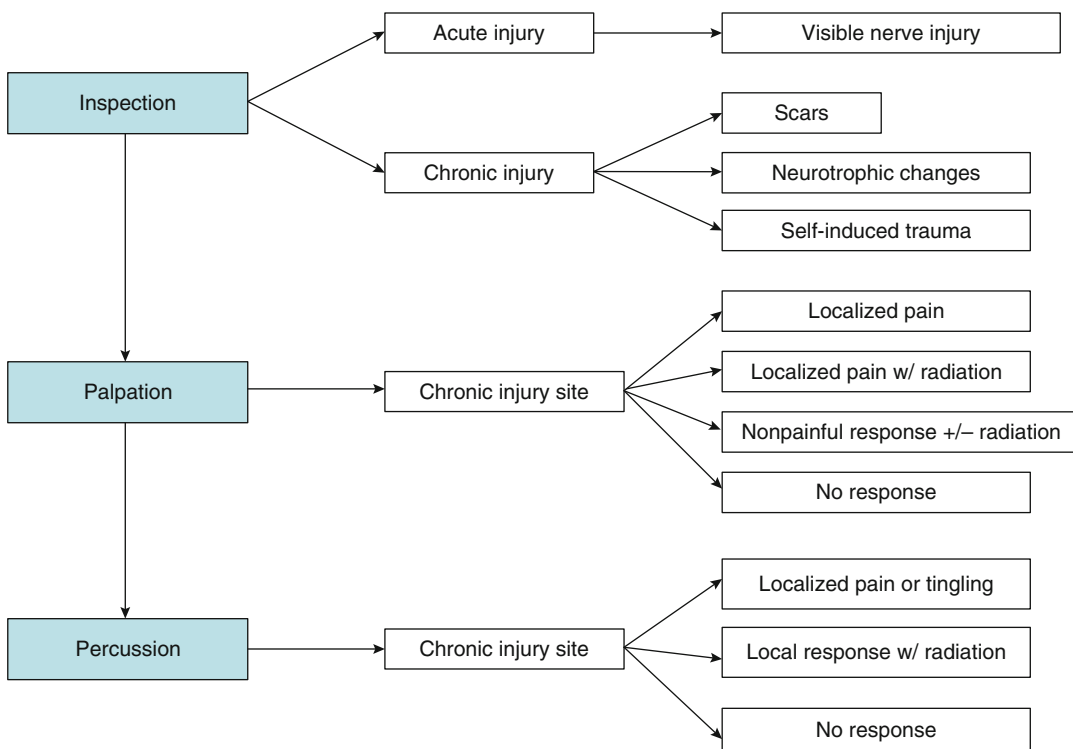


Fig. 10.4 The initial part of the NST includes inspection, palpation, and percussion of the head, neck, and oral regions. Positive findings in this screening process may

lead the clinician to the location of the nerve injury and provide important information about its severity

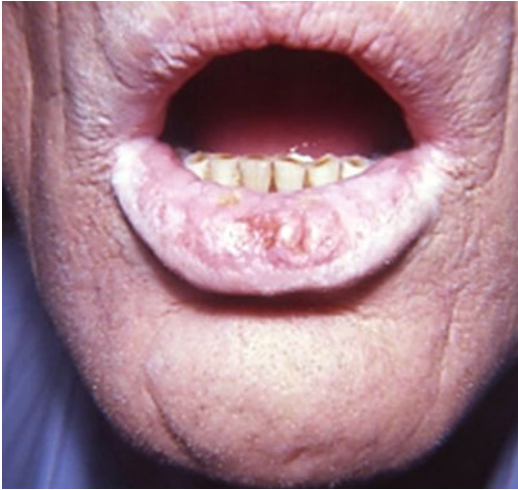

Fig. 10.5 A 62-year-old fisherman with loss of sensation in lower lip and chin from injuries sustained from chronic lower lip biting for 20 years. The central portion of the lower lip, initially thought to show the results of self-induced injury, on biopsy was found to be squamous cell carcinoma, while the rest of the lower lip showed precancerous dysplastic changes

for signs of recent or past injury or surgery (e.g., sutured or healing incisions, scars) or neurotrophic changes of the skin (edema, erythema, ulcerations, hypohidrosis, loss of hair, hypokeratosis) that may develop following sensory loss in that area. The patient with long-standing sensory dysfunction may repeatedly traumatize insensate soft tissues, producing factitious (self-induced) injury (Fig. 10.5). In the neck, scars from previous injury or surgical incisions when stimulated by repeated gentle stroking with the examining finger or a cotton swab may respond with symptoms and signs of sympathetic nervous system hyperactivity (hyperesthesia, sweating, blanching, flushing, skin temperature changes) in the cutaneous area supplied by the injured nerve. Such findings may be diagnostic of *sympathetic-mediated pain* (SMP; also known as reflex sympathetic dystrophy or complex regional pain syndrome [26]).

Palpation or *percussion* is done directly over the mandibular retromolar area or the medial surface of the mandible adjacent to the third molar tooth (for the LN), over the mental foramen either on the skin surface or intraorally between the mandibular premolar teeth (for the MN), beneath the inferior orbital rim on the skin or

transorally superior to the maxillary premolar teeth (for the IFN), and at the midpoint of the eyebrow (for the supraorbital nerve (SON)). One of three possible responses, each called a *trigger*, may be induced in the presence of a nerve injury (Fig. 10.6). First, a painful sensation (often characterized by the patient as an “electric shock”) is induced and is limited to the area of applied stimulation. Second, this painful sensation may radiate from the area of stimulation and proceed distally into the area supplied by the affected nerve (e.g., palpation of the lingual nerve causes ipsilateral painful sensations in the tongue and floor of mouth). Third, nonpainful responses (tingling, crawling, itching) radiate from the area of nerve palpation. In some patients, palpation or percussion over the injured nerve induces no trigger response. Subsequent direct observations of the injured nerve during microsurgical repair usually confirm that the trigger area denotes the site of nerve injury [70]. A painful response without radiation frequently indicates a complete nerve severance with a proximal stump neuroma as the source of the pain. On other hand, a painful response, or a nonpainful response with radiation, in some patients is a sign of partial nerve transection or a neuroma-in-continuity. This sign has been referred to as the *Tinel’s sign*, and it may indicate regenerating nerve fibers present in the area of palpation, or it may indicate the presence of a neuroma. In other patients with complete nerve severance, there are distally radiating sensations from the trigger area which probably represent *phantom pain* [33]. Occasionally, a patient with a significant nerve injury fails to give a trigger response to stimulation over the injury site. Therefore, a trigger response should be considered indirect evidence of a significant nerve injury, whereas a lack of response does not rule out the presence of injury.

Percussion of the mandibular teeth may invoke tingling or unpleasant sensations that may or may not radiate from the teeth to the lower lip or chin. Palpation, percussion, or gentle stroking of the lower lip or chin may also cause sensations that radiate to the lower teeth. The significance of these findings in relation to the extent or nature of the injury to the IAN is not well understood

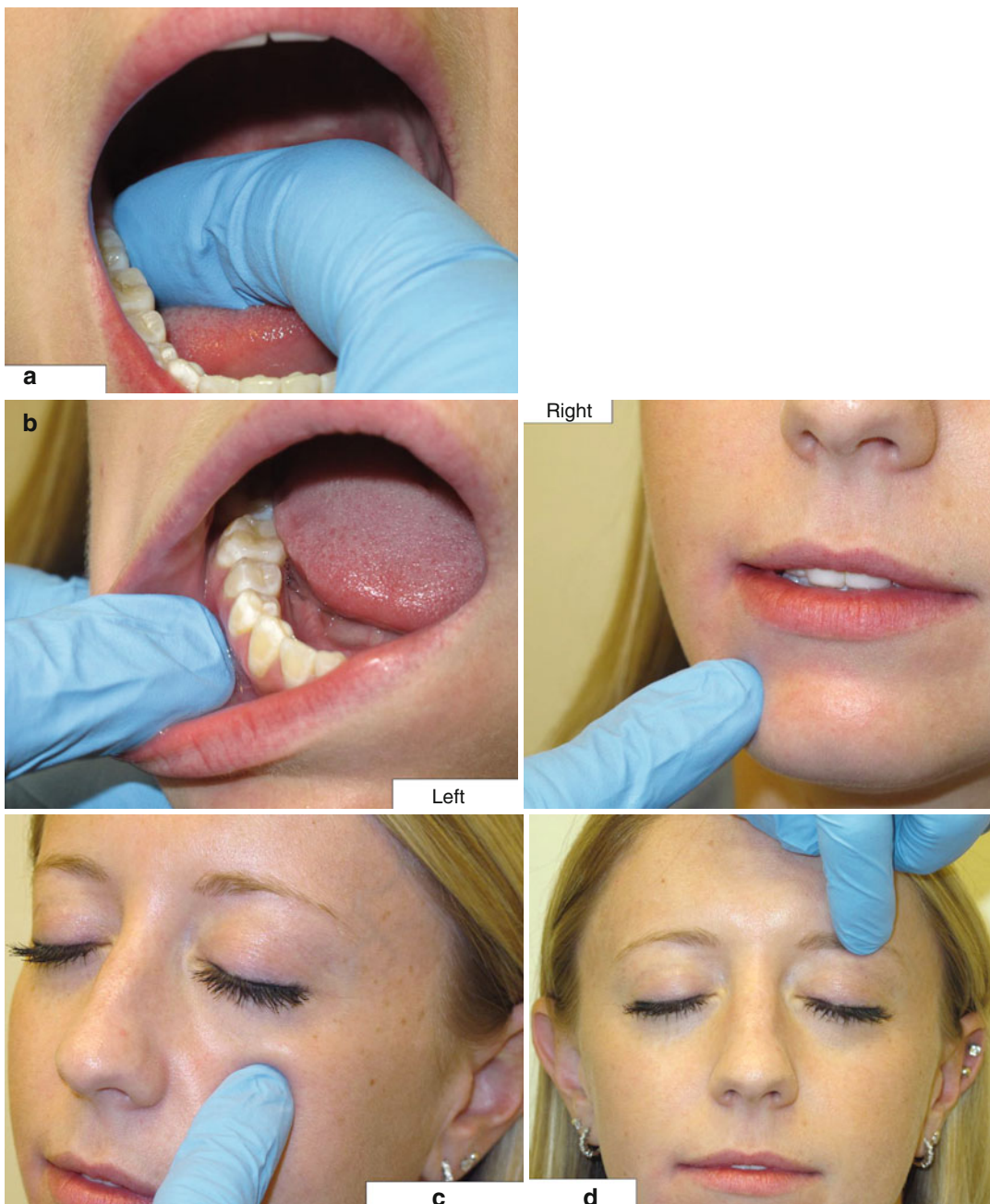


Fig. 10.6 Palpation is done directly over a nerve contained in soft tissue to check for a trigger response: (a) right LN is palpated on the lingual aspect of the mandibular third molar area; (b) the right mental nerve is palpated either intraorally in the mandibular buccal vestibule (*left*)

or on the face (*right*); (c) the left infraorbital nerve is palpated on the face beneath the inferior orbital rim, but it can be accessed intraorally as well; (d) the left supraorbital nerve is felt as it exits the orbit just superior to the superior orbital rim

[24, 25, 41, 66]. The appearance of the nerve at surgery does not always correlate well with the extent of injury implied by results of the clinical

examination; examination and neurosensory testing (see below) are less accurate at predicting the extent of IAN injury than that of LN injury [70].

The evaluation of taste sensation requires special equipment (see below), it is a technically demanding endeavor [68], and the results may be difficult to interpret [28]. Most patients who have sustained an LN injury are primarily concerned with lost, altered, or painful general tongue sensation and the sequelae of accidental tongue biting, difficulty chewing food, painful toothbrushing (if there is a trigger area), effects on speech, and interference with the playing of wind musical instruments. Whether or not the patient has altered taste sensation seldom, if ever, influences the surgeon's decision regarding surgical or other treatment for the injured LN [3, 53]. Therefore, taste testing is not usually included in the routine evaluation of the patient with a peripheral trigeminal nerve injury. In the patient who develops a taste aberration in the absence of known peripheral nerve injury, taste testing may be helpful in documenting whether or not there is an anatomical cause for actual loss of taste function (which might represent a symptom and sign of a brain tumor, for instance) rather than its being due to a side effect of medication (e.g., chlorothiazide diuretics) or to a strictly psychological aberration. The taste buds in the anterior two-thirds of the tongue receive special sensory supply from the chorda tympani fibers that originate in the nucleus of the FN7 and join the LN peripherally before its course to the tongue. Taste buds in the posterior one-third of the tongue are supplied by the glossopharyngeal nerve (GP9). Therefore, application of substances must be carefully confined to one or the other segments of the tongue, and crossover of the substances to the contralateral side must be prevented to allow valid interpretation of the results. Further complicating this special sense is that taste is greatly influenced by the sense of smell (note the common loss of taste sensation during an upper respiratory affliction such as the common cold or rhinitis from allergies). During taste testing, olfaction must be blocked, or non-aromatic substances must be used. Some patients have reported no change in taste sensation in instances of documented LN anesthesia [53]. Clinical testing has shown a "remarkable difference" between a patient's stated impression of

his taste perception and his true ability to taste specific substances based on testing [29]. Some patients may not even be aware of significant deficits in taste perception [8]. The ability of the chorda tympani nerve nuclei to regenerate after severance of peripheral axons has been shown to be highly unpredictable and sometimes to a lesser degree than the general sensory nerve nuclei of the trigeminal nerve [23]. Psychological factors not presently known or understood may influence a patient's perception of taste, whether or not there has been an injury to one of the nerves carrying special sense impulses from the taste buds [52].

If the clinician wishes to evaluate taste sensation, the examination may include either *regional testing* or *whole mouth testing* [21]. Regional testing evaluates selected groups of taste buds (i.e., those on the anterior two-thirds or those on the posterior one-third of the tongue) and allows the clinician to differentiate between the special sensory input of the LN and the GP9 [28]. Therefore, regional testing is more valuable when one desires to measure the function of a specific nerve with regards to taste sensation [44]. Whole mouth testing gives a more global and nonspecific overview of the integrity of taste rather than focusing on the specific innervation of selected groups of taste buds. The sense of taste conducted from the taste buds supplied by the chorda tympani branch of the facial nerve via the LN can be tested by applying sweet (sucrose), sour (citric acid), salt (saline), and bitter (quinine) substances to the anterior two-thirds of the tongue [8]. The substances are applied via an enclosed "surface chamber" to confine them to an isolated and discrete area of the tongue [68]. The patient's eyes are closed and the nares are occluded during the taste applications. The patient is requested to report whether they feel the application of the test substance on the tongue and to identify the specific taste. Findings are graded on a 0–2 scale (2=patient feels application and correctly identifies its taste as sweet, sour, salt, or bitter; 1=patient feels application, but has no taste identification; 0=patient does not feel application and has no taste identification).

10.5 Neurosensory Testing

Neurosensory testing (NST) includes a group of standardized clinical diagnostic maneuvers designed to evaluate general sensory function in as unbiased a manner as possible. Such testing, although the methods have been characterized as being subjective in that they are influenced by the patient's level of cooperation and interpretation [65], is reproducible on serial repetition on the same patient by the same or other examiners. The patient who is malingering, is considering a legal action against the practitioner who performed a procedure thought to be responsible for a nerve injury, or is attempting to embellish an application for worker's compensation for a job-related injury may be a challenge for the clinician who strives to gain an accurate assessment of the level of sensory dysfunction. In some instances, the patient may seek to exaggerate responses to NST (as well as overestimate the severity of symptoms in the history). A patient who complains of symptoms or functional impairment in distinct disproportion to the results of the clinical examination should arouse suspicion that there is a "hidden agenda" involved with attempts to manipulate the results of the neurosensory testing. By randomizing the order, type, or location of stimulus application (or in some instances not applying the stimulus at all) and carefully observing the patient's nonverbal responses (e.g., promptness or lack of response or withdrawal from a stimulus) or "body language" (disinterested facial expression, grimacing or sneering, failure to make eye contact during the evaluation, nervous hand mannerisms, excessive facial sweating, facial flushing or pallor), the astute examiner may be able to recognize inappropriate behavior and prevent patient attempts to distort or misrepresent the results.

The material presented below is a summary of methods used by clinicians experienced in the field of peripheral nerve injuries [16, 22, 36, 43, 48, 49, 67]. The rationale for their use and the validity of their results have been established in various studies [19, 70].

During the neurosensory examination, the patient is seated comfortably in a quiet room, and most maneuvers are performed with the patient's

eyes closed. When the patient's lips are being tested, they should be separated so that pressure or vibration of applied stimuli is not transferred from the stimulated lip to the opposite lip. The specific tests and responses are described in detail to the patient so that he understands and is able to make the appropriate responses during NST. The examiner explains each step beforehand with reassurance that the stimulus will be applied gently and with due concern for any areas of pain or hypersensitivity that were described in the patient's history or elicited in the general head, neck, and oral examination. The contralateral normal side is always tested first to determine the patient's *normal "control" responses* in order to establish a baseline for examination of the abnormal side.

The NST begins by determining the area of altered sensation with the *marching needle* technique. A 27-gauge local anesthetic needle is advanced from a normal area adjacent to the area of sensory dysfunction indicated by the patient's history. The needle contacts the surface mucosa or skin lightly at 1–2 mm intervals until the patient indicates (by raising the ipsilateral hand) the location where the sensation of the needle-point begins to change. This process is repeated until the border of the entire area of altered sensation is determined. Within this area when the injured nerve has lost all ability to transmit impulses, there will be an *intermediate zone* adjacent to the border where there is a decrease in the appreciation of the stimulus (*hypoesthesia*, in which sharp becomes "dull," but contact is still perceived by the patient) [11]. This is probably due to crossover sensory fibers from an adjacent or contralateral nerve [20]. Further into the affected area (usually within a few millimeters), the patient fails to feel the stimulus at all (*anesthesia*). If this area is on the skin, it is indicated with a colored erasable marking pen. The markings can later be easily removed with alcohol or orange solvent (Fig. 10.7). The NST then begins, first, on the contralateral normal side (e.g., the right lower lip to establish normal responses for that patient) and then on the ipsilateral side (the left lower lip with altered sensation) to ascertain the level of abnormal responses. In a patient with bilateral nerve injuries, an adjacent normal area

is chosen for control responses (e.g., for bilateral IAN injuries, the vermilion border of the normal upper lip for comparison with the abnormal upper lip; for bilateral LN injuries, the normal lower labial mucosa for comparison with the abnormal lower lip; for bilateral IFN injuries, the normal lower

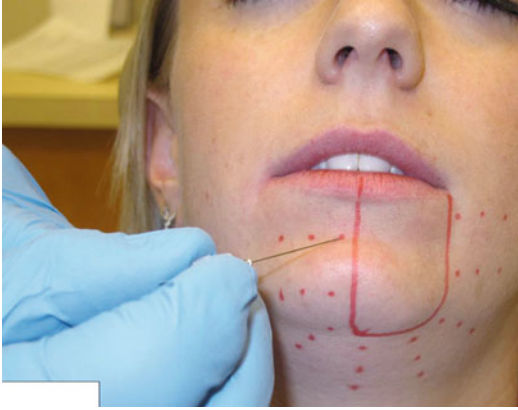

Fig. 10.7 The “marching needle” technique is used to determine the boundaries of the area of altered sensation in a patient with complaints of left lower lip and chin numbness after lower third molar removal. A 27-gauge needle is used beginning in an area of normal sensation, and multiple contacts are made (*red dots*) every few millimeters until the patient reports a change in the sensation (e.g., “sharp” changes to “dull”). After these determinations have been made from the left, right, and inferior to superior, the border of the affected area can be delineated (*solid red line*)

lip vermilion border for comparison with the abnormal upper lip; for bilateral LN injuries, the normal lower labial mucosa for comparison with the abnormal lower lip; for bilateral IFN injuries, the normal lower

lip vermilion border for comparison with the abnormal upper lip; for bilateral LN injuries, the normal lower labial mucosa for comparison with the abnormal lower lip; for bilateral IFN injuries, the normal lower lingual gingiva and tongue numbness).
When performing NST, it is important to understand the concept of *threshold of response* [60]. When a stimulus (such as a needle) is applied to the skin or mucosal surface, it is done initially with little minimal pressure and with *no indentation* of the surface tissue. If the patient responds to the stimulus (raised ipsilateral hand), it is noted that the response was at the *normal threshold*. If the patient does not feel the stimulus, then the stimulus is applied again with just enough additional pressure to produce indentation, but not piercing, of the skin or mucosa. If the patient now responds to the stimulus, this response is noted to be at an *increased threshold*. This is an abnormal response indicating that the nerve has sustained injury but still has the ability to transmit electrical impulses from the periphery to the CNS. However, that ability is compromised in terms of the numbers of axons able to transmit and/or their speed of transmission (Fig. 10.8). If the patient still fails to respond at the increased threshold, it is noted that there is *no response* (*NR*), and no further additional pressure is applied

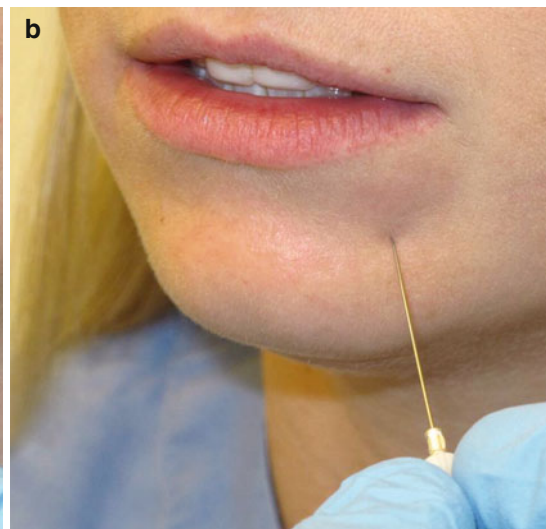
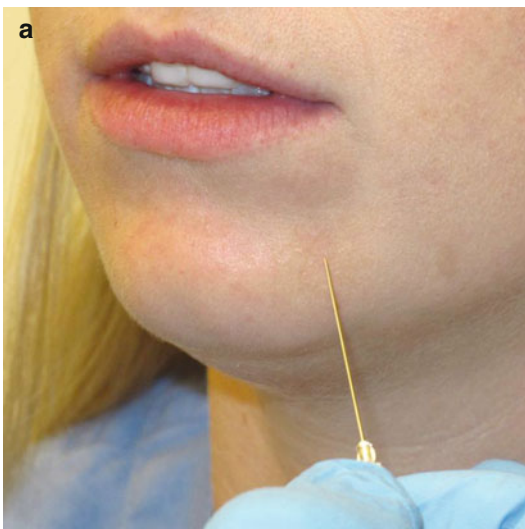


Fig. 10.8 Grading the threshold of applied pressure necessary to elicit a response. (a) A 27-gauge needle is placed in light contact with the skin of the left chin without indenting the skin surface. If the patient responds to the stimulus, this is a response at the *normal threshold*. (b) If

the patient does not respond at this threshold, additional pressure is applied to the needle sufficient to indent the skin without piercing it. If the patient now responds, this is a response at an *increased threshold*

to the stimulus. To further increase the pressure applied to the stimulus (i.e., needle) at this juncture will induce penetration of the skin or mucosa with bleeding and will add no helpful information. This concept produces a simple, but accurate and reproducible, measurement of responses to static light touch and pain (level B and level C testing, see below). Other methods will be described as well.

The NST of a patient with *decreased* altered sensation differs from that of the patient who complains of *unpleasant* altered sensation. The goals for diagnosis and treatment are not the same for these two categories of sensory nerve injury patients. In the former (decreased altered sensation), the clinical objective is to improve or restore lost sensory function, whereas, in the latter, reduction or relief of pain is the primary reason for treatment. Therefore, the evaluation of each of these two types of sensory nerve injury patients is discussed separately.

10.5.1 Decreased Altered Sensation

Three levels of NST are available for the patient with decreased or altered sensation without pain. The objective of testing for this type of nerve injury patient is to assess the level of impairment of sensory function as *normal*, *mild*, *moderate*, or *severe hypoesthesia*, or *complete* loss of sensation (i.e., anesthesia). The tests are done in the order discussed below, and one level of testing may or may not lead to another, depending on the patient's responses.

Level A testing evaluates spatiotemporal perception which is an indirect assessment of the function of the larger diameter, myelinated, slowly and rapidly adapting A-alpha sensory nerve fibers (5–12 μm diameter). Directional discrimination (moving brush stroke identification, MBSI), static two-point discrimination (2PD), and stimulus localization (SL, to assess for the presence or absence of *synesthesia*) are included in Level A. MBSI is evaluated by lightly applying a series of ten randomly directed moving strokes (on the skin or tongue only) with a cotton wisp, camel hair brush, or Semmes-Weinstein monofilament to the test area (always the normal

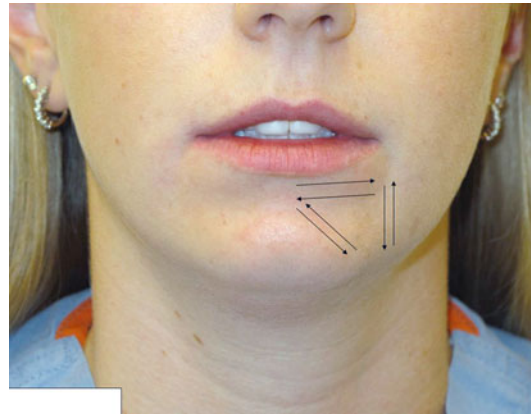


Fig. 10.9 Level A testing for moving brush stroke identification: the *arrows* indicate horizontal, vertical, and diagonal directions of the stimuli that are applied randomly by the examiner. After each stimulus, the patient is requested to duplicate the direction with a finger or cotton swab

side first). The strokes may be directed horizontally, vertically, or diagonally (Fig. 10.9). After the application of each stroke, the patient is asked to indicate the direction verbally or to retrace it with a cotton swab. The normal response on the normal/control side is nine or ten out of ten correct directional identifications. Eight or fewer correct identifications on the abnormal side indicate the level of sensory impairment for that test, which is recorded as 7/10, 3/10, and so forth, or 0/10 or “no response (NR).”

Determination of 2PD is done routinely with calipers or a fine-tip Boley gauge, although it is best to use tips that are not sharp and may evoke level C pinprick nociception. The Disk-Criminator [19, 37] and the two-point pressure esthesiometer [19, 22] are other devices used by some clinicians and researchers. Although control of the force of application of the stimulus might be a desirable advantage of the esthesiometer, 2PD responses may be independent of the force of application of the stimulus [34] that renders the hand-held calipers an acceptable clinical tool. More recent work indicates this may not be the case [15, 59]. However, the accuracy required for clinical evaluation of a sensory nerve and the information needed to make determinations regarding treatment are not as great as that for data collection for research. This test is administered using the method of limits [19], beginning with the tips of

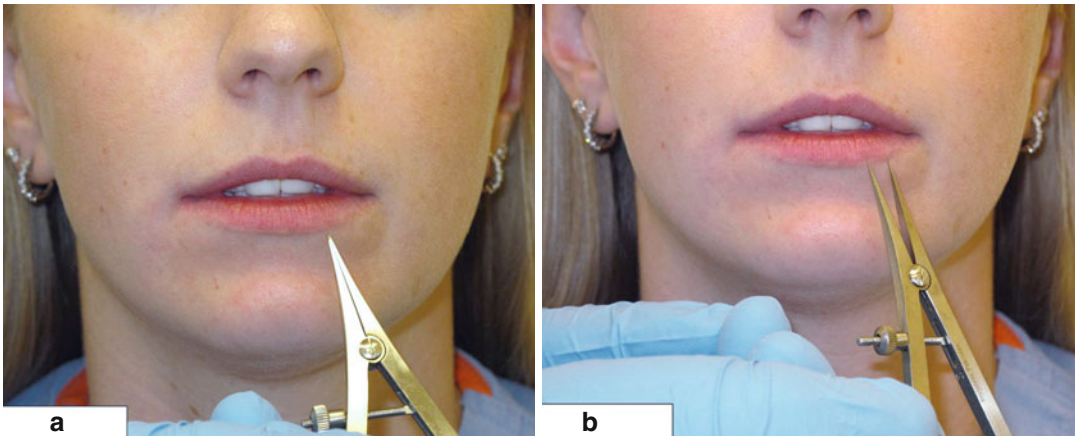


Fig. 10.10 Level A testing for two-point discrimination (static). (a) Initial contact is with calipers closed together (blunt tips are preferred). (b) Contact continues with incremental 1 mm additional separation of caliper tips

with each subsequent application until patient indicates that two simultaneously applied caliper tips are felt as two discrete contact points

the calipers together (zero distance). Before contact with the caliper tips is gently made on the skin or mucosal surface, the patient is asked to indicate when contact is felt and to identify (verbally or with fingers) whether that contact is of one or two points (Fig. 10.10). If the patient expresses uncertainty about the number of contact points, the response is graded as “one.” The distance between the caliper tips for each subsequent contact is increased by 1 mm until the patient is able to identify two simultaneous points of contact (threshold distance). Further applications are made to overshoot this distance by 2–3 mm; then the process is reversed from that point, again in 1 mm increments until the patient no longer is able to perceive simultaneous contact with two points. Generally, in both the ascending and descending portions of the test, the threshold distance is the same or within one millimeter. Occasionally, the examiner will apply only one caliper tip or fail to apply any stimulus to verify that the patient is not trying to manipulate the test results. Normal values for 2PD are provided in Table 10.1.

Stimulus localization is a method of estimating the amount of synesthesia (the inability to determine the exact point of stimulus application) associated with a partial sensory loss or with a recovering sensory nerve injury. This estimation

Table 10.1 Normal values for two-point discrimination^a

| Test area | Average normal threshold distance (mm) | Upper normal limit (mm) ^b |
|--------------------|--|--------------------------------------|
| Forehead | 13.5 | 22.0 |
| Cheek (face) | 9.0 | 17.0 |
| Upper lip (skin) | 4.5 | 8.0 |
| Upper lip (mucosa) | 3.0 | 6.0 |
| Lower lip (mucosa) | 3.5 | 6.5 |
| Lower lip (skin) | 5.0 | 9.0 |
| Chin | 9.0 | 18.0 |
| Tongue (tip) | 3.0 | 4.5 |
| Tongue (dorsum) | 5.0 | 12.0 |

^aValues collated from the literature (as reported by Zuniga and Essick [67])

^bDistance greater than upper normal limit is considered to be abnormal

is done by lightly contacting the skin with the wooden end of a cotton swab stick and then asking the patient to touch the exact same location with another swab stick. A normal response is contact within 1–3 mm of the examiner’s point of application. Generally, five contacts are applied in each tested area (Fig. 10.11), and the patient’s response is graded by the number of normal responses (e.g., 5/5 and 3/5).

Patients complaining of decreased altered sensation but who give normal responses to level A

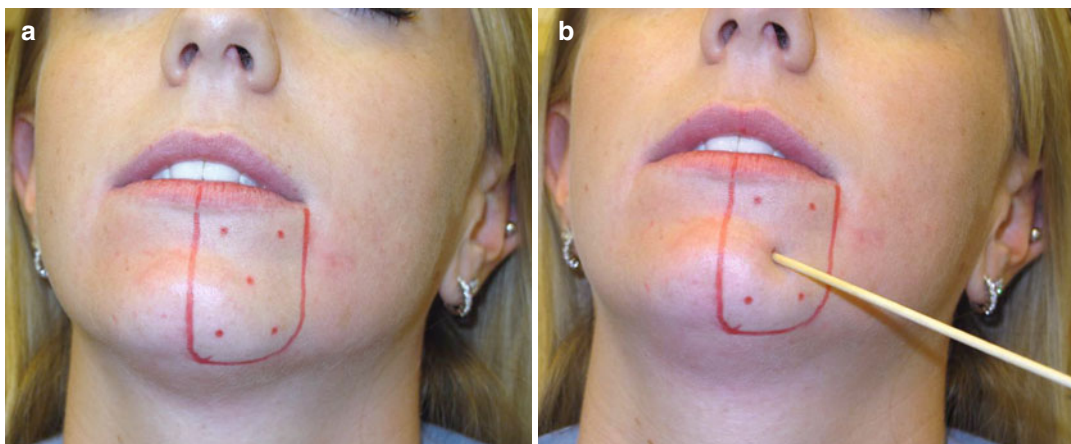


Fig. 10.11 Level A testing for stimulus localization. (a) Five contact points (*red dots*) are selected by the examiner. (b) The examiner contacts the skin at each contact point in random order. After each stimulus application,

the patient is instructed to contact the exact same point. The wooden end of a cotton swab or an appropriate-size monofilament can be used as the stimulus and the pointer for the patient

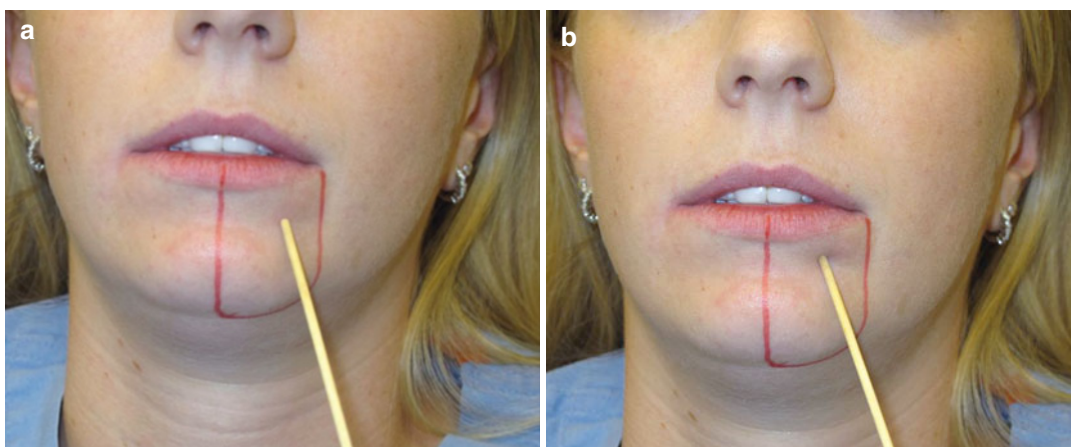


Fig. 10.12 Level B testing for contact detection. (a) The skin in the test area is contacted lightly (without indentation). If the patient feels this stimulus, this is a normal

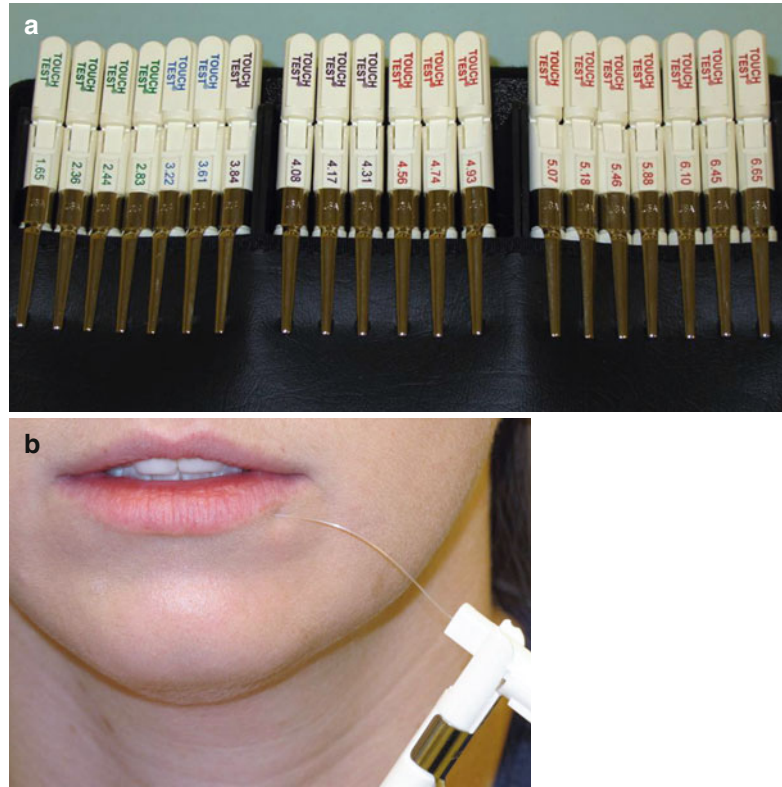response. (b) If the patient does not feel the stimulus at the normal application pressure, the skin is again contacted, this time with sufficient pressure to indent the skin

testing are judged to be “normal,” and no further testing is necessary. The patient who gives abnormal responses or no response to any of these tests has sensory impairment, and the examiner proceeds to level B testing.

Level B testing evaluates responses to static light touch (contact detection) and measures the function of medium diameter (4–8 μm diameter), myelinated, rapidly adapting A-beta sensory nerve fibers. The test area is touched lightly without indentation with the wooden end of a cotton swab stick. The patient is asked to raise the

ipsilateral hand when contact is perceived. Response to contact *without skin indentation* is at the normal threshold, and no further NST is necessary for this patient. If the patient fails to respond, the stimulus is repeated with sufficient pressure to cause skin indentation (Fig. 10.12). If the patient now responds to contact, this is at an *increased threshold*, which is an abnormal response. If the patient fails to respond at the increased threshold, this is graded as “no response.” Another method of testing for contact detection is with Semmes-Weinstein monofilaments or von

Fig. 10.13 (a) Semmes-Weinstein monofilaments used for testing static light touch. The number on each instrument corresponds to the force/application pressure required to bend the monofilament when placed against the skin. (b) The monofilament placed against the skin with sufficient force/pressure to cause bending is the test stimulus

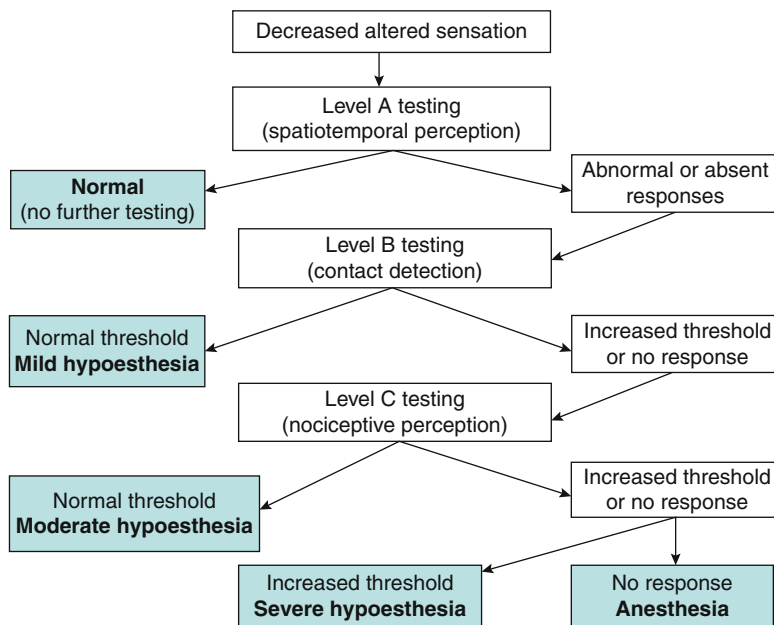


Frey hairs [19]. The monofilaments are labeled with the manufacturer's number or marking which corresponds to a force in grams of pressure application that causes the monofilament to bend; the smallest number indicates the smallest force and lowest pressure required to deflect the monofilament. Each monofilament is placed against the skin or tongue and then additional pressure is applied until the monofilament bends slightly (Fig. 10.13). Using the normal control side first, the normal contact threshold is determined using ascending and descending sequential applications of successively larger and then successively smaller, respectively, monofilaments. The initial application of the ascending phase should be of a monofilament small enough to not be detected in the normal control area. Once a size of monofilament is reached in the ascendant phase in which contact is perceived, two additional larger monofilaments are applied; then the monofilaments are applied in descending order of size. The smallest monofilament that the patient perceives is the *normal threshold for contact detection*, and the size of that monofilament (manufacturer's number)

is recorded. The test is then repeated on the abnormal side, and the threshold size of monofilament (if the patient is able to respond) is recorded. An abnormal response is one that requires a monofilament delivering 2.5 times the force/pressure of the threshold response on the normal side. If the responses to monofilament testing are normal, no further testing is required. However, for patients who respond at an *increased threshold* or have *no response* on the abnormal side, the NST proceeds to level C testing.

Level C testing measures nociception (the appreciation of painful stimuli). Some clinicians include temperature discrimination as well. These impulses are mediated by poorly myelinated A-delta or unmyelinated C small diameter (0.05–1.0 μm) sensory nerve fibers. The test area is contacted lightly (without indentation) with the tip of a 27-gauge needle (Fig. 10.8). The normal response is that the patient raises the ipsilateral hand when sharp contact is applied and identified as sharp (vs. dull). If the patient gives no response, the test area is again contacted with the needle and the skin or mucosa is indented (but not pierced)

Fig. 10.14 Algorithm for steps in neurosensory testing (NST) of the nerve injury patient who complains of decreased altered sensation. Diagnoses are in bold type



with the needle tip. If the patient responds only at this increased threshold, this is an abnormal response. If the patient fails to respond at the increased threshold, no additional increase in contact pressure is applied to the needle tip, and the result is recorded as “no response.” Alternately, a sharp probe spring-loaded to a strain gauge (algometer) may be used, and the magnitude of the stimulus can be quantified [67]. Measurement of hot and cold temperature sensation can be performed by the application of a heated probe and of ice cubes or frozen liquid-containing spray on a cotton-tipped applicator, respectively. Much easier to use and more accurate but of higher cost are the Minnesota Thermal Disks which confine contact to prevent spread of the stimulus to adjacent areas and provide a definitive measurement of the patient’s response [17]. A vitalometer can be used to assess pain threshold in the mandibular teeth of a patient with an IAN injury (Fig. 10.3).

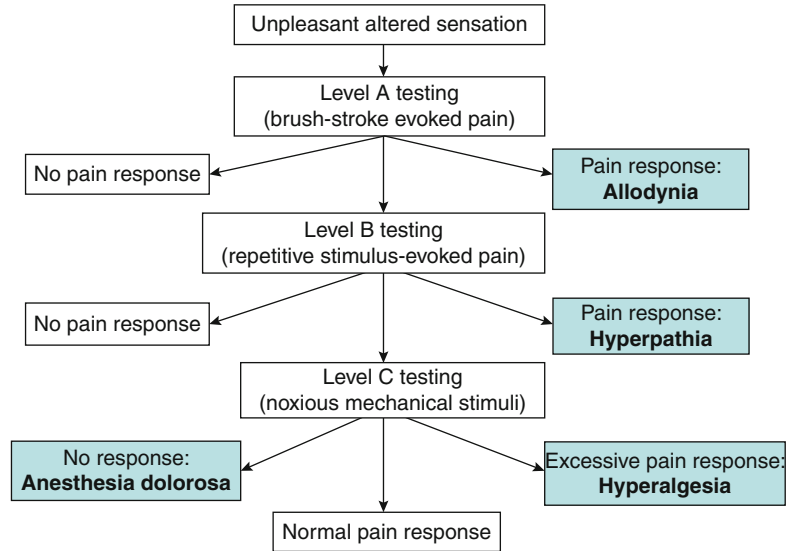
Depending upon the patient’s responses to level A, B, and C testing, the patient with decreased altered sensation will be diagnosed as normal, mild hypoesthesia, moderate hypoesthesia, severe hypoesthesia, or anesthesia (Fig. 10.14). It may be helpful to consider these five levels of results of the clinical NST to correlate with Sunderland’s classification of nerve injury, in the following manner: normal (Sunderland grade I), mild (grade II),

moderate (III), severe (IV), and complete anesthesia (V) (Miloró, 2012, personal communication). In the conscious and cooperative patient who has sustained maxillofacial trauma (fractures, lacerations, missile injuries, blunt injuries), levels B and C testing are done to screen for an injury to one or more branches of the trigeminal nerve [2]. Of course, evaluation for injuries to other cranial nerves in trauma patients is indicated as well. Having this information before the patient is taken to the operating room may modify the surgical approach to trauma repair, and it is a useful baseline of comparison for future follow-up, whether the injured nerve is repaired at the time of initial repair of the other traumatic injuries or at a later date.

10.5.2 Unpleasant Altered Sensation

Similar to the NST for decreased altered sensation, three levels of NST are performed on the patient who complains of unpleasant altered sensation, but the tests and the goals of diagnosis and treatment differ from those of the patient with decreased altered sensation (Fig. 10.15). In contrast to the patient with decreased altered sensation, all levels of testing are completed in the patient with painful altered sensation, regardless of the responses at each level. The aims of these

Fig. 10.15 Algorithm for neurosensory testing (NST) of the patient who complains of unpleasant/painful altered sensation. Pain diagnoses are shown in bold type



tests are to elicit and characterize the types of abnormal pain responses to various stimuli (*hyperesthesia*) that may have implications for diagnosis, treatment, and prognosis [24, 25].

Level A testing for the patient with painful or unpleasant sensation determines whether an innocuous mechanical stimulus (not normally interpreted by the patient as painful) evokes a pain response within the distribution of the injured nerve. In this level A test, the normal contralateral side is stimulated first with a gentle stroke from a cotton wisp, a camel hair brush, or a Semmes-Weinstein monofilament applied to the skin or mucosal surface of the tongue as a control. Then this maneuver is repeated within the abnormal ipsilateral area. Pain evoked in response to this stimulus that is not painful on the control side, and which ceases when the stimulus is withdrawn, is termed *allodynia*, frequently described by the patient as “hypersensitive.” The duration and intensity of the stimulus-evoked pain (patient’s description or use of a VAS) are recorded.

The aim of level B testing is to assess whether the patient has *hyperpathia*, pain that has an onset delayed after the application of the stimulus, increases in intensity with repeated stimuli, and/or continues (aftersensation, afterglow, overshoot) for some time (seconds or minutes) after withdrawal of the stimulus. Any one or more of these three phenomena is diagnostic of a

hyperpathic response. The stimulus is applied repeatedly by gently touching the test area with the wooden end of a cotton swab stick (up to ten applications at a rate of 1/sec). Alternately, the test area can be repetitively stimulated with a Semmes-Weinstein monofilament.

Level C testing evaluates responses to noxious mechanical or thermal stimuli. This test is performed similarly to level C testing for the patient with decreased altered sensation (described above, Sect. 10.5.1). When the noxious stimulus is applied at the normal threshold and the increased threshold, the patient describes a painful sensation (i.e., a light pinprick that seems like an “electric shock,” a “hot poker,” or a “stabbing” sensation) or displays a pain reaction (withdrawal, grimace, utterance of an exclamation) out of proportion to the intensity of the applied stimulus. Such a reaction is classified as *hyperalgesia*. Other than a 27-gauge needle, alternative methods of delivering a noxious stimulus have been described above.

The patient who complains of both numbness and pain as a result of nerve injury and is found to be anesthetic to all levels of testing for decreased altered sensation also might fail to respond to any testing levels for unpleasant altered sensation discussed above. If pain is a prominent and long-standing spontaneous symptom in an area of complete loss or marked reduction of sensory response, not initiated or aggravated by stimuli,

this patient is probably afflicted with *anesthesia dolorosa* [24]. Such pain has a central component and is often accompanied by phantom sensations (e.g., radiations of sensation or pain into the tongue even though the ipsilateral lingual nerve has been severed) [33].

Some patients, following trauma or elective surgery to the face or neck in which a branch of the trigeminal nerve is injured, develop pain elicited or enhanced in response to increased sympathetic nervous system input, exposure to cold, emotional stimuli, and application of normally innocuous stimuli [26]. In such instances, a scar or healed incision when stimulated by gentle stroking with a cotton wisp or monofilament (level A testing) might exhibit blanching accompanied by the patient's complaint of sudden onset of severe pain which might be brief or last beyond withdrawal of the stimulus. This reactive area is often outside the area of altered sensation supplied by the injured trigeminal nerve branch. This is an example of *sympathetic-mediated pain*, which is usually not favorably affected by surgical treatment of the TN5 (see below Sect. 10.5.4).

A diagnosis to be considered, only after all other causes have been ruled out, is that of *psychogenic pain*. Psychogenic pain, however, should never be a "diagnosis of exclusion" or a waste-basket term into which patients whose pain from a nerve injury seems "excessive" or "out of proportion" to the examiner is assigned. This diagnosis should be based upon the clinician's suspicion that the patient may have a psychopathologic disorder underlying the complaint of pain. Although patients afflicted with dysesthesia following a peripheral nerve injury may exhibit personality traits of depression, hypochondriasis, or hysteria when subjected to a personality profile inventory, this does not necessarily mean that the patient's pain is caused by psychological factors [62]. Rather, the patient who is suffering chronic pain may have developed the psychopathologic characteristics *in response* to the long-standing pain. In the patient with psychogenic pain, the complaints of pain are well out of proportion to any responses to NST; the pain seems to cross the midline or otherwise not conform to normal neuroanatomical boundaries; the pain is chronic (at

least 6 months duration), constant, and not relieved by any previous treatment; the patient has consulted with numerous previous practitioners without success; the patient may present with a "clinging" persona who praises the clinician as the only one who can "save" him/her from a dread disease; and there are no physical or imaging findings indicative of pathology [1]. Such patients, if they can be convinced of the need, might find great benefit from psychiatric consultation and counseling.

10.5.3 Diagnostic Nerve Blocks

The patient who complains of unpleasant altered sensation and has documented abnormal responses to NST may be a candidate for a local anesthetic block of the injured peripheral nerve suspected of being the source of pain [10]. In all such instances, the clinician is attempting to establish whether the pain is emanating from the injured peripheral nerve (neuroma), from local collateralization, from regional sympathetic fibers, from the central nervous system, or related to psychological factors (so-called psychogenic pain). In all but the first of these five possibilities, surgical repair of the peripheral nerve will have little or no likelihood of successfully relieving the patient's pain. Even when there is a peripheral nerve injury resulting in the development of a painful neuroma, for example, there may also be a central nervous system component of pain due to the effects of deafferentation [24]. In this instance, removal of the neuroma would not result in complete resolution of the patient's pain. If a successful local anesthetic block of the suspected nerve results in a substantial decrease or abolition of the patient's pain for the duration of the block, this is significant evidence that peripheral factors (i.e., within the injured nerve) are likely the cause of the patient's pain and that the pain *might* be relieved, or significantly reduced in its intensity, by exploration and repair of that nerve. Such is certainly the case with pain characterized as allodynia, hyperpathia, and hyperalgesia, while the results on reduction in pain severity following peripheral nerve operations on patients afflicted with *anesthesia dolorosa* and sympathetic-mediated pain are poor [24].

Unfortunately, in many instances, peripheral nerve surgery performed after local anesthetic nerve blocks have failed to temporarily relieve pain has resulted in an increase in the frequency, duration, and intensity of the patient's painful affliction.

When the decision is made to perform a diagnostic nerve block, the clinician should begin first with the more distal branch(es) of the nerve (e.g., the MN before the IAN; the anterior superior alveolar nerve before the IFN) before proceeding to block the more proximal branches. This protocol enables the examiner to more closely pinpoint the source of pain and if it is relieved by the block (Fig. 10.16). Small amounts of local anesthetic solution should be used initially (0.5–1.0 ml) in order to minimize diffusion to adjacent nerves whenever possible. The initial block should use a relatively short-acting anesthetic (e.g., 1 or 2 % lidocaine without epinephrine). After a reasonable waiting period, the affected tissues should be tested (i.e., pinprick) to ascertain if anesthesia has been achieved. If the block is successful, it can be repeated using a longer-acting agent (e.g., 0.5 % bupivacaine with 1:100,000 epinephrine) for production of several hours of pain relief, if the patient so desires.

If the pain is originating from an injury or previous operation in the face, neck, or upper extremity and the patient has shown localized signs of exaggerated sympathetic nervous system activity (see SMP, above), an ipsilateral stellate ganglion anesthetic block is indicated [30, 31]. Relief of pain after this block is diagnostic of SMP, although the block may have to be repeated more than once to achieve a satisfactory level of pain relief. If the examiner does not routinely perform stellate ganglion blocks, the patient is referred to an anesthesiologist trained in regional anesthesia techniques.

10.5.4 Mapping

Pictorial representation of the results of NST in the patient's record serves as an excellent method of preserving the boundaries of the sensory deficit (so-called mapping). Along with the recording of the patient's responses to the various evaluation

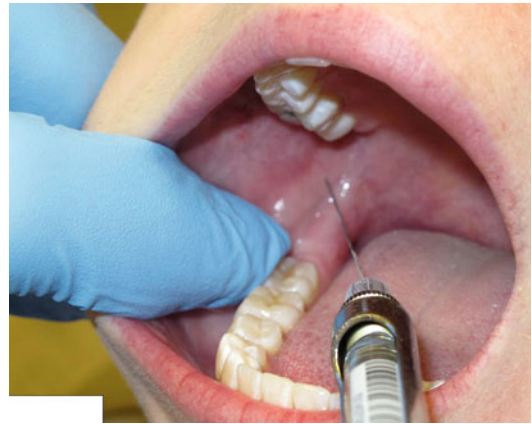

Fig. 10.16 Right IAN block to determine an effect on neuropathic pain in the right mandible. A right mental nerve block, administered just before this, failed to relieve the patient's pain

maneuvers and NST, drawings of the patient's face and oral cavity are used to impose outlines (often in red ink) of the area(s) affected by sensory dysfunction (Fig. 10.17). Various schemes for doing this are reported in the literature [19, 43, 51, 67, 70], and the reader is referred to the "Nerve Injury Examination" form which appears in the Appendix 10.A.2.

Additional documentation in the form of patient photographs with the area of sensory dysfunction outlined can be a valuable addition to the patient's record for use for future comparisons of the change in the area affected [50]. It may be helpful to some patients to be able to visualize in retrospect an area of altered sensation that has decreased in size or completely resolved either spontaneously over time or as the result of surgical intervention (Fig. 10.18).

10.6 Imaging

No evaluation of a trigeminal nerve injury following a traumatic injury, dental procedure, or elective surgical operation in the oral and maxillofacial regions is complete without appropriate imaging of the structures in the vicinity of the injury. Depending upon the indications and need for additional diagnostic information, plain films,

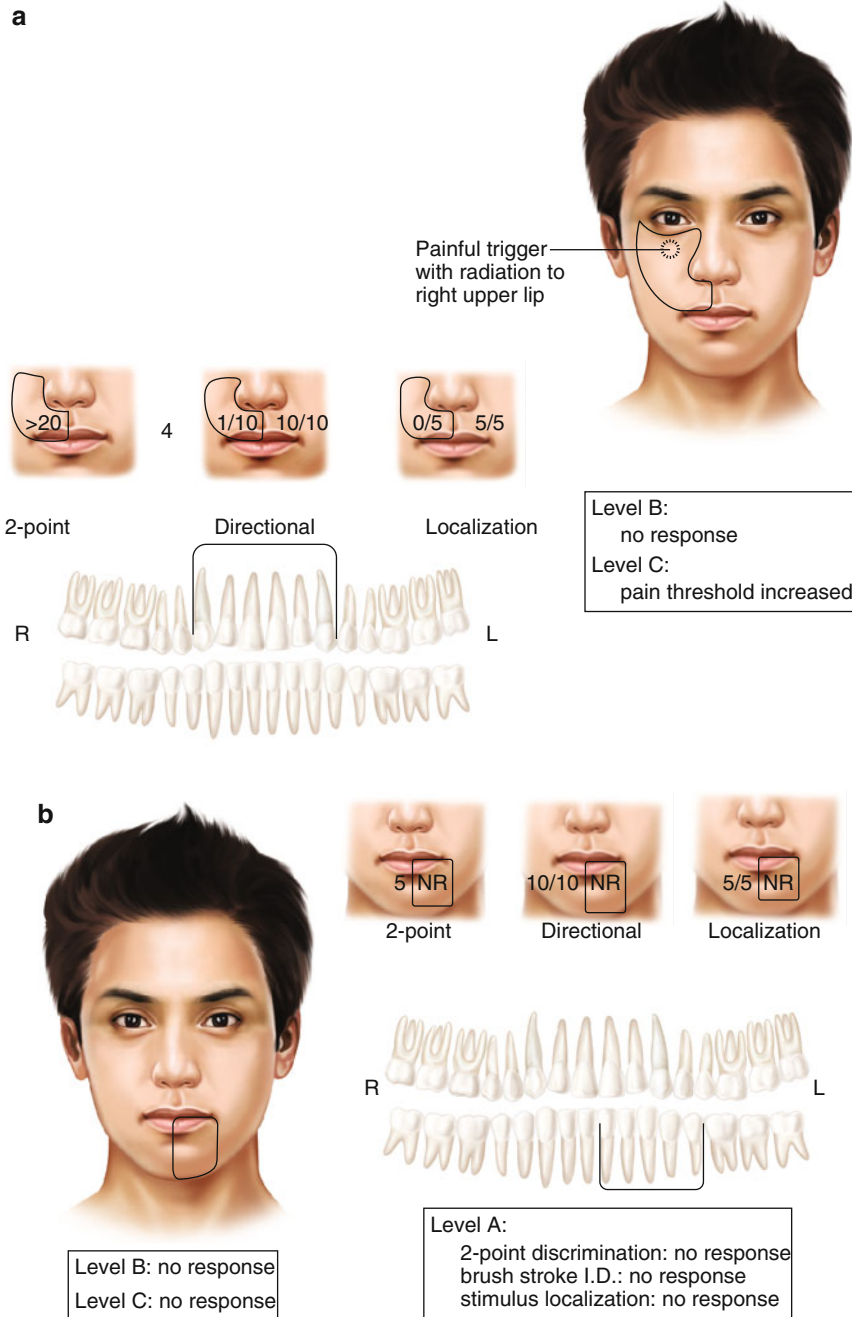


Fig. 10.17 The area of altered sensation and the results of NST are entered into the patient’s record. The printed diagrams are in Appendix 10.A.2. (a) Patient with numbness and pain in the right face 6 months following a right ZMC fracture involving the right orbital floor and inferior orbital rim. Affected areas of face and mouth contained within *solid black line* and there is severe hypoesthesia of the right infraorbital nerve. (b) Patient with loss of sensation in the left lower lip, chin, and left mandibular gingiva (affected areas contained within *solid black line*) 4 months

after BSSO. Immediate postoperative sensory loss on the right side has resolved. There is anesthesia of the left IAN. (c) Patient with numbness of the right tongue 3 months after removal of the mandibular right third molar. There are also complaints of pain in right tongue and lingual gingiva when chewing food and brushing the right lower teeth. Affected areas contained within *solid black line*. Note the trigger area on lingual aspect of right mandible. The patient has anesthesia of the right lingual nerve. NR no response

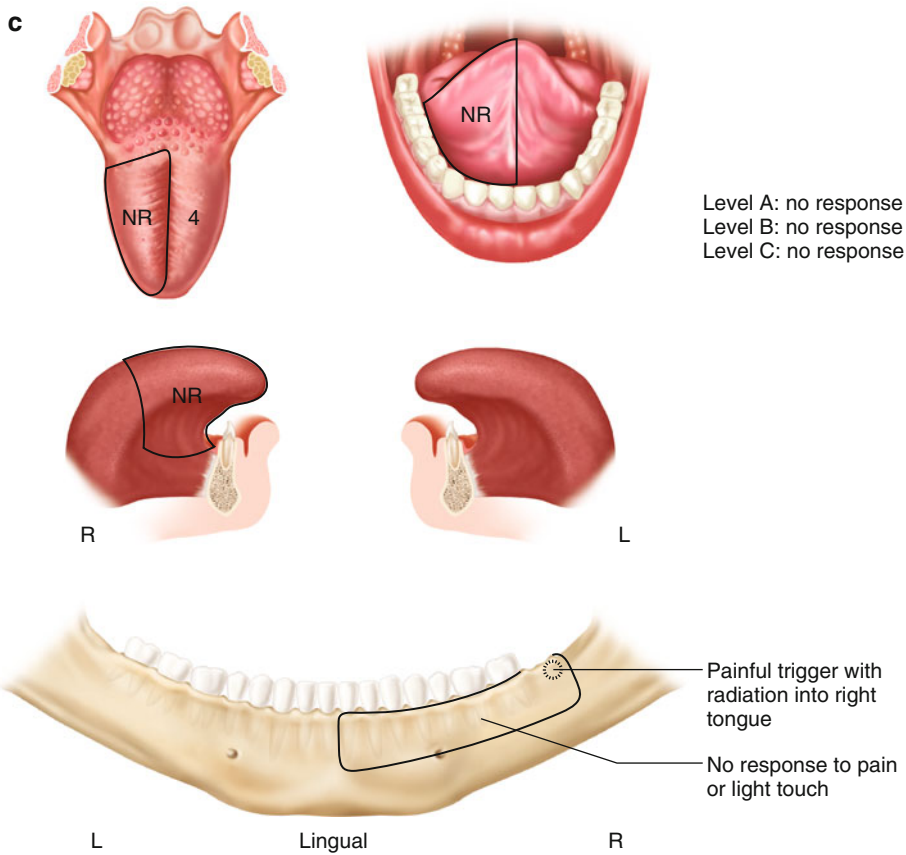


Fig. 10.17 (continued)

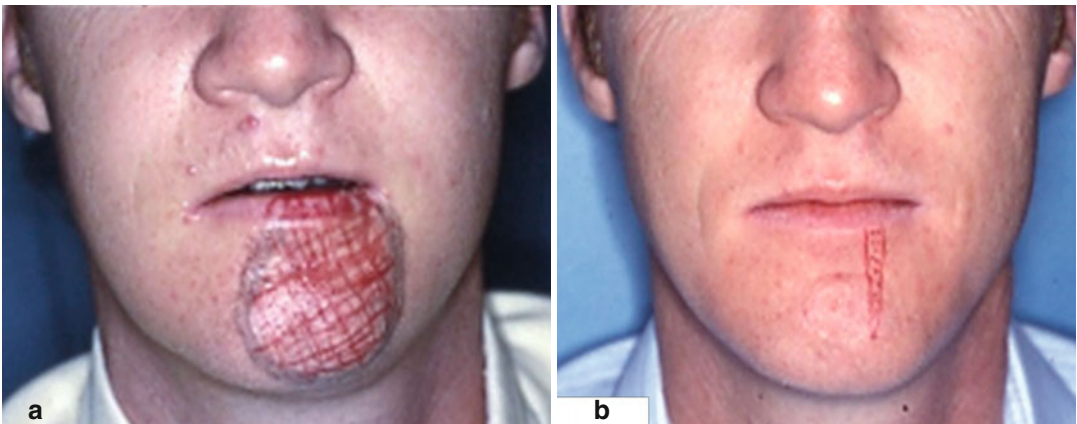


Fig. 10.18 A 33-year-old male who sustained a left mental nerve severance during a genioplasty. The nerve injury was not repaired at the time of surgery. (a) Area of total sensory loss outlined on left lower lip and chin 6 weeks following original surgery. (b) Subsequently, the left mental nerve was repaired with a neurorrhaphy. Six months

following nerve repair, only a small area of altered sensation remains. Within the outlined area, the patient responded normally to painful stimuli and to light touch at a threshold greater than the normal right side. Two-point discrimination threshold in the left lower lip was 10 mm, compared to 5 mm on the normal right side

panoramic imaging, computed tomography, or magnetic resonance imaging may be included in the radiographic evaluation. Basic imaging studies are often helpful in the assessment of the patient with a trigeminal nerve injury, and once an abnormality is seen on a plain film, additional images (e.g., cone-beam computed tomography (CBCT)) may be indicated. Examples of information obtained from imaging studies that can be helpful in the assessment of nerve-injured patients are shown in Fig. 10.19. These significant findings may include retained roots, retention of foreign bodies (e.g., broken instruments), mandible fracture, fixation plates and screws, and iatrogenic injuries from rotary instruments which may be in proximity to the IAN or LN. For further discussion of imaging, the reader is referred to Chap. 11.

10.7 Diagnosis and Classification

Following the data gathering and correlation of all the clinical information obtained from the initial NST evaluation presented above, the clinician should be able to establish a diagnosis of the extent and severity of the sensory deficit. The level of sensory impairment is identified at the appropriate stage along a continuum from mild hypoesthesia to complete loss of sensation (anesthesia). Painful injuries are designated as being due to peripheral factors (and as such, potentially amenable to surgical intervention), to sympathetic nervous system input (SMP), to central nervous system conditions (e.g., deafferentation), or to psychogenic factors. However, if the injured nerve was not directly observed at the time of injury, it may be necessary to see the

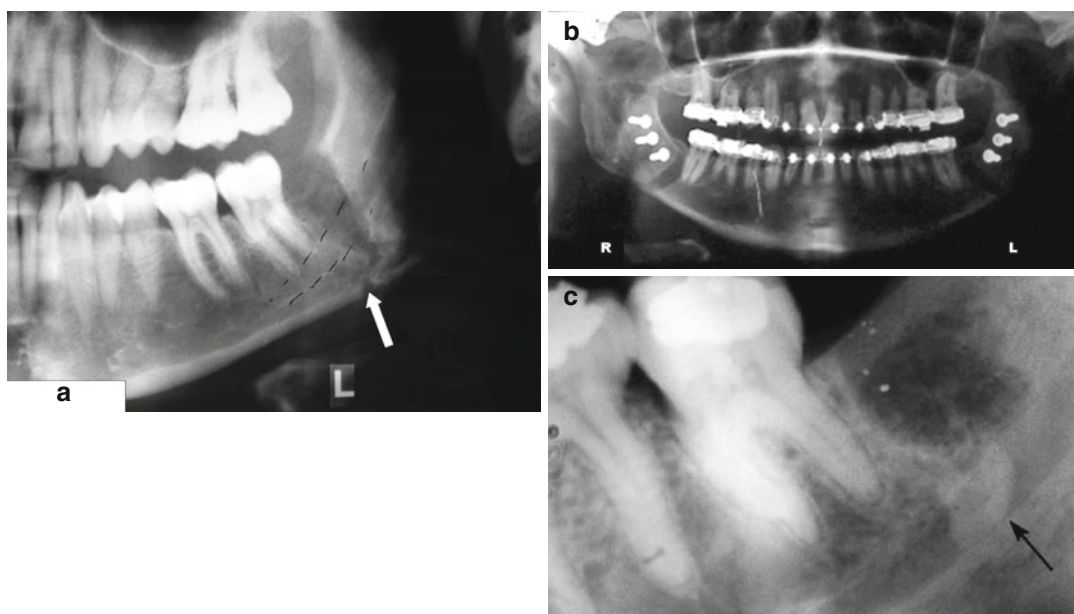


Fig. 10.19 (a) A patient with numbness and pain in the left lower lip and jaw several weeks following removal of a left mandibular third molar. The panoramic film shows a non-displaced fracture (*white arrow*) traversing the extraction socket and the left IAC (parallel interrupted *black lines*). The fracture was repaired, and the patient spontaneously regained normal left lower lip sensation within 3 months. (b) After BSSO, this patient regained normal sensation in the left lower lip and chin within 6 weeks. At 3 months after surgery, severe hypoesthesia and allodynia were observed in the right lower lip. Panorex shows three

internal fixation screws superimposed over the right IAC. A CBCT is indicated to assess the relationship of the fixation screws to the right IAC. (c) Removal of a mandibular left third molar was incomplete, but the surgeon elected to leave the remaining root fragment in situ, and the patient experienced persistent numbness in the left lower lip after 1 year and sought another opinion. Plain film shows retained root fragment (*arrow*) superimposed upon the left IAC. A CBCT is indicated to ascertain the position of the root fragment in relation to the left IAC before deciding about the necessity for its removal

Table 10.2 Comparison of Seddon^a and Sunderland^b classifications of peripheral nerve injuries

| Seddon/Sunderland | Neurapraxia grade I | Axonotmesis II, III, IV | Neurotmesis V | VI ^c |
|------------------------|-----------------------|-------------------------|---------------------|-------------------|
| Nerve sheath | Intact | Intact | Interrupted | Mixed injury |
| Axons | Intact | Some are interrupted | All are interrupted | Mixed injury |
| Wallerian degeneration | None | Yes, some axons | Yes, all axons | Yes, some axons |
| Conduction failure | Transitory (<4 weeks) | Prolonged (months) | Often permanent | Variable duration |

^aSeddon [54]^bSunderland [57]^cMackinnon and Dellon [38]

patient for subsequent re-evaluations to determine the classification of the nerve injury as it evolves over time. The classification of the injury is helpful to the clinician in making *timely decisions* regarding treatment intervention.

One classification of peripheral nerve injuries that is useful to clinicians is the *Seddon* classification. Sir Herbert J. Seddon (1903–1977) was a British orthopedic surgeon who gained extraordinary clinical experience in the treatment of missile-induced nerve injuries of the extremities during, and after, World War II [32]. His classification scheme is based upon clinical factors [54]. Reflecting his astuteness as a clinician, he emphasized the importance of timing in the surgical intervention of injured peripheral nerves, when he famously wrote in 1947, “If a purely expectant policy is pursued, the most favorable time for operative intervention will always be missed...” [55].

Another frequently referenced classification system of peripheral nerve injuries is that of Sunderland, a contemporary of Seddon. Sunderland’s classification scheme is based upon histopathology of nerve injury and, as such, is of more interest to neuroanatomists, neurophysiologists, and researchers and includes five grades of nerve injury [57]. A sixth degree of injury that describes a mixed combination of Sunderland’s five degrees of injury was added subsequently [38]. The two classification systems are compared in Table 10.2. For a complete discussion of the classification of trigeminal nerve injuries, the reader is referred to Chap. 2.

After establishing a diagnosis of the nature and extent of the sensory deficit and assignment of the appropriate classification to the nerve injury, the clinician will be able to make

decisions regarding the need for treatment and the nature (surgical or nonsurgical) and timing of that treatment. A standardized classification system also permits clear communication between practitioners. Guidelines for treatment of nerve injuries are fully explored in Chap. 20.

10.8 Summary

This chapter has presented a method of clinical evaluation of the patient with a trigeminal nerve injury that is utilized by various surgical disciplines involved in nerve injury management. The diagnostic maneuvers presented have been shown by experience and investigation to be reliable and reproducible, and they are well within the capability of any clinician, regardless of whether or not he/she is a nerve injury specialist. The armamentarium required is readily available in most practitioners’ offices. This method provides subjective, semi-objective, and objective neurosensory information that is used to arrive at a diagnosis (assessment of the degree of sensory dysfunction) and classification of the nerve injury that will enable the clinician to make appropriate and timely decisions regarding treatment.

Additional methods of evaluating nerve function are available, although these are used primarily in basic science and clinical research rather than in clinical practice. The interested reader is encouraged to peruse the appropriate references for additional information on this important aspect of evaluation of peripheral nerve function [12, 19, 21, 35, 40, 46, 56, 65, 68].

Appendices

A.1 Nerve Injury History

NERVE INJURY HISTORY

Patient: _____ Age: _____ Date: _____

Please complete answers to the following questions (pages 1-3). Add any comments you feel are important. This information will be reviewed with you by your surgeon and will be very helpful in evaluating your nerve injury.

1. Do you have altered, abnormal, unpleasant or absent sensation (feeling) in your face, mouth, jaws or neck? Circle which: YES NO If YES, circle below all that apply:

| Right | Left | Both sides | | |
|-------------|------------|------------|--------|--------|
| forehead | eyebrow | ear | nose | tongue |
| upper lip | cheek | face | chin | teeth |
| lower lip | upper gums | lower gums | palate | mouth |
| other _____ | | | | |

2. What is your most distressing or bothersome symptom? (circle which)

LOSS of FEELING (numbness) PAIN BOTH (pain and numbness)

3. Which of the following symptoms describe(s) your complaint? (Circle all that apply; add any others which you feel are pertinent to your condition):

| | | | |
|-----------|---------------|----------------|--------------|
| numb | stretched | itching | tender |
| tickling | swollen | pricking | sore |
| tingling | wooden | stinging | painful |
| twitching | crawling | electric shock | burning |
| wet | vibrating | icy cold | excruciating |
| rubbery | drawing | hot | |
| cool | pulling | | |
| warm | others? _____ | | |

4. If you have a painful condition, is it (circle which):

CONSTANT INTERMITTENT

If it is INTERMITTENT, is it (check which) ???

Spontaneous in onset

Evoked or initiated by STIMULI (if so, circle which ones below):

| | | |
|---------------------------------|----------------|----------|
| touch | brushing teeth | drinking |
| face washing | smoking | speaking |
| shaving | kissing | smiling |
| placing make-up or lipstick | | singing |
| playing wind musical instrument | | |
| others _____ | | |

If the pain is intermittent, how long does it last? (circle which):

seconds minutes hours days

If you are in pain NOW, estimate how bad it is on the scale below (circle the number):

0 ___ 1 ___ 2 ___ 3 ___ 4 ___ 5 ___ 6 ___ 7 ___ 8 ___ 9 ___ 10

[0 = no pain; 5 = moderate pain; 10 = worst pain you have ever experienced]

Does anything relieve your pain? If YES, what? _____

5. Was there dental or surgical treatment associated with the onset of your symptoms?

Circle which: YES NO If YES, please indicate what was done:

Local anesthetic injections. If so, was there severe pain or shock? YES NO

Removal of impacted wisdom teeth

Osteotomy or other surgery for jaw deformity

Dental implants

Root canal filling

Facial or jaw fractures or other facial injuries

Other _____

Name of surgeon or dentist _____ Address _____

_____ Tele. no. _____

When did you symptoms begin (date)? _____

6. Since the onset of your symptom, what has been your progress? (check which):

- No change
- Minimal improvement
- Marked improvement
- Minimal worsening or increase
- Marked worsening or increase

7. Have you experienced or are you experiencing any of the following impairments because of your nerve injury? If so, check all that apply (x) and note the level of impairment using the following scale:

1 = minimal interference with normal activity

2 = moderate (50%) interference

3 = total or nearly total interference

Impairment (1, 2, 3)

- _____ Lip, cheek, tongue biting (circle which)
- _____ Burning of lip or tongue (circle which) with hot liquids/food
- _____ Drooling/dribbling of fluids, saliva, food
- _____ Difficulty chewing food
- _____ Difficulty drinking/swallowing liquids or food
- _____ Loss, decreased, altered taste sensation
- _____ Difficulty speaking/singing
- _____ Difficulty smiling, laughing, frowning
- _____ Difficulty sleeping
- _____ Difficulty with toothbrushing, using dental floss
- _____ Difficulty applying make-up, lipstick
- _____ Difficulty shaving, washing your face
- _____ Difficulty playing wind musical instruments

Thank you for completing this evaluation form. Your answers will be reviewed and discussed further with you by your surgeon during your examination. Please sign your name below:

Name: _____ Date _____

(patient/guardian or parent)

Reviewed by _____, MD, DMD, DDS Date _____

A.2 Nerve Injury Examination

Name _____ Date _____

Referred by _____ Address _____
Tele. no. _____

Chief Complaint:

H.P.I:

B.P: / P: /min R.: /min T: Wt. lbs. Ht. ' "

| | <u>WNL</u> | <u>Abnormal</u> | | <u>Cranial Nerves</u> |
|-------|------------|-----------------|-------|-----------------------|
| Head | () | () | _____ | I: _____ |
| TMJ's | () | () | _____ | II: _____ |
| Eyes | () | () | _____ | III: _____ |
| Ears | () | () | _____ | IV: _____ |
| Nose | () | () | _____ | V: _____ |
| Neck | () | () | _____ | VII: _____ |
| | | | | VIII: _____ |
| | | | | IX: _____ |
| | | | | X: _____ |
| | | | | XI: _____ |
| | | | | XII: _____ |

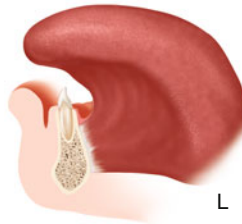
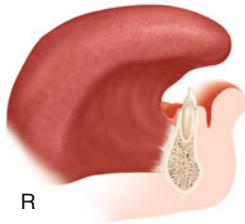
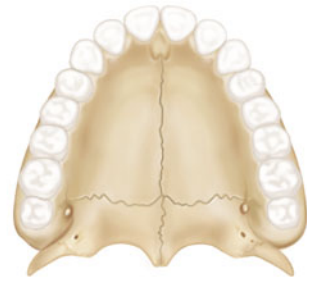
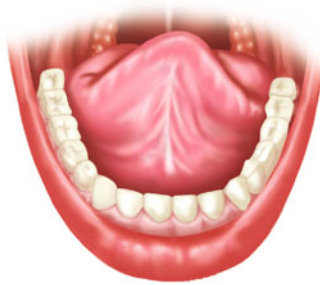
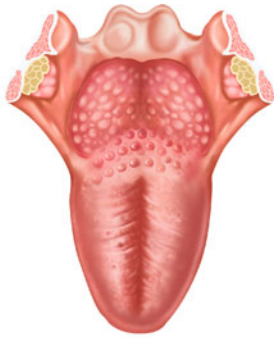
Pain: () normal; () increased; () NR

Allodynia Hyperpathia Hyperalgesia

Light touch:

Rt: _____ Lt: _____



Vitalometer
Tooth # Reading

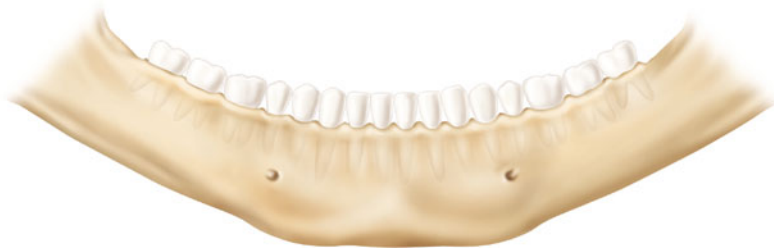
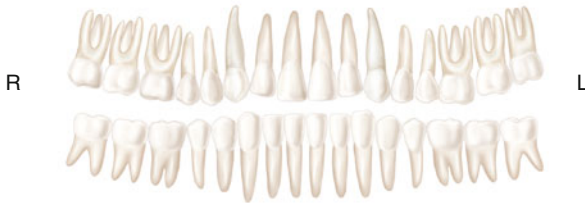
X-rays

2-point

Directional

Localization



L

Lingual

R

Nerve Injury Examination

Local anesthetic block of Anesth. Solution/amount Result

DIAGNOSIS

| <u>R</u> | <u>L</u> | <u>Nerve</u> | <u>Classification (if known)</u> | <u>Prognosis</u> |
|----------|----------|---------------|----------------------------------|------------------|
| _____ | _____ | Mental | | |
| _____ | _____ | Inf. Alveolar | | |
| _____ | _____ | Lingual | | |
| _____ | _____ | Long buccal | | |
| _____ | _____ | Infraorbital | | |
| _____ | _____ | _____ | | |

() Sensory loss

() Unpleasant sensation

| <u>R</u> | <u>L</u> | | <u>R</u> | <u>L</u> | |
|----------|----------|-----------------------|----------|----------|--------------|
| _____ | _____ | Hypoesthesia () mild | _____ | _____ | Sympath Med |
| | | () moderate | _____ | _____ | Anesth Dolor |
| | | () severe | _____ | _____ | Psychogenic |
| _____ | _____ | Anesthesia | _____ | _____ | Neuroma |

RECOMMENDATIONS:

- () No further observations/treatment indicated
 - () Observation/reevaluation in _____ weeks/months
 - () Sensory reeducation exercises for _____, __ times daily x _____ months
 - () Medications: _____
 - () Microneurosurgery on _____ nerve(s)
 - () _____
- () Report to be sent to Dr. _____ () dictated, _____ (date)

Examined by: _____, DMD, DDS, MD Date _____

References

- American Psychiatric Association (2000) Diagnostic and statistical manual of mental disorders, 3rd edn. American Psychiatric Association, Arlington
- Bagheri SC, Meyer RA, Ali Khan H et al (2009) Microsurgical repair of trigeminal nerve injuries from maxillofacial trauma. *J Oral Maxillofac Surg* 67:1791–1799
- Bagheri SC, Meyer RA, Ali Khan H et al (2010) Retrospective review of microsurgical repair of 222 lingual nerve injuries. *J Oral Maxillofac Surg* 68:715–723
- Bagheri SC, Meyer RA, Ali Khan H et al (2010) Microsurgical repair of the peripheral trigeminal nerve after mandibular sagittal split ramus osteotomy. *J Oral Maxillofac Surg* 68:2770–2782
- Bagheri SC, Meyer RA, Cho SH et al (2012) Microsurgical repair of the inferior alveolar nerve: success rate and factors which adversely affect outcome. *J Oral Maxillofac Surg* 70(8):1978–1990
- Baker SB, Foote JW, DiNick V (1995) Gustatory recovery in microsurgical repair of the lingual nerve. *J Oral Maxillofac Surg* 53:137
- Birch R, Bonney G, Wynn Parry CB (1998) Surgical disorders of the peripheral nerves. Churchill Livingstone, Edinburgh, Scotland, UK
- Bornstein WS (1940) Cortical representation of taste in man and monkey II. The localization of the cortical test area in man and method of measuring impairment of taste in man. *Yale J Biol Med* 13:133
- Boyne PJ (1982) Postexodontia osseous repair involving the mandibular canal. *J Oral Maxillofac Surg* 40:69–77
- Campbell RL (1992) The role of nerve blocks in the diagnosis of traumatic trigeminal neuralgia. *Oral Maxillofac Surg Clin North Am* 4:369–374
- Campbell RL, Shamaskin RG, Harkins SW (1987) Assessment of recovery from injury to inferior alveolar and mental nerves. *Oral Surg Oral Med Oral Pathol* 64:519
- Colin W (1993) Conduction velocity of the human inferior alveolar nerve: a preliminary report. *J Oral Maxillofac Surg* 51:1018–1023
- Cooper BY, Sessle BJ (1992) Anatomy, physiology, and pathophysiology of trigeminal system paresthesias and dysesthesias. *Oral Maxillofac Surg Clin North Am* 4:297–322
- Cunningham LL, Tiner BD, Clark GM et al (1996) A comparison of questionnaire versus monofilament assessment of neurosensory deficit. *J Oral Maxillofac Surg* 54:454–459
- Dellon AL (2002) The relationship of facial two-point discrimination to applied force under clinical test conditions (discussion). *Plast Reconstr Surg* 109:953–955
- Dellon AL, Andonian E, DeJesus RA (2007) Measuring sensibility of the trigeminal nerve. *Plast Reconstr Surg* 120:1546–1550
- Dyck PJ, Curtis DJ, Bushek W et al (1974) Description of “Minnesota Thermal Disks” and normal values of cutaneous thermal discrimination in man. *Neurology* 24:325–330
- Dykes RW (1984) Central consequences of peripheral nerve injuries. *Ann Plast Surg* 13:412
- Essick GK (1992) Comprehensive clinical evaluation of perioral sensory function. *Oral Maxillofac Surg Clin North Am* 4:503–526
- Essick GK, Patel S, Trullsson M (2002) Mechanosensory and thermosensory changes across the border of impaired sensitivity to pinprick after mandibular nerve injury. *J Oral Maxillofac Surg* 60:1250–1266
- Frank ME, Hettinger TP, Clive JM (1995) Currents methods in measuring taste. In: Doty RL (ed) *Handbook of olfaction and gustation*. Marcel Dekker, New York
- Ghali GE, Epker BN (1989) Clinical neurosensory testing: practical applications. *J Oral Maxillofac Surg* 47:1074–1078
- Girod SC, Neukam FW, Girod B et al (1989) The fascicular structure of the lingual nerve and the chorda tympani: an anatomical study. *J Oral Maxillofac Surg* 47:607–609
- Gregg JM (1990) Studies of traumatic neuralgia in the maxillofacial region: symptom complexes and response to microsurgery. *J Oral Maxillofac Surg* 48:135–140
- Gregg JM (1990) Studies of traumatic neuralgia in the maxillofacial region: surgical pathology and neural mechanisms. *J Oral Maxillofac Surg* 48:228–237
- Gregg JM (1992) Abnormal responses to trigeminal nerve injury. *Oral Maxillofac Surg Clin North Am* 4:339–351
- Gregg JM (1996) A comparison of questionnaire versus monofilament assessment of neurosensory deficit (discussion). *J Oral Maxillofac Surg* 54:459–460
- Hillerup S (2000) Taste perception after lingual nerve repair (discussion). *J Oral Maxillofac Surg* 58:5–6
- Hillerup S, Hjørtting-Hansen E, Reumert T (1994) Repair of the lingual nerve after iatrogenic injury: a follow-up study of return of sensation and taste. *J Oral Maxillofac Surg* 52:1028–1031
- Hobbins W (1988) RSD and thermography. *Reflex Sympath Dystrophy Assoc Digest* 1:1–16
- Jaeger B, Singer E, Kroening R (1986) Reflex sympathetic dystrophy of the face. *Arch Neurol* 43:693–695
- James JIP (1978) Obituaries: Sir Herbert Seddon 1903–1977. *Int Orthop* 2:275–276
- Jensen TS, Krebs B, Nielsen J et al (1983) Phantom limbs, phantom pain and stump pain in amputees during the first six months following limb amputation. *Pain* 17:243
- Johnson KO, Philips JR (1981) Tactile spatial resolution: I. Two-point discrimination, gap detection, grating resolution and letter recognition. *J Neurophysiol* 46:1177
- Jones DL, Thrash WJ (1992) Electrophysical assessment of human inferior alveolar nerve function. *J Oral Maxillofac Surg* 50:581–585
- Kesarwani A, Antonyshyn O, Mackinnon SE et al (1989) Facial sensibility testing in the normal and posttraumatic population. *Ann Plast Surg* 22:416–425

37. Mackinnon SE, Dellon AL (1985) Two-point discrimination test. *J Hand Surg* 10:906
38. Mackinnon SE, Dellon AL (1988) *Surgery of the peripheral nerve*. Thieme Medical Publishers, New York
39. McDonald AR (1998) The accuracy of clinical neurosensory testing for nerve injury diagnosis (discussion). *J Oral Maxillofac Surg* 56:8
40. McDonald AR, Pogrel MA (2001) The use of magnetic source imaging to examine neurosensory function after dental trauma. *Oral Maxillofac Surg Clin North Am* 13:325–330
41. Meyer RA (1990) Studies of traumatic neuralgia in the maxillofacial region: symptom complexes and response to microsurgery (discussion). *J Oral Maxillofac Surg* 48:141
42. Meyer RA (1992) Applications of microneurosurgery to the repair of trigeminal nerve injuries. *Oral Maxillofac Surg Clin North Am* 4:405–416
43. Meyer RA, Bagheri SC (2011) Clinical evaluation of peripheral trigeminal nerve injuries. *Atlas Oral Maxillofac Surg Clin North Am* 19:15–33
44. Miller IJ (1995) Anatomy of the peripheral taste system. In: Doty RL (ed) *Handbook of olfaction and gustation*. Marcel Dekker, New York
45. Phillips C, Essick G, Zuniga J et al (2006) Qualitative descriptors used by patients following orthognathic surgery to portray altered sensation. *J Oral Maxillofac Surg* 64:1751–1760
46. Pogrel MA (1992) Trigeminal evoked potentials and electrophysical assessment of the trigeminal nerve. *Oral Maxillofac Surg Clin North Am* 4:535–541
47. Poort LJ, van Neck JW, van der Wal KGH (2009) Sensory testing of inferior alveolar nerve injuries: a review of methods used in prospective studies. *J Oral Maxillofac Surg* 67:292–300
48. Posnick JC, Grossman JAI (2000) Facial sensibility testing: a clinical update. *Plast Reconstr Surg* 106:892–894
49. Posnick JC, Zimble AG, Grossman JAI (1990) Normal cutaneous sensibility of the face. *Plast Reconstr Surg* 86:429–433
50. Robinson PP (1988) Observations on the recovery of sensation following inferior alveolar nerve injuries. *Br J Oral Maxillofac Surg* 26:117
51. Robinson RC, Williams CW (1986) Documentation method for inferior alveolar and lingual nerve paresthesias. *Oral Surg Oral Med Oral Pathol* 6:128–131
52. Schwartzman RJ, Grothusen J, Thomas R et al (2001) Neuropathic central pain: epidemiology, etiology and treatment options. *Arch Neurol* 58:1547–1551
53. Scrivani SJ, Moses M, Donoff RB et al (2000) Taste perception after lingual nerve repair. *J Oral Maxillofac Surg* 58:3–5
54. Seddon HJ (1943) Three types of nerve injury. *Brain* 66:237–288
55. Seddon HJ (1947) Nerve lesions complicating certain closed bone injuries. *J Am Med Assoc* 135:691–694
56. Smith SJM (1998) Electrodiagnosis. In: Birch R, Bonney G, Wynn Parry CB (eds) *Surgical disorders of the peripheral nerves*. Churchill Livingstone, Philadelphia
57. Sunderland S (1951) A classification of peripheral nerve injuries produced by loss of function. *Brain* 74:491–516
58. Upton GL, Rajvanakarn M, Hayward JR (1987) Evaluation of the regenerative capacity of the inferior alveolar nerve following surgical trauma. *J Oral Maxillofac Surg* 45:212–216
59. Vriens JPM, van der Glas HW (2002) The relationship of facial two-point discrimination to applied force under clinical test conditions. *Plast Reconstr Surg* 109:943–952
60. Vriens JPM, van der Glas HW (2009) Extension of normal values on sensory function for facial areas using clinical tests on touch and two-point discrimination. *Int J Oral Maxillofac Surg* 38:1154–1158
61. Waller A (1850) Experiments on the section of the glossopharyngeal and hypoglossal nerves of the frog, and observations of the alterations produced thereby in the structure of their primitive fibres. *Phil Trans Roy Soc Lond* 140:423–429
62. Walter JM, Gregg JM (1979) Analysis of postsurgical neurologic alteration in the trigeminal nerve. *J Oral Surg* 37:410–414
63. Weinstein S (1962) Tactile sensitivities of the phalanges. *Percept Mot Skills* 14:351–354
64. Zicardi VB, Steinberg M (2007) Timing of trigeminal nerve microsurgery: a review of the literature. *J Oral Maxillofac Surg* 65:1341–1345
65. Ziccardi VB, Dragoo J, Eliav E et al (2012) Comparison of current perception threshold testing to clinical sensory testing for lingual nerve injuries. *J Oral Maxillofac Surg* 70:289–294
66. Zuniga JR (1990) Studies of traumatic neuralgias in the maxillofacial region: surgical pathology and neural mechanisms (discussion). *J Oral Maxillofac Surg* 48:238–239
67. Zuniga JR, Essick GK (1992) A contemporary approach to the clinical evaluation of trigeminal nerve injuries. *Oral Maxillofac Surg Clin North Am* 4:353–367
68. Zuniga JR, Hegtvedt AK, Alling CC (1992) Future applications in the management of trigeminal nerve injuries. *Oral Maxillofac Surg Clin North Am* 4:543–554
69. Zuniga JR, Chen N, Phillips CL (1997) Chemosensory and somatosensory regeneration after lingual nerve repair in humans. *J Oral Maxillofac Surg* 55:2–13
70. Zuniga JR, Meyer RA, Gregg JM et al (1998) The accuracy of neurosensory testing for nerve injury diagnosis. *J Oral Maxillofac Surg* 56:2–8

Michael Miloro and Antonia Kolokythas

11.1 Introduction

The clinical neurosensory testing of the patient who sustains an injury to the lingual nerve or inferior alveolar nerve is comprised of both objective tests and subjective tests. It has been suggested that there are no “purely” objective testing modalities available for the evaluation of iatrogenic injuries to the terminal branches of the trigeminal nerve, and this makes the clinical diagnosis and management of these conditions complex for the clinician. All available clinical neurosensory testing modalities require patient cooperation and are based upon a patient response, thus introducing a subjective component to the testing protocol. Furthermore, all testing is commonly performed following the nerve injury, so no individual baseline testing results are available for comparison and true determination of the

magnitude of the resultant damage for each individual patient. For objective radiographic assessment, a number of imaging modalities are available to assist in the preoperative risk assessment of the trigeminal nerve, as related the commonly performed procedures in the vicinity of the nerve, mostly third molar surgery. In addition, these studies may be applied for objective functional monitoring of either spontaneous or surgically assisted recovery of the inferior alveolar (IAN) and lingual (LN) nerves. This chapter will provide a review of all currently available imaging modalities and their clinical application relative to the preoperative nerve injury risk assessment, and post-injury and postsurgical repair status of the IAN and LN.

11.2 General Considerations

Since the LN and IAN are at risk for injury during a variety of common oral and maxillofacial surgical procedures, including third molar removal, interest in documenting the position of these specific nerves prior to surgery has been significant. Early attempts at documenting the position of the LN in the third molar region have included cadaveric dissections and clinical observations during third molar extraction surgery. These studies suffer from a variety of methodological problems including the potential for iatrogenic displacement of the nerves during the surgical dissection (in both the cadaveric studies and the clinical trials), as well as artifacts from

M. Miloro, DMD, MD, FACS (✉)
Department of Oral and Maxillofacial Surgery,
University of Illinois at Chicago,
801 S. Paulina Street, MC 835, Chicago, IL 60612, USA
e-mail: mmiloro@uic.edu

A. Kolokythas, DDS, MS
Department of Oral and Maxillofacial Surgery,
University of Illinois at Chicago,
801 S. Paulina Street, MC 835, Chicago, IL 60612, USA
Cancer Center, University of Illinois at Chicago,
801 S. Paulina Street, MC 835, Chicago, IL 60612, USA
e-mail: ga1@uic.edu

the cadaveric specimen fixation process. Despite these limitations, Kisselbach and Chamberlain reported the position of the LN in the third molar region in 34 cadaver specimens and 256 cases of third molar extraction. This study found that in 17.6 % of cadaver specimens, and in 4.6 % of clinical cases, the LN was superior to the lingual crest, and in 62 % of cases, the LN was in direct contact with the lingual cortex. In another anatomic study, Pogrel et al. examined the LN position in the third molar region using reproducible landmarks in 20 cadavers (40 sides) and found the LN above the lingual crest in 15 % of cases and a mean horizontal distance from the lingual crest of 3.45 mm. Both of these anatomic studies confirmed the relative vulnerable position of the LN during third molar surgery.

Objective, noninvasive, radiologic imaging modalities in the preoperative assessment of the patient at risk for nerve injury as well as a method for monitoring following injury and post-repair phases of neurosensory recovery are clinically desirable. Radiologic assessment should be categorized with regard to the timing of the imaging period, that is, pre-injury, post-injury, and post-repair phases. Pre-injury assessment refers to the documentation of the in situ position of a nerve prior to any surgical intervention that may place that nerve at risk for iatrogenic injury (e.g., third molar removal). Intraoperative monitoring of nerve function during a surgical procedure (e.g., sagittal split mandibular osteotomy) that involves a specific nerve may also be used, most commonly with a functional assessment of nerve conduction and electrophysiological status, such as with somatosensory evoked potentials. These testing devices are not readily available and are generally reserved for research purposes and not routine clinical testing. Post-injury imaging may be divided into a primary phase (following nerve injury and allowing for spontaneous neurosensory recovery without microneurosurgical intervention) and a secondary phase (following surgical nerve exploration and microneurosurgical repair). Primary post-injury imaging may be clinically significant if it can correlate objective (radiologic) findings with subjective (clinical examination) findings, and thereby guide the need for microneurosurgical intervention, and possibly aid in

treatment planning (i.e., accurate determination of the length of altered neural anatomy and the need for an interpositional nerve graft or direct neuro-rhaphy). In general, based upon clinical neurosensory testing, an attempt is made to classify the injury according to one or more classification schemes. The classification systems of Seddon and Sunderland are based upon histological assessment of nerve injury and are intended to serve as prognostic indicators of the potential for spontaneous neurosensory recovery.

There have been several reports of intraoperative nerve monitoring specifically during LeFort osteotomy (V_2 division) and mandibular sagittal split ramus osteotomy (V_3 division) procedures. These studies have utilized somatosensory evoked potentials to document the transient increased latency and decreased amplitude of signal activity that occurs during surgical manipulation of the nerve during the osteotomy procedures. Somatosensory evoked potentials can be used as a post-injury or post-repair test, to document the degree of neural injury and to monitor the progression of neurosensory recovery over time.

11.3 Preoperative Radiologic Risk Assessment of the IAN and LN

11.3.1 Panoramic Radiography

The preoperative assessment of the position of the IAN during third molar consultation has been routinely performed with the use of a panoramic radiograph. Obviously, the information obtained from this study is limited due to the two-dimensional nature of the image, the variable magnification of the bony anatomy (for the IAN), and the inability to visualize the position of the lingual nerve. It should be kept in mind that this radiograph demonstrates the position of the inferior alveolar canal (IAC), and not the IAN, specifically. Valuable information can be obtained from the panoramic radiograph as a sole imaging modality with regard to the relationship of the IAN in the vertical plane, but not in the horizontal dimension. The most useful aspect of the panoramic radiograph is in assessing increased potential for IAN injury during third molar

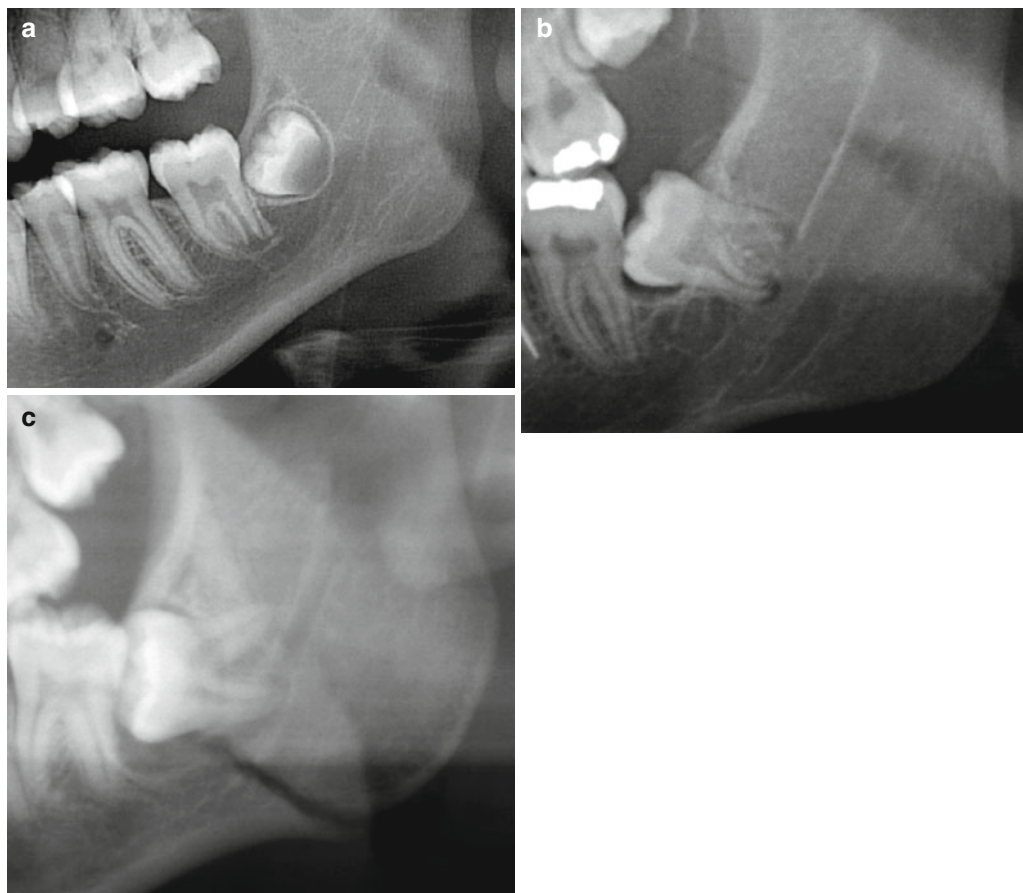


Fig. 11.1 (a) Panoramic radiograph of impacted third molar showing increased potential for nerve injury with loss of superior cortical outline of the IAC (inferior alveolar canal) in the region of the tooth roots. (b) Panoramic radiograph of impacted third molar with radiographic predictors of nerve injury, including loss of superior cortical

outline of the IAC, and darkening of the tooth roots. (c) Panoramic radiograph of left mandible fracture associated with an impacted third molar, showing mild displacement and discontinuity of the IAC. No information is provided about the status of the IAN itself

extraction based upon the presence of several radiographic predictors (Fig. 11.1).

Other types of plain radiographs such as periapical (Fig. 11.2) or anteroposterior films and lateral cephalograms are not routinely used for accurate preoperative routine risk assessment for IAN injury. Superimposition and wide variations in magnification of the structures based on their location do not allow for reliable and reproducible information to be obtained with plain films. Furthermore, even if the IAN could be visualized in the third molar region, only a rough outline of tooth and root anatomy would be obtained making these images of limited if any value for nerve injury appraisal.

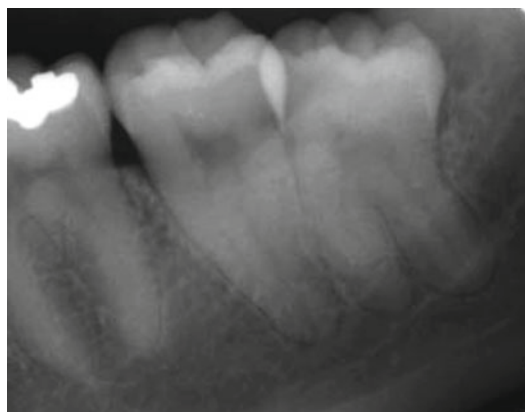

Fig. 11.2 Periapical radiograph showing proximity of third molar roots to the IAC, with root darkening

11.3.2 Computerized Tomography

The use of computerized tomography (CT) in the assessment of nerve injuries is very limited, although it has been used more recently for assessment of the inferior alveolar canal with regard to the position of the third molar. An

evaluation of bone window attenuation images may indicate violation of the cortical outline of the inferior alveolar canal, either from the roots of the third molar, iatrogenic implant placement, or following facial trauma (e.g., posterior mandible fracture) (Fig. 11.3), but yields little information regarding the condition or integrity of

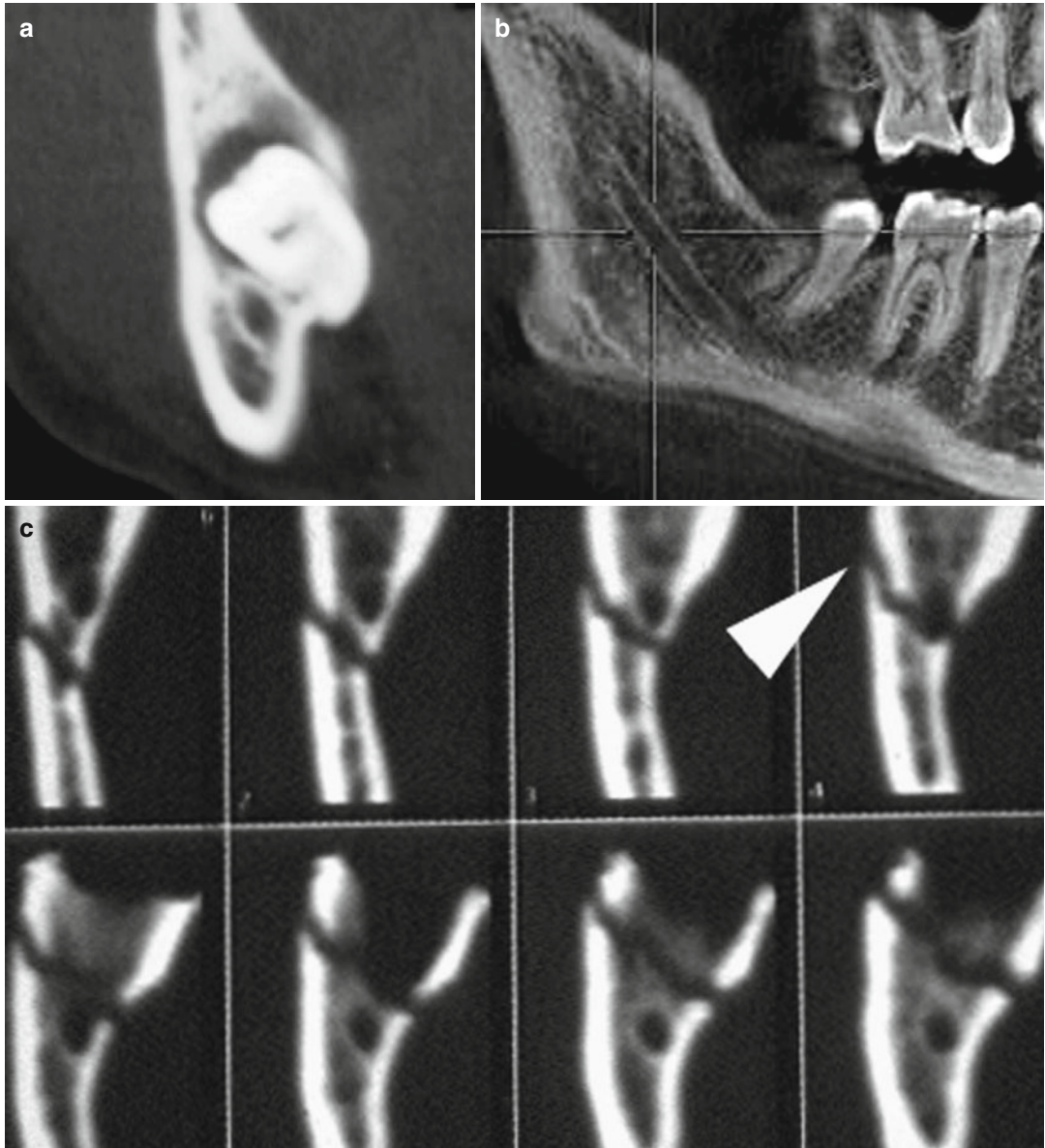

Fig. 11.3 (a) CBCT scan with coronal soft tissue window images showing the IAC displaced inferiorly and the roots of the tooth perforating the lingual plate, with the inability to discern any components of the inferior alveolar neurovascular bundle. (b) CBCT scan sagittal image with improved detail resolution of the position of the IAC.

(c) CT scan images with coronal bony window images showing mandibular fracture involving the IAC (*arrowhead*). (d) CT scan with axial soft tissue window images in a patient with a cystic lesion of the mandible showing the inferior alveolar neurovascular bundle without significant detail (*arrowhead*).



Fig. 11.3 (continued)

the IAN itself or the neurovascular bundle. The use of soft tissue window CT images for the LN or IAN is compromised by very poor detail resolution that precludes its routine application in neural assessment. Furthermore, dental artifacts often pose severe limitations in obtaining accurate information regarding the position of the LN to the lingual cortex of the mandible in critical areas, even in the soft tissue window views, and despite the current use of high-resolution image acquisition.

In 1998, CT cone beam (CBCT) technology, previously used only in angiographic imaging, was employed in the United States as a potential imaging modality for the maxillomandibular complex. The presurgical evaluation of impacted mandibular third molar relationship to the IAN has gained popularity over conventional CT scanning and plain panoramic radiographs among oral and maxillofacial surgeons. The need for accurate imaging with the lowest possible dose of radiation (i.e., ALARA rule, as low as reasonably achievable) seems to be satisfied acceptably with this technology. CBCT provides the desirable three-dimensional representation of the anatomic location of interest, with minimal distortion compared to traditional plain films

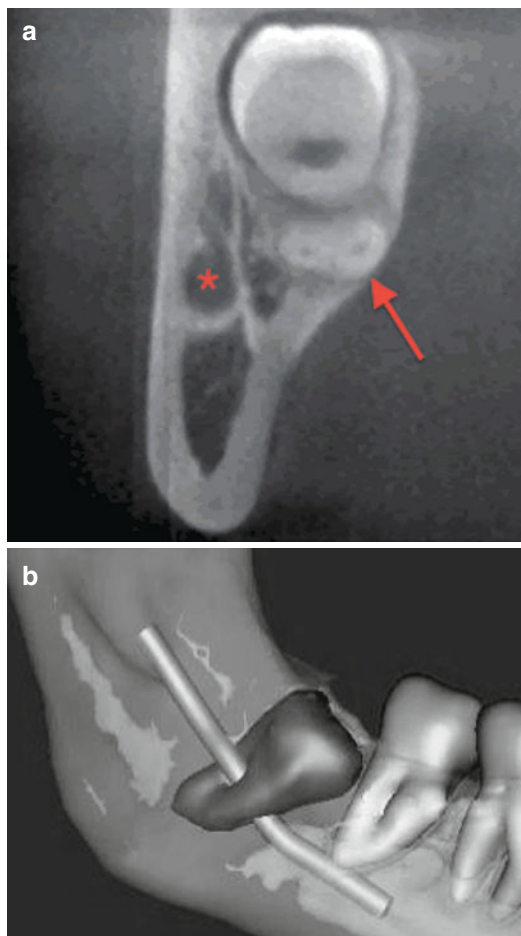


Fig. 11.4 (a) CBCT image in the mandibular third molar region showing buccal displacement of the IAC (*asterisk*) and thinning of the lingual plate near the third molar roots (*arrow*). Neither the IAN nor LN is visible on these images. (b) Three-dimensional CBCT reconstruction showing position the course of the inferior alveolar canal between the impacted third molar roots. This is merely a reconstruction of the inferior alveolar canal without any information about the IAN itself

and by simpler acquisition compared to traditional CT systems. Similar to the panoramic radiograph, CBCT can be used for preoperative risk assessment in various dentoalveolar procedures such as third molar surgery or dental implants and preprosthetic surgery. A major limitation, of course, remains the inability to visualize the IAN itself (within the inferior alveolar canal), or the LN, since no accurate soft tissue information can be obtained with use of CBCT (Fig. 11.4).

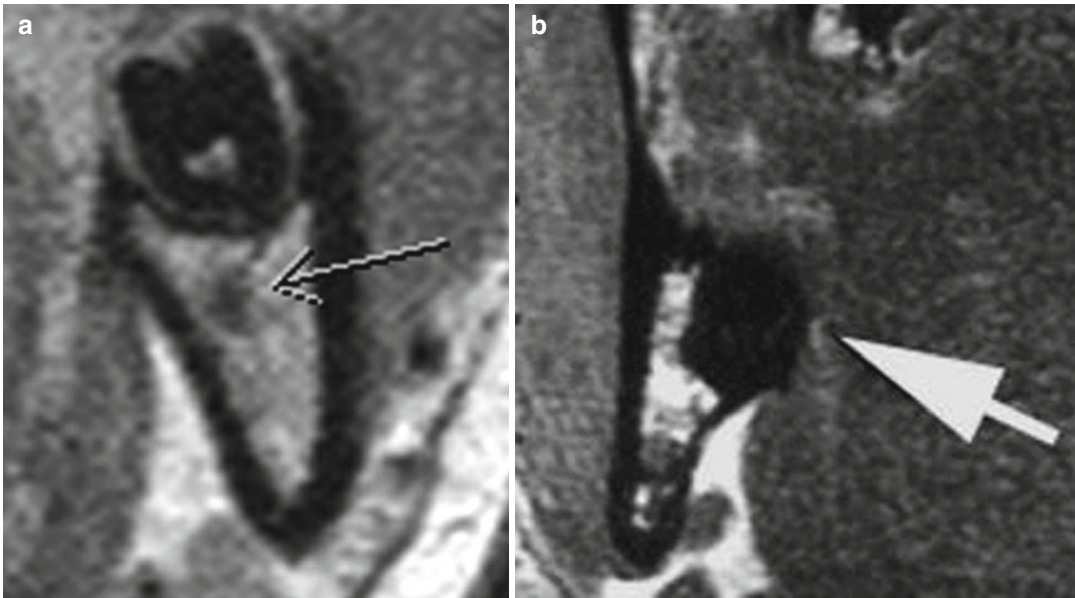


Fig. 11.5 (a) High-resolution MRI (HR-MRI) image in the third molar region showing minimal detail of the inferior alveolar neurovascular bundle (*arrow*). (b)

High-resolution MRI (HR-MRI) image in the third molar region. *Arrow* indicates lingual nerve in direct contact with the lingual cortical plate (*arrow*)

11.3.3 High-Resolution Magnetic Resonance Imaging (HR-MRI)

Magnetic resonance imaging (MRI) is the method of choice for radiographic visualization of all cranial nerves (CN), and each nerve segment can be seen and examined in detail with specific MRI sequences. Due to the complexity of the course of the CNs and surrounding anatomic structures, detailed examination of the CNs is made possible only with careful planning and selection of the specific MRI technique. The imaging plane, coil selection, slice selection, in-plane resolution, and use of special techniques can be tailored based upon the individual CN, and the segment of interest so that the highest possible image quality may be obtained. The trigeminal nuclei (intra-axial), cisternal portion (preganglionic), and Meckel's cave (intradural) segments contain both the motor and sensory components of the trigeminal nerve and can be visualized with high-resolution T1- or T2-weighted MRI images. At the anterior aspect of the Gasserian ganglion, the sensory root divides into the ophthalmic (V1), maxillary (V2), and mandibular (V3) divisions and each may be followed

and examined separately based upon their known course peripherally. The course of the LN and IAN branches of the mandibular division, after exiting from foramen ovale, can be followed with high-resolution, contrast-enhanced, T1-weighted (T1W), or T1W three-dimensional, fast-field echo (T1W 3D FFE) sequences in the axial, coronal, and sagittal, or parasagittal, planes. Although detailed information can be obtained with the use of MRI, routine presurgical evaluation of the route and integrity of the LN and IAN is not standard practice. Rather the MRI is employed as the preferred imaging modality for examination of the status of the CNs most commonly in the presence of a disease process or following brain or nerve injury.

Miloro et al. have used high-resolution MRI (HR-MRI) in an attempt to document the in situ position of the LN in the third molar region directly, without surgical manipulation or tissue distortion artifact as in the studies by Kisselbach and Pogrel. Ten patients (20 sides) without prior dental surgery were imaged using an HR-MRI sequence (PETRA-phase encode time reduction acquisition) that enabled direct visualization of the LN (Fig. 11.5). This study documented that

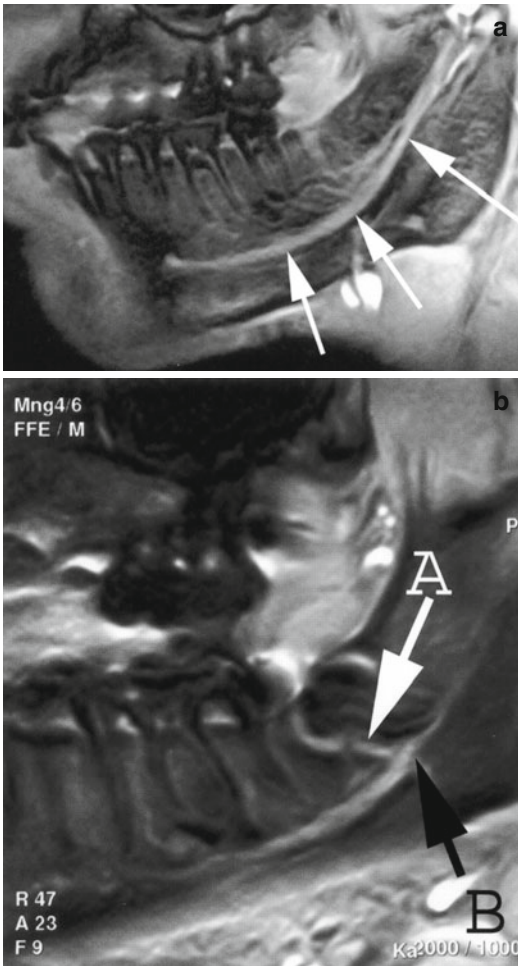


Fig. 11.6 (a) Sagittal mandibular MRI image of a normal inferior alveolar nerve (*arrows*) (Adapted from Kress et al. [17], p. 1636). (b) Sagittal mandibular MRI image of a mandible fracture associated with the mesial aspect of the impacted third molar (A), showing continuity of the inferior alveolar nerve (B) but lack of detailed fascicular anatomy (Adapted from Kress et al. [17], p. 1636)

the lingual nerve position, while variable, was indeed vulnerable during third molar surgery, and the LN was found to be superior to the lingual crest in 10 % of cases, and in direct contact with the lingual plate in 25 % of cases. Kress and colleagues have been able to image the IAN using T2-weighted MRI imaging to visualize the IAN in the in situ position as well as in cases of mandibular fractures (Fig. 11.6); yet there is still lack of detailed resolution of the fascicular anatomy of the IAN itself.

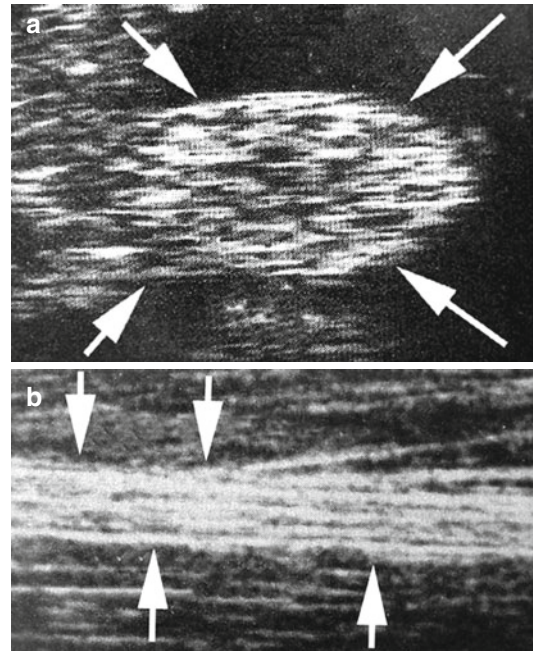


Fig. 11.7 (a) High-resolution ultrasound image of sciatic nerve in cross section. Note ability to visualize fascicular pattern (*arrows*). (b) High-resolution ultrasound image of sciatic nerve in longitudinal section (*arrows*) (Adapted from Graif et al. [10])

11.3.4 Ultrasonography

Several reports have described the use of ultrasonography (US) and high-resolution ultrasound technology primarily for the assessment of peripheral nerve lesions. This real-time advanced technology, with recently available high-resolution probes, can offer compound imaging without radiation and in a relatively inexpensive manner. Although US has not been employed or investigated as a potential preoperative risk assessment tool for the trigeminal nerve, it has been demonstrated to be valuable in identification and safe advancement of the needle in brachial plexus and sciatic nerve blocks. It would be reasonable though to anticipate limitations with the use of US in examination of the IAN in the third molar region due to the presence of bone and teeth that might affect the echogenic signal. Visualization and documentation of the course and integrity of the LN on the other hand should be relatively easy with US, requiring only minimal training and familiarity of the operator with the regional oral anatomy (Fig. 11.7).

11.4 Post-Injury Radiographic Assessment of the IAN and LN

The majority of current interest is in documenting the post-injury condition of the nerve by objective means, since the information gathered by clinical and radiologic examination could be useful in staging the degree of neural injury, determining the prognosis for recovery, and planning microneurosurgical intervention. With increased image resolution, the precise degree of architectural disruption of the nerve could be visualized, and surgical intervention could be planned accordingly. Additionally, this information could be used to document the exact location of the injury prior to surgical exploration for repair. For example, this documentation could help to avoid surgical nerve exploration in the third molar region if the injury occurred in the pterygomandibular space as a result of a mandibular block injection injury. The information may also be used to determine the size and extent of the neuromatous segment and the possible need for a nerve graft. Finally, radiologic techniques could be used to objectively monitor neurosensory progression, in conjunction with clinical examination, either after nerve injury or in the post-repair phases of neural recovery.

11.4.1 Panoramic Radiography

The post-surgery assessment of the nerve-injured patient usually includes a panoramic radiograph that may demonstrate a variety of clinically significant findings. The presence of a foreign body in the region of one or both nerves must be ruled out; and these may include metallic foreign bodies from rotary instruments or amalgam particles from neighboring teeth, as well as retained tooth or root fragments following third molar surgery. Also, the presence of iatrogenic surgical disturbances of the nerves may be indicated by evidence of bone removal in proximity to the inferior alveolar neurovascular bundle or the lingual nerve (Fig. 11.8). A panoramic radiograph, or any other plain film, is rarely used though to monitor progression following nerve injury or repair.

11.4.2 Computerized Tomography

Postoperative investigation of the surgical site for examination of the integrity of the IAN canal or presence of foreign material, such as tooth or root fragments within the canal, could be more reliably performed with CT or CBCT imaging rather than using traditional panoramic imaging. Direct investigation of the integrity of the LN cannot be reliably examined with either modality due to the fact that there is not bony conduit surrounding the nerve. Disruption of the lingual cortex of the mandible at the third molar region, which may be noted on a postoperative panoramic radiograph and which may imply iatrogenic injury in the region, can be reviewed in more detail with CT or CBCT (Fig. 11.3). Direct comparisons of pre- and postoperative images can be made and add to the information gathered from the clinical examination, and potentially assist in the decision-making process for surgical or nonsurgical management.

11.4.3 Magnetic Source Imaging (MSI)

One of the few objective radiologic studies that are capable of documenting IAN injuries involves the use of magnetic source imaging (MSI), which combines magnetoencephalography (MEG) with high-resolution magnetic resonance imaging (HR-MRI). MEG technology uses magnetic fields to measure electrical brain activity, and is influenced less by intervening soft tissues than electroencephalography (EEG), and therefore produces a more detailed image with higher resolution. Similar to somatosensory evoked potentials, a stimulus is applied peripherally (to the lower lip or tongue), and a signal is recorded centrally over the somatosensory cerebral cortex devoted to that particular area; this enables measurement of signal latency, conduction velocity, and action potential amplitude. The information obtained from MEG is combined with HR-MRI images to produce a structural and functional magnetic source image (MSI) of a particular region of the brain (Fig. 11.9). McDonald et al. used MSI on six

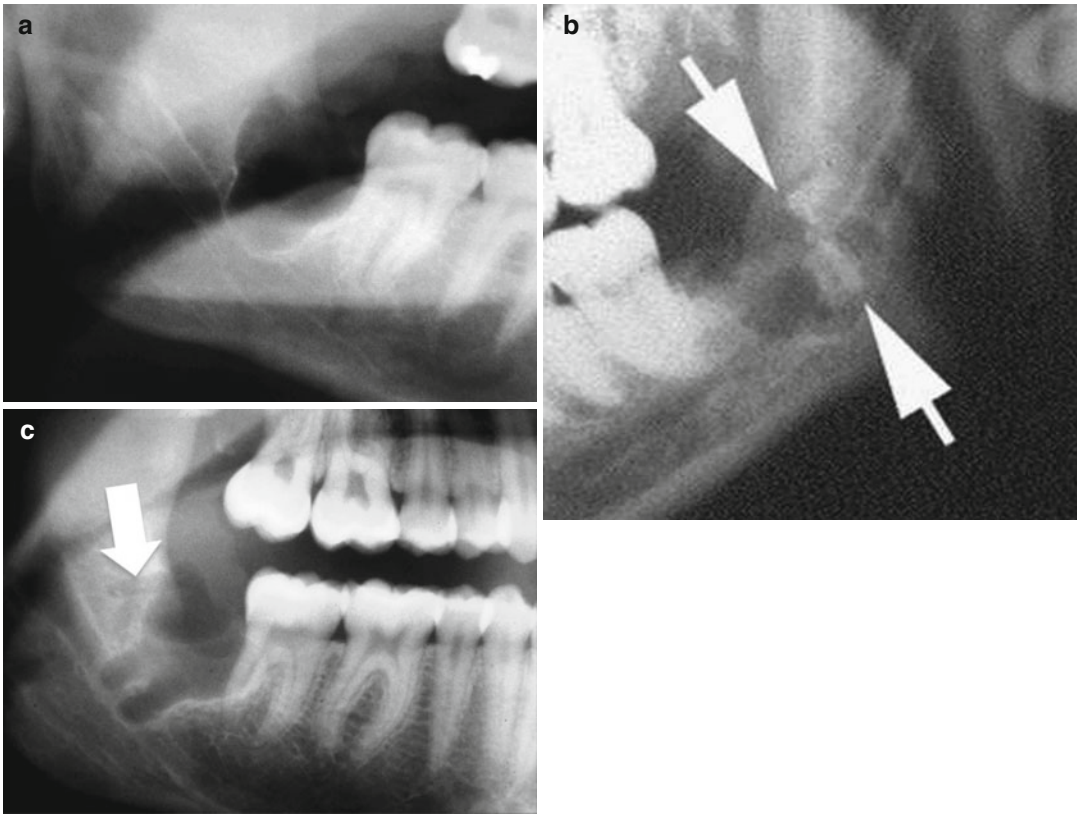


Fig. 11.8 (a) Panoramic radiograph post-extraction, showing evidence the presence of radiographic predictors of potential IAN injury. (b) Panoramic radiograph showing evidence of retained root tips following third molar extraction

(arrows) that may impede neural regeneration. (c) Panoramic radiograph showing evidence of bone removal distal to the third molar socket (arrow) in a patient with a left lingual nerve injury

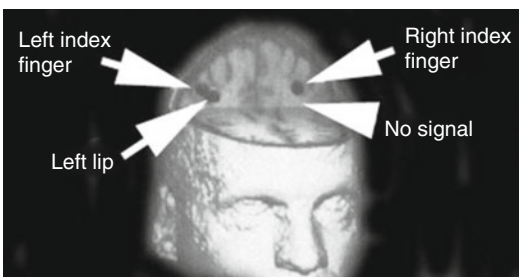


Fig. 11.9 Magnetic source image (MSI) in a patient with a right IAN injury showing lack of cortical signal (arrow-head). The right and left index fingers serve as controls (Adapted from McDonald et al. [20], p. 1070)

examination and MSI imaging were correlated with surgical findings, and neural continuity defects were identified as radiographically different from intact nerves. Despite some limitations of the study design (e.g., small, lack of blinded examiners and surgeons), there is potential for MSI to be applied in the post-injury and post-repair phases in order to monitor the progression of neurosensory recovery. Of course, this would require expensive equipment and individuals trained on its use and interpretation.

patients with unilateral IAN injury and demonstrated that MSI technology may be able to differentiate various grades of neural injury based upon signal readings. The findings on clinical

11.4.4 High-Resolution Magnetic Resonance Imaging (HR-MRI)

The application of HR-MRI modality to the assessment of the nerve following injury is in

the early phases of clinical trials. The expectation is that with improved image resolution, a variety of detailed anatomic changes in the nerve may be visualized. First, a change in nerve diameter may be visualized in cases of nerve injury with Wallerian degeneration of the nerve segment distal to the site of injury, with an acute or gradual decrease in nerve diameter noted from proximal to distal nerve. Second, an acute change in nerve position may be seen, for example, where the lingual nerve is retracted into the region of the third molar socket with the formation of a lateral adhesive or exophytic neuromatous segment. Third, a change in nerve shape, for example, in a case of a fusiform neuroma-in-continuity, with a change in shape of the nerve and/or increase in nerve diameter for a certain distance with return to normal shape distal to the neuroma, may be able to be visualized, and, thereby, the length of nerve resection required can be determined, and the possible need for indirect nerve grafting using either a sural nerve or possibly a cadaveric nerve allograft can also be assessed preoperatively.

The application of HR-MRI to post-injury neural assessment is currently hindered by a variety of factors. The degree of image resolution and magnification significantly limits precise anatomic examination of the individual neural elements. The ability to image the internal architecture of neural anatomy will require dramatic improvements in resolution from currently available techniques. Also, while the LN lies within soft tissue and its course is unaccompanied, other than by the chorda tympani branch of the facial nerve, the IAN lies within a cortical bony conduit and is accompanied by an artery and a vein throughout its intrabony course. Preliminary studies with HR-MRI have allowed gross visualization of the LN since it is the sole structure in the area, but examination of the IAN has been complicated by the presence of the vessels, although attempts to attenuate the image signal may be able to overcome this problem, possibly with the use of magnetic resonance neurography (MRN). Depending upon the plane of image

section, HR-MRI may miss several anatomic indicators that a nerve injury has occurred. Individual transverse (or coronal, in the case of the LN in the third molar region) sections of the nerve may not visualize a short discontinuity, or abrupt alteration in course, of the nerve depending upon the distance between the images. This problem may be avoided with the use of a sagittal, or longitudinal, image oriented along the course of the individual nerve fibers. However, this is difficult since the position of the nerve varies normally in the uninjured patient, and may change significantly in the injured patient, thereby requiring either patient repositioning or redirection of the imaging plane.

The use of a noninvasive HR-MRI, with the lack of radiation exposure, for the nerve-injured patient would provide the advantage of correlating the results of clinical neurosensory testing and subjective patient evaluation, with an objective assessment of the anatomy of the injured nerve site. While it may seem that a transection injury (Sunderland grade V) might be visualized easily with HR-MRI, the less severe injuries (Sunderland grades III and IV) may be extremely difficult to discern and quantify radiographically. Future study designs with HR-MRI should include an experimental group of post-nerve injury patients who undergo clinical neurosensory testing and HR-MRI, and then microneurosurgical nerve exploration and repair, if indicated. This would then allow correlation of post-injury radiologic results and findings at the time of nerve repair surgery to determine the ability of HR-MRI to accurately predict the actual degree of anatomic nerve injury. HR-MRI might also prove useful in monitoring the progression of anatomic neurosensory recovery (correlated with clinical signs and subjective symptoms) following nerve injury and/or microneurosurgical repair. As mentioned, Kress et al. have used MRI imaging in cases of mandible fractures and following third molar removal to assess individual nerve fiber disruption in cases of mandible fracture, and changes in signal intensity following third molar extractions (Fig. 11.10).

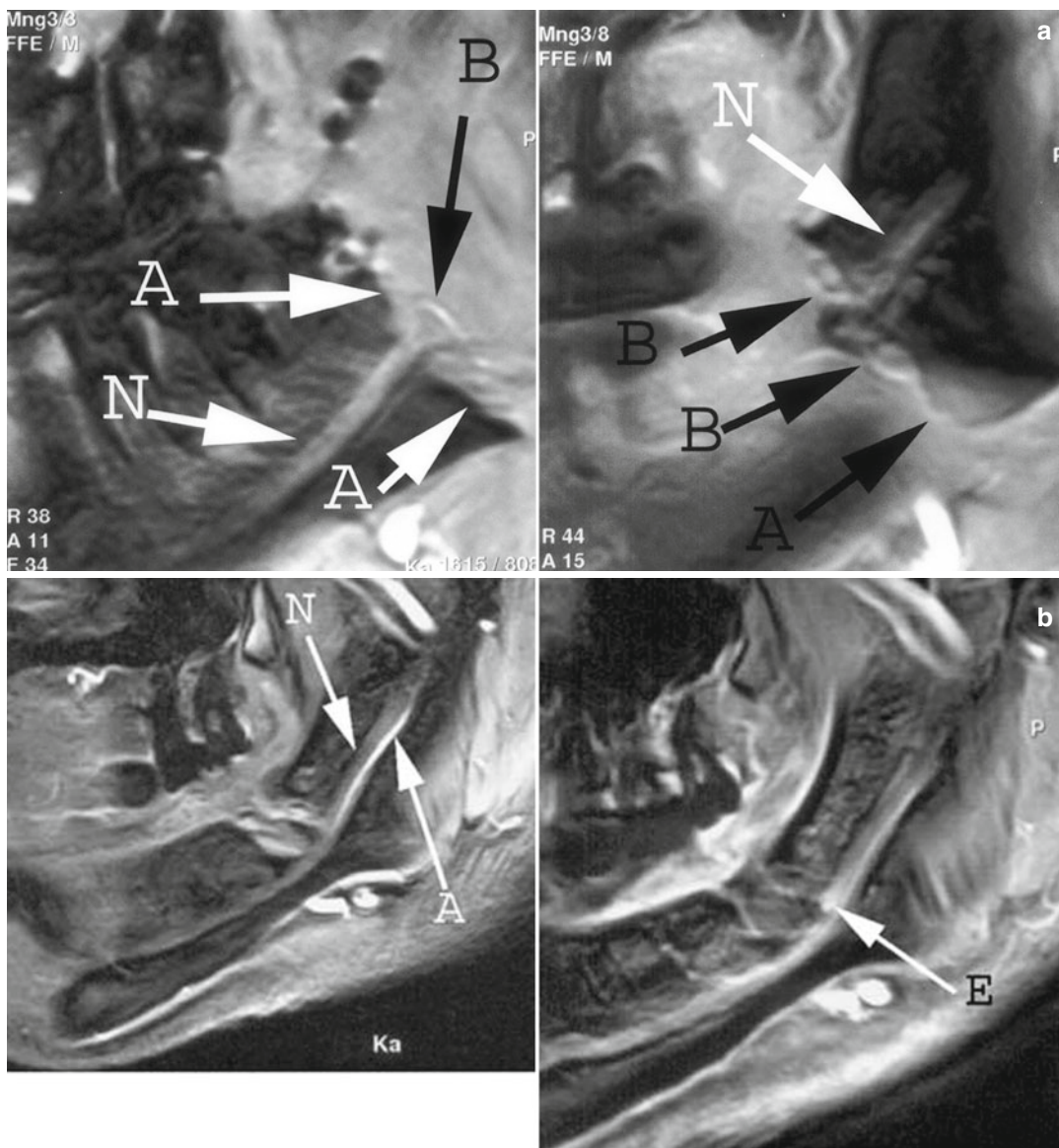


Fig. 11.10 (a) Sagittal MRI images of mandibular angle fracture (A), with IAN (N) discontinuity (note significant difference in the position of the IAN in each view), and possibly individual ruptured nerve fibers (B) (Adapted from Kress et al. [17], p. 1636). (b) Sagittal T1 MRI

images following third molar removal with IV contrast injection to distinguish the IAN (N) from the artery (A). There is evidence of signal increase in the IAN near the third molar extraction site (E) (Adapted from Kress et al. [16], 1419)

11.4.5 Magnetic Resonance Neurography (MRN)

Following the application of MRI technology to blood vessels, or magnetic resonance angiography (MRA), direct imaging of nerves with magnetic resonance neurography (MRN) was a logical

technological progression. The MRN images are obtained using axial, coronal, and longitudinal T1 and T2 image acquisition with customized phased array coils and imaging protocols. The application of MRN relies upon its ability to distinguish nerves from surrounding structures such as blood vessels, lymph nodes, ligaments, adipose tissue,

and salivary ducts. These advantages would allow isolation of the IAN from the neighboring artery and vein contained within the inferior alveolar canal. The MRN studies to date have documented the ability to distinguish intraneural from perineural masses, demonstrate nerve continuity vs. discontinuity at the fascicular level, and localize extraneural nerve compression prior to nerve exploration. The majority of research has focused on larger, peripheral motor nerves including the brachial plexus, sciatic nerve, peroneal nerve, and femoral nerve. Filler et al. documented nerve compression and signal hyperintensity of an IAN in a patient with a lymphoma of the pterygomandibular space (Fig. 11.11). MRN has been able to document an increased diameter of injured nerves, as well as increased signal intensity, and longitudinal variations associated with nerve injury and recovery. There does not seem to be any correlation between the amount of hyperintensity and the degree of neural injury, and its significance has not yet been clearly defined. The finding of signal hyperintensity has been demonstrated for a transient period following neural anastomosis, as well as distal to a nerve graft site. The remarkable ability of MRN to depict fascicular architecture is based upon the difference in fluid composition of the neural elements. The fascicles contain a preponderance of endoneurial fluid and axoplasmic water, while the interfascicular space is largely composed on fibrofatty connective tissue. In a sense, these images may be able to define radiographically the histological characteristics of different grades of nerve injuries set forth by Sunderland. Similarly, sequential images over time could be used to monitor nerve recovery at the fascicular level. One of the most advantageous characteristics of MRN images is the ability to image the nerve in a longitudinal plane. In a technique similar to that of an MRA used to image the anatomy of an abdominal aortic aneurysm, these MRN images can easily be assessed for variations in nerve anatomy, diameter, location, discontinuity, and signal intensity which may indicate areas of nerve injury, and thereby guide surgical intervention as well as monitor neurosensory recovery.

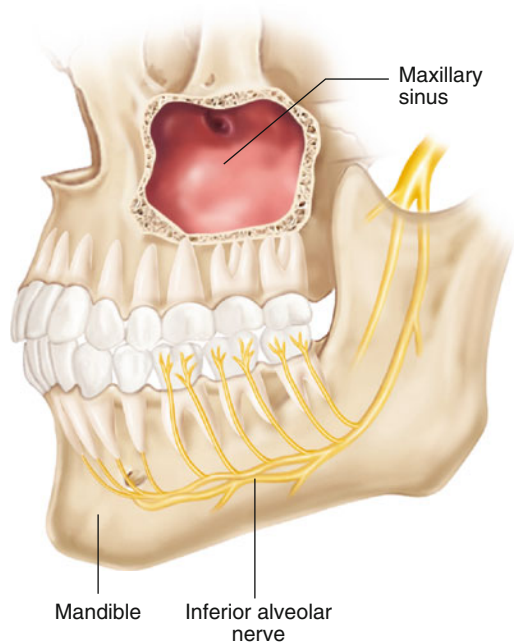
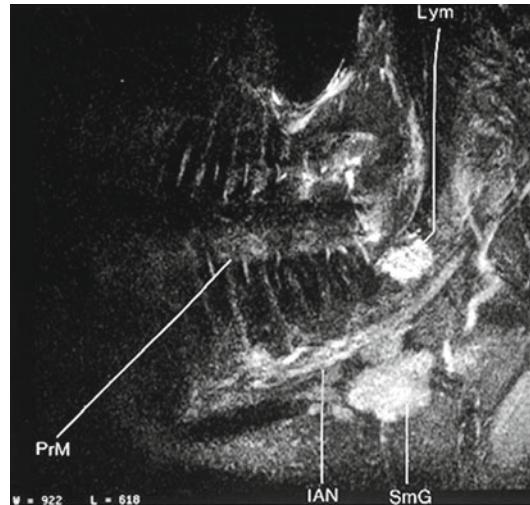


Fig. 11.11 Magnetic resonance neurogram (MRN) showing increased signal in the pterygomandibular space from a lymphoma (arrow) and delineation of the inferior alveolar nerve (IAN), submandibular gland (SmG), and premolar (PrM) (Adapted from Filler et al. [5], p. 306)

11.4.6 Ultrasonography (US)

Some promising findings were reported with the use of ultrasonography (US) for visualization of lingual trauma in the pig cadaver head. In the

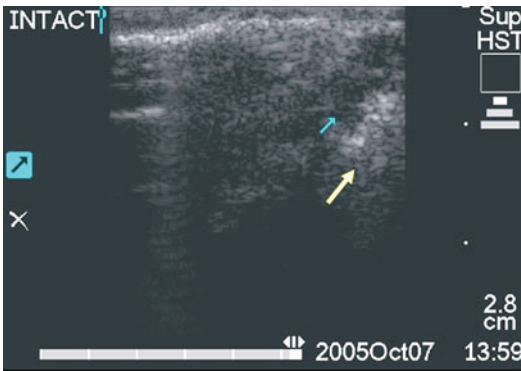


Fig. 11.12 Ultrasound image showing the echogenic shadow of the lingual nerve (*upper arrow*) above the lingual crest of the mandible (*lower arrow*) (Adapted from Olsen et al. [22], p. 2299)

study by Olsen et al., the iatrogenic injuries created were successfully categorized in 17 out of 27 attempts once the examiners became familiar with visualization of the LN (Fig. 11.12), indicating that with any new application of technology, there is a learning curve to be overcome. Therefore, one of the major remaining limiting factors in the use of US for such application is the lack of training and familiarity with the US technology and imaging among surgeons and radiologists. The possibility of incorporating US for investigation of the integrity of LN postoperatively together with clinical evaluation seems like a promising endeavor. The potential for US examination in several subsequent visits in a non-invasive manner, without the need for radiation, additional cost, or discomfort, with the ability to document findings of every exam for comparison and evaluation of progression, makes this modality a valuable one to investigate further.

11.5 Post-Injury Functional Assessment of the IAN and LN

Among the imaging modalities discussed thus far, it should be evident that the only few that could potentially contribute to the functional assessment of the post-nerve repair patients are the MRI-HR functional MRI or MRN, and US

technology. Success or failure of post-nerve repair grafting or direct anastomosis can be assessed only after several months have elapsed and is generally based upon the findings of the neurosensory examination. The use of MRN has been proven valuable to evaluate the repair site for neuroma formation, or problems with the suture repair when there is no recovery post-repair, and this information can help to direct the need for intervention. The few limitations that may be introduced by the presence of a hematoma in the early stages post-repair initially discussed in the literature are no longer a major factor with the current advances in the MRN. Finally, nerve continuity after direct repair or interpositional grafting can be examined with US, but more details may be obtained with MRN. Once again, a major limitation with the use of US is the lack of training and familiarity among surgeons with the acquired images for appropriate interpretation.

The current advances in MRI technology with high-resolution, functional, or metabolic-based images (BOLD, blood oxygenation level-dependent images) certainly allow for detailed examination of the neural structures, nerve pathology, and nerve injury. Perhaps the main potential limitations in routine use of these advanced applications for investigation of IAN and LN injuries and recovery would be the cost associated with the studies, and the lack of familiarity of the neuroradiologists and surgeons regarding their applications and interpretations.

Although our current ability to image the IAN and LN with precision, detail, and accuracy is limited, with the current rapid development of technological advancements and improvements in imaging modalities, there will certainly be three-dimensional imaging capabilities that will effectively image both the IAN and LN, allowing precise evaluation of fascicular disruption. Also, functional neural and brain imaging will allow correlation of the clinical neurosensory examination with direct anatomic and physiologic functional parameters of the IAN and LN.

Suggested Reading

1. Britz GW, Dailey AT, West GA et al (1995) Magnetic resonance imaging in the evaluation and treatment of peripheral nerve problems. *Perspect Neurosurg* 6:53–66
2. Dailey A, Tsuruda JS, Filler AG et al (1997) Magnetic resonance neurography of peripheral nerve degeneration and regeneration. *Lancet* 350:1221–1222
3. Dailey AT, Tsuruda JS, Goodkin R et al (1996) Magnetic resonance neurography for cervical radiculopathy: a preliminary report. *Neurosurgery* 38:488–492
4. Filler AG, Howe FA, Hayes CE et al (1993) Magnetic resonance neurography. *Lancet* 341:659–661
5. Filler AG, Kliot M, Hayes CE et al (1996) Application of magnetic resonance neurography in the evaluation of patients with peripheral nerve pathology. *J Neurosurg* 85:299–309
6. Filler AG, Maravilla KR, Tsuruda JS (2004) MR neurography and muscle MR imaging for image diagnosis of disorders affecting the peripheral nerves and musculature. *Neurol Clin* 22(3):643–682, vi–vii
7. Garbedian J (2009) The relationship of the lingual nerve to the 3rd molar region: a three dimensional analysis, Master Thesis in Graduate Department of Dentistry. University of Toronto, Toronto, p 95
8. George JS, Aine CJ, Mosher JC (1995) Mapping function in the human brain with magnetoencephalography, anatomical magnetic resonance imaging, and functional magnetic resonance imaging. *J Clin Neurophysiol* 12:406
9. Ghaemina H, Meijer GJ, Soehardi A et al (2009) Position of the impacted third molar in relation to the mandibular canal. Diagnostic accuracy of cone beam computed tomography compared with panoramic radiography. *Int J Oral Maxillofac Surg* 38(9):964–971
10. Graif M, Seton A, Nerubai J, Horosowski H, Itzchak Y (1991) Sciatic nerve: sonographic evaluation and anatomic-pathologic considerations. *Radiology* 181:405–408
11. Hayes CE, Tsuruda JS, Mathis CM et al (1997) Brachial plexus: MR imaging with a dedicated phased array surface coil. *Radiology* 203:286–289
12. Howe FA, Filler AG, Bell BA et al (1992) Magnetic resonance neurography. *Magn Reson Med* 28:328–338
13. Howe FA, Saunders D, Filler AG et al (1994) Magnetic resonance neurography of the median nerve. *Br J Radiol* 67:1169–1172
14. Jaaskelainen SK, Teerijoki-Oksa T, Forssell K, Vahatalo K et al (2000) Intraoperative monitoring of the inferior alveolar nerve during mandibular sagittal-split osteotomy. *Muscle Nerve* 23:368–375
15. Kiesselbach JE, Chamberlain JG (1984) Clinical and anatomic observations on the relationship of the lingual nerve to the mandibular third molar region. *J Oral Maxillofac Surg* 42:565–567
16. Kress B, Gottschalk A, Anders L et al (2004) High-resolution dental magnetic resonance imaging of inferior alveolar nerve responses to the extraction of third molars. *Eur Radiol* 14:1416–1420
17. Kress B, Gottschalk A, Stippich C et al (2003) MR imaging of traumatic lesions of the inferior alveolar nerve in patients with fractures of the mandible. *Am J Neuroradiol* 24:1635–1638
18. Kuntz C, Blake L, Britz G et al (1996) Magnetic resonance neurography of peripheral nerve lesions in the lower extremity. *Neurosurgery* 39:750–757
19. Maloney SR, Bell WL, Shoaf SC, Blair D et al (2000) Measurement of lingual and palatine somatosensory evoked potentials. *Clin Neurophysiol* 111:291–296
20. McDonald AR, Roberts TPL, Rowley HA, Pogrel MA (1996) Noninvasive somatosensory monitoring of the injured inferior alveolar nerve using magnetic source imaging. *J Oral Maxillofac Surg* 54:1068–1072
21. Miloro M, Halkias LE, Chakeres DW, Slone W (1997) Assessment of the lingual nerve in the third molar region using magnetic resonance imaging. *J Oral Maxillofac Surg* 55:134–137
22. Olsen J, Papadaki M, Troulis M et al (2007) Using ultrasound to visualize the lingual nerve. *J Oral Maxillofac Surg* 65(11):2295–2300
23. Pogrel MA, Renaut A, Schmidt B, Ammar A (1995) The relationship of the lingual nerve to the mandibular third molar region: an anatomic study. *J Oral Maxillofac Surg* 53:1178–1181
24. Rood JP, Shehab AAN (1990) The radiological prediction of inferior alveolar nerve injury during third molar surgery. *Br J Oral Maxillofac Surg* 28:20
25. Seddon JJ (1943) Three types of nerve injury. *Brain* 66:237
26. Slimp JC (2000) Intraoperative monitoring of nerve repairs. *Hand Clin* 16:25–36
27. Sunderland S (1951) A classification of peripheral nerve injuries produced by loss of function. *Brain* 74:491
28. Tanrikulu L, Hastreiter P, Richter P et al (2008) Virtual neuroendoscopy: MRI-based three-dimensional visualization of the cranial nerves in the posterior cranial fossa. *Br J Neurosurg* 22(2):207–212
29. Zuniga JR, Meyer RA, Gregg JM, Miloro M, Davis LF (1998) The accuracy of clinical neurosensory testing for nerve injury diagnosis. *J Oral Maxillofac Surg* 56:2–8

Tara Renton

12.1 Introduction

The most significant complications from dental and oral surgical interventions are iatrogenic trigeminal nerve injuries that can result in permanent altered sensation and pain causing significant functional and psychological disability [1]. These injuries are best prevented, and management is complex and currently often inadequate [1]. Dependent upon the mechanism and duration of trigeminal nerve injury, results on relatively few patients undergoing reparative surgery, this chapter aims to provide an outline of the nonsurgical management of these injuries. The trigeminal nerve is the largest peripheral sensory nerve in the body with representation occupying over half of the sensory cortex. Altered feedback from a sensory nerve can cause permanent changes in the sensory cortex after 3 months [2] and, in addition, results in significant functional and affective problems. Since the face and mouth are rather “important” parts of a human being, challenges and changes to the orofacial area are likely to have a high psychological impact and altered self-perception [3].

Altered sensation and pain in the orofacial region may interfere with speaking, eating,

kissing, shaving, applying makeup, toothbrushing, and drinking, in fact just about every social interaction we take for granted on a daily basis [4]. Usually after oral rehabilitation, the patient expects and experiences significant improvements, not only regarding jaw function, but also in relation to dental, facial, and even overall body image. Thus, these injuries have a significant negative effect on the patient’s self-image and quality of life and may lead to significant psychological effects [5].

Iatrogenesis is damage to the patient caused by surgical or medical intervention. Surprisingly very little research attends to this unfortunate side of surgery and medicine.

It is well known that chronic pain causes stress and anxiety in over 50 % of affected patients [6] and postsurgical sensory neuropathy is often associated with chronic neuropathic pain [7]. As 50–70 % of patients presenting at a specialist clinic present with neuropathic pain [3] that does not respond to surgery [8, 9], there is a huge demand for nonsurgical management for these patients.

Current management of these nerve injuries is inadequate. The World Health Organization’s model of health suggests that nerve injury outcomes should be assessed in terms of impairment, activity limitations, and participation restrictions [6]. The focus for trigeminal nerve injury management misguidedly remains on surgical correction or laser therapy of the nerve itself with little or no attention to the patient’s complaints. A more holistic approach, such as medical or

T. Renton, BDS, MDS, PhD, FRACDS (OMS),
FDS, RCS, FHEA, ILTM
Department of Oral Surgery, Kings College London,
Kings College Hospital London,
Bessemer Rd, Denmark Hill, London SE5 9RS, UK
e-mail: tara.renton@kcl.ac.uk

counseling intervention with consideration for the patients' psychological, functional, or pain-related complaints, is required. The fault partly rests with how we assess these patients clinically. Neurosensory assessment tends to show little regard for the functional or pain evaluation, with the main focus remaining on basic mechanosensory evaluation, which is not necessarily reflective of the patients' subjective difficulties. Oral and maxillofacial surgery specialists assessing these injuries should therefore follow guidelines from the World Health Organization, which suggests that nerve injury assessment should focus on level of impairment, activity limitations, and participation restrictions [9]. Guidelines for management of chronic neuropathic pain are set out by NICE, the International Association for the Study of Pain, and the American Academy of Neurology [10–12].

Specific recommendations have been made with regard to the assessment of trigeminal neuropathy using qualitative sensory testing (QST), pain profiling, and quality of life (QoL) questionnaires containing psychometric scales reflecting the important criteria by which we should assess the effectiveness of our therapeutic interventions [13]. These recommendations, without exception, are holistic when compared with current reports evaluating the management of trigeminal nerve injuries.

To date, as dental clinicians, we have mistakenly applied a sit and wait observation policy to these iatrogenic trigeminal nerve injuries based upon research regarding lingual access for third molar surgery (mostly now only of historic interest) causing predominantly temporary lingual nerve injuries, with approximately 90 % resolving by 8 weeks post-surgery [14, 15]. This expectant approach is not applicable to other trigeminal nerve injuries or indeed to other causes. More recently, researchers have taken a more holistic approach to assessing patients with these nerve injuries and they have identified significant neuropathic pain incidence, functional problems with related psychological problems that require management of the type not usually corrected or addressed by surgical intervention [3].

A priority in managing these patients is reassurance and an honest opinion as to whether the nerve injury is likely to be temporary or permanent. This approach will first provide the patient a realistic platform on which to decide on future treatment and secondly whether pain control and rehabilitation need to be instituted as early as possible. Reparative surgery may be indicated when the patient complains of persistent problems related to the nerve injury, is important for optimal physiologic and functional recovery, and is generally undertaken within 3 months post-injury [17]; however, there remains a significant deficiency in evidence-based research to support this practice pattern.

The presenting complaints of patients may include functional problems due to the reduced sensation, or intolerable sensations or pain, with the latter being predominantly intransigent to surgery. Frequently, poorly expressed psychological problems relating the iatrogenesis of the injury to the chronic pain are overlooked [18]. Generally for lesions of the peripheral sensory nerves in man, the gold standard is to repair the nerve as soon as possible after injury [2]. However, the relatively few series of reports on trigeminal nerve repair on human subjects relate mainly to repairs undertaken at significantly more than 6 months after injury, which is unsatisfactory. This phenomenon is peculiar only to dentistry and may be based upon the misconception that the majority of trigeminal nerve injuries resolve, when, in fact, it is only lingual nerve injuries related to lingual access for third molar surgery that usually resolve at 10 weeks in 88 % of cases [14, 15].

It is evident from a review of the literature that there needs to be a cultural and philosophical change in the choice of intervention, timing, and outcome criteria that should be evaluated for therapeutic modalities for trigeminal nerve injuries. To date, there have been a very limited number of prospective randomized studies to evaluate the effect of treatment delay, as well as the surgical, medical, or counseling outcomes for trigeminal nerve injuries in humans; this is probably due to the ethical difficulties in initiating such a study.

12.2 Trigeminal Nerve Injury Management Protocols

Management of nerve injuries should be considered in terms of immediate early interventions and later delayed interventions.

12.2.1 Early/Immediate Interventions

Early/immediate interventions would be repair of a known nerve transections or severely damaged nerves. Endodontic- and implant-related nerve injuries may also warrant early intervention [19]. A strategy for management of trigeminal nerve injuries based upon the mechanism (Fig. 12.1) and duration of the injury (Table 12.1).

High-dose corticosteroids and/or nonsteroidal anti-inflammatory medications administered in the early days following nerve injury should reduce local inflammation and, in theory, should minimize further damage to the injured nerve, but paradoxically these medications could interfere with the neural healing process. To date, there is little or no evidence that this pharmacologic intervention will minimize the extent and duration of trigeminal nerve injury [20].

The clinician responsible for the nerve injury must be honest and caring with the patient and show concern with a home check, or a phone call to the patient within 6–24 h post-surgery, to ensure that the clinician knows if there is any extreme pain or neuropathy that may be associated with the nerve injury and avail the patient of

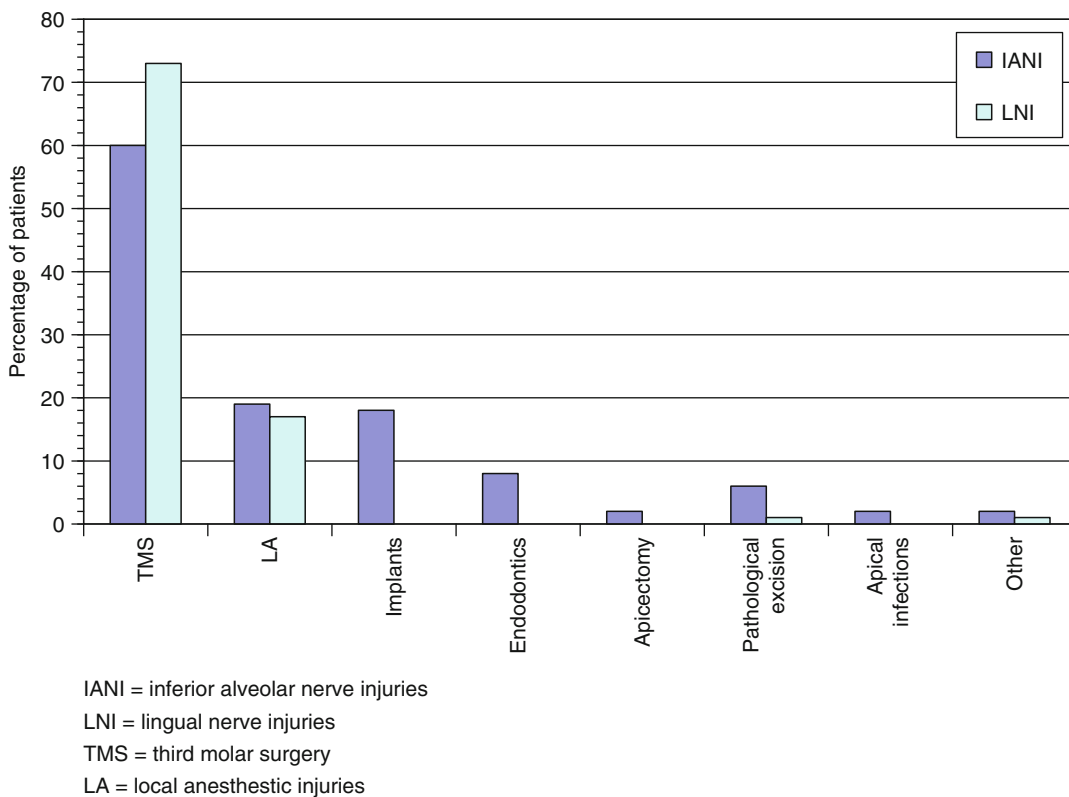


Fig. 12.1 Etiology of IANI and LNI [16]. The majority of IANI and LNI are caused by third molar surgery, followed by local anesthetics (LA). Only IANIs were also

caused by implants and endodontics. *IANI* inferior alveolar nerve injuries, *LNI* lingual nerve injuries, *TMS* third molar surgery, *LA* local anesthetic injuries

Table 12.1 Management strategies for iatrogenic trigeminal nerve injuries [16]

| Mechanism | Duration | Treatment |
|---|-----------|-------------------------------|
| Known or suspected nerve transection | | Immediate nerve exploration |
| TMS IANI – retained roots | <30 h | Immediate nerve exploration |
| Implant | <30 h | Remove implant |
| Implant | >30 h | Treat patient therapeutically |
| Endodontic | <30 h | Remove tooth/overfill |
| Endodontic | >30 h | Treat patient therapeutically |
| TMS IANI – large neuropathic area, pain, and disability | <3 months | Consider nerve exploration |
| TMS LNI – large neuropathic area, pain, and disability | <3 months | Consider nerve exploration |
| TMS IANI | >6 month | Treat patient therapeutically |
| TMS LNI | >6 month | Treat patient therapeutically |
| Local anesthesia, jaw fracture, orthognathic, other surgery | | Treat patient therapeutically |

Adapted from Renton and Yilmaz [16]

TMS third molar surgery, IANI inferior alveolar nerve injury, LNI lingual nerve injury

the appropriate intervention options, if required. Poor management by the clinician, extreme defensive behavior, and/or ignoring the patient’s complaints will only add to the frustration and anger of the patient, compounding the injured patients’ experience, so these injuries must be managed empathetically.

12.2.2 Later or Delayed Management

Later or delayed management of nerve injuries will depend upon the mechanism and the duration of the event (Table 12.1) [16]. The patient’s ability to cope with the neuropathy and pain, functional problems, and their overall psychological status will drive the need for therapeutic intervention. Considering that the majority of these patients present with neuropathic pain, most are managed with reassurance and medications; however, psychological techniques are being developed for these patients. Many injuries have limited benefit from surgical intervention and should be managed symptomatically using medication or counseling. In order to manage the patient appropriately, you must assess what is causing the patient’s problems. It is important to identify key symptoms including pain or altered sensory perception that may be impairing the patient’s functional abilities. Secondly, it is critical to inquire about functional problems (Fig. 12.2) in order to identify

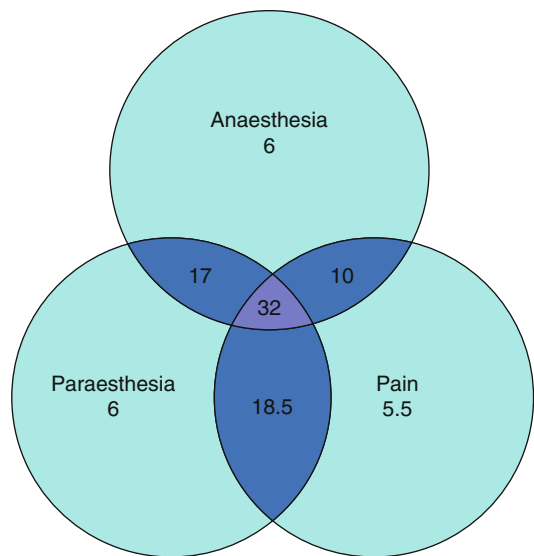


Fig. 12.2 Incidence (%) of pain, anesthesia, and paraesthesia among all patients [16]

what specifically is most responsible for the patient’s distress. Symptoms like numbness with pain with light touch (mechanical allodynia) or pain with cold stimuli (cold allodynia) often confuses and distresses the patient. An explanation of these symptoms by the clinician often alleviates the patient’s anxiety in most cases. Therapeutic interventions may include the following:

1. Consultation, reassurance, and understanding will assist many patients in dealing with these

nerve injuries. Education about their condition and reassurance that the damaged nerves will not lead to more serious diseases probably is the first and most powerful intervention for the patient. Psychological intervention is recommended for irreversible injuries and injuries that cannot be surgically rectified (e.g., LA-related, endodontic chemical damage, and gross surgery) in patients who are challenged by coming to terms with the permanent non-operative nerve injury.

2. Medical pharmacologic symptomatic therapy may be indicated for patients with pain or discomfort. Medications for chronic pain may include:
 - Topical agents for pain
 - Systemic agents for pain
3. Surgical exploration (as discussed in other chapters)
 - Immediate repair if nerve transection is known or suspected
 - Removal of an implant or endodontic filling material within 30 h
 - Exploration of IAN injuries through the extraction socket (less than 4 weeks)
 - Exploration of LN injuries before 12 weeks

The surgical management for trigeminal nerve injuries is discussed in the other chapters of this book, and this chapter addresses several nonsurgical strategies that can be used to assist the practitioner in preventing and managing complications related to some common dental surgical procedures. In a recent study, surgery with no other form of treatment was a management option for only 22 % of all patients presenting with trigeminal nerve injuries [16].

The planned treatment must address the patient's concerns appropriately, and the aims of treatment would ideally include the reduction of pain and discomfort and ultimately provide improved neurosensory function. It is important to stress that treatment may not completely restore function, such as eating, drinking, speaking, and sleeping; in addition, any treatment will not restore normal sensation in the neuropathic area, including general sensory (i.e., mechanosensory function) or special sensory function

(i.e., taste). Escalation of a patient's symptoms from intermittent pain to persistent pain would be a significant negative outcome, as would causing a patient to have discomfort or pain when previously they only reported anesthesia. Therefore, particularly with surgery, each patient must be warned of the potential risk of escalating their neuropathic symptoms, which in this study [16] resulted in 40 % of patients declining offered reparative nerve surgery.

12.3 Nonsurgical Management of Trigeminal Nerve Injuries

The strategy for selecting the mode and timing of intervention must be based upon the etiology of the injury, the patient's current symptoms, the extent and permanency of the injury, and ultimately the patients' choice of treatment following informed consent and education by the clinician. The key management strategies include counseling and reassurance, medication, and surgery.

In order to successfully manage patients with nerve injuries, the clinician must consult with the patient in an in-depth fashion, provide realistic expectations by reaffirming the nerve injury is permanent if the patient has had their symptoms for more than 3 months, and provide reassurance that these injuries do not predispose them to other disease processes (e.g., cancer), and indeed will likely not worsen. Such reassurance can successfully manage patients who can manage their pain but cannot cope with the consequences of their nerve injury and have associated functional chronic neuropathic pain and resultant psychological difficulties that significantly impact upon their social life or professional life, or usual activities of daily living.

12.3.1 Functional Morbidity

Despite recognition that lingual nerve injuries can cause significant deficiencies in pronunciation [21], there is no evidence that patients suffering with speech problems due to their nerve

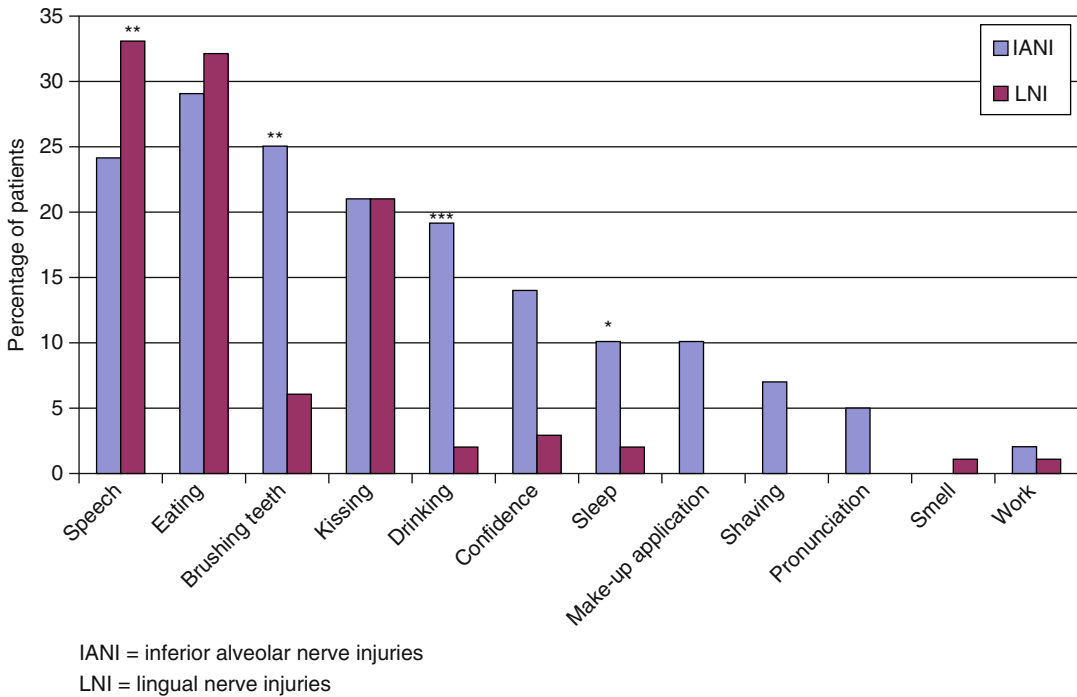


Fig. 12.3 Interference with functionality of the IANI and LNI patients. The majority of IANI and LNI patients had problems with speech and eating, where speech was

injury may also benefit from speech therapy. A patient with a nerve injury that complains of disability associated with altered sensation, severe discomfort, pain and/or numbness, or a large neuropathic area may also complain of interference with daily functions, such as eating and drinking (Fig. 12.2) [3]. Taste is also a function that may be impaired with some lingual nerve injuries due to involvement of the chorda tympani branch of the facial nerve as it courses with the lingual nerve. Inability to perform functional activities of daily life, such as applying lipstick, toothbrushing, kissing, or shaving due to an inferior alveolar nerve injury, may also occur. Also, sleep patterns may be affected (Fig. 12.3).

12.3.2 Pain Management

Neuropathic pain is defined as “pain arising as a direct consequence of a lesion or disease affecting the somatosensory system” [11]. Unlike nociceptive pain, neuropathy is associated with “shooting” or “burning” pains, sensations similar to

significantly affected more in LNI patients than IANI patients. (** $p < .001$) drinking (** $p < .0001$) confidence (** $p < .001$), and sleep (* $p < .05$) [3]

electric shocks, and abnormal responses to touch, heat, or cold. This type of pain typically does not respond to anti-inflammatory analgesics.

Neuropathic pain is reported to be present in 50–70 % of patients attending specialist nerve injury clinics [3, 16, 22]. Despite the additional presence of anesthesia and/or paresthesia, a similar cohort of patients was reported to have a 45 % incidence of dysesthesia (Robinson, *JOMS* 2011). Neuropathy was evident in all patients with varying degrees of mechanosensory functional loss, paresthesia, dysesthesia, allodynia, and hyperalgesia. Patients with chronic neuropathy were treated by one or more of the following three key modalities: counseling, medical intervention usually for pain (antiepileptics or antidepressants), the application of topical 5 % lidocaine patches, and/or lastly surgery (Table 12.2) [11]. In order to make the correct choice of management of patients with nerve injury, the clinician must discern what he/she is attempting to treat; is it poor mechanosensory function, or, more pertinently, should it be the patient’s chief complaint? Therefore, a thorough

Table 12.2 Medical management of neuropathic pain [11]

| Drug | Starting dose | Maximum dose | Cost of 4 week treatment | Comments |
|--|--|---|--|---|
| <i>Oral agents: refer to product literature for full list of doses, cautions, contraindications and drug interactions</i> | | | | |
| Amitriptyline | 10 mg/day | 75 mg/day | 10 mg/day = £1.12 25 mg/day = £1.13 75 mg/day = £2.39 | Higher doses could be considered in consultation with a specialist pain service |
| Duloxetine | 60 mg/day | 120 mg/day | 60 mg/day = £27.72 120 mg/day = £55.44 | Maximum of 120mg daily in divided doses |
| Gabapentin | 300 mg/day (see comments) | 3.6 g/day | 900 mg/day = £4.19 1.8 g/day = £8.38 2.7 g/day = £12.57 3.6 g/day = £15.12 | 300 mg once daily on day 1, then 300 mg twice daily on day 2, then 300 mg three times daily (approx. every 8 h) on day 3 or initially 300 mg 3 times daily on day 1, then increased according to response in steps of 300 mg daily (in three divided doses) every 2–3 days to max. 3.6 g The titration above has been recommended by the BNF 59. Local expert opinion suggests that a slower titration than the BNF recommendation may improve tolerance to gabapentin |
| Pregabalin | 150 mg/day in two divided doses | 600 mg/day | 150 mg/day = £64.40 200 mg/day = £64.40 300 mg/day = £64.40 600 mg/day = £64.40 | A lower starting dose may be appropriate for some |
| Tramadol | 50–100 mg not more often than every 4 h | 400 mg/day | 400 mg/day = £6.38 | There is a possible interaction between duloxetine and tramadol: possible increased serotonergic effects when duloxetine given with tramadol—use with caution |
| Prices based on the Drug Tariff August 2010 | | | | |
| Full range of doses not listed under cost. Costs based on 4 week treatment and is stated for information purposes only | | | | |
| <i>Topical agents: refer to product literature for full list of doses, cautions, contraindications and drug interactions</i> | | | | |
| Lidocaine Patch | Apply patch to skin once daily for up to 12 h followed by a 12 h plaster free period | Up to 3 plasters may be used to cover large areas | 1 patch daily = £67.57 3 patch daily = £202.72 | Apply to intact, dry, non-hairy, non-irritated skin once daily for up to 12 h, followed by a 12-h plaster-free period; discontinue if no response after 4 weeks Up to 3 plasters may be used to cover large areas; plasters may be cut |
| Prices based on the BNF 59 March 2010 | | | | |

assessment of the patient is vital before making such an important decision.

Nonsurgical interventions for pain include medications that may be topical or systemic analgesic agents, or psychological interventions.

Psychological interventions include reassurance, counseling, and cognitive behavioral therapy. Patients suffering from chronic neuropathic pain and for whom surgical and pharmacological interventions did not provide satisfactory pain

relief may benefit from a psychological approach to pain management. Therapies with the best evidence for improvement in chronic pain are cognitive behavioral therapy (CBT) and acceptance and commitment therapy (ACT). These therapies are not intended to lower the patient’s perceived pain levels, but enable the patient to better cope with their pain, and this therapy often includes the patient’s acceptance of a chronic condition.

12.3.2.1 Topical Analgesia

Novel strategies that include a combination of topical 5 % lidocaine patches, topical clonazepam, and botulinum toxin injections may be effective for managing posttraumatic trigeminal neuropathic pain.

Patches containing lidocaine have successfully reduced the pain experience among patients with postherpetic neuralgia (PHN), painful diabetic neuropathy, and low back pain [23, 24]. A small proportion of IANI patients experiencing neuropathic pain in a recent study were managed by applying topical 5 % lidocaine patches to the area in which they were experiencing pain, and

this therapy provided significant pain relief [16]. However, clinicians prescribing these topical patches should warn the patients to discontinue use of the patch if they develop a rash, since the patches are applied overnight on a 12-h-on and 12-h-off cycle. This modality is very useful for patients suffering from sleep interruption due to mechanical allodynia. The combined application of topical 5 % lidocaine patches with other modalities is potentially a simple useful strategy for patients with permanent inferior alveolar nerve injury suffering from neuropathic pain (Fig. 12.4).

Some evidence has shown that botulinum toxin injections are useful in managing peripheral extraoral or intraoral sensory neuropathic pain [25]; however, evidence of its effective use for posttraumatic trigeminal pain remains limited.

Clonazepam (used topically as a crushed 300 mg tablet) applied to the mucosa for 3–5 min, and not swallowed, followed by rinsing, may reduce oral mucosal neuropathic pain, but evidence is weak for widespread application of this technique.

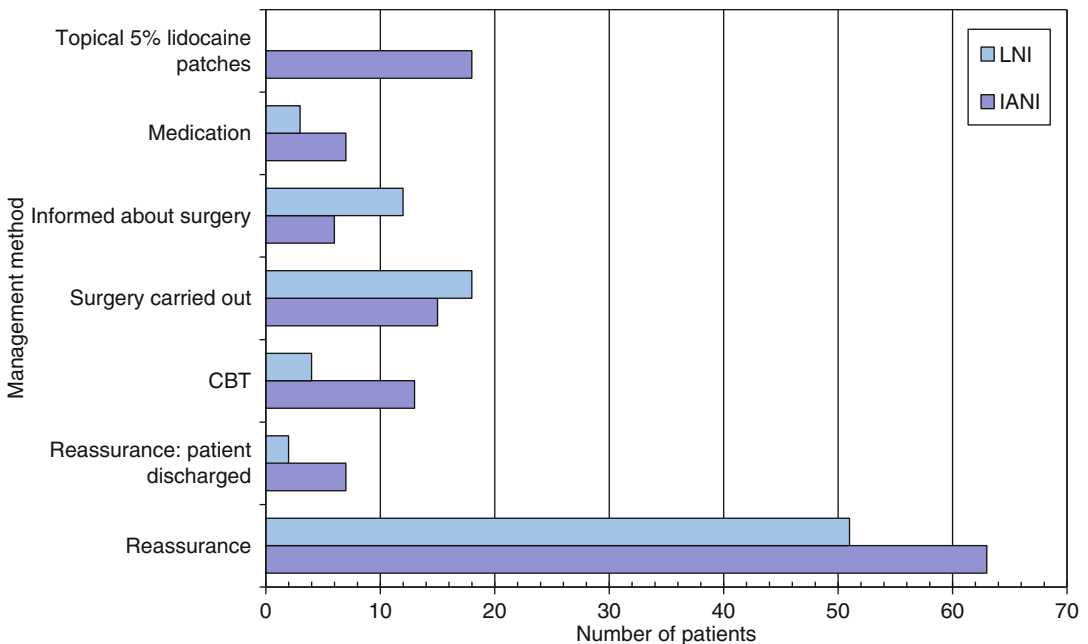


Fig. 12.4 Key management modalities for IANI and LNI patients [16]

12.3.2.2 Systemic Analgesia

Guidelines for the medical management of chronic neuropathic pain have been made by NICE, set out by the International Association for the Study of Pain and the American Academy of Neurology [10–12]. A flow chart summarizes the NICE guidelines for the medical management of neuropathic pain (Fig. 12.5).

Low-dose antidepressants (amitriptyline, nortriptyline) and/or antiepileptic agents (carbamazepine, oxcarbazepine, gabapentin, pregabalin) can be used to manage pain experienced by patients with posttraumatic neuropathy [12]. However, such systemic medications can cause a multitude of side effects that the patients would find hard to cope with in addition to their other symptoms, and only 8 % of patients treated medically for posttraumatic trigeminal nerve pain were compliant with the medication despite the side effects [16]. In contrast, many patients in this study reported that they were reluctant to take medication because they had previously tried multiple chronic pain medications prior to being referred to the clinic without any success in reducing their pain. In some cases, the level of pain was not significant enough to justify the use of medication [16].

Currently recommended neuropathic pain management strategies include systemic pregabalin, oxcarbazepine, venlafaxine, and nortriptyline as illustrated in Fig. 12.5 and Table 12.2. The primary outcomes assessed included pain relief, improved functionality, and ability of the patient to cope with their iatrogenic posttraumatic neuropathy [26].

12.3.3 Psychological Morbidity

Many patients find acceptance or coping with even minimal iatrogenic nerve injuries very difficult. This may be due to the unexpected nature of the injury, poor informed consent (or lack of recall), poor postoperative management of the patient, and an overall lack of information regarding their injury.

Patients with iatrogenic posttraumatic neuropathy of the trigeminal nerve not only often

have to face a future of chronic altered sensation or pain afflicting their orofacial region with the attendant severe compromised daily function but also have to come to terms with the fact that it has been caused by someone whom they trusted. This iatrogenic factor does have a significant psychological effect on many of these patients who often become fearsome of dental or medical practitioners and office visits. Empirically, many patients seen in specialist clinics have significant psychological distress, as indicated by hospital anxiety and depression scale (HADS) scores higher than 15. A recent study reported that a limited number of patients were treated with individualized cognitive behavioral therapy (CBT), and early signs of fear and avoidance of attending their general dental practitioner indicate that this group may be suffering from a form of posttraumatic stress disorder (PTSD) [16]. This situation is often compounded by lack of prior informed consent (or, at least, lack of recall of the informed consent discussion) and poor postoperative management by the practitioner subsequent to the nerve injury. There is a need for research into the psychological effects of these iatrogenic injuries, and the benefits of nonsurgical interventions for these patients.

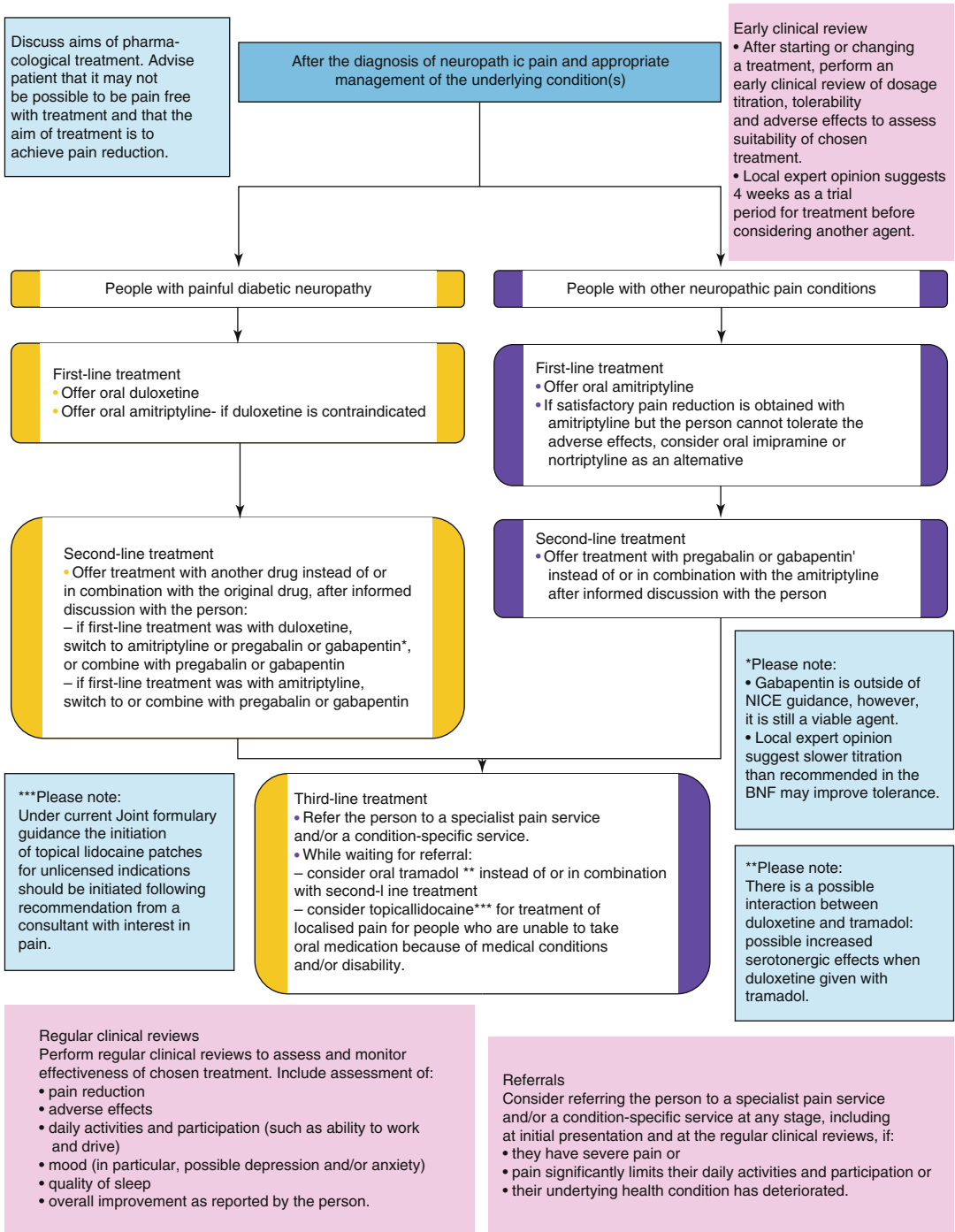
12.3.3.1 Psychiatric and Psychological Therapies

It is well established that patients who develop chronic orofacial pain conditions undergo marked negative psychological and personality changes [27, 28] and display increased levels of anxiety, depression, and psychosocial distress [29]. Significantly, a number of recent studies have reported reduced quality of life, impaired psychosocial functioning, and elevated levels of anxiety and depression in patients suffering from orofacial pain with a neuropathic component, such as patients diagnosed with trigeminal neuralgia and idiopathic continuous orofacial pain [30].

Assessment and treatment by a psychiatrist and clinical psychologist can help in the management of these psychological changes in these patients. The iatrogenic nature of many nerve injuries can compound preexisting mental health problems, and, interestingly, evidence suggests

Care pathway for the management of neuropathic pain in adults in non-specialist settings including primary care

This flow diagram was adapted from the NICE Neuropathic Pain Guideline and is used for the management of neuropathic pain for adult patients within *******(change accordingly)*******



Approved <<insert month 2010>>

Fig. 12.5 Algorithm for medical intervention for neuropathic pain [11]

that treating concomitant anxiety and depression can lead to a decrease in pain [31].

Therapies with the best evidence for chronic pain are cognitive behavioral therapy (CBT) and acceptance and commitment therapy (ACT). These therapies are not intended to lower the patients perceived pain levels, but enable the patient to better cope with their pain. This often includes the acceptance by the patient of the presence of their chronic condition.

CBT

CBT currently has the largest amount of research carried out on its effectiveness and is recommended by NICE for a wide variety of mental health and behavioral conditions [32]. CBT focuses on what people think, how those thoughts affect them emotionally, and how they ultimately behave as a result. When a patient is distressed or anxious, the manner in which they see and evaluate themselves can become negative. CBT therapists work alongside the patient to help them begin to see the link between negative thoughts and mood. This empowers patients to assert control over negative emotions and to change or modify their behaviors.

CBT can be delivered at a number of levels in a stepped care model. In the lower levels of the stepped care model, techniques such as guided self-help are used, placing emphasis on the patient to maintain diary sheets and other interventions with the support and guidance of a trained worker. Self-help patient resources are often CBT-based and are suitable for a range of conditions and can be carried out over the phone or face-to-face by a trained therapist.

Further up the stepped care model is pure CBT, for problems of a more complex and long-standing nature. CBT is delivered by a trained therapist, usually in a clinical setting. During CBT, the therapist will first assist in identifying the problem (along with the behavior, thoughts, and feelings that may be linked to the problem). Once the problem has been explored, the therapist will help to examine the thought and behavior patterns and help to work on ways of changing these patterns. If the patient accesses this type of therapy, they will often be provided

a set number of sessions that typically last 50 min per session. Therapists will usually set “homework tasks” that are completed between sessions. Homework tasks may include carrying out activities such as thought monitoring and entering these into a thought diary, or practicing specific behaviors through what is known as “behavioral exposure.”

Cognitive behavioral approaches are delivered in a number of clinical settings, with various differing protocols. While the cognitive elements of the program are usually the province of psychologists, other staff working alongside them, such as physiotherapists, occupational therapists, nurses, and doctors, are required to improve their psychological understanding and skills to enable them to contribute to the treatment regimen. Not surprisingly, the outcomes vary greatly between individual patients, with some subjects finding the ideas life-changing in their relevance and applicability, while others struggle to make even small changes. Studies demonstrate that although there is some diminution in effect with time, most patients never return to their previous levels of distress or disability [33].

Delivering effective CBT in the group format described above requires considerable skill, an effective team, and significant organization and resources. As a result, it is easy to administer CBT in an improper manner. Limitations of training, therapist availability, and lack of resources are barriers to the penetration of these techniques into the current health-care system; therefore, it is often easier to write a prescription, or repeat an injection, than to engage the person in a comprehensive program of CBT.

Numerous studies attest to the efficacy of CBT, but many questions remain about the essential processes involved, and the most rational and effective modes of delivery. Research continues to shed light on this fascinating area of clinical medicine. In any event, it is likely that the CBT approach to pain with its humanistic emphasis, practical utility, and demonstrable efficacy is here to stay [34].

Cognitive behavioral therapy (CBT) alone, or within the context of an interdisciplinary pain rehabilitation program, has the greatest

empirical evidence for success in patients with chronic pain conditions [34], and there is emerging evidence that CBT-based treatment methods can improve both short-term and long-term outcomes in patients with chronic orofacial pain [31, 36]. However, thus far, there is no evidence of the benefits of CBT for patients with IANI- or LNI-induced neuropathic pain. The majority of patients in these studies were successfully managed with psychiatric support and psychological therapies, without any additional topical analgesia, medical, or surgical intervention in a recent study [16].

There are an increasing number of studies qualifying the role of CBT in the management of chronic pain; however, more recently, several novel techniques are gaining credibility in this field including ACT [35].

Acceptance and Commitment Therapy (ACT)

Acceptance and commitment therapy is a third wave behavioral therapy (along with dialectical behavior therapy and mindfulness-based cognitive therapy) that uses mindfulness skills to develop psychological flexibility and help clarify and direct values-guided behavior. ACT, pronounced “act” and not by the initials “A-C-T,” does not attempt to directly change or stop unwanted thoughts or feelings, but aims to develop a new mindful relationship with those experiences to free a person up to be open to take action that is consistent with their chosen life values. Thus, values clarification is a key component to ACT.

Evidence suggests that ACT can help to improve mental health [36]. In a comparative trial with CBT, ACT was shown to have comparable outcomes [35]. There is increasing evidence to support its use with chronic pain in both a group and individual setting [36].

Other Nonsurgical Interventions

Other nonsurgical interventions (Table 12.3) include education, TENS, peripheral nerve stimulation, massage, acupuncture, and exercise/reconditioning. These strategies have mainly been explored for chronic pain management applicable to many patients with permanent trigeminal nerve injuries [31].

Combined Therapies

Combined therapies include CBT, surgery, medication with 5 % lidocaine patches, and/or botulinum toxin (Fig. 12.4) [16].

12.4 Summary

12.4.1 Improved Management of These Injuries

Commonly the patient’s anger and frustration due to the iatrogenic injury is compounded by poor immediate management by the clinician involved. After causing the injury, many patients complain that the treating clinician refuses to even communicate with the patient or remains in denial about the injury. Furthermore, particularly in secondary care, patients are seen for many months or even years, by consecutive junior staff providing them with unrealistic false hope and reassurance that their nerve injury will resolve spontaneously. Most importantly, prevention is preferable to the inadequate treatment modalities we currently possess to treat posttraumatic trigeminal neuropathy. However, if the damage occurs, earlier recognition and referral of trigeminal injuries are fundamental to the improved treatment of these patients. A suggested strategy for management of these patients is summarized in Table 12.1.

In conclusion, the frequent incidence of pain, in patients with lingual nerve and inferior alveolar nerve injuries, indicates that consent should highlight the likelihood of hyperesthesia and pain, rather than numbness, prior to high-risk procedures. Attention should also be directed to the misconception that IAN injuries resolve similarly to LN injuries, which is not the case, and they often require more urgent management strategies. The pain-associated functional difficulties present in these cases explain the significant psychological distress seen in these cases. Possibly, the psychological distress is compounded by the iatrogenic injury, inadequate or unrecalled informed consent, and poor management in most cases. This chapter highlights several strategies that may be used to assist the practitioner in

Table 12.3 Nonsurgical (medical) interventions for chronic pain

| Intervention | Definition | Purpose/goals | Examples of uses |
|---------------------------|--|---|---|
| Stretching | Gentle exercise to improve flexibility | Improve ROM, function, comfort | Arthritis, LBP, fibromyalgia, myofascial pain syndrome |
| Exercise/reconditioning | Reconditioning exercises can improve strength and endurance as well as combat stiffness and weakness associated with pain-related inactivity | Useful in regaining muscle and tendon strength, as well as improving ROM, endurance, comfort, and function Transforms painful activities into more easily tolerated ones Minimizes atrophy, demineralization, and deconditioning | Arthritis, LBP, fibromyalgia, CRPS |
| Gait and posture training | Appropriate attention to gait and posture, including preventive and therapeutic ergonomics | Relieve pain and restore function; prophylax is against further pain | LBP, neck pain, tension HA |
| Applied heat or cold | Application of cold (cryotherapy) to decrease pain and swelling and improve function; later application of heat (thermotherapy) to augment performance and diminish pain | Application of cold produces local analgesia, slows nerve conduction, and promotes tendon flexibility Application of heat produces local analgesia, dilates (widens) blood vessels, and promotes flexibility | Acute trauma (e.g., injury, surgery); repetitive trauma, arthritis, muscle pain or spasm, acute LBP |
| Immobilization | Reduction of activity and avoidance of strain for certain duration; may involve brace to assist, restrict, or limit function of joint | May be needed to maintain proper alignment during post-injury repair but is generally harmful for patients with CNCN | Some postoperative, injury (e.g., fracture) |
| TENS | Selective stimulation of cutaneous receptors sensitive to mechanical stimuli (mechanoreceptors) by applying low-intensity current via skin electrodes ^a | TENS can reduce pain and analgesic use and improve physical mobility, presumably by interfering with transmission of nociceptive impulses in nerve fibers | Trauma, postoperative, labor, abdominal pain; neuralgias, other neuropathic pain, PVD, angina, musculoskeletal pain |
| PNS SCS IC | Electrical stimulation of selected regions of the nervous system via implantable devices ^b | The goal of electrical stimulation is to disrupt nociceptive signaling | Chronic pain of the trunk and limbs (e.g., PVD), neuropathic pain (deafferentation, poststroke pain), cancer pain |
| Massage | Rubbing of painful or nonpainful adjacent area | Facilitates relaxation and decreases muscle tension and pain | Postoperative pain, arthritis, fibromyalgia |
| Acupuncture | Old Chinese healing technique involves insertion of fine needles into the skin at varying depths; application of pressure at acupuncture sites is called acupressure | Acupuncture may cause the secretion of endorphins and interfere with transmission of nociceptive information to relieve pain | Postoperative, radiculopathy, chronic LBP, fibromyalgia |

From the American Academy of Pain

CNCN chronic noncancer pain, *CRPS* chronic regional pain syndrome types I and II, *HA* headache, *IC* intracerebral stimulation, *LBP* lower back pain, *PNS* peripheral nerve stimulation, *PVD* peripheral vascular disease, *ROM* range of motion, *SCS* spinal cord stimulation, *TENS* transcutaneous electrical nerve stimulation

^aTENS appears to work best when applied to skin close to the pain's site of origin and when sense of touch and pressure are preserved

^bThe implanted portion of the device consists of a pulse generator and leads connected to electrodes located in fascia in close proximity to a peripheral nerve (PNS), the spinal canal (SCS), or brain (IC). The patient or clinician controls stimulation using non-implanted system components

managing trigeminal nerve injuries while, at the same time, reaffirming that there is no one ideal treatment option in treating these patients.

Acknowledgements Ms Sarah Barker Lead Clinical Psychologist for Orofacial Pains services Kings College Hospital London for her assistance with interventional psychological management strategies for patients with Trigeminal nerve injuries.

References

- Renton T (2010) Prevention of iatrogenic inferior alveolar nerve injuries in relation to dental procedures. *Dent Update* 37(6):350–352, 354–356, 358–360
- Birch R, Bonney G, Dowell J, Hollingdale J (1991) Iatrogenic injuries of peripheral nerves. *J Bone Joint Surg Br* 73:280–282
- Renton T, Yilmaz Z (2011) Profiling of patients presenting with posttraumatic neuropathy of the trigeminal nerve. *J Orofac Pain* 25(4):333–344
- Hillerup S (2007) Iatrogenic injury to oral branches of the trigeminal nerve: records of 449 cases. *Clin Oral Investig* 11(2):133–142
- Kiyak HA, Beach BH, Worthington P, Taylor T, Bolender C, Evans J (1990) Psychological impact of osseointegrated dental implants. *Int J Oral Maxillofac Implants* 5:61–69
- Locker D, Grushka M (1987) The impact of dental and facial pain. *J Dent Res* 66:1414–1417
- Kehlet H, Jensen TS, Woolf CJ (2006) Persistent post-surgical pain: risk factors and prevention. *Lancet* 367(9522):1618–1625
- Woolf C, Mannion RJ (1999) Neuropathic pain: aetiology, symptoms, mechanisms and management. *Lancet* 353(9168):1959–1964
- MacDermid JC (2005) Measurement of health outcomes following tendon and nerve repair. *J Hand Ther* 18:297–312
- NICE Neuropathic pain (2010) The pharmacological management of neuropathic pain in adults in non-specialist settings. NICE, London. <http://www.nice.org.uk/nicemedia/live/12948/47949/47949.pdf>
- Haanpää M, Attal N, Backonja M et al (2011) Guidelines on neuropathic pain assessment [NeuPSIG]. *Pain* 152(1):14–27. doi: 10.1016/j.pain.2010.07.031
- Bril V, England J, Franklin GM et al (2011) Evidence-based guideline: treatment of painful diabetic neuropathy. *Am Acad Neurol* 17;76(20):1758–65
- Cruccu G, Anand P, Attal N, Garcia-Larrea L, Haanpää M, Jørum E, Serra J, Jensen TS (2004) EFNS guidelines on neuropathic pain assessment. *Eur J Neurol* 11:153–162
- Blackburn CW (1990) A method of assessment in cases of lingual nerve injury. *Br J Oral Maxillofac Surg* 28:238–245
- Mason DA (1988) Lingual nerve damage following lower third molar surgery. *Int J Oral Maxillofac Surg* 17:290–294
- Renton T, Yilmaz Z (2012) Managing iatrogenic trigeminal nerve injury: a case series and review of the literature. *Int J Oral Maxillofac Surg* 41:629–637
- Susarla SM, Kaban LB, Donoff RB, Dodson TB (2007) Functional sensory recovery after trigeminal nerve repair. *J Oral Maxillofac Surg* 65:60–65
- Kiyak HA, Beach BH, Worthington P, Taylor T, Bolender C, Evans J (1990) Psychological impact of osseointegrated dental implants. *Int J Oral Maxillofac Implants* 5(1):9–61
- Khawaja N, Renton T (2009) Case studies on implant removal influencing the resolution of inferior alveolar nerve injury. *Br Dent J* 206(7):365–370
- Barron RP, Benoliel R, Zeltser R, Eliav E, Nahlieli O, Gracely RH (2004) Effect of dexamethasone and dipyrone on lingual and inferior alveolar nerve hypersensitivity following third molar extractions: preliminary report. *J Orofac Pain* 18:62–68
- Niemi M, Laaksonen JP, Vabatalo K et al (2002) Effects of transitory lingual nerve impairment on speech: an acoustic study of vowel sounds. *J Oral Maxillofac Surg* 60:647
- Robinson PP (2011) Characteristics of patients referred to a UK trigeminal nerve injury service. *J Oral Surg* 4:8–14
- Baron R, Mayoral V, Leijon G et al (2009) Efficacy and safety of 5 % lidocaine (lignocaine) medicated plaster in comparison with pregabalin in patients with postherpetic neuralgia and diabetic polyneuropathy: interim analysis from an open-label, two-stage adaptive, randomized, controlled trial. *Clin Drug Investig* 29(4):231–241
- Argoff CE, Galer BS, Jensen MP, Oleka N, Gammaitoni AR (2004) Effectiveness of the lidocaine patch 5 % on pain qualities in three chronic pain states: assessment with the Neuropathic Pain Scale. *Curr Med Res Opin* 20(Suppl 2):S21–S28
- Ngeow WC, Nair R (2010) Injection of botulinum toxin type A (BOTOX) into trigger zone of trigeminal neuralgia as a means to control pain. *Oral Surg Oral Med Oral Pathol Oral Radiol Endod* 109:e47–e50
- Dworkin RH, O'Connor AB, Backonja M, Farrar JT, Finnerup NB, Jensen TS, Kalso EA, Loeser JD, Miaskowski C, Nurmikko TJ, Portenoy RK, Rice AS, Stacey BR, Treede RD, Turk DC, Wallace MS (2007) Pharmacologic management of neuropathic pain: evidence-based recommendations. *Pain* 132(3):237–251
- Aggarwal VR, Lovell K, Peters S, Javid H, Joughin A, Goldthorpe J (2011) Psychosocial interventions for the management of chronic orofacial pain. *Cochrane Database Syst Rev* (11):CD008456
- Vickers ER, Boocock H (2005) Chronic orofacial pain is associated with psychological morbidity and negative personality changes: a comparison to the general population. *Aust Dent J* 50:21–30

29. Gustin SM, Wilcox SL, Peck CC, Murray GM, Henderson LA (2011) Similarity of suffering: equivalence of psychological and psychosocial factors in neuropathic and non-neuropathic orofacial pain patients. *Pain* 152:825–832
30. Tolle T, Dukes E, Sadosky A (2006) Patient burden of trigeminal neuralgia: results from a cross-sectional survey of health state impairment and treatment patterns in six European countries. *Pain Pract* 6:153–160
31. Aggarwal VR, Tickle M, Javidi H, Peters S (2010) Reviewing the evidence: can cognitive behavioral therapy improve outcomes for patients with chronic orofacial pain? *J Orofac Pain* 24(2):163–171
32. Morley S, Williams A, Hussain S (2008) Estimating the clinical effectiveness of cognitive behavioural therapy in the clinic: evaluation of a CBT informed pain management programme. *Pain* 137:670–680
33. Bogart RK, McDaniel RJ, Dunn WJ, Hunter C, Peterson AL, Wright EF (2007) Efficacy of group cognitive behavior therapy for the treatment of masticatory myofascial pain. *Mil Med* 172(2):169–174
34. Arch JJ, Eifert GH, Davies C, Vilardaga JC, Rose RD, Craske MG (2012) Randomized clinical trial of cognitive behavioral therapy (CBT) versus acceptance and commitment therapy (ACT) for mixed anxiety disorders. *J Consult Clin Psychol* 80:750–765
35. Fledderus M, Bohlmeijer ET, Pieterse ME, Schreurs KMG (2012) Acceptance and commitment therapy as guided self-help for psychological distress and positive mental health: a randomized controlled trial. *Psychol Med* 42(3):485–495
36. McCracken LM, Gutiérrez-Martínez O (2011) Processes of change in psychological flexibility in an interdisciplinary group-based treatment for chronic pain based on Acceptance and Commitment Therapy. *Behav Res Ther* 49:267–274

Vincent B. Ziccardi and Rabie M. Shanti

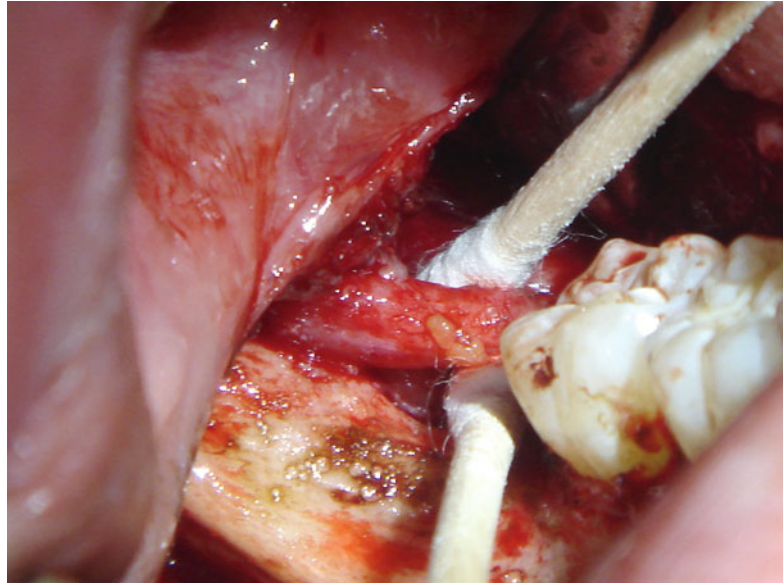
13.1 Introduction

The lingual nerve (LN) is a branch of the mandibular division of the trigeminal nerve, which is formed from afferent branches from the body of the tongue that travel along the lateral surface of the tongue [1]. Injury to the LN may cause significant patient morbidity and is one of the leading causes of litigation in dentistry and oral and maxillofacial surgery. Injury to the LN can occur during a multitude of surgical procedures including third molar extraction, local anesthetic injections, preprosthetic surgery, placement of dental endosseous implants, orthognathic surgery, excision of maxillofacial pathology, and penetrating trauma to the floor of mouth and tongue. There have also been infrequent reports of LN injury secondary to laryngoscopy for intubation and placement of a laryngeal mask airway [2, 3]. The vast majority of LN injuries that are routinely seen by trigeminal nerve microsurgical specialists are those that are iatrogenic in nature occurring with mandibular third molar extractions and dentoalveolar surgery. During mandibular third molar surgery, the LN is not generally visualized intraoperatively and is usually protected

through the judicious placement of incisions and subperiosteal plane flap elevation. With anatomical aberrancy, iatrogenic injury to the LN can occur even in the most skilled surgeon's hands. Injury to the LN can occur in situations where the nerve is located in a "high-risk" position, namely, at or above the level of the lingual crest or medial and contiguous with the lingual cortical plate (Fig. 13.1) [4]. Numerous anatomic studies have reported on the variable position of the LN with regard to third molar extraction. In a study by Pogrel and colleagues, the LN was located above the lingual crest in 15 % of cadavers within a 3.45 mm mean horizontal distance from the lingual crest in the third molar region [5]. Miloro and colleagues using magnetic resonance imaging (MRI) identified the LN above the lingual alveolar crest in about 10 % of specimens, and in direct contact with the lingual plate in approximately 25 % of specimens [6]. Therefore, medially directed crestal incisions, fractures, or perforations of the lingual cortex, aggressive dissection, and curettage on the medial tissues of the surgical site can all potentially result in an LN injury [4]. A frequently cited study using a questionnaire reported that LN injuries occur in 11 % of cases involving the removal of a mandibular third molar [7]. In these cases, the authors reported that approximately 50 % of patients made full neurosensory recovery within 36 weeks, and all but 6 (0.5 %) of the cases ultimately recovered sensation. There is a wide range of LN injury incidence reported in the literature, dependent upon varying measurements and classifications

V.B. Ziccardi, DDS, MD, FACS (✉)
R.M. Shanti, DMD, MD
Department of Oral and Maxillofacial Surgery,
University of Medicine and Dentistry
of New Jersey, New Jersey Dental School,
110 Bergen Street, Room B-854,
Newark, NJ 07103-2400, USA
e-mail: ziccarvb@umdnj.edu; shantira@umdnj.edu

Fig. 13.1 Clinical photograph showing a “high” left lingual nerve which was injured during extraction of tooth #17, requiring external neurolysis of the nerve



of injury utilized. Unfortunately, most of the past literature has been retrospective in nature with no standardization in measuring sensory levels until more recent publications utilizing the British Medical Research Council Scale (MRCS) [8]. The British MRCS was developed for grading sensation subsequent to peripheral nerve injuries since neurosensory function cannot be assessed directly [8–10]. This scale takes into account the sensations of vibration, pinprick, light touch, two-point discrimination, and temperature and is ranked on scale of S0–S4 (functional sensory recovery defined as greater than S3).

When evaluating patients with LN injuries, the microsurgeon must be prepared for potential patient frustration and anxiety that often accompany these injuries. Patients will question whether it was poor surgical technique or the nature of their anatomy or pathology that contributed to their neurosensory deficit. For instance, in the case of the inferior alveolar nerve (IAN), it is standard of care for most surgeons to obtain a preoperative panoramic radiograph that enables visualization of the course of the inferior alveolar canal (IAC) and its proximity to the area of surgical interest. There are statistically validated radiographic signs that indicate increased risk of IAN injury [11]. If there is radiographic evidence of potential for nerve injury, the surgeon has the

option to obtain a preoperative computed tomography (CT) scan or cone beam CT (CBCT). With this technology, the surgeon is able to better visualize the course of the IAC in preoperative planning of extraction of impacted teeth, placement of dental endosseous implants, evaluation of jaw lesions, and designing jaw osteotomies. A major additional advantage of CT is that it allows the surgeon to better educate the patient regarding the potential risk of injury to the IAN and preparing the patient for such an event should it occur. However, with regard to the LN, no practical imaging modality exists for the visualization of the LN and its course other than possibly high-resolution MRI scans. Therefore, the combination of the variant course of the LN and lack of easily obtainable and reproducible imaging of the nerve makes the planning for potential LN injuries more difficult as well as postoperative discussions with patients regarding this potential complication should it occur.

The evaluation and surgical management of patients with LN injuries is a challenging task that requires a sound treatment philosophy based upon experience with careful outcome analysis to refine surgical procedures in order to maximize patient benefit. This chapter shall discuss the anatomy of the LN, microsurgical treatment options, and present a case series.

13.2 Surgical Anatomy

The trigeminal nerve is the fifth and largest cranial nerve that is considered a mixed motor and sensory nerve. The afferent (sensory) component provides general sensation to the skin of the face, teeth, oral cavity, and tongue. The efferent (motor) component provides innervation to the muscles of mastication and other cranial muscles. The ophthalmic (V1) and maxillary (V2) divisions carry only sensory nerves, while the mandibular division (V3) carries both sensory and motor nerves. The LN is a branch of the mandibular division of the trigeminal nerve, and it is formed from afferent branches from the body of the tongue that travel along the lateral surface of the tongue and finally the posterior floor of mouth [1].

As the LN descends into the oral cavity, it is located medial to the mandibular ramus, coursing superior to Wharton's duct. An understanding of the relationship of the LN to the adjacent Wharton's duct is critical during a transoral exploration of the floor of the mouth. The LN courses from lateral to medial, and crosses Wharton's duct in the area of the first and second molars, and lateral to the hypoglossal nerve. Once the LN loops around Wharton's duct, it then passes upward onto the genioglossus muscle as it enters the substance of the tongue. The position of the LN at the third molar region is dependent upon the flare of the mandible, but generally courses below the lingual alveolar crest and several millimeters medial to the lingual cortex. As described previously, this is an area of anatomic variability that can make the LN susceptible to injury during third molar surgery regardless of the specific surgical technique utilized.

13.3 Indications for Surgical Management

The key to accurate repair of LN injuries is establishing a precise diagnosis. During the initial examination, the surgeon must establish the nature of the sensory disturbance including the affected area, degree of sensory deficit, and presence or absence of any neuropathic pain component [4].

Indications for LN microsurgery are generally accepted to include (1) observed nerve transection, (2) development of pain due to nerve entrapment, (3) no improvement in spontaneous sensory regeneration for greater than 3 months, (4) progressively worsening hypoesthesia or dysesthesia, and (5) hypoesthesia that is intolerable to the patient and amendable to surgical improvement. Of note, some patients seek microsurgical intervention for mild sensory deficits that would not be significantly improved to warrant surgical exploration considering the potential risks of general anesthesia [12]. Contraindications to LN microsurgery can include any of the following scenarios: (1) clinical evidence of spontaneous improving neurosensory function, (2) development of central neuropathic pain, (3) a level of hypoesthesia that is acceptable to the patient, (4) severely medically compromised patient unable to tolerate general anesthesia, and (5) excessive time elapsed since the initial injury based upon current understanding of timing issues as they relate to trigeminal nerve microsurgery [12, 13].

13.4 Surgical Approach and Techniques

Operating magnification is recommended for dissection and mobilization of the proximal and distal portions of the LN, with nasal endotracheal intubation and muscle relaxation to enable unhampered access to the oral cavity to facilitate intraoral surgery. Once the endotracheal tube is secured, a properly sized pharyngeal pack is placed and the patient's oral cavity is subsequently prepped with 0.12 % chlorhexidine solution or other such solution. The patient is prepped and draped in a sterile fashion consistent with other oral surgical procedures. It is helpful if the patient is placed in slight reverse Trendelenburg position which facilitates venous drainage and results in less intraoperative bleeding. Mouth opening can be accomplished with a rubber bite block or a Molt mouth gag with silicone tips. One must consider undue stress on the temporomandibular joint during these procedures, which can last up to several hours, especially in cases where extensive dissection is

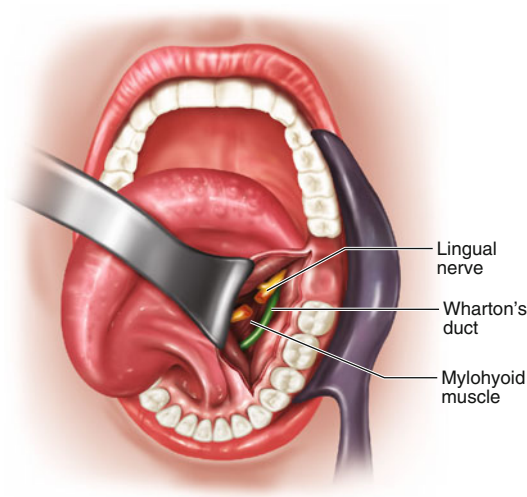


Fig. 13.2 Dashed line depicting transoral approach to lingual nerve using a paralingual mucosal incision, and straight line depicting a lingual gingival sulcus incision (Must Redraw Picture with Tongue Retracted Away from Incision Design)

needed to identify the proximal and distal portions of the nerve; therefore, the mandible should not be maintained in a fully open position for the duration of surgery [4]. Finally, a local anesthetic with vasoconstrictor is injected in the operative site, allowing adequate time to ensure adequate vasoconstriction. Of note, nerve blocks should be avoided under general anesthesia due to risk of accidental intraneural injection with the patient being unable to respond to this incident resulting in possible additional chemical or mechanical injury to the LN or IAN.

Exploration and repair of the LN can generally be accomplished with a transoral approach using either a paralingual mucosal incision or lingual gingival sulcus incision (Fig. 13.2). The advantages of the paralingual mucosal incision is the direct visualization of the LN it provides with a smaller incision; however, the proximal and distal nerve trunks may have a tendency to retract from the surgical field on exposure and blunt dissection for complete injuries. The lingual gingival sulcus incision requires a larger incision with both disto-buccal release and lingual crevicular incision; however, this will not result in retraction of the nerve during surgical dissection or retraction. Furthermore, the lingual gingival sulcus incision is technically more familiar to surgeons with the

elevation of a subperiosteal flap that requires a lateral release along the external oblique ridge similar to an extended incision utilized for third molar surgery with extension along the lingual sulci of posterior teeth to approximately the area of the canine tooth. With the lingual gingival sulcus incision, one must handle the gingival tissues gently to prevent gingival recession and/or loss of interdental papilla, especially distal to the second molar, if present, that could result in potential gingival recession and root sensitivity. This flap is then gently elevated in a subperiosteal plane to allow placement of a lateral retractor, preferably an Obwegeser toe-out retractor, and lingual retraction by the assistant with consideration for placement of silk suture to the contralateral rubber bite block to allow passive lingual flap retraction. This surgical approach allows for close inspection of the alveolar ridge and residual dental socket, if applicable. In particular, the microsurgeon should observe the level of the lingual alveolar crest, integrity of the lingual plate, presence of perforations from rotary instrumentation, or any other bony irregularities. These pertinent positive or negative intraoperative findings should be included in the final operative dictation report. In some instances, the surgeon may find a lingually oriented residual socket where the bony lingual ridge was obliterated by the former dental crown of the third molar tooth. This is very relevant in describing the position of the LN relative to where the ridge might have been anticipated if not for the aberrant position of the impacted tooth.

Most surgeons will utilize either an operating microscope or loupe magnification to expose and repair the injured lingual nerve. If using an operating microscope, the operating room table must be turned 90° relative to the anesthesiologist to facilitate placement of the surgical microscope with the affected side away from the anesthesiologist. The microscope should be calibrated and set up prior to surgeon scrubbing. A multi-head scope is particularly useful to allow the assistant surgeon to have visual access during the surgical procedure. There is a steep learning curve involved with mastering indirect hand-eye coordination in the microsurgical repair of nerve injuries; however, once mastered, the operating microscope has become indispensable in our management of these

injuries. This skill generally requires practice outside of the operating room with suture boards in the cadaver laboratory.

The initial step in the microsurgical repair of LN injuries is external neurolysis, which simply involves the release of the nerve from its tissue bed without penetrating the epineurium or entering the substance of the nerve. During external neurolysis, all soft tissue restrictions should be externally removed from the nerve that could potentially lead to conduction blockade or prevent neurosensory recovery [12]. For the described LN technique, the periosteum and associated perineural scar tissue is excised to allow blunt dissection and exploration of the proximal and distal nerve. In rare circumstances, the nerve may be directly visualized within the flap once elevated indicating a superficial location of the LN. Evaluating the bony alveolar anatomy in the region may provide a guide to the position of the injury and nerve within the flap. Many times in microneurosurgery, “less is more,” meaning aggressive and wide dissection can induce scar tissue formation leading to a potential postoperative compressive neuropathy. For some patients, external neurolysis is the only procedure required, especially in cases of moderate sensory disturbance without neuroma formation and when nerve continuity is present (Fig. 13.3).

Internal neurolysis is another microsurgical technique indicated when there is evidence of nerve fibrosis, constriction, or expansion. Internal neurolysis requires opening of the epineurium to examine the internal substance of the nerve. This can be performed under microscopic guidance using a Beaver blade creating a longitudinal incision in a procedure referred to as an epineural epineurotomy. As previously discussed, the surgeon must be vigilant in creating an ideal healing environment by minimizing postoperative scarring in the surgical field. In the case of internal neurolysis, due to the sparse amount of epineurium normally present with the trigeminal nerve, any manipulation could potentially lead to further scar formation and adverse effect on outcome [12]. In the presence of mild-moderate degrees of nerve fibrosis, LN neurosensory recovery may occur with the simple release of epineural fibrosis indicated by subsequent nerve expansion observed intraoperatively. If no nerve expansion is visualized, consideration should be given to remove the affected fibrotic segment back to the level of healthy-appearing nerve segments. An uncommonly performed procedure, epineural epineurectomy, involves the circumferential removal of the epineurium to expose the underlining nerve fascicles. This procedure can lead to significant iatrogenic injury and scarring and is not generally recommended.

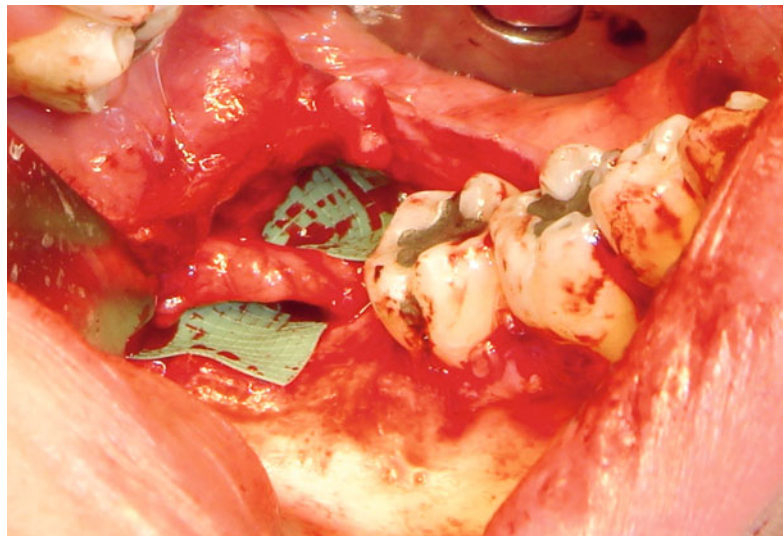


Fig. 13.3 Right lingual nerve after external neurolysis

Although such procedures have been utilized in the past when dealing with nerve involvement resulting from benign maxillofacial pathology, in most cases today, a nerve pull-through and re-anastomosis technique or nerve graft would more likely be utilized [12]. In cases where no expansion is observed and severe nerve fibrosis exists such as occurs with chemical injuries, excision of the affected segment of nerve would be indicated with primary tension-free neurorrhaphy at the level of the epineurium using 7-0 to 8-0 non-resorbable nonreactive sutures. A similar approach could be utilized for excision of a neuroma prior to primary direct neurorrhaphy. In cases of nerve discontinuity, both the proximal and distal nerve segments must be prepared by excising the neuroma/scar tissue to the level of healthy nerve prior to performing the neurorrhaphy procedure. In general, three to four sutures are optimally placed circumferentially for satisfactory neurorrhaphy of the LN. Tension-free primary neurorrhaphy is critical to allow for any meaningful sensory recovery; if there is tension on the repair site, consideration should be given toward utilizing an allogeneic or autogenous nerve graft (Figs. 13.7, 13.8, and 13.9).

It is the author's preference to wrap the LN with a resorbable conduit irrespective of whether external neurolysis, internal neurolysis, or combination of these procedures was performed. Moreover, it has been our experience that the use of conduits after microsurgical repair of the LN has been helpful in reducing postoperative recurrent scarring with documented sensory improvement [17]. In this study, Ziccardi and colleagues reported on the role of type I collagen nerve conduit in the repair of LN injuries with the results indicating a greater level of functional sensory recovery in patients treated with the nerve conduit compared to those without the use of a conduit. Once repair of the LN is complete, meticulous intraoperative hemostasis must be achieved in order to prevent postoperative hematoma formation. Residual clotted blood not only possess a risk for infection or wound dehiscence, but if it remains in proximity to a nerve repair, can result in compression-induced ischemia and further scarring potentiating demyelination and

lack of a successful nerve repair [12]. In cases where the nerve is extremely friable and not conducive to multiple suture neurorrhaphy, consideration should be given toward nerve grafting, use of conduits, or possibly fibrin glue, which is an area of future research and clinical interest. In conclusion, the goal of the surgical repair of LN injuries is to release the nerve from scar tissue, remove nonviable tissue, and achieve a tension-free repair to allow normal mechanisms of nerve healing to occur.

13.5 Outcomes

As previously discussed, LN injuries are a source of significant patient morbidity and medicolegal litigation. Therefore, the surgeon interested in managing these injuries, as with any other reconstructive procedure, must formulate a sound treatment algorithm starting with an accurate diagnosis. Microsurgical repair of LN injuries has been shown to provide significant improvements in clinical neurosensory function [13–16]. The surgical pearls and techniques previously described are preferred by the authors and gained from several years of experience.

While other chapters in this textbook review the literature regarding the etiology, diagnosis, outcomes, and adjunctive technologies (i.e., nerve guidance conduits), timing of repairs remains a critical issue. A retrospective analysis of 41 cases of LN injuries treated in our surgical unit identified that the most prognostic factor in the repair of LN injuries is the injury-to-surgery interval [17]. The significance of surgical intervention prior to 6 months since the time of injury is consistently cited as the most significant indicator of neurosensory recovery [18].

13.6 Case Presentations of LN Repair

Case 1—21-year-old man S/P extraction of tooth #32 sustaining numbness on the right side of his tongue. Intraoperatively, the patient

Fig. 13.4 Complete transection of right lingual nerve

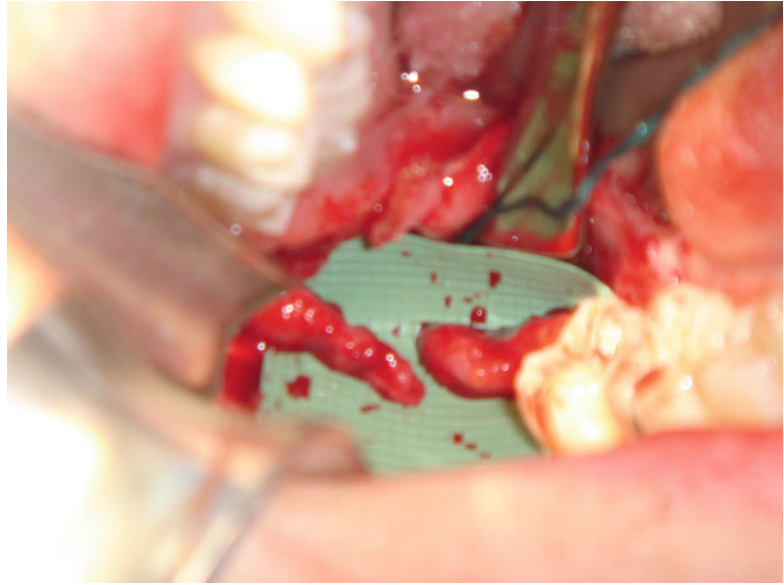
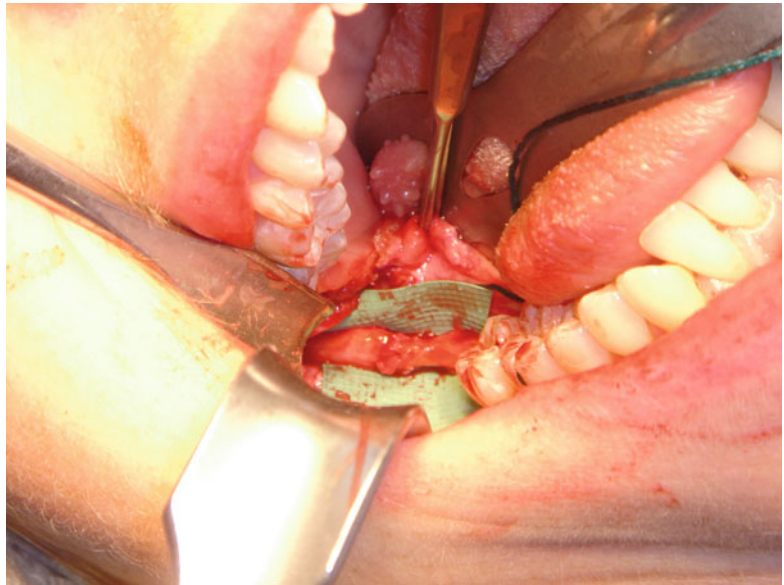

Fig. 13.5 Primary neurorrhaphy of right lingual nerve



was found to have a significant amount of scar tissue present around the nerve causing compression. The patient underwent external neurolysis and entubulization with a type I collagen conduit (Neuragen®, Integra, Plainsboro, NJ) (Fig. 13.3).

Case 2—39-year-old woman S/P extraction of tooth #32 sustaining anesthesia of the right

side of tongue. Intraoperatively, the patient was found to have complete transection of the right LN (Fig. 13.4). The patient underwent primary neurorrhaphy after preparation of the proximal and distal stumps with nerve entubulization using a porcine extracellular matrix-derived nerve conduit (Axoguard®, Axogen, Alachua, FL) (Figs. 13.5 and 13.6).

Fig. 13.6 Entubulization of right lingual nerve repair site using a porcine extracellular matrix-derived nerve conduit (Axoguard[®], Axogen Inc., Alachua, FL)

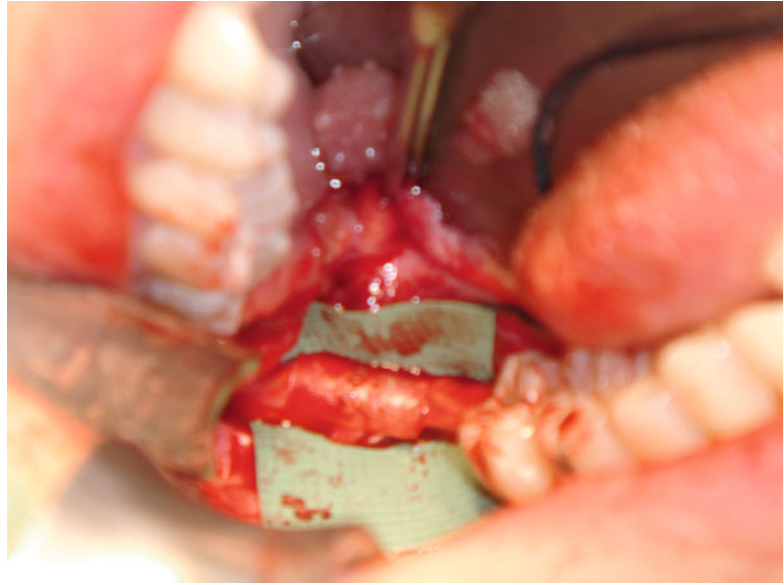
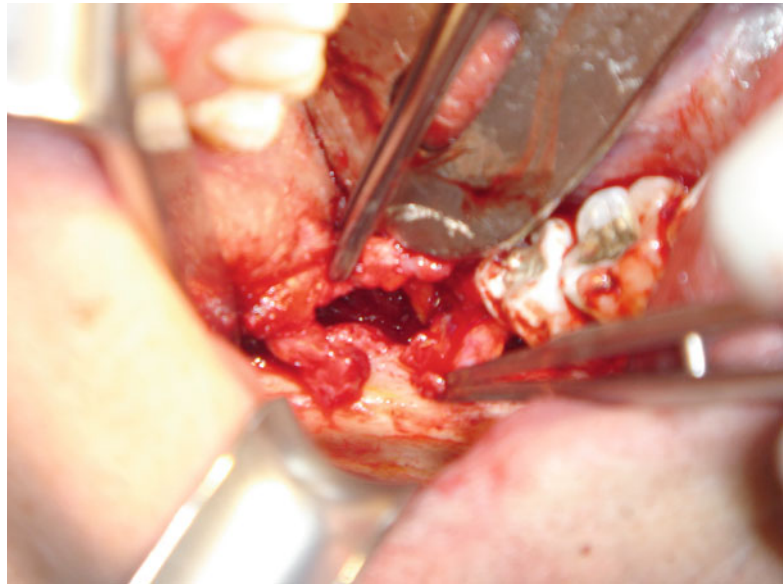


Fig. 13.7 Complete transection of right lingual nerve



Case 3—33-year-old man S/P extraction of tooth #32 sustaining anesthesia of the right side of tongue. Intraoperatively, the patient was found to have complete transection of right LN (Fig. 13.7). A tension-free primary neuroorrhaphy could not be achieved, so a cadaveric

allogeneic nerve graft (Avance[®], Axogen, Alachua, FL) was used to reconstruct the nerve in a tension-free manner (Fig. 13.8). A type I collagen conduit was used subsequently to entubulize the reconstructed segment of the LN (Fig. 13.9).

Fig. 13.8 Reconstruction of right lingual nerve using a cadaveric nerve tissue graft (Avance®, Axogen Inc., Alachua, FL)

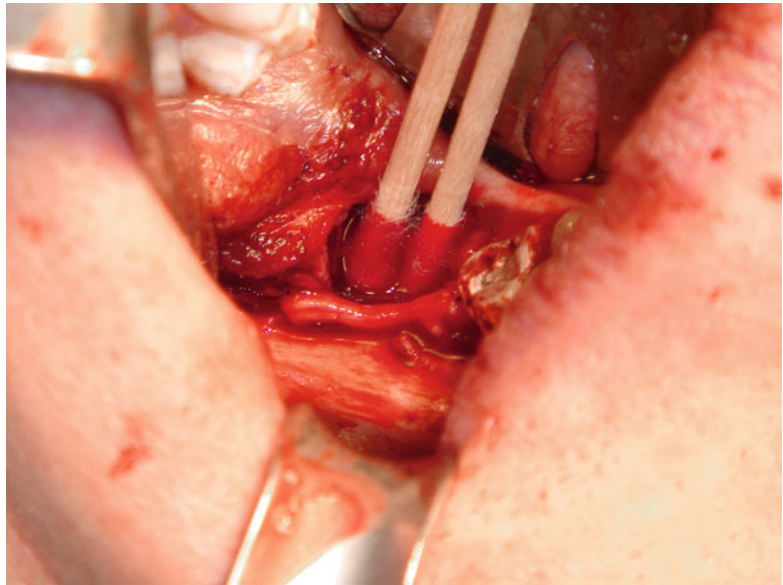
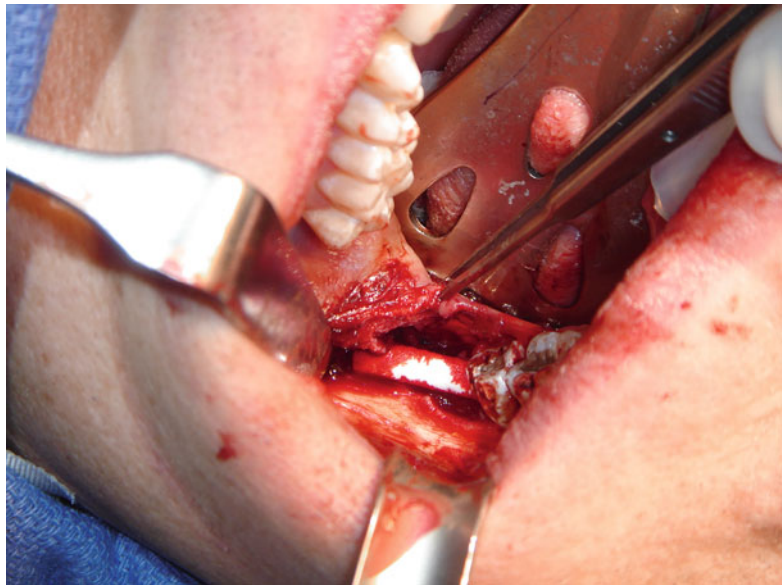


Fig. 13.9 Entubulization of reconstructed right lingual nerve using a type I collagen conduit (Neuragen®, Integra, Plainsboro, NJ)



References

1. Fehrenbach MJ, Herring SW (eds) (2002) Illustrated anatomy of the head and neck. Saunders, Philadelphia, p 207
2. Renesh SH, Zwart R, Scheffer GJ et al (2011) Lingual nerve injury following the use of an i-gel laryngeal mask. *Anesthesia* 66:226
3. Lang MS, Waite PD (2001) Bilateral lingual nerve injury after laryngoscopy for intubation. *J Oral Maxillofac Surg* 59:1497
4. Ruggiero SL (2001) Surgical management of lingual nerve injuries. *Atlas Oral Maxillofac Surg Clin North Am* 9:13
5. Pogrel MA, Renaut A, Schmidt B et al (1995) The relationship of the lingual nerve to the mandibular third molar region: an anatomic study. *J Oral Maxillofac Surg* 53:1178

6. Miloro M, Halkias LE, Slone HW et al (1997) Assessment of the lingual nerve in the third molar region using magnetic resonance imaging. *J Oral Maxillofac Surg* 55:134
7. Blackburn CW, Bramley PA (1989) Lingual nerve damage associated with the removal of lower third molars. *Br Dent J* 167:103
8. Susarla SM, Kaban LB, Donoff RB et al (2007) Functional sensory recovery after trigeminal nerve repair. *J Oral Maxillofac Surg* 65:60
9. Dodson TB, Kaban LB (1997) Recommendations for management of trigeminal nerve defects based on a critical appraisal of the literature. *J Oral Maxillofac Surg* 55:1380
10. Pogrel MA (2002) The results of microneurosurgery of the inferior alveolar and lingual nerve. *J Oral Maxillofac Surg* 60:485
11. Rood JP, Shehab BA (1990) The radiological prediction of the inferior alveolar nerve injury during third molar surgery. *Br J Oral Maxillofac Surg* 28:20
12. Ziccardi VB (2011) Microsurgical techniques for repair of the inferior alveolar and lingual nerves. *Atlas Oral Maxillofac Surg Clin North Am* 19:79
13. Ziccardi VB, Steinberg MJ (2007) Timing of trigeminal nerve microsurgery: a review of the literature. *J Oral Maxillofac Surg* 65:1341
14. Rutner TW, Ziccardi VB, Janal MN (2005) Long-term outcome assessment for lingual nerve microsurgery. *J Oral Maxillofac Surg* 63:1145
15. Susarla SM, Kaban LB, Donoff RB et al (2007) Does early repair of lingual nerve injuries improve functional sensory recovery? *J Oral Maxillofac Surg* 65:1070
16. Susarla SM, Lam NP, Donoff RB et al (2005) A comparison of patient satisfaction and objective assessment of neurosensory function after trigeminal nerve repair. *J Oral Maxillofac Surg* 63:1138
17. Erakat MS, Chuang SK, Shanti RM et al (2012) Interval between injury and lingual nerve repair as a prognostic factor for success using type I collagen conduit. *J Oral Maxillofac Surg* (in press)
18. Ziccardi VB, Rivera L, Gomes J (2009) Comparison of lingual and inferior alveolar nerve microsurgery outcomes. *Quintessence Int* 40:295

M. Anthony Pogrel

Injuries to the inferior alveolar nerve (IAN) occur from multiple causes including trauma, tumor (benign and malignant) involvement or surgery, and iatrogenic causes including orthognathic surgery (usually the sagittal split osteotomy), implant-related procedures in the posterior mandible, as well as dentoalveolar surgery including third molar removal [1]. Less common causes include root canal treatment in the posterior mandible and as a result of an IAN block-type injection [1–3].

Fortunately, in most cases, the IAN has good regenerative potential and recovers spontaneously better than the lingual nerve (LN), particularly in the short term. This is probably because the nerve is encased in a bony canal which guides recovery [4]. Estimates vary, but it is felt that for traumatic injuries, including fractures, injuries from orthognathic surgery, injuries from dentoalveolar surgery, and injuries from local anesthesia, the spontaneous recovery rate is in excess of 50 % and, in some cases, may reach 80 % or higher [4]. The situation is a little different with root canal therapy since if an overextended root canal sealant comes in contact with the IAN and causes physicochemical damage, if the sealant is

not removed within a day or two, the damage is likely to be permanent [2].

14.1 Criteria for Surgical Intervention

Unfortunately, at the present time, imaging by plain radiographs or CT scanning is rarely helpful in determining the etiology or prognosis for a nerve injury, and even MRI scanning, utilizing magnetic resonance neurography [5, 6] (MRN), is generally not helpful, although it may identify large neuromas. Therefore, surgery is generally exploratory, to determine the site of injury, type of injury, and type of repair that might be required. In general, early repairs are felt to provide better results than late repairs, but there is no consensus on what constitutes “early” or “late,” especially since most nerve injuries recover spontaneously. However, some general rules do seem to apply, including the following:

- (a) If there has been a witnessed transection of the IAN (e.g., when removing a third molar or during orthognathic surgery), it is best repaired immediately, and, in fact, if it is repaired at the same time as the surgery that damaged it, patients can make a virtually full recovery.
- (b) When root canal sealant is radiographically within the confines of the inferior alveolar canal (Fig. 14.1) and the patient is symptomatic (anesthesia or dysesthesia), surgical

M.A. Pogrel, DDS, MD, FRCS, FACS
Department of Oral and Maxillofacial Surgery,
University of California, San Francisco,
Room C – 522, 521 Parnassus Avenue, Box 0440
San Francisco, CA 94143-0440, USA
e-mail: tony.pogrel@ucsf.edu

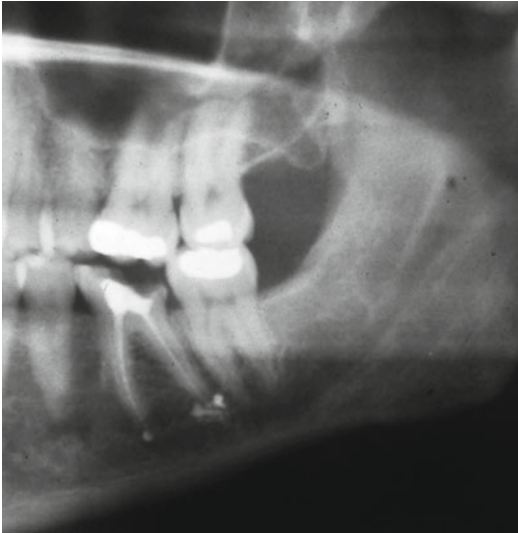

Fig. 14.1 Panorex film showing endodontic sealant in the inferior alveolar canal below the lower left first molar. If symptomatic, the material should be debrided promptly

intervention should be carried out as soon as possible and certainly within 48–72 h of the injury. After this time, nerve injuries tend to become permanent [2].

- (c) If there was no witnessed transection, yet the patient is completely anesthetic or has quality of life-altering dysesthesia 2–3 months after injury, surgery is likely indicated.
- (d) If, after 4–6 months, the patient still does not have protective reflexes (cannot feel when hot or cold substances come in contact with the area innervated by the IAN or are in danger of biting their lip continuously), then surgery may be indicated. Protective reflexes are felt to be present when a patient has 30 % or more of normal feeling (usually measured with a combination of Von Frey's hairs and two-point discrimination) [7].
- (e) Surgery has not been shown to be helpful at any time with injuries related to an IAN local anesthetic block [8]
- (f) Nerve repairs performed after 1 year are felt to provide poor results, but some authors have shown reasonable results with LN repairs, even after as long as 4 years post-injury [9].

14.2 Surgical Approaches to the IAN

The IAN can be approached surgically from an extraoral approach or by an intraoral approach. To a certain extent, this may depend upon surgeon preference, patient preference, and the site of the nerve injury.

Advantages of the extraoral approach are superior surgical access and visualization and, therefore, an increased opportunity to carry out an effective nerve repair. This is particularly true since a surgeon can use the operating microscope at right angles to the mandible, and also bring his/her arms in from the sides, which is the ideal position for carrying out microsurgery. The disadvantages of the extraoral approach are the obvious occurrence of a facial scar (though it is beneath the jaw line), and the possibility of facial nerve involvement, which would add to the original injury.

The intraoral approach is obviously preferable from a cosmetic point of view, but from a surgical standpoint, it is very difficult to use the operating microscope at an oblique angle to the mandible and also difficult to get one's hands in at the same time. A long focal-length lens is necessary on the operating microscope, and a lens of at least 250 mm focal length should be utilized. Many surgeons prefer to carry out intraoral exploration and repair with surgical loupe magnification, usually in the range of four to five times magnification. As far as the actual approach to the IAN is concerned, a number of possible approaches have been described including the following:

1. A block decortication of the mandible [10]. This is the author's personal preference since it does allow isolation and visualization of the IAN over a long portion of its length, allowing visualization of any neuromas, and appropriate mobilization of the nerve to carry out any surgery required. The approach is normally performed with a combination of a reciprocating saw and chisels to fracture off a sufficiently long section of the buccal cortex, revealing the underlying marrow. Care must be taken to avoid penetrating too deeply through the buccal plate with the

reciprocating saw so as not to cause further iatrogenic nerve trauma. If necessary, the inferior border-reciprocating saw can be used to score the inferior border of the mandible to facilitate the splitting of the buccal plate. With careful manipulation of the marrow, the IAN can be identified and isolated and hopefully the site of injury identified. Efforts should be made to remove the buccal cortical plate in one piece, so that it is then stored moist in

saline, and at the end of the surgery, it can be drilled out on the inner surface to avoid traumatizing or compressing the nerve and reattached with one screw for rigid stabilization. It is felt to be important that the IAN be covered on its buccal aspect by bone so that it is not in direct contact with the soft tissues of the cheek. One must be careful with the placement of the screw that it does not in itself iatrogenically damage the IAN (Fig. 14.2).

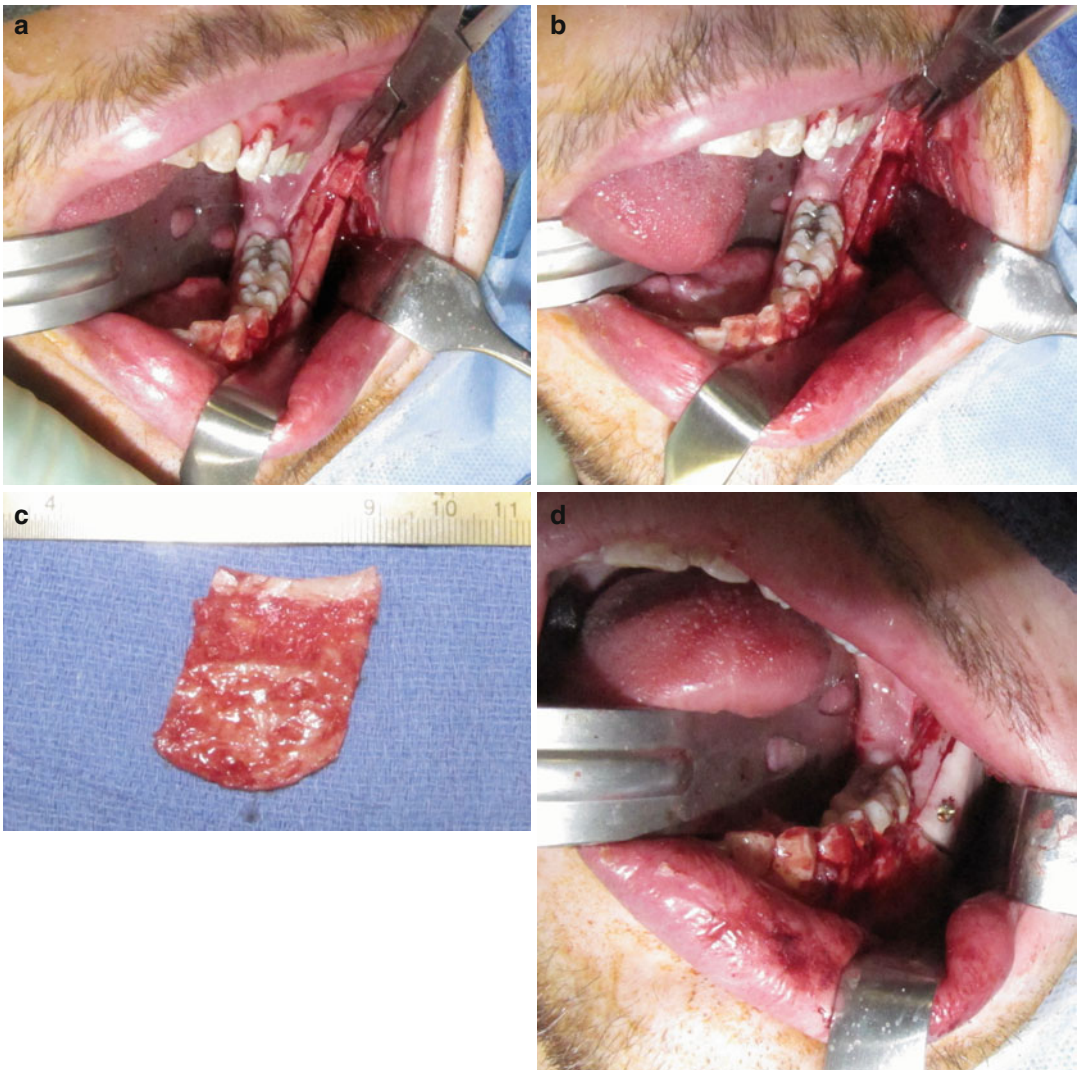


Fig. 14.2 (a) A buccal plate osteotomy outlined with a reciprocating saw. (b) Buccal plate removed to show the inferior alveolar nerve. (c) The buccal plate is stored in saline and hollowed out on its inner aspect to avoid

compressing the IAN when the buccal plate is replaced. (d) The buccal plate replaced to protect the IAN and secured with one screw. (e) Radiographic appearance of the screw securing the buccal plate following IAN repair

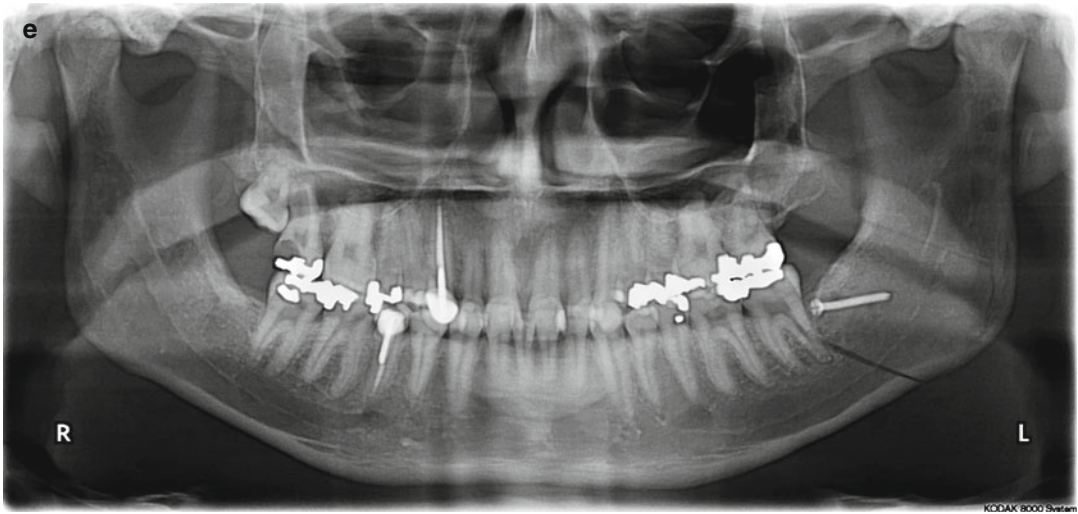
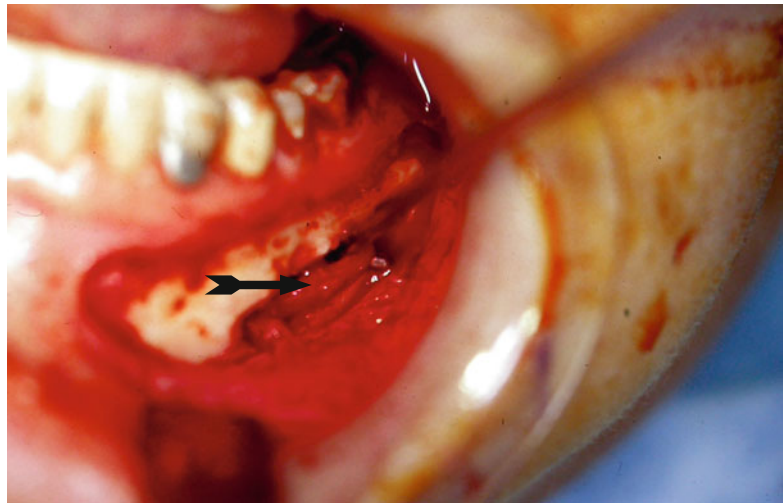


Fig. 14.2 (continued)

Fig. 14.3 The inferior alveolar nerve (*arrow*) approached directly through an isolated buccal plate decortication with a drill



2. The IAN may be approached via a sagittal split osteotomy, and this can provide quite reasonable access to the nerve. The main complication of this technique is the possibility of a resulting malunion or malocclusion that would add to the patient's concerns, in addition to the need to use bone screws or plates.
3. A third approach is to drill directly through the buccal plate to the position of the IAN as identified from cone beam CT scanning (Fig. 14.3). Although the nerve can be approached in this way, it is located at the bottom of a trough, which does not lend itself to adequate exposure and visualization for nerve repair.
4. If the injury is in the region of the mental foramen, then the mental foramen must be identified and dissected out. This is normally done by means of the "donut" technique whereby the buccal cortex is perforated circumferentially about 3 mm from the mental foramen, and then, the perforations are joined together, and the resulting "donut" of bone is removed without injury to the nerve

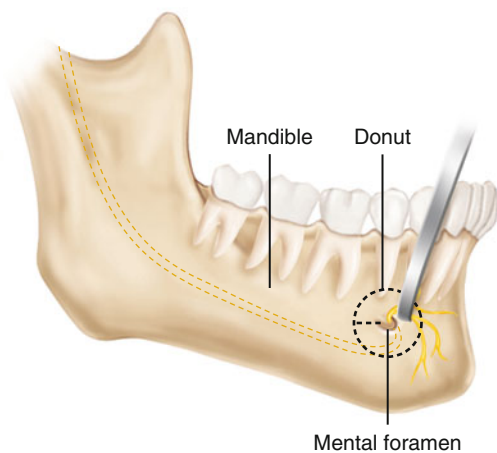


Fig. 14.4 Diagram of the “donut hole” marked out around the mental foramen to gain access to the IAN

(Fig. 14.4). At this point, the IAN can be identified from the mental foramen and exposed appropriately. In many cases, when performing a mental nerve repair, the incisive branch of the IAN must be sacrificed.

5. It is sometimes recommended to perform a nerve repair through a tooth socket when the nerve has been injured or transected during removal of a tooth. In the author’s experience, this has been virtually impossible to achieve, and the best that can be carried out through a tooth socket is to reposition the two ends of the nerve as close as possible at the base of the socket and cover them with an inert barrier that can be resorbable or non-resorbable.

14.3 Surgical Procedures of the IAN

After having exposed, identified, and isolated the IAN via any of the above techniques, it must now be examined to determine the type of injury and the possibility of performing an adequate nerve repair. Conceptually, when visualized, the injury may be a crush-type injury or a partial transection or complete transection, which is usually relatively easy to identify. Stretch-type injuries and injuries from possible intraneural hematomas are more difficult to identify and tend to involve a greater length of the nerve.

Iatrogenic injuries caused by a scalpel or other sharp instrument are often quite clean in nature, whereas those caused by a dental drill are often quite ragged [11]. Where the injury is more profound, and the time from injury to surgical intervention is increased, there is a higher possibility that neuroma formation has taken place. Depending upon the type of injury, this can be a lateral neuroma over a partial transection or a terminal neuroma over a complete transection [12]. Neuromas normally form on the proximal side of an injury, but smaller neuroma type lesions can also develop on the distal aspect of a nerve injury site. One of the advantages of operating early is that there is less possibility of neuroma formation, since it is generally felt that neuroma formation does not commence for 6–8 weeks after an injury and are not fully formed for several months. If there is a complete transection, or a neuroma has to be excised, it may be difficult to perform an end-to-end anastomosis since the IAN will only stretch a few millimeters, in contrast to the lingual nerve that can often be stretched 1–2 cm. Therefore, if a nerve gap of over 7 or 8 mm develops in the IAN, it probably cannot be reapproximated directly and will likely need an interpositional graft of some type.

In addition to the possibility of neuroma formation, another sequelae of delayed repair of a transection injury is that the nerve ends tend to retract away from the site of injury, and the gap may be filled with fibrous tissue, making surgical dissection difficult. There is also often some atrophy of the distal portion of the nerve, such that after several months, it may only be a fibrous strand of tissue (Fig. 14.5) and therefore very difficult to anastomose, with a predictably poor result. This may be due in part to the Wallerian degeneration that has occurred in the distal stump, and, in order for an effective repair to be performed, will require distal dissection to locate normal nerve fascicles for repair with an interpositional graft.

In general, the sequencing of surgery is to first isolate the IAN, then examine it to determine the site and type of injury, and finally determine the type of repair that is necessary (direct vs. indirect (gap) repair).

Fig. 14.5 Diagram of a transected IAN showing a neuroma at the proximal end (on *left*), and atrophy of the distal end (on *right*), making any nerve repair more difficult

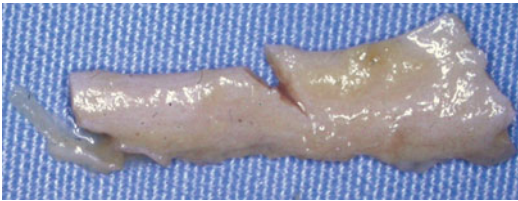



Fig. 14.6 Nerve specimen showing a partial transection injury leaving a V-shaped defect, amenable to epineurial repair

Possible repair procedures include the following:

1. If there is a clean transection with a sharp instrument, and the repair is carried out within 6–8 weeks, then a direct end-to-end anastomosis can often be carried out quite successfully, and, in fact, the fascicles can be lined up correctly (i.e., coaptation) on many occasions offering a better prognosis.
2. If there is a partial transection, then it is sometimes possible to perform a direct repair on the partial transection by approximating the arms of the “V defect” together (Fig. 14.6).
3. If there is a crush injury that can be clearly identified, or a neuroma that has to be excised, then the nerve should be mobilized as much as possible to perform a tension-free anastomosis following resection of the damaged segment, but, if this is not possible, an interpositional graft will be required, as will be described.
4. Implant-related injuries of the IAN can be variable (Fig. 14.7). If the nerve injury is caused by the implant itself, it will usually take the form of a crush-type injury requiring removal of the implant from the area and possible excision of the crushed area of the nerve with a possible reanastomosis. In the author’s experience, if the patient has an implant-related IAN damage, immediate removal of the offending implant leads to neurosensory recovery in about 20 % of cases. However, most implant-related IAN injuries are likely caused by the initial drilling process involving the pilot twist drills. In this case, the injury to the nerve is often ragged and quite severe [11] and may be too extensive for a direct anastomosis and therefore may require an interpositional graft, with a subsequently lower success rate.
5. If the injury is caused by a root canal sealant material, the sealant should be removed from the canal itself by vigorous irrigation, and then, the epineurium should be entered longitudinally and the individual fascicles irrigated thoroughly to remove all sealant from the vicinity of the nerve fascicles. If carried out within 48–72 h of the injury, a good result is normally obtained [2].
6. Regarding mental nerve involvement, the mental nerve normally splits into three branches as it exits from the mental foramen, and if the three branches can be successfully reanastomosed to the main trunk at the point of transection, a reasonable result can be obtained. If only one or two branches can be repaired, it is preferable to repair the two posterior branches since they supply most of the feeling to the lip itself, particularly the outer aspect of the lip. The anterior branch supplies mainly the anterior intraoral mucosa. Mental nerve repairs need to be carried out as soon as possible after injury since with delay the branches become

Fig. 14.7 Panorex showing implants encroaching on the inferior alveolar canal and IAN



difficult to identify in the surrounding scar tissues. Mental nerve repairs carried out within 4 weeks may be more successful than later repairs. Any attempts at mental nerve repair should be done with caution because the nerve fibers are very delicate and repair may lead to scar formation in the area that may adversely affect the nerve repair.

IAN repairs are normally performed with an inert, non-resorbable, suture material, commonly using a monofilament nylon (Ethilon) or polypropylene (Prolene) suture to evoke as minimal inflammatory reaction in the site of the nerve repair. Definitive repairs are best carried out with an 8-0 or 9-0 nylon suture; although preliminary repair with stay sutures can be done with one or two 6-0 or 7-0 nylon sutures, in order to approximate the nerve ends primarily, and then the 8-0 or 9-0 suture could be used for definitive repair and the 6-0 or 7-0 suture(s) can be removed at the end of the case. In general, four epineurial sutures are adequate for the main trunk of the nerve, although for the terminal branches of the mental nerve, only one or two sutures may be all that can be placed due to the decreased diameter of these mental nerve fibers. If four sutures can be placed to repair the IAN, they should be placed opposite each other at the 12 and 6 o'clock and 3 and 9 o'clock positions. All repairs for the IAN (and LN) are epineurial repairs only, since fascicular repairs actually give poorer results in the trigeminal nerve due to the excessive manipulation of the fascicles necessary [13].

On occasion, no site of injury can be identified upon examination of the nerve after exposure, in which case no repair can be carried out, and the

wound is either closed or occasionally a neurectomy may be performed. In these cases of finding a normal nerve at exposure, the injury is more likely to be the result of a stretch-type injury or an intraneural hematoma that have resolved or an injection-related injury of the IAN occurring in the pterygomandibular space and not at the third molar or implant site.

When the repair of the IAN is complete, it is preferable to place an inert barrier over the repair to protect it from the surrounding tissues. If the nerve has been exposed by lateral decortication or by sagittal split osteotomy, then the nerve can be covered by the buccal cortical bone replacement. However, if the nerve has been approached by a direct drilling technique, then it may lie exposed at the bottom of a trench and may need to be covered with an inert membrane so that it does not come in contact with, or even adhere to, the soft tissues of the cheek.

14.3.1 Interpositional Grafts

When direct anastomosis of a nerve is not possible because the gap is too large to achieve a tension-free closure, then an interpositional graft is required. There is no consensus on the most appropriate grafting material, but the options include the following:

1. Autogenous nerve grafts have been the "gold standard," but there are few descriptions of results, which make comparisons of outcomes difficult [14]. A nerve should be selected of approximately the same diameter as the IAN and with approximately the same number of fascicles (five to seven is ideal).

Nerves that have been used for IAN (and LN) repairs include the sural nerve (normally taken just behind the lateral malleolus of the ankle) (Fig. 14.8), the great auricular nerve (easy to access if an extraoral approach to the mandible has been used and more problematic if an intraoral approach has been used since a second extraoral incision is required), and the medial antebrachial cutaneous nerve of the forearm [15]. Of the three, the sural nerve is preferable since it is easy to obtain an appropriate length of nerve, its size and diameter is approximately equal to the IAN (and LN), and the resulting anesthesia over the lateral aspect of the foot can normally be well-tolerated by the patient (Fig. 14.9) [16]. In theory, it does not matter in which direction

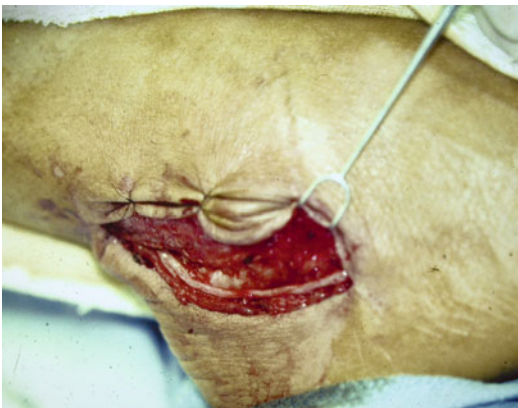


Fig. 14.8 The sural nerve isolated below and posterior to the lateral malleolus of the ankle

the nerve graft is inset between the proximal and distal nerve stumps during the repair since one is only using the graft as an inert tube(s). But, in practice, most microsurgeons prefer to place it with the proximal end placed proximally. The greater auricular nerve does not require a second surgical incision if the extraoral approach to the mandible has been used, but it does leave the patient with an additional area of anesthesia over the angle of the mandible and part of the cheek and lower ear which can be problematic, particularly if they also remain partially or fully anesthetic over the distribution of the IAN. For this reason, as well as the smaller diameter, it is probably better to avoid the greater auricular nerve for trigeminal nerve grafting.

2. Vein grafts have been utilized as an inert tube down which a new nerve can grow. The vein normally employed is the facial vein, but the saphenous vein has also been utilized. If the saphenous vein is utilized one should try and employ a section with no valves within it, and just in case there is a valve, it should be placed with the distal end of the vein to the proximal end of the nerve (Fig. 14.10). In general, it is easy to place a vein graft if it is stretched laterally at each end with a pair of forceps and then placed gently over the ends of the nerve at each end and tacked into place with two sutures (Fig. 14.11). Vein grafts have shown reasonable results for the IAN but not for the lingual nerve [17] (Fig. 14.12) [18]. This

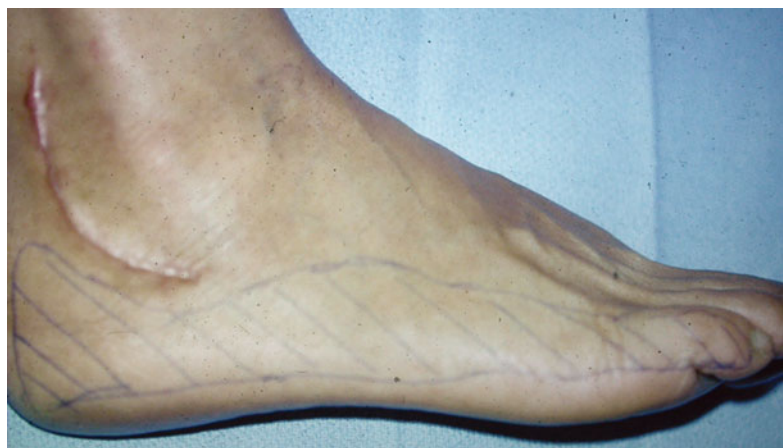

Fig. 14.9 The resulting scar and sensory deficit on the lateral aspect of the foot (outlined) following sural nerve harvest

difference is probably a mechanical issue since the vein is held still with the IAN repair in the inferior alveolar canal, whereas for the lingual nerve, it is constantly being flexed and extended with mouth opening and tongue movement. Veins contain nerve growth factors within the wall of the vein that may help nerve growth, and, in fact, it has been shown that nerve growth factors are more prominently present on the outer aspect of the vein rather than the inner aspect, and therefore, it has been suggested that an inverted vein graft may be preferable [19]. However, numbers are small and there are no controlled studies, and it is also technically difficult to invert a vein graft.

3. Alloplastic nerves (Axogen, Alachua, FL), which are human homografts, are FDA-approved and have been used on a few occasions for repair of the IAN and LN with some success, but more studies are required to

assess their usefulness [20]. Again, these nerve grafts provide the form of an inert tube down which new neurons could grow, following Wallerian degeneration.

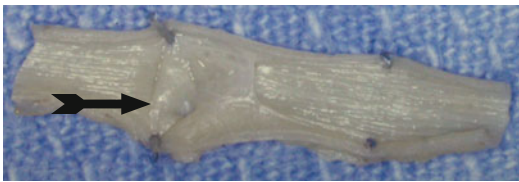


Fig. 14.10 A saphenous vein graft specimen showing a valve within the lumen of the vein (arrow)

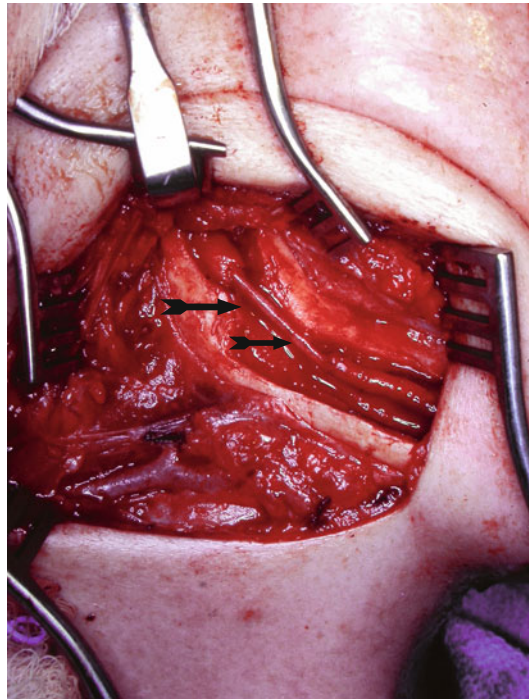


Fig. 14.12 A completed vein graft (arrows) to the right IAN placed via an extraoral approach

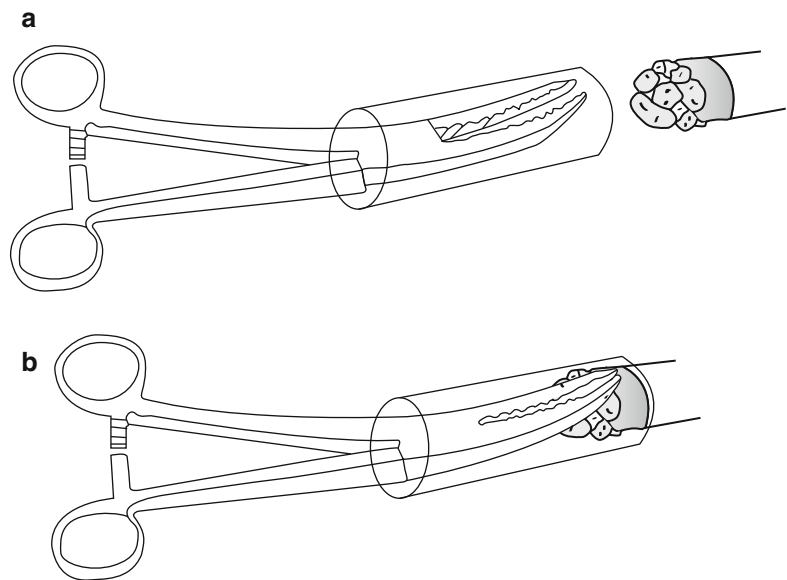


Fig. 14.11 Diagram of a vein graft used to replace a damaged section of an IAN. The vein is expanded with forceps (a) and placed over the stump of the nerve (b) and secured with two sutures at each end (Reprinted from Pogrel and Maghen [17], p. 985, with permission)

4. Synthetic alloplastic tubes have not proven successful as interpositional grafts, and a number of studies have shown that nerves do not appear to grow through Dacron or Goretex (expanded polytetrafluoroethylene, e-PTFE) tubes even though they are easy to obtain and easy to place on each end of the nerve. Although there has been some success in using e-PTFE in the animal model [21], they are not clinically applicable [22, 23] (Fig. 14.13).

Nerve growth factors are becoming available clinically and, in the future, could show promise in improving the success rates of interpositional grafts of various kinds. Basement membrane laminin (matrigel) is commercially available and has been used on isolated occasions inside a vein graft or an inert graft to try and encourage nerve regrowth, but the results appear variable [24]. This material is not, however, FDA-approved for this purpose.

14.3.2 Inferior Alveolar Nerve Neurectomy

On some occasions, it is either not possible to carry out a nerve repair, a nerve repair may have failed, or the patient may be having so much dysesthesia that they do not want to attempt a nerve repair. In these cases, a complete neurectomy of the IAN may be justified. However, patients should realize the possible side effects and consequences of this procedure. In particular, it is possible that if dysesthesia is the main concern, then the pain may have “centralized” such that even complete transection of the nerve may result in a “phantom limb” type phenomenon whereby the patient is totally numb over the area of the nerve transection but still has centrally mediated or neuropathic pain [25, 26]. To a certain extent, the success of a diagnostic IAN block injection administered preoperatively can help to determine whether a neurectomy would be successful. This type of dysesthesia does not normally centralize for at least 4 months such that the earlier the neurectomy is carried out to some extent, the better the result. Another problem with a neurectomy is that some patients adapt poorly to permanent

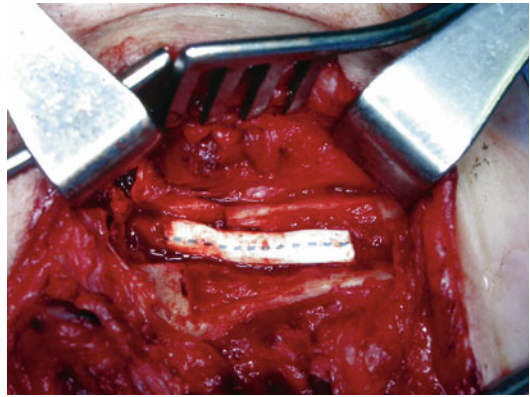


Fig. 14.13 A Goretex tube used as an inert conduit in an attempt to repair the IAN from an extraoral approach. This repair was not successful in achieving significant neurosensory recovery

and complete anesthesia of the lower lip and chin. They often think preoperatively that it will be preferable to the symptoms that they are having at present, but it is not unknown for patients to regret this decision afterwards. Therefore, they do need to be administered a long-acting IAN block to provide them some idea of what a neurectomy procedure will feel like in the long term.

Although there are various techniques described for an IAN neurectomy, the author’s belief is that if it is to be carried out, it should be performed adequately and using sound surgical principles. The technique employed is to identify the IAN at the lingula by means of a 2 cm incision over the external oblique ridge with blunt medial dissection back to the lingula. Similarly, the IAN is identified at the mental foramen, and the mental nerve is sectioned, as well as the incisive branch, which is sectioned blindly via the mental foremen utilizing a number 11 pointed scalpel blade. Having been sectioned, the cut ends of the mental nerve are then ligated securely with a non-resorbable suture. Black silk sutures are still largely employed for this procedure. Once the IAN has been separated from the mental nerve, it is then pulled from the lingula such that one can normally pull out the entire IAN from the inferior alveolar canal so that one has 5 or 6 cm of nerve at the lingula (Fig. 14.14). This nerve is then cut and discarded, and the proximal cut end of the IAN is now double ligated with black silk and buried into adjacent muscle tissue.

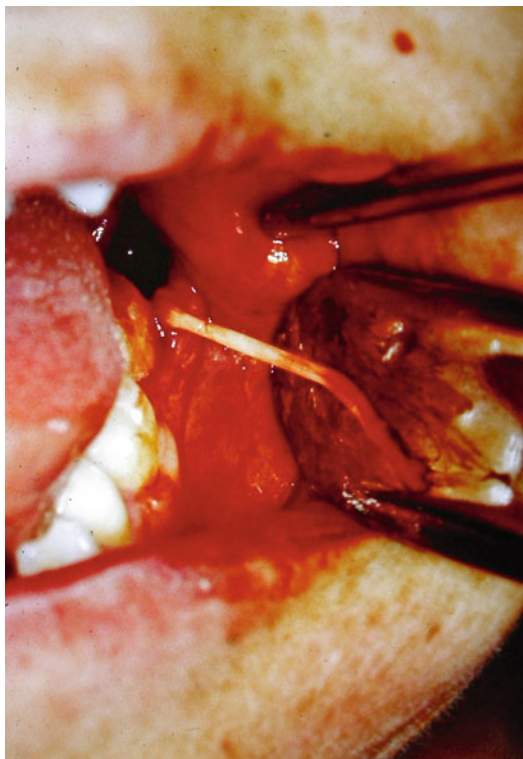


Fig. 14.14 The IAN pulled out of the mandible from the lingula as part of an IAN neurectomy procedure

The muscle utilized is the medial pterygoid muscle, and the technique is to leave the most distal of the two ties on the nerve with one long end, and a blunt pair of forceps are passed through the medial pterygoid muscle from its medial aspect, picks up the end of the suture laterally, and pulls the suture and the nerve into the body of the medial pterygoid muscle where it is left in position (Fig. 14.15). The reason for this is that muscle is rich in laminin which coats the end of the IAN and may minimize the possibility of neuroma formation. To try to ensure that nerve regrowth cannot occur, the inferior alveolar canal is blocked at the lingula and at the mental foramen with bone wax.

14.3.3 Results of IAN Repair Surgery

It is difficult to assess the results of IAN surgery since reports are few, and the patient demographics are heterogeneous, including the fact that the

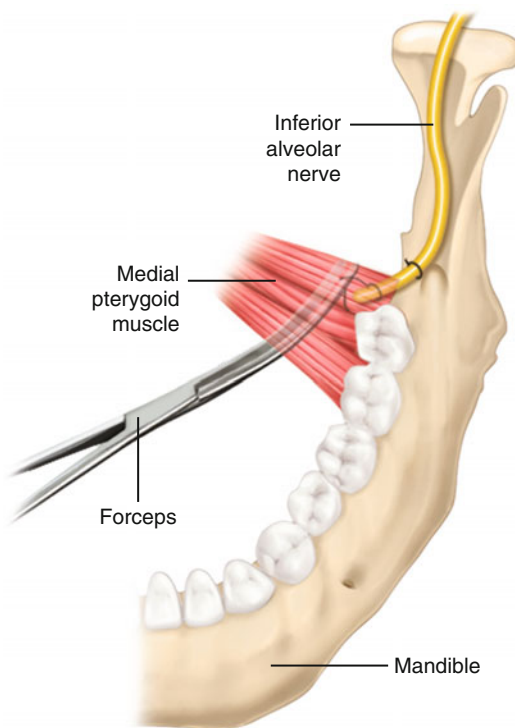
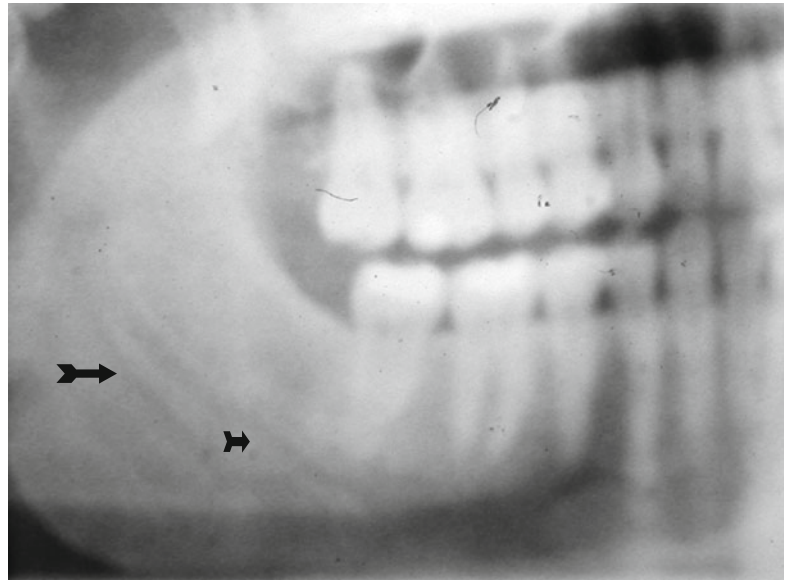

Fig. 14.15 Diagram of a stump of the IAN pulled into the medial pterygoid muscle

timing of repair is different in the studies, and the success is measured in different ways [14]. Nevertheless, it does appear that overall, if repairs are carried out within 2–3 months, then over 50 % of patients will recover over 50 % of sensation, although some authors do publish higher success rates. When repairs are carried out later, results are less satisfactory, and results utilizing interpositional grafts appear to be less successful, probably because a regenerating neuron must negotiate two neural anastomosis sites. Patients need to take these less than satisfactory results into account when determining whether to undergo surgery or not.

It has been noted from recent cone beam computed tomography (CBCT) studies that up to 5 % of the population may have a bifid IAN [23] (Fig. 14.16) which could certainly help to explain some of the atypical responses noted with some injuries when it may be assumed that only one of two branches of the nerve may have been injured and the other branch is intact.

Fig. 14.16 Panorex showing two inferior alveolar canals (*arrows*) in a patient with a bifid IAN



A recent long-term study of patients who did not undergo nerve repair surgery shows that with time most patients do get some improvement and are generally less troubled by the injury. This may be due to a natural process of adaptation but certainly should be factored into the equation of whether or not to proceed with surgery [24].

References

1. Pogrel MA, Thamby S (1999) The etiology of altered sensation in the inferior alveolar, lingual, and mental nerves as a result of dental treatment. *J Calif Dent Assoc* 27(7):531, 534–538
2. Pogrel MA (2007) Damage to the inferior alveolar nerve as the result of root canal therapy. *J Am Dent Assoc* 138(1):65–69
3. Pogrel MA (2007) Permanent nerve damage from inferior alveolar nerve blocks – an update to include articaine. *J Calif Dent Assoc* 35(4):271–273
4. Alling CC 3rd (1986) Dysesthesia of the lingual and inferior alveolar nerves following third molar surgery. *J Oral Maxillofac Surg* 44(6):454–457
5. Chau A (2012) Comparison between the use of magnetic resonance imaging and cone beam computed tomography for mandibular nerve identification. *Clin Oral Implants Res* 23:253–256
6. Terumitsu M et al (2011) Morphologic evaluation of the inferior alveolar nerve in patients with sensory disorders by high-resolution 3D volume rendering magnetic resonance neurography on a 3.0-T system. *Oral Surg Oral Med Oral Pathol Oral Radiol Endod* 111(1):95–102
7. Pogrel MA (2002) The results of microneurosurgery of the inferior alveolar and lingual nerve. *J Oral Maxillofac Surg* 60(5):485–489
8. Pogrel MA, Thamby S (2000) Permanent nerve involvement resulting from inferior alveolar nerve blocks. *J Am Dent Assoc* 131(7):901–907
9. Robinson PP, Smith KG (1996) A study on the efficacy of late lingual nerve repair. *Br J Oral Maxillofac Surg* 34(1):96–103
10. Miloro M (1995) Surgical access for inferior alveolar nerve repair. *J Oral Maxillofac Surg* 53(10):1224–1225
11. Pogrel MA, Le H (2006) Etiology of lingual nerve injuries in the third molar region: a cadaver and histologic study. *J Oral Maxillofac Surg* 64(12):1790–1794
12. Gregg JM (1992) Abnormal responses to trigeminal nerve injuries. *Oral Maxillofac Surg Clin North Am* 4:339–351
13. Zuniga JR (2001) Principles of neurosurgery. *Oral Maxillofac Surg Clin North Am* 13:331–342
14. Gregg JM (2001) An outcome analysis of clinical trials of surgical treatment of traumatic trigeminal sensory neuropathy. *Oral Maxillofac Surg Clin North Am* 13:377–381
15. McCormick SU et al (1994) Microanatomic analysis of the medial antebrachial nerve as a potential donor nerve in maxillofacial grafting. *J Oral Maxillofac Surg* 52(10):1022–1025; discussion 1026–1027
16. Miloro M, Stoner JA (2005) Subjective outcomes following sural nerve harvest. *J Oral Maxillofac Surg* 63(8):1150–1154
17. Pogrel MA, Maghen A (2001) The use of autogenous vein grafts for inferior alveolar and lingual nerve reconstruction. *J Oral Maxillofac Surg* 59(9):985–988; discussion 988–993

18. Miloro M (2001) Discussion: the use of autogenous vein grafts for inferior alveolar and lingual nerve reconstruction. *J Oral Maxillofac Surg* 59(3): 988–993
19. Wang J, Goodger NM, Pogrel MA (2003) A method of invaginating the facial vein for inferior alveolar nerve repair. *J Oral Maxillofac Surg* 61(7): 848–849
20. Shanti RM, Ziccardi VB (2011) Use of decellularized nerve allograft for inferior alveolar nerve reconstruction: a case report. *J Oral Maxillofac Surg* 69(2):550–553
21. Miloro M, Macy JM (2000) Expanded polytetrafluoroethylene entubulation of the rabbit inferior alveolar nerve. *Oral Surg Oral Med Oral Pathol Oral Radiol Endod* 89(3):292–298
22. Pogrel MA, McDonald AR, Kaban LB (1998) Goretex tubing as a conduit for repair of lingual and inferior alveolar nerve continuity defects: a preliminary report. *J Oral Maxillofac Surg* 56(3):319–321; discussion 321–322
23. Pitta MC et al (2001) Use of Goretex tubing as a conduit for inferior alveolar and lingual nerve repair: experience with 6 cases. *J Oral Maxillofac Surg* 59(5):493–496; discussion 497
24. Kim SM, Lee SK, Lee JH (2007) Peripheral nerve regeneration using a three dimensionally cultured Schwann cell conduit. *J Craniofac Surg* 18(3): 475–488
25. Campbell R (1992) Neuroablative procedures in the management of traumatic trigeminal neuropathies. *Oral Maxillofac Surg Clin North Am* 4:465–472
26. Gregg JM (2001) Medical management of traumatic neuropathies. *Oral Maxillofac Surg Clin North Am* 13:343–363

Alison Snyder-Warwick, Thomas H. Tung,
and Susan E. Mackinnon

Facial expressions provide unique insight into an individual's emotions, and distinct, universal facial expressions have been identified for a multitude of emotions [23]. The anatomy involved with facial expression has been the interest of many investigators over the years. Ekman and Friesen defined 46 action units that correspond to independent facial movements. Darwin, a student of Charles Bell, sought to anatomically describe the musculature involved in specific facial expressions [24]. Rubin [74] studied the active, dominant facial musculature and its vector of pull during smiling and described the three main smile types. This anatomical interest in facial expression holds particular importance to the reconstructive surgeon treating facial nerve injuries. Subtle recreation of native anatomy is the ultimate goal, one that is most challenging for dynamic expression.

Facial nerve injuries or dysfunction can have devastating sequelae. Facial expression is integral to human communication and plays an important role in human perceptions of self and others. Functional deficits, such as eye irritation or corneal ulceration, speech deficits, nasal collapse,

and oral incompetence, may result. Facial nerve pathology may result from a multitude of etiologies, affecting all age ranges. The treatment of facial nerve pathology also varies, according to the individual circumstance. This chapter describes the processes of facial nerve dysfunction, the principles of surgical management, and possible future endeavors for additional treatment techniques.

15.1 Facial Nerve Anatomy

As with all surgery, appropriate anatomical knowledge facilitates diagnosis and management of pathology. The facial nerve is composed of motor fibers, which innervate the muscles of facial expression, and the nervus intermedius, which is composed of somatosensory and visceral motor fibers, supplying taste to the anterior two-thirds of the tongue, taste to soft palate, and parasympathetic innervation to the submandibular, sublingual, and lacrimal glands. The course of the facial nerve and its central connections is divided into anatomical segments.

Signaling along the facial nerve pathway originates in the cerebral cortex and passes via the corticobulbar tracts and posterior limbs of the internal capsule to the brainstem. En route, the corticobulbar tracts to the upper face cross twice, while the corticobulbar tracts to the lower face cross only once. The facial nucleus is located within the pontine tegmentum in the

A. Snyder-Warwick, MD (✉) • T.H. Tung, MD
S.E. Mackinnon, MD
Division of Plastic and Reconstructive Surgery,
Washington University School of Medicine,
660 South Euclid Ave., Campus 8238,
St. Louis, MO, 63110, USA
e-mail: snyderak@wudosis.wustl.edu;
tungt@wudosis.wustl.edu;
mackinnon@wudosis.wustl.edu

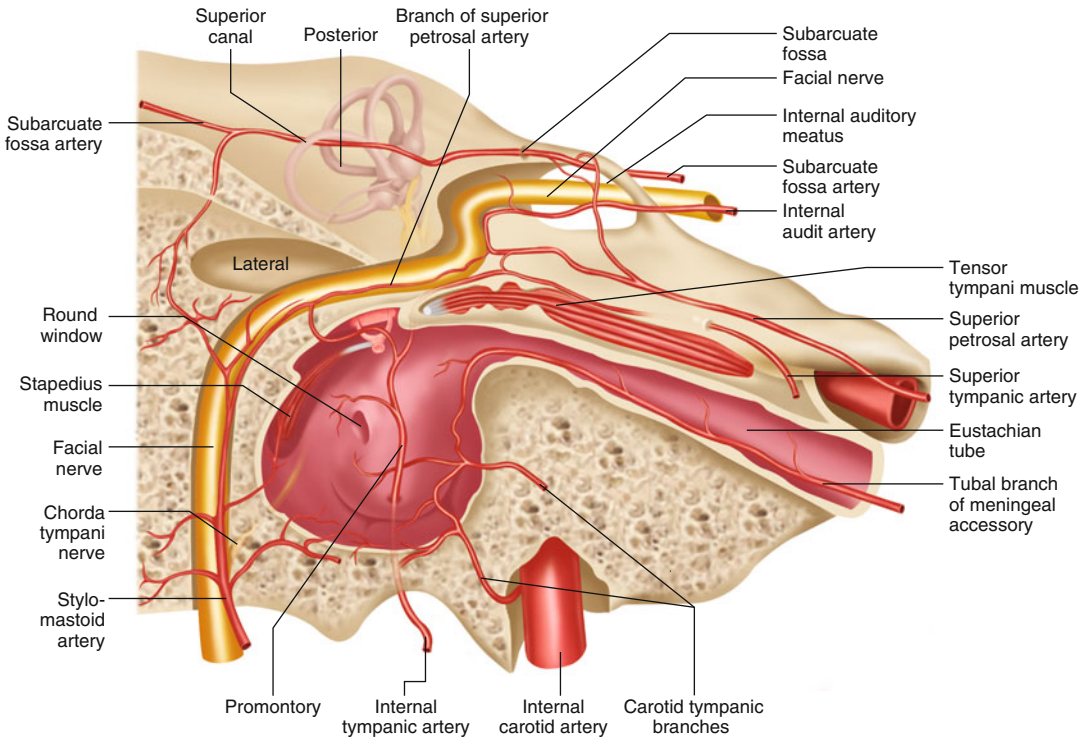


Fig. 15.1 Intratemporal course of the facial nerve. The intratemporal course of the facial nerve consists of three segments: the labyrinthine, tympanic, and mastoid segments. The narrow bony confines of the labyrinthine

segment combined with the absence of anastomosing arterial cascades make this segment most vulnerable to ischemic insult

lower third of the pons. Postsynaptic motor fibers exit the cerebellopontine angle after contributing to the facial colliculus of the fourth ventricle and passing the abducens nucleus. The facial nerve is accompanied by the nervus intermedius and the vestibulocochlear nerve as it exits the cerebellopontine angle. These nerves then enter the meatal segment at the internal auditory canal, with the facial nerve traveling more cephalad. The intratemporal course of the facial nerve consists of three segments: the labyrinthine, tympanic (horizontal), and mastoid (descending) regions (Fig. 15.1) [63, 68, 69]. The facial nerve travels through the petrous portion of the temporal bone in a canal called the fallopian canal. The labyrinthine segment extends for 3–5 mm from the internal acoustic meatus to the facial hiatus ([69]; summarized in [65]). This segment is the narrowest section of

the facial nerve's course and also lacks anastomosing arterial cascades, making this portion of the nerve most susceptible to various pathologic states [36, 45, 69]. The nerve course then makes a sharp angle, or genu, at the geniculate ganglion. The geniculate ganglion results from the joining of the facial nerve and the nervus intermedius fibers into a common trunk. The chorda tympani also contributes to this ganglion, which then branches into the petrosal nerves. The geniculate ganglion marks the start of the tympanic segment. The tympanic segment spans 8–11 mm to the pyramidal eminence and horizontal semicircular canal. A second genu lies in this region, between the posterior auditory canal wall and the lateral semicircular canal. The stapedial portion of the tympanic segment marks the second narrowest region of the facial nerve's intratemporal course [45]. The mastoid segment

extends 10–14 mm vertically from the second genu to the stylomastoid foramen, where the facial nerve exits the temporal bone. The mastoid segment marks the longest portion of the facial nerve's intratemporal course ([69]; summarized in [65]). The facial nerve has variable internal topography within its intratemporal portion, complicating surgical repairs along this portion.

From the stylomastoid foramen, the facial nerve passes between the digastric and stylohyoid muscles and enters the parotid. Branches supplying the posterior auricular muscles as well as the stylohyoid and posterior belly of the digastric exit the facial nerve before it enters the parotid. The facial nerve courses between the superficial and deep parotid lobes. At the pes anserinus, the facial nerve divides into the temporofacial and cervicofacial trunks. Further branching of the facial nerve results in the temporal, zygomatic, buccal, marginal mandibular, and cervical divisions ([69]; summarized in [65]). Many of these branches have variable branching patterns that may differ between the two sides of the face within the same individual. The facial nerve also demonstrates frequent interconnections among branches, resulting in redundant motor function [100], allowing transfer of a contralateral redundant branch for surgical reconstruction.

Pathology at any point along this pathway may result in facial nerve dysfunction. With

knowledge of the facial nerve anatomy, a careful history and physical examination, occasionally combined with appropriate diagnostic studies, may identify the location of the nerve pathology and better guide management.

15.2 Etiopathology of Facial Paralysis

Facial paralysis (FP) may occur due to a multitude of processes, which are summarized in Table 15.1. The palsy may be complete or incomplete, congenital or acquired, bilateral or unilateral, and central or peripheral. Causes of facial nerve dysfunction differ between pediatric and adult patients, although Bell's palsy is frequently causative in patients of all ages [16, 25, 80, 81, 102].

Bell's palsy refers to idiopathic facial paralysis, which accounts for 30–70 % of reported cases of acquired facial palsy [7]. Herpes simplex virus (HSV) is now believed to account for this phenomenon. The virus is latent within the geniculate ganglion cells. At autopsy, polymerase chain reaction (PCR) has confirmed the presence of HSV genomic material in human geniculate ganglia [87]. In addition, facial paralysis has been induced by HSV infection in animal models [99], with a small percentage of animals exhibiting transient paralysis upon HSV reactivation [86]. Viral replication after reactivation

Table 15.1 Etiologies of facial paralysis

| | |
|---------------|---|
| Congenital | Syndromic, non-syndromic, vascular malformation, Möbius syndrome, hemifacial microsomia, Goldenhar, Poland, Melkersson-Rosenthal (episodic) |
| Birth related | Traumatic or difficult delivery, instrumentation |
| Bell's | Idiopathic, HSV |
| Traumatic | Temporal bone fracture, blunt force to cheek |
| Infectious | Acute otitis media, Lyme disease, VZV (Ramsay Hunt), HSV, EBV, mycoplasma, mastoiditis |
| Neoplastic | Central, parotid, or acoustic tumors |
| Iatrogenic | Brain, middle ear, and facial surgery |
| Ischemic | |
| Neurogenic | Guillain-Barre |
| Hematologic | Leukemia, hemophilia |
| Hypertension | |

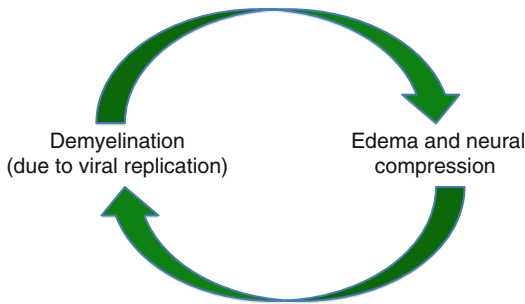


Fig. 15.2 Pathophysiology of Bell's palsy. Herpes simplex viral replication results in nerve demyelination and edema which cause neural compression within the fallopian canal, creating a cycle of neural injury

tion causes facial nerve demyelination, resulting in neural edema. This edema may cause facial nerve compression within the fallopian canal, resulting in a cycle of neural damage (Fig. 15.2). While this phenomenon can occur at any age, the mean age of occurrence is 40–44 years (reviewed in [35]). A review of the emergency room visits for children with facial palsy in Taiwan determined that 50 % of cases resulted from Bell's palsy [102].

In the pediatric population, Bell's palsy, infectious etiologies, and trauma are the most common causes of facial palsy [16, 25, 80, 102]. In a review of 157 pediatric patients with facial palsy, Cha et al. [16] determined 66 % of cases resulted from Bell's, while 14 % had infectious and 13 % traumatic etiologies. In their comparison to adult patients with facial palsy treated at the same institution, pediatric patients displayed higher rates of Bell's palsy (66 % compared to 55 %) and traumatic (16 % compared to 5.9 %) etiologies. Shih et al. [80] described Bell's in 78 % of their 56 cases of pediatric FP. A review of 35 cases of pediatric facial nerve palsy at Boston Children's demonstrated 37 % of cases resulted from an infectious etiology, 20 % from trauma, and only 9 % from Bell's. There was a bimodal distribution of ages of patients with traumatic and infectious causes of facial palsy at 2 years and 11.5 years [25]. In pediatric patients with an infectious etiology for FP, acute otitis media and varicella-zoster virus (VZV) [33, 67] are common instigators. Acute otitis media accounted for 10 % of the emergency room visits for FP in children, all

under the age of 2 years, at Chang Gung Memorial Hospital [102]. Lyme disease is the most common cause of acute pediatric facial paralysis in endemic areas and should be considered in cases of bilateral paralysis and recent exposure to endemic areas in the summer months [81]. In general, the pediatric population with FP displays a greater incidence of trauma, neoplasm, and congenital anomalies compared to adult patients with FP [80, 102]. The facial nerve is positioned more laterally in infancy, making it more susceptible to trauma, including birth-related trauma [81]. When evaluating the pediatric patient with acquired facial paralysis, it is important to consider that facial palsy may be an early sign of systemic disease. Rarely, hematologic disorders, such as leukemia and hemophilia, and neoplastic processes may present with acute facial paralysis [81].

A knowledge of the etiology of facial paralysis provides valuable information regarding management, such as antibiotic and steroid administration and surgical intervention, but also may help delineate prognostic expectations. In the setting of Bell's palsy, 10–15 % of patients regain no or poor function and 5–29 % have residual sequelae (such as spasm or synkinesis), which varies in severity [70, 71]. The overall recovery rate is related to the severity of paralysis. House-Brackmann grades of I or II often result in recovery rates of ~90 % [16], and good recovery may be expected if neurodegeneration is <90 % [35]. Conversely, more severe paralysis with higher House-Brackmann scores carries a worse prognosis for recovery [49]. Age is inversely related to the recovery rate in patients with Bell's palsy [22], and recovery is worse in patients greater than 50 years of age [49]. In pediatric patients with facial palsy, Evans et al. [25] noted faster recovery with infectious etiologies (~1 month) compared to traumatic etiologies (~8 months). Recovery rates range from 81 to 100 % for Bell's palsy, 73–91 % for infectious etiologies, and 43–90 % in traumatic etiologies in the pediatric population [16, 25, 26, 83]. Prognosis is poorer in paralysis due to congenital and neoplastic processes [97, 102]. Adults demonstrate similar recovery rates of 89 % for infectious etiologies and 64 % from

traumatic injury [16]. In general, prognosis is more favorable in cases with younger patient age, House-Brackmann score < III, normal nerve excitability testing, and a normal stapedial reflex [49, 84].

15.3 Evaluation

Careful evaluation of the patient with facial palsy is required to establish a proper diagnosis. Management of the patient with facial paralysis differs depending on the diagnosis. There is a fundamental difference in the natural history and pathology between acquired and congenital FP, for example. Acquired FP includes sequelae of reinnervation and may have a progressive or improving course. Congenital cases, however, may have absent or hypoplastic structures, a static course, and absence of reinnervation sequelae. Establishing the correct diagnosis for facial paralysis is essential to effective management.

A detailed history provides immense diagnostic information. The onset of symptoms should be discussed to determine the temporal pattern of onset. It is important to note that FP beginning from the time of birth does not automatically indicate a congenital etiology, as birth-related trauma, particularly use of instrumentation such as forceps, may result in facial nerve injury beginning at the time of birth. Birth history including birth weight, duration and difficulty of labor, and requirement for instrumentation can help to elucidate these different etiologies. In traumatic nerve injury, the mechanism of injury is important. The chronicity of onset is also important. An abrupt onset of FP may indicate an infectious, traumatic, or ischemic etiology, while an insidious, progressive onset of FP is more suggestive of a neoplastic process. The presence of any additional symptoms occurring simultaneously with the facial paralysis should also be noted. Simultaneous abducens nerve palsy suggests localization of the etiologic process to the region of the facial nucleus at the cerebellopontine angle, while hearing difficulties may indicate a process within the middle ear. For acquired cases of FP, the elapsed time from onset is important to determine potential for improve-

ment and the possibility of reinnervation of native musculature.

The functional consequences of facial paralysis should also be elicited during initial evaluation. Protection of the cornea is paramount, particularly in acquired cases as patients with congenital FP tend to maintain corneal protection. The history should investigate frequent tearing, eye irritation, and the presence of lagophthalmos during sleep. Patients may describe difficulties with oral incompetence, speech (bilabial sounds), and altered taste sensation. Nasal breathing difficulties due to external valve collapse are often overlooked and should be discussed during the patient interview. The psychosocial impact of the patient's FP should also be investigated.

A complete head and neck examination, including full cranial nerve evaluation, should be documented. Ocular examination should include assessment of extraocular movements, Bell's reflex, and corneal sensation. Any abnormalities in corneal sensation necessitate ophthalmologic referral. Each facial nerve branch should be independently evaluated via brow elevation, forced eye closure, relaxed eye closure, maximal smile, lip elevation (show teeth), pucker, lower lip depression, and platysmal contraction. Facial symmetry is assessed both at rest and with animation. Particular note is made of midline shift of the mouth and asymmetries in oral commissure position at rest and with movement. Synkinetic and dyskinetic movements are also noted. Documentation of initial facial function at the time of presentation serves as an important baseline for outcomes assessment. The functional status of facial movements can be classified according to the House-Brackmann scale [48] (Tables 15.2 and 15.3). While this scale is not ideal for isolated paralysis of a facial nerve branch or congenital cases, it is user friendly and is the accepted scale of the Facial Nerve Disorders Committee of the American Academy of Otolaryngology—Head and Neck Surgery. In addition to grading, facial function should be documented photographically as well as with video with a standardized set of movements. Quantification of facial movements may also be assessed and documented in a

Table 15.2 The House-Brackmann facial nerve grading scale

| Grade | Description |
|-------|--|
| I | Normal |
| II | Mild dysfunction, slight weakness noticeable only on close inspection, good to moderate forehead function, complete eye closure with minimal effort, slight smile asymmetry with maximal effort, synkinesis barely noticeable |
| III | Moderate dysfunction, obvious but not disfiguring difference between sides, slight to moderate forehead movement, complete eye closure with effort, strong but asymmetric mouth movement, noticeable but not severe synkinesis |
| IV | Moderately severe dysfunction, obvious weakness and/or disfiguring asymmetry, normal rest symmetry and tone, inability to lift brow, incomplete eye closure, mouth asymmetry with maximal effort, severe synkinesis |
| V | Severe dysfunction, motion barely perceptible, rest asymmetry, no forehead motion, incomplete eye closure, slight movement corner mouth, synkinesis usually absent |
| VI | No movement, no synkinesis |

House and Brackmann [48]

Table 15.3 Modified House-Brackmann facial grading system

| Facial nerve grading scale 1.0 | | | | | |
|--------------------------------|--------------|------------|----------------|-----------------|-------|
| Gross | Resting tone | Forehead | Eye closure | Mouth | Grade |
| Normal function | | | | | I |
| Slight | Normal | Mod-good | Minimal effort | Slight asymm | II |
| Obvious | Normal | Slight-mod | Full effort | Slight weak | III |
| Disfiguring | Normal | None | Incomplete | Asymmetric | IV |
| Barely perceptible | Asymmetric | None | Incomplete | Slight movement | V |
| Total paralysis: no movement | | | | | VI |

From Henstrom et al. [47]

number of ways ranging from measurements with a simple handheld ruler [4, 62] to complex video-graphic systems [32]. Bray et al. [14] have developed software that utilizes the standard reference of iris diameter to normalize smile measurements on still digital photographs [38, 41], providing an easy to use standard to determine oral commissure excursion that is universally applicable.

While not universally utilized, specific diagnostic studies may occasionally be useful adjuncts in the management of facial nerve injury. In the setting of acute FP, electroneuronography (ENOG) can predict which patients will have a poor outcome. ENOG records a compound action potential of facial muscle after a maximal electrically evoked transdermal stimulus near the stylomastoid foramen by measuring the movement of the facial muscles with a surface electrode at the nasolabial fold or perioral region. The recorded amplitude is proportional to the number of axon fibers that have a conduction block proximally at

the level of the lesion that could still be stimulated (neurapraxia) [34]. Those axons that have undergone Wallerian degeneration (axonotmesis, neurotmesis) are unable to propagate electrically generated evoked potentials distal to the lesion. Results from the injured facial nerve are compared to the uninjured side, and deficits are expressed as a percentage of the action potential of the uninjured side. Patients with <90 % loss of function demonstrate satisfactory spontaneous recovery [35]. The timing of Wallerian degeneration may also be of prognostic value. Axons with a neurotmetic lesion undergo Wallerian degeneration early (3–5 days) and have no chance of recovery. An axonotmetic lesion will result in Wallerian degeneration later (14–21 days) and can still recover as regeneration occurs through the intact neural sheaths. Degeneration between 6 and 14 days will have variable degrees of axonotmesis versus neurotmesis and therefore recovery will be less predictable. ENOG is useful

from days 3 to 21 after nerve injury/symptom onset. Beyond day 21, electromyography (EMG) is more useful [35, 81]. Fibrillations on EMG indicate neuronal injury, while motor unit potentials (MUPs) indicate recovery. EMG may also be beneficial to evaluate possible donor nerves in cases of multi-nerve dysfunction.

15.4 Treatment

The management goals of facial nerve injuries are to restore normal function, establish facial symmetry both at rest and with animation, minimize any donor deficit, and achieve normal facial contour through reliable and safe procedures. The pathway through which these goals are achieved varies depending upon the etiology and degree of facial paralysis, duration of denervation, and patient's health, age, and goals. Multiple algorithms have been described to reflect this decision-making process [28, 35, 39, 65, 77, 89]. Regardless of the treatment pathway, corneal protection is of paramount importance and should be emphatically reviewed with patients.

Duration of denervation guides management. In cases of acquired facial nerve pathology, reinnervation of native facial musculature is ideal. After prolonged denervation, native musculature is no longer capable of reinnervation, and alternative reconstructive techniques must be employed. The duration of the acceptable denervation period has been somewhat debated but is generally agreed to be ~12–18 months. Following nerve injury, Wallerian degeneration occurs distally. In this process, Schwann cells, fibroblasts, myocytes, and injured axons express neurotrophic factors as neural elements are degraded. In addition to the degeneration process, regeneration is also supported. After prolonged denervation (>6 months), however, distal Schwann cells provide less neuroregenerative support and may even undergo apoptosis [29, 76], providing a suboptimal environment for neuroregeneration. During denervation, changes occur not only in the nerve but also in the denervated muscle, a sequence of events termed denervation atrophy. Proteases cause myofibril

reabsorption, myosin and actin filament catabolism, and increased collagen deposition [55]. Capillaries are lost, creating regions of avascular muscle [9]. Normally, acetylcholine receptors and neural cell adhesion molecules are upregulated to help guide neural ingrowth. Once the regenerating nerve reaches the target muscle, a neuromuscular junction is formed, and these growth factors are less ubiquitously expressed [55]. With increasing periods of denervation, the state of high affinity between the regenerating nerve and muscle diminishes. Eventually, the muscle becomes refractory to synaptic formation; it can never be reinnervated, regardless of neuroregeneration status. Motor reinnervation, then, is time-sensitive. Given the rate of neuroregeneration of 1 mm daily, lesions distant from end-target muscles may not be amenable to repair at the point of injury. Similarly, a cross-face nerve graft (CFNG) from the contralateral VIIth nerve may not be a viable solution for direct muscle reinnervation at 12 months post-injury. Nerve transfers provide a solution of providing motor input to the denervated muscle in a more timely manner as the transfer can be performed in closer proximity to the target than the nerve injury.

Facial nerve deficits are not always best managed surgically. In Bell's palsy, improved recovery has been noted in patients receiving steroids and antivirals in close proximity to symptom onset [44, 85, 101]. Physiotherapy and biofeedback exercises are effective management tools for enhancement of facial movement and suppression of synkinesis. Neuromuscular reeducation is also imperative in the postoperative rehabilitation after nerve transfer procedures. Rehabilitation techniques are effective and continue to benefit patients even up to 3 years after facial nerve injury [57]. Chemodenervation also plays an important role in reducing synkinesis and improving facial symmetry [10, 30, 39, 53, 77]. The optimal treatment of facial nerve injuries requires a multimodality approach [39], and the importance of these techniques should not be underestimated, although they are not the focus of this chapter and are not thoroughly discussed.

15.4.1 Surgical Management of Acute Facial Nerve Lesions

Direct facial nerve repair should be completed when possible. Nerve repair within 72 h from the time of injury allows stimulation to aid identification of distal nerve ends [103]. After 72 h from injury, motor end-plate depolarization is not possible as neurotransmitter stores are depleted in the absence of antegrade axoplasmic transport. Repairs should always be performed without tension. If a tensionless repair is not possible, nerve autografts should be utilized. Common donors are the sural, great auricular, cervical plexus, medial antebrachial cutaneous, and lateral antebrachial cutaneous nerves. The neuroorrhaphy should be performed with healthy nerve ends. An elegant nerve repair or reconstruction performed within the zone of injury has no functional value. Facial nerve repair should be completed with meticulous technique, by surgeons with experience in neuroorrhaphy, in an appropriate setting with proper lighting, magnification, and instruments.

Depending upon the mechanism of injury, the facial nerve may be in continuity but incur injury due to external compression. Neural edema within the bony confines of the intratemporal segment can impair function. Facial nerve decompression was first described as a treatment for Bell's palsy by Balance and Duel in 1932 [6] and is controversial. Proponents claim the usefulness of decompression when performed within 12–14 days of traumatic injury or the onset of Bell's palsy in patients who will have a poor recovery or who have an unfavorable electrodiagnostic profile [35, 46]. Poorer recovery has been reported when decompression was performed more than 2 weeks after nerve injury [46]. Multiple potential sites of compression exist, although differences in functional recovery by region of decompression have not been shown [46]. Opponents of facial nerve decompression also cite the difficulty in predicting which patients will have a poor outcome, although this task is aided with ENOG, and note few differences in recovery for patients who have undergone decompression compared to those with spontaneous recovery [1]. The authors have

not utilized this procedure in the management of facial nerve injuries.

In the setting of acute facial nerve injuries when a proximal facial nerve stump is not available (damaged in trauma, resected with tumor, etc), an alternative neuronal source should be used to reinnervate the native mimetic musculature. The contralateral facial nerve or other nearby cranial nerves can provide neuronal input.

If available, the contralateral facial nerve in combination with a cross-face nerve graft (CFNG) (typically the sural nerve) may be used to innervate the affected facial muscles. First described by several authors in the early 1970s [2, 78, 82], this technique has the benefit of borrowing nerves of like function to reconstruct facial movement and therefore allows spontaneous and emotional facial expression without dyskinesia. In addition, the need for motor reeducation is eliminated. Due to redundancy of facial nerve branches and complex facial muscle innervation patterns, a branch of the contralateral facial nerve can be harvested after careful facial nerve mapping with minimal to no donor deficit. The downside of this technique is that the innervation source is not as robust as some other cranial nerves, such as branches of the trigeminal. The reconstruction requires neuroregeneration across a lengthy CFNG and two coaptation sites. The increased time for neuroregeneration allows greater muscle atrophy and a poorer neuronal trophic environment [52]. Through a preauricular incision with caudal extension just posterior to the mandible on the unaffected side of the face, the healthy facial nerve branches are meticulously mapped. For smile reconstruction, a buccal or zygomatic branch is identified, typically at a point half the distance between the tragus and the oral commissure (Zucker's point). Nerve branches are identified and then stimulated to determine function. The branch that provides oral commissure, upper lip, and alar elevation, with redundant function, is selected as the donor. Use of a donor branch that produces the intended motion may decrease synkinesis and involuntary motion as the donor has similar cortical origins as the injured side. Care is taken to ensure redundancy and preservation of periocular muscle function. The injured facial

nerve segment is exposed through an identical preauricular incision on the injured side of the face. A subcutaneous tunnel is created in the upper lip, and a nerve graft is passed between the two sides of the face. Tensionless neural coaptations are then performed between the donor facial nerve and the nerve graft and between the downstream nerve graft and the distal segment of the injured facial nerve. Return of facial nerve function is often noted 6–9 months after reconstruction. Neuroregeneration may be followed by an advancing Tinel's sign across the CFNG. This technique may also be performed in two stages: donor branch selection and coaptation with CFNG, followed by coaptation of the CFNG to the distal target nerves in a second procedure approximately 6–12 months later.

If the contralateral facial nerve is unavailable and the native facial musculature remains appropriate for reinnervation, an alternative neural source may be utilized for direct muscle reinnervation. The ipsilateral masseter branch of the trigeminal nerve provides a robust axonal source, often without the need for an intervening nerve graft and therefore with only a single coaptation. Use of this neuronal source was initially described by Zuker et al. [108] for free segmental muscle transplantation to the face for patients with Möbius syndrome, but this nerve transfer can also be used for direct mimetic muscle neurotization [21]. The motor nerve to the masseter muscle can be identified along the deep surface of the masseter muscle coursing obliquely from the posterior-superior to the anterior-inferior muscle borders [51, 108]. It is located approximately 3 cm anterior to the tragus and 1 cm inferior to the zygomatic arch [11]. Because of the close proximity between the facial and trigeminal nuclei in the pons, motor reeducation after this procedure is often rapid, even in the absence of formal therapy, for both adult and pediatric patients. The ability to smile without active biting has been reported in 66–82 % of patients [51, 61, 75, 105]. The motor branch to the masseter provides a robust innervation source with greater axonal numbers compared to the buccal branch of the facial nerve, with clinical facial movement often noted 3 months postoperatively [21]. No

donor deficit has been reported after use of the motor branch to the masseter [21, 61, 108].

If both the contralateral VII and the motor branch to the masseter are unavailable for mimetic muscle reinnervation, alternative nerve transfers such as the spinal accessory (first completed by Drobnick in 1879, as cited by Griebie [37]), hypoglossal [20], partial spinal accessory [13], partial hypoglossal [3, 64], phrenic [73, 106], and C7 [90] nerves have been successfully used. These alternative nerve sources, however, have increased donor morbidity and often result in dyskinetic facial motions (reviewed in [72]). Today, none of these procedures are considered first-line donor nerve selections by our group.

The babysitter technique, described by Terzis [88, 95], utilizes the concept of reinnervation while waiting for definitive neuroregeneration with use of a partial hypoglossal nerve transfer. The theory is that immediate reinnervation will protect motor end plates within the target muscle and prevent denervation atrophy. The question of whether two separate reinnervation procedures are more harmful than a single denervation period followed by a single reinnervation transition has been raised in the literature [107].

15.4.2 Surgical Management of Established Facial Nerve Lesions

With prolonged muscle denervation (approximately 12–24 months), changes within both the target nerve and muscle preclude further reinnervation of native musculature. As a result, surgical intervention may establish static or dynamic reconstructions depending upon associated patient factors, such as physical health, psychological state, psychosocial support, and preference.

15.4.2.1 Static Slings

Dynamic facial reanimation is generally preferred, but static techniques still have a role in selected patients. Static procedures are short and relatively straightforward and therefore ideal for patients who are elderly and have significant medical issues that prohibit a complex and long dynamic

reconstruction. They may also be preferred by some young patients who do not initially desire an extensive dynamic reconstruction and rehabilitation. Finally, static slings may also be useful for temporary but prolonged paralysis when functional recovery is ultimately expected. While they do not provide a smile, they do improve cosmetic appearance and symmetry at rest and can improve functional impairment [56].

A variety of materials are available for use as slings. These include autologous fascia lata, acellular cadaveric dermis, animal-based dermal collagen, and prosthetic materials such as expanded polytetrafluoroethylene (Gore-Tex). Each has advantages and disadvantages. Fascia lata is the most commonly preferred donor site because of the amount and length of tissue available, but it may stretch with time and has associated donor morbidity. Cadaveric or animal-based dermis is readily available without donor-site issues. Because it is revascularized and incorporated, it is more resistant to infection but also may undergo variable degrees of resorption, and long-term stretching may be more extensive and unpredictable. Prosthetic materials also avoid donor morbidity, and there is much less stretching over time but with higher rates of infection and extrusion.

The standard approach includes a preauricular or post-tragal incision and incisions lateral to the lip on the nasolabial fold and at the vermilion border of the upper and lower lip near the midline for lip extensions. The sling is positioned subcutaneously from the lateral zygomatic arch to the oral commissure and then split longitudinally to extend through the upper and lower lip towards the midline. The tension is set with some degree of overcorrection based on the type of material that is being used. Stretching and laxity make up the most common long-term complication, and revisions may be necessary and are more easily undertaken compared to dynamic reconstructions.

15.4.2.2 Regional Muscle Transfer

Regional muscle transfers provide satisfactory dynamic facial reanimation with shorter operative time and recovery period. They provide

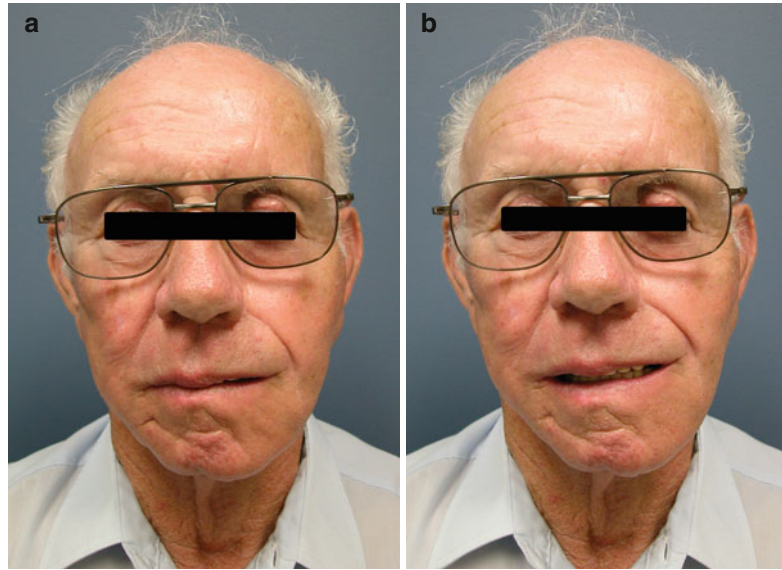advantages especially in the elderly patient population in which a longer procedure is risky or otherwise less desirable, and microvascular surgery is less optimal due to vessel disease, or inflow vessels are not available. The temporalis muscle is the most commonly used pedicled regional muscle transfer. Originally described as a turndown transfer of the entire muscle belly over the zygomatic arch to the oral commissure [17], it is associated with a significant donor-site deformity with hollowing of the temporal region and excessive bulkiness over the zygomatic arch. Modifications have included transfer of only the central portion of the muscle belly [92] and the use of autologous or cadaveric grafts or prosthetic implants in the temporal fossa with variable long-term success (Fig. 15.3). The most recent modification has been the orthodromic temporalis tendon transfer (TTT) [15], involving transfer of the insertion onto the coronoid process to the oral commissure. The advantages of this procedure are an immediate result and lack of a donor-site defect. The approach may be transoral, which is more straightforward, or transfacial, which is technically more difficult but minimizes oral contamination [8]. The most recent modifications have included extensions using fascia lata or tendon grafts through the upper and lower lips towards the midline to address the orbicularis oris paralysis and asymmetry [27].

The masseter muscle has also been described for treatment of facial palsy [5]. Its origin is from the inferior aspect of the zygomatic arch, and it inserts onto the body and ramus of the mandible. For transfer, its insertion inferiorly is released, and the muscle is mobilized and transposed anteriorly to the oral commissure and lips with a vector that is similar to the temporalis muscle, although with a more lateral vector of pull. Another disadvantage in comparison to the temporalis muscle is a short excursion, and it is therefore considered only when the temporalis muscle is not available.

15.4.2.3 Free Functional Muscle Transfer

Since Harii et al. [41] described the first free functional muscle transfer (FFMT) to the face for smile reconstruction in 1976, FFMT has become

Fig. 15.3 Postoperative photographs of 70-year-old male with left facial palsy secondary to previous resection of parotid tumor, now after left temporalis muscle turndown flap, insertion of gold weight in left eyelid, and placement of AlloDerm into left temporal donor-site defect. (a) At rest and (b) smiling



the standard for dynamic reconstruction of facial expression. FFMT is most commonly used for dynamic midface reconstruction. Reconstructive goals include achievement of a natural, spontaneous, and symmetric smile via a reliable surgical technique. A spectrum of muscles has been utilized for this purpose, including gracilis [41], latissimus dorsi [58, 105], pectoralis minor [43], and serratus anterior [104]. Challenges and considerations with donor muscle selection include pedicle length and reliability, muscle bulk, and muscle fiber orientation. The gracilis muscle is the authors' donor of choice due to its ease of dissection, minimal donor-site morbidity, lengthy and reliable pedicle, and ability to be segmentally transferred (Fig. 15.4).

Excess bulk can be a disadvantage of FFMT. Transplant of large muscles to the face, such as the latissimus dorsi or the entire gracilis muscle, results in suboptimal aesthetics. In his early experience with FFMT, Chuang reported bulkiness in up to one third of patients [18]. In 1984, Manktelow and Zuker [60] introduced the concept of functional muscular anatomy. They noted that individual nerve fascicles supply independent muscle territories and could be individually stimulated. Transplant of only a segment, or single fascicular territory, of the gracilis muscle was therefore possible without

functional compromise, and their results are superior. The gracilis, then, can be split into thirds without damage to the muscle and then trimmed to the appropriate length for transfer to the face. Others have advocated trimming the gracilis in specific manners [18], but this also requires detailed knowledge of the neurovascular pedicle to avoid damage to the transferred muscle. When debulking the muscle, careful attention must be directed at hemostasis prior to ischemia time to avoid hematoma risks in the face after transfer [66].

Donor nerve selection involves consideration of the native contralateral smile (if applicable), axonal load, and donor nerve availability, as summarized in the acute injury section. Ideally nerve donors are synergistic and must be dispensable. Patients with unilateral facial paralysis and robust, contralateral oral commissure excursion require robust excursion of the affected commissure to achieve final symmetry, which is observed with use of the motor nerve branch to the masseter muscle [4, 21, 51] due to its increased axonal load [21]. Alternatively, the patient requiring less oral commissure movement for symmetry may be better served with the use of the contralateral facial nerve and a CFNG. Classically, this technique results in a more spontaneous smile, with less requirement for motor reeducation (as outlined

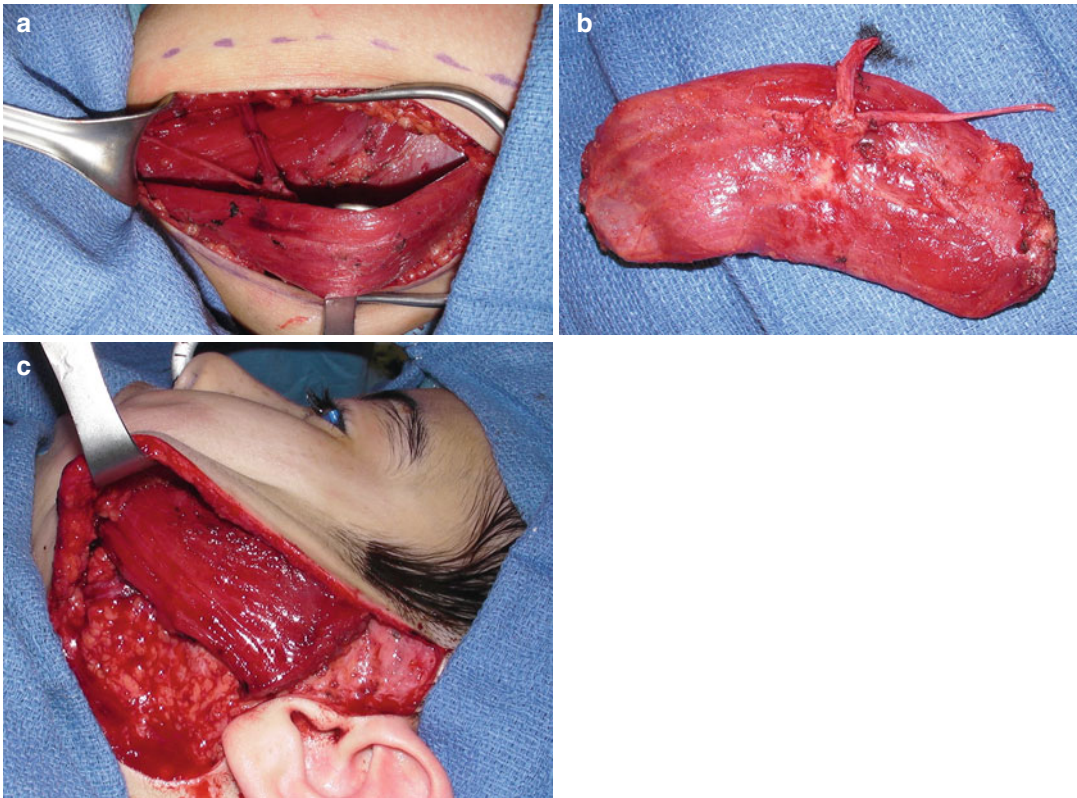


Fig. 15.4 (a) Gracilis muscle harvest. Mobilization prior to harvest with isolation of neurovascular pedicle. (b) Harvest and (c) transfer to the face prior to inseting

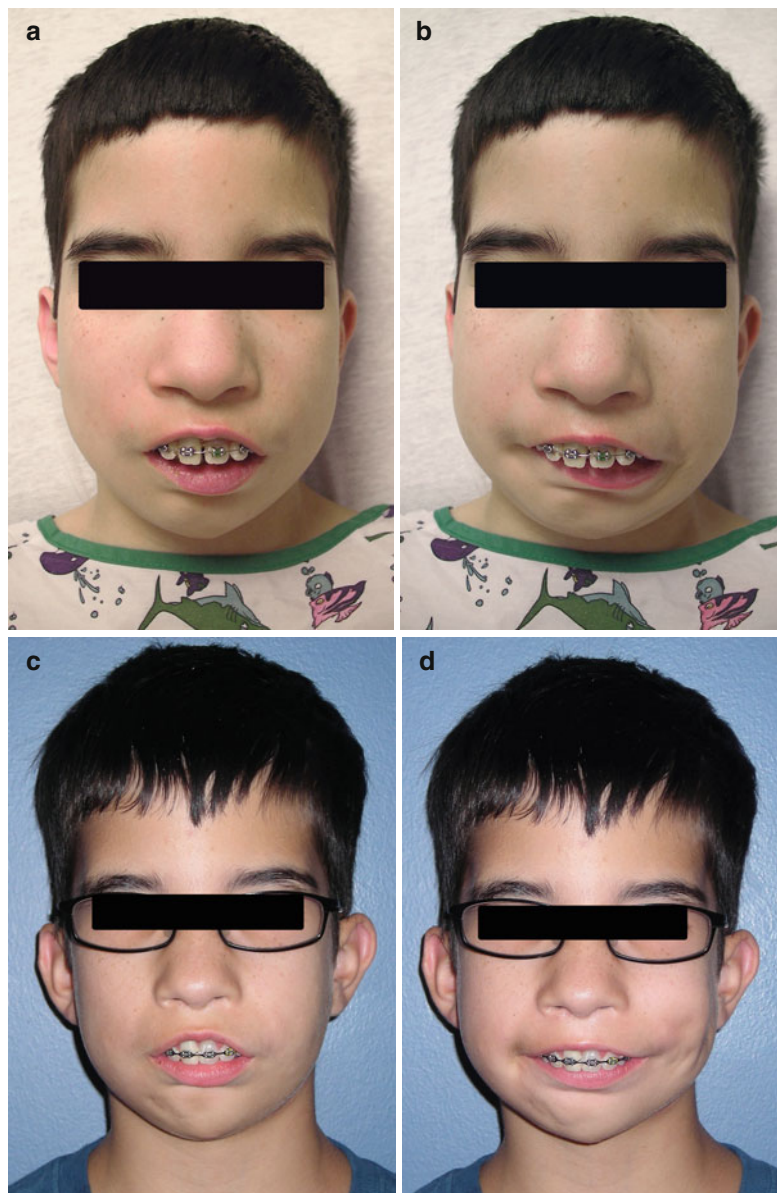in the previous section). Axonal dropout occurs with neuroregeneration across neural coaptations [31, 43]. Because the CFNG requires regenerating neuronal fibers to cross two separate coaptations, fewer axons are available to power the free muscle [50], although Terzis observed that donor nerve fiber counts, rather than downstream nerve graft fiber counts, correlated with functional outcome [96]. Shorter neuroregeneration periods also follow from ipsilateral donor cranial nerves due to the shorter distance traveled. Results may vary among individuals, and the selection of a donor nerve is dependent upon availability of additional cranial nerves, the patient's native smile, and the duration of injury.

Free tissue transfer may occur in one or two stages. The first stage consists of donor nerve selection with coaptation to a nerve graft if required. After allowing time required for neuroregeneration to the distal end of the nerve graft

(follow Tinel's sign, 6–12 months later), the free muscle may be transferred and coapted to the donor nerve/nerve graft. Alternatively, donor nerve selection \pm nerve graft may occur simultaneously with muscle transfer, although the delay in muscle neurotization may have suboptimal results. The authors' preferred technique for FFMT is the two-staged method to optimize functional results (Fig. 15.5).

Free tissue transfer provides a reliable method for dynamic midface reconstruction, but results for dynamic reconstruction in other facial regions are variable. The evaluation and management of the patient with facial palsy should follow a systematic regional investigation to ensure assessment of all regions of the face and not just areas of obvious pathology or asymmetry. Five specific facial regions have been proposed for evaluation in the management of facial nerve injuries: the brow, the ocular region, the midface and

Fig. 15.5 Preoperative photographs of 12-year-old male with Möbius syndrome and incomplete right facial paralysis. (a) At rest and (b) attempting to smile. (c, d) Postoperative photographs after single-stage free functional gracilis muscle transfer innervated by masseteric motor branch. At rest and smiling



nasolabial fold, the oral commissure, and the lower lip [39]. Management of the face as a whole may require multimodality treatment involving the use of a combination of static and dynamic techniques. In general, symmetry is achieved by either augmentation of deficient motion or weakening of intact motion. For example, in cases of unilateral depressor muscle dysfunction in the lower lip, improved symmetry may be established via regional or free muscle transfer to the

affected side or via depressor muscle weakening on the healthy side via chemodenervation, myectomy, or transection of the healthy marginal mandibular nerve [42]. Injection of long-acting local anesthetics into muscles allows the patient's temporary assessment of outcome following muscle weakening [59]. Multiple procedures for static reconstructions improve symmetry and are relatively simple to perform and are reviewed in Hadlock et al. [39].

15.5 Complications and Prognosis

Reconstruction of facial expression or symmetry is a complicated process that requires skill and meticulous attention to detail. Even with careful planning and execution, complications do occur. Dynamic reconstructions may be nonfunctional or have a less optimal result due to synkinesis. Hematoma, seroma, infection, muscle disinsertion, muscle tethering, and asymmetric smile are possible complications. It is important to discuss the expected and potential courses with patients thoroughly as part of the informed consent process.

Synkinesis, or innervation of unintended targets in addition to intended targets during reinnervation, differentiates cases of congenital and acquired facial palsy. In cases of congenital FP, structures required for facial expression are absent, a pattern of reinnervation cannot occur, and synkinesis is not observed. In contrast, native innervation patterns have been established in cases of acquired FP, and therefore, synkinesis may ensue after nerve injury. Synkinesis is more likely to occur with a lesion that is proximal on the facial nerve [19]. To avoid this sequela, Chuang practices a radical technique of excavation of all regional native facial musculature prior to inset of the FFMT, negating the possibility of synkinesis [18]. For most others, synkinesis is treated not by prevention but with biofeedback and neuromuscular retraining [12]. Chemodenervation is also an effective therapeutic modality for unwanted facial movement [10, 30, 39, 53].

The failure rate for FFMT to the face is variable. Upon review of 17 patients who had undergone 19 FFMT procedures, Hadlock et al. [40] reported muscle failures, which they defined as lack of >2 cm movement, in 11 % of pediatric patients and in 21 % of an adult cohort. Similarly, a review of 100 FFMTs in a population of both adult and pediatric patients demonstrated a moderate or better result in 80 % of patients [91]. A 9 % failure rate was reported in a long-term retrospective review of 23 adults undergoing FFMT for facial paralysis [92]. A long-term review of 47 patients undergoing dynamic facial reconstruction with FFMT revealed an 11 %

failure rate, indicating no resultant muscle motion, and an additional 15 % did not have facial motion that was independent from the contralateral side [66].

Long-term follow-up of patients after FFMT for facial paralysis is positive. A review of 24 patients who had undergone CFNG followed by free gracilis transfer with a minimum of 5-year follow-up demonstrated gains in muscle excursion for over 2 years with no clinical or electrodiagnostic evidence of diminishing function [93]. A similar long-term follow-up of pediatric patients after CFNG and free functional gracilis transfer also demonstrated stable muscle function and no evidence of negative effects on facial skeletal growth [94]. Overall results have been recorded as excellent or good in ~50 % of adult and pediatric patients, and patients' self-reported assessments of overall outcomes are more positive [66]. A small percentage of patients may request or require revisionary surgery for severe facial contracture [19, 66].

15.6 Future Directions

Reconstruction of facial animation is challenging but also life changing for patients. While the field has been revolutionized by technical advances, there remains room for improvement. One limitation that has limited progress is the absence of a universal outcome measure, limiting multicenter comparisons and meta-analyses. While this limitation still remains a challenge for the field, Hadlock and colleagues have contributed a measurement tool for analysis of facial movements [14, 38], which provides a standardized, accurate, and efficient method of quantifying facial movement. A standardized method of facial movement quantification allows longitudinal outcome analysis not only for individual patients but also within a practice and among institutions. Because the patient population requiring operative intervention for facial paralysis is relatively small, trends in outcomes can be difficult to measure. A centralized database of patients with facial paralysis can speed outcome analysis to benefit both patients and clinicians. Basic science research

pursuits to investigate methods to enhance neuroregeneration, focus end target specificity, and maintain and protect native musculature continue. In addition, new pursuits involving biomedical engineering and other disciplines have shown applicability to facial movement. Electroactive polymer artificial muscle may be useful to facilitate eyelid blink in patients with FP [79, 98]. Functional electrical stimulation channeled from the unaffected contralateral face has shown potential for clinical applicability [54]. The field of facial animation and reanimation is entering an exciting era of continued technological advancement and collaboration among practitioners and different disciplines. With a team approach, the future is bright for facial paralysis.

References

1. Adour K, Diamond C (1982) Decompression of the facial nerve in Bell's palsy: a historical review. *Otolaryngol Head Neck Surg* 90:453–460
2. Anderl H (1976) Cross-face nerve transplantation in facial palsy. *Proc R Soc Med* 69:781–783
3. Arai H, Sato K, Yanai A (1995) Hemihypoglossal-facial nerve anastomosis in treating unilateral facial palsy after acoustic neuroma resection. *J Neurosurg* 82:51–54
4. Bae Y, Zuker R, Manktelow R et al (2006) A comparison of commissure excursion following gracilis muscle transplantation for facial paralysis using a cross-face nerve graft versus the motor nerve to the masseter nerve. *Plast Reconstr Surg* 117:2407–2413
5. Baker DC, Conley J (1979) Regional muscle transposition for rehabilitation of the paralyzed face. *Clin Plast Surg* 6:317–331
6. Balance C, Duel A (1932) The operative treatment of facial palsy: by the introduction of nerve grafts into the fallopian canal and by other intratemporal methods. *Arch Otolaryngol* 15:1–70
7. Bleicher J, Hamiel B, Gengler J (1996) A survey of facial paralysis: etiology and incidence. *Ear Nose Throat J* 75:355–357
8. Boahene KD (2008) Dynamic muscle transfer in facial reanimation. *Facial Plast Surg* 24:204–210
9. Borisov A, Huang S, Carlson B (2000) Remodeling of the vascular bed and progressive loss of capillaries in denervated skeletal muscle. *Anat Rec* 258:292
10. Boroojerdi B, Ferbert A, Schwarz M et al (1998) Botulinum toxin treatment of synkinesia and hyperlacrimation after facial palsy. *J Neurol Neurosurg Psychiatry* 65:111–114
11. Borschel G, Kawamura D, Ksukurthi R et al (2011) The motor nerve to the masseter muscle: an anatomic and histomorphometric study to facilitate its use in facial reanimation. *J Plast Reconstr Aesthet Surg*. doi:10.1016/j.bjps.2011.09.026
12. Brach J, Van Swearingen J, Lenert J et al (1997) Facial neuromuscular retraining for oral synkinesis. *Plast Reconstr Surg* 99:1922–1931
13. Bragdon F, Gray G (1962) Differential spinal accessory-facial anastomosis with preservation of function of trapezius. *J Neurosurg* 19:981–985
14. Bray D, Henstrom D, Cheney M et al (2010) Assessing outcomes in facial reanimation: evaluation and validation of the SMILE system for measuring lip excursion during smiling. *Arch Facial Plast Surg* 12:352–354
15. Byrne PJ, Kim M, Boahene K et al (2007) Temporalis tendon transfer as part of a comprehensive approach to facial reanimation. *Arch Facial Plast Surg* 9:234–241
16. Cha C, Hong C, Park M et al (2008) Comparison of facial nerve paralysis in adults and children. *Yonsei Med J* 49:725–734
17. Cheney ML, McKenna MJ, Megerian CA et al (1995) Early temporalis muscle transposition for the management of facial paralysis. *Laryngoscope* 105:993–1000
18. Chuang D (2002) Technique evolution for facial paralysis reconstruction using functioning free muscle transplantation—experience of Chang Gung Memorial Hospital. *Clin Plast Surg* 29:449–459
19. Chuang D, Devaraj VC, Wei F-C (1995) Irreversible muscle contracture after functioning free muscle transplantation using the ipsilateral facial nerve for innervation. *Br J Plast Surg* 48:1–7
20. Conley J, Baker D (1979) Hypoglossal-facial nerve anastomosis for reinnervation of the paralyzed face. *Plast Reconstr Surg* 63:63–72
21. Coombs C, Ek E, Wu T et al (2009) Masseteric-facial nerve coaptation—an alternative technique for facial nerve reinnervation. *J Plast Reconstr Aesthet Surg* 62:1580–1588
22. Danielidis V, Skevas A, Van Cauwenberge P et al (1999) A comparative study of age and degree of facial nerve recovery in patients with Bell's palsy. *Eur Arch Otorhinolaryngol* 256:520–522
23. Ekman P (1993) Facial expression and emotion. *Am Psychol* 48:384–392
24. Ekman P (2009) Darwin's contributions to our understanding of emotional expressions. *Philos Trans R Soc Lond B Biol Sci* 364:3449–3451
25. Evans A, Licameli G, Brietzke S et al (2005) Pediatric facial nerve paralysis: patients, management and outcomes. *Int J Pediatr Otorhinolaryngol* 69:1521–1528
26. Falco N, Eriksson E (1990) Facial nerve palsy in the newborn: incidence and outcome. *Plast Reconstr Surg* 85:1–4
27. Faria JC, Scopel GP, Alonso N et al (2009) Muscle transplants for facial reanimation: rationale and results of insertion technique using the palmaris longus tendon. *Ann Plast Surg* 63:148–152
28. Fattah A, Borschel G, Manktelow R et al (2012) Facial palsy and reconstruction. *Plast Reconstr Surg* 129:340e–352e

29. Fernandes K, Tsui B, Cassar S et al (1999) Influence of the axotomy to cell body distance in rat rubrospinal and spinal motoneurons: differential regulation of GAP-43, tubulins, and neurofilament-M. *J Comp Neurol* 414:495–510
30. Filipio R, Spahiu I, Covelli E et al (2012) Botulinum toxin in the treatment of facial synkinesis and hyperkinesis. *Laryngoscope* 122:266–270
31. Frey M, Happak W, Girsch W et al (1991) Histomorphometric studies in patients with facial palsy treated by functional muscle transplantation: new aspects for the surgical concept. *Ann Plast Surg* 26:370–379
32. Frey M, Michaelidou M, Tzou C et al (2008) Three-dimensional video analysis of the paralyzed face reanimated by cross-face nerve grafting and free gracilis muscle transplantation: quantification of the functional outcome. *Plast Reconstr Surg* 122:1709–1722
33. Furuta Y, Ohtani F, Aizawana H et al (2005) Varicella-zoster virus reactivation is an important cause of acute peripheral facial paralysis in children. *Pediatr Infect Dis J* 24:97–101
34. Gantz B, Gmur A, Holliday M et al (1984) Electroneurographic evaluation of the facial nerve: method and technical problems. *Ann Otol Rhinol Laryngol* 93:394–398
35. Gantz B, Rubinstein J, Gidley P et al (1999) Surgical management of Bell's palsy. *Laryngoscope* 109:1177–1188
36. Ge X, Spector G (1981) Labyrinthine segment and geniculate ganglion of facial nerve in fetal and adult human temporal bones. *Ann Otol Rhinol Laryngol* 90(Suppl 85):1–12
37. Griebie M, Huff J (1998) Selective role of partial XI-VII anastomosis in facial reanimation. *Laryngoscope* 108:1664–1668
38. Hadlock T, Urban L (2012) Toward a universal, automated facial measurement tool in facial reanimation. *Arch Facial Plast Surg*. doi:10.1001/archfacial.2012.111
39. Hadlock T, Greenfield L, Wernick-Robinson M et al (2006) Multimodality approach to management of the paralyzed face. *Laryngoscope* 116:1385–1389
40. Hadlock T, Malo J, Cheney M et al (2011) Free gracilis transfer for smile in children: the Massachusetts Eye and Ear Infirmary experience in excursion and quality-of-life changes. *Arch Facial Plast Surg* 13:190–194
41. Harii K, Ohmori K, Torii S (1976) Free gracilis muscle transplantation, with microneurovascular anastomoses for the treatment of facial paralysis. A preliminary report. *Plast Reconstr Surg* 57:133–143
42. Harrison D (1980) Surgical correction of unilateral and bilateral facial palsy. *Postgrad Med J* 81:562–567
43. Harrison D (1985) The pectoralis minor vascularized muscle graft for the treatment of unilateral facial palsy. *Plast Reconstr Surg* 75:206–216
44. Hato N, Yamada H, Kohno H et al (2007) Valacyclovir and prednisolone treatment for Bell's palsy: a multi-center, randomized, placebo-controlled study. *Otol Neurotol* 28:408–413
45. Hato N, Nota J, Komobuchi H et al (2011) Facial nerve decompression surgery using bFGF-impregnated biodegradable gelatin hydrogel in patients with Bell palsy. *Otolaryngol Head Neck Surg* XX:1–6
46. Hato N, Nota J, Hakuba N et al (2011) Facial nerve decompression surgery in patients with temporal bone trauma: analysis of 66 cases. *J Trauma* 71:1789–1793
47. Henstrom D, Skilbeck C, Weinberg J et al (2011) Good correlation between original and modified House Brackmann facial grading systems. *Laryngoscope* 121:47–50
48. House J, Brackmann D (1985) Facial nerve grading system. *Otolaryngol Head Neck Surg* 93:146–147
49. Ikeda M, Abiko Y, Kukimoto N et al (2005) Clinical factors that influence the prognosis of facial nerve paralysis and the magnitudes of influence. *Laryngoscope* 115:855–860
50. Jacobs J, Laing J, Harrison D (1996) Regeneration through a long nerve graft used in the correction a facial palsy: a qualitative and quantitative study. *Brain* 119:271–279
51. Klebuc M, Shenaq S (2004) Donor nerve selection in facial reanimation surgery. *Semin Plast Surg* 18:53–59
52. Kobayashi J, Mackinnon S, Watanabe O et al (1997) The effect of duration of muscle denervation on functional recovery in the rat model. *Muscle Nerve* 20:858
53. Kollewe K, Mohammadi B, Dengler R et al (2010) Hemifacial spasm and reinnervation synkinesis: long-term treatment with either Botox or Dysport. *J Neural Transm* 117:759–763
54. Kurita M, Takushima A, Muraoka Y et al (2010) Feasibility of bionic reanimation of a paralyzed face: a preliminary study of functional electrical stimulation of a paralyzed facial muscle controlled with electromyography of the contralateral healthy hemiface. *Plast Reconstr Surg* 126:81e–83e
55. Lien S, Cederna P, Kuzon W (2008) Optimizing skeletal muscle reinnervation with nerve transfer. *Hand Clin* 24:445
56. Liu Y, Sherris D (2008) Static procedures for the management of the midface and lower face. *Facial Plast Surg* 24:211–215
57. Lindsay R, Robinson M, Hadlock T (2010) Comprehensive facial rehabilitation improves function in people with facial paralysis: a 5-year experience at the Massachusetts Eye and Ear Infirmary. *Phys Ther* 90:391–397
58. Mackinnon S, Dellon A (1988) Technical considerations of the latissimus dorsi muscle flap: a segmentally innervated muscle transfer for facial reanimation. *Microsurgery* 9:36–45
59. Manktelow R (2000) Microsurgical strategies in 74 patients for restoration of dynamic depressor mechanism. *Plast Reconstr Surg* 105:1932–1934
60. Manktelow R, Zuker R (1984) Muscle transplantation by fascicular territory. *Plast Reconstr Surg* 73:751–755
61. Manktelow R, Tomat L, Zuker R et al (2006) Smile reconstruction in adults with free muscle transfer innervated by the masseter motor nerve: effectiveness and cerebral adaptation. *Plast Reconstr Surg* 118:885–899

62. Manktelow R, Zuker R, Tomat L (2008) Facial paralysis measurement with a handheld ruler. *Plast Reconstr Surg* 121:435–442
63. Maru N, Cheita A, Mogoanta C et al (2010) Intratemporal course of the facial nerve: morphological, topographic and morphometric features. *Rom J Morphol Embryol* 51:243–248
64. May M, Sobol S, Mester SJ (1991) Hypoglossal-facial nerve interpositional-jump graft for facial reanimation without tongue atrophy. *Otolaryngol Head Neck Surg* 104:818–825
65. Myckatyn T, Mackinnon S (2003) The surgical management of facial nerve injury. *Clin Plast Surg* 30:307–318
66. O'Brien B, Pederson W, Khazanchi R et al (1990) Results of management of facial palsy with microvascular free muscle transfer. *Plast Reconstr Surg* 86:12–22
67. Ogita S, Terada K, Niizuma T et al (2006) Characteristics of facial nerve palsy during childhood in Japan: frequency of varicella-zoster virus association. *Pediatr Int* 48:245–249
68. Patel A, Groppo E (2010) Management of temporal bone trauma. *Craniofacial Trauma Reconstr* 3:105–113
69. Patel A, Tanna N, Meyers A et al (2012) Facial nerve anatomy. Medscape reference. <http://emedicine.medscape.com/article/835286-overview>. Accessed 25 May 2012
70. Peitersen E (1982) The natural history of Bell's palsy. *Am J Otol* 4:107–111
71. Peitersen E (2002) Bell's palsy: the spontaneous course of 2,500 peripheral facial nerve palsies of different etiologies. *Acta Otolaryngol Suppl* 549:4–30
72. Poe D, Scher N, Panje W (1989) Facial reanimation by XI-VII anastomosis without shoulder paralysis. *Laryngoscope* 99:1040–1047
73. Rosenwasser R, Liebman E, Jimenez D et al (1991) Facial reanimation after facial nerve injury. *Neurosurgery* 29:568–574
74. Rubin L (1974) The anatomy of a smile: Its importance in the treatment of facial paralysis. *Plast Reconstr Surg* 53:384–387
75. Rubin L, Rubin P, Simpson R et al (1999) The search for the neurocranial pathways to the fifth nerve nucleus in the reanimation of the paralyzed face. *Plast Reconstr Surg* 103:1725–1728
76. Saito H, Dahlin L (2009) Delayed nerve repair increases number of caspase 3 stained Schwann cells. *Neurosci Lett* 456:30–33
77. Salles A, Toledo P, Ferreira M (2009) Botulinum toxin injection in long-standing facial paralysis patients: improvement of facial symmetry observed up to 6 months. *Aesthetic Plast Surg* 33:582–590
78. Scaramella L, Tobias E (1973) Facial nerve anastomosis. *Laryngoscope* 83:1834–1840
79. Senders C, Tollefson T, Curtiss S et al (2010) Force requirements for artificial muscle to create an eyelid blink with eyelid sling. *Arch Facial Plast Surg* 12:30–36
80. Shih W, Tseng F, Yeh T et al (2009) Outcomes of facial palsy in children. *Acta Otolaryngol* 129:915–920
81. Singhi P, Jain V (2003) Bell's palsy in children. *Semin Pediatr Neurol* 10:289–297
82. Smith J (1972) Advances in facial nerve repair. *Surg Clin North Am* 52:1287–1306
83. Smith J, Crumley R, Harker L et al (1981) Facial paralysis in the newborn. *Otolaryngol Head Neck Surg* 89:1021–1024
84. Smith I, Heath J, Murray J et al (1988) Idiopathic facial (Bell's) palsy: a clinical survey of prognostic factors. *Clin Otolaryngol Allied Sci* 13:17–23
85. Sullivan F, Swan I, Donnan P et al (2007) Early treatment with prednisolone or acyclovir in Bell's palsy. *N Engl J Med* 357:1598–1607
86. Takahashi H, Hitsumoto Y, Honda N et al (2001) Mouse model of Bell's palsy induced by reactivation of herpes simplex virus type 1. *J Neuropathol Exp Neurol* 60:621–627
87. Takasu T, Furuta Y, Sato K et al (1992) Detection of latent herpes simplex virus DNA and RNA in human geniculate ganglia by the polymerase chain reaction. *Acta Otolaryngol* 112:1004–1111
88. Terzis J (1990) "Babysitters": an exciting new concept in facial reanimation. In: Castro D (ed) Proceedings of the sixth international symposium on the facial nerve, Rio de Janeiro, Brazil, October 2–5 1988. Kugler & Ghedini, Amsterdam/Berkeley/Milano
89. Terzis J, Konofaos P (2008) Nerve transfers in facial palsy. *Facial Plast Surg* 24:177–193
90. Terzis J, Konofaos P (2010) Novel use of C7 spinal nerve for Moebius. *Plast Reconstr Surg* 126:106–117
91. Terzis J, Noah M (1997) Analysis of 100 cases of free-muscle transplantation for facial paralysis. *Plast Reconstr Surg* 99:1905–1921
92. Terzis J, Olivares FS (2009) Mini-temporalis transfer as an adjunct procedure for smile restoration. *Plast Reconstr Surg* 123:533–542
93. Terzis J, Olivares F (2009) Long-term outcomes of free-muscle transfer for smile restoration in adults. *Plast Reconstr Surg* 123:877–888
94. Terzis J, Olivares F (2009) Long-term outcomes of free muscle transfer for smile restoration in children. *Plast Reconstr Surg* 123:543–555
95. Terzis J, Tzafetta K (2009) The "babysitter" procedure: minihypoglossal to facial nerve transfer and cross-facial nerve grafting. *Plast Reconstr Surg* 123:865–876
96. Terzis J, Wang W, Zhao Y (2009) Effect of axonal load on the functional and aesthetic outcomes of the cross-facial nerve graft procedure for facial reanimation. *Plast Reconstr Surg* 124:1499–1512
97. Toelle S, Boltshauser E (2001) Long-term outcome in children with congenital unilateral facial nerve palsy. *Neuropediatrics* 32:130–135
98. Tollefson T, Senders C (2007) Restoration of eyelid closure in facial paralysis using artificial muscle: preliminary cadaveric analysis. *Laryngoscope* 117:1907–1911
99. Toshiaki S, Murakami S, Yanagihara N et al (1995) Facial nerve paralysis induced by herpes simplex virus in mice: an animal model of acute and transient facial paralysis. *Ann Otol Rhinol Laryngol* 104:574–581

100. Tzafetta K, Terzis J (2010) Essays on the facial nerve: part I. Microanatomy. *Plast Reconstr Surg* 125:879–889
101. Van der Veen E, Rovers M, de Ru J et al (2011) A small effect of adding antiviral agents in treating patients with severe Bell palsy. *Otolaryngol Head Neck Surg* XX:1–5
102. Wang C, Chang Y, Shih H et al (2010) Facial palsy in children: emergency department management and outcome. *Pediatr Emerg Care* 26:121–125
103. Watchmaker G, Mackinnon S (1996) Nerve injury and repair. In: Peimer C (ed) *Surgery of the hand and upper extremity*. McGraw-Hill, New York
104. Whitney T, Buncke H, Alpert B et al (1990) The serratus anterior free-muscle flap: experience with 100 consecutive cases. *Plast Reconstr Surg* 86:481–490
105. Wollard A, Harrison D, Grobbelaar A (2010) An approach to bilateral facial paralysis. *J Plast Reconstr Aesthet Surg* XX:1–4
106. Xu Y, Liu J, Li P et al (2009) The phrenic nerve as a motor nerve donor for facial reanimation with the free latissimus dorsi muscle. *J Reconstr Microsurg* 25:457–463
107. Yoshimura K, Asato H, Jejurikar S et al (2002) The effect of two episodes of denervation and reinnervation on skeletal muscle contractile function. *Plast Reconstr Surg* 109:212–219
108. Zuker R, Goldberg C, Manktelow R (2000) Facial animation in children with Mobius syndrome after segmental gracilis muscle transplant. *Plast Reconstr Surg* 106:1–8

Larry M. Wolford and Daniel B. Rodrigues

Injuries to the peripheral nervous system affect 1 in 1,000 individuals each year. The implications of sustaining such an injury are considerable, with loss of sensory and/or motor function [34]. Some nerve injuries require repair in order to regain sensory or motor function. Although this chapter focuses primarily on trigeminal nerve (TN) injuries and repairs, the facts presented may apply to any peripheral nerve repair. The primary indications for nerve repair or grafting include the following: (1) an injury or continuity defect in a nerve, as a result of trauma, pathology, surgery, or disease, which cannot regain normal function without surgical intervention, and (2) loss of normal neurologic function, resulting in anesthesia, paresthesia, dysesthesia, or paralysis, which cannot be corrected by nonsurgical treatment. In some nerve injuries (e.g., neuropraxia), the nerve regains sensory or motor function unless irreversible compression, neuroma (axonotmesis),

or transection (neurotmesis) occurs. In more severe injuries, there may be significant loss of nerve substance (continuity defect), or a section of nerve may need to be removed to expose normal nerve tissue in preparation for nerve repair. Thus, nerve repair and nerve grafting procedures may be required to provide continuity between the proximal and distal portions of the nerve.

The three major branches of the TN that can be involved in injuries are the inferior alveolar nerve (IAN), lingual nerve (LN), and infraorbital nerve (ION). The most common types of injury to the IAN and LN are iatrogenic, related to removal of impacted teeth (Fig. 16.1), orthognathic surgery (Fig. 16.2a, b), periodontics, endodontics (Fig. 16.3), dental implants (Fig. 16.4), curettage

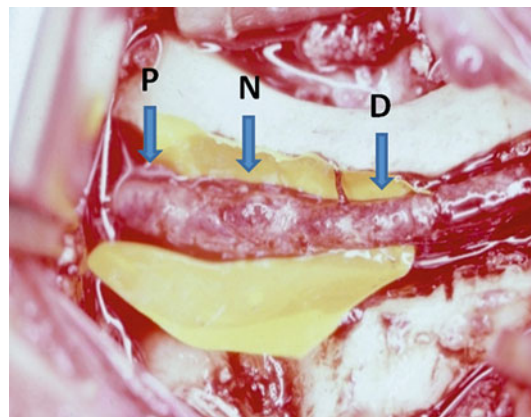


Fig. 16.1 A large traumatic neuroma (*N*) is seen 1 year after removal of a third molar. Note the significant atrophy of the distal (*D*) portion of the nerve and the mismatch in size compared with the proximal (*P*) portion of the nerve

L.M. Wolford, DMD (✉)
Department of Oral and Maxillofacial Surgery,
Texas A&M University Health Science Center,
Baylor College of Dentistry,
Private Practice at Baylor University Medical Center,
3409 Worth Street – Suite 400, Dallas,
TX 75246, USA
e-mail: lwolford@swbell.net

D.B. Rodrigues, DDS
Department of Oral and Maxillofacial Surgery,
Universidade Federal da Bahia/Obras Sociais
Irma Dulce and Private Practice,
Avenida ACM n 3244 sala 917. Caminho das Arvores,
Salvador, BA CEP 41800-700, Brazil
e-mail: dbarrosr@yahoo.com.br

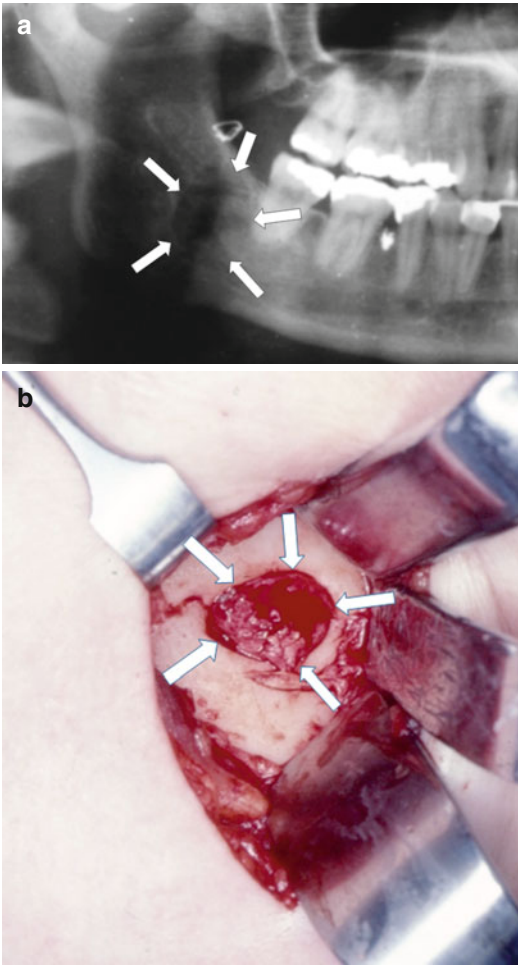


Fig. 16.2 (a) A posteriorly directed lateral osteotomy for a sagittal split procedure injured the IAN causing a large neuroma that created a bone defect in the buccal cortical plate (arrows outline bone defect). (b) The neuroma (outlined by arrows) is observed through an extraoral approach

of intrabony lesions, partial or total resection of the mandible or tongue in tumor removal, and other surgical procedures as well as trauma. Injuries to the ION are more commonly caused by trauma to the middle third of the face (Fig. 16.5a), partial or total maxillectomy and orbital exenteration during resection of benign or malignant tumors, or inadvertent nerve injury during maxillary and midface osteotomy procedures. Nerve injuries which are more difficult to manage include severe stretch-type injuries and chemical injuries such as those that occur when alcohol, steroid, or other caustic agents are injected into or around nerves (Fig. 16.3). The nature and extent of the

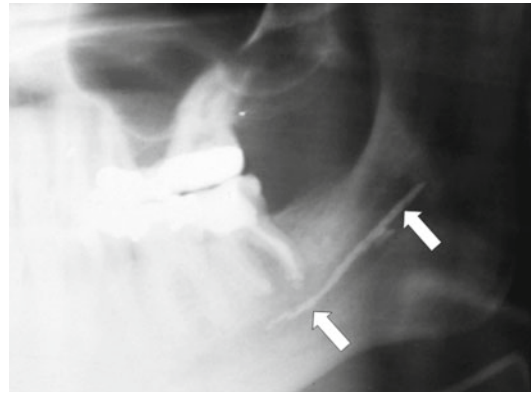


Fig. 16.3 A root canal procedure was performed on a mandibular molar with Sargenti paste injected into the root canals with extravasation (arrows) into the IAN canal. This caustic material causes severe nerve damage that adversely affects the nerve beyond the extent of the material

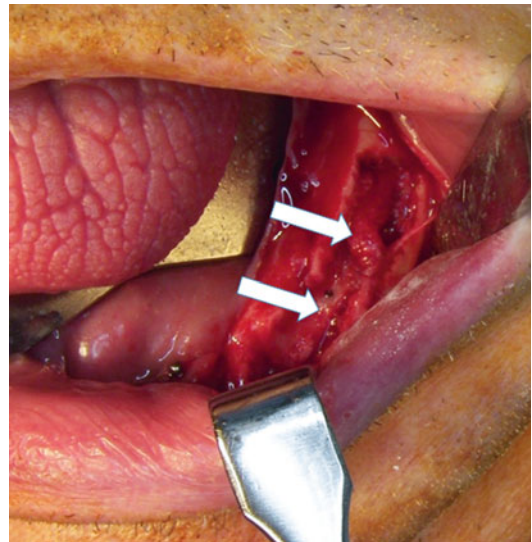


Fig. 16.4 This nerve injury resulted from placement of a dental implant that crushed the IAN. The injured IAN is between the arrows. Note the atrophy of the distal nerve segment

nerve pathology will influence the type and quality of repair [54, 55].

16.1 Considerations for Direct Nerve Repair

When surgical repair is required for a transected nerve or a nerve injury requiring excision, the best results, when conditions permit, are achieved

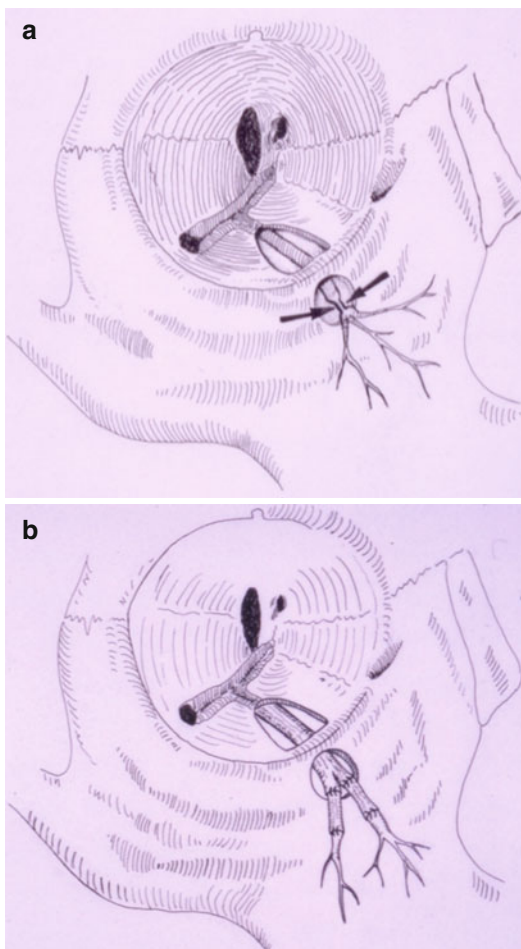


Fig. 16.5 (a) This illustration shows a crush injury to a right infraorbital nerve from a previous zygomatico-orbital fracture. (b) The nerve has been repaired with nerve grafts obtained from the greater auricular nerve as a cable graft

with a direct nerve repair, without grafting. There are basically three types of nerve repair.

Perineural repair involves repairing the individual fascicles and placing sutures through the perineurium. Complications of this technique include trauma to the nerve in dissecting out each fascicle and fibrosis that develops because of the dissections and numerous sutures placed. The IAN and LN may have 9–21 fascicles depending on the location of the injury, so this perineural repair method is impractical.

Group funicular repair involves repairing grouped fascicles with sutures placed through the intraneural epineurium, aligning groups of

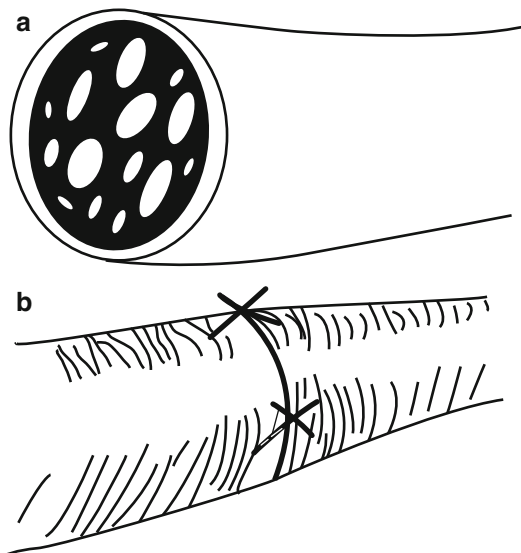


Fig. 16.6 (a) Since the trigeminal nerve is polyfascicular and the fascicles are non-grouped, (b) the epineurial repair is the preferred technique for neuroorrhaphy

fascicles. Since the TN branches have non-grouped fascicles, this technique is not applicable.

Epineurial repair involves aligning the nerve ends and placing sutures through the epineurium only. Since the TN branches are polyfascicular (multiple, different-sized fascicles) and non-grouped, the epineurial technique is the most logical choice of repair method for the TN (Fig. 16.6a, b).

16.2 Considerations for Autogenous Nerve Grafts

When continuity defects are present in the injured nerve or created in preparation of nerve repair, a nerve graft procedure may be indicated. An additional indication includes nerve sharing, where the proximal end of a nerve is severely damaged and nonfunctional, but the distal aspect can be salvaged. A portion of another nerve is isolated, a nerve graft attached, and anastomosed to the distal end of the injured nerve (Fig. 16.7a–c). There are various types of donor nerve grafts available including the following: *Autogenous nerve graft* is transplanted from one site to another in the same recipient; *isograft* is transplanted between genetically identical and nearly identical

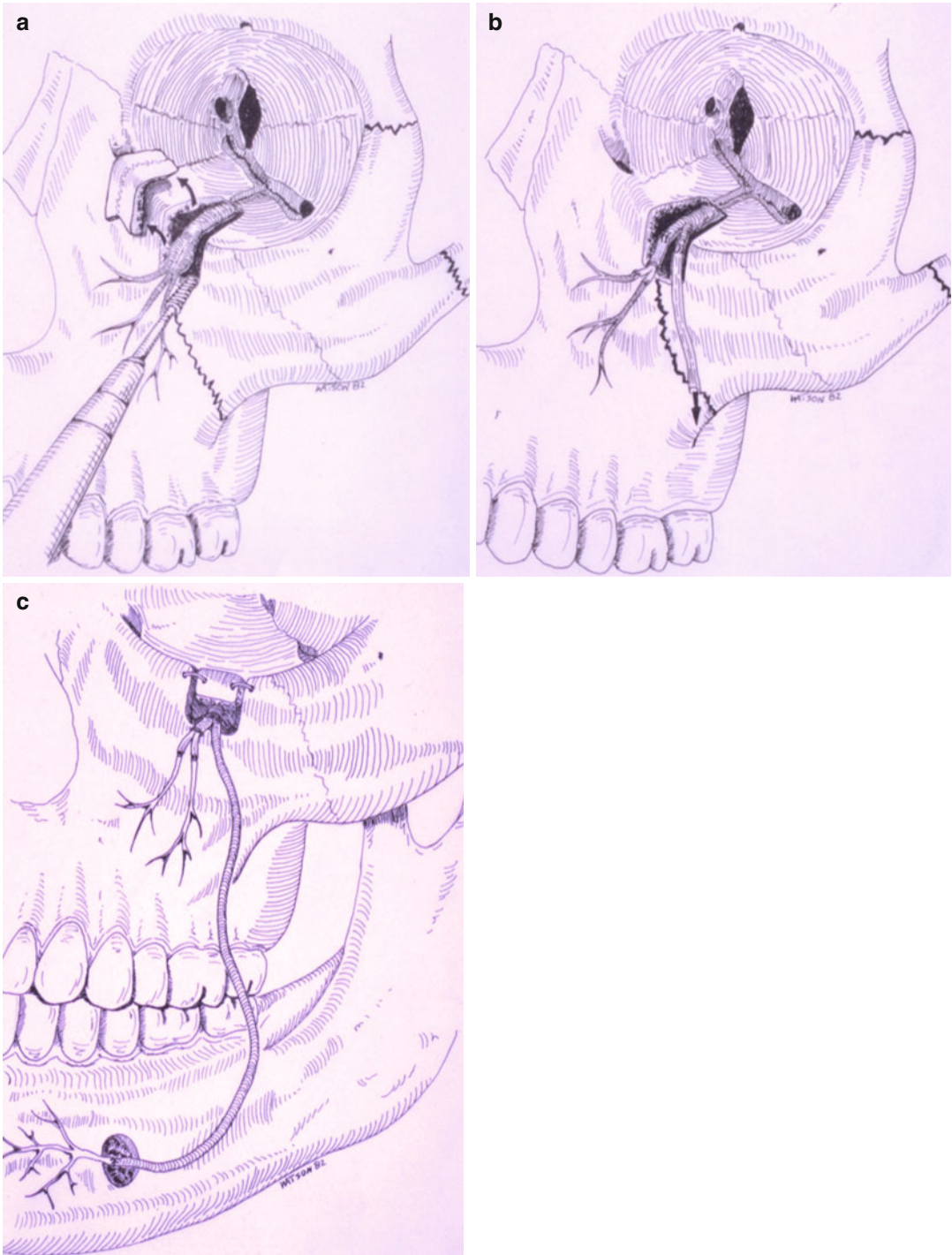


Fig. 16.7 (a) Diagram showing injury to the infraorbital nerve and loss of the proximal branch of the IAN from severe facial trauma, but the mental nerve was still present. (b) The infraorbital nerve was divided with short sural nerve grafts used to reanastomose the distal branches of

the infraorbital nerve and a long graft from the other part of the proximal infraorbital nerve and (c) to anastomose to the mental nerve. In this case of nerve sharing or nerve transfer, the patient did regain some sensibility to the distribution of these nerve branches

individuals; *allograft* is transplanted between genetically nonidentical individuals of the same species; and *xenograft* is transplanted from a donor of one species and grafted into a recipient of another species.

The two most common autogenous donor nerves for TN repair are the sural and the greater auricular nerves. Selection of a donor nerve is predicated in part on ease of harvesting and on minimizing postsurgical symptoms associated with the donor nerve and its functional distribution. Both the sural and greater auricular nerves are relatively easy to harvest but yield localized areas of sensory deficit after surgery. Other potential donor nerves include the saphenous dorsal cutaneous branch of the ulnar nerve, the medial antebrachial cutaneous, lateral antebrachial cutaneous, superficial branch of the radial, intercostal, and other nerve branches of the cervical plexus [24, 47]. Several factors that are important to consider when selecting a donor nerve are as follows.

16.2.1 Diameters of Donor and Host Nerves

Ideally, the diameter of the nerve graft should correlate exactly with the diameter of the proximal and distal ends of the prepared host nerve. The average diameter of the IAN is 2.4 mm [43]; LN, 3.2 mm [1]; sural nerve, 2.1 mm [8]; and greater auricular nerve, 1.5 mm [43]. For IAN grafting, the sural nerve is generally considered the best cross-sectional match because its diameter is 87 % that of the IAN, but only 66 % that of the LN. The greater auricular nerve diameter is about 63 % of the IAN and 47 % of the LN diameter. The greater auricular nerve works best if placed as a cable graft (Fig. 16.8), with two or more par-

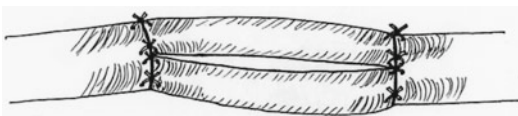


Fig. 16.8 The cable grafting technique may be indicated to improve the match of graft to host nerve in cross-sectional diameter, number of fascicles, and fascicular pattern

allel graft strands, so the combined diameter of the two strands would be adequate (125 % of the IAN and 94 % of the LN diameter).

16.2.2 Length of Nerve Graft Required

It may be difficult to obtain a graft longer than 2–4 cm from the greater auricular nerve. Since the greater auricular nerve (Fig. 16.9a) is generally half the diameter of the IAN and LN, a two-strand cable graft usually works best for diameter match (Fig. 16.8). Therefore, it may be difficult to graft a defect larger than 1–1.5 cm if the graft is harvested unilaterally. The sural nerve is larger in diameter, and a 20- to 30-cm length can be harvested without much difficulty (Fig. 16.9b). Since a longer graft will usually be necessary for nerve sharing techniques, the sural nerve would be the autogenous donor choice (Fig. 16.7a, b).

16.2.3 Number of Fascicles

The number and size of fascicles should correlate between the donor and host nerves. The IAN usually has 18–21 fascicles in the third molar area (Fig. 16.10a), decreasing to about 12 fascicles just

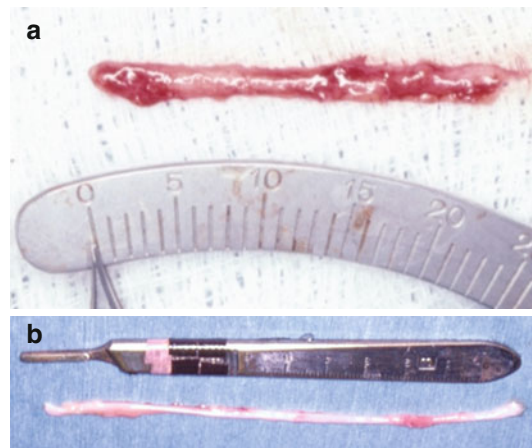


Fig. 16.9 (a) The greater auricular nerve provides a shorter length of graft, and the diameter is significantly smaller than the trigeminal nerve branches. (b) A significantly longer graft can be harvested from the sural nerve, and it has a larger diameter than the greater auricular nerve

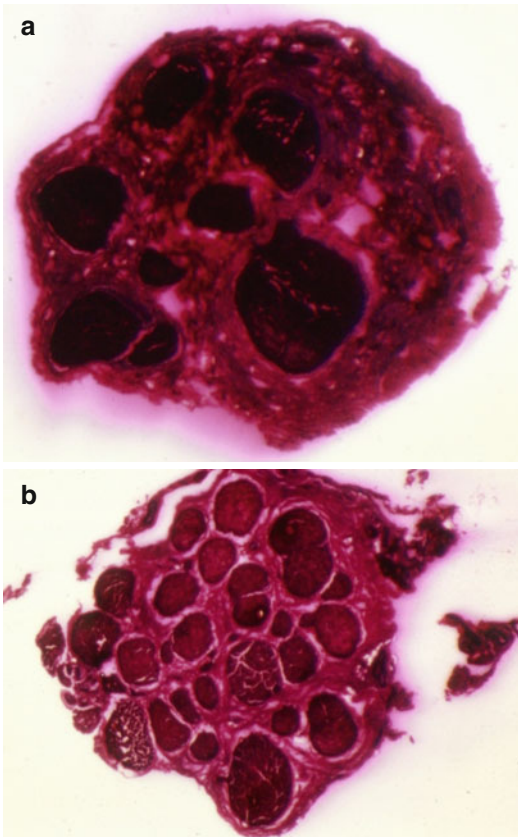


Fig. 16.10 (a) This cross-sectional histological view of the IAN at the third molar area shows the polyfascicular pattern. (b) Just proximal to the mental foramen, the number of fascicles in the IAN decreases significantly

proximal to the mental foramen area (Fig. 16.10b) [43]. The LN in the third molar area usually has 15–18 fascicles [1], decreasing to 9 fascicles as it enters the tongue [48]. The sural nerve usually has 11–12 fascicles [8], which is 54 % of the number of fascicles in the IAN and 69 % of the number in the LN. The greater auricular nerve usually has 8–9 fascicles [47], which is significantly less than the number in the IAN (44 %) and LN (52 %). However, if a cable graft with two parallel nerve graft strands is used (Fig. 16.8), the combined number of fascicles correlates more closely with those of the IAN (87 %) and LN (104 %). Sometimes, the greater auricular nerve is even smaller, and the transverse cervical nerve may be considered. If the nerve graft is significantly smaller in diameter than the proximal host nerve stump, useful fascicles are lost, and a neuroma may form from collateral

axonal microsprouting. If the graft is too large at the distal host nerve stump, then some of the regenerating nerve fascicles in the graft will be lost. If the distal portion of the graft is smaller than the distal portion of the host nerve, then a number of the fascicles in the distal portion of the host nerve will not regenerate.

16.2.4 Fascicular Pattern

The IAN and LN have polyfascicular patterns; the fascicles have various sizes from small to large diameter, but without fascicular grouping [1, 43]. The sural nerve has an oligofascicular (uniform size) pattern, but with small-diameter fascicles [8]. The greater auricular nerve is a polyfascicular nerve with grouping, a pattern that more closely approximates the fascicular pattern of the IAN and LN than the sural nerve [44]. The axons in the sural nerve are much smaller and fewer in number than those in the IAN and LN, creating another significant mismatch.

16.2.5 Cross-Sectional Shape and Area

The IAN and LN are round [1, 43], whereas the sural nerve is basically flat or elliptical. The greater auricular nerve is round-oval, and therefore, it more closely resembles the IAN and LN than does the sural nerve. The approximate total cross-sectional area of the IAN is 4.6 mm²; the LN, 5.2 mm²; the sural nerve, 3.5 mm²; and the greater auricular nerve, 1.8 mm². There is no significant difference in fascicular pattern and total nerve areas among the IAN, LN, and greater auricular nerve [1, 43]. The sural nerve has significantly smaller axonal size and number of axons per unit area (50 % less) than the others [16].

16.2.6 Patient Preference

Harvesting the sural nerve results in numbness of the heel and lateral aspect of the foot (Fig. 16.11).

Fig. 16.11 The sural nerve may be harvested through multiple small incisions in the lower leg

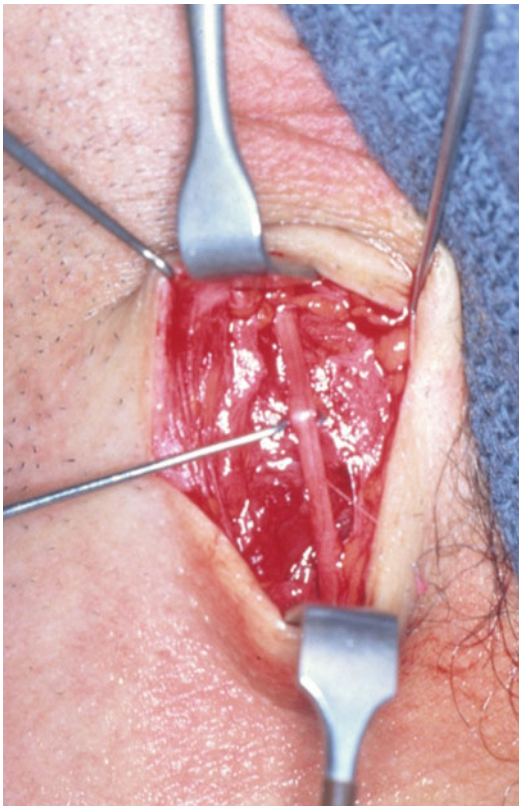
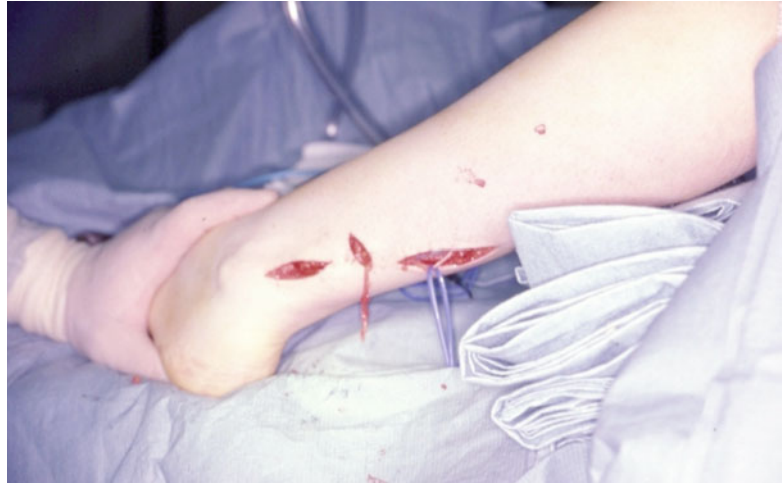

Fig. 16.12 The greater auricular nerve is harvested from the neck through a horizontal incision

Harvesting the greater auricular nerve results in numbness to the ear, lateral neck, and skin overlying the posterior aspect of the mandible (Fig. 16.12). An additional risk at the donor area in addition to

the cervical scar is development of a painful neuroma that may require additional treatment. Patients may prefer that their numbness and/or potential complications be in the foot rather than in the head and neck area, therefore favoring the sural nerve as the preferred donor nerve, and, in fact, improved IAN or LN recovery following nerve repair correlates well with less patient-perceived morbidity from the nerve harvest site [33].

16.3 Factors Affecting Nerve Graft Success

The success and ultimate outcome of a nerve repair or grafting procedure are based on a number of factors, and the more favorable the factors, the better and more predictable the outcome.

16.3.1 Time Since the Injury

In general, peripheral nerve injuries requiring surgical intervention will have better results the earlier the nerve is repaired after injury. Therefore, repairs with or without grafting performed immediately after the injury have better results, with progressively worsening results if done 3, 6, 9, or 12 months or longer after the injury. Wietholter and colleagues reported best results for IAN and LN repair if reconstruction was done within 3 weeks of the injury [53]. Early repair circumvents

major problems encountered with elapsed time such as Wallerian degeneration, atrophy, and fibrosis in the distal portion of the nerve (Fig. 16.1). Atrophy creates a significant size match discrepancy between the nerve graft and either or both nerve stumps. The time factor reflects the rate and extent of degeneration and atrophy of the distal fascicles prior to nerve repair. However, if the injury is primarily a traumatic neuroma without atrophy or degenerative neurologic changes in the distal portion of the nerve, the time factor may not be as important; that is, whether the repair is done at 3 weeks or 2 years may not make a difference in functional outcome.

16.3.2 Type and Extent of Injury

The more localized and confined the injury to the nerve, the less trauma to the nerve, and the shorter the required nerve graft (or possibility of repair without grafting), then the better the outcome. Stretch-type injuries or injuries caused by the injection of alcohol, steroid, or other caustic chemical into or adjacent to a nerve (Fig. 16.3) can cause significant irreversible damage to the nerve, which can extend proximally into the ganglion cell bodies, beyond a surgically accessible area, thus rendering peripheral nerve repair ineffective. In addition, significant ganglion cell death from nerve trauma may occur early (within 90 days) following axotomy injuries, and this further supports the hypothesis that early repairs have improved outcomes.

16.3.3 Vascularity in Host Bed

For a nerve graft to be successful, it must be revascularized rapidly. Therefore, having the graft and the areas of neural anastomosis exposed to adjacent healthy soft tissues will help in this regard. The importance of the access of the nerve repair site to the surrounding vasculature must be weighed against the risk of cicatricial contraction of the soft tissues around the nerve repair site. Therefore, placing a membrane or covering over the nerve repair site to protect the repair or plac-

ing the graft inside a bony canal or in an area of significant scar tissue may have poorer results because of delayed revascularization of the nerve repair site and nerve graft if utilized.

16.3.4 Orientation of Nerve Graft Placement

It is important to place a nerve graft so that it is oriented in the same functional direction from which it was harvested. That is, the proximal end of the nerve graft should approximate the proximal end of the host nerve, and the distal end of the graft should anastomose with the distal end of the host nerve. Axoplasmic flow should be maintained in the same direction. Therefore, when a nerve graft is harvested, the orientation should be carefully noted. It is also believed that the direction of axoplasmic flow is not important since the nerve graft essentially functions as a conduit, and antero- and retrograde flow will be reestablished regardless of the orientation of the nerve graft between the proximal and distal nerve stumps.

16.3.5 Length of Nerve Graft Required

In general, the shorter the nerve graft required, the better the result, and the longer the nerve graft, the less predictable the result. This is due in part to the amount of time it takes for regeneration to occur across each anastomosis area (7–14 days) and along the length of the nerve (0.2–3.0 mm/day). The longer the nerve graft, the more time that is required for regeneration to reach the distal anastomosis of the graft, increasing the risk of atrophy and fibrous ingrowth into the distal anastomosis area, resulting in a poorer outcome (Fig. 16.7).

16.3.6 Quality and Type of Repair

Quality of repair is particularly sensitive to the surgeon's skill and experience. Obviously, the highest quality repairs yield the best results. A high-quality repair includes atraumatic management of the proximal and distal ends of the host and graft nerves and meticulous

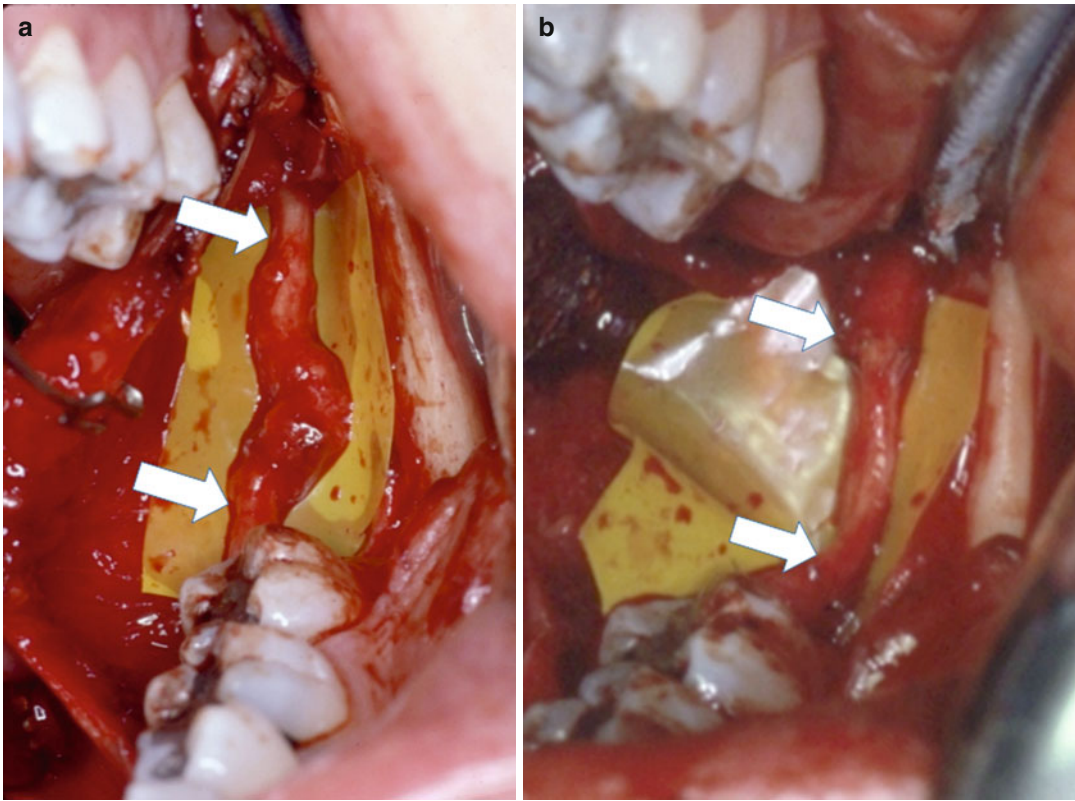


Fig. 16.13 (a) Lingual nerve with a large neuroma (between *arrows*) as a result of an impacted third molar removal. (b) The nerve has been repaired with a sural

nerve graft without any tension on the nerve segments. The distal and proximal anastomoses are delineated by *arrows*

neurorrhaphy techniques. The TN branches are polyfascicular without grouping and have a large number of fascicles, so epineurial repair is the most logical and appropriate technique (Fig. 16.6). Depending on the situation, 8-0 to 10-0 monofilament nylon suture can be used for the repairs. Minimizing the number of sutures (3–6 is optimal) is helpful as long as the approximation of the nerve graft to the nerve stumps is accurate. It is important to attempt to suture only the epineurium and not pass the needle and suture through the fascicles, since this can create more fascicular damage and scarring, yielding a poorer result.

16.3.7 Tension on Repaired Nerve

The nerve should be repaired or grafted with no tension on the nerve segments and areas of

anastomosis (Fig. 16.13a, b). Excessive tension can cause breakdown at the area of anastomosis with scar tissue formation, resulting in a poor outcome. The host nerve should be prepared prior to harvesting the graft so that graft length can be determined as accurately as possible. It must be remembered that the sectioned host nerve segments will retract, yielding a larger defect. Additionally, a harvested nerve graft shrinks in length by approximately 20 %, and additional length may be lost in final preparation of host and nerve graft ends. Therefore, the nerve graft harvested should be at least 25 % longer than the initially measured host nerve defect to compensate for these predictable changes.

16.3.8 Preparation of the Host Nerve

A good outcome requires complete removal of the area of injury and assurance of healthy, viable

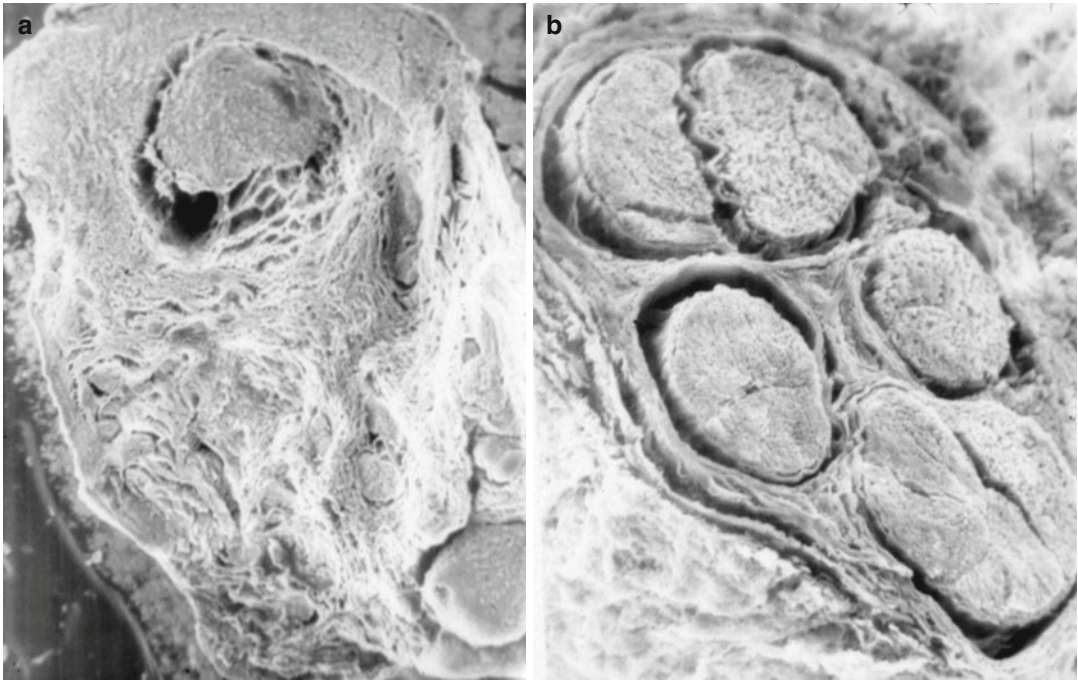


Fig. 16.14 (a) Frozen section of an injured proximal nerve segment shows significant fibrosis and no viable fascicles. (b) Frozen nerve section further proximal demonstrates viable nerve tissue

nerve tissues at the proximal and distal stumps. Frozen sections for histological assessment of the proximal and distal stumps may be helpful to determine when good, viable nerve tissue has been reached [51]. In the distal end, there may be degenerative changes (Wallerian degeneration) involving the fascicles. However, it is important to be sure that no significant fibrosis or other obstructions remain in the distal portion of the host nerve (Fig. 16.14a, b). The proximal and distal nerve stumps should be prepared with 1.0-mm resections until healthy fascicles are encountered. Of course, with continued incremental resection, the need for nerve grafting, or defect management, increases significantly, but this is a necessary step to ensure that scar tissue does not remain at the host nerve stumps since this would result in a poor outcome.

16.3.9 Age of Patient and Other Health Factors

In general, younger patients have the best results, and elderly patients have the poorest results following nerve repair or grafting.

Children have a greater ability to centrally adapt to altered nerve programming, greater regenerative capabilities, and greater healing and metabolic rates than older patients. Systemic factors that can adversely affect outcome include connective tissue and autoimmune diseases (e.g., scleroderma, mixed connective tissue disease, rheumatoid diseases, and systemic lupus erythematosus), diabetes mellitus, vascular and bleeding disorders, inherited or acquired neuropathies, alcoholism, smoking, and others. These factors must be considered when counseling patients about risks, complications, and expected outcomes following nerve repair.

16.4 Expected Outcomes

Many factors influence the quality of results following nerve repair. If the donor nerve and other success factors are all favorable, then good results can be expected. The definition of a successful and acceptable outcome varies widely among patients and surgeons, since there is no accepted standard assessment protocol. The quality of

outcome for a given patient may not be predictable, but the more favorable the factors affecting success, the greater the potential for a good outcome. It must be understood that the best result may not be able to restore function to the pre-injury level. With LN injury, return of taste sensation is unpredictable and should not be expected.

Wietholter and colleagues found better results for IAN repair with end-to-end anastomosis than with nerve grafting [53]. This has been the senior author's experience as well. Therefore, with IAN injuries, the possibility of decortication of the mandible over the distal portion of the IAN should be evaluated, and the distal portion of the IAN and mental nerve should be posteriorly repositioned to facilitate end-to-end repair before considering a nerve graft. Hessling et al. reported that only 40 % of patients who underwent IAN reconstruction and 35 % who underwent LN reconstruction have good results. They recommended reconstruction of these nerves only if the patient has pain in addition to loss of sensitivity [21]. Bagheri and colleagues found an 81 % IAN restoration of acceptable levels of neurosensory function. They report that the likelihood of regaining neurosensory function threshold drops significantly at 12 months after nerve injury and at 51 years of age [4]. Zuniga reported on outcomes of nerve repair in ten patients; both patients and surgeon rated the overall outcomes as mostly good, although there were differences in specific outcome ratings by surgeon and patients [57]. Donoff and Colin reported improvement in 63 % of their patients who underwent LN repair (31 nerves): 77 % in the anesthesia group and 42 % in the pain-paresthesia group. Overall, improvement was seen in 77 % of patients who underwent IAN repair [15].

Less favorable results in some studies may be related to unfavorable factors affecting outcome. Assessment of the literature indicates that LN repairs are less successful than other nerve repairs. Perhaps difficulty in surgical access and constant mobility of the area after surgery (i.e., eating, swallowing, and speaking) may contribute to the lower success rate. Also, the LN is the largest branch of the trigeminal system. Most surgeons use only a single-strand graft for repair of

any of the TN branches, resulting in a significant mismatch in size and fascicular characteristics, which may contribute to a less satisfactory outcome. Use of cable grafting may improve the results for some patients [54, 55]. Bagheri and colleagues performed a chart review of 222 patients receiving a LN repair with a follow-up of at least 1 year. They found that the microsurgical repair of LN injury has the best chance of successful restoration if done within 9 months of injury, and the likelihood of recovery after nerve repair decreases progressively when the repair occurred more than 9 months after injury and with increasing patient age (5.5 % decrease in the chance of recovery for every year of age in patients 45 years old or older [3]).

16.5 Nerve Grafting with Other Tissues

Alternative tissues such as veins, collagen conduits and filaments, and perineurial tubes have been used in the past for nerve repair. The majority of human and animal studies have involved vein grafts. Pogrel and Maghen [37] and Miloro [31] (rabbit model) (2001) showed that vein grafts may be useful for TN repair. Tang and colleagues reported on a technique in which a vein was taken from the forearm and reversed to bridge digital nerve defects [45]. For nerve defects >2.0 cm, normal nerve slices were inserted inside vein conduits. Follow-up revealed excellent recovery in two digital nerves, good in nine, fair in five, and poor in two.

Chiu and Strauch reported a prospective comparative clinical study evaluating direct nerve repair, nerve grafting, and vein grafting for distal sensory nerve defects <3 cm. A total of 34 nerves were repaired: 15 with a venous nerve conduit, 4 with a sural nerve graft, and 15 with direct repair. Significant symptom relief and satisfactory sensory function return were observed in all patients. Two-point discrimination measurements indicated the superiority of direct repair, followed by conventional nerve grafting, and then vein grafting. However, the universally favorable patient acceptance and the return of measurable two-point discrimination indicated the effectiveness of autogenous

vein grafts as nerve conduits when selectively applied to bridge a small nerve gap (<3 cm) on nonessential peripheral sensory nerves [12].

Walton and colleagues reported a retrospective study on the use of autogenous vein grafts in 22 digital nerve repairs. Two-point discrimination averaged 4.6 mm for 11 acute digital nerve repairs using vein conduits 1–3 cm in length. Delayed digital nerve repair with vein conduits yielded poor results. Comparing end-to-end digital nerve repairs and digital nerve grafting suggests that repair of 1- to 3-cm gaps in digital nerves with segments of autologous vein grafts appears to give results comparable to those of nerve grafting [49]. Some investigators have suggested that the vein graft should be used in an inside-out fashion since the outer surface of the vein contains the neurotrophic and neurotropic factors to help promote and support nerve growth from the proximal nerve stump.

However, a major concern with autogenous vein grafts is that they have little mechanical resistance to kinking and collapse [51]. Tang and colleagues demonstrated that repair of digital nerves with gaps ranging from 4 to 5.8 cm using vein conduits yielded no detectable recovery of sensibility in autonomous areas of these nerves and no sign of recovery of the innervated muscles during follow-up [45]. Re-exploration revealed that the vein conduits used for repair of the median nerves were constricted by surrounding scar tissue; axon regeneration was precluded [46].

16.6 Allograft Nerve Grafts

The cadaveric nerve allograft provides an unlimited graft source acting as viable nerve conduits without the morbidities associated with autogenous nerve harvesting. This grafting method has the advantage of harvesting the same nerve from the host to be grafted to the recipient site providing the best nerve graft characteristics (nerve diameter, fascicular pattern, etc.). Host motor and sensory axons grow to reach the host target via those conduits. Function is provided by the regenerating autologous nerves, and this regeneration

is supported by allogeneic cells. To ensure Schwann cell viability and minimal fibrosis, the allograft must be revascularized in an early post-transplant period [40].

These allogeneic nerve grafts are rapidly rejected unless appropriate immunosuppression is achieved. The toxicity associated with immunosuppression required to promote graft acceptance must be compared with relative benefits of reinnervation before nerve allotransplantation can be safely applied in routine practice [40]. Mackinnon and colleagues treated seven patients with allograft nerve transplantation, up to 37 cm in length, to the extremities with immunosuppression therapy started several days before surgery. The average time of immunosuppressive therapy was 18 months with no posttreatment evidence of adverse reactions, and only one nerve graft was rejected. The other patients at longest follow-up had light touch, hot and cold, as well as pain sensations, but no two-point discrimination [27]. Optimal treatment methods for nerve allograft transplantation must minimize or prevent rejection and permit nerve regeneration at the same time.

One option is the use of processed allografts such as AxoGen Avance® (AxoGen Inc., Alachua, FL), a human decellularized allograft product (Fig. 16.15). Processed allografts retain the scaffold of nerve tissue but are made to be non-immunogenic and inert in the body by a variety of processing methods. Examples of processing techniques include the following: repeated freeze-thaw cycles, exposure to radiation, extended storage in cold University of Wisconsin solution, and decellularization with detergents. Processed allografts provide a biological substrate for nerve regeneration without the requirements for immunosuppression [40].

Whitlock and colleagues used a rat model to compare isograft, NeuraGen (type I collagen conduit), and processed rat allografts comparable to AxoGen Avance®. In the long sciatic nerve gap model (28 mm), isograft was superior to processed allograft, which was superior to NeuraGen conduits at 6 weeks postoperatively. The authors conclude that in the long-gap model, nerve grafting alternatives fail to deliver the regenerative

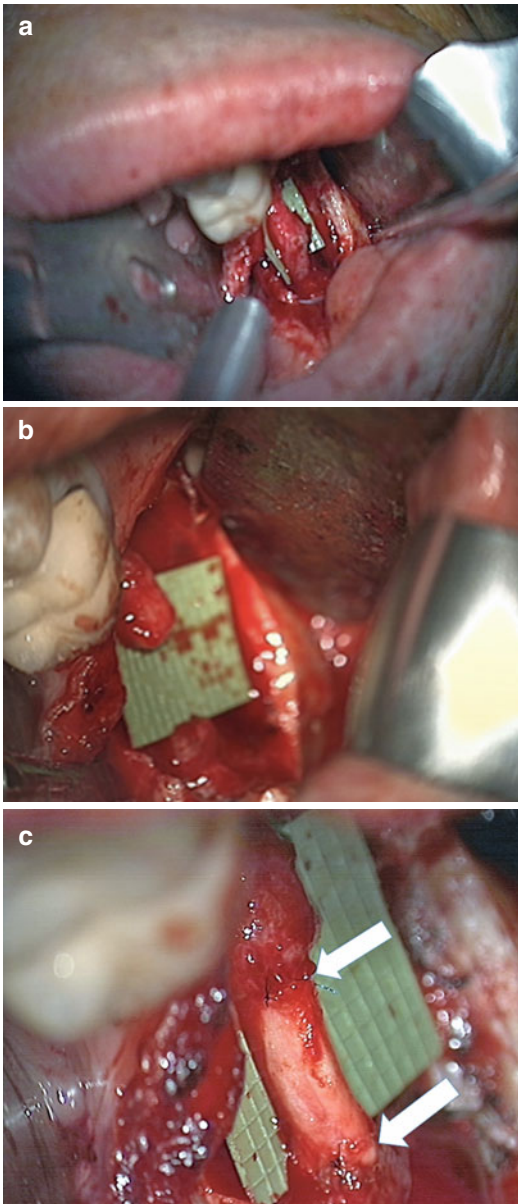


Fig. 16.15 (a) Left IAN neuroma. (b) The neuroma has been excised. (c) The IAN has been repaired with an Avance decellularized cadaveric nerve. A 3–4-mm diameter \times 30-mm Avance nerve graft was trimmed to span the 10-mm defect. The *arrows* delineate the graft (Photos courtesy of Martin Steed, DDS, Atlanta, Georgia)

advantages of an isograft. However, in the short sciatic nerve gap model (14 mm), there was no significant difference between the three groups relative to nerve regeneration at 22 weeks [52]. Although the use of processed decellularized

cadaveric allografts look promising for nerve injury repair, there is only one study (abstract) available to determine the efficacy of using this graft system for repair of LN or IAN nerve injuries [19]. In 8 patients (5 LN and 3 IAN) who had an Axogen Avance[®] nerve graft, 4 patients had some recovery, 1 had minimal recovery, and 3 patients had no recovery of sensation. At best this could be seen as a 50 % success with the use of this technique, but more data is needed for adequate interpretation of the usefulness of this graft option.

16.7 Alloplastic Nerve Grafts

End-to-end suture neurorrhaphy of nerves and autologous nerve graft are the “gold standard” repair and reconstruction of peripheral nerves. However, this treatment may be associated with a variety of clinical complications, such as donor-site morbidity, limited availability, nerve site mismatch, and the formation of neuromas [42]. Nerve conduits provide a channel for direction of axonal sprouts from the proximal stump to the distal nerve stump. In addition to this, they allow diffusion of neurotrophic and neurotropic factors secreted by the Schwann cells of the distal stump and minimize infiltration of fibrous scar tissue. A variety of synthetic materials are available (e.g., silicone, polyglycolic acid, glycolide trimethylene carbonate, and poly lactide-co-caprolactone) [10]. This section will present the alloplastic options to treat nerve defect injuries.

16.7.1 Nonresorbable Materials

Silicone is a permanent conduit material that has been used for nerve grafting. However, long-term entubulization of a nerve produces localized compression with resultant decreased axonal conduction, although the total number of nerve fibers and size of the axons remain constant. However, alterations in the blood-nerve barrier occur, followed by demyelination of the nerve fibers [25, 26]. Silicone tubes used for neural conduits must be removed in order to achieve

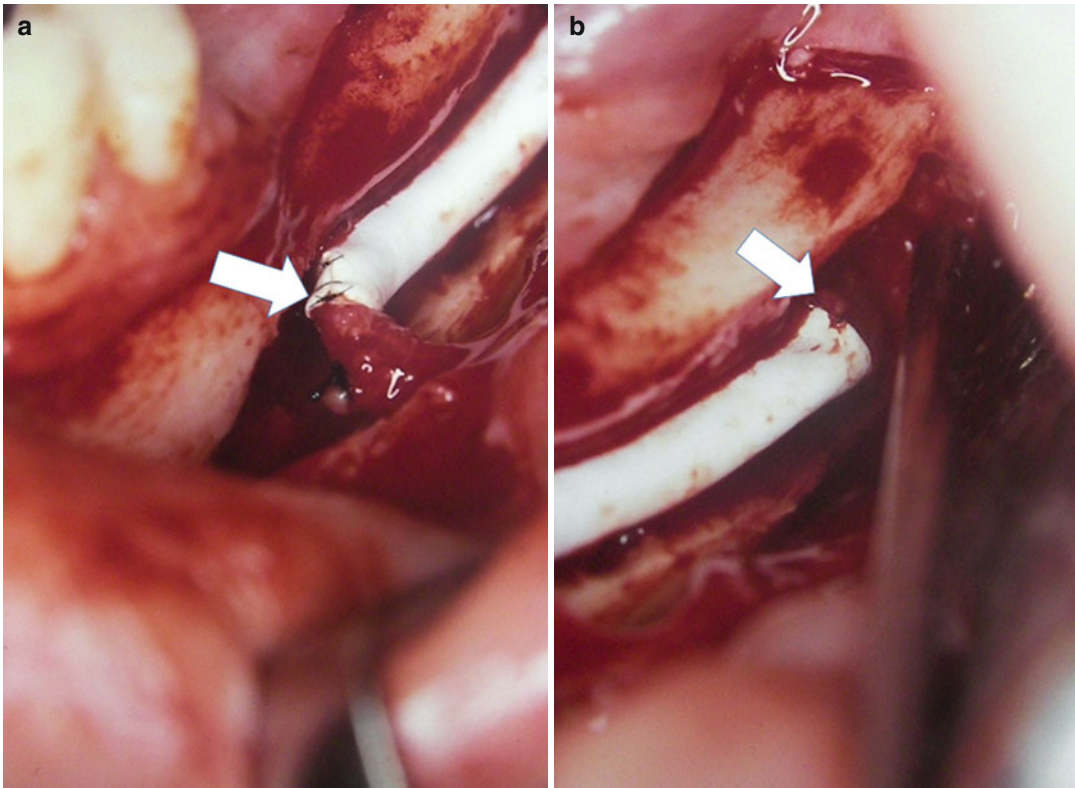


Fig. 16.16 (a) Gore-Tex conduit used for nerve reconstruction, demonstrating the distal repair (*arrow*). Due to distal nerve atrophy, the distal end of the graft has been narrowed to conform to the diameter of the distal nerve

segment. This modification can be used for other conduit products. (b) The proximal repair is seen (*arrow*). However, Gore-Tex grafts are not recommended for repair of trigeminal nerve branches

a positive outcome [14]. Similar unfavorable outcomes occur when using Gore-Tex (expanded polytetrafluorethylene) grafts (WL Gore and Associates, Inc, Flagstaff, AZ) as a nerve graft conduit (Fig. 16.16a, b). Although animal studies have shown promise in the use of Gore-Tex for a nerve continuity defect [32], the clinical studies indicate that Gore-Tex tubing is not effective and therefore not recommended in the repair of continuity defects of IAN and LN. The Gore-Tex tubing collapses following surgery since it has little inherent strength which impedes neural regeneration [36, 38]. Other nondegradable materials with poor results are elastomer hydrogel or porous stainless steel. These artificial materials have the disadvantage of engendering chronic foreign body reactions due to scar formation, inflexibility, and lack of stability [41], and these are not used for TN repair.

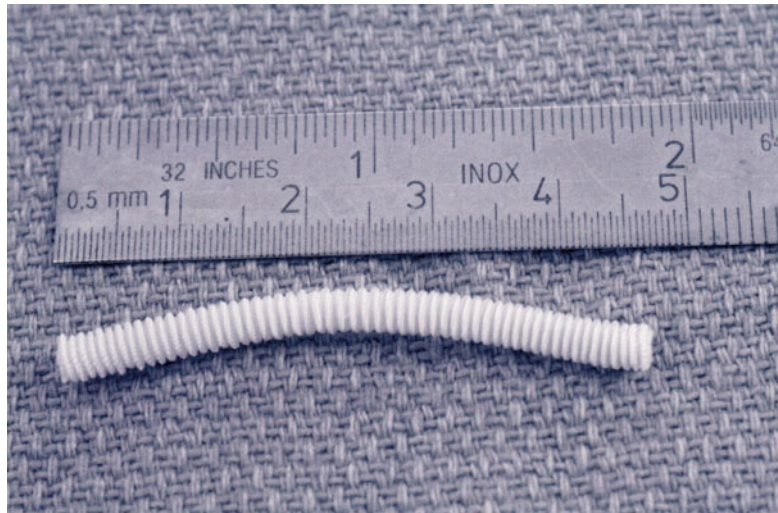
16.7.2 Biodegradable Synthetic Materials

The biodegradable or resorbable nerve tubes are an alternative for repairing peripheral nerve defects in order to avoid the problems associated with nondegradable polymeric conduits, such as foreign body reactions.

16.7.2.1 Polyglycolic Acid

Polyglycolic acid (Dexon, American Cyanamid Co, Wayne, NJ) is a bioabsorbable substance that is currently used as a suture material [20] and in mesh form to invest internal organs injured as a result of trauma [28]. It is absorbed in the body via hydrolysis, begins to breakdown at 3 months, and is resorbed within 6–8 months. A bioabsorbable polyglycolic acid conduit has been developed for nerve grafting in which the nerve gap

Fig. 16.17 Neurotube is a bioabsorbable polyglycolic acid tube with porosity, flexibility, and corrugation to resist occlusive forces



is ≥ 8 mm but ≤ 3 cm (Neurotube, Synovis Life Technologies Inc., St.Paul, MN) (Figs. 16.17 and 16.18a–g). Characteristics of this tube include the following: (1) porosity, which provides an oxygen-rich environment for the regenerating nerve; (2) flexibility, to accommodate movement of joints and associated tendon gliding; (3) corrugation, to resist the occlusive force of surrounding soft tissue; and (4) bioabsorbability, eliminating the need for removal at a subsequent operation. This corrugated tube has available internal diameters from 2.3, 4.0, to 8 mm and lengths from 2 to 4 cm [5, 18].

Weber and colleagues reported a prospective study on 136 nerve repairs in the hand, divided into two groups: group 1 consisted of standard repair with either end-to-end anastomosis or nerve graft and group 2 consisted of nerve repair using a Neurotube conduit (Fig. 16.17). Although there were no statistical differences between the two groups overall, two-point discrimination was better in the Neurotube group (6.8 ± 3.8 mm) than in the direct anastomosis or nerve graft group (12.9 ± 2.4 mm). The Neurotube conduit provided superior results and eliminated donor-site morbidity [50]. Mackinnon and Dellon reported good to excellent results in 86 % of digital nerve repairs in 15 patients using Neurotube [29]. Also, it is recommended to fill the tube with heparinized saline. Casanas et al. studied 17 patients with digital nerve defects ranging from 2 to 3.5 cm grafted

with Neurotube with good results [9]. Navissano and colleagues reported on using Neurotube to repair facial nerve defects from 1 to 3 cm with good results in five of seven patients [35].

Few articles have been published on Neurotube as an alloplastic material for TN repair. Crawley and Dellon reported an isolated case in which a 2.0-mm diameter Neurotube conduit was used in a 51-year-old woman to repair a right IAN 16 months following injury. The Neurotube conduit was filled with autologous serum to prevent blood clot formation. At 12 months after surgery, pressure and vibratory perception were similar to those of the contralateral lip and chin area [13].

The authors have utilized the Neurotube conduit for IAN and LN grafting with good preliminary results. The technique includes preparation of the proximal and distal ends of the host nerve and of a conduit graft that is at least 1 cm longer than the size of the defect. Three to four 8-0 to 10-0 nylon sutures are passed through the tube 5 mm from the end, through the epineurium of the proximal nerve stump, and back out through the tube in a horizontal mattress fashion. After all sutures are passed, the sutures are then gently pulled to deliver the proximal end of the nerve within the tube several millimeters (Figs. 16.17 and 16.18). The same horizontal mattress procedure is carried out for the distal end of the nerve. If there is a discrepancy in the sizes of host nerve end and tube diameter, the tube can be slit at the

end to allow expansion or contraction to correlate with the host nerve diameter. The artificial nerve conduit is then filled with a solution containing

1,000 U of heparin per 100 mL of isotonic saline to help prevent blood clot formation, which could impede axonal regeneration.

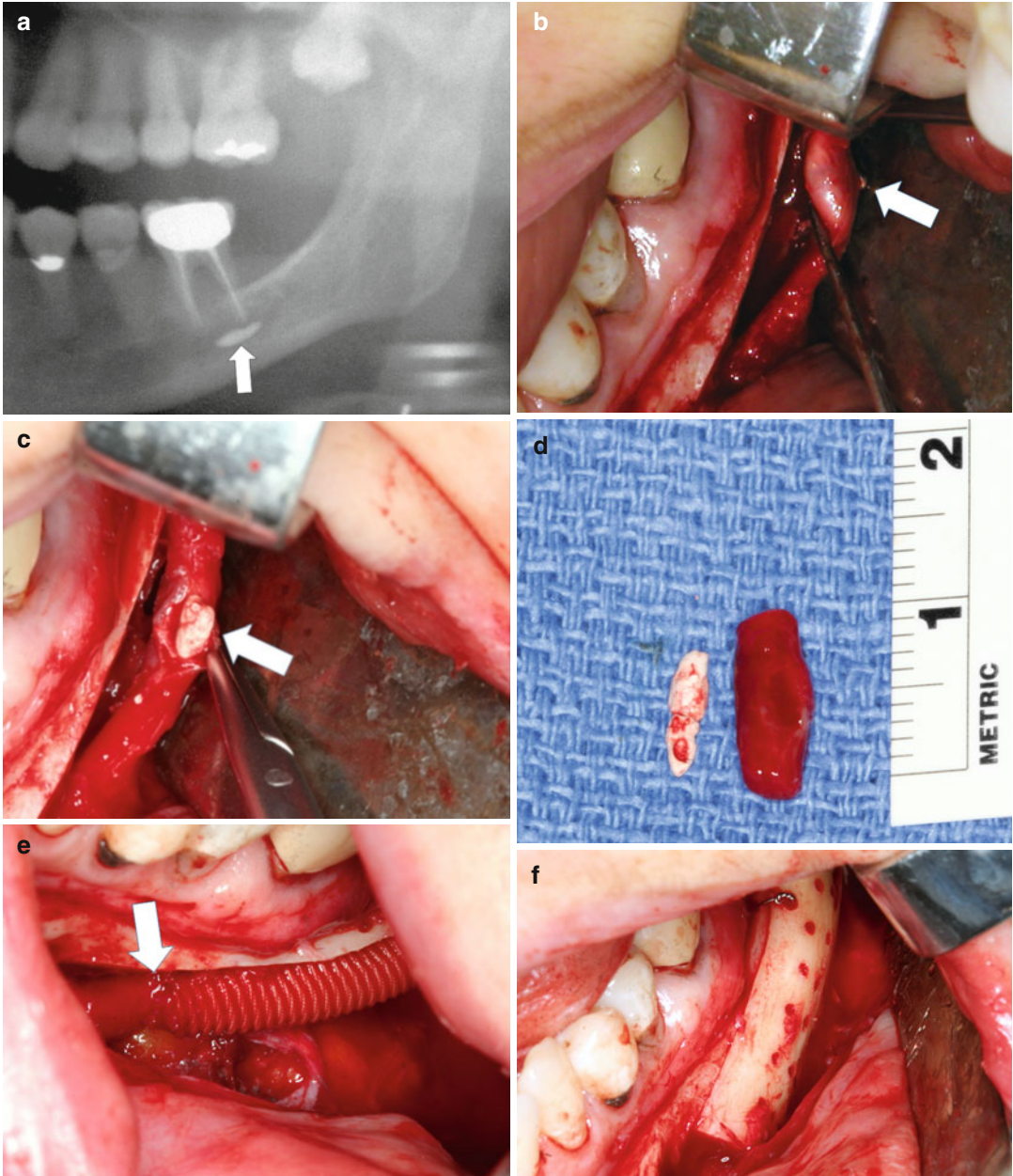


Fig. 16.18 (a) Radiograph shows foreign material (*arrow*) in the IAN canal following root canal treatment resulting in a painful dysesthesia to the distribution of the IAN. (b) Following decortications of the mandible, the IAN has been lateralized from the mandible. The *arrow* points to the nerve lesion. (c) An incision into the nerve shows a foreign body within the nerve (*arrow*). (d) The

IAN lesion has been resected, and the foreign body removed. (e) The nerve has been repaired with a 2.3-mm diameter Neurotube with the distal repair observed (*arrow*). (f) The lateral cortical bone that was removed for access to the IAN is replaced in position. The holes placed in the bone are to aid in revascularization of the repair site. (g) Radiograph shows the replaced buccal cortical bone

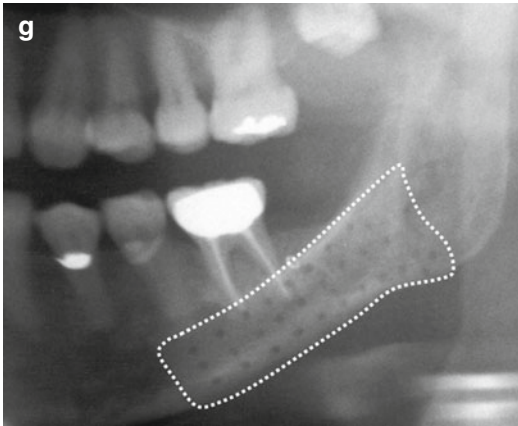


Fig. 16.18 (continued)

16.7.2.2 Polyesters and Copolyesters

Poly(DL-lactide-ε-caprolactone) NeuroLac nerve guide (Polyganics Inc. Groningen, NL) is another synthetic nerve conduit with a 3.5-cm length and a variable 1.5- to 10-mm internal diameter. The tube is less flexible, tends to swell, and takes 16–24 months to resorb. Bertleff and colleagues reported results in 54 patients with digital nerve injuries with controls using direct repair or nerve grafting and the experimental group treated with NeuroLac conduits [7]. Interim results showed comparable outcomes, but at longer follow-up, the NeuroLac group did not show better function and had significantly more complications related to the initial stiffness of the conduits but subsequent collapse during the absorption phase [30]. Chiriac and colleagues treated a series of 23 patients in a total of 28 nerve lesions (arm, forearm, wrist, palm, and fingers). Defects averaged 11.03 mm and were repaired using NeuroLac. After an average of 21.9 months, they observed eight complications with the most serious being two fistulizations of the NeuroLac device close to a joint and one neuroma. They concluded that the results do not support its use in repairing hand nerve defects [11]. Alternatively, Battiston and colleagues reported on 28 digital nerve repairs with NeuroLac with 93 % good to excellent results [6]. No studies have been done on the use of NeuroLac in TN repair.

16.7.2.3 Collagen

Semipermeable collagen type 1 nerve guides have been developed (Collagen NeuroGen Nerve

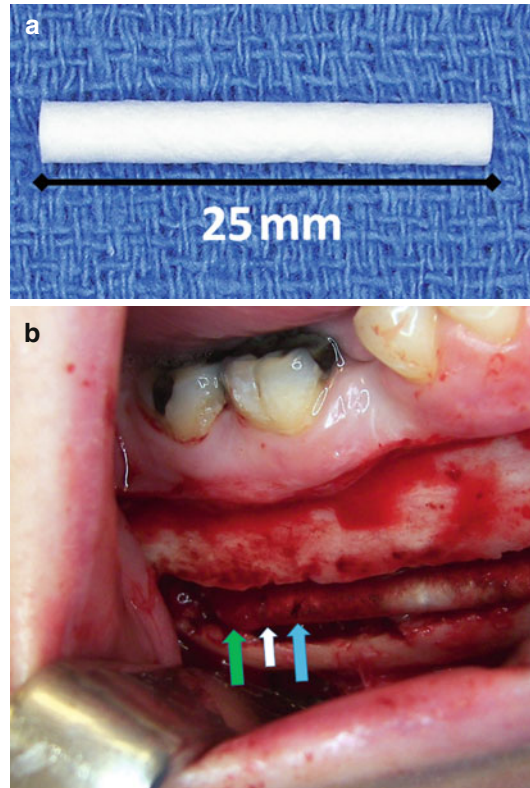


Fig. 16.19 (a) A collagen NeuroGen nerve guide can be used for nerve repair. (b) The NeuroGen tube has been used to repair the IAN. The *green arrow* shows the proximal nerve end. The *white arrow* shows where the IAN inserts into the NeuroGen tube. The *blue arrow* points at one of the three sutures used to deliver the IAN within the conduit and stabilize it in place

Guide, Integra NeuroSciences, Plainsboro, NJ). Type 1 collagen-based implants support and guide tissue regeneration *in vivo*, have low immunogenicity, and are biocompatible (Fig. 16.19a, b). Tube lengths are 2 to 3 cm with internal diameters ranging from 1.5 to 7 mm with an absorption rate of 4–8 months. Ashley and colleagues used NeuroGen nerve conduits in patients with brachial plexus birth injuries with four of five patients showing good recovery at 2 years post-surgery [2]. Lohmeyer and colleagues used NeuroGen grafts in hand surgery reporting four of six patients with excellent results at 1 year post-surgery [23]. Farole and Jamal described the results of using NeuroGen cuffs placed around nerve repair sites in eight patients with nine repairs. Following primary nerve repair, a NeuroGen conduit was split

longitudinally and encased around the repair site with at least 1.5 cm of margin. At 1–2.5 years follow-up, four repairs were found to have good improvement, four had some improvement, and one had no improvement [17]. NeuroMatrix and Neuroflex (Collagen Matrix Inc., Franklin Lakes, NJ) also make a nerve cuff that is described as nonfriable, crimped, semipermeable, tubular membrane matrix with type 1 collagen. The length is 2.5 cm and internal diameters from 2 to 6 mm with 4 to 8 months for absorption.

Since these absorbable conduits disintegrate, the problems associated with permanent tubing (i.e., Silastic, Gore-Tex), including compression and demyelination, are eliminated. The superior results achieved with nerve graft conduits are related to the elimination of the problems associated with harvested nerve grafts, host-donor differences in diameter, mismatches in number and pattern of fascicles and cross-sectional shape and area, as well as morbidity of the donor area. However, absorbable conduit grafting results will still be affected by such factors as time since injury, type and extent of injury, vascularity, graft size match, length of nerve graft required (results are good for defects <3 cm), quality of the repair (surgical skill), tension on the repair site, preparation of the host nerve, age of the patient, and other health factors.

Meeks and Coert recommend Neurotube as the preferred resorbable conduit for nerve repair following their extensive review of the various options [30]. Shin et al. performed a rat study creating 10-mm gaps in the sciatic nerve with four groups: Group I had reversed autografts, Group II had Neurolac conduits, Group III had NeuraGen conduits, and Group IV had Neurotube conduits. Groups I and II had the best results with no significant difference between them. Group VI had the poorest results but in part due to the diameter of the sciatic nerve was 1.5 mm, and the smallest Neurotube was 2.3 mm, while the other conduits were the appropriate size [39]. This study further supports the importance of having a coordinated diameter size of the conduit to the host nerve.

16.8 Molecular and Cell Therapy

Experimental studies have shown that the use of conduits seeded with cultured Schwann cells improves nerve regeneration. The use of fetal and adult progenitor neuronal cells and bone marrow stem cells are alternative techniques to the use of Schwann cells. Liu and colleagues investigated the effect of the adipose-derived stem cells (ADSCs) on peripheral nerve repair. They evaluated nerve regeneration across a 15-mm lesion in the sciatic nerve by using an acellular nerve injected with allogenic ADSCs. Results showed that the recovery of the ADSC-treated group was significantly better than that of the control group ($p < 0.05$). They conclude that the ADSC transplantation represents a powerful therapeutic approach for peripheral nerve injury, although the detailed mechanism by which the ADSCs promote peripheral nerve regeneration is being investigated [22]. Zhao and colleagues studied eighteen mice divided into three groups ($n = 6$ for each group) for nerve repair with nerve autograft, acellular nerve graft, and acellular nerve graft supplemented with bone marrow mesenchymal stromal cells (MSCs) and fibrin glue around the graft. The mouse static sciatic index was evaluated by walking-track testing every 2 weeks. The results showed that the nerve repair by the nerve autografting obtained the best functional recovery of the limb. The nerve repair with acellular nerve graft supplemented with MSCs achieved better functional recovery and higher axon number than that with the acellular nerve graft alone at 8 weeks post-surgery [56].

Another approach that has been studied is the incorporation of neurotrophic and neurotropic factors (e.g., basement membrane laminin) into nerve conduits in order to support nerve growth and improve the nerve regeneration process. The use of these techniques has been largely experimental to date. Cell therapy is limited by the technical and logistical difficulties in culturing and expanding these cells in vitro [10].

16.9 Summary

Nerve repairs and nerve grafting techniques have been around for many years. Autogenous nerve grafts have worked reasonably well in the right circumstances but are associated with difficulties in achieving a proper donor-host match as well as adverse postsurgical sequelae at the donor site. Vein grafts appear to work almost as well as autogenous nerve grafts in digital nerve repairs that require a graft <3 cm in length, but not with TN repairs. Currently, nerve graft materials such as polyglycolic acid tubes and processed decellularized allografts have shown reasonable results without the morbidity of autogenous nerve grafts. However, more research studies using these materials for TN repairs are needed to validate the usefulness and applicability of these procedures. Molecular and cell therapy applied to various nerve grafting techniques will certainly be the future for this challenging field of addressing the peripheral nerve gap.

Conflict of Interest This work has no competing conflict of interest and no funding.

References

1. Abby PA, LaBanc JP, Lupkiewicz S et al (1987) Fascicular characterization of the human lingual nerve: implications for injury and repair. *J Oral Maxillofac Surg* 45:43
2. Ashley WW, Weatherly T, Park TS (2006) Collagen nerve guides for surgical repair of brachial plexus birth injury. *J Neurosurg* 105:452–456
3. Bagheri SC, Meyer RA, Khan HA et al (2010) Retrospective review of microsurgical repair of 222 lingual nerve injuries. *J Oral Maxillofac Surg* 68:715–723
4. Bagheri SC, Meyer RA, Choo SH et al (2012) Microsurgical repair of the inferior alveolar nerve: success rate and factors that adversely affect outcomes. *J Oral Maxillofac Surg* 70:1978–1990
5. Barrows TH (1986) Degradable implant materials: a review of synthetic absorbable polymers and their applications. *Clin Mater* 1:233
6. Battiston B, Geuna S, Ferrero M et al (2005) Nerve repair by means of tubulization: literature review and personal clinical experience comparing biological and synthetic conduits for sensory nerve repair. *Microsurgery* 25:258–267
7. Bertleff MJ, Meek MF, Nicolai J-PA (2005) A prospective clinical evaluation of biodegradable Neurolac nerve guides for sensory nerve repair in the hand. *J Hand Surg [Am]* 30:513–518
8. Brammer JP, Epker BN (1988) Anatomic-histologic survey of the sural nerve: implications for inferior alveolar nerve grafting. *J Oral Maxillofac Surg* 46:111–117
9. Casanas J, Serra J, Orduna M et al (2000) Repair of digital sensory nerves of the hand using polyglycolic acid conduits. *J Hand Surg Br* 25:44
10. Chimutengwende-Gordon M, Khan W (2012) Recent advances and developments in neural repair and regeneration for hand surgery. *Open Orthop J* 6:103–107
11. Chiriac S, Facca S, Diaconu M et al (2012) Experience of using the bioresorbable copolyester poly(DL-lactide-ε-caprolactone) nerve conduit guide Neurolac for nerve repair in peripheral nerve defects: report on a series of 28 lesions. *J Hand Surg Eur* 37:342–349
12. Chiu DT, Strauch B (1990) A prospective clinical evaluation of autogenous vein grafts used as a nerve conduit for distal sensory nerve defects of 3 cm or less. *Plast Reconstr Surg* 86:928–934
13. Crawley WA, Dellon AL (1992) Inferior alveolar nerve reconstruction with a polyglycolic acid bioabsorbable nerve conduit. *Plast Reconstr Surg* 90:300–302
14. Dellon AL (1994) Use of a silicone tube for the reconstruction of a nerve injury. *J Hand Surg Br* 19:271–272
15. Donoff RB, Colin W (1990) Neurologic complications of oral and maxillofacial surgery. *Oral Maxillofac Surg Clin North Am* 2:453–462
16. Eppley BL, Snyders RV Jr (1991) Microanatomic analysis of the trigeminal nerve and potential nerve graft donor sites. *J Oral Maxillofac Surg* 49:612–618
17. Farole A, Jamal BT (2008) A bioabsorbable collagen nerve cuff (NeuraGen) for repair of lingual and inferior alveolar nerve injuries: a case series. *J Oral Maxillofac Surg* 66:2058–2062
18. Ginde RM, Gupta RK (1987) In vitro chemical degradation of polyglycolic acid pellets and fibers. *J Appl Polymer Sci* 33:2411
19. Green J (2009) Use of decellularized human nerve grafts for IAN and LN. *J Oral Maxillofac Surg* 67(Suppl 1): 54–55
20. Herrmann JB, Kelly RJ, Higgins GA (1970) Polyglycolic acid sutures. Laboratory and clinical evaluation of a new absorbable suture material. *Arch Surg* 100:486–490
21. Hessling KH, Reich RH, Hausamen JE et al (1990) Long-term results of microsurgical nerve reconstruction in the area of the head-neck. *Fortschr Kiefer Gesichtschir* 35:134–138
22. Liu G, Cheng Y, Feng Y et al (2011) Adipose-derived stem cells promote peripheral nerve repair. *Arch Med Sci* 4:592–596

23. Lohmeyer J, Zimmermann S, Sommer B et al (2007) Bridging peripheral nerve defects by means of nerve conduits. *Der Chirurg* 78:142–147
24. Mackinnon SE, Dellon AL (1988) *Surgery of the peripheral nerve*. Thieme Medical Publishers, New York
25. Mackinnon SE, Dellon AL, Hudson AR et al (1984) Chronic nerve compression an experimental model in the rat. *Ann Plast Surg* 13:112–120
26. Mackinnon SE, Dellon AL, Hudson AR et al (1985) A primate model for chronic nerve compression. *J Reconstr Microsurg* 1:185–195
27. Mackinnon SE, Doolabh VB, Novak CB et al (2001) Clinical outcome following nerve allograft transplantation. *Plast Reconstr Surg* 107:1419–1429
28. Marmon LM, Vinocur CD, Standiford SB et al (1985) Evaluation of absorbable polyglycolic acid mesh as a wound support. *J Pediatr Surg* 20:737–742
29. Mckinnon SE, Dellon AL (1990) Clinical nerve reconstruction with a bioabsorbable polyglycolic acid tube. *Plast Reconstr Surg* 85:419–424
30. Meek MF, Coert JH (2008) US Food and Drug Administration/Conformit Europe-approved absorbable nerve conduits for clinical repair of peripheral and cranial nerves. *Ann Plast Surg* 60:110–116
31. Miloro M (2001) Discussion: the use of autogenous vein grafts for inferior alveolar and lingual nerve reconstruction. *J Oral Maxillofac Surg* 59:988–993
32. Miloro M, Macy J (2000) Expanded polytetrafluoroethylene entubulation of the rabbit inferior alveolar nerve. *Oral Surg Oral Med Oral Pathol* 89:292–298
33. Miloro M, Stoner JA (2005) Subjective outcomes following sural nerve harvest. *J Oral Maxillofac Surg* 63:1150–1154
34. Murray-Dunning C, Mc Arthur SL, Sun T et al (2011) Three-dimensional alignment of Schwann cells using hydrolysable microfiber scaffolds: strategies for peripheral nerve repair. *Methods Mol Biol* 695:155–166
35. Navissano M, Malan F, Carnino R et al (2005) Neurotube for facial nerve repair. *Microsurgery* 25: 268–271
36. Pitta MC, Wolford LM, Mehra P et al (2001) Use of Gore-Tex tubing as a conduit for inferior alveolar and lingual nerve repair: experience with 6 cases. *J Oral Maxillofac Surg* 59:493–496
37. Pogrel MA, Maghen A (2001) The use of autogenous vein grafts for inferior alveolar and lingual nerve reconstruction. *J Oral Maxillofac Surg* 59:985–988
38. Pogrel MA, McDonald AR, Kaban LB (1998) Gore-Tex tubing as a conduit for repair of lingual and inferior alveolar nerve continuity defects: a preliminary report. *J Oral Maxillofac Surg* 56:319–321
39. Shin RH, Friedrich PF, Crum BA et al (2009) Treatment of a segmental nerve defect in the rat with use of bioabsorbable synthetic nerve conduits: a comparison of commercially available conduits. *J Bone Joint Surg Am* 91:2194–2204
40. Siemionow M, Sonmez E (2007) Nerve allograft transplantation: a review. *J Reconstr Microsurg* 8:511–520
41. Siemionow M, Bozkurt M, Zor F (2010) Regeneration and repair of peripheral nerves with different biomaterials: review. *Microsurgery* 30:574–588
42. Steed MB, Mukhatyar V, Valmikinathan C et al (2011) Advances in bioengineered conduits for peripheral nerve regeneration. *Atlas Oral Maxillofac Surg Clin North Am* 19:119–130
43. Svane TJ, Wolford LM, Milam SB et al (1986) Fascicular characteristics of the human inferior alveolar nerve. *J Oral Maxillofac Surg* 44:431–434
44. Svane TJ (1989) *The fascicular characteristics of human inferior alveolar and greater auricular nerves* (master's thesis) Waco, TX: Baylor University
45. Tang JB, Gu YQ, Song YS (1993) Repair of digital nerve defect with autogenous vein graft during flexor tendon surgery in zone 2. *J Hand Surg Br* 18:449–453
46. Tang JB, Shi D, Zhou H (1995) Vein conduits for repair of nerves with a prolonged gap or in unfavorable conditions: an analysis of three failed cases. *Microsurgery* 16:133–137
47. Terzis JK (1987) *Microreconstruction of nerve injuries*. WB Saunders, Philadelphia, pp 227–228
48. Trullsson M, Essick GK (1997) Low-threshold mechanoreceptive afferents in the human lingual nerve. *J Neurophysiol* 77:737–748
49. Walton RL, Brown RE, Matory WE Jr et al (1989) Autogenous vein graft repair of digital nerve defects in the finger: a retrospective clinical study. *Plast Reconstr Surg* 84:944–949
50. Weber RA, Breidenbach WC, Brown RE et al (2000) A randomized prospective study of polyglycolic acid conduits for digital nerve reconstruction in humans. *Plast Reconstr Surg* 106:1036–1045
51. Wessberg GA, Wolford LM, Epker BN (1982) Experiences with microsurgical reconstruction of the inferior alveolar nerve. *J Oral Maxillofac Surg* 40: 651–655
52. Whitlock EL, Tuffaha SH, Luciano JP et al (2009) Processed allografts and type I collagen conduits for repair of peripheral nerve gaps. *Muscle Nerve* 39: 787–799
53. Wietholter H, Riediger D, Ehrenfeld M et al (1990) Results of micro-surgery of sensory peripheral branches of the mandibular nerve. *Fortschr Kiefer Gesichtschir* 35:128–134
54. Wolford LM (1992) Autogenous nerve graft repair of the trigeminal nerve. *Oral Maxillofac Surg Clin North Am* 4:447–457
55. Wolford LM, Rodrigues DB (2011) Autogenous graft/allografts/conduits for bridging peripheral trigeminal nerve gaps. *Atlas Oral Maxillofac Surg Clin North Am* 19:91–107
56. Zhao Z, Wang YU, Peng J et al (2011) Repair of nerve defect with acellular nerve graft supplemented by bone marrow stromal cells in mice. *Microsurgery* 31: 388–394
57. Zuniga JR (1991) Perceived expectation, outcome, and satisfaction of microsurgical nerve repair. *J Oral Maxillofac Surg* 49(Suppl 1):77

Michael Miloro, Thomas Schlieve,
and Antonia Kolokythas

Injuries to the terminal branches of the trigeminal nerve often heal spontaneously without medical or surgical intervention. In those patients that require treatment, there are a number of complications that may arise from care of these nerve injuries. These adverse sequelae may be at the site of nerve injury, at the nerve graft donor site, or related to the side effects of medications used for neuropathic pain or dysesthesia. In addition, the failure to achieve patient expectations of outcome, or surgeon expectations of success, is also a potentially avoidable but unfortunately a common complication. This chapter will attempt to address adverse outcomes of trigeminal nerve treatment including surgical site complications, donor site complications, and complications of medical management including systemic

medications, local injections, or neuroablative techniques.

17.1 Failure to Achieve Expected Outcomes

The failure to achieve patient or surgeon expectations of outcomes is a common complication associated with trigeminal nerve injury repair irrespective of the treatment modality. Patient education with a thorough discussion of all potential outcomes, complications, and treatment options, including no treatment, is essential in avoiding or minimizing this complication and unexpected outcomes. As an example, patients with dysesthesia may be willing to accept anesthesia as an outcome of treatment rather than endure their chronic pain; however, there are patients in which anesthesia is more bothersome than the dysesthesia for which the patient initially sought treatment. In addition, depending upon the length of time of chronic neuropathic pain, neuroablative procedures may be ineffective in reducing or eliminating the pain or dysesthesia due to central cortical reorganization of the peripheral information. Patients need to be informed clearly regarding expected success rates for treatment based upon the literature as well as personal surgeon experience, and understand how success is defined since this can vary greatly in the literature, and in fact, there is little consensus on a definition of functional sensory recovery following nerve repair. Also, the definition of success may

M. Miloro, DMD, MD, FACS
T. Schlieve, DDS, MD (✉)
Department of Oral and Maxillofacial Surgery,
University of Illinois at Chicago,
801 S. Paulina St., MC 835, Chicago, IL 60612, USA
e-mail: mmiloro@uic.edu; tschlieve@gmail.com

A. Kolokythas, DDS, MS
Department of Oral and Maxillofacial Surgery,
University of Illinois at Chicago,
801 S. Paulina St., MC 835, Chicago, IL 60612, USA

Cancer Center, University of Illinois at Chicago,
801 S. Paulina Street, MC 835,
Chicago, IL 60612, USA
e-mail: ga1@uic.edu

vary from that of the patient and the treating surgeon. As a general rule, it is unlikely a patient will achieve 100 % return of objective sensation following any nerve injury requiring surgical intervention, and this should be discussed prior to beginning an irreversible treatment plan.

17.2 Surgical Site Complications

17.2.1 Mandible Fracture

The incidence of mandibular fracture specific to inferior alveolar nerve (IAN) repair is not reported in the literature; however, in third molar surgery, the incidence of mandibular fracture ranges from 0.00490 to 0.00003 %. Depending upon the location of the injury and the method of surgical access, the possibility of mandibular fracture will vary. Specifically for surgical access to the IAN [4] (Fig. 17.1), bone removal for nerve exposure may compromise the integrity of the mandible and result in a pathologic fracture following treatment of an IAN injury (Fig. 17.2).

17.2.2 Malocclusion

If the IAN exposure technique involves a sagittal split ramus osteotomy (SSRO), then a malocclusion may result following IAN repair (Fig. 17.3). In addition, a pathologic mandible fracture following IAN repair also carries the risk of malocclusion as well as nonunion or malunion.

17.2.3 Iatrogenic Nerve Injury

Injury to the IAN or lingual nerve (LN) from an SSRO access is associated with the same complications as an SSRO for orthognathic surgery. Injury to the IAN from the SSRO procedure itself is associated with >80 % immediate postoperative and 0–89.5 % long-term neurosensory impairment. Lingual nerve impairment ranges from 1 to 11.7 % long-term paresthesia. Other complications and concerns associated with the SSRO exposure technique for the IAN include failure of fixation (8 %), bad splits (inadvertent osteotomies), the

possible need for postoperative maxillomandibular fixation, and TMJ dysfunction (29 %) [7, 9].

In fact, any surgical approach to the IAN or LN places the nerves at risk for iatrogenic injury. For the LN, the exposure should begin with a lateral distobuccal release from the second molar tooth, and then, the incision should extend into the lingual gingival sulcus of the molar and premolar teeth anteriorly to the canine tooth (Fig. 17.4). While this is a similar incision for third molar surgery so it may place the long buccal nerve at risk for iatrogenic injury, it will help protect the LN from injury from surgical access.

Any of the access approaches to the IAN place the nerve at risk for iatrogenic injury. Lateral decortication may damage the nerve from direct injury from the bur, so a diamond bur or piezosurgery may be advantageous to minimize this risk. The removal of a block of the lateral cortex of the mandible to expose the IAN widely also places the IAN at risk for injury during the vertical osteotomy cuts, so these should be made only through the cortex and not extend deep into the marrow space. The osteotomy should be completed with osteotomes. Despite attempts to prevent iatrogenic IAN injury, the fact remains that the nerve is certainly at risk during surgical exposure through any of the various osteotomy techniques [4].

17.2.4 Trismus

Due to the location of the IAN and LN for exposure in the posterior region of the oral cavity, surgical access often requires dissection in or around one or more of the muscles of mastication. Trismus due to dissection of the masseter, medial pterygoid, and/or temporalis muscle is not uncommon in the immediate postoperative period. Treatment with nonsteroidal anti-inflammatory drugs (NSAIDs), massage, heat, and physical therapy may be all that is required during the healing process.

17.2.5 Inappropriate Choice of Surgery

It may be possible to perform a nerve resection with neuroorrhaphy or nerve graft when

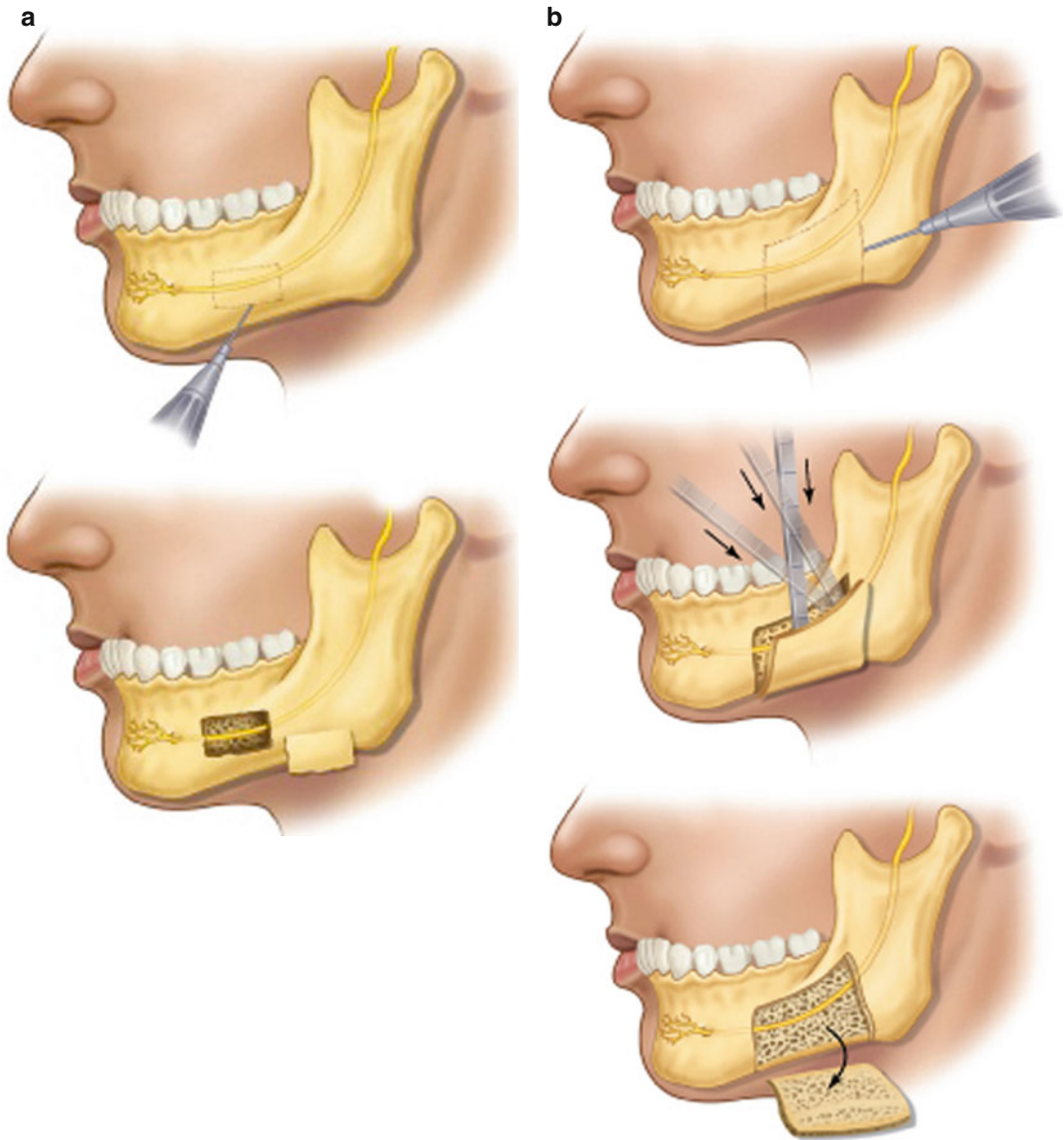


Fig. 17.1 (a) Surgical access to the IAN via lateral cortical window. The drilling procedure places the IAN at risk for iatrogenic injury. (b) Surgical access to the IAN via a

buccal corticotomy approach that may also injure the IAN iatrogenically

decompression or external neurolysis would have been adequate to allow for neural regeneration. The potential for neurosensory recovery is generally better with only decompression or external neurolysis, unless the degree of intraneuronal fibrosis is extensive and prevents axonal migration following release of the nerve from the surrounding tissues. This complication is simply the performance of

more surgery than is necessary to accomplish the intended goals. The inexperienced surgeon should consider decompression as a primary treatment option, with a tentative plan to return to the operating room for a more invasive surgical procedure (internal neurolysis or neuroma resection) if neurosensory recovery from the external neurolysis procedure is incomplete.

Fig. 17.2 Mandibular angle fracture sustained following exposure of the IAN via decortication for surgical access, stabilized with monocortical plate and screw fixation

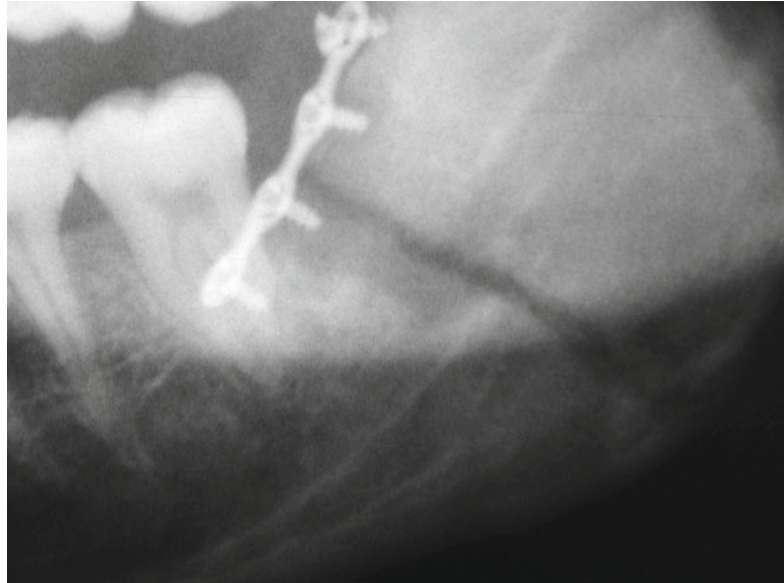
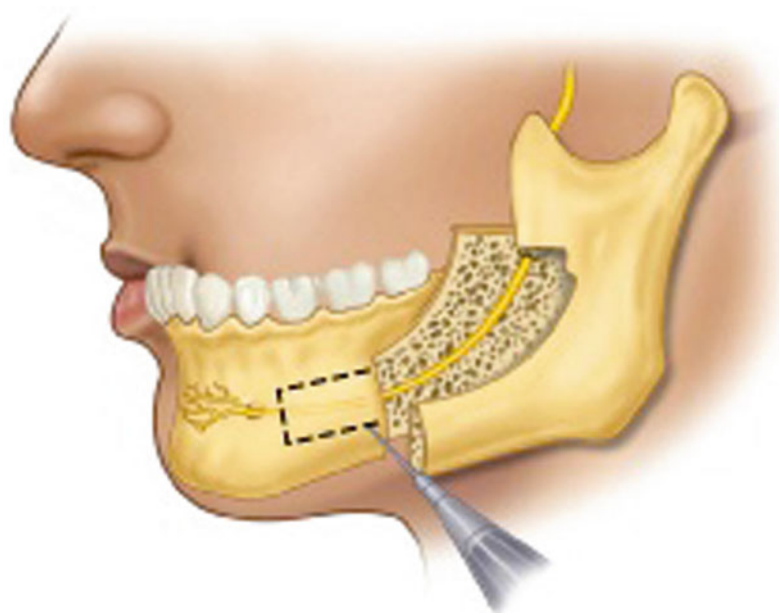


Fig. 17.3 Sagittal split ramus osteotomy approach to the IAN, with possible decortication to the mental foramen for improved IAN mobilization if necessary. This technique has the risk of iatrogenic nerve injury as well as malocclusion



17.2.6 Transcervical Approach Morbidity

The transcervical approach to the lateral cortex of the mandible for IAN repair is associated with potential additional complications beyond that of a transoral approach. A visible incision scar will always be present to a varying degree and may or may not be acceptable to the patient. In addition,

patients who have developed a neuroma from trigeminal nerve injury may be at increased risk for incisional neuropathic pain from the cutaneous nerves. Injury to the marginal mandibular branch of the facial nerve (VII) may occur due to its location in proximity to the incision and surgical dissection. The decision regarding surgical access depends upon many factors including patient anatomy, patient preference, the site of

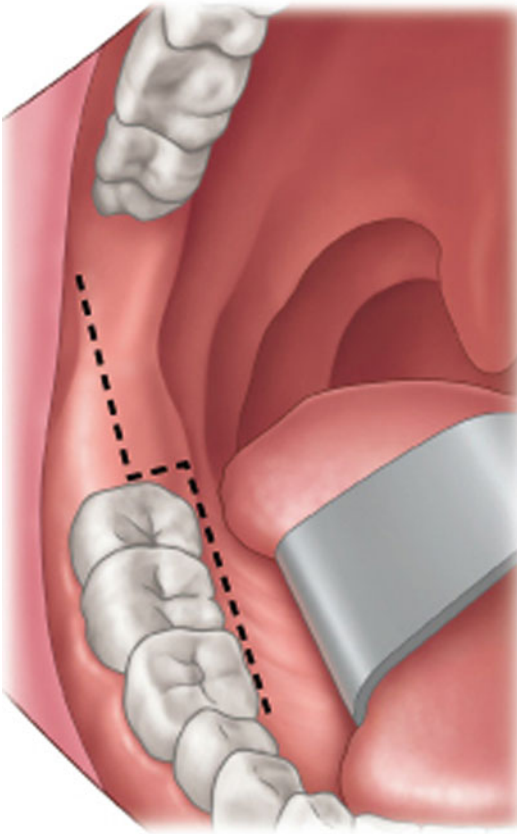


Fig. 17.4 Surgical access to the LN should include a distobuccal releasing incision extending into a lingual gingival sulcus incision to avoid iatrogenic injury to the LN

nerve injury, planned microsurgical procedures, and the surgeon's skill and experience.

17.2.7 Development of Neuropathic Pain

Surgical repair of the trigeminal nerve following injury is nothing more than a controlled injury to the affected nerve, with careful direct repair or indirect repair. As a result, the same outcomes associated with the initial injury can occur following trigeminal nerve surgery. As discussed elsewhere, failure to achieve significant sensory recovery following surgery is a possibility. The length of time from injury to repair, patient age, and degree of injury influence the likelihood of recovery. A patient with dysesthesia or neuropathic

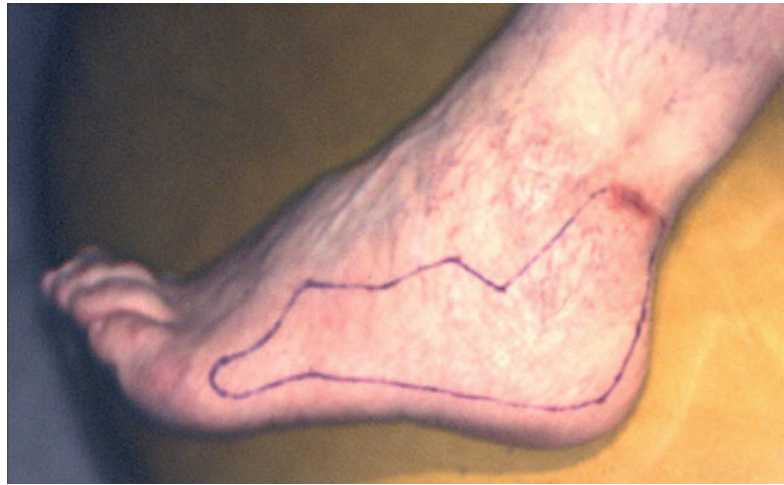pain may have already developed a central neuropathic pain syndrome prior to an attempted surgical repair, and care must be taken to recognize these patients prior to any surgery, since little to no improvement would be expected. Even complete resection of a large segment of the nerve without any repair or additional methods to prevent neuroma formation (e.g., bone graft between nerve stumps or nerve stump redirection into a muscle) can fail to improve neurosensory function in these patients. Patients without dysesthesia prior to nerve repair surgery can potentially develop painful dysesthesia or allodynia following surgery, and all patients should be made aware of this potential adverse outcome. Of note, the development of dysesthesia following trigeminal nerve repair in a patient without preexisting dysesthesia is an uncommon outcome according to the literature as well as personal experience.

17.3 Donor Site Complications

17.3.1 Sural Nerve Harvest Morbidity

The most common nerve utilized for indirect or gap repair of the trigeminal nerve is the sural nerve or, more appropriately, the medial sural cutaneous nerve. Complications associated with sural nerve graft harvest include paresthesia in the area of the sural nerve distribution, cold or pressure sensitivity, pain, cutaneous scar, and possible disturbance with physical activity involving the ankle (Fig. 17.5) [5]. In a review of outcomes following sural nerve harvest for orthopedic use, at a mean follow-up period of 2 years, there was no area of anesthesia in 50 % of the patients, with a mean area of anesthesia of 12 cm² and mean area of reduced sensation of 55 cm². In this study, 25 % of patients were dissatisfied with the appearance and esthetics of the scar [6]. Up to 20 cm of sural nerve graft was harvested by a single longitudinal incision in this series, and this is much more than commonly used for trigeminal nerve repairs. Miloro reported on subjective outcomes following sural nerve harvest specific to trigeminal nerve repair, and in 96 % of subjects, the subjective area of decreased sensation was less

Fig. 17.5 Sensory distribution of the sural nerve outlined on the lateral foot and ankle



than or equal to the size of a quarter dollar, and no subjects experienced pain or cold sensitivity at long-term follow-up. In this study, 15 % stated that there was an effect on their activities of daily living, and 85 % of patients were satisfied with the scar appearance. It must be noted that in this series of patients, one single 5–10 mm transverse incision posterior and just superior to the lateral malleolus was used to harvest nerve segments 2.5–4.0 cm in length (Fig. 17.6) [5].

It is interesting to note that in the senior author's experience patients with dysesthesia of the trigeminal nerve are more likely to develop dysesthesia following sural nerve harvest since the individual patient response to nerve injury has already shown healing with dysesthesia. It may be necessary to treat a neuroma of the sural nerve if it develops following sural nerve harvest (Fig. 17.7). It is also interesting to note that patients are not likely to develop dysesthesia of the IAN or LN following nerve repair if dysesthesia did not exist prior to the nerve repair procedure.

17.3.2 Greater Auricular Nerve Harvest Morbidity

Reports on the complications of greater auricular nerve harvest in relation to trigeminal nerve repair are sparse in the literature. The most obvious complication is permanent

neurosensory disturbance in the area of innervation (Fig. 17.8). As a branch of the cervical plexus, the greater auricular nerve provides sensory innervation for the skin overlying the parotid gland, mastoid process, and lower third of the ear. Following harvest, impaired sensation to this area is expected and may or may not be an acceptable trade-off for the patient with impaired sensation in another region of the face or tongue due to trigeminal nerve injury. Injury to the spinal accessory nerve, although rare, is an additional possible complication of greater auricular nerve harvest. A highly visible surgical scar along the posterior lateral neck and incisional neuropathic pain can also result from this approach [3].

17.4 Medical Management Complications

Pharmacologic treatment of trigeminal nerve injury with dysesthesia or allodynia or neuropathic pain and trigeminal neuralgia should be managed in consultation with an individual experienced in the treatment of facial pain, such as a neurologist or facial pain specialist or anesthesiologist. Numerous medications can be utilized in varying doses and combinations to improve or ameliorate patient symptoms. Several medications for neuropathic pain and their potential side effects can be found in Table 17.1.

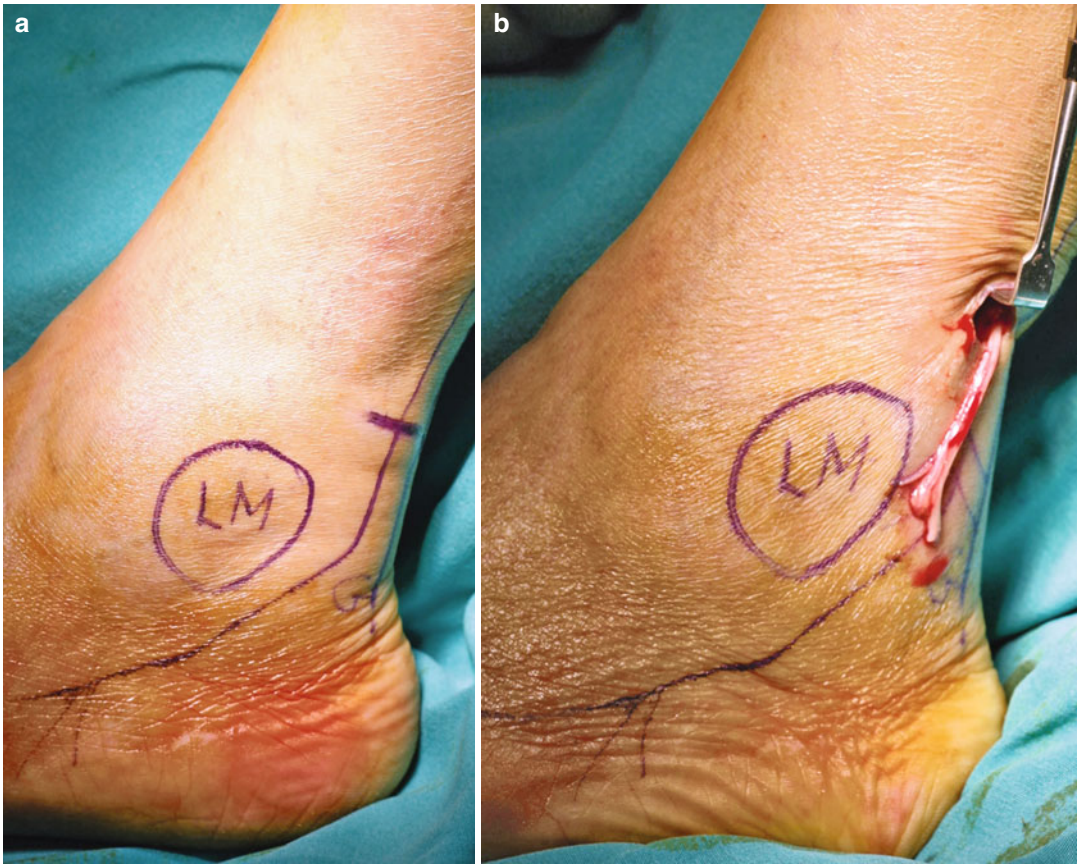


Fig. 17.6 (a) Landmarks for left sural nerve graft harvest. The 5–7 mm transverse incision is made between the lateral malleolus (*LM*) and the gastrocnemius tendon (*G*) just cephalad to the lateral malleolus to avoid the terminal branching of the sural nerve. (b) Harvest of the left sural

nerve (approximately 4–5 cm through the 5–7 mm incision) showing the distal branching; this area of the nerve is not useful for trigeminal nerve grafting due to the large size mismatch

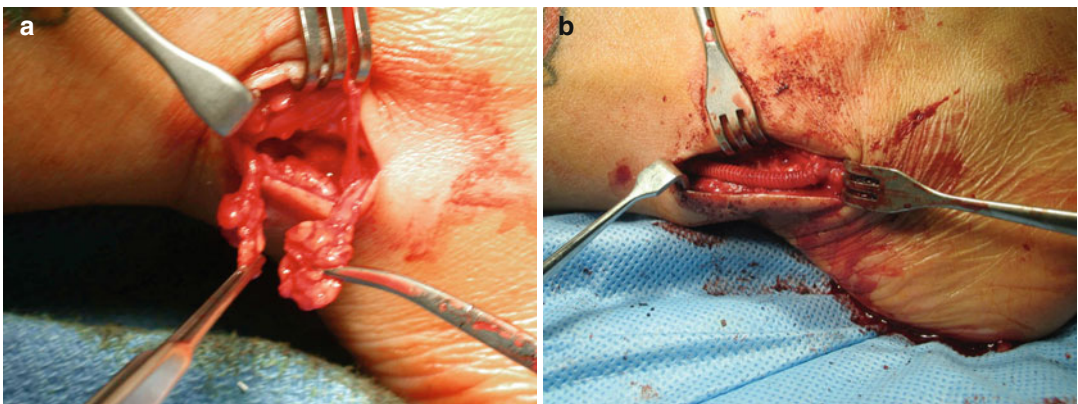
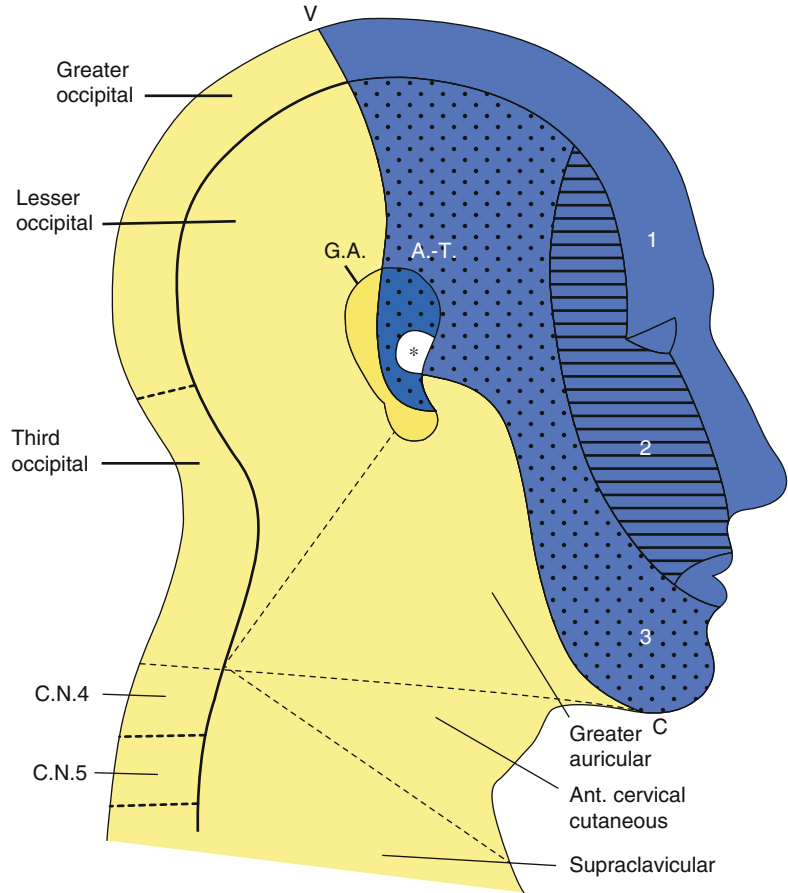


Fig. 17.7 (a) Sural nerve amputation (or stump) neuromas of the proximal and distal nerve ends several months following sural nerve harvest. (b) Following excision of

sural nerve amputation neuromas, the nerve defect is repaired using a polyglycolic acid conduit (Neurotube, Synovis Life Technologies Inc, St. Paul, MN)

Fig. 17.8 Cutaneous sensory distribution of the greater auricular nerve including the skin in the cervical region, angle of the mandible, and preauricular and postauricular regions including the posterior ear extending to the helix. Labels 1,2,3 represent the distribution of the ophthalmic, maxillary and mandibular branches of trigeminal nerve respectively



There are a variety of medications that can be used for the patient with trigeminal nerve dysesthesia including topical anesthetic agents, neuropeptides (capsaicin cream), NSAIDs, clonidine, steroids, antidepressants, narcotics, anticonvulsants (carbamazepine), tricyclic antidepressants (TCA), muscle relaxants (baclofen, flexeril), benzodiazepines, and antisympathetic agents. Each of these medications has inherent side effects that may be significant and may lead to patient non-compliance and drug discontinuation.

17.5 Other Treatment Complications

Although not commonly performed for trigeminal nerve injury and often not performed by the oral and maxillofacial surgeon, injection

of medicaments, microvascular decompression, radiofrequency rhizotomy procedures, and gamma knife surgery can be utilized in selected patients for treatment of dysesthesia or neuropathic pain as well as trigeminal neuralgia management.

Glycerol or alcohol injections are associated with a 0.73–3 % rate of complications, including swelling, pain, infection, skin or mucosal irritation or erythema or necrosis, trismus, rare allergic reactions, and dysesthesia due to further neural damage from tissue damage from the caustic solutions used. In addition, these injections are not a permanent solution and must be repeated frequently since there is a high recurrence rate of pain [1, 8].

Microvascular decompression (MVD, Janetta procedure) is a common procedure used for debilitating trigeminal neuralgia and involves

Table 17.1 Neuropathic pain medications and side effects

| Drug class | Adverse effects |
|--|--|
| Tricyclic antidepressants Amitriptyline Nortriptyline Desipramine | Anticholinergic effects |
| Anticonvulsants Clonazepam Gabapentin Pregabalin Tegretol | Sedation, dizziness, lower extremity edema, hepatotoxicity, and agranulocytosis (Tegretol) |
| Corticosteroids Dexamethasone Prednisone | Psychosis, delirium, dyspepsia |
| Local anesthetics Mexiletine Lidocaine | Lightheadedness, tremor, paresthesias, arrhythmias |
| N-methyl-D-aspartate receptor antagonists Ketamine | Confusion, bizarre dreams |
| Alpha-2 adrenergic agonists Clonidine | Hypotension, rebound hypertension |
| Antispasmodics Baclofen | Muscle weakness, cognitive changes |

exposure of the trigeminal nerve at the base of the skull (via craniotomy), and insertion of a Teflon pad between the arteries thought to be compressing the nerve. Complications of MVD include neck pain and stiffness, intracranial bleeding and vascular injury (stroke), infection, cerebrospinal fluid (CSF) leakage, damage to the VIII cranial nerve with hearing loss (since the fifth, seventh, and eighth cranial nerves are typically dissected), and facial paralysis (VII nerve injury), and overall, the procedure is associated with a 10 % mortality rate.

The technique of gamma knife radiosurgery is a noninvasive treatment modality that targets focused radiation beams at the trigeminal nerve at the brainstem. Gamma knife treatment has a reasonable success rate in resolving neuropathic symptoms, but it takes several weeks to months to have an effect of the treatment. Gamma knife therapy is associated with typical side effects of radiation as well as headaches, nausea, dizziness, fatigue, and facial numbness or tingling.

With radiofrequency rhizotomy thermocoagulation, electrode is inserted through the cheek to

access the trigeminal nerve, and heat is used to damage the nerve and, like gamma knife surgery, to selectively injure the nerve fibers responsible for pain and temperature sensation (A-delta and C fibers). The reported complications of radiofrequency thermal neurolysis include limited cheek pain, anesthesia dolorosa, motor paresis, and ocular problems such as corneal anesthesia. In addition, at one year there is a 68 % recurrence of pain with radiofrequency treatment [2].

References

1. Fardy MJ et al (1994) Complications associated with peripheral alcohol injections in the management of trigeminal neuralgia. *Br J Oral Maxillofac Surg* 32: 387–391
2. Gregg JM, Small EW (1986) Surgical management of trigeminal pain with radiofrequency lesions of peripheral nerves. *J Oral Maxillofac Surg* 44:122
3. Günther M, Danckwardt-Lillieström N, Gudjonsson O, Nyberg G, Kinnefors A, Rask-Andersen H, Ekvall L (2010) Surgical treatment of patients with facial neuromas – a report of 26 consecutive operations. *Otol Neurotol* 31(9):1493–1497

4. Miloro M (1995) Surgical access for inferior alveolar nerve repair. *J Oral Maxillofac Surg* 53:1224–1225
5. Miloro M, Stoner JA (2005) Subjective outcomes following sural nerve harvest. *J Oral Maxillofac Surg* 63(8):1150–1154
6. Ng SS, Kwan MK, Ahmad TS (2006) Quantitative and qualitative evaluation of sural nerve graft donor site. *Med J Malaysia* 61(Suppl B):13–17
7. Panula K (2001) Incidence of complications & problems related to orthognathic surgery. 655 pts. *J Oral Maxillofac Surg* 59:1128, Finland
8. Shah SA, Khan MN, Shah SF, Ghafoor A, Khattak A (2011) Is peripheral alcohol injection of value in the treatment of trigeminal neuralgia? An analysis of 100 cases. *Int J Oral Maxillofac Surg* 40(4):388–392, Epub 2010 Dec 17
9. Zuniga J (1995) Nerve injuries: considerations in orthognathic surgery. *OMFS Knowl Update* 1(Part II):43

Greg K. Essick, George Blakey III, and Ceib Phillips

18.1 Introduction

Every year in the USA millions of people suffer from somatosensory deficits caused by acute injury to the peripheral nervous system (PNS). Because of the broad scope of the specialty with procedures ranging from trauma to dentoalveolar and orthognathic surgery, oral and maxillofacial surgeons will likely encounter patients who experience such an injury. These injuries result in symptoms that range from a loss of sensation (hypoesthesia), to nonpainful tingling sensations (paresthesia), to increased sensitivity to touch or pressure with or without numbness or discomfort (dysesthesia), to peripheral neuropathic pain. The symptoms of somatosensory injury are not constant over time and may include only an abnormal reaction to a stimulus and/or spontaneous

pain in the affected area [60, 83]. Treatment options for individuals with persistent altered sensation following peripheral nerve injury remain limited. Microsurgical nerve decompression and repair can be beneficial in some patients but is costly and not indicated for all patients who have persistent, bothersome altered sensation. Recently, two noninvasive therapies have been identified that improve patients' perception of residual altered sensation (sensory retraining) or accelerate functional recovery (vitamin B12 administration). Evidence supporting the use of these therapies in patients with trigeminal nerve injuries will be presented in this chapter.

18.2 Orthognathic Surgery: An Experimental Model of Posttraumatic Nerve Injury

Evaluating the efficacy of any putative therapy for improving the extent or rate of recovery from acute trigeminal nerve injury is dependent upon the identification of a suitable clinical model. Ideally, the subjects would be otherwise healthy and available for neurosensory assessment before the injury. In contrast to other possible human models of nerve injury from repetitive motion, accidental or iatrogenic trauma, patients scheduled to have

G.K. Essick, DDS, PhD (✉)
Department of Prosthodontics,
School of Dentistry CB# 7450,
Regional Center for Neurosensory Disorders,
University of North Carolina
at Chapel Hill, Chapel Hill, NC 27599-7450, USA
e-mail: greg_essick@dentistry.unc.edu

G. Blakey III, DDS
Department of Oral and Maxillofacial Surgery,
University of North Carolina at Chapel Hill,
Chapel Hill, NC 27599-7450, USA
e-mail: blakeyg@dentistry.unc.edu

C. Phillips, MPH, PhD
Department of Orthodontics,
University of North Carolina at Chapel Hill,
Chapel Hill, NC 27599-7450, USA
e-mail: ceib_phillips@dentistry.unc.edu

The projects were supported in part by the Oral and Maxillofacial Surgery Foundation, an investigator-initiated application to QoI Medical, NIDCR R01 005215, and UNC Clinical Translational Research Center #2572.

orthognathic surgery in conjunction with orthodontics for the correction of a severe skeletal disharmony or severe malocclusion are healthy without medical comorbidities before surgery and have a lengthy course of treatment over several years. This allows time for “pre-injury” testing without delaying treatment and for “post-injury” assessments with a decreased likelihood of loss to follow-up because of ongoing treatment relationship with an orthodontist. Patients having a mandibular osteotomy (sagittal split osteotomy) alone or in conjunction with a maxillary osteotomy predictably have an injury to the inferior alveolar nerve (IAN) as evidenced by (1) abnormal electrophysiological testing (nerve conduction or evoked potential studies) [34, 40, 57, 59, 80] and (2) abnormal neurosensory testing (e.g., abnormal tactile detection or thermal thresholds) [21–23, 39, 82]. In some patients, axonal damage is severe, requiring reconnection of axonal sprouts to target tissues, reconstitution of axonal diameter, and remyelination of myelinated afferents [40, 58]. As such, the iatrogenic injury of the IAN activates neural recovery pathways common to all peripheral nerve injury [58, 88]. For the majority of patients, altered sensation, documented by sensory testing and patient report, persists for 1–2 years after surgery [23, 40, 57, 62, 83]. The characteristics of the neural response to the injury and the nerve recovery pattern associated with mandibular osteotomy provide an excellent experimental clinical model for the assessment of the efficacy of treatments for traumatic/iatrogenic peripheral sensory nerve injury.

18.3 Biological Response to Nerve Injury

Any novel therapy targeted on improving sensory function after injury should enhance the natural course of recovery of a nerve injury. Following peripheral nerve injury, a complex of cellular and molecular signaling alterations is immediately initiated, and the quality of functional nerve recovery tightly correlates to the molecular responses that attempt to repair and restore the nerve to its pre-injury state. After resolution of

inflammation and edema, the residual sensory deficits can be attributed to anatomical or functional changes within the peripheral nerve and the often underappreciated accompanying changes induced in the central nervous system by the nerve injury [4, 18, 35]. Several temporally overlapping phases may be used to describe this biological response: the fate of the nerve cell body which is located central to the site of the injury; the restoration of any loss in the continuity of the proximal and distal segments of the axon including axonal diameter and myelination; and remodeling in the central connections of the nerve, i.e., the cortical representation of the tissues innervated by the damaged axon [58].

18.3.1 Peripheral Neural Response to Nerve Injury

Virtually all of the existing recovery data is derived from transectional or crush injuries in animal models. In these types of injuries, axonal regrowth, reconstitution, and remyelination are essential. It is reasonable to assume that non-transecting nerve injuries in patients activate similar pathways [3] and that even without transection, axonal damage can require that axonal sprouts reconnect to target tissues followed by remyelination of nerve afferents [40, 58]. Once injury occurs in the clinical setting, it can be assumed that the surviving cell body actively intensifies its transcriptional machinery heightening the synthesis of structural proteins for axonal repair and regeneration followed over time by electrical conduction from the tissues and restoration of nerve function [1, 8, 33, 36, 52].

18.3.2 Assessment of Nerve Response

Sensory testing methods are derived from the field of psychophysics and are generally used to quantitatively estimate the extent of nerve injury by the patient’s responses to stimuli applied to the skin or mucosa. Contact detection and two-point discrimination are characterized by an unequivocally correct or incorrect response to each stimulus. In

contrast, for tasks such as two-point perception and thermal perception, no correct answer exists; the response is dependent on the patient's cognitive response to the stimulus which may vary even for noninjured nerves. The contact (touch) detection threshold (CDT) assesses the functional integrity of the large diameter A β mechanoreceptors in the nerve trunk and has been shown to be one of the most sensitive and useful, noninvasive indicators of trigeminal nerve injury [10, 11, 19, 82]. Estimates of the CDT responses obtained postsurgery correlate significantly with objectively assessed nerve injury during surgery [81] and with patient report of altered sensation for up to 1 year after surgery [21, 82].

Thermal perception tests are used to assess the functional integrity of small diameter A δ myelinated thermoreceptors and unmyelinated C-fiber thermoreceptors in the nerve trunk [19, 20]. The warmth perception threshold is thought to be the most sensitive of the thermal indicators of nerve injury. Repair of the small diameter fibers, if it occurs, takes longer than the large diameter fibers, and the warmth perception measure will remain abnormal longer during the recovery process than other threshold measures of sensory function [10, 19, 81, 85]. A small, but significant, percentage of patients after orthognathic surgery develop increased sensitivity (allodynia) to cold, detected clinically by a pain response at a temperature higher than temperatures that usually are identified as "cold" [18].

18.3.3 Central Neural Response to Nerve Injury

Although not as easy to detect clinically, almost all injury-associated alterations in the peripheral nerve induce changes in neural substrates at both subcortical and cortical levels within the CNS [46, 88]. The underlying mechanisms of this central plasticity are largely unknown, but a heightened excitability is often observed in cortical regions that are remodeling in response to nerve injury [58]. In a sense this neuroplasticity reflects competition between afferent inputs for connections in the sensory cortex. Microelectrodes implanted in the cortex and the subcortical relay

stations along the sensory path from the face in rats showed the cortex responding to new input detected from other facial areas within minutes of the deactivation of the usual sensory input following a peripheral nerve injury [24].

This cortical reorganization is reflected in altered symptoms experienced by individuals after sensory nerve injuries. In the normal state, stimulation of the face or lips activates the sensory receptors and a profile of neural impulses follows. These impulses impact upon the sensory cortex and are associated with previous memory of similar experiences. After a nerve injury, the profile differs: The same contact (the same stimulus) elicits a different, altered profile of neural impulses [14].

18.3.4 Assessment of Cognitive Changes

If complete presurgery nerve function is unlikely after nerve injury or if the patient is bothered or concerned by the altered sensation, then an important clinical consideration becomes the patient's accommodation to the altered sensitivity. In this case, stimulus perception measures such as two-point perception or patient self-report of recovery may be preferred to a battery of more objective measures. Two-point perception is the subject's interpretation of two versus one point of contact and is heavily influenced by cognitive factors as well as subjects' discriminative capacities [85, 86]. And patient self-report has been shown to be quite reliable. Given the same instructions by multiple examiners, patients provided identical responses when requested to describe alterations that occur spontaneously or were elicited by touch [6, 7, 25, 53, 61].

18.4 Sensory Retraining Alters the Central Neural Response to Nerve Injury

Sensory retraining (also referred to as sensory reeducation) is a cognitive behavioral therapy technique that helps the patient with a nerve injury to interpret the neural impulses reaching

his conscious level after the injured area has been stimulated [14]. The repetitive neural input from sensory retraining exercises is thought to produce plasticity changes in the somatosensory cortex via the same mechanisms as those invoked by altered input from the original nerve damage. This central reorganization gained by retraining over time can compensate, in part, for some of the impairments associated with nerve injury [12, 15, 17, 31, 54, 87, 93].

Animal studies have shown that behavioral sensory training alters the central neural representation of the involved skin sites, alters the response of individual somatosensory cortical cells to tactile stimulation, and increases synapse to neuron ratios and improves behavioral function after induced brain damage more than simple repetitive exercise [28, 42, 44, 45, 68–70]. Neuroimaging studies indicate that similar changes occur in human subjects following sensory denervation and sensory training [50]. Sensory experience or retraining results in somatosensory cortical maps that exhibit higher sensory resolution and greater topographical organization which facilitate better interpretation of sensory inputs. In contrast to the central neural changes, sensory retraining does not alter the course of nerve regeneration or the absolute thresholds to touch [5, 22, 23, 45], but does improve both the patient’s cognitive and

adaptive response to stimulation of the affected skin region [13, 14, 61–63, 72].

18.5 Sensory Retraining After Injuries to the Hand

Sensory retraining as a rehabilitative approach has been used extensively over the past several decades for patients who have had nerve injuries affecting the hand. The emphasis of the sensory retraining exercises for hand injury and stroke patients has been to teach the patient to interpret the percepts of objects manipulated by the fingers in a meaningful and functional way [14, 55, 77, 92, 94]. Hand injury patients learn to recognize and to discriminate the shapes of small objects (various buttons, coins, and keys). Patients gain the ability to button their own shirt and to identify shapes without visual cues (e.g., a key vs. a coin). Although touch perceptions produced by the objects remain abnormal after retraining, patients become more comfortable with, and accepting of, the situation since the clinical situation is no longer functionally disabling.

Historically, in the early phase of sensory retraining (Table 18.1), the intent is to reeducate for constant and moving touch perceptions. That is, a patient must relearn what constant touch feels like compared to moving touch and where

Table 18.1 General concepts of sensory reeducation training

| | |
|--------------------------|---|
| Two phases | Early phase: constant vs. moving touch Late phase: directionality |
| Frequency | Three or four times a day for a couple of minutes |
| General strategies | 1. Quiet surroundings 2. Concentration is important 3. Use stimulus (cloth, cosmetic brush, cotton swab), not finger 4. Using a finger would create two sets of sensory information for the patient which would confuse the already distorted sensory picture |
| Components of retraining | 1. Observation of touch/movement. For the face, it’s critical to use visual feedback via a mirror 2. Concentration on perception of touch/movement with eyes closed in order to combine the mental with the visual picture 3. Repeat observation for visual confirmation of touch/movement 4. Verbalize the touch/movement being performed and what it feels like 5. Incorporate unaffected areas using the same procedure so that the sensation on the two sides may be compared |

Adapted from Phillips et al. [64]

on the skin the touch is actually occurring. In the early phase of retraining, a greater stimulus intensity may be necessary for the patient to differentiate constant from moving touch, but the intensity should never be so great as to evoke pain. If hyperesthesia or dysesthesia occurs, desensitization with gentle stroking using different textures or gentle tapping is recommended [9, 38, 55, 91]. In the late phase of retraining (Table 18.1), the intent is to reeducate for the directionality of movement of the stimulus. For example, is the movement of an external object across the skin from left to right or right to left?

The process of sensory retraining can be thought of as similar to the brain learning a new language with progressive, increasing phases of difficulty. Initially when learning a language, use of words is slow, challenging, and error prone. With time and practice, language fluency may be acquired. Unfortunately, no research has been conducted to determine the optimal number of phases or the exercises required to obtain the maximum benefit to patients with orofacial nerve injuries. The potential to acquire the “second language” by sensory retraining does decrease with age [51, 62, 63], varies with the verbal learning capacity and visuospatial cognitive skills of the patient, and depends on motivation and positive reinforcement [50].

18.6 Sensory Retraining After Injuries to the Orofacial Region

18.6.1 Initial Clinical Observations

The question of whether sensory retraining exercises could be used effectively with patients with altered orofacial sensation was first raised in the 1992 literature by Gregg [32]. In 2001, Meyer and Rath presented a retrospective review of 372 patients who had had a microsurgical repair for a nerve injury after 1981 and for whom at least an 18-month postsurgical follow-up was available. A nonrandom sample of patients had been given facial sensory exercise instructions that incorporated some of the early-stage components of sensory retraining with the expectation that sensory

retraining would help patients with altered orofacial sensation following nerve injury by (1) improving patients’ ability to interpret lip/chin sensations and movements, (2) improving perioral motor function subjectively and objectively, and (3) lessening the objectionable impression of numb/paresthetic sensations in the lip and chin by decreasing the subjective differences between affected and unaffected skin areas [55]. The percentage of patients who achieved a useful sensory recovery on the Medical Research Council Scale (MRCs), a clinical assessment, did not differ for those who did and did not receive instructions regarding facial sensory exercises. However, those patients who received instructions reached their final level of sensory recovery much sooner, on average 3 months earlier [55].

18.6.2 Findings from a Randomized Clinical Trial

In order to assess the efficacy of sensory retraining for facial altered sensation, a multicenter double-blind parallel two-arm stratified block randomized clinical trial (RCT) was conducted at an academic center and a community-based center with enrollment of 191 subjects [61]. The intent was to assess whether the magnitude and duration of patient-reported burden from altered sensation was lessened when facial sensory retraining exercises were performed in conjunction with standard opening exercises than when the opening exercises were performed alone. The subjects were patients with a developmental disharmony who were scheduled for bilateral sagittal split osteotomy with or without maxillary osteotomy.

The emphasis in the RCT on patient-report was motivated by two factors: (1) the assumption that sensory retraining would not affect actual nerve recovery including objective sensory testing measures of nerve function and (2) the recognition of the difference in function of the sensory innervations to the facial as compared to skin in other anatomic areas like the fingers. The terminal distribution of the inferior alveolar nerve, i.e., the mental nerve, innervates skin functionally

Table 18.2 Synopsis of instructions for sensory reeducation training

| Visit | Sensory retraining exercises |
|----------|---|
| 1 week | Alternate simple touch and stroke with cosmetic brush (motion training) Feedback from mirror Visualization with eyes closed |
| 1 month | Alternate up/down and side/side strokes (orientation training) Feedback from mirror Visualization with eyes closed |
| 3 months | Alternate up → down and down → up strokes (directionality training) Feedback from mirror Visualization with eyes closed |

Adapted from Phillips et al. [61]

more like the back of the hand (radial nerve) than the palm side of the hand (median and ulnar nerves) [16, 84]. Thus, the receptors in the skin of the hairy lower lip/chin of the face deform in response to movements during function, and as such, the evoked neural discharge serves a proprioceptive role including a conscious awareness of facial expressions [16, 30].

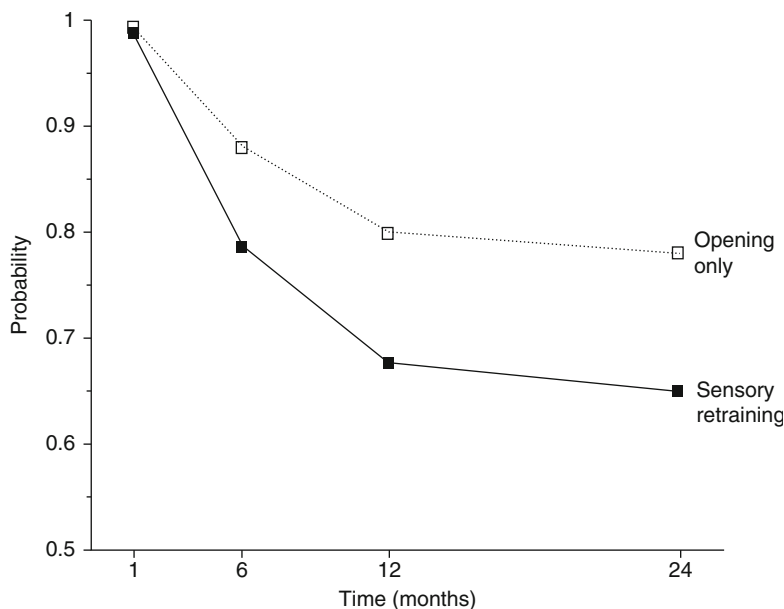
The sensory retraining protocol in the RCT had three time-dependent levels of instructions that were given to patients at 1 week, 1 month (4–6 weeks), and 3 months after surgery. The time points were selected based on their use in clinical studies of the impact of sensory reeducation in patients with an injured median or ulnar nerve [94] and in clinical studies of sensory impairment in patients following orthognathic surgery [29, 48, 85, 96]. The three levels of sensory retraining were designed to increasingly challenge patients congruent with the early and late phases of sensory education used for the hand: constant versus moving touch, orientation of moving touch, and direction of moving touch (Table 18.2). (Three videos demonstrating each exercise at each level are available online at [http://www.oralmaxsurgeryatlas.theclinics.com/article/S1061-3315\(10\)00065-X/abstract](http://www.oralmaxsurgeryatlas.theclinics.com/article/S1061-3315(10)00065-X/abstract), March 2011 issue. The videos were produced by Video Services of the Center for Instructional Technology at the University of North Carolina. Written instructions provided to subjects and copies of the instructional

tapes are available from the corresponding author upon request.)

Consistent with the anecdotal reports, the patients in this clinical trial who received the sensory retraining exercise instruction were less likely to report a problem related to unusual feelings on the face, loss of lip sensitivity, or numbness at 3 and 6 months after surgery than subjects who received standard opening exercises only [61]. At 6 months, subjects in the opening-only exercise group were almost twice as likely as those in the sensory retraining group to report a problem with altered sensation [61]. In addition to patient-reported outcomes, two-point perception, two-point discrimination, and contact detection thresholds were measured as secondary outcomes. The sensory retraining patients were more adept at discerning touch, indicating accommodation, even though there was no improvement in the ability to discriminate two distinct points of contact from one or to detect the presence of tactile stimulation (nerve recovery) [22].

The positive effect of the sensory retraining persisted even after the exercise protocol was completed (Fig. 18.1). Although the likelihood that a subject would report altered sensation steadily decreased in both groups over a 2-year follow-up protocol, the difference between the groups was relatively constant. Even at 2 years after surgery, patients who received only the opening exercises were about two times more likely to report an altered sensation than patients who used the sensory retraining exercises after surgery (Fig. 18.1) [62]. And patients in the sensory retraining group were less likely to report interference in daily life activities from numbness or loss of lip sensitivity (Fig. 18.2a, b) [63]. This difference between the two exercise groups appears to be related to the difference in how the “retrained” individual experienced or interpreted tactile stimuli rather than any difference in nerve recovery or repair [22, 23]. Two years after surgery, patients who received sensory training during the initial 3-month period still exhibited greater sensitivity on tests of two-point perception, i.e., sensory retraining subjects reported perceiving two-point contact from a one-point

Fig. 18.1 Estimated likelihood of the presence of altered sensations for subjects who did and did not receive sensory retraining exercises after controlling for psychological distress and age (Data from Phillips et al. [62])



contact at a shorter separation between the points (Fig. 18.3) [23].

The results at 6 months and the longer-term analyses at 24 months suggest that for patients who experience an acute nerve injury, as is highly likely during a mandibular osteotomy, the simple, noninvasive sensory retraining facial exercises, which require only an inexpensive cosmetic brush and a mirror, are an effective therapy to promote accommodation to a sensory deficit on the face. Perhaps the desired outcome for “retrained” patients was best stated by Callahan, “If sensory re-education results in a person’s increased ability to better enjoy the tactile sensations of everyday living, then reeducation has been meaningful and successful” [9].

For orofacial sensory retraining, an important component of the retraining is the visual feedback provided by performing the exercises in front of a mirror. This elicits two different sensory events, the sensation of the brush on the facial skin and the sight of the brush on the face. Recent experimental studies have shown that viewing a body surface can directly enhance tactile perception and detection [27, 79] even when the “touch” is not physical but a mirrored reflection [71, 74]. The frequency of the repetitiveness with which

the exercises are performed each day is much more important than the length of time spent at any given point in time. It may be that encouraging patients to perform orofacial sensory retraining exercises with a small handheld mirror for a short period of time, perhaps 1–2 min, four to six times per day would be more effective than a longer time in a less frequent protocol.

18.7 Vitamin B12 Alters the Peripheral Neural Response to Nerve Injury

Vitamin B12 is a potential pharmacological treatment for the restoration of nerve function after acute peripheral nerve injury. The neurodegenerative effects of vitamin B12 deficiency and the resolution of these effects with vitamin B12 supplementation are well documented [35, 76]. Vitamin B12 supplementation has been suggested as an ameliorative treatment for conditions such as amyotrophic lateral sclerosis, diabetic neuropathy, Bell’s palsy, carpal tunnel syndrome, and dialysis-induced neuropathy [37, 41, 47, 49, 73, 75, 78, 95]. These studies involving patients with chronic

Fig. 18.2 Estimated likelihood of a subject reporting no problem or interference in daily life after controlling for psychological distress and age for subjects who did and did not receive sensory retraining exercises. **(a)** No problem associated with numbness. **(b)** No problem associated with loss of lip sensitivity (Data from Phillips et al. [63])

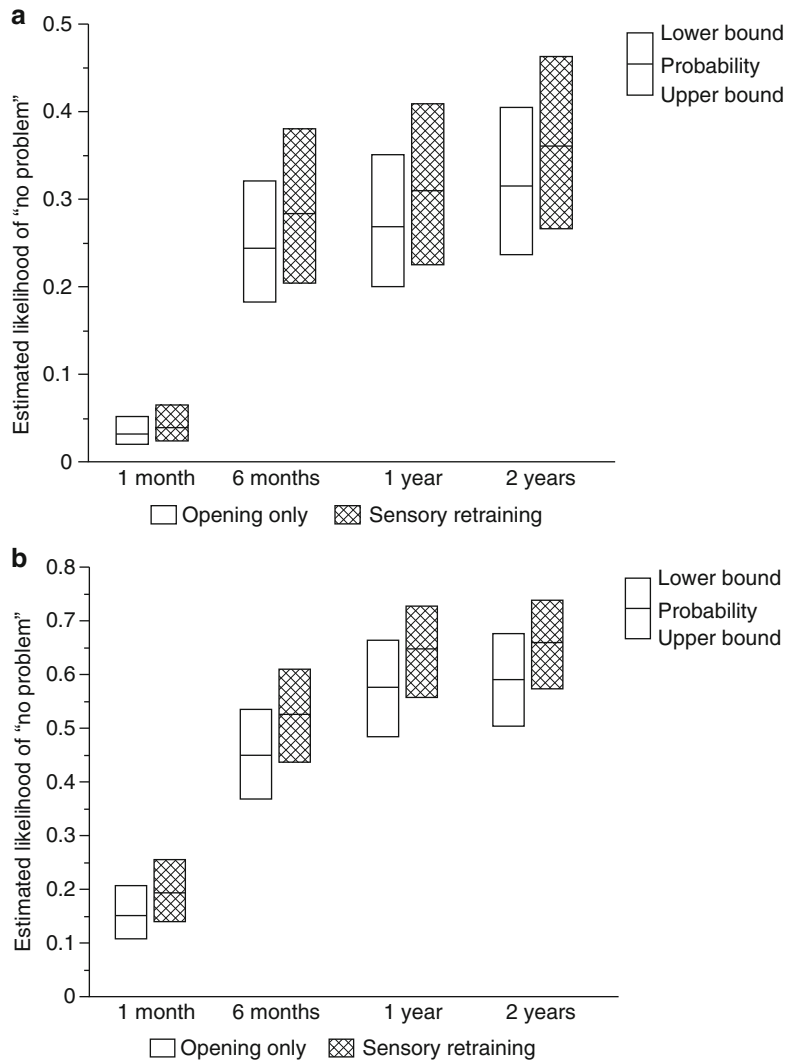
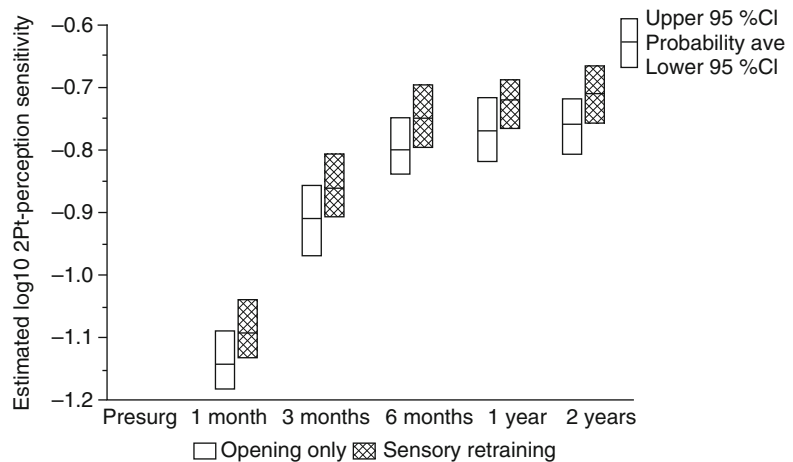


Fig. 18.3 Estimates of the adjusted mean sensitivity in two-point perception for subjects who did and did not receive sensory retraining exercises. The higher two-point perception sensitivity, on average, for the sensory retraining (SR) group indicates that this group was able to report two distinct points at separations closer to that reported before surgery than the opening-only group (Data from Essick et al. [23])



conditions associated with accompanying peripheral nerve damage indicate that vitamin B12 supplementation to therapeutic levels improves nerve function with a decrease in pain.

In vivo studies in non-B12-deficient animal models have shown that vitamin B12 treatment after acute peripheral nerve injury increases the production of neurotrophic factors that impede nerve degeneration and promotes nerve regeneration [43, 56, 89, 90]. In addition to the experimental animal peripheral nerve injury models [43, 56, 89, 90], an open randomized control trial reported shorter recovery times from Bell's palsy with intramuscular methylcobalamin or methylcobalamin plus prednisone (ca 2 weeks) than with prednisone alone (ca 10 weeks) [41]. However, clinical studies to assess the effect of vitamin B12 supplementation on sensory nerve recovery after acute peripheral nerve injury in otherwise healthy human subjects are limited [65, 66].

18.8 Vitamin B12 After Injuries to the Orofacial Region

Unlike sensory retraining, vitamin B12 was expected to have an effect on the restoration of peripheral nerve function. For this reason, contact detection and thermal threshold were used as objective primary outcomes in our two exploratory B12 studies.

18.8.1 Intranasal Vitamin B12 Is Well Tolerated

Initially, we demonstrated the tolerability of weekly intranasal vitamin B12 spray applications beginning 2–3 weeks before surgery and continuing for 6 months after surgery in healthy, non-B12-deficient patients having orthognathic surgery with nasal intubation. The total serum cyanocobalamin levels reached therapeutic levels (above normal range) in the majority of patients by 1 month after surgery. A particularly encouraging finding of the tolerability study was that those patients who exhibited higher increases in B12 serum levels from baseline were less

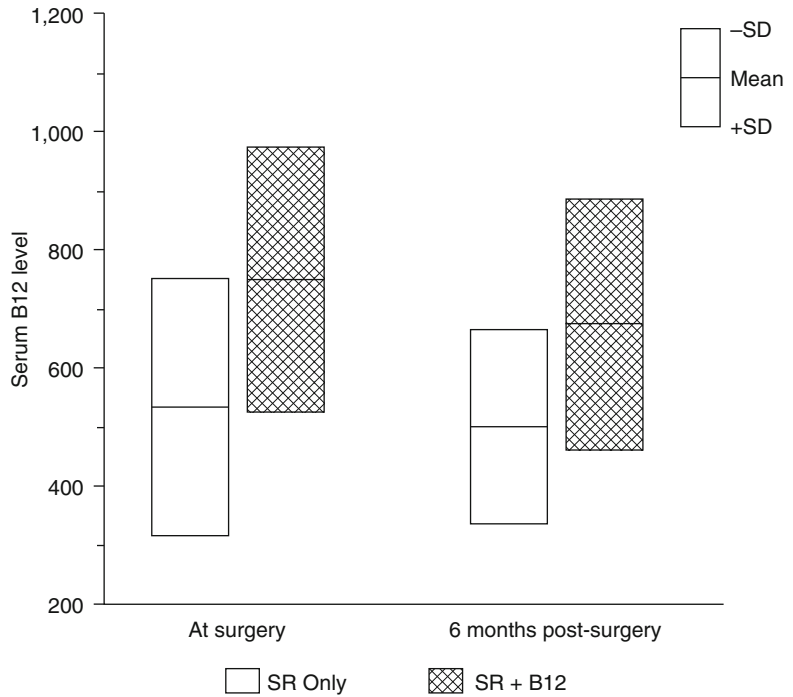
impaired in touch detection (a large diameter nerve fiber function) than those patients who exhibited lower increases in B12 levels [65].

18.8.2 Intranasal Vitamin B12 Alters the Course of Sensory Impairment

Subsequently, pilot data on the effect of B12 on small diameter (thermal thresholds) as well as large diameter nerve fiber functions were obtained in an exploratory randomized clinical trial comparing the sensory impairment following orthognathic surgery of intranasal B12 spray administered in conjunction with sensory retraining exercises compared to sensory retraining alone. Sensory retraining does not alter the course of nerve regeneration or the absolute thresholds to touch at the injured nerve site [5, 22, 23, 45], but only improves the patient's cognitive and adaptive response to stimulation of the affected skin region [14, 61, 62, 64]. For these reasons, we reasoned that the combination of vitamin B12 and sensory retraining might provide a noninvasive means for patients to achieve optimal recovery of sensory function following trigeminal nerve injury.

Although only a small trial, a parallel randomized block design was used, and the two treatment groups (vitamin B12 with sensory retraining vs. sensory retraining only) were quite similar at enrollment with respect to sex, type of surgery, and average ages at the time of surgery. The average threshold values of the two groups did not differ significantly for any of the threshold measures before surgery, i.e., before the initiation of any therapy [66]. At the time of surgery (approximately 3 weeks after initiation of the intranasal B12 spray in the SR+B12 group) and at 6 months after surgery, the average serum B12 levels were significantly different for the two groups, while the average change in serum B12 levels from surgery to 6 months was not statistically significant in either group (Fig. 18.4). As expected, the average serum B12 levels were substantially higher at both visits in the SR+B12 group, approximately 40 % higher at the time of surgery and 35 % higher at 6 months. This indicates that the increase

Fig. 18.4 Comparison of the serum B12 level in the two treatment groups at the time of surgery and 6 months postsurgery (Data from Phillips et al. [66])



in B12 levels in the SR+B12 group had been reached by the time of surgery and then was maintained during the postsurgery time frame.

18.8.2.1 Contact Detection

Since vitamin B12 supplementation for vitamin B12 deficiency appears to impact both axon and myelin structures of large diameter A β nerve fibers [2, 26, 67], we hypothesized that the CDTs would be less impaired in the SR+B12 group than in the SR-only group. Both the data of this study and the previous study [65] support this hypothesis. In the B12 tolerability study, patients who experienced greater increases in B12 serum levels (>400 pg/ml) at the time of postsurgical tactile testing compared to the presurgical baseline levels exhibited less impairment in touch detection associated with the mandibular osteotomies than patients who experienced lesser increases in B12 serum levels. The data from the exploratory RCT additionally indicated that the largest difference between groups occurred early (1 month) after nerve injury (Fig. 18.5). The better tactile detec-

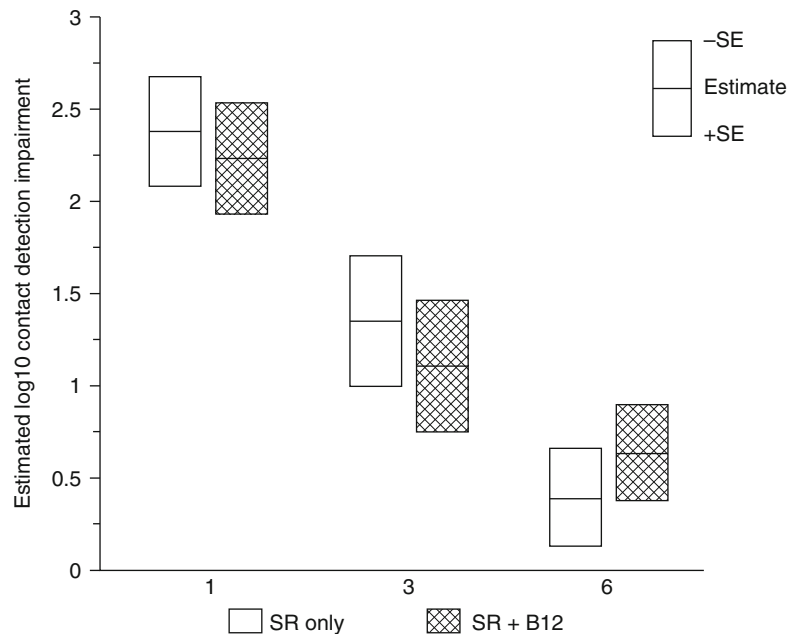
tion sensitivity at 1-month postsurgery in the SR+B12 group may indicate faster remyelination in the SR+B12 group than in the SR-only group since a higher proportion of traumatically injured nerves likely experience demyelination damage and recovery from demyelination occurs more quickly [40, 83].

Alternatively, since B12 supplementation was initiated 2–3 weeks before the injury, the earlier recovery in the SR+B12 group may indicate a neuroprotective effect. This would be important clinically if a nerve injury is anticipated to occur.

18.8.2.2 Two-Point Perception

Because sensory retraining serves to compensate for the altered sensation experienced by patients in response to mechanical stimulation, we hypothesized that sensory retraining plus vitamin B12 might not improve two-point perception beyond that achieved from sensory retraining alone. Consistent with this hypothesis, there was little or no difference between the SR+B12

Fig. 18.5 Impairment in contact (touch) detection threshold (CDT) on the chin. Shown are the geometric least-square means of the log₁₀ impairment ratio separately by treatment group controlling for age at surgery, type of surgery, and presence of a genioplasty at 1, 3, and 6 months postsurgery (Data from Phillips et al. [66])



and SR-only groups in the adjusted estimates of two-point perception at 1, 3, and 6 months postsurgery. Moreover, the levels of impairment postsurgery were similar to those observed in our previous study of sensory retraining.

18.8.2.3 Thermal Sensibility

For all four threshold measures, less impairment was observed for the SR+B12 group than the SR-only group. However, a greater difference was observed for the warm and heat discomfort perception thresholds than for the cool and cold discomfort perception thresholds. Moreover, at 3 and 6 months, subjects on average exhibited hypersensitivity to cold, but less so for those who received vitamin B12 than those who did not. Although a possibility, the difference in instructional protocol (cold at threshold uncomfortable vs. cold at threshold perceived to be burning, pricking, or stinging) prohibits us from suggesting that vitamin B12 may potentially reduce the likelihood or severity of cold allodynia. The large difference between the two groups in the warm perception threshold and heat discomfort perception threshold is consistent with a difference in the functional innervation densities of the

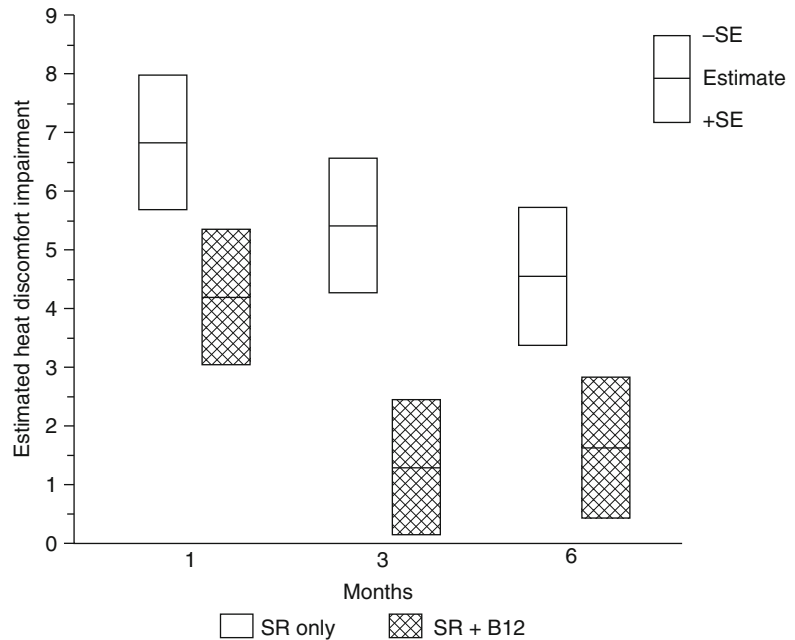
unmyelinated afferents that serve these two thermal sensibilities. Even at 6 months postsurgery, subjects who did not receive vitamin B12 required temperatures to be about 4.5 °C hotter than before surgery to experience heat discomfort (Fig. 18.6) [66]. In contrast, subjects who received vitamin B12 required temperatures to be only about 1.5 °C hotter.

In summary, vitamin B12 and sensory retraining show potential as noninvasive treatment options for acute peripheral nerve injuries. Further investigation is needed to document the effectiveness of different temporal applications of sensory retraining relative to the time of injury and to clarify procedural and dosage applications of vitamin B12. Such noninvasive therapies could reduce the need for subsequent surgical treatment of posttraumatic nerve injury in patients with annoying or disabling outcomes related to altered sensation.

Acknowledgements The authors wish to thank Debora Price for her participation in the data collection and analysis for all the research projects and Andrew Blank for technical assistance in manuscript preparation.

Conflict of Interest The authors have no conflict of interest to report.

Fig. 18.6 Impairment in the heat discomfort threshold (HPT) on the chin. Shown are the least-square means of the impairment in °C, separately by treatment group controlling for age at surgery, type of surgery, and presence of a genioplasty at 1, 3, and 6 months postsurgery (Data from Phillips et al. [66])



References

- Abe N, Cavalli V (2008) Nerve injury signaling. *Curr Opin Neurobiol* 18:276–283
- Al-Shubaili AF, Farah SA, Hussein JM, Trontelj JV, Khuraibet A (1998) Axonal and demyelinating neuropathy with reversible proximal conduction block, an unusual feature of vitamin B12 deficiency. *Muscle Nerve* 21:1341–1343
- Atsumi Y, Imai T, Matsumoto K, Sakuda M, Maeda T, Kurisu K, Wakisaka S (2000) Effects of different types of injury to the inferior alveolar nerve on the behavior of Schwann cells during the regeneration of periodontal nerve fibers of rat incisor. *Arch Histol Cytol* 63:43–54
- Becerra L, Morris S, Bazes S, Gostic R et al (2006) Trigeminal neuropathic pain alters responses in CNS circuits to mechanical (brush) and thermal (cold and heat) stimuli. *J Neurosci* 26:10646–10657
- Bell-Krotoski J, Weinstein S, Weinstein C (1993) Testing sensibility, including tough-pressure, two-point discrimination, point localization, and vibration. *J Hand Ther* 6:114–123
- Bouhassira D, Attal N, Fermanian J, Alchaar H, Gautron M, Masquelier E, Rostaing S, Lanteri-Minet M, Collin E, Grisart J, Boureau F (2004) Development and validation of the neuropathic pain symptom inventory. *Pain* 108(3):248–257
- Bouhassira D, Attal N, Alchaar H, Boureau F, Brochet B, Bruxelle J, Cunin G, Fermanian J, Ginies P, Grun-Overdyking A, Jafari-Schluep H, Lantéri-Minet M, Laurent B, Mick G, Serrie A, Valade D, Vicaut E (2005) Comparison of pain syndromes associated with nervous or somatic lesions and development of a new neuropathic pain diagnostic questionnaire. *Pain* 114(1–2):29–36
- Boyd JG, Gordon T (2003) Neurotrophic factors and their receptors in axonal regeneration and functional recovery after peripheral nerve injury. *Mol Neurobiol* 27:277–324
- Callahan AD (1995) Methods of compensation and re-education for sensory dysfunction. In: Hunter JM, Mackin EJ, Callahan AD (eds) *Rehabilitation of the hand*. Mosby, St. Louis
- Campbell RL, Shamaskin RG, Harkins SW (1987) Assessment of recovery from injury to inferior alveolar and mental nerves. *Oral Surg Oral Med Oral Pathol* 64:519–526
- Cunningham LL, Tiner BD, Clark GM, Bays RA, Keeling SD, Rugh JD (1996) A comparison of questionnaire versus monofilament assessment of neurosensory deficit. *J Oral Maxillofac Surg* 54:454–459
- Cusick CG, Wall JT, Whiting JHJ, Wiley RG (1990) Temporal progression of cortical reorganization following nerve injury. *Brain Res* 537(1–2):355–358
- Daniele HR, Aguado L (2003) Early compensatory sensory re-education. *J Reconstr Microsurg* 19:107–110
- Dellon AL (1988) *Re-education of sensation*. John D Lucas, Baltimore
- Dubner R, Ruda MA (1992) Activity-dependent neuronal plasticity following tissue injury and inflammation. *Trends Neurosci* 15(3):96–103
- Edin BB, Johansson N (1995) Skin strain patterns provide kinaesthetic information to the human central nervous system. *J Physiol (Lond)* 1:243
- Essick GK (1992) Comprehensive clinical evaluation of perioral sensory function. *Oral Maxillofac Surg Clin North Am* 4(2):503–526

18. Essick G (2004) Psychophysical assessment of patients with posttraumatic neuropathic trigeminal pain. *J Orofac Pain* 18:345–354
19. Essick G, Patel J, Trulsson M (2002) Mechanosensory and thermosensory changes across the border of impaired sensitivity to pinprick after mandibular nerve injury. *J Oral Maxillofac Surg* 60(11):1250–1266
20. Essick G, Guest S, Martinez E, Chen C, McGlone F (2004) Site-dependent and subject-related variations in perioral thermal sensitivity. *Somatosens Mot Res* 21:159–175
21. Essick GK, Phillips C, Turvey TA, Tucker M (2007) Facial altered sensation and sensory impairment after orthognathic surgery. *Int J Oral Maxillofac Surg* 36:577–582
22. Essick GK, Phillips C, Zuniga J (2007) Effect of facial sensory retraining on sensory thresholds. *J Dent Res* 86:571–575
23. Essick GK, Phillips C, Kim SK, Zuniga J (2009) Sensory retraining following orthognathic surgery: effect on threshold measures of sensory function. *J Oral Rehabil* 36:415–426
24. Faggin BM, Nguyen KT, Nicoletis MAL (1997) Immediate and simultaneous sensory reorganization at cortical and subcortical levels of the somatosensory system. *Proc Natl Acad Sci USA* 94:9428–9433
25. Feldman S, Essick G, Zuniga JR, Phillips C (1997) Interexaminer reliability of three subjective clinical neurosensory tests. *Int J Adult Orthod Orthognath Surg* 12:273–275
26. Fine EJ, Soria ED (1991) Myths about vitamin B12 deficiency. *South Med J* 84(12):1475–1481
27. Fiorio M, Haggard P (2005) Viewing the body prepares the brain for touch: effects of TMS over somatosensory cortex. *Eur J Neurosci* 22:773–777
28. Florence SL, Boydston LA, Hackett TA, Taub Lachoff H, Strata F, Niblock MM (2001) Sensory enrichment after peripheral nerve injury restores cortical, not thalamic, receptive field organization. *Eur J Neurosci* 13:1755–1766
29. Fridrich KL, Holton TJ, Pansegrau KJ, Buckley MJ (1995) Neurosensory recovery following the mandibular bilateral sagittal split osteotomy. *J Oral Maxillofac Surg* 53:1300–1306
30. Gandevia SC, Phegan CML (1999) Perceptual distortions of the human body image produced by local anaesthesia, pain and cutaneous stimulation. *J Physiol* 2:609–616
31. Gregg JM (1990) Studies of traumatic neuralgias in the maxillofacial region: surgical pathology and neural mechanisms. *J Oral Maxillofac Surg* 48(s):228–237
32. Gregg JM (1992) Nonsurgical management of traumatic trigeminal neuralgias and sensory neuropathies. *Oral Maxillofac Surg Clin North Am* 4:375–392
33. Hanz S, Fainzilber M (2006) Retrograde signaling in injured nerve—the axon reaction revisited. *J Neurochem* 99:13–19
34. Hashiba Y, Ueki K, Marukawa K, Shimada M, Yoshida K, Shimizu C, Alam S, Nakagawa K (2007) A comparison of lower lip hypoesthesia measured by trigeminal somatosensory-evoked potential between different types of mandibular osteotomies and fixation. *Oral Surg Oral Med Oral Pathol Oral Radiol Endod* 104(2):177–185
35. Havelius U, Hindfelt B, Rosén I (1982) Reversibility of neurological deficits in vitamin B12 deficiency. *Arch Psychiatr Nervenkr* 232:473–478
36. Herdegen T, Skene P, Bahr M (1997) The c-Jun transcription factor – bipotential mediator of neuronal death, survival and regeneration. *Trends Neurosci* 20:227–231
37. Ide H, Fujiya S, Asanuma Y, Tsuji M, Sakai H, Agashi Y (1987) Clinical usefulness of intrathecal injection of methylcobalamin in patients with diabetic neuropathy. *Clin Ther* 9:183–192
38. Imai H, Tajima T, Natsumi Y (1991) Successful reeducation of functional sensibility after median nerve repair at the wrist. *J Hand Surg* 16:60–65
39. Jääskeläinen SK (2004) The utility of clinical neurophysiological and quantitative sensory testing for trigeminal neuropathy. *J Orofac Pain* 18:355–359
40. Jääskeläinen SK, Teerijoki-Oksa T, Virtanen A, Tenovuo O, Forssell H (2004) Sensory regeneration following intraoperatively verified trigeminal nerve injury. *Neurology* 62:1951–1957
41. Jalaludin MA (1995) Methylcobalamin treatment of Bell's palsy. *Methods Find Exp Clin Pharmacol* 17:539–544
42. Jenkins WM, Merzenich MM, Ochs MT, Allard T, Guic-Robles E (1990) Functional reorganization of primary somatosensory cortex in adult owl monkeys after behaviorally controlled tactile stimulation. *J Neurophysiol* 63:82–104
43. Jian-bo L, Cheng-ya W, Jia-wei C, Ziao-lu L, Zhen-qing F, Hong-tai M (2010) The preventive efficacy of methylcobalamin on rat peripheral neuropathy influenced by diabetes via neural IGF-1 levels. *Nutr Neurosci* 13:79–86
44. Jones TA, Hawrylak N, Klintsova AY, Greenough WT (1998) Brain damage, behavior, rehabilitation, recovery, and brain plasticity. *Ment Retard Dev Disabil Res Rev* 4:231–237
45. Jones TA, Ghu CJ, Grande LA, Gregory AD (1999) Motor skills training enhances lesion-induced structural plasticity in the motor cortex of adult rats. *J Neurosci* 19(22):10153–10163
46. Kaas JH, Collins CE (2003) Anatomic and functional reorganization of somatosensory cortex in mature primates after peripheral nerve and spinal cord injury. *Adv Neurol* 93:87–95
47. Kaji R, Kodama M, Imamura A, Hashida T, Kohara N, Ishizu M, Inui K, Kimura J (1998) Effect of ultrahigh-dose methylcobalamin on compound muscle action potentials in amyotrophic lateral sclerosis: a double-blind controlled study. *Muscle Nerve* 21:1775–1778
48. Karas ND, Boyd SB, Sinn DP (1990) Recovery of neurosensory function following orthognathic surgery. *J Oral Maxillofac Surg* 48:124–134
49. Kuwabara S, Nakazawa R, Azuma N, Suzuki M, Miyajima K, Fukutake T, Hattori T (1999) Intravenous methylcobalamin treatment for uremic and diabetic neuropathy in chronic hemodialysis patients. *Intern Med* 38:472–475

50. Lundborg G (2003) Nerve injury and repair-A challenge to the plastic brain. *J Peripher Nerv Syst* 8: 209–226
51. Lundborg G, Rosen B (2001) Sensory relearning after nerve repair. *Lancet* 358:809–810
52. Mandolesi G, Madeddu F, Bozzi Y, Maffei L, Ratto GM (2004) Acute physiological response of mammalian central neurons to axotomy: ionic regulation and electrical activity. *FASEB J* 18:1934–1936
53. Marchettini P (2005) The burning case of neuropathic pain wording. *Pain* 114(3):313–314
54. Merzenich MM, Recanzone G, Jenkins WM, Allard TT, Nudo RJ (1988) Cortical representational plasticity. In: Rakic P, Singer W (eds) *Neurobiology of neocortex*. John Wiley & Sons, New York
55. Meyer RA, Rath EM (2001) Sensory rehabilitation after trigeminal nerve injury or nerve repair. *Atlas Oral Maxillofac Surg Clin North Am* 13:365–376
56. Morani AS, Bodhankar SL (2010) Early co-administration of vitamin E acetate and methylcobalamin improves thermal hyperalgesia and motor nerve conduction velocity following sciatic nerve crush injury in rats. *Pharmacol Rep* 62:405–409
57. Nakagawa K, Ueki K, Takatsuka S, Yamamoto E (2003) Trigeminal nerve hypesthesia after sagittal split osteotomy in setback cases: correlation of post-operative computed tomography and long-term trigeminal somatosensory evoked potentials. *J Oral Maxillofac Surg* 61:898–903
58. Navarro X, Vivó M, Valero-Cabré A (2007) Neural plasticity after peripheral nerve injury and regeneration. *Prog Neurobiol* 82(4):163–201
59. Panula K, Finne K, Oikarinen K (2004) Neurosensory deficits after bilateral sagittal split ramus osteotomy of the mandible – influence of soft tissue handling medial to the ascending ramus. *Int J Oral Maxillofac Surg* 33:543–548
60. Phillips C, Essick G, Zuniga J, Tucker M, Blakey GH III (2006) Qualitative descriptors used by patients following orthognathic surgery to portray altered sensation. *J Oral Maxillofac Surg* 64:1751–1760
61. Phillips C, Essick G, Preisser JS, Turvey TA, Tucker M, Lin D (2007) Sensory retraining following orthognathic surgery: effect on patient perception of altered sensation. *J Oral Maxillofac Surg* 65(6):1162–1173
62. Phillips C, Kim S, Essick G, Tucker M, Turvey TA (2009) Sensory retraining following orthognathic surgery: effect on patient report of the presence of altered sensation. *Am J Orthod Dentofacial Orthop* 136(6):788–794
63. Phillips C, Kim S, Tucker M, Turvey TA (2010) Sensory retraining: burden in daily life related to altered sensation after orthognathic surgery, a randomized clinical trial. *Orthod Craniofac Res* 13(3):169–178
64. Phillips C, Blakey G III, Essick GK (2011) Sensory retraining: a cognitive behavioral therapy for altered sensation. *Atlas Oral Maxillofac Surg Clin North Am* 19:109–118
65. Phillips C, Blakey G III, Essick GK (2012) A tolerability study in orthognathic surgery patients of intranasal cyanocobalamin spray: a potential treatment for acute peripheral nerve injury. *J Maxillofac Trauma* 1:13–19
66. Phillips C, Essick GK, Chung Y, Blakey G III (2012) Non-invasive therapy for altered facial sensation following orthognathic surgery: an exploratory randomized clinical trial of intranasal vitamin B12 spray. *J Maxillofac Trauma* 1:20–29
67. Puri V, Chaudhry N, Goel S, Gulati P, Nehru R, Chowdhury D (2005) Vitamin B12 deficiency: a clinical and electrophysiological profile. *Electromyogr Clin Neurophysiol* 45(5):273–284
68. Recanzone GH, Jenkins WM, Hradek GT, Merzenich MM (1992) Progressive improvement in discriminative abilities in adult owl monkeys performing a tactile frequency discrimination task. *J Neurophysiol* 67: 1015–1030
69. Recanzone GH, Merzenich MM, Jenkins WM, Grajski KA, Dinse HR (1992) Topographic reorganization of the hand representation in cortical area 3b of owl monkeys trained in a frequency-discrimination task. *J Neurophysiol* 67:1031–1056
70. Recanzone GH, Merzenich MM, Schreiner CE (1992) Changes in the distributed temporal response properties of SI cortical neurons reflect improvements in performance on a temporally based tactile discrimination task. *J Neurophysiol* 67:1071–1091
71. Ro T, Wallace R, Hagedorn J, Farne A, Pienkos E (2004) Visual enhancing of tactile perception in the posterior parietal cortex. *J Cogn Neurosci* 16:24–30
72. Rosen B, Lundborg G (2004) Sensory re-education after nerve repair: aspects of timing. *Handchir Mikrochir Plast Chir* 36:8–12
73. Rostand SG (1976) Vitamin B12 levels and nerve conduction velocities in patients undergoing maintenance hemodialysis. *Am J Clin Nutr* 29:691–697
74. Sathian K, Greenspan AI, Wolf SL (2000) Doing it with mirrors: a case study of a novel approach to neurorehabilitation. *Neurorehabil Neural Repair* 14: 73–76
75. Sato Y, Honda Y, Iwamoto J, Kanoko T, Satoh K (2005) Amelioration by mecobalamin of subclinical carpal tunnel syndrome involving unaffected limbs in stroke patients. *J Neurol Sci* 231:13–18
76. Scalabrino G, Buccellato FR, Veber D, Mutti E (2003) New basis of the neurotrophic action of vitamin B12. *Clin Chem Lab Med* 41:1435–1437
77. Shieh S-J, Chiu HOY, Lee J-W, Hsu H-Y (1995) Evaluation of the effectiveness of sensory reeducation following digital replantation and revascularization. *Microsurgery* 16:578–582
78. Sun Y, Lai M-S, Lu C-J (2005) Effectiveness of vitamin B12 on diabetic neuropathy: systematic review of clinical controlled trials. *Acta Neurol Taiwan* 14:48–54
79. Taylor-Clarke M, Kennett S, Haggard P (2002) Vision modulates somatosensory cortical processing. *Curr Biol* 12:233–236
80. Teerijoki-Oksa T, Jääskeläinen SK, Forssell K, Forssell H, Vahatalo K, Tammisalo T et al (2002) Risk factors of nerve injury during mandibular sagittal split osteotomy. *Int J Oral Maxillofac Surg* 31:33–39

81. Teerijoki-Oksa T, Jääskeläinen S, Forssell K, Virtanen A, Forssell H (2003) An evaluation of clinical and electrophysiologic tests in nerve injury diagnosis after mandibular sagittal split osteotomy. *Int J Oral Maxillofac Surg* 32(1):15–23
82. Teerijoki-Oksa T, Jääskeläinen SK, Forssell K, Forssell H (2004) Recovery of nerve injury after mandibular sagittal split osteotomy. Diagnostic value of clinical and electrophysiologic tests in the follow-up. *Int J Oral Maxillofac Surg* 33(2):134–140
83. Teerijoki-Oksa T, Jääskeläinen SK, Soukka T, Virtanen A, Forssell H (2011) Subjective sensory symptoms associated with axonal and demyelinating nerve injuries after mandibular sagittal split osteotomy. *J Oral Maxillofac Surg* 69:e208–e213
84. Trulsson M, Essick GK (1997) Low-threshold mechanoreceptive afferents in the human lingual nerve. *J Neurophysiol* 77:737–748
85. Van Boven R, Johnson K (1994) A psychophysical study of the mechanisms of sensory recovery following nerve injury in humans. *Brain* 117(Pt 1): 149–167
86. Van Boven R, Johnson K (1994) The limits of tactile spatial resolution in humans: grating orientation discrimination at the lip, tongue, and finger. *J Neurol* 44:2361–2366
87. Wall JT, Kaas JH, Sur M, Nelson RJ, Felleman DF, Merzenich MM (1986) Functional reorganization in somatosensory cortical areas 3b and 1 of adult monkeys after median nerve repair: possible relationships to sensory recovery in humans. *J Neurosci* 6:218–223
88. Wall JT, Xu J, Wang X (2002) Human brain plasticity: an emerging view of the multiple substrates and mechanisms that cause cortical changes and related sensory dysfunctions after injuries of sensory inputs from the body. *Brain Res Rev* 39(2–3):181–215
89. Wang Z, Gan Q, Rupert RL, Zeng Y, Song X (2005) Thiamine, pyridoxine, cyanocobalamin and their combination inhibit thermal, but not mechanical hyperalgesia in rats with primary sensory neuron injury. *Pain* 114:266–277
90. Watanabe T, Kaji R, Oka N, Bara W, Kimura J (1994) Ultra-high dose methylcobalamin promotes nerve regeneration in experimental acrylamide neuropathy. *J Neurol Sci* 122:140–143
91. Waylett-Rendall J (1988) Sensibility evaluation and rehabilitation. *Orthop Clin North Am* 19:43–56
92. Wei F-C, Ma H-S (1995) Delayed sensory reeducation after toe-to-hand transfer. *Microsurgery* 16: 583–585
93. Woolf CJ, Walters ET (1991) Common patterns of plasticity contributing to nociceptive sensitization in mammals and Aplysia. *Trends Neurosci* 14(2):74–78
94. Wynn Parry CB, Slater M (1976) Sensory re-education after median nerve lesions. *Hand* 8:250–257
95. Yaqub BA, Siddique A, Sulimani R (1992) Effects of methylcobalamin on diabetic neuropathy. *Clin Neurol Neurosurg* 94:105–111
96. Yoshida T, Nagamine T, Kobayashi T, Michimi N, Nakajima T, Sasakura H, Hanada K (1989) Impairment of the inferior alveolar nerve after sagittal split osteotomy. *J Craniomaxillofac Surg* 17:271–277

Peter P. Robinson, Keith G. Smith,
and Søren Hillerup

19.1 Introduction

This chapter describes the outcomes of trigeminal nerve repair at two European centres, one in Sheffield, UK, and the other in Copenhagen, Denmark, and compares results with those reported in the published literature. We will compare outcomes with those reported in studies undertaken elsewhere and address a series of specific questions. We will focus on outcomes of surgery to the lingual nerve (LN) and inferior alveolar nerve (IAN), as most information is available for these trigeminal nerve branches. The analysis reveals that LN repair using direct reapposition by epineurial suture is a worthwhile procedure for most patients. It does not reduce the number of patients who report pain or spontaneous paraesthesia, although the level

of severity of these symptoms may decline. LN repair within 6 months of the injury may be associated with better recovery than later repair, but late repair can still result in significant neurosensory improvement. IAN decompression and neurolysis is a single procedure. It results in significant reduction in the level of dysaesthesia as well as improvement in sensation. However, as the overall level of improvement is small, and some patients do not improve at all, the procedure should only be offered to patients who are significantly affected by their symptoms.

19.2 Outcomes of Lingual Nerve Repair

19.2.1 Introduction

Many of the early descriptions of LN repair included little information about outcome [12, 18, 33] or about the methods used to assess a successful result [36]. The first published reports on outcome evaluated by sensory testing appeared in the late 1980s and 1990s [5, 19, 22, 43, 48, 72] and, while some results were encouraging, the number of patients assessed was small or they were treated by a range of different surgical techniques. The largest report was from a retrospective postal questionnaire appraisal of 205 lingual nerve repairs at seven units in the USA [27]. The operations included decompression, direct suturing, or nerve grafting, and although the authors reported an 80 % success rate, their

P.P. Robinson, BDS, FDSRCS, PhD, DSc, F.Med.Sci (✉)
K.G. Smith, BDS, FDSRCS, PhD
Unit of Oral & Maxillofacial Medicine and Surgery,
University of Sheffield, School of Clinical Dentistry,
Claremont Crescent, Sheffield, S10 2TA, UK
e-mail: p.robinson@sheffield.ac.uk;
k.g.smith@sheffield.ac.uk

S. Hillerup, PhD, Dr.Odont
Department of Oral and Maxillofacial Surgery,
University of Copenhagen Rigshospitalet,
Blegdamsvej 9, DK-2100, Copenhagen Ø, Denmark

Institute of Odontology, Panum Institutet,
University of Copenhagen, Norre Alle 20,
2200, Copenhagen, Denmark
e-mail: sohi@rh.dk

primary conclusion was ‘it is apparent that there is need for a detailed prospective study of specific injury conditions and their response to standardised microneurosurgical interventions’. A subsequent critical appraisal of publications confirmed that view [11]. Therefore, most of the outcomes described in this chapter are based upon the results of prospective studies undertaken at one centre in the UK, using a consistent repair method for all patients. For comparison, and to show the similarity of the outcomes in different centres with different surgeons, some results from a centre in Denmark will also be illustrated.

Our UK approach to the management of patients with persistent LN sensory disturbance is based upon the results of an extensive series of animal investigations. Using a combination of electrophysiological and ultrastructural techniques, we have assessed the extent of functional recovery of each of the nerve fibre groups in the lingual branch of the trigeminal nerve and the chorda tympani branch of the facial nerve after a range of manipulations and recovery periods. These studies allowed assessment of the functional characteristics of mechanosensitive, thermosensitive, and gustatory fibres that had regenerated after injury, as well as quantification of the recovery of the autonomic fibres responsible for salivary secretion and vasomotor effects. These data showed that permanent sensory abnormalities were more likely to result from nerve section than from a crush injury [23, 45, 46], that repair by epineurial suture was more effective than entubulation [24, 55, 56], that repair of a gap was better achieved by mobilisation of the stumps than by sural nerve grafts or autologous frozen skeletal muscle grafts [57, 58], and that a 3-month delay before repair had little effect on the outcome [59, 60]. Attempts to improve recovery by the application of neurotrophic agents to the repair site were unsuccessful [61]. We have taken the principles derived from all of these studies and applied them to the clinical management of our patients. We have prospectively established protocols for a series of sensory tests performed before and after nerve repair surgery, to allow statistical

comparisons and to specifically address the following questions:

- Is lingual nerve repair worthwhile?
- Do some neurosensory functions recover better than others?
- Does nerve repair surgery reduce dysaesthesia?
- Is early repair more effective than late repair?
- Do other factors influence the outcome?

19.2.2 Patients and Methods for UK Analysis

The series comprised 53 of the patients referred to our nerve injury clinic in Sheffield over an 8-year period [50]. All the injuries had occurred during removal of third molars, and the patients had been selected as appropriate for operation because they showed little or no evidence of recovery by 3 months after the injury [4] or very limited recovery at later stages. There were 15 men and 38 women, mean age 30 years (range 16–54), and the injuries were on the left side in 30 patients and on the right side in 23. The delay before nerve repair ranged from 4 to 47 (mean: 15) months, and all patients were followed up for at least 1 year.

All of the repairs were performed under general anaesthesia by one of the authors (PPR, KGS), and the technique was similar for each patient. The LN was exposed by elevating a lingual flap, dividing the lingual periosteum, and using careful blunt dissection to identify the proximal and distal nerve stumps. At the injury site, the LN was usually adherent to the lingual periosteum, always trapped in dense surrounding scar tissue, and sometimes expanded to form a neuroma (Fig. 19.1a). In about half of the patients, there was evidence of some degree of continuity between the proximal and distal stumps of the nerve, but in the others, the nerve seemed to have been completely divided, and the two ends had retracted apart from one another. Small fragments of metal were sometimes found embedded within the epineurium and scar tissue, and these had presumably been shaved from the edge of a metal instrument by the bur during the initial third molar operation. The segment of nerve that

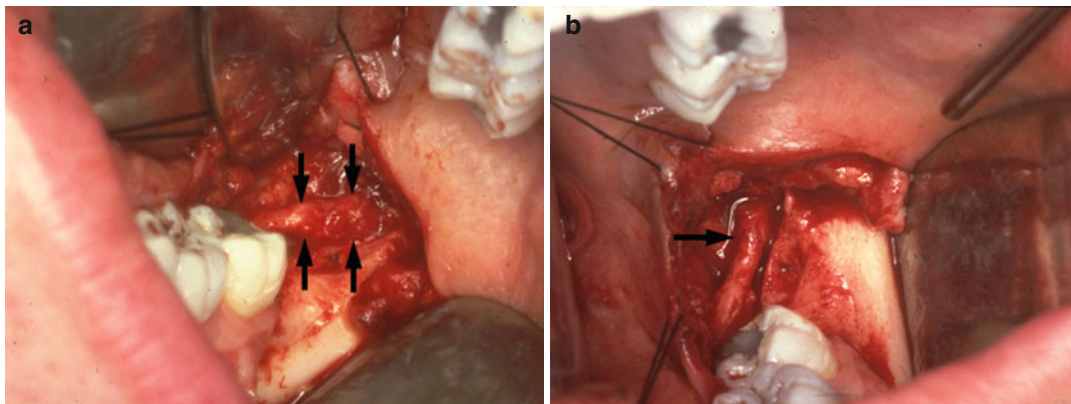


Fig. 19.1 (a) A large neuroma on the lingual nerve (*arrows*) at the site of damage during the removal of an impacted third molar 18 months earlier. (b) The neuroma

has been excised, and the nerve ends mobilised and repaired using epineurial sutures (*arrow*) (From Robinson et al. [50]; reproduced with kind permission of Elsevier)

appeared damaged under the operating microscope was excised; the nerve resection was 4–14 (mean: 9.5) mm in length and, where possible, included all of the expanded neuroma. None of the nerves were grafted, so the length of excised segment was restricted by the extensibility of the two nerve stumps. Repair was accomplished with 5–10 (mean: 7) epineurial sutures (Fig. 19.1b) with 8/0 monofilament polyamide (Ethilon, Ethicon Ltd, UK). The wound was closed with polyglactin 910 (Vicryl), and all patients were administered systemic prophylactic antibiotics and dexamethasone (8 mg preoperatively and 12 h postoperatively).

In all patients, sensation on the affected side of the tongue was assessed preoperatively and at approximately 1, 4, and 12 months or more (median: 13 months) postoperatively. Initially, each patient was asked a series of standard questions from a proforma including the following: whether the affected part of the tongue was completely numb, whether it was painful, whether they had tingling (paraesthesia) spontaneously or initiated by touching or moving the tongue, whether they tended to bite the tongue by accident, and whether they thought that their speech or taste was affected. We then made an examination to establish the presence of fungiform papillae on each side of the tongue, the presence of a palpable neuroma in the third molar region, or sensation in the tongue evoked by palpation in this region.

A series of neurosensory tests was then administered by one of the authors (PPR or KGS) in a quiet room with the patient's eyes closed and the tongue protruded. These tests included evaluation of light touch sensation using von Frey hairs, pinprick (pain) sensation, two-point discrimination, and taste sensation using both gustatory stimuli and electrogustometry. Full details of the methods used are described elsewhere [49, 50]. Finally, at the last testing session only, the patients were asked to give a subjective score to the value of the operation on a scale of 0–10. They were told that 0 indicated that the operation had been a waste of time and that 10 indicated a perfect outcome. They were told to consider this only from their own perspective, ignoring the results of the sensory testing and the perception of the surgeons.

Statistical comparisons between the results of tests at different stages were made with the chi-square test or Mann-Whitney U test as appropriate, unless otherwise stated. The effect on outcome of delay between injury and repair was assessed with Pearson's correlation coefficient.

19.2.3 Outcome of UK Analysis

19.2.3.1 Responses to Questions

A comparison between the responses to questions asked preoperatively and at the final test is shown in Table 19.1. There was a highly significant

Table 19.1 A comparison between the responses to questions asked preoperatively and at the final test for patients who had undergone lingual nerve repair in the UK study

| | Preoperatively | Postoperatively | <i>p</i> value |
|---------------------------|----------------|-----------------|----------------|
| Complete numbness? | 34 (64 %) | 6 (11 %) | <0.0001 |
| Pain? | 16 (30 %) | 14 (26 %) | 0.8 |
| Spontaneous tingling? | 25 (47 %) | 24 (45 %) | 1 |
| Touch-evoked tingling? | 9 (17 %) | 15 (28 %) | 0.3 |
| Movement-evoked tingling? | 10 (19 %) | 17 (32 %) | 0.2 |
| Tongue biting? | 39 (74 %) | 26 (49 %) | <0.02 |
| Speech affected? | 30 (57 %) | 30 (57 %) | 1 |
| Taste disturbance? | 34 (64 %) | 30 (57 %) | 0.6 |

Data are number (%) of patients ($n=53$)

reduction in the number of patients who thought that the affected part of the tongue was completely numb (34 to 6, $p<0.0001$). A substantial proportion of the patients ($n=16$) initially reported pain from the affected part of the tongue, and almost half of them ($n=25$) had spontaneous paraesthesia. There was no significant change in the number reporting these problems at the final assessment, and although some patients reported a reduction in the intensity of these symptoms, we did not attempt to quantify this difference. There was a small but insignificant increase in the number of patients who reported paraesthesia initiated by touching or moving the tongue, suggesting abnormal properties of the reinnervated receptors on the tongue. Accidental tongue biting was initially a problem for 39 patients, but there was a significant reduction in this number at the final assessment ($n=26$, $p<0.02$). A large proportion of patients reported disturbances of speech ($n=30$) and taste ($n=34$), and these proportions had not changed significantly at the final assessment.

19.2.3.2 Observations

There appeared to be fewer fungiform papillae on the affected side of the tongue in 34 (74 %) of the patients preoperatively and in 24 (45 %) at the final assessment ($p<0.01$). An expanded swelling, thought to be a neuroma, could be detected by palpation in five patients preoperatively and in four patients after the nerve repair operation ($p=1$). Palpation in the lingual sulcus at the site where the nerve injury was expected to have occurred evoked a sensation in the tongue in

31 patients (58 %) before the operation and in 29 (55 %) after the operation.

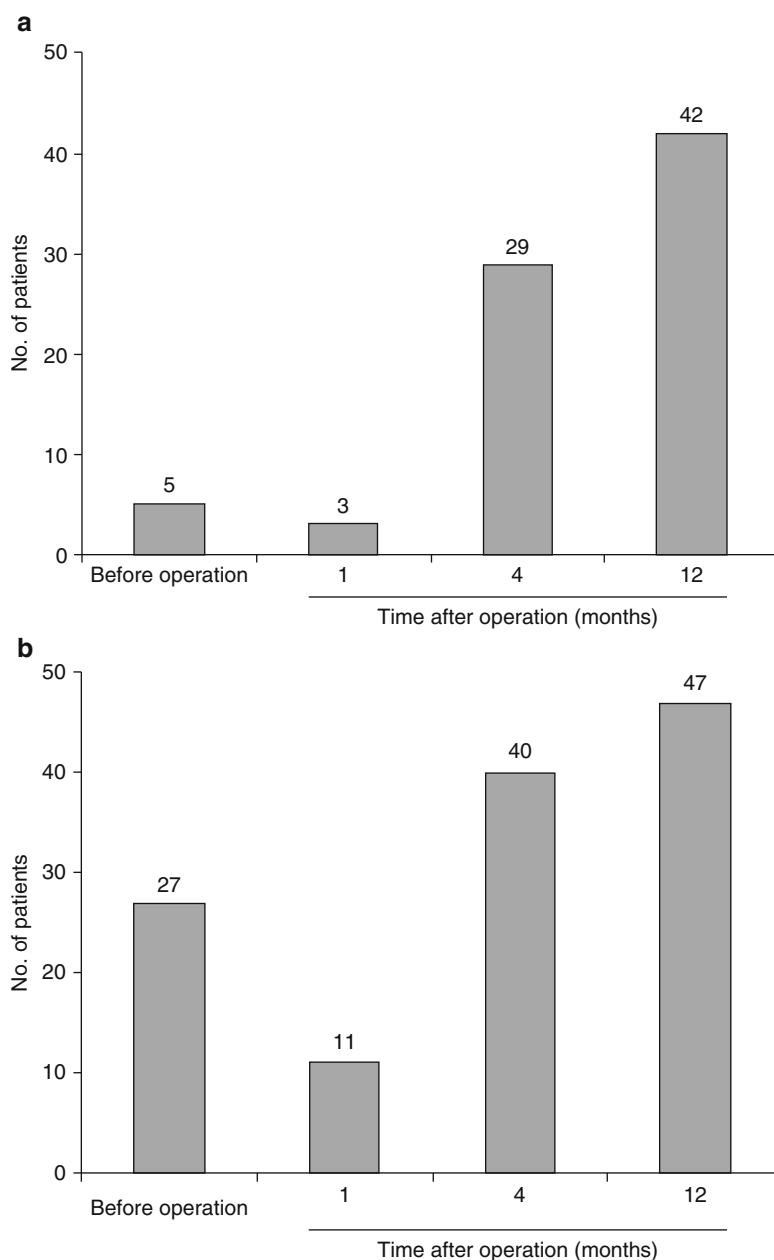
19.2.3.3 Neurosensory Tests

On the normal, uninjured (control) side of the tongue, all patients were able to detect light touch stimuli with a 20 mN von Frey hair, pinprick stimuli of up to 150 mN, and the electrical stimuli used for electrogustometry. The two-point discrimination thresholds ranged from 2 to 10 mm (median: 4), and the ability to identify correctly the gustatory stimuli ranged from 1 to 8 (median: 6) out of eight trials.

The results of the neurosensory tests on the side of injury are shown graphically in two ways. Firstly, for the responses to light touch and pinprick stimuli, the number of patients who responded in some way to these stimuli at each assessment interval is shown in Fig. 19.2a, b. In each case, these charts show a reduction in the number of patients who responded in the early postoperative period, followed by a progressive increase beyond the initial numbers, until 42 (79 %) and 47(89 %), respectively, responded at the final test.

A more critical appraisal of the outcome is demonstrated by a comparison of the quantitative scores recorded at the preoperative and final postoperative assessments. These data are shown for the responses to light touch stimuli in Fig. 19.3 and indicate that 27 (51 %) of the patients responded to tests in most or all areas at the final assessment, with a highly significant improvement in the pooled responses ($p<0.0001$). Equivalent data for the responses to pinprick

Fig. 19.2 (a) The number of patients who could detect some light touch stimuli with a 20 mN von Frey hair on the affected side, at various stages before and after operation. (b) The number of patients who could detect some pin prick stimuli of up to 150 mN on the affected side, at various stages before and after operation (From Robinson et al. [50]; reproduced with kind permission of Elsevier)



stimuli are shown in Fig. 19.4; 41 of the patients (77 %) responded to tests in most or all areas at the final test, again with a highly significant improvement in the pooled responses ($p < 0.0001$). Due to the size of the tongue, two-point discrimination thresholds could be recorded for each side only if they were less than 14 mm, and the results are shown in Fig. 19.5. The pooled data again

show a highly significant reduction in thresholds ($p < 0.0001$). Figure 19.6 indicates the extent of recovery of gustatory responses: 11 patients (21 %) could detect some taste solutions preoperatively and 33 (62 %) postoperatively ($p < 0.0001$). Electrogustometry evoked responses from 13 patients preoperatively, with a mean (SEM) threshold of 497 (31) μA . Postoperatively

Fig. 19.3 The level of responses to light touch stimuli with a 20 mN von Frey hair, subdivided on a four-point scale: 0, no response; 1, response at the tip only; 2, response in most areas; and 3, responses apparently similar to those on the unaffected side. Preoperative data are shown in *blue* and responses at the final postoperative test are shown in *red*. The difference between the preoperative and postoperative data is highly significant ($p < 0.0001$)

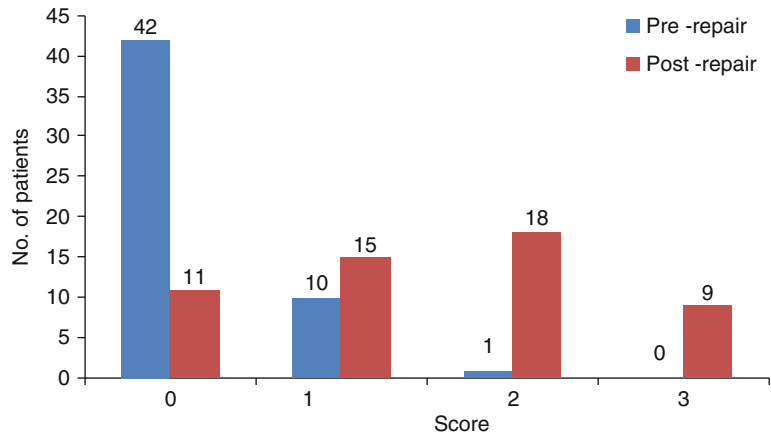


Fig. 19.4 The level of responses to pinprick stimuli of up to 150 mN, subdivided on a four-point scale: 0, no response; 1, response at the tip only; 2, response in most areas but with an increased threshold; and 3, responses apparently similar to those on the unaffected side. Preoperative data are shown in *blue*, and responses at the final postoperative test are shown in *red*. The difference between the preoperative and postoperative data is highly significant ($p < 0.0001$)

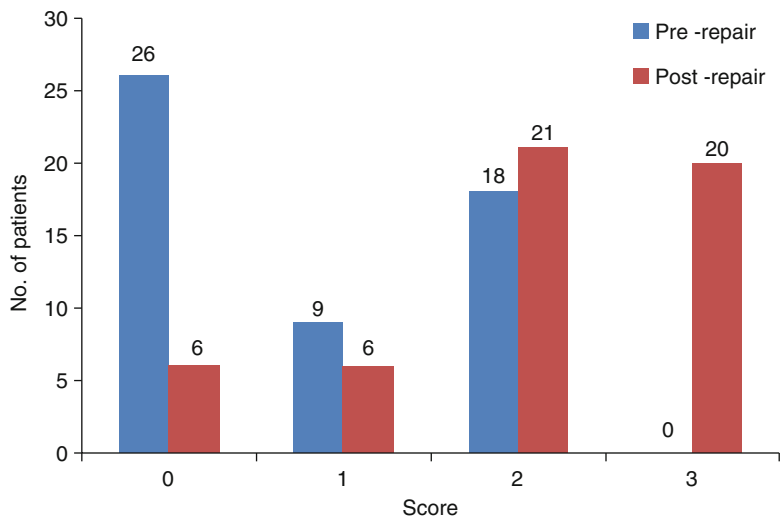


Fig. 19.5 The two-point discrimination thresholds measured preoperatively (in *blue*) and at the final postoperative test (in *red*). Because of tongue size, a threshold of more than 14 mm could not be reliably assessed, and these patients have been placed in the >14 mm column. The difference between the preoperative and postoperative data is highly significant ($p < 0.0001$)

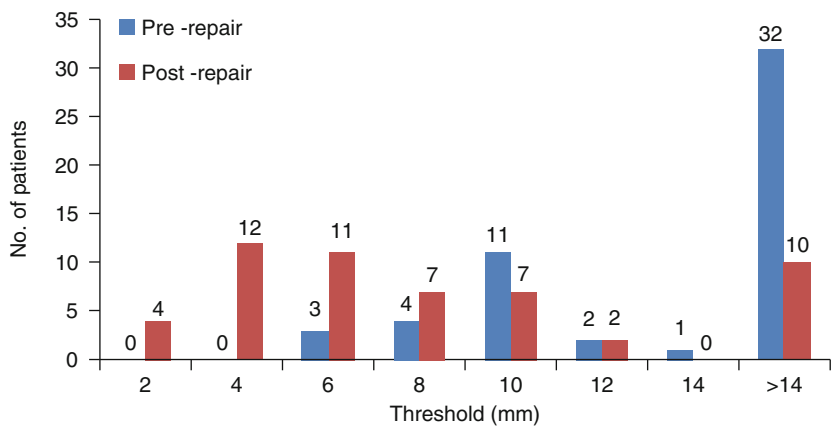


Fig. 19.6 The level of responses to gustatory stimuli, subdivided on a three-point scale: 0, no response; 1, some correct responses; and 2, a similar number of correct responses on each side of the tongue. Preoperative data are shown in *blue*, and responses at the final postoperative test are shown in *red*. The difference between the preoperative and postoperative data is highly significant ($p < 0.0001$)

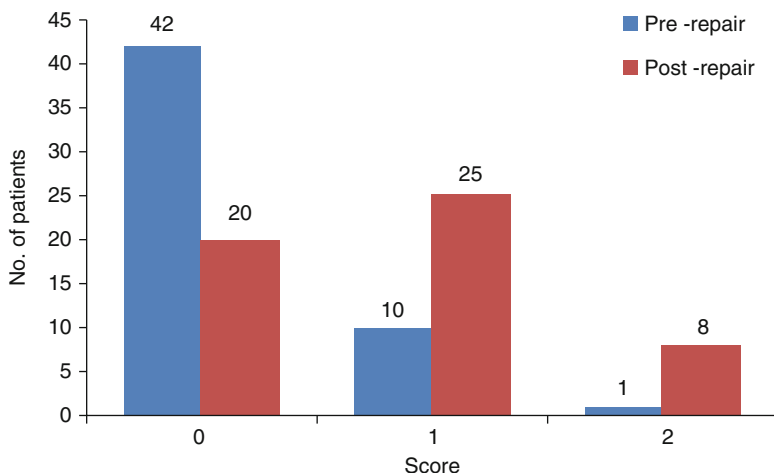
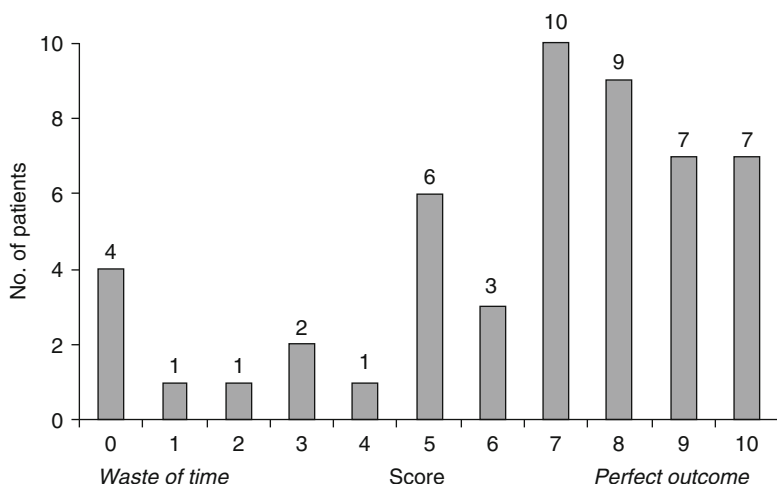


Fig. 19.7 The overall value of the operation as assessed subjectively by the patients on a scale of 0–10 ($n = 51$) (From Robinson et al. [50]; reproduced with kind permission of Elsevier)



responses were evoked in 42 patients ($p < 0.0001$) with a mean (SEM) threshold of 312 (27) μA ($p < 0.001$, student's *t* test).

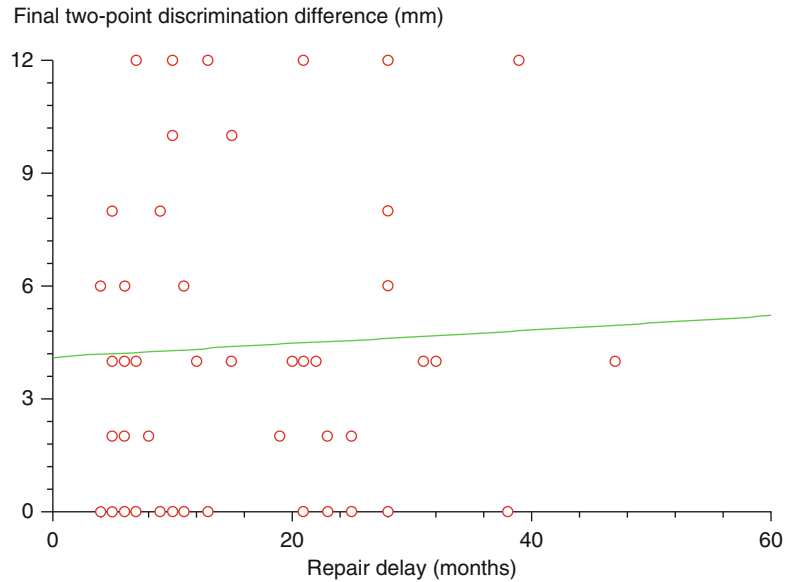
19.2.3.4 Subjective Assessment

The patients' subjective assessment of the value of the operation, taking all aspects of their experience into consideration, is shown in Fig. 19.7. The scores covered the full range from 0 to 10, with four patients reporting a score of 0 and 42 patients reporting a score of 5 or more. The median score reported by all patients was 7.

19.2.3.5 Effect of Delay in Repair

The relationship between the final outcome of the nerve repair operation and the period between injury and repair was assessed for all neurosensory tests as well as the patients' subjective scores. In no case was there any significant correlation, and an example is shown in Fig. 19.8 which shows the difference between two-point discrimination thresholds on each side of the tongue at the final test, as a good indicator of the level of recovery, plotted against the delay in repair.

Fig. 19.8 The delay (months) between the nerve injury and repair plotted against the final outcome expressed as the difference between the two-point discrimination thresholds on the affected and unaffected sides of the tongue ($p > 0.2$) (From Robinson et al. [50]; reproduced with kind permission of Elsevier)



19.2.4 Patients and Methods for the Denmark Analysis

This series comprised 67 LN injuries of the patients seen in a nerve injury clinic in Copenhagen, Denmark, during the period of 1987–2005 [21]. Significantly, more patients were females (47, 70 %) than males (20, 30 %; $p < 0.0001$). Their median age was 30 years, with a range of 19–53 years, with no difference related to gender. The LN injuries were all caused by third molar removal, and the mean delay between injury and surgery was 12 months (range: <1–57 months).

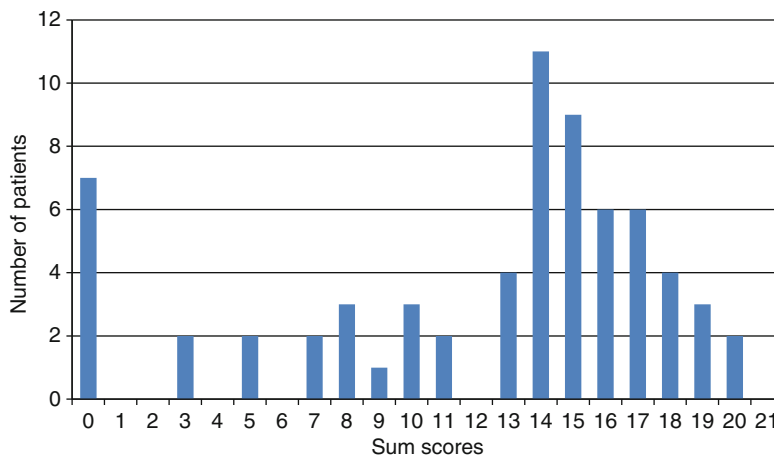
The surgical approach was similar to that described for the UK study, except that the procedure was performed with a magnifying head loupe (3.5×) rather than an operating microscope. The neuroma on the proximal stump was resected to a level of visible fascicles, and the distal stump was cut at a level without scar tissue. From this point, a channel retractor resting on the medial cortex of the mandible was found useful to provide space for instrumentation. The nerve stumps were approximated with a holding suture if appropriate (7/0 monofilament nylon) to overcome tension, and 6–8 epineurial 8/0 monofilament nylon sutures completed the repair.

In all patients, sensation on the affected side of the tongue was assessed preoperatively and

postoperatively at 1, 3, 6, and 12 months (if possible), using a standard protocol [20, 21]. Patients were questioned about sensory abnormalities (paraesthesia, dysaesthesia, etc.) and asked to rate their subjective level of sensory function on a four-point scale (0–3). In addition, the perception of *tactile* (feather light touch, pinprick, pointed/dull discrimination), *thermal* (cold, 0–20 °C and warm 45–50 °C), and *location* stimuli (location of touch and brush stroke direction) was assessed. Responses to each of these stimuli were rated on a four-point scale (0=no perception of touch; 1=perception of touch with no ability to differentiate (pointed/blunt, warm/cold, location of touch, brush stroke direction); 2=perception with ability to differentiate less clear than normal; 3=normal perception). The overall level of neurosensory function was characterised through the summation of all of these rating scores, therefore ranging from 0 to 21. Thus, a score of 0 signified complete absence of sensation, a score of 21 denoted normal neurosensory function, and the sensory recovery was expressed by the sum score improvement.

Two-point discrimination thresholds were assessed at 5, 10, 15, and 20 mm. Pain perception on pinching with tissue forceps was assessed through the patient's reported experience of pain, a blink reflex, or a protective reaction, and rated as present or absent.

Fig. 19.9 The overall level of sensation at final follow-up examination in 65 patients after lingual nerve repair. Sum scores are the combined ratings of responses to seven test stimuli (feather light touch, pinprick, point/dull discrimination, warm, cold, location of touch, and brush stroke direction)



As soon as perception of stimuli was demonstrable, the patients were instructed to begin neurosensory retraining exercises with continued stimulation of the injured and healthy side of their tongue with recognisable items such as metal, wood, fabric, paper, and so forth.

Statistical differences between categorical scores were tested with a *sign test*; Chi-square or Kruskal-Wallis tests were applied to test differences between distributions.

19.2.5 Outcome of Denmark Analysis

The outcomes of nerve repair in this analysis spanned the full spectrum, with seven patients (10 %) showing no evidence of recovery, but others showing a fairly rewarding level of recovery of sensation.

19.2.5.1 Subjective Assessment of Sensation

Preoperatively, 38 patients (57 %) subjectively rated their sensory function in the affected area as 0, and the remaining 24 patients provided an average rating of 0.9 (range: 0.5–2, no data in 5 patients). Postoperatively, the subjective rating scores averaged 1.2 (range: 0–2.5).

Prior to LN repair, paraesthesia was experienced by 39 patients (58 %), 11 patients (17 %) complained of dysaesthesia, and 2 patients (3 %) had allodynia. After nerve repair, paraesthesia was still the most prevalent disturbance, felt by

40 patients (60 %), followed by 8 patients (12 %) with dysaesthesia, and 1 patient with allodynia (2 %). In 29 patients, the sensory abnormality was persistent, while in 19 it was episodic, and only 11 patients (16 %) had no neuropathic sensory disturbance (no data in 6 patients). Thus, the incidence of neurogenic discomfort was unaffected by the nerve repair.

Preoperative palpation in the lingual sulcus at the site where the nerve injury would have been expected evoked a sensation in the tongue in 55 patients (82 %), suggesting the presence of a traumatic neuroma. At the final examination, a similar response was observed in 51 patients (76 %).

19.2.5.2 Tactile Perception

Preoperative sensory testing revealed that 31 patients (46 %) had complete loss of sensation (sum score 0) on the affected side of the tongue. The remaining 36 patients had a median initial sum score of 2.0 (range 1–8), with the perception of cold being the response most frequently retained ($n=23$, 34 %). After repair, the level of sensation recovered to a final median sum score of 14 (25th percentile: 9.0, 75th percentile: 16.0; min. 0, max. 20) (Fig. 19.9). The rate of recovery was fastest during the first 6 months after surgery, thereafter declining (Fig. 19.10). It appears that some patients showed a peak of sensory recovery with a subsequent loss, beyond what might have been expected from variations in neurosensory testing.

Fig. 19.10 The overall level of sensation (combined sum scores) at intervals after lingual nerve repair in 67 patients (From Hillerup and Stoltze [21]; reproduced with kind permission of Elsevier)

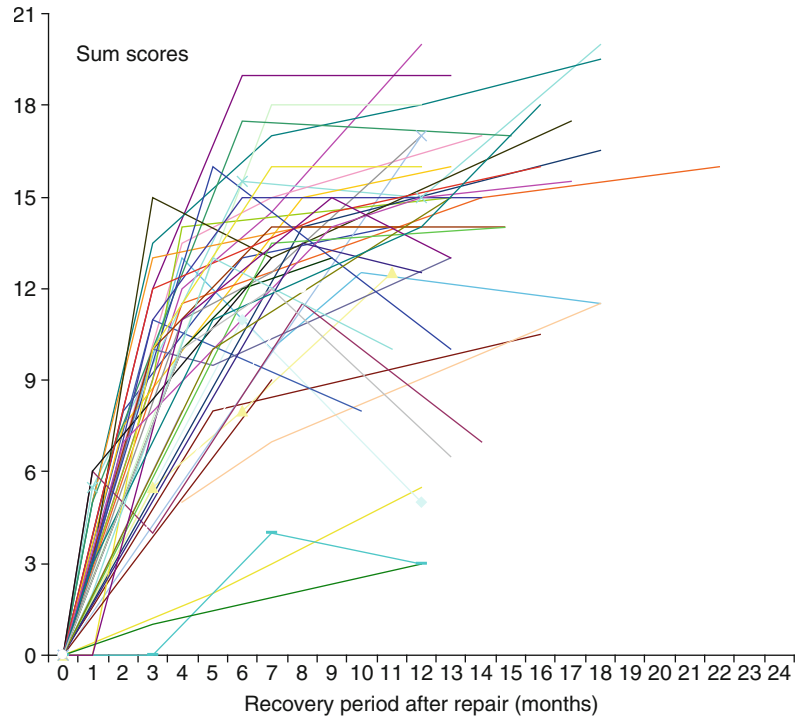
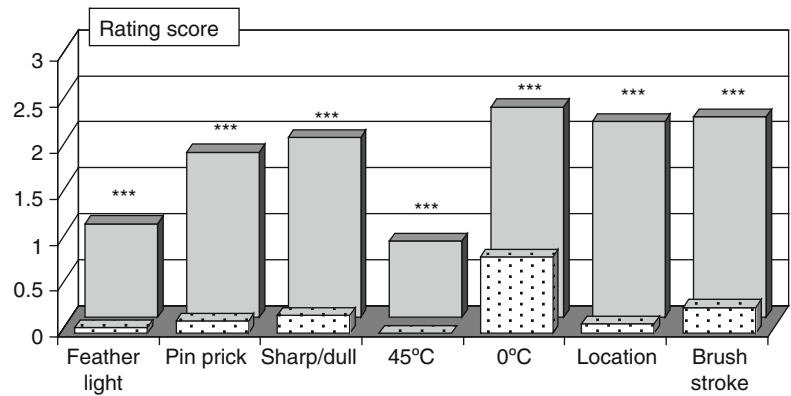


Fig. 19.11 Mean rating scores preoperatively (*light shading*) and at the final examination (*dark shading*) for responses to specific stimuli; feather light touch, pinprick, point/dull discrimination, warm, cold, location of touch, and brush stroke direction. Significant recovery for all tests, *** $p < 0.001$ (From Hillerup and Stoltze [21]; reproduced with kind permission of Elsevier)



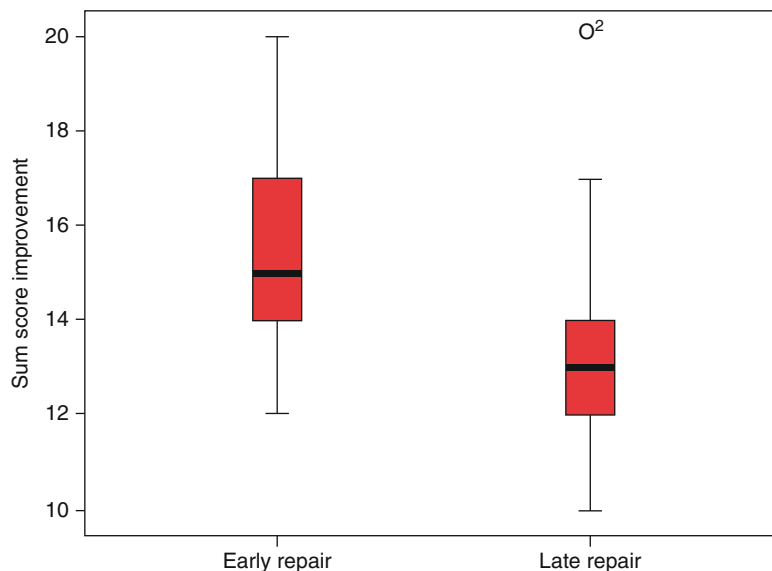
The responses to all stimuli recovered significantly, as shown in Fig. 19.11. Feather light touch and heat (45 °C) was perceived only vaguely, and the final rating score for these stimuli averaged 1 (perception of stimulus without discrimination of its quality). The remaining tests (pinprick, sharp/dull discrimination, cold, location of touch, and brush stroke direction) were generally recognised, and a score of 2 was a typical rating (perception with ability to differentiate less clear than normal). However, none of the

patients regained completely normal neurosensory perception. The recovery expressed as sum score improvement correlated well with the patients subjective ratings ($r=0.58, p < 0.01$).

19.2.5.3 Two-Point Discrimination

A two-point discrimination threshold could only be determined in one patient preoperatively (at 15 mm), but in the other patients was ≥ 20 mm. After nerve repair, 25 patients still had a threshold of ≥ 20 mm. The remaining 41 patients had

Fig. 19.12 Box plots showing improvement of sum scores in patients operated on within 6 months of injury (early repair) or after 6 months (late repair) $p < 0.01$. Data shown for 48 patients with a final sum score > 9 (From Hillerup and Stoltze [21]; reproduced with kind permission of Elsevier)



a mean threshold value at the final examination of 9.9 mm. For comparison, the threshold on the uninjured side was 5.6 mm (sd. 1.8, $p < 0.0001$).

19.2.5.4 Pain Perception

Preoperatively, in 19 patients (28 %) pain or a pain-like sensation was perceived on pinching the affected lateral margin of the tongue. Fifty-five patients (82 %) showed pain perception at the final examination, revealing a significant recovery ($p < 0.001$).

19.2.5.5 Factors Influencing Recovery

When analysing the effect of age or gender on neurosensory recovery, no significant effect was found. The delay between injury and repair surgery also did not seem to influence the magnitude of recovery when considering the whole sample of 67 patients. However, assuming that other factors might be more significant determinants for poor recovery in unsuccessful cases, a test on *successful* cases (final sum score > 9 , follow-up > 11 months, $n = 48$) was performed. This revealed that the early repair cases (operated on within the first 6 months after the injury) showed a mean improvement of sum score of 15.9 (SD 2.4, min. 12, max. 20) and thus a better recovery than patients with later repair (mean improvement of

sum score = 12.6 (SD 3.1, min. 2, max. 19), $p \sim 0.002$) (Fig. 19.12). The age of the patient still had no effect in this subgroup of patients ($p \sim 0.13$).

19.2.6 Discussion on Outcome of Lingual Nerve Repair

This discussion will be structured to consider the five questions posed in the introduction.

19.2.6.1 Is Lingual Nerve Repair Worthwhile?

The extent of sensory recovery after our method of LN repair was variable, but the overall results were good. In the UK series, there were highly significant improvements in the pooled responses to light touch, pinprick, and gustatory stimuli (including electrogustometry), and highly significant reductions in the two-point discrimination thresholds. The proportion of patients who responded to most or all light touch stimuli increased from 0 to 51 % after the repair, and the proportion of patients who responded to most or all pinprick stimuli increased from 34 to 77 %. This improved level of sensation resulted in a significant reduction in the number of patients

who reported accidental tongue biting, although persistent speech and taste disturbances were reported in 57 % of the patients. Most patients considered the operation worthwhile with a median subjective score of 7 on a scale of 0–10, and this equates closely with the mean score of about 2.5 on a scale of 0–4 reported for ‘global satisfaction’, by Zuniga et al. [72].

In the series of patients treated in Denmark, the outcomes were very similar. The proportion of patients with pain perception increased from 26 to 82 % after repair, the median sum score for responses to a range of seven stimuli increased from 2 to 14 (scale ranging from 0 to 21), and this correlated well with the patients’ subjective ratings. Susarla et al. [64] showed a strong correlation between neurosensory function and patient satisfaction after repair, and it is interesting to note the striking similarity between the profile of sum scores in the Denmark study, and patient subjective scores in the UK study (Figs. 19.7 and 19.9).

Comparison between our results on outcome and those reported in other studies is difficult because of variations in methods, but there are some similarities. Riediger et al. [43] indicated good or excellent recovery (with recovery of ‘protective sensitivity’) in 44 % of 16 patients who had repair by direct suture. Rutner et al. [54] reported that 90 % of their 20 patients had some improvement in neurosensory function after repair using a range of different methods. LaBanc and Gregg’s large retrospective multicentre study [27] reported that 80 % of patients could detect light touch stimuli from a von Frey hair or camel-hair brush more than 80 % of the time, but this type of study poses particular difficulties in observer consistency. A more recent retrospective review of 222 lingual nerve repairs reported complete or useful recovery of sensory function in 90.5 % of patients, although this population included injuries with a range of different aetiologies, and repaired using a range of different methods [2]. Retrospective reviews of LN repairs undertaken during two periods at the Massachusetts General Hospital reported that 81 % [65] and 75 % [13] of patients gained ‘functional sensory recovery’.

To summarise the data from the present and other studies, it seems clear that LN repair using

direct reapposition by epineurial suture is a worthwhile procedure for most patients. The results seem to be better than those reported after other methods of repair such as nerve grafting [19, 36, 39], artificial conduits [41], or external neurolysis [5]. Nevertheless, the outcome of nerve repair is still not ideal as some patients do not improve, speech and taste sensation may remain affected, and recovery is rarely, if ever, complete.

19.2.6.2 Do Some Neurosensory Functions Recover Better than Others?

In the UK series, our results provided little indication of different levels of recovery for different sensory modalities. Experiments in laboratory animals have suggested this possibility, since large diameter nerve fibres seem to regenerate more successfully than small diameter fibres [9], and specific functional groups are associated with a particular range of fibre sizes. This may explain the poor recovery of the small diameter gustatory fibres in our laboratory experiments [45, 56], although it could also have occurred because few of this small population would be likely to encounter an appropriate endoneurial sheath in the distal nerve stump and be guided to a suitable taste bud receptor site. In view of this, we were slightly surprised to find the presence of some responses to gustatory stimuli in 62 % of our patients after repair. This contrasts with the results of Riediger et al. [43] who found recovery of taste sensation in only one of their patients but is consistent with the reports of Hillerup et al. [22] and Zuniga et al. [71] who reported some recovery of taste. The later report of Zuniga et al. [72] recorded return of gustatory responses in five of ten patients, which is similar to our results. The reduction in the number of patients who had fewer fungiform papillae on the side of injury after repair is a physical expression of the reinnervation by gustatory fibres and has been reported previously [48, 71].

A higher proportion of our patients responded to pinprick (painful) stimuli than light touch stimuli, in both the UK and Denmark series. It is unlikely that this indicates better regeneration of

nociceptive fibres than low-threshold mechanoreceptive fibres and probably merely reflects the higher intensity of the pinprick stimuli. Similarly, in the Denmark study, the stimulus most likely to be detected after repair was a 0 °C cold stimulus, and this may have resulted from the high intensity of this stimulus rather than the preferential regeneration of cold sensitive fibres. Conversely, the Denmark study found that the perception of feather light touch and warm stimuli showed the weakest recovery. Previous laboratory investigations have shown that, even after long recovery periods, reinnervated mechanoreceptors have reduced levels of sensitivity [29] and may, therefore, respond only to higher intensity stimuli. On the tongue, the reinnervated receptors may fail to respond to the 20 mN von Frey hair used in the UK study [46].

A number of other changes in the characteristics of regenerated nerve fibres have been reported in laboratory studies on both trigeminal and other peripheral nerves. These include alterations in the number and diameter of myelinated and non-myelinated axons in the proximal and distal nerve stumps [23–25], changes in conduction velocities, and alterations in mechanoreceptive fields [25, 44–46]. In view of these changes, it is not surprising that patients do not regain normal sensation after reinnervation of the tongue and continue to report some abnormalities. LaBanc and Gregg [27] noted that despite evidence of recovery, some patients still complained of ‘numbness,’ and in both the UK and Denmark studies, no patient reported completely normal sensation after nerve repair surgery.

19.2.6.3 Does Nerve Repair Surgery Reduce Dysaesthesia?

In both the UK and Denmark studies, nerve repair resulted in no significant change in the number of patients who reported pain or spontaneous paraesthesia. This is surprising since all surgeons (PPR, KGS, SH) had the impression that the symptoms of dysaesthesia were reduced by the operation. Unfortunately, neither assessment protocol included any attempt to quantify the level of these symptoms, but other studies have clearly indicated a reduction. Gregg [15] has reported a 49 %

reduction in severity of pain in 31 patients after LN repair and indicated that the results seemed to vary according to the nature of the sensory disorder. Furthermore, the retrospective multicentre study by LaBanc and Gregg [27] suggested that repair resulted in a 30 % reduction in pain levels in 67.5 % of patients with hyperaesthesia. Interestingly, Pogrel and Kaban [39] reported uniformly excellent results as far as elimination of dysaesthesia was concerned, and it is difficult to explain this apparent difference in outcomes.

It has been our experience that the treatment of dysaesthesia after LN injury remains one of the most difficult clinical management problems. Pain was reported preoperatively by 30 % of the UK patients and 19 % of the Denmark patients, and the low incidence of LN dysaesthesia reported in one study is surprising [73]. The aetiology of this complex group of sensory disorders remains uncertain [10, 51], but our animal studies have shown the development of persistent spontaneous neural activity from a nerve injury site, together with mechanical sensitivity of the damaged axons [6, 7, 69]. This is consistent with the observation that palpation over the site of nerve injury evoked a sensation in the tongue in 58 % of the UK patients and 82 % of the Denmark patients, and a study by Zuniga et al. [73] noted ‘triggers’ in 76 % of their patients with a LN injury. As this sign could still be evoked in 55 % of the UK patients (and 76 % of the Denmark patients) after repair, it suggests that there are still many mechanosensitive axonal sprouts trapped in scar tissue in this region. This could result in part from inadequate excision of a neuroma at the time of repair, since it is difficult to differentiate between the tail of a spindle-shaped neuroma and a normal fascicle. However, even after the best anastomosis, it is likely that some regenerating axons will not regain continuity with the distal stump and will form a new neuroma in continuity.

19.2.6.4 Is Early Repair More Effective than Late Repair?

Several papers have suggested that late repair is followed by a poorer outcome than early repair [36, 39], and Riediger et al. [43] were sceptical

about repair undertaken more than 12 months after the injury. Meyer [34] reported 90 % success if the repair was undertaken within 3 months, reducing to 10 % success by 12 months, although the nature of his analysis is unclear. In a subsequent report of an expanded dataset from the same group [2], outcome was classified on a simple scale that surprisingly defined 66 % of their patients as gaining 'complete return of sensation'. The authors calculated that 94 % of their patients gained 'useful sensory recovery' when repair was undertaken within 6 months of the injury, but only 85.4 % gained the same level of improvement if repaired later than 6 months after injury. In a similar evaluation of 64 patients, Susarla et al. [65] reported that 'functional sensory recovery' was achieved in 93 % of patients who had repair within 90 days of the injury, compared with 78 % of subjects who had a later repair. This difference was not significant although recovery was achieved more rapidly in the early repair group. Furthermore, as more than one type of surgical procedure was undertaken and the groups were poorly matched, it is difficult to draw clear conclusions. A more recent study from the same group found no correlation between early repair and any positive outcome measurement [13], and Rutner et al. [54] have made similar observations.

In the UK series of patients, there was no significant correlation between repair delay and any measure of outcome. The Danish study also found no correlation when evaluating the whole group, but when those patients with very poor recovery were excluded (where other factors are likely to have been involved, see below), there were better outcomes with early repair. The results of animal studies are variable but generally agree that early repair and regeneration should be more effective, in that both central and peripheral degenerative changes will be limited [59, 60]. A likely explanation for the discrepancy between different clinical studies is that when a large population is studied, other factors are dominant and may mask this effect. However, for an individual patient, early repair probably has the potential to produce the most optimal result.

Arguably, this debate is of limited importance as few would dispute that early referral to a centre that manages trigeminal nerve injuries is appropriate and that surgical intervention should be undertaken as soon as it is clear that there will not be satisfactory spontaneous recovery [52]. The difficulty is the timing of that decision, so as to avoid unnecessary surgery in patients who would recover adequate sensation spontaneously, whilst also avoiding a long period of monitoring that could hamper the healing potential. Our Denmark data suggest that repair within 6 months after the injury may be associated with better recovery than later repair, so should not be postponed. Equally, our present and previous [48] results, and those of others, clearly show that later repair is considered to be worthwhile, so this option should not be denied on the basis of late presentation.

19.2.6.5 Do Other Factors Influence the Outcome?

It is inevitable that the extent of initial nerve injury will have a major impact on the outcome, and this relationship has led to the commonly used classifications of nerve injury (e.g., Sunderland [63]). As most trigeminal nerve injuries are 'closed' (or unobserved injuries) and only become apparent postoperatively, an understanding of the type of physical injury cannot be used to provide patients or clinicians with a prediction of outcome. Most injuries are likely to have been caused by the surgical bur, and damage may vary from partial nerve transection through to complete division and may have been complicated by extensive stretching of the nerve stumps, leading to intraneural fibrosis along a substantial section of nerve. The early recovery after most crush injuries allows this group to be distinguished [4], but other injury factors remain largely unknown, even at the time of repair. The observation that better preoperative sensory function is associated with more rapid return of function after repair [13] is consistent with the influence of the extent of initial injury. This variable has also impeded attempts to identify other factors that might influence the outcome. For example, the inconsistency between compari-

sons of early and late repair, as described above, probably results from the heterogeneous nature of the injuries in the study populations. Similarly, our Denmark study showed no effect of patient age (or gender) on recovery, whereas Bagheri et al. [2] reported a progressive decrease in the chance of recovery of patients over 45 years old, and Fagin et al. [13] also showed that age was a predictor of outcome. A range of other factors seem likely to have an effect, such as size of the neuroma, length of nerve excised, tension on the anastomosis, quality of the repair, and alignment of the fascicles, but it may prove extremely difficult to show these potential relationships in clinical studies.

19.3 Outcome of Inferior Alveolar Nerve Surgery

19.3.1 Introduction

There is a surprising paucity of published data on the efficacy of any form of exploration or repair of the inferior alveolar nerve (IAN). As the usual injury site is within the bony mandibular canal, excision of the area of damage, mobilisation of the nerve stumps, and direct reapproximation are not possible unless the defect created is very small. Various alternative approaches have been described, including nerve grafting [40, 42], entubulation [8, 38, 41], or nerve sharing [17, 26]. Other authors describe a ‘cascade’ of options for managing the injury [28]. However, most reports only include small numbers, or data have been combined with those from other nerves, so their value remains uncertain. Rather remarkably, Mozsary and Syers [37] reported ‘complete recovery’ in 20 of 23 patients who had undergone some form of microsurgical reconstruction of the IAN, but they used no form of objective testing. The largest report in the literature is an appraisal using retrospective postal questionnaires of 316 operations on the IAN at seven units in the USA [27]. This included a range of procedures and described an overall success rate of 74 %. More recently, a large retrospective single-centre study on 167 patients

that had undergone a range of procedures reported functional sensory recovery in 81 % [3]. The authors graded outcomes using a single global score, which provides little detail on the level of recovery or relief of symptoms, and the criteria for being adjudged a ‘success’ appear relatively easy to achieve. This may explain why the level of success was apparently the same, whatever surgical procedure was used.

The procedure of IAN decompression was first advocated by Merrill [31], and in subsequent studies on dogs [32], he showed that nerve regeneration was more successful when bone surrounding a crushed nerve was surgically removed. It has since been suggested that bony decompression should be followed by a neurolysis [16] to divide any constricting scar tissue in the epineurium [30]. Useful studies on the outcome of this type of procedure have been published recently by Greenwood and Corbett [14] and Strauss et al. [62]. We have adopted the same approach, and the outcomes illustrated in this section follow surgery undertaken at one centre in the UK, using a consistent method for all patients. Data has been collected prospectively from 25 consecutive patients followed up for at least 1 year, and the results of a series of neurosensory tests performed before and after the operation have been quantified to allow statistical comparisons. These data, together with a review of the relevant literature, will be used to address the following questions:

- Does IAN decompression and neurolysis significantly reduce dysaesthesia?
- Does IAN surgery significantly improve sensation?
- Is the level of improvement obtained worthwhile?

19.3.2 Patients and Methods

The criteria for surgical intervention were as outlined by Robinson et al. [52]: Early intervention (one patient in the present series) was undertaken if a radiograph revealed that a fragment of cortical bone from the roof of the mandibular canal had been displaced inferiorly and was obstructing the inferior alveolar canal; late intervention

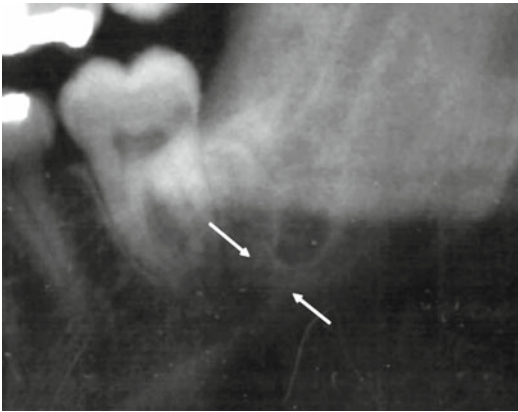


Fig. 19.13 A radiograph taken 23 months after removal of a lower third molar. The mandibular canal is disrupted with little evidence of continuity either radiographically or at the time of subsequent decompression. The *white arrows* indicate an area of bone formation across the site of the original canal with a cortical outline to the proximal section (From Robinson et al. [52]; reproduced with kind permission of Elsevier)

was undertaken if patients had either a substantial neurosensory deficit or persistent dysaesthesia [16]. Patients with a minor degree of hypoesthesia or mild paraesthesia were advised against any surgical intervention. Furthermore, all operated patients had radiographic evidence (usually on a sectional dental panoramic tomogram) of disruption of the mandibular canal at the site of injury (Fig. 19.13).

The IAN injuries were caused by third molar removal ($n = 18$), first molar removal (1), impacted premolar removal (2), implant placement (2), cyst removal (1), or management of a fractured mandible (1). There were 4 men (aged 22–43 years) and 21 women (aged 34–62 years), and the injuries were on the left side in 14 patients and on the right side in 11 patients. The delay before surgery ranged from 2 months (the one early repair) to 96 months, with a mean of 28.4 ± 24.8 (SD) months.

19.3.2.1 Surgical Procedure

All of the procedures were performed under general anaesthesia by one of the two UK authors (PPR, KGS), and the technique was similar for each patient. Using an intraoral approach, access was gained to a 2–3 cm length of the mandibular

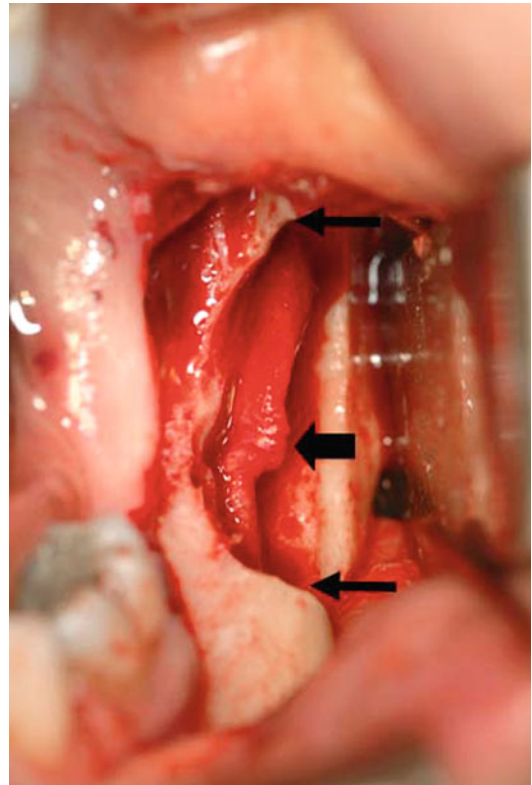


Fig. 19.14 A surgical picture showing exploration and decompression of the left inferior alveolar nerve. The *small arrows* indicate the site of the anterior and posterior cortical cuts made before a segment of the buccal plate was removed. The *large arrow* indicates a neuroma that extended laterally and towards the alveolar crest from the neurovascular bundle and the bundle narrows distal to this point (From Robinson et al. [53]; reproduced with kind permission of Wiley)

canal at the site of injury by removing a segment of buccal plate: The anterior, posterior, and superior limits were defined by cuts through the cortex with a bur, a groove scored at the level of the canal, and the segment removed with a chisel and discarded. This approach is similar to that described by Miloro [35] but does not extend to the lower border of the mandible. More bone was then carefully removed with a large round diamond bur (approximately 4 mm diameter), or ultrasonic curette, together with dental excavators, until the neurovascular bundle could be gently eased laterally from the canal for examination (Fig. 19.14). Under the operating

microscope, any lateral neuroma was excised (without dividing the nerve trunk) and constricting scar tissue at the site of injury released by one or more longitudinal incisions through the epineurium (neurolysis). One or more sutures were inserted to realign the nerve in six patients, using 8/0 monofilament polyamide (Ethilon, Ethicon Ltd, UK). In one patient, the procedure was combined with the removal of a dental implant that had caused the IAN injury. The wound was closed with polyglactin 910 (Vicryl), and all patients were given prophylactic antibiotics and dexamethasone (8 mg preoperatively and 12 h postoperatively).

19.3.2.2 Neurosensory Assessment

In all patients, sensation on the affected side of the lower lip and chin was assessed both preoperatively and at 12 months or more (mean: 16.63, range: 12–41 months) postoperatively. Initially each patient was asked a series of standard questions from a proforma including the following: whether the affected area was completely or partially numb; whether it was hypersensitive (hyperaesthesia); what their subjective level of sensation was on a scale of 0 % (numb) to 100 % (normal); whether they could detect thermal stimuli normally; whether they had pain or tingling (paraesthesia) either spontaneously or initiated by touching, moving, or thermal stimuli to the area; whether they tended to bite their lip by accident; and whether they thought that their speech was affected. They were also asked to complete three visual analogue scales (VAS) indicating the level of pain, tingling, and discomfort from the affected area. Clinical examination determined whether palpation of the mucosa overlying the injury site (such as the alveolar crest at the site of tooth removal) evoked any sensations in the affected lip or chin. A series of sensory tests [49] were then undertaken in a quiet room with the patient's eyes closed. These determined responses to light touch stimuli with a von Frey hair, pinprick (pain) sensation, and two-point discrimination thresholds. Full details of the methods used are described elsewhere [49, 53].

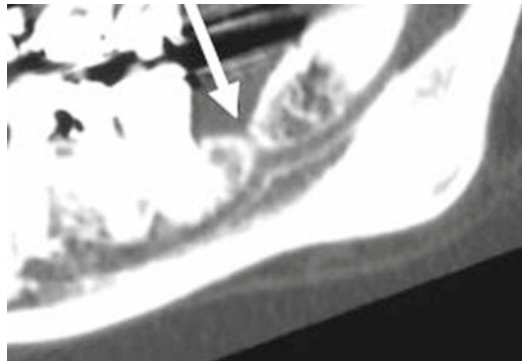


Fig. 19.15 A CT scan showing displacement of the mandibular canal toward the alveolus at the site of previous third molar removal. The *arrow* indicates the site of a soft tissue connection between the neurovascular bundle and the overlying mucosa (Courtesy of Mr. N. Whear. From Robinson et al. [53]; reproduced with kind permission of Wiley)

Finally, at the last testing session only, the patients were asked to provide a subjective score to the value of the operation on a scale of 0–10 (ranging from a *waste of time* to a *perfect outcome*). Statistical comparisons between the results of tests at different stages were made with a paired t test, chi-square test, or Fisher's exact test, as appropriate.

19.3.3 Outcome of IAN Decompression and Neurolysis

19.3.3.1 Clinical Observations

The extent of disruption of the inferior alveolar neurovascular bundle seen at operation varied widely; in some patients with significant symptoms, the nerve seemed macroscopically intact, whereas in others it was markedly narrowed, scarred, or the canal was largely obstructed by bone. In several patients who had sustained the IAN injury during third molar removal, the operation revealed a band of soft tissue that passed through the socket, joining the neurovascular bundle and overlying mucosa. Some predecompression radiographs or CT scans suggested that the neurovascular bundle had been drawn towards the surface at this point (Fig. 19.15).

Table 19.2 A comparison between the responses to questions asked preoperatively and at the final test for patients who had undergone inferior alveolar nerve decompression and neurolysis

| | Preoperatively | Postoperatively | <i>p</i> value |
|--------------------------------------|-------------------|--------------------|----------------|
| Complete numbness? | 4 (16 %) | 0 | 0.055 |
| Partial numbness? | 21 (84 %) | 25 (100 %) | 0.055 |
| Hypersensitivity? | 11 (44 %) | 11 (44 %) | 1 |
| Mean subjective level of sensation | 35 % (range 0–85) | 56 % (range 5–100) | 0.01 |
| Can detect thermal stimuli normally? | 3 (12 %) | 9 (36 %) | 0.046 |
| Speech affected? | 11 (44 %) | 8 (32 %) | 0.31 |
| Bite lip by accident? | 15 (60 %) | 12 (48 %) | 0.21 |

Data are number (%) of patients ($n=25$)

Palpation of the mucosa overlying the injury site evoked a sensation in the affected lip or chin in five patients prior to decompression. This implies that some damaged axons from the IAN had regenerated inappropriately through the tooth socket or bony defect and had reinnervated the overlying mucosa. In one unusual example where the injury had been caused during removal of an impacted lower second premolar, palpation in the *lingual* sulcus evoked a sensation in the lower lip, and the operation revealed a bony defect between the neurovascular bundle and floor of the mouth. After decompression and neurolysis, palpation of tissues overlying the injury site evoked a sensation in the lip or chin in just two patients, neither of whom had this symptom preoperatively.

19.3.3.2 Responses to Questions

A comparison between the responses to questions asked preoperatively, and at the final test is shown in Table 19.2. All patients continued to complain of partial numbness at the final post-decompression test. The same number of patients reported hypersensitivity of the lip and chin pre- and post-decompression, but some of these 11 patients had changed; 4 patients with hypersensitivity preoperatively lost that symptom, but 4 others developed that symptom postoperatively. There was a significant increase in the subjective level of sensation reported by the patients (a mean improvement of 21 %), and more of them indicated that they could detect thermal stimuli

normally. There was a small but insignificant reduction in the number of patients who thought that their speech was affected by the sensory deficit or that it caused them to bite their lip by accident.

The reported presence of pain or tingling, either spontaneously or initiated by touch, movement, or thermal stimuli, is shown in Fig. 19.16. This shows that the number of patients with these symptoms was usually lower post-decompression, the only exception being an increase in the number of patients with hot-evoked pain or cold-evoked tingling. The number of patients with *no* spontaneous or evoked pain increased from 9 to 16 post-decompression ($p=0.048$), and the number with no tingling increased from 2 to 4 ($p=0.33$).

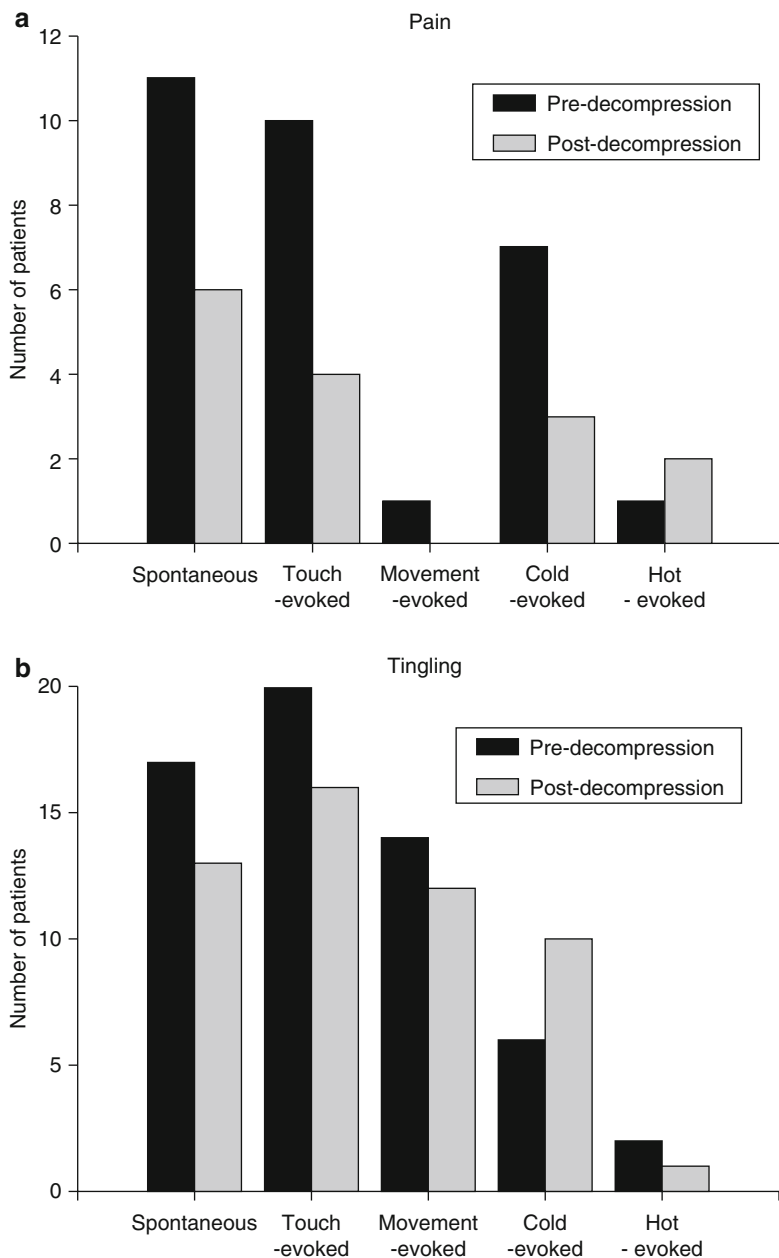
19.3.3.3 VAS Scores

The pre- and post-decompression VAS scores for pain, tingling, and discomfort are shown in Fig. 19.17. All three parameters were reduced by decompression, with a mean reduction of approximately 12 % for pain, 27 % for tingling, and 17 % for discomfort. However, due to the wide variation between patients, this difference was only statistically significant for the level of tingling ($p=0.009$).

19.3.3.4 Neurosensory Tests

On the unaffected side of the lip and chin, the patients were all able to detect light touch stimuli with a 20 mN von Frey hair, pinprick stimuli of

Fig. 19.16 The number of patients who reported pain (a) or tingling (b) either spontaneously, or evoked by touching, moving or thermal stimuli to the affected area. Data are shown for the preoperative test and the final test post-decompression (From Robinson et al. [53]; reproduced with kind permission of Wiley)



up to 150 mN, and two-point discrimination thresholds usually ranged from 2 to 4 mm on the lip and 6–10 mm on the chin.

The ability of patients to detect light touch stimuli on the side of injury improved after decompression. Using a rating scale (0, no

response; 1, occasional response; 2, response in most areas; 3, responses apparently similar to those on the unaffected side), the mean pre-decompression score was 1.96 ± 0.98 (SD) but was significantly higher post-decompression (2.48 ± 0.59 , $p=0.003$, paired t test). Similarly,

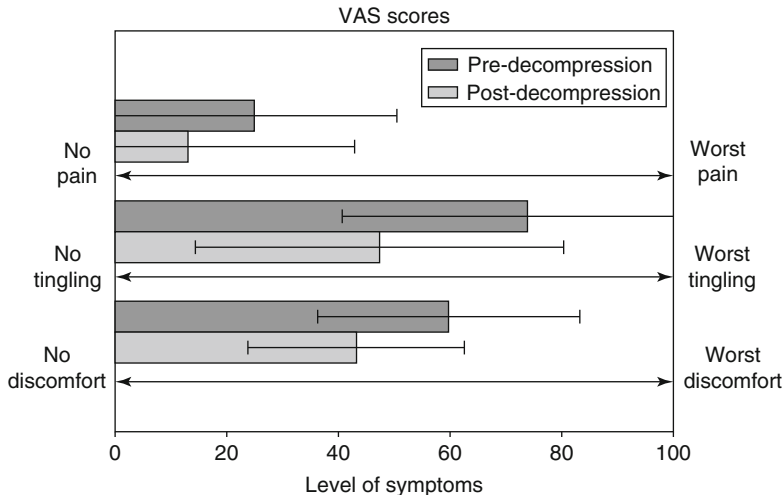


Fig. 19.17 Mean (\pm SD) VAS scores for the level of pain, tingling, and discomfort, measured pre- and post-decompression. An absence of symptoms would be scored at the left end of the scale and the worst imaginable (pain, discomfort) or continuous (tingling) symptoms at the right

end. There was a significant reduction in tingling post-decompression ($p=0.009$, paired t test), but the reductions in pain ($p=0.07$) and discomfort ($p=0.051$) were not significant (From Robinson et al. [53]; reproduced with kind permission of Wiley)

scores for responses to pinprick stimuli also improved after the surgery (pre-decompression, 1.88 ± 0.72 ; post-decompression, 2.28 ± 0.46 , $p=0.015$). Two-point discrimination thresholds for all of the patients pre- and post-decompression are shown in Fig. 19.18, for both the lip and chin. This reveals a shift towards lower thresholds post-operatively and is confirmed by the mean values (Lip: pre-decompression, 11.2 ± 5.1 mm; post-decompression, 8.4 ± 4.0 mm, $p=0.006$. Chin: pre-decompression, 13.3 ± 4.2 mm; post-decompression, 11 ± 5.6 mm, $p=0.03$). Despite this threshold reduction (a mean improvement of approximately 21 %), values remained substantially higher than on the unaffected side.

19.3.3.5 Subjective Assessment

The patients' subjective assessment of the value of the operation is shown in Fig. 19.19. The scores covered the full range from 0 to 10, and the median score was 7.

19.3.4 Discussion on Outcome of IAN Decompression and Neurolysis

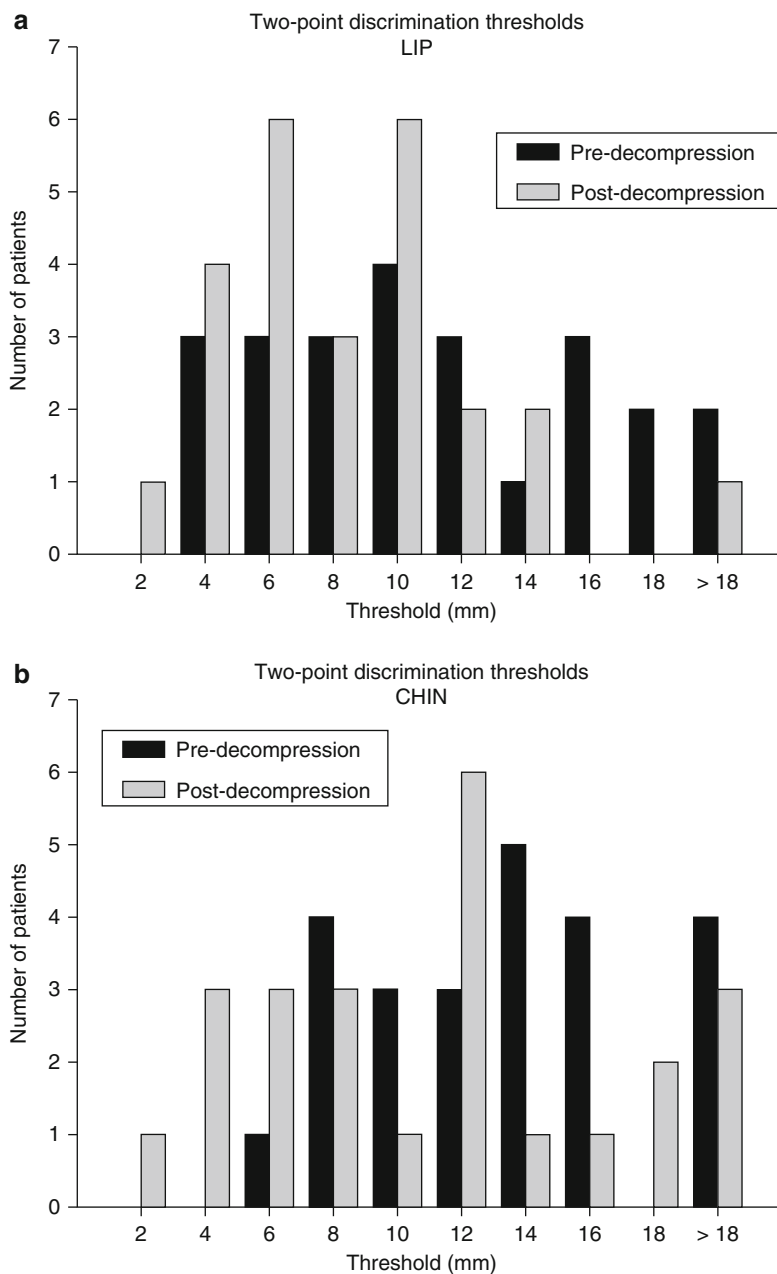
This discussion will be structured to consider the three questions posed in the introduction.

19.3.4.1 Does IAN Decompression and Neurolysis Reduce Dyaesthesia?

In our UK study, pain from the area of sensory disturbance was reported prior to decompression in 64 % of patients, spontaneous tingling in 68 %, and hyperaesthesia in 44 %. The operation appears to have reduced dyaesthesia, as significantly fewer patients (36 %) had pain post-decompression, and the number with evoked pain or tingling was lower in all categories except for hot-evoked pain and cold-evoked tingling. These latter results may have arisen because of the increased innervation density in the peripheral tissues, i.e., more nerve fibres had regenerated, but more were behaving abnormally. Furthermore, the VAS scales for pain, tingling, and discomfort all showed a reduction in symptoms post-decompression, although this was only significant for the level of tingling.

Previous studies on the effect of IAN surgery have provided little information on changes in the incidence or level of dyaesthesia. Gregg [16] expressed reservations about a surgical approach to the management of some forms of dyaesthesia resulting from IAN injury and specifically discouraged early intervention. Furthermore, our UK study on the outcome of *lingual* nerve repair

Fig. 19.18 The two-point discrimination thresholds on the lower lip (a) and chin (b) measured pre- and post-decompression. Because of the size of the area being tested, a threshold of more than 18 mm could not be reliably assessed, and all these results have been placed in the >18 mm column. Both charts show a shift of patients to the left (lower thresholds) post-decompression (From Robinson et al. [53]; reproduced with kind permission of Wiley)

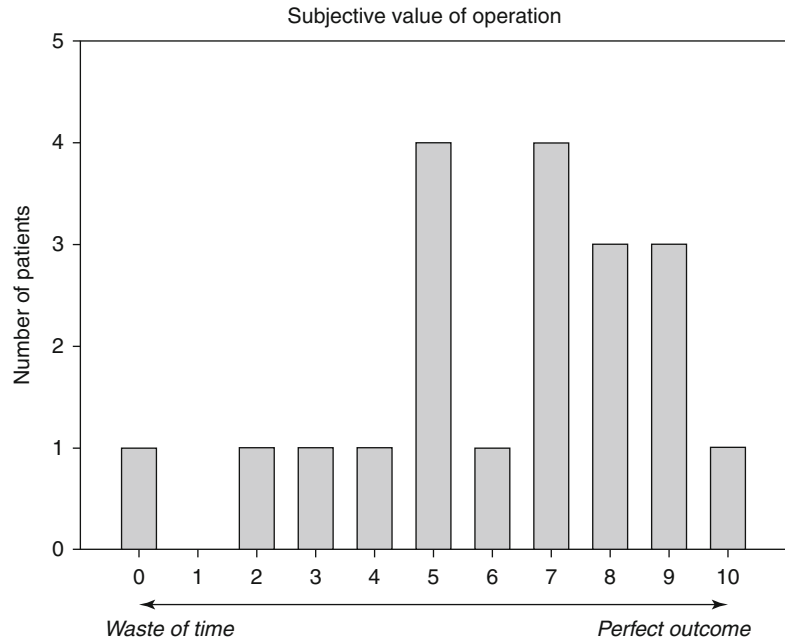


(described above) failed to show a significant reduction in the number of patients with dysaesthesia, although the level of symptoms often declined. The positive effects of IAN decompression and neurolysis in this study are therefore encouraging. Pogrel and Kaban [39] reported that most of their patients gained relief from dysaesthesia after trigeminal nerve repair, although they

were reporting on a mixed population of IAN and LN procedures. In the large cohort reported by Bagheri et al. [3], 66.6 % complained of pain (with or without numbness) preoperatively, and the presence of pain did not appear to affect the outcome.

A question frequently asked by patients considering surgical intervention after a nerve injury is

Fig. 19.19 The overall value of the operation as assessed subjectively by the patients on a scale of 0 (a waste of time) to 10 (a perfect outcome) ($n=20$) (From Robinson et al. [53]; reproduced with kind permission of Wiley)



‘can the operation make my symptoms worse?’ This is a sensible question for a patient who has already suffered one unfortunate complication. In general, a deterioration in symptoms would be an uncommon outcome, and patients free of dysaesthesia preoperatively usually remain free of dysaesthesia postoperatively. Greenwood and Corbett [14] indicated that none of their 12 patients had a worsening of symptoms after IAN neurolysis, and Bagheri et al. [3] indicated that no patient who did not have pain as a major complaint before nerve repair developed it after repair. However, as indicated above, enhanced regeneration of damaged nerve fibres may give rise to more abnormally behaving reinnervated terminals peripherally. Indeed, patients should expect paraesthesia during the process of reinnervation. Other evidence of a potentially unfavourable outcome was found when recording the number of patients who described hypersensitivity (hyperaesthesia) of the affected skin. Whilst the number of patients with this symptom was unchanged by the operation, four patients (16 %) previously without hypersensitivity developed it postoperatively. It would be appropriate to warn patients of this possibility, although unusual, when they are considering nerve repair surgery.

19.3.4.2 Does IAN Surgery Improve Sensation?

The present study has provided clear evidence that decompression and neurolysis can improve sensation. The patients’ subjective assessment of the level of sensation was significantly higher post-decompression, there were significantly improved responses to neurosensory testing with light touch and pin prick stimuli, and two-point discrimination thresholds were reduced. However, the level of these improvements was small, and significant improvements were based on comparisons for the whole population pre- and post-surgery. For an individual patient, the outcome was variable, and some patients did not improve.

Previous studies on IAN surgery have also shown improvements in sensation. In an early study, Riediger and colleagues [43] found ‘good’ or ‘excellent’ recovery in 80 % of their patients who had exposure and direct suture repair of the damaged nerve but in only 28 % of patients who had an interpositional sural nerve graft. In a study confined to decompression and neurolysis, Greenwood and Corbett [14] reported that 5 of their 12 patients demonstrated an improvement in sensation, two regaining ‘normal’ sensation.

Similarly, Strauss and colleagues [62] made statistical comparisons between pre- and postoperative data in 28 patients and found significant improvements in the results of all sensory tests, and Bagheri et al. [3] found significant improvements in global scores. Although direct comparison between studies is difficult because of variations in methods and criteria, the general conclusion is that sensation can be enhanced in some patients by decompression and neurolysis.

19.3.4.3 Is the Level of Improvement Obtained Worthwhile?

The subjective scores of the operation value indicate that patients usually considered it to be worthwhile, as the median score was seven out of ten. Within this group, however, were four patients with a score of less than five, including one with a score of 0. It is not possible to predict which patients will have a successful outcome preoperatively, so all patients must be appraised of the variable results achieved. Strauss and colleagues [62] reported that in their study of 28 patients, 10 reported significant improvement, 15 reported mild improvement, and 3 had no improvement; these results appear similar to ours. Susarla and colleagues [64] showed that after trigeminal nerve repair, there was a strong correlation between patient satisfaction and the results of sensory tests, but only 2 of their 19 patients had sustained an IAN injury.

Ziccardi et al. [70] found no significant differences when comparing the outcomes of LN and IAN microsurgery, whilst our observations suggest that IAN decompression and neurolysis produced more modest improvements. The level of improvement could be assessed in our study by determining changes in the various parameters recorded. Thus, there was a mean improvement of 21 % in the subjective level of sensation reported by the patients; a mean reduction of approximately 12 % on the VAS scores for pain, 27 % for tingling, and 17 % for discomfort; and a mean improvement of approximately 21 % in the two-point discrimination thresholds for the lip and chin. Taken together, it therefore seems reasonable to advise patients that the operation could result in a '20 % improvement' in their condition,

although they may have a better or worse outcome. None of our patients regained *normal* sensation, and all continued to describe partial numbness, so patients must be informed of this expectation, however successful the surgery. Our results show that this residual sensory disturbance may also continue to affect their speech, and they may continue to bite their lip by accident. This information allows patients to have realistic expectations and to make an informed judgement on whether or not to proceed. It also helps to ensure selection of only those patients for whom the symptoms are severe and for whom any improvement is worthwhile.

19.3.4.4 Other Observations

It was interesting to note that the patients presenting for this treatment were predominantly female (84 %) and usually middle-aged, and this is consistent with the characteristics of patients referred to a UK trigeminal nerve injury clinic [47]. The high proportion of females is also evident in previous studies, such as those of Greenwood and Corbett ([14]: 75 %), Strauss et al. ([62]: 61 %), Susarla et al. ([64]: 74 %; [66]: 68 %), and Bagheri et al. ([3]: 75 %). There is laboratory evidence for gender differences in susceptibility to the development of nerve injury-induced pain [67], and epidemiological studies show that older females are more likely to suffer from chronic neuropathic pain [68]. There is, therefore, a risk that the trend to remove lower third molars only when they cause symptoms later in life may render female patients more susceptible to the development of dysaesthesia if they sustain a nerve injury. It is also of note that the substantial population of (usually younger) patients in whom the IAN is damaged as a result of mandibular fractures or orthognathic surgery rarely complain of dysaesthesia and rarely seek treatment. Therefore, in addition to patient susceptibility, the nature of the initial injury may be important.

Surprisingly, some patients report an improvement in sensation on the first postoperative day after decompression and neurolysis. Although we did not undertake any sensory tests at that stage, we would not expect any immediate improvement, and it is more likely that the

patients were feeling the benefit of an early reduction in dysaesthesia (sometimes associated with a transient *reduction* in sensation). Similar comments may be made by patients who have undergone LN repair [50].

Most of our patients were assessed and treated surgically at long periods after the initial injury; the mean delay was 28 months and ranged up to 96 months. It is possible that we would have achieved better results with earlier decompression, and the debate regarding early and late intervention is similar to that described above for LN injuries. After IAN decompression and neurolysis, Strauss et al. [62] showed no significant correlation between the delay prior to repair and the extent of recovery. In their cohort of patients that had undergone a range of IAN procedures, Bagheri et al. [3] found a decline in outcomes both with increasing delay and in older patients, particularly over the age of 51 years. Once again, it is possible that, for an individual patient, early surgery has the potential to produce the optimal result, but when a large population is studied, other factors are dominant and mask this effect. Future improvements in outcome are likely to result from improving the potential for regeneration. This might be achieved, for example, by reducing the level of scar formation at the injury site [1], as new scar formation will inevitably follow the neurolysis. Other advances are needed to improve the management of patients with dysaesthesia.

In summary, we conclude that IAN decompression and neurolysis can reduce dysaesthesia and improve sensation and is a worthwhile operation in carefully selected patients who have severe symptoms. Patients should be informed that, on average, there is a 20 % improvement in sensation and symptoms as a result of the operation, and that they will not regain normal sensation. There is a small risk of initiating hyperaesthesia or thermally evoked dysaesthesia in the affected area.

References

- Atkins S, Smith KG, Robinson PP et al (2006) Scarring impedes regeneration at sites of peripheral nerve repair. *Neuroreport* 17:1245–1249
- Bagheri SC, Meyer RA, Khan HA et al (2010) Retrospective review of microsurgical repair of 222 lingual nerve injuries. *J Oral Maxillofac Surg* 68:715–723
- Bagheri SC, Meyer RA, Cho SH et al (2012) Microsurgical repair of the inferior alveolar nerve: success rate and factors that adversely affect outcome. *J Oral Maxillofac Surg* 70:1978–1990
- Blackburn CW (1990) A method of assessment in cases of lingual nerve injury. *Br J Oral Maxillofac Surg* 28:238–245
- Blackburn CW (1992) Experiences in lingual nerve repair. *Br J Oral Maxillofac Surg* 30:72–77
- Bongehiellm U, Robinson PP (1996) Spontaneous and mechanically evoked afferent activity originating from myelinated fibres in ferret inferior alveolar nerve neuromas. *Pain* 67:399–406
- Bongehiellm U, Robinson PP (1998) Afferent activity from myelinated inferior alveolar nerve fibres in ferrets after constriction or section and regeneration. *Pain* 74:123–132
- Crawley WA, Dellon AL (1992) Inferior alveolar nerve reconstruction with a polyglycolic acid bioresorbable nerve conduit. *Plast Reconstr Surg* 90:300–302
- Devor M, Govrin-Lippmann R (1979) Selective regeneration of sensory fibres following nerve crush injury. *Exp Neurol* 65:243–254
- Devor M, Seltzer Z (1999) Pathophysiology of damaged nerves in relation to chronic pain. In: Wall PD, Melzak R (eds) *Textbook of pain*. Churchill Livingstone, London, pp 129–164
- Dodson TB, Kaban LB (1997) Recommendations for management of trigeminal nerve defects based on a critical appraisal of the literature. *J Oral Maxillofac Surg* 55:1380–1386
- Donoff RB, Guralnick W (1982) The application of microneurosurgery to oral-neurological problems. *J Oral Maxillofac Surg* 40:156–159
- Fagin AP, Susarla SM, Donoff RB et al (2012) What factors are associated with functional sensory recovery following lingual nerve repair? *J Oral Maxillofac Surg* 70:2907–2915, <http://dx.doi.org/10.1016/j.joms.2012.03.019>
- Greenwood M, Corbett IP (2005) Observations on the exploration and external neurolysis of injured inferior alveolar nerves. *Int J Oral Maxillofac Surg* 34:252–256
- Gregg JM (1990) Studies of traumatic neuralgia in the maxillofacial region: symptom complexes and response to microsurgery. *J Oral Maxillofac Surg* 48:135–140
- Gregg JM (1995) Surgical management of inferior alveolar nerve injuries (part II): the case for delayed management. *J Oral Maxillofac Surg* 53:1330–1333
- Haschemi A (1981) Partial anastomosis between the lingual and mandibular nerves for restoration of sensibility in the mental area after injury to the mandibular nerve. *J Maxillofac Surg* 9:225–227
- Hausamen JE (1981) Principles and clinical application of micronerve surgery and nerve transplantation in the maxillofacial area. *Ann Plast Surg* 7:428–433

19. Hausamen JE, Schmelzeisen R (1996) Current principles in microsurgical nerve repair. *Br J Oral Maxillofac Surg* 34:143–157
20. Hillerup S (2007) Iatrogenic injury to oral branches of the trigeminal nerve: records of 449 cases. *Clin Oral Investig* 11:133–142
21. Hillerup S, Stoltze K (2007) Lingual nerve injury II. Observations on sensory recovery after micro-neurosurgical reconstruction. *Int J Oral Maxillofac Surg* 36:1139–1145
22. Hillerup S, Hjørting-Hansen E, Reumert T (1994) Repair of the lingual nerve after iatrogenic injury. *J Oral Maxillofac Surg* 52:1028–1031
23. Holland GR, Smith KG, Robinson PP et al (1996) A quantitative morphological study on the recovery of cat lingual nerves after transection or crushing. *J Anat* 188:289–297
24. Holland GR, Smith KG, Robinson PP et al (1996) A quantitative morphological comparison of cat lingual nerve repair using epineurial sutures or entubulation. *J Dent Res* 75:942–948
25. Horch KW, Lisney SJW (1981) On the number and nature of regenerating myelinated axons after lesions of cutaneous nerves in the cat. *J Physiol* 313: 275–286
26. Kaban LB, Upton J (1986) Cross mental nerve graft for restoration of lip sensation after inferior alveolar nerve damage: report of a case. *J Oral Maxillofac Surg* 44:649–651
27. LaBanc JP, Gregg JM (1992) Trigeminal nerve injuries. Basic problems, historical perspectives, early successes and remaining challenges. In: LaBanc JP, Gregg JM (eds) *Oral and Maxillofacial Surgery Clinics of North America: trigeminal nerve injury: diagnosis and management*. W B Saunders, Philadelphia, pp 277–283
28. LaBanc JP, Van Boven RW (1992) Surgical management of inferior alveolar nerve injuries. In: LaBanc JP, Gregg JM (eds) *Oral and Maxillofacial Surgery Clinics of North America: trigeminal nerve injury: diagnosis and management*, vol 4. W B Saunders, Philadelphia, pp 425–437
29. Loescher AR, Robinson PP (1991) Properties of periodontal mechanoreceptors supplying the cat's lower canine at short and long periods after reinnervation. *J Physiol* 444:85–97
30. Mazal PR, Millesi H (2005) Neurolysis: is it beneficial or harmful? *Acta Neurochir Suppl* 92:3–6
31. Merrill RG (1964) Decompression for inferior alveolar nerve injuries. *J Oral Surg Anesth Hosp Dent Serv* 22:291–300
32. Merrill RG (1966) Further studies in decompression for inferior alveolar nerve injury. *J Oral Surg* 24:233–238
33. Merrill RG (1979) Prevention, treatment and prognosis for nerve injury related to the difficult impaction. *Dent Clin North Am* 23:471–488
34. Meyer RA (1992) Applications of microneurosurgery to the repair of trigeminal nerve injuries. In: LaBanc JP, Gregg JM (eds) *Oral and Maxillofacial Surgery Clinics of North America: trigeminal nerve injury: diagnosis and management*. W B Saunders, Philadelphia, pp 405–416
35. Miloro M (1995) Surgical access for inferior alveolar nerve repair. *J Oral Maxillofac Surg* 53:1224–1225
36. Mozsary PG, Middleton RA (1984) Microsurgical reconstruction of the lingual nerve. *J Oral Maxillofac Surg* 42:415–420
37. Mozsary PG, Syers CS (1985) Microsurgical correction of the injured inferior alveolar nerve. *J Oral Maxillofac Surg* 43:353–358
38. Pitta MC, Wolford LM, Mehra P et al (2001) Use of GoreTex tubing as a conduit for inferior alveolar and lingual nerve repair: experience with 6 cases. *J Oral Maxillofac Surg* 59:493–496
39. Pogrel MA, Kaban LB (1993) Injuries to the inferior alveolar and lingual nerves. *J Can Dent Assoc* 21:50–54
40. Pogrel MA, Maghen A (2001) The use of autologous vein grafts for inferior alveolar and lingual nerve reconstruction. *J Oral Maxillofac Surg* 59:985–988
41. Pogrel MA, McDonald AR, Kaban LB (1998) Gore-Tex tubing as a conduit for repair of lingual and inferior alveolar nerve continuity defects: a preliminary report. *J Oral Maxillofac Surg* 56:319–321
42. Rath EM (2002) Skeletal muscle autograft for repair of human inferior alveolar nerve: a case report. *J Oral Maxillofac Surg* 60:330–334
43. Riediger D, Ehrenfeld M, Cornelius CP (1989) Microneurve surgery on the inferior alveolar and lingual nerve with special consideration for nerve replacement. In: Riediger D, Ehrenfeld M (eds) *Microsurgical tissue transplantation*. Quintessence Publishing Co, San Francisco, pp 189–194
44. Robinson PP (1981) The reinnervation of teeth, mucous membrane and skin following inferior alveolar nerve section in the cat. *Brain Res* 220:241–253
45. Robinson PP (1989) The reinnervation of the tongue and salivary glands after lingual nerve injuries in cats. *Brain Res* 483:259–271
46. Robinson PP (1992) The effect of injury on the properties of afferent fibres in the lingual nerve. *Br J Oral Maxillofac Surg* 30:39–45
47. Robinson PP (2011) Characteristics of patients referred to a UK trigeminal nerve injury service. *Oral Surg* 4:8–14
48. Robinson PP, Smith KG (1996) A study on the efficacy of late lingual nerve repair. *Br J Oral Maxillofac Surg* 34:96–103
49. Robinson PP, Smith KG, Johnson FP et al (1992) Equipment and methods for simple sensory testing. *Br J Oral Maxillofac Surg* 30:387–389
50. Robinson PP, Loescher AR, Smith KG (2000) A prospective, quantitative study on the clinical outcome of lingual nerve repair. *Br J Oral Maxillofac Surg* 38:255–263
51. Robinson PP, Boissonade FM, Loescher AR et al (2004) Peripheral mechanisms for the initiation of pain following trigeminal nerve injuries. *J Orofac Pain* 18:287–292
52. Robinson PP, Loescher AR, Yates JM et al (2004) Current management of damage to the inferior

- alveolar and lingual nerves as a result of removal of third molars. *Br J Oral Maxillofac Surg* 42: 285–292
53. Robinson PP, Yates JM, Smith KG (2008) A prospective, quantitative study on the clinical outcome of inferior alveolar nerve decompression and neurolysis. *Oral Surg* 1:35–44
 54. Rutner TW, Ziccardi VB, Janal MN (2005) Long-term outcome assessment for lingual nerve microsurgery. *J Oral Maxillofac Surg* 63:1145–1149
 55. Smith KG, Robinson PP (1995) An experimental study of lingual nerve repair using epineurial suture or entubulation. *Br J Oral Maxillofac Surg* 33:211–219
 56. Smith KG, Robinson PP (1995) The reinnervation of the tongue and salivary glands after two methods of lingual nerve repair in the cat. *Arch Oral Biol* 40: 373–383
 57. Smith KG, Robinson PP (1995) Lingual nerve defect repair by three methods. *J Oral Maxillofac Surg* 53:1052–1062
 58. Smith KG, Robinson PP (1995) The reinnervation of the tongue and salivary glands after lingual nerve repair by stretch, sural nerve graft or frozen muscle graft. *J Dent Res* 74:1850–1860
 59. Smith KG, Robinson PP (1995) An experimental study on the recovery of the lingual nerve after injury with or without repair. *Int J Oral Maxillofac Surg* 24:372–379
 60. Smith KG, Robinson PP (1995) The effect of delayed nerve repair on the properties of regenerated afferent fibres in the chorda tympani. *Brain Res* 691:142–152
 61. Smith KG, Yates JM, Robinson PP (1998) The use of neurotrophic factors to enhance lingual nerve repair. *Br J Oral Maxillofac Surg* 36:228
 62. Strauss ER, Ziccardi VB, Janal MN (2006) Outcome assessment of inferior alveolar nerve microsurgery: a retrospective review. *J Oral Maxillofac Surg* 64:1767–1770
 63. Sunderland S (1951) A classification of peripheral nerve injuries producing loss of function. *Brain Res* 74:491–516
 64. Susarla SM, Lam NP, Donoff RB et al (2005) A comparison of patient satisfaction and objective assessment of neurosensory function after trigeminal nerve repair. *J Oral Maxillofac Surg* 63:1138–1144
 65. Susarla SM, Kaban LB, Donoff RB et al (2007) Does early repair of lingual nerve injuries improve functional sensory recovery? *J Oral Maxillofac Surg* 65:1070–1076
 66. Susarla SM, Kaban LB, Donoff RB et al (2007) Functional sensory recovery after trigeminal nerve repair. *J Oral Maxillofac Surg* 65:60–65
 67. Tall JM, Stuess SL, Cruce WL et al (2001) Gender and the behavioral manifestations of neuropathic pain. *Pharmacol Biochem Behav* 68:99–104
 68. Torrance N, Smith BH, Bennett MI et al (2006) The epidemiology of chronic pain of predominantly neuropathic origin. Results from a general population survey. *J Pain* 7:281–289
 69. Yates JM, Smith KG, Robinson PP (2000) Ectopic neural activity from myelinated afferent fibres in the lingual nerve of the ferret following three types of injury. *Brain Res* 874:37–47
 70. Ziccardi VB, Rivera L, Gomes J (2009) Comparison of lingual and inferior alveolar nerve microsurgery outcomes. *Quintessence Int* 40:295–301
 71. Zuniga JR, Chen N, Miller IJ (1994) Effects of chordal-lingual injury and repair on human taste. *Chem Senses* 19:657–665
 72. Zuniga JR, Chen N, Phillips CL (1997) Chemosensory and somatosensory regeneration after lingual nerve repair in humans. *J Oral Maxillofac Surg* 55:2–13
 73. Zuniga JR, Meyer RA, Gregg JM, Miloro M, Davis LF (1998) The accuracy of clinical neurosensory testing for nerve injury diagnosis. *J Oral Maxillofac Surg* 56:2–8

Guidelines for Diagnosis and Treatment of Trigeminal Nerve Injuries

20

Salvatore L. Ruggiero and Michael Proothi

Injury to the trigeminal nerve is a well-recognized risk associated with certain routine dental and oral surgical procedures. The assessment and management of a patient with a traumatic trigeminal neuropathy requires a logical step-wise approach.

The proper application and interpretation of the various neurosensory tests and maneuvers is critical to establishing an accurate diagnosis. The implementation of a surgical or nonsurgical treatment strategy is based not only on the perceived diagnosis but also a multitude of variables including patient age, timing and nature of the injury, and the emotional or psychological impact.

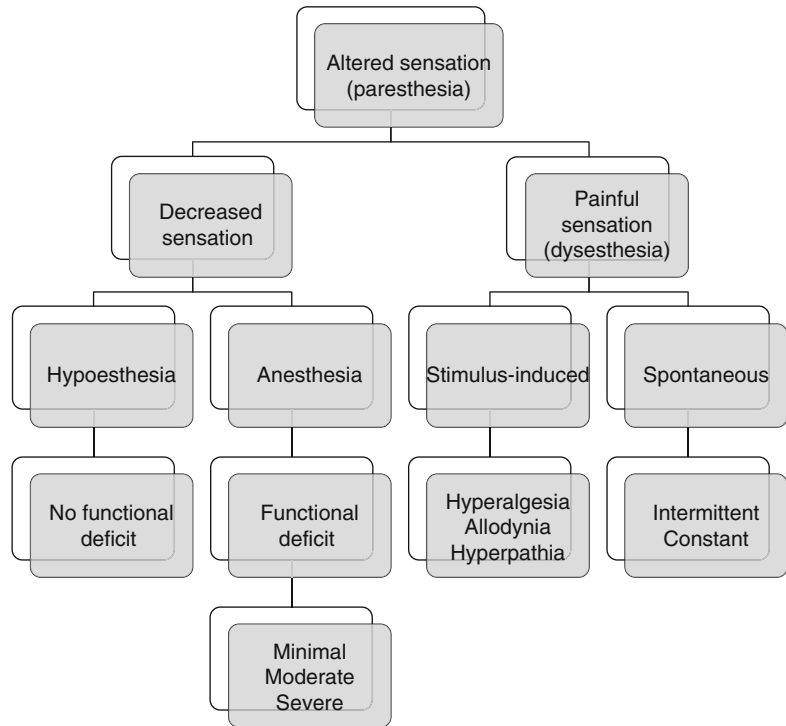
The lingual nerve (LN), inferior alveolar nerve (IAN), and infraorbital nerve (ION) can be injured as a result of iatrogenic mechanisms (odontectomies, implant placement, orthognathic surgery, bone graft/augmentation procedures, apical endodontic surgery, tumor/cyst surgery, local anesthetic injections) or nontreatment-related trauma such as fractures, lacerations, and gunshot wounds. The nature and character of the

neurosensory dysfunction following such injuries is highly variable and not necessarily injury specific. For example, a simple extraction of an erupted mandibular third molar can result in profound sensory dysfunction (anesthesia and/or pain) of the IAN or LN, while the treatment of a severely displaced mandibular angle fracture may only result in a temporary alteration in sensation. This underscores the importance of the initial evaluation and continued reassessment of the neurological status for those patients who present with a traumatic neuropathy of one or more of the terminal branches of the trigeminal nerve.

Similar to other pathological conditions, the assessment and management of a patient with a neurosensory disturbance requires a logical step-wise approach. This includes a detailed history, clinical neurosensory examination, development of a working diagnosis, and a treatment strategy. The initial evaluation and clinical exam is by far the most important since all subsequent exams will be compared to it in order to decide if there has been improvement or deterioration in the neurosensory status over time. The time-honored practice of utilizing algorithms to stratify the many clinical characteristics associated with the patient that presents with a traumatic neuropathy has proven to be very helpful. These algorithms have been developed and revised over time and represent the collective experience of many surgeons with extensive experience in treating these types of injuries [2]. In this chapter we will also utilize this algorithmic approach to organize the various aspects of diagnosis and treatment.

S.L. Ruggiero, DMD, MD, FACS (✉)
M. Proothi, DMD, MD
Stony Brook School of Dental Medicine,
Hofstra LIJ-NorthShore School of Medicine,
New York Center for Orthognathic
and Maxillofacial Surgery,
2001 Marcus Ave, Suite N10,
Lake Success, NY 11042, USA
e-mail: druggiero@nycoms.com;
drproothi@nytcoms.com

Fig. 20.1 Sensory response to nerve injury (Adapted from Zuniga and Essick [63]; with permission)



20.1 Evaluation and Diagnosis

20.1.1 The Patient Interview

Often times the initial evaluation and discussion can be very upsetting for patients when they are asked to describe and reconstruct elements of a disabling disorder that is new to them. A genuinely empathetic approach will be reassuring to the patient and allow the clinician to obtain the necessary information that is required for establishing a diagnosis. During the initial interview it is essential that the timing of the injury be ascertained. Sensory alterations that recover within 4–6 weeks are likely neuropraxia-type injuries that often have an excellent prognosis. Patients with a more prolonged schedule of recovery or improvement (2–3 months) represent a more involved injury (axonotmesis type) where the degree spontaneous recovery can be very variable. Those patients who present with no signs of sensory function return beyond 3 months are indicative of a more serious injury (neurotmesis type) and are associated with poor prognosis for spontaneous recovery. Regardless of the nature of the injury, if

the time from injury exceeds 12 months, the likelihood of a favorable outcome following surgical treatment, if required, is greatly diminished [3]. Information about the mechanism of injury can also be very relevant in certain clinical scenarios. More specifically, while injection-related injuries are rarely addressed with surgical treatment, nerve injuries that occur as a result of endodontic treatment often require surgical treatment as soon as possible [10].

Patients should be initially segregated based on whether their altered sensation is a decreased sensation (anesthesia, paresthesia) or a painful sensation (dysesthesia, allodynia) and patients may experience a wide variety of symptoms (Fig. 20.1). The importance of this initial distinction is based upon the fact that the treatment and evaluation of these entities is very different. In that regard the patient's description of the sensory disturbance can be very helpful in discerning the type of disorder. Descriptors such as numbness, tingling, swollen, and tightness are suggestive of a decreased level sensation, whereas terms like stinging, burning, and tenderness are more suggestive of a painful neuropathy. The clinician has to also be aware that patients may

Table 20.1 Common functional impairments for the injured inferior alveolar and lingual nerve

| |
|-------------------------------------|
| Difficulty masticating food bolus |
| Drooling |
| Difficulty with speech |
| Decreased taste sensation |
| Difficulty maintaining oral hygiene |
| Biting of lip, cheek, tongue |
| Decreased sense of self-worth |

be understandably angry about their condition and motivated to exaggerate their symptoms for medical-legal or other reasons. Therefore, it is important to differentiate what patients report as “painful” or “disturbing” from a numbness that is annoying or frustrating. Also the patient’s perception of a functional deficit is also relevant since this is typically a factor that motivates patients to consider surgical treatment [20, 54]. The nature of the functional impairment will depend upon which sensory nerve was injured and whether the altered sensation is painful or not. Patients with an IAN or LN injury should be queried as to the presence of lip/tongue biting, drooling, burning of the lip/tongue, speech difficulties, difficulty in chewing/swallowing/drinking, inability to distinguish between excessively hot and cold foods, difficulty with kissing or being intimate with a partner, pain or limitation when performing routine dental hygiene, and difficulty in playing a musical instrument (Table 20.1). If present, these types of functional impairments can also trigger feelings of an altered self-image, difficulties with socialization, and depression [52].

Patients should also be queried as to whether the pain or numbness is progressive in nature or has improved or subsided since the injury. In those instances where a patient has received previous surgical or medical care, the response to such care is important to determine so that an accurate assessment of the type and efficacy of future treatment can be made.

20.2 Physical Examination and Neurosensory Testing

The clinical neurosensory examination is the most important tool in deciding the most appropriate type of treatment that would potentially

benefit the patient. As noted above, a detailed history of the injury along with current complaints followed by subjective and objective testing will organize patients into groups in which treatment decisions can be made. The patient history will aid the clinician in deciding whether the patient has decreased overall sensation or pain (Fig. 20.1). Once this determination is made, further testing is performed according to the appropriate algorithm.

Patients with decreased sensation are those who experience a loss of sensation without pain. These patients either have a diminished response to a painful or non-painful stimulus (paresthesia), or are completely without sensation (anesthesia). In the anesthesia scenario, a determination should then be made to establish if a given patient has a mild, moderate, or severe functional impairment. Common functional impairments for the injured IAN and LN are outlined in Table 20.1 [43, 63].

Patients with significant pain after initial questioning follow the other branch of the algorithm in Fig. 20.1. It must first be determined whether the pain is stimulus induced or spontaneous in nature. Stimulus-induced pain is characterized as hyperalgesia (an exaggerated response to sharp pain, e.g., pin prick), allodynia (painful sensation to a stimulus that normally does not cause pain, e.g., shaving, kissing, or brushing teeth), or hyperpathia (a delayed or prolonged response to a normally painful stimulus). On the other hand, spontaneous pain can be either intermittent or constant. Intermittent pain is unpredictable and must not be confused with a delayed response to a hyperpathic stimulus. Constant pain occurs within the deep or superficial tissues and can be a chronic, dull, throbbing ache with or without lancinating electric shock-like sensations [43, 61].

After determining which aspect of the algorithm to follow for a particular patient (Fig. 20.1), a specific physical exam can be tailored for the individual patient to confirm a diagnosis and develop a treatment plan. A complete head and neck examination is followed by a focused inspection of the injured area. The degree and location of injury may be evident by disruption of mucosa, erythema, ulceration, hyperkeratosis, texture changes, or signs of self-induced trauma. Palpation of a trigger response may elicit abnormal sensations at or

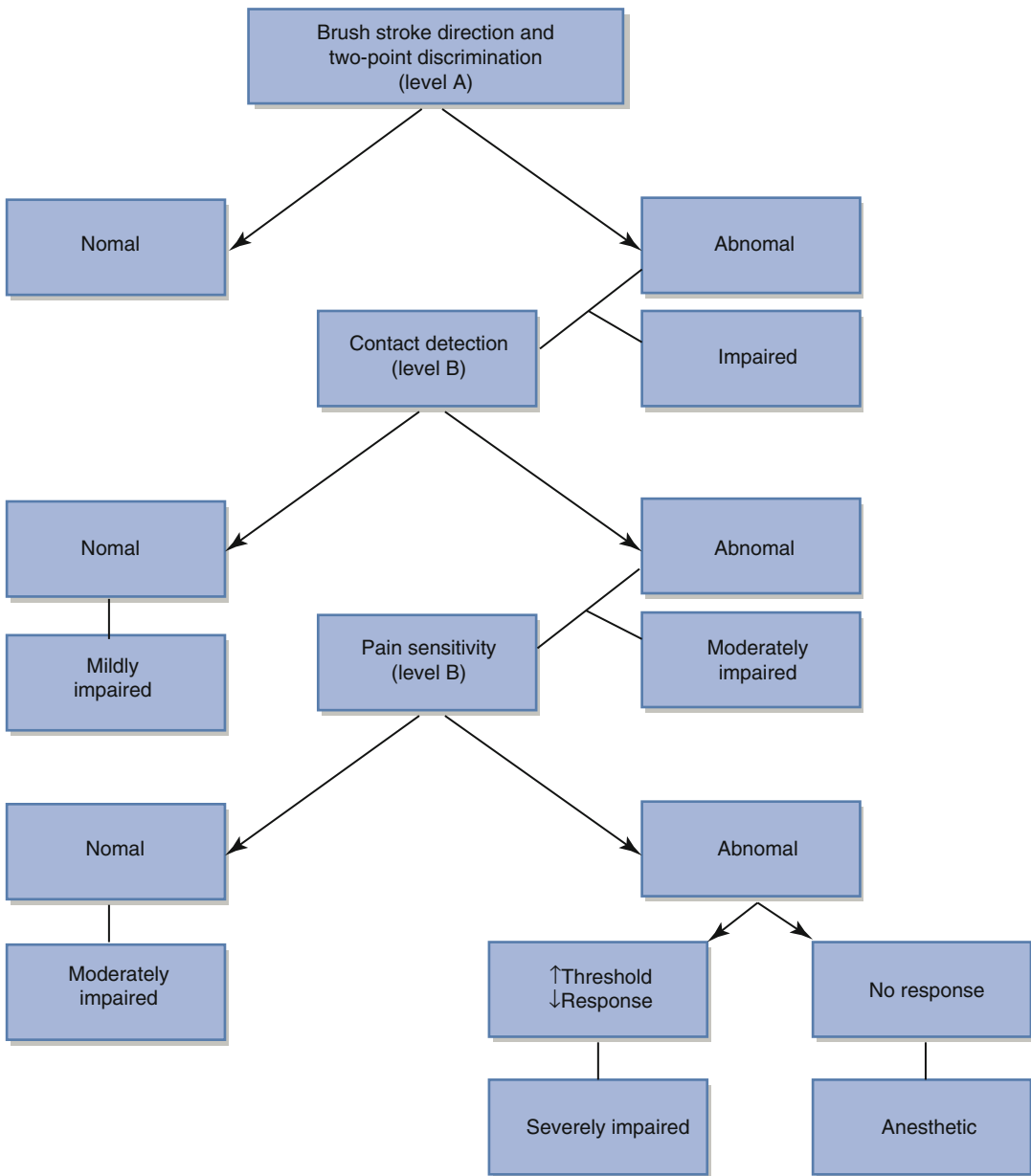


Fig. 20.2 Clinical neurosensory testing

distal to the injured site (Tinel’s sign). Evaluation of the contralateral or “normal” side is used as a control [61]. The method of neurosensory testing performed is based upon whether the patient has pain or decreased sensation, established during the patient interview. If the patient is without pain, sensory testing proceeds under the “decreased sensation” algorithm. Whereas if the patient has pain,

sensory testing proceeds in a different manner [43]. Neurosensory testing for the decreased sensation patient is divided into three levels (Fig. 20.2). *Level A* testing evaluates for tactile brush stroke direction and two-point discrimination. Tactile brush stroke directional discrimination is assessed by using a soft brush (0.75×0.5 cm) stroked in four directions along the test site. This test is repeated and

compared to the control side. Two-point discrimination testing measures spatial acuity. The stimulating device must provide two points of skin contact and is readily adjustable. A two-point discrimination of greater than 6.5 mm is a reliable indicator of sensory impairment in the majority of the population. The stimulus should have blunt tips and be applied perpendicular to the skin surface, and pressure is applied to not cause discomfort, blanching, or vibration of the tissue. The stimulus should last 2 s, and the patient is asked to report “one” or “two” with each stimulus application. Two-point distances should be increased and decreased from this measurement and compared to the control side. If the patient consistently discriminates tactile direction correctly and the two-point discrimination exam is ≤ 6.5 mm, the impairment is extremely subtle and sensory testing may cease. However, if level A testing is abnormal in the “decreased sensation” patient, proceed to level B testing [17]. *Level B* testing estimates the level of contact detection, using a set of Semmes-Weinstein pressure aesthesiometers (also called von Frey’s hair fibers). The test or injured site threshold is deemed abnormal if it is 250 % less sensitive compared with the control value or greater than two standard deviations above the published normative mean values [17]. Only a few axons require regeneration in order to achieve a normal result to testing. Therefore, patients with test site sensitivity comparable to the control site are designated as being mildly impaired, and there is no need to continue testing. A test site sensitivity less than that of the control or published normative values is considered as having a moderately impaired response and will proceed to level C testing. *Level C* testing evaluates the test area’s response to noxious stimuli (mechanical and thermal). Mechanical pain can be induced by pinprick; however, this type of testing may cause tissue damage (bleeding) and significant pain on the control side. The responses are subjective and difficult to quantify. An algometer (spring-loaded sharp probe) can be used as opposed to traditional pinprick to quantify the force needed to generate pain in these patients and compared with the control side. Thermal testing is the final level C neurosensory test. Hot (>40 °C) and cold (<20 °C) metal probes are utilized. A probe is warmed or cooled using

beakers of hot/cold saline or any other method of temperature regulation and placed over the test and control side for thermal evaluation. A heated stimulus of 50 °C against normal tissue will evoke an intolerable pain response without causing tissue damage. An abnormal thermal pain response is one that requires a heated stimulus that is significantly higher on the test site compared with the control. Patients with a significantly high threshold for level C testing are considered severely impaired, whereas those with a relatively normal response to level C testing will maintain the level B diagnosis of moderately impaired sensation [17].

Neurosensory testing for the “painful altered sensation” patient, in contrast to the “decreased sensation” patient, involves all three levels of testing (A, B, and C) for all patients. Level A testing involves an innocuous mechanical stimulus (brush stroke), which may potentially elicit a painful response known as *allodynia*. A moving brush stroke over the involved area will evoke a painful response over the distribution of the damaged nerve. The clinician should report frequency, duration, and intensity when discomfort is felt by the moving stimulus. Level B testing evaluates for possible *hyperpathia* in pain patients. These patients exhibit an explosive, radiating, poorly localized pain with a delayed occurrence that may last for an extended period of time. This exam utilizes a suprathreshold von Frey fiber that is repeatedly probed over the test site. Roughly ten repeated tactile pulses are delivered followed by a 1-min rest period to evaluate for delayed pain. Pain frequency, duration, and intensity are recorded by the clinician. Level C testing in the pain patient involves the use of mechanical and thermal noxious stimuli with hot and cold metal probes to elicit a painful response. After level A, B, and C neurosensory testing, the pain patient will undergo diagnostic nerve blocks to evaluate a peripheral versus central etiology of the pain and to assess the contribution of sympathetic output to the maintenance of the pain [38].

A final neurosensory examination performed for both the decreased sensation and pain patient is a taste test challenge. This is performed for lingual nerve damage patients only. Sugar and salt-water beakers are set up without the patient’s

knowledge. A cotton tip applicator is dipped into the sugar water and applied over the mucosa of the injured lingual nerve distribution. The patient is questioned if there is any specific taste they are experiencing during the test. After their response, the control side is tested in a similar manner. They must then rinse with water and the examination is repeated using salt water. Responses to these tests are recorded as part of an objective functional impairment.

20.3 Imaging

The history and physical examination of nerve injury patients are the most important part of developing a working diagnosis and making treatment decisions. However, there are some advantages of imaging techniques in some patients. The panoramic radiograph offers limited information due to the two-dimensional nature of the study, but the presence of a foreign body in the region of the LN or IAN may be identified, thus making it a useful screening tool. Rotary instrumentation, remnants of root tips, implant perforation, or root canal filling material may be seen in this study and can aid in localizing the site of injury. The use of computed tomography is helpful in delineating the anatomic relationship between the IAN and the tooth structures. This has facilitated the preoperative risk assessment for IAN injury [26, 56]. Computed tomography (CT) or cone-beam CT (CBCT) imaging may localize a foreign body in three dimensions or illustrate a violation of cortical outline of the inferior alveolar canal or lingual cortical plate. In this regard it can be helpful in planning surgical treatment. However, this modality of imaging provides limited information about the condition of an injured nerve.

Magnetic resonance imaging has been used in various anatomic locations to assess the integrity of large diameter nerves and characterize pathology [6, 8, 9, 30, 40, 46, 49, 58, 60]. High-resolution MRI may offer some helpful information with regard to the condition of the injured LN. A change in nerve diameter may be appreciated due to Wallerian degeneration of the

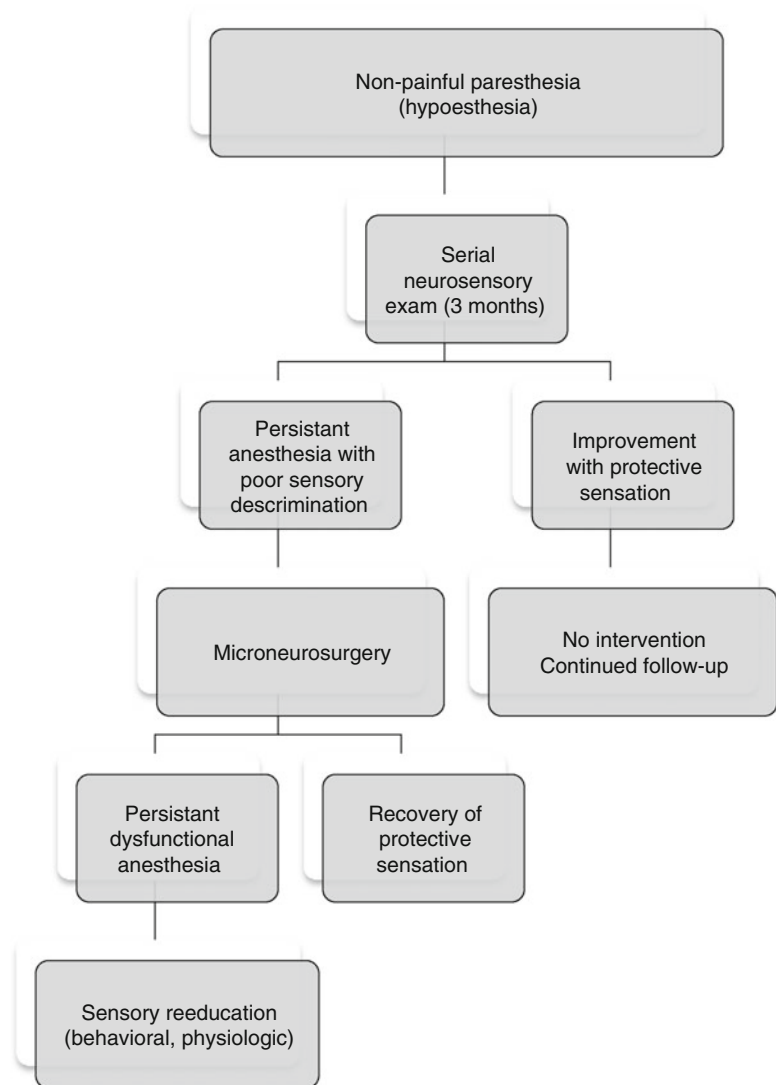
nerve distal to the site of injury, or an acute change in nerve position or shape due to retraction or neuroma formation may be visualized [44]. It is important to note that these imaging modalities can and should only be used as a supplement to a thorough history and clinical neurosensory examination.

20.4 Surgical Treatment Guidelines

The decision to proceed with microneurosurgical treatment is established on an individual basis and depends upon the specific presentation and clinical course for each patient. Surgical repair should be considered when the disability is of concern to the patient and there is clinical evidence of moderate, severe or complete sensory impairment, dystrophic ageusia, or neuropathic pain of peripheral origin. As the clinician follows the serial neurosensory exam over time, careful attention is directed at the extent and character of sensory recovery (Figs. 20.3 and 20.4). The Medical Research Council Scale (MRC), a well-defined guideline for assessing sensory function, was established by Mackinnon and Dellon [39] for extremity injuries (Table 20.2). This has been adapted by others to grade sensory recovery in the domain of the trigeminal nerve [11, 42]. Based upon the response to several neurosensory measurements, a score is assigned which can range from S0 (no recovery) to S4 (complete recovery). If there is clinical evidence of spontaneous restoration of useful protective sensation (MRC score ≥ 3), then surgical intervention is usually not indicated since both endpoints are similar.

The most important variable to consider is the amount of time that has elapsed since the injury. Since the primary objective for surgical intervention is to reestablish neural continuity of the proximal nerve segment with the distal end organ (lip or tongue), the integrity of the nerve section distal to the site of the injury is pivotal to a successful postsurgical outcome. Following a disconnect from the central nervous system and cell body, the distal nerve segment will undergo atrophy and degeneration (Wallerian degeneration) if

Fig. 20.3 Evaluation and management guidelines for patients with decreased sensation



it is not exposed to the neurotrophic influences of the proximal segment. As the degeneration continues, the endoneural tubules in the distal segment are replaced with scar tissue that effectively eliminates the potential for axonal repopulation into the distal nerve segment [53, 61]. It has been estimated that within 1 year from injury a significant component of the distal nerve will become atrophied and surgically unreparable [55, 61]. This has also been substantiated from outcomes and clinical findings during repair attempts in patients with nerve injuries that exceeded 12 months [41]. Despite sporadic reports of recovery several years following a sensory

nerve injury [21], most clinical studies have demonstrated poor neurosensory recovery beyond 6 months from the time of injury [5, 13, 31]. In Donoff's study of 44 lingual and inferior alveolar nerve injuries, they reported a positive correlation with improved sensation and microsurgical repair within 6 months from the injury [14]. Likewise, in Bagheri's et al. [3] retrospective review of 222 lingual nerve injuries, patients who were repaired more than 9 months following the injury were more likely to experience poor sensory improvement. A logistic regression analysis of their data demonstrated that the odds of improvement decreased by 5.8 % for each month

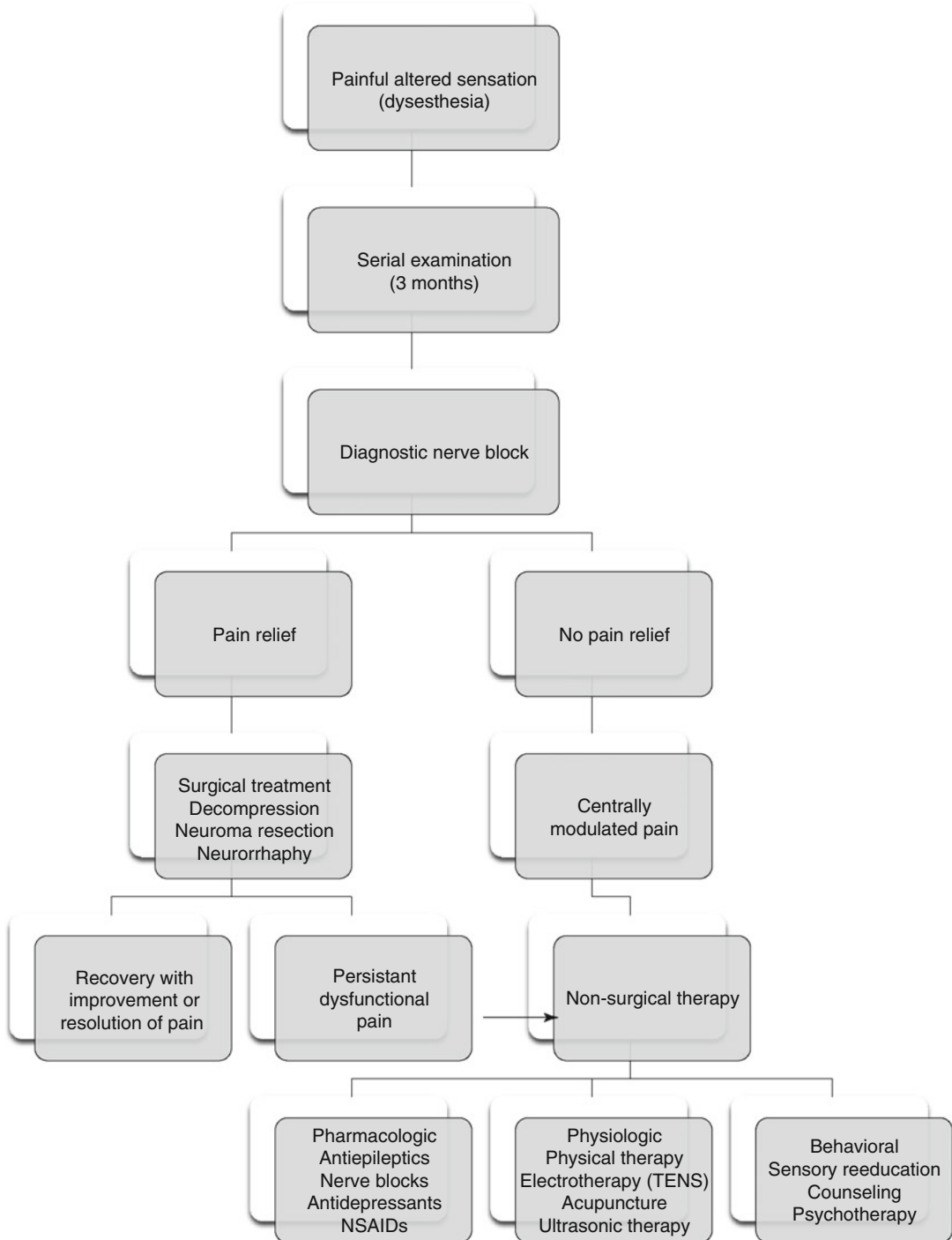


Fig. 20.4 Evaluation and management guidelines for patients with painful altered sensation

of delay beyond the injury date. For those patients who were repaired within 9 months of the injury, 65 % achieved “complete” return of sensation

and 25 % achieved “useful” sensory function as defined by the Medical Research Council Scale (Table 20.2).

Table 20.2 Medical Research Council Scale (MRCs) of neurosensory recovery

| Score | Description |
|-------|---|
| S0 | No sensation |
| S1 | Deep cutaneous pain in autonomous zone |
| S2 | Some superficial pain and touch |
| S2+ | Superficial pain and touch plus hyperesthesia |
| S3 | Superficial pain and touch without hyperesthesia; static two-point discrimination >15 mm |
| S3+ | Same as S3 with good stimulus localization and static two-point discrimination of 7–15 mm |
| S4 | Same as S3 and static two-point discrimination of 6 mm |

In this same study, a relationship was also reported between sensory outcome and age where patients 45 years of age or older were statistically less likely to have a positive outcome [3]. In their analysis, the chance of a recovery decreased by 5.5 % for each year of age beyond 45. In other studies, a similar relationship to age and postsurgical sensory recovery has not been reported [54, 57].

The character of the altered sensation must also be considered prior to proceeding with surgical treatment. The primary treatment objective for patients that present with painful neuropathies is to eliminate or significantly reduce their level of pain (Fig. 20.4). In a multicenter, retrospective study of 521 patients that received surgical treatment, the success rate for patients with hyperesthetic neuropathies was significantly worse than those who presented with non-painful altered sensation [34]. In a study by Gregg [23] the outcome of surgical therapy varied and was dependent upon the nature of the dysesthesia. In this report, the level of pain reduction following microsurgical repair was poor for patients who presented with anesthesia dolorosa (14.6 %) and sympathetic-mediated pain (20.7 %), while those patients with hyperalgesia (60.5 %) and hyperpathia (56.3) achieved a much better level of pain control following surgery. Donoff and Colin reported similar finding where sensory function was improved in 77 % patients with anesthesia, whereas pain relief was established in only 42 % of patients that presented with pain [14]. The duration of the painful neuropathy may also be important. Short-term

painful neuropathies (<6 months) may indicate early neuroma formation, while long-term painful neuropathies (>6 months) may result in central cortical changes that are not amenable to peripheral nerve repair. As a result, surgical management addressed at decreasing painful neuropathic pain may be more successful for early dysesthesia as opposed to late dysesthesia.

The utilization of local anesthetic blocks has been useful in segregating patients with painful neuropathies [7]. Total or near total relief of pain following a local anesthetic nerve block establishes that the neural dysfunction is localized to the peripheral nerve structure and not centrally modulated. Patients with a positive response to a diagnostic nerve block are more likely to experience pain relief following surgical therapy [23]. In order to determine the precise location of the nerve lesion, typically a diagnostic block is performed by beginning with a distal infiltration of local anesthesia and then proceeding in a more proximal direction.

The distinction between a witnessed (open) nerve injury and an unwitnessed (closed) nerve injury should also be established during the initial evaluation. In those uncommon scenarios where there nature of the injury is known to the operating surgeon or the subsequently treating surgeon, serial neurosensory examinations over several months are not required to establish the extent of the neurosensory injury. If there were a witnessed or intentional transection of the LN or IAN during ablative surgery for tumors, sagittal split osteotomy, or third molar surgery, immediate neural repair results in the best outcome for return of meaningful sensory function. The indications for immediate primary repair are the following: (1) observed, transected unaligned nerve segments within mobile soft tissue (lingual, mental nerves) and (2) nerve segments that are widely exposed with easy surgical access (sagittal osteotomy, ablative surgical procedures) [43]. The benefit of immediate reconstruction is based upon the limited degree of neural degeneration and scar tissue formation that occurs when neural continuity is reestablished at the time of injury. In situations where an immediate repair cannot be accomplished due to operator inexperience, surgical

access issues, or patient care problems, a delayed or early secondary repair can be considered within 7–10 days with results similar to an immediate repair [29]. Delayed primary repair may be considered for avulsive-type nerve injuries at 21 days following the injury in order for the magnitude of the neural damage to declare itself proximally and distally; also, the presence of neurotropic and neurotrophic factors are highest at the site of injury at this time.

Closed or unwitnessed nerve injuries represent the majority of nerve injury cases that present for routine neurosensory evaluation. In this scenario, no clinical information is available about the character or the extent of the injury. These patients must be evaluated and followed with serial neurosensory examinations (Figs. 20.3 and 20.4). This approach allows for proper identification and segregation of minor or less severe injuries that will improve spontaneously (Sunderland I, II, and III injuries), from those that require intervention (Sunderland IV and V injuries). Patients with a neuropraxia-type injury will demonstrate early signs of improved sensory function and will likely not require surgical intervention. Those patients who present with persistent anesthesia, intolerable or sustained triggered pain (allodynia, hyperalgesia), and persistent or worsening functionally debilitating sensory deficits that persist beyond 3 months are associated with more complex injuries (axonotmesis or neurotmesis) that will likely require microneurosurgical treatment.

Chemical injuries to the trigeminal nerve are rare events that can result in significant neurosensory disturbances ranging from mild paresthesia to complete anesthesia and pain [10]. Most reports of this type of injury are isolated to the IAN due to its proximity to root canal filling material, extraction socket medicaments, and various agents used as adjuncts to surgical treatment of certain tumors and cysts of the jaws (Table 20.3).

The extent of the chemical injury that these various agents can induce is often dependent upon the integrity of the epineurium surrounding the IAN at the time of exposure. If the epineurium has been disrupted following dentoalveolar surgery or over-instrumentation of a root

Table 20.3 Neurologic response to chemical exposure

| Chemical agent | Tissue response |
|--------------------------------|--|
| Carnoy's solution | Altered nerve conduction velocity |
| Whiteheads varnish | Altered nerve conduction velocity |
| Tetracycline | Perifascicular inflammation, giant cell reaction |
| Oxidized cellulose (Surgicel®) | Altered nerve conduction velocity, inflammation |
| Gutta-percha | Inflammation |
| Calcium hydroxide | Inflammation |
| Phenols (eugenol) | Direct neurotoxicity |

canal, the fascicles will be directly exposed to these toxic agents. In this scenario, neuronal inflammation, giant cell reaction, neuronal degradation, and axonal death have been reported [1, 12, 16, 18, 35–37, 45, 48]. In open IAN exposures, such as in extraction sites or large bony defects from extirpative cyst or tumor surgery, the agents can sometimes be removed and the site irrigated, thus limiting the exposure time. Serial neurosensory examination is then indicated to direct the appropriate modality of treatment since many of these injuries result in painful neuropathies (Fig. 20.4). In closed exposures typically seen following root canal therapy, the offending chemical remains in contact with the IAN. This results in prolonged exposure to the noxious chemical and a more significant degree of injury (Fig. 20.5). The mechanism of neuronal injury following endodontic therapy includes the following: (1) mechanical trauma due to over-instrumentation, (2) direct chemical injury, (3) direct impingement on the IAN from extruded filling material (foreign body), (4) neuronal inflammation and edema with compromise of the microneural circulation (compartment syndrome). Often times it is a combination of these factors that are responsible for the altered sensation in these cases. Patients that experience severe non-painful altered sensation, or a painful altered sensation in the presence an identifiable foreign body within the canal (gutta-percha, sealant material), should be considered for surgical therapy (decompression, debridement, or reconstruction) as soon as possible. When altered

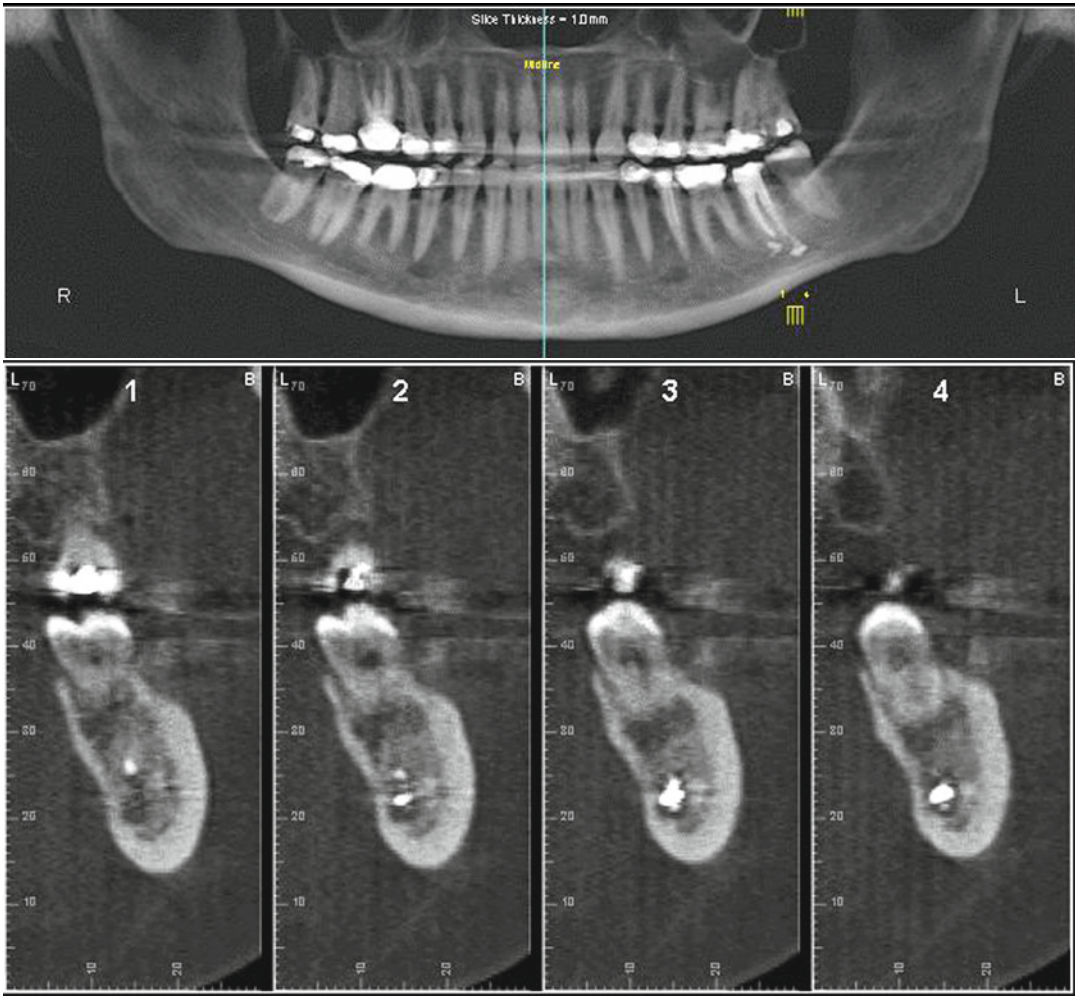


Fig. 20.5 Panoramic and CT image demonstrating endodontic filling material expressed beyond the apex of the lower left first molar into the inferior alveolar canal

sensation is delayed for several days following endodontic treatment, this results in an intense inflammatory response to the chemical agent. In this scenario anti-inflammatory therapy, as well as antibiotic treatment, should be considered provided that there is no evidence of a foreign body within the inferior alveolar canal that should be removed promptly.

Prolonged or permanent altered sensation following local anesthetic injection is another uncommon but well-recognized etiologic entity in IAN and LN injuries. The reported incidence of such injuries varies from 1:750,000 to 1:30,000 [24, 25, 32, 51]. Unlike other traumatic trigeminal nerve injuries,

injection injuries affect the LN more often than the IAN [51, 59], are more likely to result in painful neuropathies [51], and are more common in female patients [51], and the pattern of sensory dysfunction may extend beyond the dermatome of the injured nerve (e.g., to involve V2 and V1). The mechanism of the injection injury is theorized to be related to direct mechanical trauma from the needle insertion [47] or a chemical-type injury from the local anesthetic solution concentration [19, 28]. However, in patients with injection injuries, the reported occurrence of an injection-related “shock-type sensation,” which would indicate direct mechanical injury, is low [25] suggesting that a chemical-induced injury may

play more of a significant role in these patients. The treatment of these injuries has been mostly nonsurgical in nature given the anatomic challenges that surgical exposure poses. The site of injury for most injuries is located at the mandibular foramen, which is typically 1.5–2 cm posterior to the anterior border of the ascending ramus in the pterygomandibular space. This makes surgical access for exploration and repair very difficult. Pogrel and Schmidt [50] conducted a focused survey of oral and maxillofacial surgeons who perform microneurosurgery and queried them as to their intraoperative findings and postsurgical outcomes for these type of injuries. In those instances when surgery was performed, except for a minimal amount of surrounding fibrosis, no identifiable neural injury was found. Moreover, the degree of postoperative sensory improvement was universally poor. Currently there are no evidenced-based studies or expert-based consensus on how to prevent, or treat, these types of neural injuries. Empiric strategies including early surgical exploration, site irrigation, and immediate steroid therapy have been described for injection injuries involving chemicals other than local anesthetics, but these have not been applied to the trigeminal nerve. Therefore, painful and non-painful injection-induced neuropathies are best managed with nonsurgical therapy consisting of behavioral, pharmacologic, and physiologic treatment modalities.

Implant-related injuries represent another unique type of closed neural trauma. During implant placement, the IAN may be traumatized by several mechanisms including direct mechanical trauma from the drill, thermal injury from the drilling process, and compression during implant placement. These injuries have been reported with a wide incidence range [15] which is likely reflective of the many variables that are involved. For those patients who require nerve lateralization or transposition procedures, the incidence of post-implant-altered sensation can be significant [38]. The management strategy for patients that develop altered sensation following implant placement is dependent upon the timing of the implant surgery and the nature of the altered sensation (Fig. 20.6). Those patients who present with non-painful altered sensation, or pain that presents shortly following implant placement, should be initially

managed with nonsteroidal or steroidal anti-inflammatory medications. If there is radiographic evidence of neural compression from the implant (Fig. 20.7), then the implant should be backed off the nerve or removed. If an implant will not be restorable following elevation due poor bone support or occlusal space impingement, then it should be removed and possibly replaced with a shorter implant. When sufficient time has elapsed and the implant has integrated (late development or detection of a nerve injury), implant removal will likely provide little if any benefit and also carries the risk of further iatrogenic nerve injury. Serial neurosensory evaluations are then required to assess neural recovery and function. Patients with severe sensory impairment or neurogenic pain that persists for 3 months after the implant injury are not likely to experience spontaneous recovery and are candidates for microsurgery [33, 62].

Realistic goals for microsurgical repair of an injured peripheral sensory nerve, regardless of the etiology, should include reduction of painful sensations, improvement of stimulus detection, and restoration of protective sensation. In cases of LN injuries, improvement or restoration of taste sensation is not as predictable as other modalities of sensation. Patients must also be aware that despite successful microsurgical neural anastomosis via microneurosurgery, preoperative unpleasant sensations and the inability to characterize stimuli may persist. These differences in recovery may be attributable to local factors at the site of the injury, neuromodulation that occurs at the central nervous system level, or psychological factors. In this setting, functional sensory recovery (based upon MRCS) may be further optimized by specialized nonsurgical therapy.

20.5 Nonsurgical Management

In addition to the supportive role that nonsurgical treatment may have for patients undergoing spontaneous or postoperative recovery, nonsurgical therapies are considered the primary mode of treatment for most patients with long-standing,

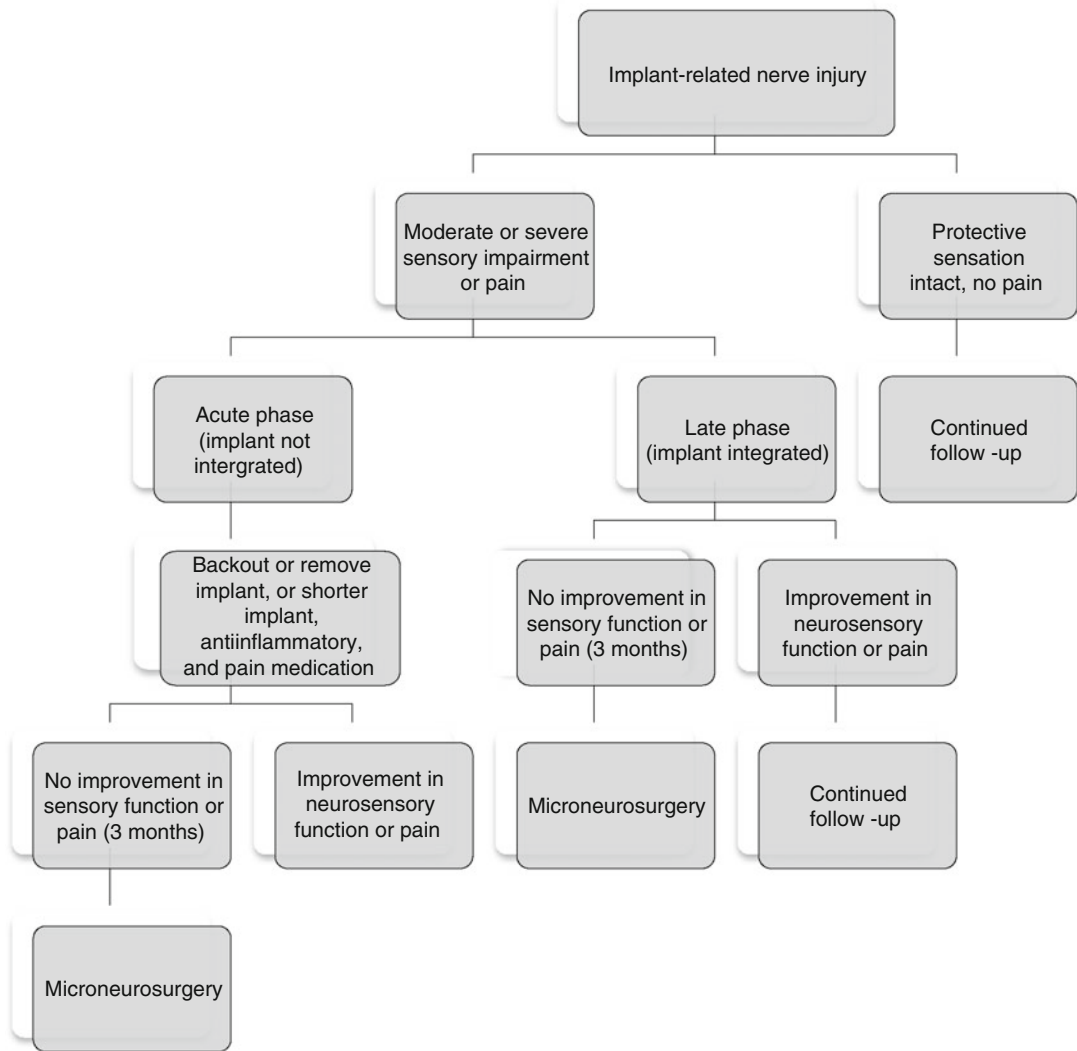


Fig. 20.6 Evaluation and treatment guidelines for patients with implant-related nerve injuries

dysfunctional nerve injury or pain. The goals of nonsurgical treatment include reduction in pain, prevention or reversal of addiction, avoidance of surgical procedures with a poor likelihood of success, and the improvement of the patient’s ability to carry on with the activities of normal daily living. The clinical indications for such treatment has been outlined by Gregg [22] and Meyer [43] and include the following:

- Patients with peripheral neuromas that have failed surgical therapy
- Centrally mediated pain
- Sympathetically mediated pain
- Metabolic neuropathies
- Atypical pain that does not conform to the appropriate dermatome
- Pain not relieved by local anesthetic injection
- Non-repairable injuries (proximal injuries, distal nerve segment atrophy, extensive surrounding soft tissue injury)
- Patients with poor medical status that cannot tolerate surgery
- Patients with non-painful neuropathies that interfere life functions

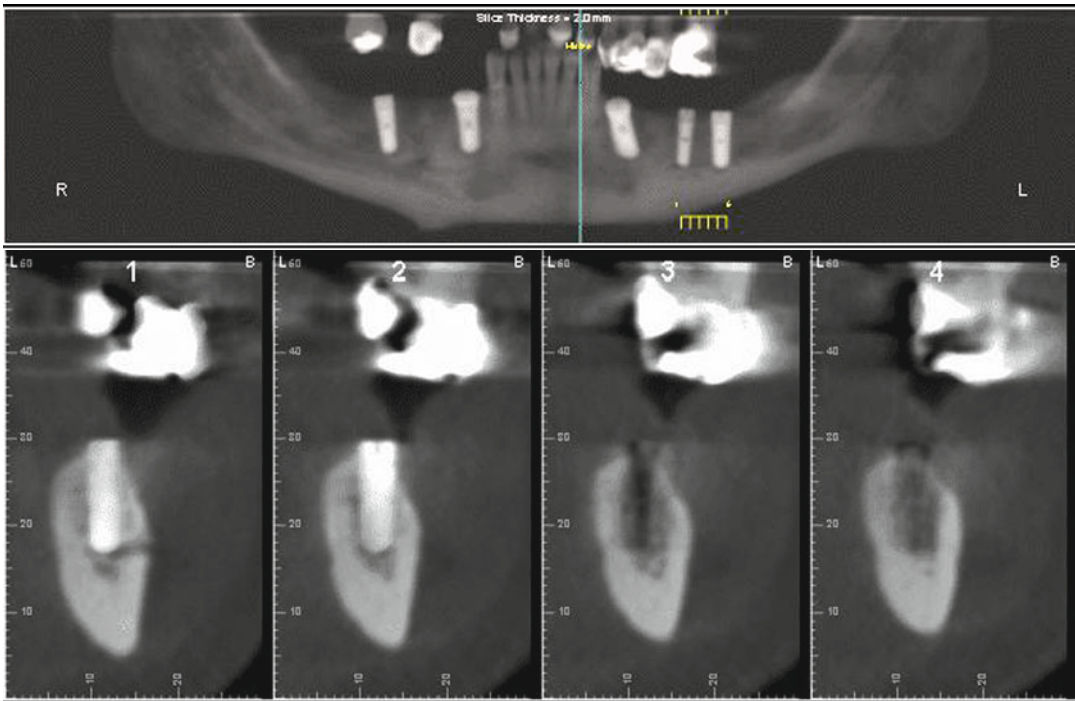


Fig. 20.7 Panoramic and CT image indicating impingement of the left inferior nerve by a dental implant

The modalities of nonsurgical care can be segregated into behavioral, physiologic, and pharmacologic treatments. For certain patients, more than one type of nonsurgical treatment may be indicated.

20.5.1 Behavioral Treatment

In the acute setting, patients should be counseled in a reassuring manner as to the nature of the injury, the lengthy time course for spontaneous recovery, the options for treatment, and the possible outcomes. A non-defensive posture is most suitable to gain a patient's trust and confidence who have likely lost confidence in their previous clinician. For those injuries that are chronic in nature, sensory reeducation can be beneficial [42]. Sensory reeducation exercises, a form of biofeedback, involves introducing various repeated stimuli to the affected dermatome using a mirror for feedback, which is thought to allow the central nervous system to reorganize and reprocess the altered sensory

information. Relaxation therapies (yoga, meditation) and other occupational treatments can also be beneficial.

20.5.2 Physiologic Treatment

Immediately following a neural injury, the application of cryotherapy and immobilization, when possible, may limit the extent of neural injury [22]. For chronic neuropathies and pain syndromes, physiologic stimulation therapies such as transcutaneous electrical nerve stimulation (TENS) and acupuncture may also be indicated. Both low- and high-frequency TENS therapy have demonstrated efficacy in managing traumatic neuralgias [4] by modulating pain through endorphin release (Lo TENS) or blockage of central nociceptor activity (Hi TENS). The efficacy of acupuncture therapy is believed to be related to the excitation of descending pain inhibitory pathways and elevation of pain thresholds. The reversal of certain acupuncture-induced effects by naloxone suggests that opioid release may also play a role in pathogenesis [27].

20.5.3 Pharmacologic Treatment

Several drug classes have demonstrated efficacy in managing or preventing the pain and psychological trauma associated with neurotrauma. The drug or drug combination therapies should be tailored to each patient and will vary depending upon the character of the problem (acute or chronic pain), the outcome or endpoint that is desired, and the patient's response to the titrated therapy. In certain situations when multiple drug regimens are required to address a complex neuropathic pain syndrome, the use of a pain team is usually the most efficient means by which to facilitate the multidisciplinary treatment that these patients often require.

During the acute phase of neural injury, medical therapy is directed at blunting the inflammatory response and the associated anxiety and pain. A short course of steroidal anti-inflammatory medication and narcotic analgesics is often helpful in addressing the pain of the acute injury. Benzodiazepine drugs (Klonopin, Valium) are useful in addressing the anxiety and stress that is often present. Patients with chronic, long-term neuropathic pain will often benefit from anticonvulsant medical treatment (Neurontin (gabapentin), Lyrica (pregabalin)), in addition to maintaining anti-inflammatory therapy. If the pain syndrome is accompanied by depression, tricyclic antidepressant agents (Elavil (amitriptyline)) may be added to the medical regimen. Narcotic analgesics administered orally or transcutaneously may be considered if the other pharmacologic strategies are not successful.

20.6 Summary

Injury to the trigeminal nerve injuries is a well-recognized risk associated with many routine dental and oral surgical procedures. The assessment and management of a patient with a traumatic trigeminal neuropathy requires a logical stepwise approach.

The proper application and interpretation of the various neurosensory tests and maneuvers is critical to establish an accurate diagnosis. The implementation of a surgical or nonsurgical treatment

strategy is based not only upon the perceived diagnosis but also a multitude of variables including patient age, timing and nature of the injury, and the emotional or psychological impact on each patient. The parameters of care presented in this chapter are intended to serve only as guidelines, since the management strategy for a traumatic neuropathy of the trigeminal nerve must be tailored to the unique characteristics of the each individual patient.

References

1. Alkan A, İnal S, Yildirim M, Baş B, Açar E (2007) The effects of hemostatic agents on peripheral nerve function: an experimental study. *J Oral Maxillofac Surg* 65(4):630–634
2. Alling C, Schwartz E, Campbell R et al (1992) Algorithms for diagnostic assessment and surgical treatment of traumatic trigeminal neuropathies and neuralgias. *Oral Maxillofac Surg Clin North Am* 4:555
3. Bagheri S, Meyer R, Khan H, Kuhmichel A, Steed M (2010) Retrospective review of microsurgical repair of 222 lingual nerve injuries. *J Oral Maxillofac Surg* 68:715–723
4. Bemerich A, Wiegel W, Thien T, Dietz T (1988) Transcutaneous electric nerve stimulation (TENS) in the therapy of chronic pain. *J Craniomaxillofac Surg* 16:379
5. Blackburn C, Bramley P (1985) Lingual nerve damage associated with the removal of lower third molars. *Br Dent J* 167:103
6. Bowers CA, Taussky P, Duhon BS, Chin SS, Couldwell WT (2011) Malignant peripheral nerve sheath tumour of the trigeminal nerve: case report and literature review. (Translated from eng). *Br J Neurosurg* 25(6):750–753 (In Eng)
7. Campbell R (1992) The role of diagnostic nerve blocks in the diagnosis of traumatic trigeminal neuralgia. *Oral Maxillofac Surg Clin North Am* 4:369
8. Chhabra A et al (2011) MR neurography: past, present, and future. (Translated from eng). *AJR Am J Roentgenol* 197(3):583–591 (In Eng)
9. Chhabra A, Faridian-Aragh N (2012) High-resolution 3-T MR neurography of femoral neuropathy. (Translated from eng). *AJR Am J Roentgenol* 198(1):3–10 (In Eng)
10. Conrad S (2001) Neurosensory disturbance as a result of chemical injury to the inferior alveolar nerve. *Oral Maxillofac Surg Clin North Am* 13:255–263
11. Dodson TB, Kaban LB (1997) Recommendations for management of trigeminal nerve defects based on a critical appraisal of the literature. *J Oral Maxillofac Surg* 55(12):1380–1386
12. Donoff RB (1995) Experimental topical tetracycline-induced neuritis in the rat. *J Oral Maxillofac Surg* 53(4):434

13. Donoff RB (1997) Recommendations for management of trigeminal nerve defects based on a critical appraisal of the literature. *J Oral Maxillofac Surg* 55(12):1387
14. Donoff RB, Colin W (1990) Neurologic complications of oral and maxillofacial surgery. *Oral Maxillofac Surg Clin North Am* 2:453
15. Ellies LG (1999) The incidence of altered sensation of the mental nerve after mandibular implant placement. *J Oral Maxillofac Surg* 57(12):1410–1412
16. Eslami A, Van Swol RL, Sadeghi EM (1987) Connective tissue reactions to 3 % tetracycline ointment in rat skin. *J Oral Maxillofac Surg* 45(10):866–872
17. Essick G (1992) Comprehensive clinical evaluation of perioral sensory function. *Oral Maxillofac Surg Clin North Am* 4:503
18. Frerich B, Cornelius C-P, Wiethölder H (1994) Critical time of exposure of the rabbit inferior alveolar nerve to Carnoy's solution. *J Oral Maxillofac Surg* 52(6):599–606
19. Garisto G, Gaffen A, Lawrence H et al (2010) Occurrence of paresthesia after dental local anesthetic administration in the United States. *J Am Dent Assoc* 141:836
20. Ghali G, Epker B (1989) Clinical neurosensory testing: practical applications. *J Oral Maxillofac Surg* 47:1074
21. Girard K (1979) Considerations in the management of damage to the mandibular nerve. *J Am Dent Assoc* 98:65
22. Gregg J (2001) Nonsurgical management of traumatic trigeminal neuralgias and sensory neuropathies. *Oral Maxillofac Surg Clin North Am* 13:375
23. Gregg J (1990) Studies of traumatic neuralgias in the maxillofacial region: symptom complexes and response to microsurgery. *J Oral Maxillofac Surg* 48:135
24. Haas D, Lennon D (1995) A 21-year retrospective study of reports of paresthesia following local anesthetic administration. *J Can Dent Assoc* 61:319
25. Harn S, Durham T (1990) Incidence of lingual nerve trauma and postinjection complications in conventional mandibular block anesthesia. *J Am Dent Assoc* 121:519
26. Hatano Y, Kurita K, Kuroiwa Y, Yuasa H, Arijji E (2009) Clinical evaluations of the coronectomy (intentional partial odontectomy) for mandibular third molars using dental computed tomography: a case-control study. *J Oral Maxillofac Surg* 67:1806–1814
27. He L (1987) Involvement of endogenous opioid peptides in acupuncture analgesia. *Pain* 31:99
28. Hillerup S, Jensen R, Ersboll B (2011) Trigeminal nerve injury associated with injection of local anesthetic: needle lesion or neurotoxicity. *J Am Dent Assoc* 142:531–539
29. Jabaley M (1981) Current concepts in nerve repair. *Clin Plast Surg* 8:33
30. Kermarec E et al (2010) Ultrasound and magnetic resonance imaging of the peripheral nerves: current techniques, promising directions, and open issues. (Translated from eng). *Semin Musculoskelet Radiol* 14(5):463–472 (In Eng)
31. Kipp D, Goldstein B, Weiss W (1980) Dysesthesia after mandibular third molar surgery: a retrospective study and analysis of 1,377 surgical procedures. *J Am Dent Assoc* 100(2):185–192
32. Krafft T, Hickel R (1994) Clinical investigation into the incidence of direct damage to the lingual nerve caused by local anesthesia. *J Craniomaxillofac Surg* 22:294
33. Kraut R, Chahal O (2002) Management of patients with trigeminal nerve injuries after mandibular implant placement. *J Am Dent Assoc* 133(10):1351–1354
34. LaBanc J, Gregg J (1992) Basic problems, historical perspectives, early successes and remaining challenges. *Oral Maxillofac Surg Clin North Am* 4:277
35. Leist J, Zuniga J (1995) Experimental topical tetracycline-induced neuritis in the rat. *J Oral Maxillofac Surg* 53:432
36. Loescher A, Robinson P (1998) The effect of surgical medicaments on peripheral nerve function. *Br J Oral Maxillofac Surg* 36:330
37. Loescher AR (2005) The effect of injury and protocols for management. *J Oral Maxillofac Surg* 63(8):10
38. Louis P (2001) Inferior alveolar nerve transposition for endosseous implant placement. *Oral Maxillofac Surg Clin North Am* 13:265
39. Mackinnon S, Dellon A (1988) *Surgery of the peripheral nerve*. Thieme Medical Publishers, New York
40. Martinoli C (2010) Imaging of the peripheral nerves. (Translated from eng). *Semin Musculoskelet Radiol* 14(5):461–462 (In Eng)
41. Meyer R (1992) Applications of microneurosurgery to the repair of trigeminal nerve injuries. *Oral Maxillofac Surg Clin North Am* 4:405
42. Meyer R, Rath E (2001) Sensory rehabilitation after trigeminal nerve injury or repair. *Oral Maxillofac Surg Clin North Am* 13:365
43. Meyer R, Ruggiero S (2001) Guidelines for diagnosis and treatment of peripheral trigeminal nerve injuries. *Oral Maxillofac Surg Clin North Am* 13:383
44. Miloro M (2001) Radiologic assessment of the trigeminal nerve. *Oral Maxillofac Surg Clin North Am* 13:315–323
45. Moore J, Brekke J (1990) Foreign body giant cell reaction related to placement of tetracycline-treated polylactic acid. *J Oral Maxillofac Surg* 48:808
46. Morani AC, Ramani NS, Wesolowski JR (2011) Skull base, orbits, temporal bone, and cranial nerves: anatomy on MR imaging. (Translated from eng). *Magn Reson Imaging Clin N Am* 19(3):439–456 (In Eng)
47. Morris C, Rasmussen J, Throckmorton G, Finn R (2010) The anatomic basis of lingual nerve trauma associated with inferior alveolar block injections. *J Oral Maxillofac Surg* 68:2833–2836
48. Nagamatsu M, Podratz J, Windebank A (1997) Acidity is involved in the development of neuropathy caused by oxidized cellulose. *J Neurol Sci* 146:97
49. O'Shea K, Feinberg JH, Wolfe SW (2011) Imaging and electro diagnostic work-up of acute adult brachial plexus injuries. (Translated from eng). *J Hand Surg Eur* 36(9):747–759 (In Eng)

50. Pogrel M, Schmidt B (2001) Trigeminal nerve chemical neurotrauma from injectable materials. *Oral Maxillofac Surg Clin North Am* 13:247
51. Pogrel M, Thamby S (2000) Permanent nerve involvement from inferior alveolar nerve blocks. *J Am Dent Assoc* 31:901
52. Pogrel MA, Jergensen R, Burgon E, Hulme D (2011) Long-term outcome of trigeminal nerve injuries related to dental treatment. *J Oral Maxillofac Surg* 69(9):2284–2288
53. Rath E (2001) Peripheral neurotrauma-induced sensory neuropathy. *Oral Maxillofac Surg Clin North Am* 13: 223–235
54. Robinson P (1988) Observations on the recovery of sensation following inferior alveolar nerve injuries. *Br J Oral Maxillofac Surg* 26:117
55. Sunderland S (1978) Nerves and nerve injuries. Churchill Livingstone, Edinburgh
56. Susarla S, Dodson TB (2007) Preoperative computed tomography imaging in the management of impacted mandibular third molars. *J Oral Maxillofac Surg* 65:83–88
57. Susarla S, Kaban L, Donoff R, Dodson T (2007) Functional sensory recovery after trigeminal nerve repair. *J Oral Maxillofac Surg* 65:60–65
58. Tagliafico A et al (2010) Traumatic neuropathies: spectrum of imaging findings and postoperative assessment. (Translated from eng). *Semin Musculoskelet Radiol* 14(5):512–522 (In Eng)
59. Tay A, Zuniga J (2007) Clinical characteristics of trigeminal nerve injury referrals to a university center. *Int J Oral Maxillofac Surg* 36:922
60. Woertler K (2010) Tumors and tumor-like lesions of peripheral nerves. (Translated from eng). *Semin Musculoskelet Radiol* 14(5):547–558 (In Eng)
61. Zuniga J (1992) Normal response to nerve injury. *Oral Maxillofac Surg Clin North Am* 4:323–337
62. Zuniga J (2007) Trigeminal nerve injury. Quintessence, Hanover Park
63. Zuniga J, Essick G (1992) A contemporary approach to the clinical evaluation of trigeminal nerve injuries. *Oral Maxillofac Surg Clin North Am* 4:353

Glossary¹

- Ageusia** Absence of gustatory (taste) perception.
- Allodynia** Pain due to a stimulus that does not normally provoke pain.
- Analgesia** Absence of pain in the presence of stimulation that would normally be painful.
- Anesthesia** Absence of any sensation in the presence of stimulation that would normally be painful or nonpainful.
- Anesthesia dolorosa** Pain in an area or region that is anesthetic.
- Atypical neuralgia** A pain syndrome that is not typical of classic nontraumatic trigeminal neuralgia.
- Axonotmesis (Seddon) or second- through fourth-degree injuries (Sunderland)** Nerve injury characterized by axonal injury with subsequent degeneration and regeneration.
- Causalgia** Burning pain, allodynia, and hyperpathia after a partial injury of a nerve.
- Central pain** Pain associated with a primary central nervous system lesion (spinal cord or brain trauma, vascular lesions, tumors).
- Chemoreceptor** A peripheral nerve receptor that is responsive to chemicals, including catecholamines.
- Deafferentation pain** Pain occurring in a region of partial or complete traumatic nerve injury in which there is interruption of afferent impulses by destruction of the afferent pathway or other mechanism.
- Dysesthesia** An abnormal sensation, either spontaneous or evoked, that is unpleasant. All dysesthesias are a type of paresthesia but not all paresthesias are dysesthesias.
- Dysgeusia** A distortion of the gustatory sensation (e.g., metallic taste), often associated with ageusia or hypogeusia.
- Endoneurium** A connective tissue sheath surrounding individual nerve fibers and their Schwann cells.
- Epineurium** A loose connective tissue sheath that encases the entire nerve trunk.
- Fascicle** A bundle of nerve fibers encased by the perineurium.
- Hypesthesia** A decreased response to all forms of stimuli.
- Hyperalgesia** An increased response to a stimulus that is normally painful.
- Hyperesthesia** An increased sensitivity to stimulation, excluding the special senses (i.e., seeing, hearing, taste, and smell).
- Hyperpathia** A painful syndrome characterized by increased reaction to a stimulus, especially a repetitive stimulus. The threshold is increased as well.
- Hypoalgesia** Diminished pain in response to a normally painful stimulus.
- Hypoesthesia** Decreased sensitivity to stimulation, excluding the special senses (i.e., seeing, hearing, taste, and smell).
- Hypogeusia** A decrease in taste sensitivity.
- Mechanoreceptor** A peripheral nerve receptor preferentially activated by physical deformation from pressure and associated with large sensory axons.

¹Adapted from LaBanc JP, Gregg JM. Glossary. Trigeminal nerve injury: diagnosis and management. *Oral Maxillofac Surg Clin North Am* 1992;4:563.

- Mesoneurium** A connective tissue sheath, analogous to the mesentery of the intestine, that suspends the nerve trunk within soft tissue.
- Monofascicular pattern** Characteristic cross section of a nerve containing one large fascicle.
- Neuralgia** Pain in the distribution of a nerve or nerves.
- Neurapraxia (Seddon) or first-degree injury (Sunderland)** Nerve injury characterized by a conduction block, with rapid and virtually complete return of sensation or function and no axonal degeneration.
- Neuritis** A special case of neuropathy now reserved for inflammatory processes affecting nerves.
- Neurolysis** The surgical separation of adhesions from an injured peripheral nerve.
- Neuroma** An anatomically disorganized mass of collagen and nerve fascicles and a functionally abnormal region of a peripheral nerve resulting from a failed regeneration following injury.
- Neuropathy** A disturbance of function or a pathologic change in a nerve.
- Neurotization** Axonal invasion of the distal nerve trunk.
- Neurotmesis (Seddon) or fifth-degree injury (Sunderland)** Nerve injury characterized by severe disruption of the connective tissue components of the nerve trunk, with compromised sensory and functional recovery. Third-degree injury: Characterized by axonal damage and a breach of the endoneurial sheath, resulting in intrafascicular disorganization. The perineurium and epineurium remain intact. The mechanism is typically traction or compression. Fourth-degree injury: Characterized by disruption of the axon, endoneurium, and perineurium, resulting in severe fascicular disorganization. The epineurium remains intact. Possible mechanisms include traction, compression, injection injury, and chemical injury. Fifth-degree injury: Characterized by complete disruption of the nerve trunk with considerable tissue loss. Possible mechanisms include laceration, avulsion, and chemical injury.
- Nociceptor** A receptor preferentially sensitive to a noxious stimulus or to a stimulus that would become noxious if prolonged.
- Oligofascicular pattern** Characteristic cross section of a nerve containing 2 to 10 rather large fascicles.
- Paresthesia** An abnormal sensation, either spontaneous or evoked, that is not unpleasant. A global term used to encompass all types of nerve injuries.
- Perineurium** A thick connective tissue sheath surrounding fascicles.
- Polyfascicular pattern** Characteristic cross section of a nerve containing >10 fascicles of different sizes, with a prevalence of small fascicles.
- Protopathia** The inability to distinguish between two different modes of sensation, such as a painful and nonpainful pinprick.
- Sympathetically mediated pain** A general term that refers to a family of related disorders including causalgia, reflex sympathetic dystrophy, minor causalgia, Sudeck's atrophy, and postherpetic neuralgia, which may be sympathetically maintained.
- Synesthesia** A sensation felt in one part of the body when another part is stimulated.
- Wallerian degeneration** The distal degeneration of the axon and its myelin sheath following injury.

Index

A

- Acupuncture, for trigeminal nerve injuries, 5, 224, 225, 230, 356
- Adrenocorticosteroids, for trigeminal nerve injuries, 5, 129, 130
- Afferent nerve fibers, in trigeminal nerve injuries, 22, 127
- Alcohol neurolysis, for trigeminal nerve injuries, 4, 130, 298
- Allodynia, in trigeminal nerve injuries, sensory testing of, 11, 145
- Allogeneic nerve guide systems, for trigeminal nerve injuries, 96, 103, 234, 236, 282
- Alloplastic materials, in nerve reconstruction
 - historical aspects of, 10, 283–289
 - indications for, 283
 - relationship of nerve to bone in, 50
 - theoretical basis of, 283
 - types of, 283–288
- Anesthesia dolorosa, in trigeminal nerve injuries, sensory testing of, 4, 185, 299, 351
- Anesthesia, local, for trigeminal nerve injuries, 18, 38, 51, 63, 74, 128, 131, 216, 239, 351
 - of nerves, clinical features of, 21, 23
 - in trigeminal nerve injuries, 66–67
- Anticonvulsant agents, for trigeminal nerve injuries, 298, 299, 357
- Antidepressant agents, for trigeminal nerve injuries, 5, 70, 218, 221, 298, 299, 357
- Anti-inflammatory agents, for trigeminal nerve injuries, 82
- Antisymphathetic agents, for trigeminal nerve injuries, 298
- Autogenous nerve grafts
 - for inferior alveolar nerve injuries, 245, 273–274
 - for lingual nerve injuries, 141, 171, 207, 214–218, 230, 232, 349
 - for peripheral nerve injuries, 34, 46, 91, 149, 156, 157, 169, 185, 230, 277, 301, 302
 - for trigeminal nerve injuries
 - etiology in, 67–68, 74–78, 88–91, 215, 217, 329, 347, 354
 - factors affecting success of, 277–281
 - graft donor considerations in, 291

- graft placement in, 278
 - great auricular nerve graft harvest, 49, 96
 - inferior alveolar nerve preparation, 249–250, 272–273
 - infraorbital nerve preparation, 273, 274, 277–289
 - lingual nerve preparation, 234–237
 - results of, 249–250
 - sural nerve graft harvest, 102, 295–296
- Autonomically maintained pain, of nerves, clinical features of, 2–4
 - Avulsion injuries, of nerves, clinical features of, 23
 - Axonotmesis, clinical features of, 155–157
 - mechanisms of, 34–36

B

- Baclofen, for trigeminal nerve injuries, 298, 299
- Behavioral therapy, for trigeminal nerve injuries, 219–221, 223, 224
- Benzodiazepines, for trigeminal nerve injuries, 298
- Brain-derived nerve growth factor, in nerve regeneration, 163
- Brain stem relay mechanisms, in trigeminal nerve injuries, 299

C

- Capsaicin, for trigeminal nerve injuries, 298
- Carbamazepine, for trigeminal nerve injuries, 221
- Chemical injuries, of nerves, clinical features of, 21
- Clonazepam, for trigeminal nerve injuries, 220, 229
- Clonidine, for trigeminal nerve injuries, 298, 299
- Collateralization, of nerves, in trigeminal nerve injuries, 185
- Compartment syndrome, of nerves, clinical features of, 92
- Compression injuries, of nerves, clinical features of, 51
 - mechanisms of, 51
- Conduction blocks, clinical features of, 18
- Crush injuries, of nerves, regeneration of, 302, 330
- Cryoneurolysis, for trigeminal nerve injuries, 356

D

- Deafferentation, of nerves, mechanisms of, 361
- Deep brain stimulation, for trigeminal nerve injuries, 5
- Degeneration, nerve injuries
 - anatomy in, 2
 - axonal reaction in, 69, 75, 159–160
 - cellular reaction in, 159
 - receptor reaction in, 7
 - transganglionic, 130
- Disk-Criminator, to test nerve injuries, of hand, 179
- Dysesthesia, of nerves, clinical features of, 3, 23
 - in trigeminal nerve injuries, mechanisms of
(*see* Trigeminal nerve injuries)

E

- Electroacupuncture, for trigeminal nerve injuries, 5, 356
- Entubulization, in nerve reconstruction, 237
- Extraneural pathosis, in trigeminal nerve injuries, 210

F

- Face, nerve injuries of. *See* Nerve injuries

G

- Gasserian ganglion glycerolysis, for trigeminal nerve injuries, 4, 204
- Glycerolysis, for trigeminal nerve injuries, 298
- Grafts, autogenous nerve. *See* Autogenous nerve grafts
- Great auricular nerve Transfer, in microneurosurgery, for trigeminal nerve injuries.
See Microneurosurgery
- Growth-associated protein, in nerve regeneration, 164

H

- Hands, nerve injuries of. *See* Nerve injuries
- Hyperalgesia, in trigeminal nerve injuries, sensory testing of, 11, 131
- Hyperesthesia, of nerves, in trigeminal nerve injuries, 23, 131
- Hyperpathia, in trigeminal nerve injuries, sensory testing of, 345, 347
- Hypoesthesia, of nerves, in trigeminal nerve injuries, 73, 131, 132, 183

I

- Inferior alveolar nerve injuries, autogenous nerve grafts for
 - microneurosurgery for. (*See* Microneurosurgery)
 - repair of, complications of, 249–250, 272–273
- Infraorbital nerve injuries, autogenous nerve grafts for
 - microneurosurgery for, 273, 274
 - repair of, complications of, 273, 277, 289
- Injection injuries, of nerves, clinical features of, 66–67
- Intraosseous nerve injuries, clinical features of, 75

L

- Laceration, of nerves, clinical features of, 23
- Lingual nerve injuries, autogenous nerve grafts for microneurosurgery for (*see* Microneurosurgery)
 - repair of, complications of, 234–237

M

- Maxillary nerve injuries, microneurosurgery for.
 - See* Microneurosurgery
- Microneurosurgery
 - for inferior alveolar nerve injuries
 - approximation and mobilization in, 96
 - coaptation in, 244
 - diagnosis in, 87, 343
 - direct neuroorrhaphy in, 102
 - exposure in, 40, 52, 79, 104, 292, 294, 352
 - indications for, 113
 - internal neurolysis in
 - interpositional nerve grafts in, 96, 245–248
 - microdissection and external neurolysis in, 101–102, 131
 - nerve end resection and preparation in, 4
 - nerve transfer in, 259
 - transcervical exposure in, 70
 - transoral exposure in, 70
 - for lingual nerve injuries
 - indications for, 231
 - patterns of injury in, 83
 - preoperative assessment in, 200
 - prognosis for, 206
 - technique for, 231–234
 - for maxillary nerve injuries, 144–145
 - infraorbital nerves, 144
 - preoperative assessment for, 144
 - for trigeminal nerve injuries
 - choice of approaches in, 217
 - excessive, 7
 - hemostasis in, 234, 263
 - indications and timing for, 9, 217, 343
 - indications for, 231
 - instruments for, 8
 - new developments in, 1, 5
 - patient preparation for, 288
 - postoperative course in, 73
 - prognosis for, 10
 - results of, 1
 - success rates of, 291, 317
 - sutures in, 4, 48, 234
 - technique for, 199–211
 - types of procedures in, 36, 37
- Minnesota Thermal Disks, to test perioral sensory function, 183

N

- Narcotic agents, for trigeminal nerve injuries, 298
- Nerve blocks
 - to diagnose trigeminal nerve injuries
 - literature review in, 37
 - local infiltration in, 37

- sequence of, 49, 158
 - sympathetically independent pain *vs.*
 - sympathetically mediated pain, 174, 185
 - sympathetic innervation in, 253
 - trigeminal sensory block, 10
 - sensory testing of, 347
 - Nerve growth factor, in nerve regeneration, 163
 - Nerve injuries. *See also* Trigeminal nerve injuries
 - classification of
 - anatomic, 27–29
 - duration of injury in, 41
 - histopathologic, 190
 - pathophysiologic, 114
 - physiologic conduction block, 127
 - Seddon, 18, 156, 190
 - Sunderland, 18, 156, 190
 - symptomatic, 40, 51
 - evaluation of, 91, 167–196
 - of face and hand
 - classification of, 17, 18
 - normal and abnormal sensibility in, 304–307
 - painful sequelae of, 1, 8
 - sensory evaluation of, 345–347, 354
 - surgery for, preoperative preparation for,
 - technique for, 8
 - inferior alveolar, microneurosurgery for
 - (*see* Microneurosurgery)
 - lingual, microneurosurgery for
 - (*see* Microneurosurgery)
 - maxillary, microneurosurgery for
 - (*see* Microneurosurgery)
 - normal response to
 - degeneration (*see* Degeneration, nerve injuries)
 - regeneration (*see* Regeneration, nerve injuries)
 - peripheral (*see* Peripheral nerve injuries)
 - reconstruction of, alloplastic materials in
 - (*see* Alloplastic materials, in nerve reconstruction)
 - repair of, results of
 - techniques for, 231–234
 - timing of, 9, 170
 - Nerve mobilization release, for lingual nerve injuries, 33, 240
 - Nervesharing procedures, for trigeminal nerve injuries, 104
 - Neurapraxia, clinical features of, 18
 - Neuroablation
 - behavioral, 356
 - indications for, 355
 - pharmacologic
 - anticonvulsant agents, 298, 357
 - antidepressant agents, 298, 357
 - antiinflammatory and topical agents, 298, 357
 - antisympathetic agents, 298
 - local anesthetics, 298
 - narcotic agents, 298, 357
 - physiologic
 - acupuncture and electroacupuncture, 5, 356
 - deep brain stimulation, 5
 - peripheral nerve implant stimulation, 5
 - transcutaneous electrical nerve stimulation, 5, 356
 - repair of, complications of
 - inferior alveolar nerve, 54–55, 351
 - lingual nerve, 351
 - nerve graft reconstruction, 102
 - neuroorrhaphy, 102
 - sural nerve harvest, 102, 295–296
 - terminology in, glossary of, 109
 - treatment of, algorithm for, 234
 - for trigeminal nerve injuries
 - alcohol neurolysis in, 4
 - choice of methods for, 273
 - cryoneurolysis in, 129
 - Gasserian ganglion glycerolysis in, 4
 - indications for, 231
 - literature review in, 214
 - peripheral glycerolysis in, 4
 - peripheral nerve section and avulsion in, 23
 - placebo blocks in, 5
 - radiofrequency thermal neurolysis in, 4, 299
 - trigger point injection in, 5, 7
 - Neurolysis
 - for inferior alveolar nerve injuries, 317, 331, 338
 - for lingual nerve injuries, 230, 233–235
 - for trigeminal nerve injuries, 101–102, 131, 293, 317, 328, 333
 - Neuromas, clinical features of
 - in lingual nerve injuries, excision of, 318
 - mechanisms of, 6, 8
 - in peripheral nerve injuries, 6, 355
 - in trigeminal nerve injuries, excision of
 - sensory testing of, 6
 - traumatic, 4, 6, 7, 11
 - Neuropathies, central, clinical features of
 - Neuroorrhaphy
 - for inferior alveolar nerve injuries, 102
 - for lingual nerve injuries, 102
 - for trigeminal nerve injuries
 - complications of, 102
 - Neurotmesis, clinical features of, 19–21
 - Nociception, brain stem relay mechanisms in, 128
 - Nonsteroidal antiinflammatory agents, for trigeminal nerve injuries, 93, 129, 215, 292, 354
- P**
- Paresthesia, of nerves, clinical features of
 - in trigeminal nerve injuries, mechanisms of
 - (*see* Trigeminal nerve injuries)
 - Perioral sensory function, evaluation of
 - multiple tests in, 303, 357
 - test of simple contact detection in, 306
 - test of spatial resolution acuity in, 347
 - test of tactile direction discrimination in, 128
 - test of warm/cold discrimination in, 324
 - Peripheral glycerolysis, for trigeminal nerve injuries, 1, 2, 6, 7, 12, 105, 156, 160, 161, 168, 169, 176, 185, 288, 301–303, 307, 309

Peripheral nerve implant stimulation, for trigeminal nerve injuries, 224, 225

Peripheral nerve injuries
 vs. central nerve injuries, 7
 nerve regeneration in, 81, 288
 nerve repair and grafting for, 165, 271, 278, 288, 351
 painful neuromas in, 7
 reconstruction of, 130, 131, 284

Phentolamine test, of sympathetically mediated pain, in trigeminal nerve injuries, 6, 128–129, 174, 185, 351, 355

Polyglycolic acid, in tubulization, for trigeminal nerve injuries, 10, 283–287, 289, 297

Psychogenic pain, in trigeminal nerve injuries, sensory testing of, 185

Psychotherapy, for trigeminal nerve injuries, 350

R

Radiofrequency thermal neurolysis, for trigeminal nerve injuries, 4, 299

Receptors, in trigeminal nerve injuries, 7, 127, 128, 161–163, 225, 259, 303, 306, 320, 329

Referred pain, in trigeminal nerve injuries, 2

Regeneration, nerve injuries
 axonal recovery in, 158, 161–163, 286
 cellular recovery in, 149
 in crush injuries, 157
 receptor recovery in, 161, 162

Rupture, of nerves, clinical features of, 164, 209

S

Seddon classification, of nerve injuries, 18, 155, 190

Semmes-Weinstein monofilaments, to test nerve injuries, of hand, 128, 173, 179, 181–182, 184

Silicone tubes, in nerve reconstruction, 283–284

Soft tissue nerve injuries, clinical features of, 10–11, 21, 39–44, 50, 54, 56, 74–78, 88, 89, 91, 96, 101, 115, 141, 144, 174, 175, 202, 203, 206, 208, 233, 241, 245, 278, 285, 333, 351, 355, 362

Somatosensory evoked potentials, in electrophysical assessment, of trigeminal nerve injuries, 168, 200, 206

Somatosensory transmission mechanisms, in trigeminal nerve injuries, 304

Stretch injuries, of nerves, clinical features of, 88, 156
 mechanisms of, 155

Sunderland classification, of nerve injuries, 18–20, 23, 155, 156, 183, 190, 330

Sural nerve, harvest of, for autogenous nerve grafts, for trigeminal nerve injuries, 52, 97, 102, 295, 297

Sympathetically mediated pain, in trigeminal nerve injuries, 355, 362
 nerve blocks for (*see* Nerve blocks)

T

Taste, sensory testing of, in trigeminal nerve injuries, 176

Temperature, brain stem relay mechanisms in, 299

Thalamocortical relay mechanisms, in trigeminal nerve injuries, 7, 8

Touch, brain stem relay mechanisms in, 105, 304

Transcutaneous electrical nerve stimulation, for trigeminal nerve injuries, 2, 225, 356

Transection injuries, of nerves, clinical features of, 155, 159, 208, 243, 244

Tricyclic antidepressant agents, for trigeminal nerve injuries, 357

Trigeminal nerve injuries. *See also* Nerve injuries
 anatomy and physiology of
 brain stem relay mechanisms, 299
 dynamic aspects of neural function, 5, 8
 receptors and afferent nerve fibers, 22, 127
 somatosensory transmission mechanisms, 8
 thalamocortical relay mechanisms, 7, 8
 autogenous nerve grafts for (*see* Autogenous nerve grafts)
 causes and incidence of, 36–57
 clinical evaluation of
 for decreased altered sensation, 168, 179–183
 patient interview in, 344–345
 physical examination in, 345–348
 sensory testing in, 345–348
 for unpleasant altered sensation, 183–185
 clinical patterns of
 painful anesthesia and hypoesthesia, 23
 painful hyperesthesia, 23
 diagnosis of, algorithm for
 deafferentation, 189
 dysesthesias and paresthesias in, mechanisms of, 6
 nerve blocks in (*see* Nerve blocks)
 neuromas, 130
 segmental myelination, 302
 electrophysical assessment of
 abnormal results of, 200
 clinical studies of, 168
 somatosensory evoked potentials in, 141, 168, 200
 historical aspects of, 1–11
 management of, future applications in
 allogeneic nerve guide systems, 282
 enhanced nerve regeneration, 1, 9–11
 neurosensory testing methods, 346
 microneurosurgery for (*see* Microneurosurgery)
 pathophysiology of
 dysautonomia and pain affect, 131
 hyperesthesia and pain, 23, 24
 hypoesthesia, 21, 23, 24
 paresthesia, 23, 24
 referred pain and collateralization, 185
 surgical observations of, 130
 temporal patterns of, 257