

ANATOMY

- [Eye anatomy](#)

ANTERIOR CHAMBER

- [Angle, Closure](#)
- [Angle, Pigmentation](#)
- [Anterior chamber IOL](#)
- [Atalamia](#)
- [Hyphema](#)
- [Hyphema](#)
- [Hyphema](#)
- [Hyphema](#)
- [Hyphema](#)
- [Hyphema](#)
- [Hyphema](#)
- [Silicon bubble](#)
- [Synchysis scintillans](#)

CHOROID

- [Angioid Streaks](#)

CONJUNCTIVA

- [Allergic conjunctivitis, Giant papillae](#)
- [Allergic conjunctivitis, Giant papillae](#)
- [Allergic conjunctivitis, Giant papillae](#)
- [Amyloidosis](#)
- [Bacterial conjunctivitis](#)
- [Chemosis](#)
- [Cyst, Subconjunctival](#)
- [Conjunctivitis](#)
- [Conjunctivitis](#)
- [Conjunctivitis, Chlamidiae](#)
- [Conjunctivitis, Gonococcal](#)
- [Conjunctivitis, Gonococcal](#)
- [Conjunctivitis, Gonococcal](#)
- [Conjunctivitis, Ligneous](#)
- [Conjunctivitis, Viral](#)

- [Dermoid, Epibulbar](#)
- [Follicular conjunctivitis](#)
- [Folliculosis](#)
- [Kaposi's sarcoma](#)
- [Lipoma](#)
- [Lymphoma, Subconjunctival](#)
- [Melanosis](#)
- [Nevus](#)
- [Nevus](#)
- [Nevus](#)
- [Nevus](#)
- [Nevus](#)
- [Nevus, Caruncle](#)
- [Nevus, Caruncle](#)
- [Nevus](#)
- [Osler-Weber-Rendu syndrome](#)
- [Pterygium](#)
- [Simblefaron](#)
- [Sturge-Weber syndrome](#)
- [Subconjunctival hemorrhage](#)
- [Subconjunctival hemorrhage](#)
- [Subconjunctival hemorrhage](#)
- [Trachoma, Arlt](#)
- [Vernal conjunctivitis](#)
- [Vernal conjunctivitis](#)
- [Vernal conjunctivitis](#)
- [Vernal conjunctivitis](#)

CORNEA

- [Abrasion](#)
- [Abrasion](#)
- [Abrasion](#)
- [Alkali burn](#)
- [Alkali burn](#)
- [Alkali burn \(neovascularization\)](#)
- [Band keratopathy](#)
- [Band keratopathy](#)
- [Band keratopathy](#)
- [Contact lens](#)
- [Dystrophy, Granular](#)
- [Dystrophy, Latex](#)
- [Dystrophy, Latex](#)

- [Dystrophy, Meesman](#)
- [Dystrophy, Meesman](#)
- [Dystrophy, Salzmann](#)
- [Embriotoxon, Posterior](#)
- [Fabrys' disease](#)
- [Fabrys' disease](#)
- [Foreign body](#)
- [Foreign body](#)
- [Gerontoxon](#)
- [Hydrops](#)
- [Hurler's syndrome](#)
- [Hurler's syndrome](#)
- [Keratitis, Achantoameba](#)
- [Keratitis, Aspergillus](#)
- [Keratitis, Epidemic](#)
- [Keratitis, Fungal](#)
- [Keratitis, Fungal](#)
- [Keratitis, Herpes simplex](#)
- [Keratitis, Herpes simplex](#)
- [Keratitis, Herpes simplex](#)
- [Keratitis, Herpes simplex](#)
- [Keratitis, Herpes simplex](#)
- [Keratitis, Herpes simplex](#)
- [Keratitis, Serratia Marcescens](#)
- [Keratitis, Trachoma](#)
- [Keratoconus](#)
- [Keratoconus](#)
- [Keratoconus](#)
- [Keratoconus, Acute hydrops](#)
- [Keratoconus, Apex syndrome](#)
- [Keratoconus, Contact lens](#)
- [Keratoconus, Fleischer's ring](#)
- [Keratoconus, Fleischer's ring](#)
- [Keratoconus, Munson's sign](#)
- [Keratoconus, Vogt's striae](#)
- [Keratoplasty](#)
- [Keratoplasty, Corneal infection](#)
- [Keratoplasty, Corneal rejection](#)
- [Keratoplasty, Corneal rejection](#)
- [Latex dystrophy](#)
- [Leukoma](#)
- [Leukoma, Neovascularization](#)
- [Leukoma, Herpetic scar](#)

- [Limbal dermoid](#)
- [Lipidic degeneration](#)
- [Mooren's ulcer](#)
- [Mooren's ulcer](#)
- [Neovascularization](#)
- [Neovascularization](#)
- [Neurotrophic keratopathy](#)
- [Terrien's marginal degeneration](#)
- [Terrien's marginal degeneration](#)
- [Tumor, Epithelial](#)
- [Sclerocornea](#)
- [Vortex dystrophy](#)
- [Wilson's disease](#)

EXTRAOCULAR MUSCLES

- [Accomodative strabismus](#)
- [Accomodative strabismus](#)
- [Brown's syndrome](#)
- [Duane's syndrome](#)
- [Duane's syndrome](#)
- [Duane's syndrome](#)
- [Elevator superior muscle paralysis](#)
- [Endotropia](#)
- [Endotropia, High myopia](#)
- [Oblique superior muscle paralysis](#)
- [Oblique superior muscle paralysis](#)
- [SLA](#)
- [SLA](#)
- [Tilt](#)
- [Tilt](#)
- [Vertical dissociated deviation](#)

GLOBE

- [Anophthalmos](#)
- [Anophthalmos](#)

GLAUCOMA

- [Angle recession](#)
- [Glaucoma, Acute](#)
- [Glaucoma, Closure angle](#)

- [Glaucoma, Closure angle](#)
- [Glaucoma, Closure angle](#)
- [Glaucoma, Congenital](#)
- [Glaucoma, Congenital](#)
- [Glaucoma, Congenital](#)
- [Glaucoma, Neovascular](#)
- [Phacolytic glaucoma](#)
- [Pseudoexfoliative glaucoma](#)
- [Trabeculectomy, Bleb](#)
- [Trabeculectomy, Bleb](#)
- [Trabeculectomy, Bleb](#)
- [Trabeculectomy, Bleb](#)

INTRAOCULAR PRESSURE

- [Bleb after trabeculectomy](#)
- [Glaucoma cupping](#)
- [Neovascular glaucoma](#)
- [Pseudoexfoliation](#)

IRIS AND CILIARY BODY

- [Aniridia](#)
- [Anisocoria](#)
- [Ciliary body adenoma](#)
- [Coloboma](#)
- [Corectopia](#)
- [Ectropion uveae](#)
- [Epithelial iris cyst](#)
- [Epithelial iris cyst](#)
- [Eterochromia](#)
- [Iridectomy](#)
- [Iridectomy](#)
- [Iris dialysis](#)
- [Nevus](#)
- [Pigmented iris cyst](#)
- [Sectorial atrophy](#)
- [Wilson's disease](#)

LACRIMAL SYSTEM

- [Canaliculitis](#)

- [Canaliculitis](#)
- [Dacryoadenitis](#)
- [Dacryocele](#)
- [Dacryocistitis](#)
- [Dacryocistitis](#)
- [Dacryocistitis](#)
- [Mucocele](#)
- [Nasolacrimal obstruction](#)
- [Pseudocanaliculitis](#)
- [Pseudocanaliculitis](#)

LENS

- [Aphakia, Surgical](#)
- [Capsular fibrosis](#)
- [Capsular fibrosis](#)
- [Capsule rupture](#)
- [Capsulotomy, YAG](#)
- [Cataract](#)
- [Cataract, Congenital](#)
- [Cataract, Congenital](#)
- [Cataract, Corticonuclear](#)
- [Cataract, Mature](#)
- [Cataract, Mature](#)
- [Cataract, Mature](#)
- [Cataract, Mature](#)
- [Cataract, Morgagnian](#)
- [Cataract, Morgagnian](#)
- [Cataract, Morgagnian](#)
- [Cataract, Secondary](#)
- [Cataract, Surgery](#)
- [Cataract surgery, Animated GIF](#)
- [Cataract, Sutural](#)
- [Cataract, Traumatic](#)
- [Cataract, Traumatic](#)
- [Elschnig pearls](#)
- [IOL, Anterior chamber](#)
- [IOL, Anterior chamber](#)
- [IOL, Luxation](#)
- [IOL, Posterior chamber](#)
- [Luxated lens](#)
- [Luxated lens](#)
- [Luxated lens](#)

- [Luxated lens](#)
- [Pseudoexfoliatio lentis](#)
- [Pseudoexfoliatio lentis](#)

LID

- [Allergy, Atropine](#)
- [Chalasis](#)
- [Chalazium](#)
- [Chalazium](#)
- [Chalazium](#)
- [Chalazium](#)
- [Chalazium](#)
- [Coloboma](#)
- [Cyst, Sebaceous](#)
- [Ectropion, Congenital](#)
- [Entropion, Cicatrizial](#)
- [Entropion, Cicatrizial](#)
- [Entropion, Involutional](#)
- [Entropion, Involutional](#)
- [Entropion, Spastic](#)
- [Entropion, Spastic](#)
- [Epiblepharon](#)
- [Gunn, Sign](#)
- [Herpes Zoster](#)
- [Herpes Zoster](#)
- [Kaposi's sarcoma](#)
- [Keratosis](#)
- [Laxity](#)
- [Molluscum contagiosum](#)
- [Hordeolum](#)
- [Hordeolum](#)
- [Hordeolum](#)
- [Papilloma](#)
- [Ptosis](#)
- [Ptosis](#)
- [Trachoma](#)

MISCELLANEOUS

- [Volunteer Eye Care](#)

OPTIC NERVE

- [Coloboma](#)
- [Glaucoma cupping](#)
- [Melanocytoma](#)
- [Melanocytoma](#)
- [Morning glory](#)
- [Morning glory](#)
- [Papilloedema](#)

ORBIT

- [Aicardi syndrome](#)
- [Antrax](#)
- [Carotid-cavernous sinus fistula](#)
- [Cellulitis](#)
- [Cellulitis](#)
- [Cellulitis](#)
- [Crouzon's disease](#)
- [Dermoid](#)
- [Enophtalmos](#)
- [Exenteratio](#)
- [Exophtalmos](#)
- [Preseptal cellulitis](#)
- [Preseptal cellulitis](#)
- [Proptosis \(arterial aneurysma\)](#)
- [Proptosis \(leukaemia\)](#)
- [Retinoblastoma](#)
- [Retinoblastoma, Eucleation](#)
- [Rhabdomyosarcoma](#)
- [Rhabdomyosarcoma](#)
- [Rhabdomyosarcoma](#)
- [Sturge-Weber syndrome](#)
- [Tumor, Lacrimal gland](#)

PUPIL

- [Pupillary block](#)
- [Pupillary block](#)

REFRACTIVE

- [Astigmatic keratotomy, Animated GIF](#)
- [Automated Lamellar Keratoplasty, Animated GIF](#)

- [Hyperopia, Anterior chamber IOL](#)
- [Hyperopia, Anterior chamber IOL](#)
- [LASIK, Animated GIF](#)
- [LASIK, Decentered flap](#)
- [LASIK, Epithelial ingrowth](#)
- [LASIK, Keratitis](#)
- [LASIK, Keratoplasty](#)
- [LASIK, Striae](#)
- [PRK, Animated GIF](#)
- [PRK, Haze](#)
- [PRK, Haze](#)
- [Radial keratotomy](#)
- [Radial keratotomy](#)
- [Refractive defects, Set 1](#)
- [Refractive defects, Set 2](#)

RETINA

- [Angioid streaks](#)
- [Arterial branch occlusion](#)
- [Birdshot retinopathy](#)
- [Chloroquine retinopathy](#)
- [Choroideremia](#)
- [Coloboma, Choroidal](#)
- [Coloboma, Choroidal](#)
- [Coloboma, Choroidal](#)
- [Cytomegalovirus, Retinitis](#)
- [Cytomegalovirus, Retinitis](#)
- [Cytomegalovirus, Retinitis](#)
- [Cytomegalovirus, Retinitis](#)
- [Cytomegalovirus, Vasculitis](#)
- [Detachment](#)
- [Detachment](#)
- [Detachment, Tractional](#)
- [Detachment, Tractional](#)
- [Diabetic retinopathy, Proliferative](#)
- [Diabetic retinopathy, Non proliferative](#)
- [Diabetic retinopathy, Proliferative](#)
- [Drusen, Macular](#)
- [Haemangioma](#)
- [Haemorrhage, Posttraumatic](#)
- [Macular degeneration](#)
- [Macular degeneration](#)

- [Macular haemorrhage](#)
- [Macular hole](#)
- [Macular star](#)
- [Pneumocysti Carinii, Retinitis](#)
- [Purtscher's retinopathy](#)
- [Retinitis pigmentosa](#)
- [Sickle cells retinopathy](#)
- [Toxoplasmosis, Active macular infection](#)
- [Toxoplasmosis, Congenital Scar](#)
- [Toxoplasmosis, Congenital Scar](#)
- [Toxoplasmosis, Congenital Scar](#)
- [Toxoplasmosis, Neuroretinitis](#)
- [Toxoplasmosis, Perimacular scar](#)
- [Toxoplasmosis, Peripapillar scar](#)
- [Toxoplasmosis, Retinal scar](#)
- [Toxoplasmosis, Retinal scar](#)
- [Vein central occlusion](#)
- [Vein branch occlusion](#)

SCLERA

- [Episcleritis, Diffuse](#)
- [Episcleritis, Diffuse](#)
- [Episcleritis, Nodular](#)
- [Scleritis, Nodular](#)

SPECIAL TESTING

- [Autorefractor](#)
- [Computerized corneal map](#)
- [Javal ophthalmometer](#)
- [Javal ophthalmometer](#)
- [Seidel +](#)
- [Slit lamp](#)
- [Slit lamp](#)

UVEITIS

- [Behcet Disease](#)
- [Endophthalmitis, Pneumococcus](#)
- [Endophthalmitis, Pseudomonas](#)
- [Uveitis, IOL](#)

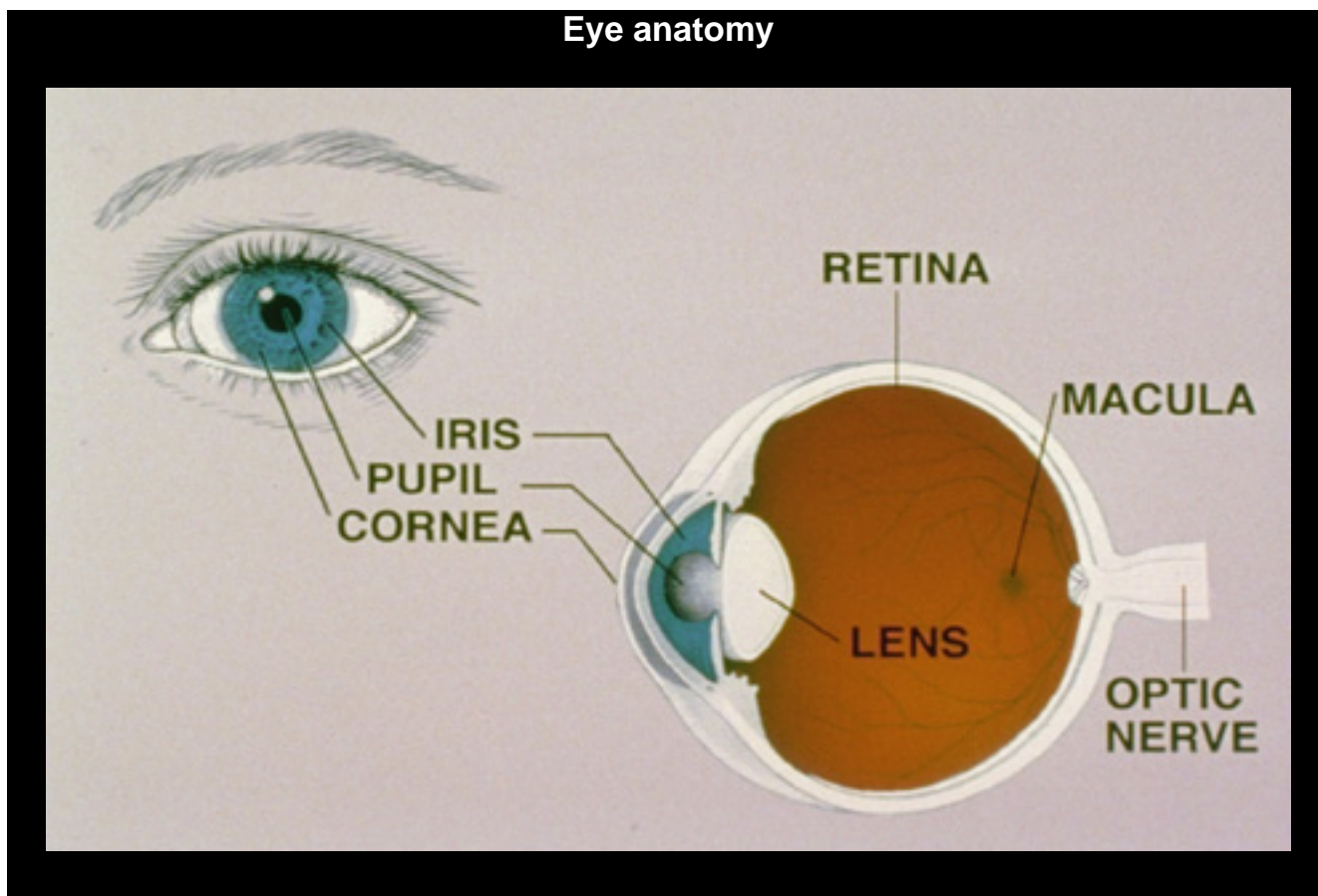
VITREOUS

- [Cholesterolosis](#)
- [Vitreitis](#)

Eyeatlas

The online Atlas of Ophthalmology

Eye anatomy

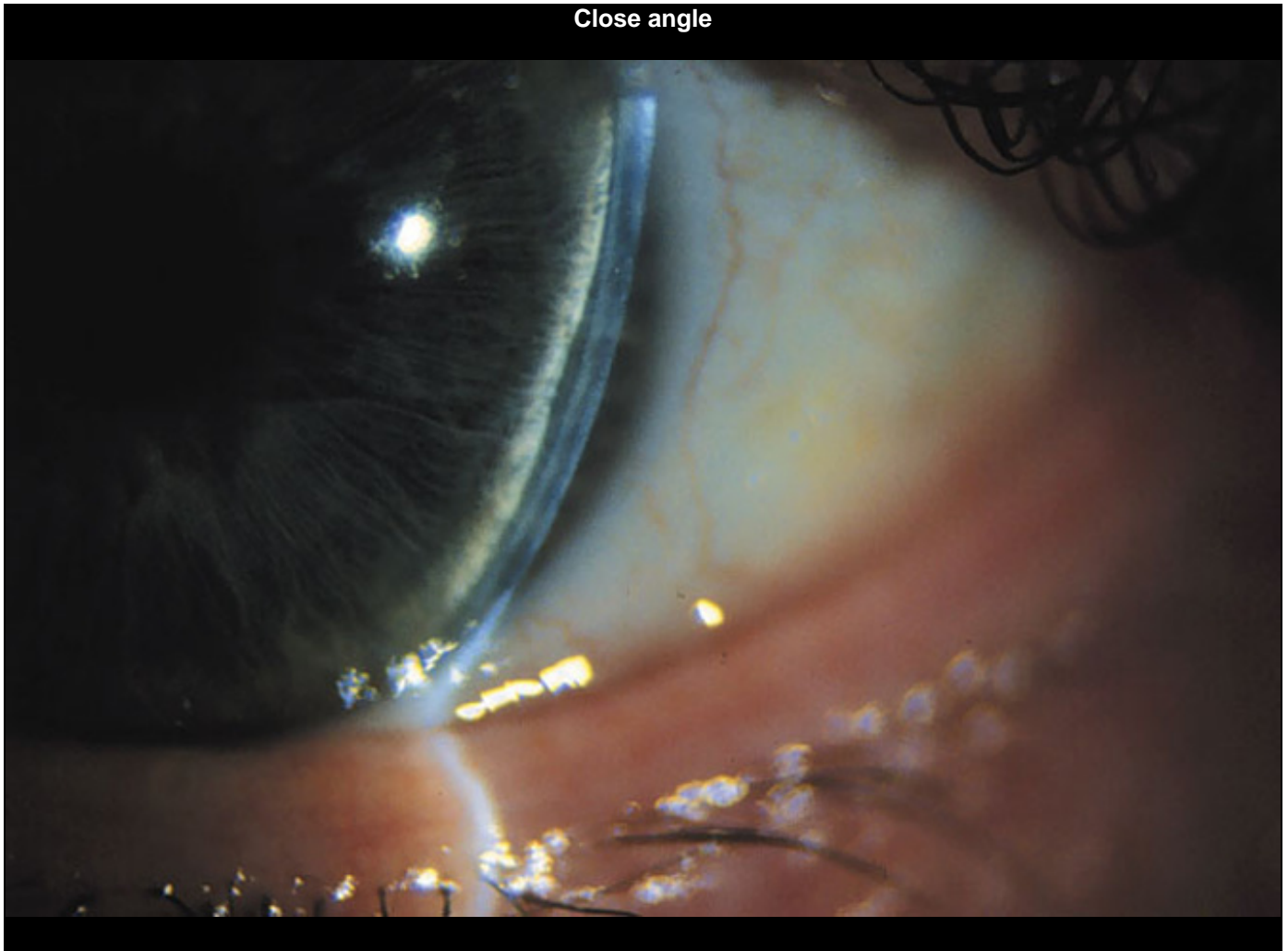


© Copyright [Oculisti OnLine](http://www.eyeatlas.com)

Eyeatlas

The online Atlas of Ophthalmology

Close angle

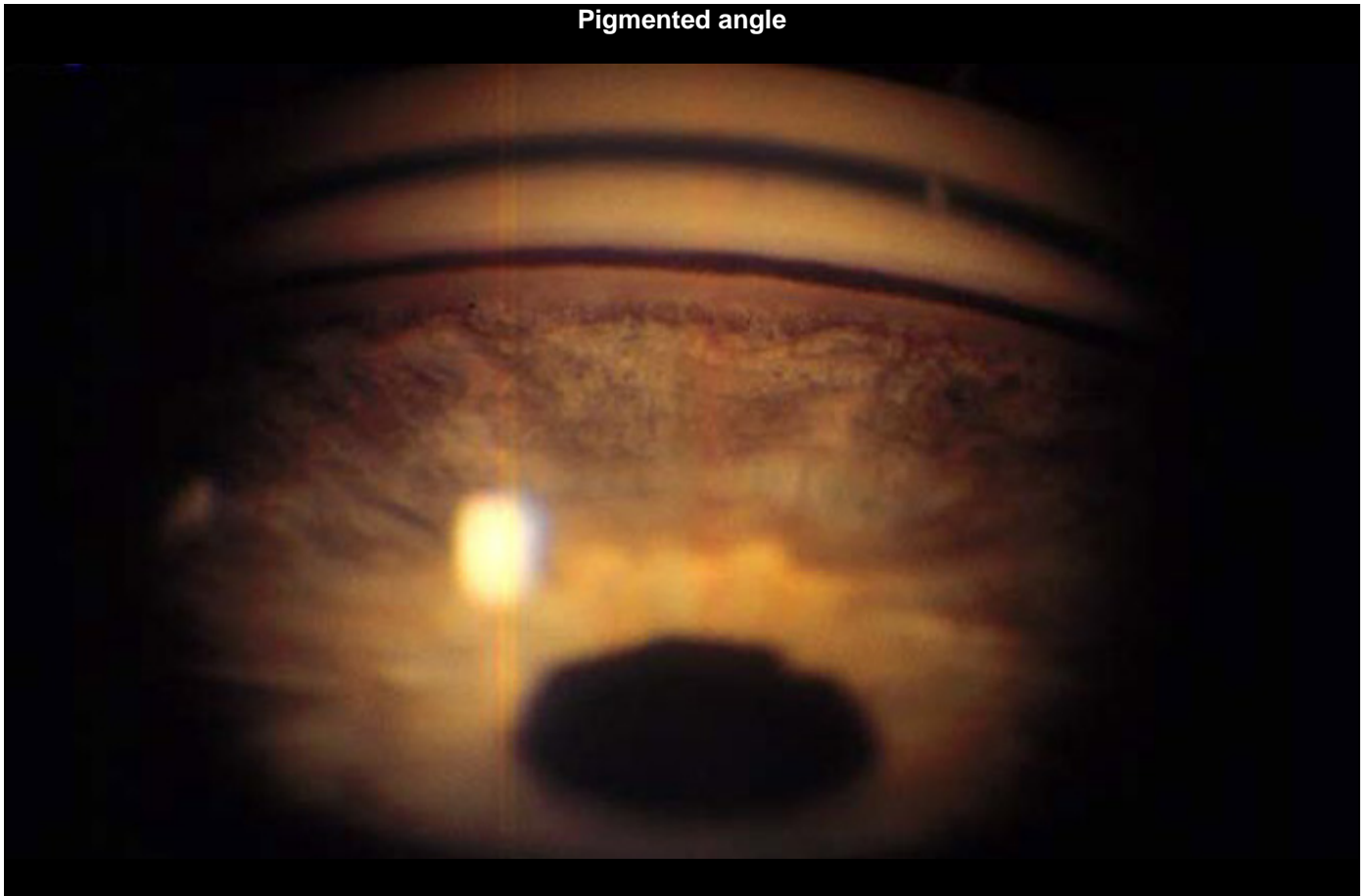


© Copyright [Oculisti OnLine](#)

Eyeatlas

The online Atlas of Ophthalmology

Pigmented angle




© Copyright [Oculisti OnLine](#)

EyeAtlas

The online Atlas of Ophthalmology

Anterior chamber IOL

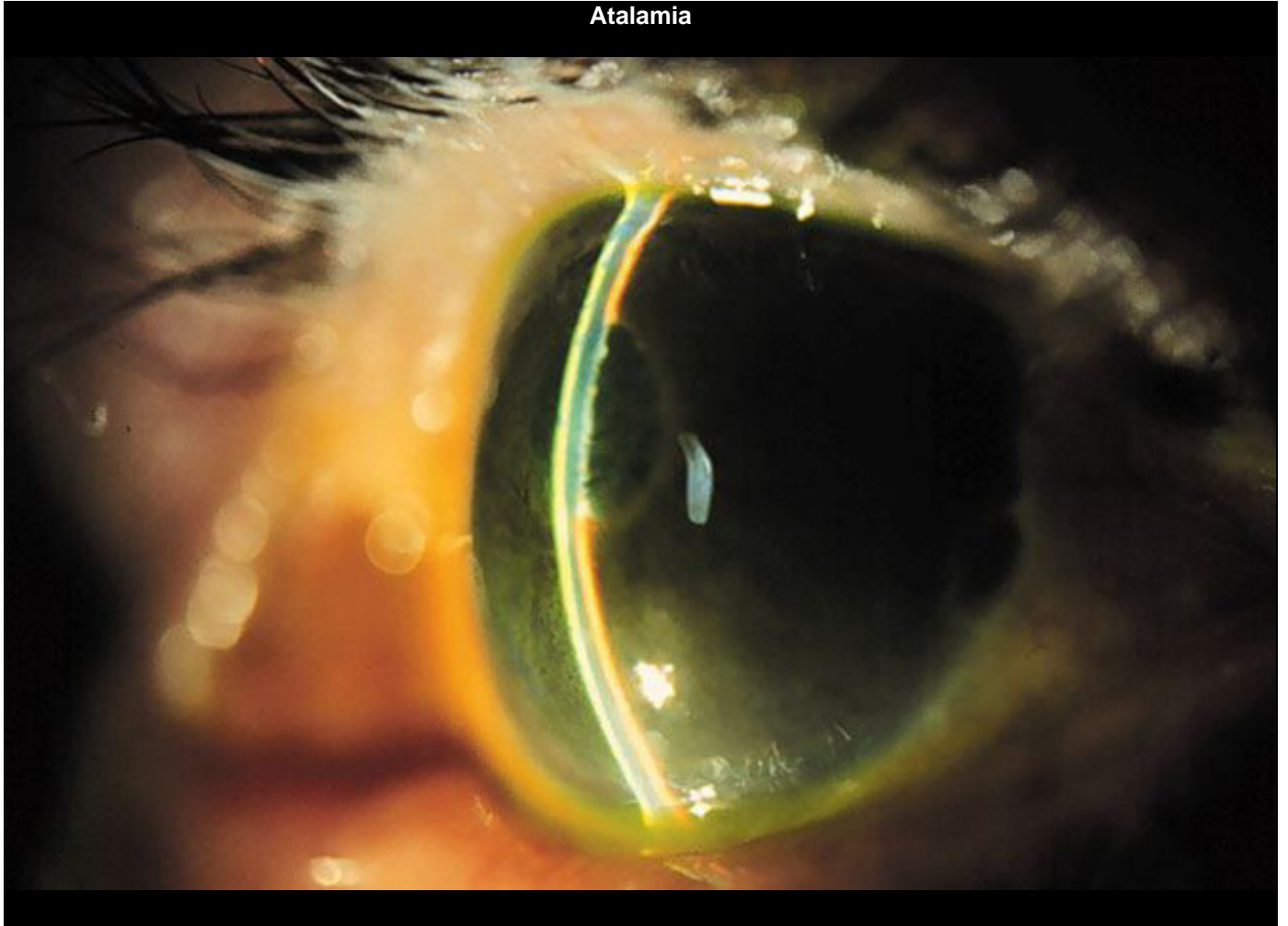

© Copyright [Oculisti OnLine](#)

EyeAtlas

The online Atlas of Ophthalmology

Atalamia

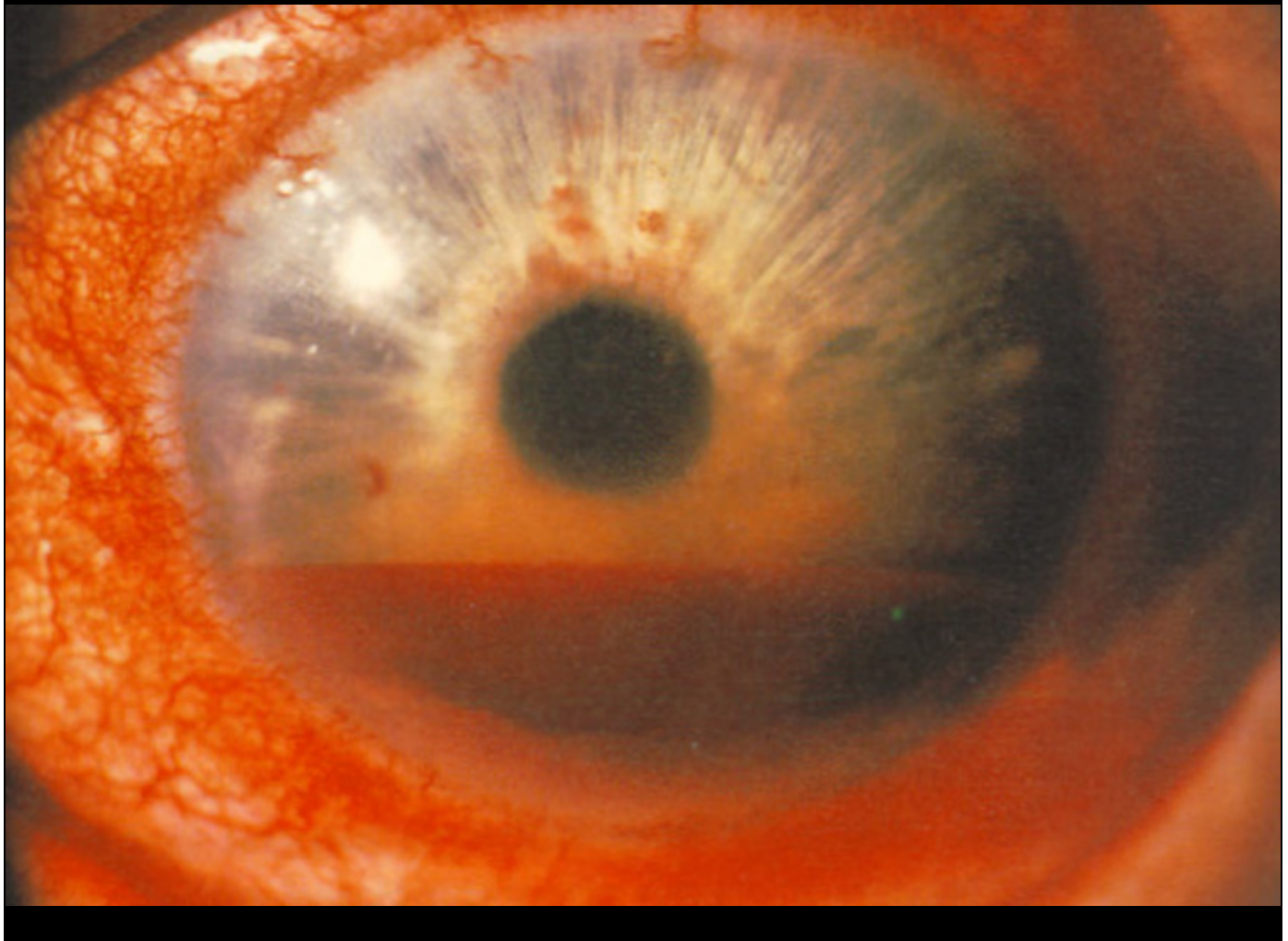


© Copyright [Oculisti OnLine](#)

Eyeatlas

The online Atlas of Ophthalmology

Anterior chamber hyphema

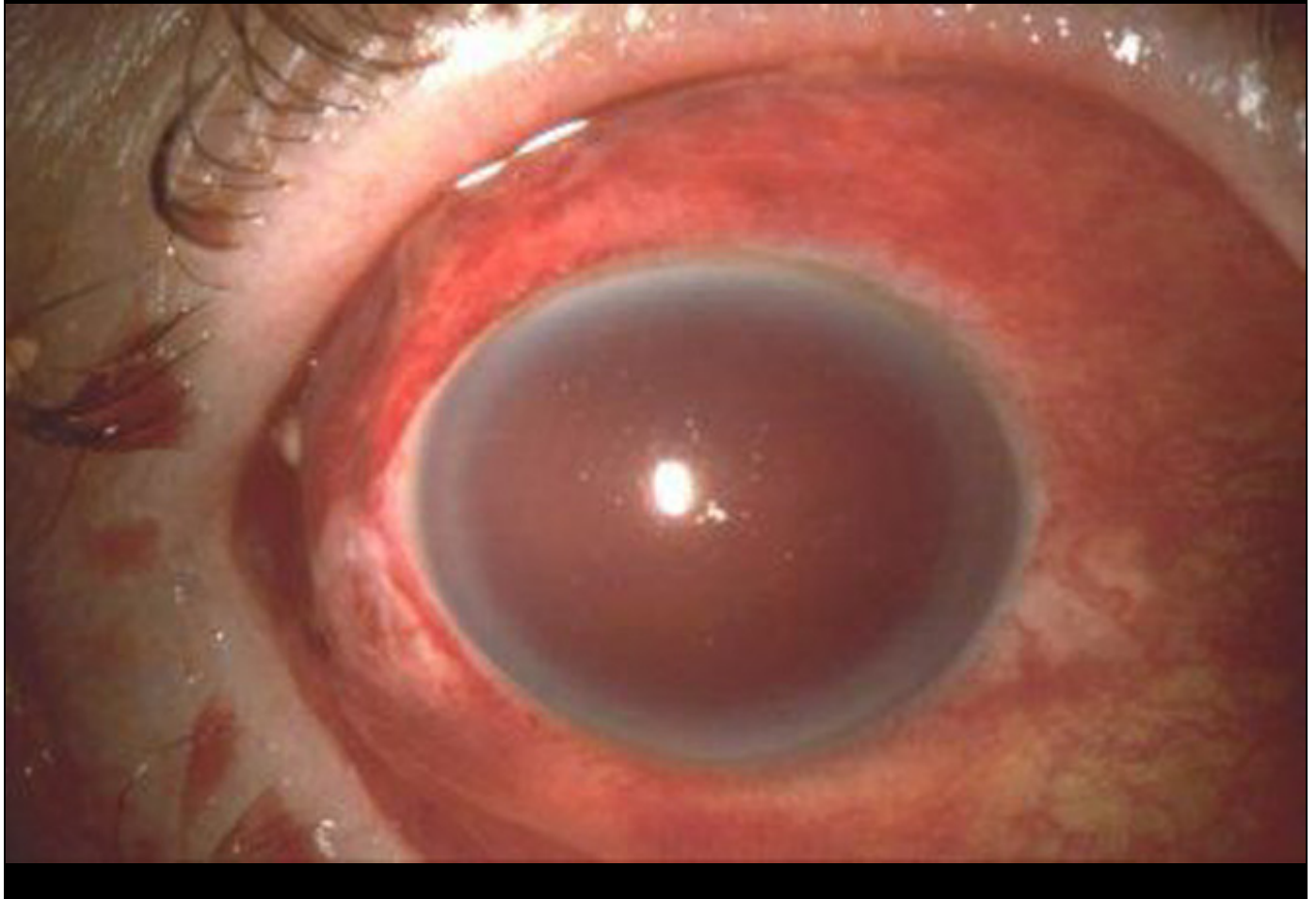


© Copyright [Oculisti OnLine](#)

EyeAtlas

The online Atlas of Ophthalmology

Traumatic hyphema

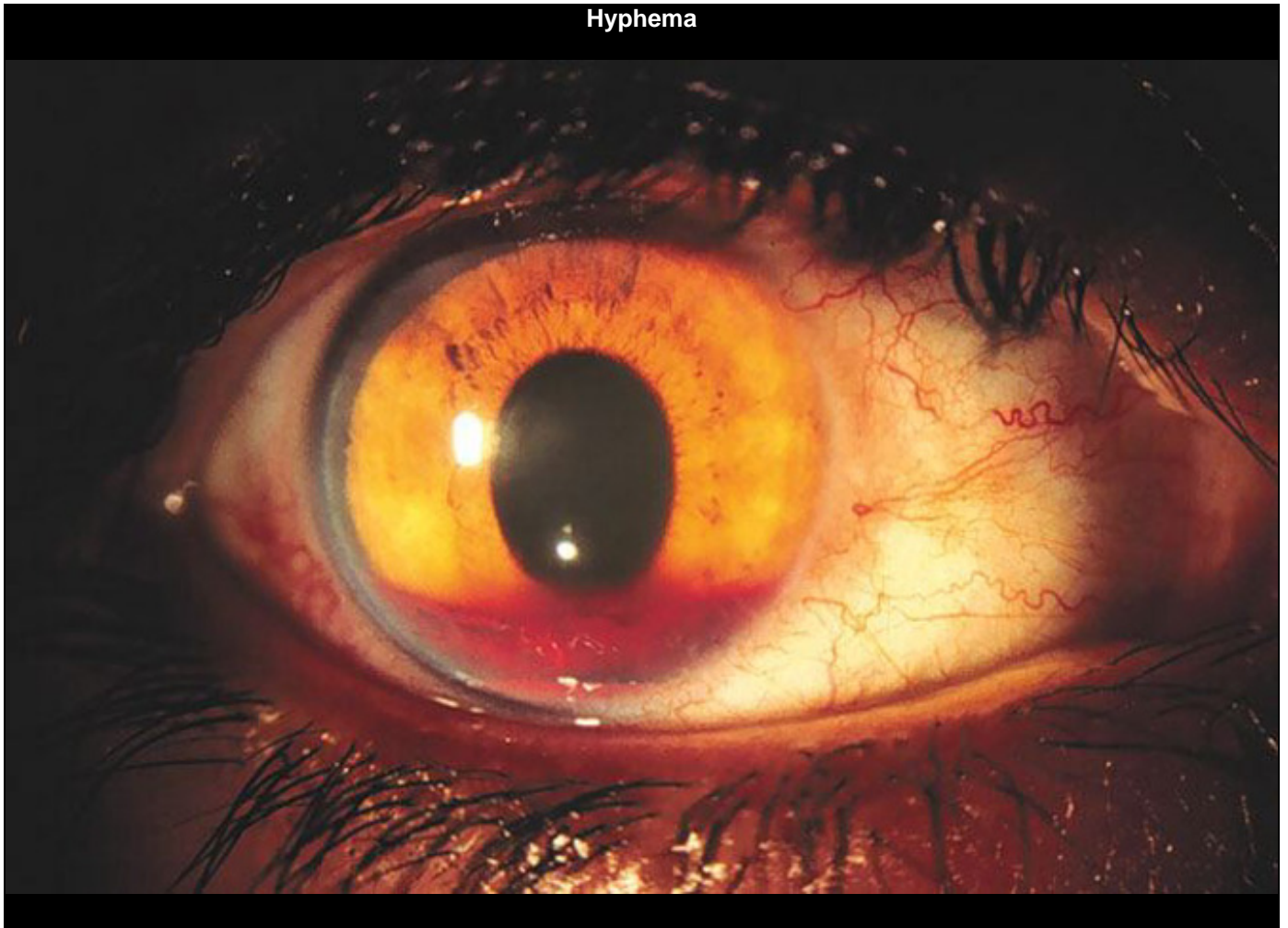


© Copyright [Oculisti OnLine](#)

EyeAtlas

The online Atlas of Ophthalmology

Hyphema

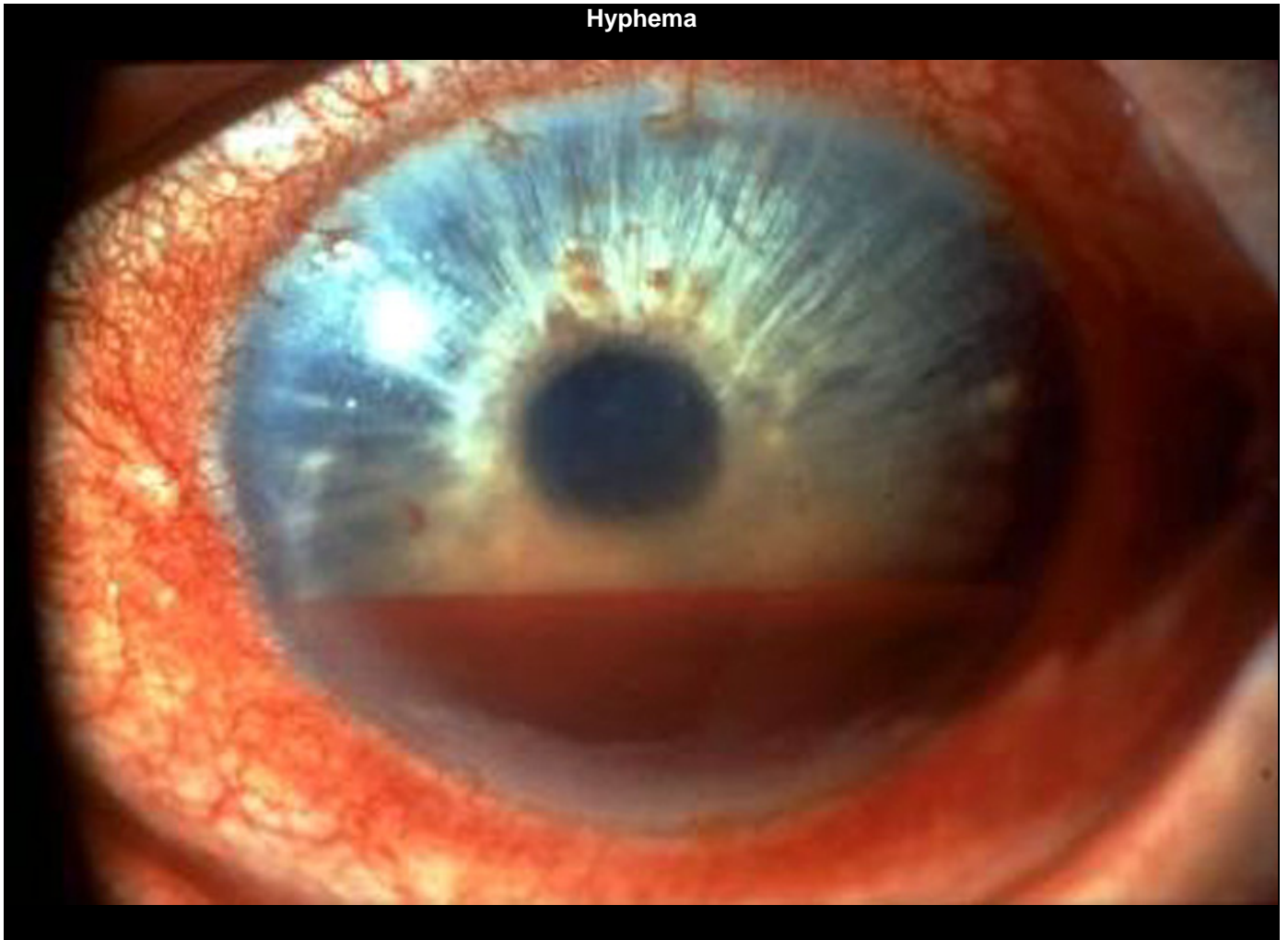


© Copyright [Oculisti OnLine](#)

Eyeatlas

The online Atlas of Ophthalmology

Hyphema

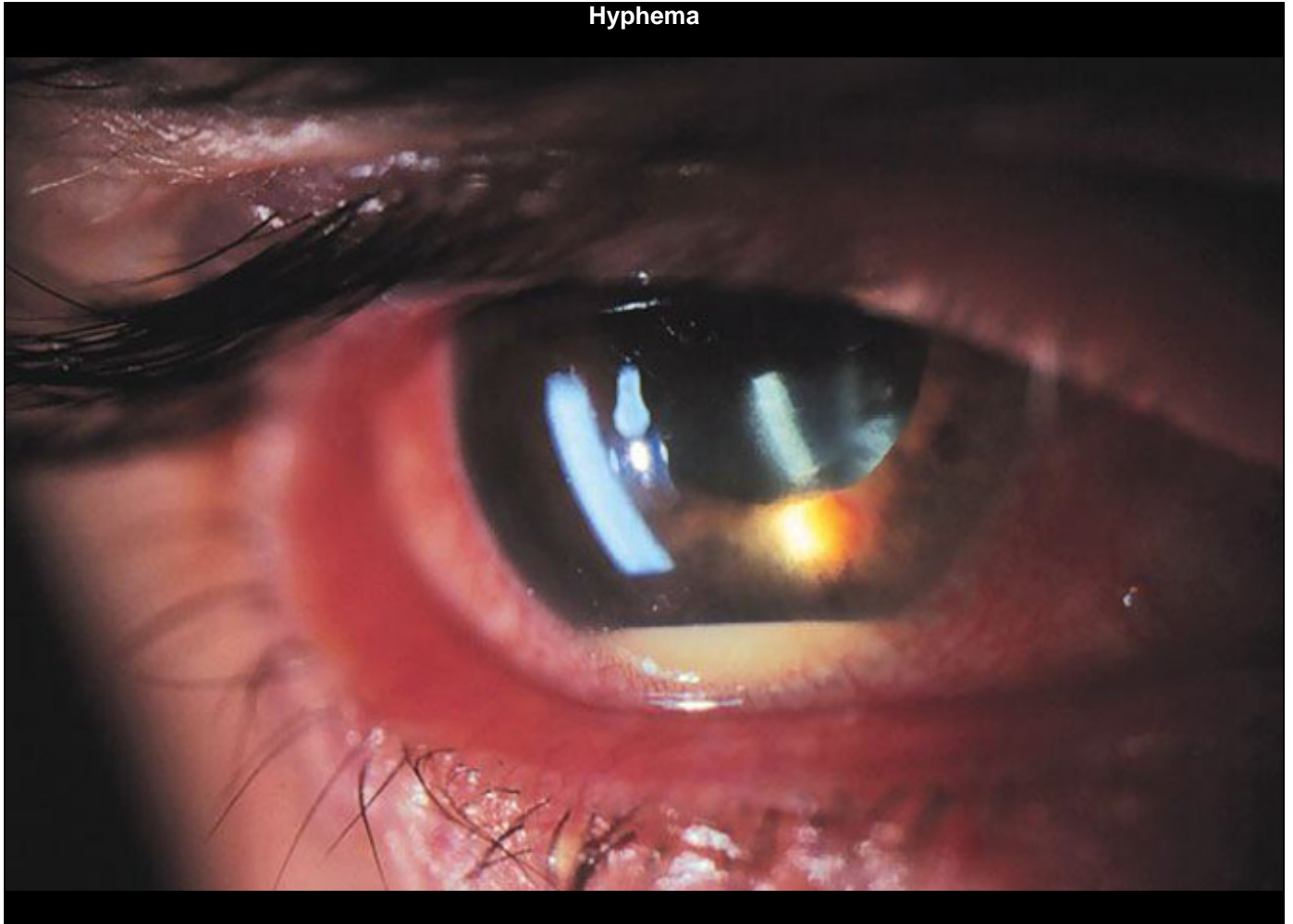

© Copyright [Oculisti OnLine](http://www.eyeatlas.com)

EyeAtlas

The online Atlas of Ophthalmology

Hyphema

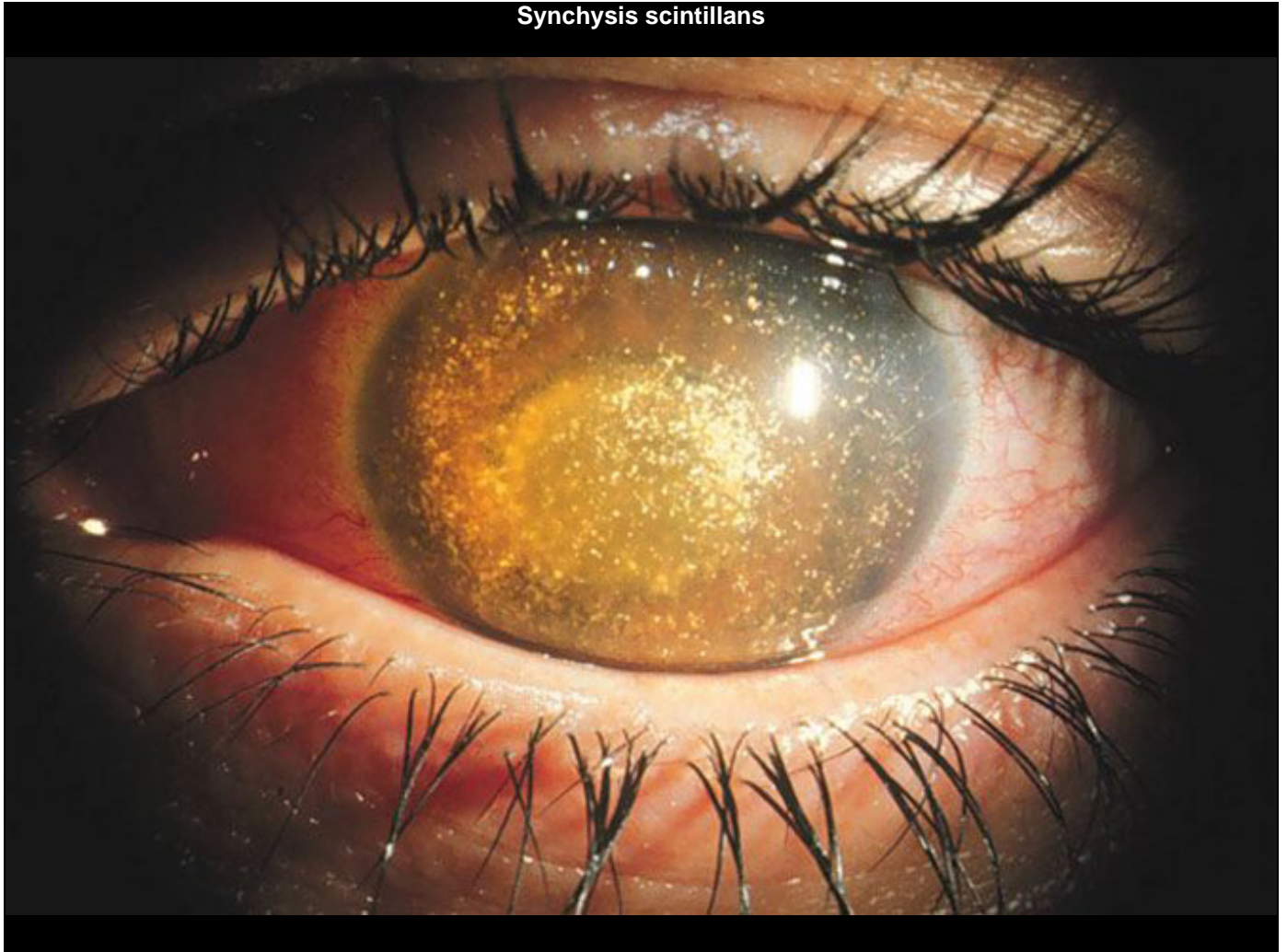


© Copyright [Oculisti OnLine](http://www.eyeatlas.com)

EyeAtlas

The online Atlas of Ophthalmology

Synchysis scintillans

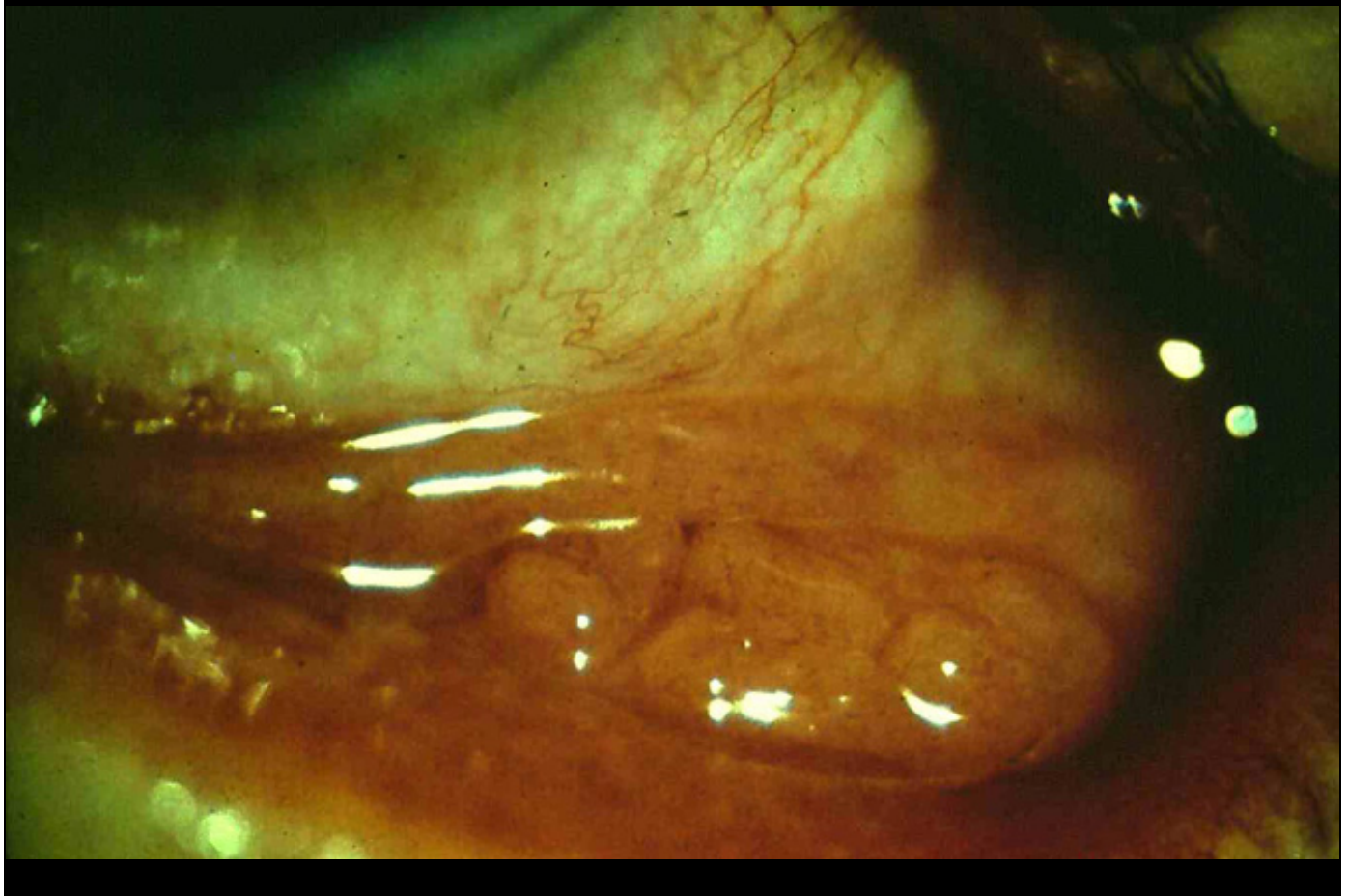

© Copyright [Oculisti OnLine](#)

EyeAtlas

The online Atlas of Ophthalmology

Allergic Conjunctivitis

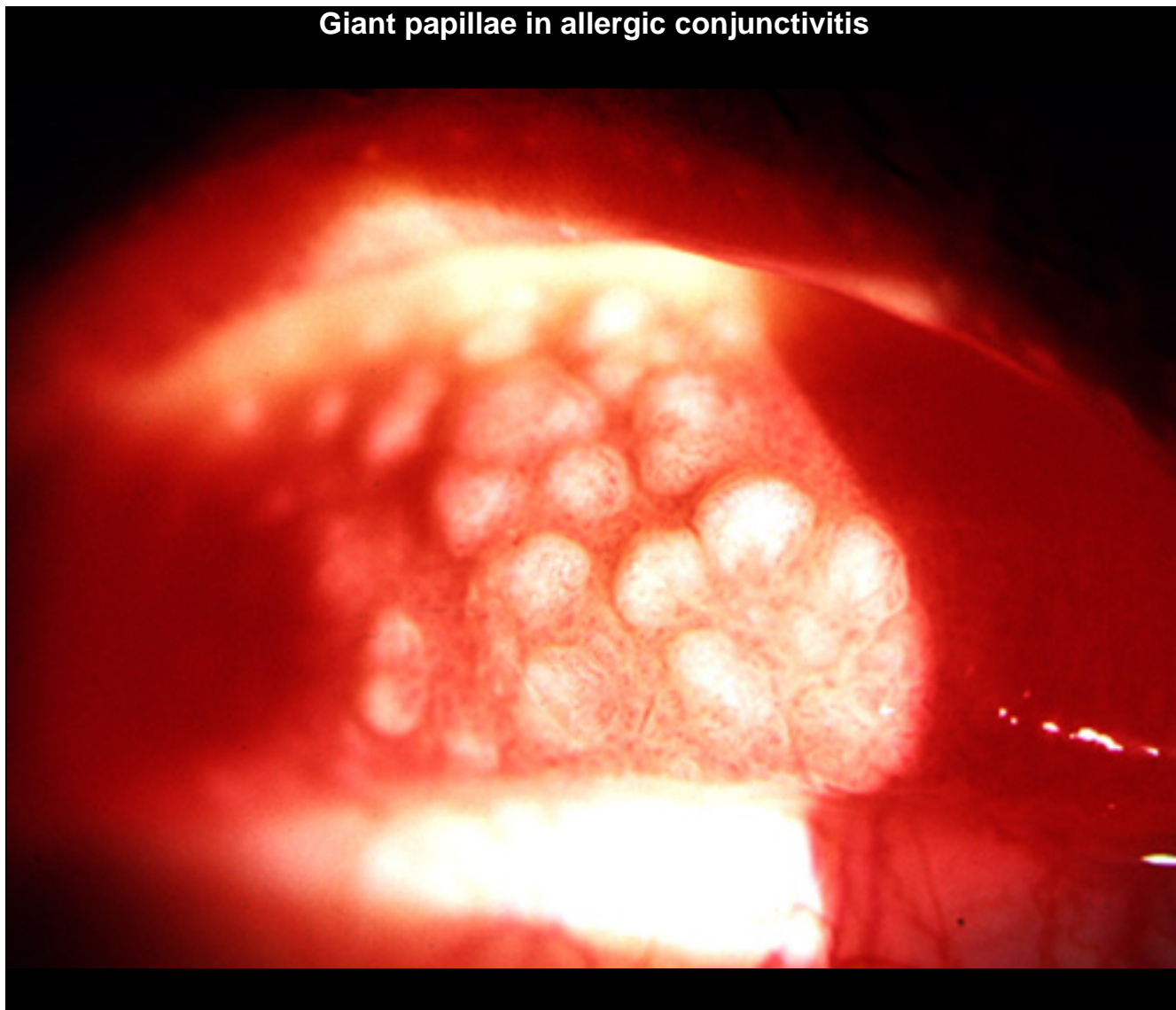

© Copyright [Oculisti OnLine](#)

Eyeatlas

The online Atlas of Ophthalmology

Giant papillae in allergic conjunctivitis

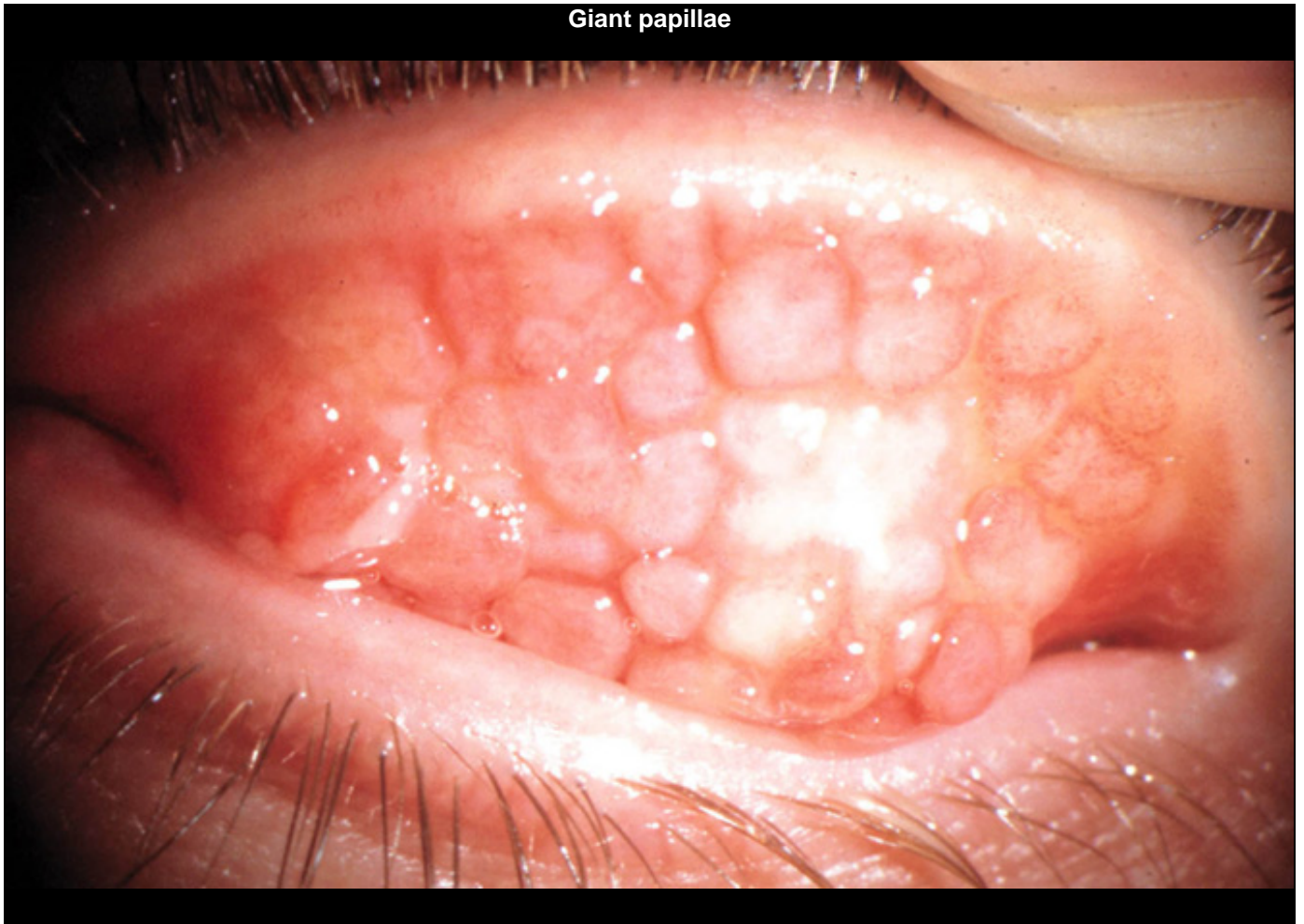

© Copyright [Oculisti OnLine](http://www.eyeatlas.com)

Eyeatlas

The online Atlas of Ophthalmology

Giant papillae

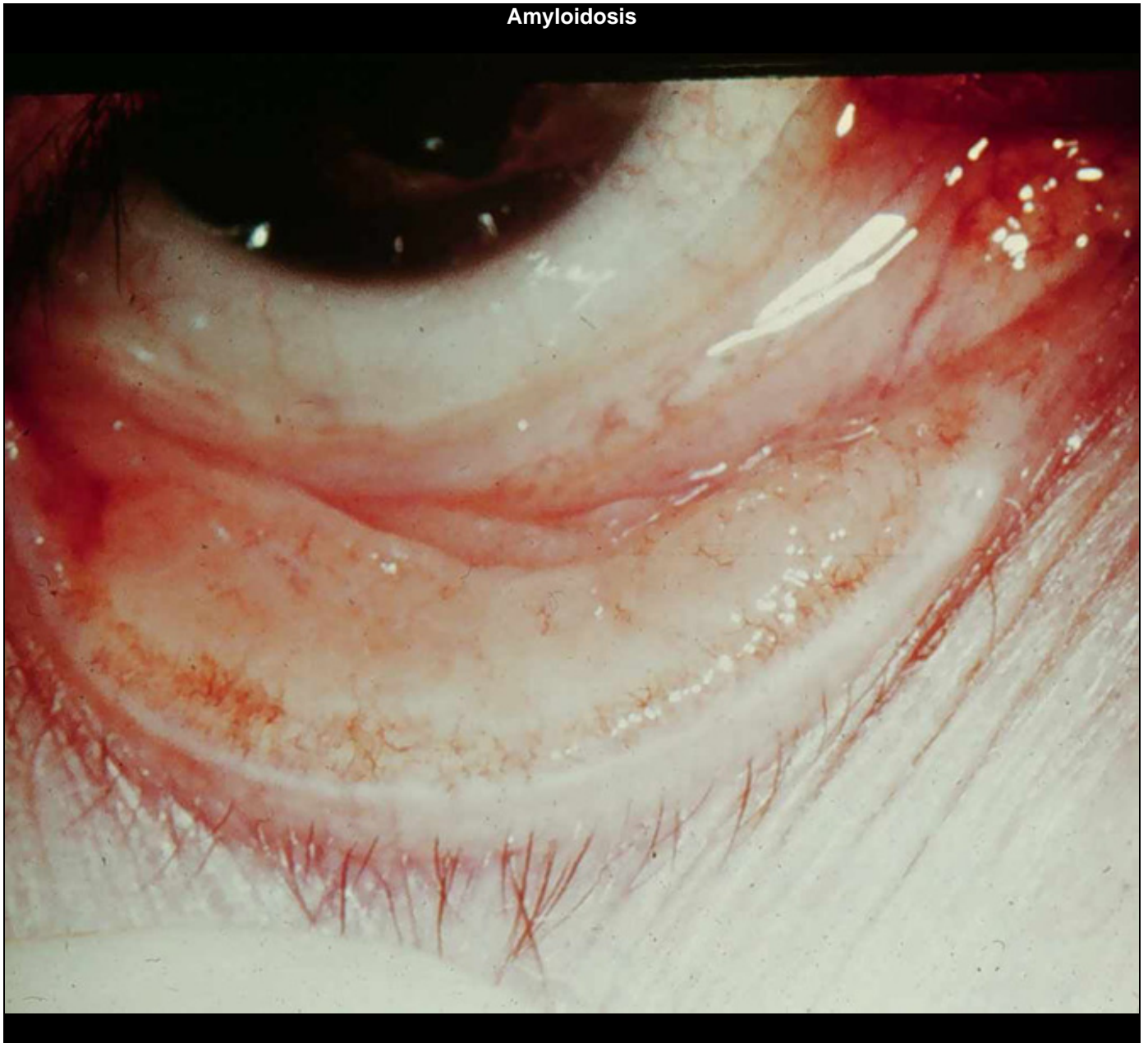

© Copyright [Oculisti OnLine](#)

EyeAtlas

The online Atlas of Ophthalmology

Amyloidosis

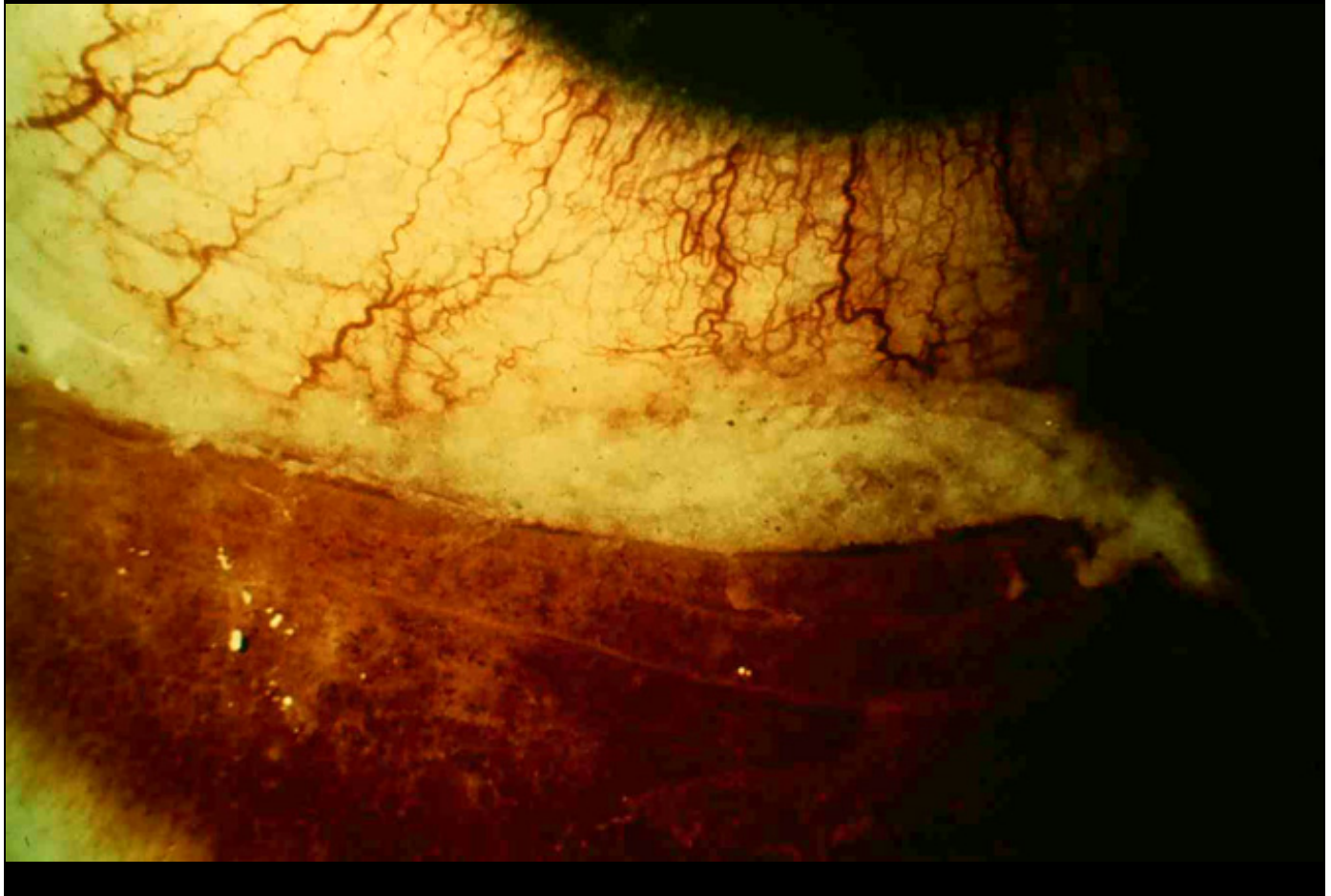

© Copyright [Oculisti OnLine](http://www.eyeatlas.com)

EyeAtlas

The online Atlas of Ophthalmology

Bacterial conjunctivitis

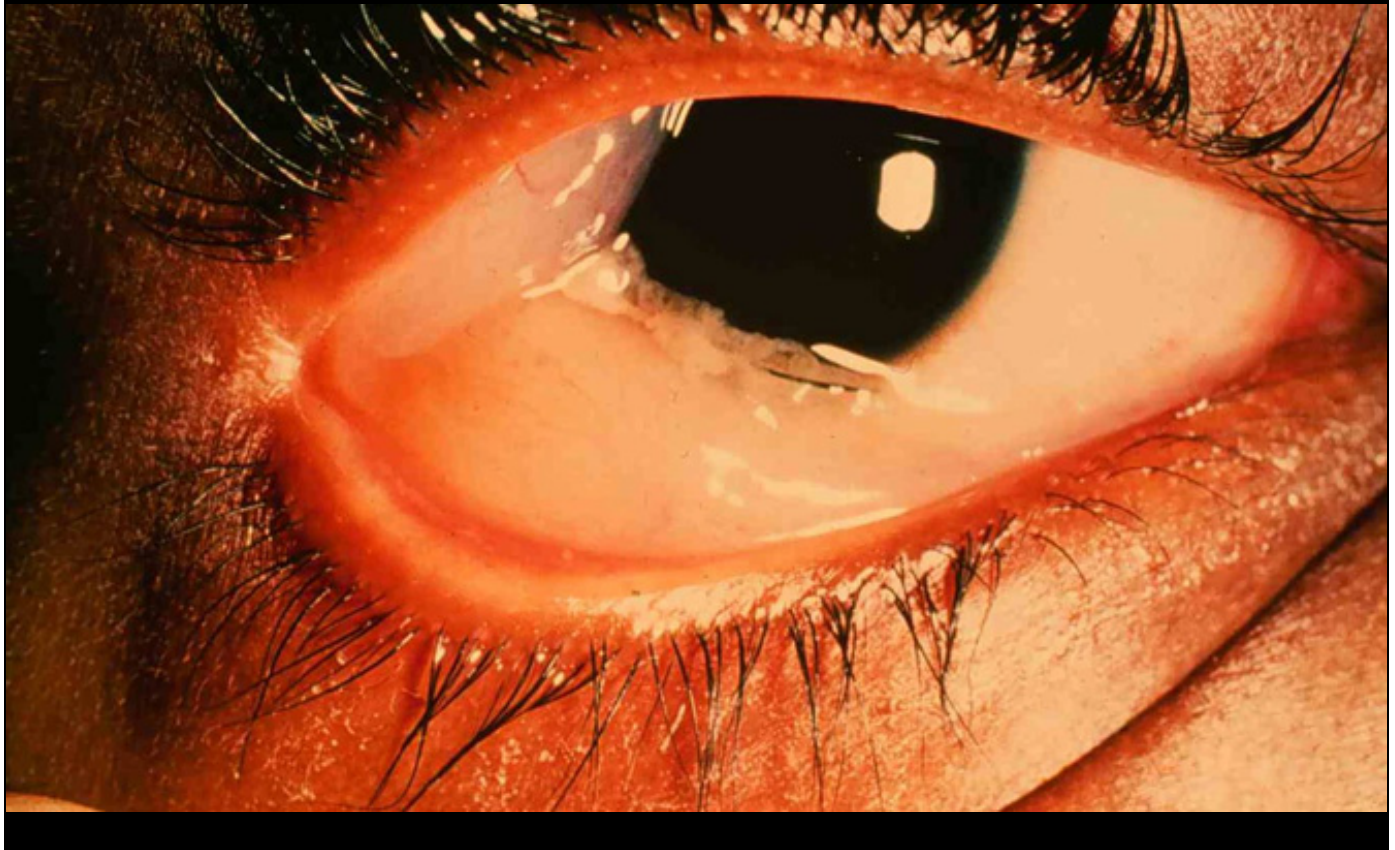


© Copyright [Oculisti OnLine](#)

EyeAtlas

The online Atlas of Ophthalmology

Chemosis

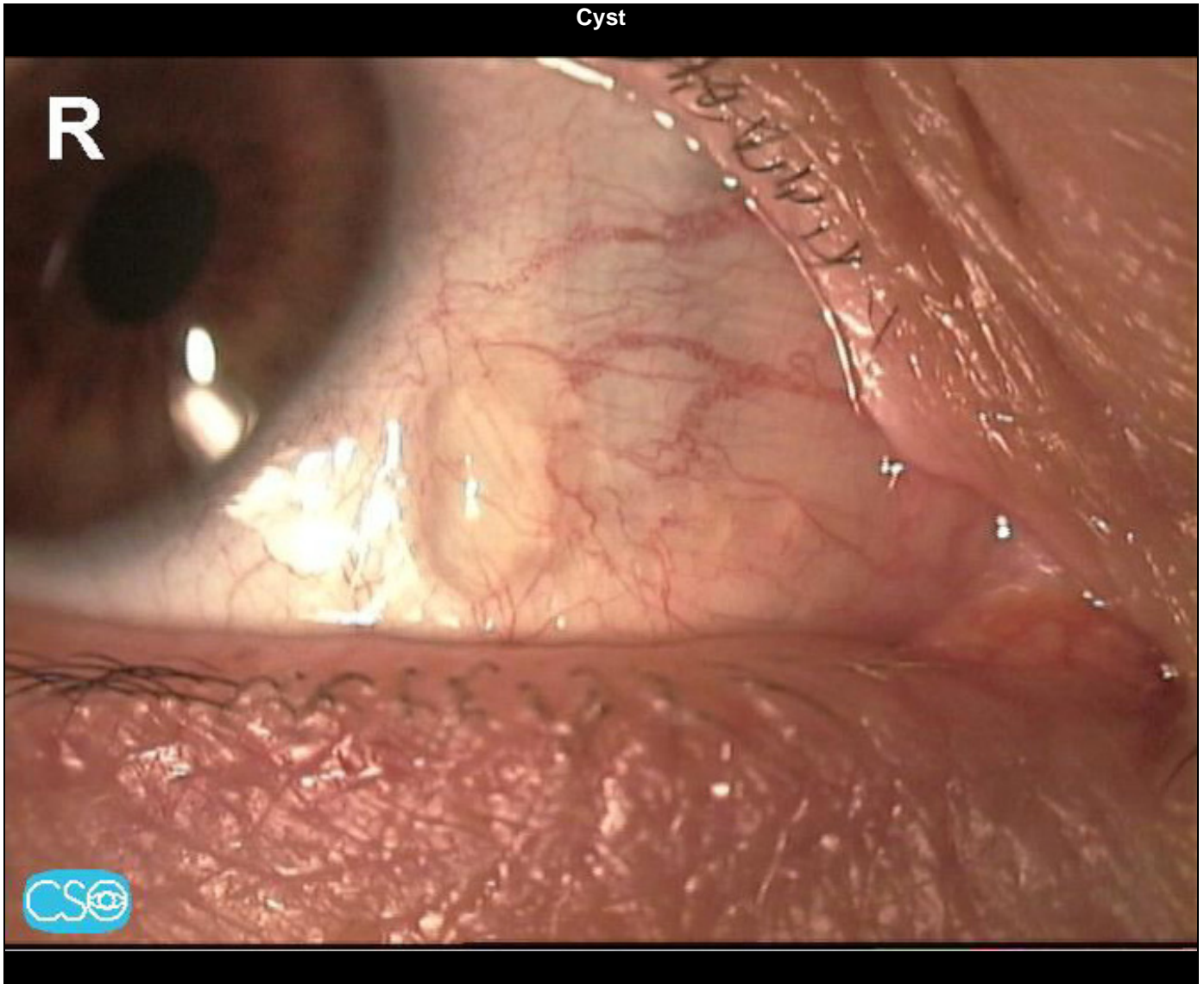

© Copyright [Oculisti OnLine](#)

EyeAtlas

The online Atlas of Ophthalmology

Cyst

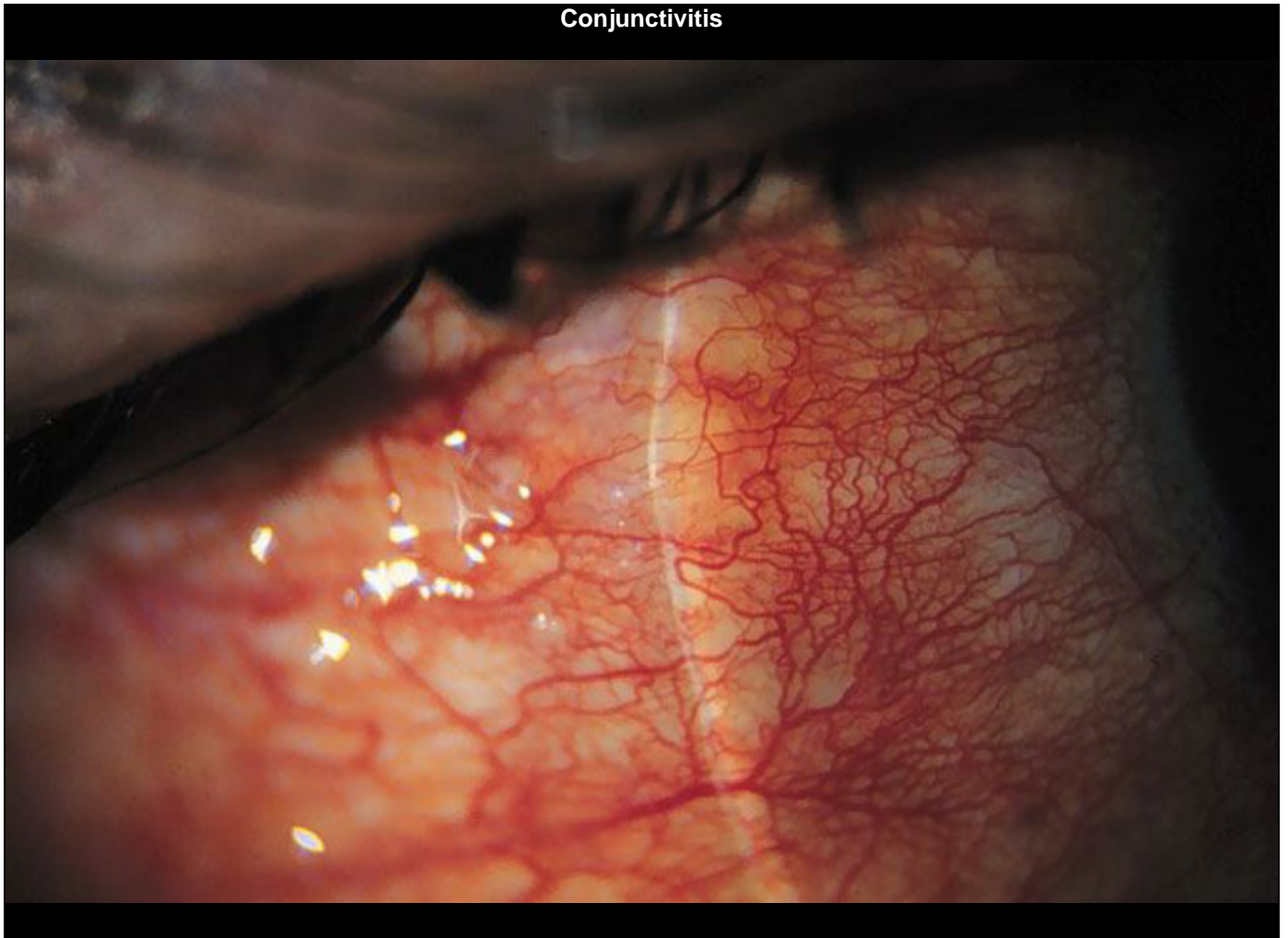

© Copyright [Oculisti OnLine](#)

EyeAtlas

The online Atlas of Ophthalmology

Conjunctivitis

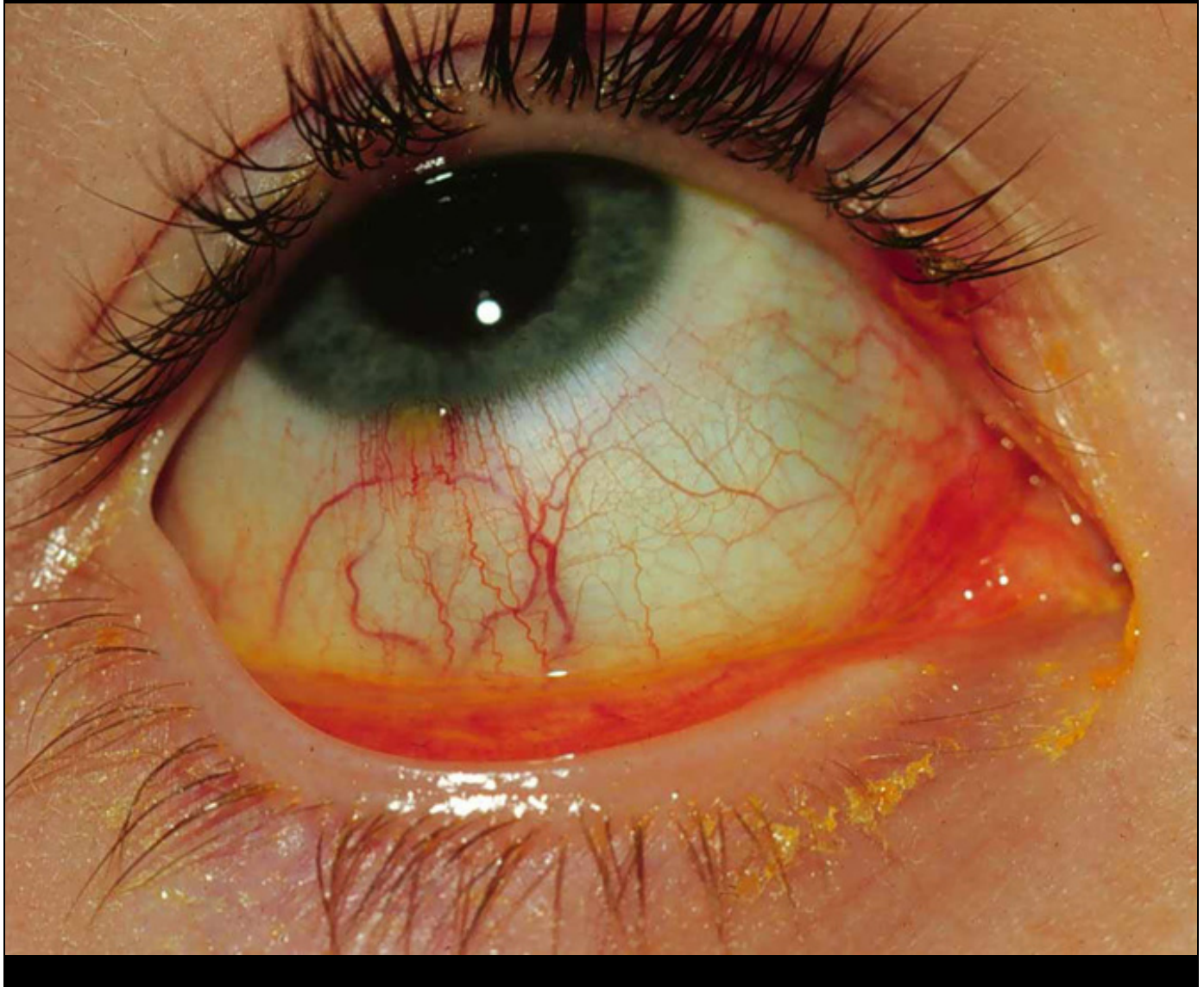

© Copyright [Oculisti OnLine](#)

EyeAtlas

The online Atlas of Ophthalmology

Conjunctivitis

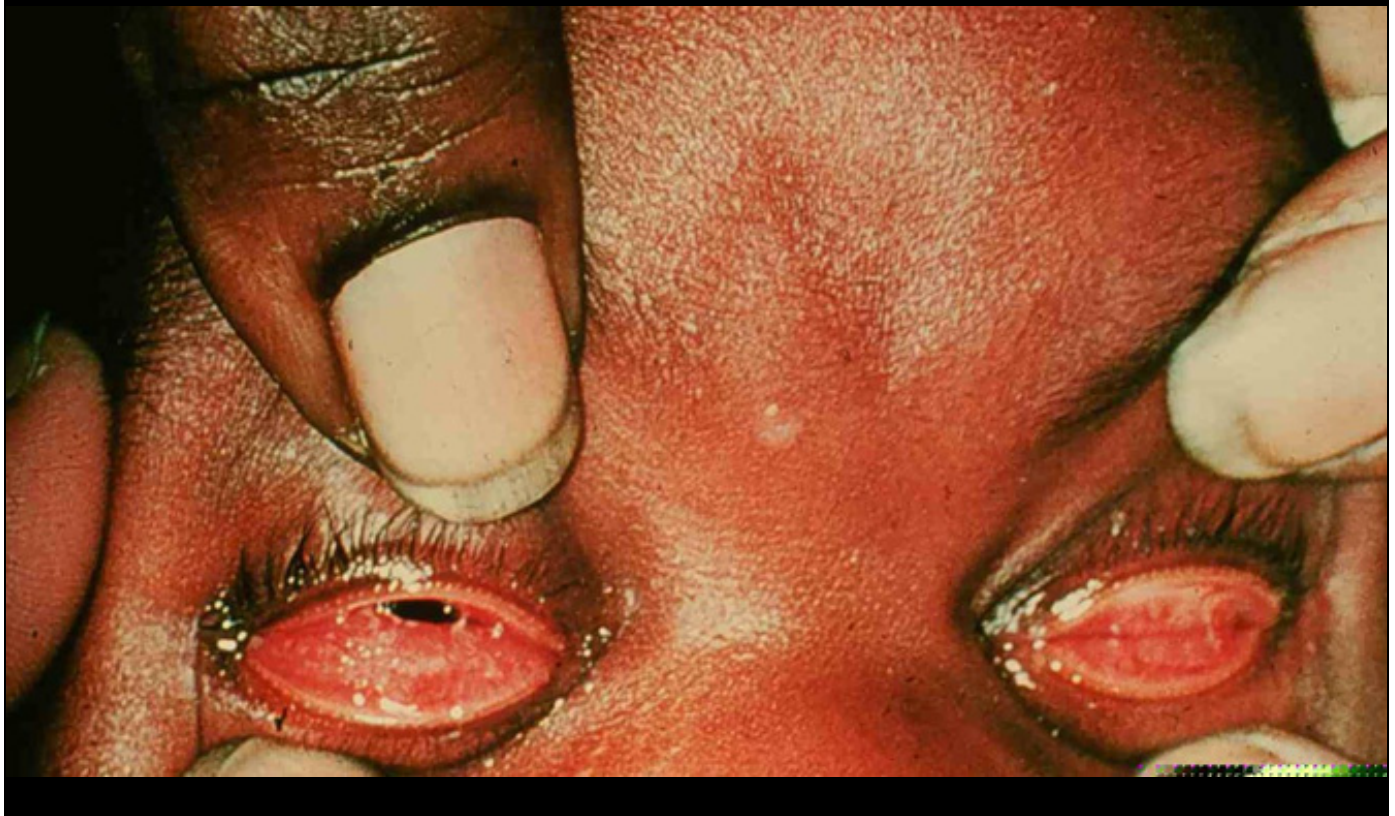


© Copyright Oculisti OnLine

EyeAtlas

The online Atlas of Ophthalmology

Chlamydiae conjunctivitis

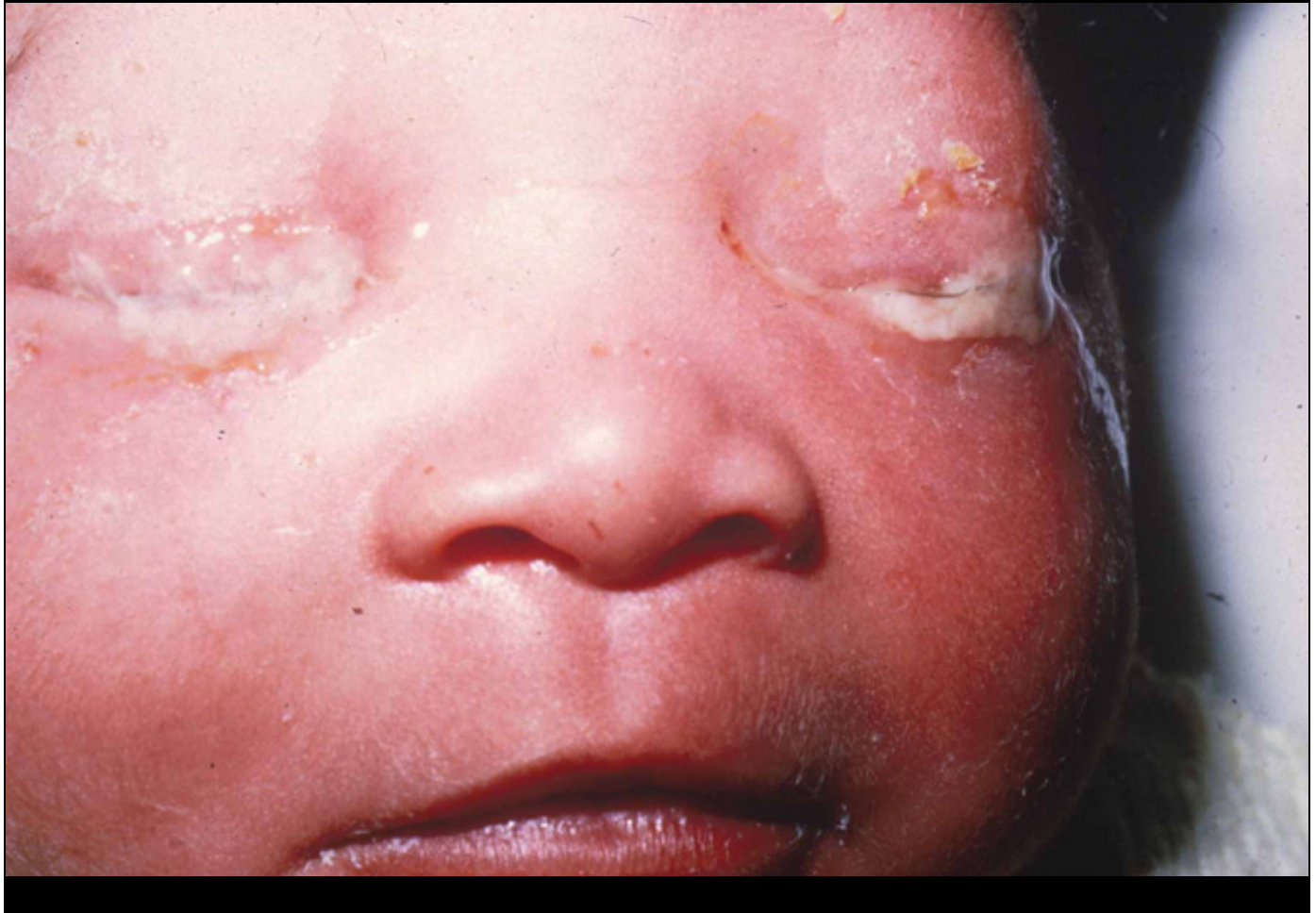

© Copyright [Oculisti OnLine](#)

EyeAtlas

The online Atlas of Ophthalmology

Gonococcal conjunctivitis

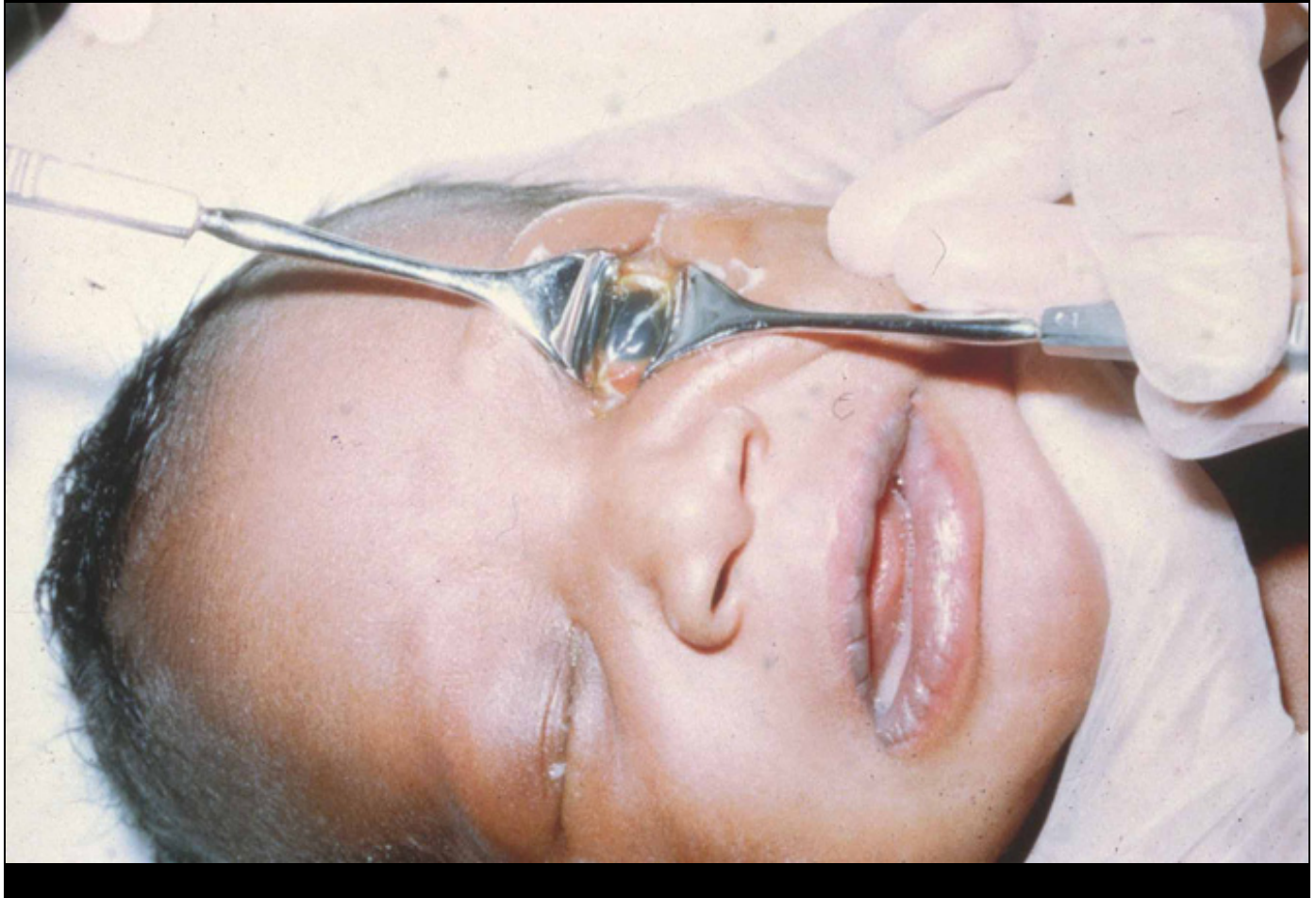

© Copyright [Oculisti OnLine](#)

EyeAtlas

The online Atlas of Ophthalmology

Gonococcal conjunctivitis

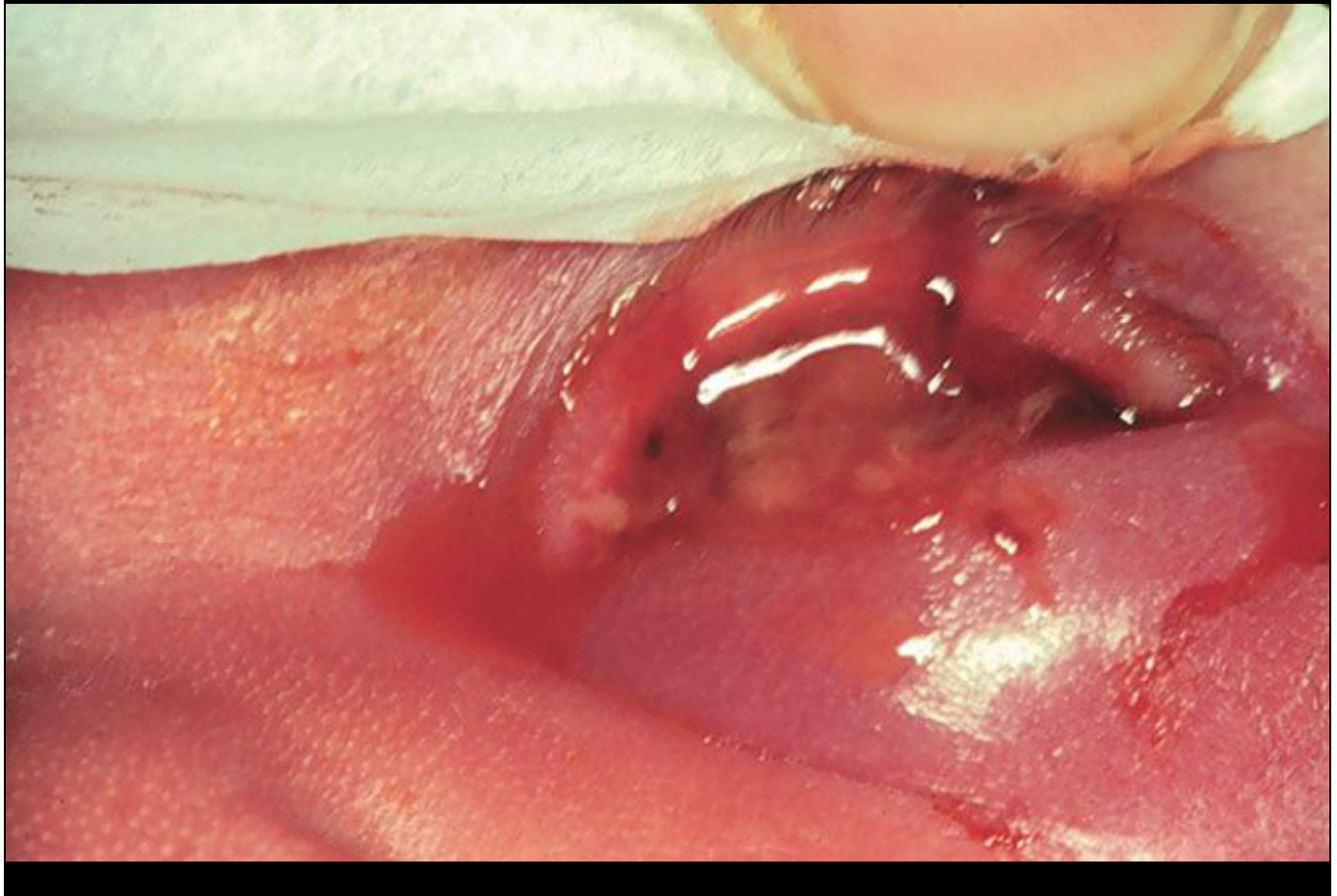

© Copyright [Oculisti OnLine](#)

EyeAtlas

The online Atlas of Ophthalmology

Gonococcal Conjunctivitis

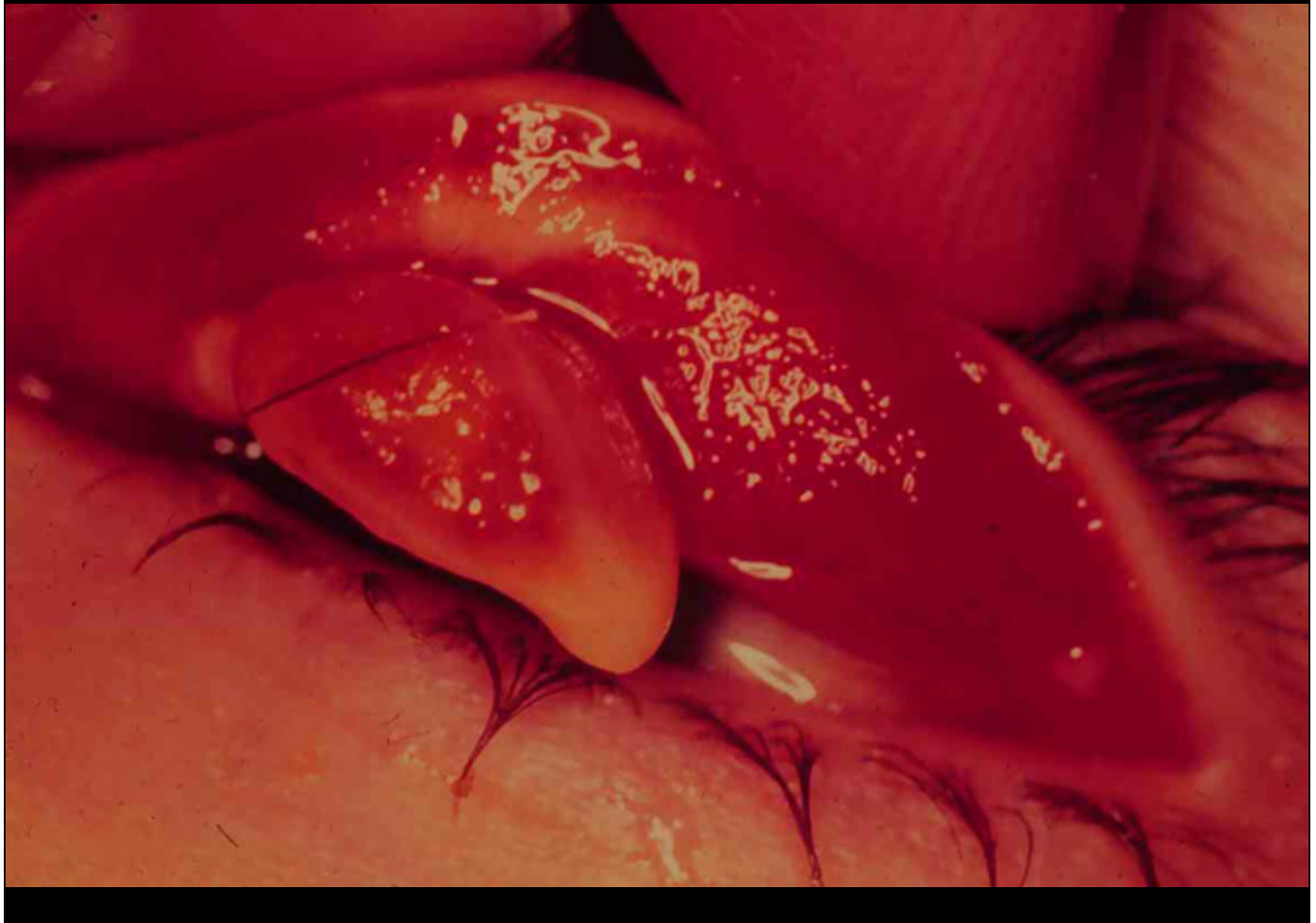

© Copyright [Oculisti OnLine](#)

EyeAtlas

The online Atlas of Ophthalmology

Ligneous conjunctivitis

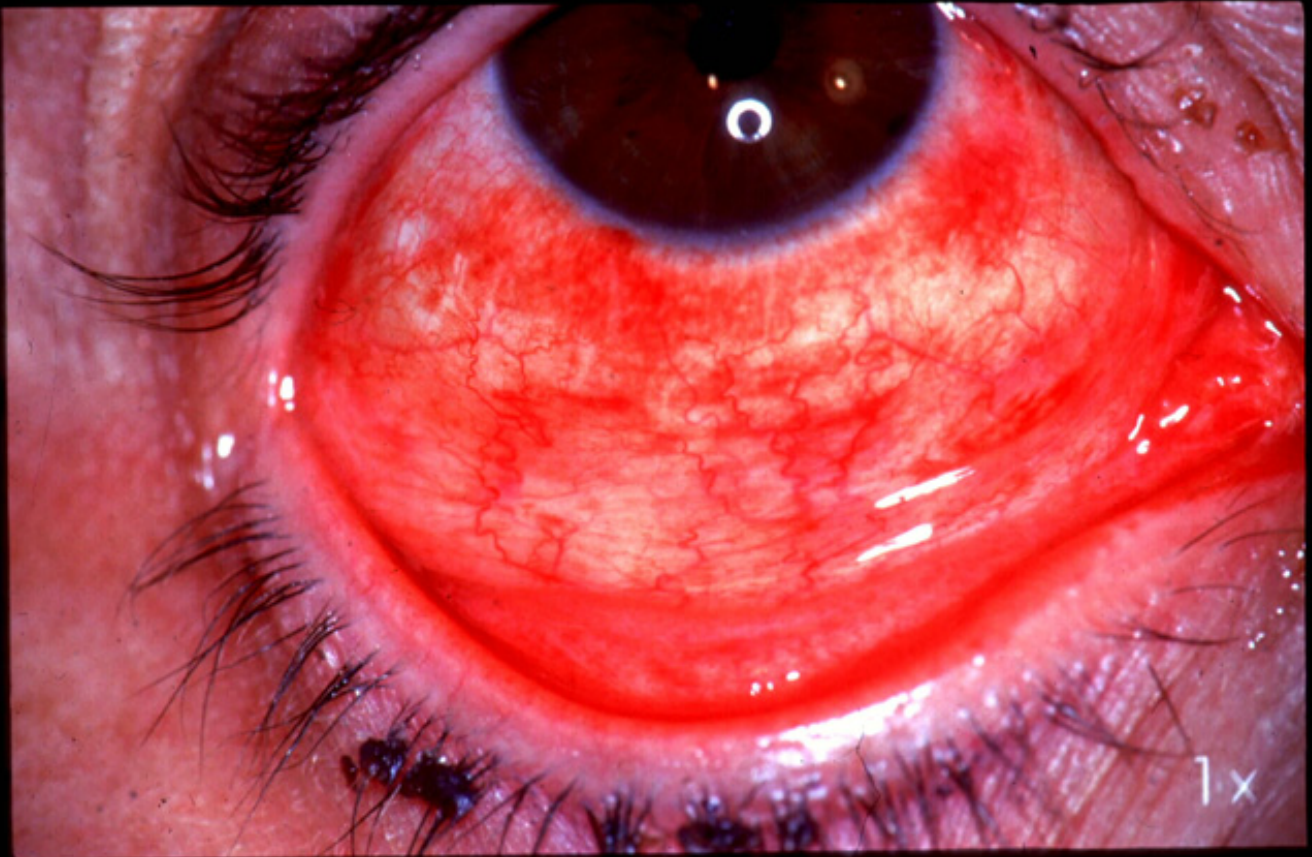


© Copyright [Oculisti OnLine](#)

EyeAtlas

The online Atlas of Ophthalmology

Viral conjunctivitis

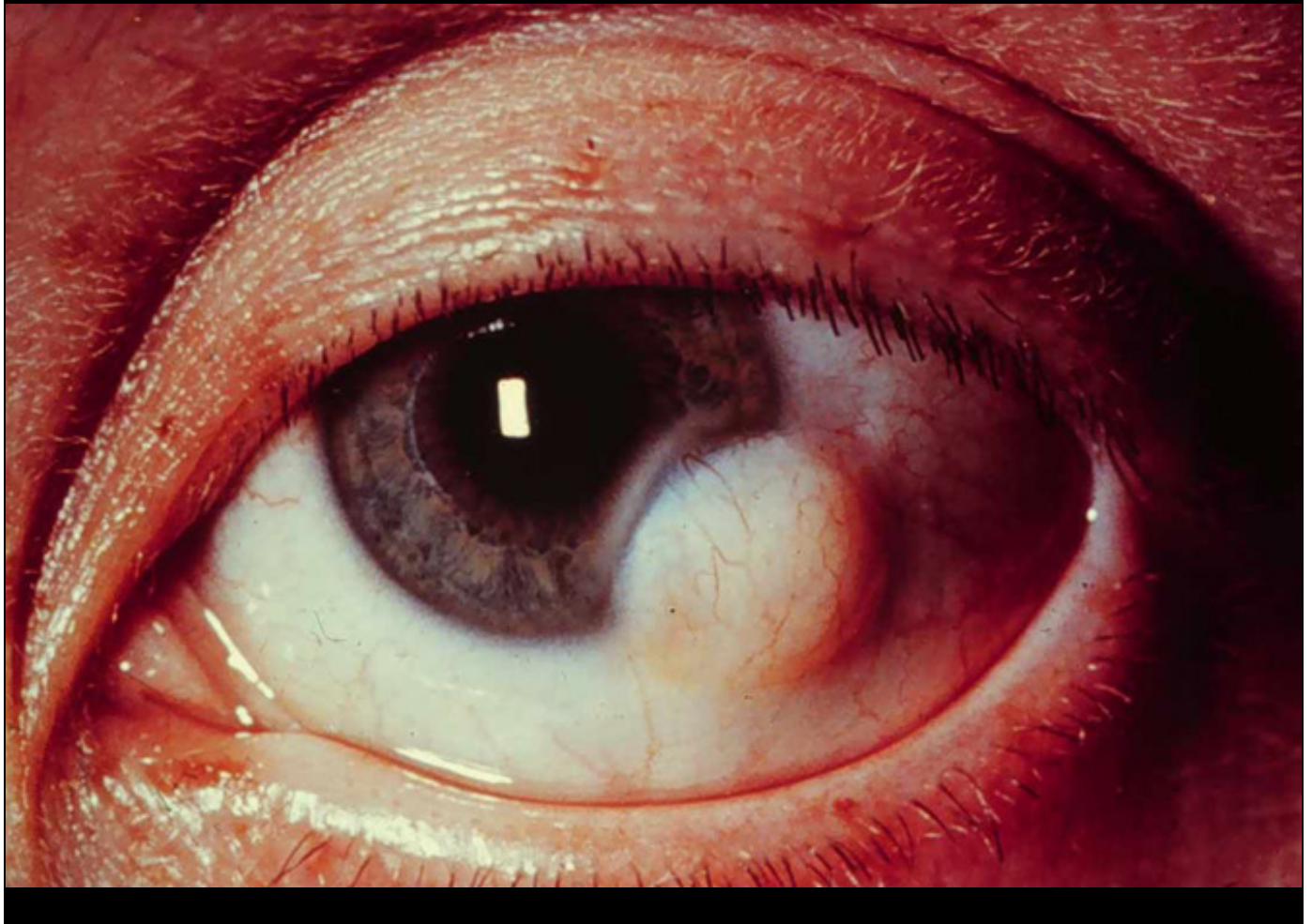

© Copyright [Oculisti OnLine](http://www.eyeatlas.com)

EyeAtlas

The online Atlas of Ophthalmology

Epibulbar dermoid

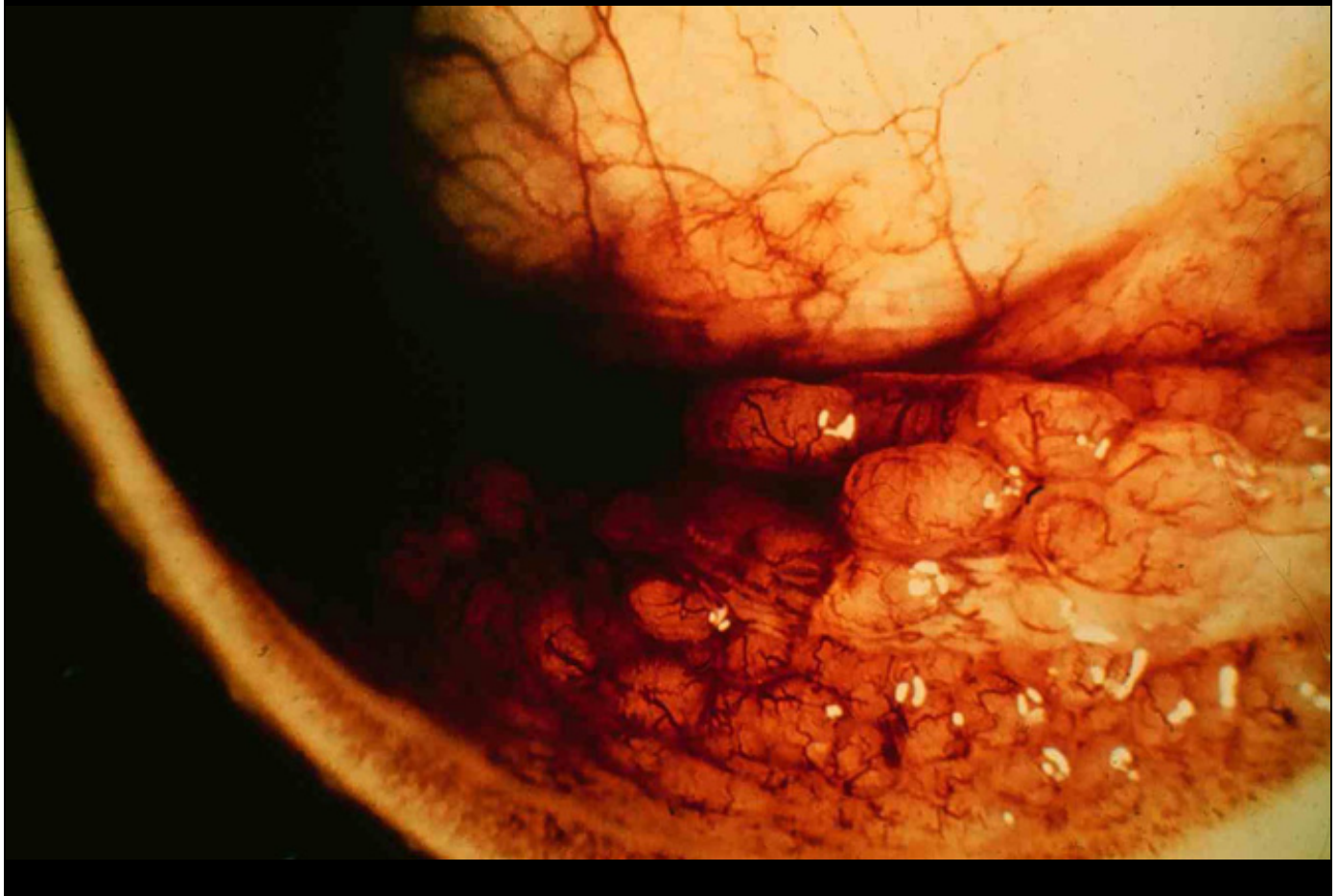


© Copyright [Oculisti OnLine](http://www.eyeatlas.com)

Eyeatlas

The online Atlas of Ophthalmology

Follicular conjunctivitis

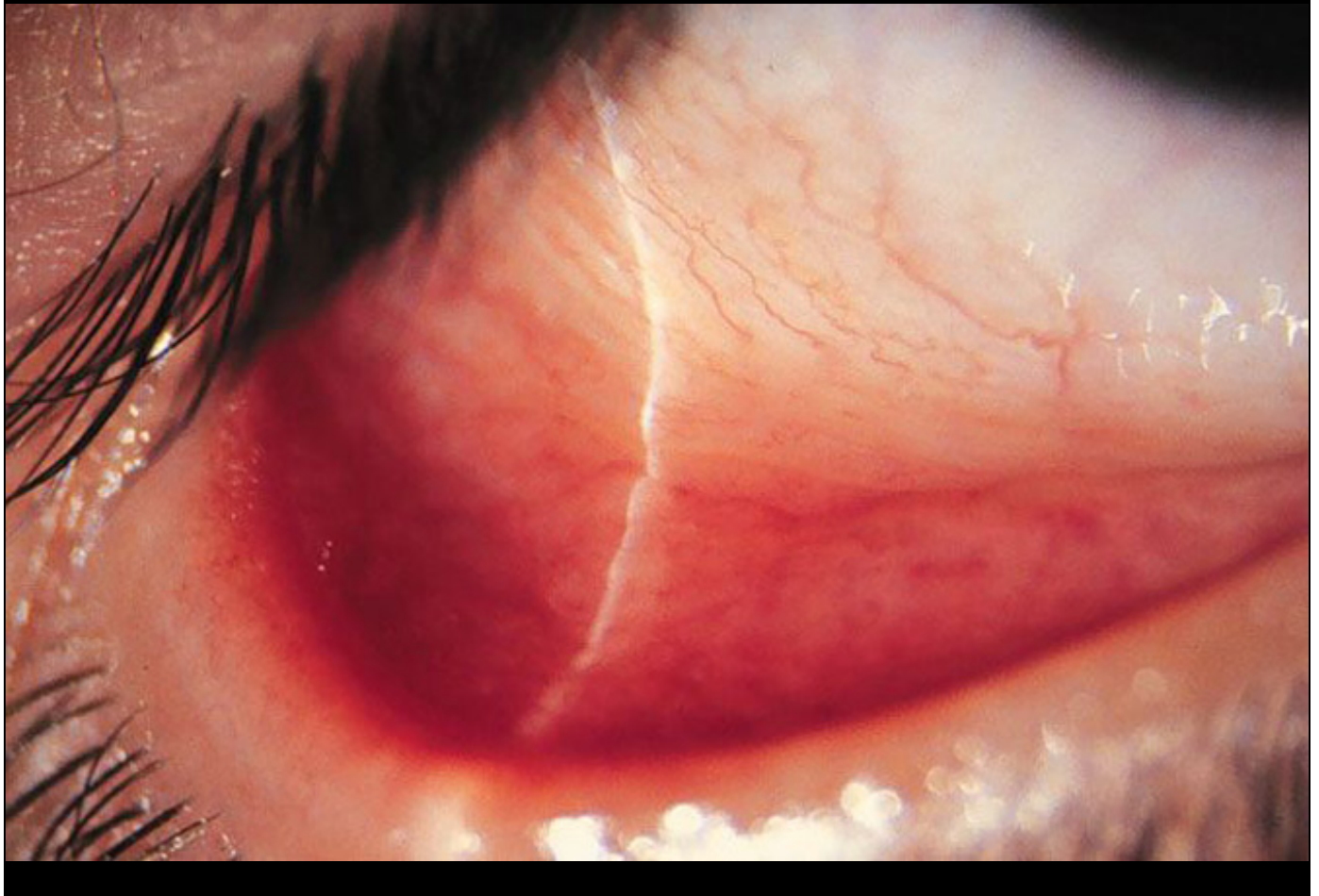


© Copyright [Oculisti OnLine](#)

EyeAtlas

The online Atlas of Ophthalmology

Folliculosis

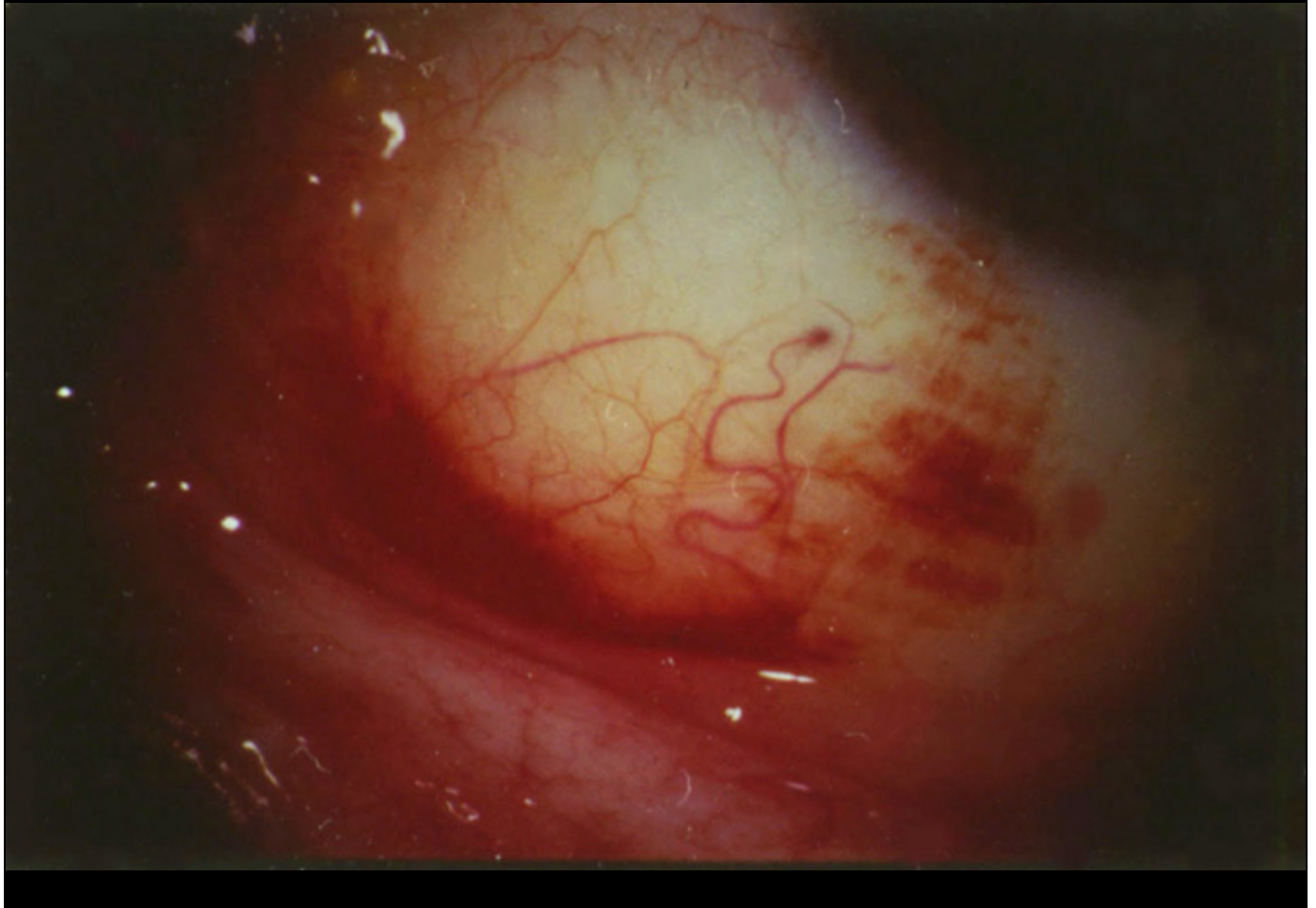


© Copyright [Oculisti OnLine](#)

EyeAtlas

The online Atlas of Ophthalmology

Kaposi's sarcoma

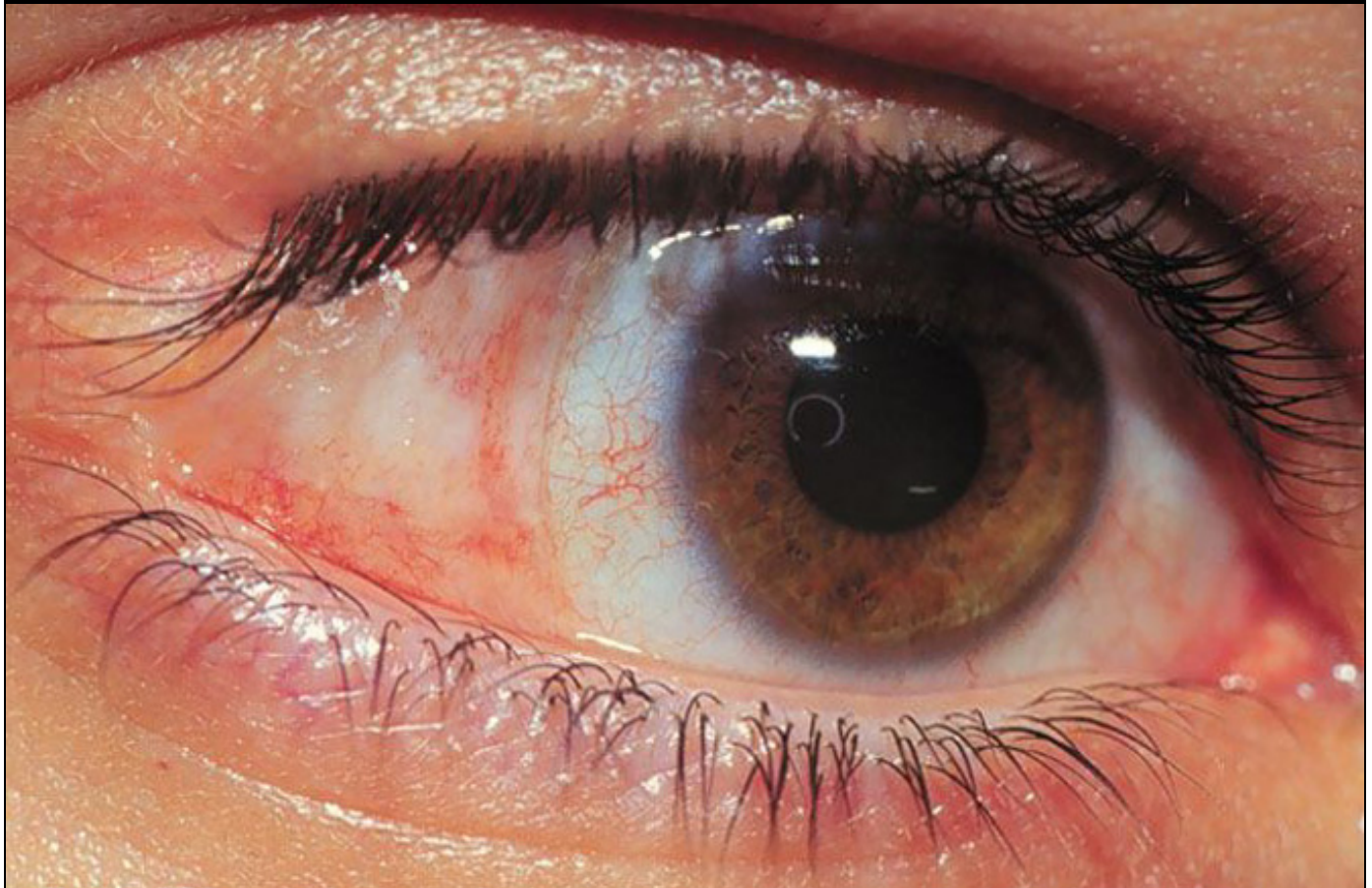

© Copyright [Oculisti OnLine](http://www.eyeatlas.com)

EyeAtlas

The online Atlas of Ophthalmology

Lipoma

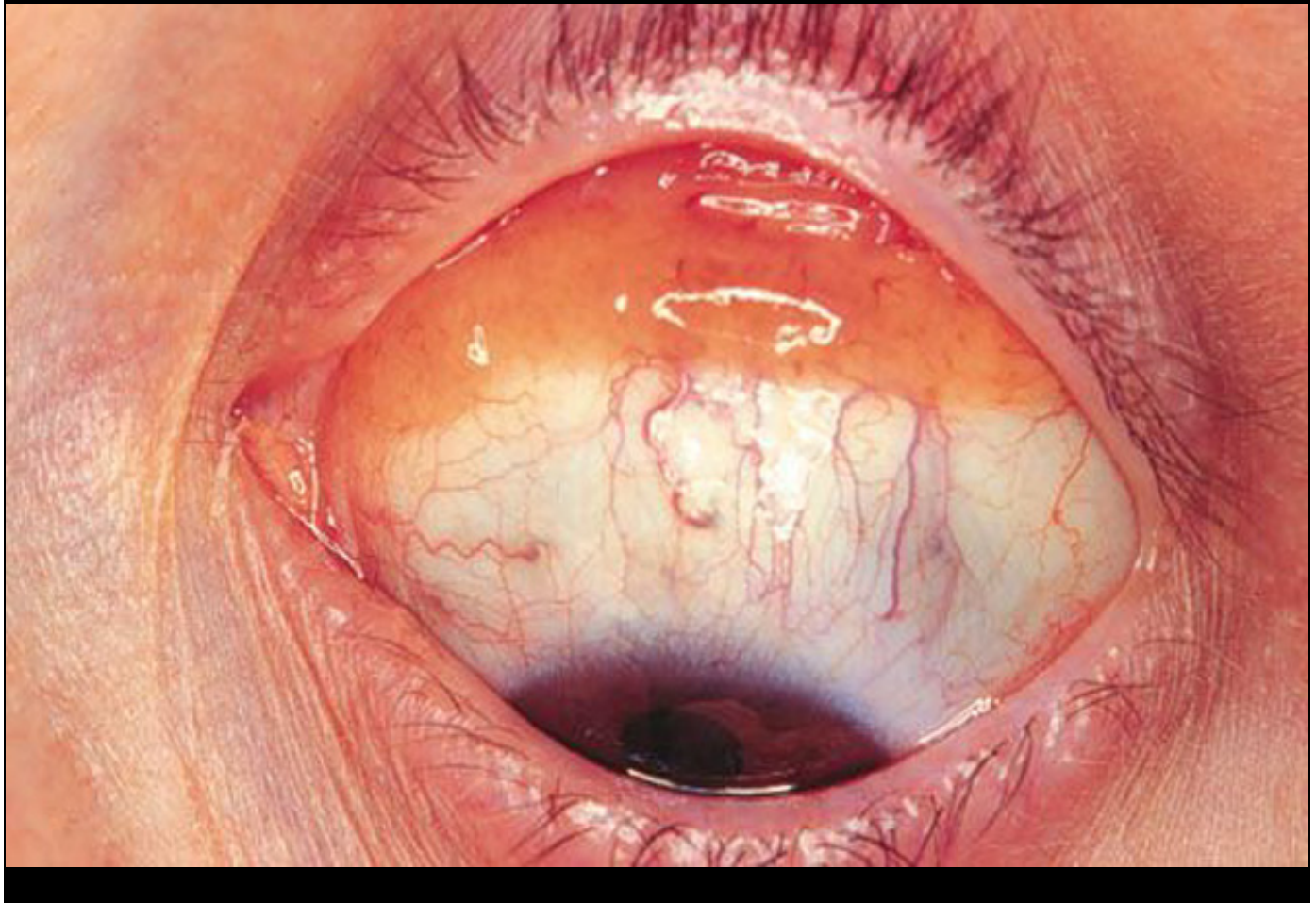

© Copyright [Oculisti OnLine](http://www.eyeatlas.com)

EyeAtlas

The online Atlas of Ophthalmology

Subconjunctival lymphoma

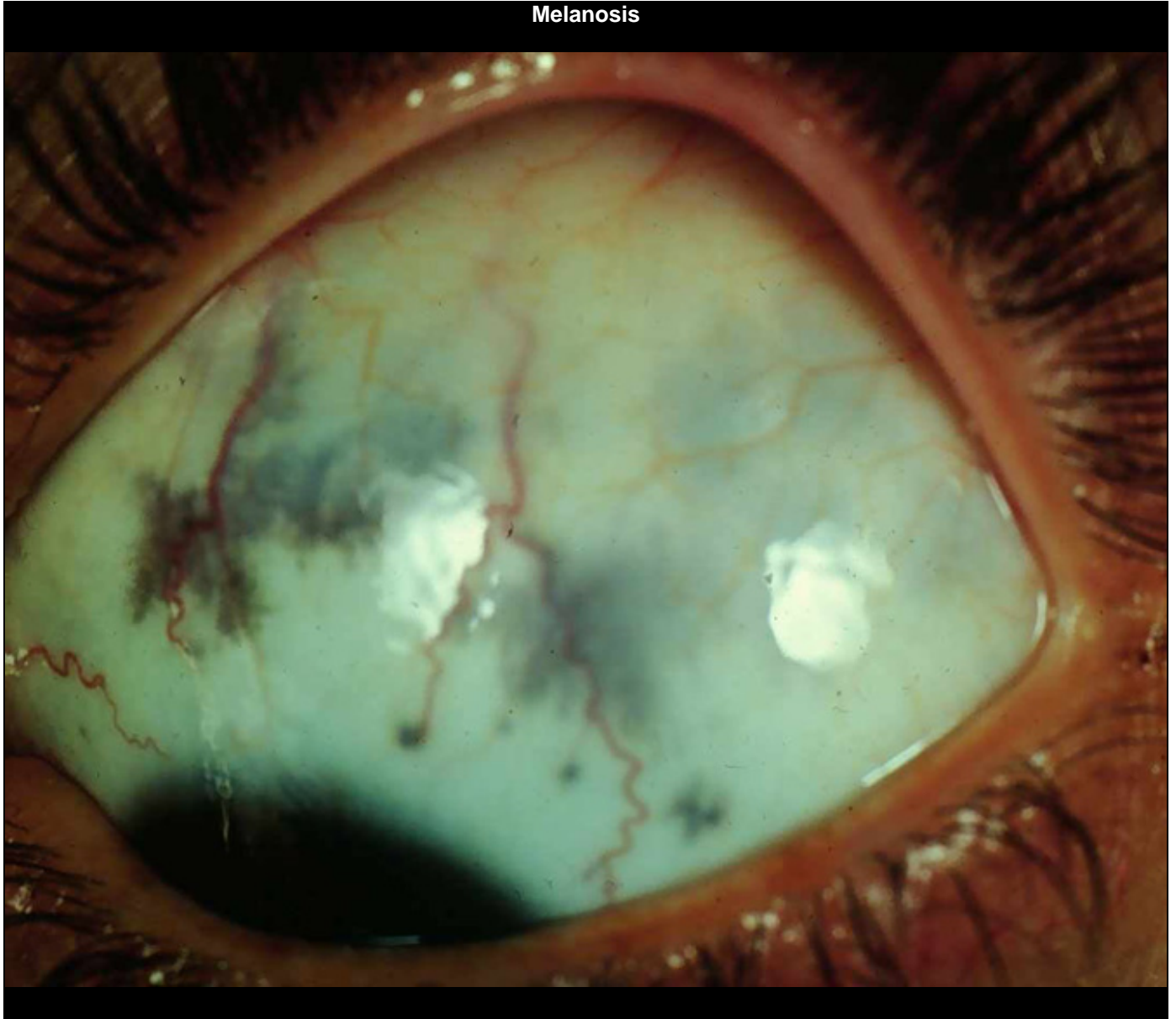

© Copyright [Oculisti OnLine](http://www.eyeatlas.com)

EyeAtlas

The online Atlas of Ophthalmology

Melanosis

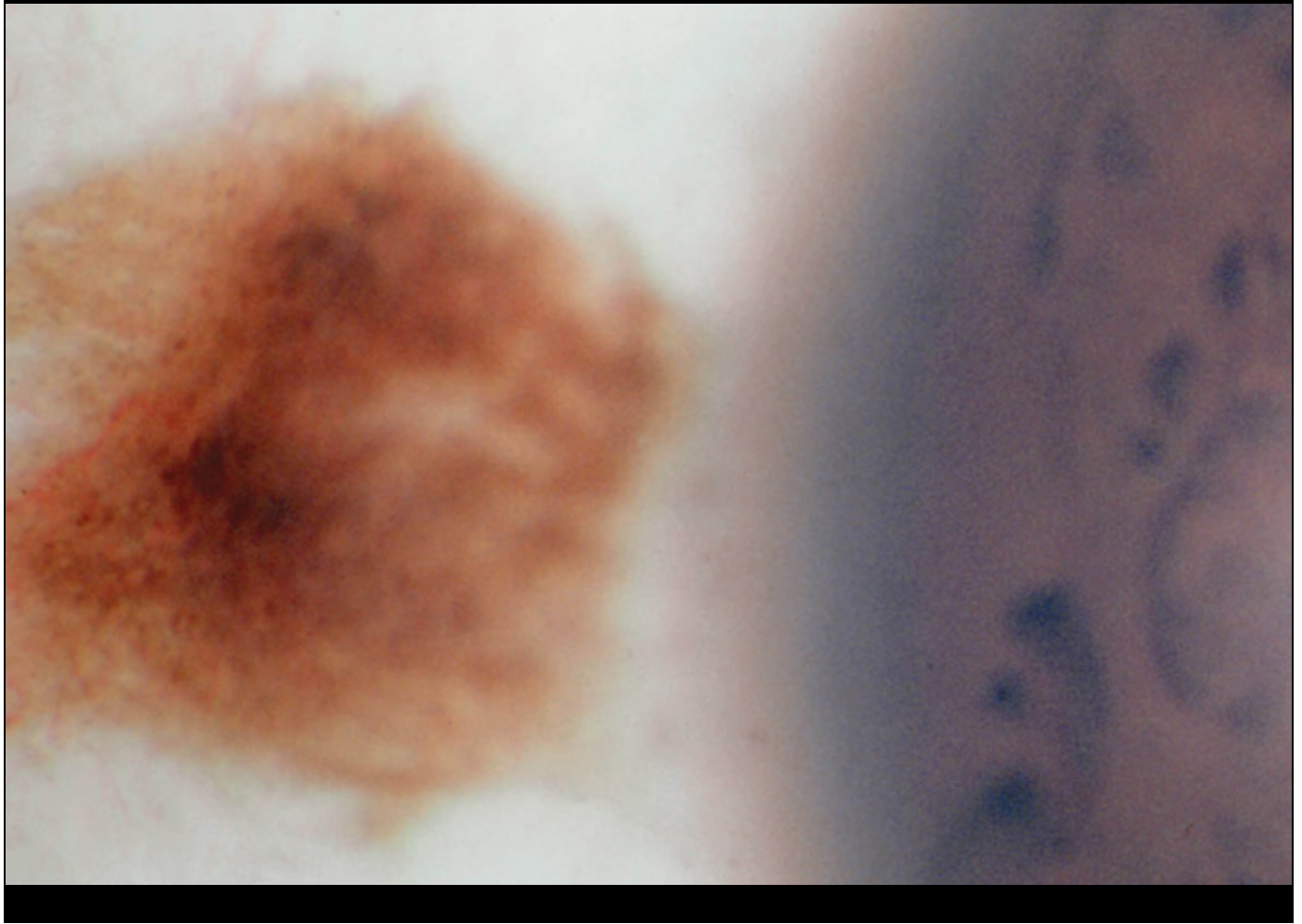


© Copyright [Oculisti OnLine](http://www.eyeatlas.com)

EyeAtlas

The online Atlas of Ophthalmology

Conjunctival nevus

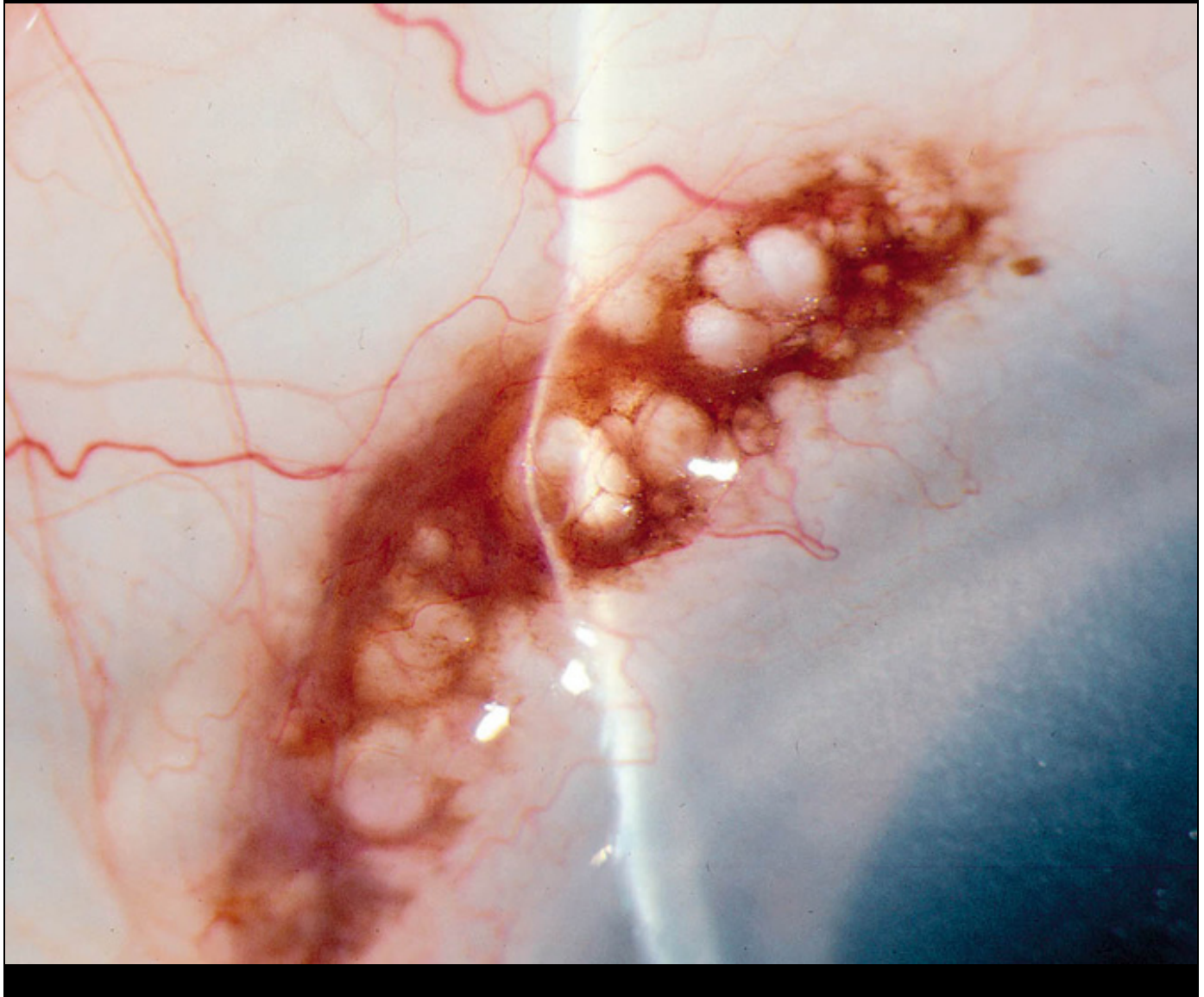

© Copyright [Oculisti OnLine](#)

EyeAtlas

The online Atlas of Ophthalmology

Conjunctival nevus

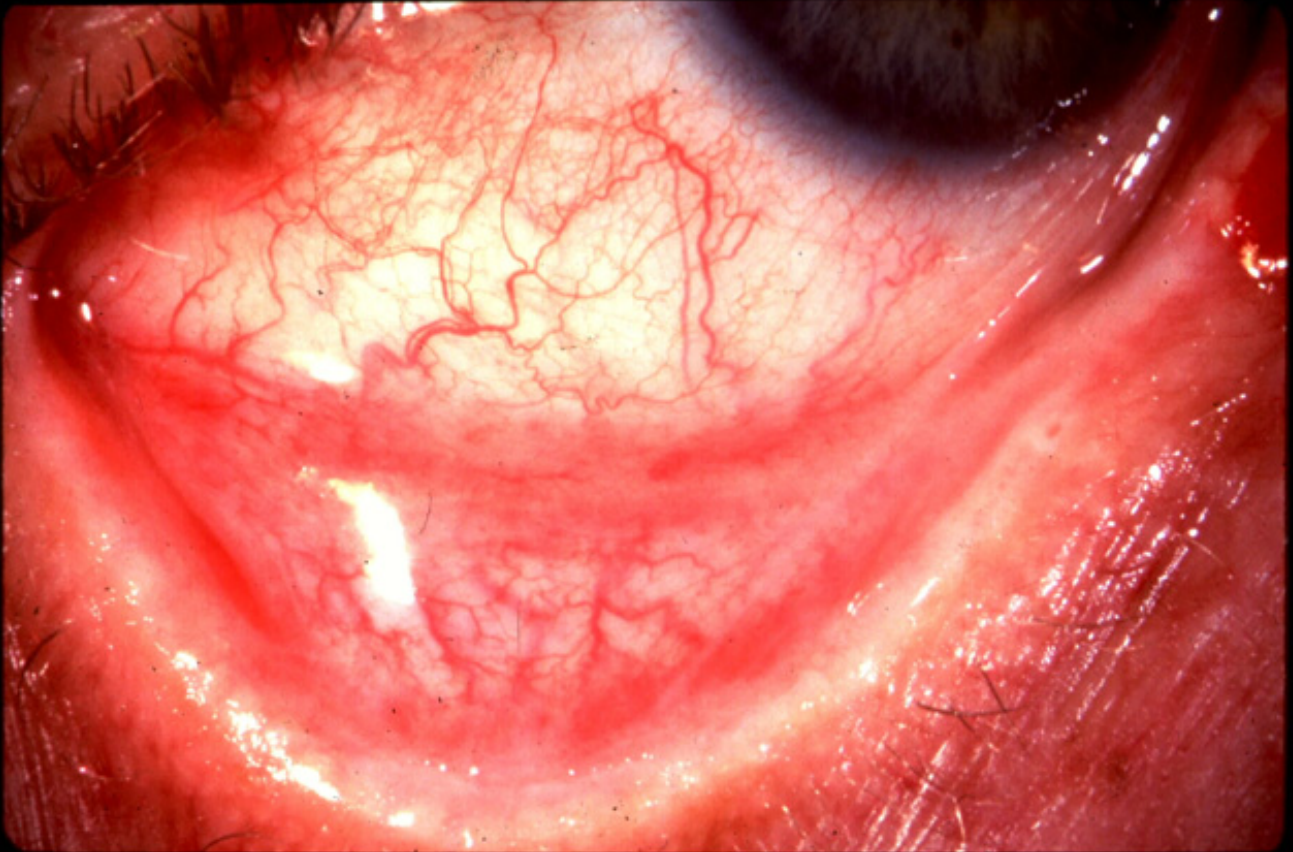

© Copyright [Oculisti OnLine](#)

EyeAtlas

The online Atlas of Ophthalmology

Simblefaron

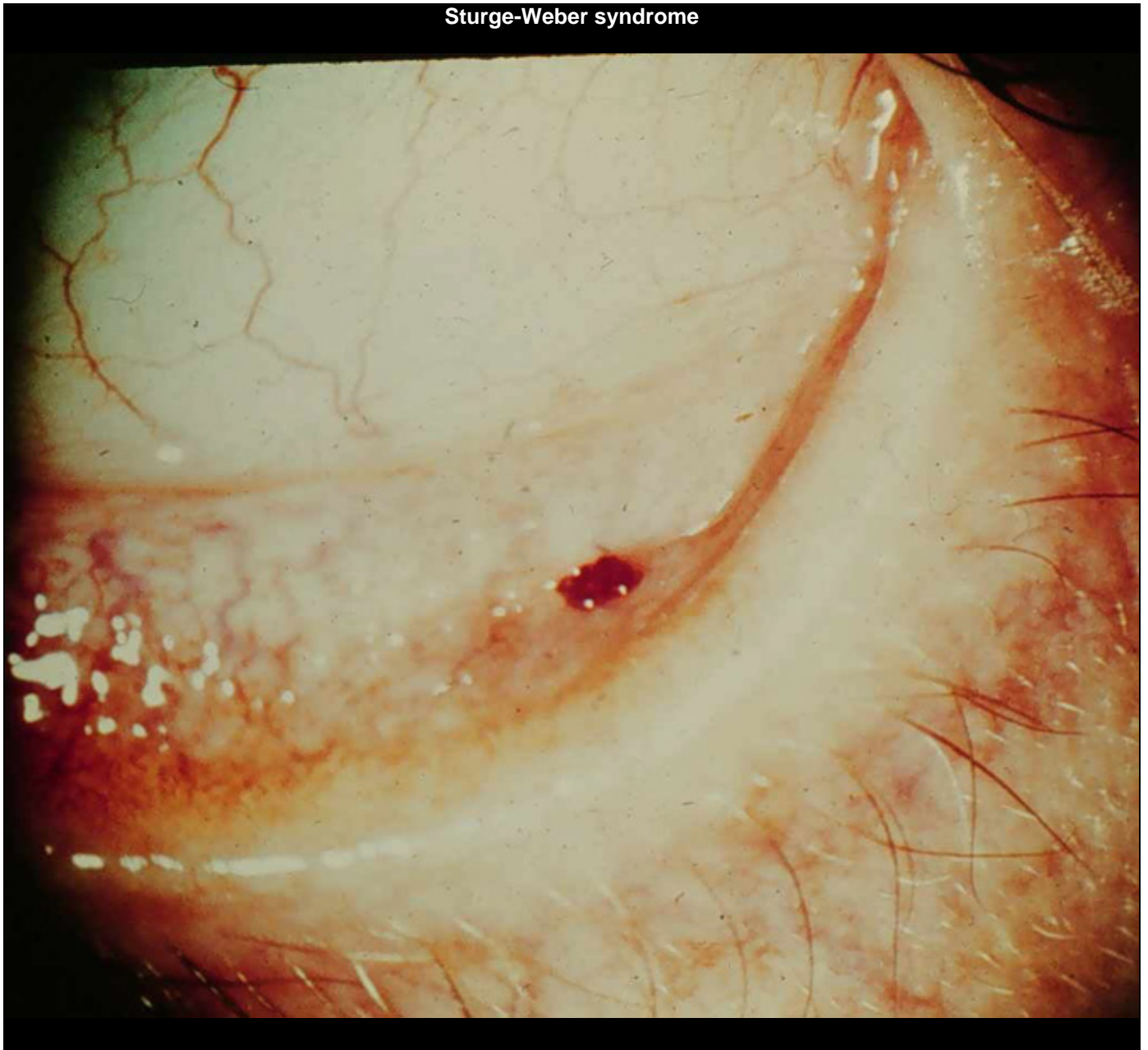


© Copyright [Oculisti OnLine](#)

EyeAtlas

The online Atlas of Ophthalmology

Sturge-Weber syndrome

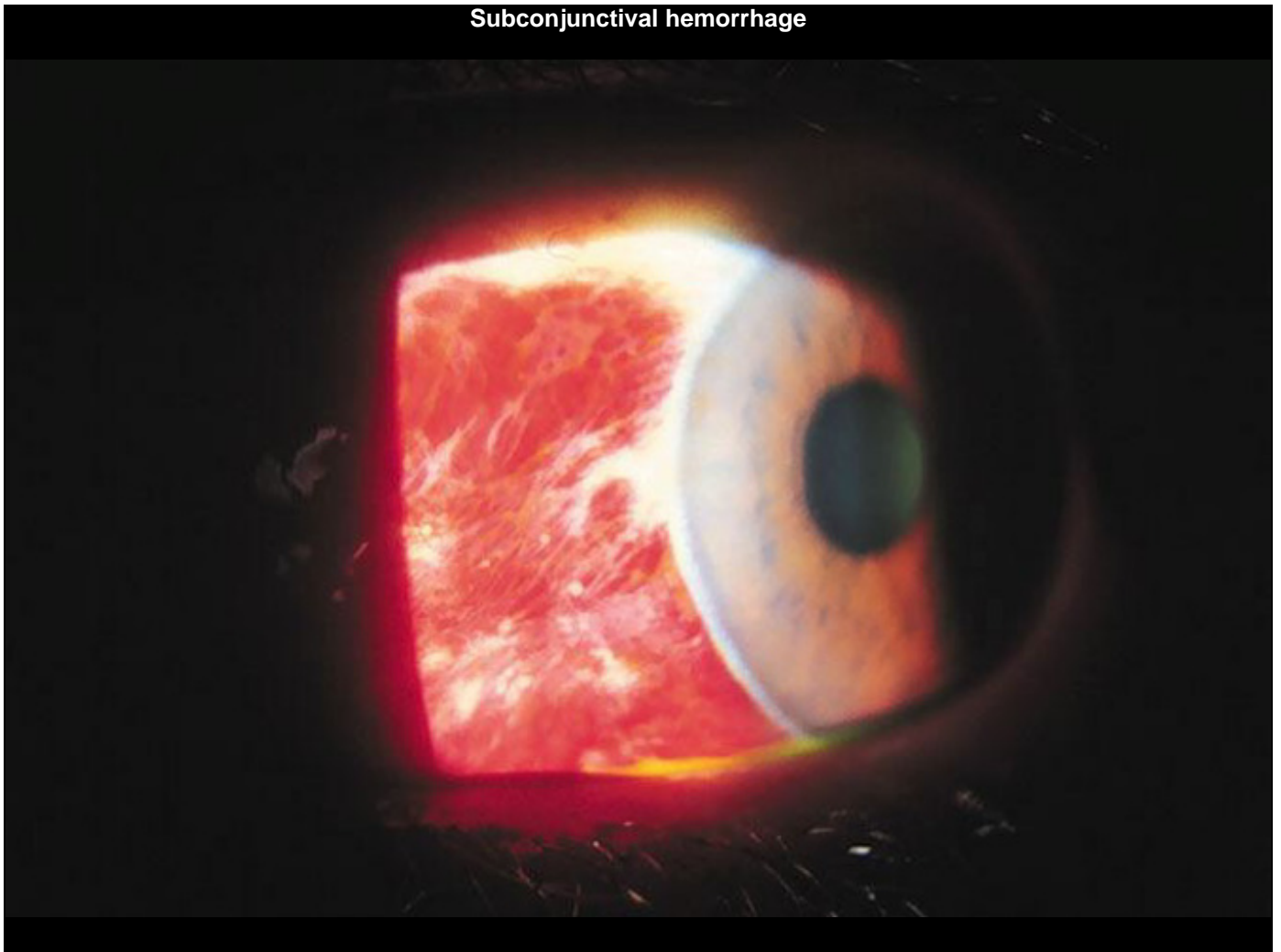


© Copyright [Oculisti OnLine](#)

EyeAtlas

The online Atlas of Ophthalmology

Subconjunctival hemorrhage

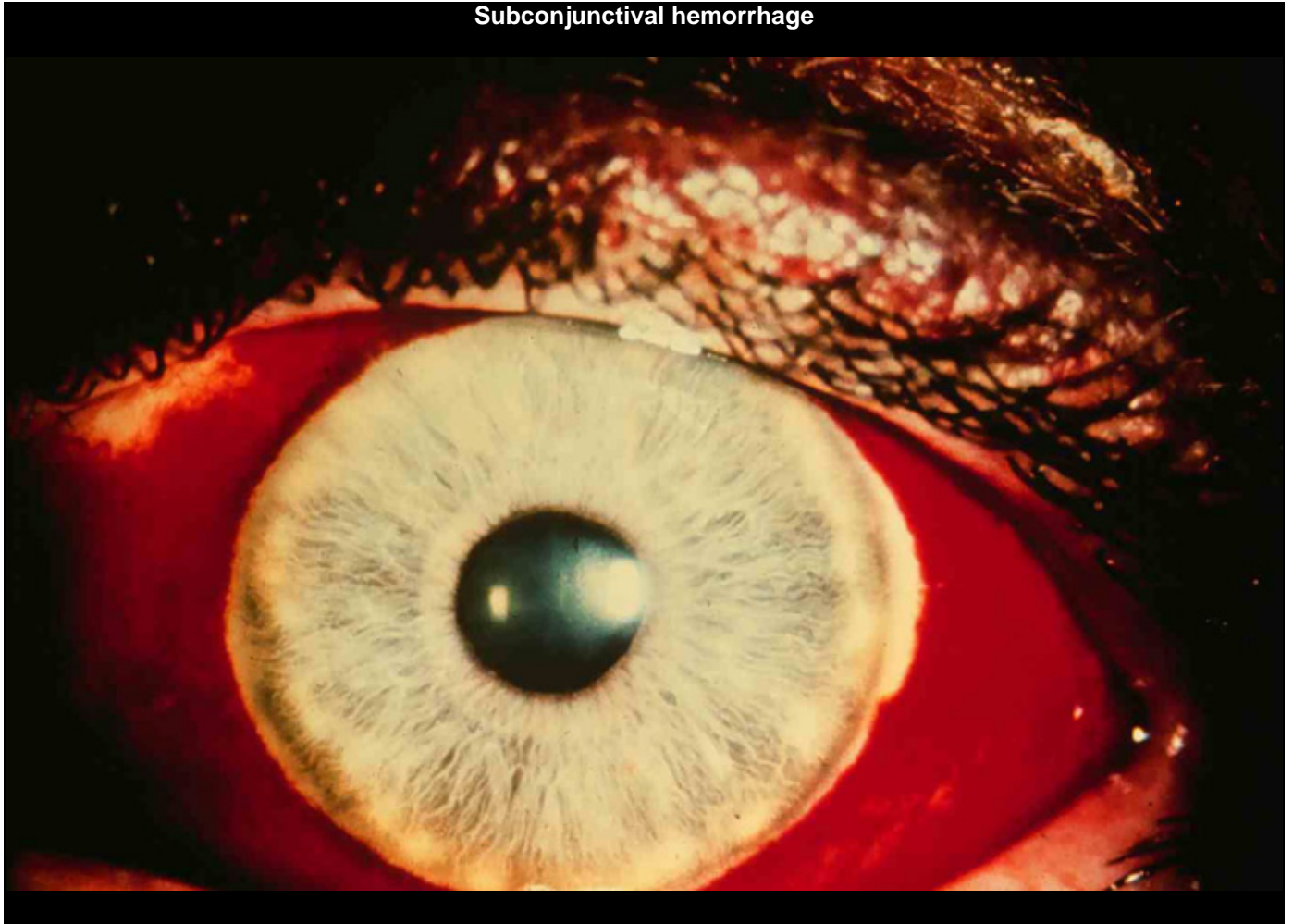


© Copyright [Oculisti OnLine](#)

EyeAtlas

The online Atlas of Ophthalmology

Subconjunctival hemorrhage

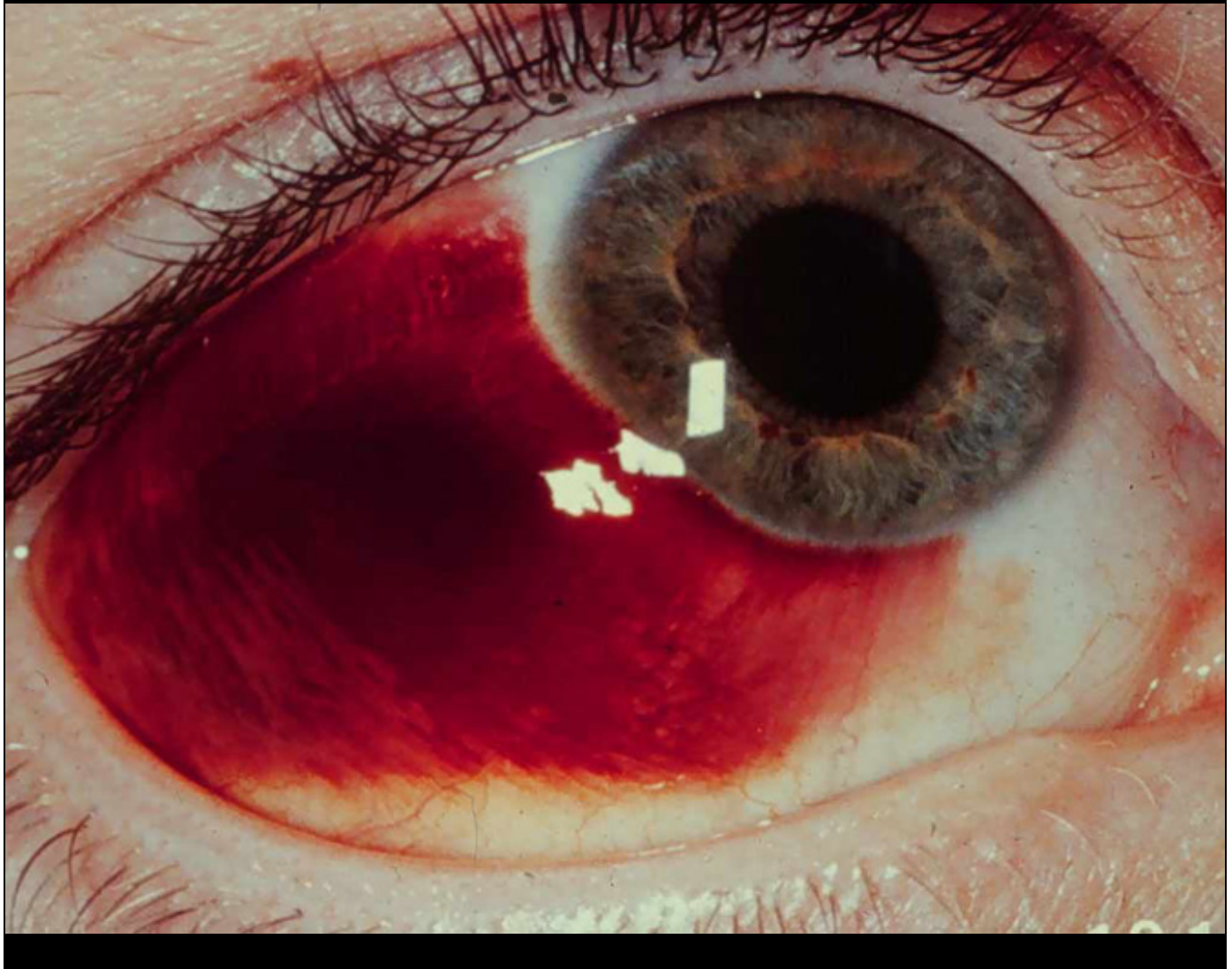

© Copyright [Oculisti OnLine](#)

EyeAtlas

The online Atlas of Ophthalmology

Sturge-Weber syndrome

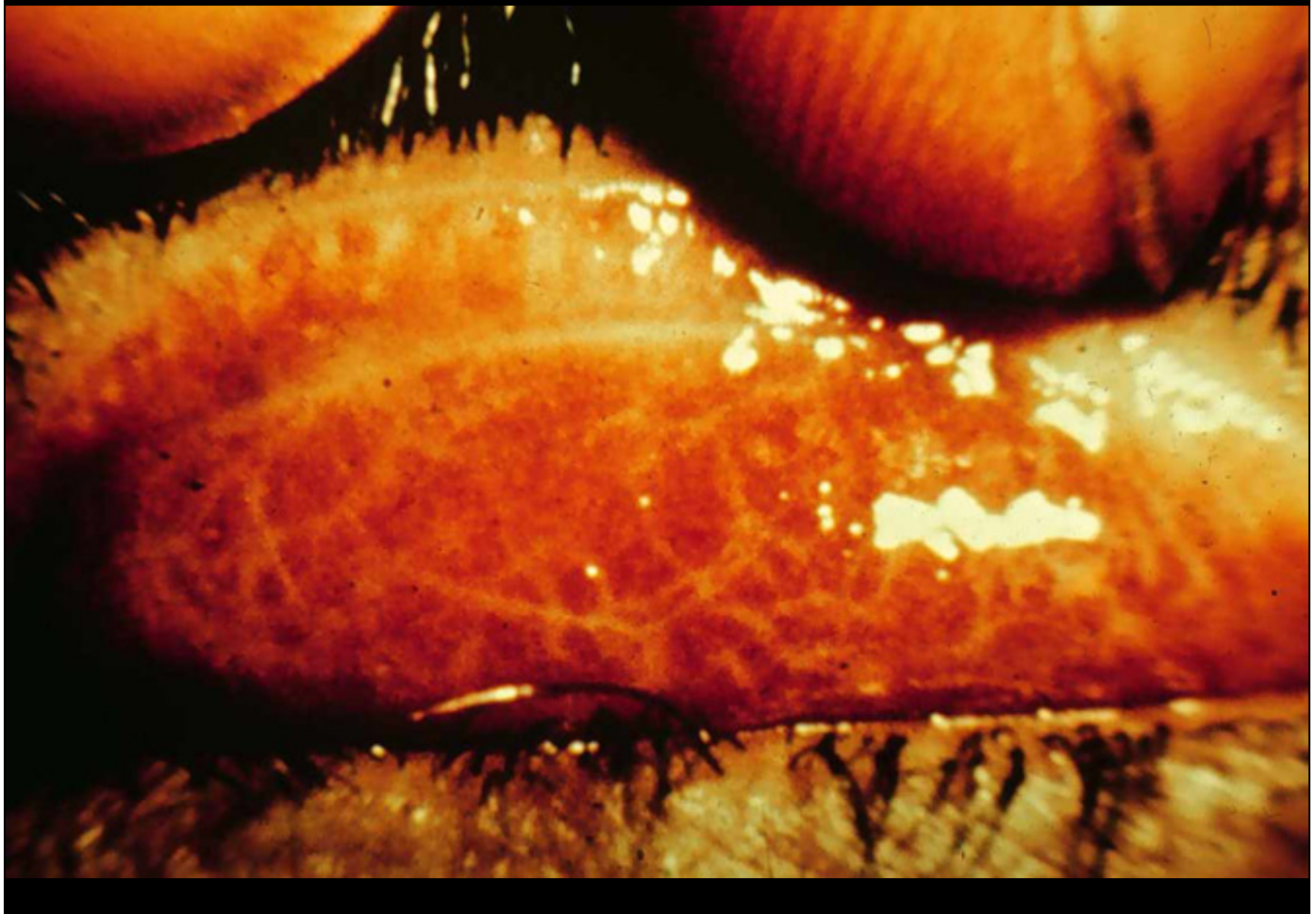


© Copyright [Oculisti OnLine](#)

EyeAtlas

The online Atlas of Ophthalmology

Trachoma

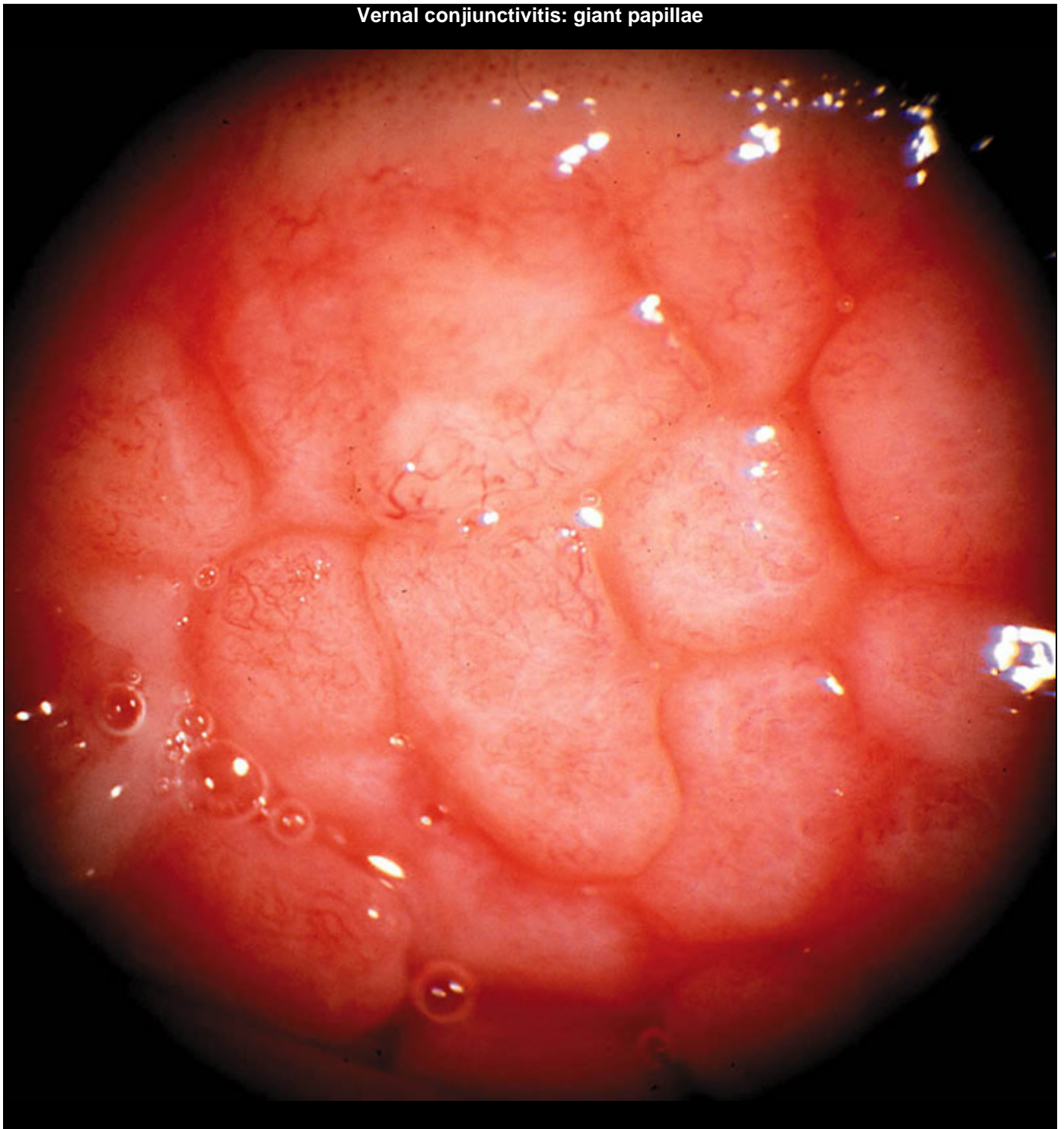


© Copyright [Oculisti OnLine](#)

Eyeatlas

The online Atlas of Ophthalmology

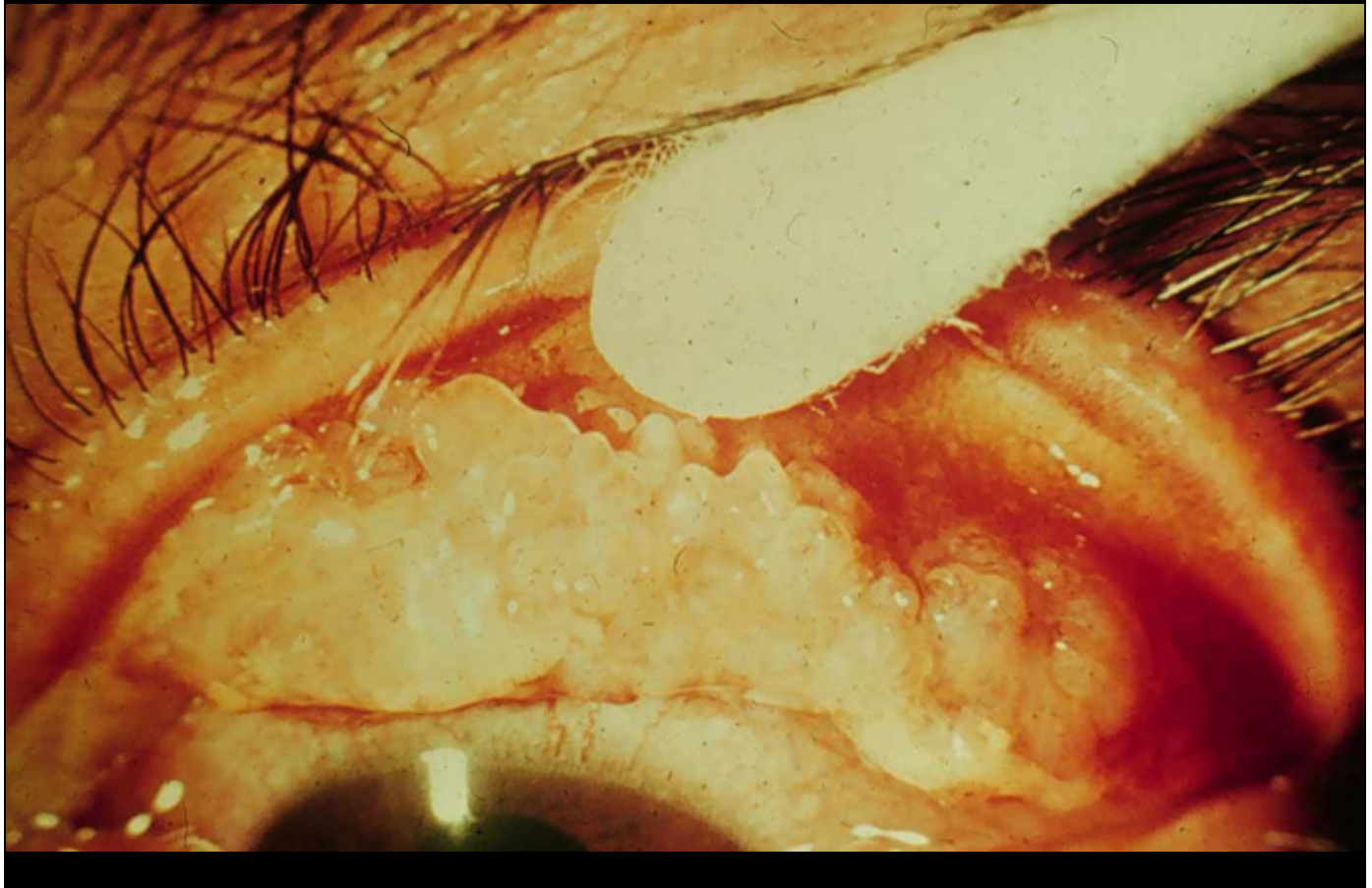
Vernal conjunctivitis: giant papillae



EyeAtlas

The online Atlas of Ophthalmology

Chronic vernal conjunctivitis

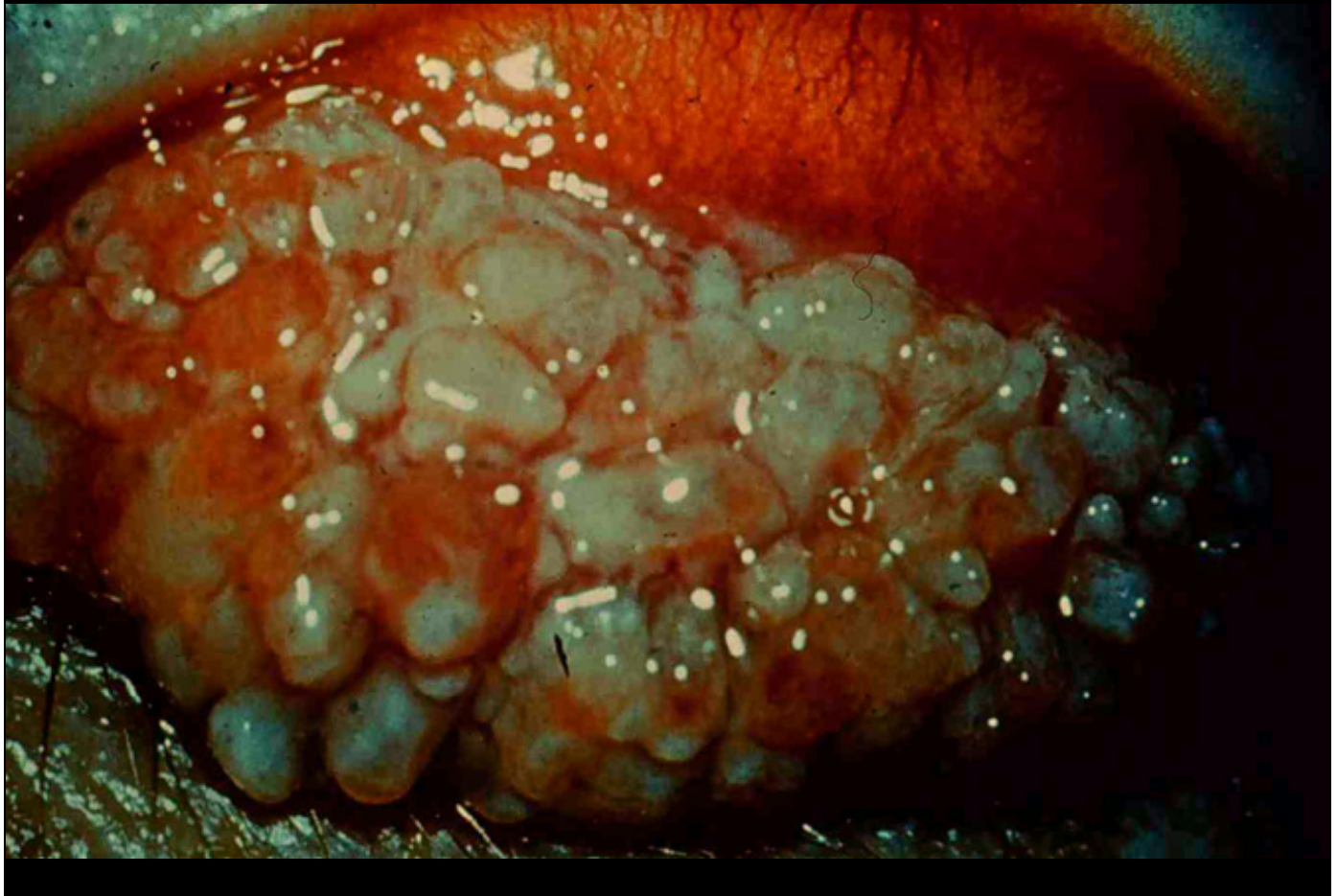

© Copyright [Oculisti OnLine](#)

EyeAtlas

The online Atlas of Ophthalmology

Vernal conjunctivitis

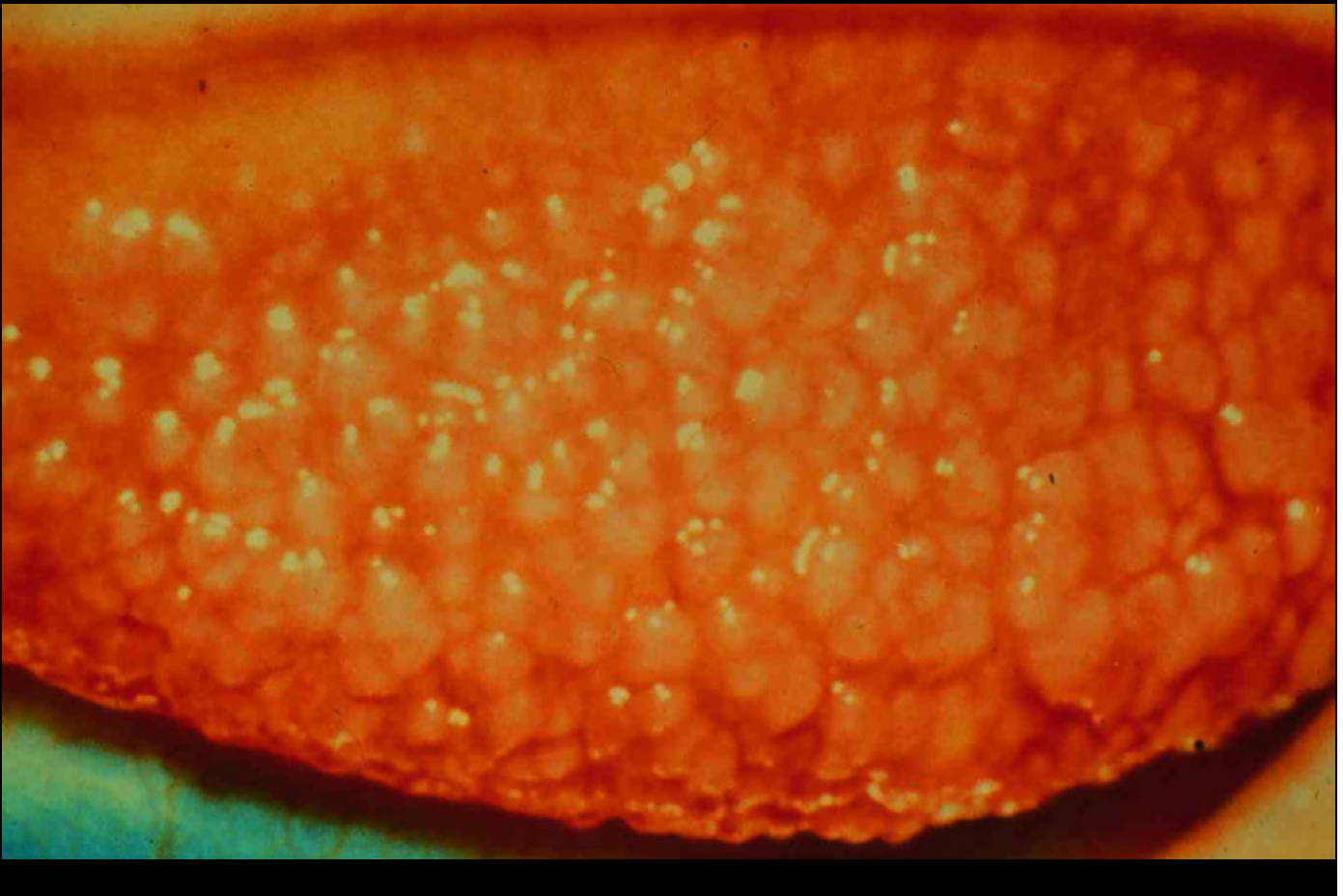


© Copyright [Oculisti OnLine](#)

EyeAtlas

The online Atlas of Ophthalmology

Vernal conjunctivitis

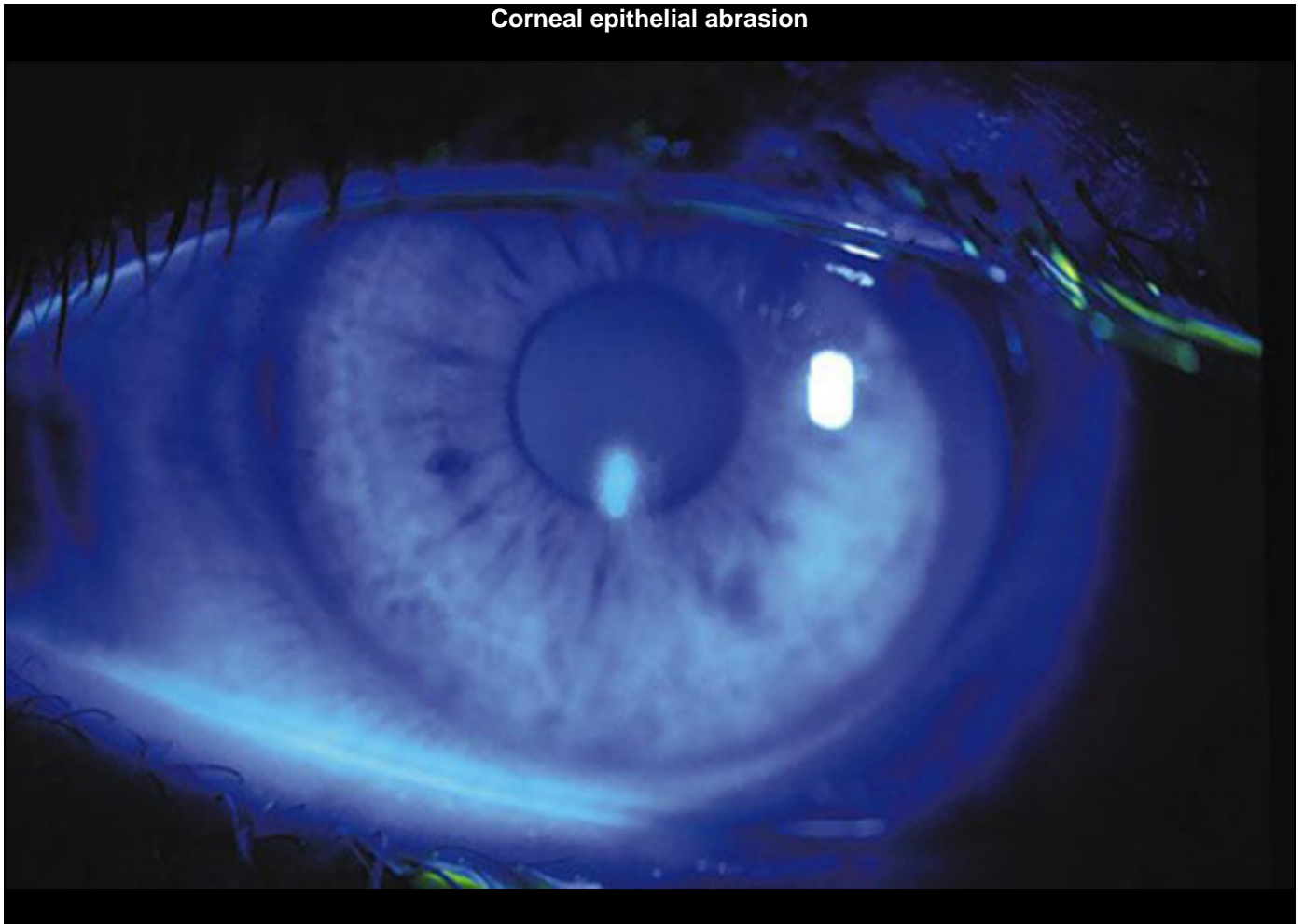


© Copyright [Oculisti OnLine](#)

EyeAtlas

The online Atlas of Ophthalmology

Corneal epithelial abrasion

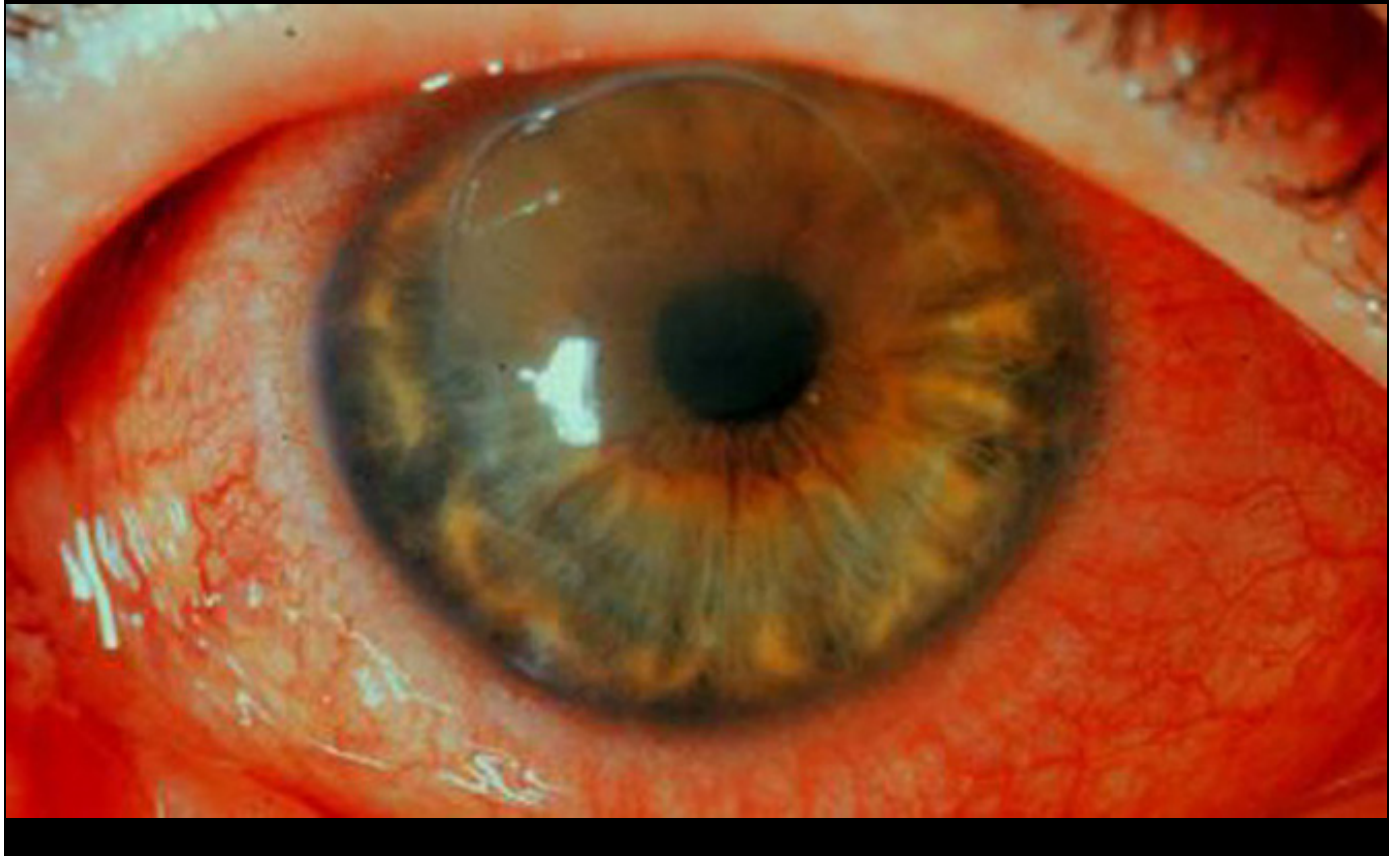


© Copyright [Oculisti OnLine](#)

Eyeatlas

The online Atlas of Ophthalmology

Corneal abrasion

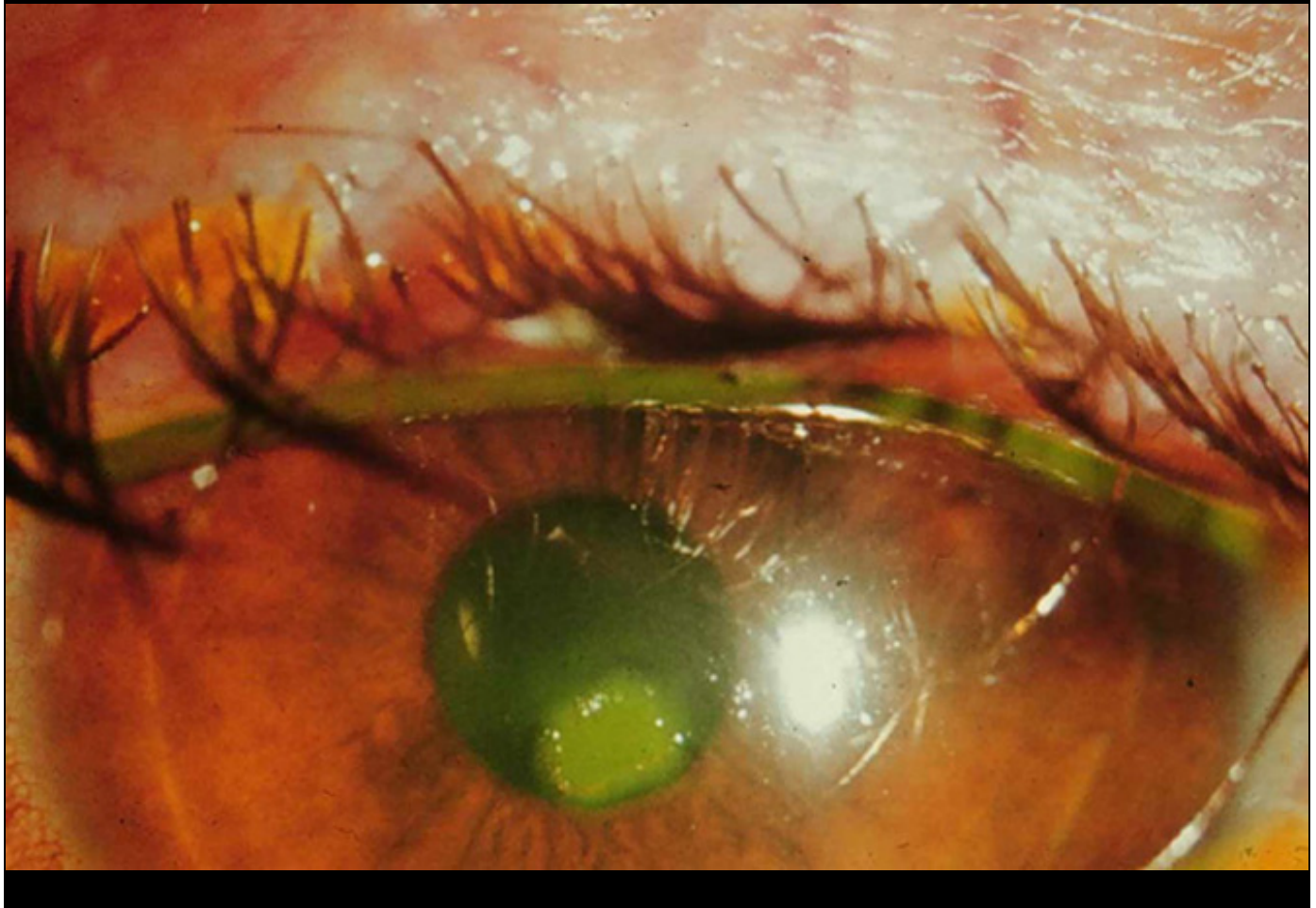


© Copyright [Oculisti OnLine](#)

EyeAtlas

The online Atlas of Ophthalmology

Corneal abrasion

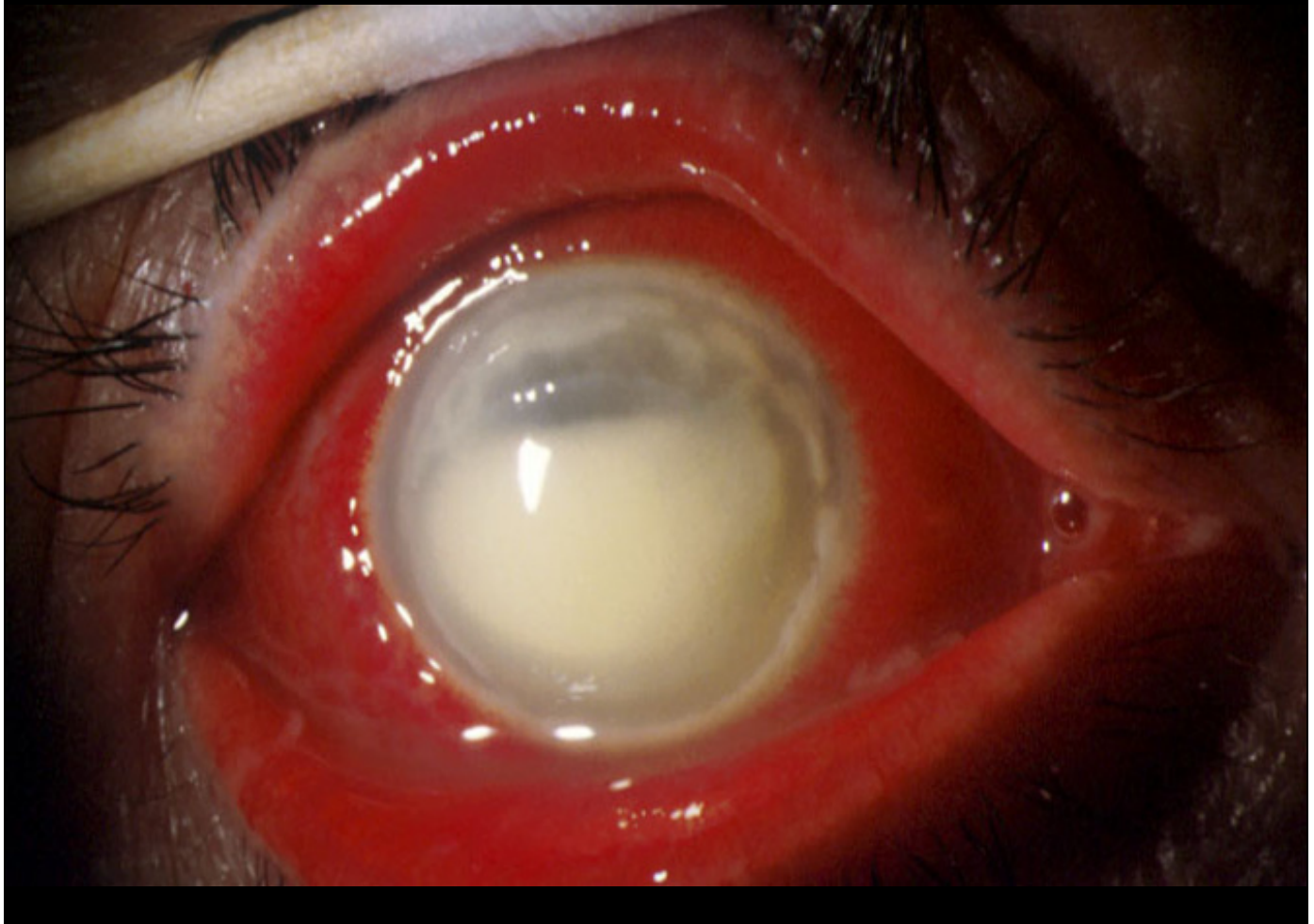

© Copyright [Oculisti OnLine](#)

EyeAtlas

The online Atlas of Ophthalmology

Corneal burn caused by alkali

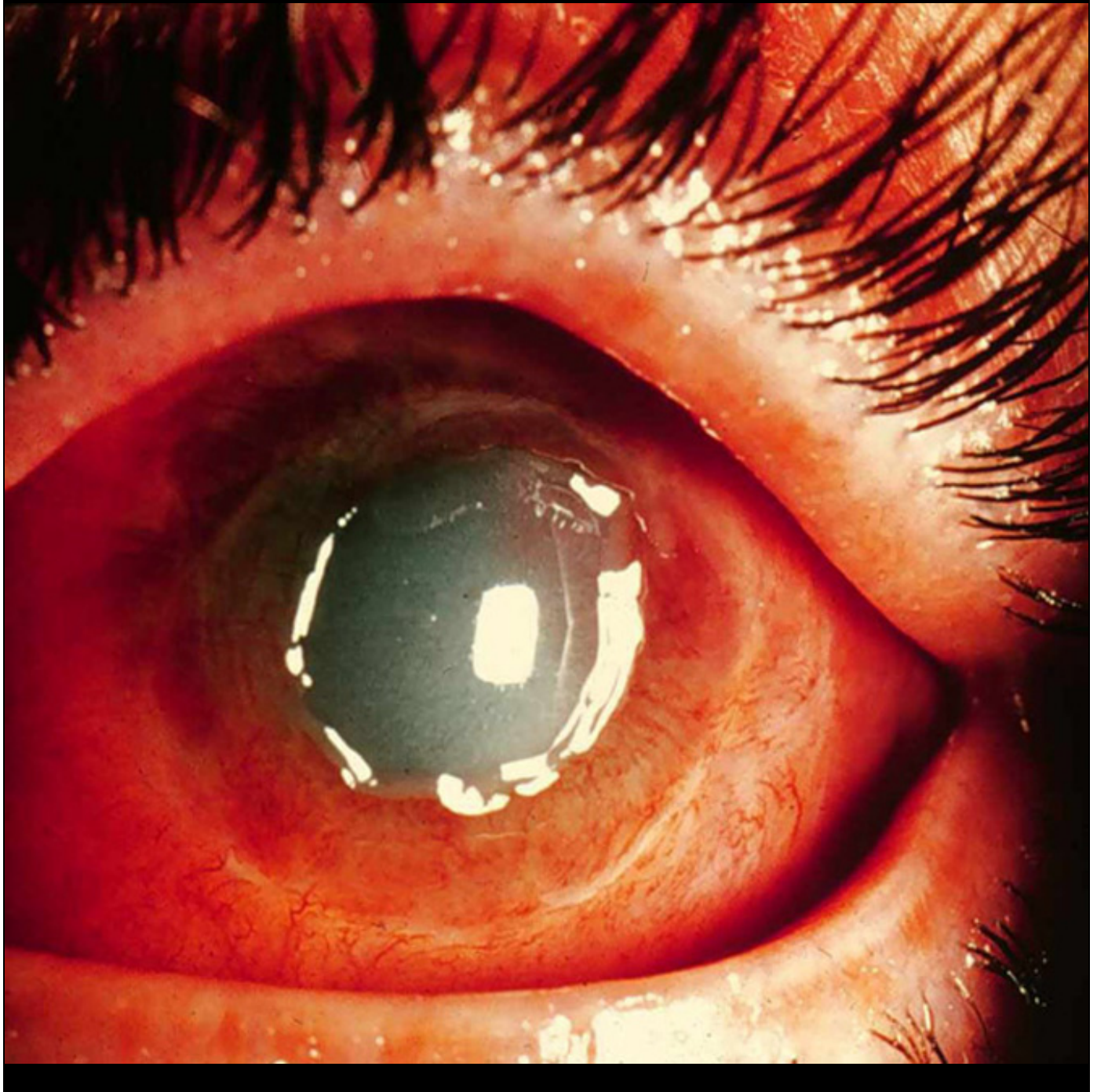


© Copyright [Oculisti OnLine](#)

EyeAtlas

The online Atlas of Ophthalmology

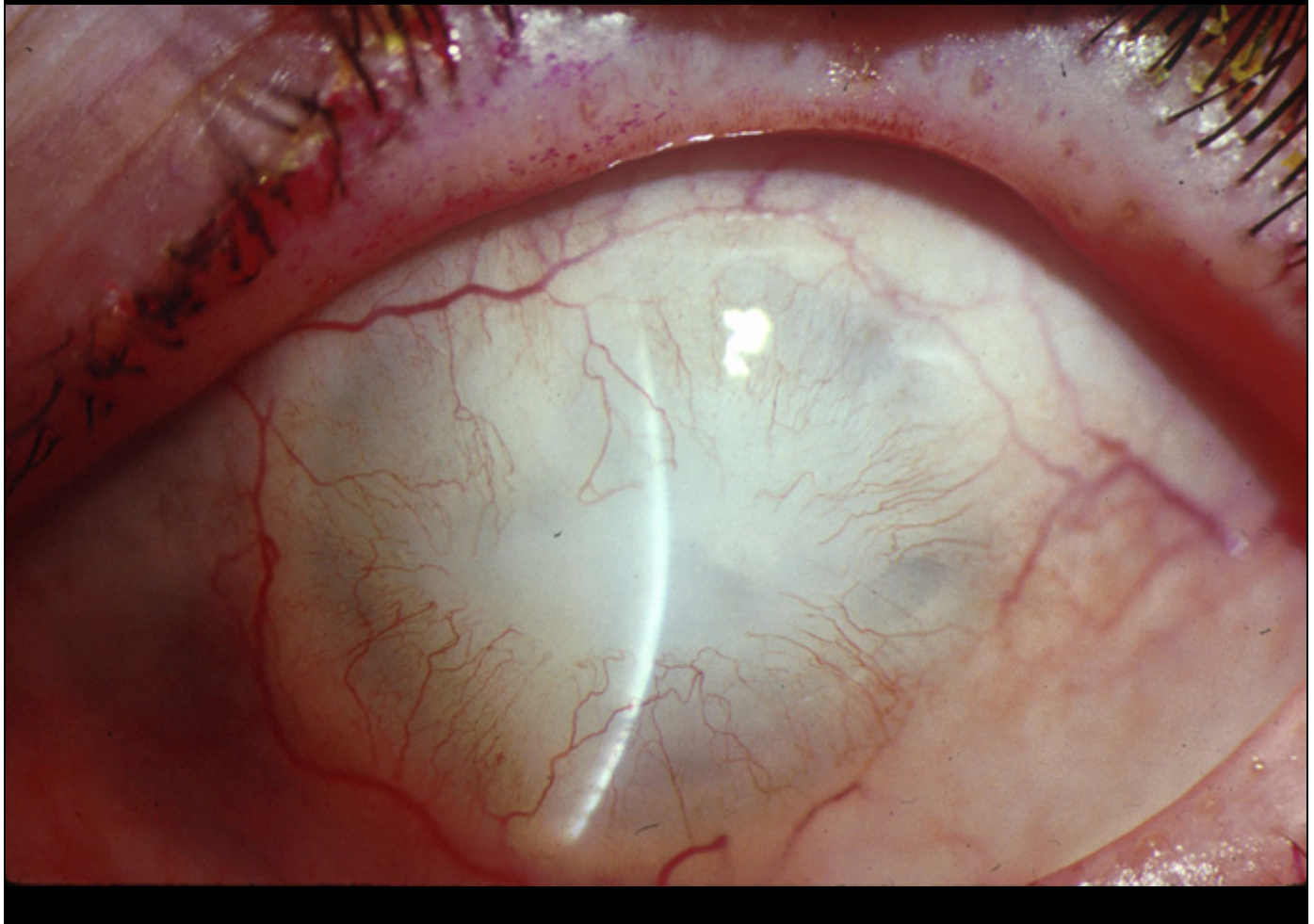
Alkali burn



EyeAtlas

The online Atlas of Ophthalmology

Corneal burn caused by alkali: corneal neovascularization

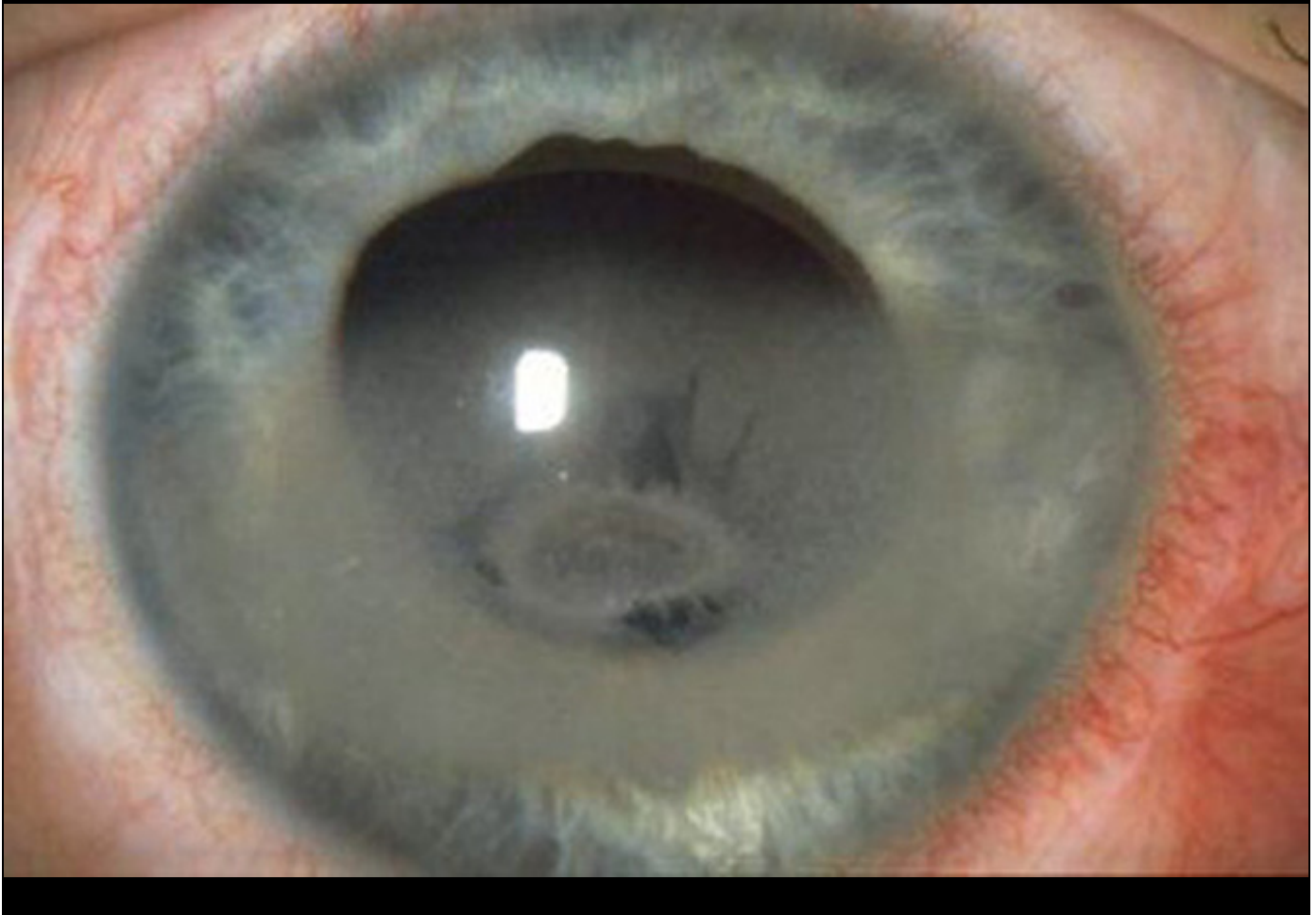


© Copyright [Oculisti OnLine](#)

EyeAtlas

The online Atlas of Ophthalmology

Band keratopathy

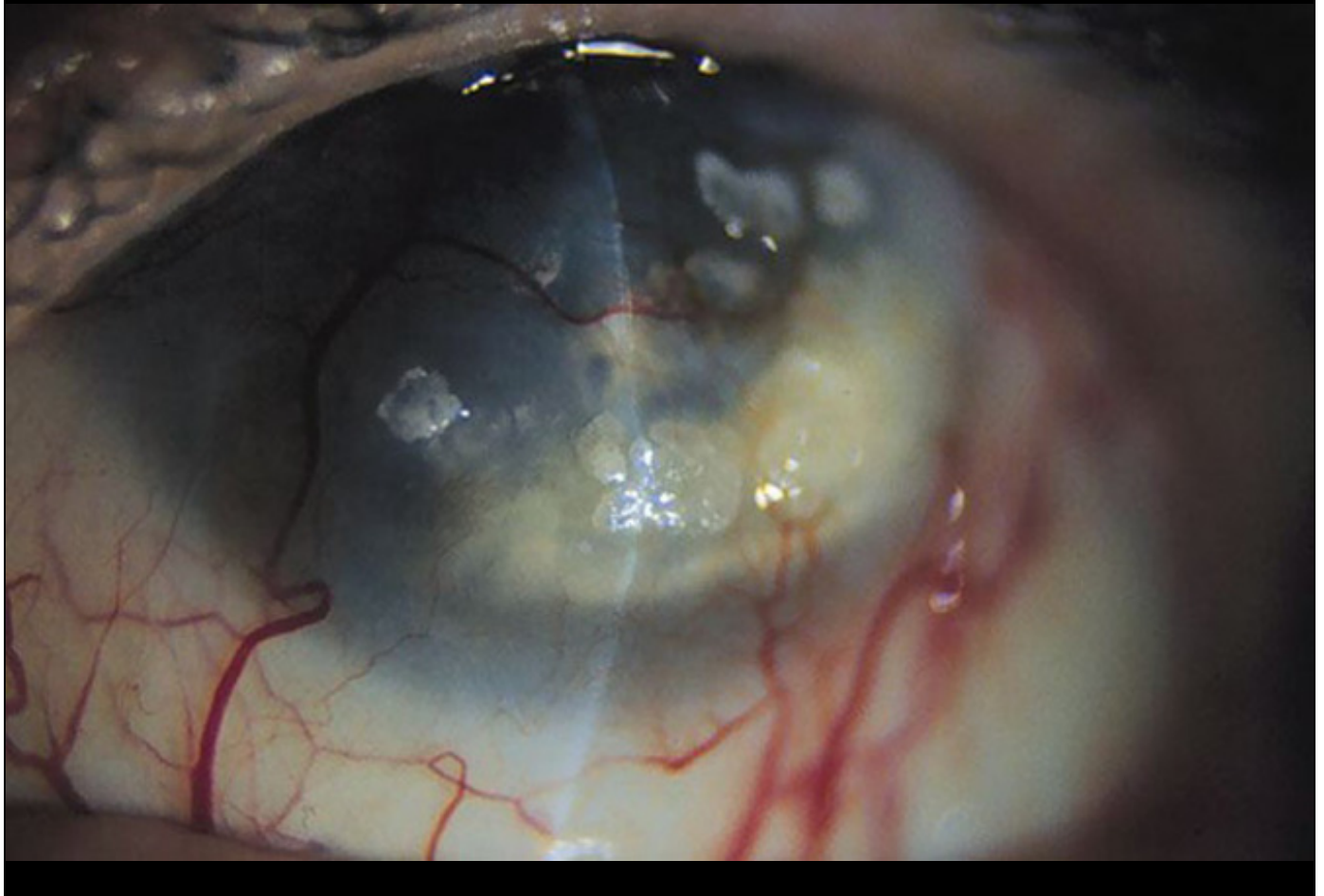


© Copyright [Oculisti OnLine](#)

EyeAtlas

The online Atlas of Ophthalmology

Band keratopathy and lipidic degeneration

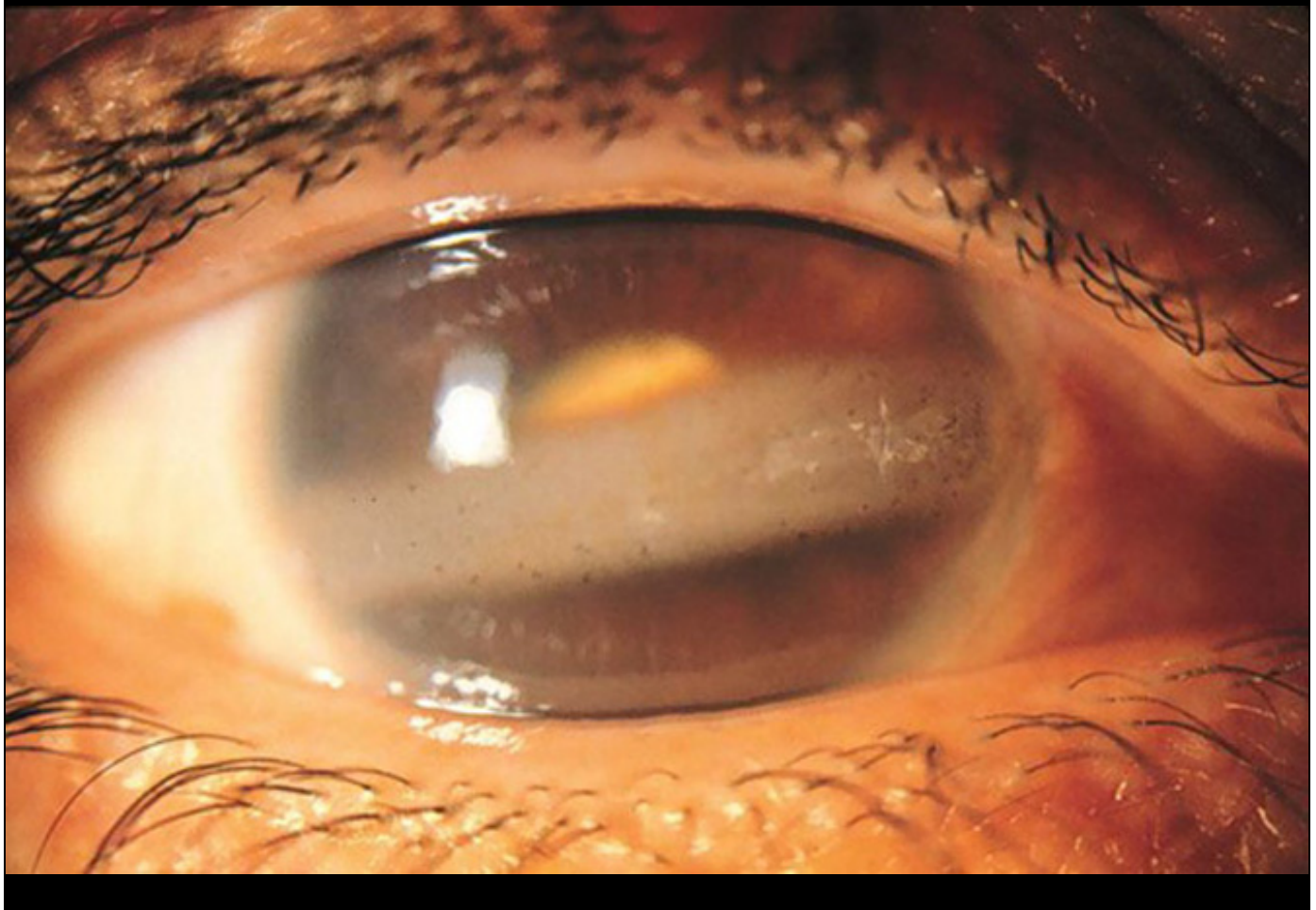


© Copyright [Oculisti OnLine](http://www.eyeatlas.com)

Eyeatlas

The online Atlas of Ophthalmology

Band keratopathy

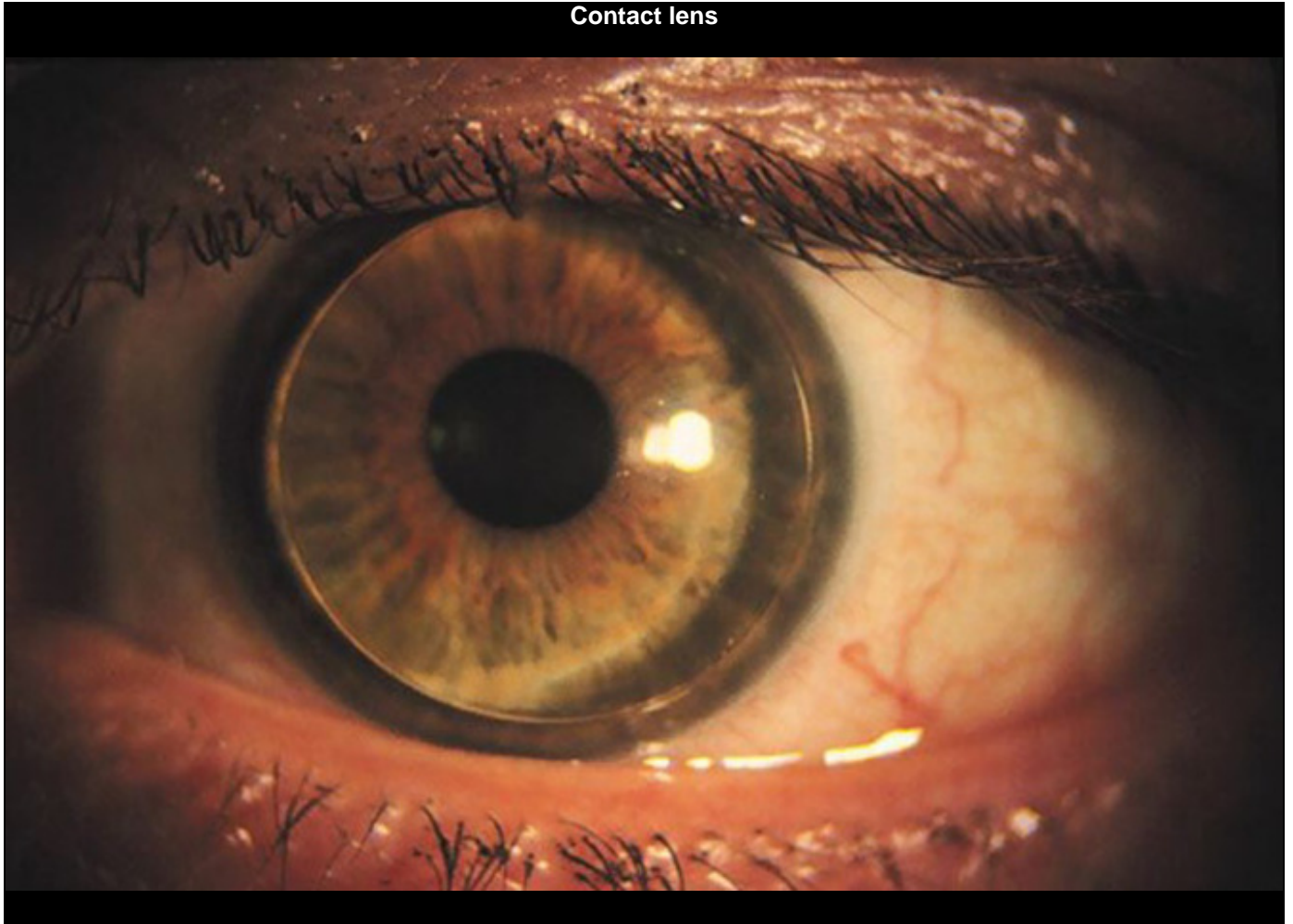

© Copyright [Oculisti OnLine](#)

EyeAtlas

The online Atlas of Ophthalmology

Contact lens

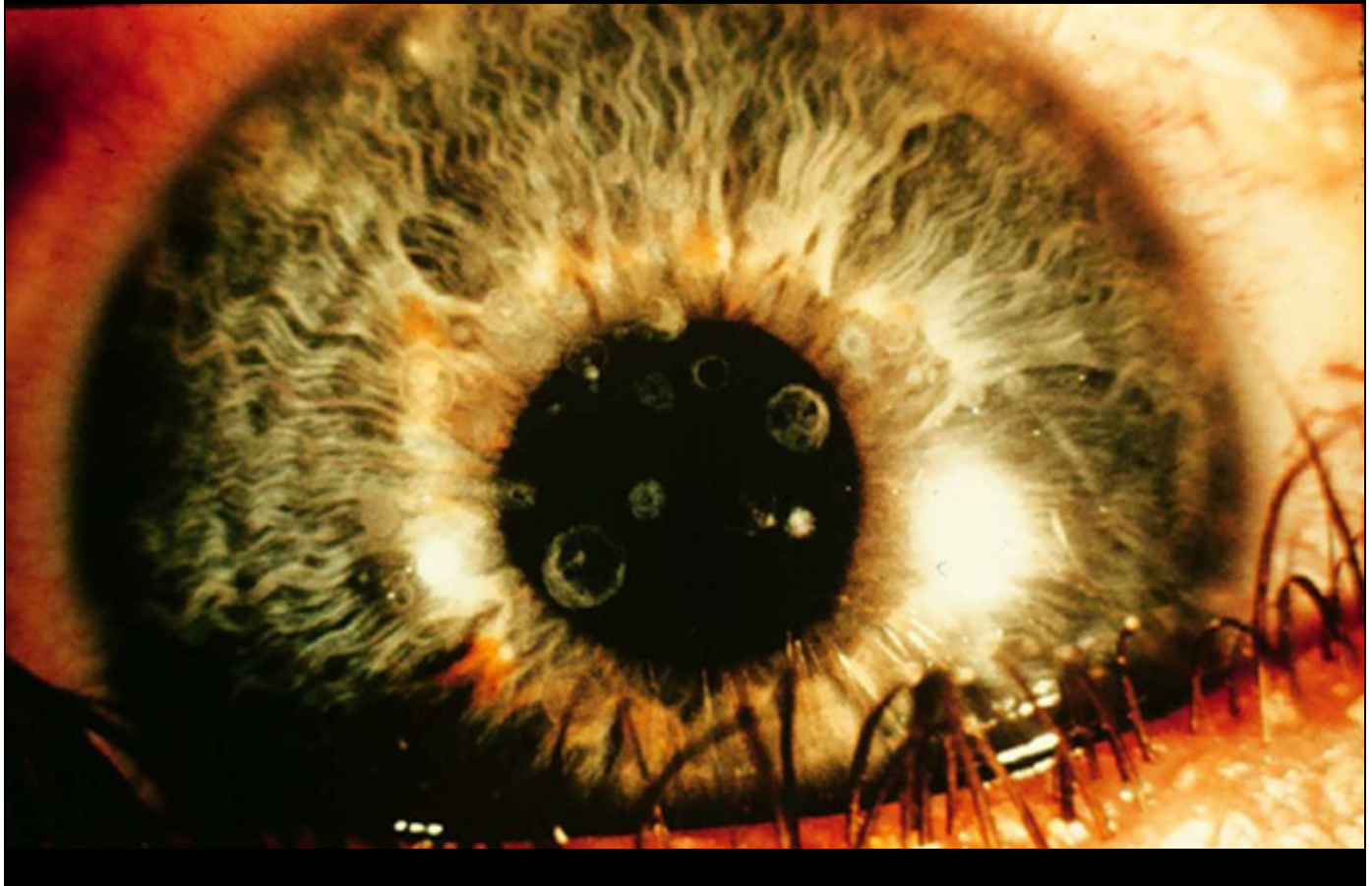


© Copyright [Oculisti OnLine](#)

EyeAtlas

The online Atlas of Ophthalmology

Granular corneal dystrophy

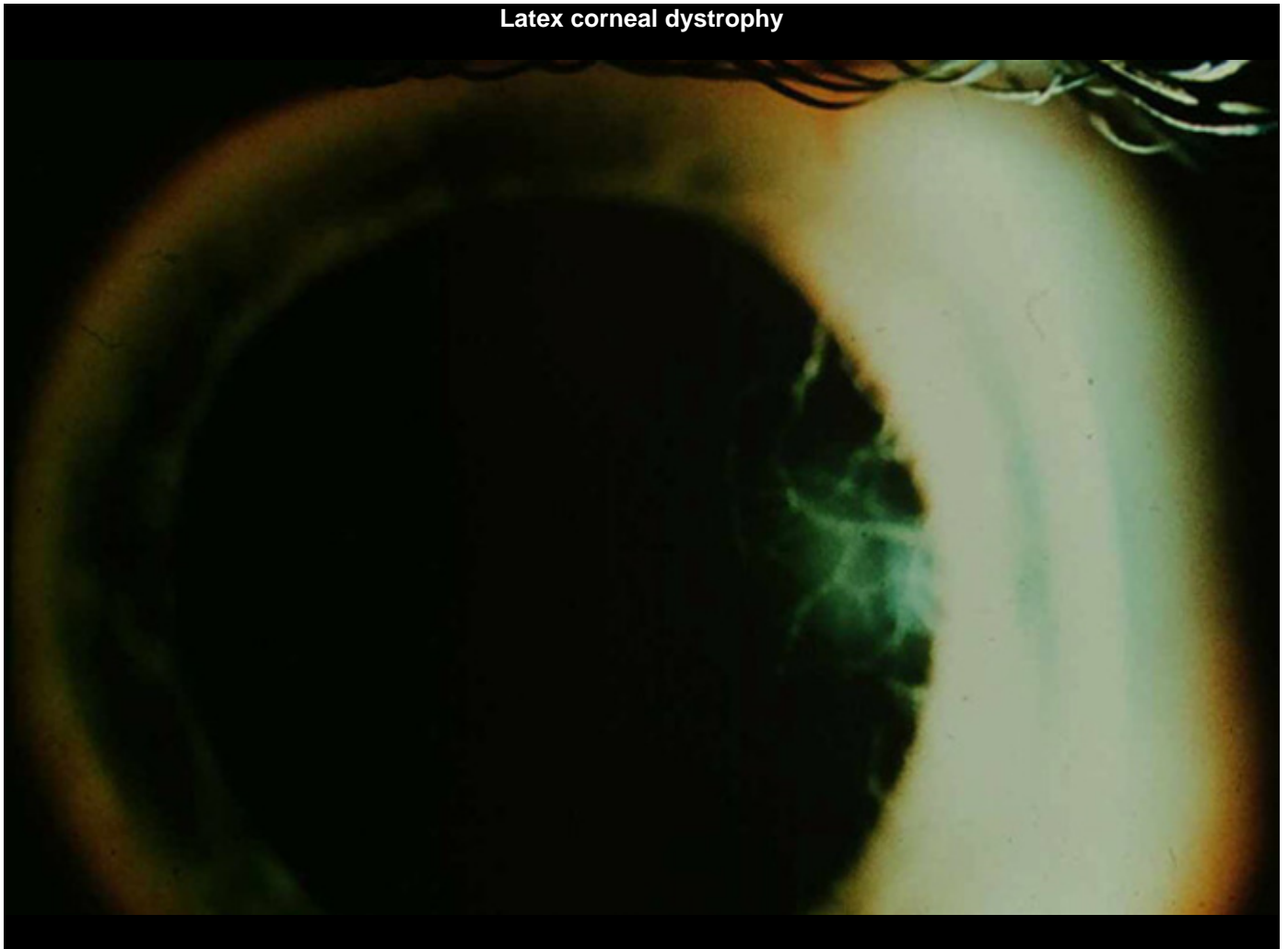


© Copyright [Oculisti OnLine](#)

EyeAtlas

The online Atlas of Ophthalmology

Latex corneal dystrophy

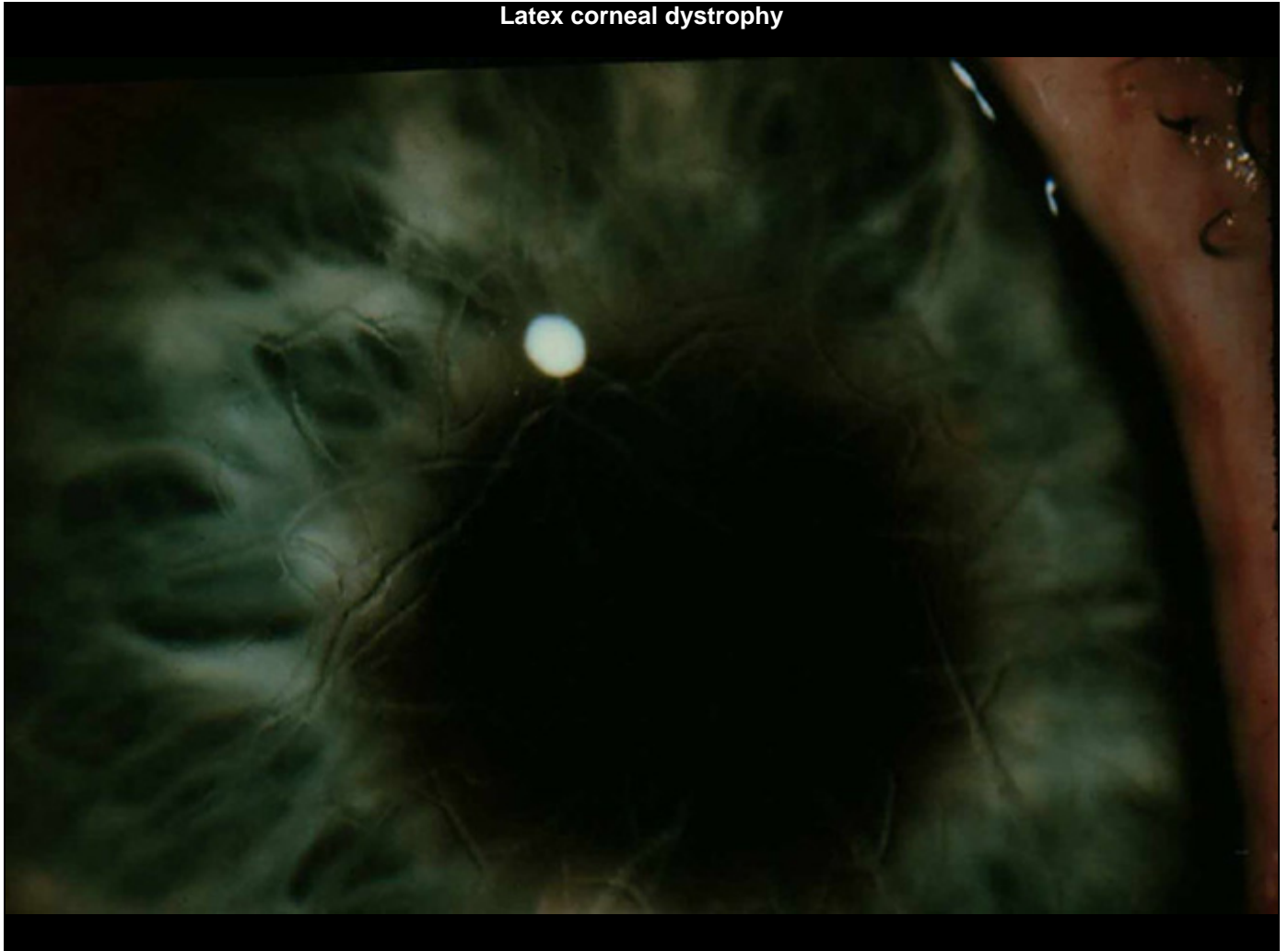

© Copyright [Oculisti OnLine](#)

Eyeatlas

The online Atlas of Ophthalmology

Latex corneal dystrophy

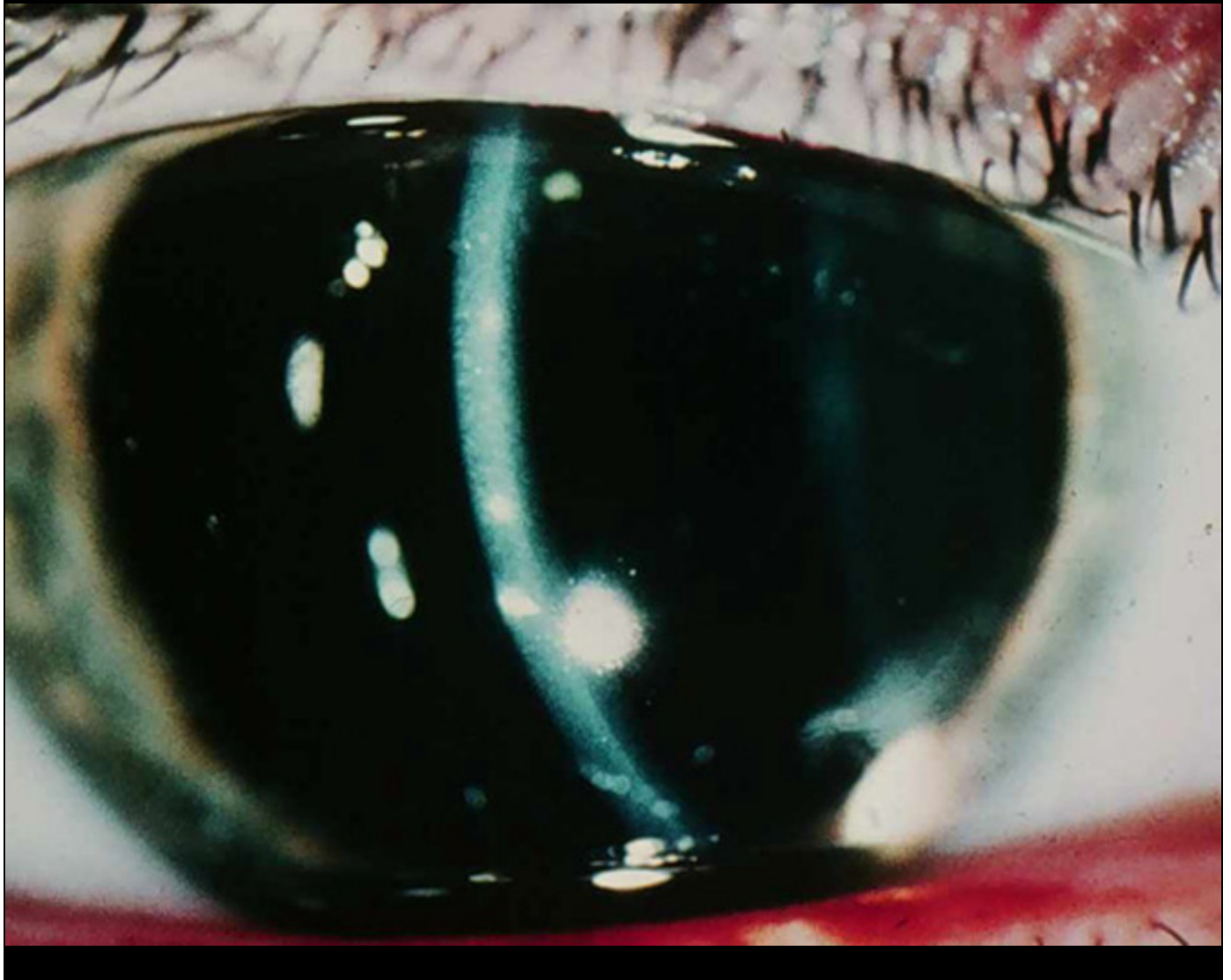


© Copyright [Oculisti OnLine](#)

EyeAtlas

The online Atlas of Ophthalmology

Meesmans' corneal dystrophy

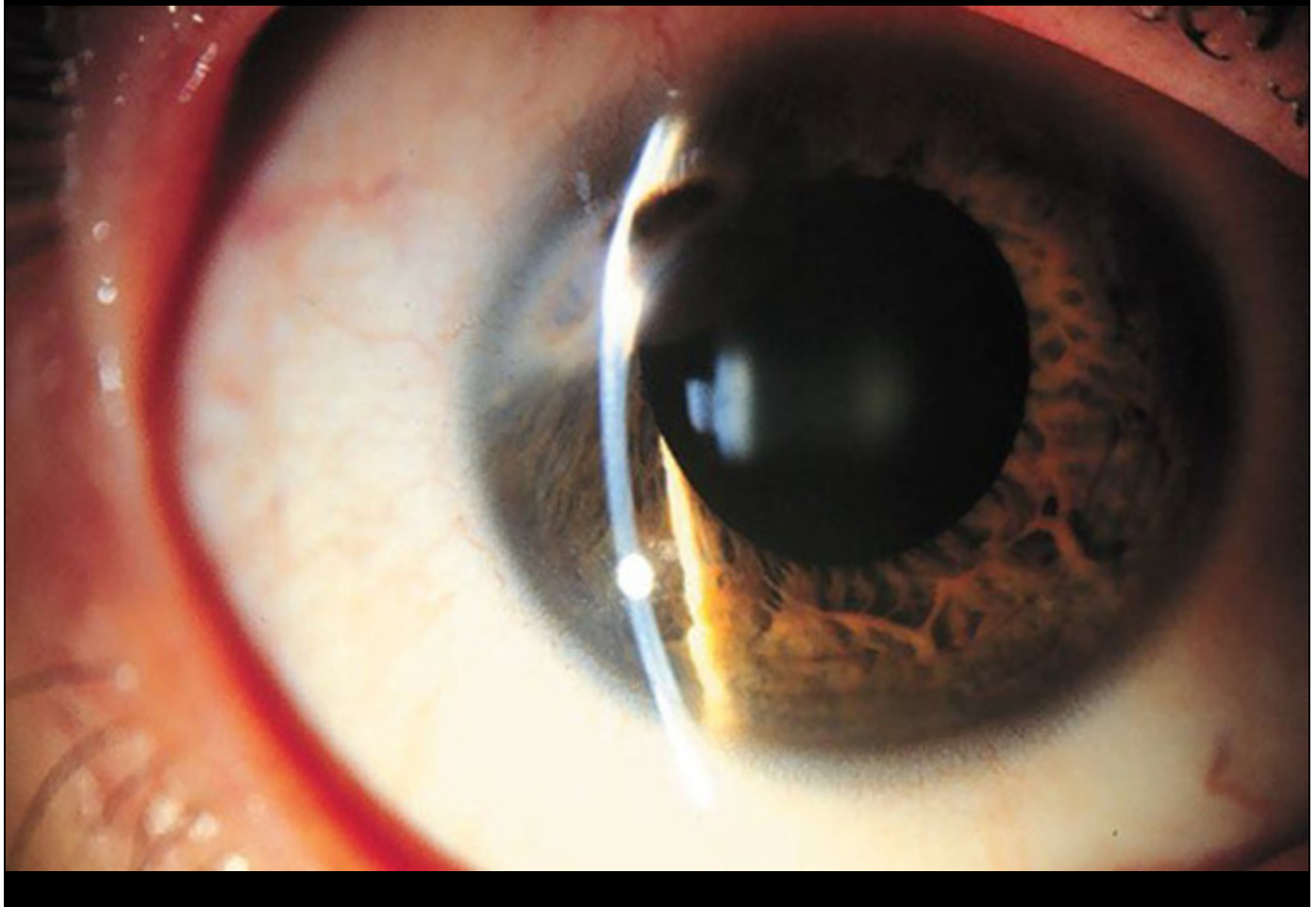


© Copyright [Oculisti OnLine](#)

EyeAtlas

The online Atlas of Ophthalmology

Meesmans' corneal dystrophy

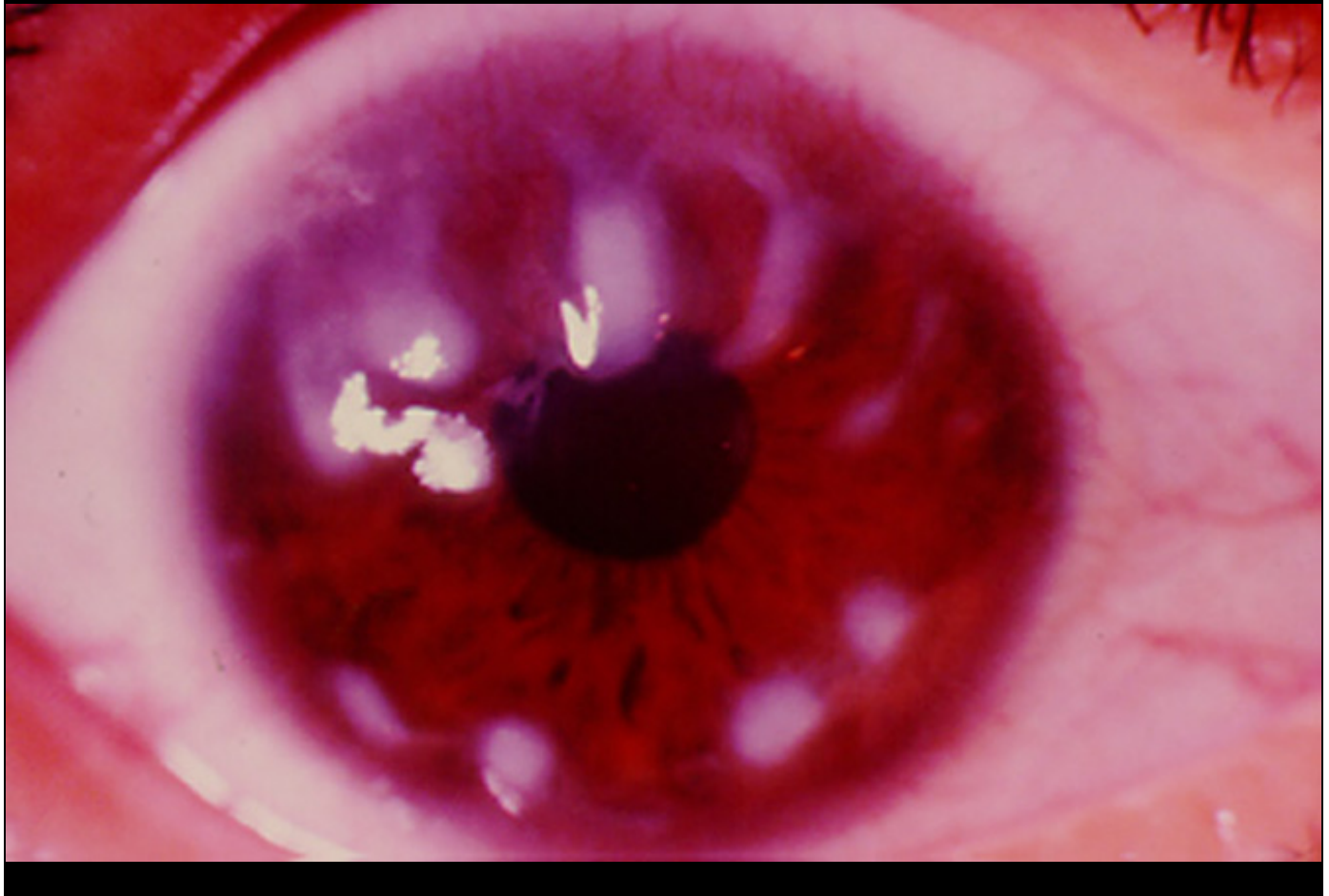


© Copyright [Oculisti OnLine](#)

EyeAtlas

The online Atlas of Ophthalmology

Salzmann's dystrophy

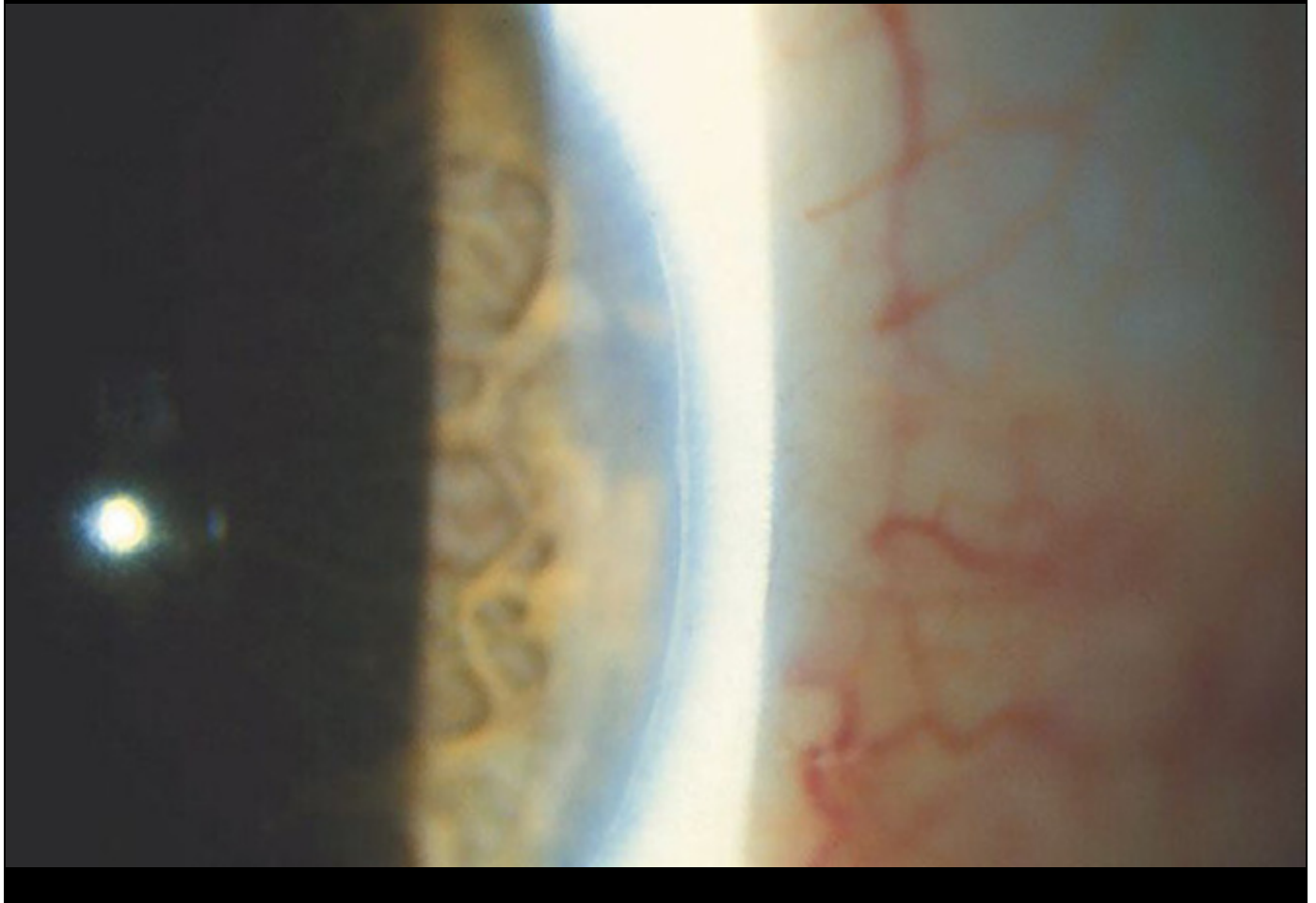


© Copyright [Oculisti OnLine](http://www.eyeatlas.com)

Eyeatlas

The online Atlas of Ophthalmology

Posterior embriotoxon

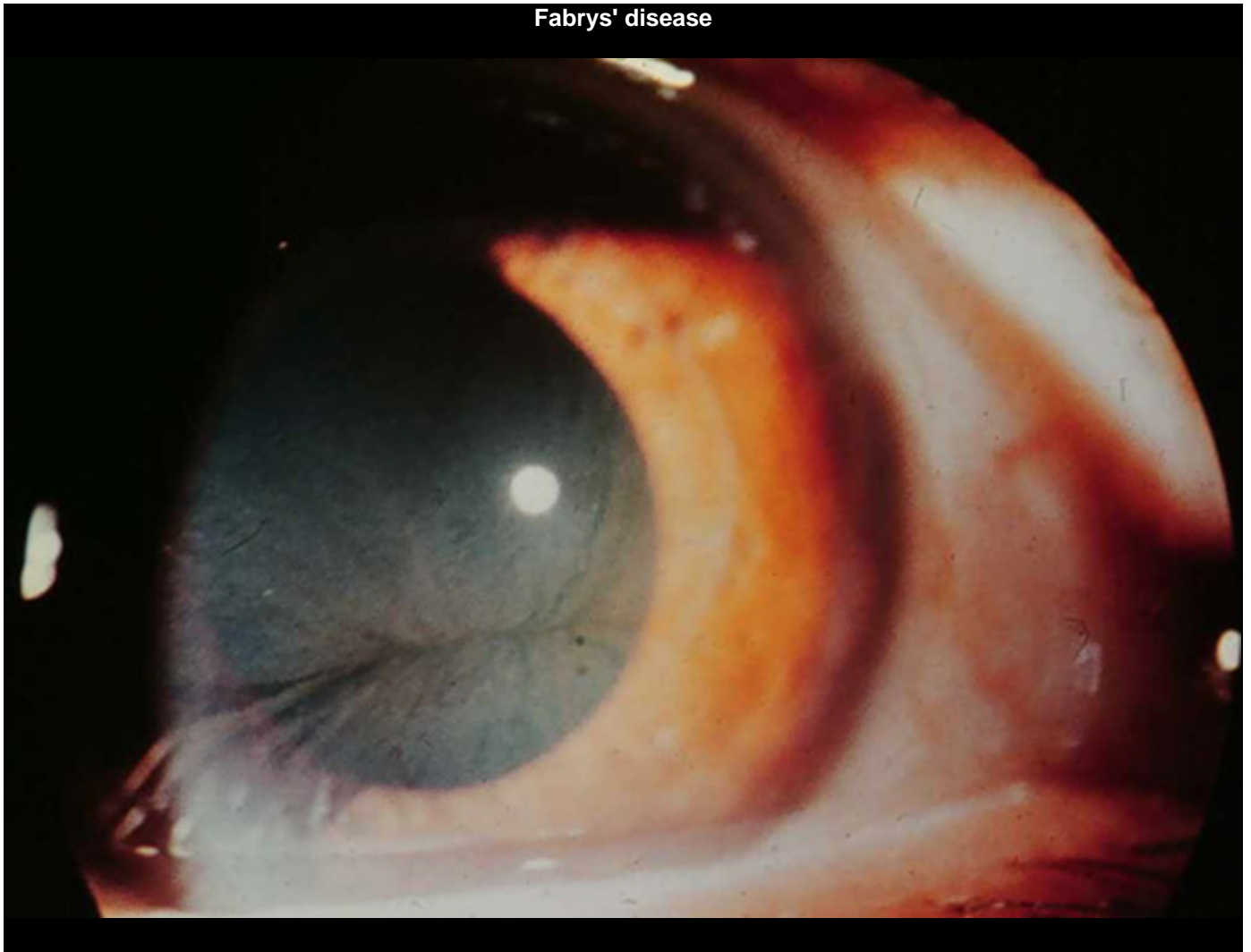


© Copyright [Oculisti OnLine](#)

EyeAtlas

The online Atlas of Ophthalmology

Fabrys' disease

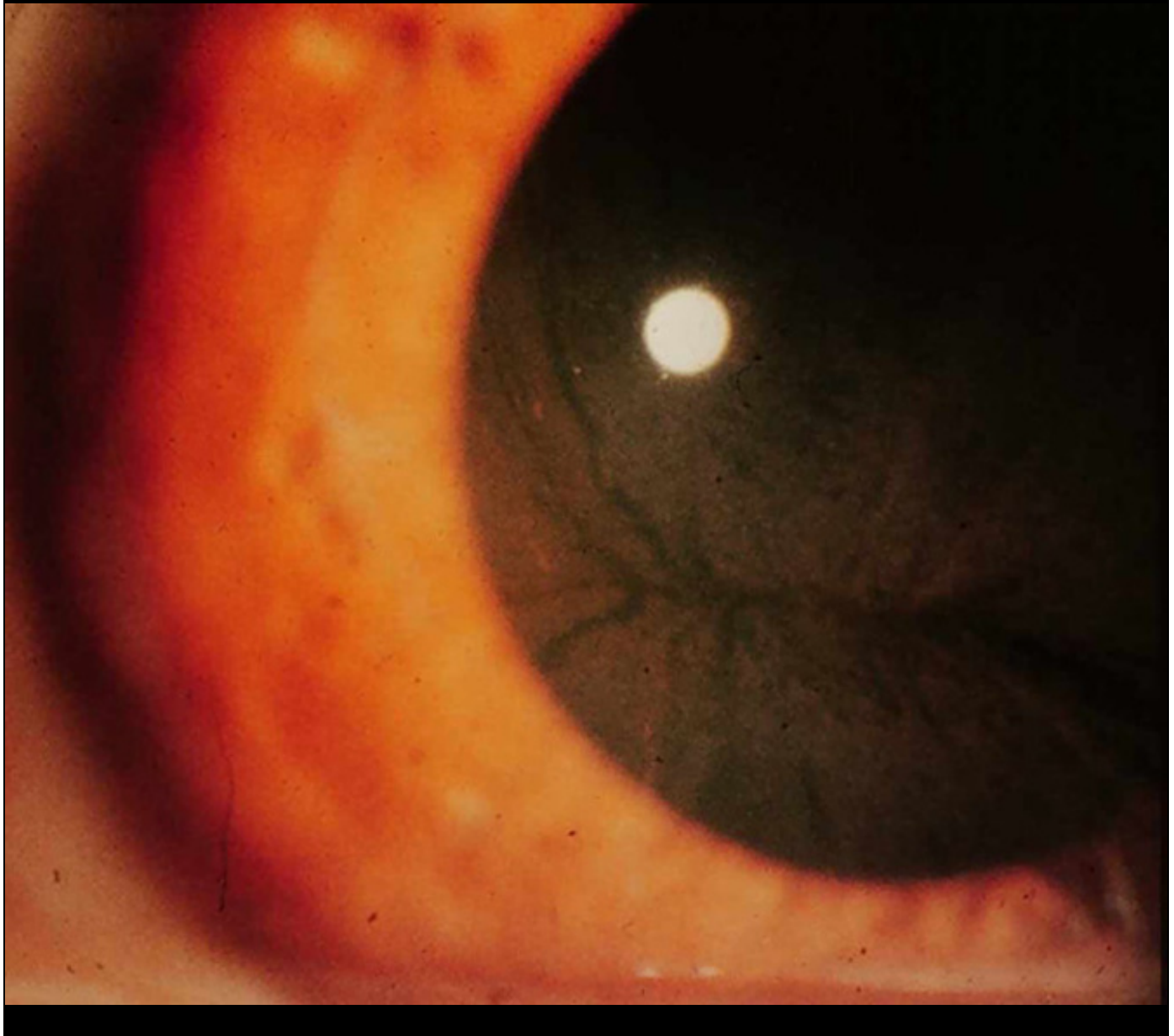


© Copyright [Oculisti OnLine](#)

EyeAtlas

The online Atlas of Ophthalmology

Fabry's disease

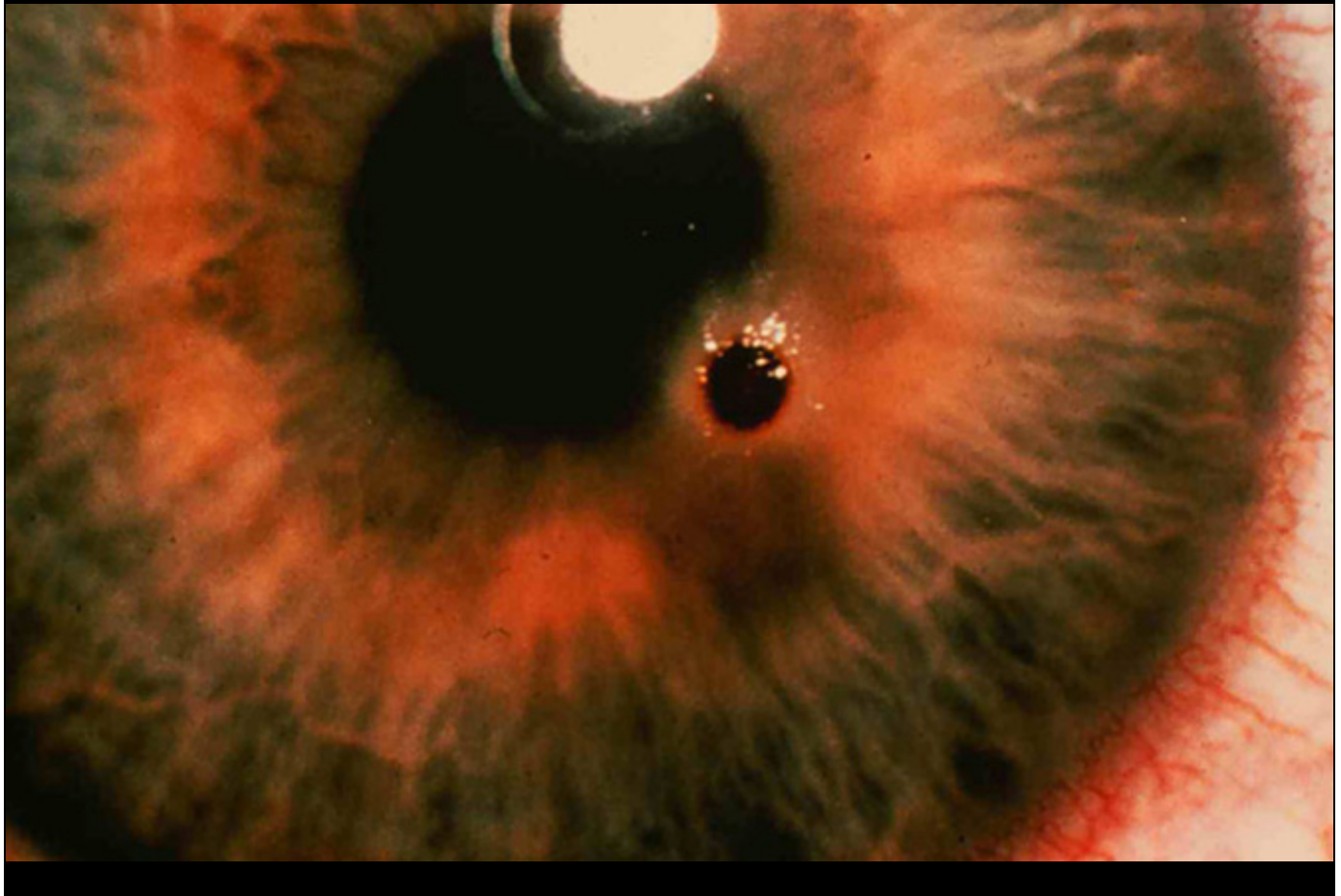


© Copyright [Oculisti OnLine](http://www.eyeatlas.com)

Eyeatlas

The online Atlas of Ophthalmology

Corneal foreign body

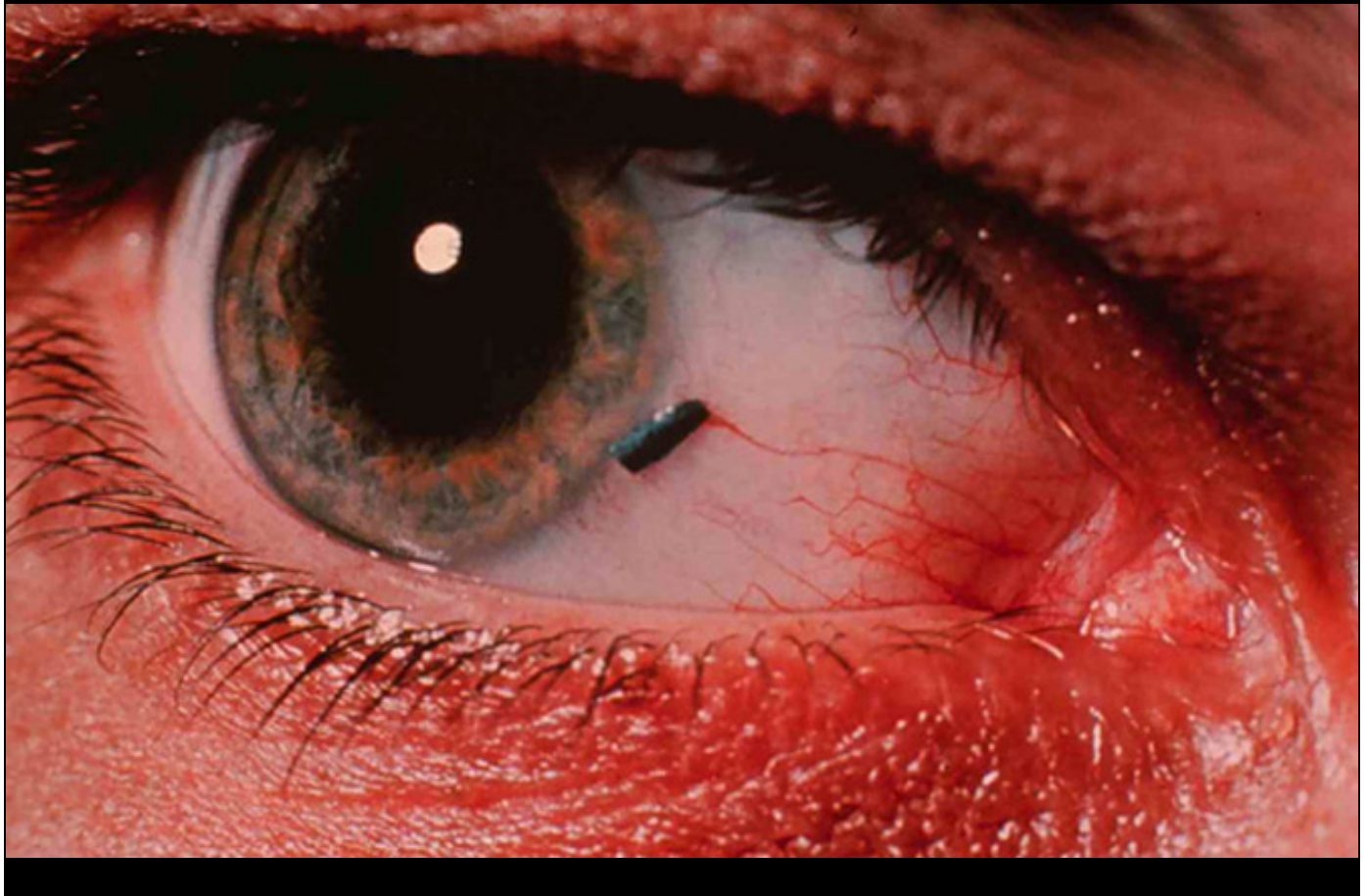

© Copyright [Oculisti OnLine](#)

EyeAtlas

The online Atlas of Ophthalmology

Corneal foreign body

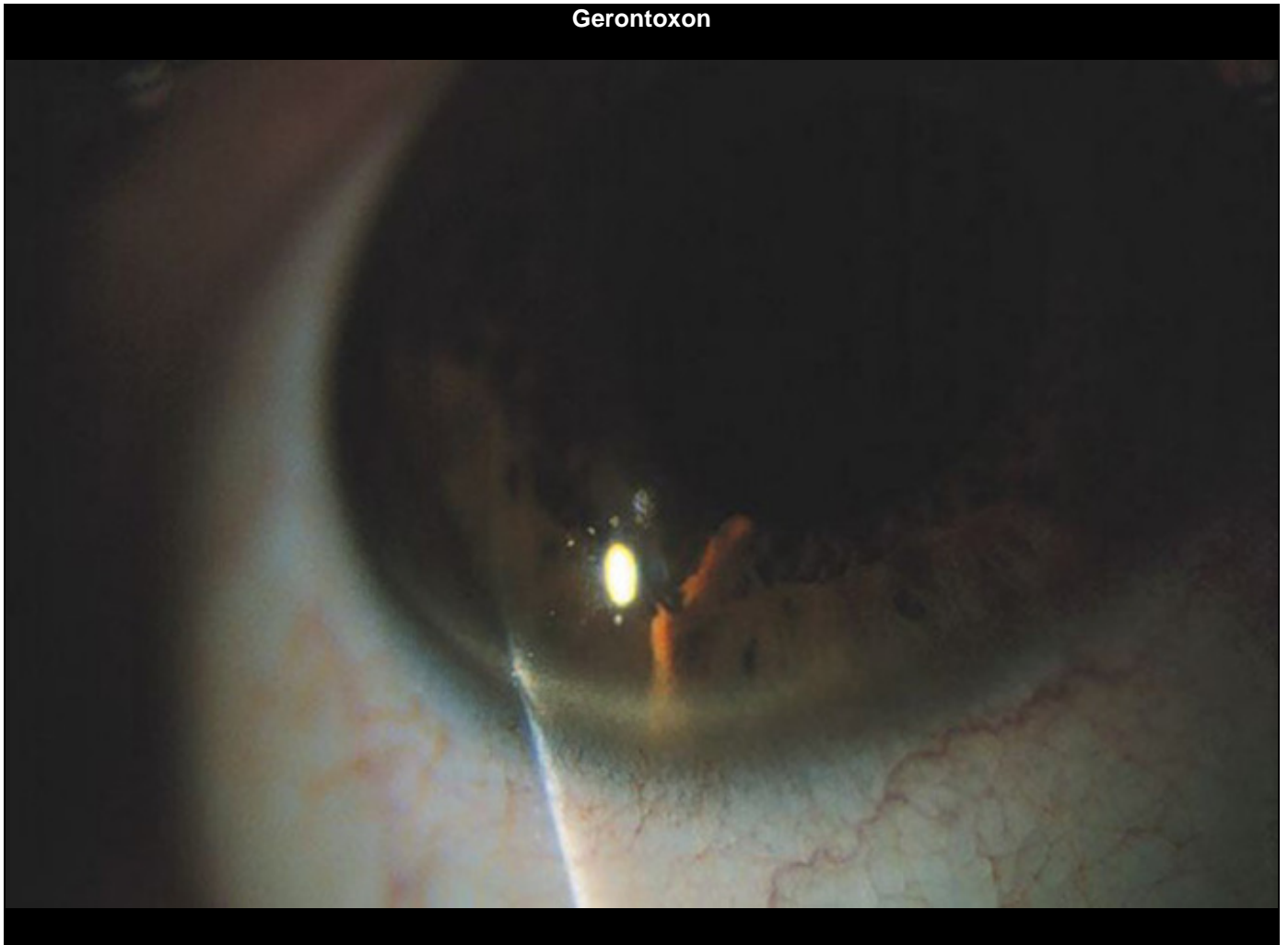

© Copyright [Oculisti OnLine](#)

EyeAtlas

The online Atlas of Ophthalmology

Gerontoxon

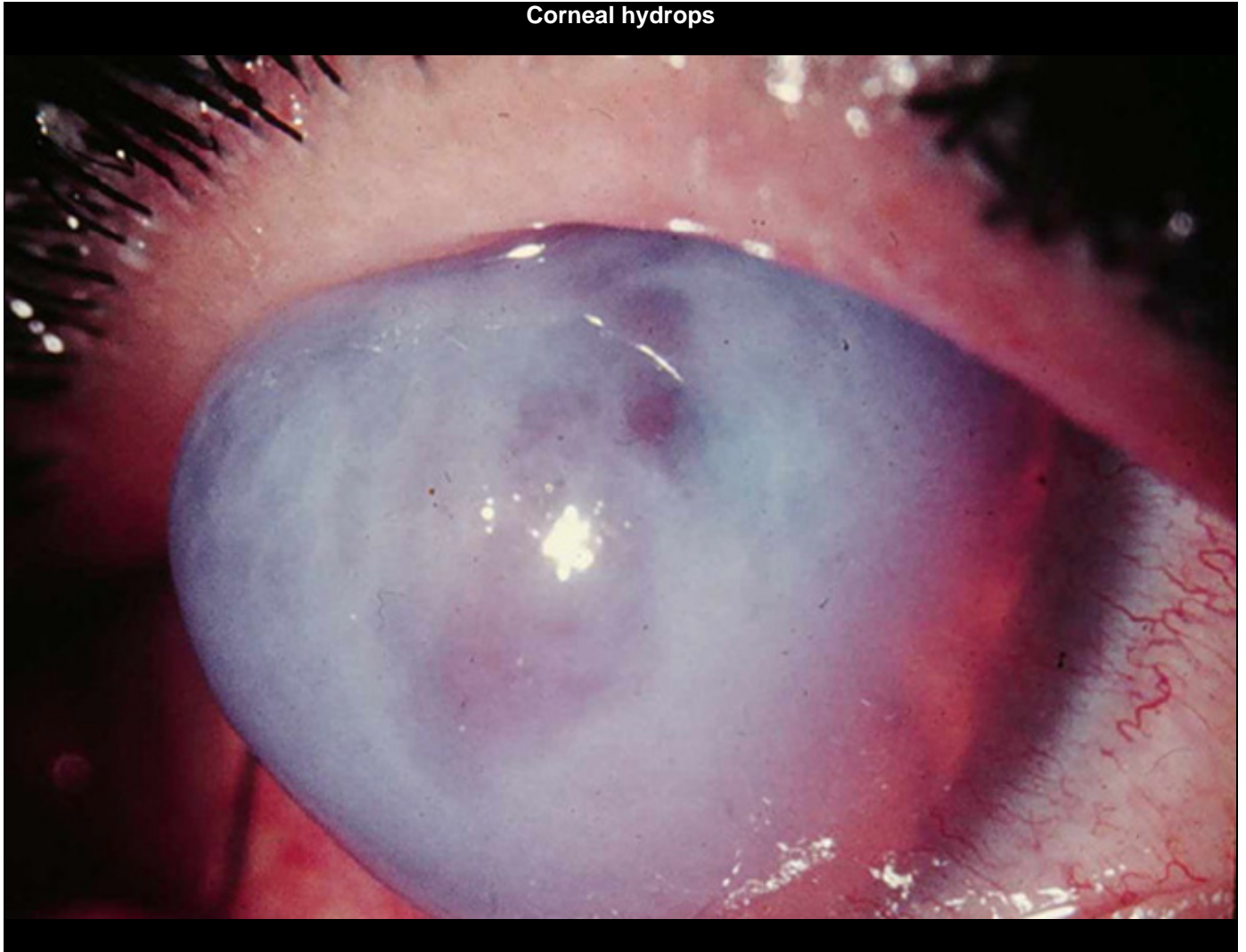

© Copyright [Oculisti OnLine](#)

EyeAtlas

The online Atlas of Ophthalmology

Corneal hydrops

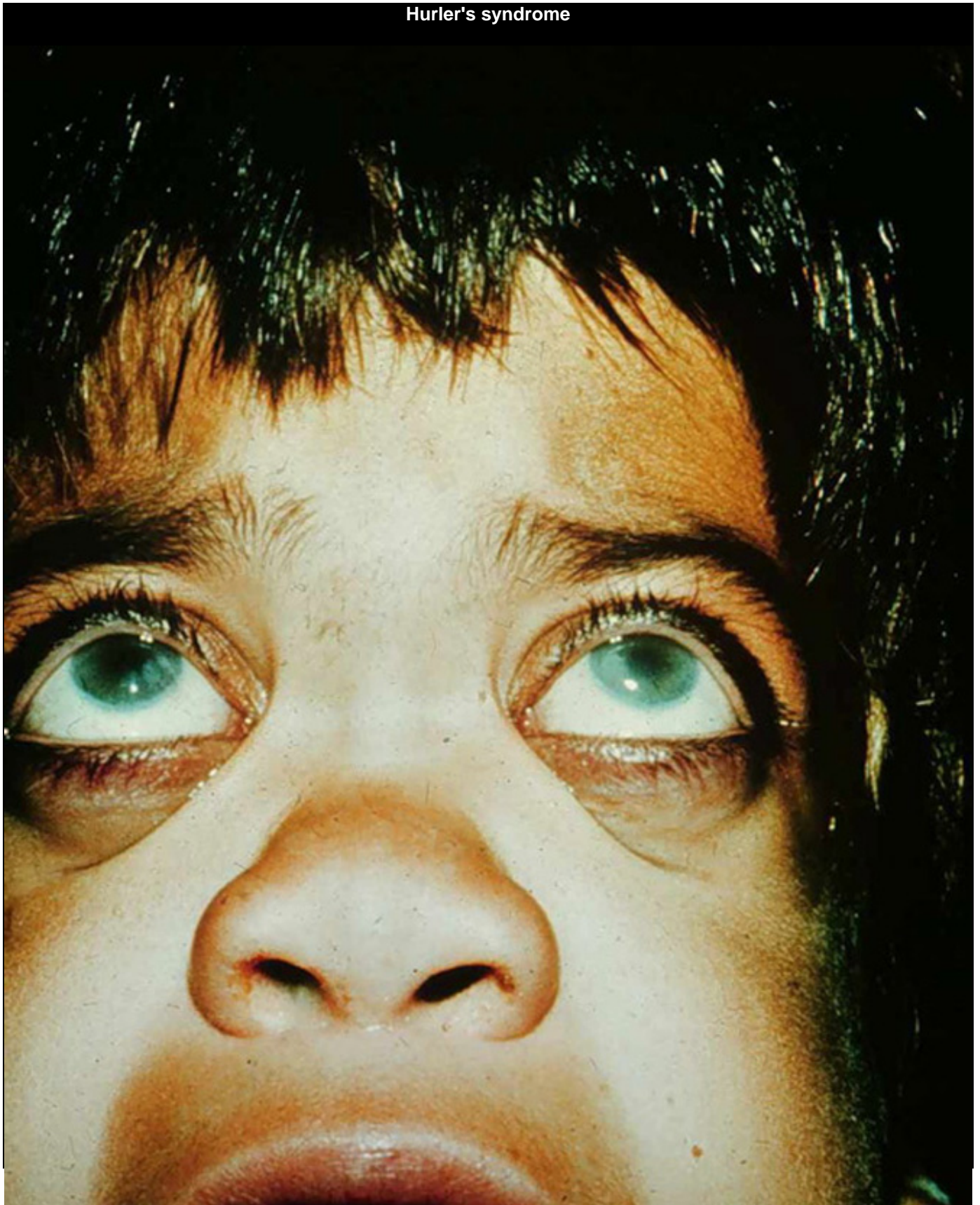


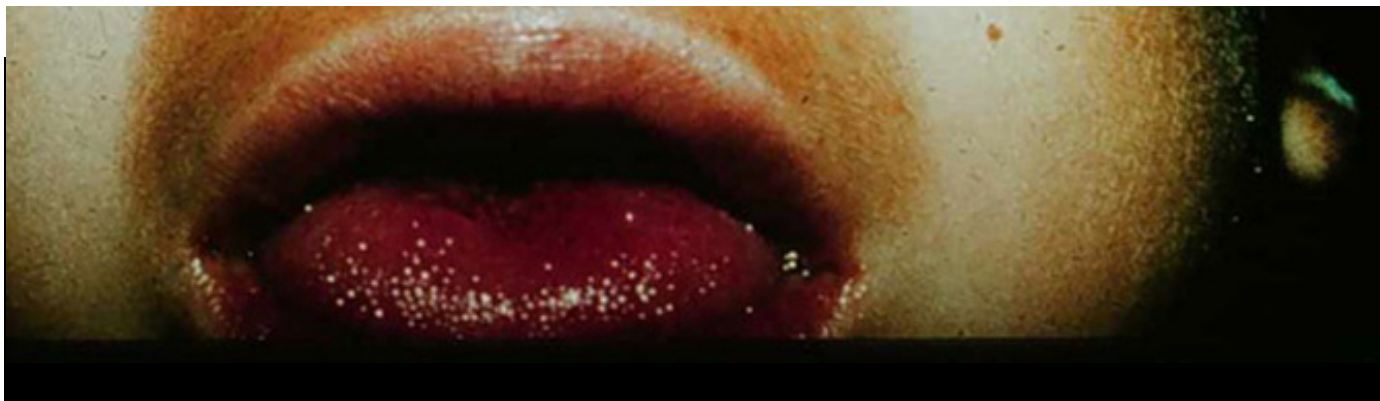© Copyright [Oculisti OnLine](#)

EyeAtlas

The online Atlas of Ophthalmology

Hurler's syndrome



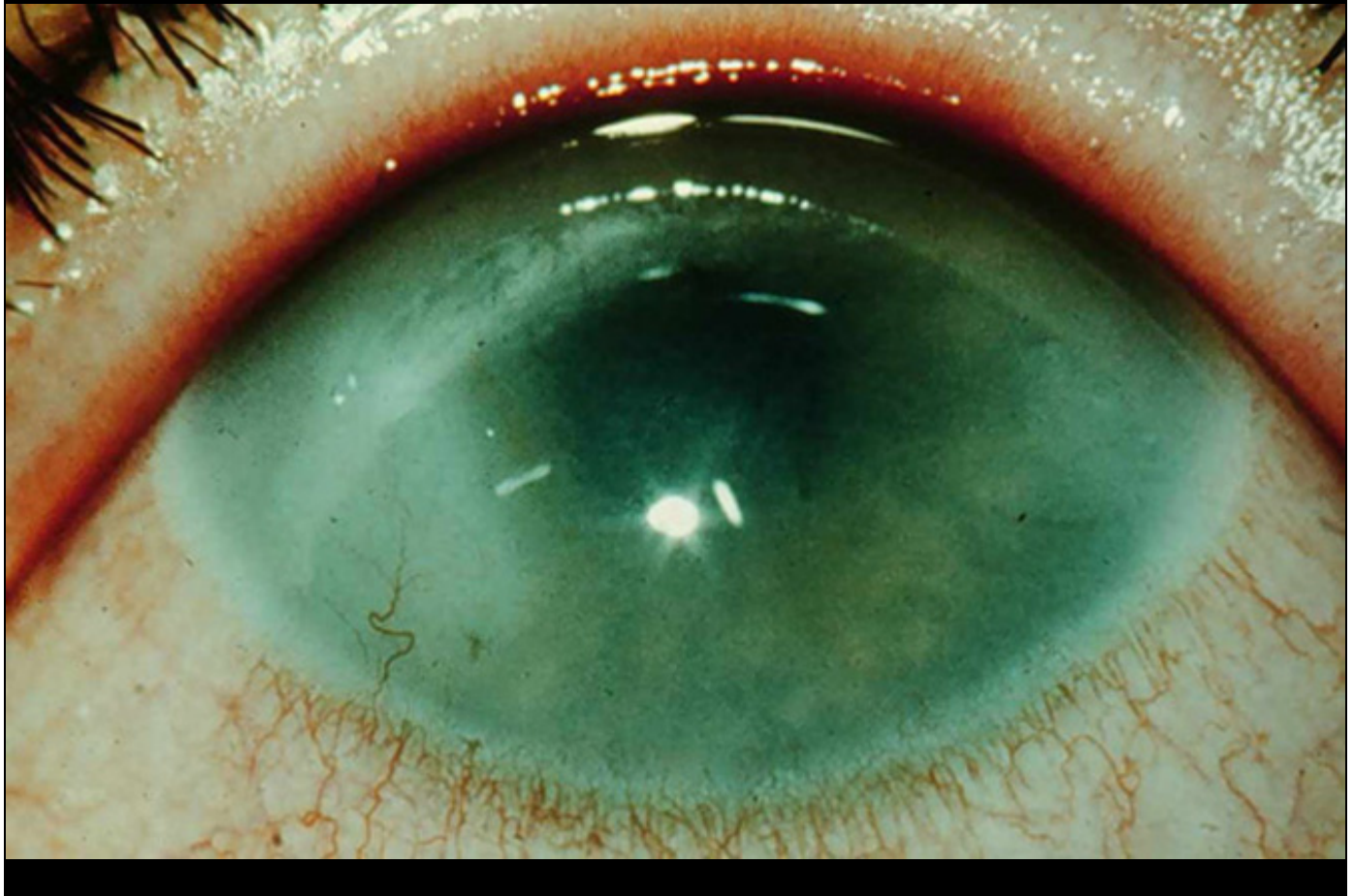


© Copyright [Oculisti OnLine](#)

EyeAtlas

The online Atlas of Ophthalmology

Hurler's syndrome

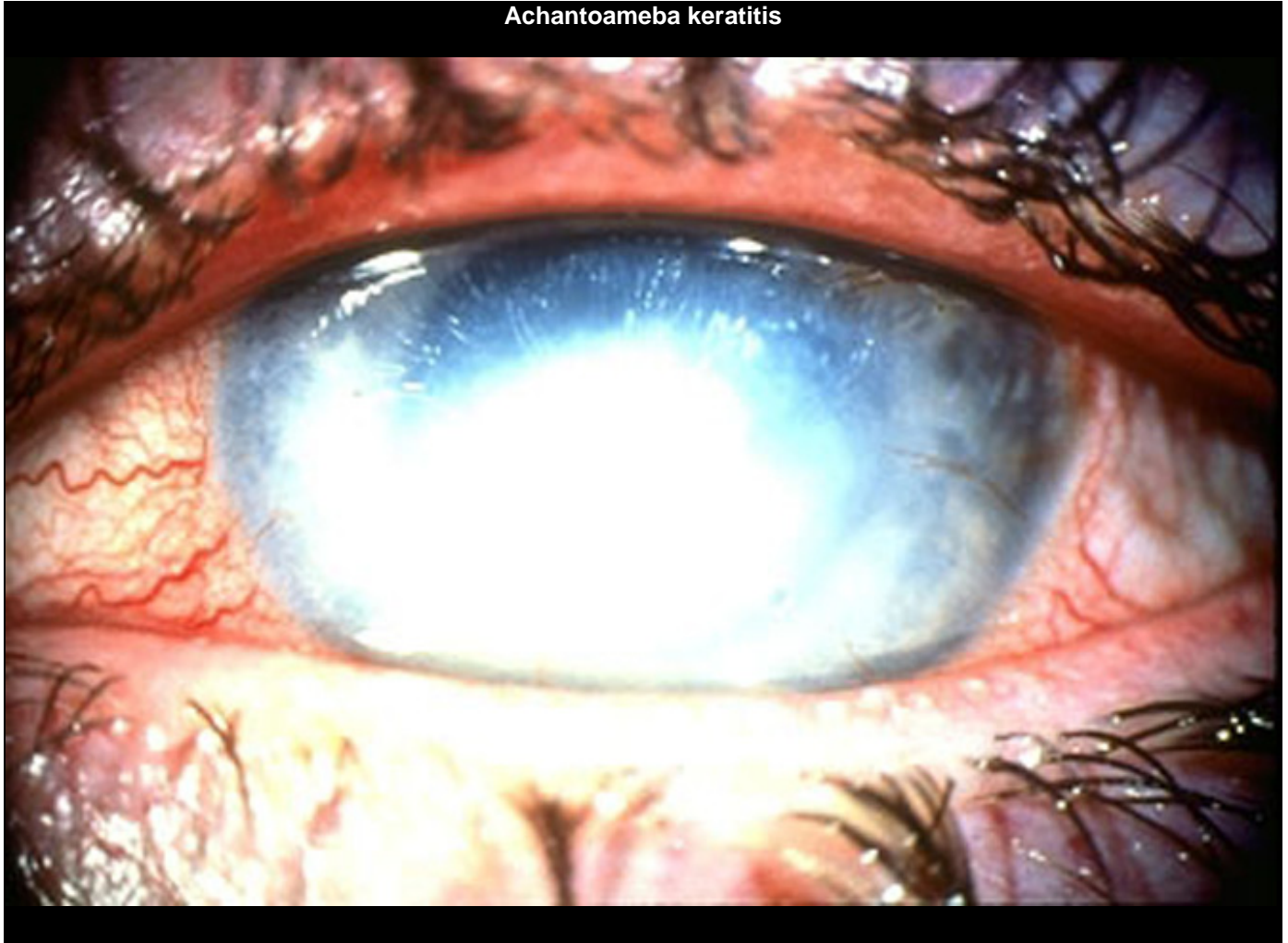

© Copyright [Oculisti OnLine](#)

EyeAtlas

The online Atlas of Ophthalmology

Achantoameba keratitis

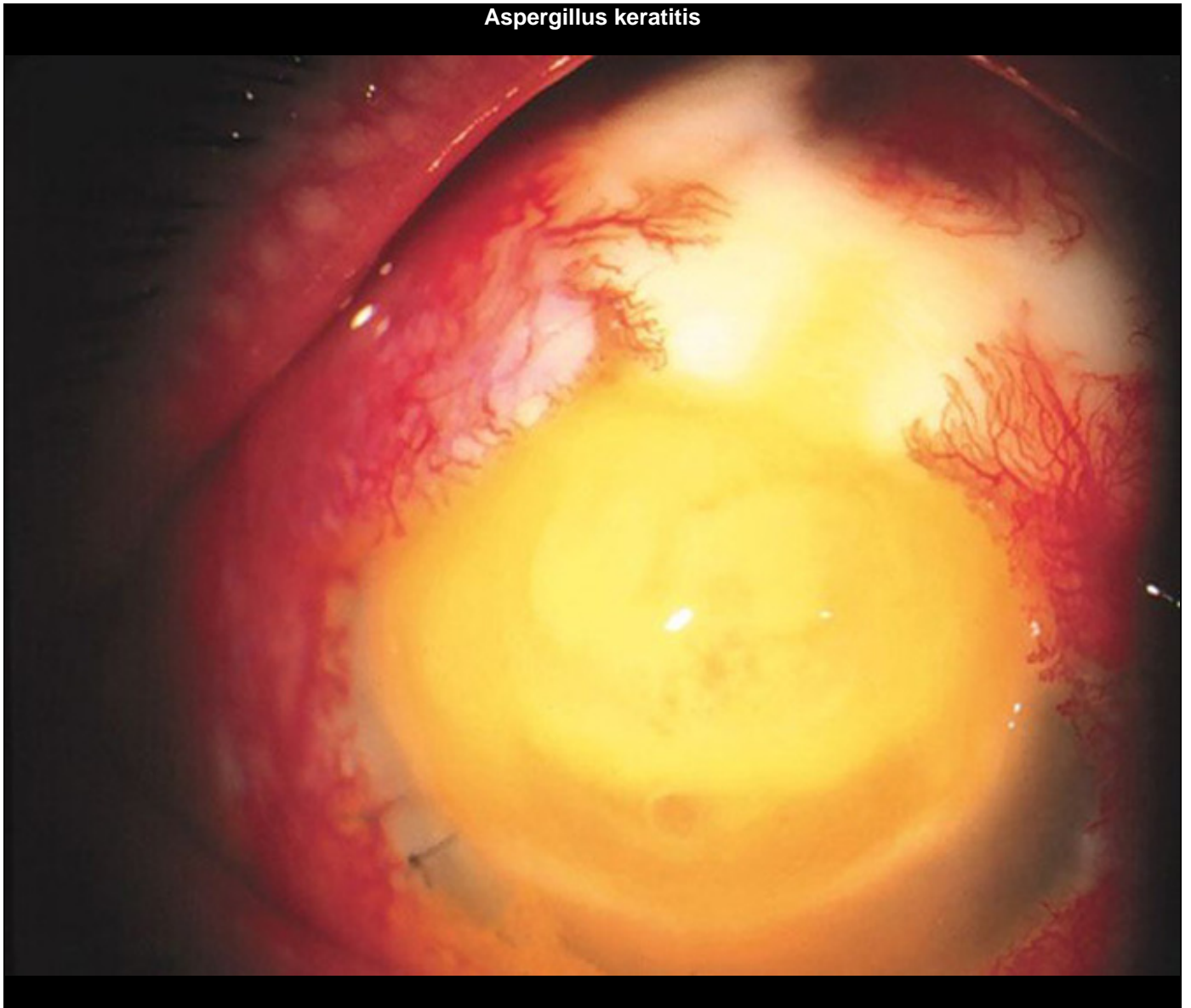

© Copyright [Oculisti OnLine](#)

EyeAtlas

The online Atlas of Ophthalmology

Aspergillus keratitis

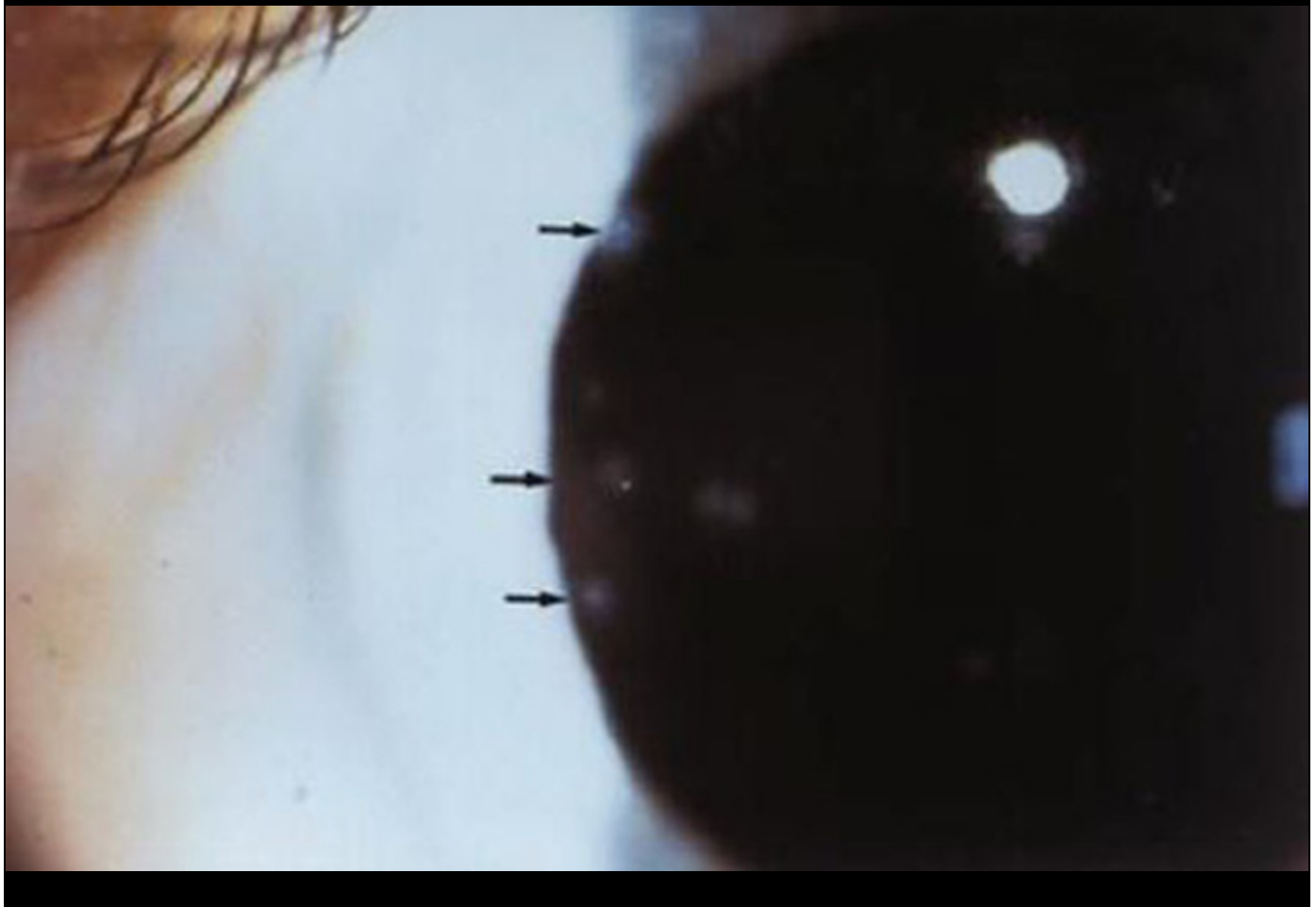


© Copyright [Oculisti OnLine](#)

EyeAtlas

The online Atlas of Ophthalmology

Epidemic keratitis

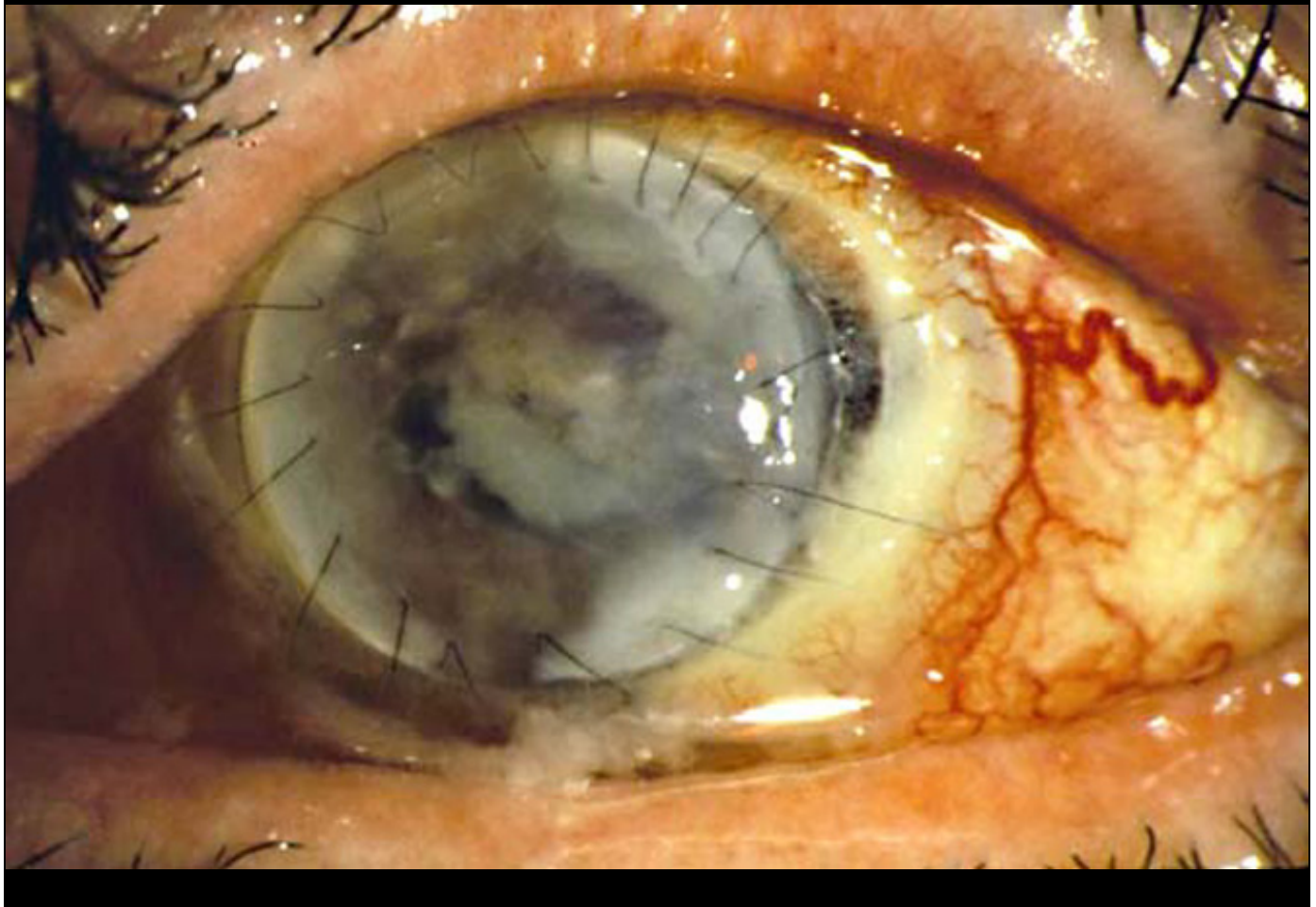


© Copyright [Oculisti OnLine](#)

EyeAtlas

The online Atlas of Ophthalmology

Fungal keratitis after keratoplasty

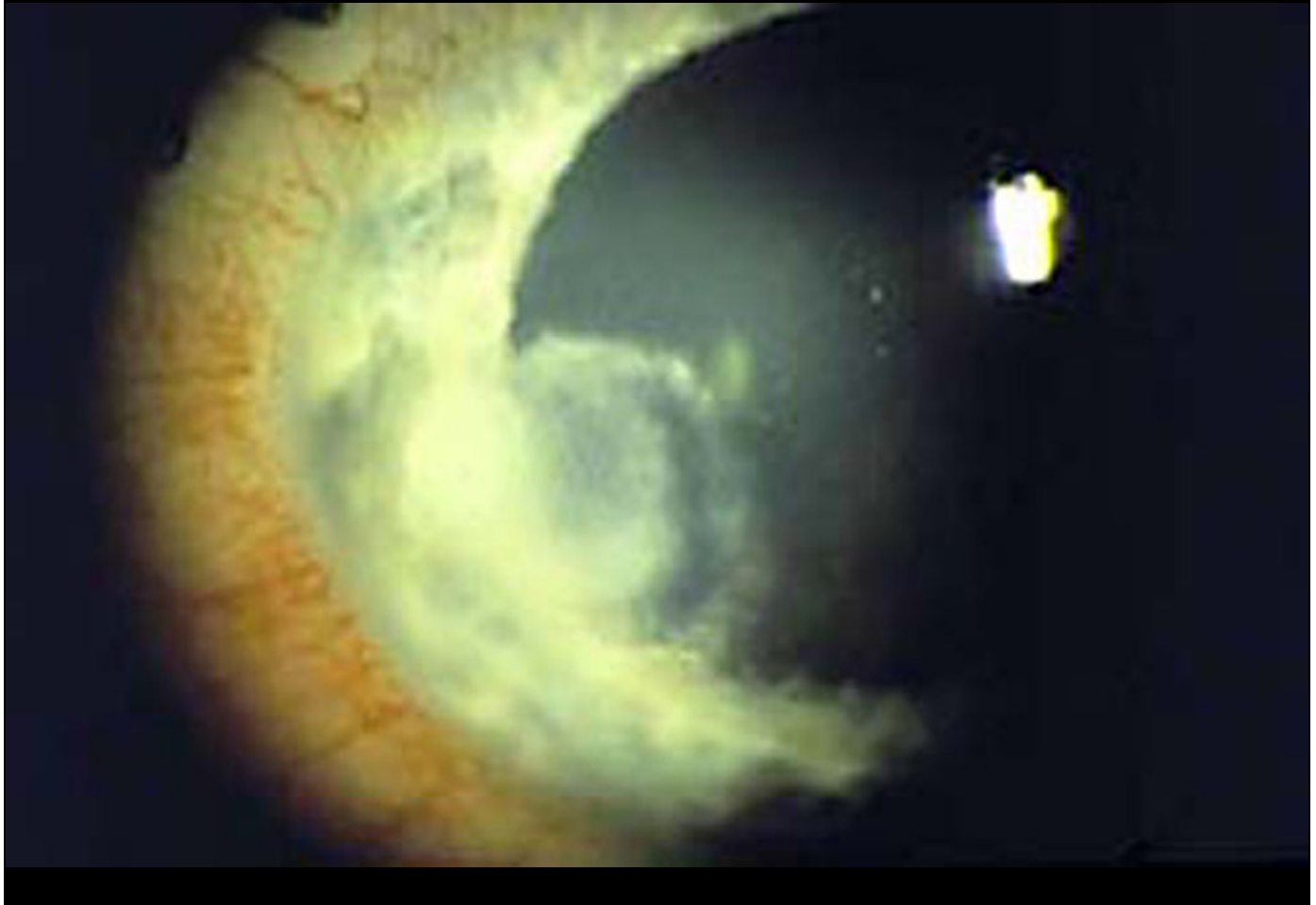


© Copyright [Oculisti OnLine](#)

EyeAtlas

The online Atlas of Ophthalmology

Fungal keratitis

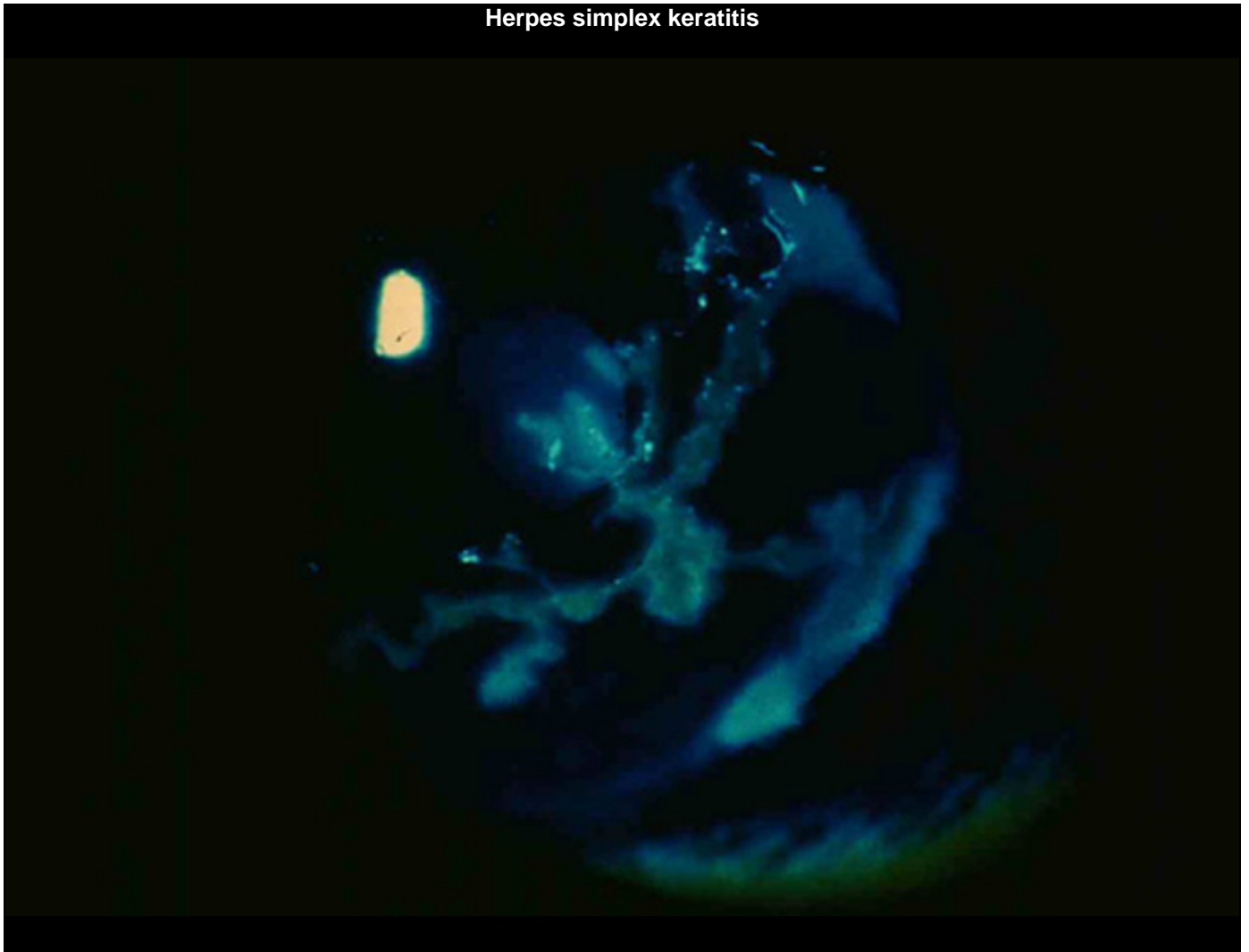


© Copyright [Oculisti OnLine](#)

EyeAtlas

The online Atlas of Ophthalmology

Herpes simplex keratitis

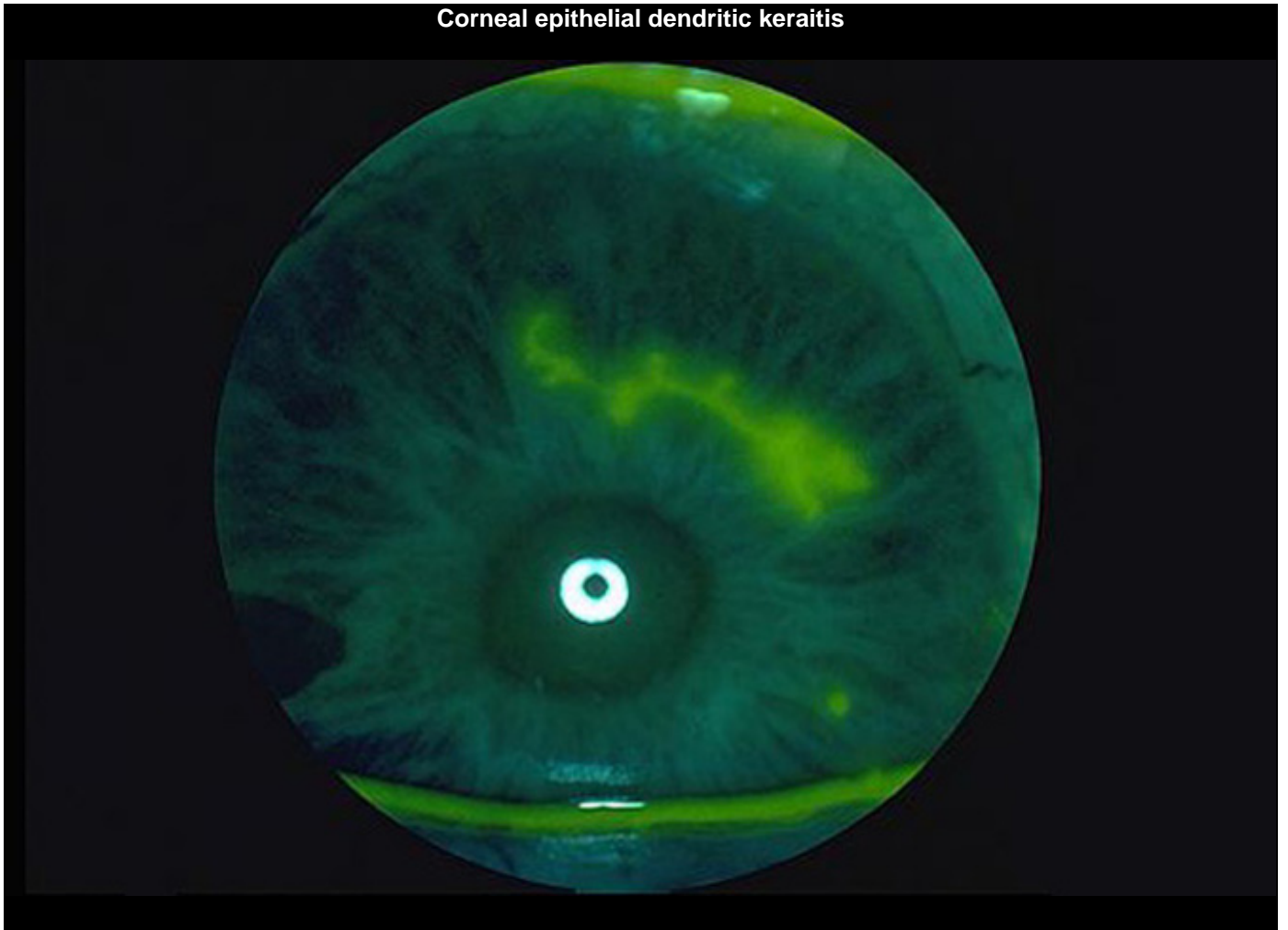


© Copyright [Oculisti OnLine](#)

EyeAtlas

The online Atlas of Ophthalmology

Corneal epithelial dendritic keratitis

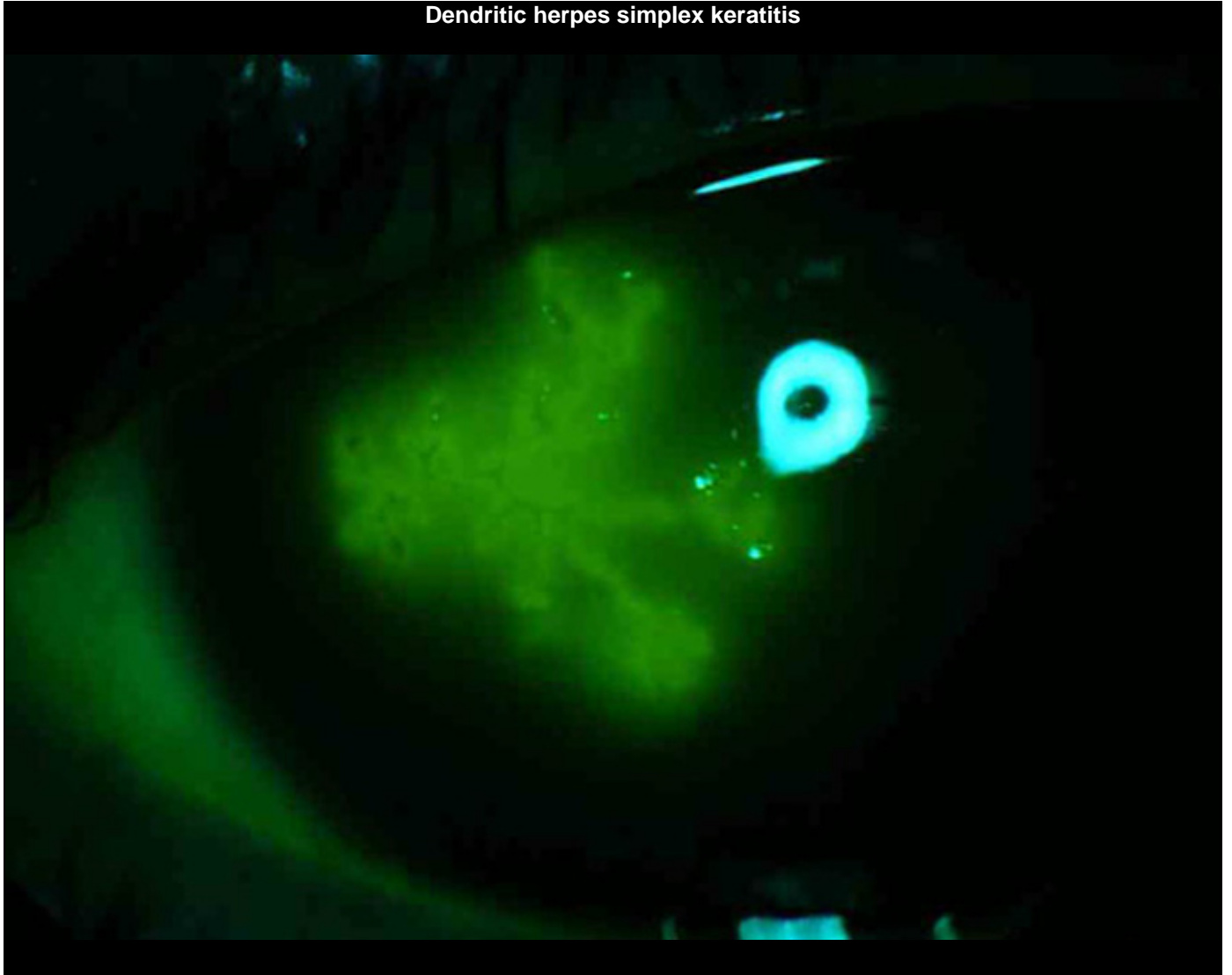


© Copyright [Oculisti OnLine](#)

EyeAtlas

The online Atlas of Ophthalmology

Dendritic herpes simplex keratitis

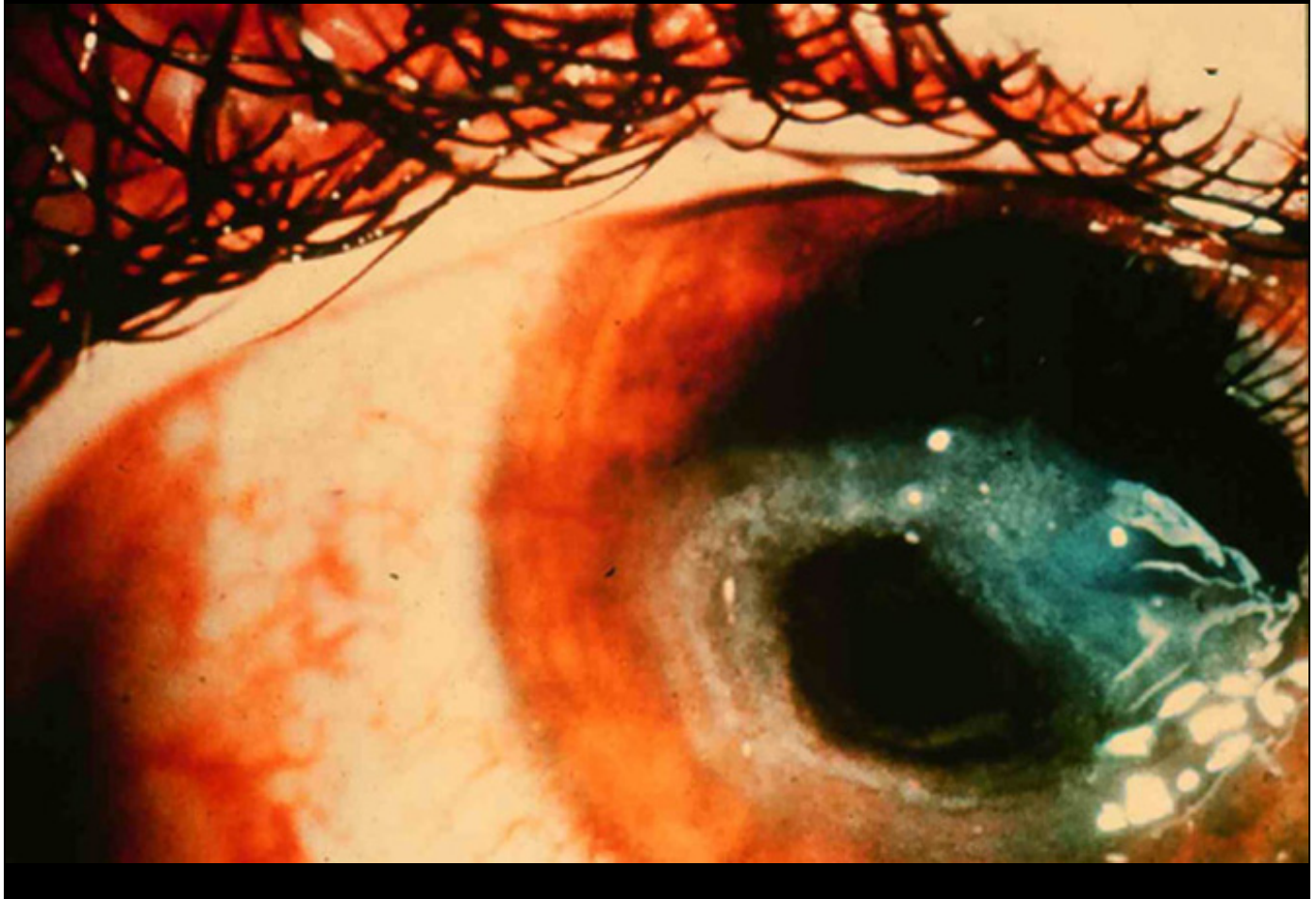


© Copyright [Oculisti OnLine](#)

EyeAtlas

The online Atlas of Ophthalmology

Herpes simplex keratitis and descemetocoele

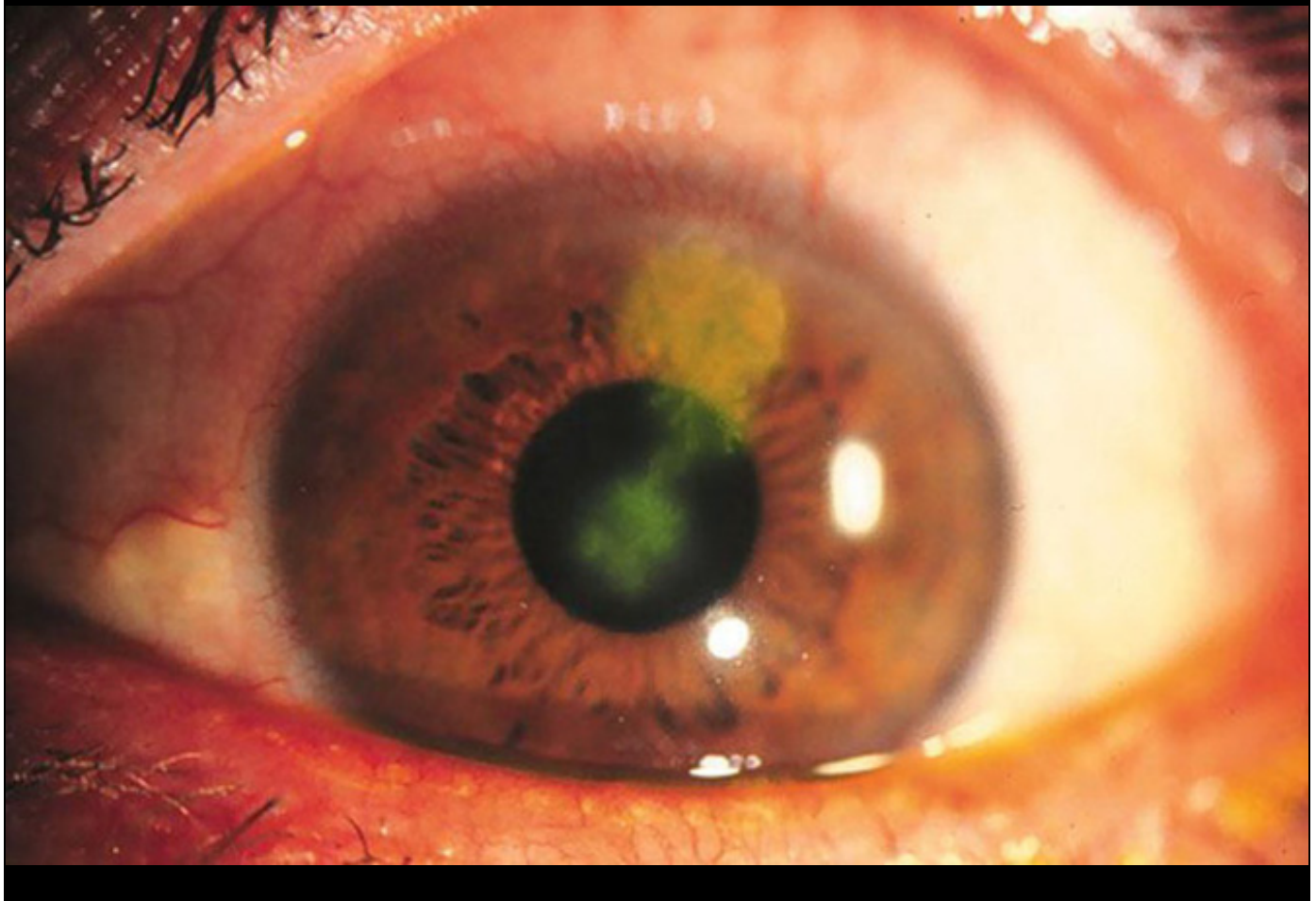


© Copyright [Oculisti OnLine](http://www.eyeatlas.com)

EyeAtlas

The online Atlas of Ophthalmology

Herpes simplex dendritic keratitis

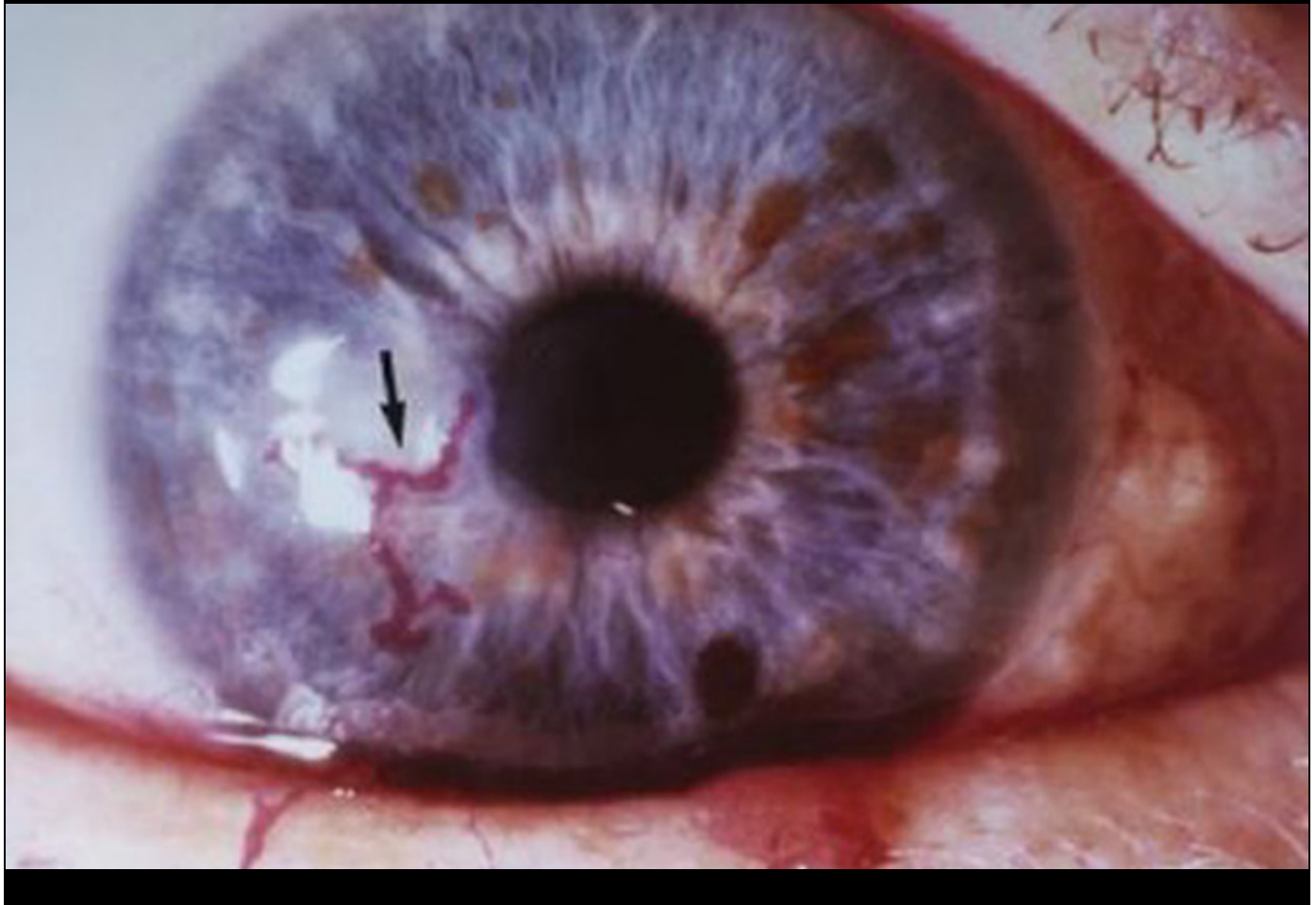


© Copyright [Oculisti OnLine](#)

EyeAtlas

The online Atlas of Ophthalmology

Herpes simplex dendritic keratitis



© Copyright [Oculisti OnLine](#)

EyeAtlas

The online Atlas of Ophthalmology

Keratitis: Serratia Marcescens

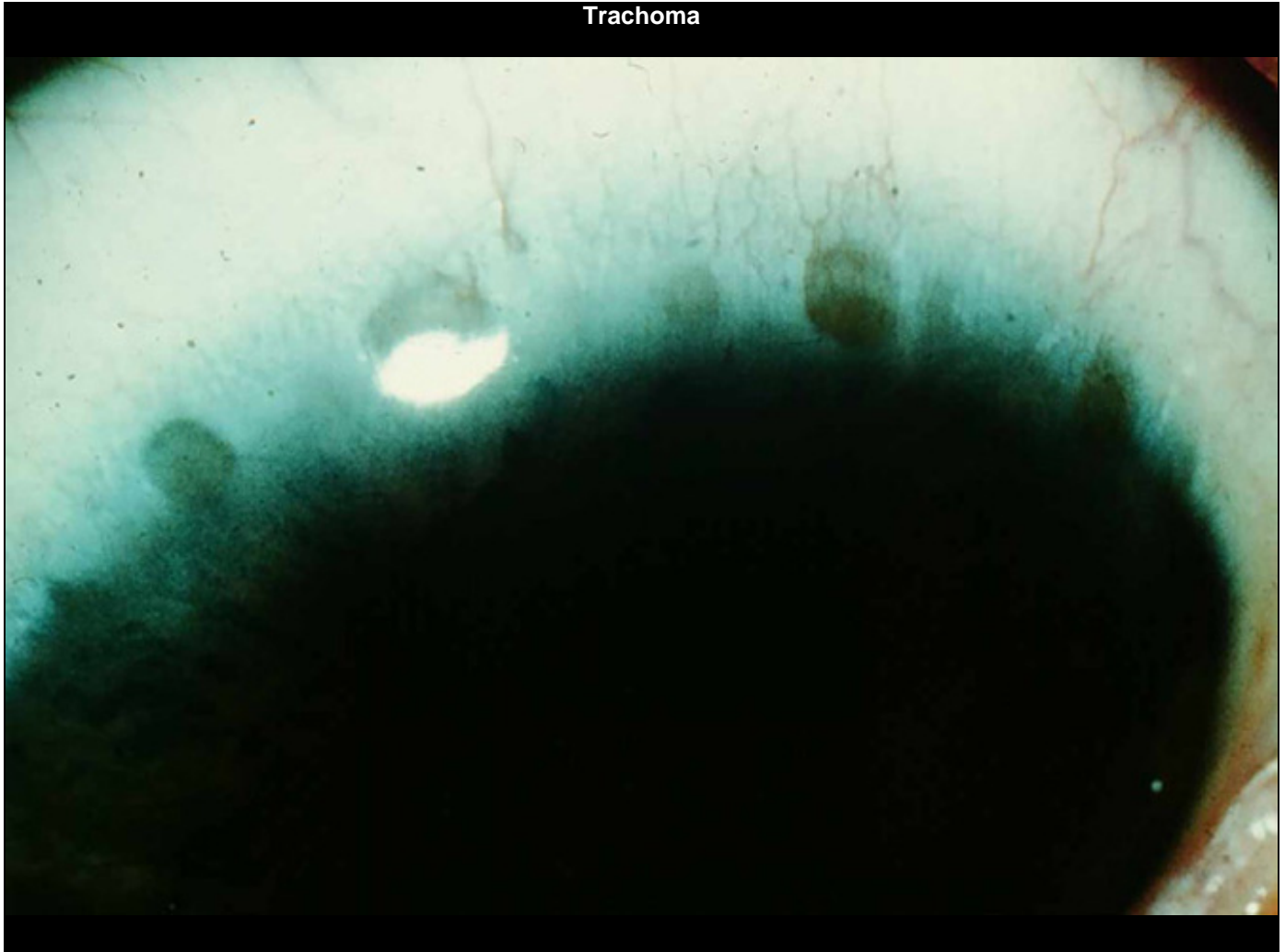


© Copyright [Oculisti OnLine](http://www.eyeatlas.com)

EyeAtlas

The online Atlas of Ophthalmology

Trachoma

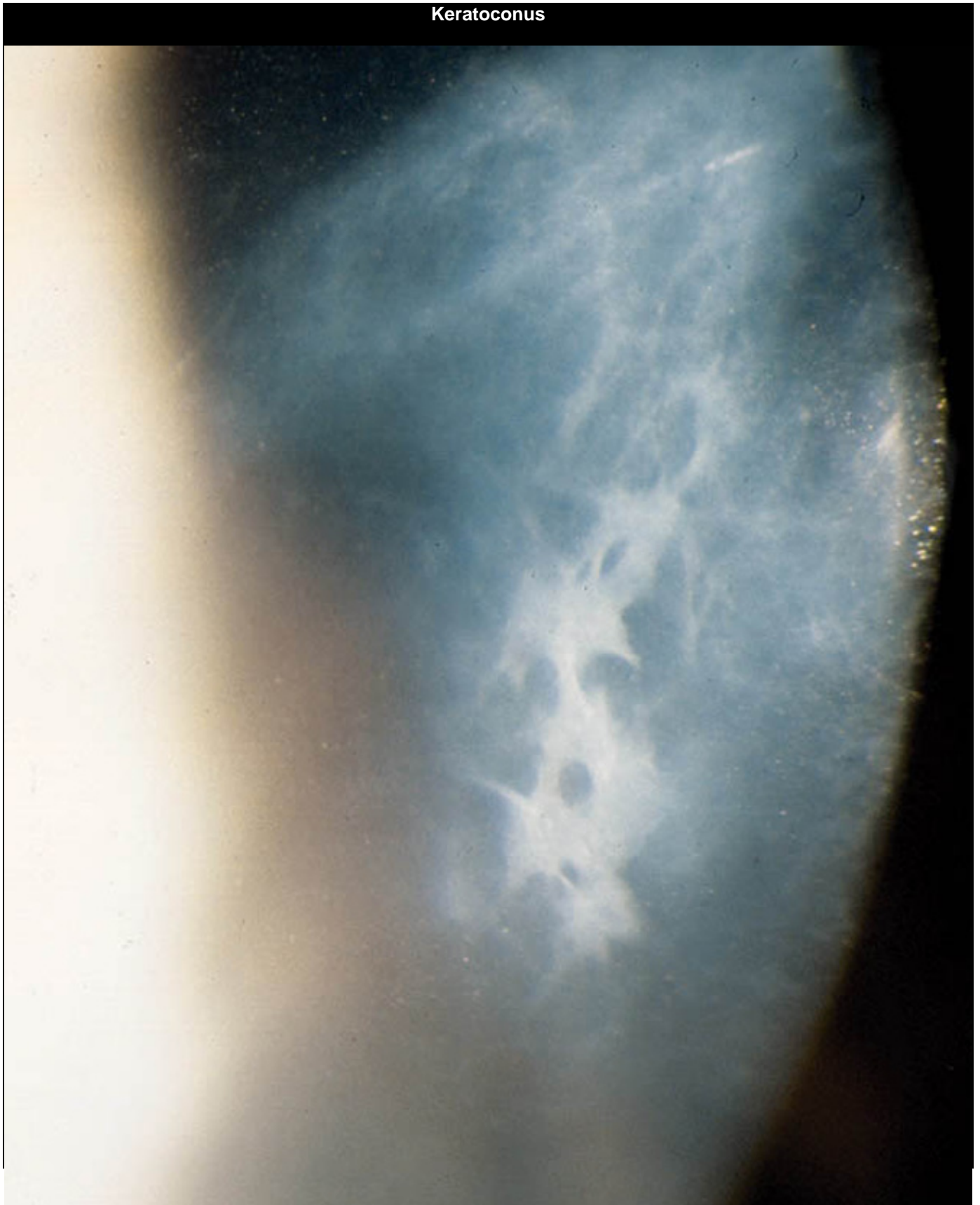


© Copyright [Oculisti OnLine](http://www.eyeatlas.com)

Eyeatlas

The online Atlas of Ophthalmology

Keratoconus



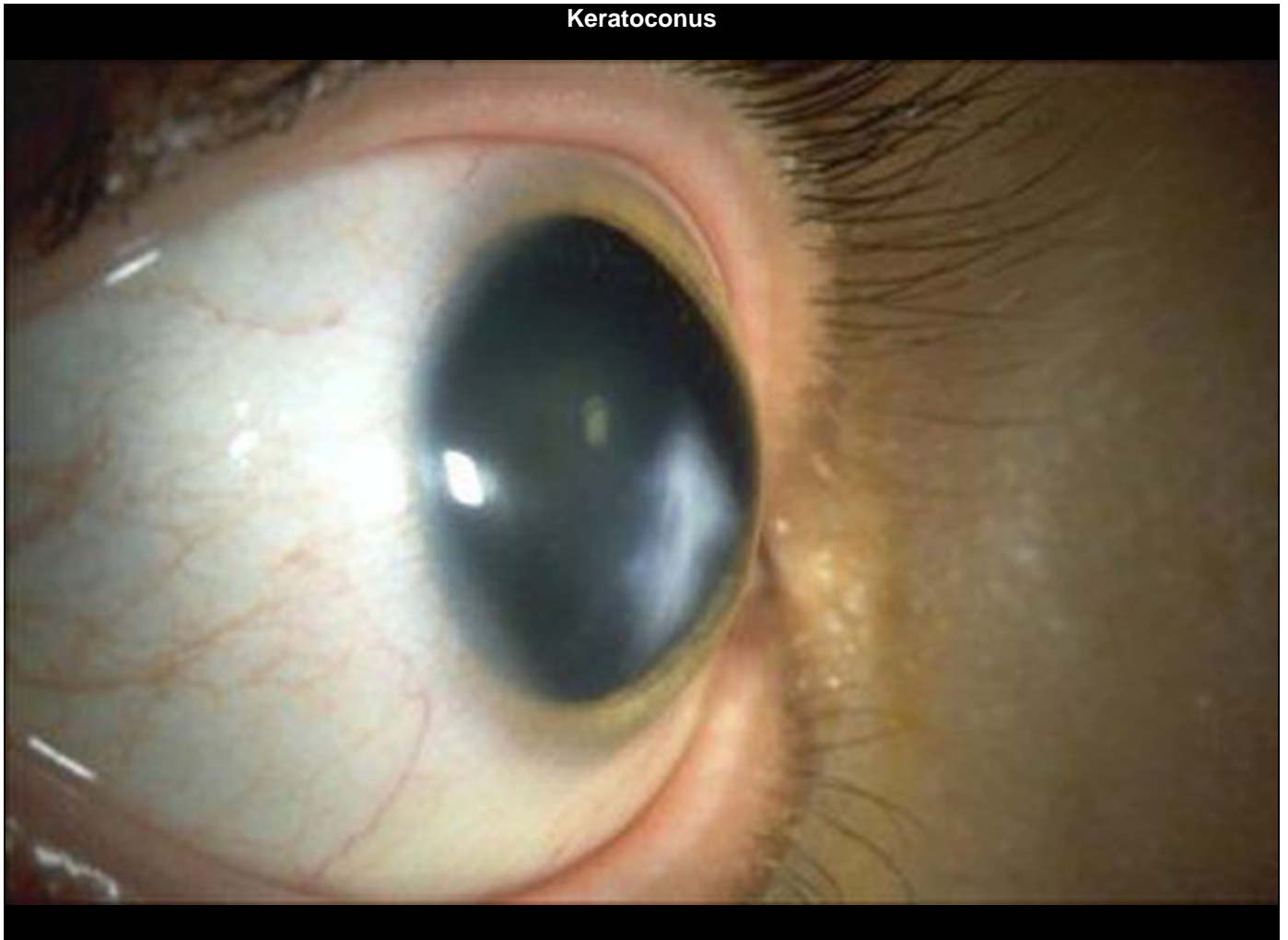

© Copyright [Oculisti OnLine](#)

EyeAtlas

The online Atlas of Ophthalmology

Keratoconus

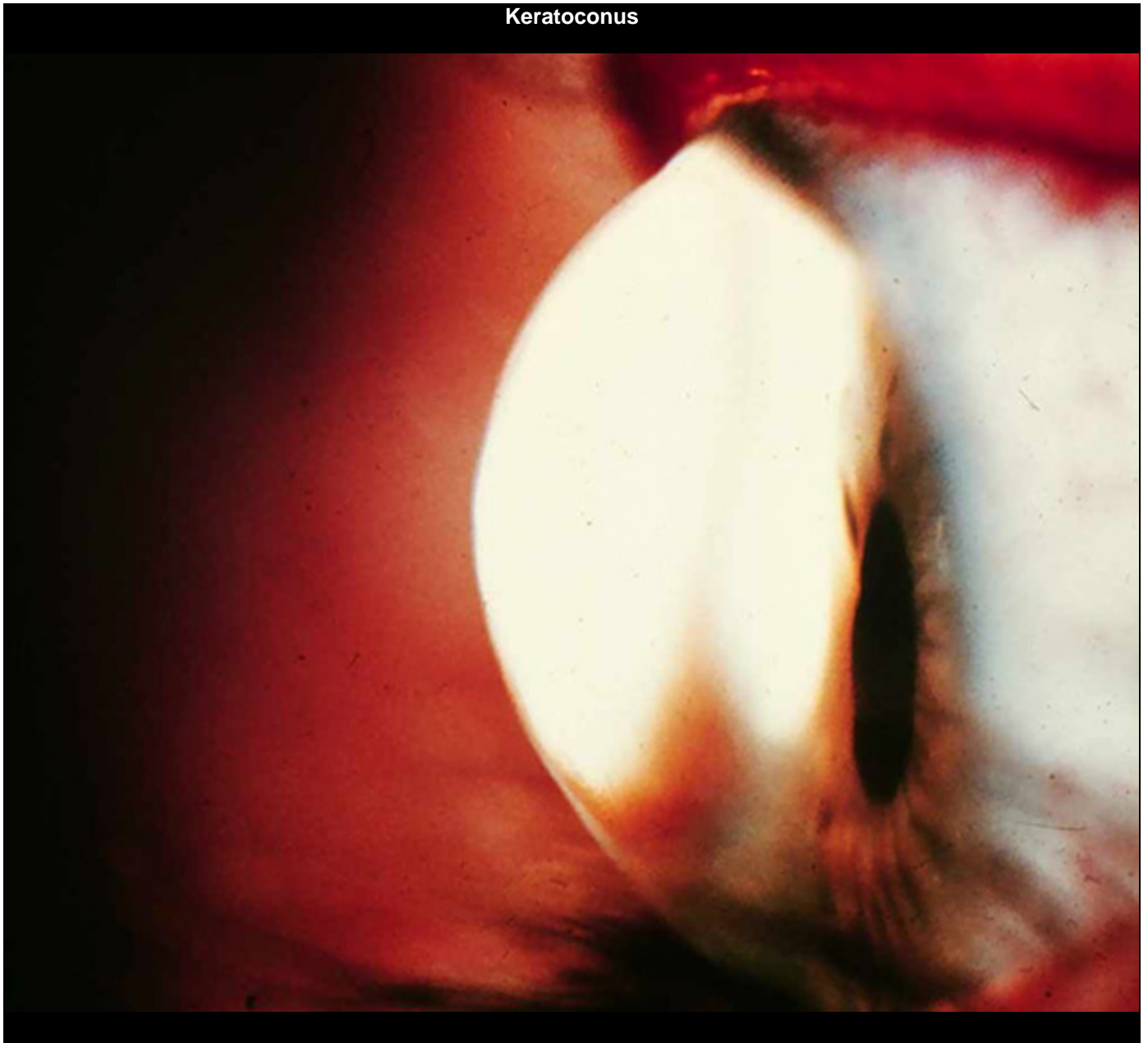

© Copyright [Oculisti OnLine](#)

EyeAtlas

The online Atlas of Ophthalmology

Keratoconus



© Copyright [Oculisti OnLine](#)

EyeAtlas

The online Atlas of Ophthalmology

Keratoconus: acute hydrops

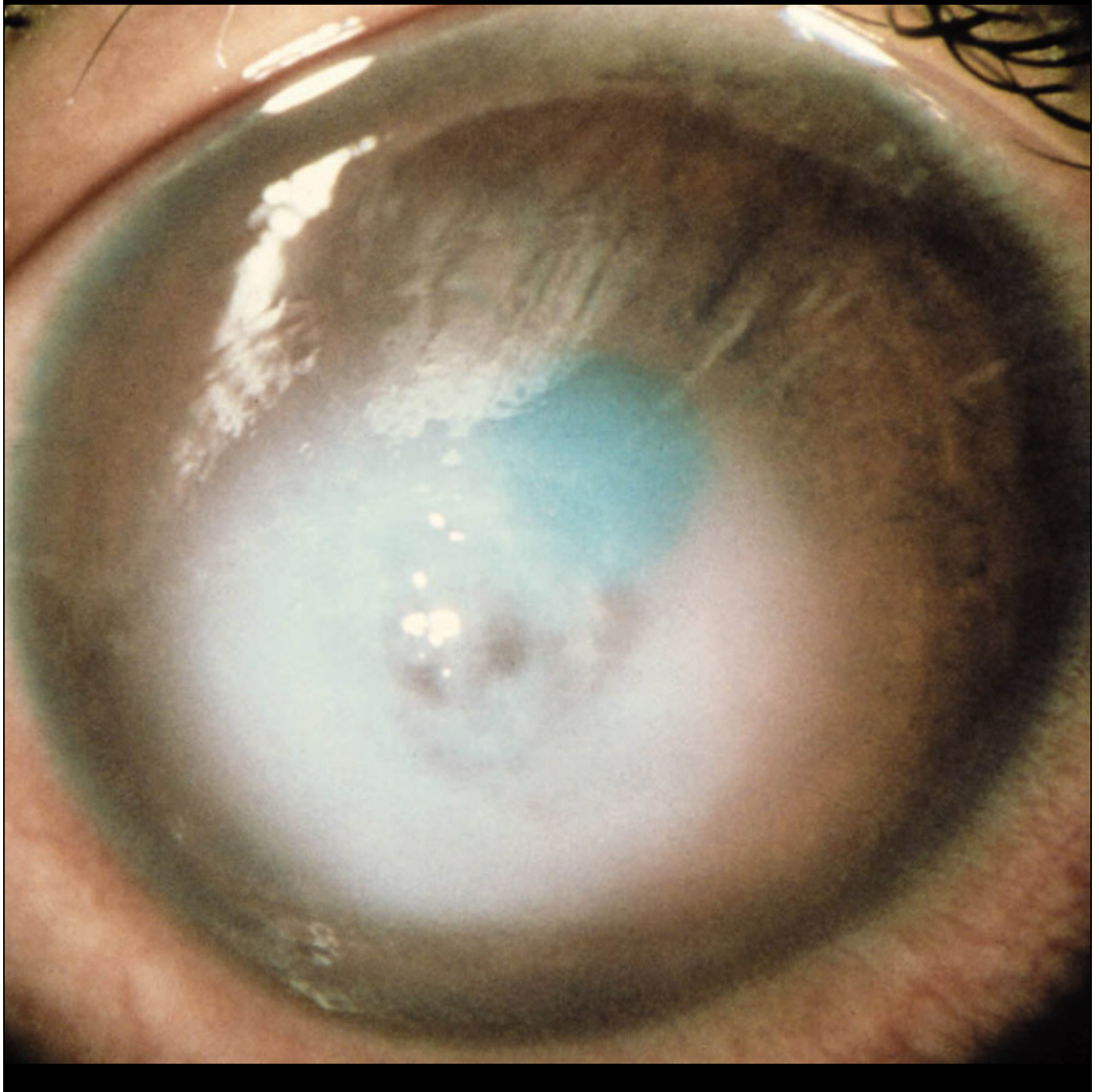


© Copyright [Oculisti OnLine](http://www.eyeatlas.com)

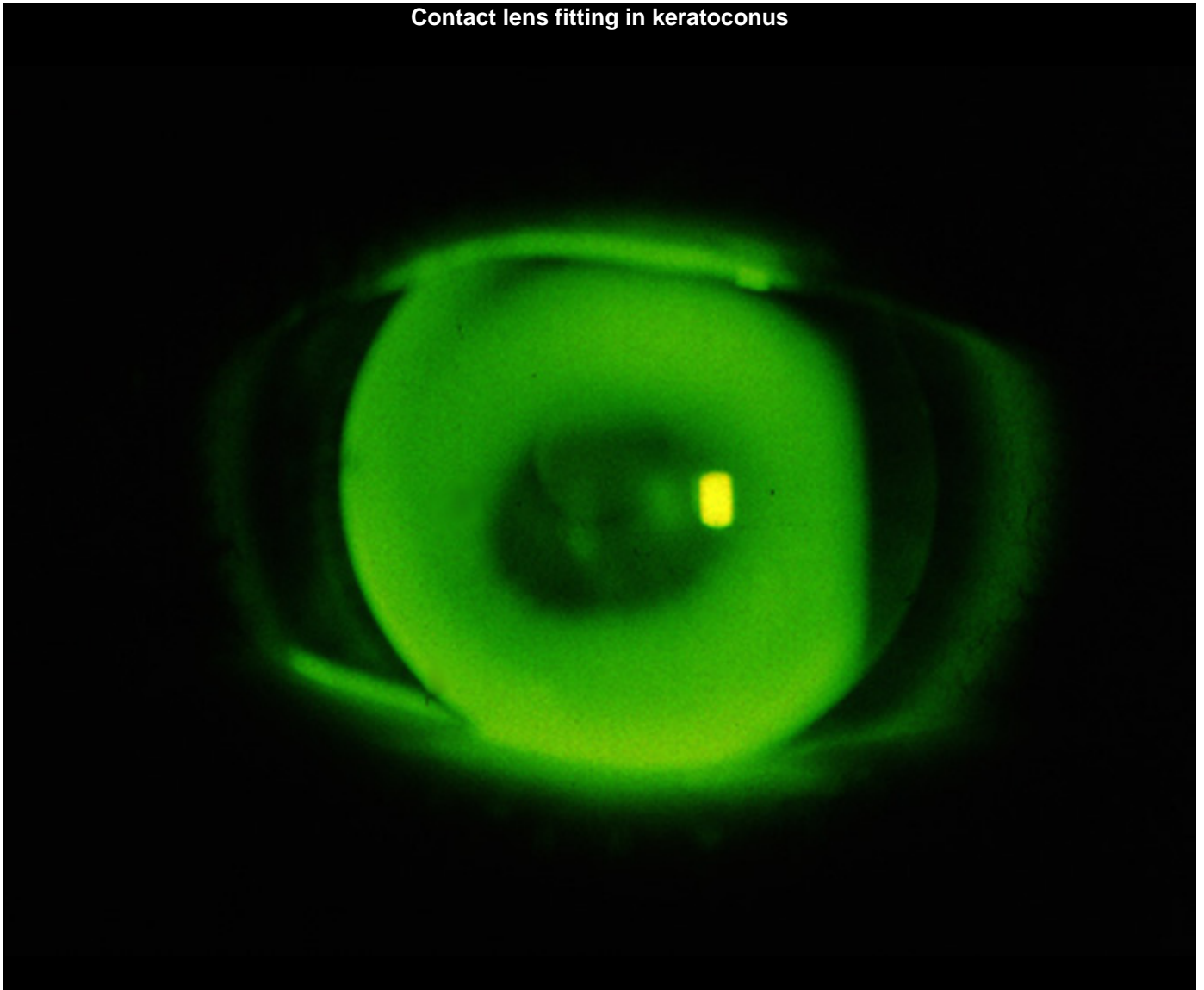
Eyeatlas

The online Atlas of Ophthalmology

Keratoconus: apex syndrome



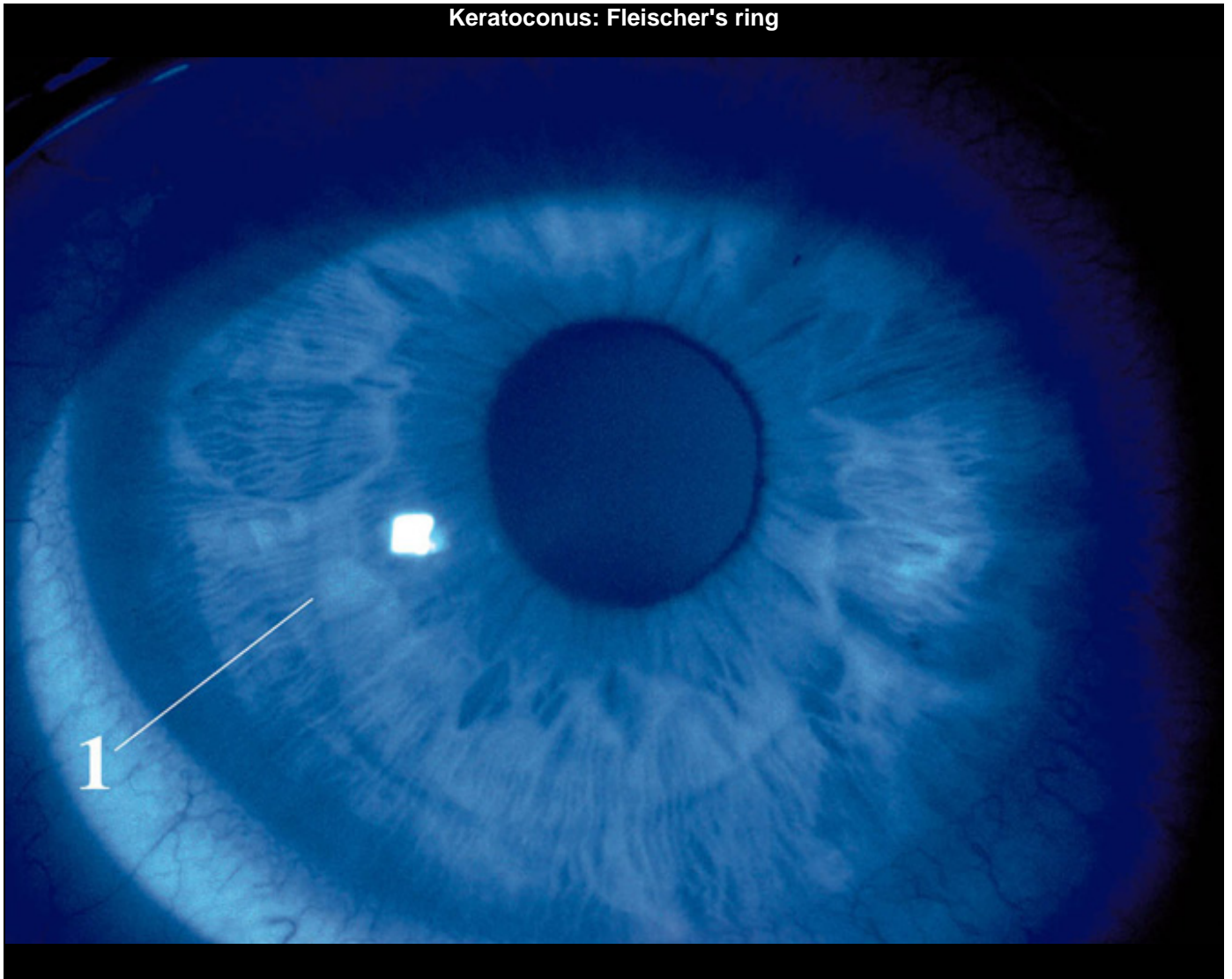
Contact lens fitting in keratoconus



EyeAtlas

The online Atlas of Ophthalmology

Keratoconus: Fleischer's ring

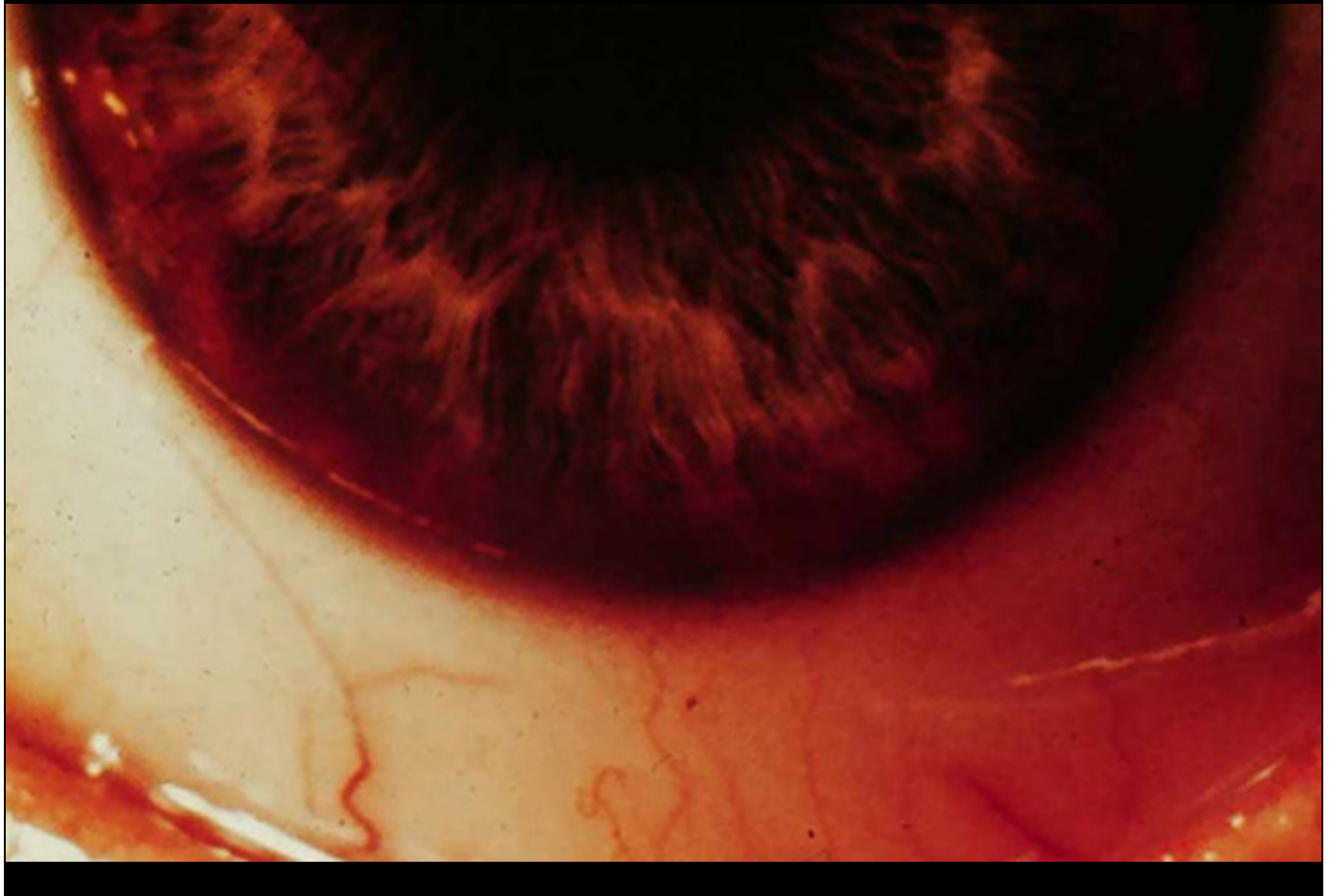

© Copyright [Oculisti OnLine](#)

EyeAtlas

The online Atlas of Ophthalmology

Keratoconus: Fleischer's ring

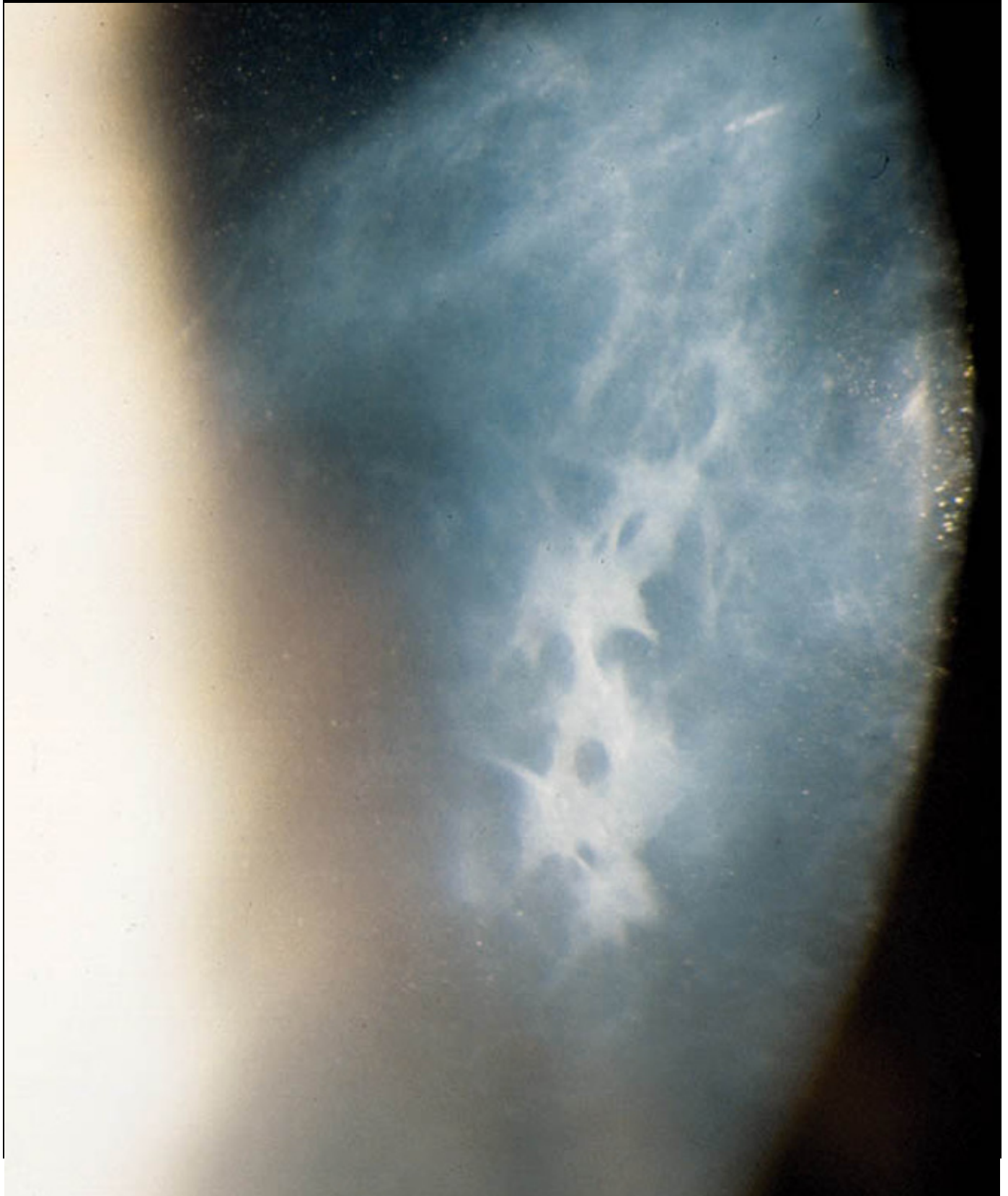



© Copyright [Oculisti OnLine](http://www.eyeatlas.com)

Eyeatlas

The online Atlas of Ophthalmology

Keratoconus: Munson's sign



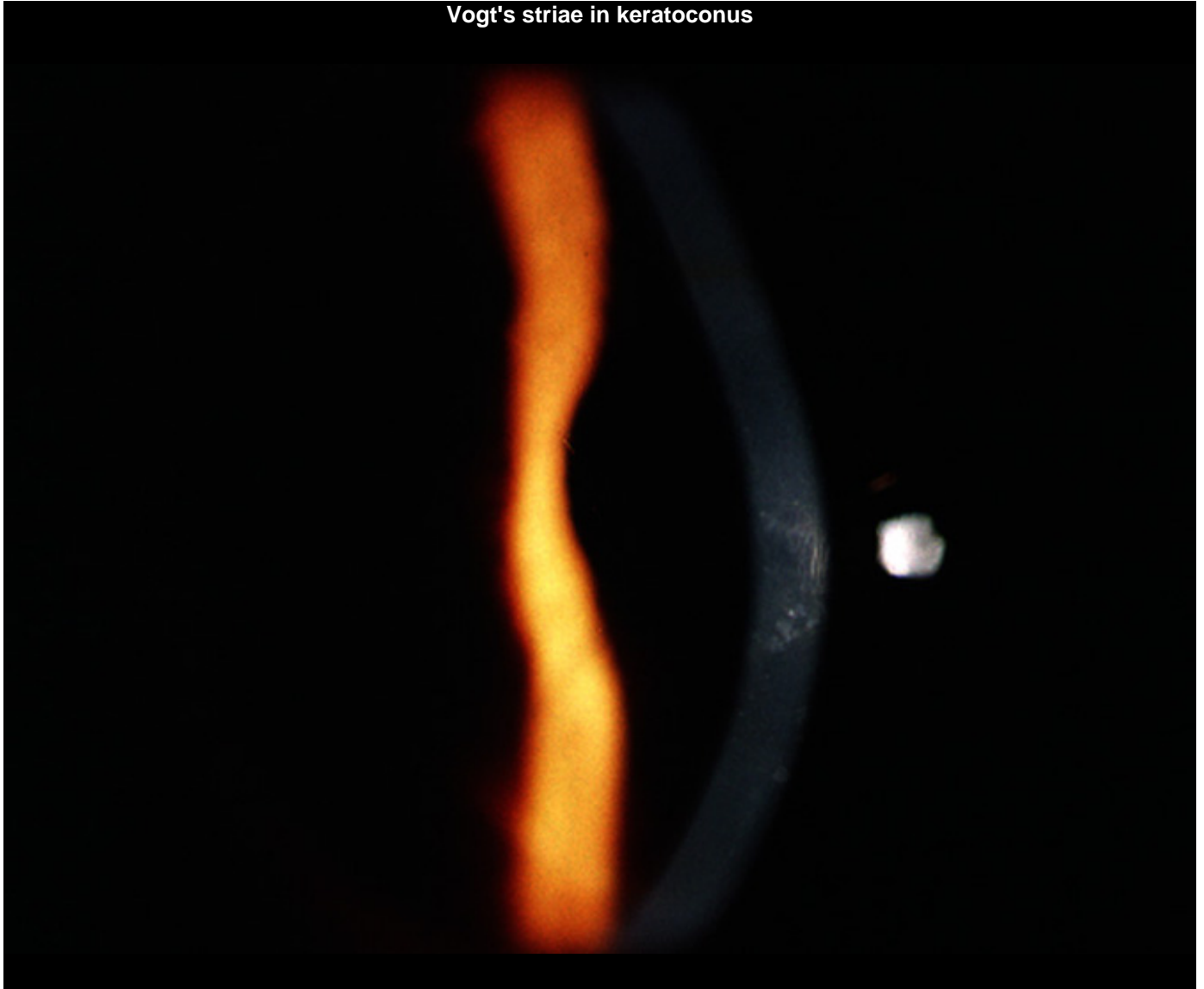

© Copyright [Oculisti OnLine](#)

Eyeatlas

The online Atlas of Ophthalmology

Vogt's striae in keratoconus

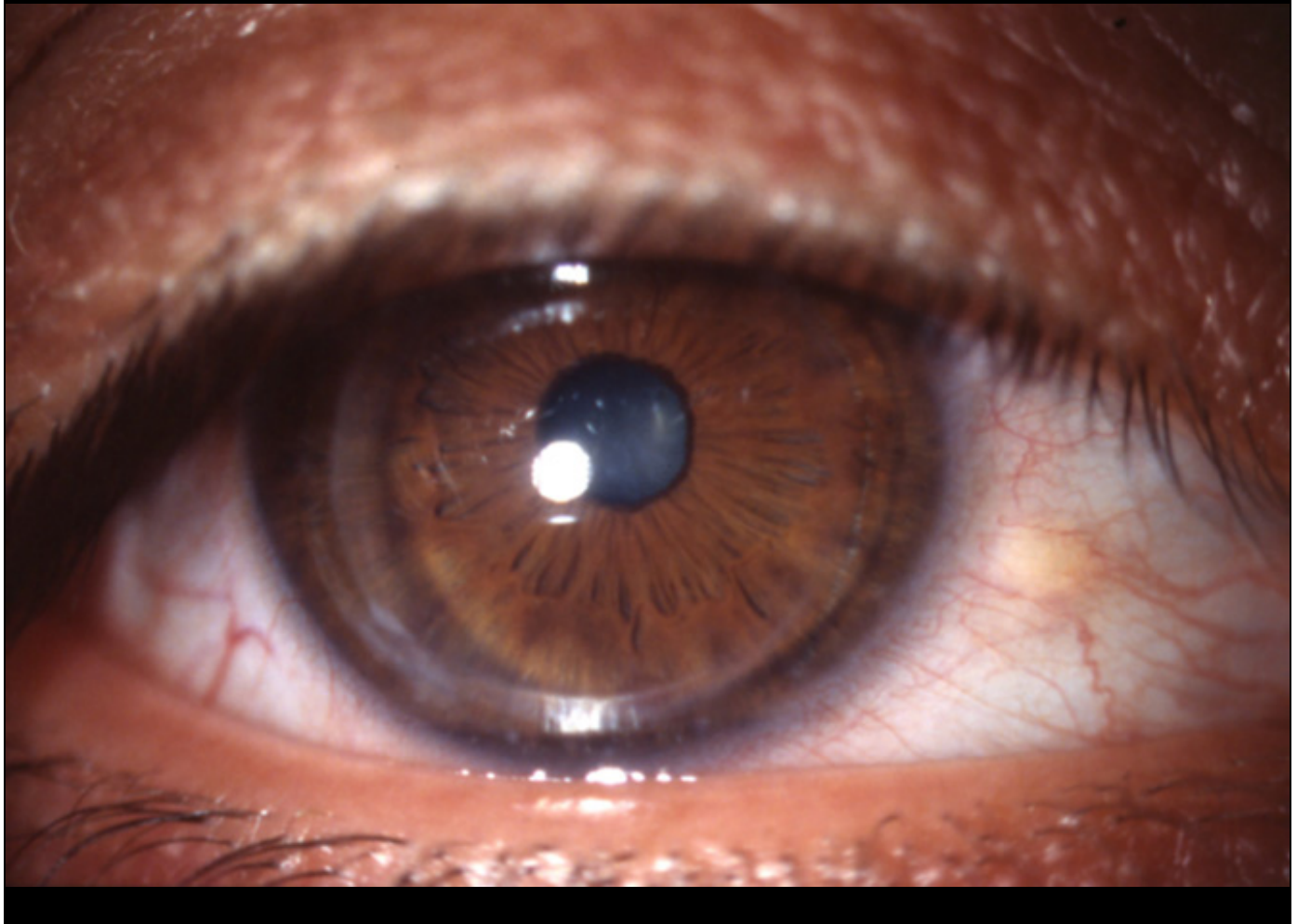


© Copyright [Oculisti OnLine](http://www.eyeatlas.com)

EyeAtlas

The online Atlas of Ophthalmology

Keratoplasty after suture removal

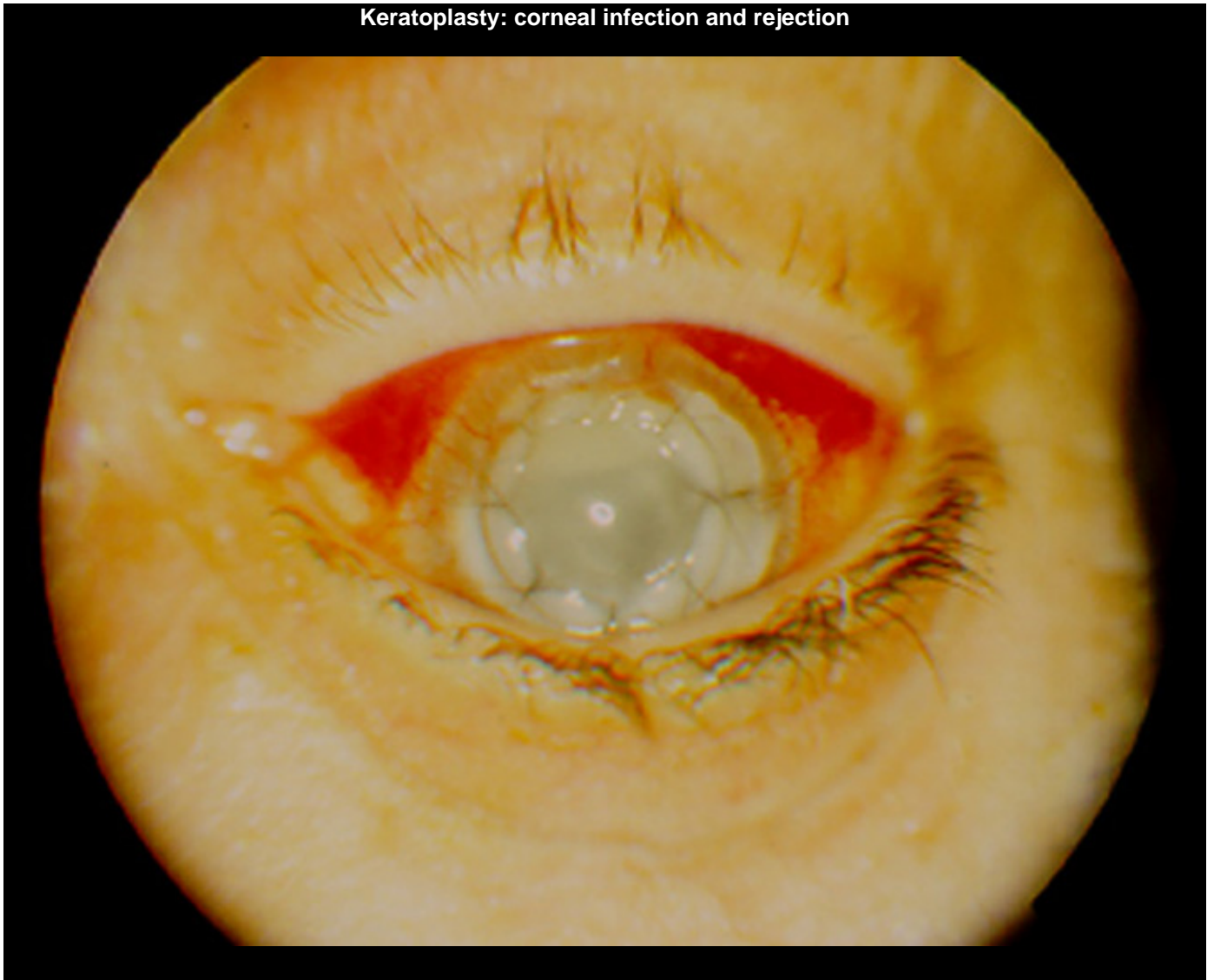

© Copyright [Oculisti OnLine](#)

EyeAtlas

The online Atlas of Ophthalmology

Keratoplasty: corneal infection and rejection

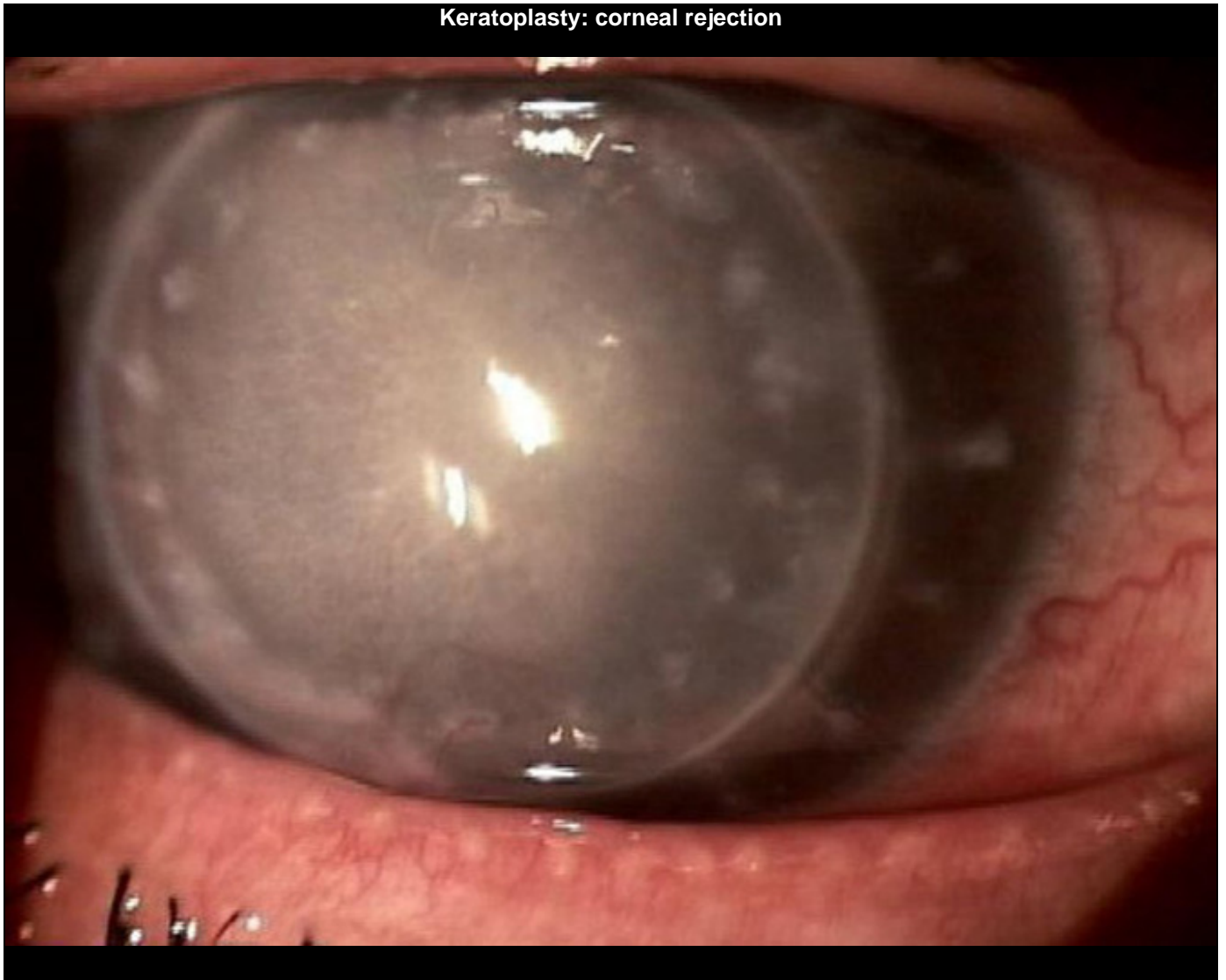

© Copyright [Oculisti OnLine](http://www.eyeatlas.com)

EyeAtlas

The online Atlas of Ophthalmology

Keratoplasty: corneal rejection

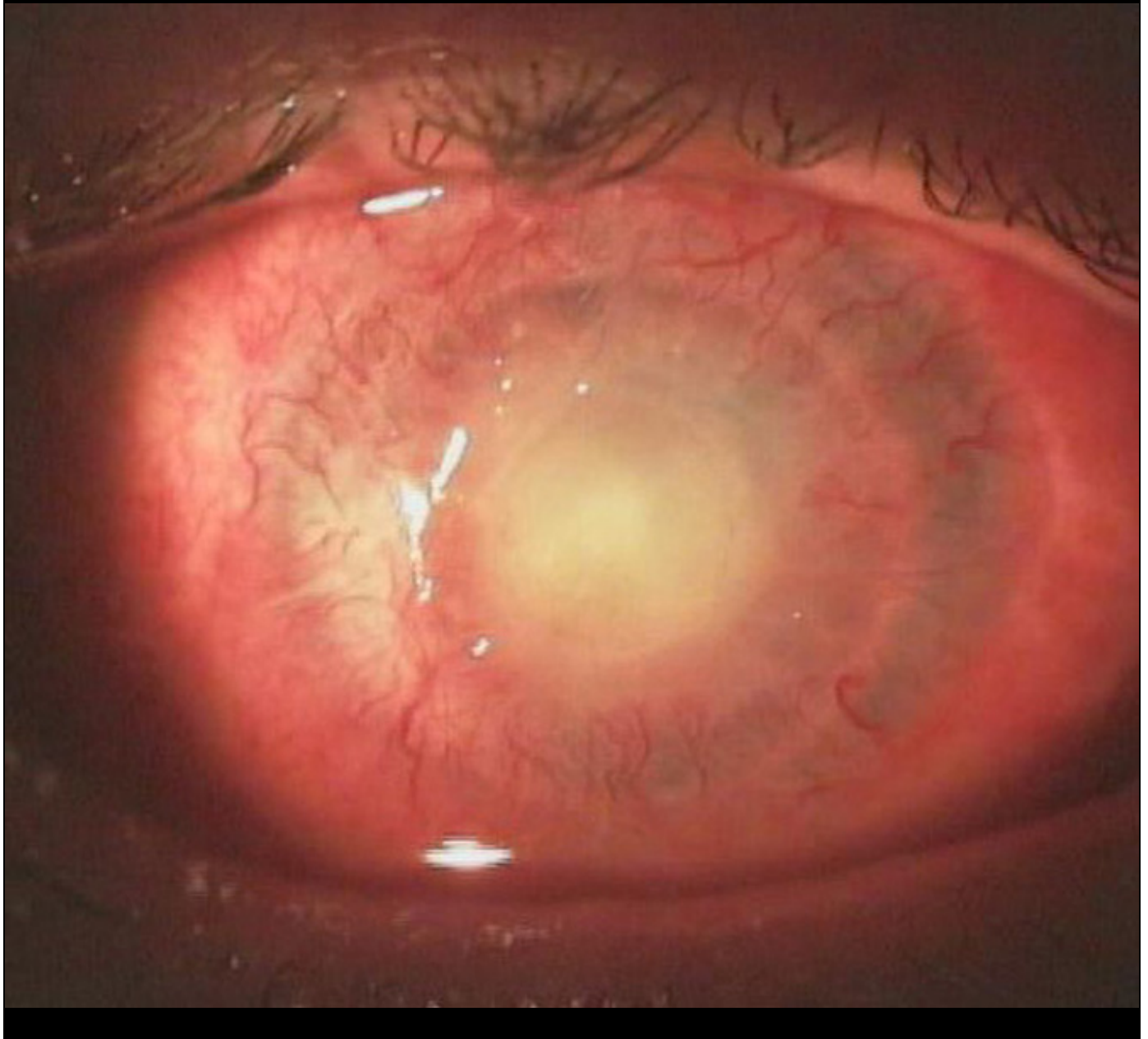


© Copyright [Oculisti OnLine](http://www.eyeatlas.com)

EyeAtlas

The online Atlas of Ophthalmology

Keratoplasty: corneal rejection

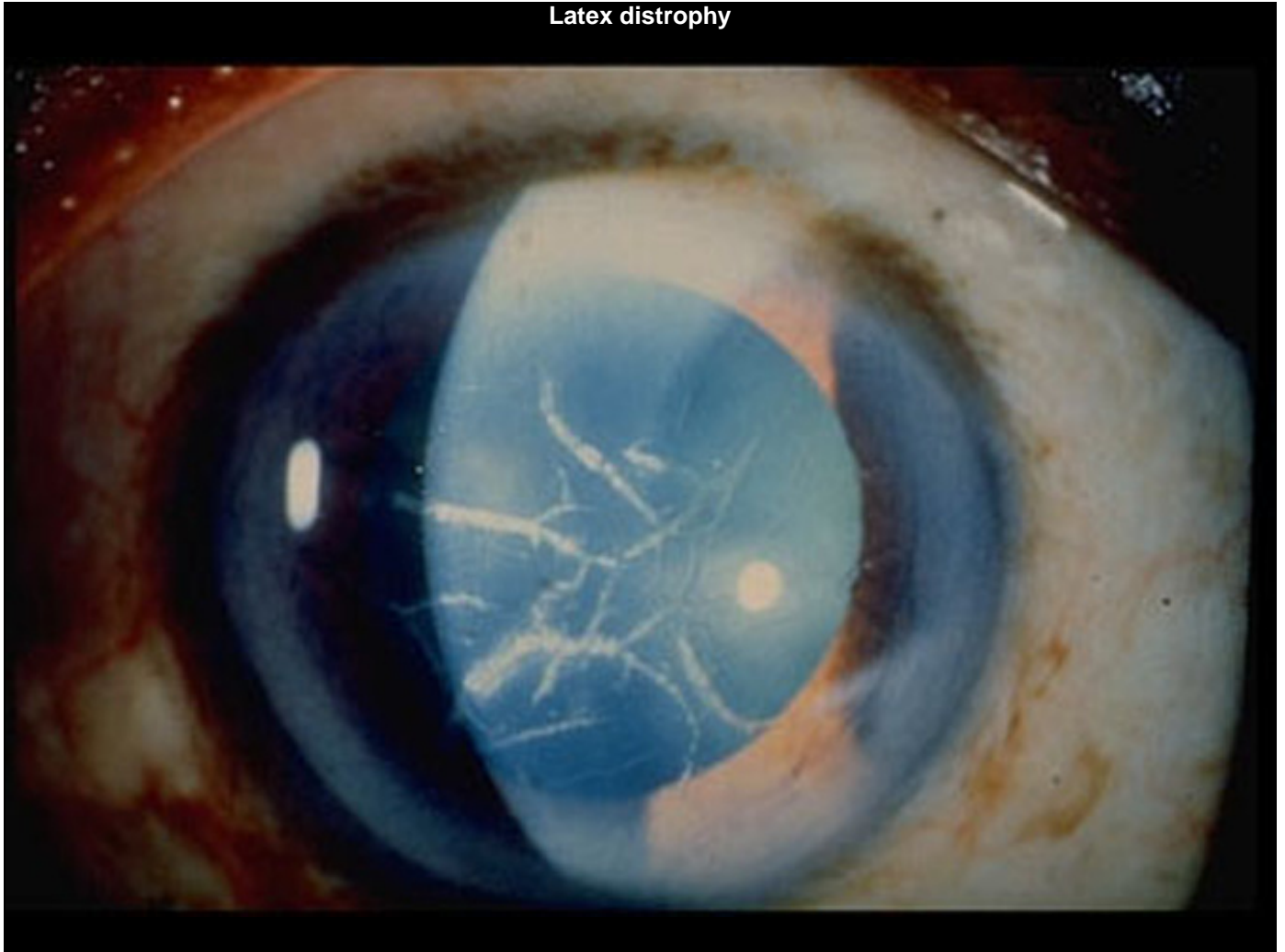


© Copyright [Oculisti OnLine](http://www.eyeatlas.com)

EyeAtlas

The online Atlas of Ophthalmology

Latex distrophy

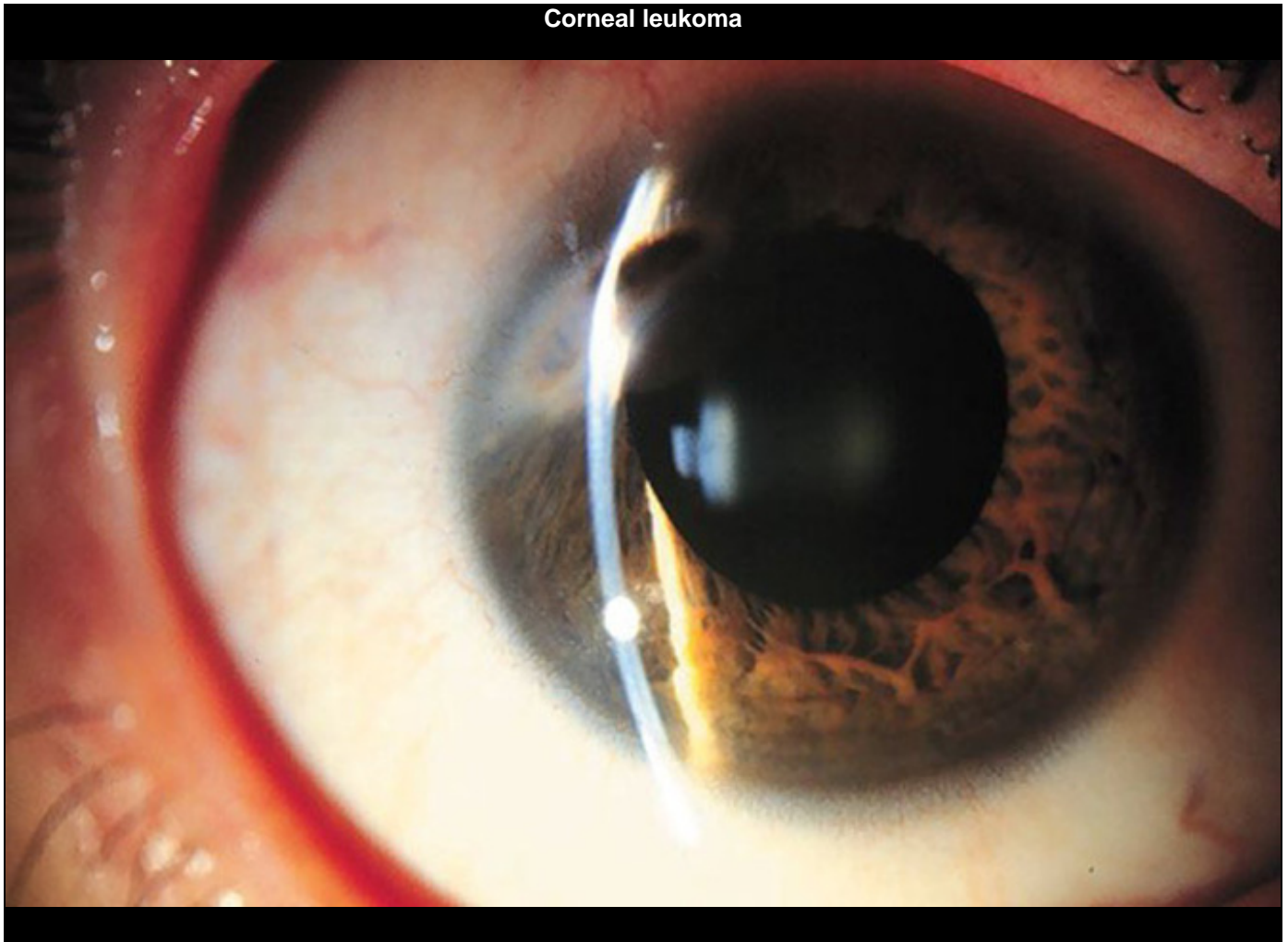


© Copyright [Oculisti OnLine](#)

EyeAtlas

The online Atlas of Ophthalmology

Corneal leukoma

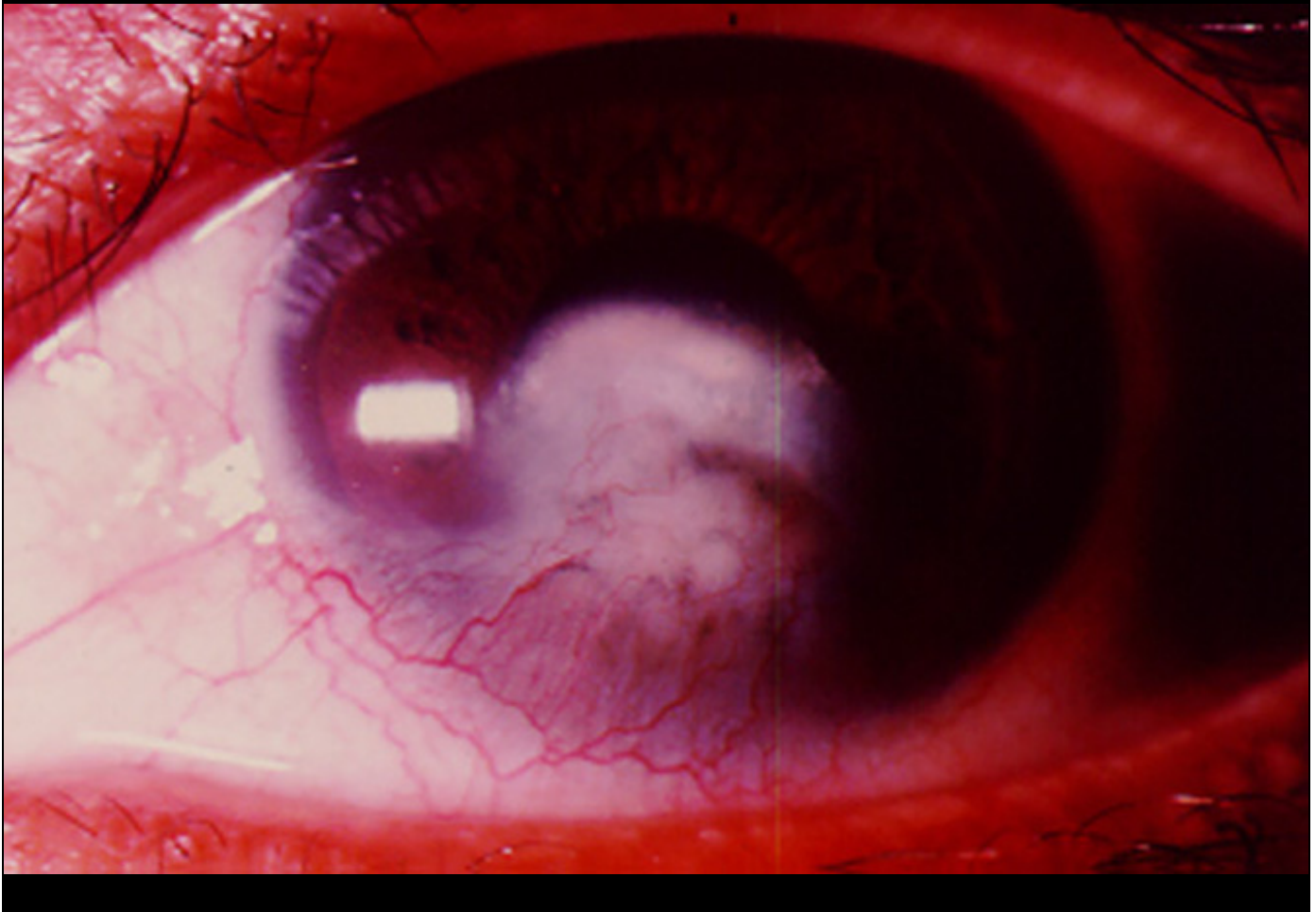


© Copyright [Oculisti OnLine](#)

EyeAtlas

The online Atlas of Ophthalmology

Corneal leukoma and neovascularization

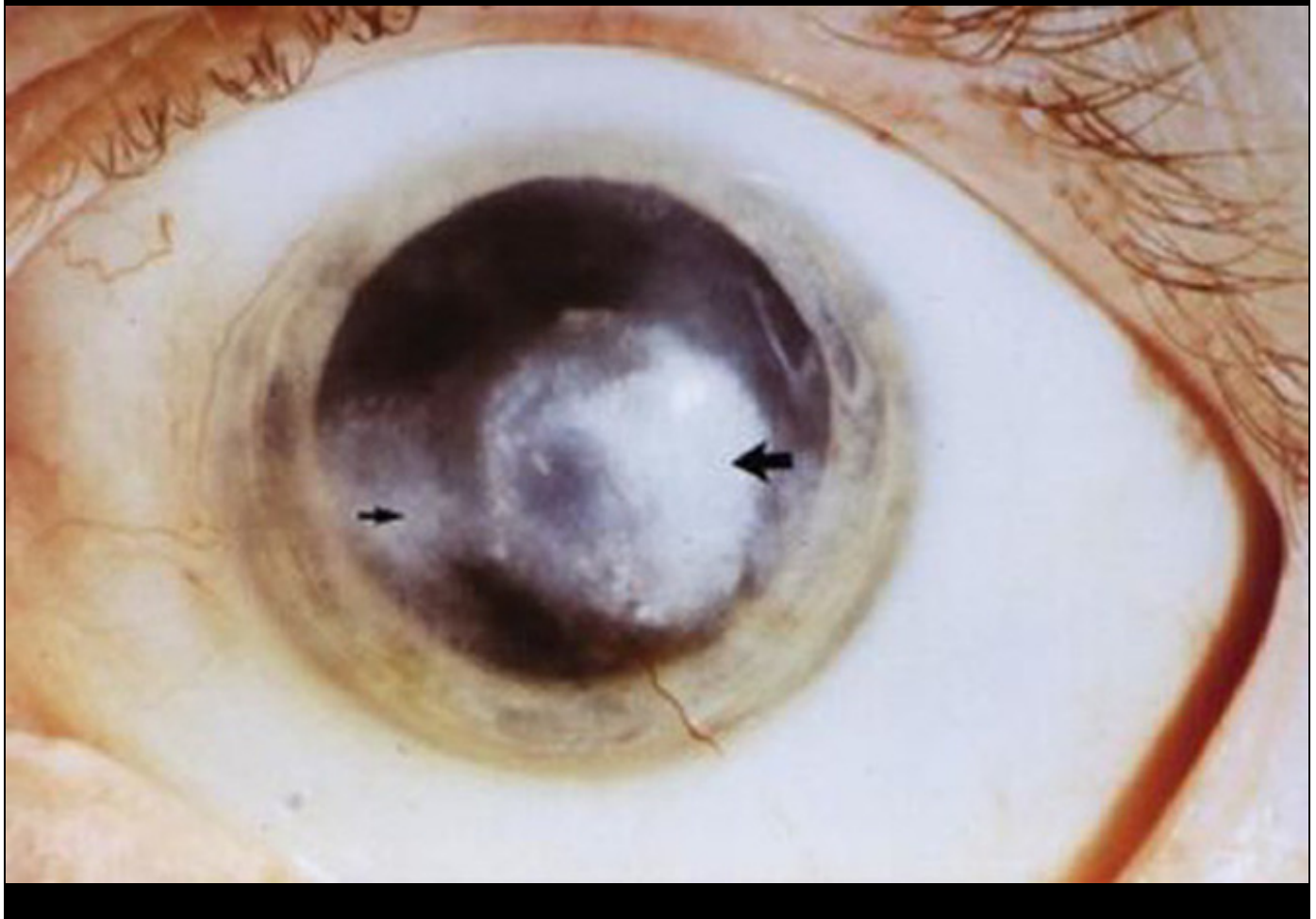


© Copyright [Oculisti OnLine](http://www.eyeatlas.com)

EyeAtlas

The online Atlas of Ophthalmology

Herpetic corneal scar

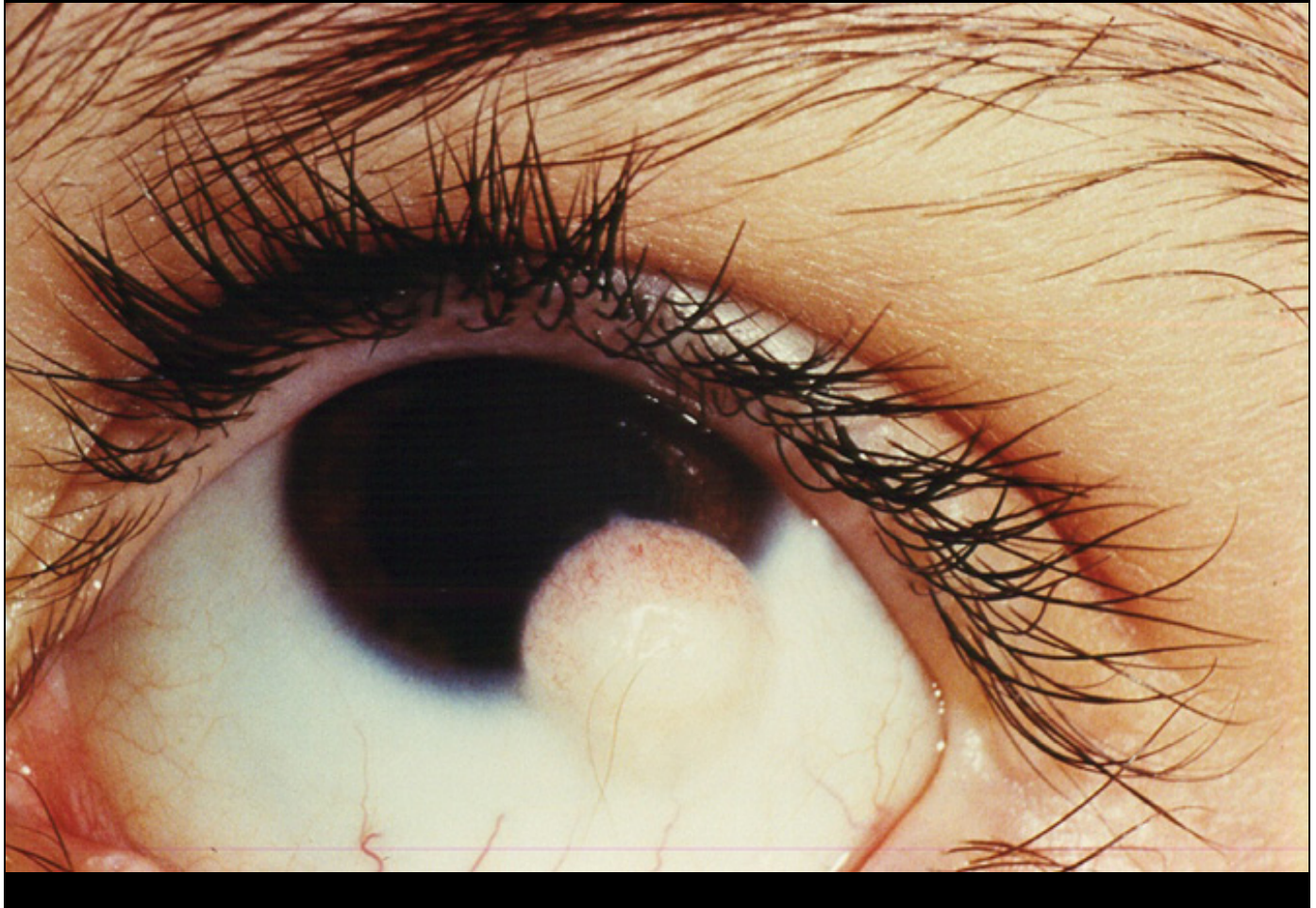

© Copyright [Oculisti OnLine](http://www.eyeatlas.com)

EyeAtlas

The online Atlas of Ophthalmology

Limbal dermoid

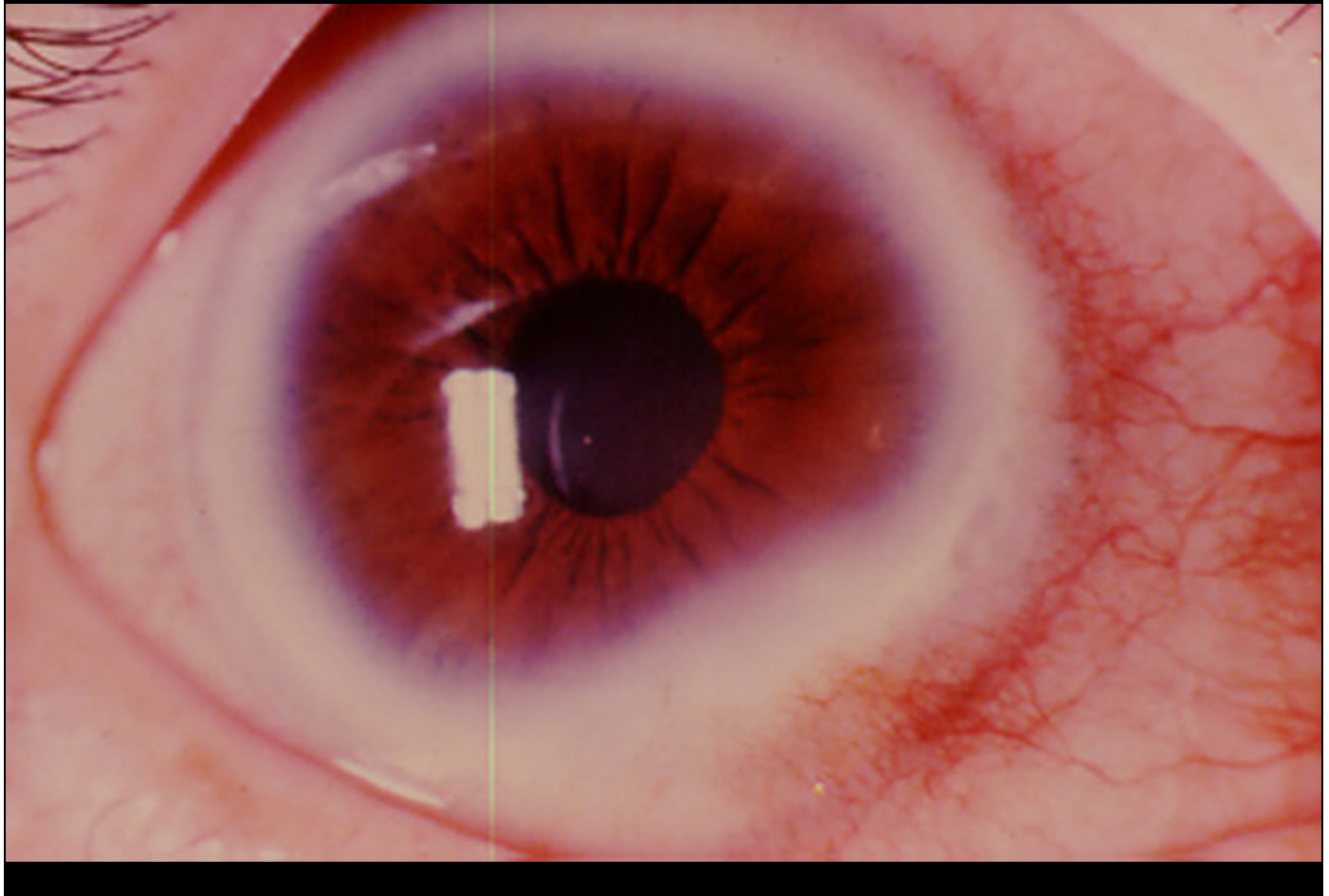


© Copyright [Oculisti OnLine](#)

EyeAtlas

The online Atlas of Ophthalmology

Lipidic corneal degeneration



© Copyright [Oculisti OnLine](http://www.eyeatlas.com)

EyeAtlas

The online Atlas of Ophthalmology

Mooren's ulcer

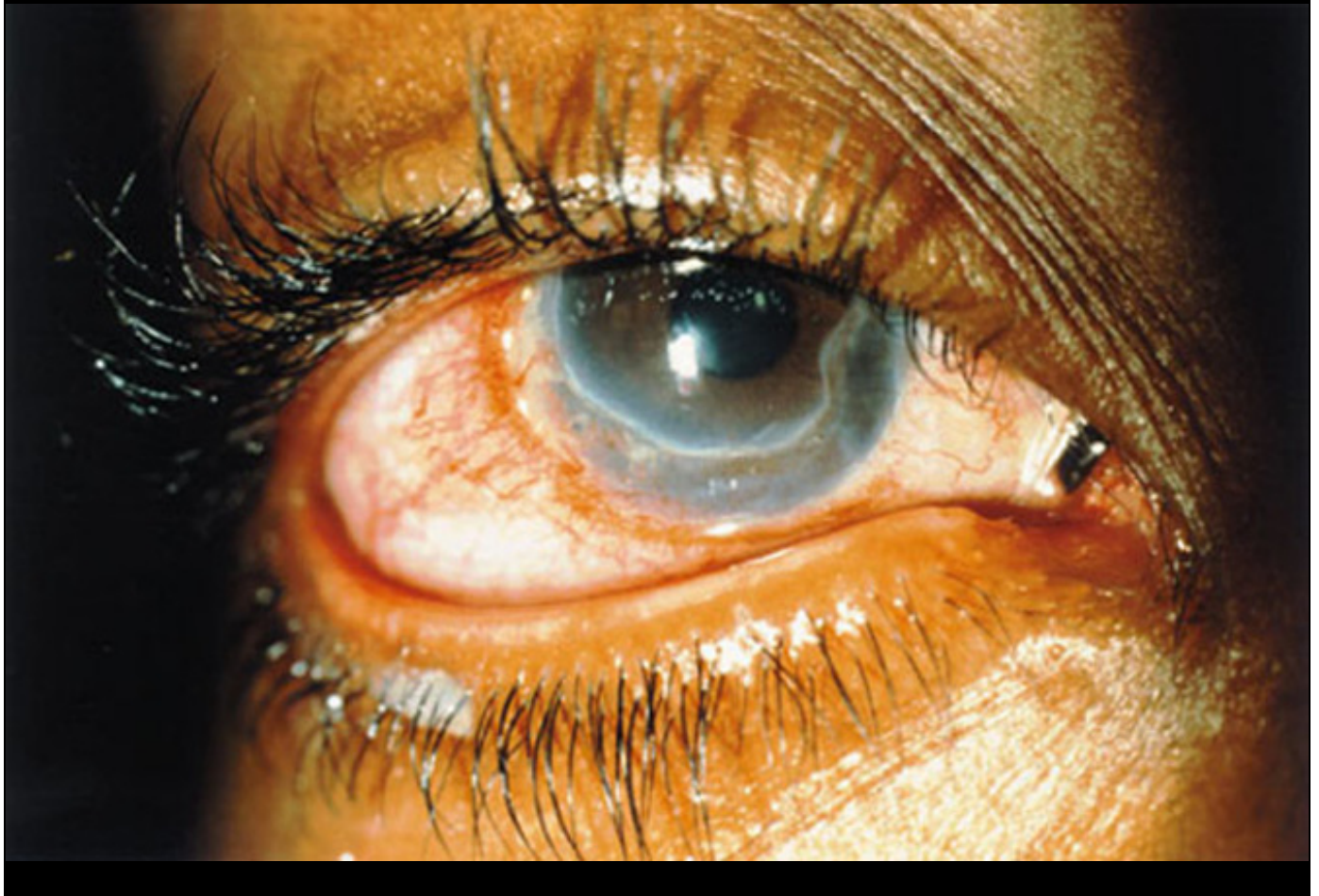

© Copyright [Oculisti OnLine](http://www.eyeatlas.com)

Eyeatlas

The online Atlas of Ophthalmology

Mooren's ulcer

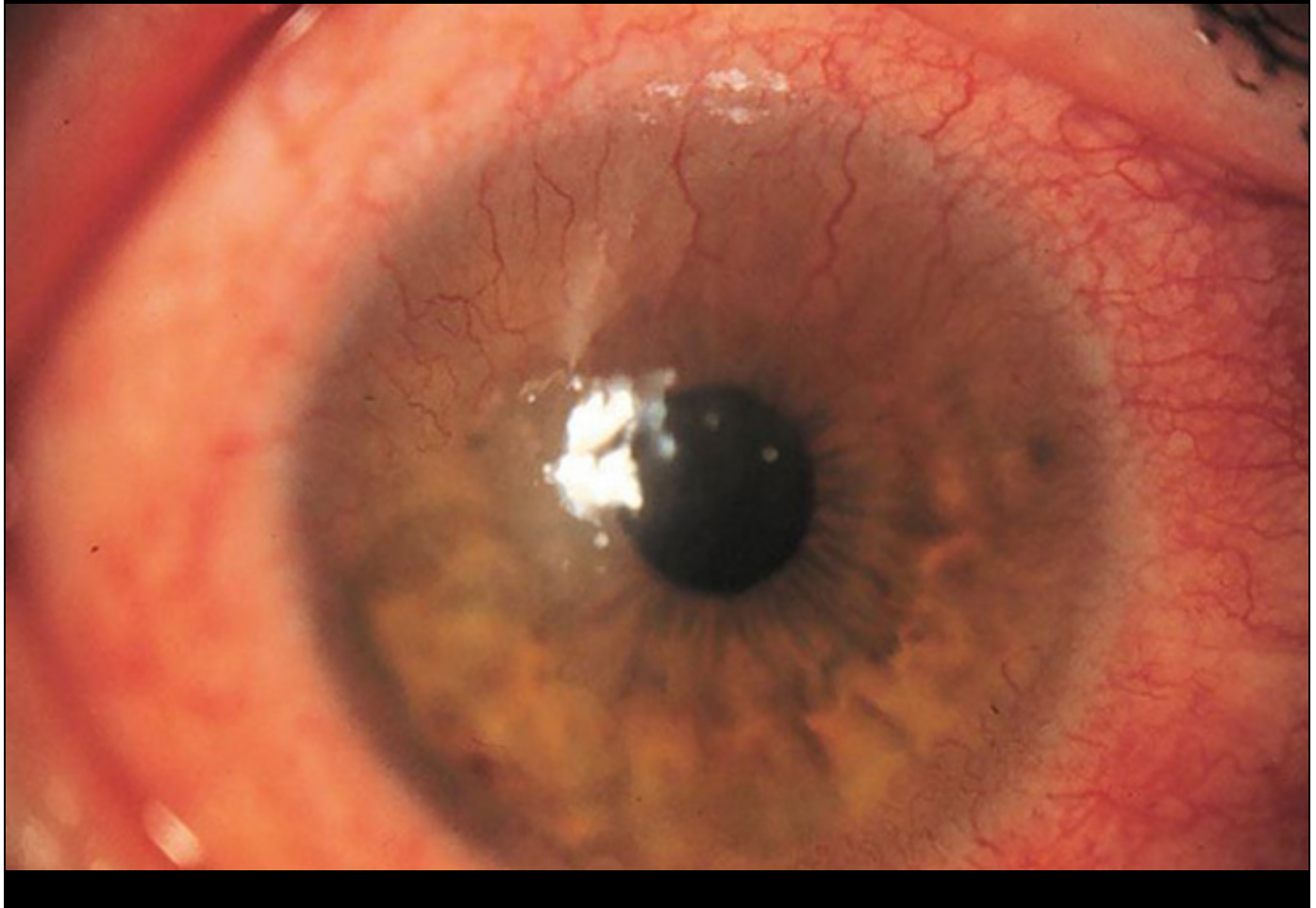


© Copyright [Oculisti OnLine](#)

EyeAtlas

The online Atlas of Ophthalmology

Corneal neovascularization

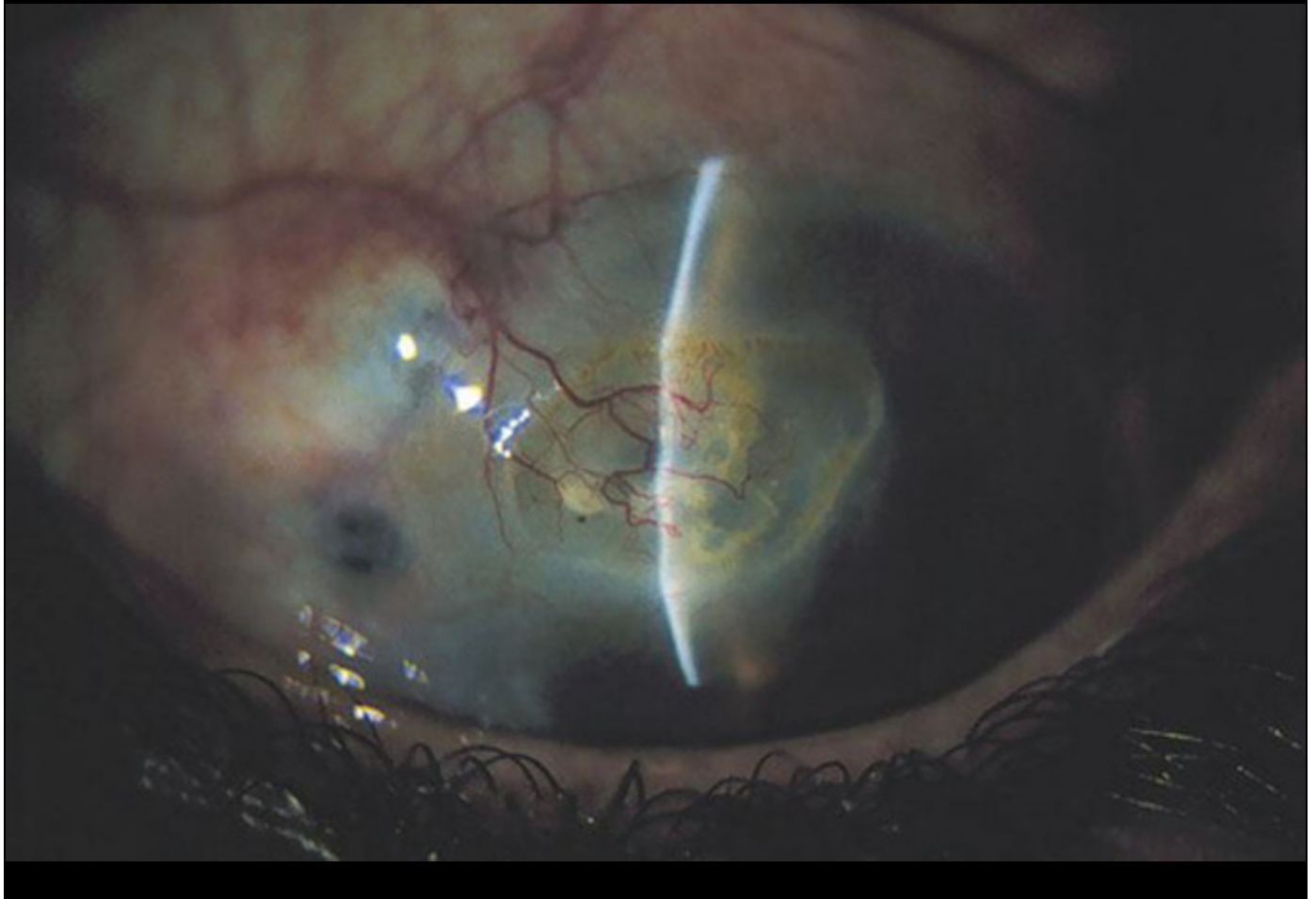


© Copyright [Oculisti OnLine](#)

EyeAtlas

The online Atlas of Ophthalmology

Corneal neovascularization after keratitis

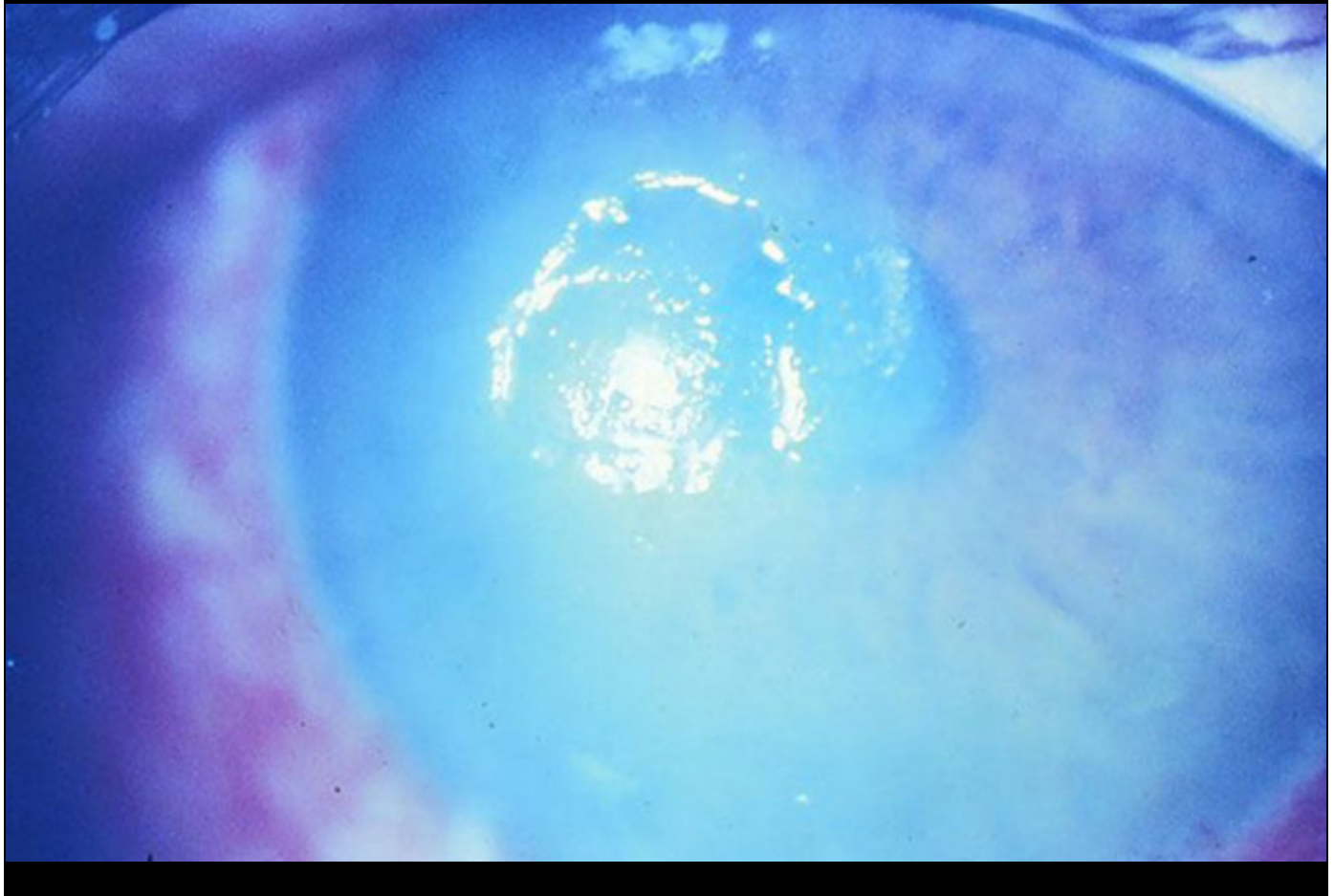


© Copyright [Oculisti OnLine](#)

EyeAtlas

The online Atlas of Ophthalmology

Neurotrophic keratopathy after zoster

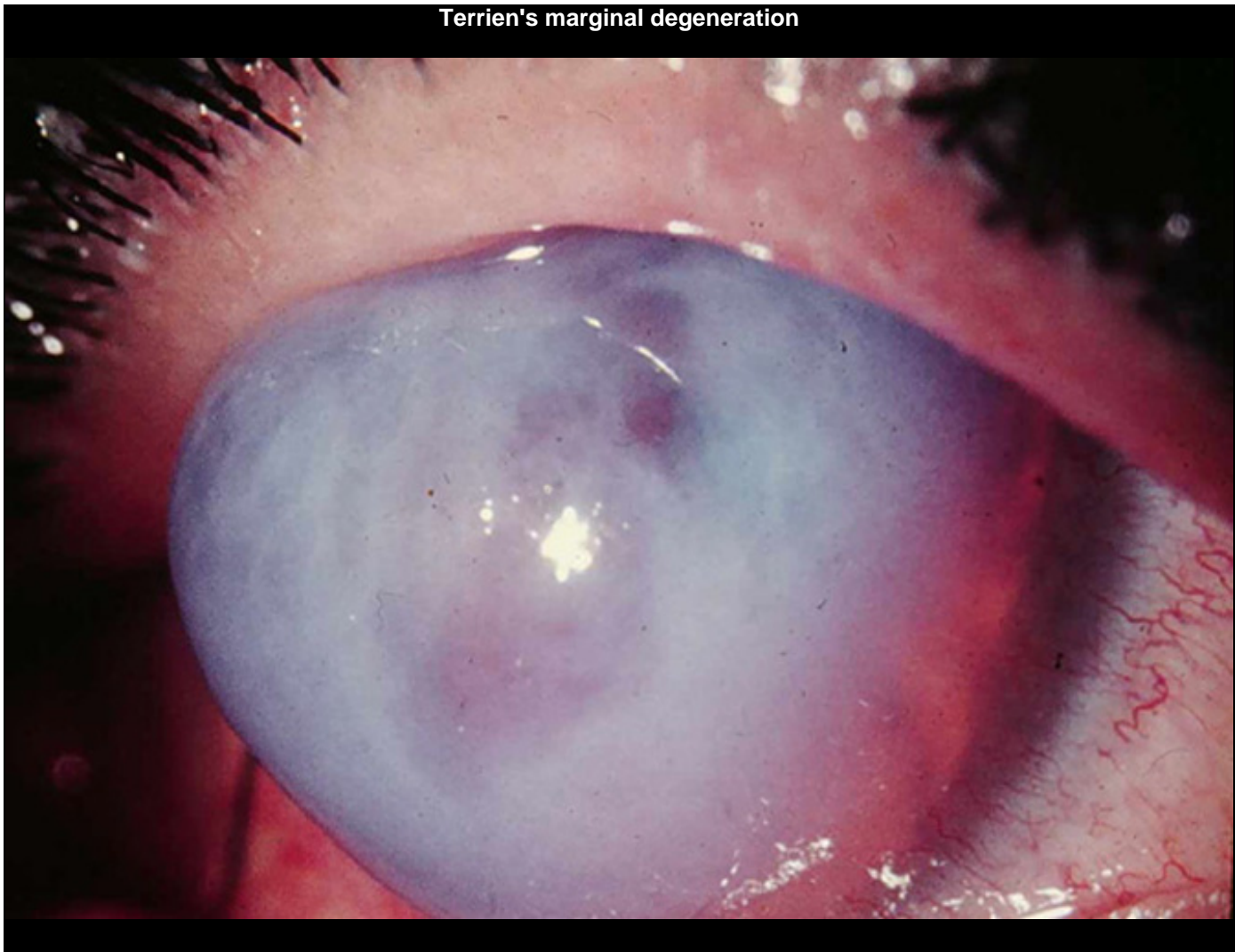

© Copyright [Oculisti OnLine](#)

EyeAtlas

The online Atlas of Ophthalmology

Terrien's marginal degeneration

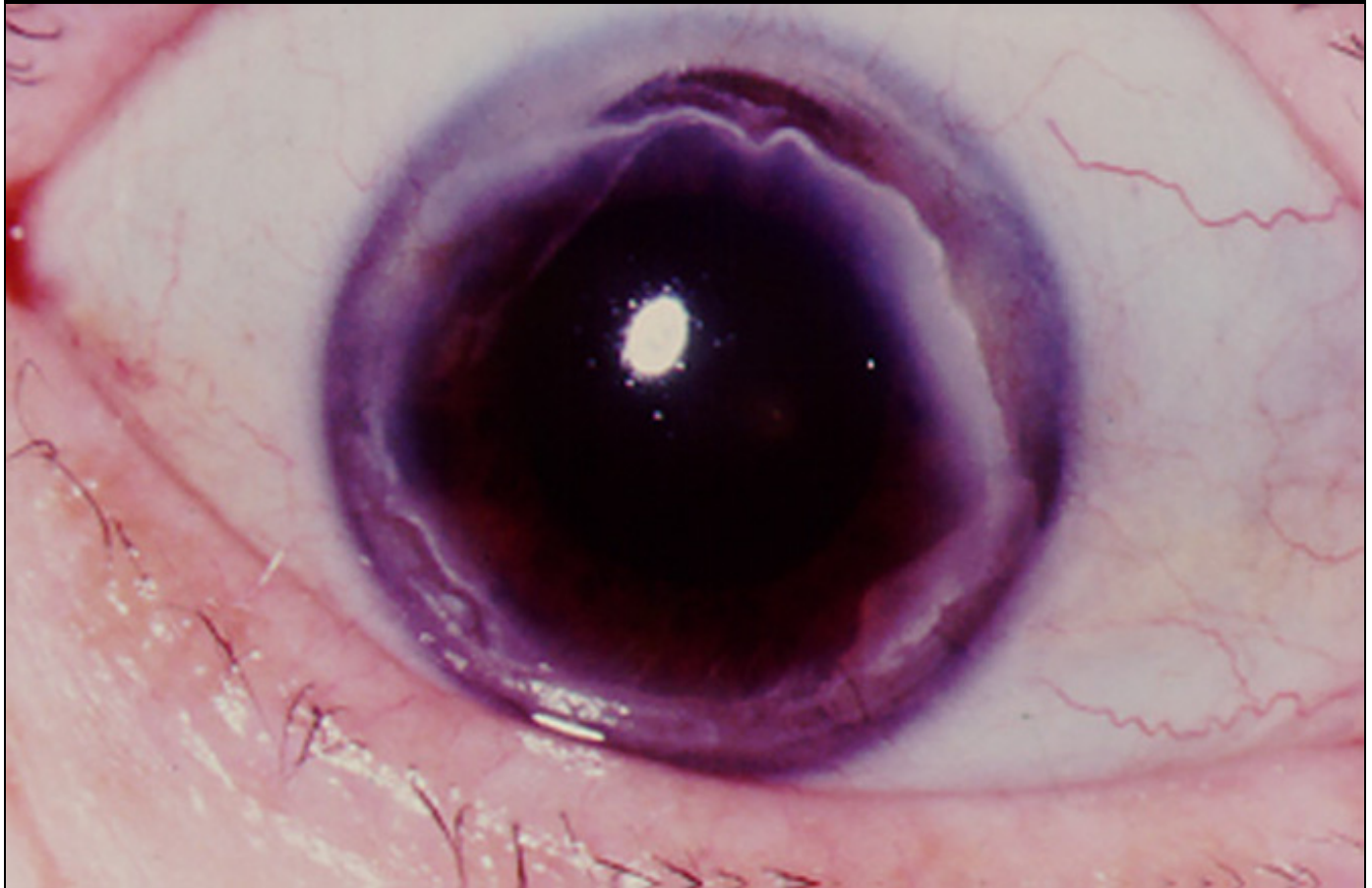


© Copyright [Oculisti OnLine](http://www.eyeatlas.com)

EyeAtlas

The online Atlas of Ophthalmology

Terrien's marginal ulceration

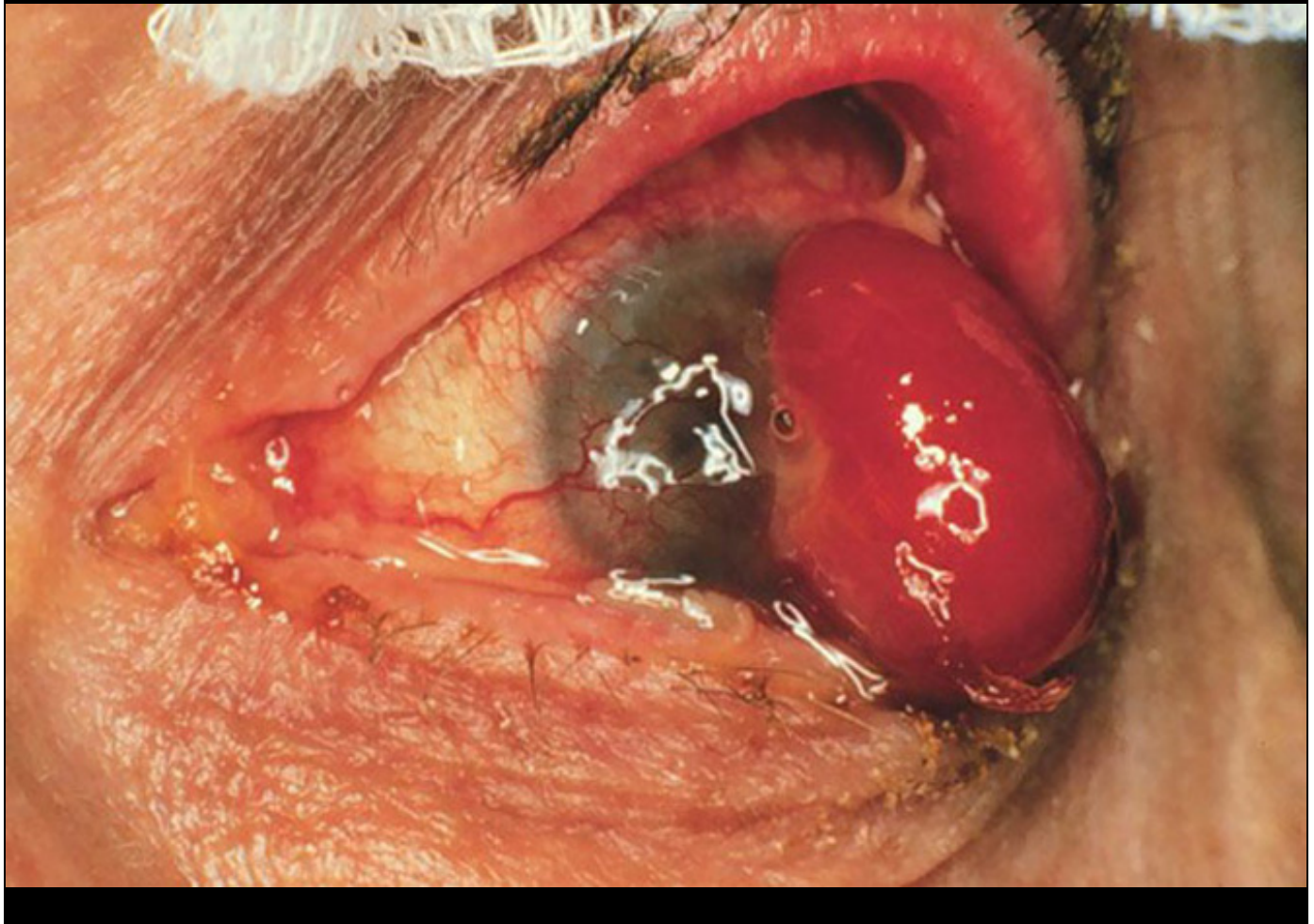


© Copyright [Oculisti OnLine](#)

EyeAtlas

The online Atlas of Ophthalmology

Epithelial limbal tumor

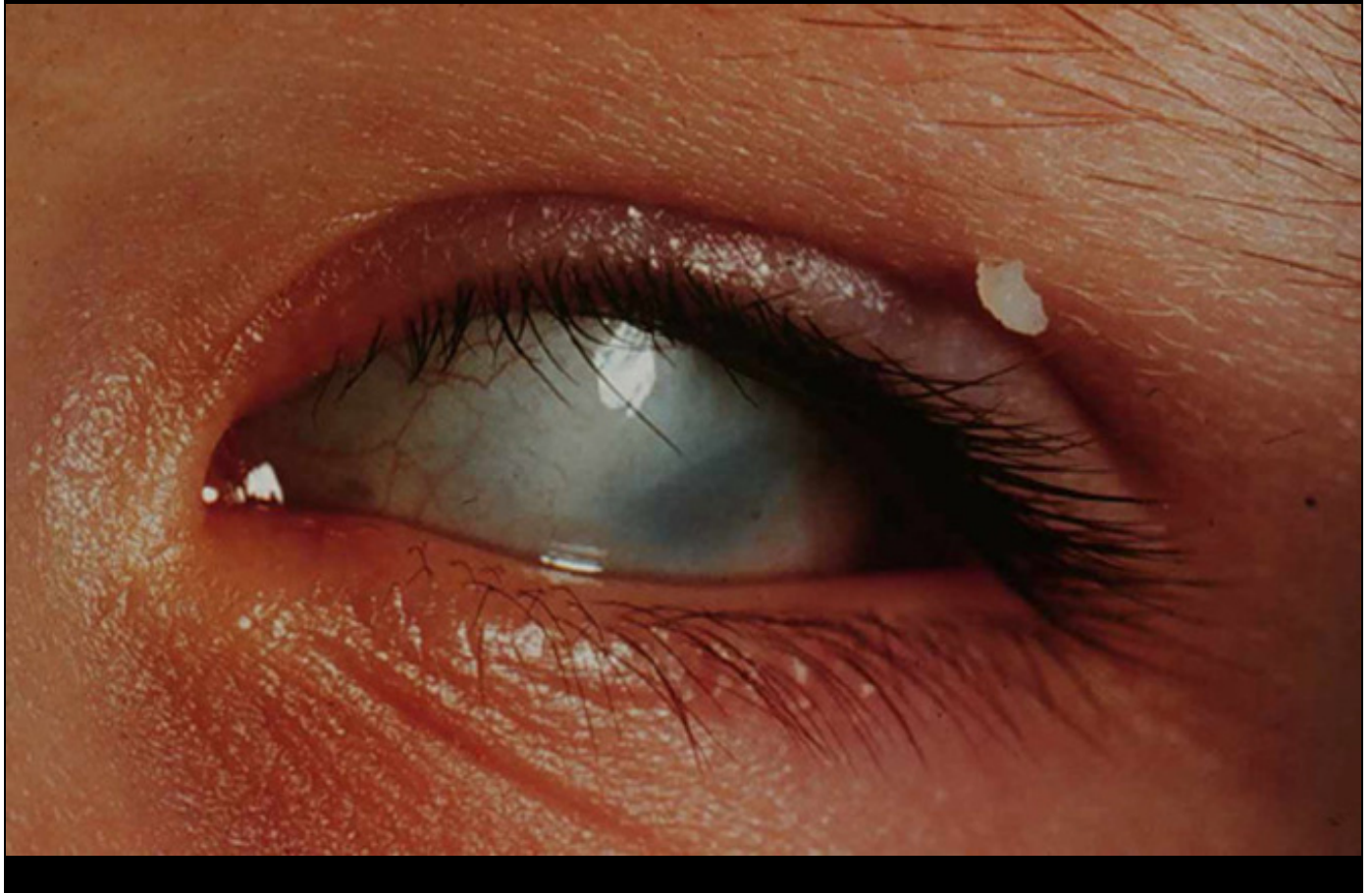


© Copyright [Oculisti OnLine](#)

EyeAtlas

The online Atlas of Ophthalmology

Sclerocornea

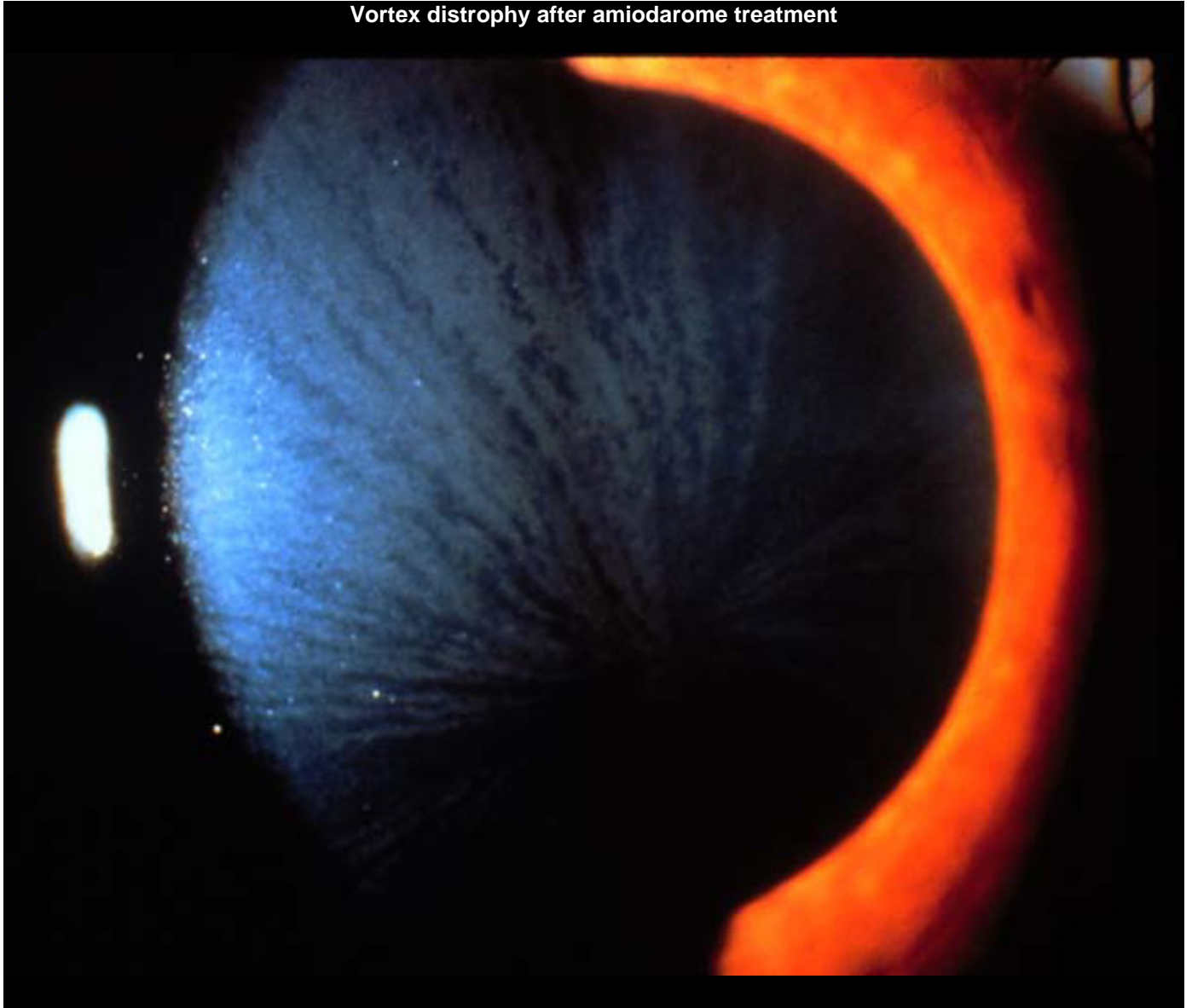


© Copyright [Oculisti OnLine](http://www.eyeatlas.com)

EyeAtlas

The online Atlas of Ophthalmology

Vortex dystrophy after amiodarone treatment

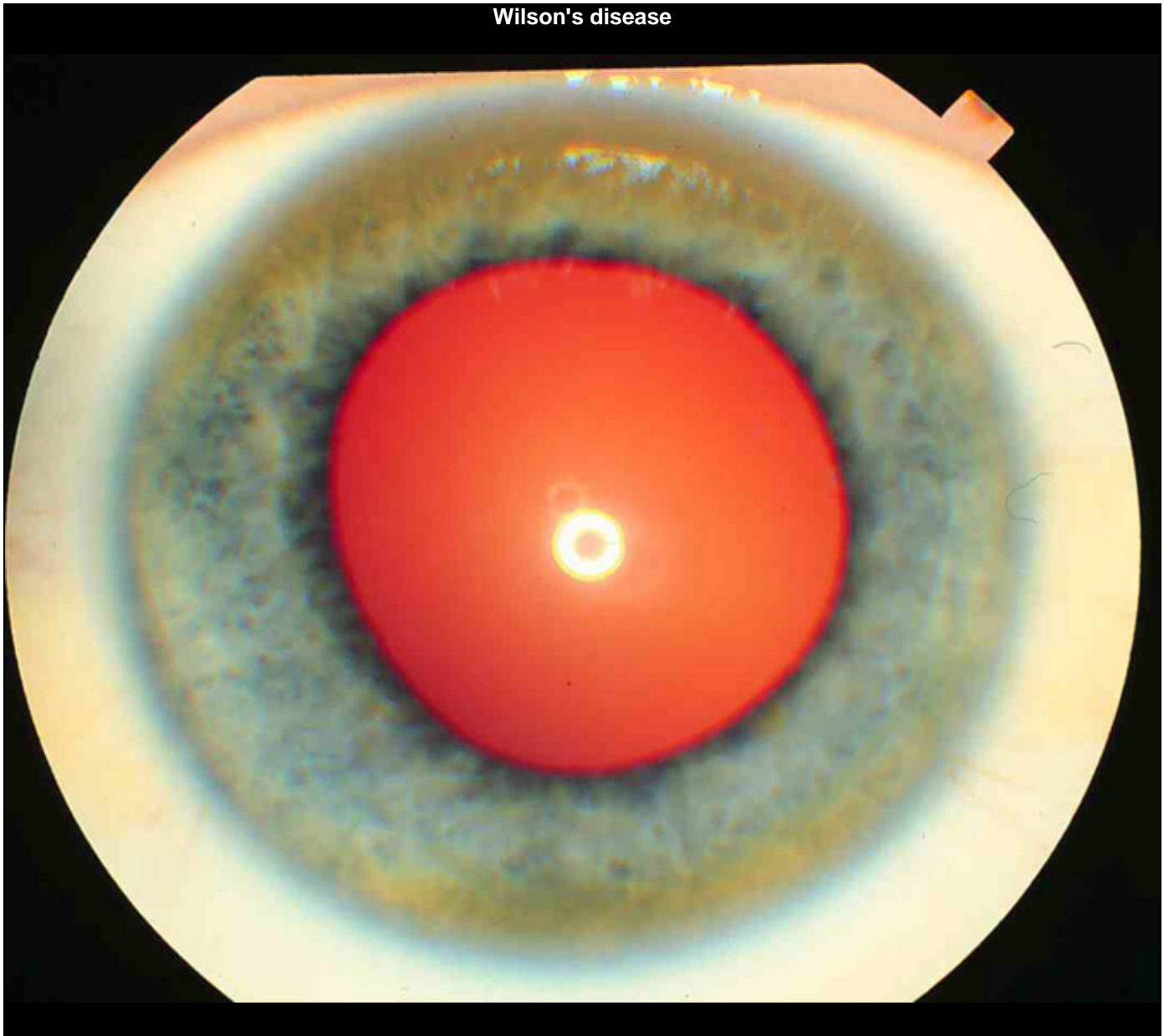


© Copyright [Oculisti OnLine](#)

EyeAtlas

The online Atlas of Ophthalmology

Wilson's disease

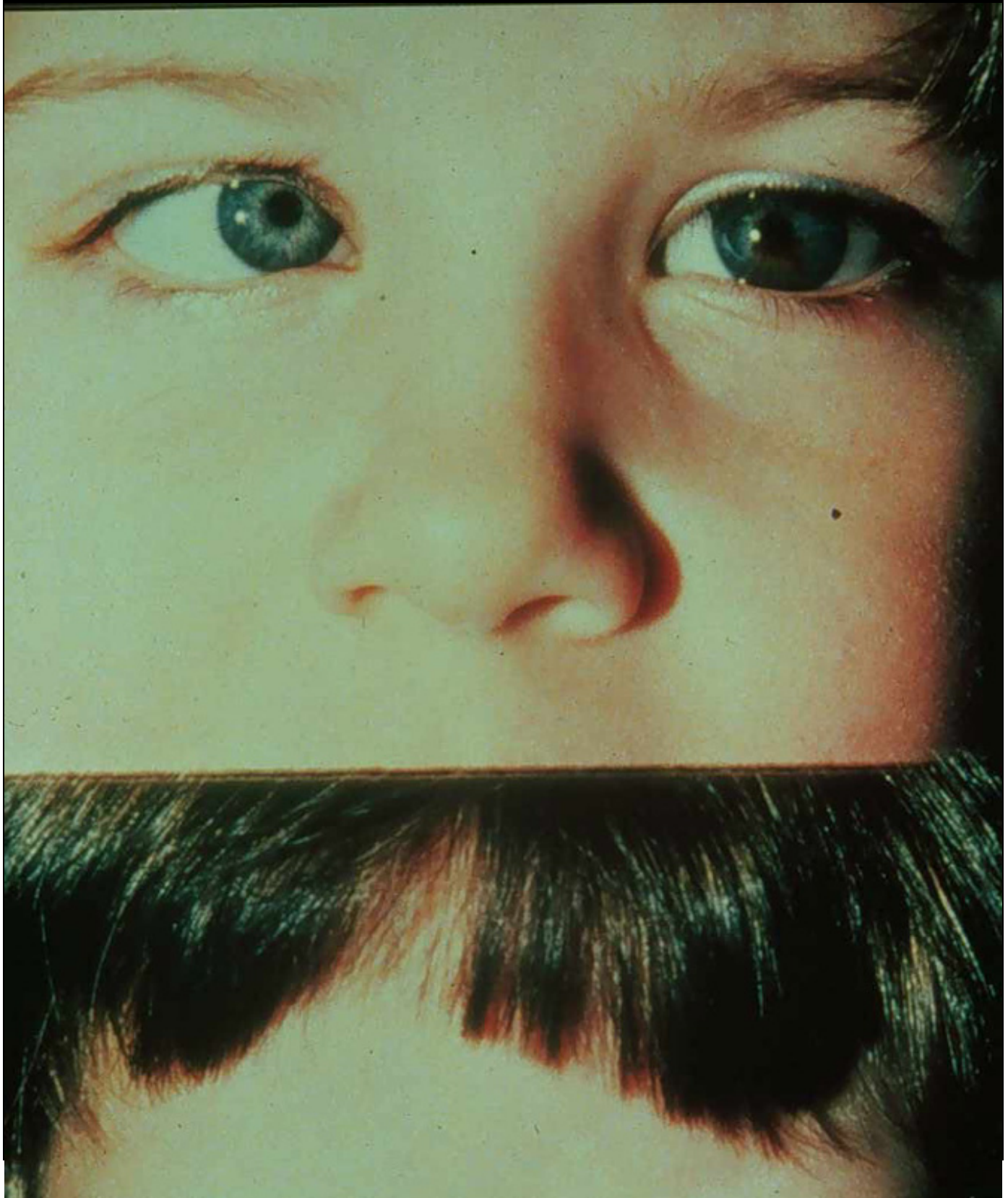


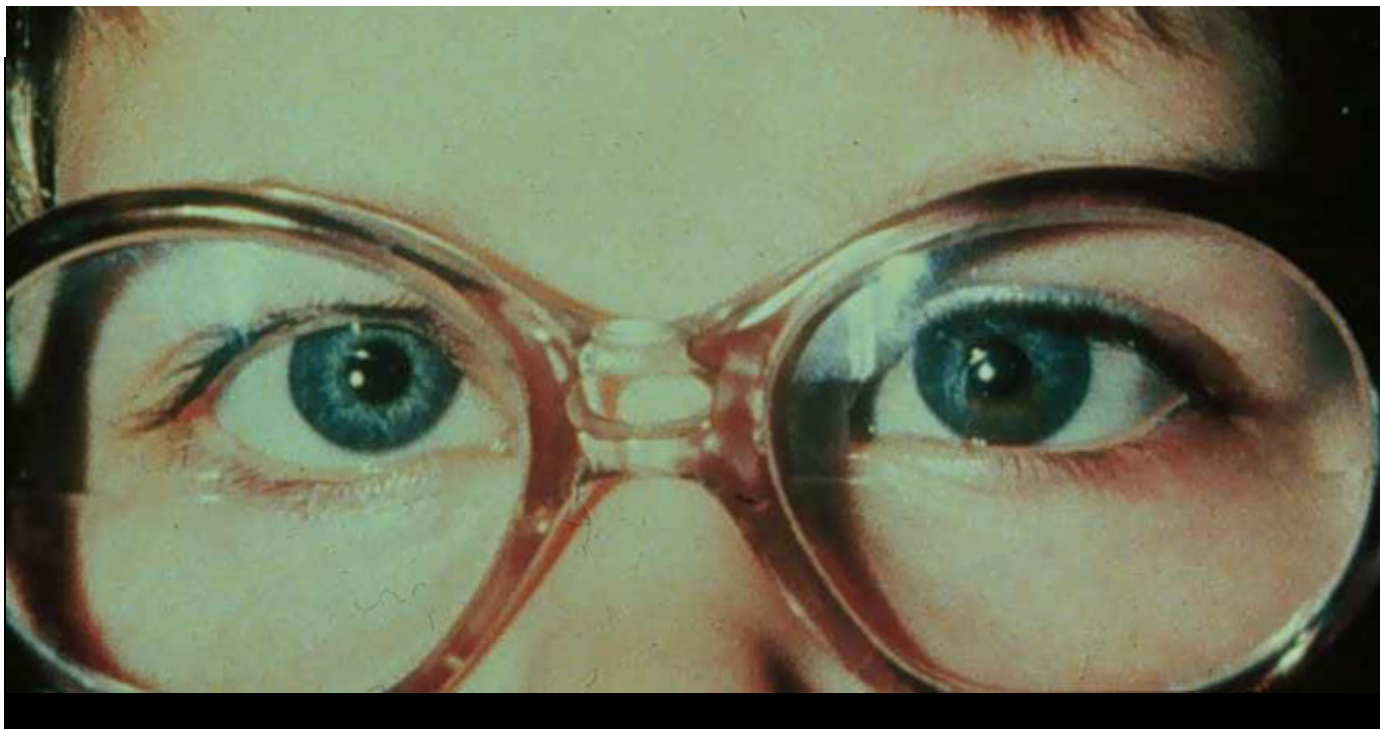© Copyright Oculisti OnLine

Eyeatlas

The online Atlas of Ophthalmology

Accomodative strabismus



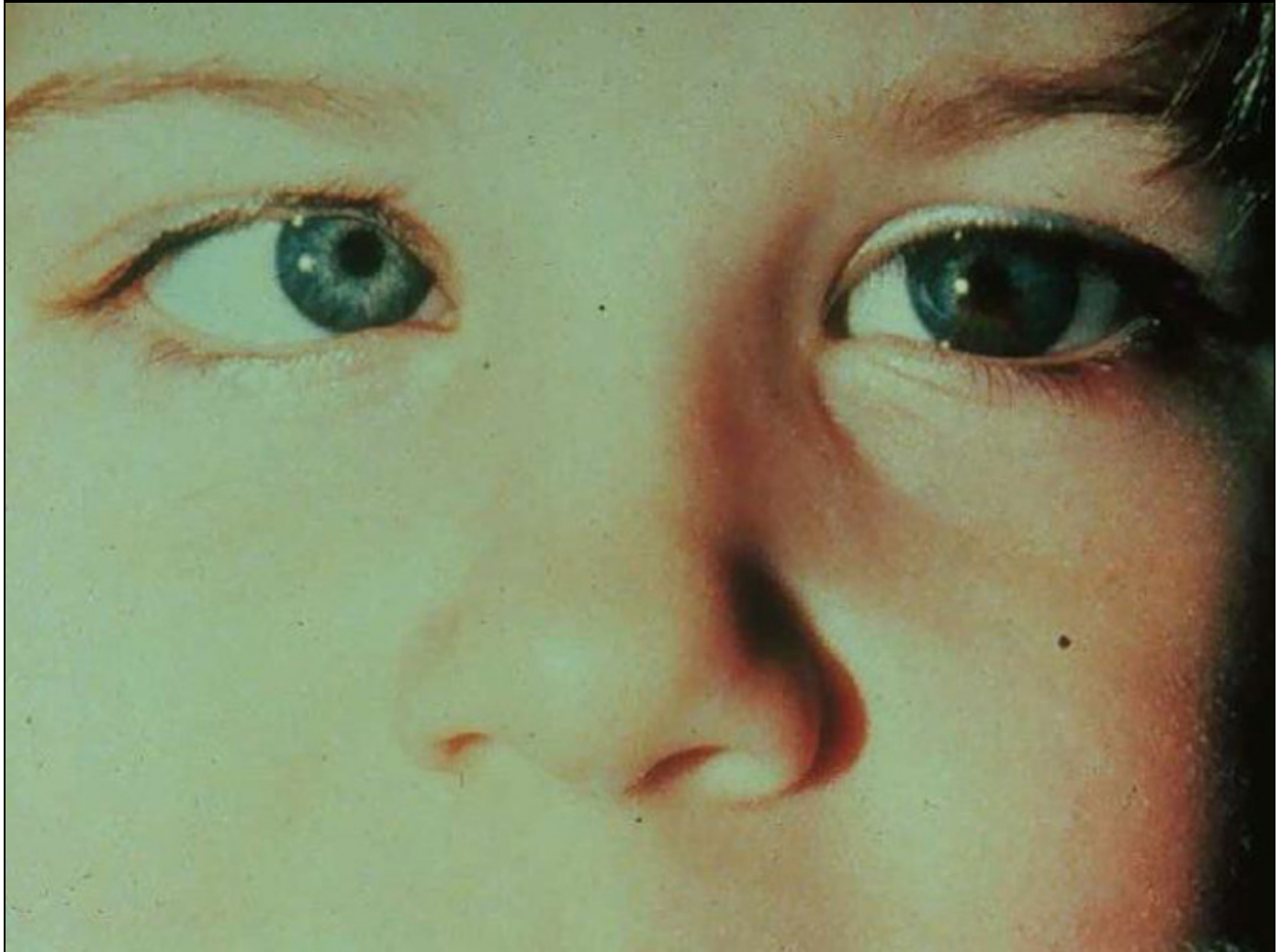

© Copyright [Oculisti OnLine](#)

Eyeatlas

The online Atlas of Ophthalmology

Patient with tilt





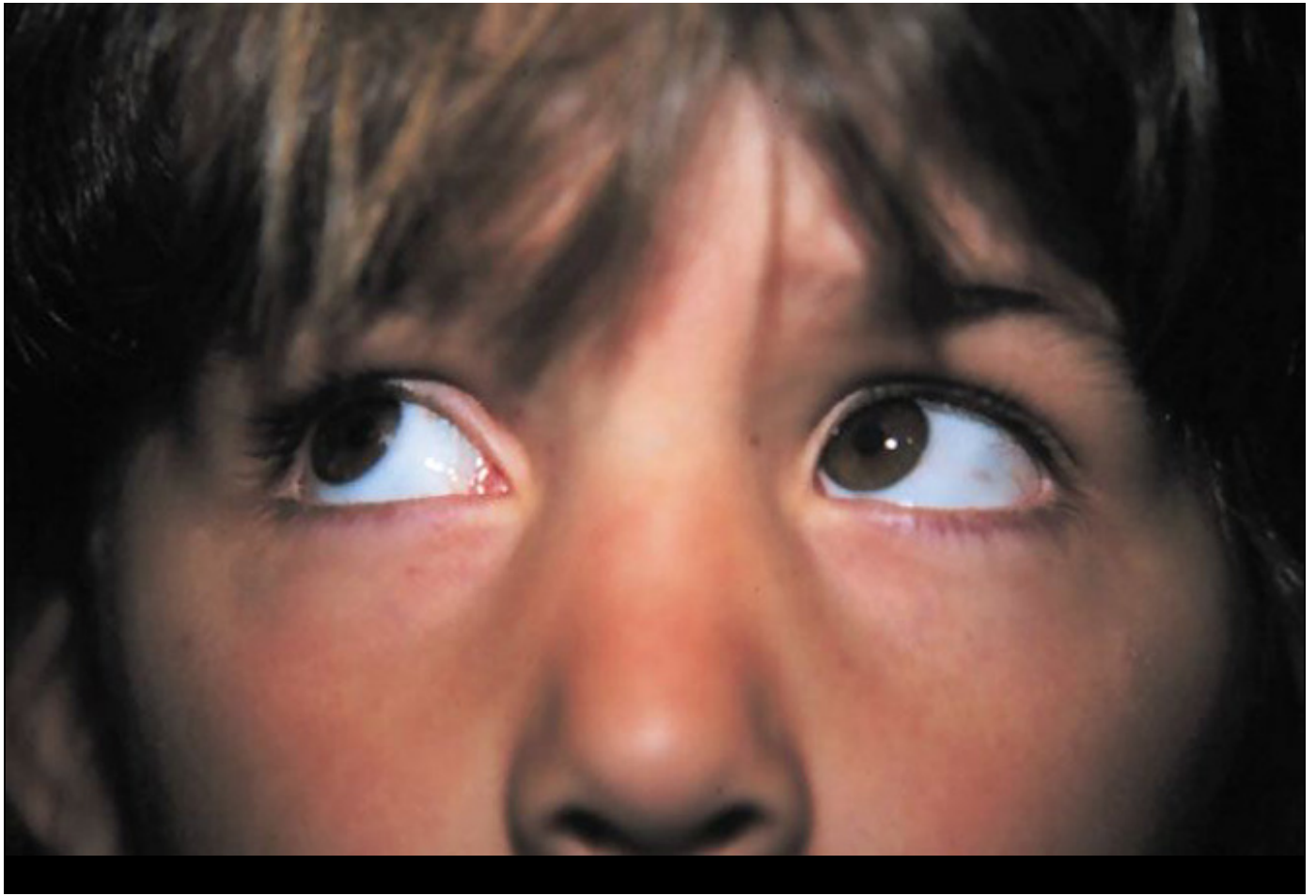© Copyright [Oculisti OnLine](#)

EyeAtlas

The online Atlas of Ophthalmology

Brown's syndrome: pre and after surgery



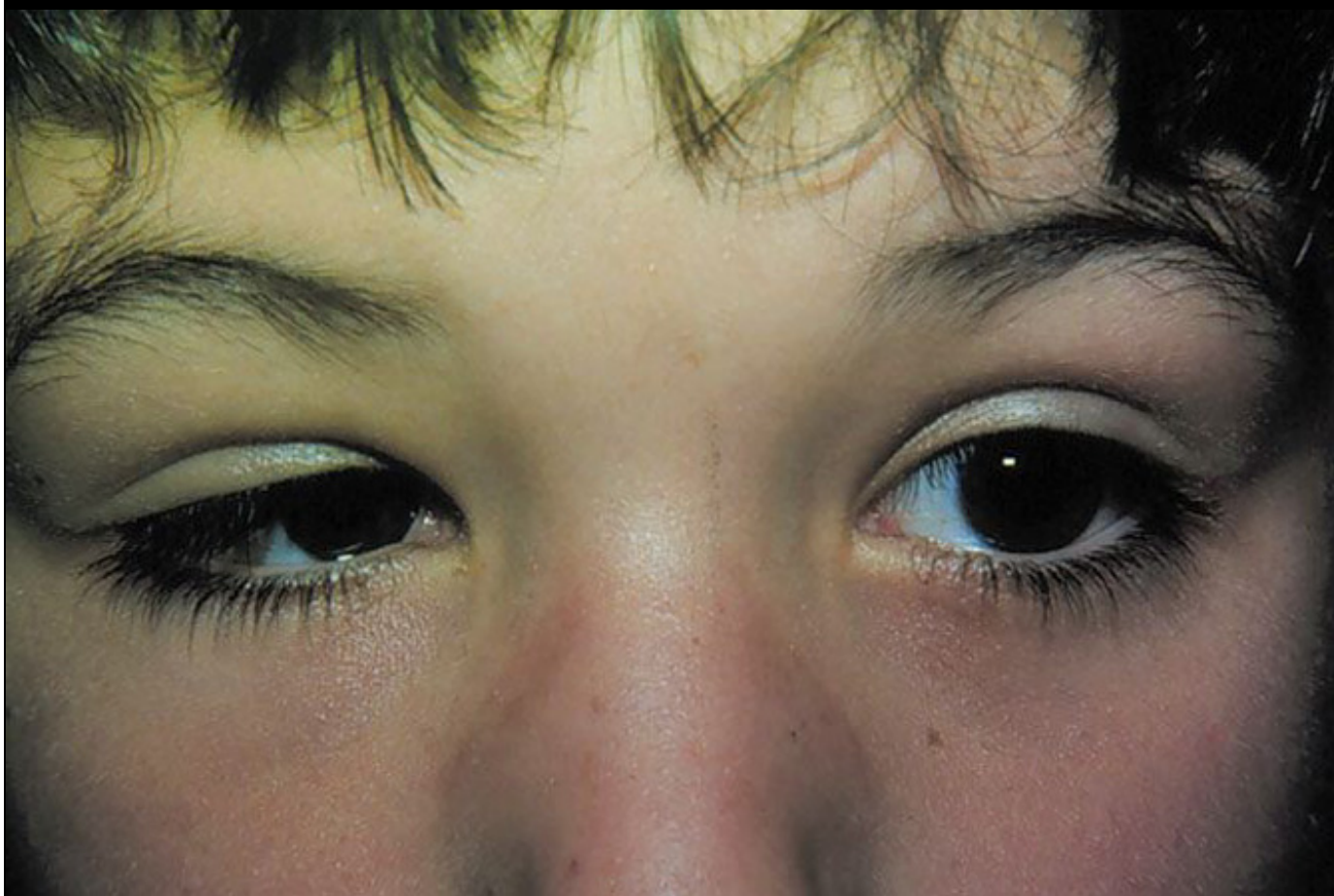

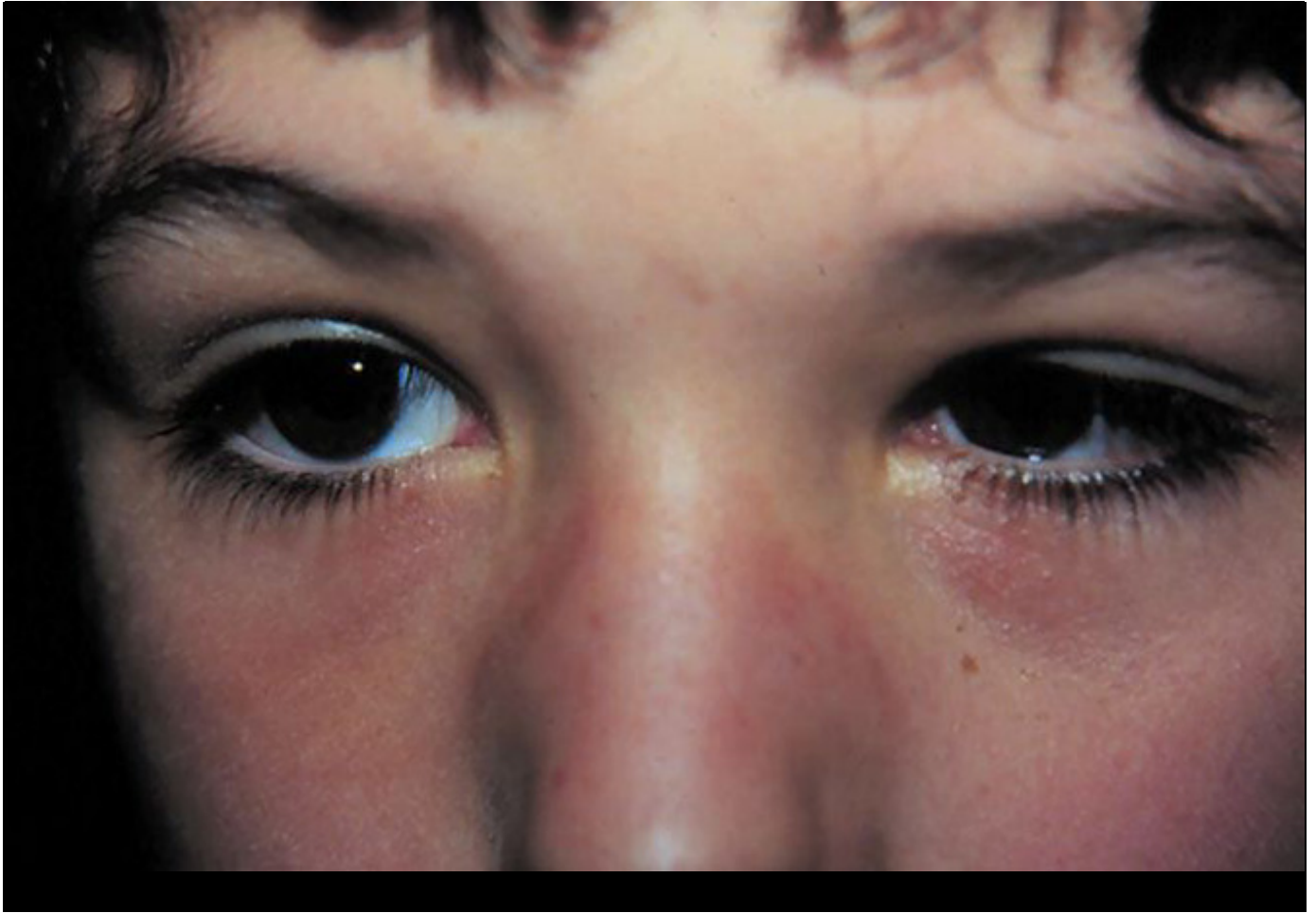© Copyright [Oculisti OnLine](#)

EyeAtlas

The online Atlas of Ophthalmology

Bilateral Duane's syndrome



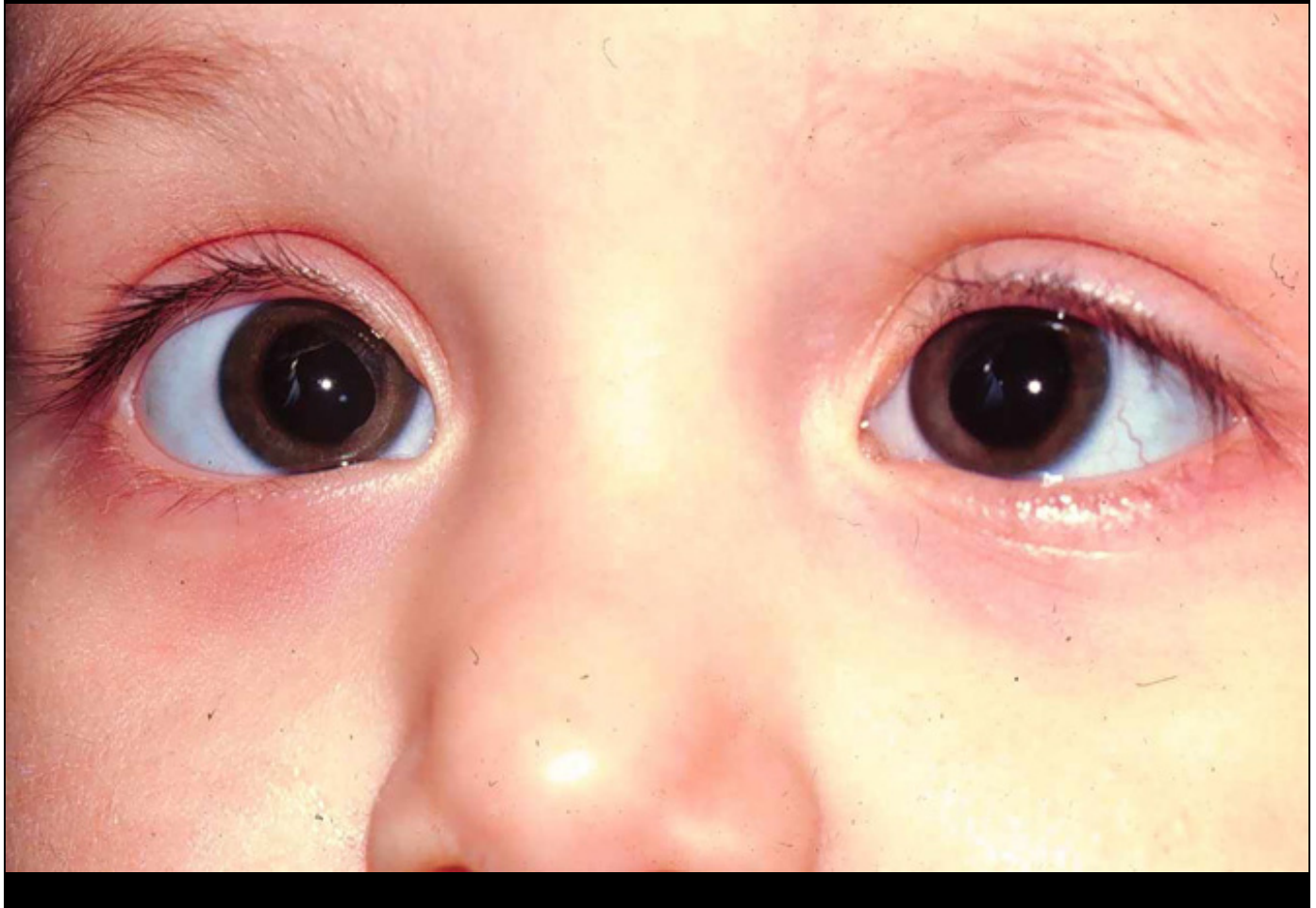

© Copyright [Oculisti OnLine](#)

EyeAtlas

The online Atlas of Ophthalmology

Duane's syndrome

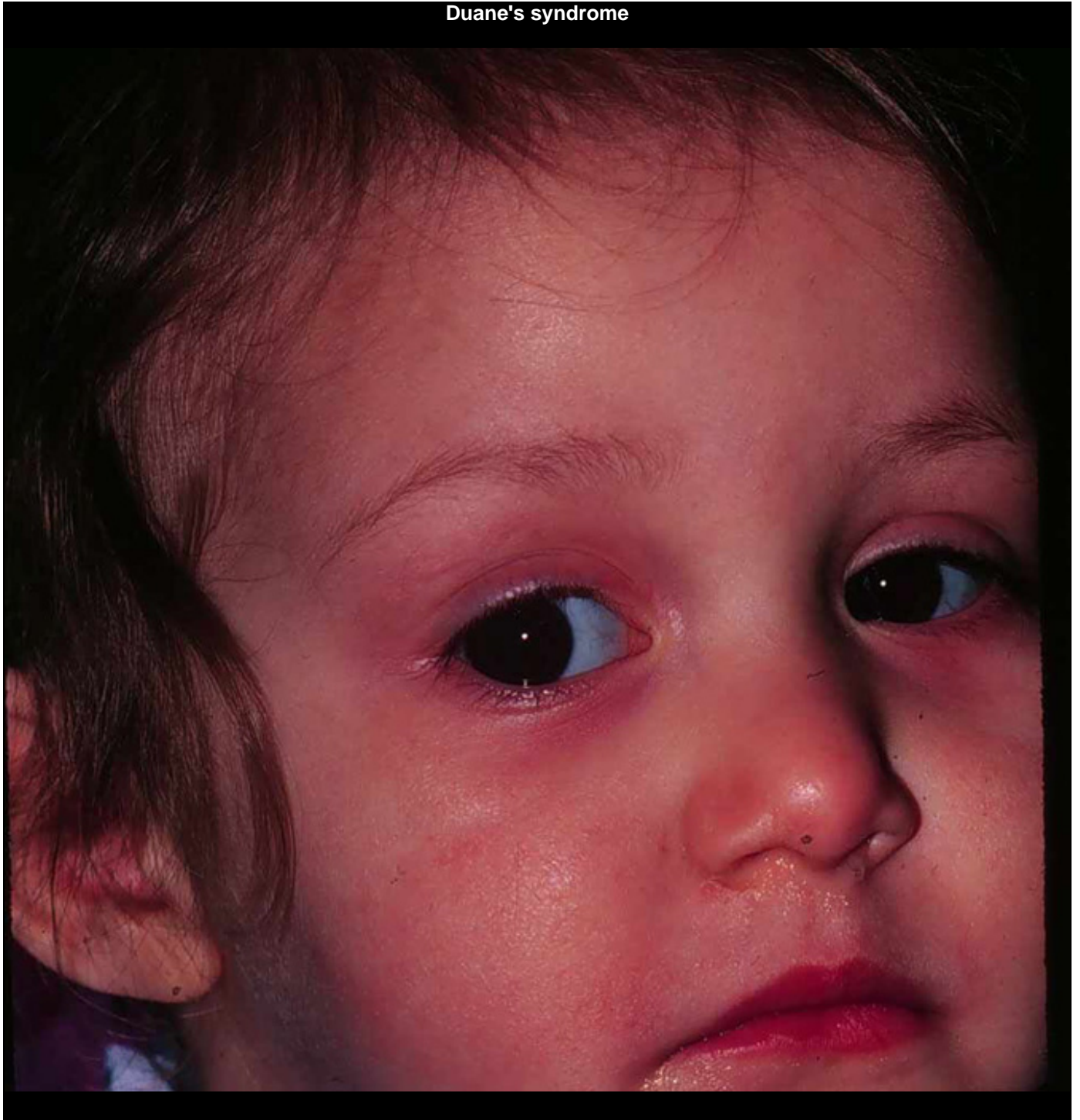


© Copyright [Oculisti OnLine](#)

Eyeatlas

The online Atlas of Ophthalmology

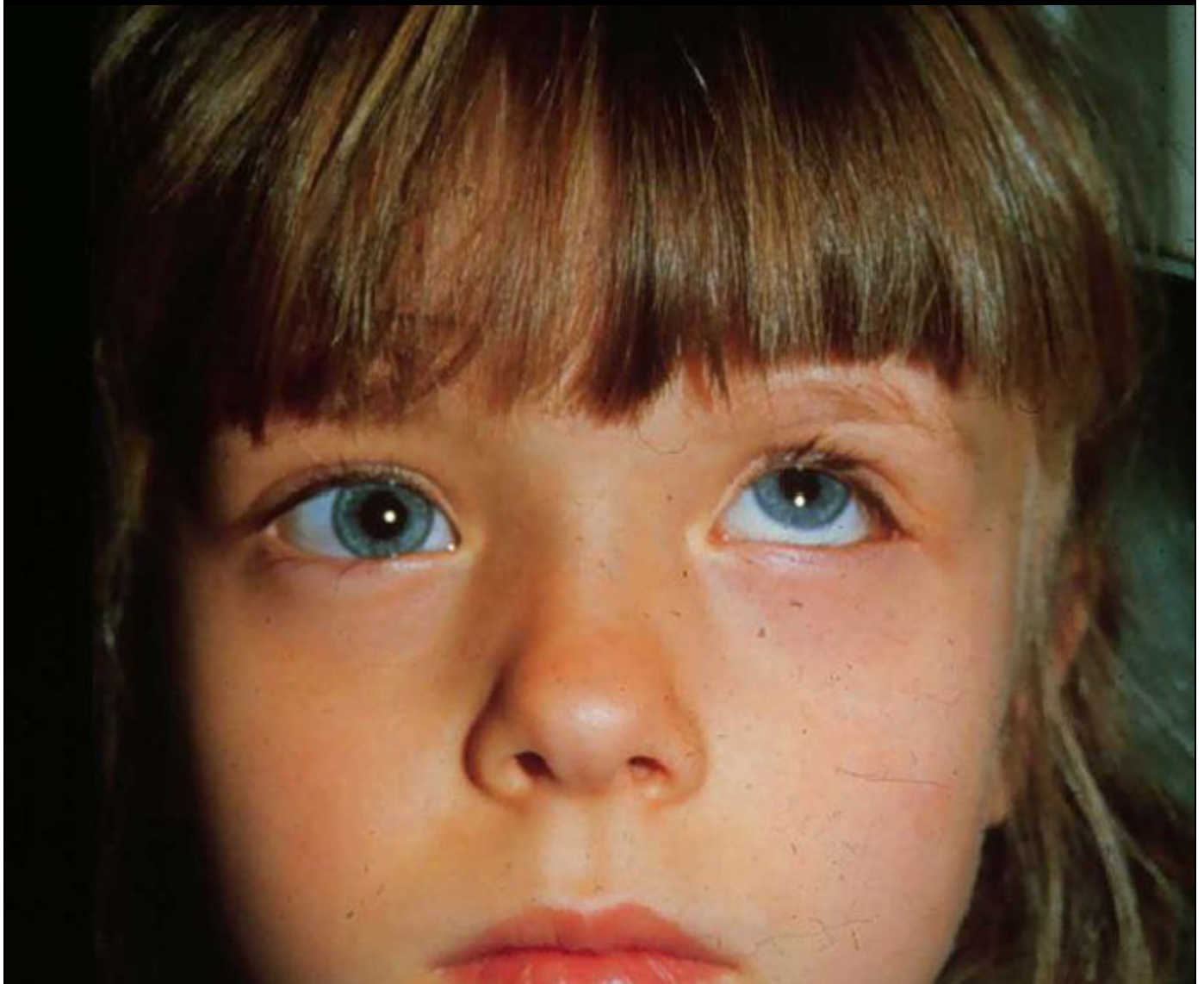Duane's syndrome

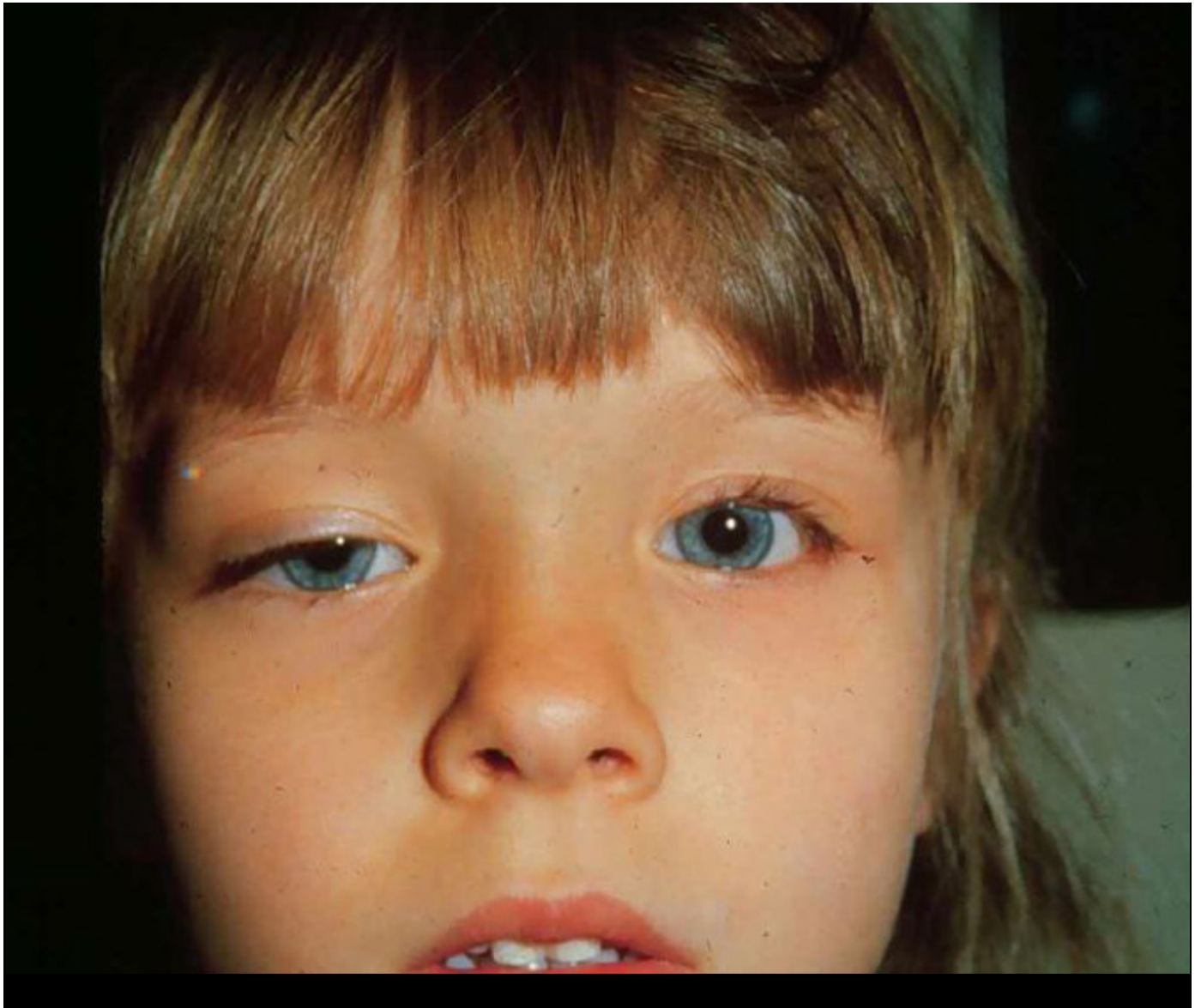

Eyeatlas

The online Atlas of Ophthalmology

Hypofunction of elevator muscle (left eye)



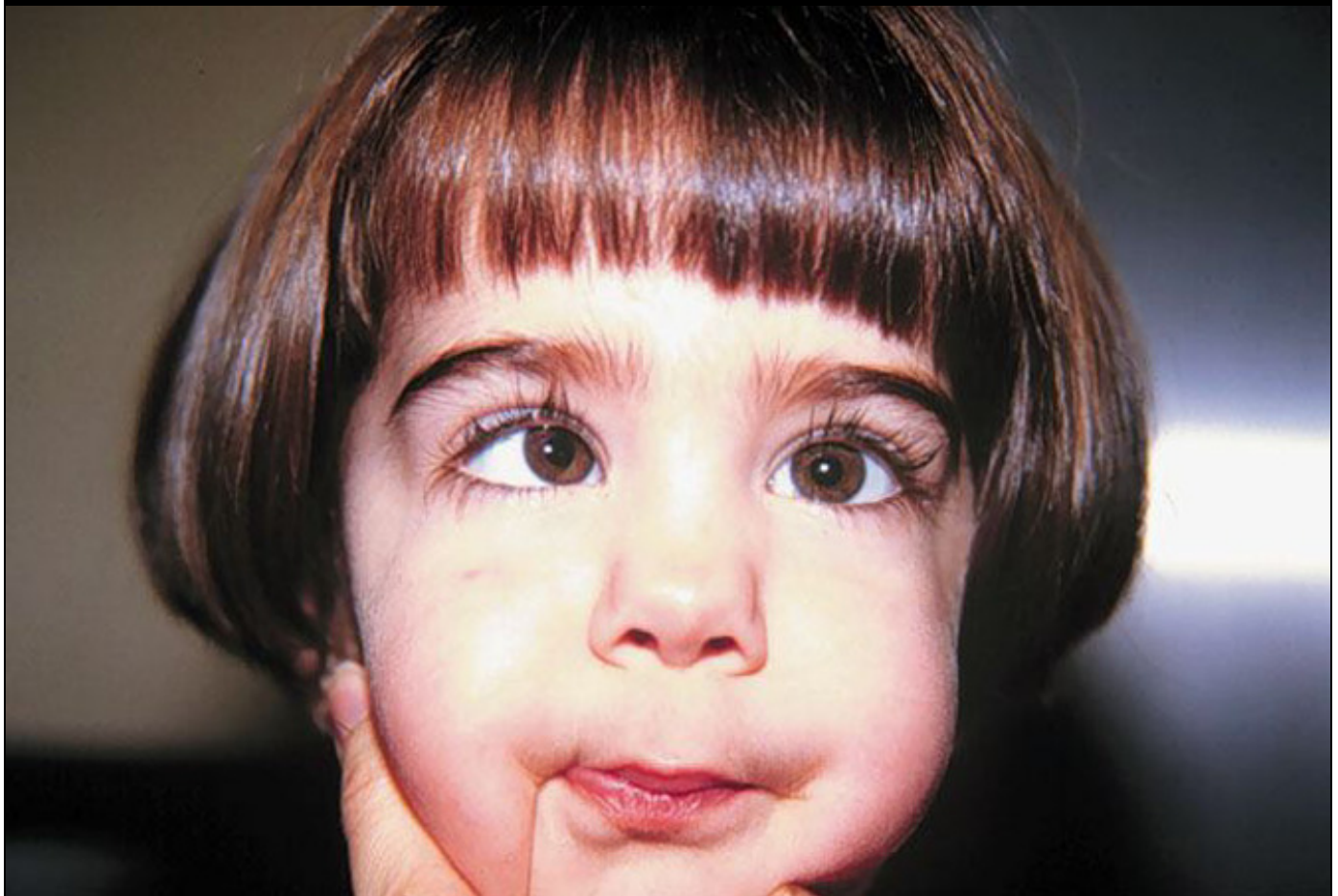

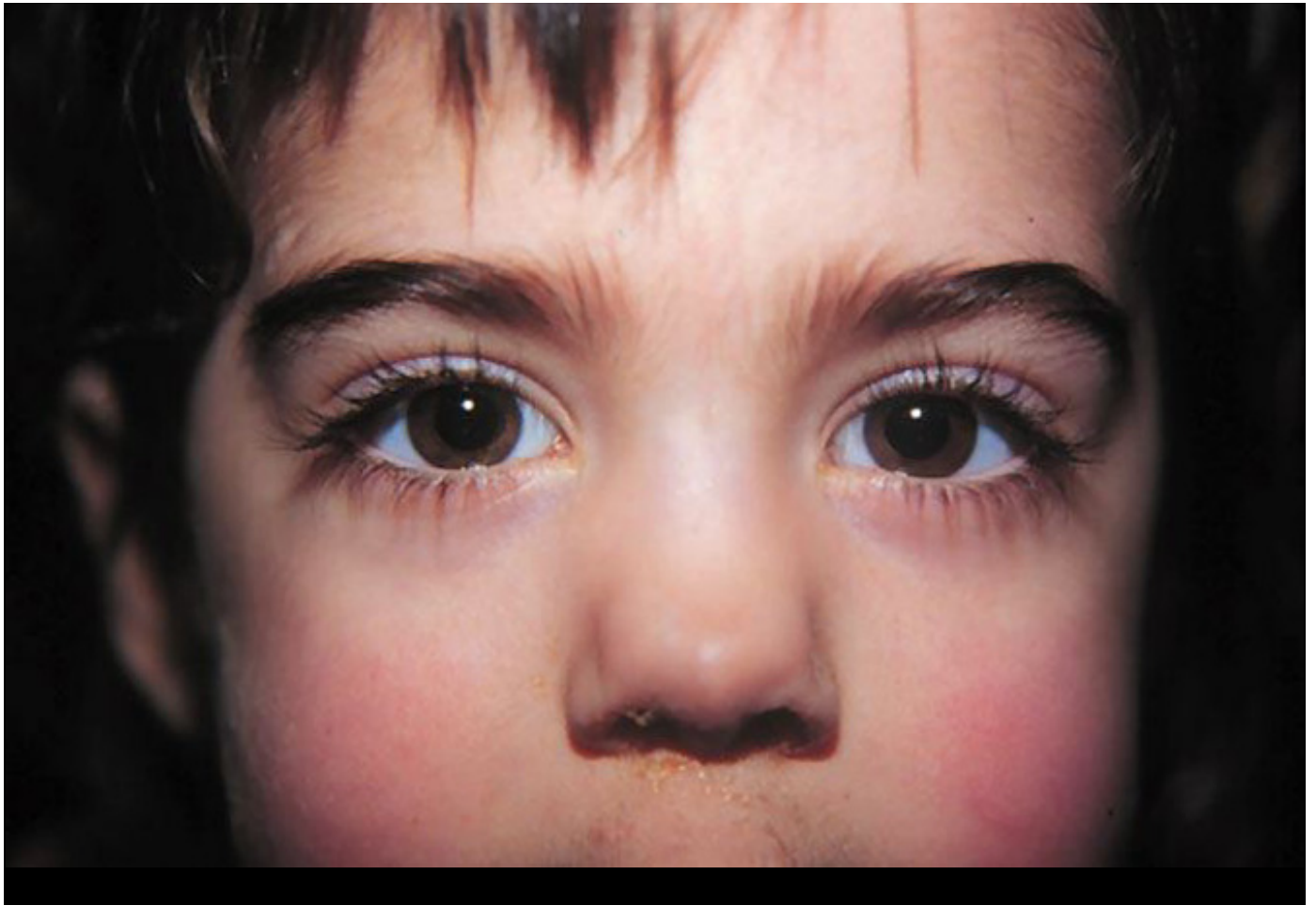© Copyright [Oculisti OnLine](#)

Eyeatlas

The online Atlas of Ophthalmology

Endotropia before and after Botox



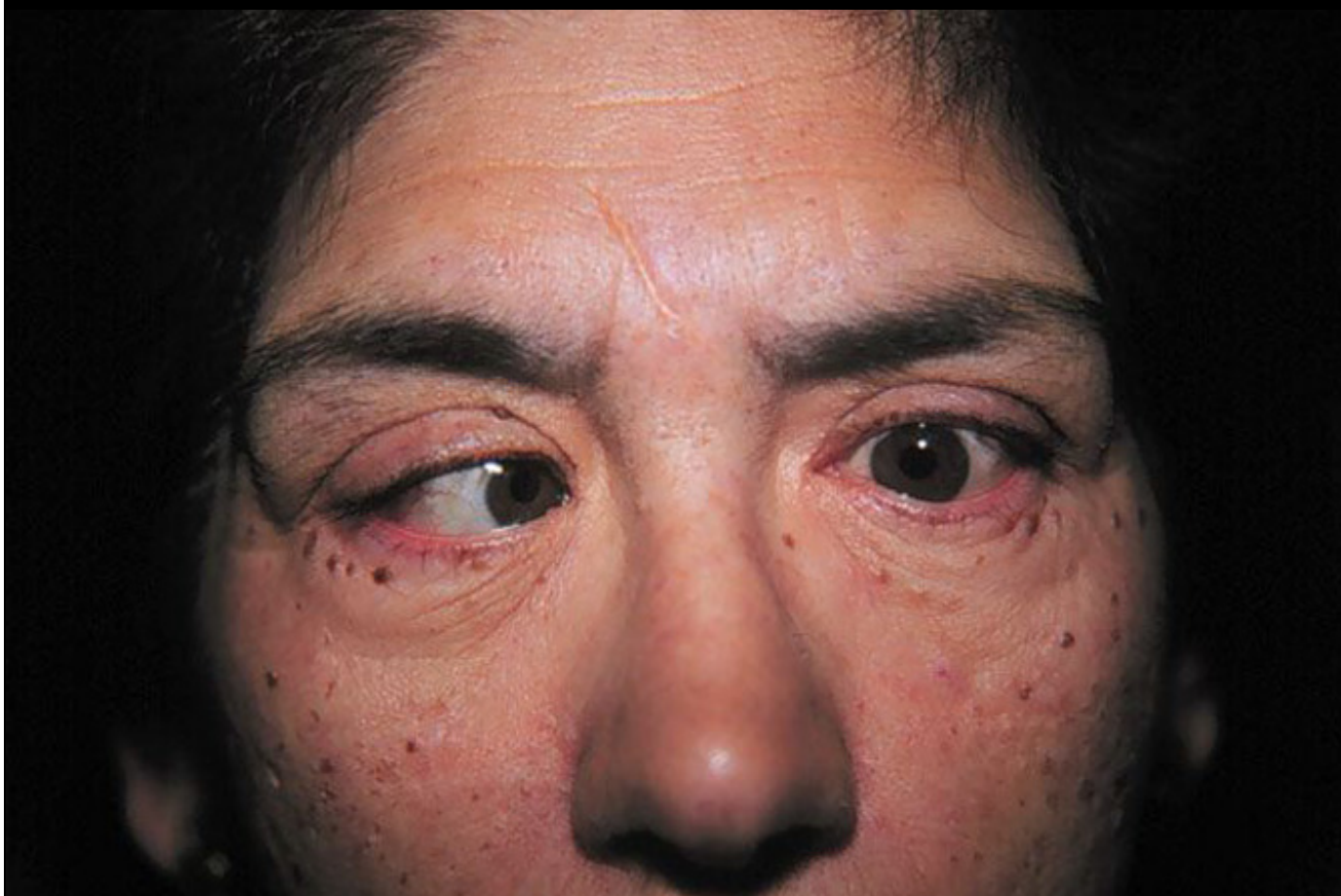

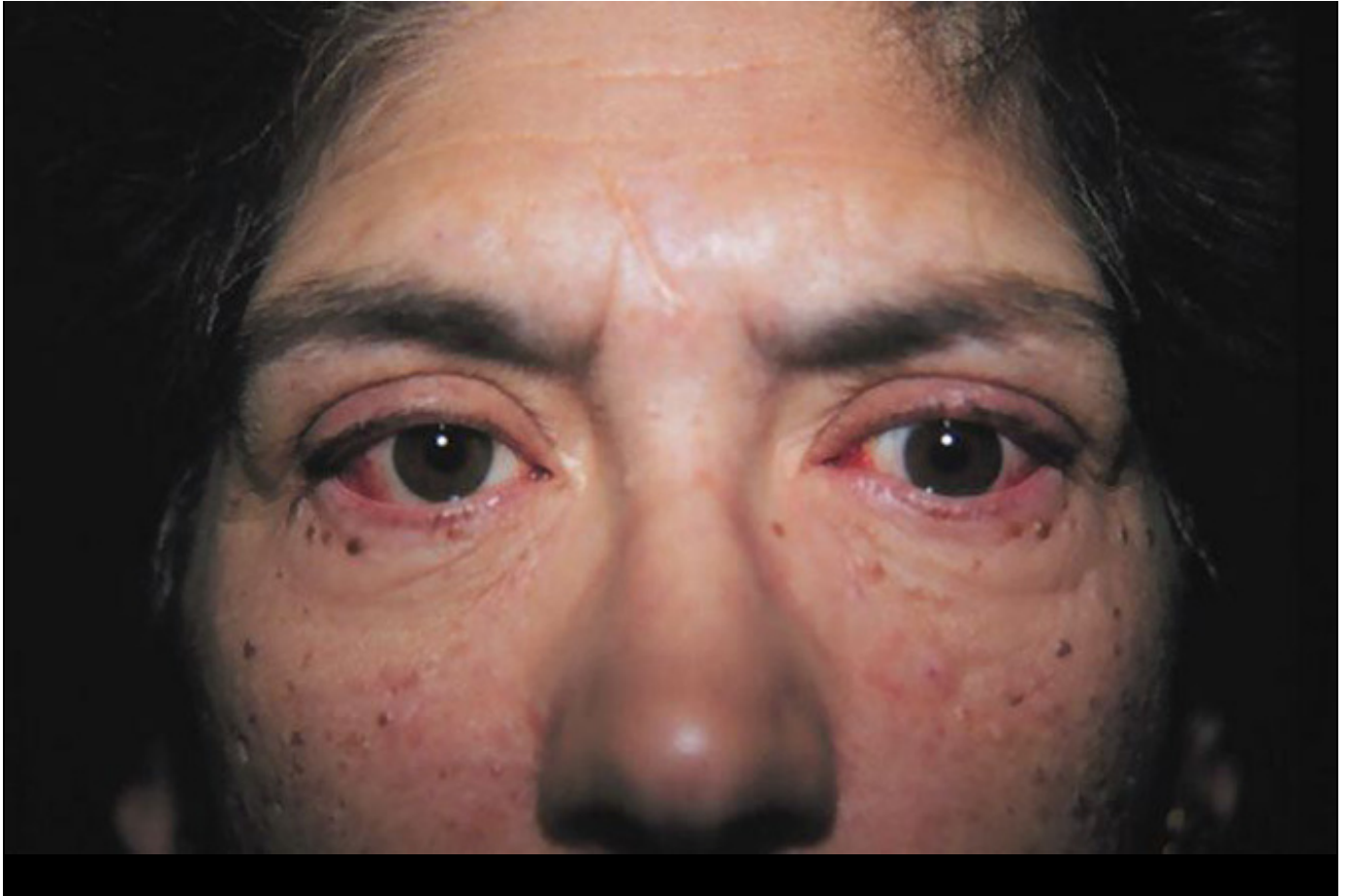© Copyright [Oculisti OnLine](#)

EyeAtlas

The online Atlas of Ophthalmology

Endotropia in high myopia before and after surgery



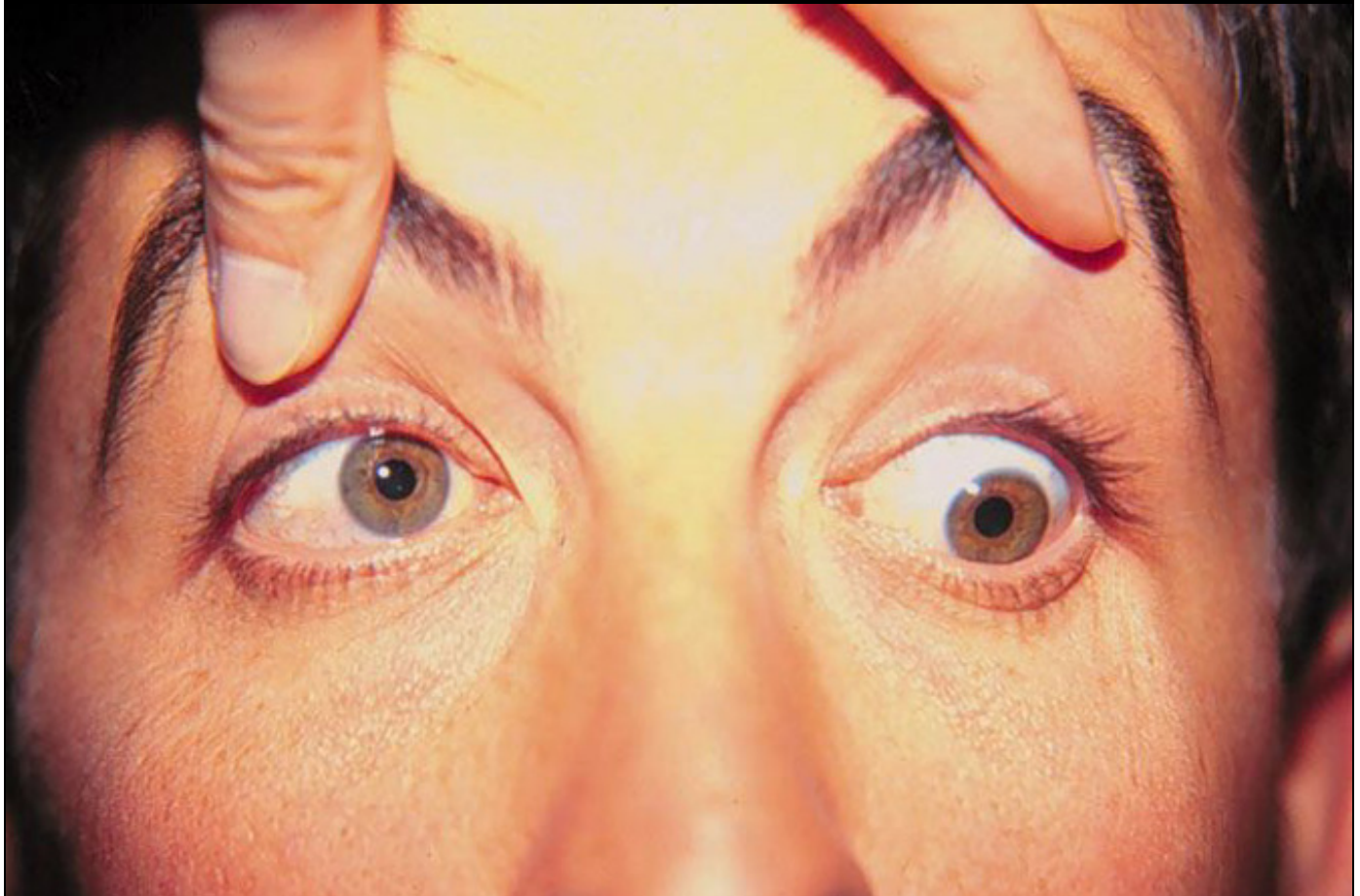

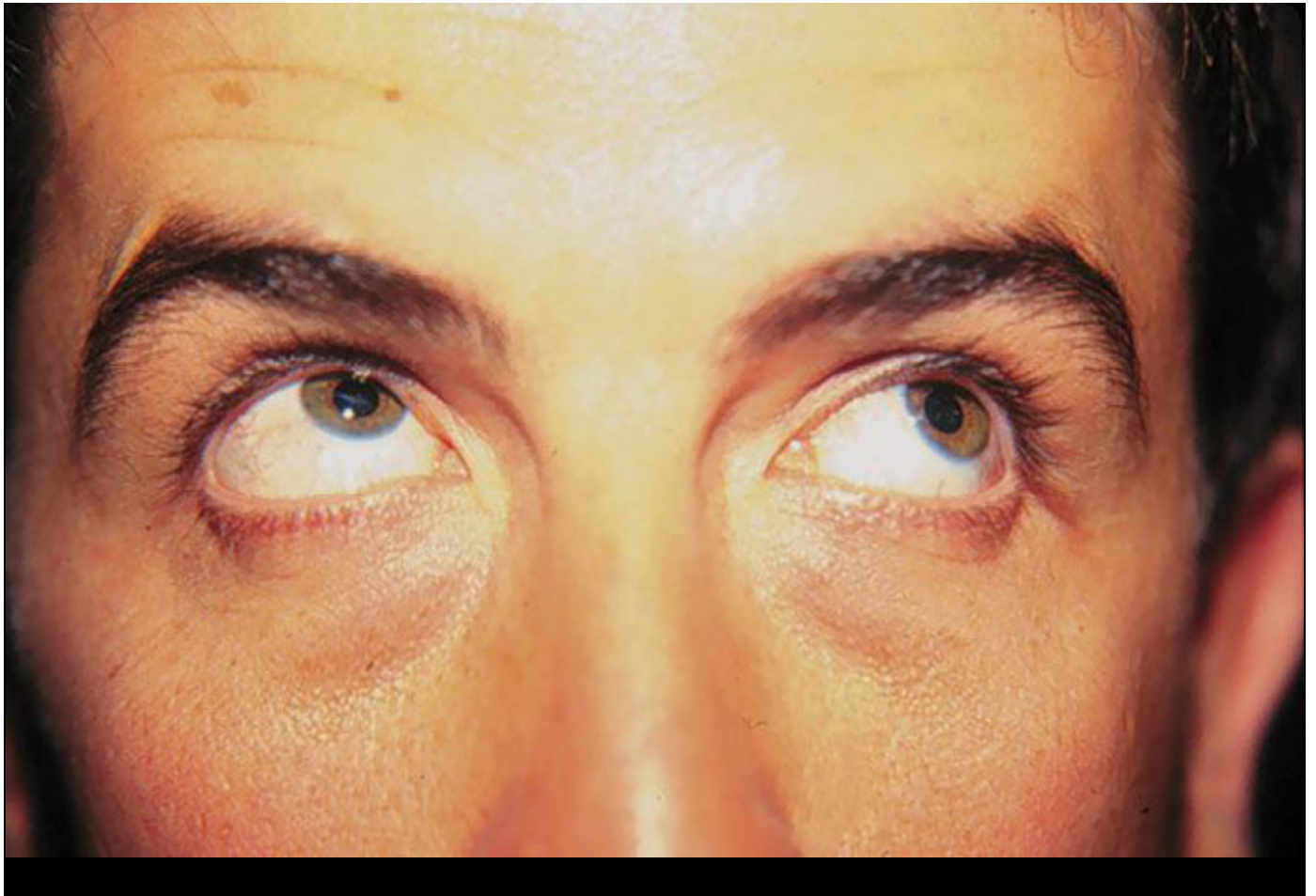© Copyright [Oculisti OnLine](#)

Eyeatlas

The online Atlas of Ophthalmology

Oblique superior muscle paralysis



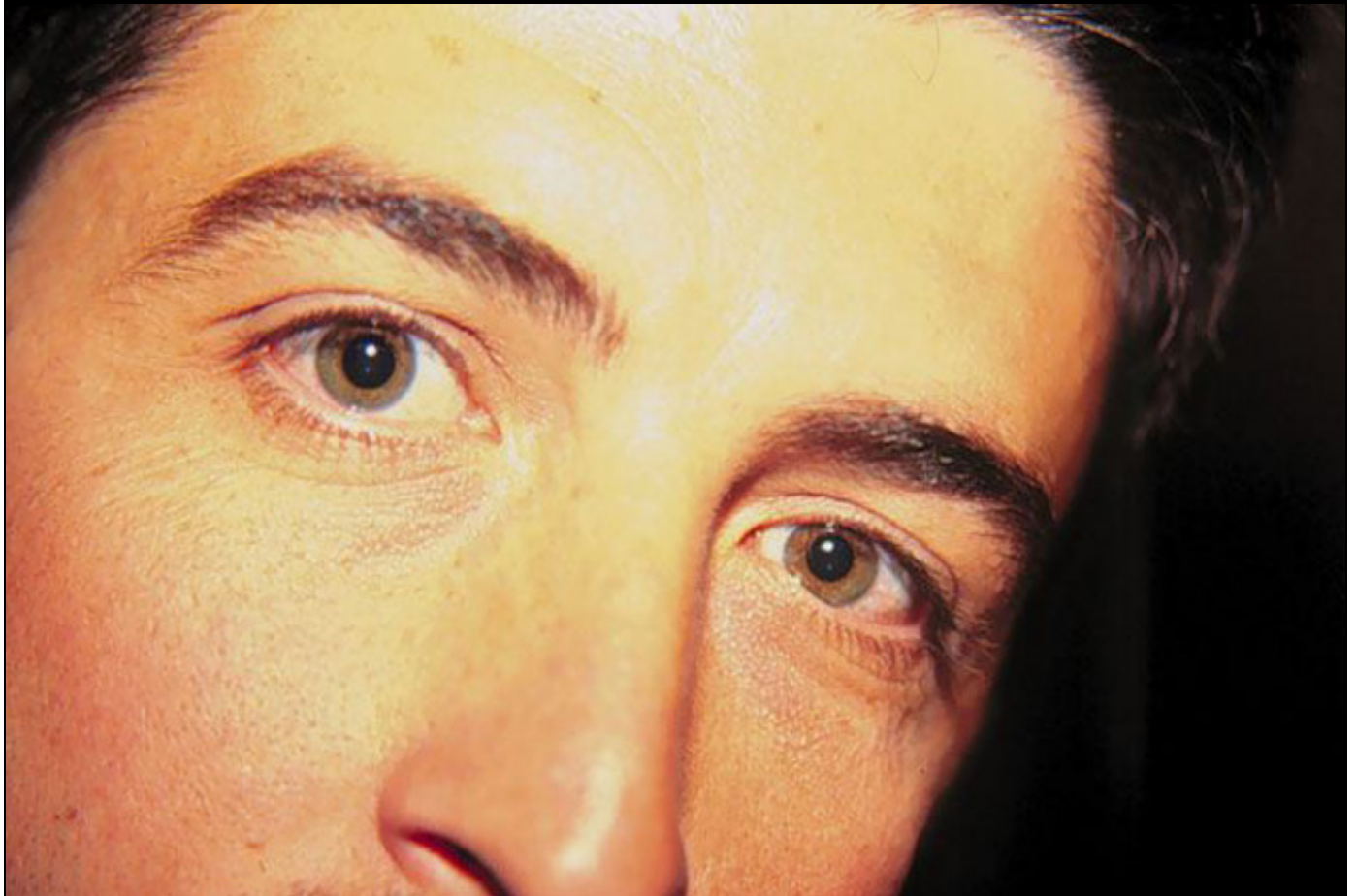

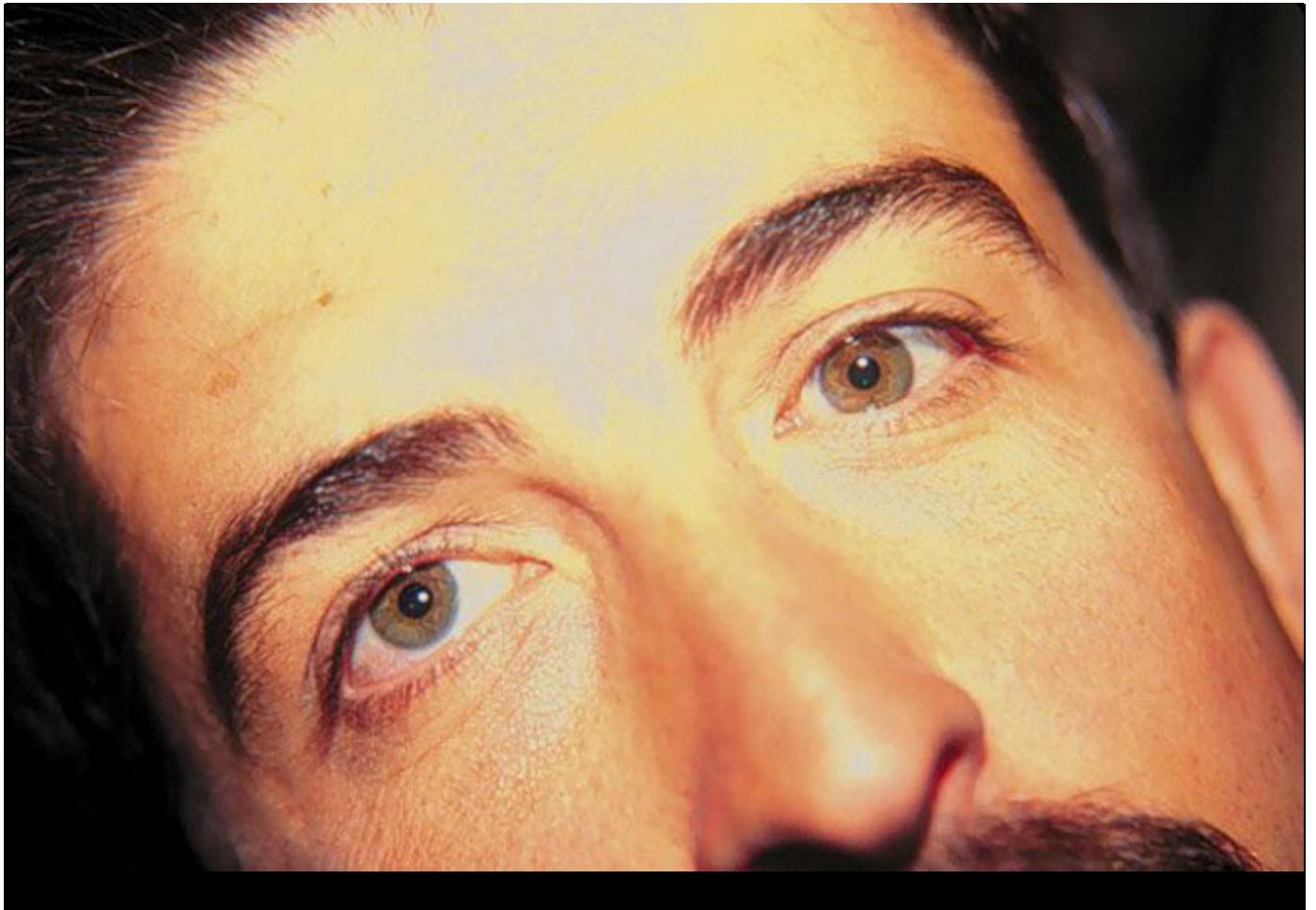© Copyright [Oculisti OnLine](#)

Eyeatlas

The online Atlas of Ophthalmology

Oblique superior muscle paralysis, Bielscowsky sign



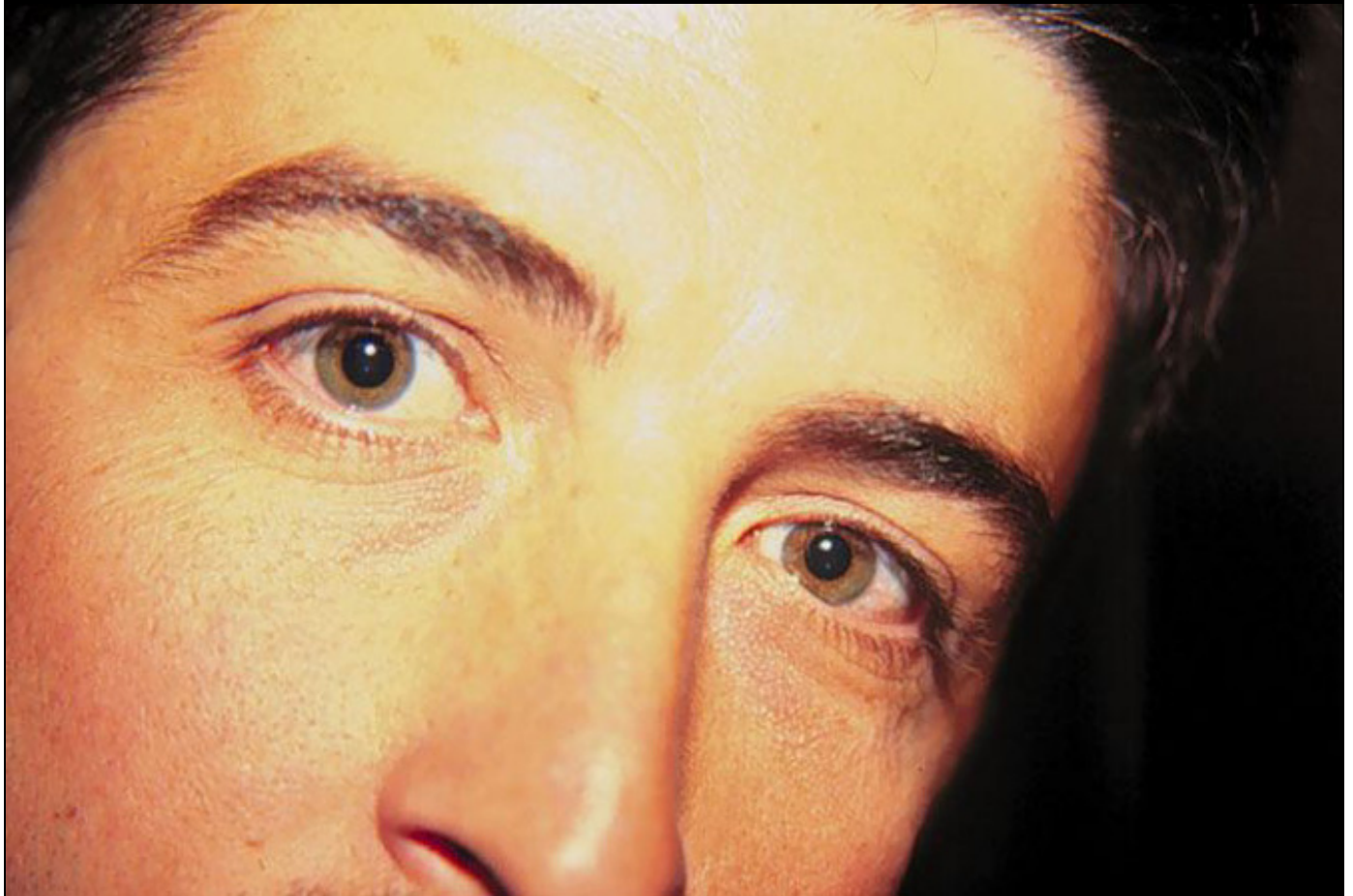

© Copyright [Oculisti OnLine](#)

Eyeatlas

The online Atlas of Ophthalmology

SLA pre and before surgery



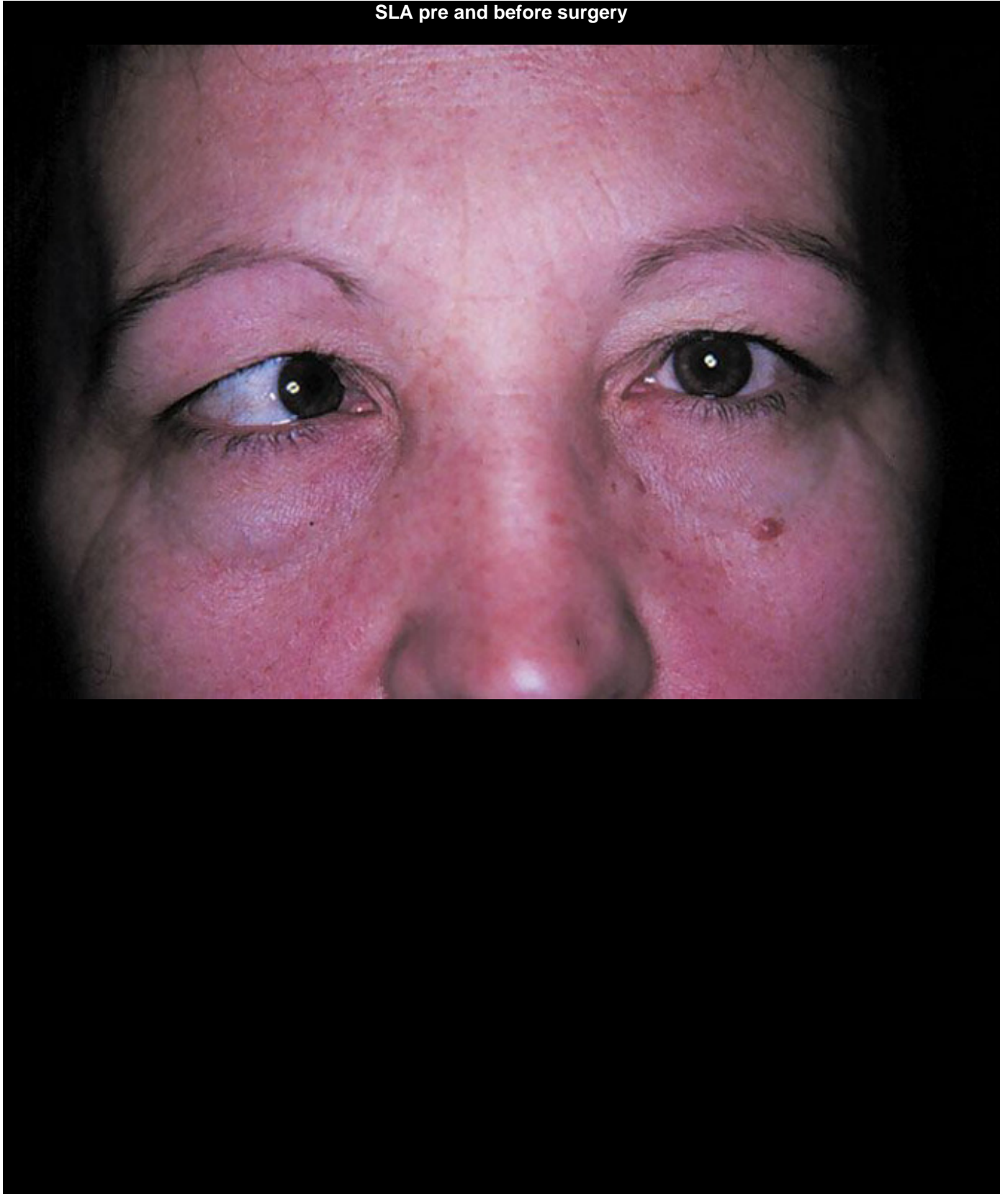

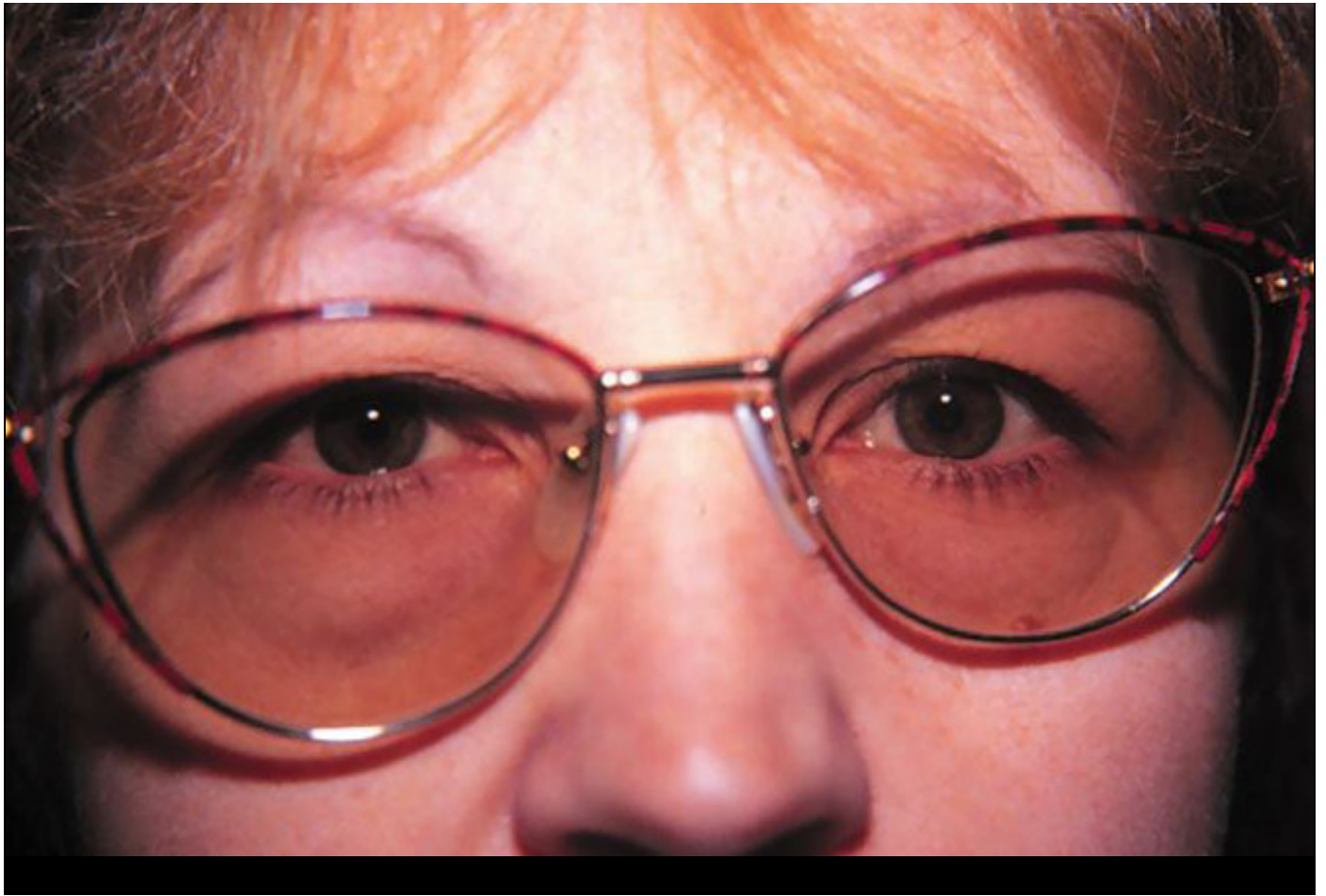© Copyright [Oculisti OnLine](#)

EyeAtlas

The online Atlas of Ophthalmology

SLA pre and before surgery



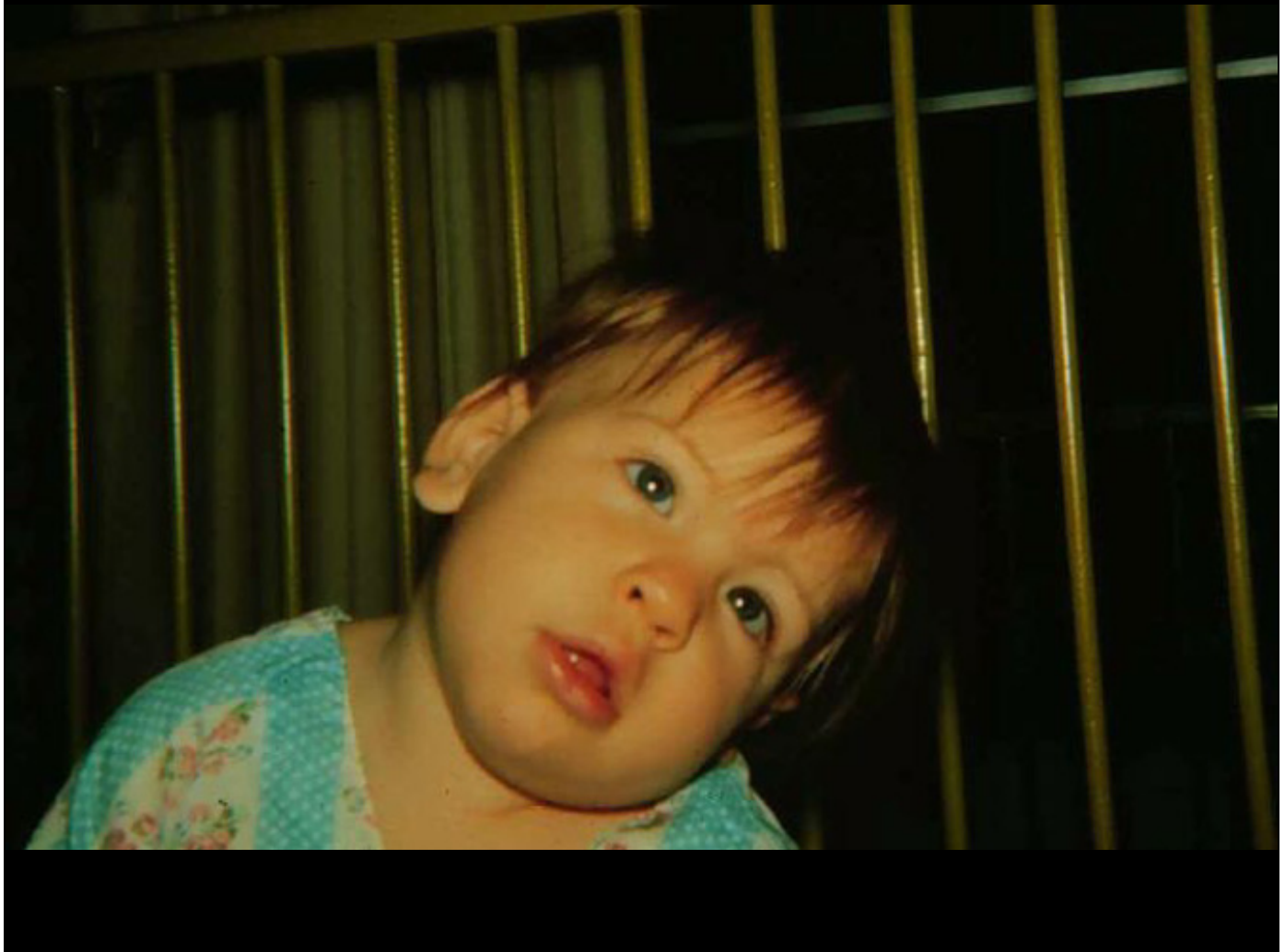

© Copyright [Oculisti OnLine](#)

EyeAtlas

The online Atlas of Ophthalmology

Patient with tilt

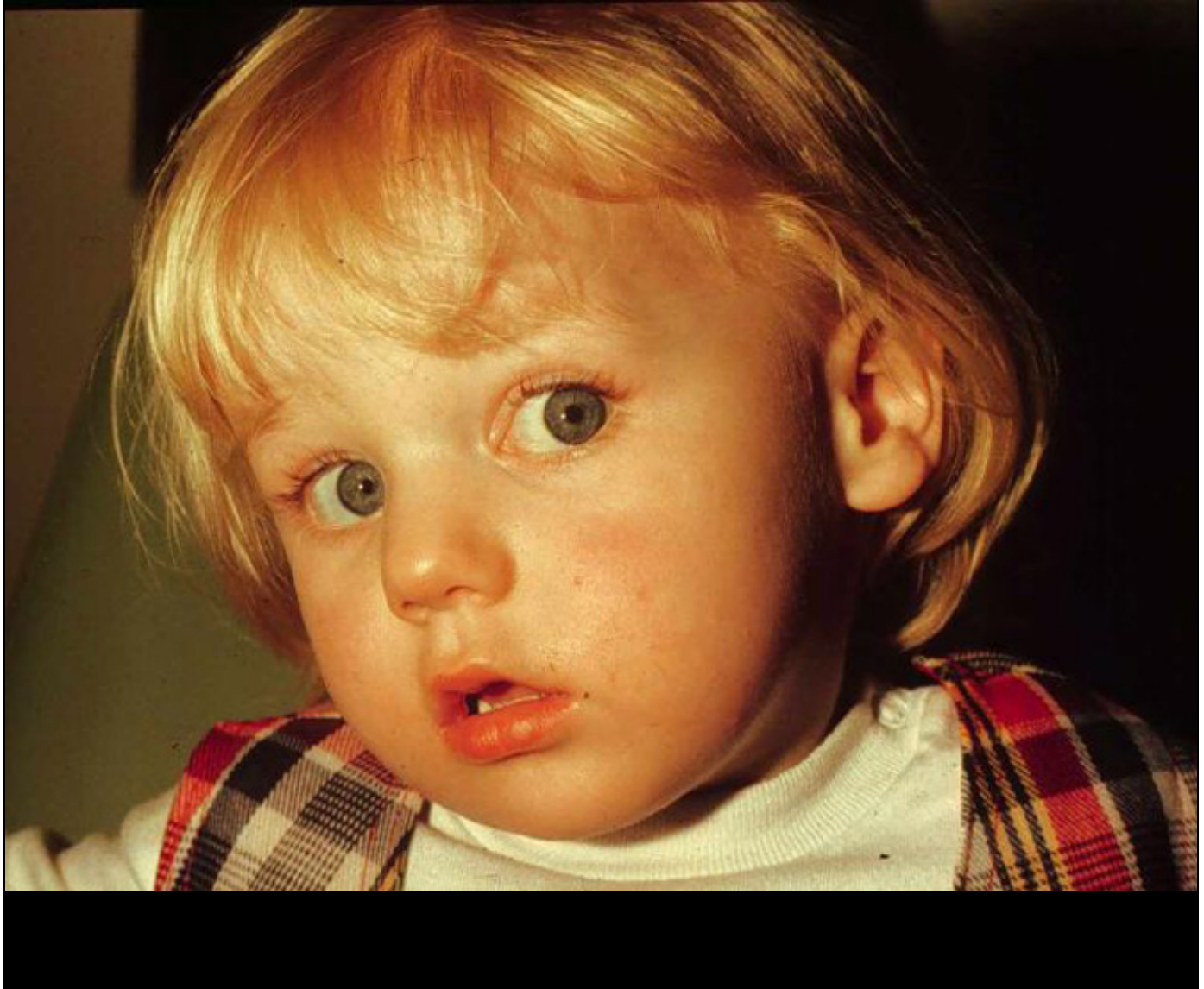

© Copyright [Oculisti OnLine](#)

EyeAtlas

The online Atlas of Ophthalmology

Patient with tilt



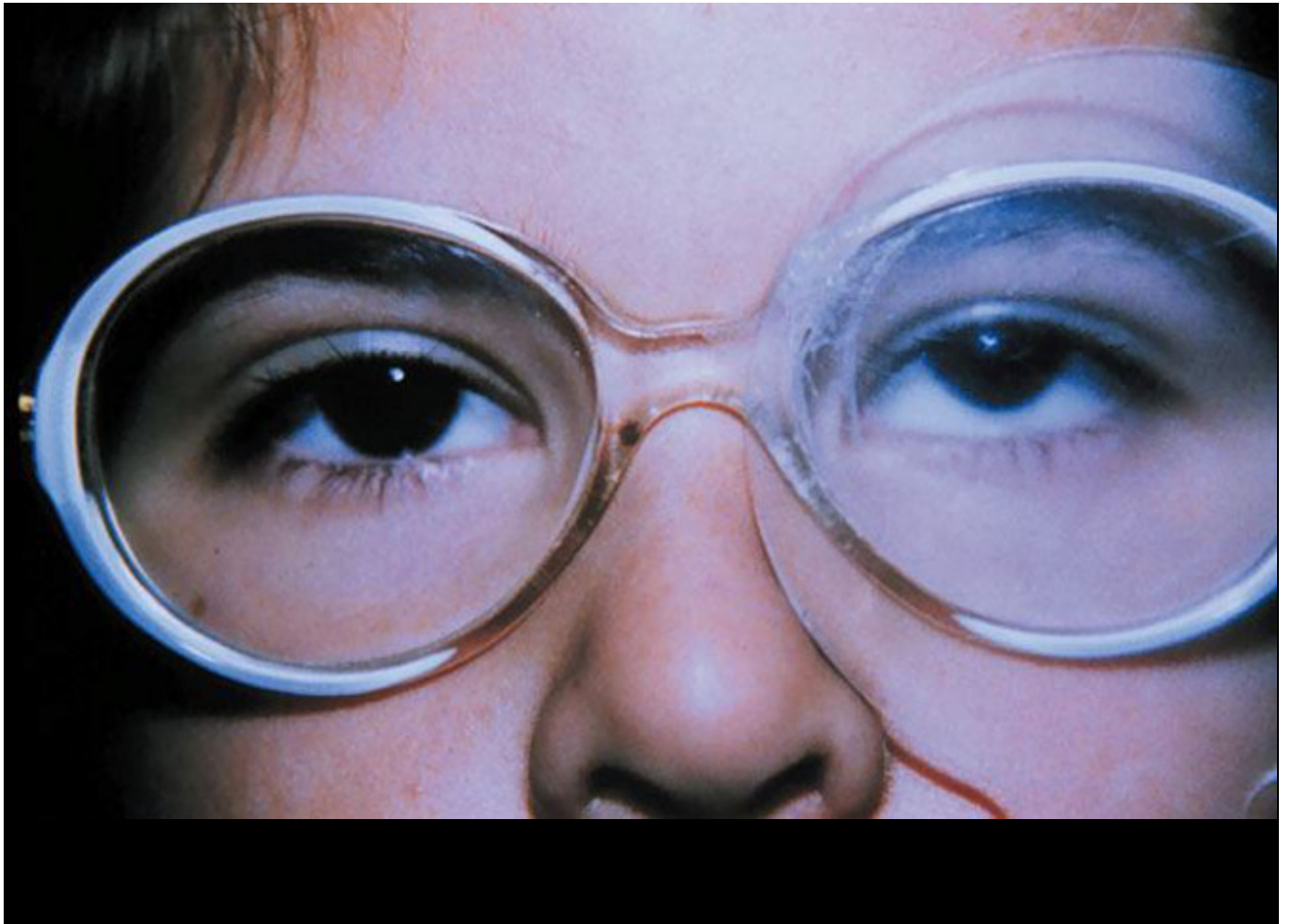© Copyright [Oculisti OnLine](http://www.eyeatlas.com)

Eyeatlas

The online Atlas of Ophthalmology

Vertical dissociated deviation



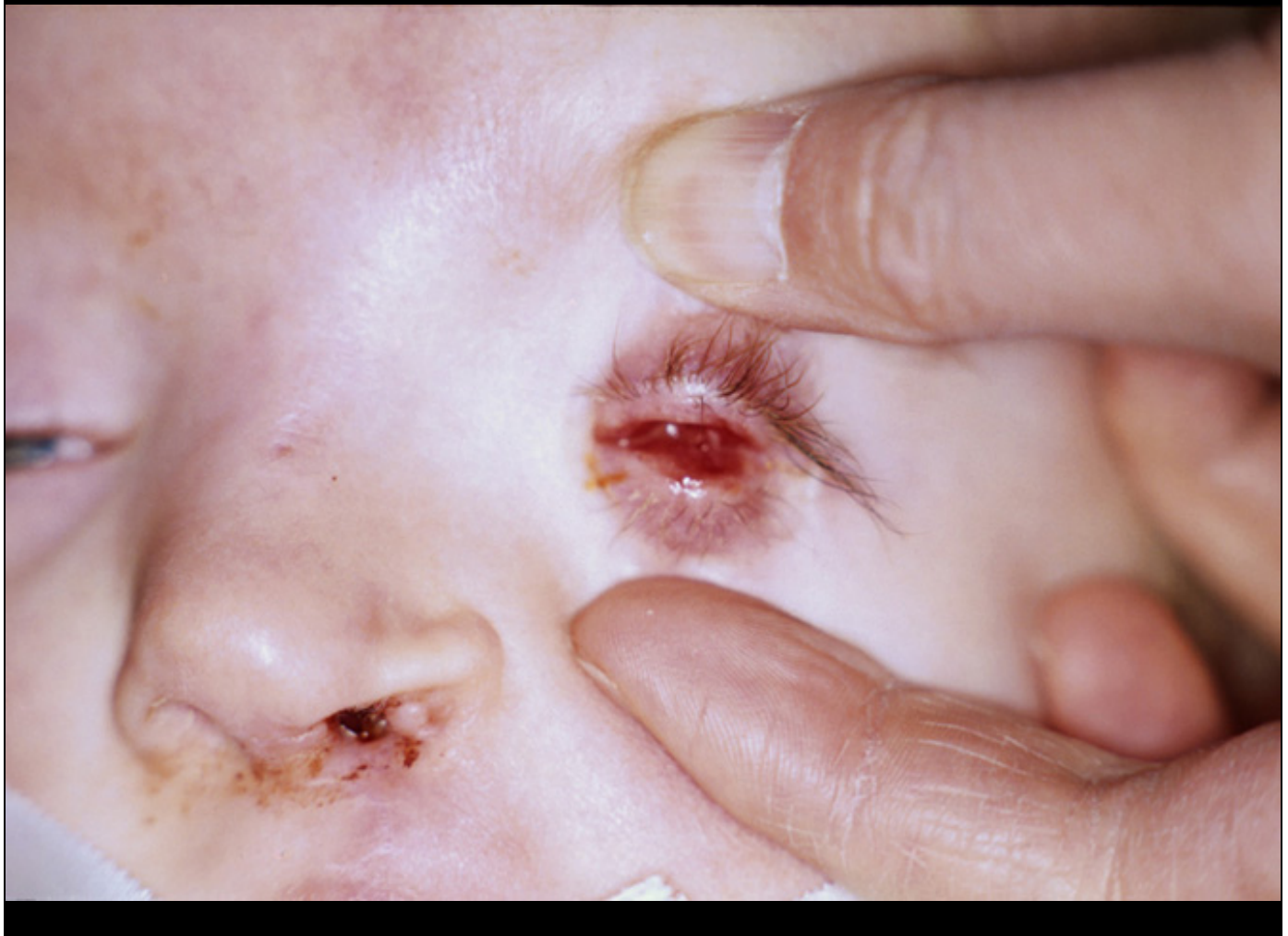

© Copyright [Oculisti OnLine](#)

EyeAtlas

The online Atlas of Ophthalmology

Anophthalmos

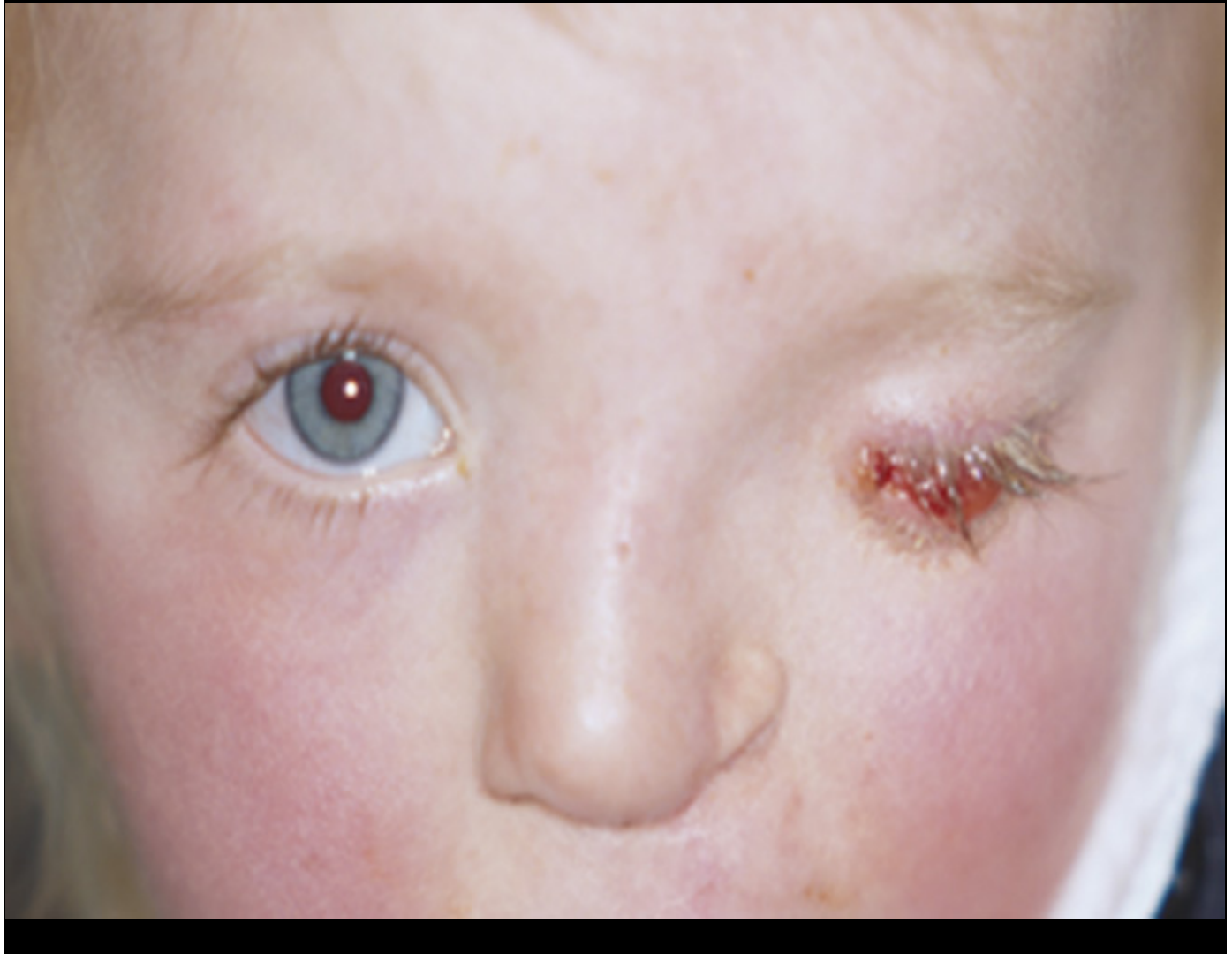

© Copyright [Oculisti OnLine](#)

EyeAtlas

The online Atlas of Ophthalmology

Anophthalmos



© Copyright [Oculisti OnLine](#)

EyeAtlas

The online Atlas of Ophthalmology

Angle recession

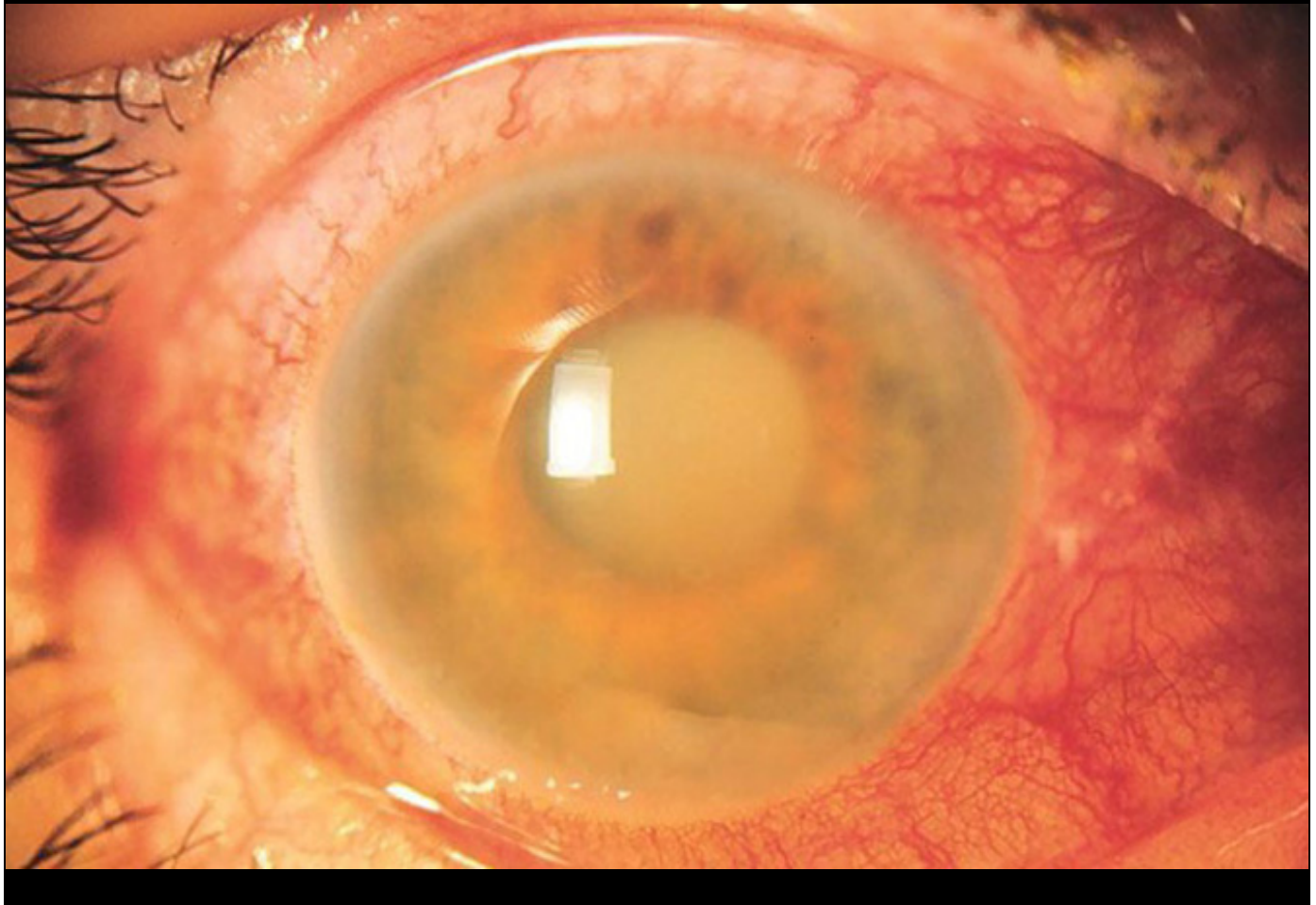


© Copyright [Oculisti OnLine](#)

EyeAtlas

The online Atlas of Ophthalmology

Phacolytic acute glaucoma

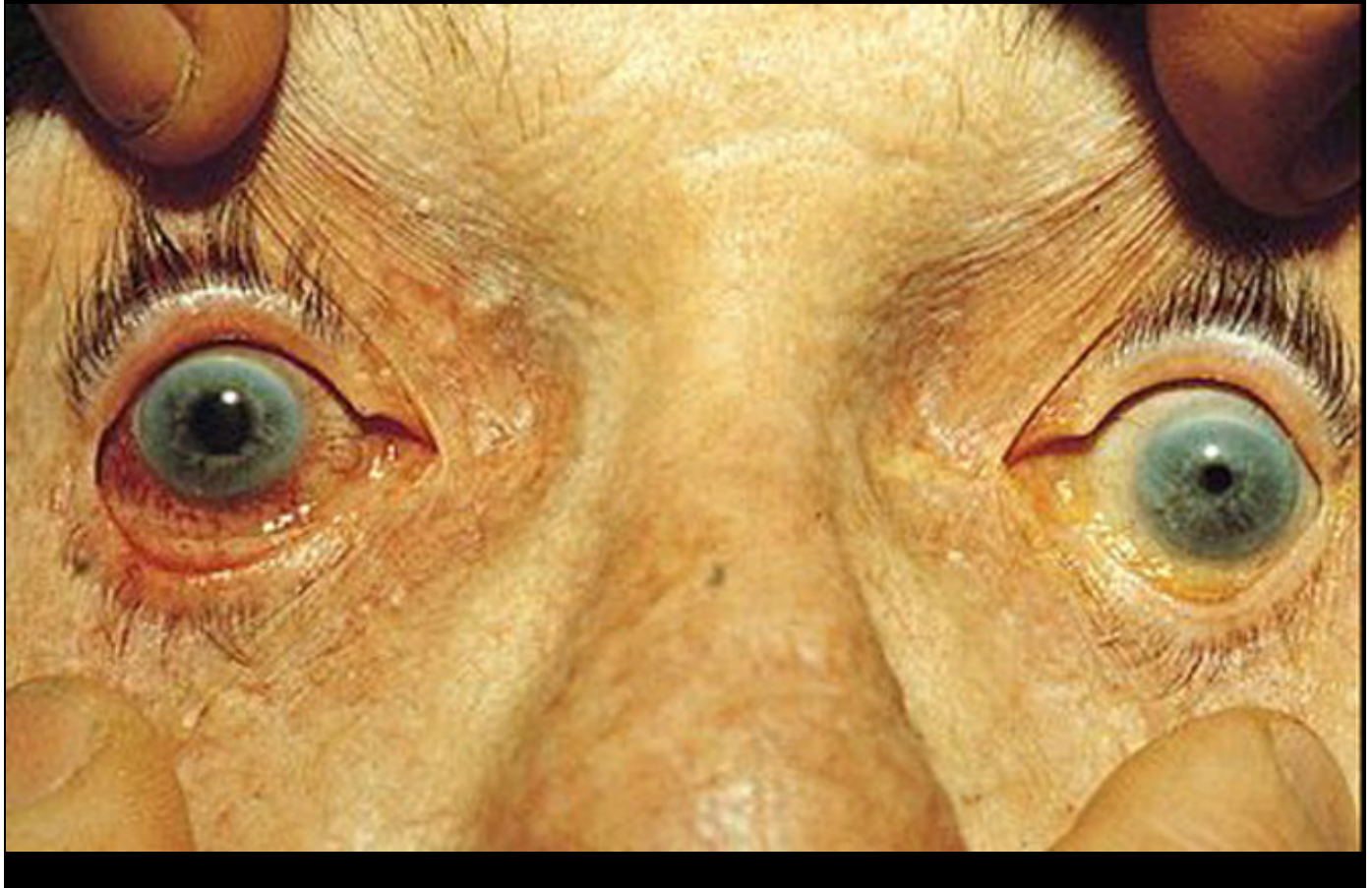

© Copyright [Oculisti OnLine](http://www.eyeatlas.com)

Eyeatlas

The online Atlas of Ophthalmology

Acute glaucoma (closure angle)

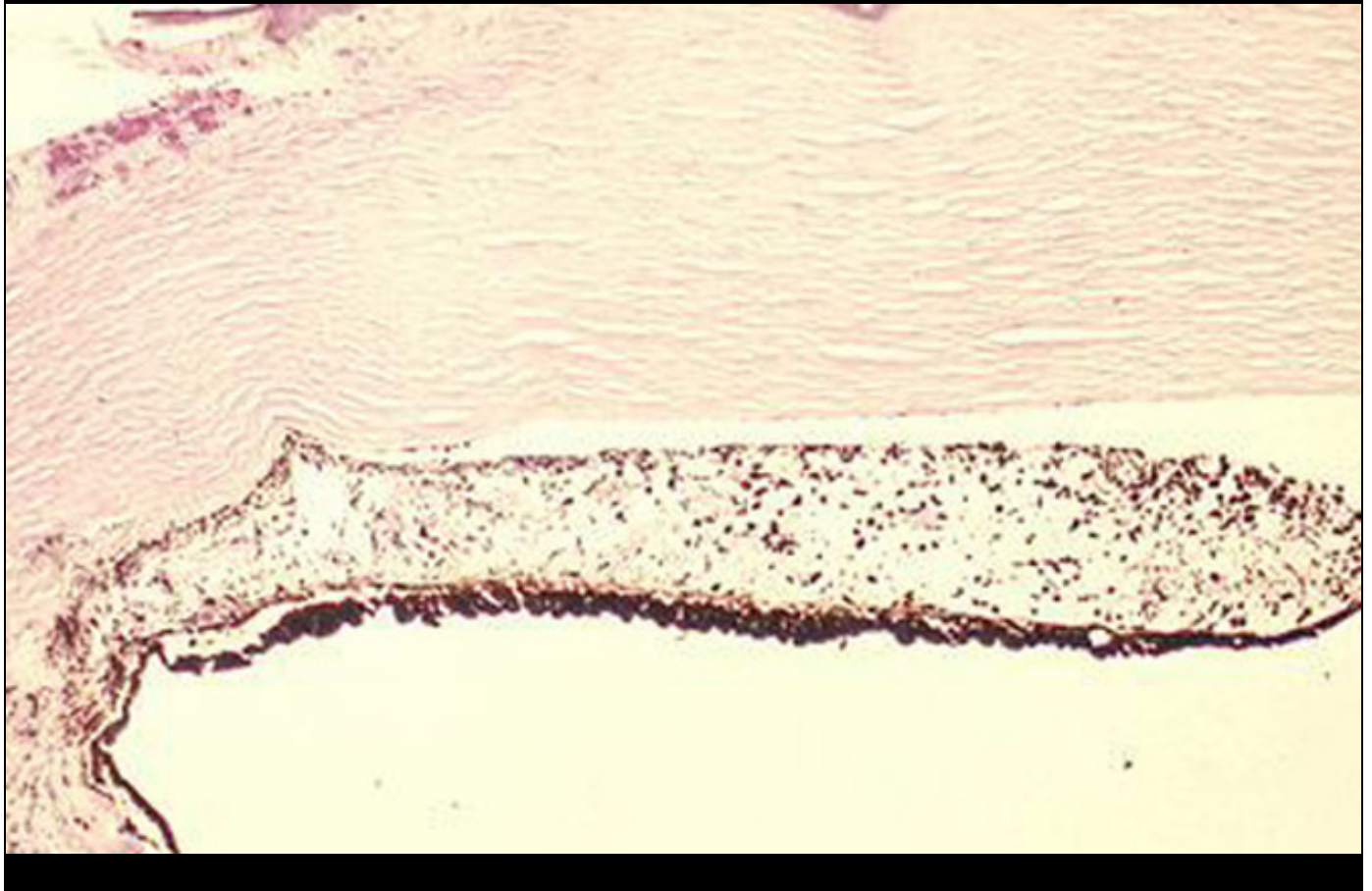


© Copyright [Oculisti OnLine](#)

Eyeatlas

The online Atlas of Ophthalmology

Acute glaucoma (closure angle)

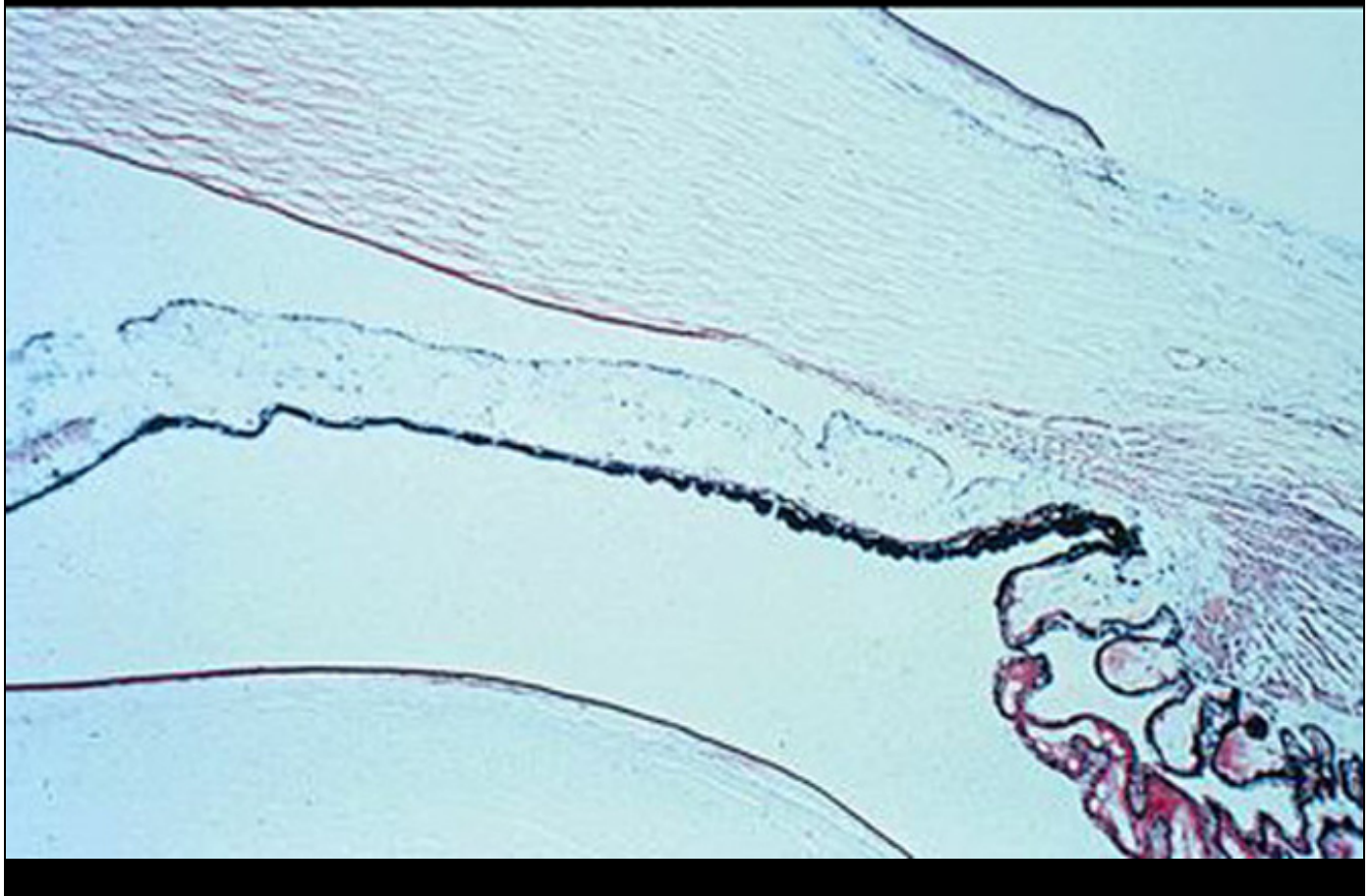

© Copyright [Oculisti OnLine](#)

EyeAtlas

The online Atlas of Ophthalmology

Acute glaucoma (closure angle)

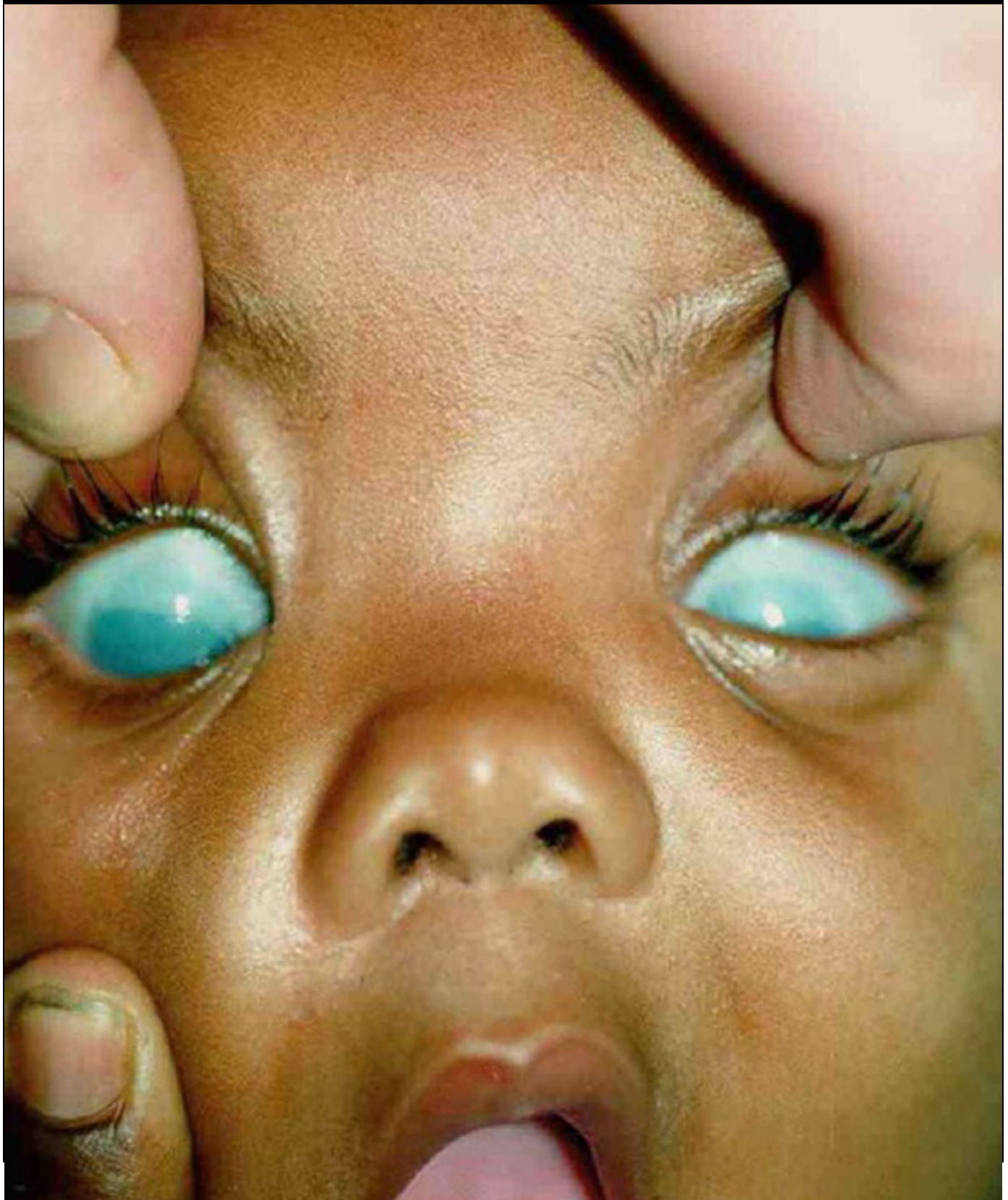


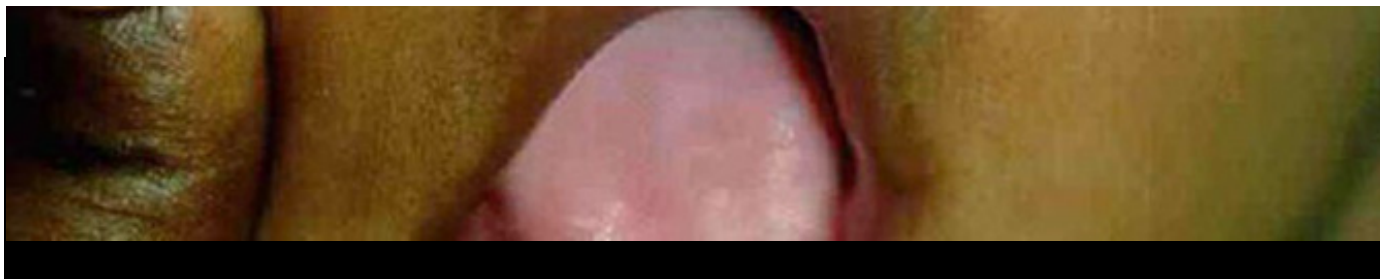© Copyright [Oculisti OnLine](#)

Eyeatlas

The online Atlas of Ophthalmology

Bilateral congenital glaucoma



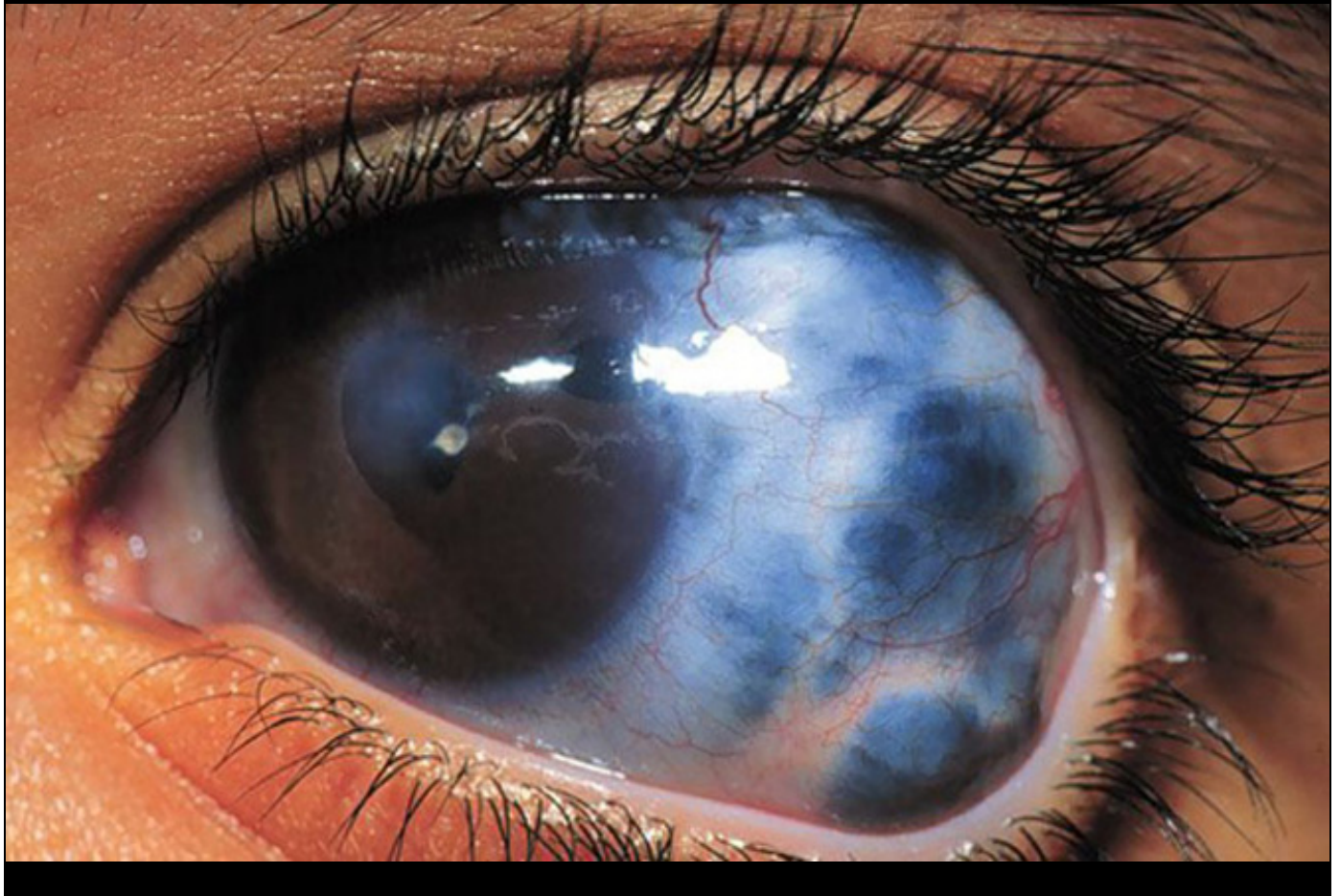


© Copyright [Oculisti OnLine](#)

EyeAtlas

The online Atlas of Ophthalmology

Bilateral congenital glaucoma and buphtalmos

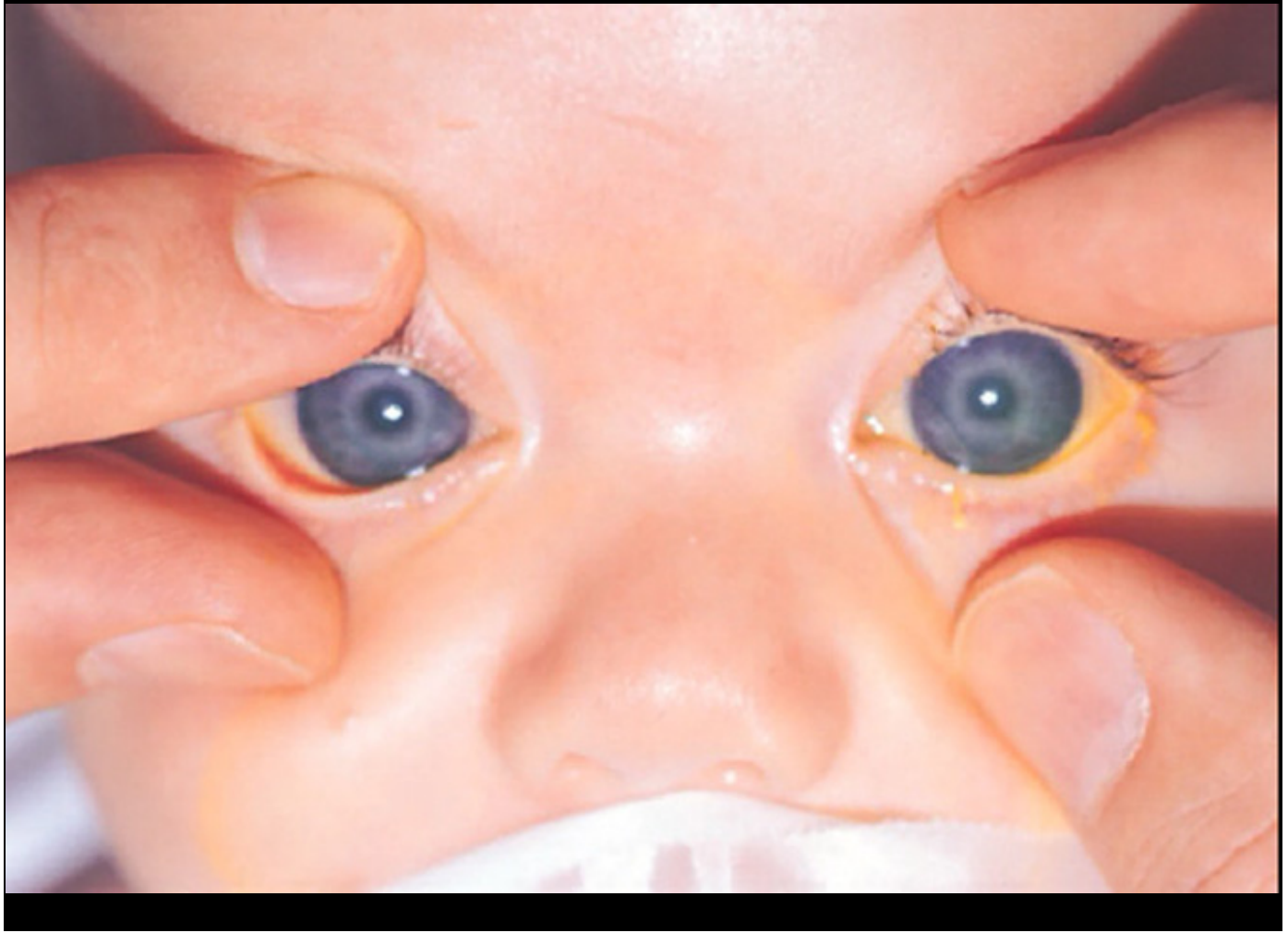

© Copyright [Oculisti OnLine](#)

EyeAtlas

The online Atlas of Ophthalmology

Congenital glaucoma

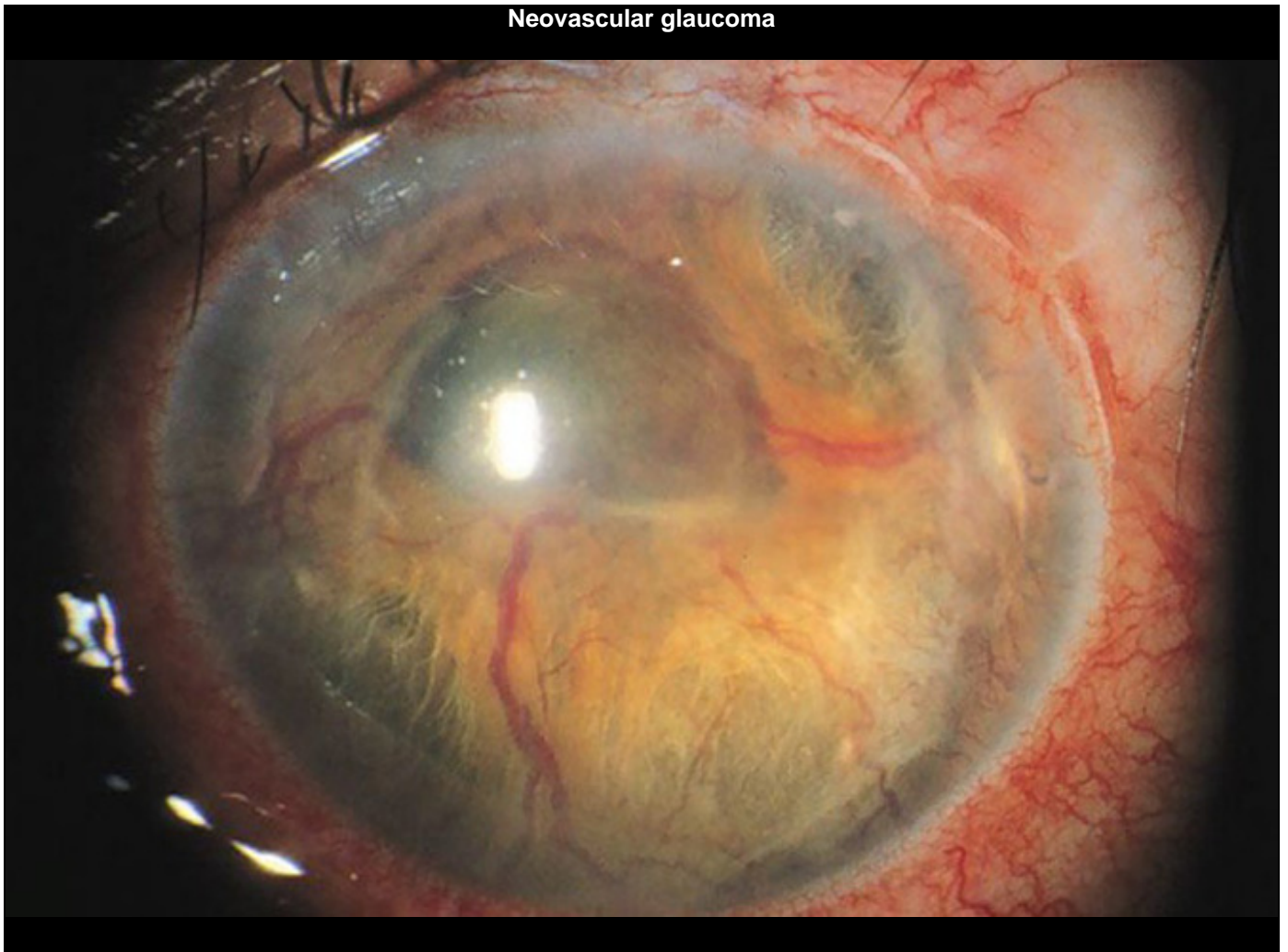


© Copyright [Oculisti OnLine](#)

EyeAtlas

The online Atlas of Ophthalmology

Neovascular glaucoma

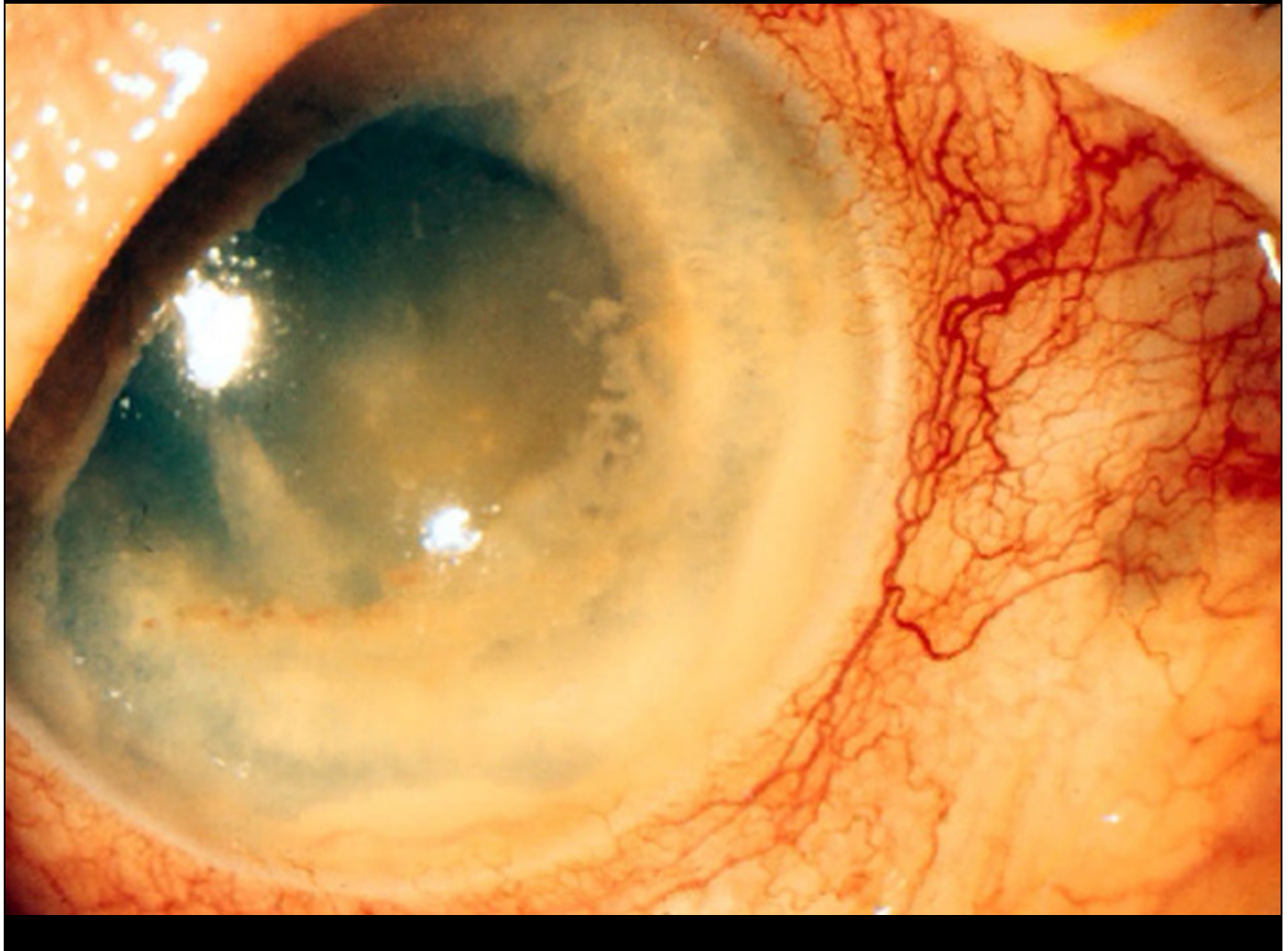


© Copyright [Oculisti OnLine](http://www.eyeatlas.com)

EyeAtlas

The online Atlas of Ophthalmology

Phacolytic glaucoma

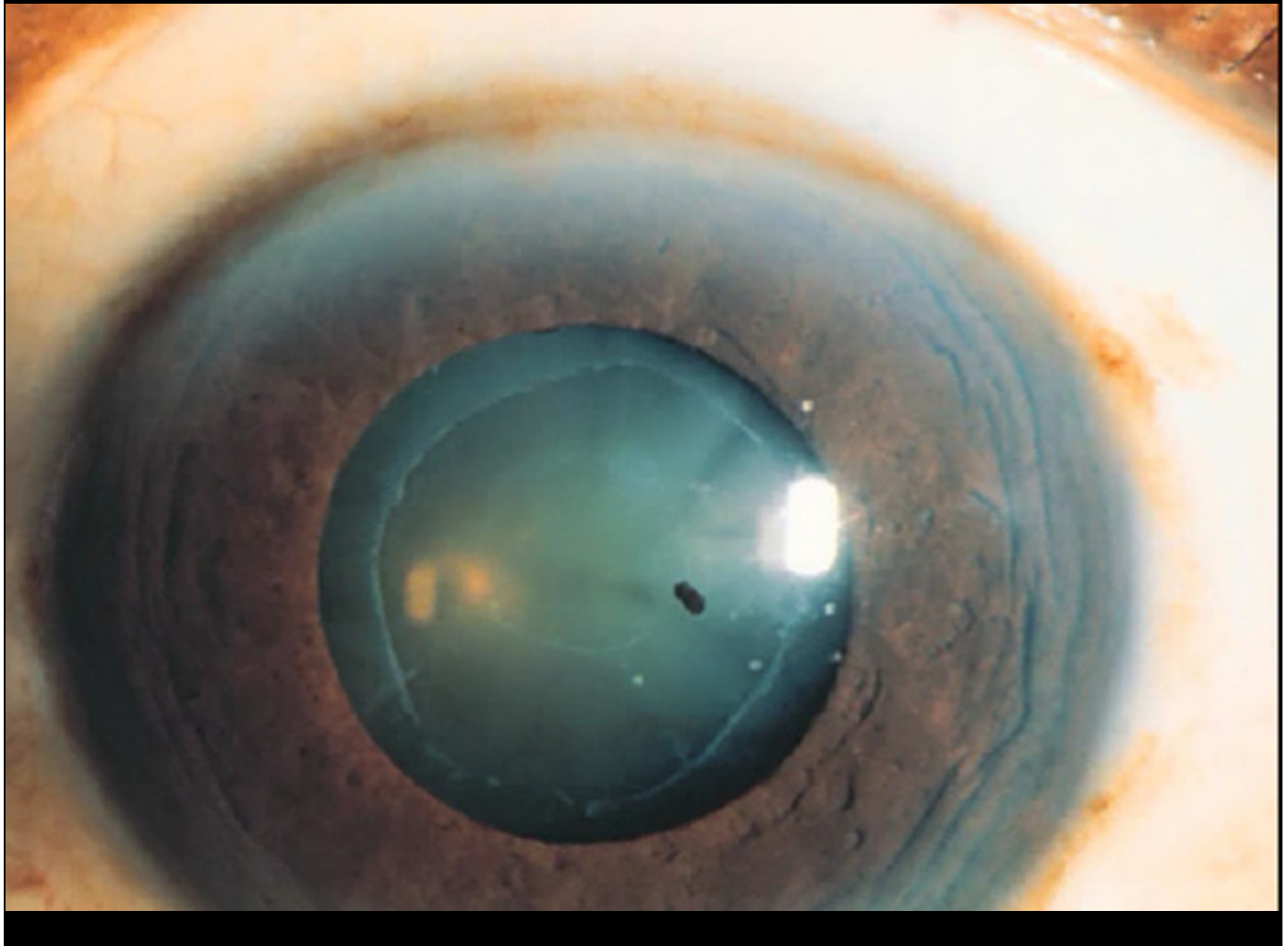


© Copyright [Oculisti OnLine](#)

EyeAtlas

The online Atlas of Ophthalmology

Pseudoexfoliative glaucoma

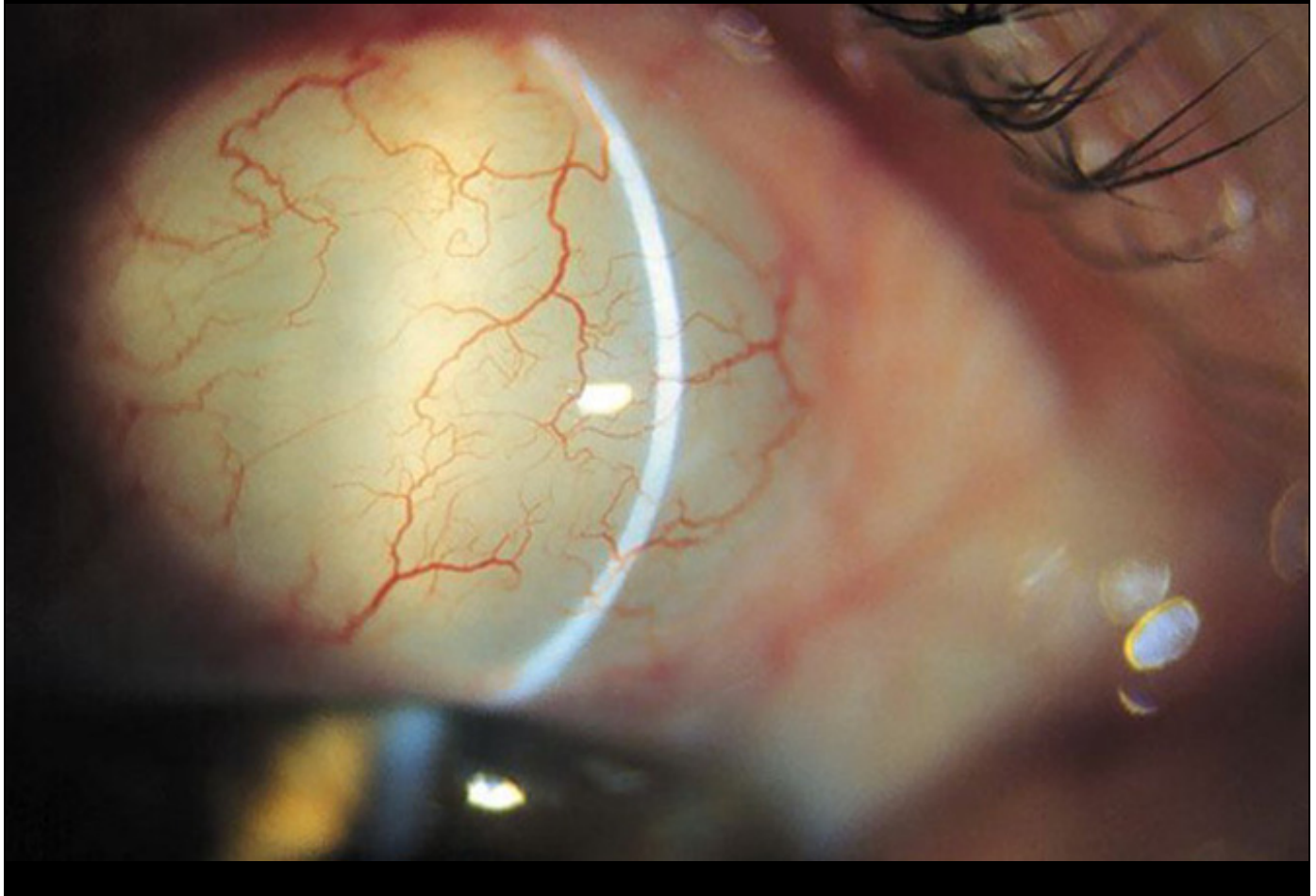


© Copyright [Oculisti OnLine](#)

EyeAtlas

The online Atlas of Ophthalmology

Bleb after trabeculectomy

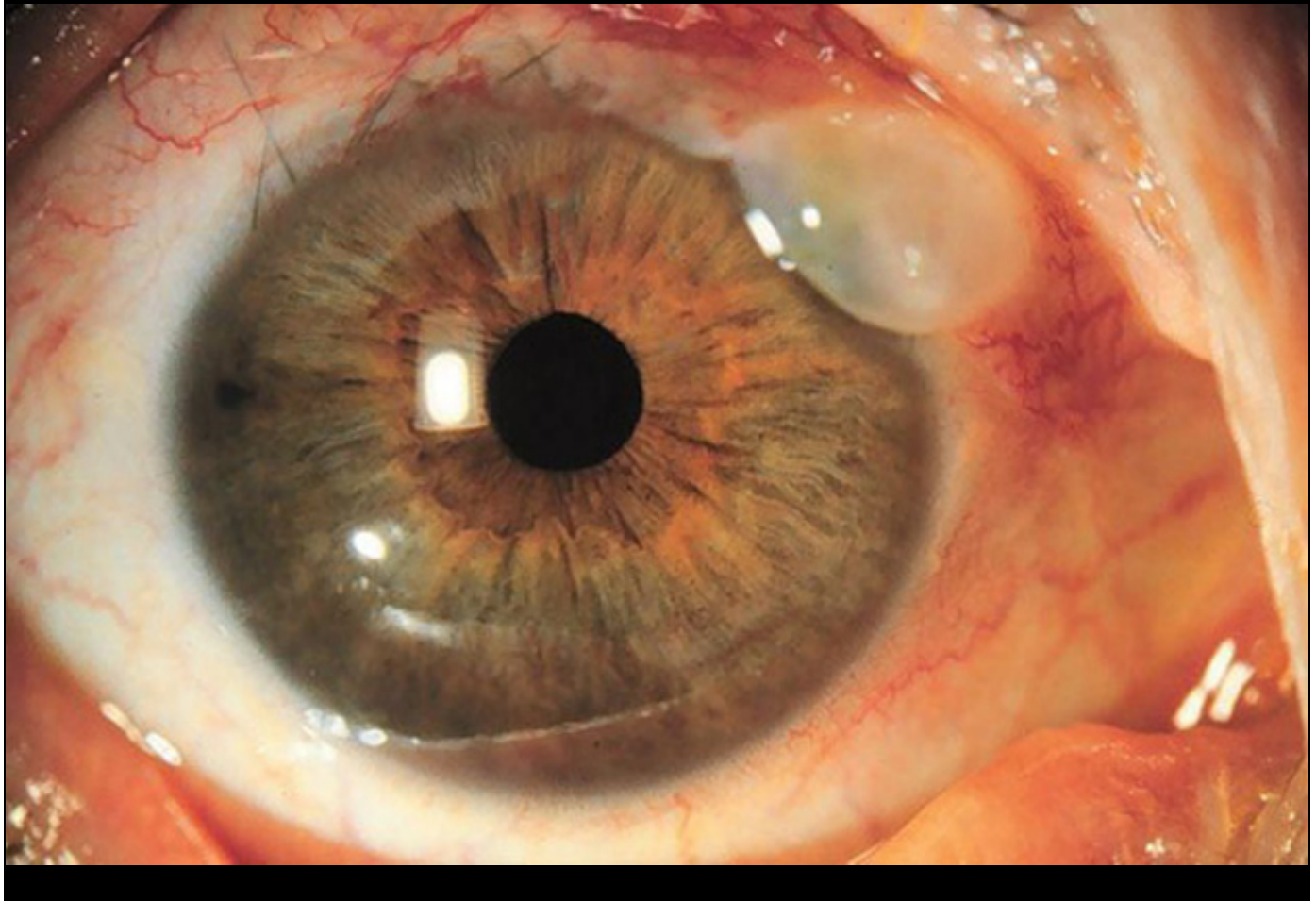


© Copyright [Oculisti OnLine](#)

EyeAtlas

The online Atlas of Ophthalmology

Bleb after trabeculectomy

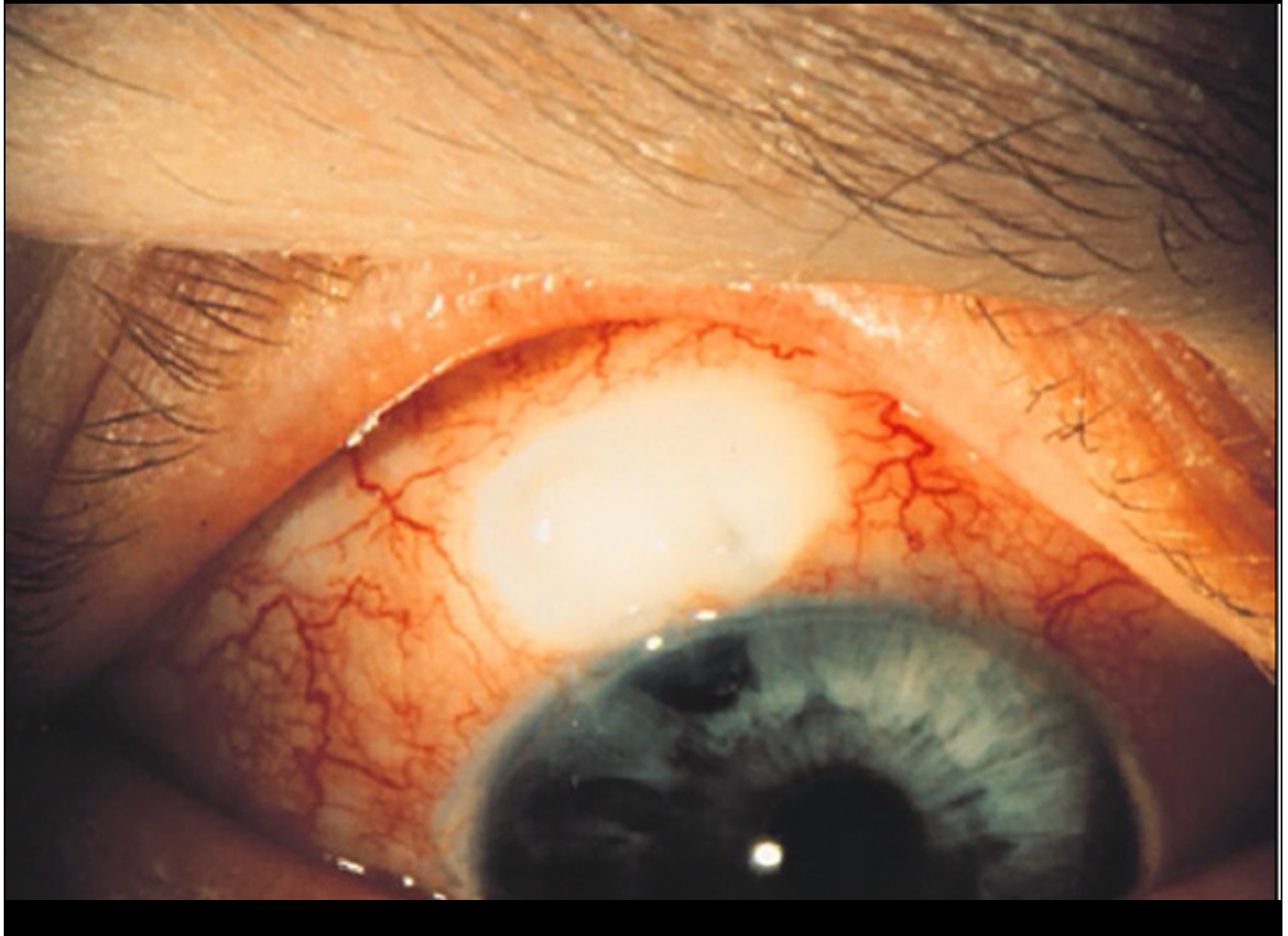

© Copyright [Oculisti OnLine](http://www.eyeatlas.com)

EyeAtlas

The online Atlas of Ophthalmology

Bleb after trabeculectomy

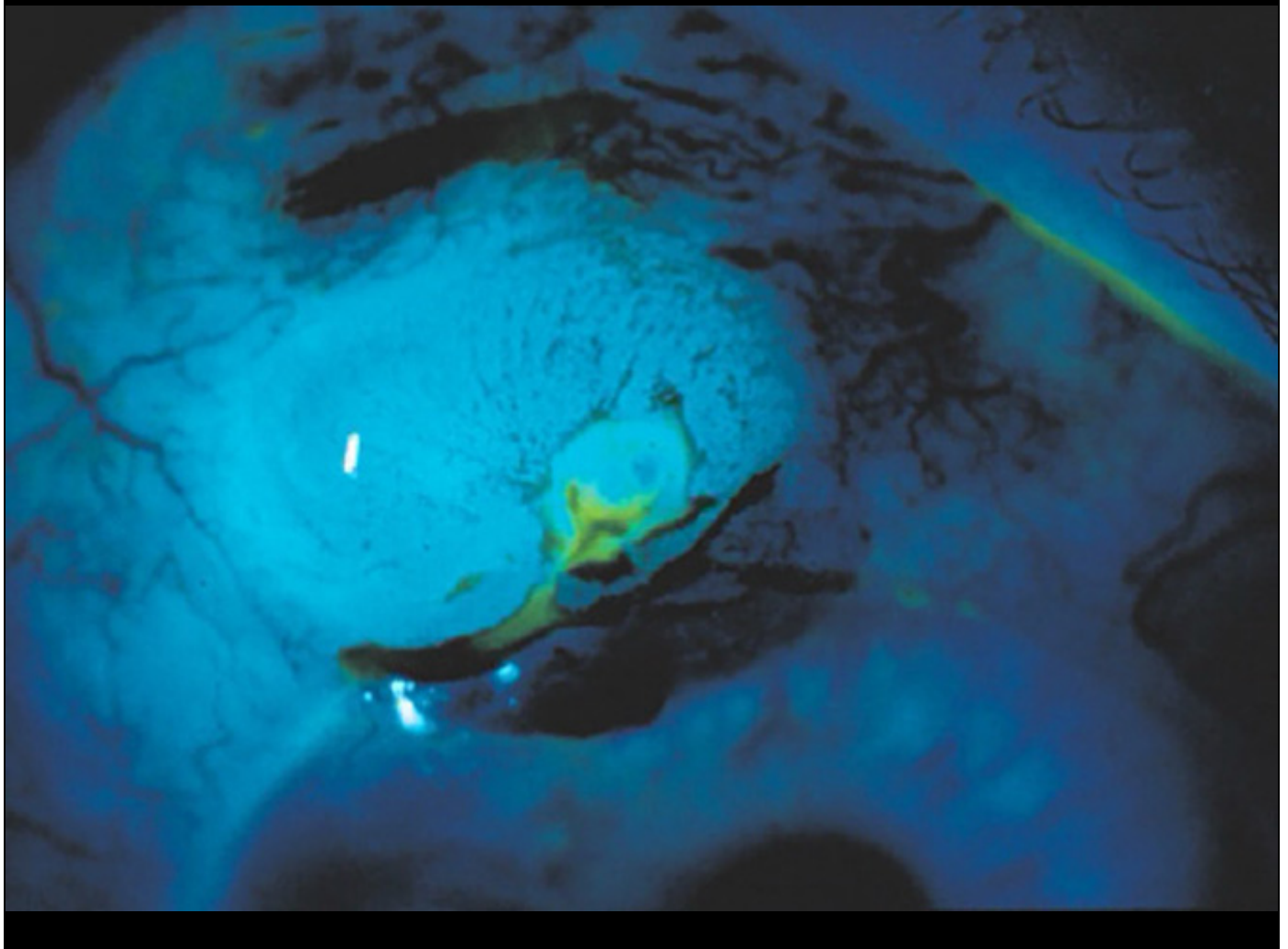


© Copyright [Oculisti OnLine](#)

EyeAtlas

The online Atlas of Ophthalmology

Bleb after trabeculectomy: Seidel's test

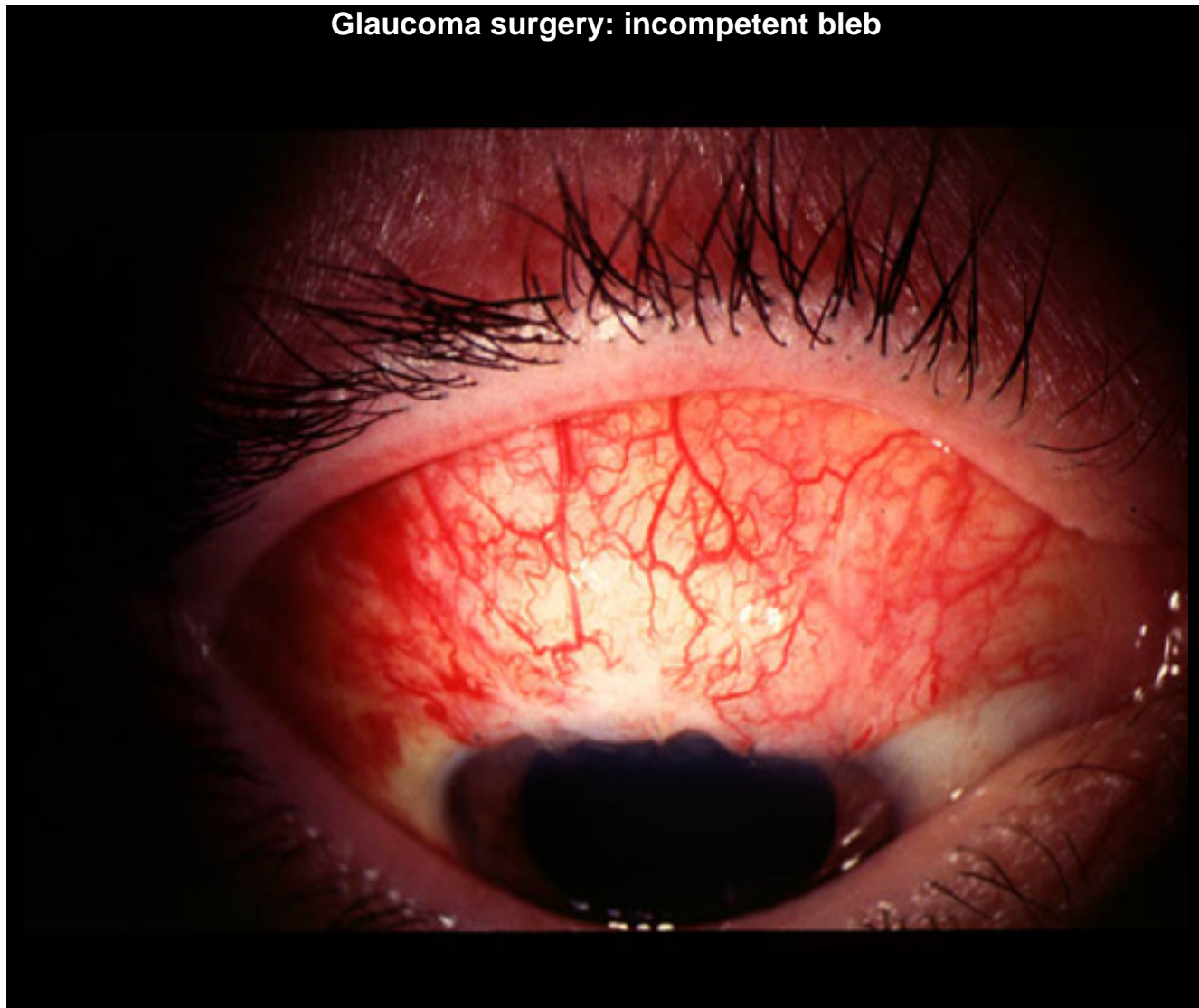

© Copyright [Oculisti OnLine](#)

EyeAtlas

The online Atlas of Ophthalmology

Glaucoma surgery: incompetent bleb

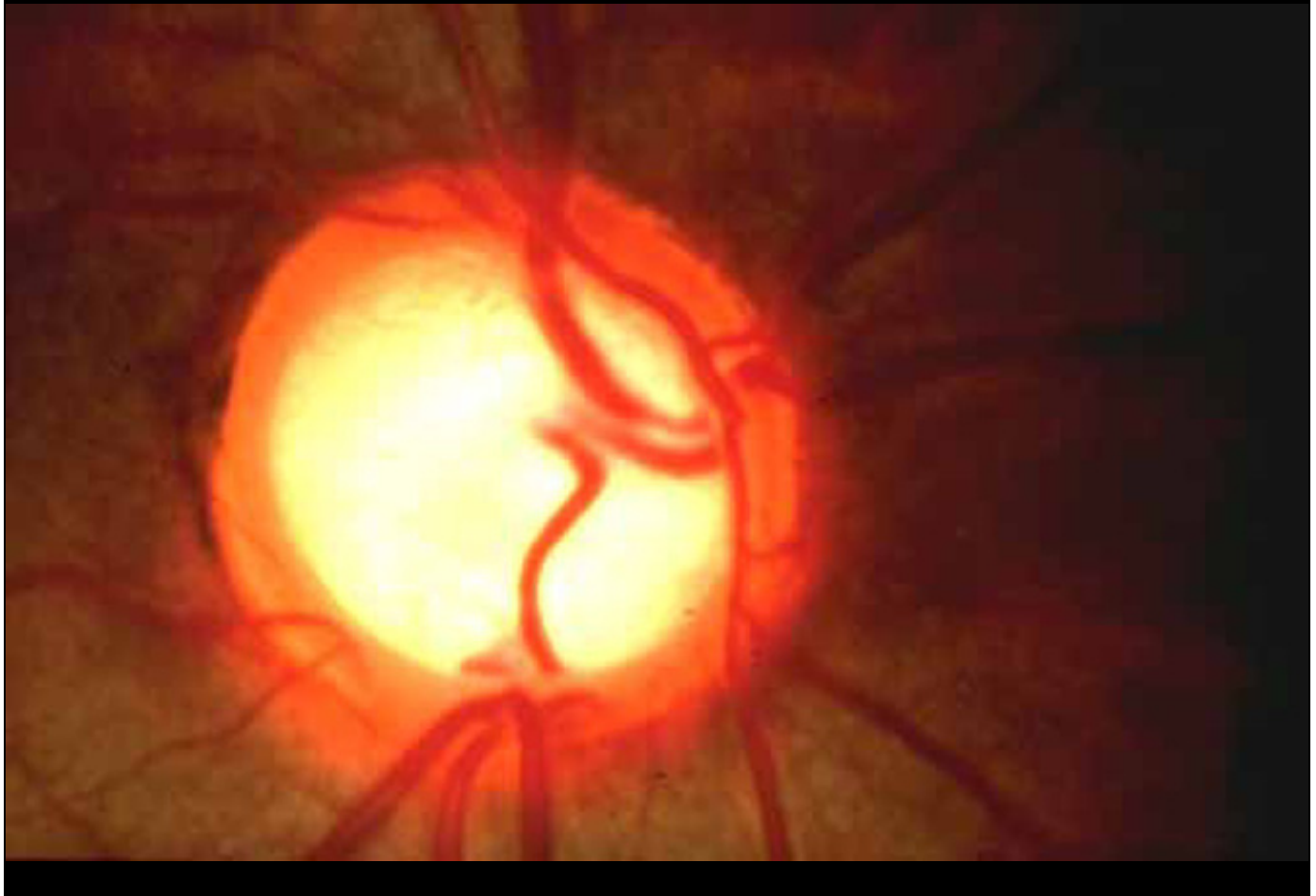


© Copyright [Oculisti OnLine](http://www.eyeatlas.com)

EyeAtlas

The online Atlas of Ophthalmology

Glaucoma cupping

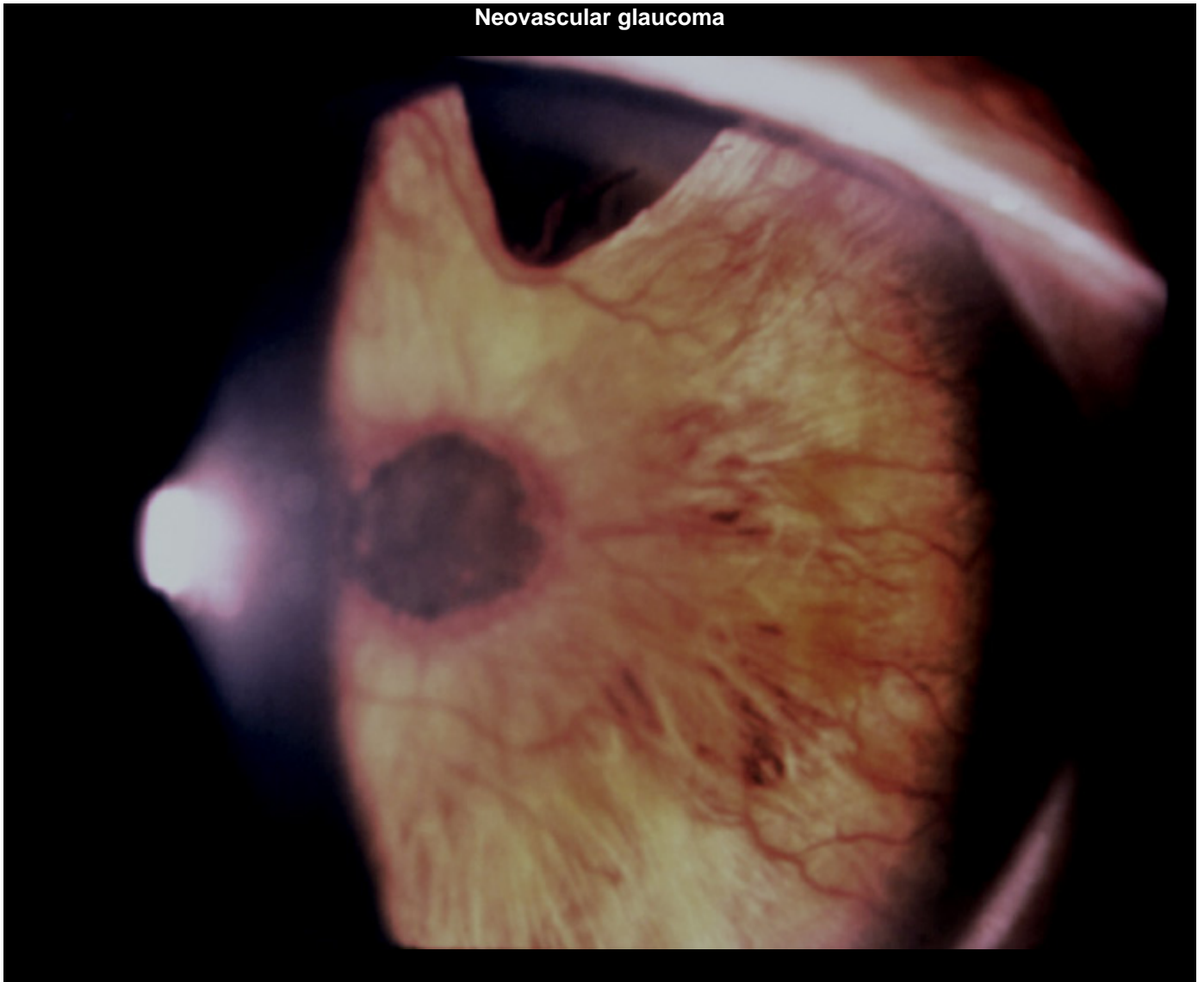

© Copyright [Oculisti OnLine](#)

EyeAtlas

The online Atlas of Ophthalmology

Neovascular glaucoma

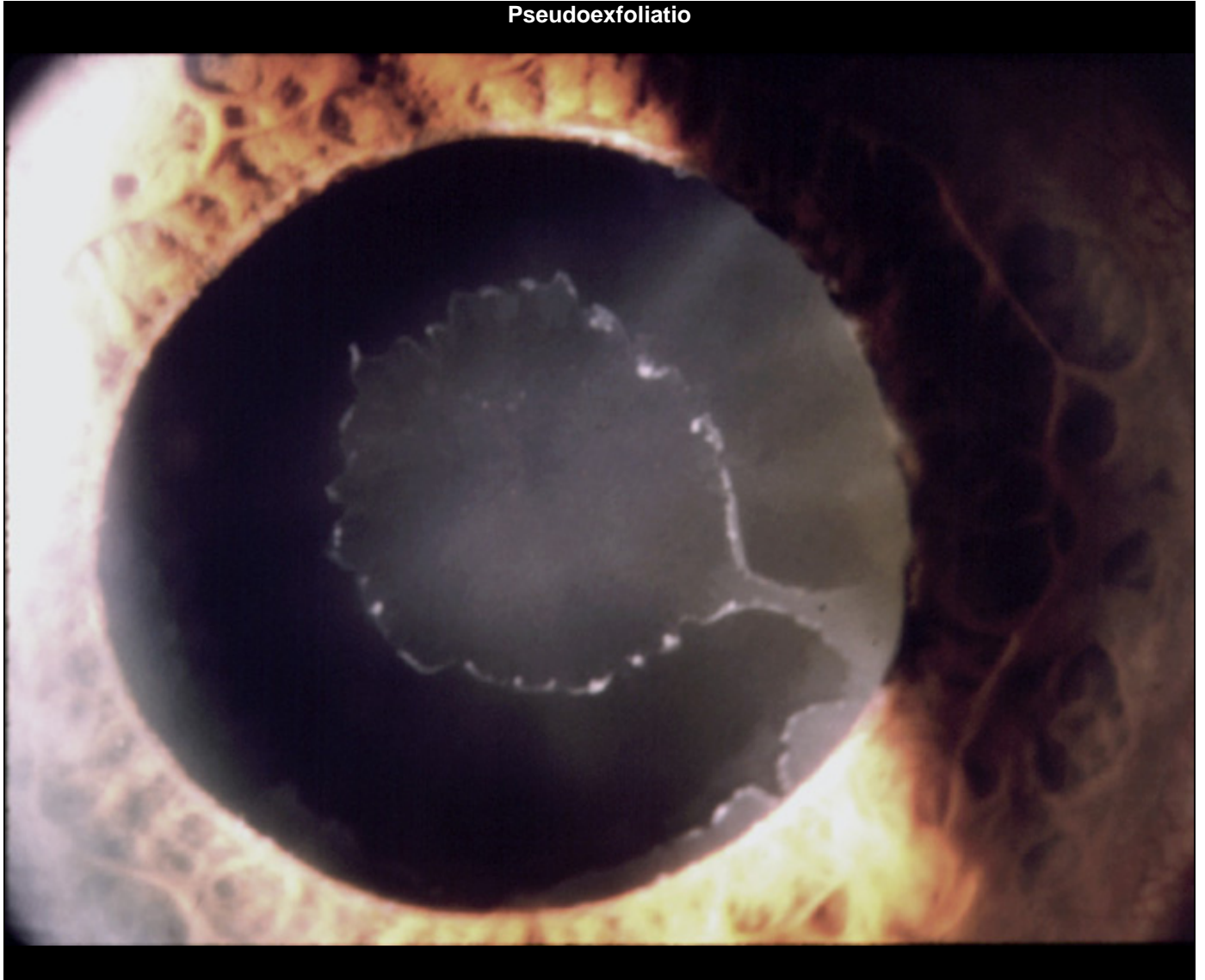


© Copyright [Oculisti OnLine](#)

EyeAtlas

The online Atlas of Ophthalmology

Pseudoexfoliation

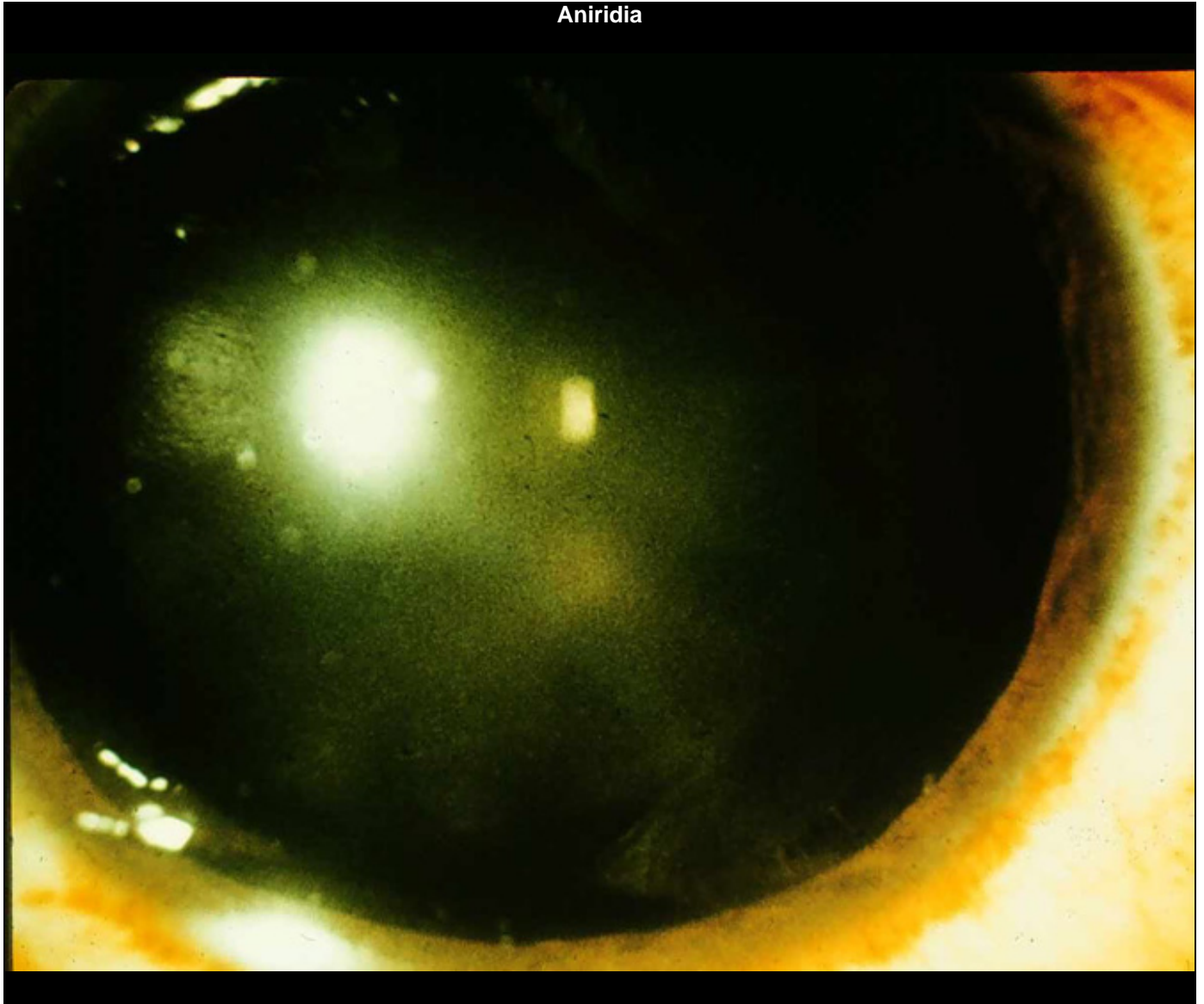


© Copyright [Oculisti OnLine](#)

Eyeatlas

The online Atlas of Ophthalmology

Aniridia

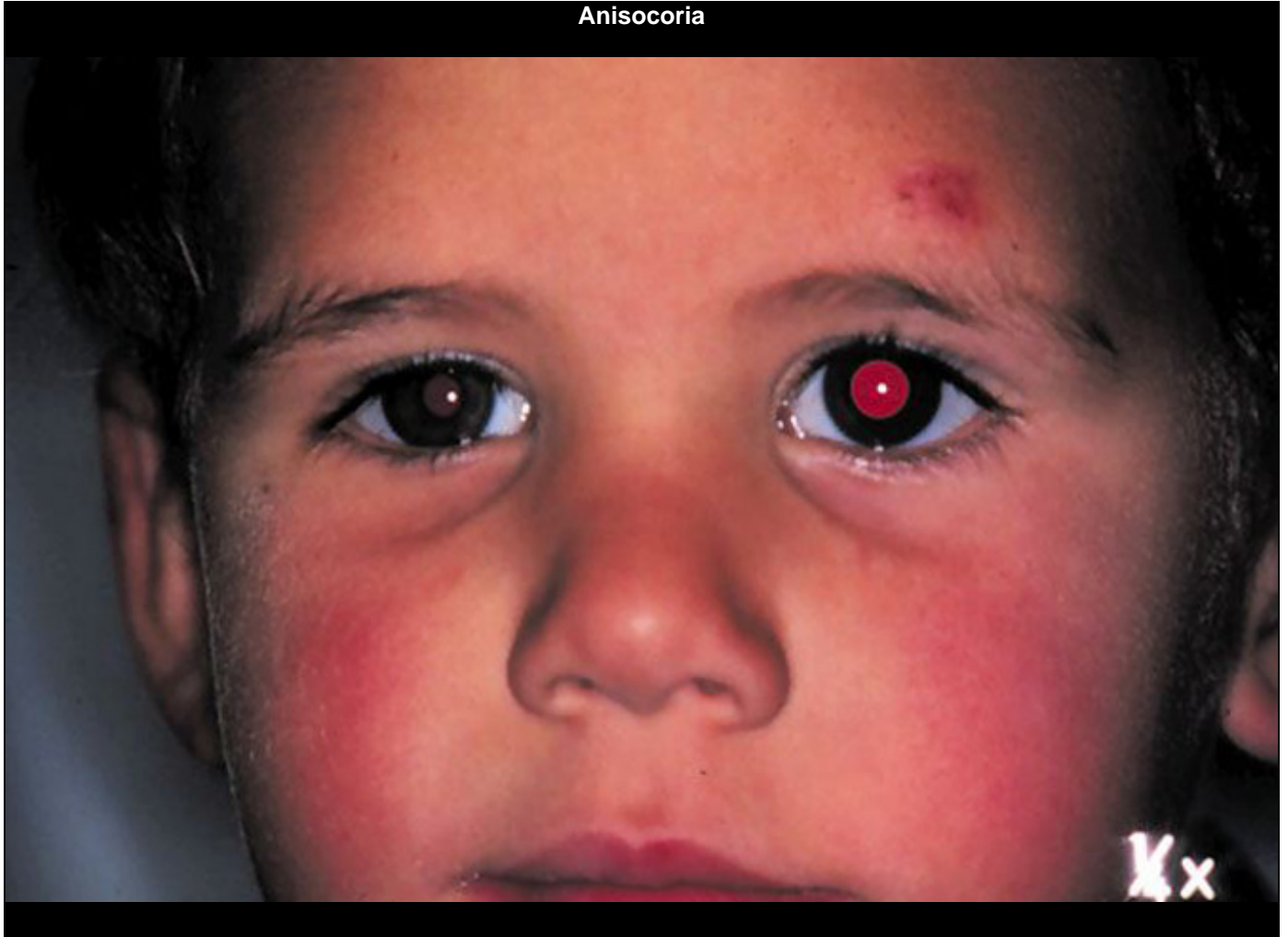

© Copyright [Oculisti OnLine](#)

EyeAtlas

The online Atlas of Ophthalmology

Anisocoria

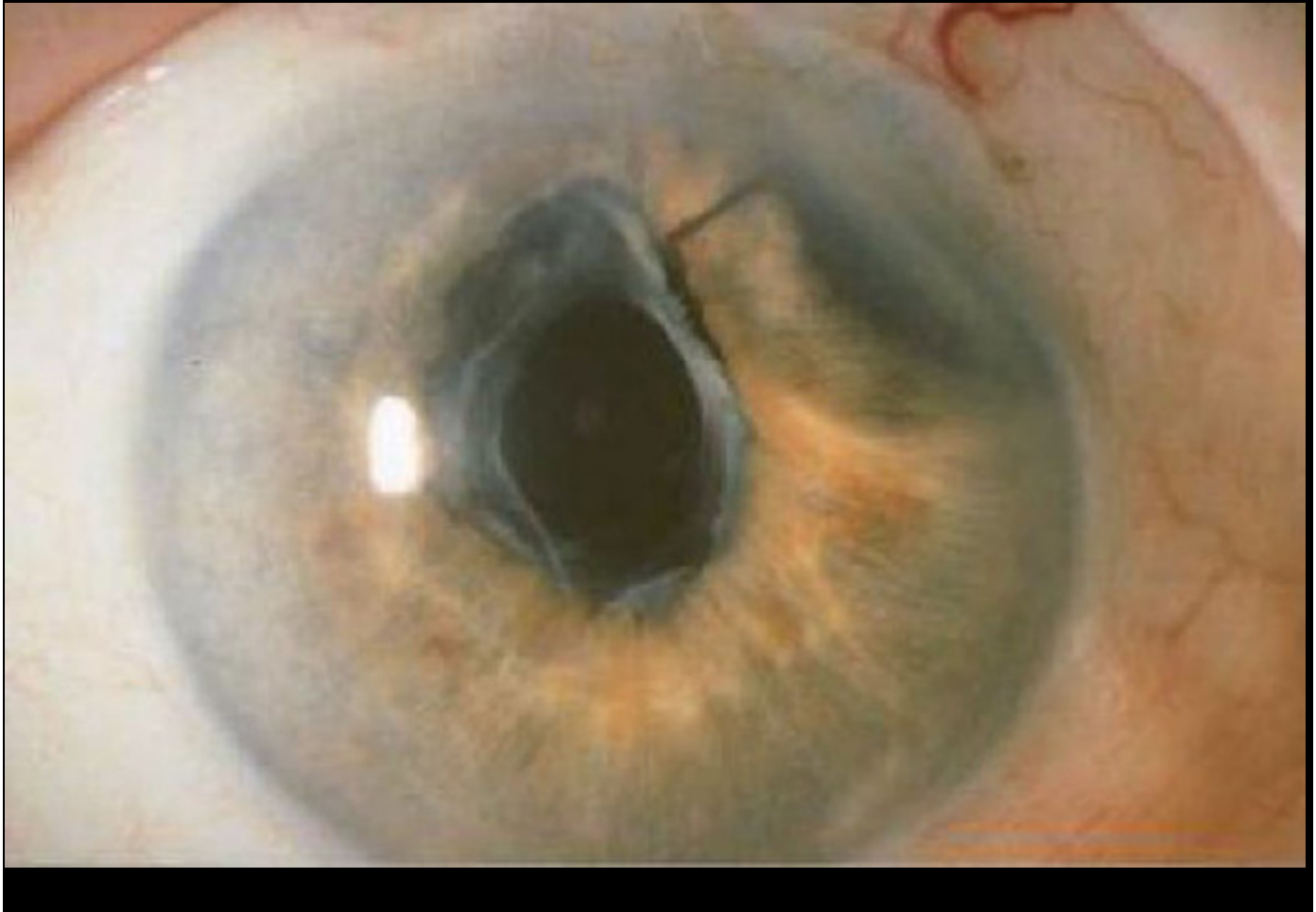


© Copyright [Oculisti OnLine](#)

Eyeatlas

The online Atlas of Ophthalmology

Ciliary body adenoma

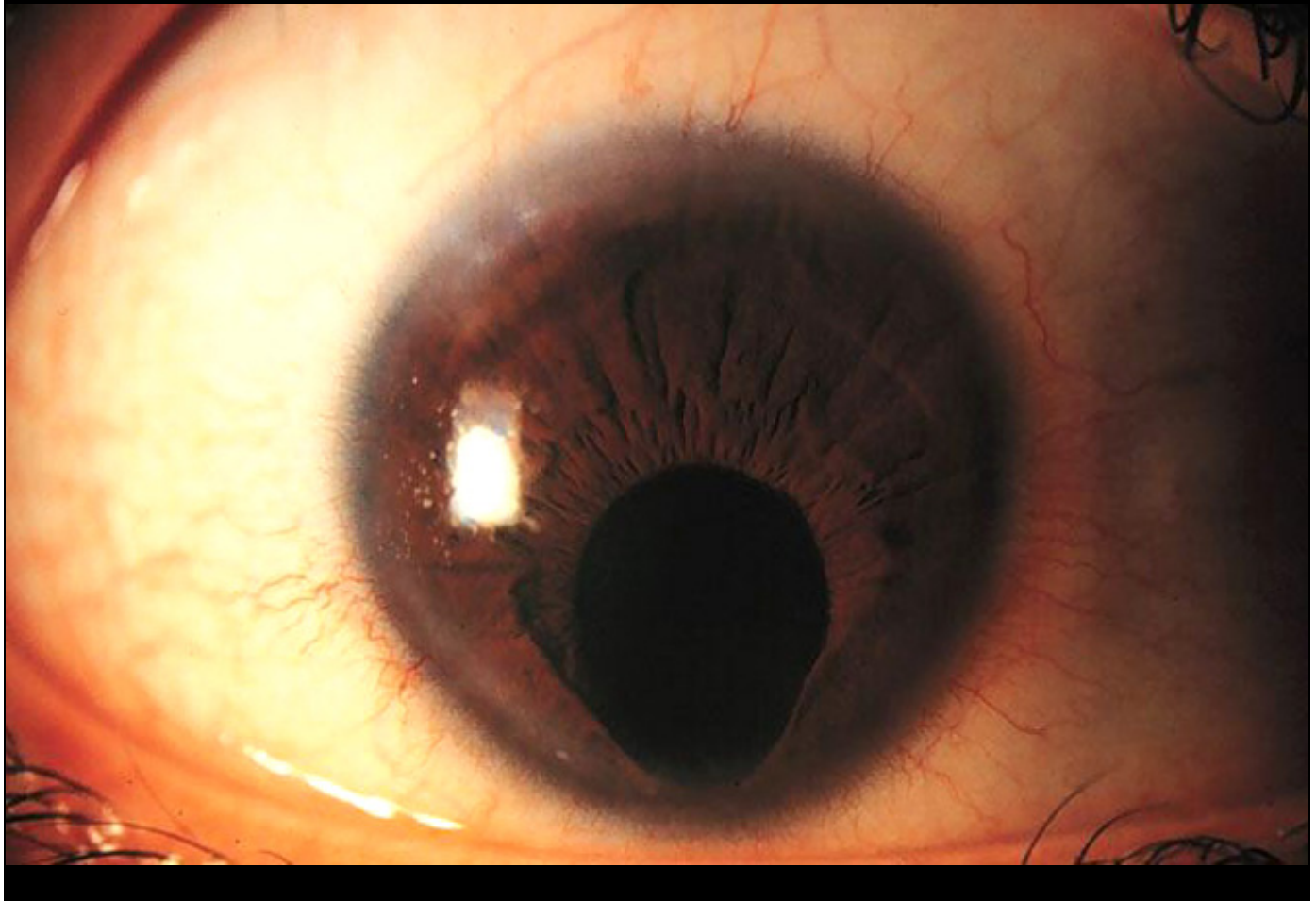


© Copyright [Oculisti OnLine](http://www.eyeatlas.com)

EyeAtlas

The online Atlas of Ophthalmology

Iris coloboma

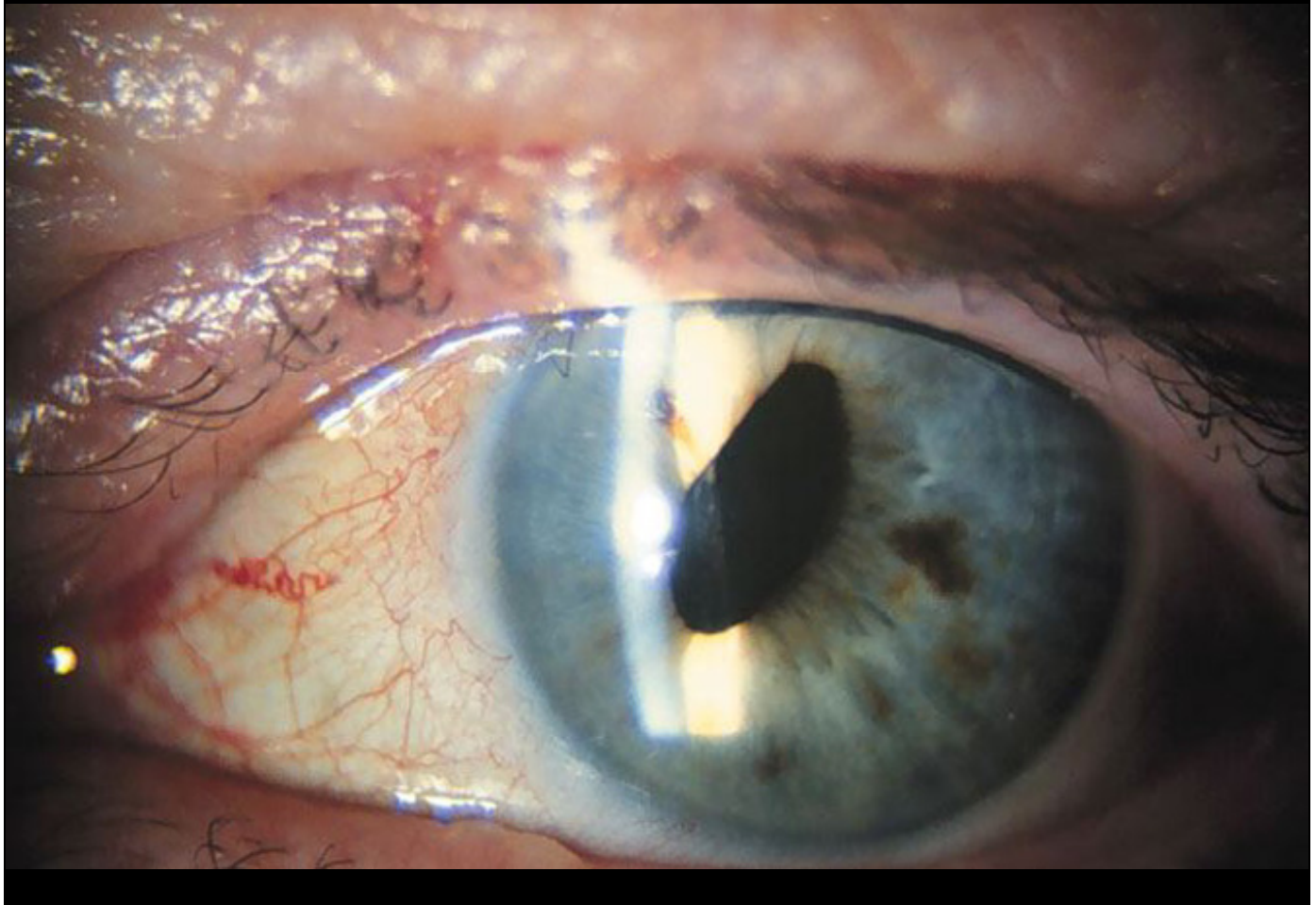


© Copyright [Oculisti OnLine](#)

EyeAtlas

The online Atlas of Ophthalmology

Iris corectopia

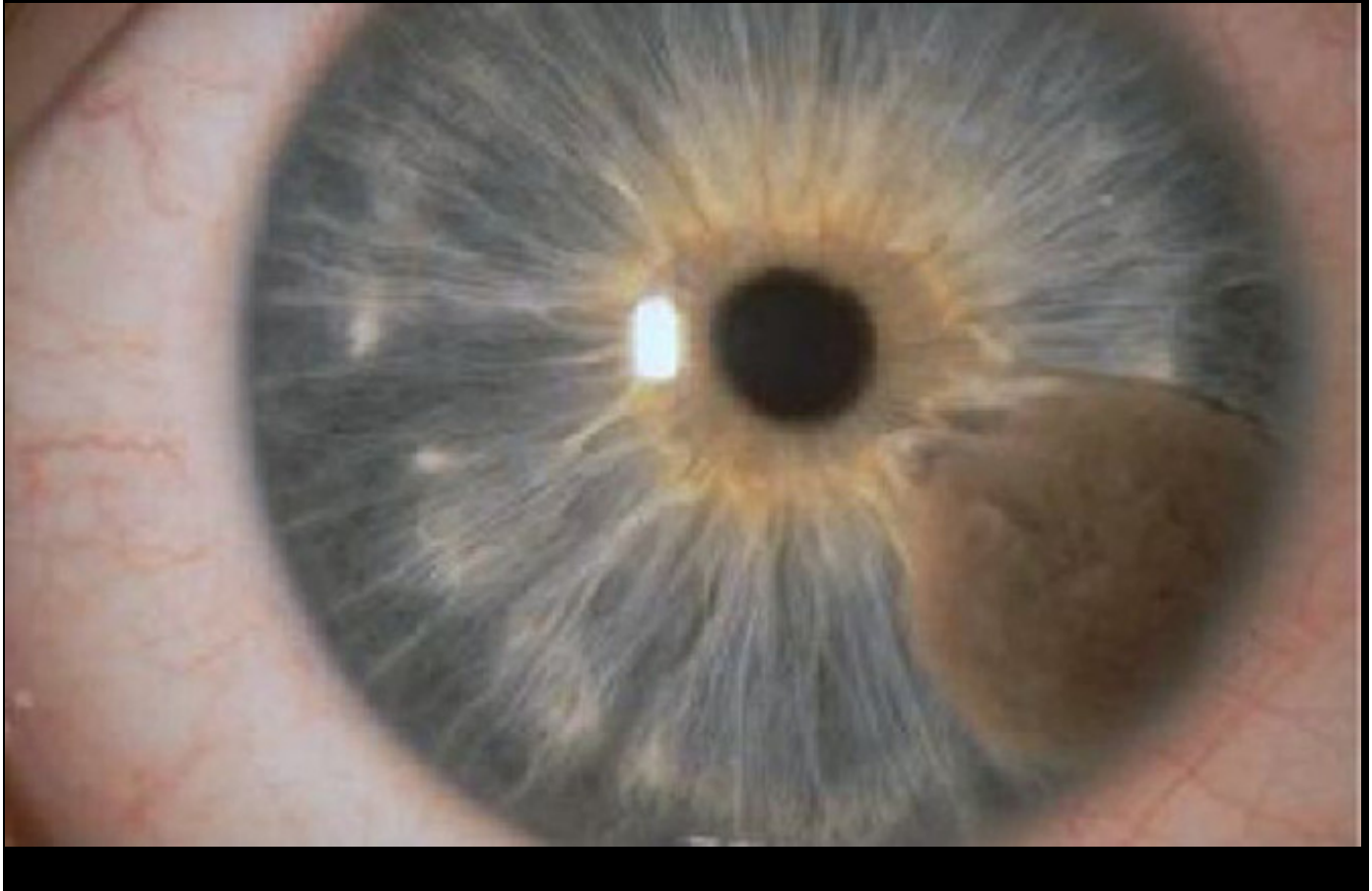


© Copyright [Oculisti OnLine](#)

Eyeatlas

The online Atlas of Ophthalmology

Ectropion uveae

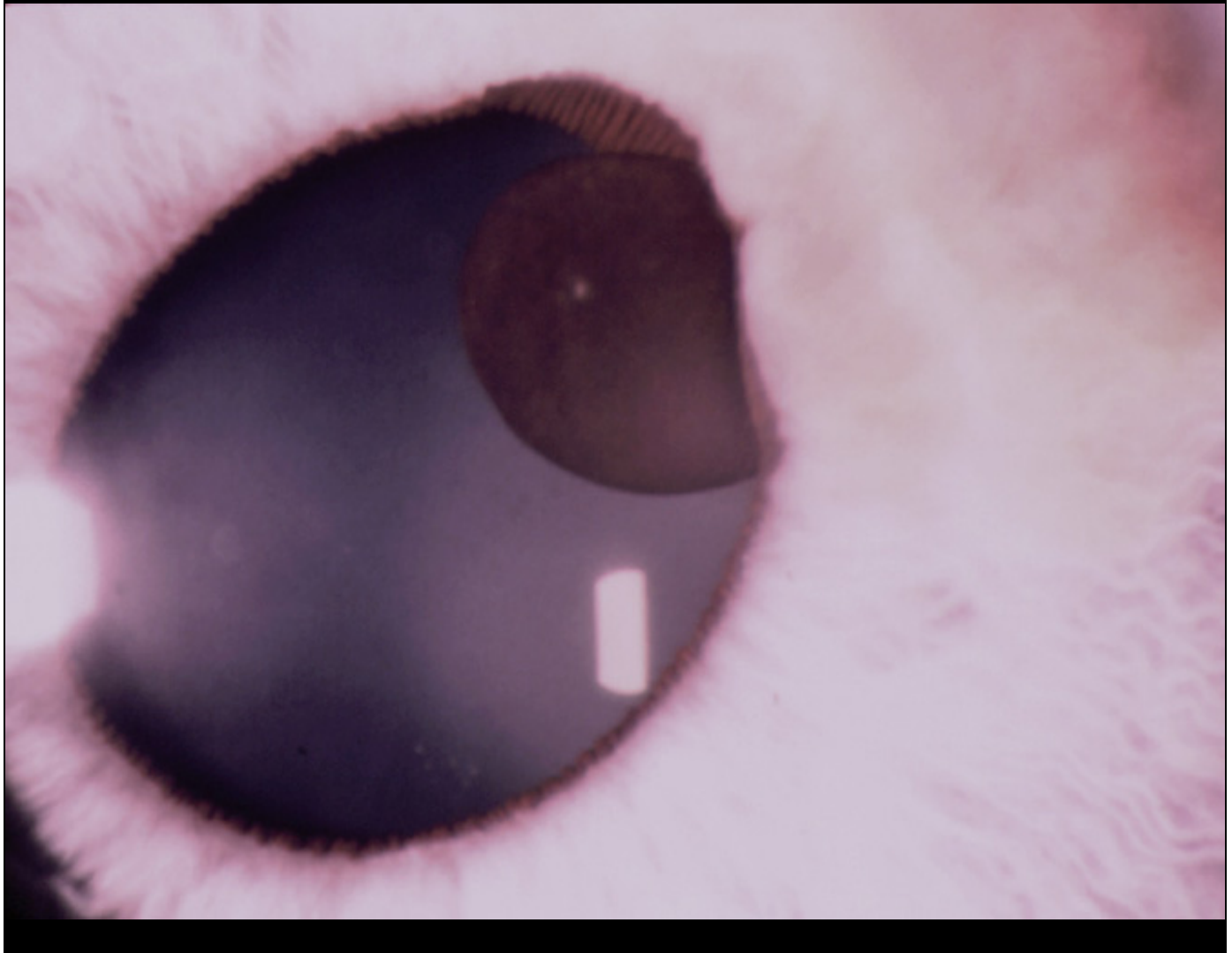


© Copyright [Oculisti OnLine](#)

EyeAtlas

The online Atlas of Ophthalmology

Epithelial iris cyst

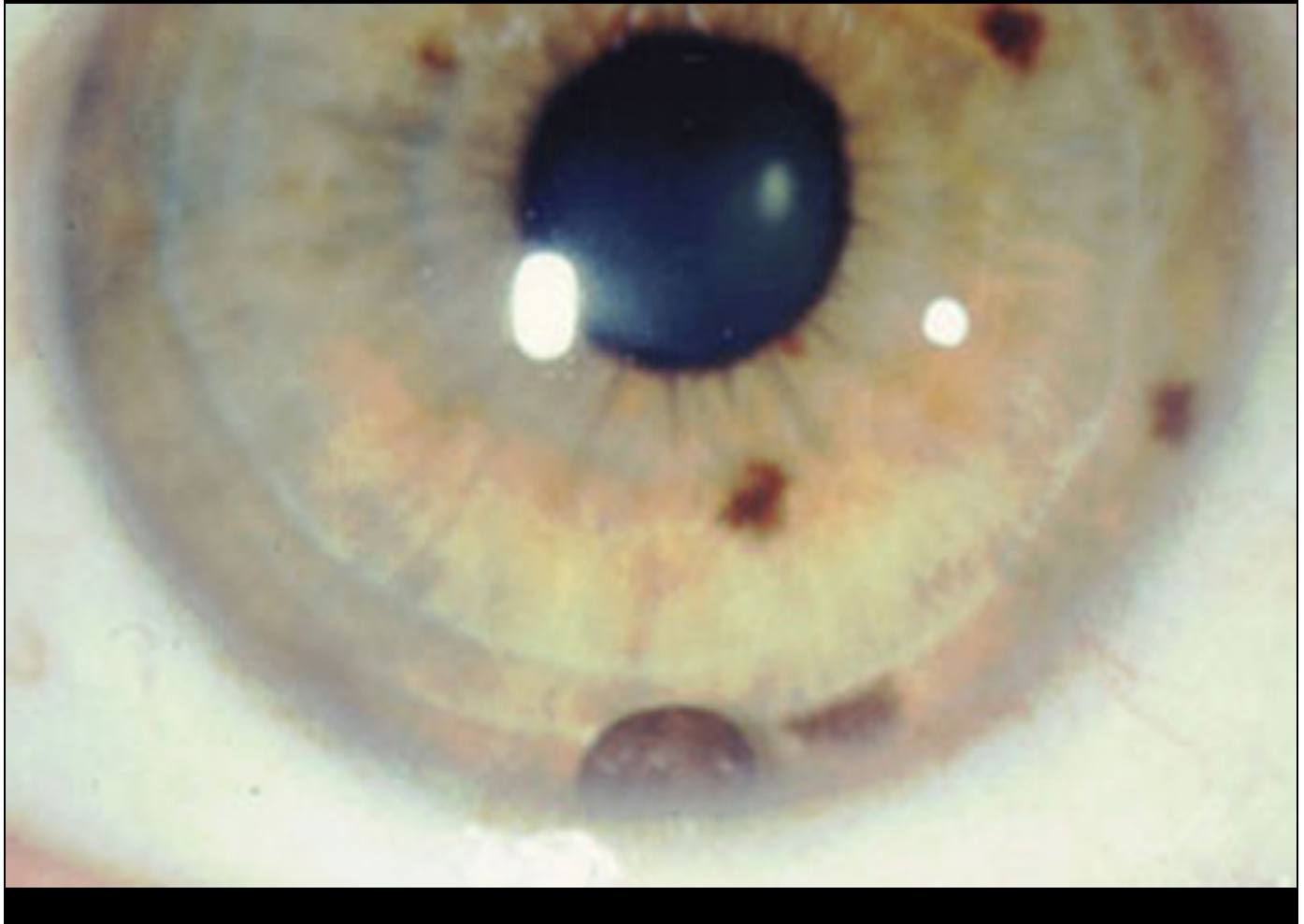

© Copyright [Oculisti OnLine](#)

Eyeatlas

The online Atlas of Ophthalmology

Epithelial iris cyst

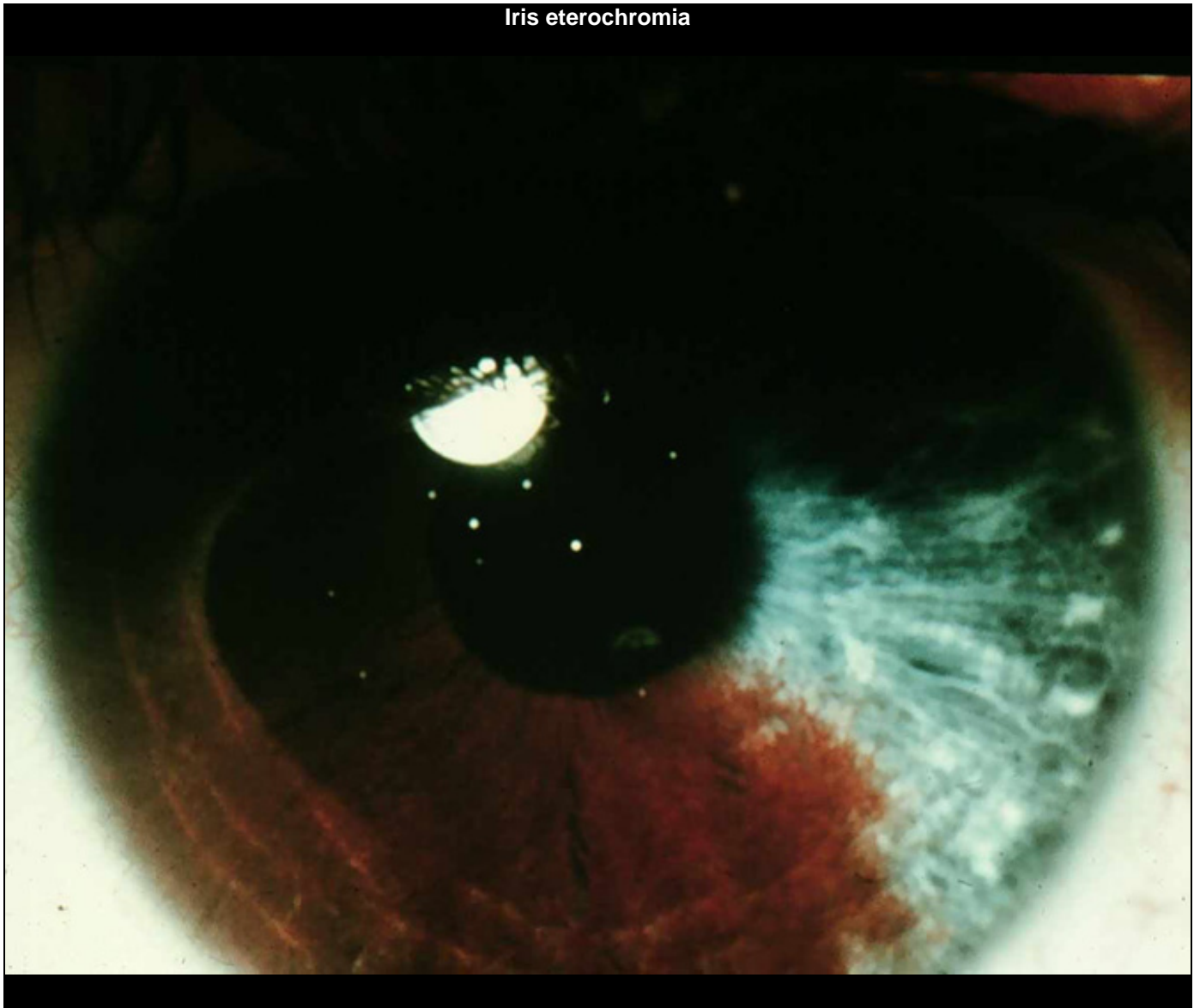


© Copyright [Oculisti OnLine](http://www.eyeatlas.com)

Eyeatlas

The online Atlas of Ophthalmology

Iris eterochromia

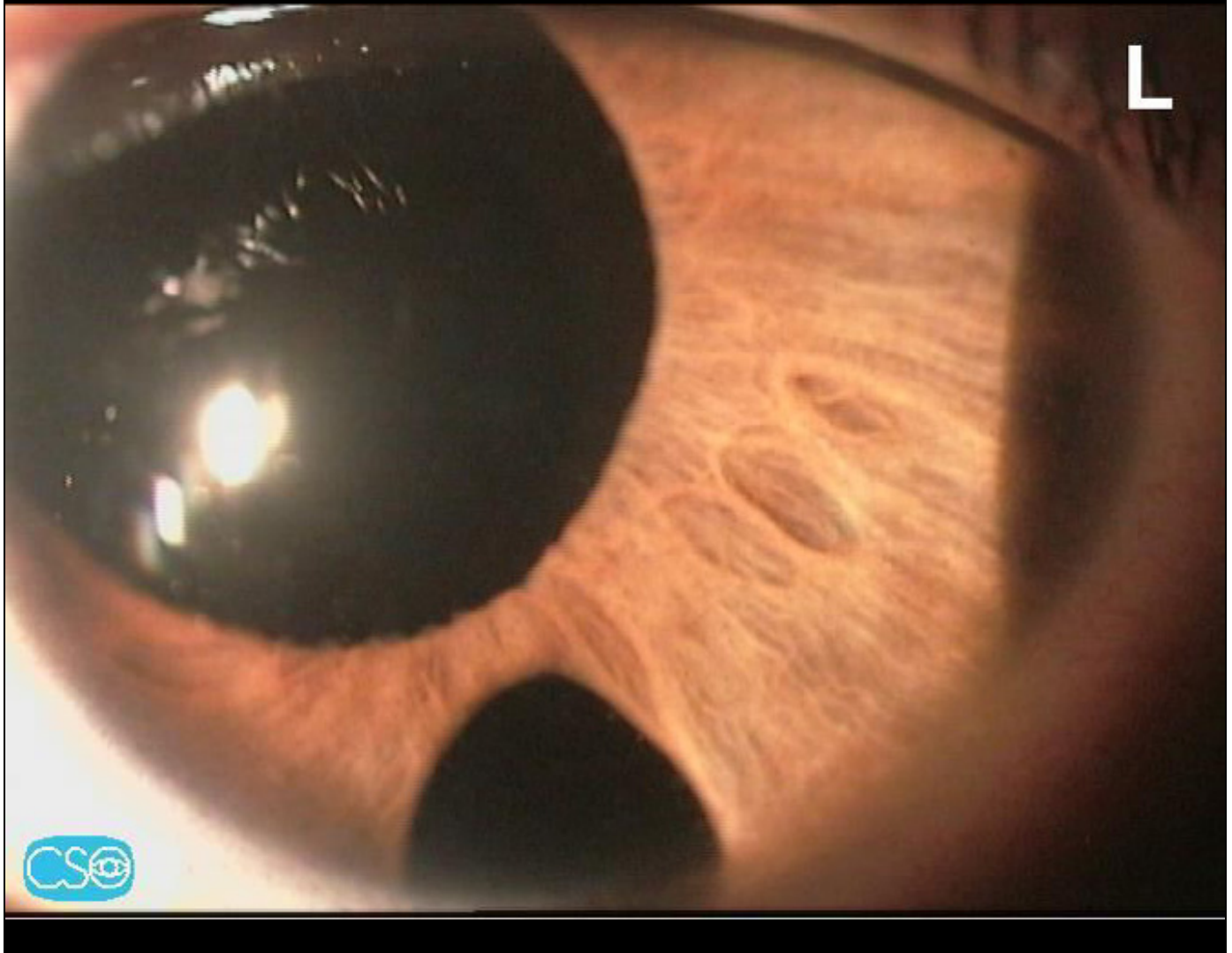

© Copyright [Oculisti OnLine](http://www.eyeatlas.com)

EyeAtlas

The online Atlas of Ophthalmology

Iridectomy

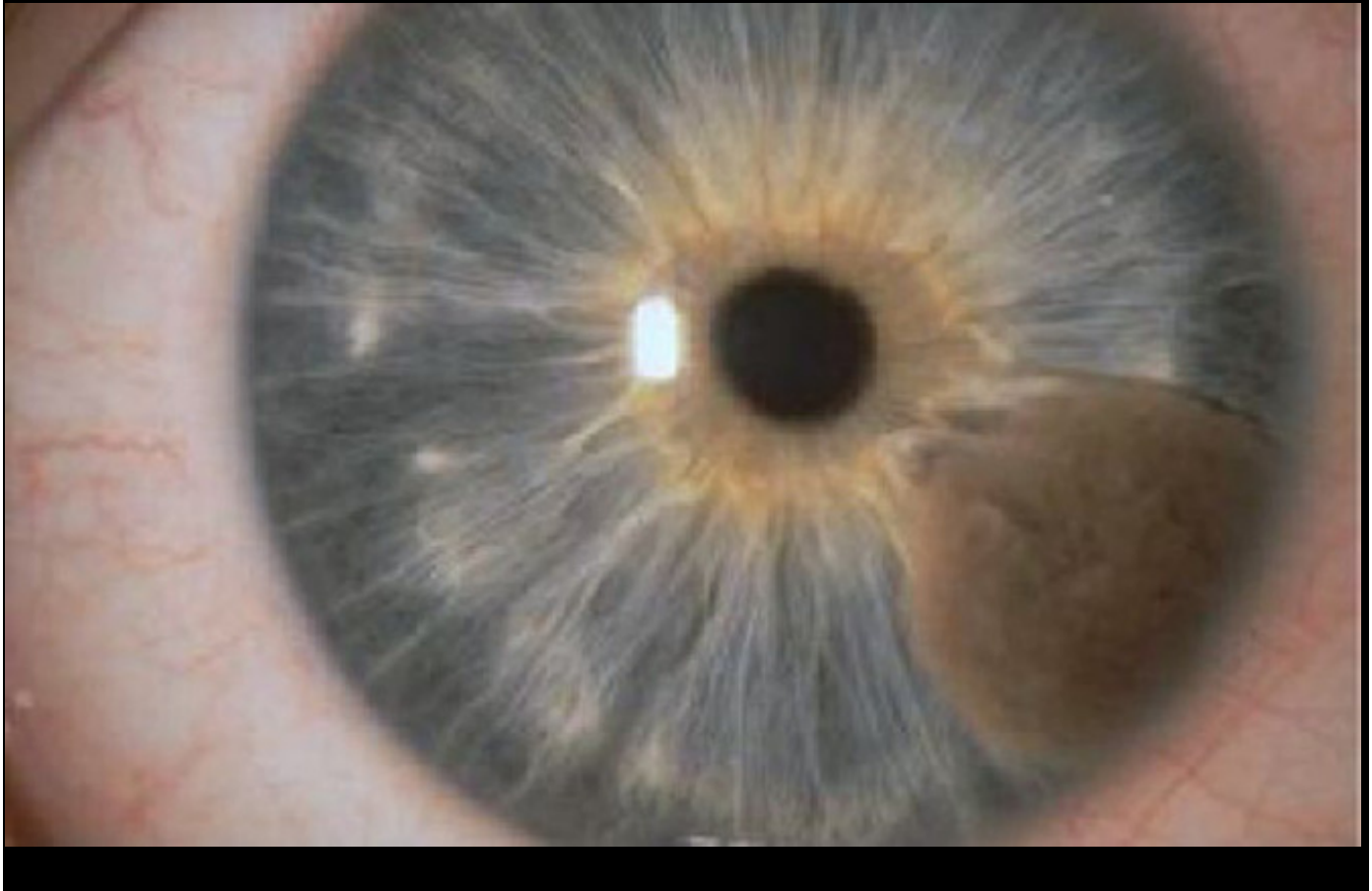


© Copyright [Oculisti OnLine](#)

EyeAtlas

The online Atlas of Ophthalmology

Iridodysplasia

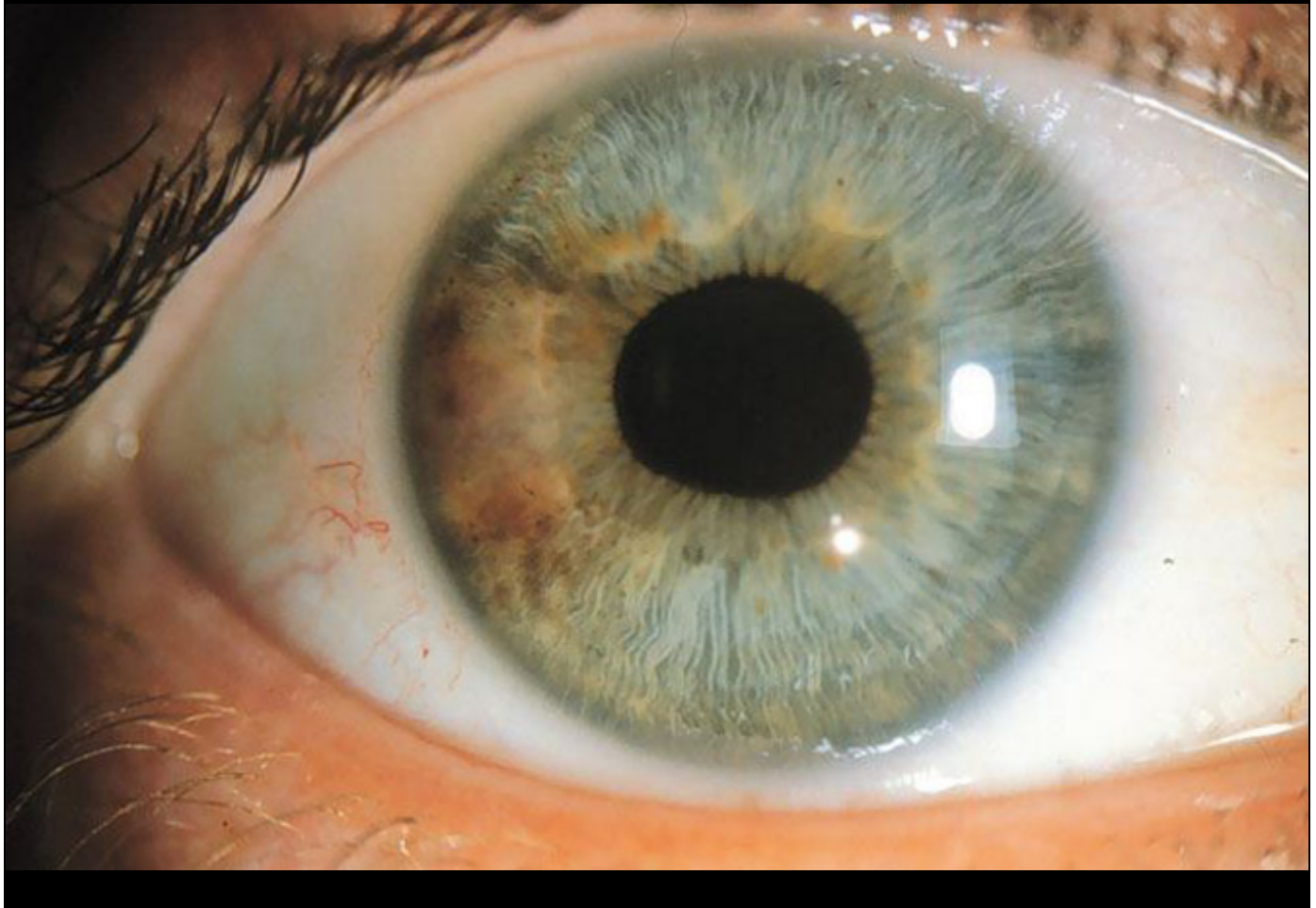


© Copyright [Oculisti OnLine](#)

EyeAtlas

The online Atlas of Ophthalmology

Iris nevus

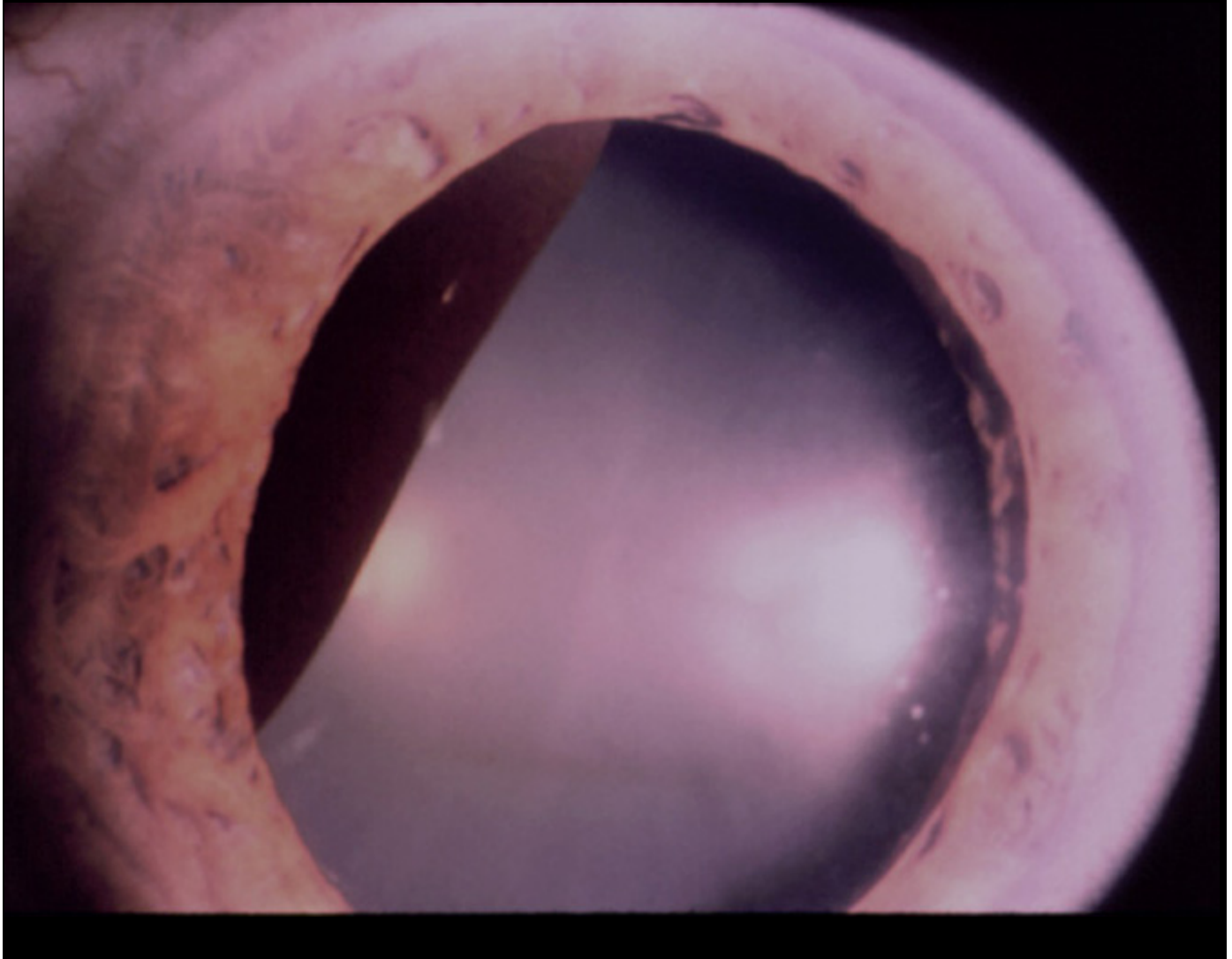


© Copyright [Oculisti OnLine](#)

Eyeatlas

The online Atlas of Ophthalmology

Pigmented iris cyst

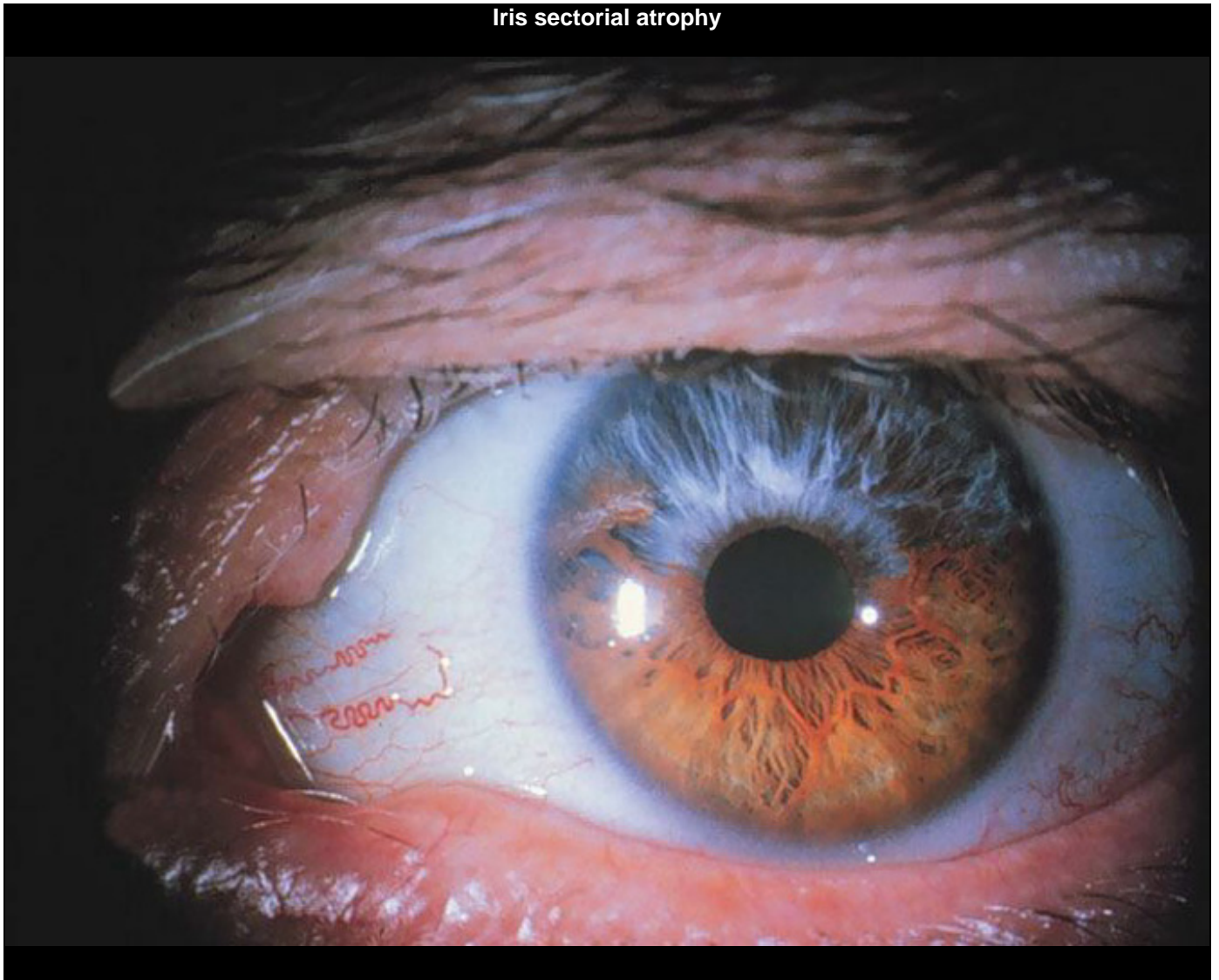

© Copyright [Oculisti OnLine](http://www.eyeatlas.com)

EyeAtlas

The online Atlas of Ophthalmology

Iris sectorial atrophy

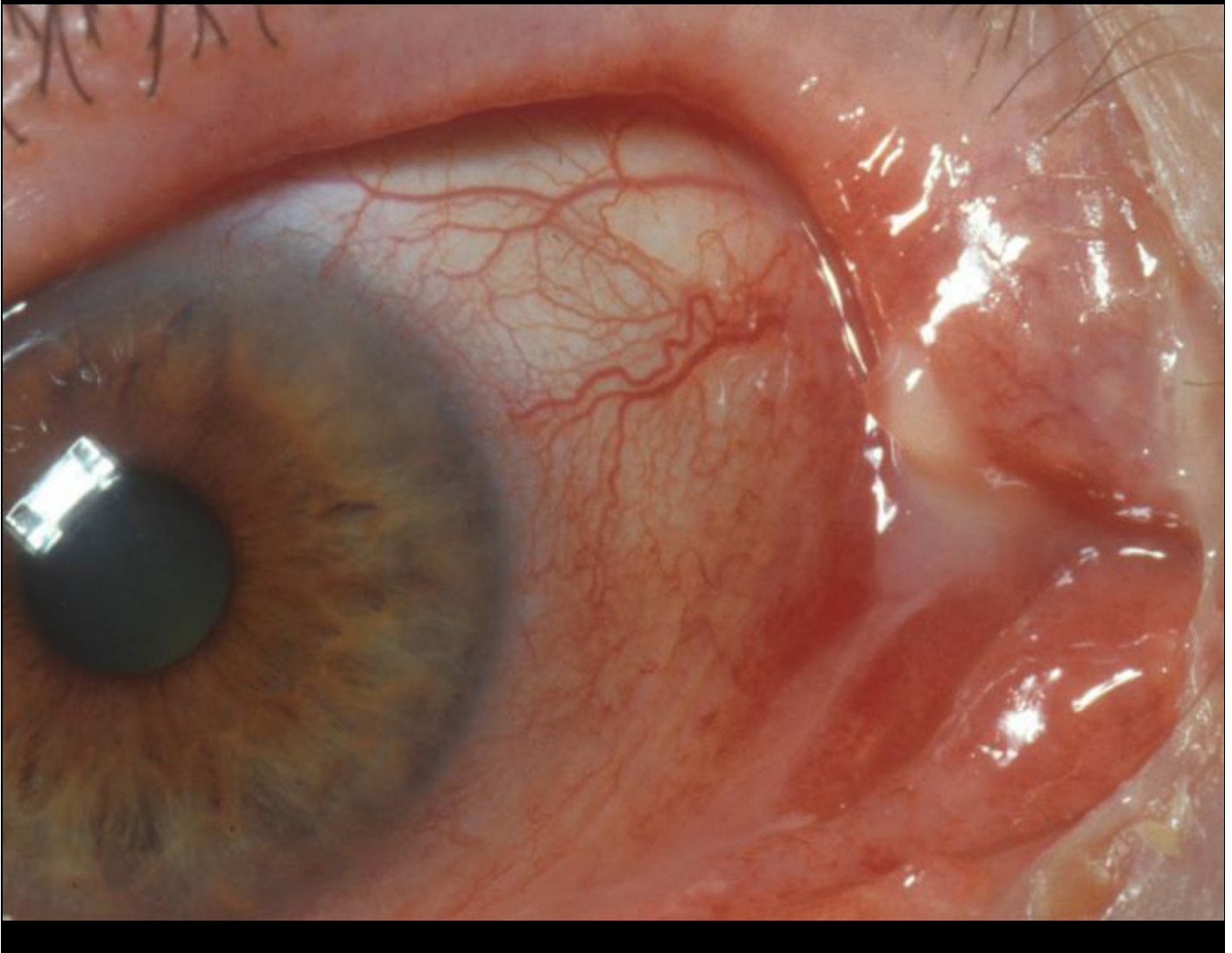


© Copyright [Oculisti OnLine](#)

EyeAtlas

The online Atlas of Ophthalmology

Canaliculitis

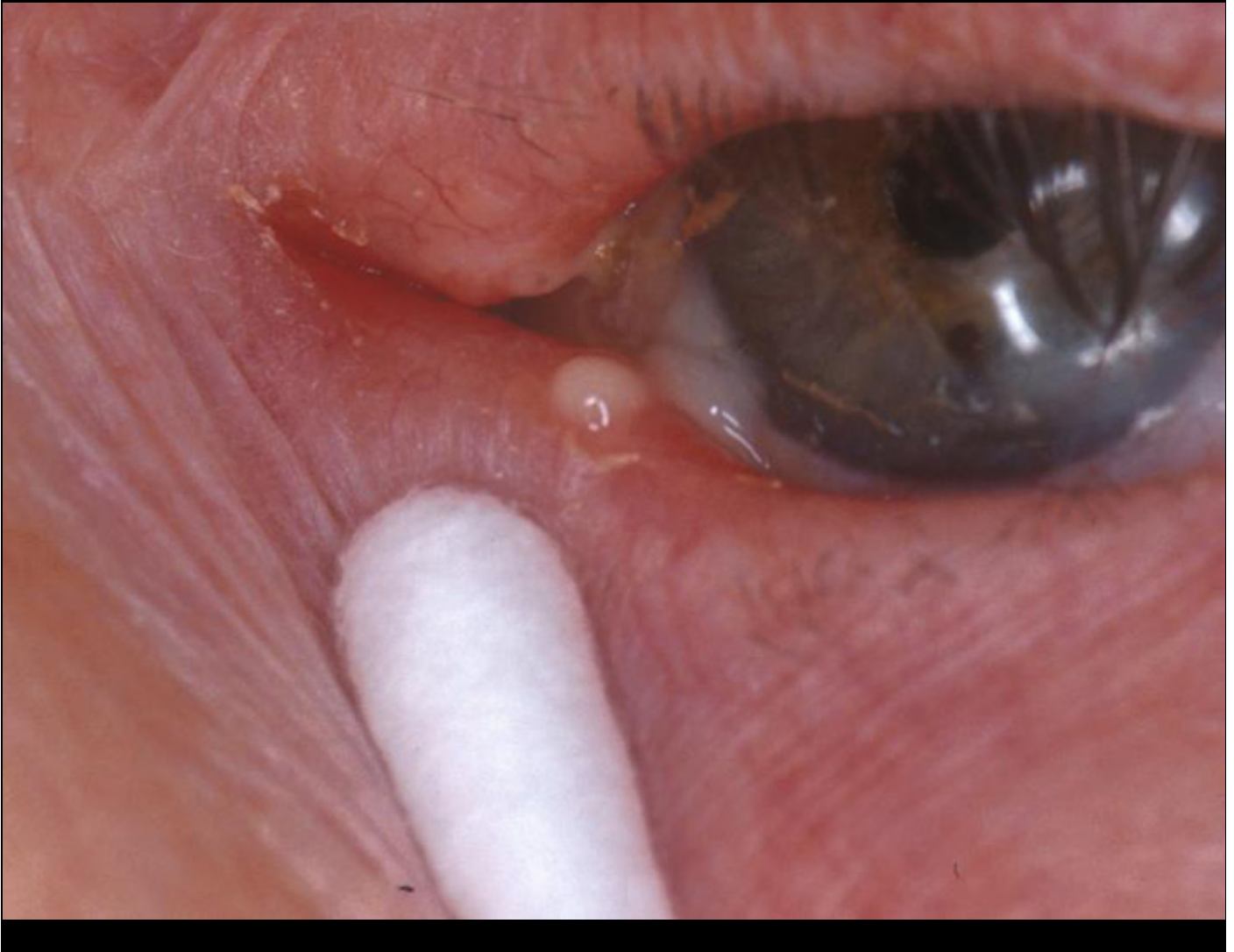

© Copyright [Oculisti OnLine](#)

EyeAtlas

The online Atlas of Ophthalmology

Canaliculitis

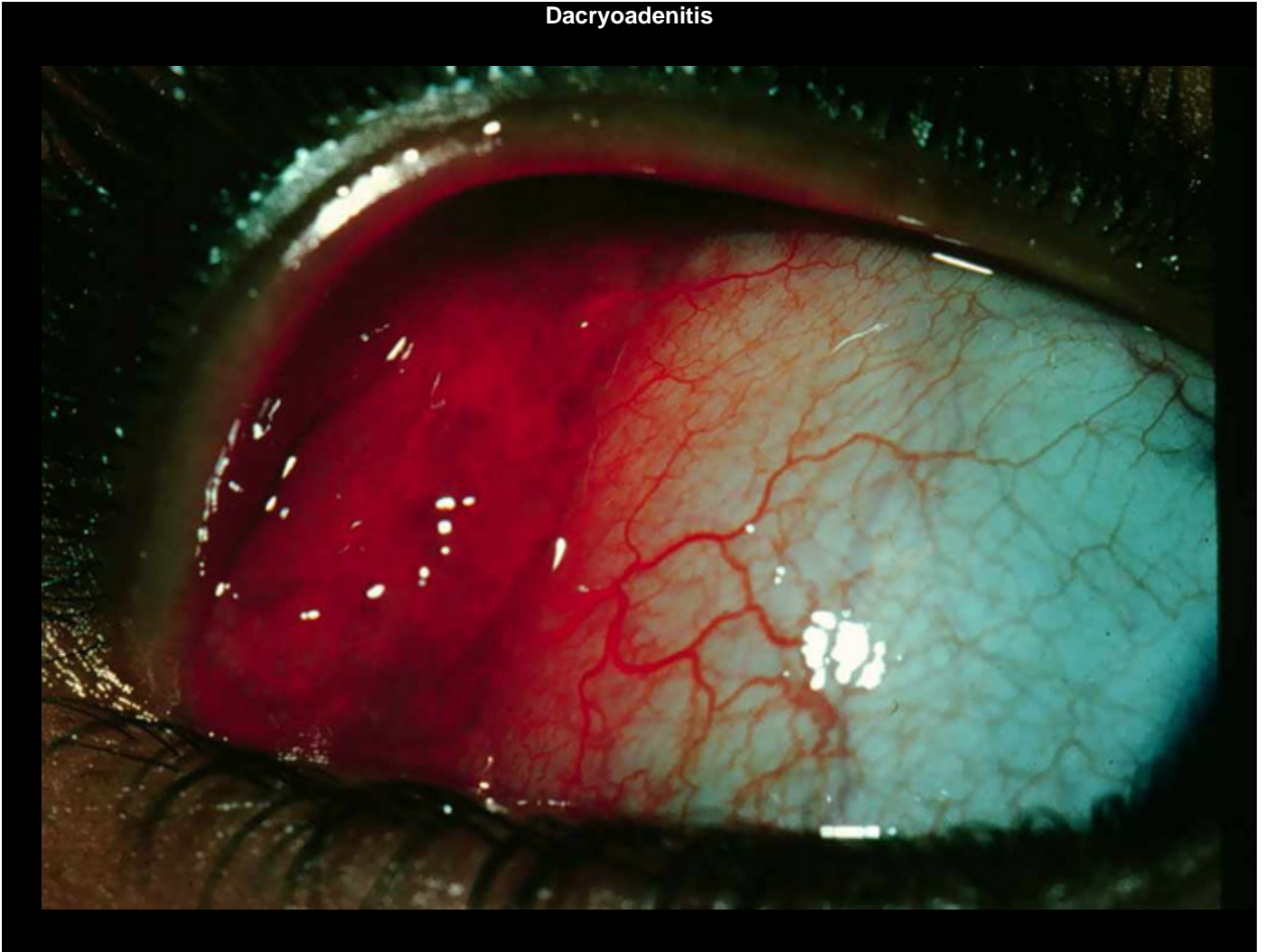


© Copyright [Oculisti OnLine](#)

Eyeatlas

The online Atlas of Ophthalmology

Dacryoadenitis

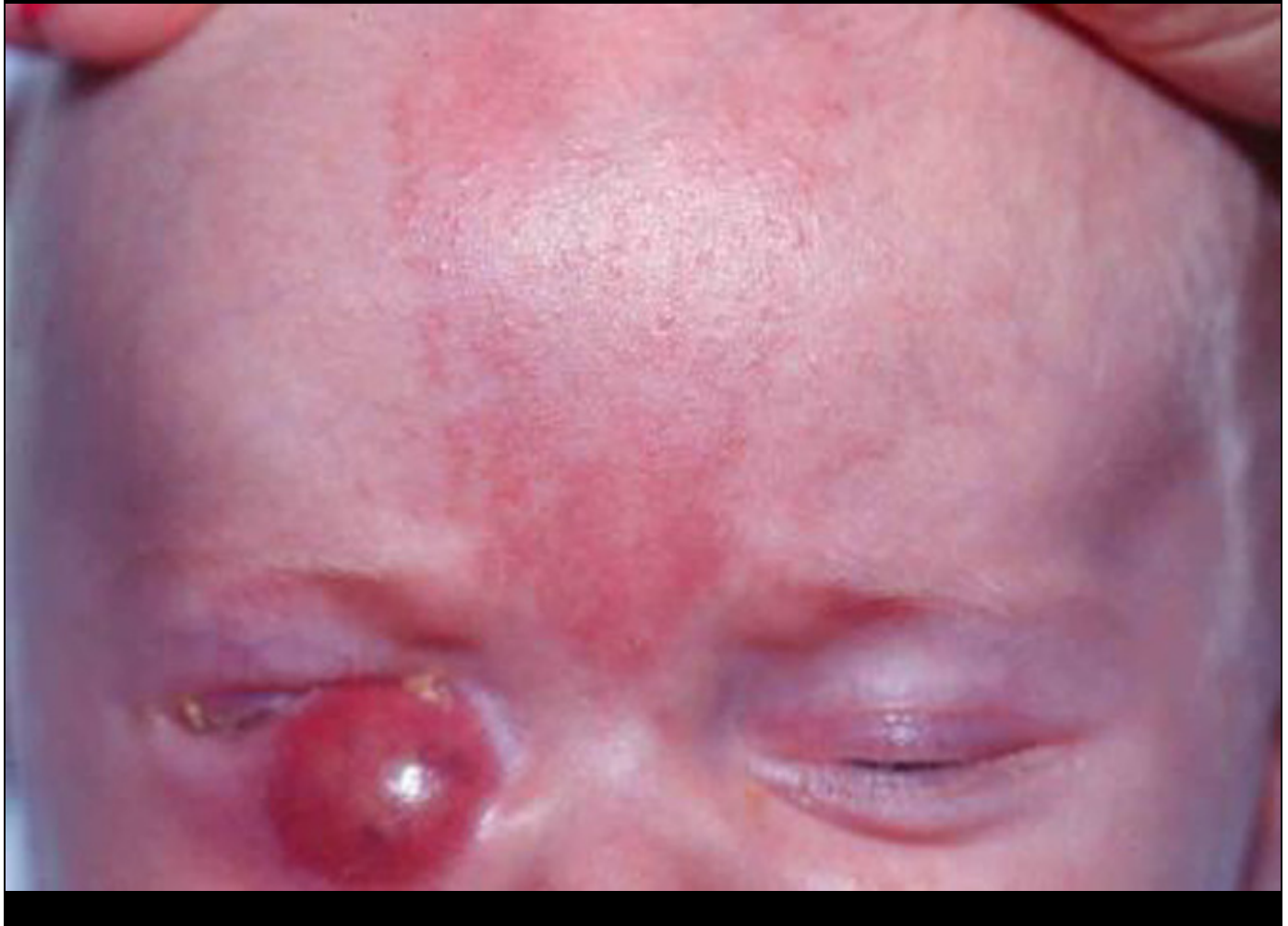

© Copyright [Oculisti OnLine](http://www.eyeatlas.com)

EyeAtlas

The online Atlas of Ophthalmology

Dacryoceles




© Copyright [Oculisti OnLine](#)

EyeAtlas

The online Atlas of Ophthalmology

Dacryocistitis

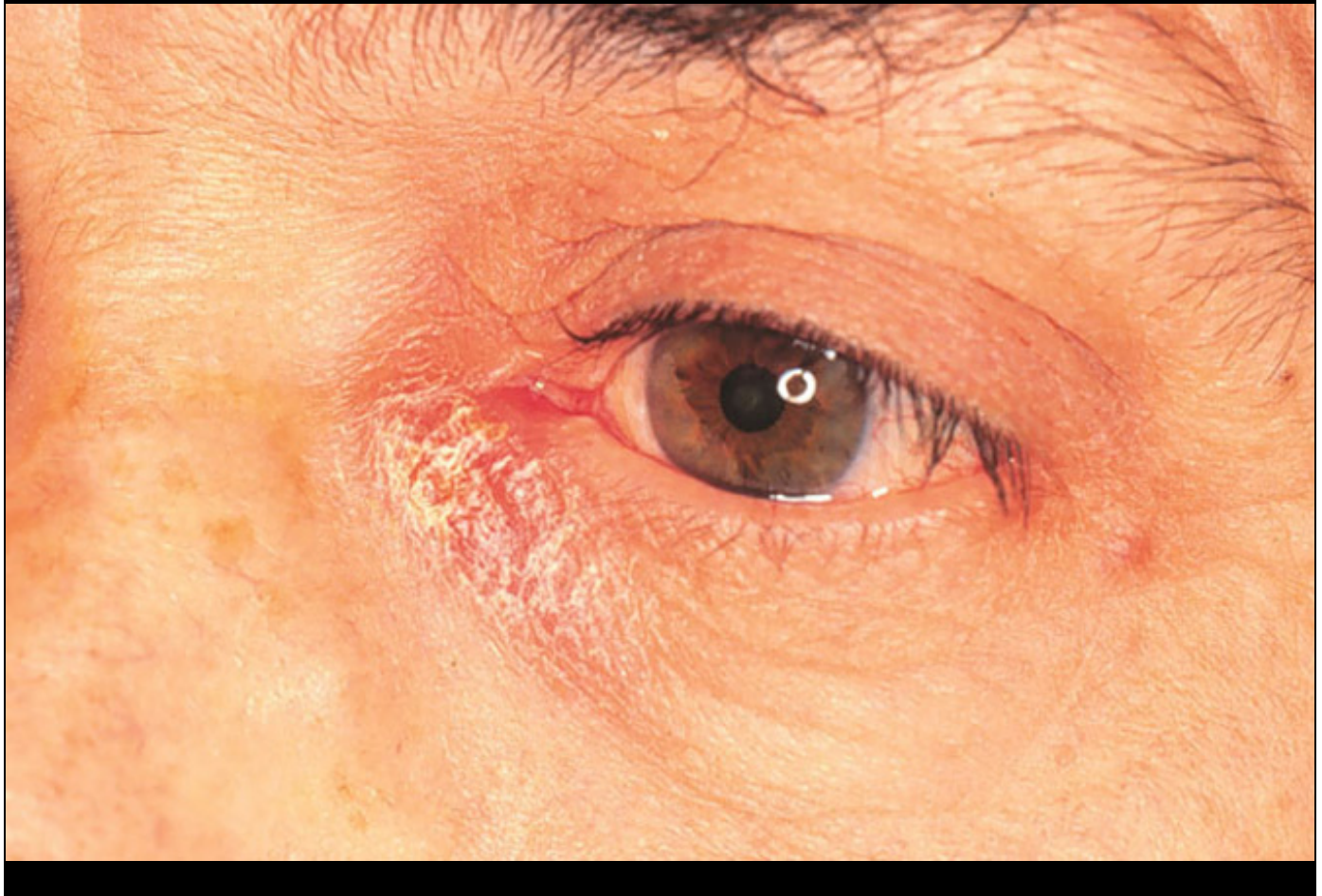


© Copyright [Oculisti OnLine](#)

EyeAtlas

The online Atlas of Ophthalmology

Acute dacryocystitis

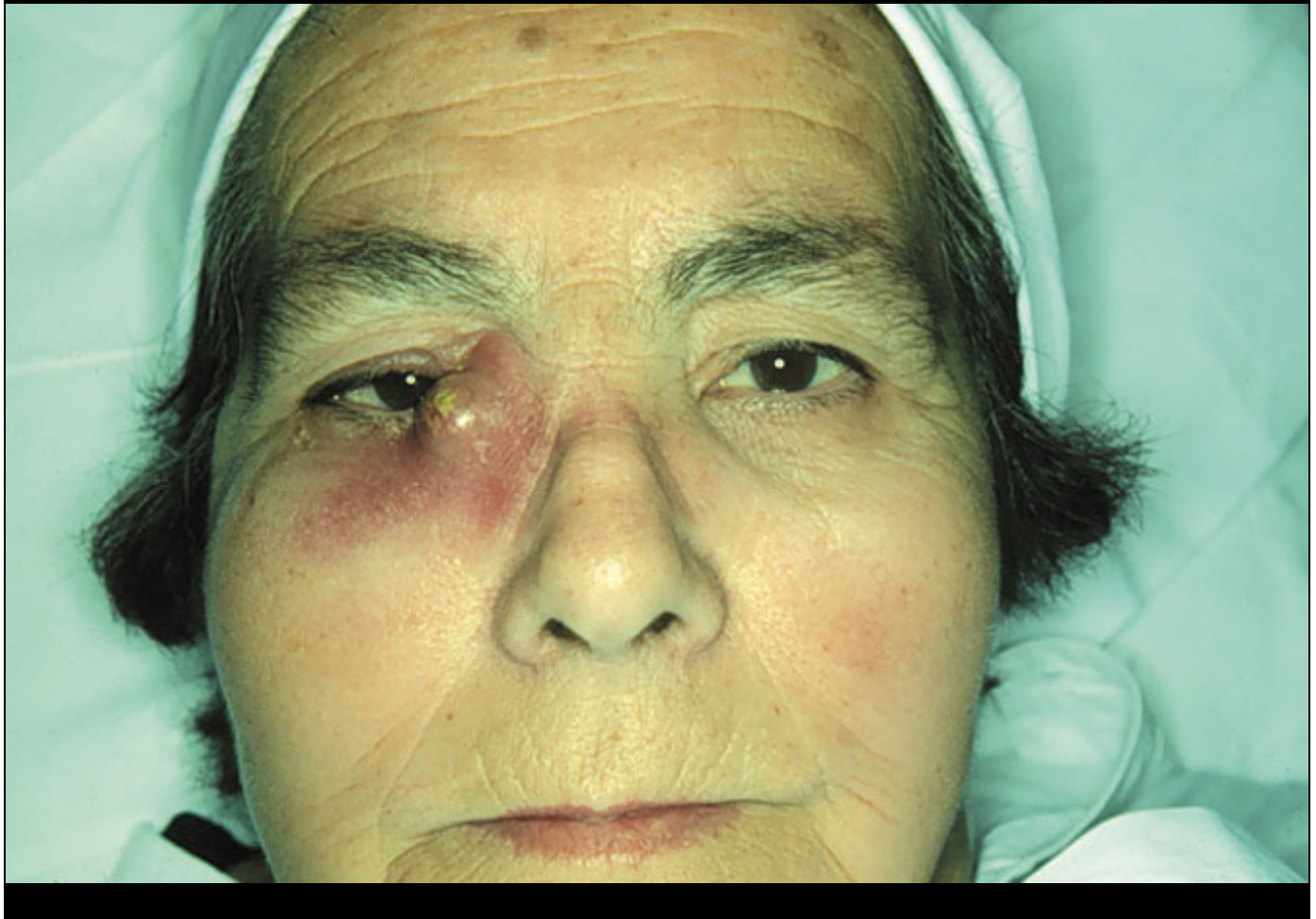

© Copyright [Oculisti OnLine](#)

EyeAtlas

The online Atlas of Ophthalmology

Acute dacryocystitis

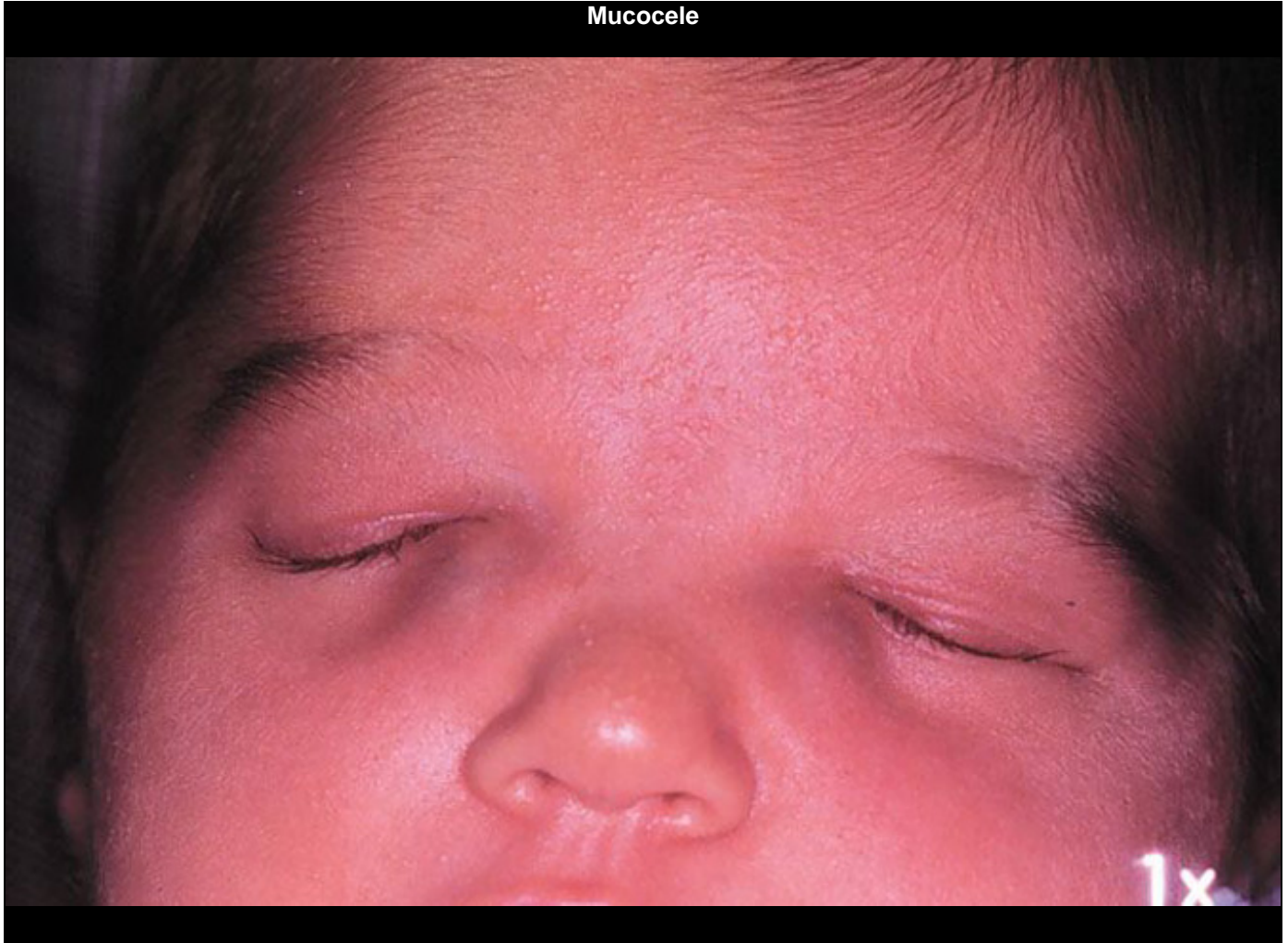


© Copyright [Oculisti OnLine](http://www.eyeatlas.com)

EyeAtlas

The online Atlas of Ophthalmology

Mucocele

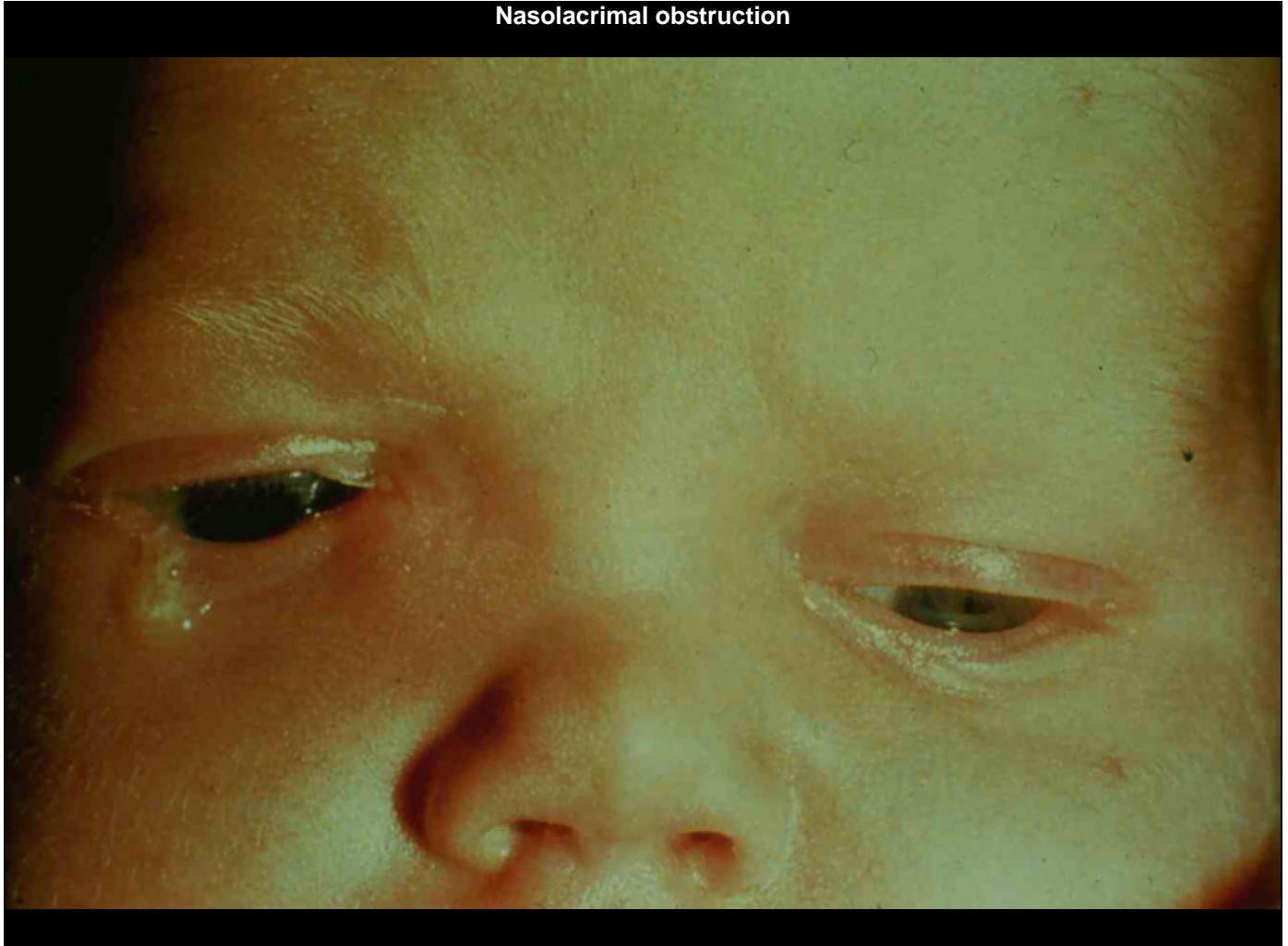


© Copyright [Oculisti OnLine](#)

EyeAtlas

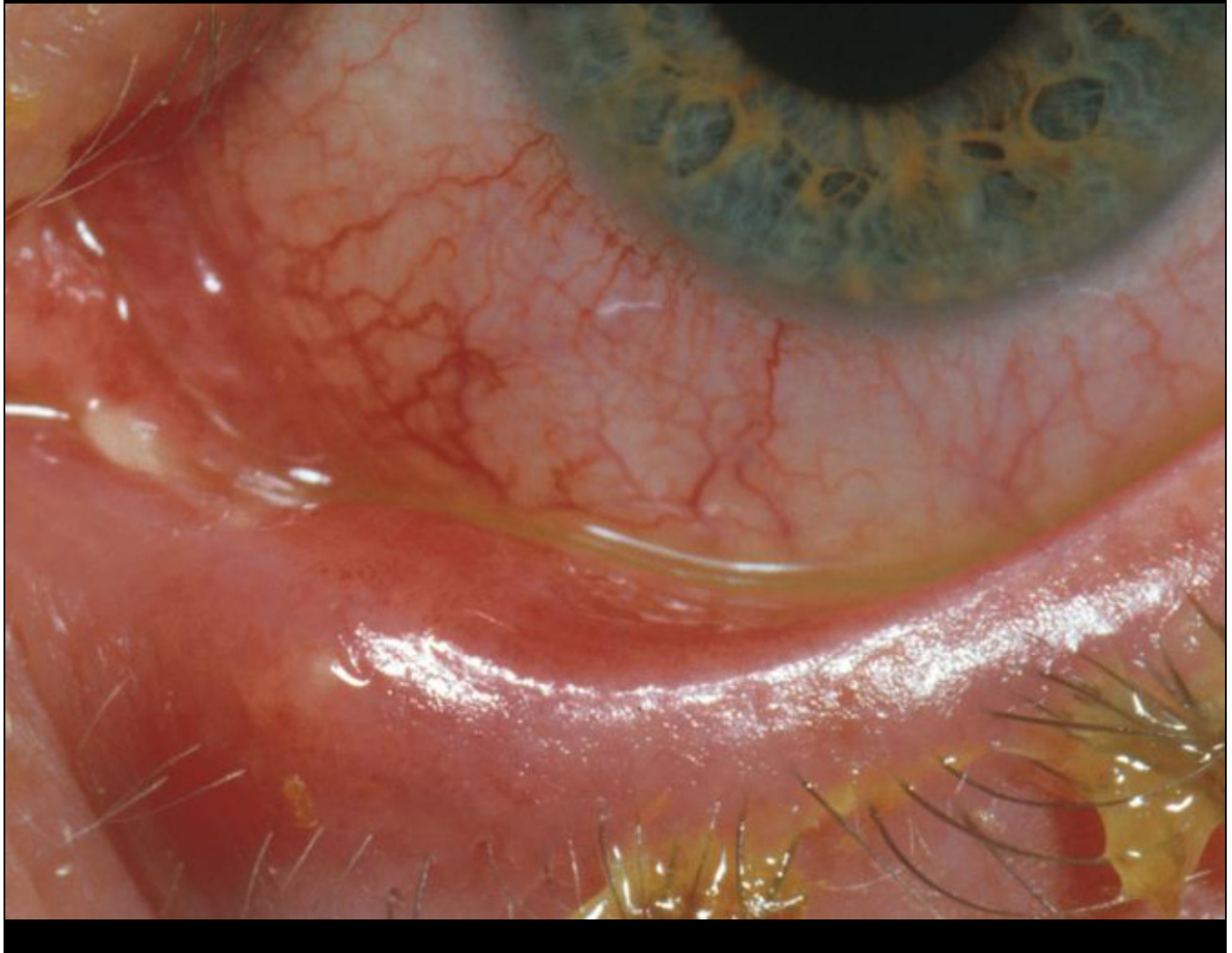
The online Atlas of Ophthalmology

Nasolacrimal obstruction



© Copyright [Oculisti OnLine](#)

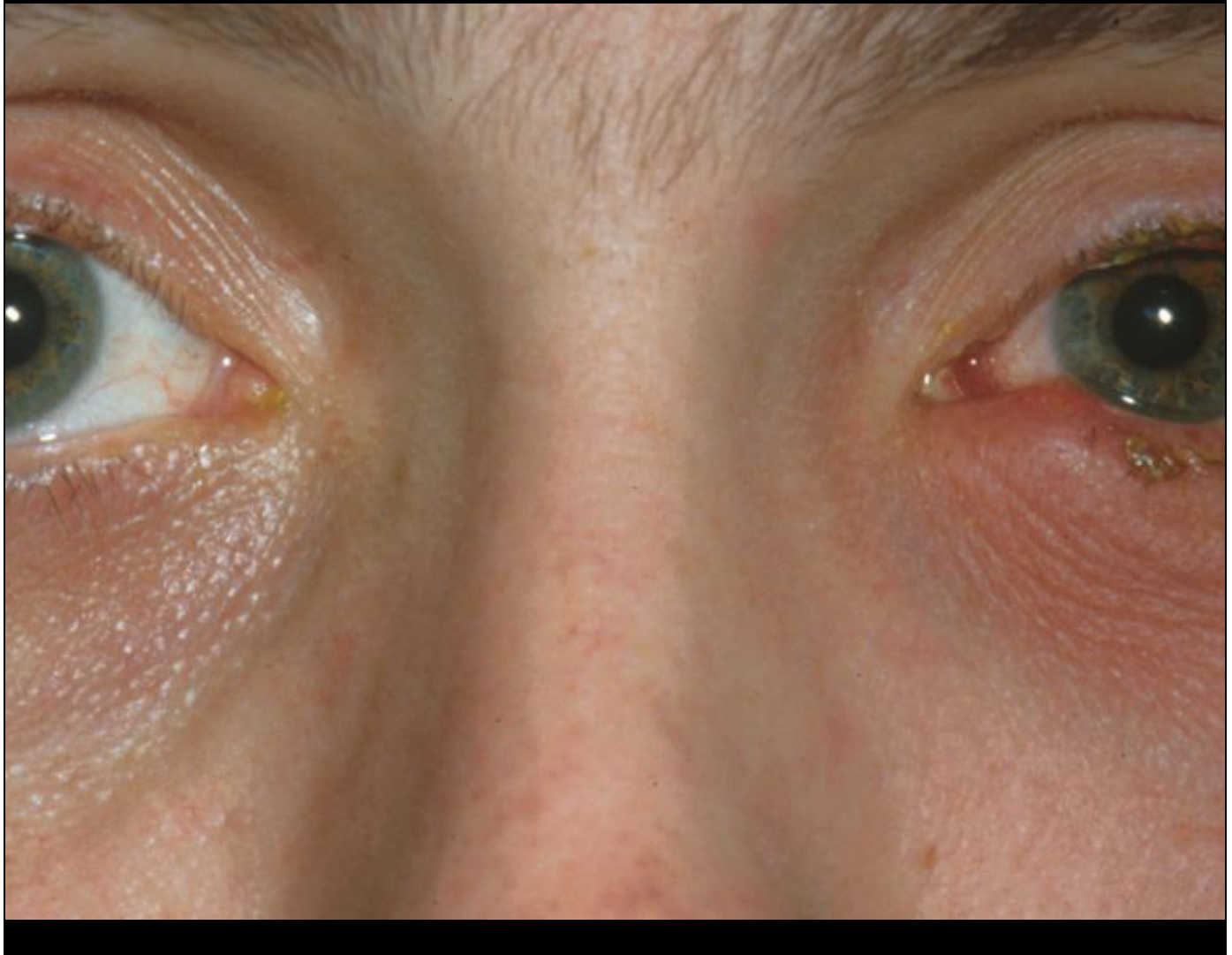Pseudocanalculitis after chalazium



EyeAtlas

The online Atlas of Ophthalmology

Pseudocanalculitis after chalazium

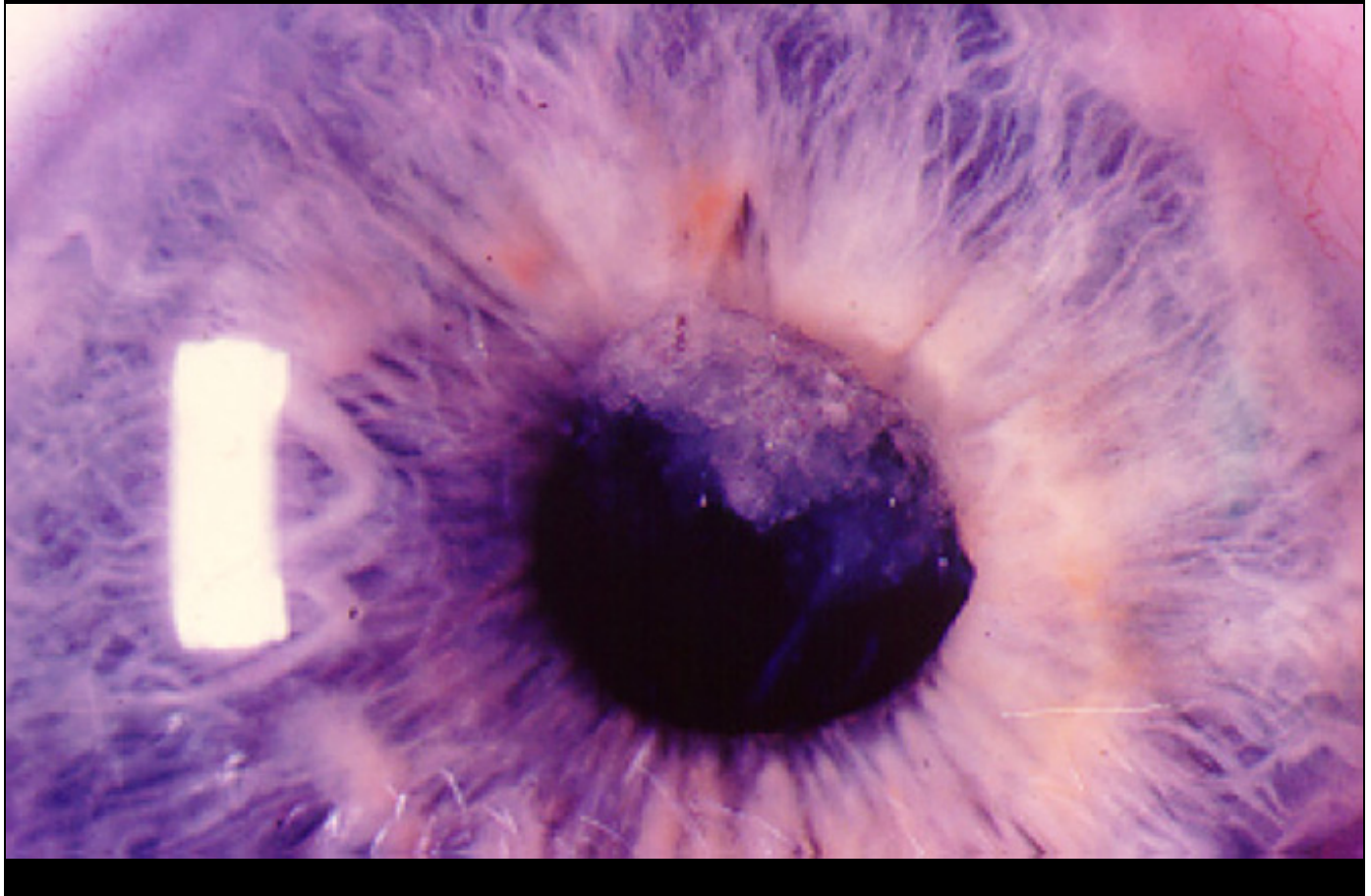

© Copyright [Oculisti OnLine](http://www.eyeatlas.com)

EyeAtlas

The online Atlas of Ophthalmology

Surgical aphakia




© Copyright [Oculisti OnLine](#)

Eyeatlas

The online Atlas of Ophthalmology

Capsular fibrosis

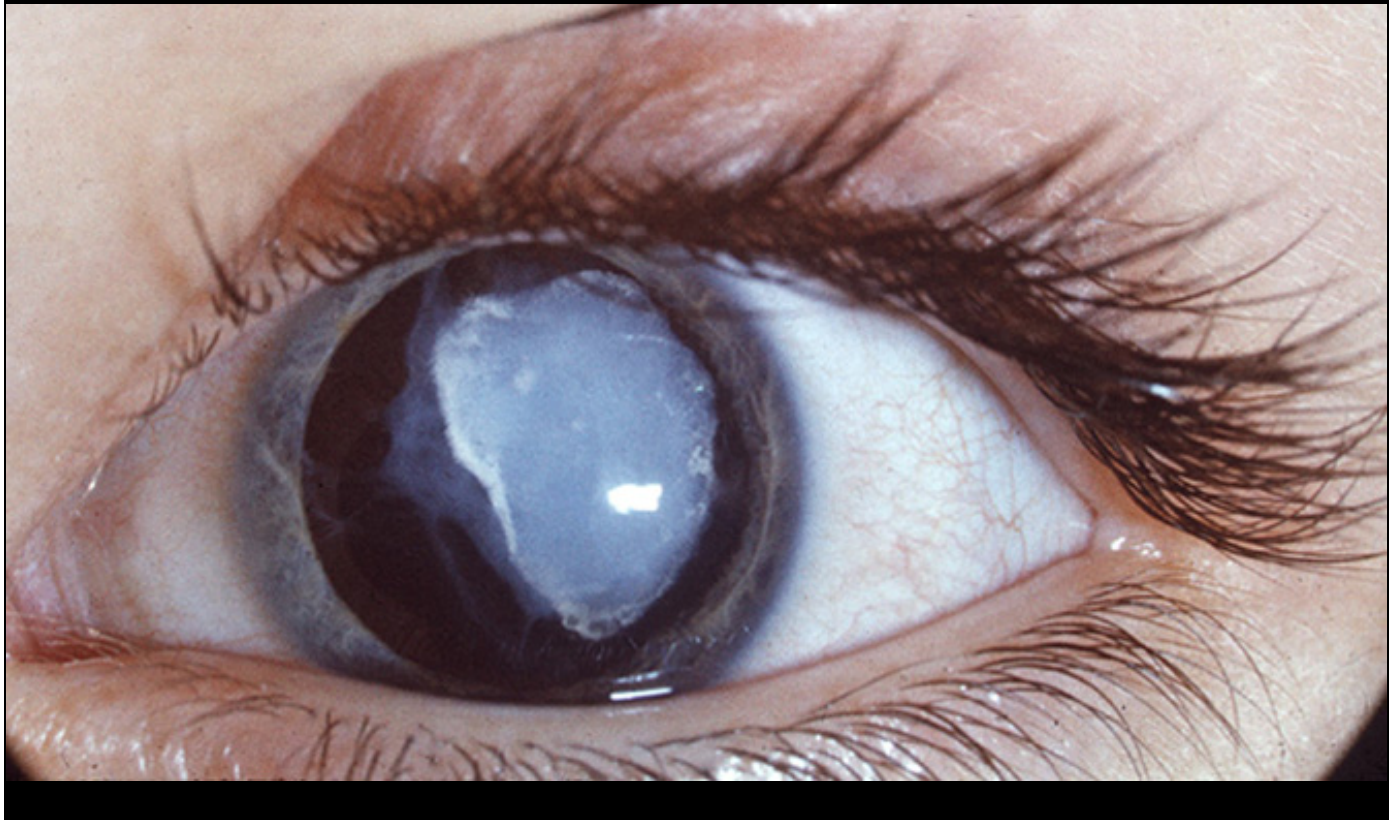


© Copyright [Oculisti OnLine](#)

EyeAtlas

The online Atlas of Ophthalmology

Lens capsule rupture

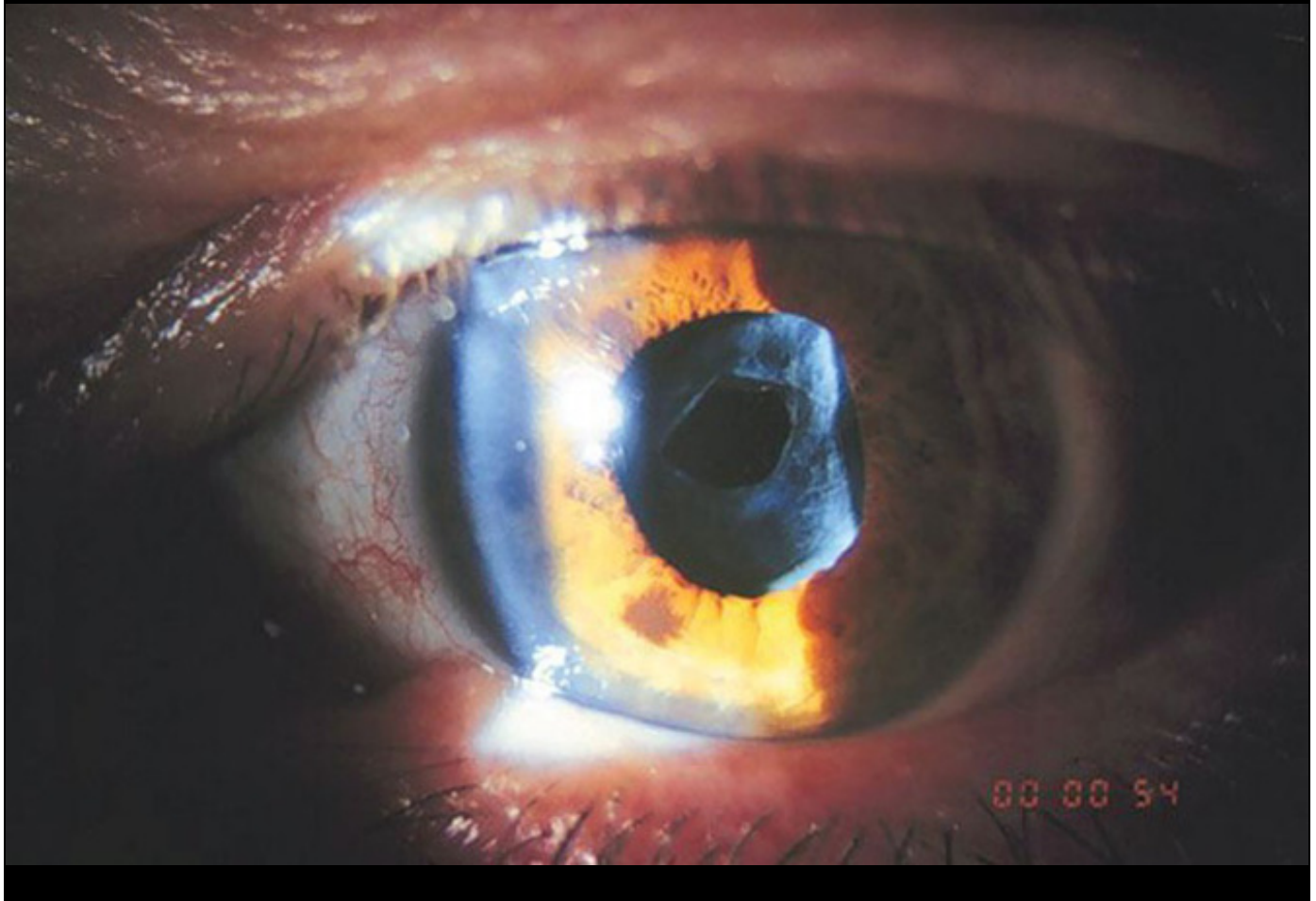


© Copyright [Oculisti OnLine](#)

Eyeatlas

The online Atlas of Ophthalmology

YAG laser capsulotomy

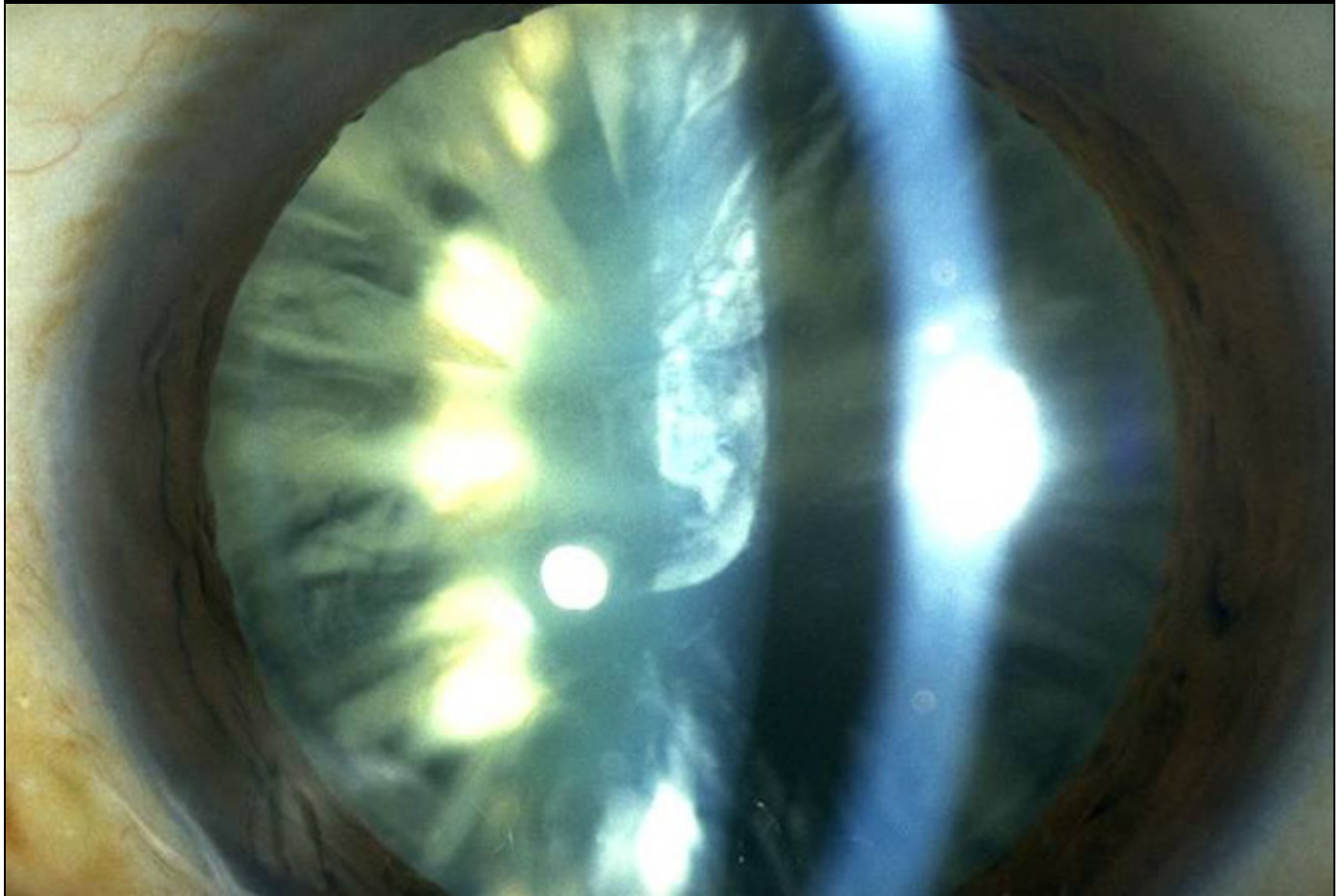


© Copyright [Oculisti OnLine](#)

Eyeatlas

The online Atlas of Ophthalmology

Cataract

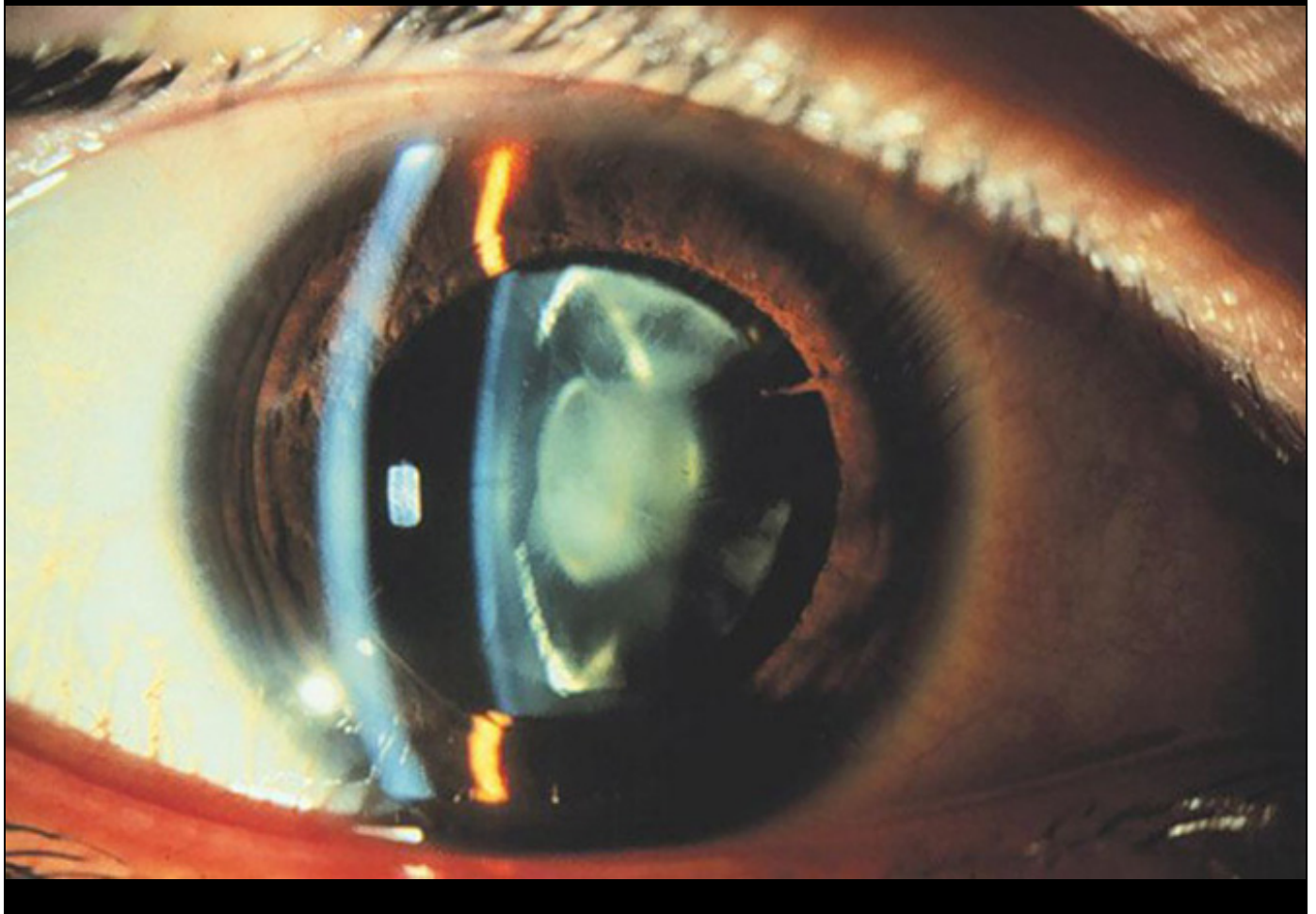


© Copyright [Oculisti OnLine](#)

EyeAtlas

The online Atlas of Ophthalmology

Congenital cataract

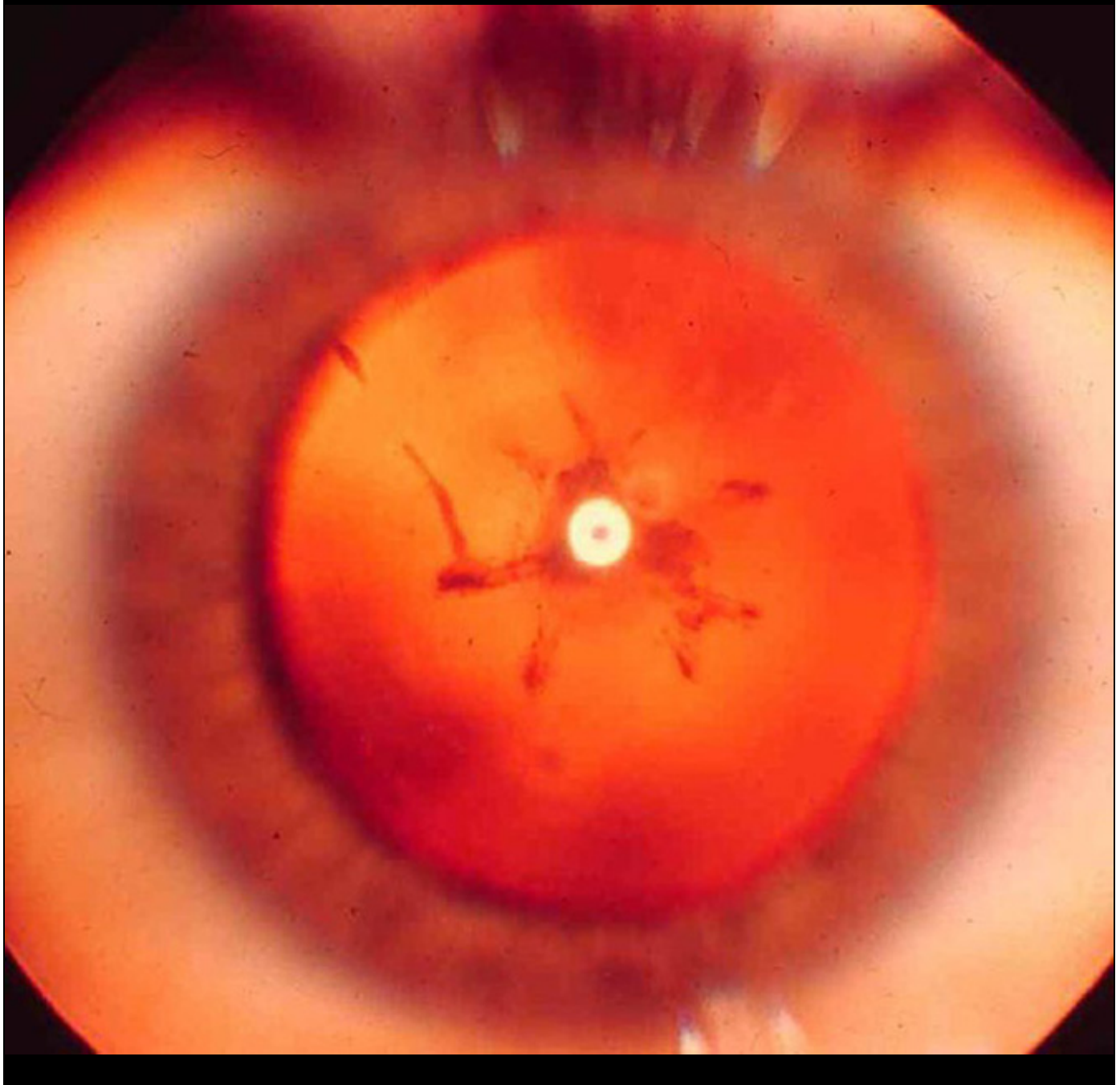


© Copyright [Oculisti OnLine](http://www.eyeatlas.com)

Eyeatlas

The online Atlas of Ophthalmology

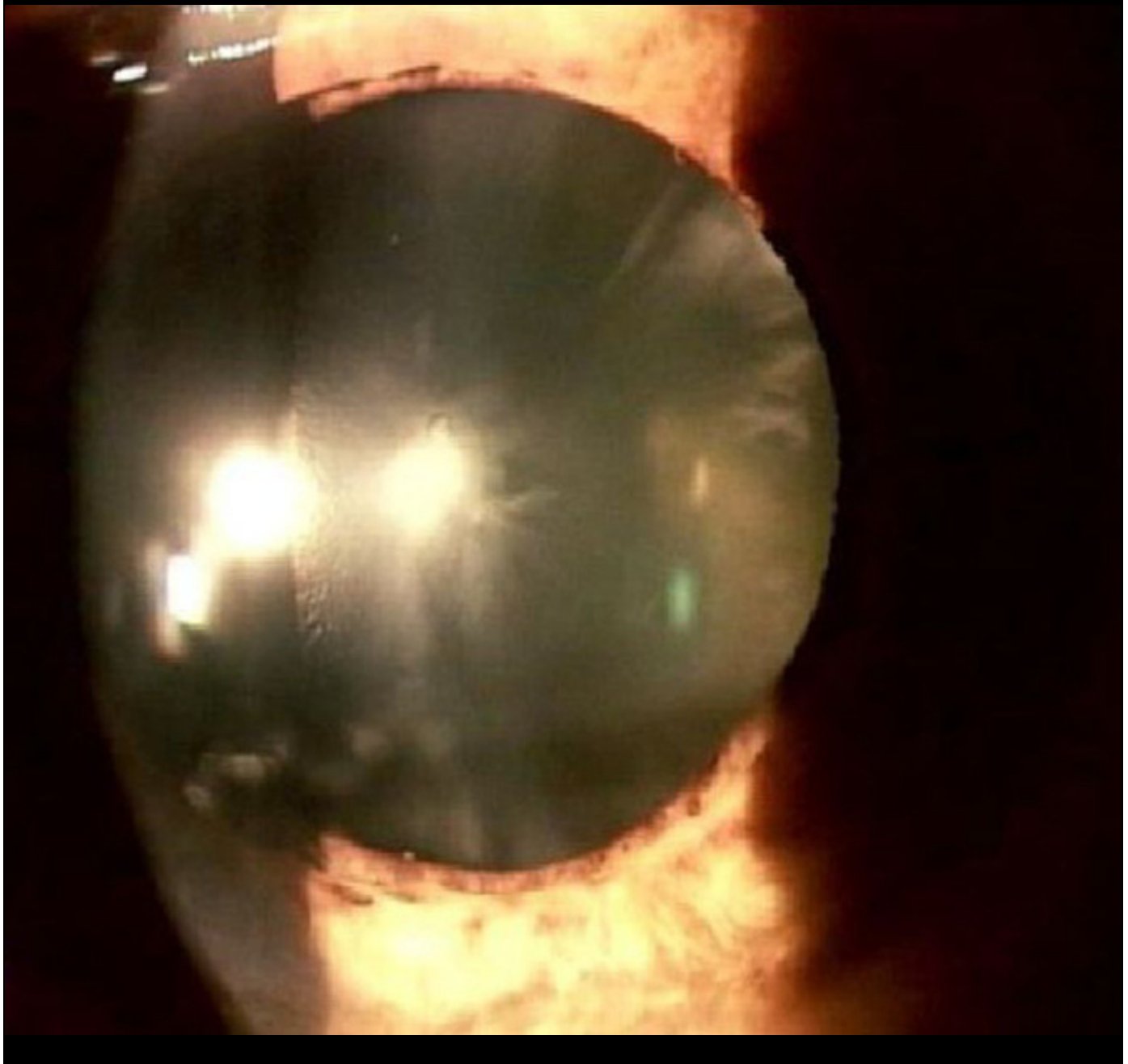
Congenital cataract



EyeAtlas

The online Atlas of Ophthalmology

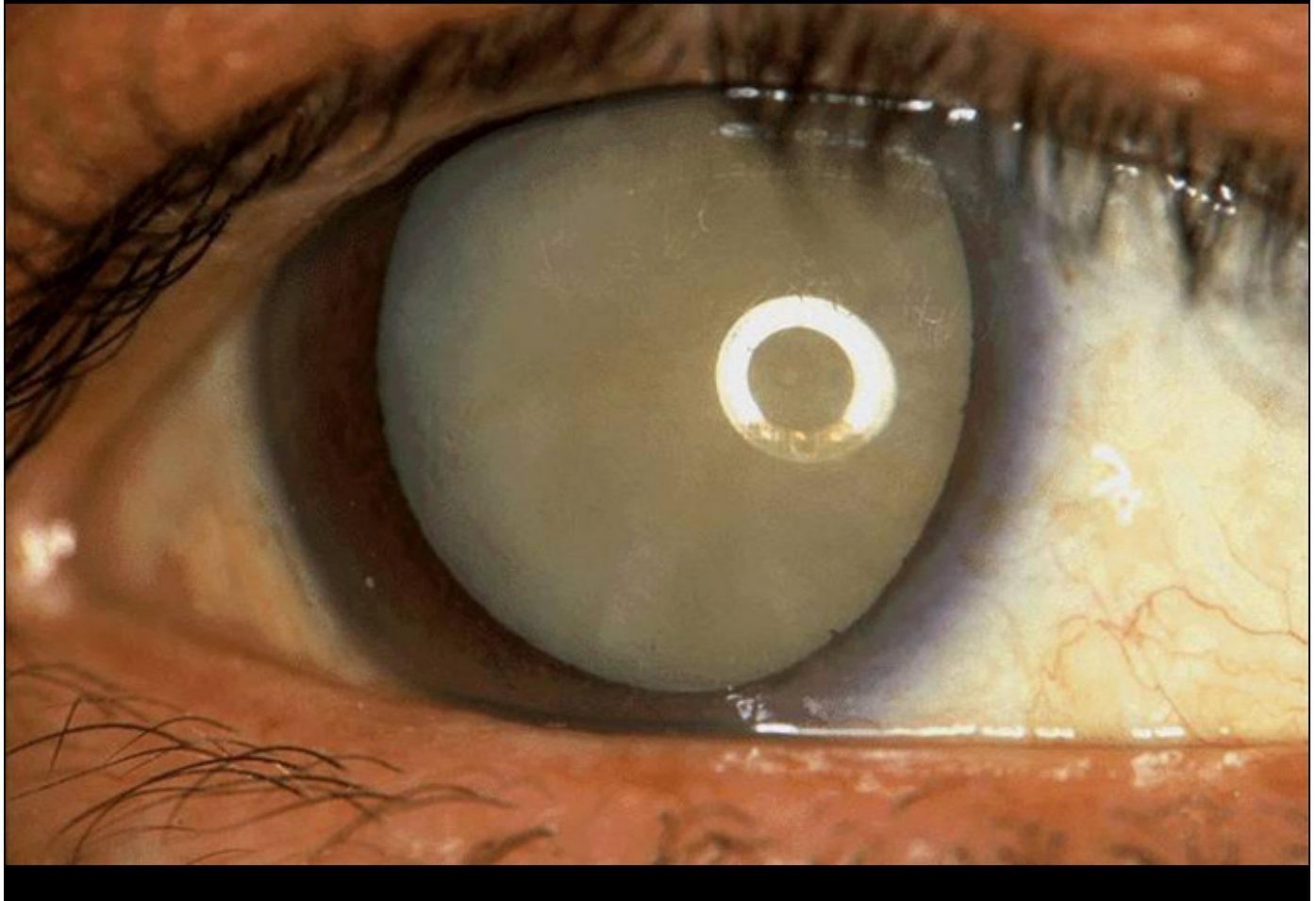
Corticonuclear cataract



EyeAtlas

The online Atlas of Ophthalmology

Mature cataract

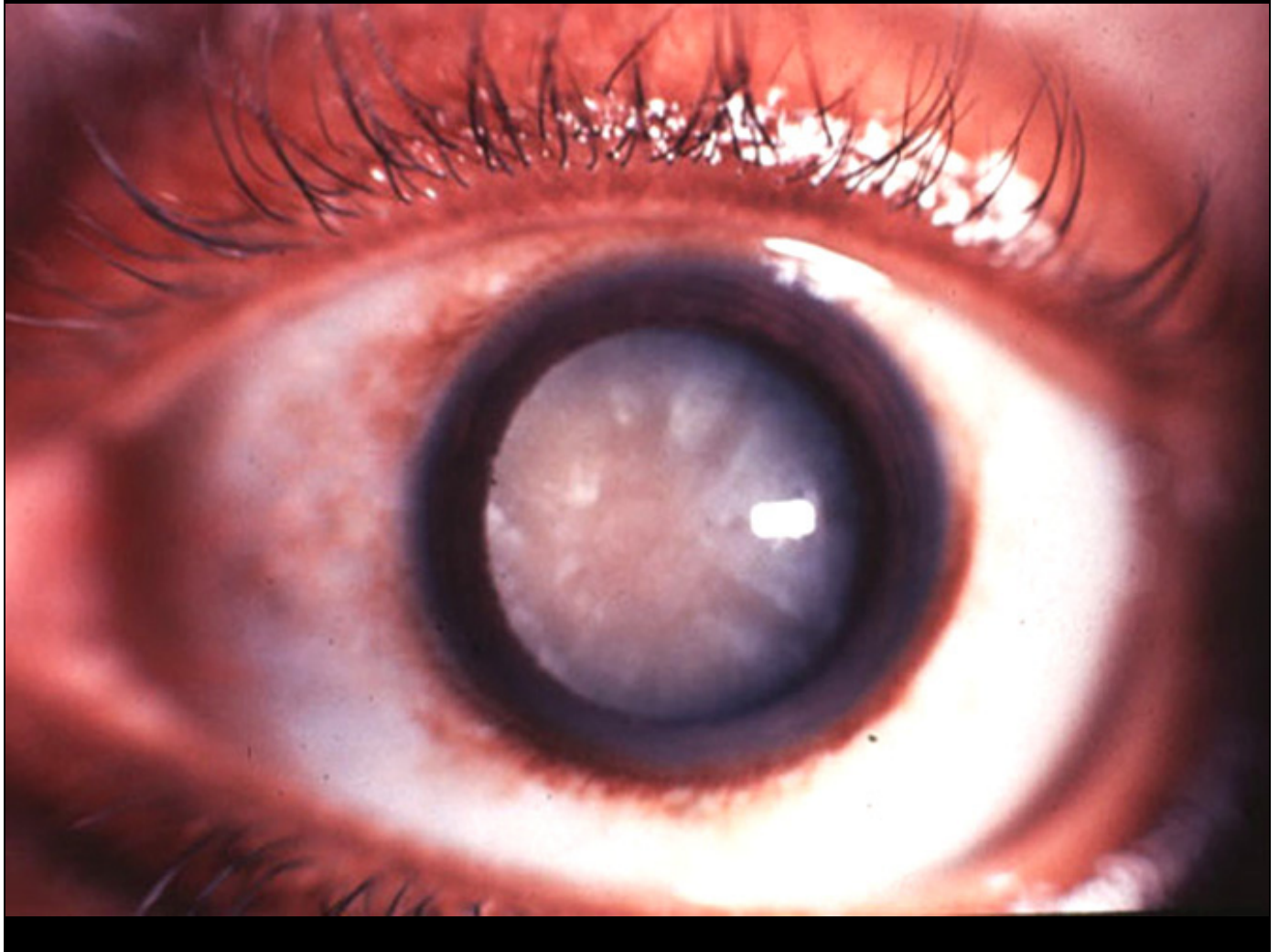


© Copyright [Oculisti OnLine](http://www.eyeatlas.com)

EyeAtlas

The online Atlas of Ophthalmology

Mature cataract

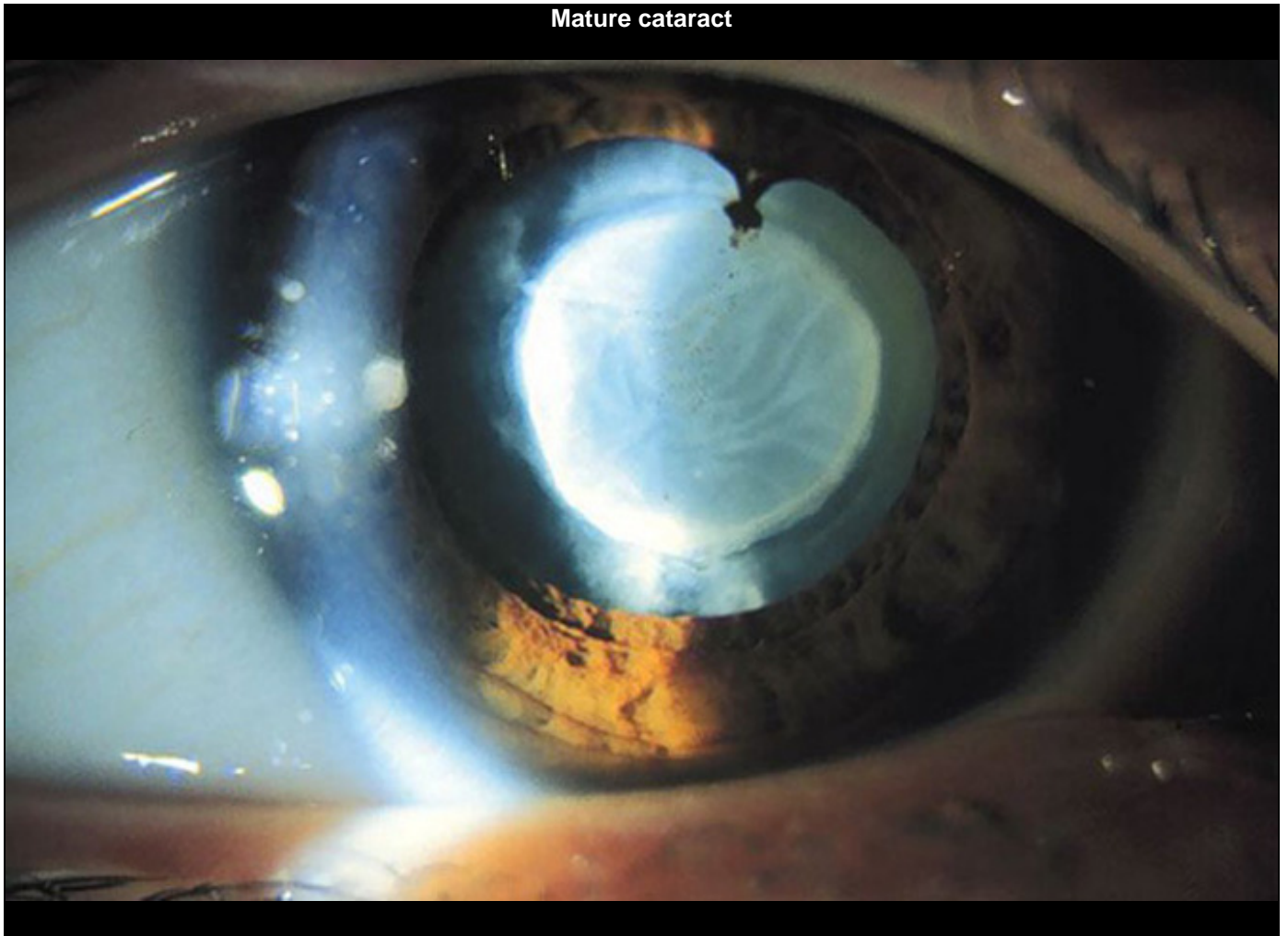


© Copyright [Oculisti OnLine](http://www.eyeatlas.com)

EyeAtlas

The online Atlas of Ophthalmology

Mature cataract

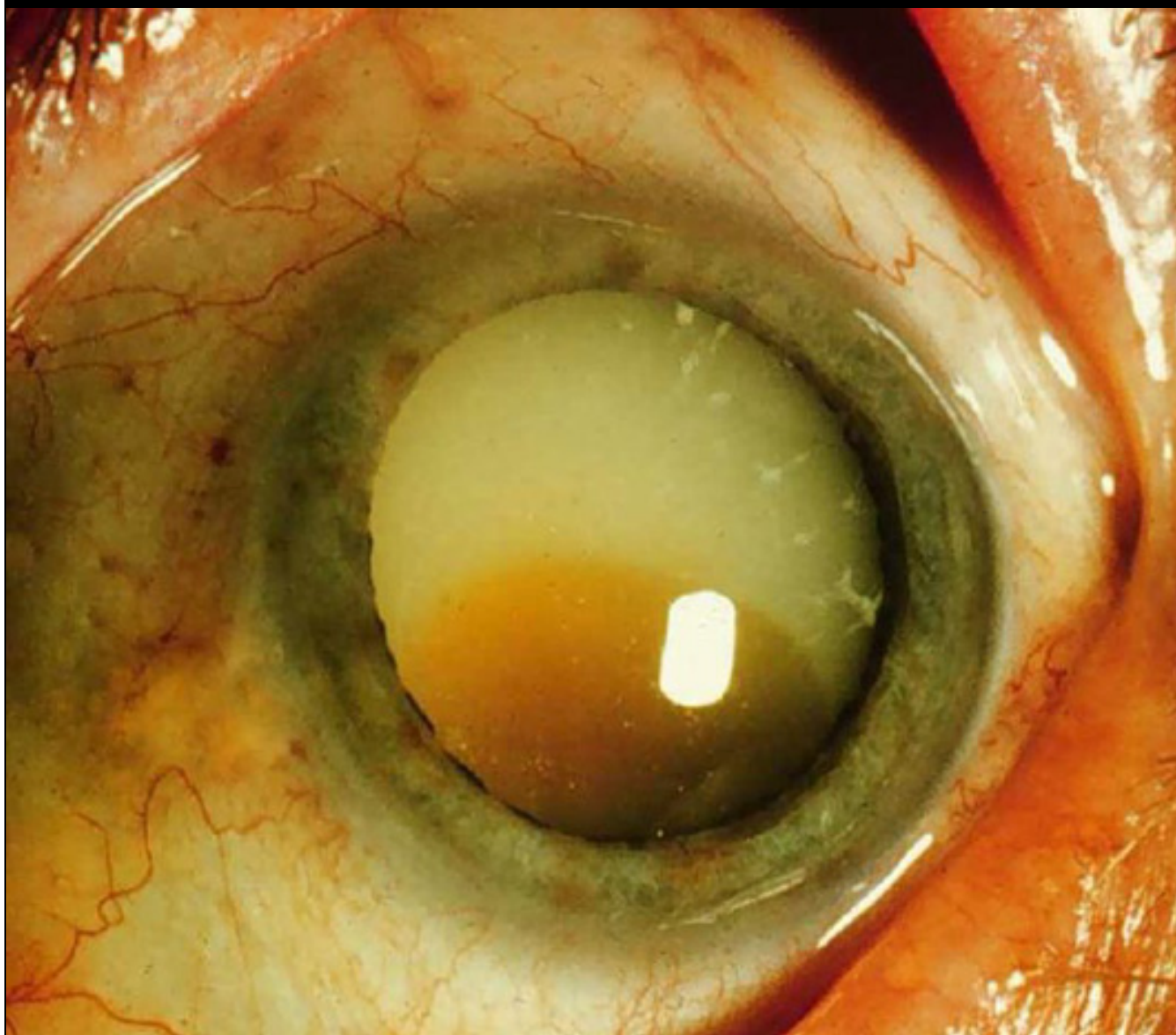


© Copyright [Oculisti OnLine](#)

EyeAtlas

The online Atlas of Ophthalmology

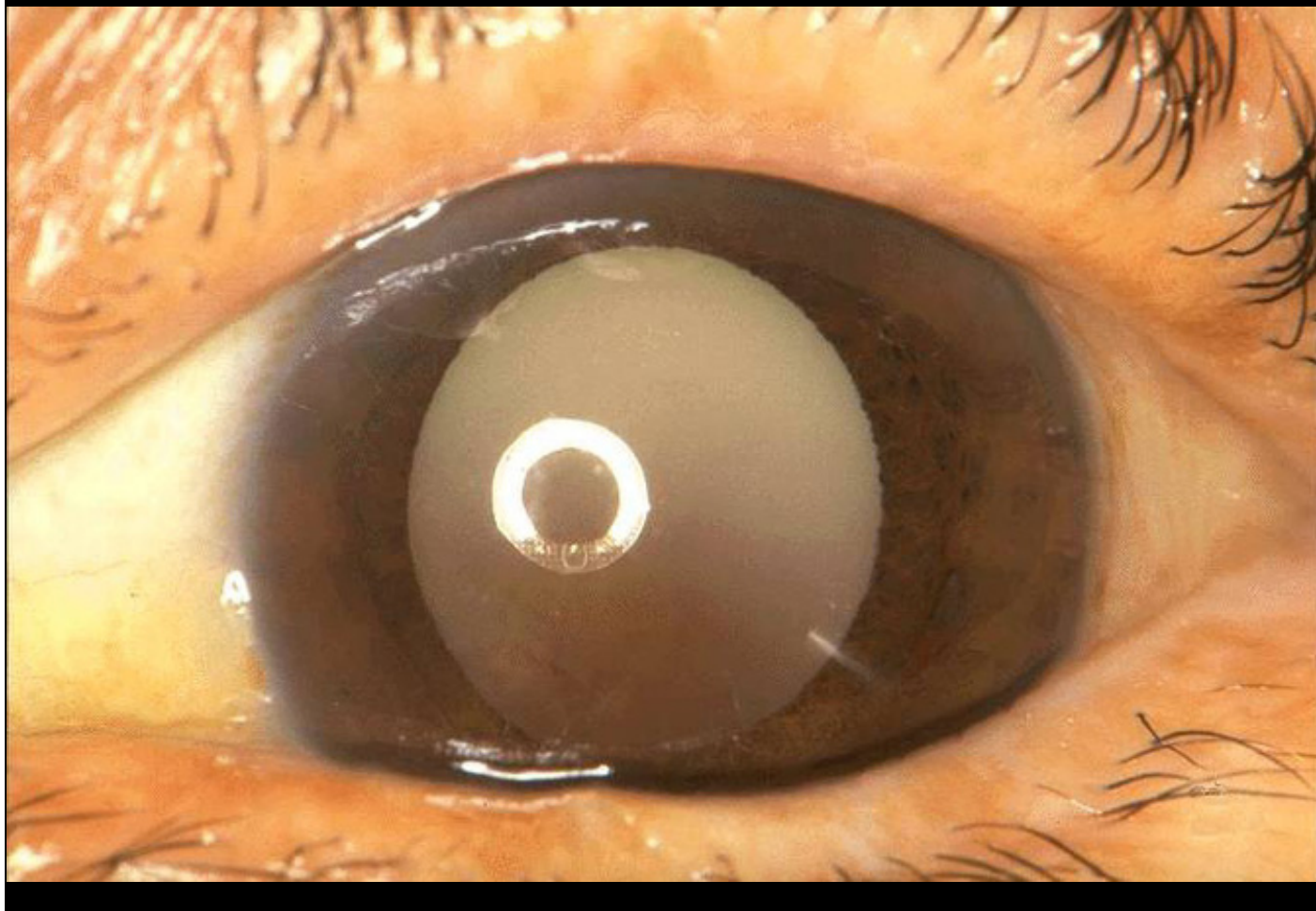
Mature cataract



EyeAtlas

The online Atlas of Ophthalmology

Morganian cataract

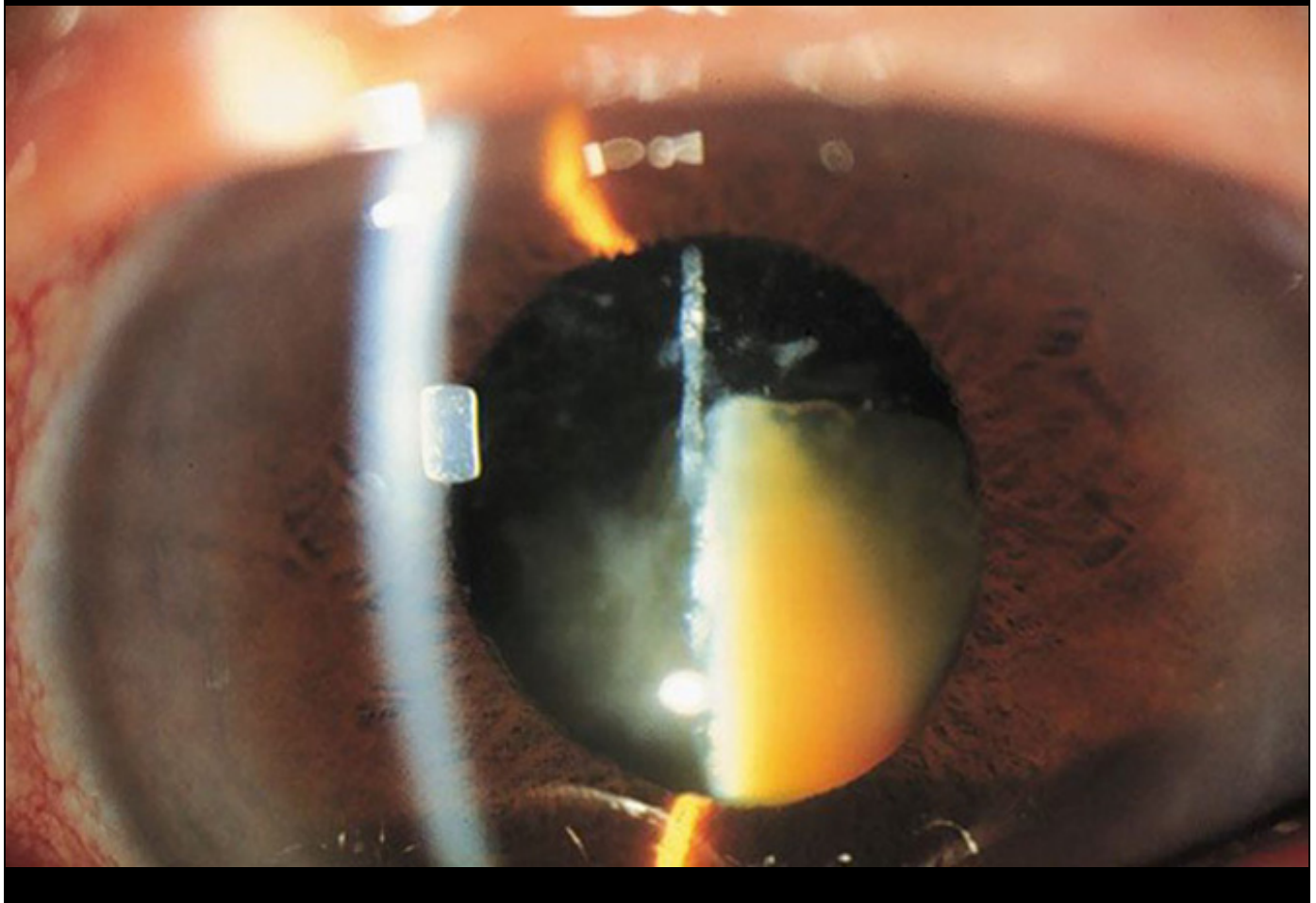


© Copyright [Oculisti OnLine](http://www.eyeatlas.com)

EyeAtlas

The online Atlas of Ophthalmology

Morganian cataract

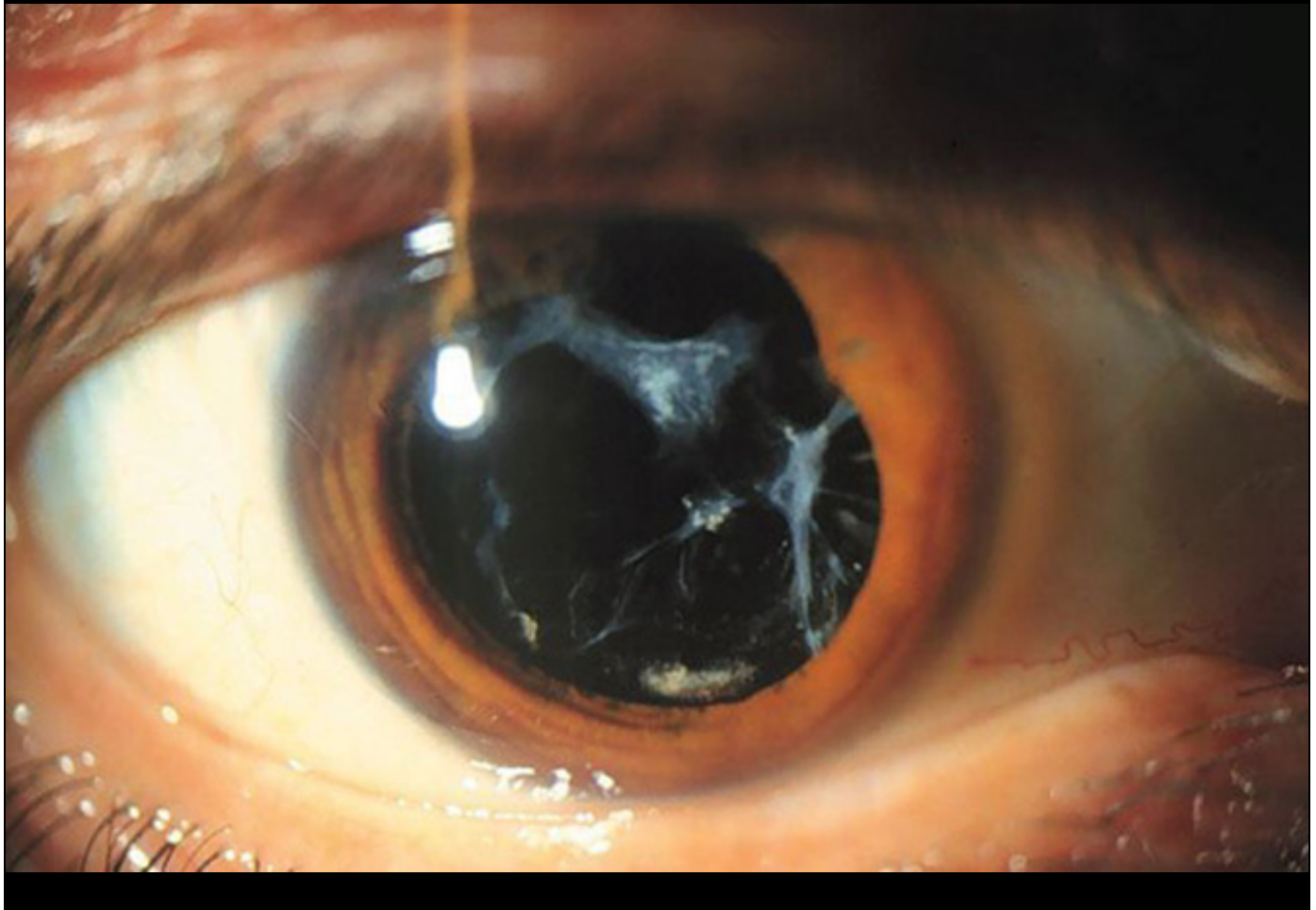

© Copyright [Oculisti OnLine](http://www.eyeatlas.com)

Eyeatlas

The online Atlas of Ophthalmology

Secondary cataract

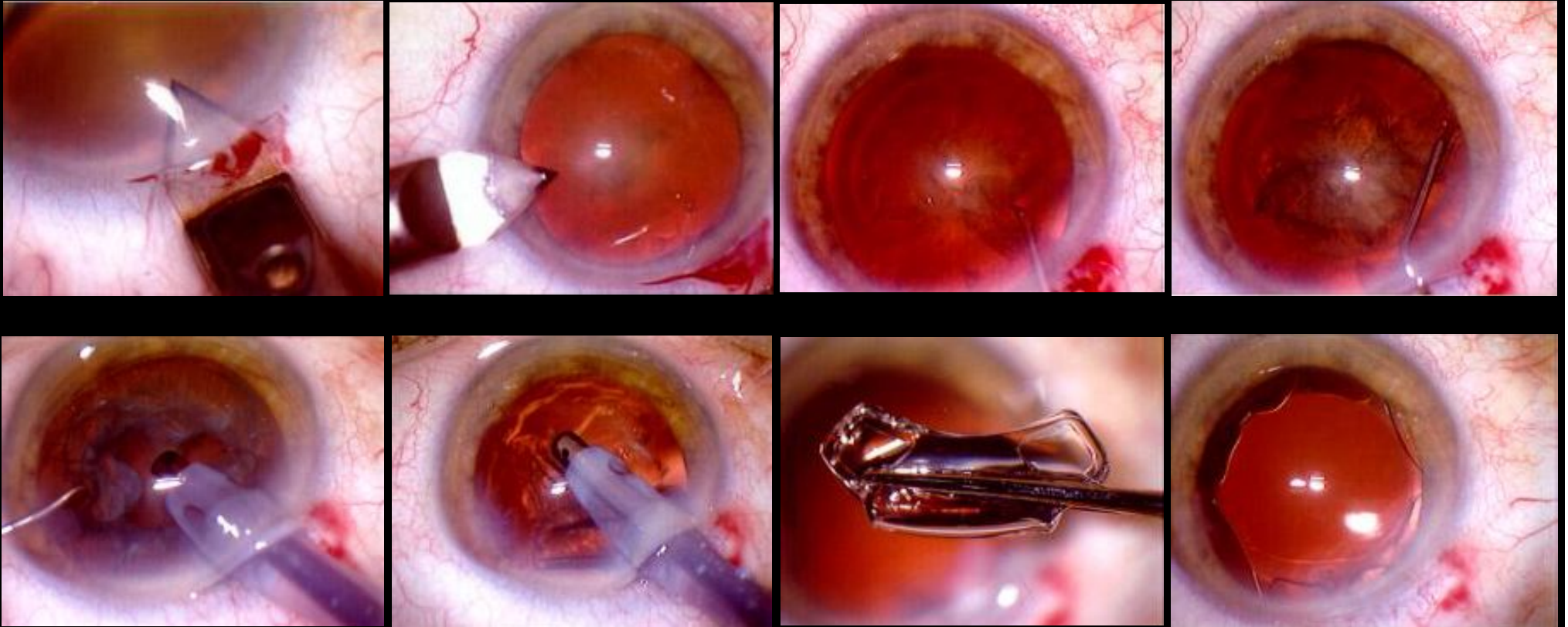


© Copyright [Oculisti OnLine](http://www.eyeatlas.com)

EyeAtlas

The online Atlas of Ophthalmology

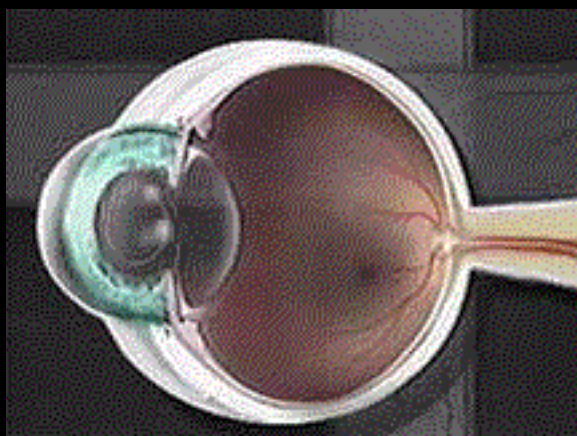
Cataract surgery



Eyeatlas

The online Atlas of Ophthalmology

Cataract surgery (animation)

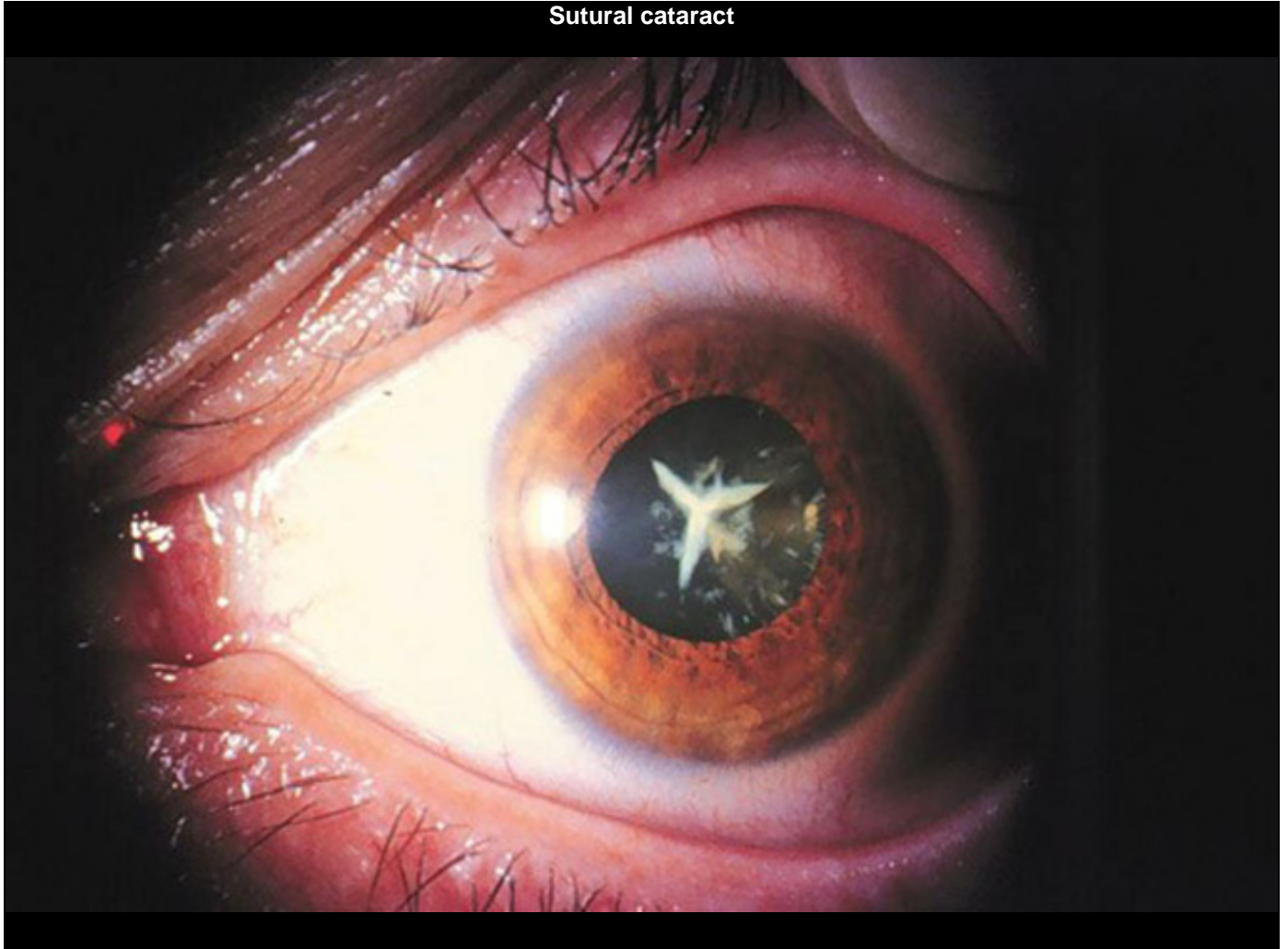

© Copyright [Oculisti OnLine](#)

EyeAtlas

The online Atlas of Ophthalmology

Sutural cataract

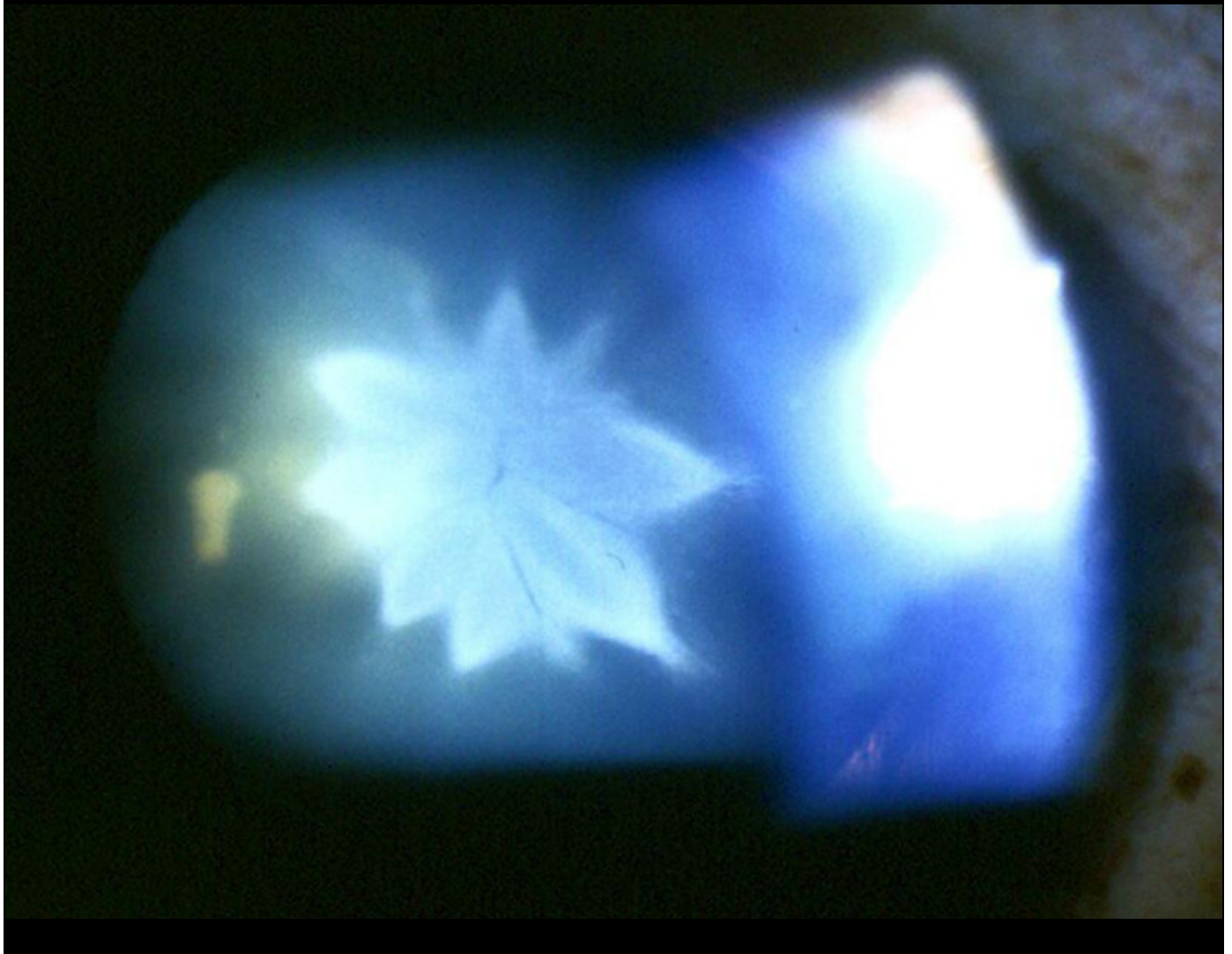


© Copyright [Oculisti OnLine](http://www.eyeatlas.com)

Eyeatlas

The online Atlas of Ophthalmology

Cataract after trauma: retroillumination

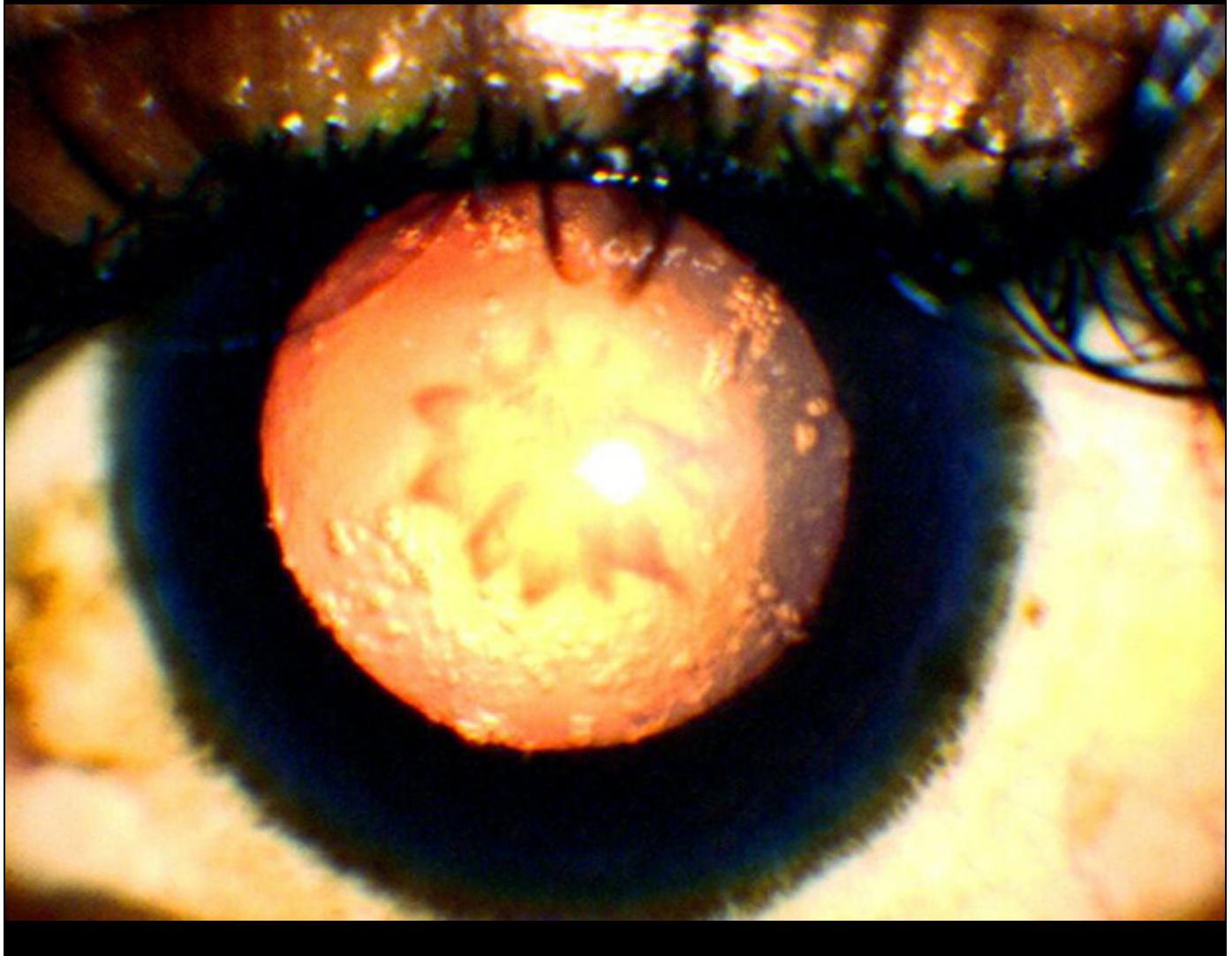


© Copyright [Oculisti OnLine](http://www.eyeatlas.com)

Eyeatlas

The online Atlas of Ophthalmology

Cataract after trauma: retroillumination

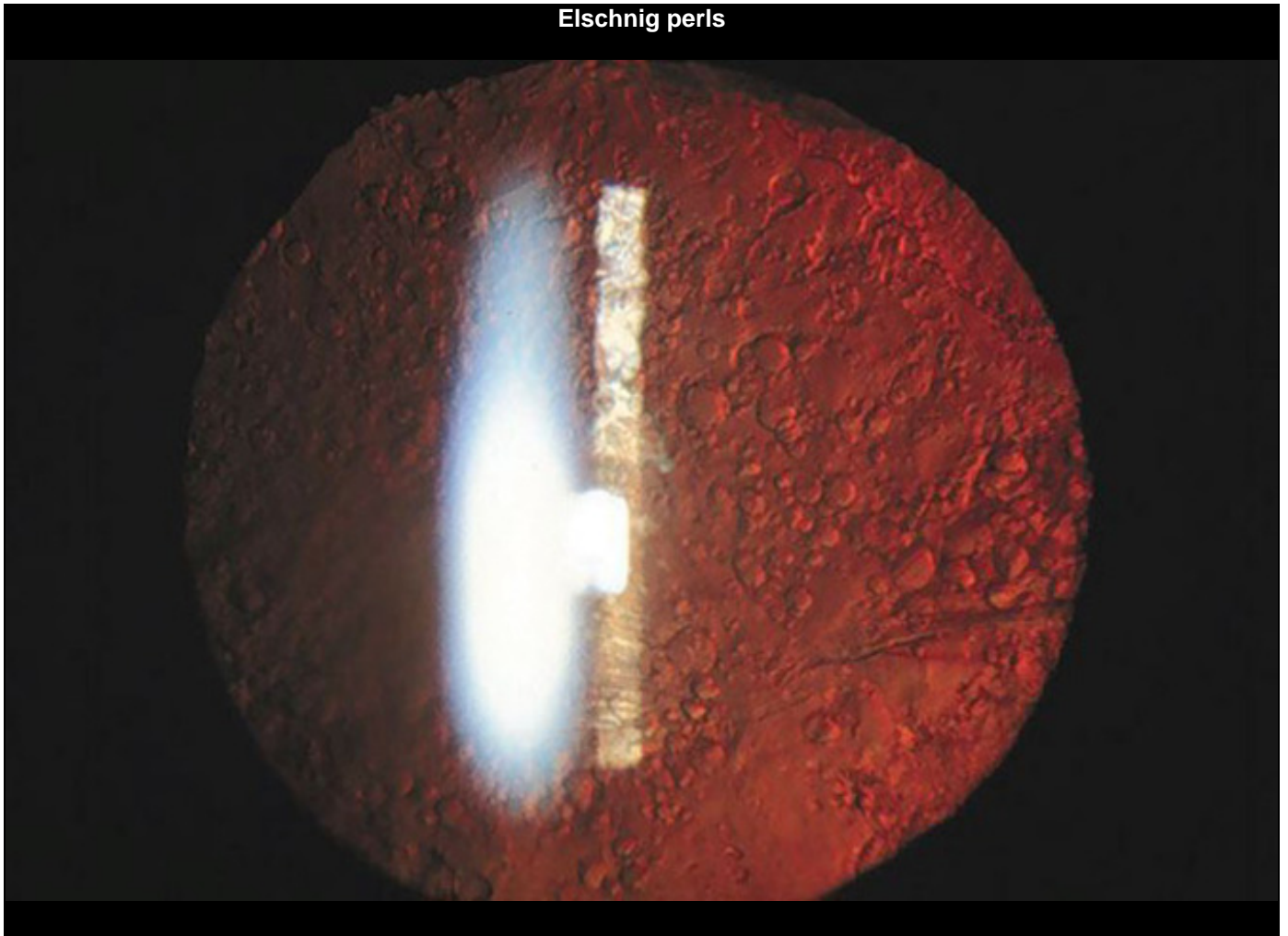


© Copyright [Oculisti OnLine](http://www.eyeatlas.com)

EyeAtlas

The online Atlas of Ophthalmology

Elschnig perls

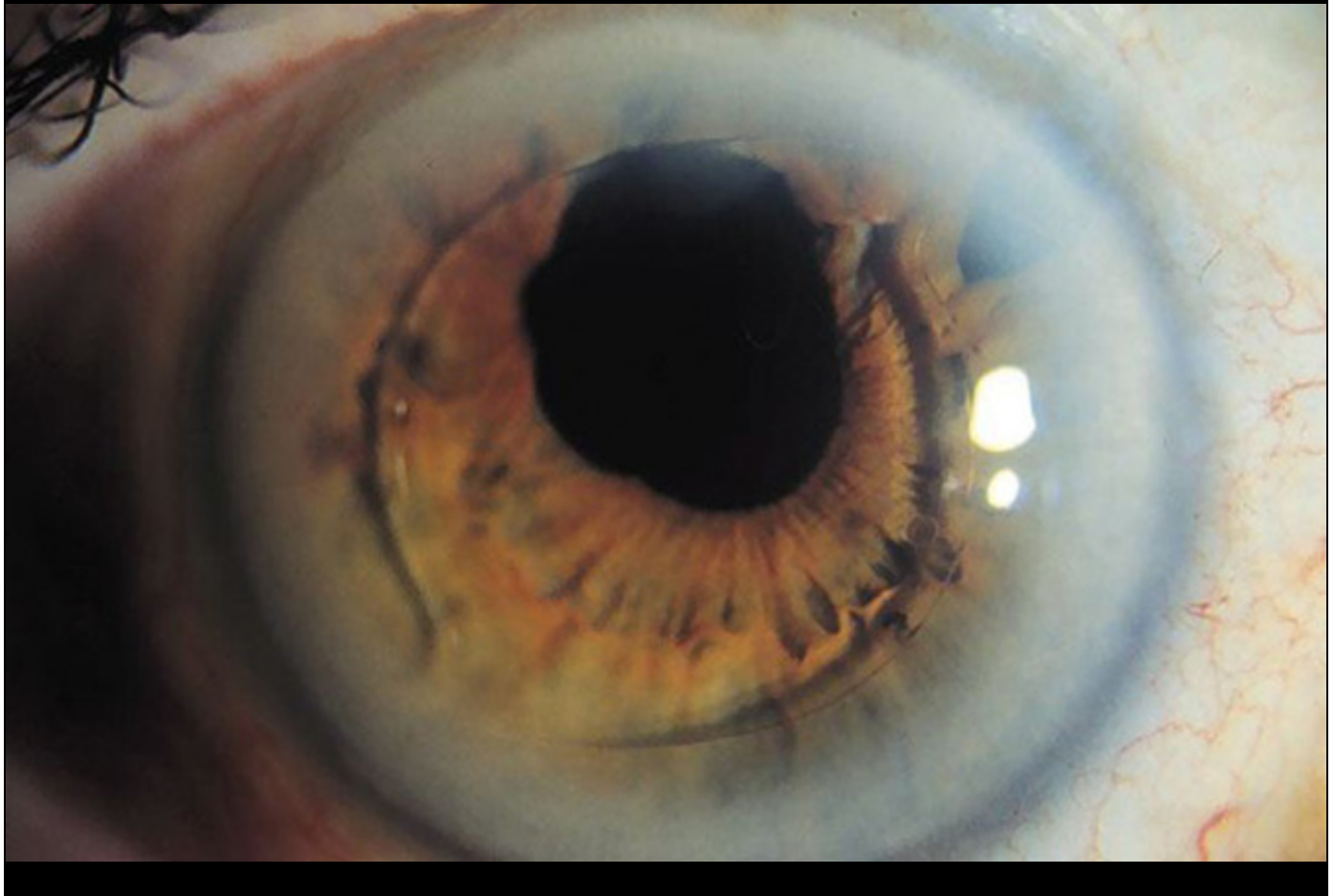


© Copyright [Oculisti OnLine](#)

EyeAtlas

The online Atlas of Ophthalmology

Anterior chamber IOL

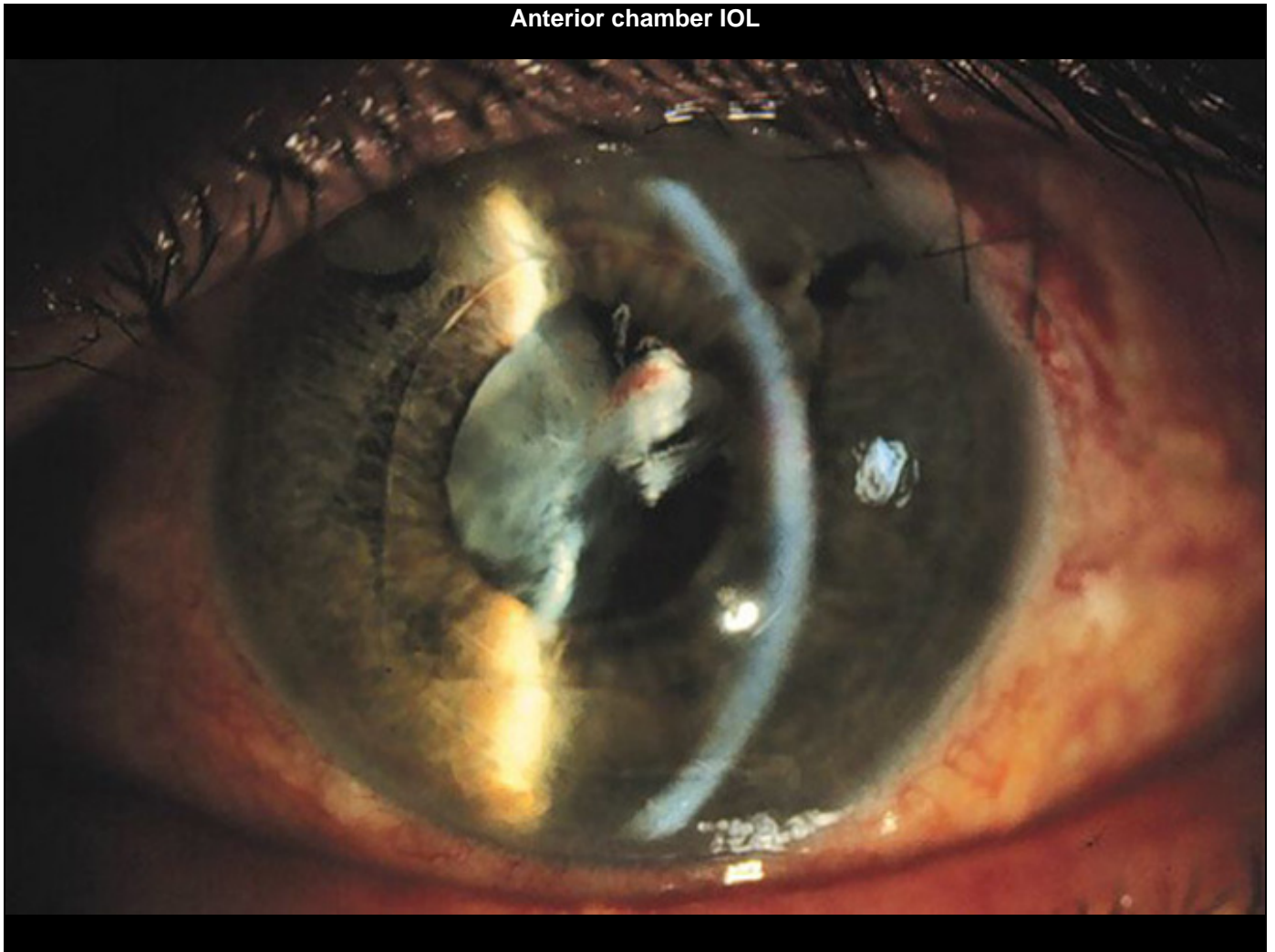

© Copyright [Oculisti OnLine](#)

Eyeatlas

The online Atlas of Ophthalmology

Anterior chamber IOL

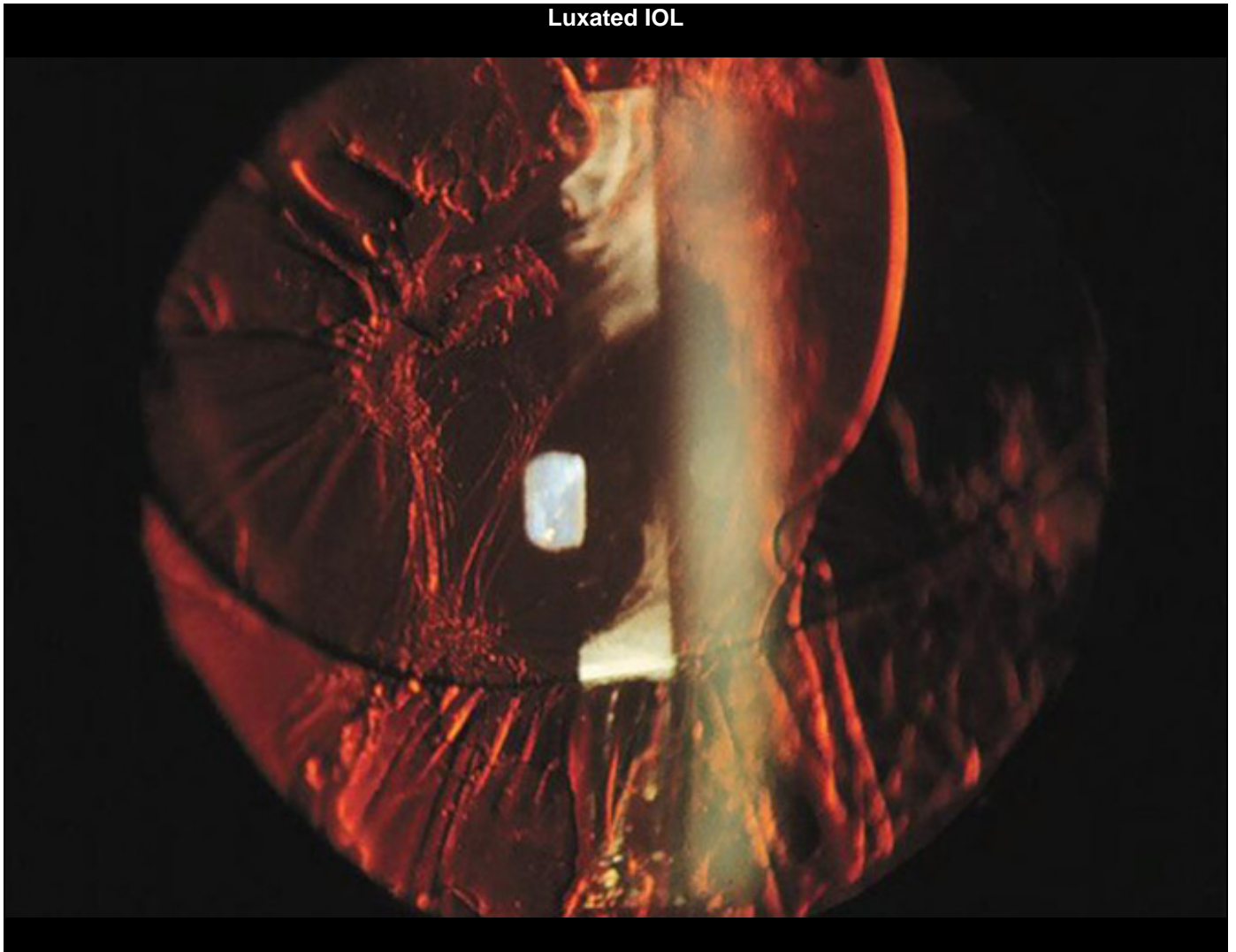

© Copyright [Oculisti OnLine](#)

EyeAtlas

The online Atlas of Ophthalmology

Luxated IOL

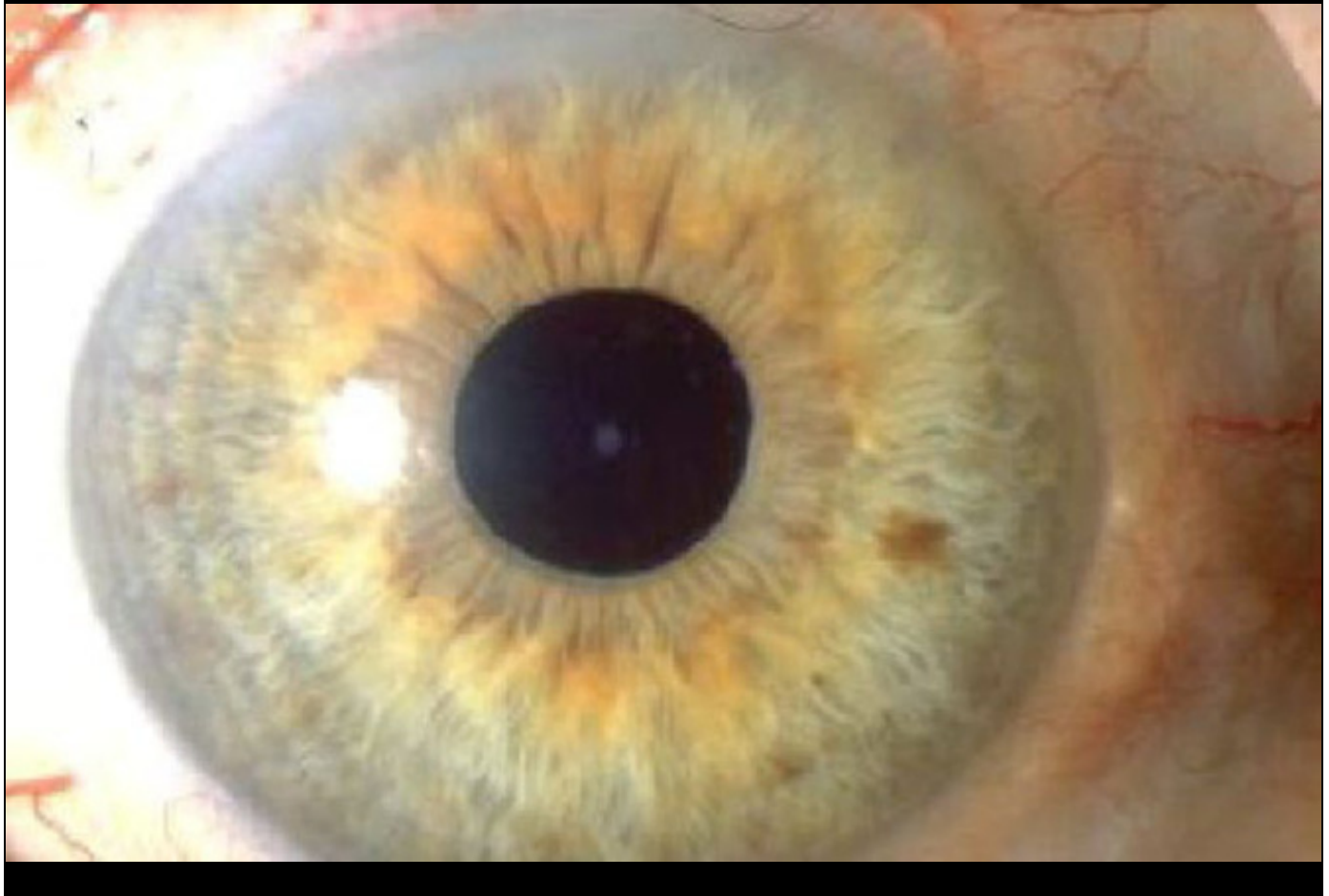


© Copyright [Oculisti OnLine](#)

Eyeatlas

The online Atlas of Ophthalmology

Posterior chamber IOL

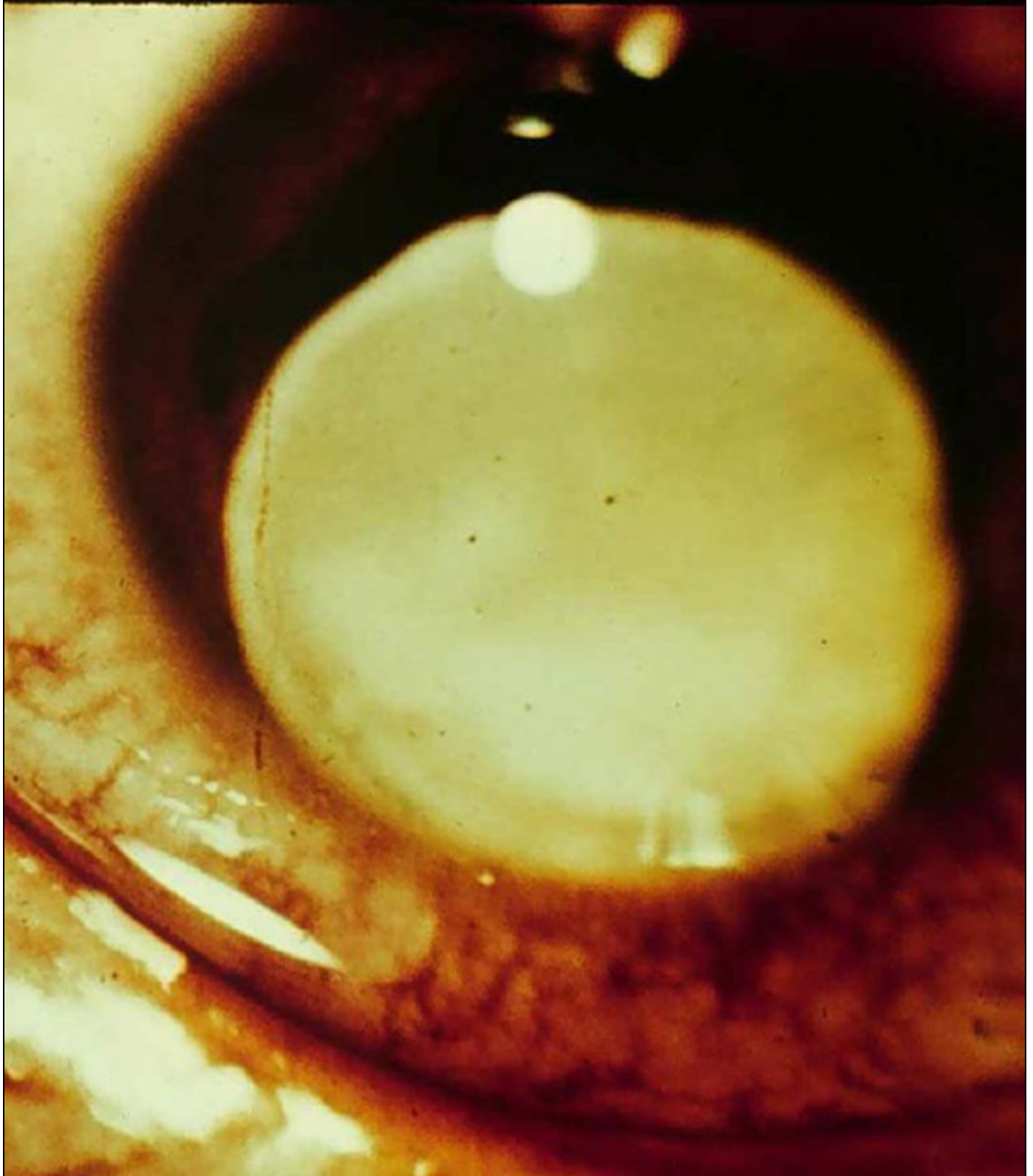


© Copyright [Oculisti OnLine](http://www.eyeatlas.com)

Eyeatlas

The online Atlas of Ophthalmology

Anterior chamber luxated lens



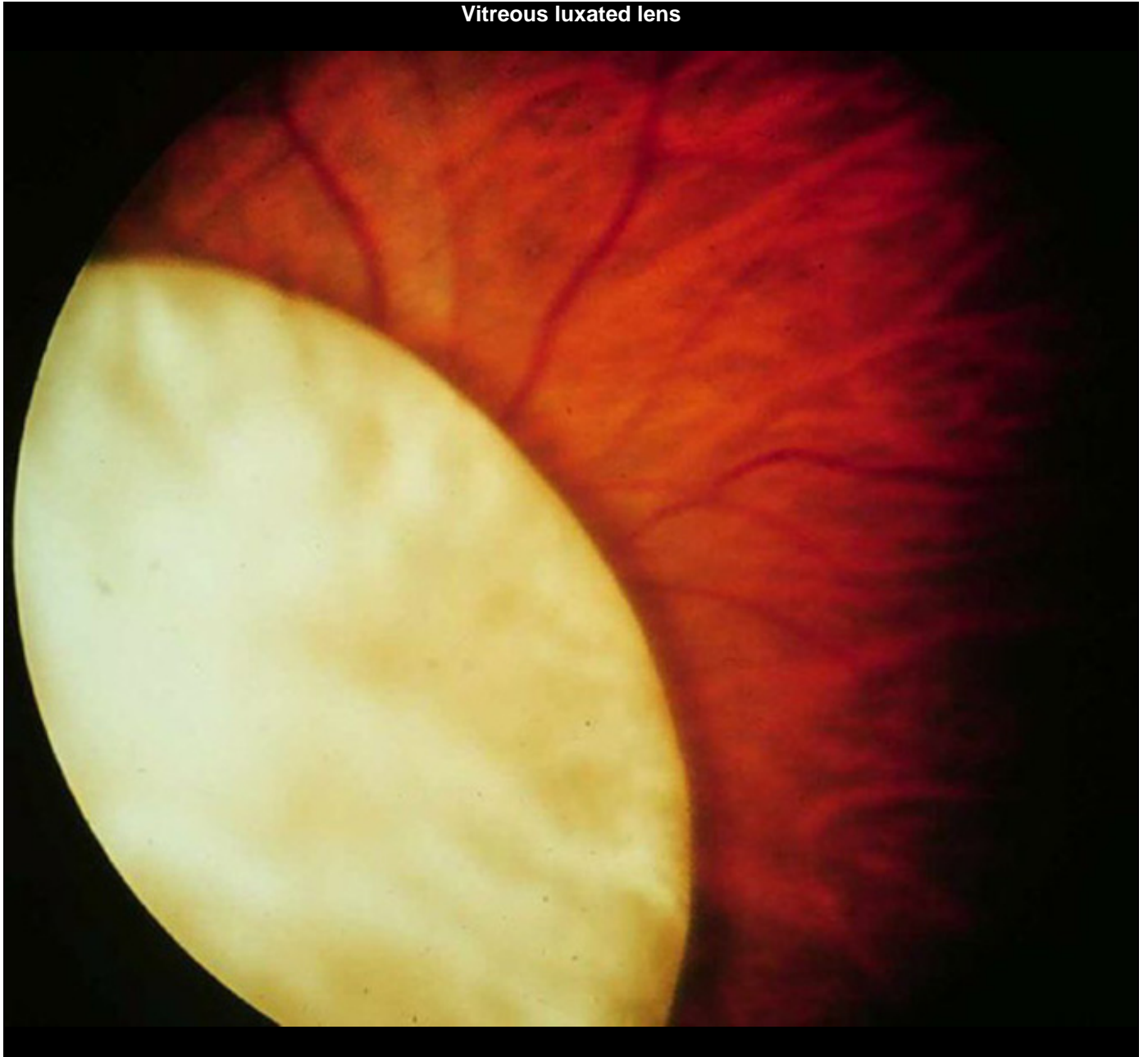

© Copyright [Oculisti OnLine](#)

Eyeatlas

The online Atlas of Ophthalmology

Vitreous luxated lens

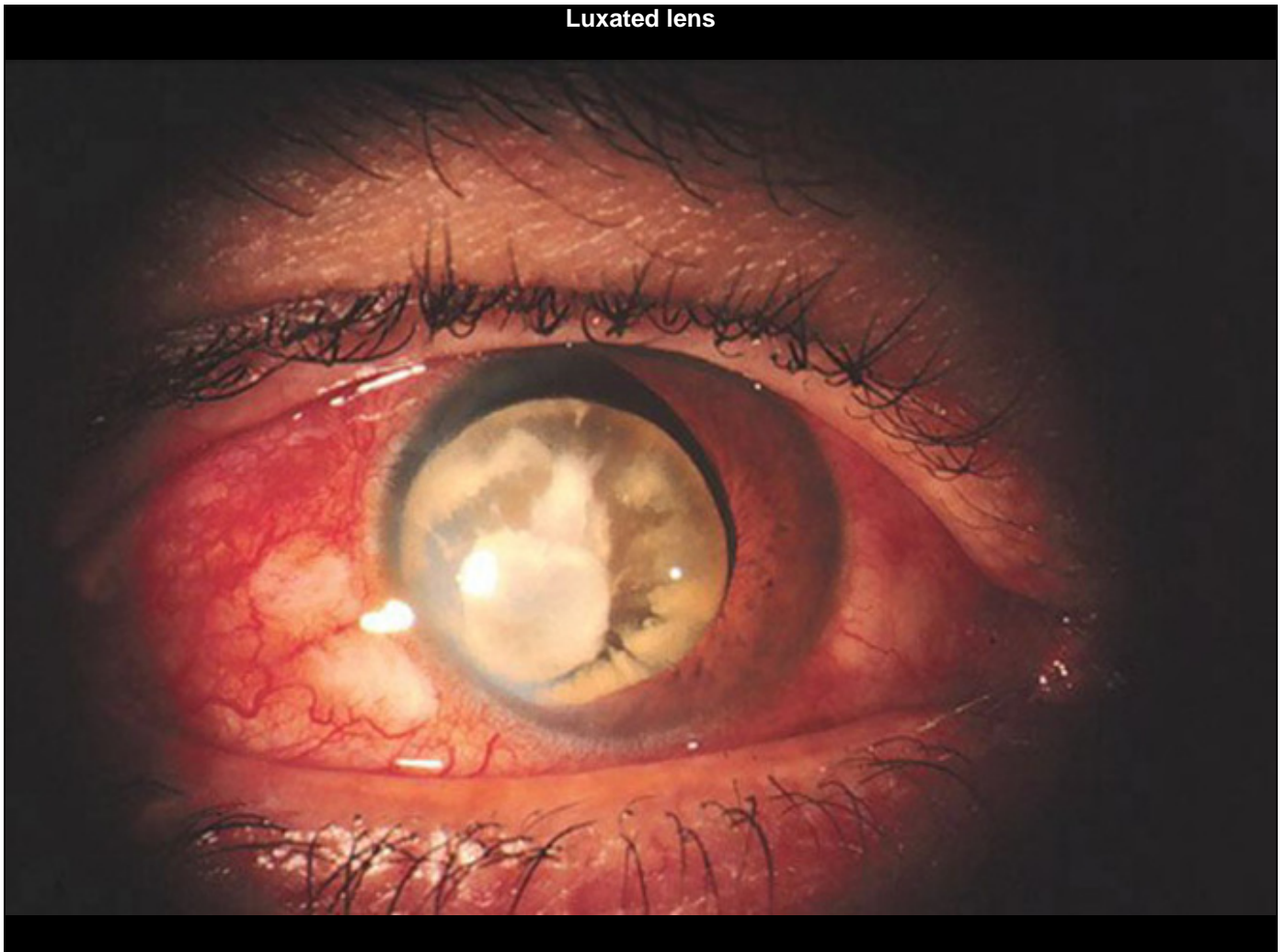

© Copyright [Oculisti OnLine](http://www.eyeatlas.com)

EyeAtlas

The online Atlas of Ophthalmology

Luxated lens

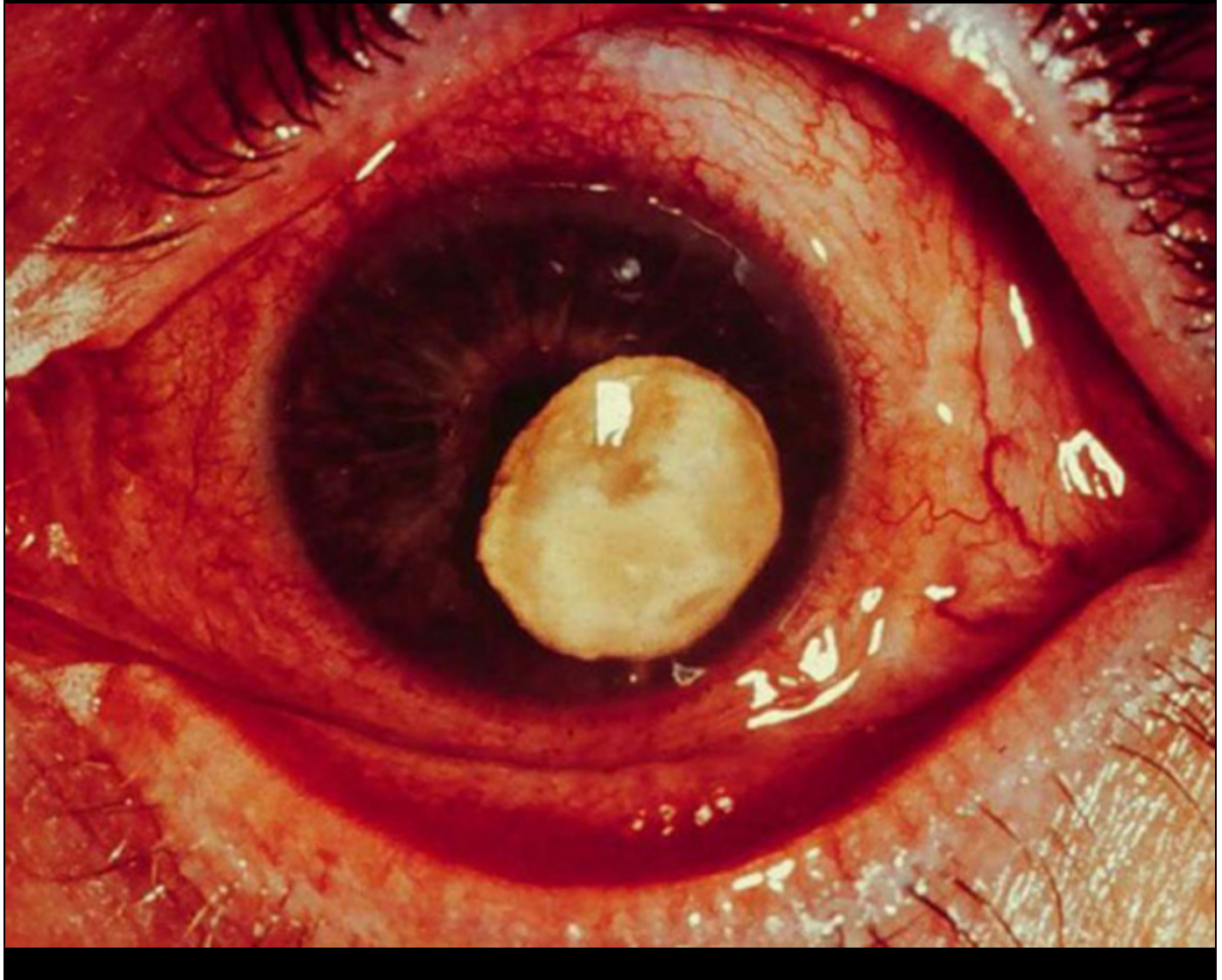


© Copyright [Oculisti OnLine](http://www.eyeatlas.com)

EyeAtlas

The online Atlas of Ophthalmology

Anterior chamber luxated lens

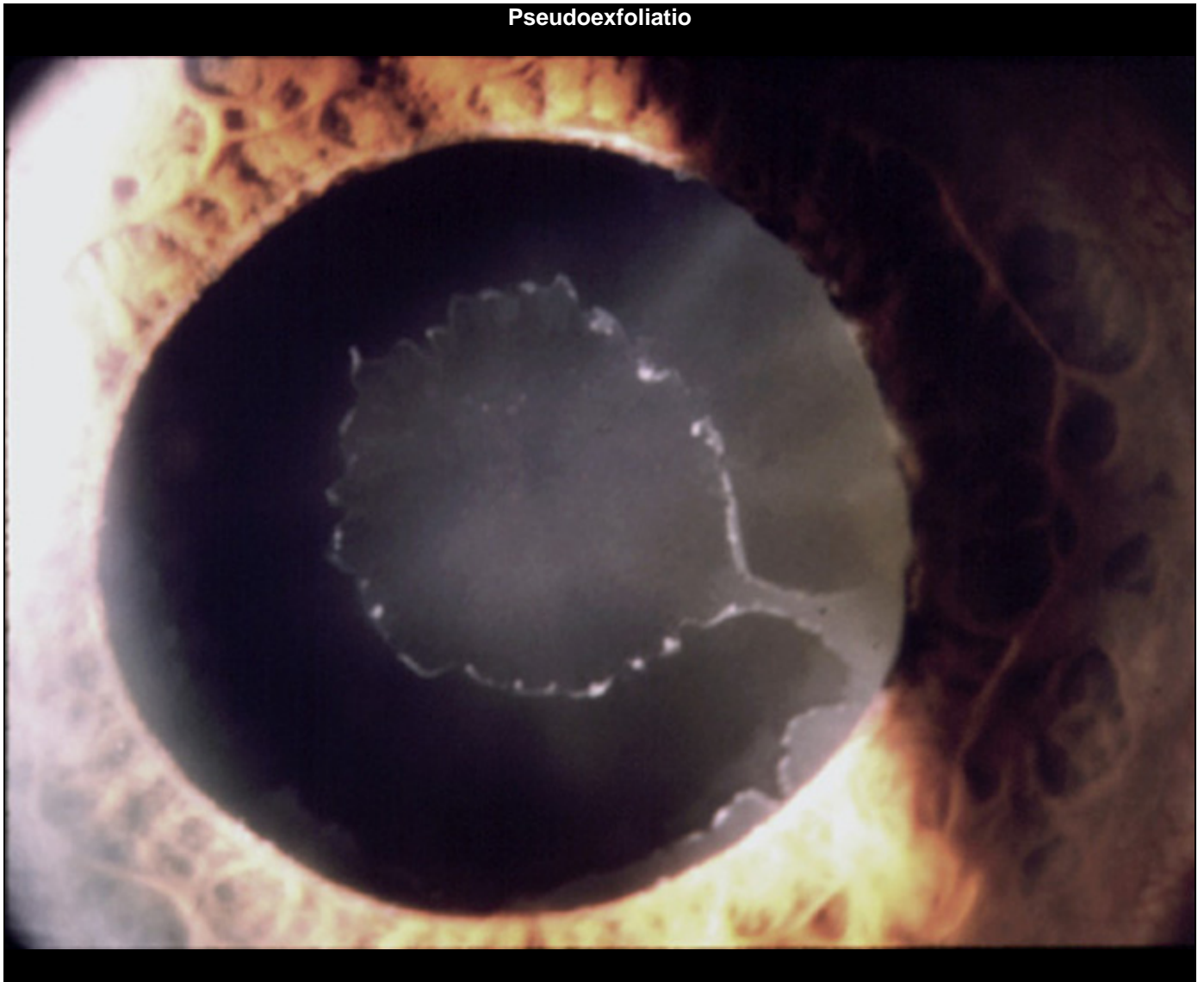


© Copyright [Oculisti OnLine](#)

EyeAtlas

The online Atlas of Ophthalmology

Pseudoexfoliation

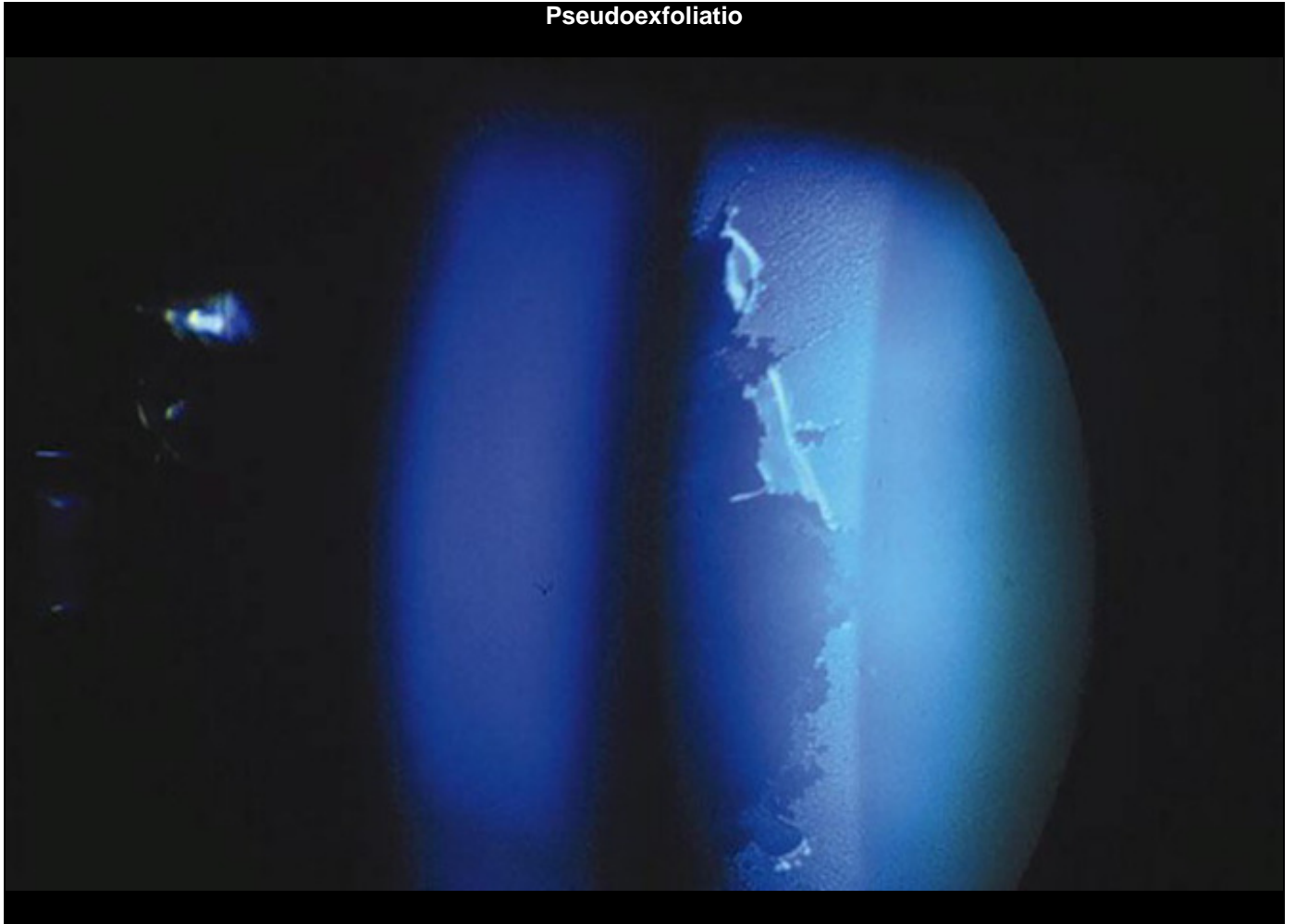

© Copyright [Oculisti OnLine](#)

Eyeatlas

The online Atlas of Ophthalmology

Pseudoexfoliation

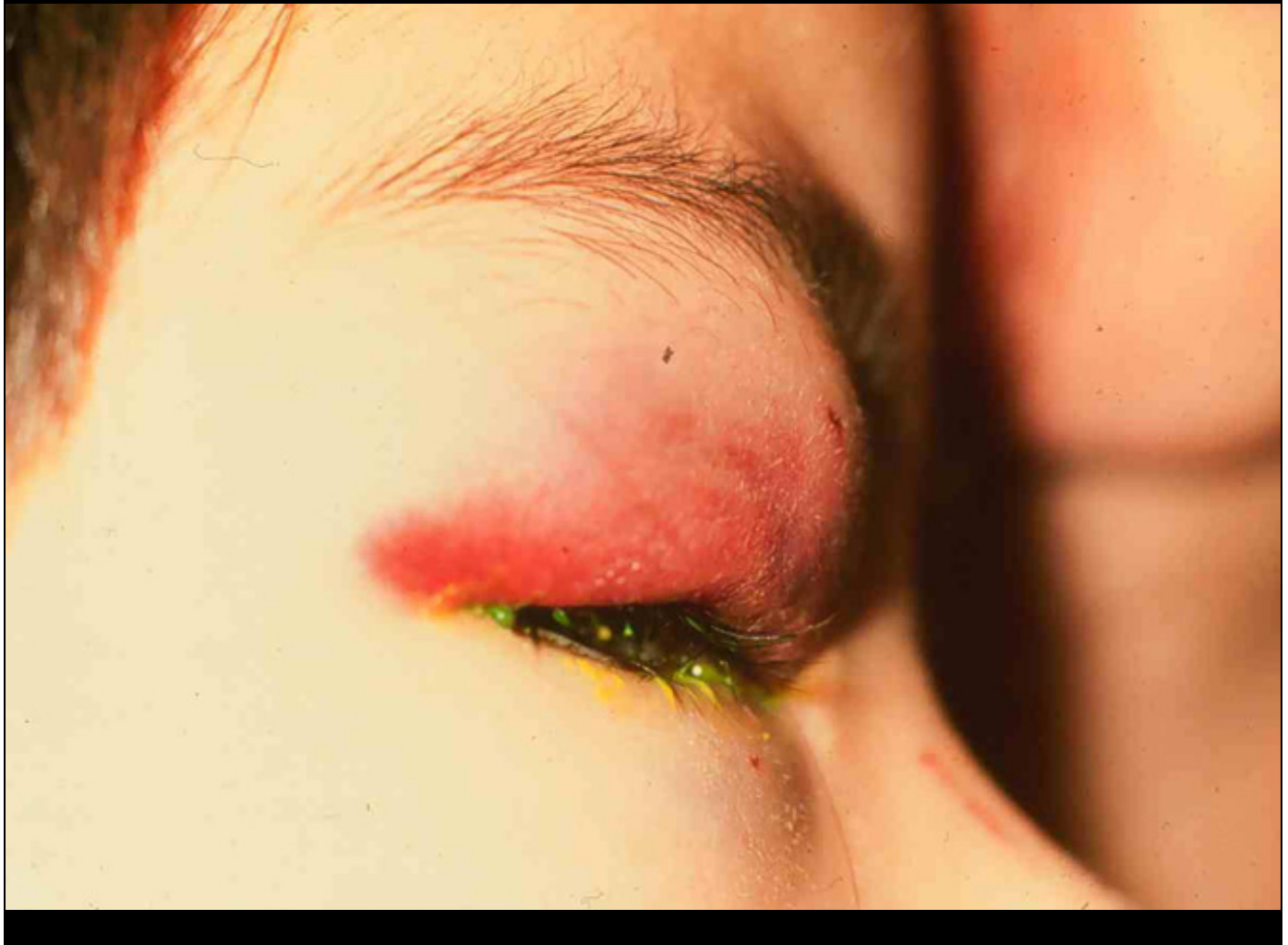

© Copyright [Oculisti OnLine](http://www.eyeatlas.com)

Eyeatlas

The online Atlas of Ophthalmology

Atropine allergy

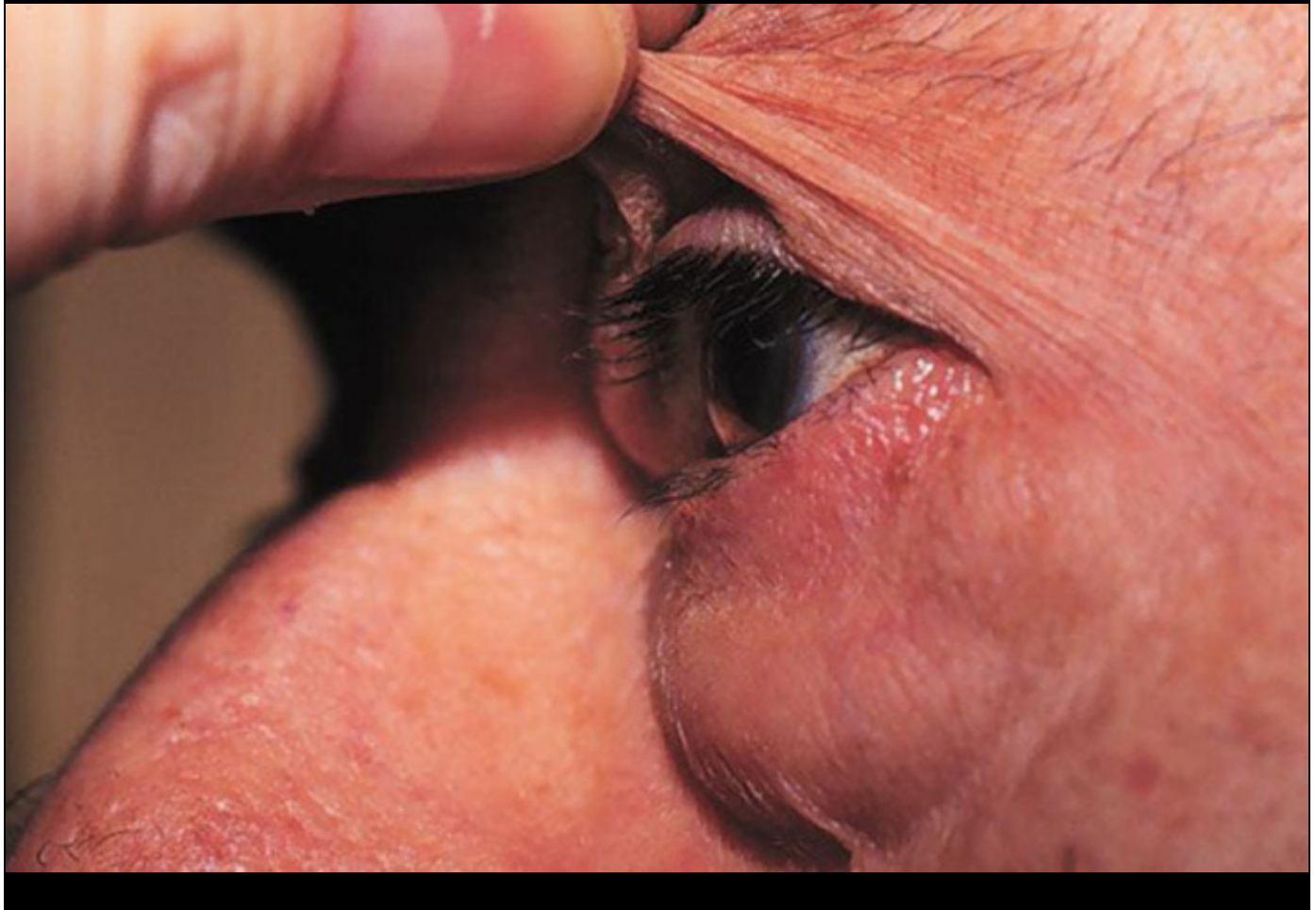

© Copyright [Oculisti OnLine](http://www.eyeatlas.com)

EyeAtlas

The online Atlas of Ophthalmology

Calasis

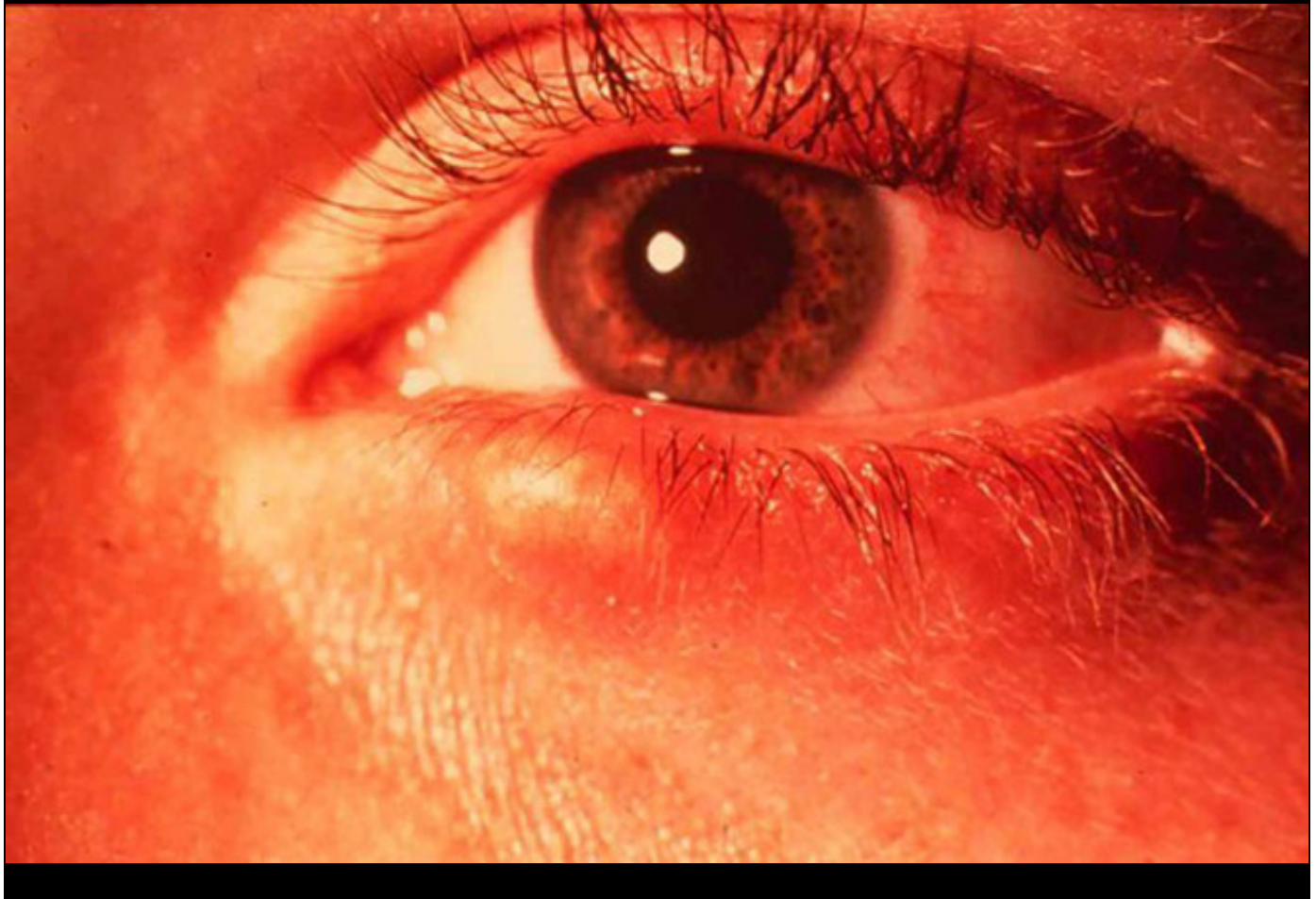

© Copyright [Oculisti OnLine](#)

Eyeatlas

The online Atlas of Ophthalmology

Chalazium

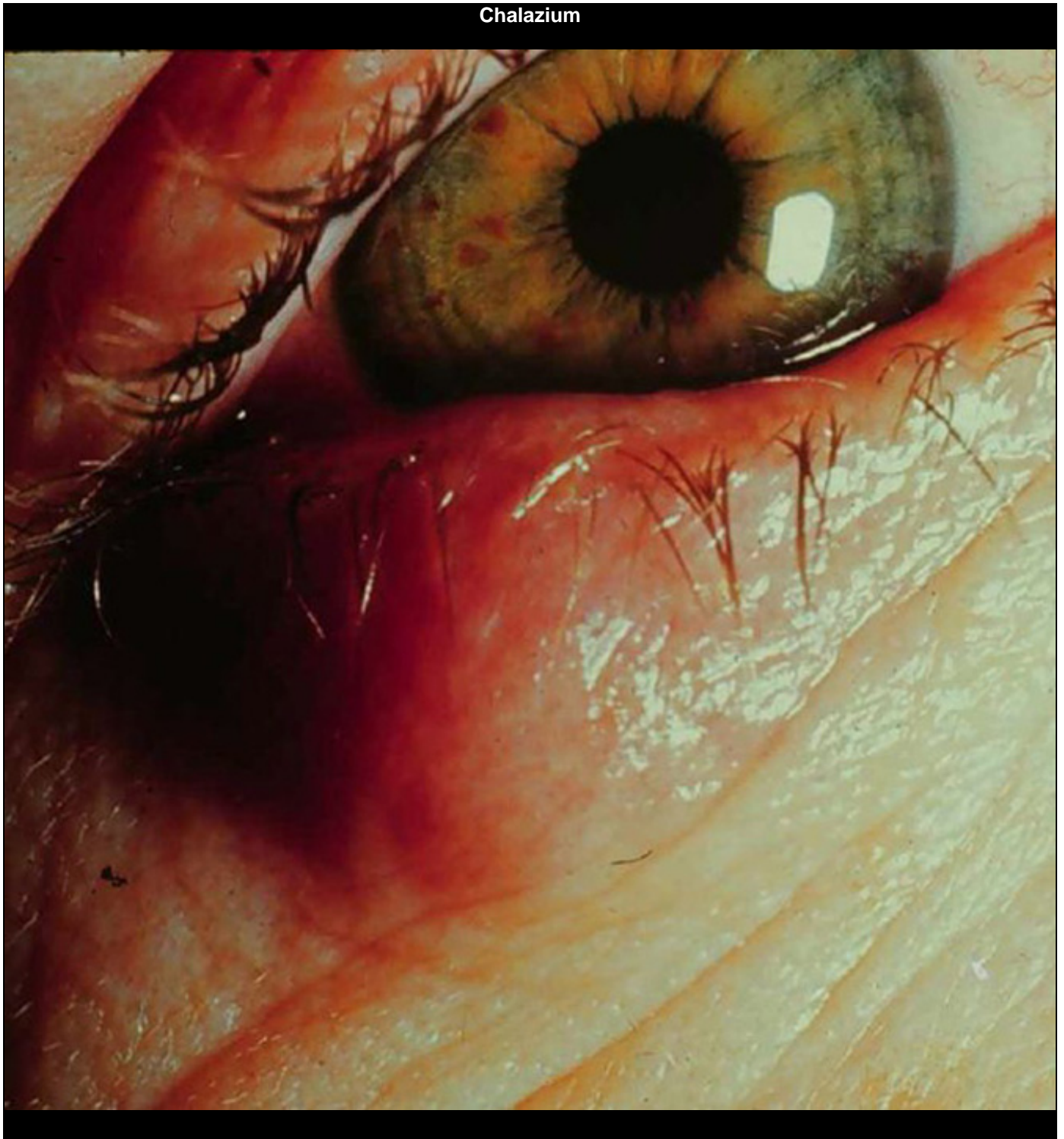

© Copyright [Oculisti OnLine](#)

EyeAtlas

The online Atlas of Ophthalmology

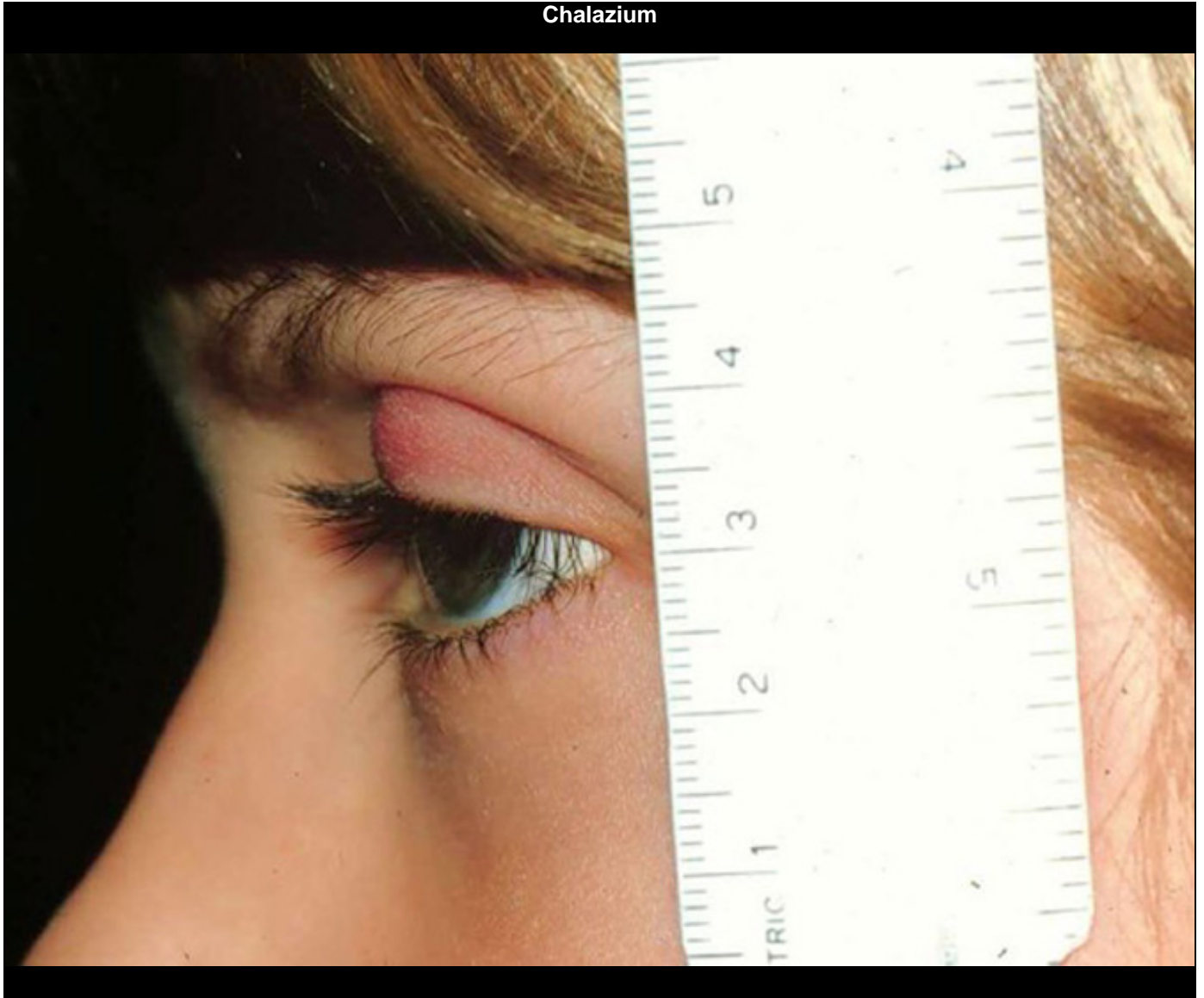Chalazium



EyeAtlas

The online Atlas of Ophthalmology

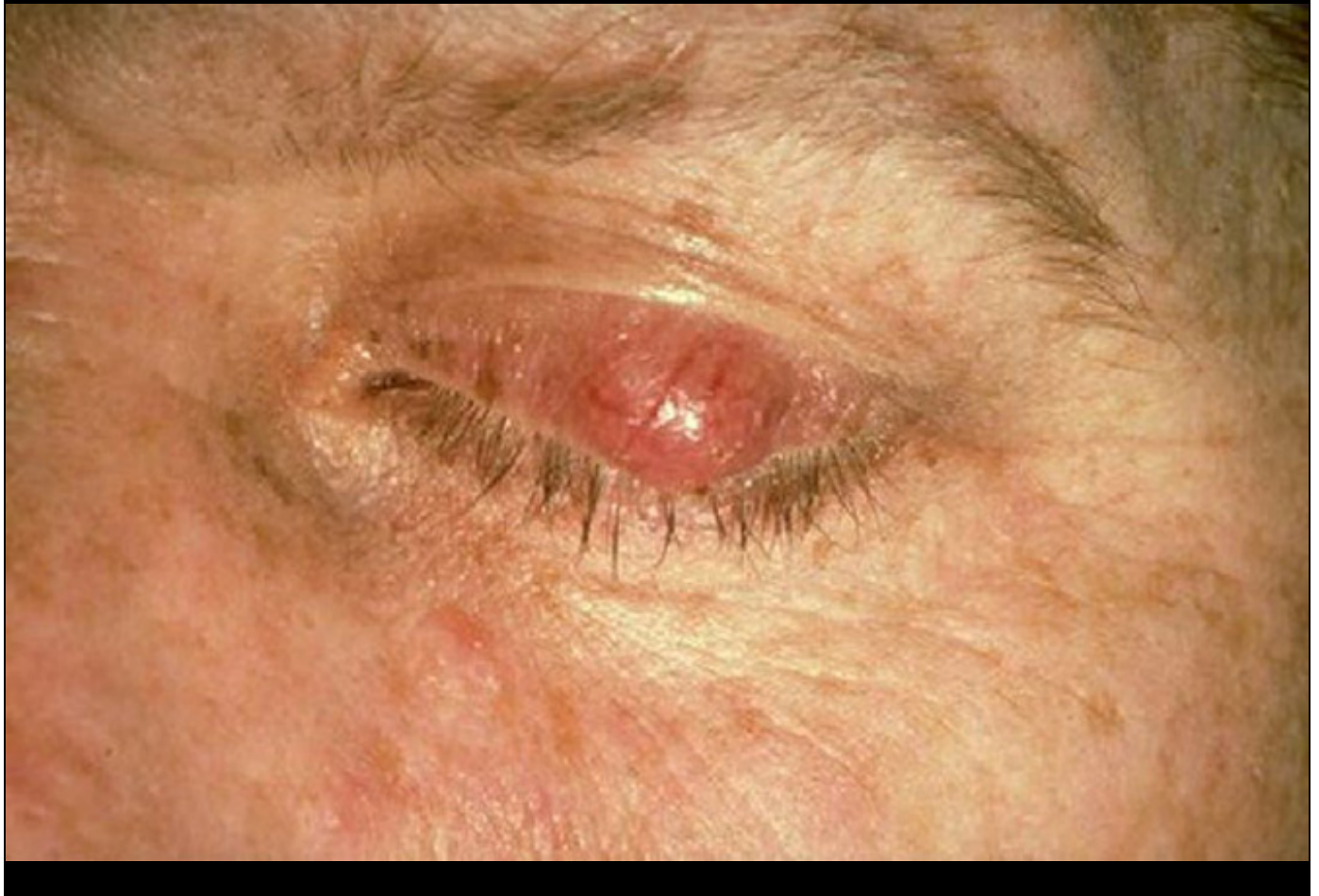Chalazium



EyeAtlas

The online Atlas of Ophthalmology

Chalazium

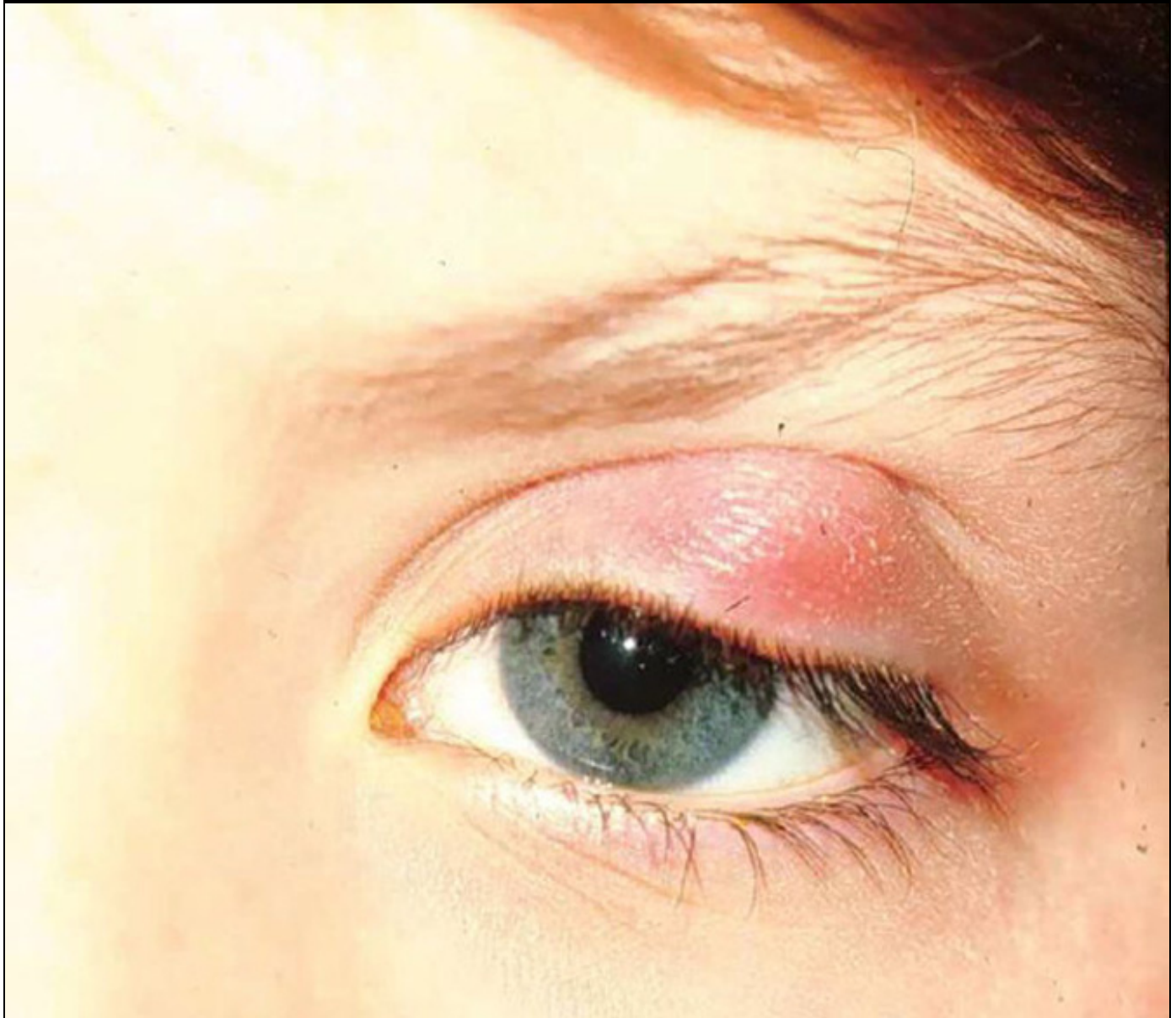

© Copyright [Oculisti OnLine](#)

EyeAtlas

The online Atlas of Ophthalmology

Chalazium

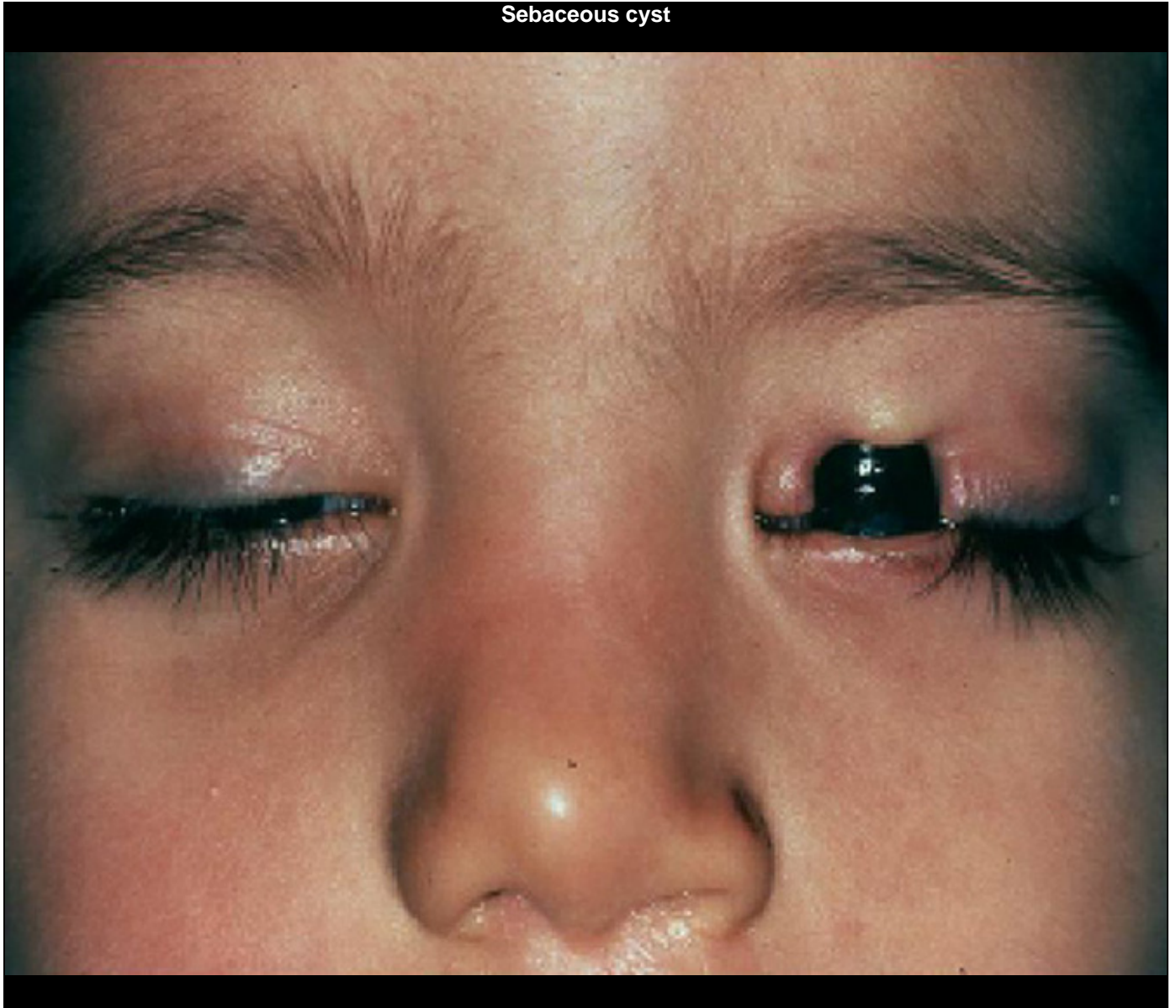

© Copyright [Oculisti OnLine](http://www.eyeatlas.com)

EyeAtlas

The online Atlas of Ophthalmology

Sebaceous cyst

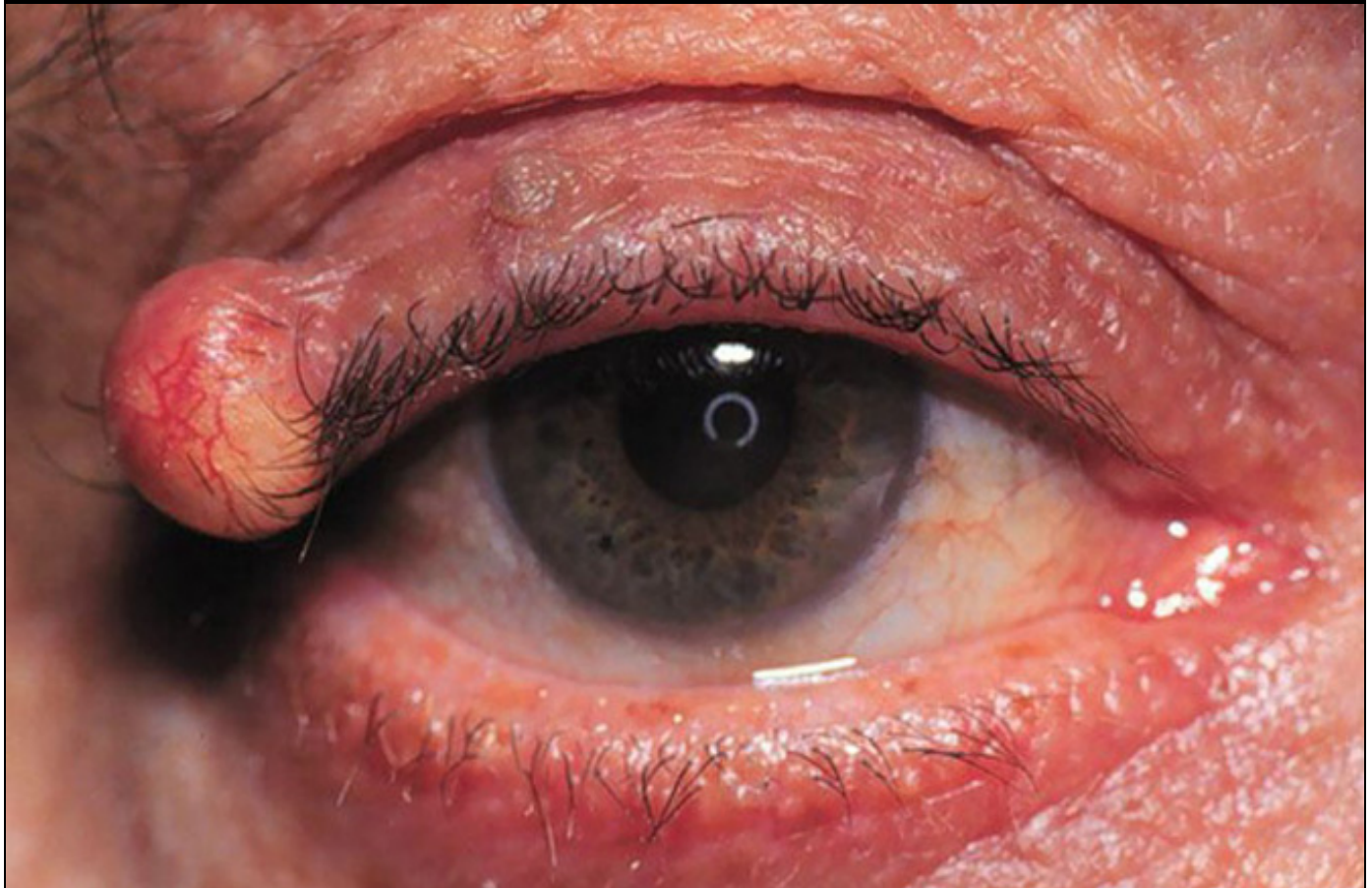

© Copyright [Oculisti OnLine](#)

EyeAtlas

The online Atlas of Ophthalmology

Sebaceous cyst

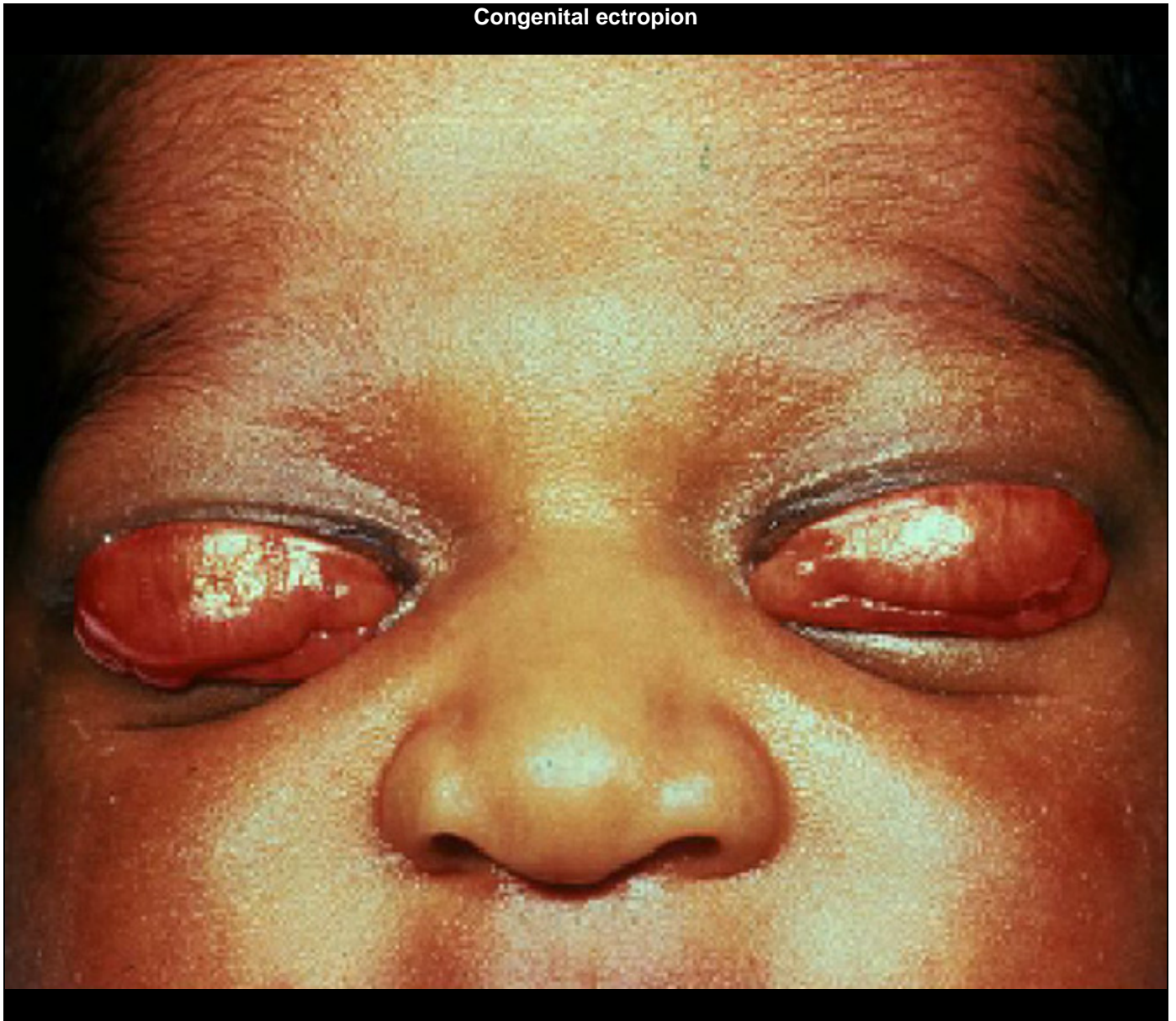


© Copyright [Oculisti OnLine](http://www.eyeatlas.com)

EyeAtlas

The online Atlas of Ophthalmology

Congenital ectropion

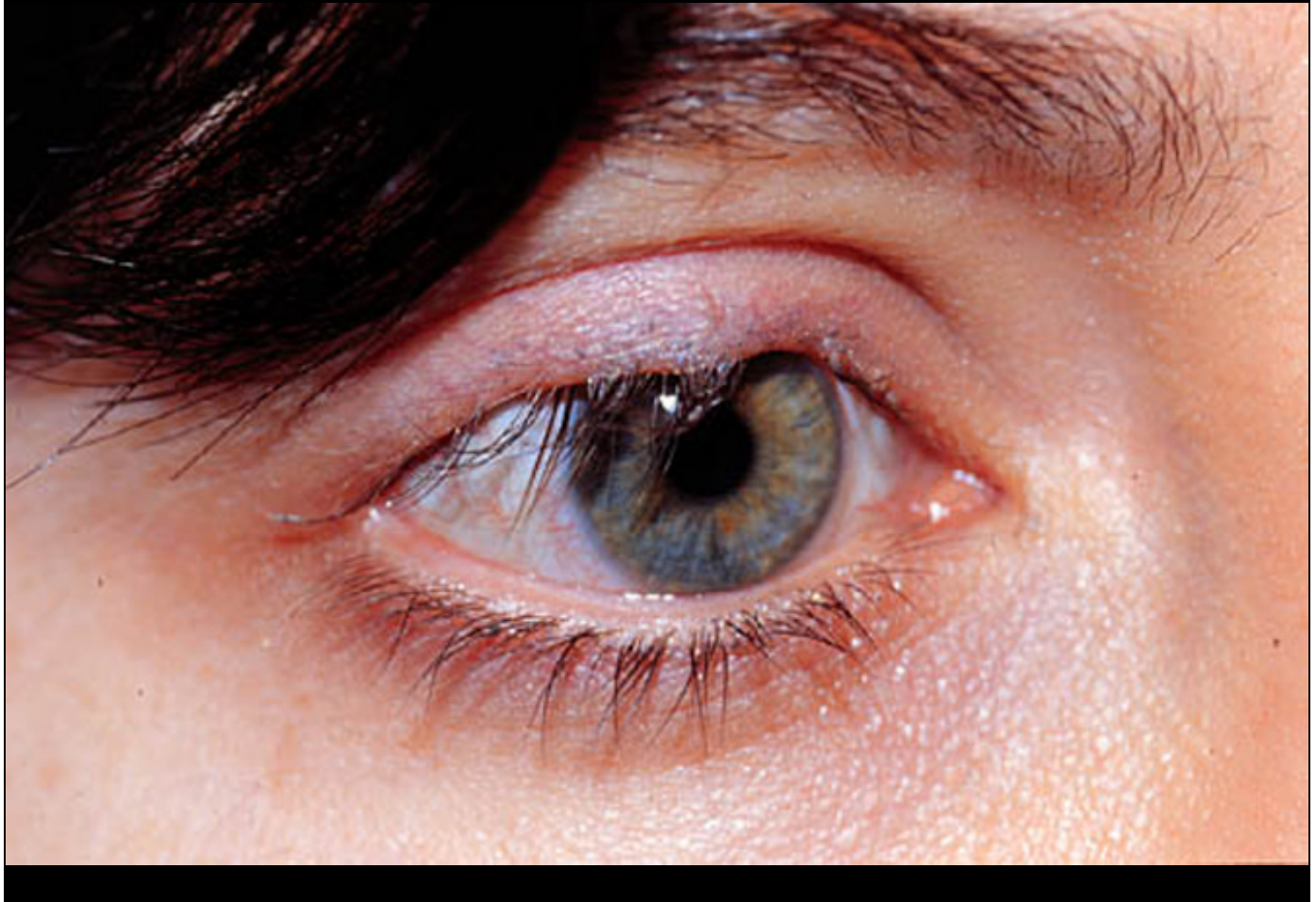


© Copyright [Oculisti OnLine](http://www.eyeatlas.com)

EyeAtlas

The online Atlas of Ophthalmology

Cicatrizial entropion

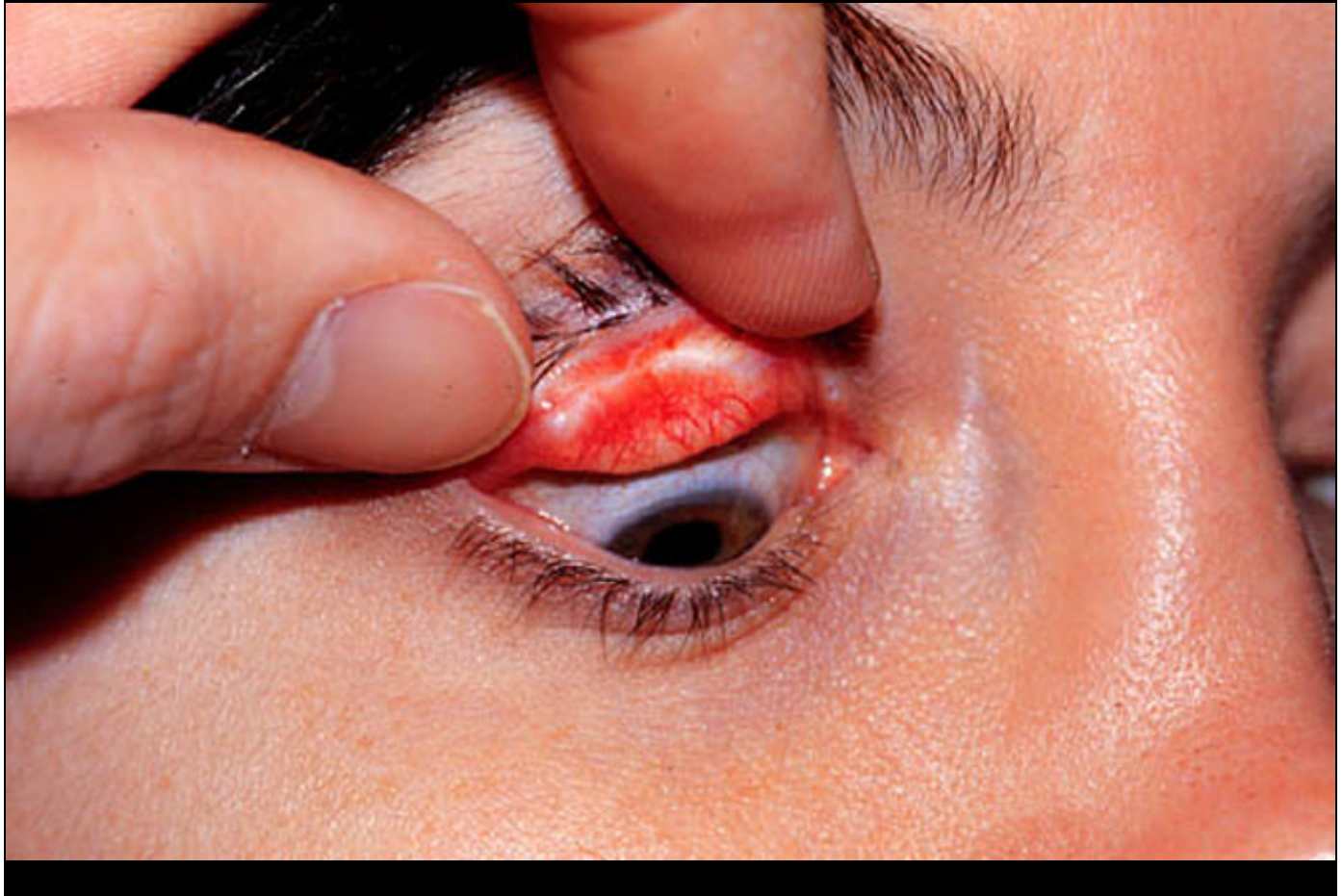

© Copyright [Oculisti OnLine](#)

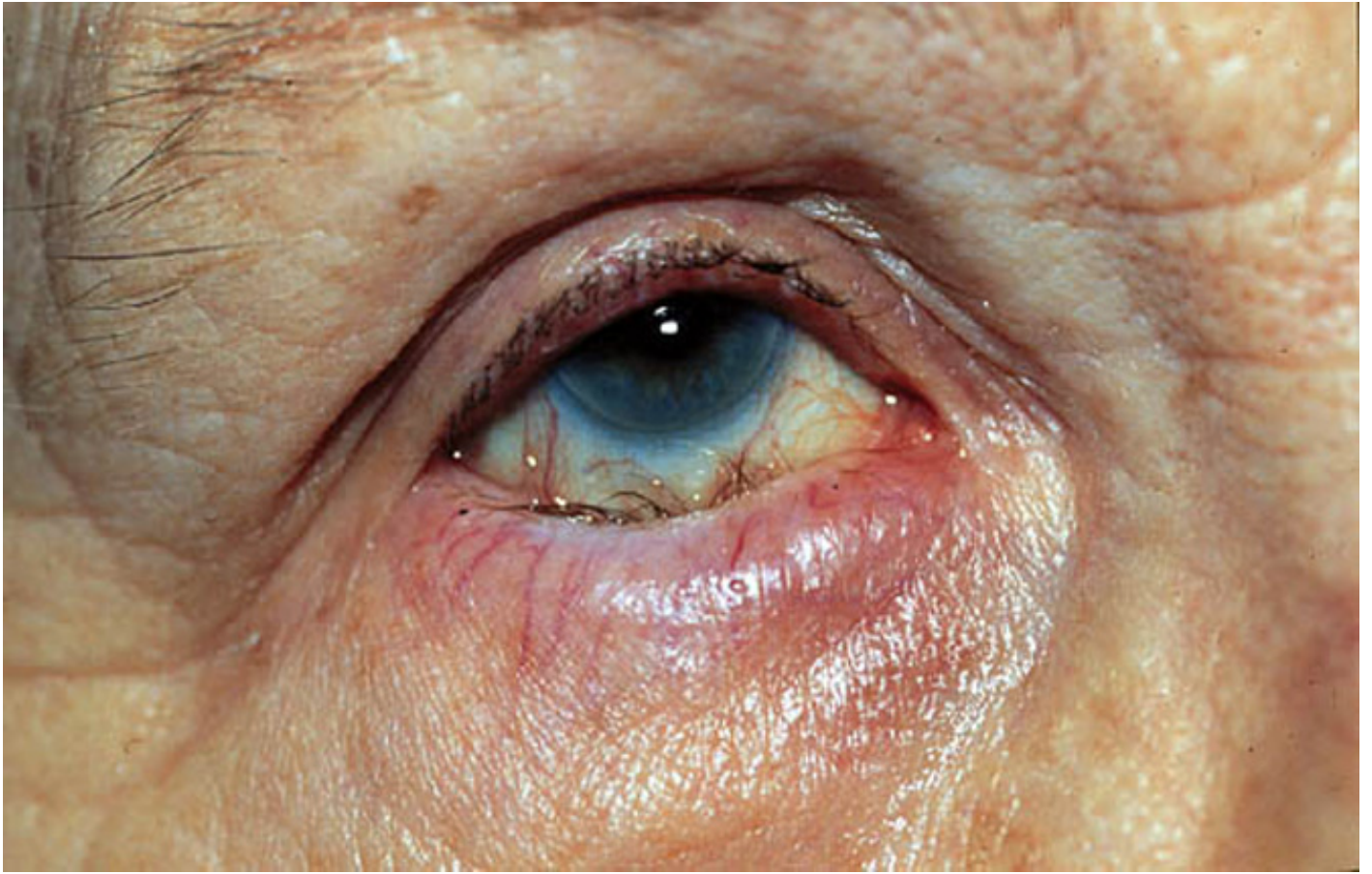
EyeAtlas

The online Atlas of Ophthalmology

Cicatrizial entropion



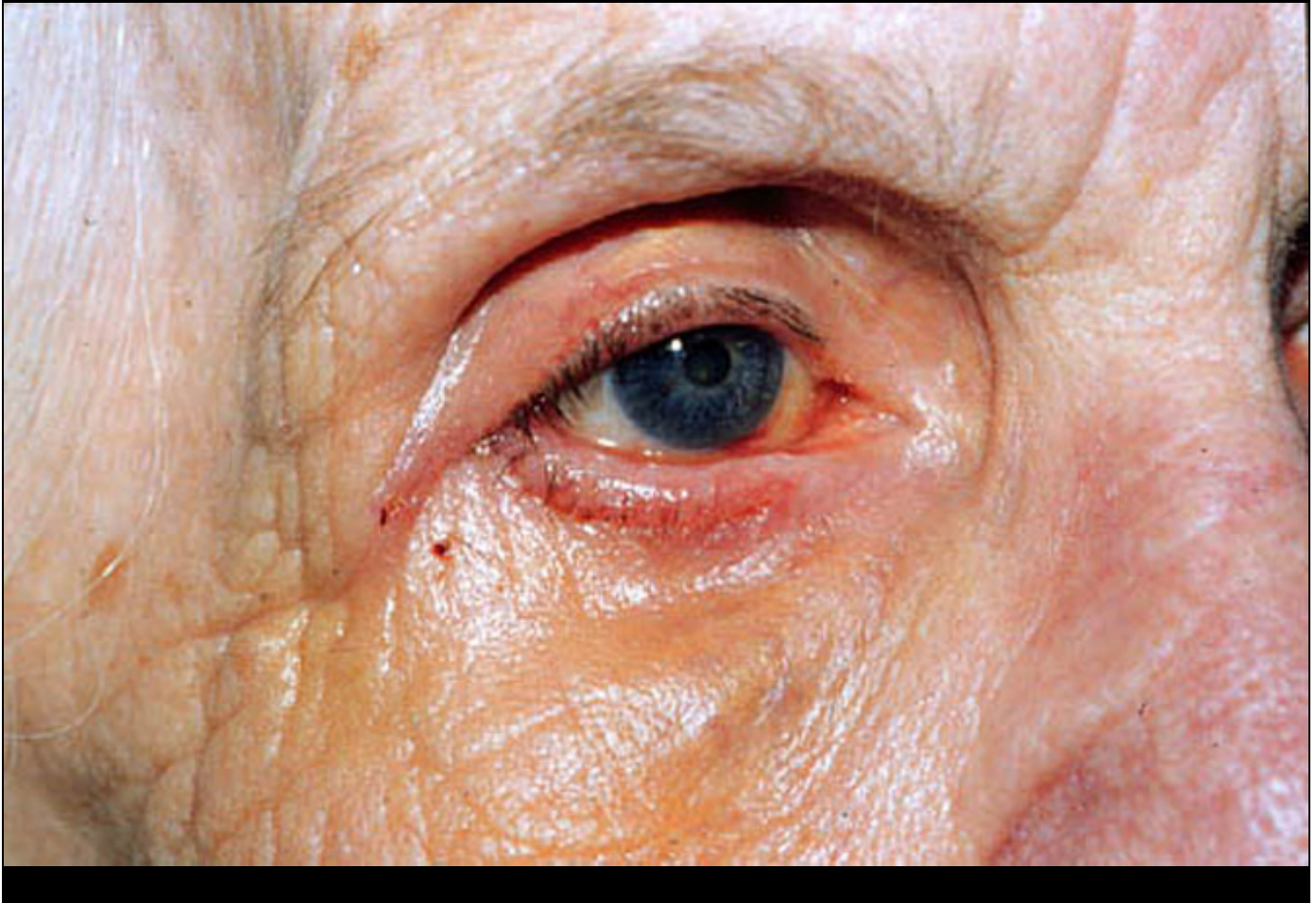© Copyright [Oculisti OnLine](#)



EyeAtlas

The online Atlas of Ophthalmology

Involutorial entropion

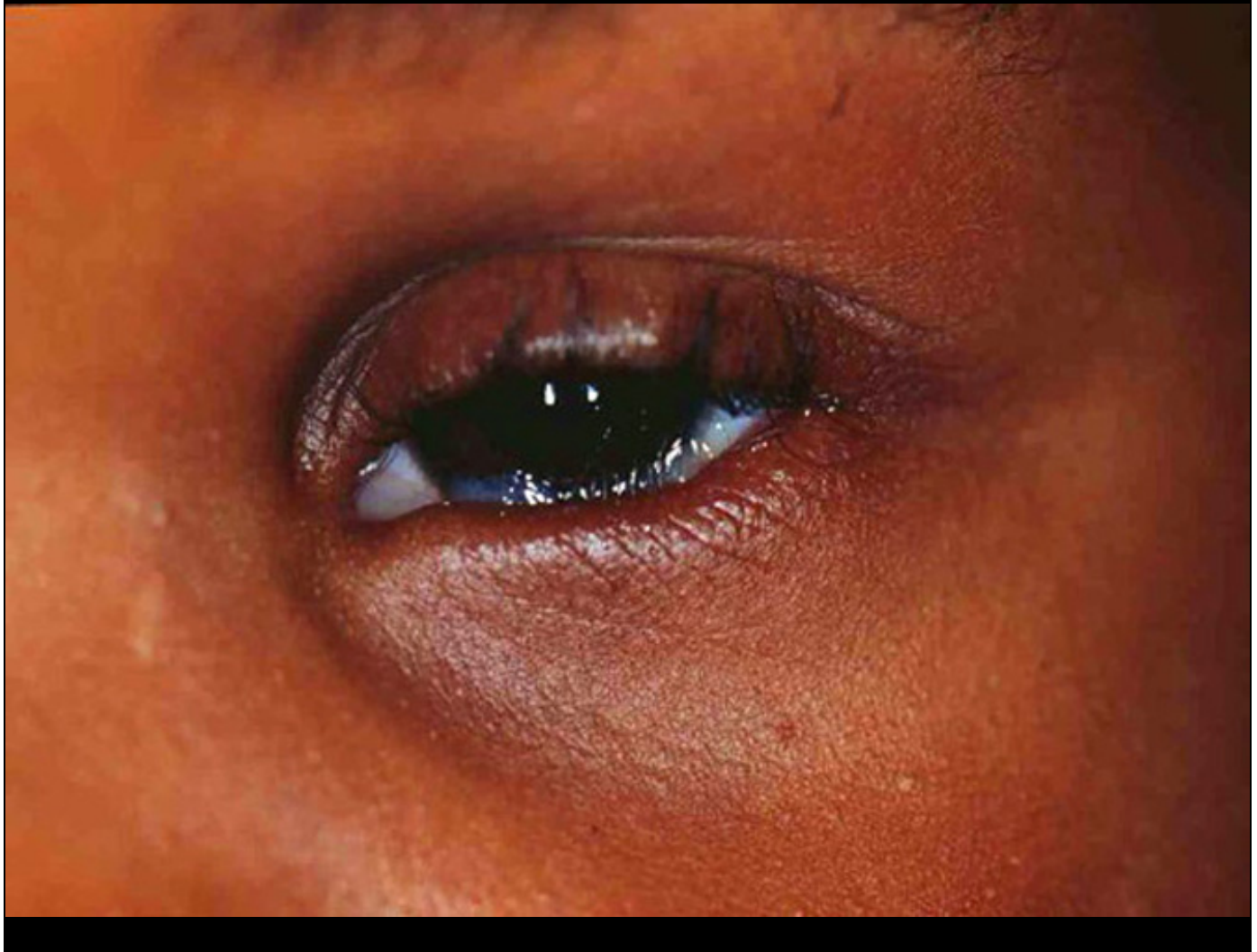


© Copyright [Oculisti OnLine](#)

EyeAtlas

The online Atlas of Ophthalmology

Spastic entropion

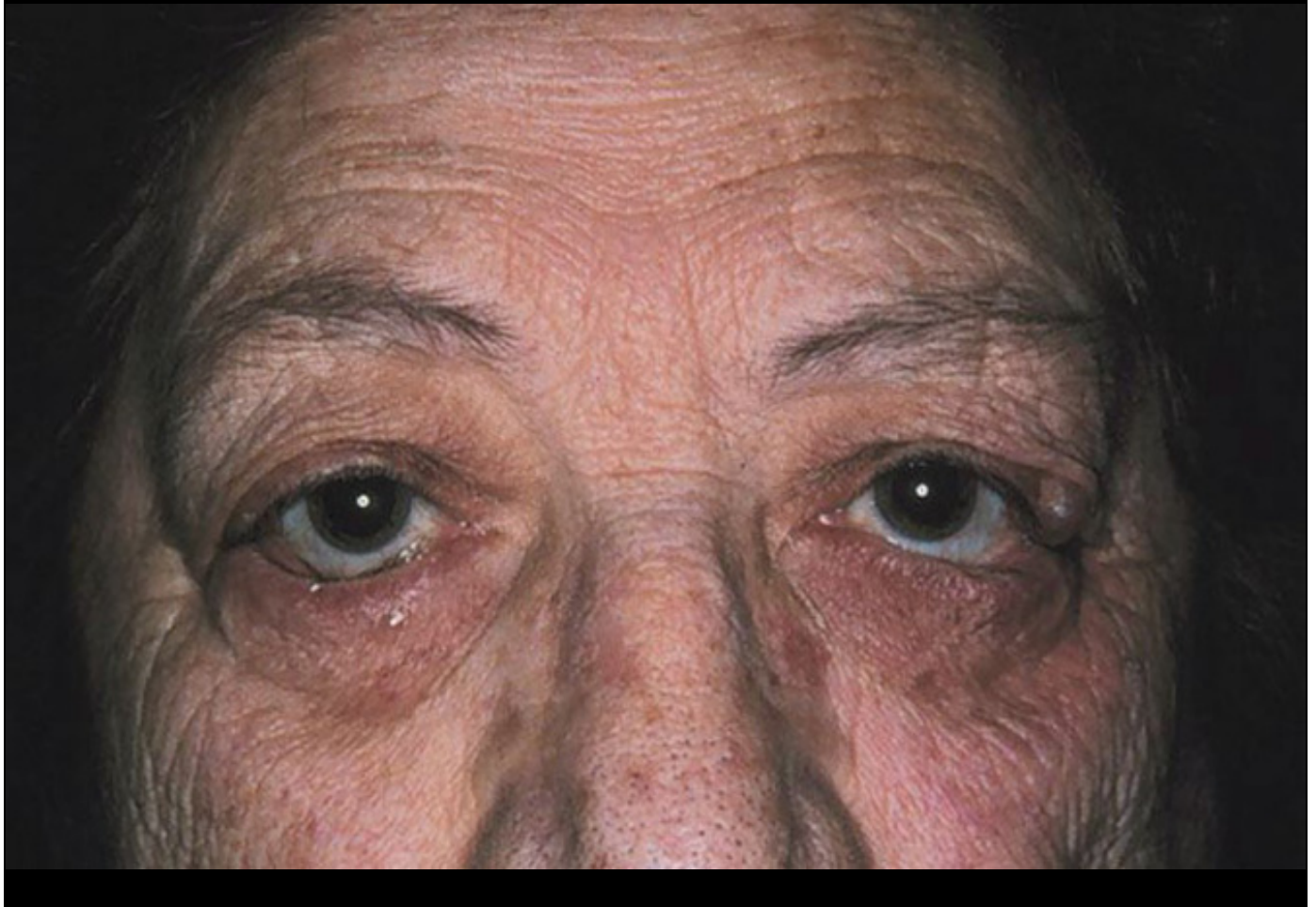

© Copyright [Oculisti OnLine](#)

EyeAtlas

The online Atlas of Ophthalmology

Spastic entropion




© Copyright [Oculisti OnLine](#)

EyeAtlas

The online Atlas of Ophthalmology

Epiblepharon

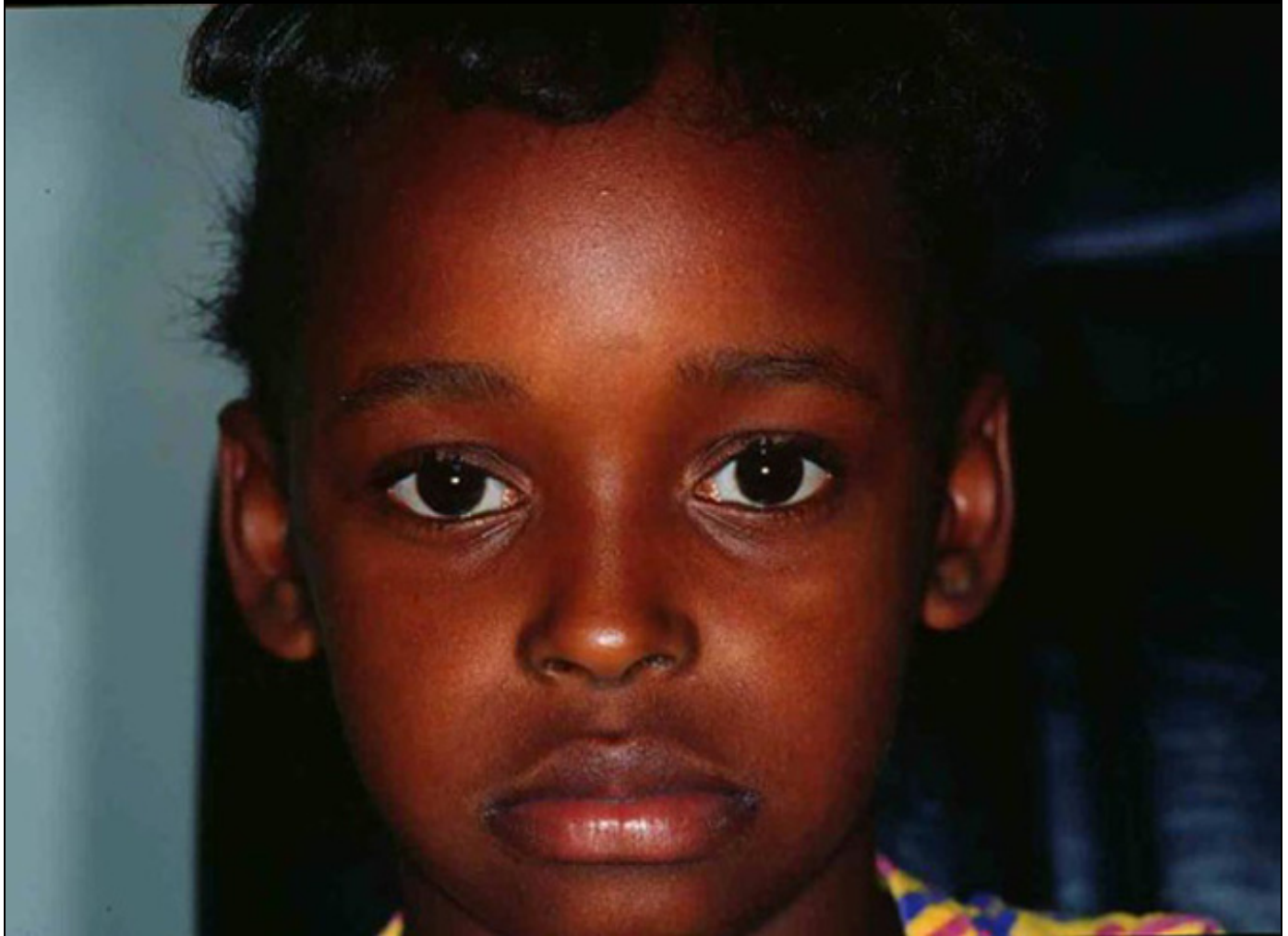

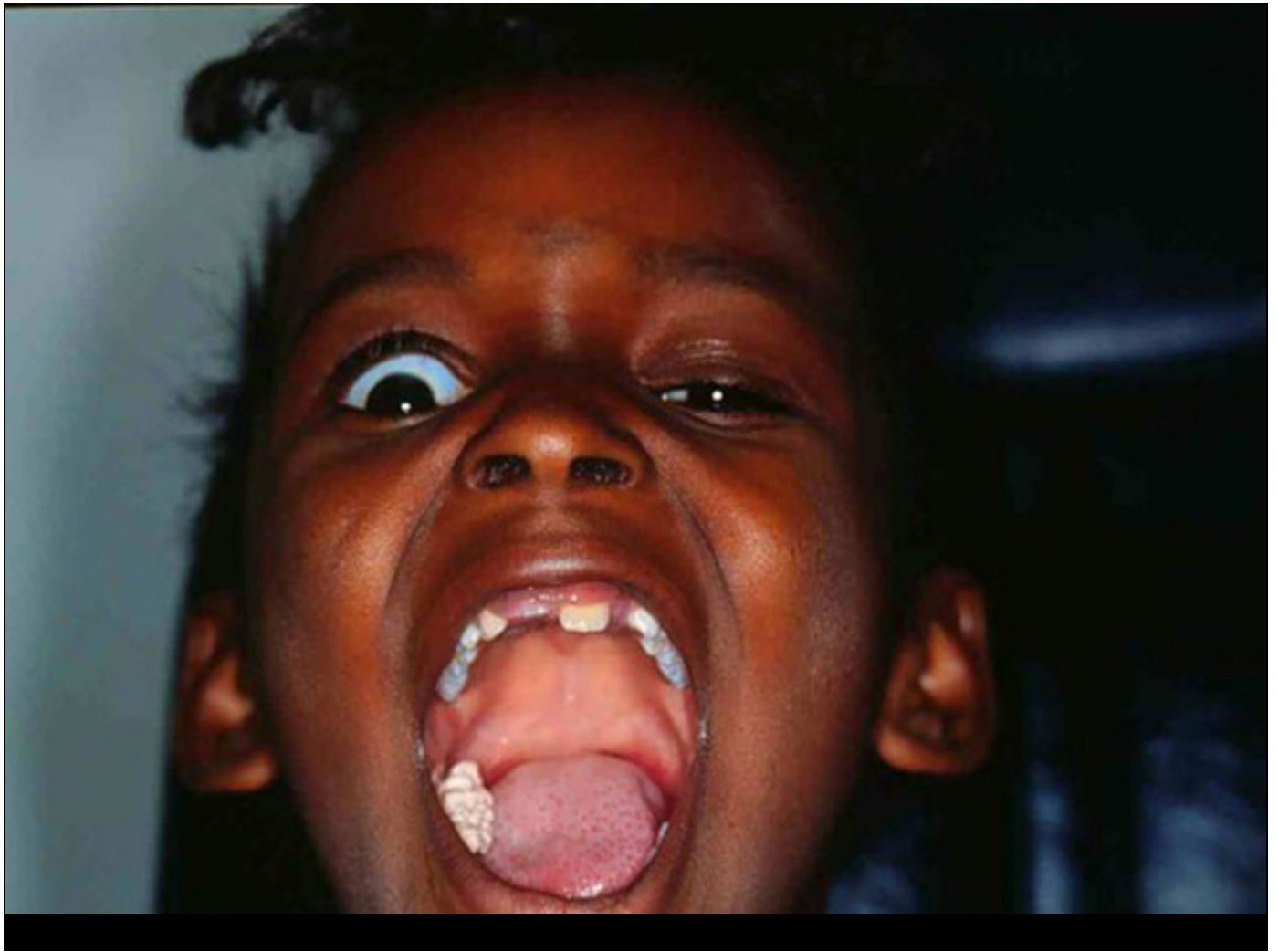
© Copyright [Oculisti OnLine](#)

Eyeatlas

The online Atlas of Ophthalmology

Gunn's sign



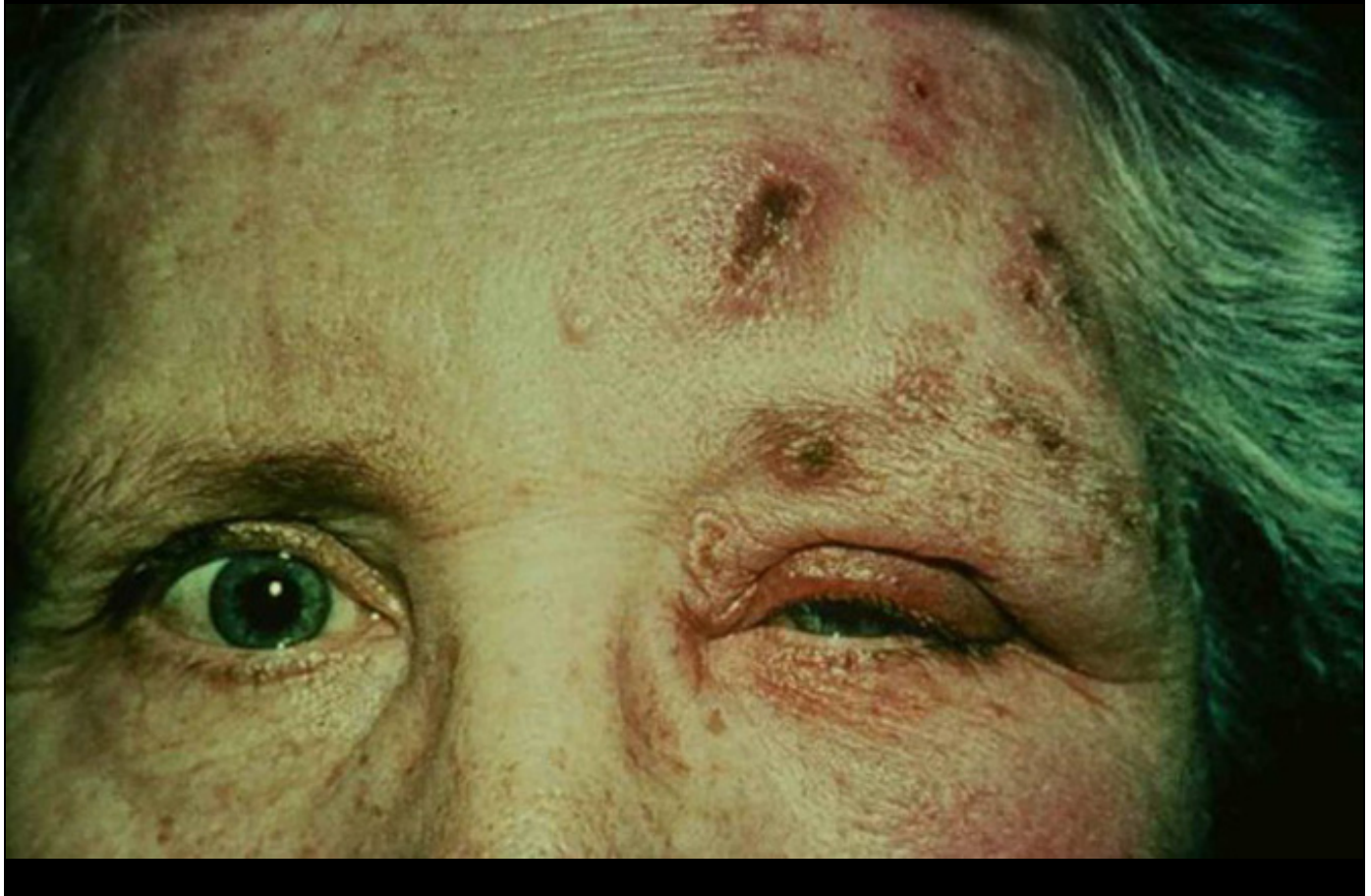

© Copyright [Oculisti OnLine](#)

EyeAtlas

The online Atlas of Ophthalmology

Herpes zoster

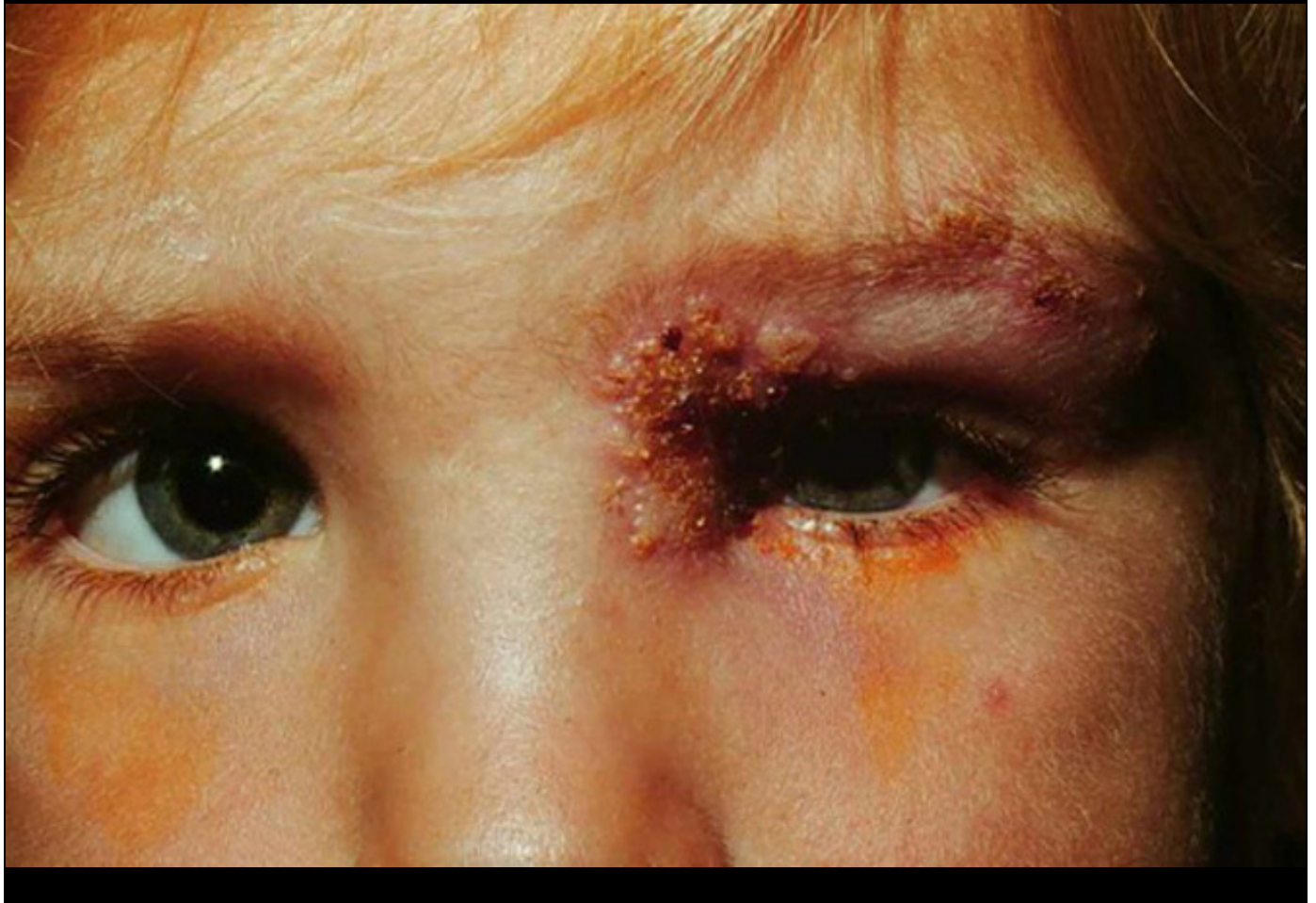

© Copyright [Oculisti OnLine](#)

EyeAtlas

The online Atlas of Ophthalmology

Herpes zoster

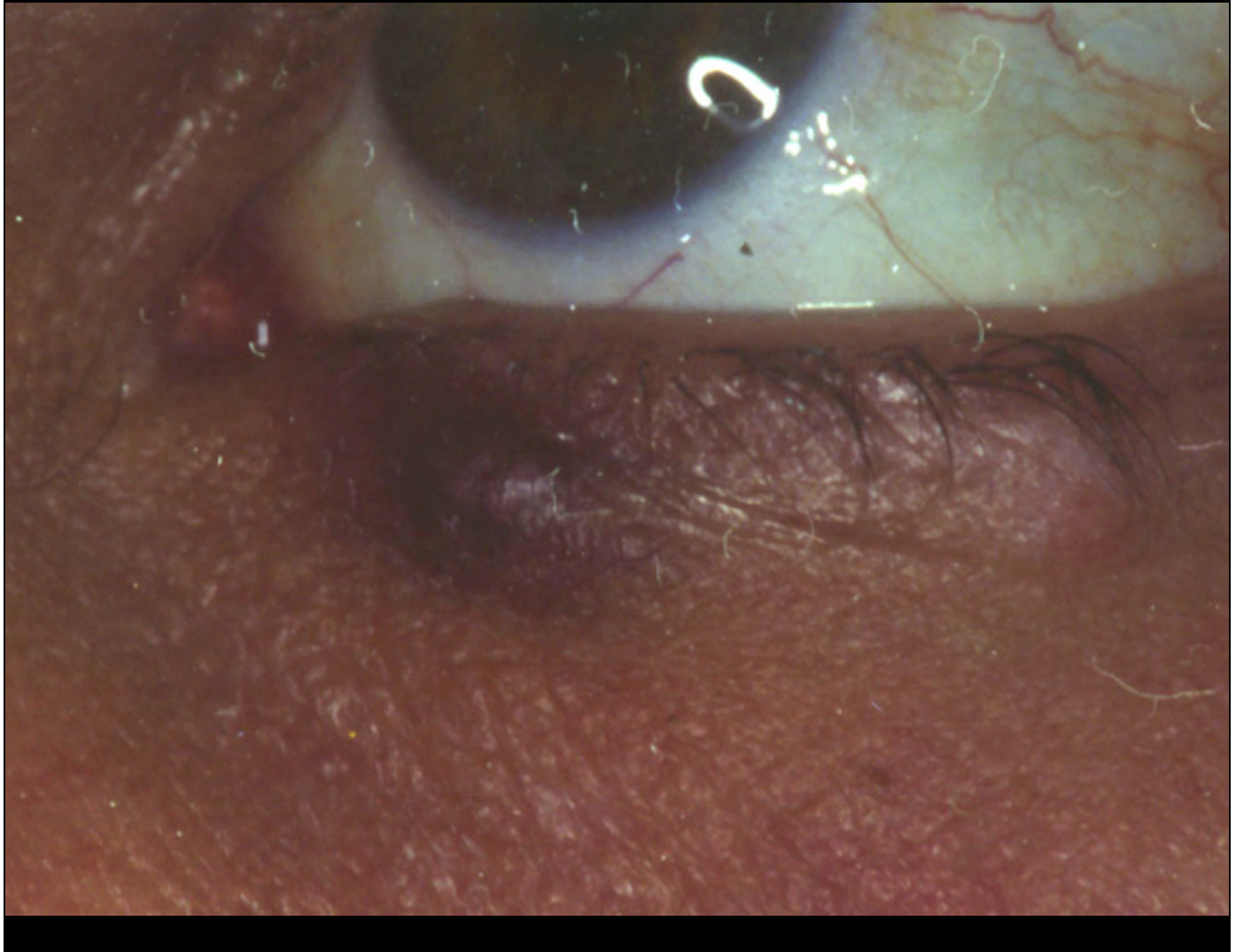


© Copyright [Oculisti OnLine](#)

EyeAtlas

The online Atlas of Ophthalmology

Kaposi's sarcoma

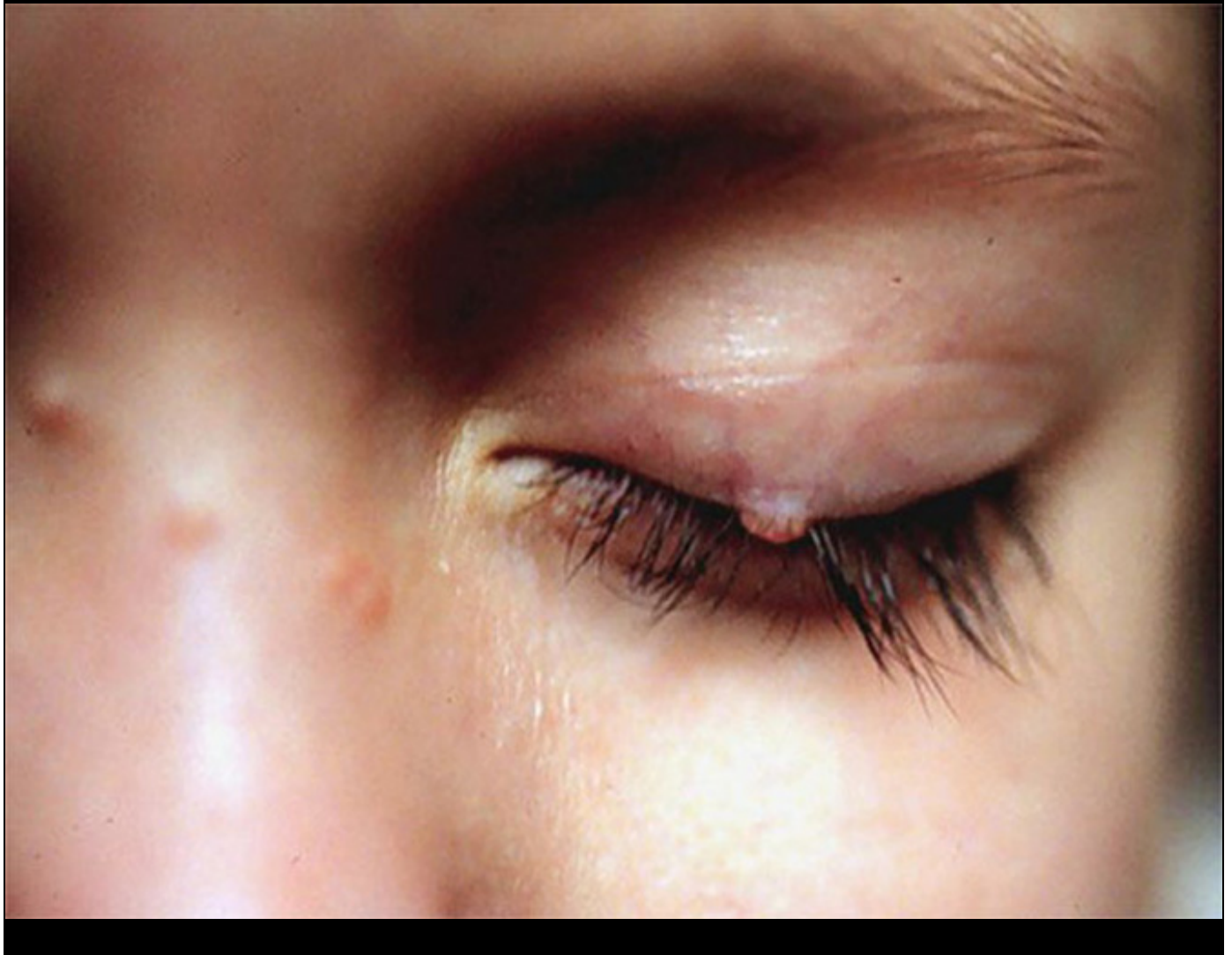

© Copyright [Oculisti OnLine](http://www.eyeatlas.com)

EyeAtlas

The online Atlas of Ophthalmology

Actinic keratosis

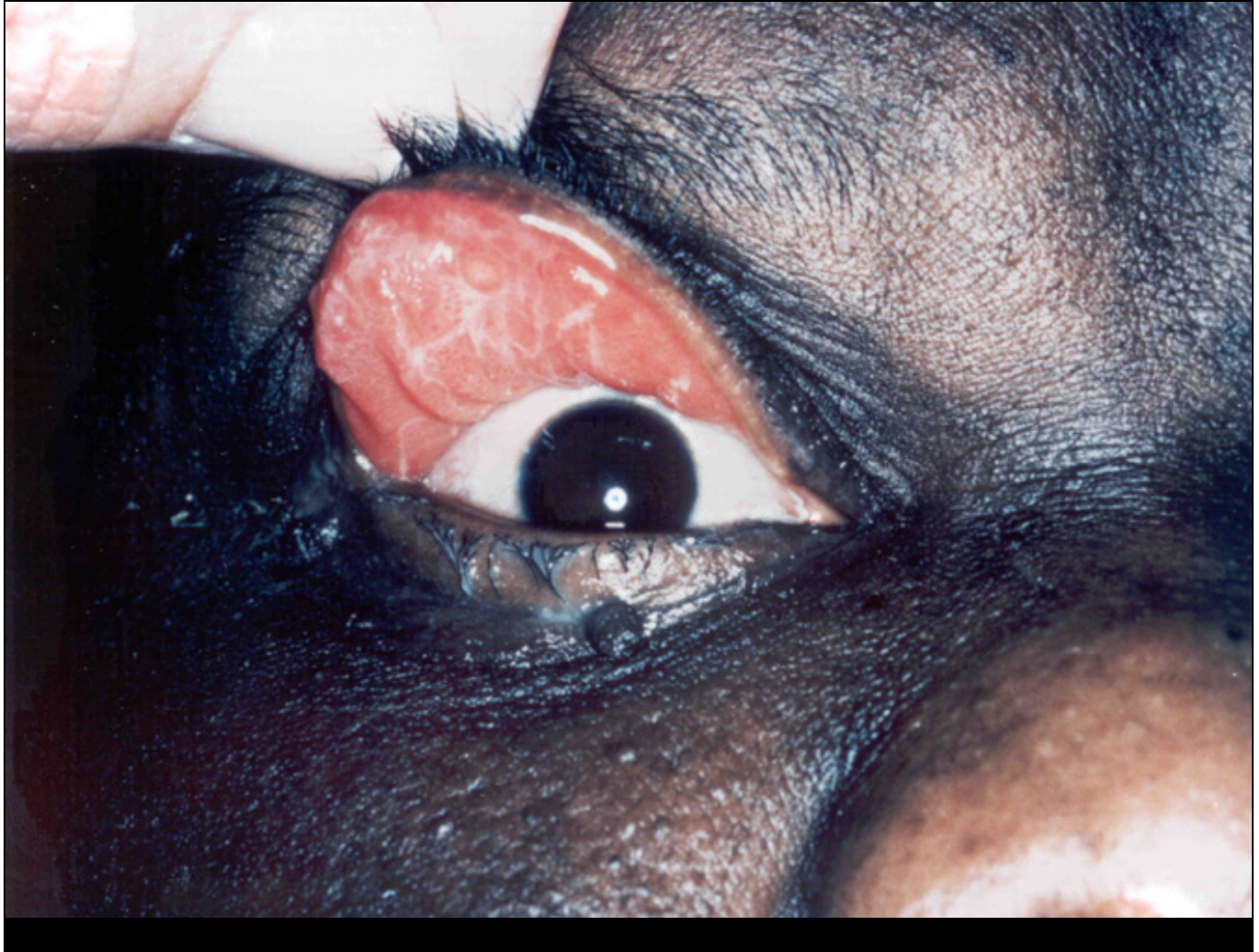

© Copyright [Oculisti OnLine](#)

EyeAtlas

The online Atlas of Ophthalmology

Lid laxity

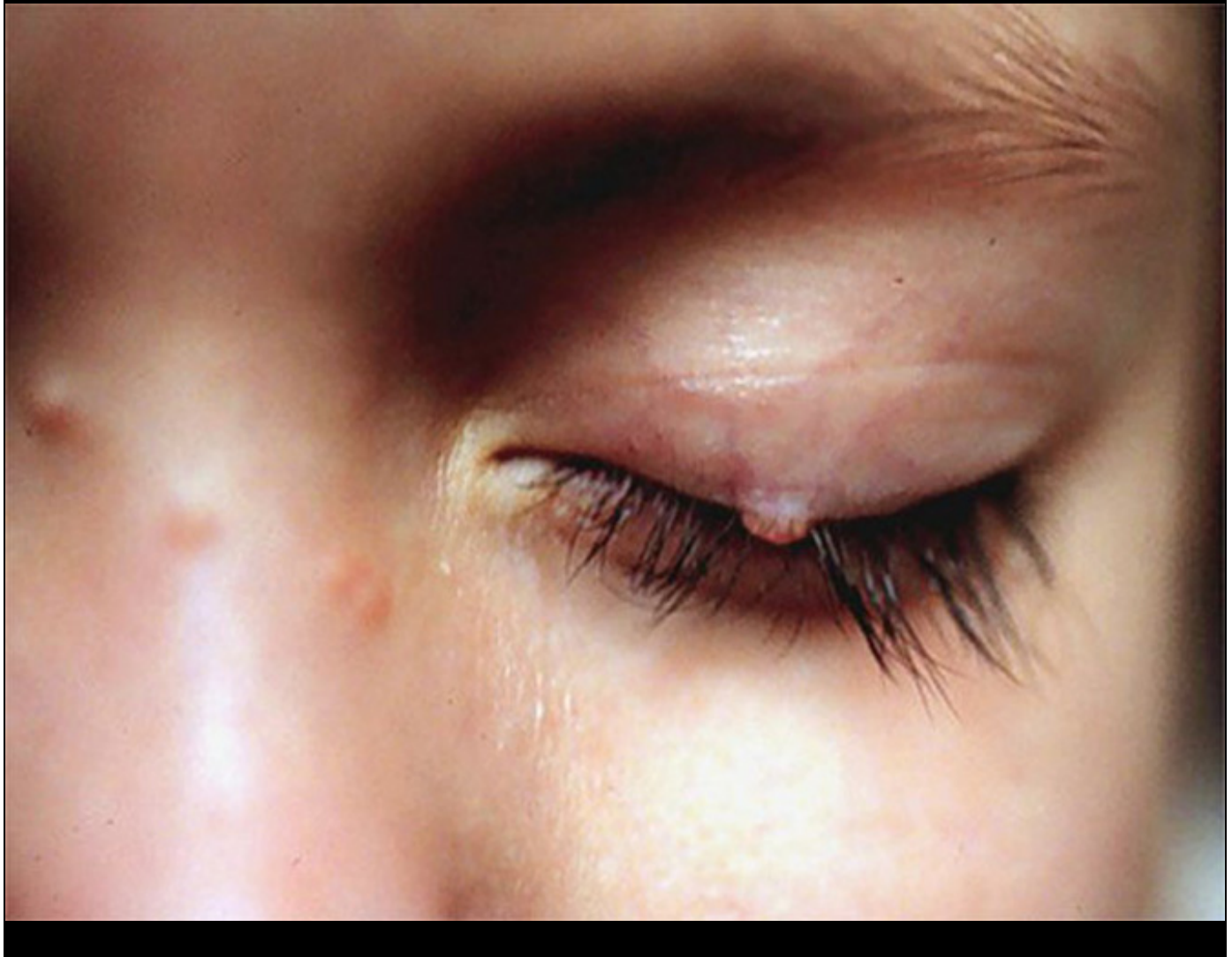

© Copyright [Oculisti OnLine](#)

EyeAtlas

The online Atlas of Ophthalmology

Molluscum contagiosum

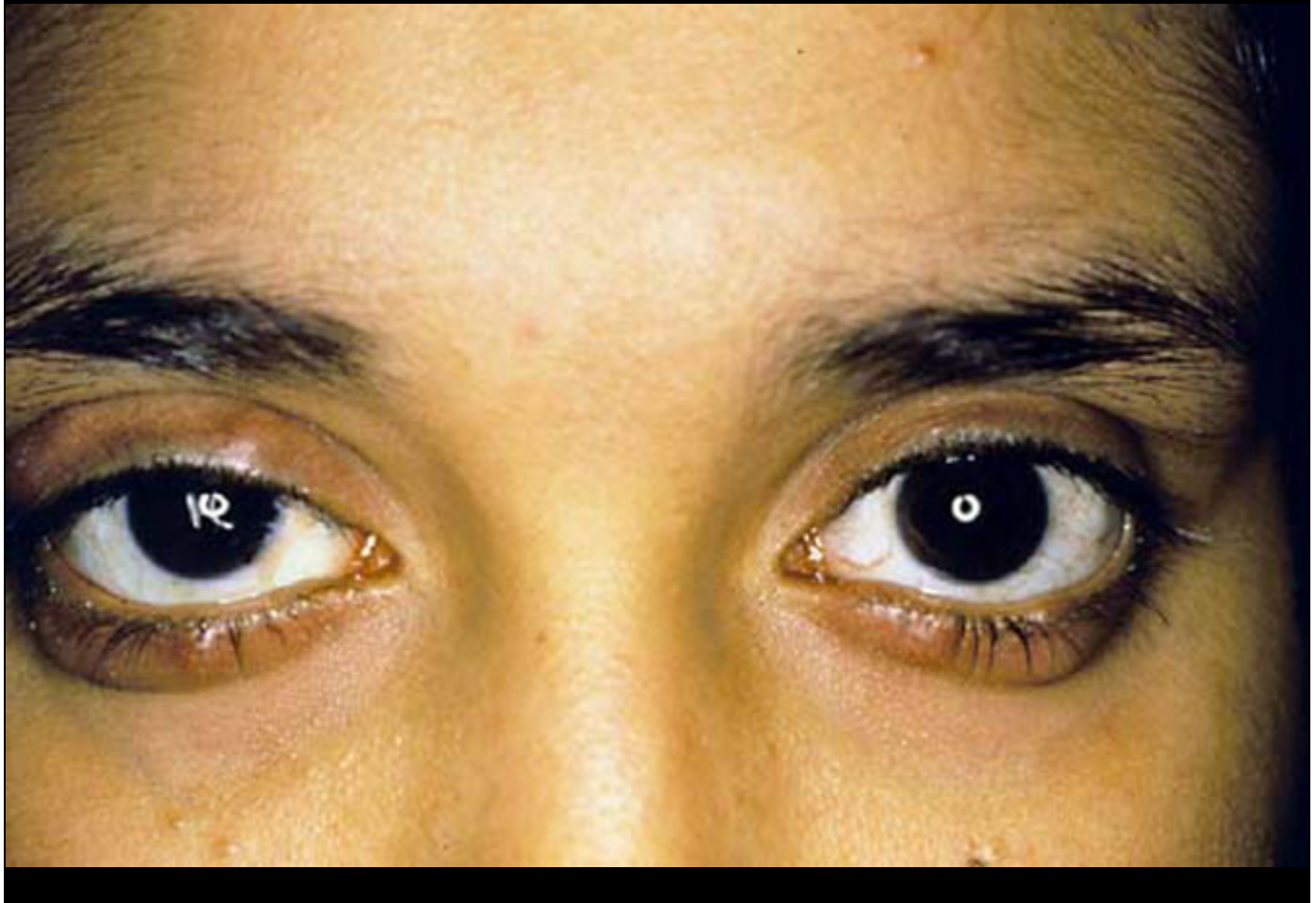

© Copyright [Oculisti OnLine](#)

EyeAtlas

The online Atlas of Ophthalmology

Hordeolum

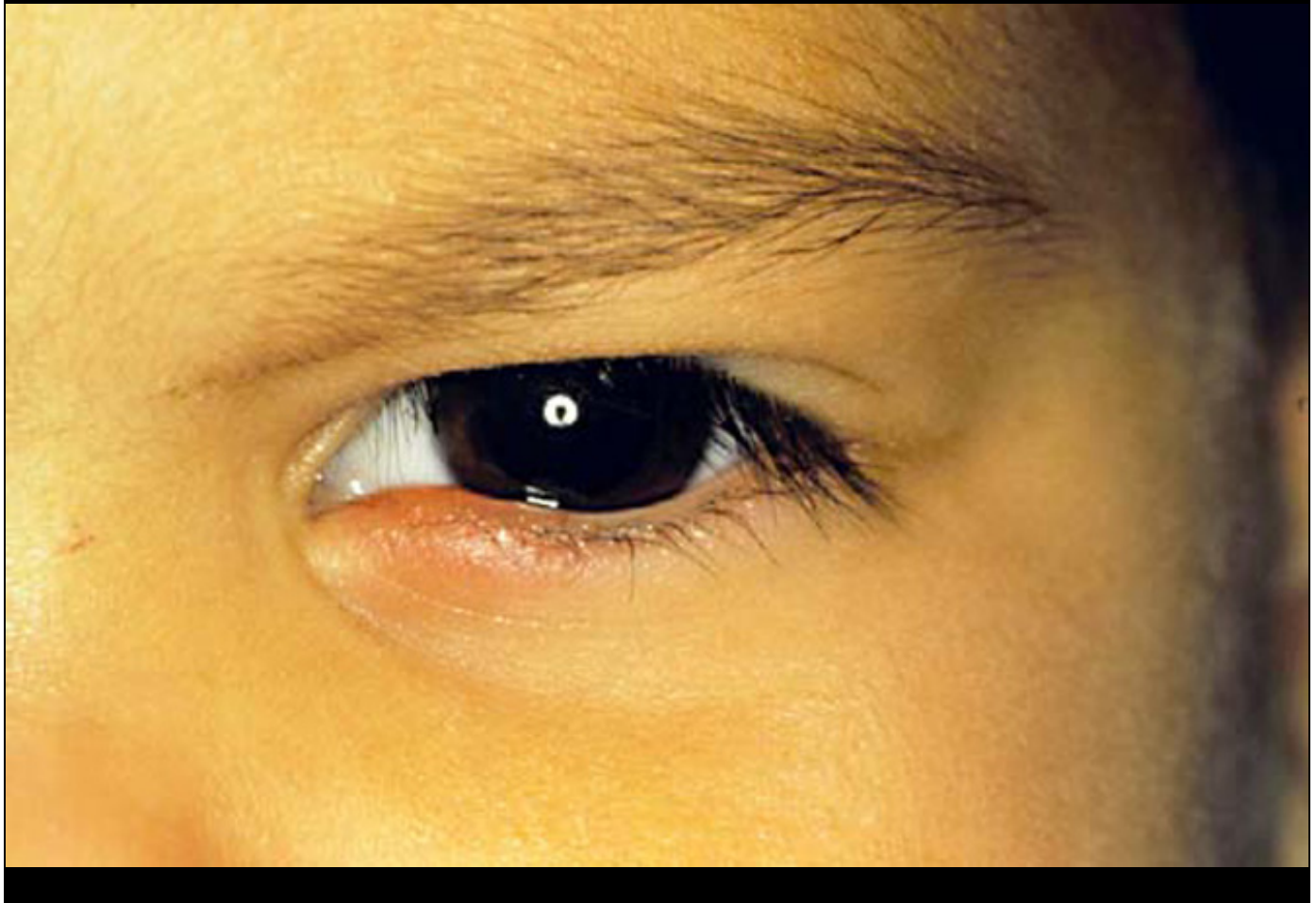

© Copyright [Oculisti OnLine](#)

EyeAtlas

The online Atlas of Ophthalmology

Hordeolum

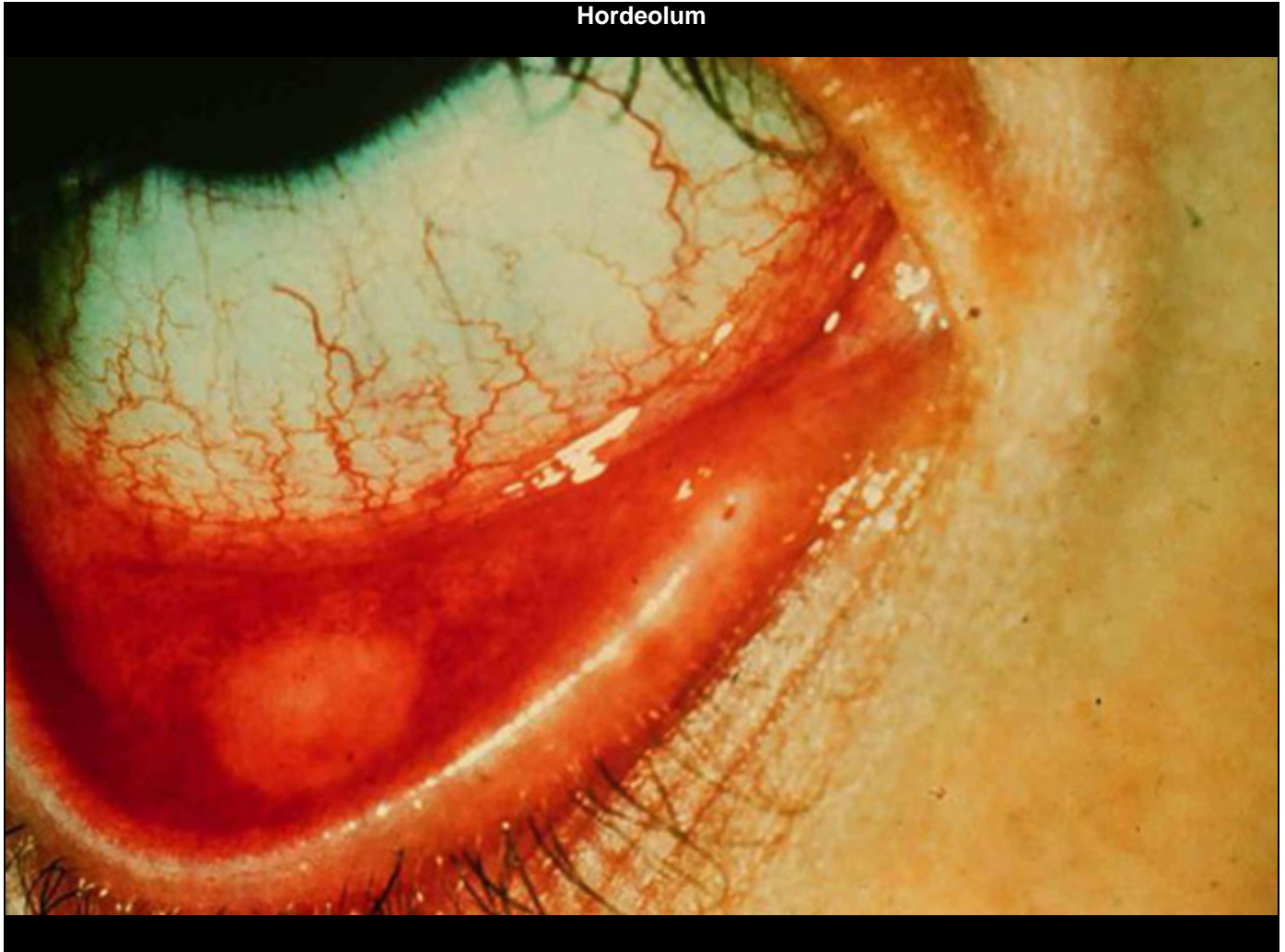

© Copyright [Oculisti OnLine](#)

EyeAtlas

The online Atlas of Ophthalmology

Hordeolum

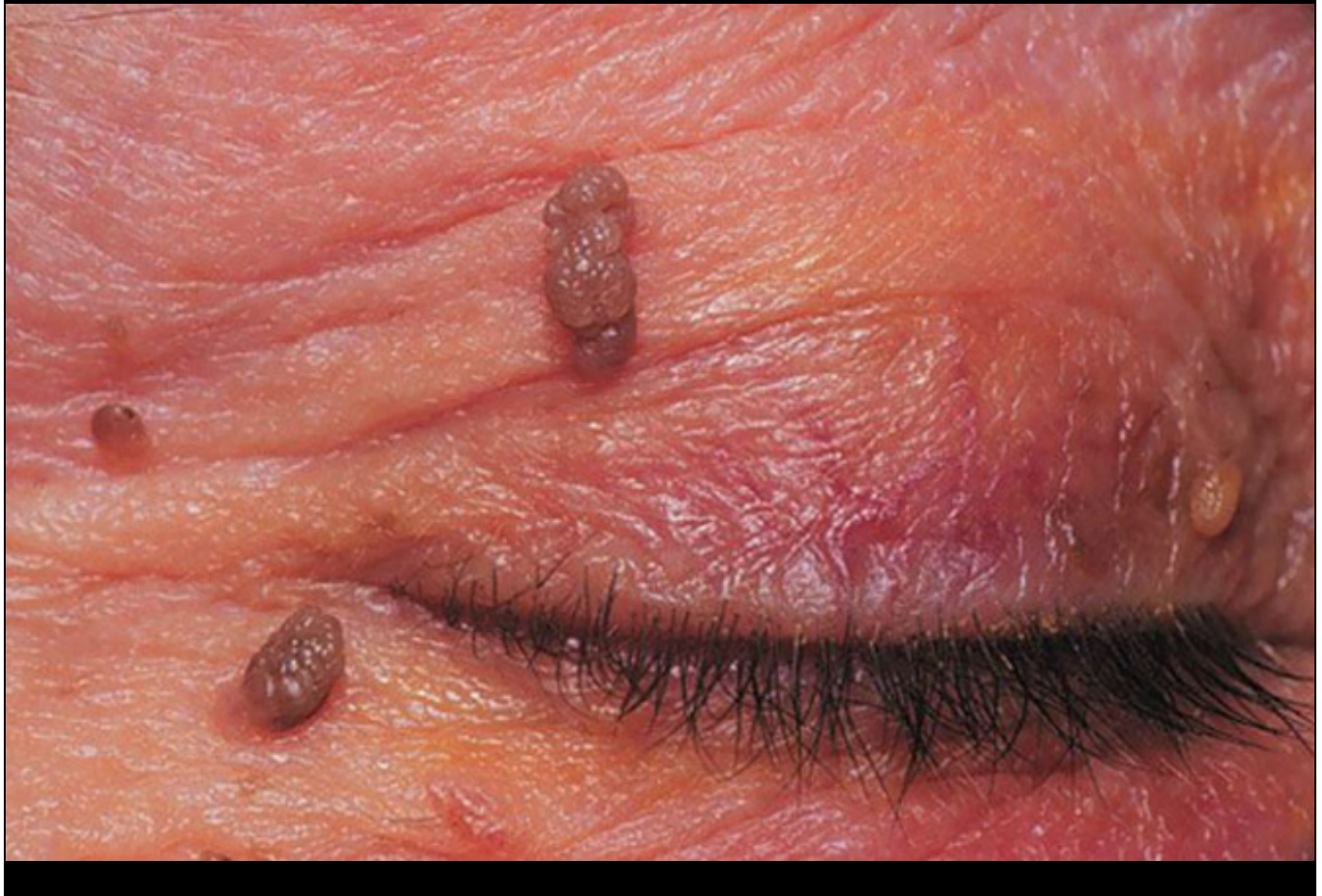

© Copyright [Oculisti OnLine](http://www.eyeatlas.com)

EyeAtlas

The online Atlas of Ophthalmology

Papilloma

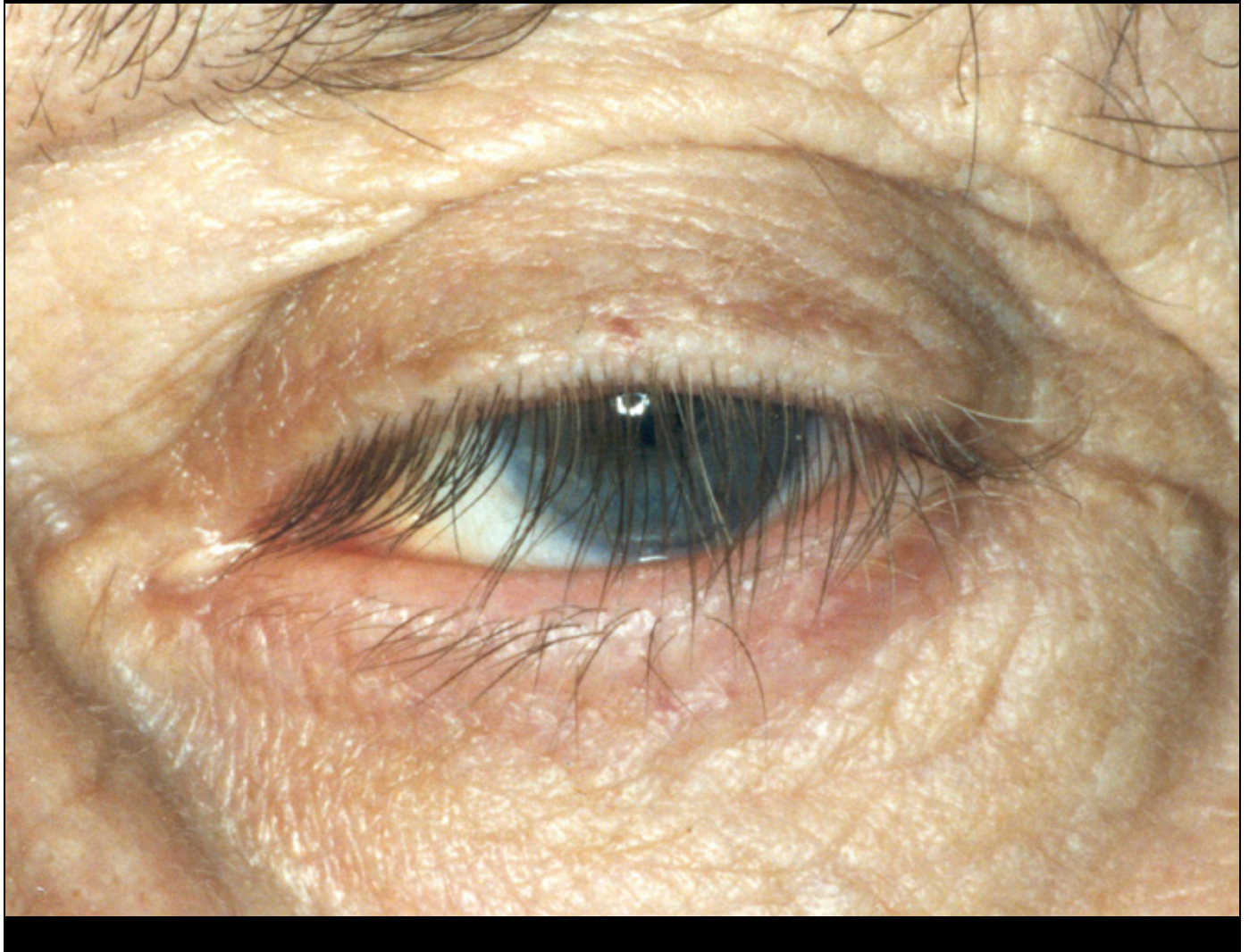


© Copyright [Oculisti OnLine](#)

EyeAtlas

The online Atlas of Ophthalmology

Ptosis

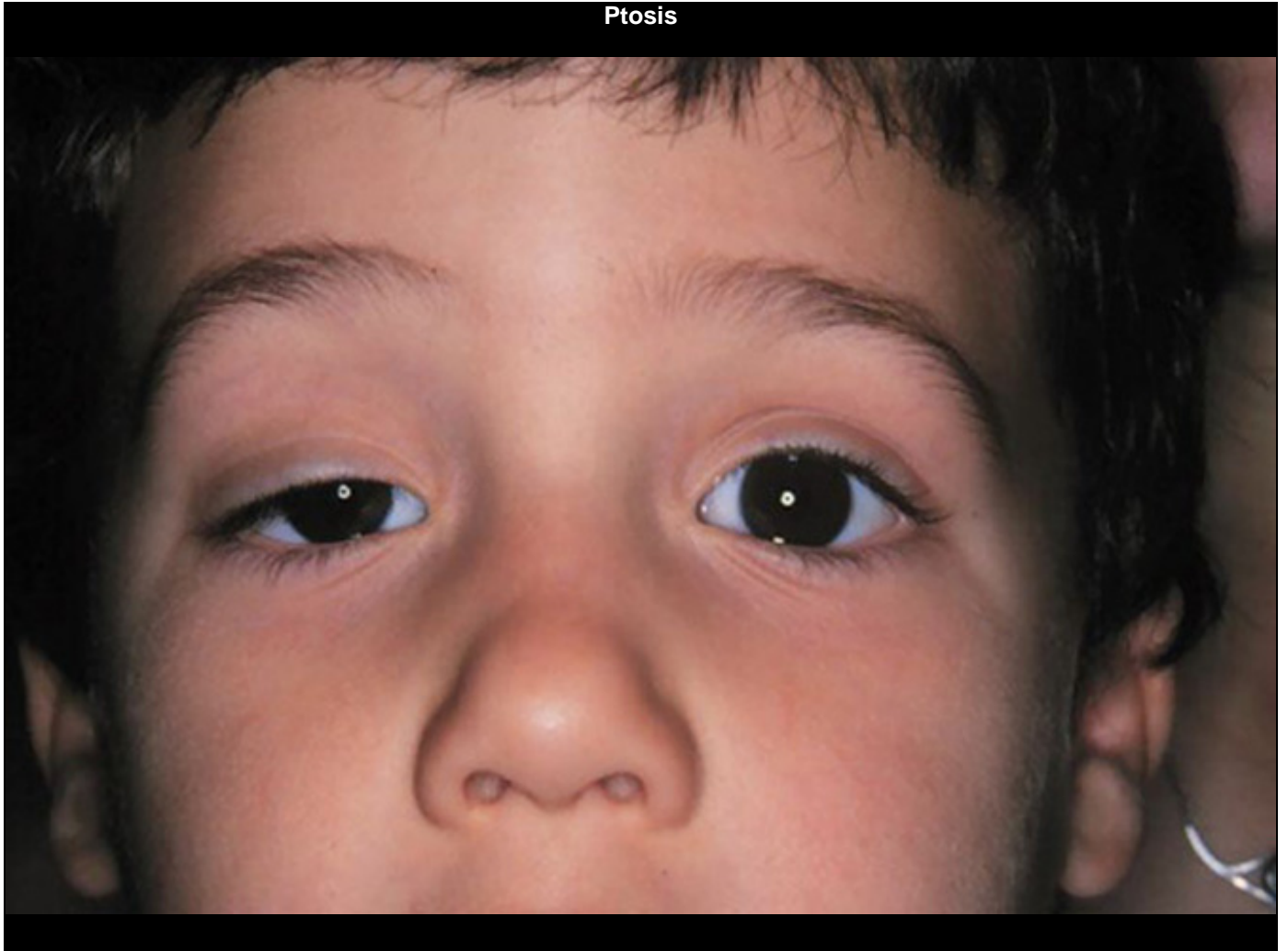


© Copyright [Oculisti OnLine](#)

EyeAtlas

The online Atlas of Ophthalmology

Ptosis

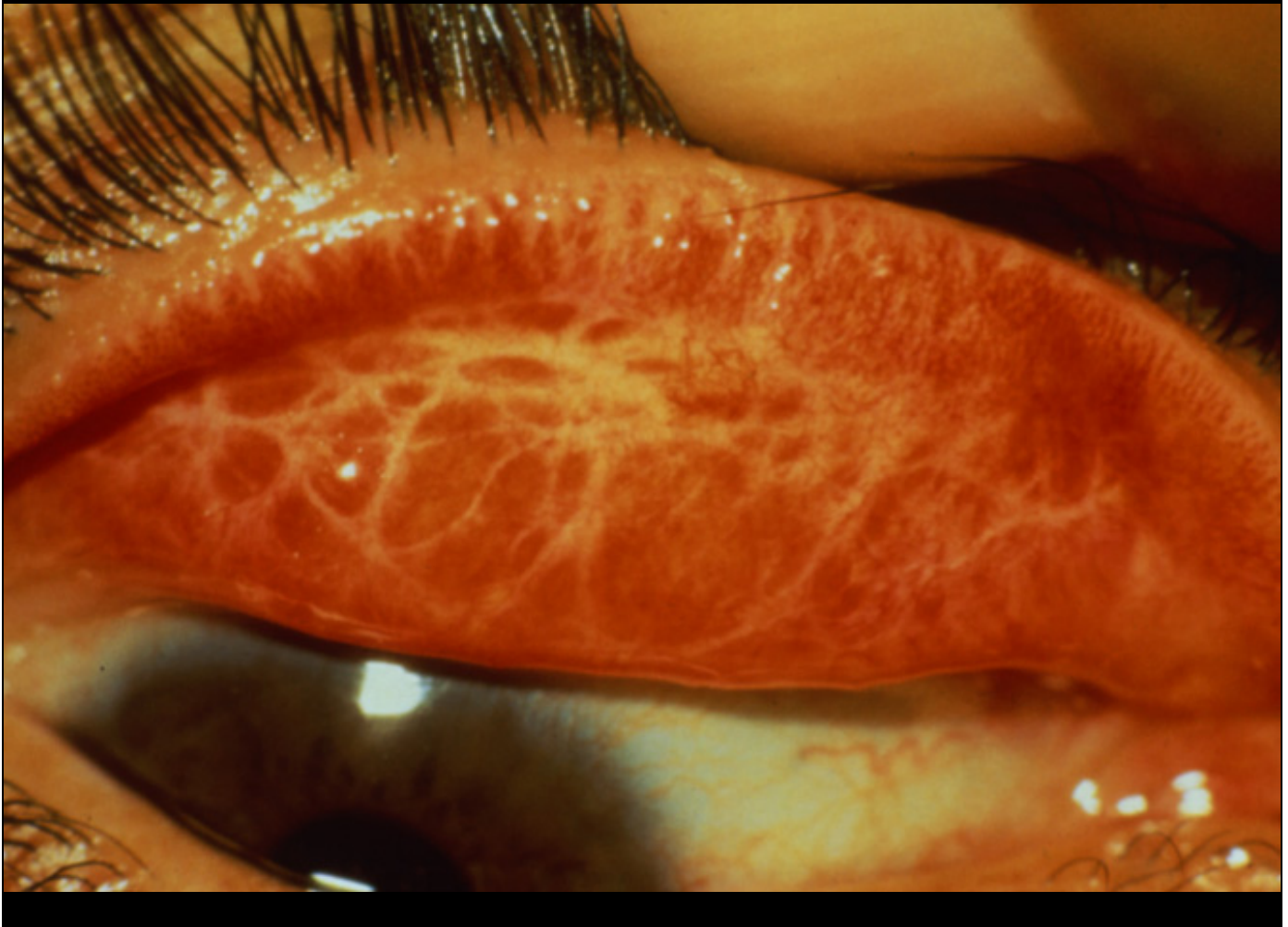

© Copyright [Oculisti OnLine](#)

EyeAtlas

The online Atlas of Ophthalmology

Trachoma: lid scars

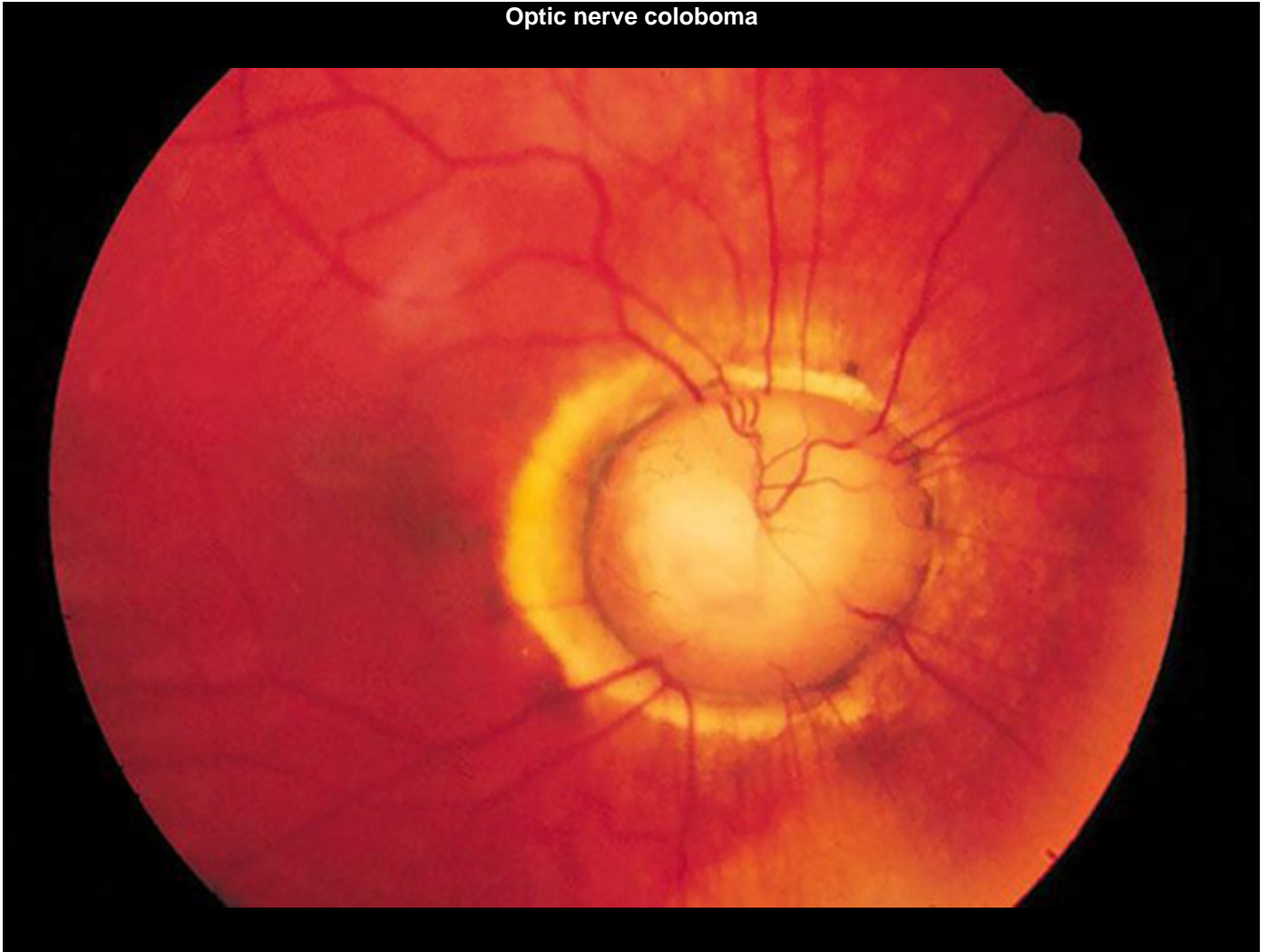

© Copyright [Oculisti OnLine](#)

Eyeatlas

The online Atlas of Ophthalmology

Optic nerve coloboma

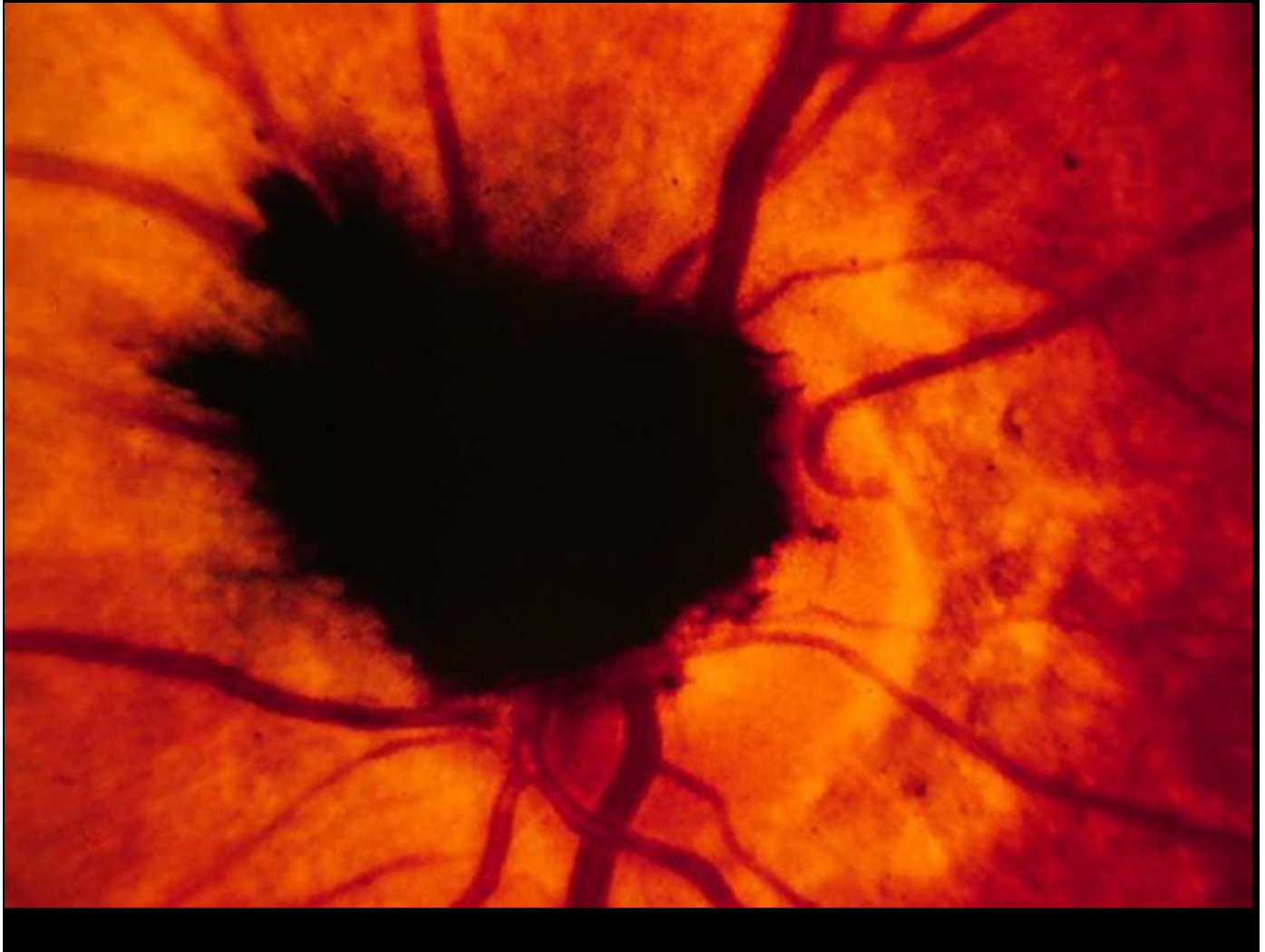

© Copyright [Oculisti OnLine](#)

EyeAtlas

The online Atlas of Ophthalmology

Melanocytoma

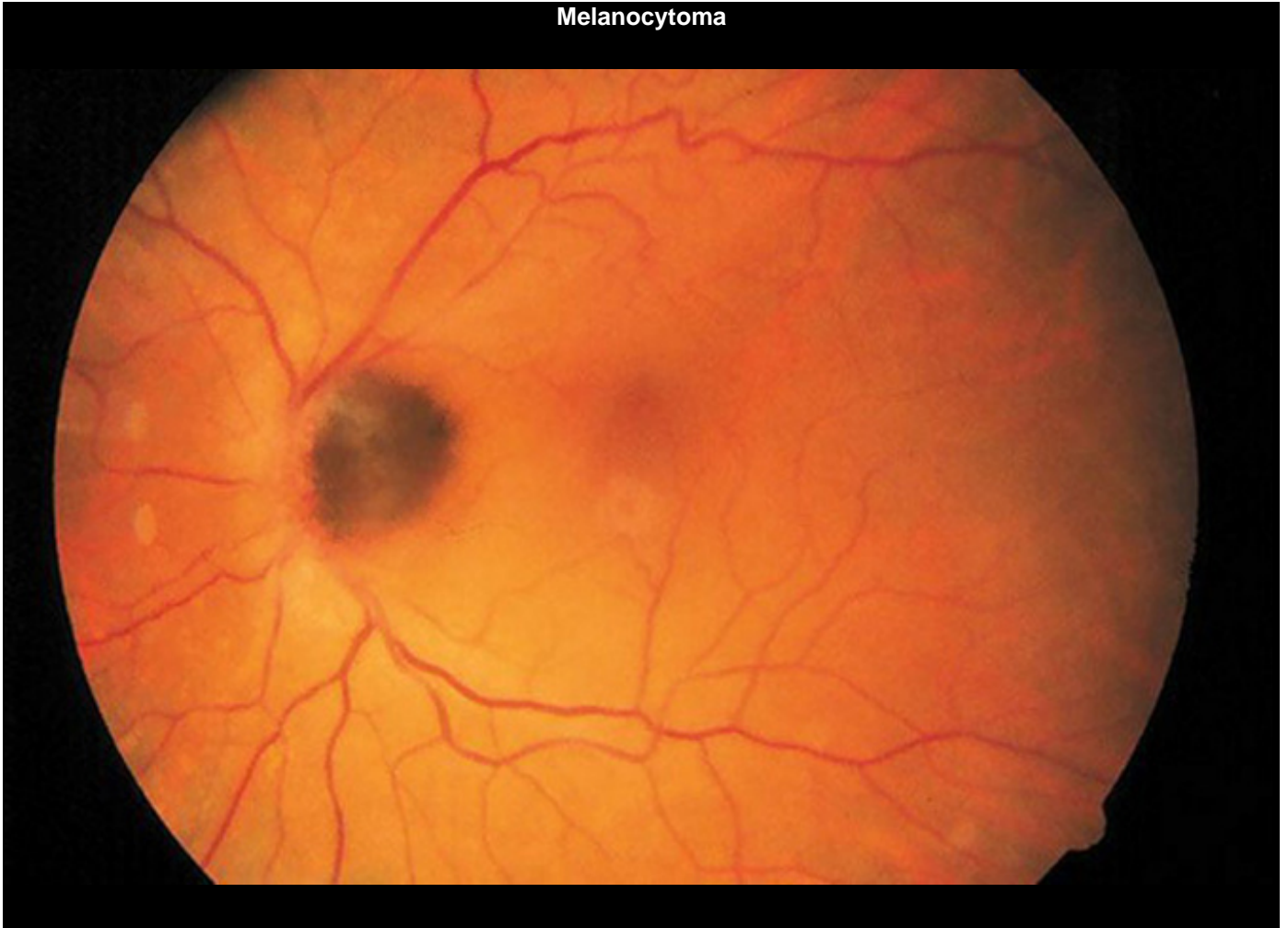

© Copyright [Oculisti OnLine](#)

EyeAtlas

The online Atlas of Ophthalmology

Melanocytoma

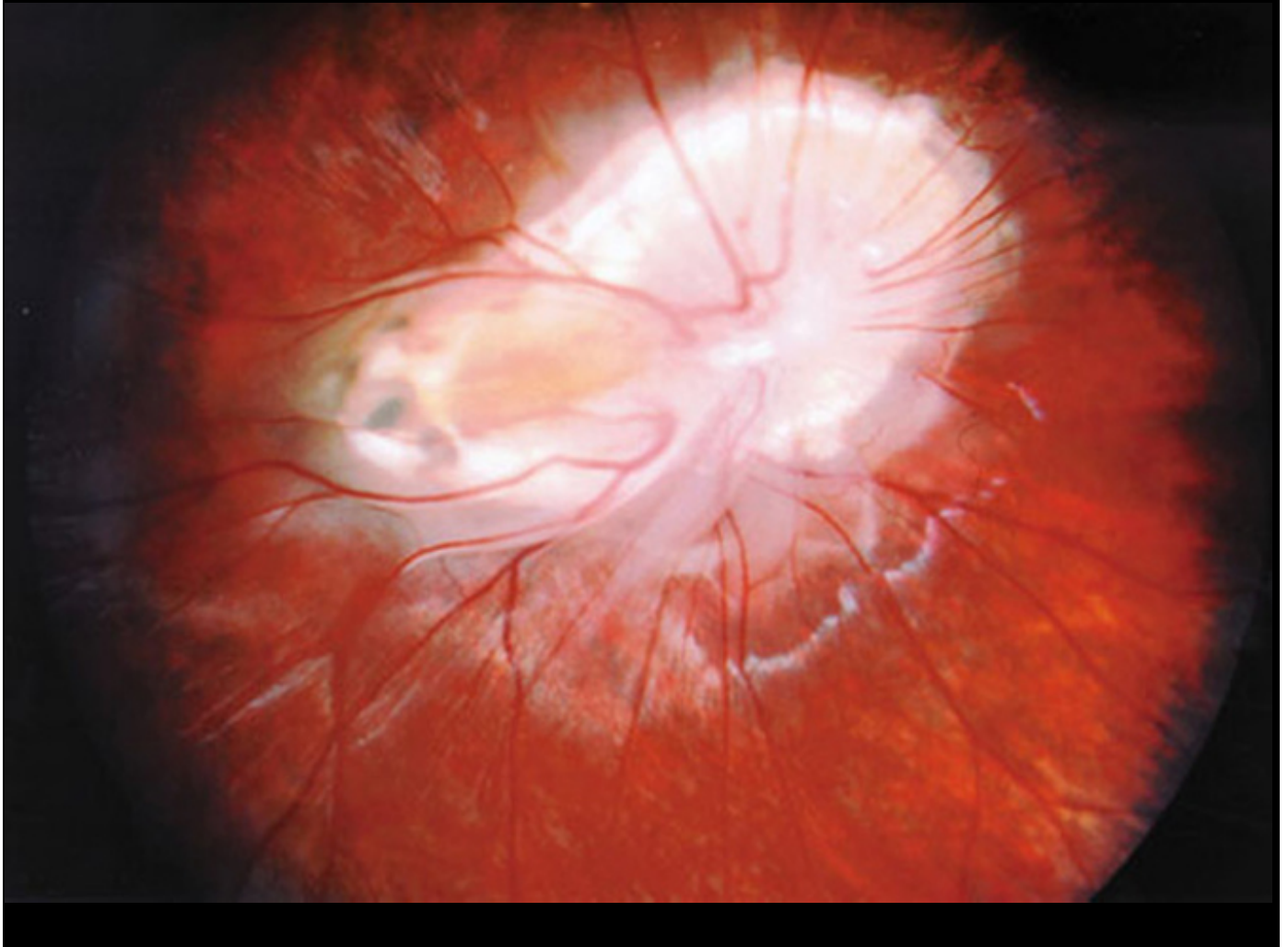


© Copyright [Oculisti OnLine](http://www.eyeatlas.com)

EyeAtlas

The online Atlas of Ophthalmology

Morning glory

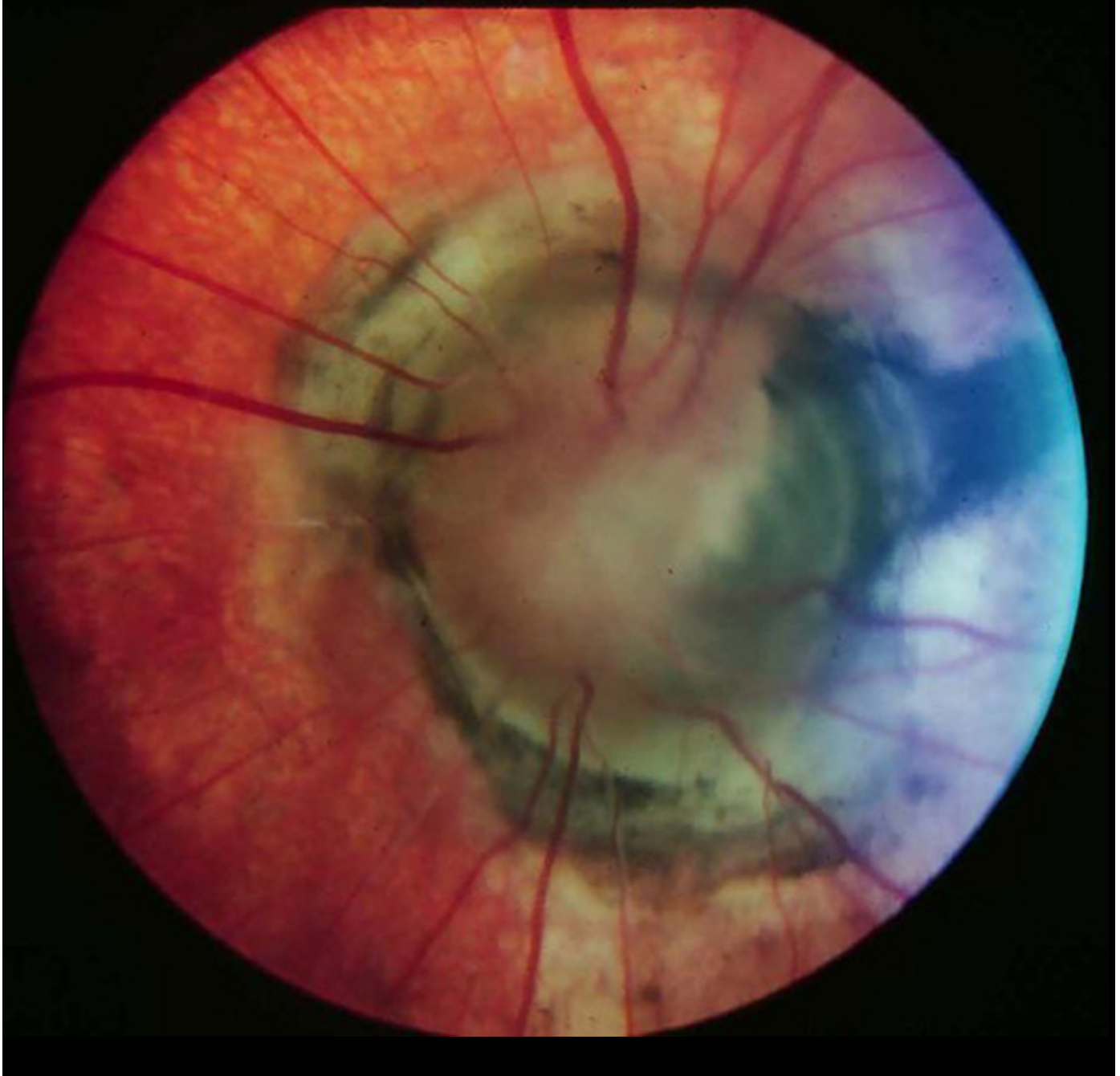

© Copyright [Oculisti OnLine](http://www.eyeatlas.com)

Eyeatlas

The online Atlas of Ophthalmology

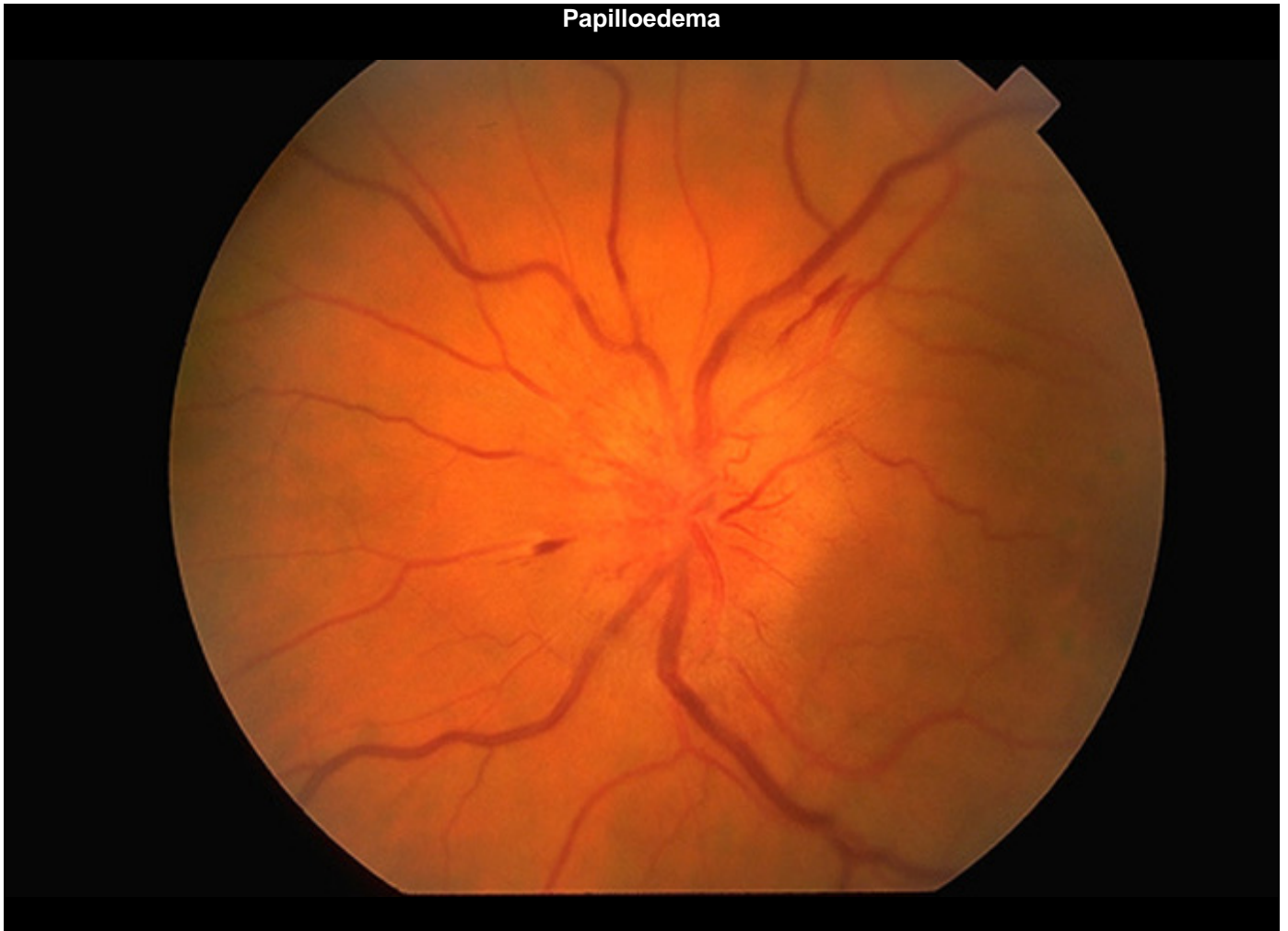Morning glory



EyeAtlas

The online Atlas of Ophthalmology

Papilloedema

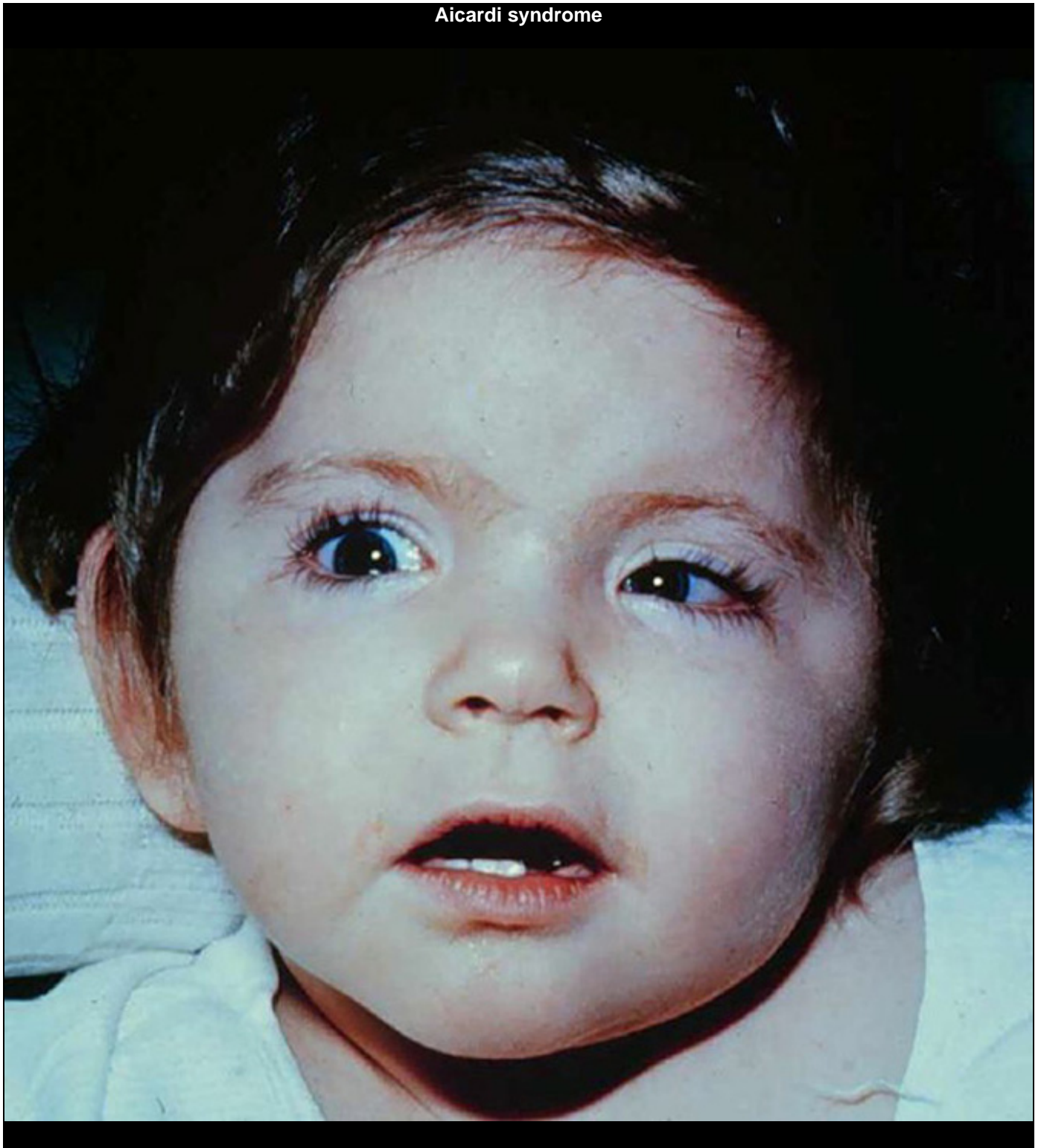

© Copyright [Oculisti OnLine](#)

Eyeatlas

The online Atlas of Ophthalmology

Aicardi syndrome

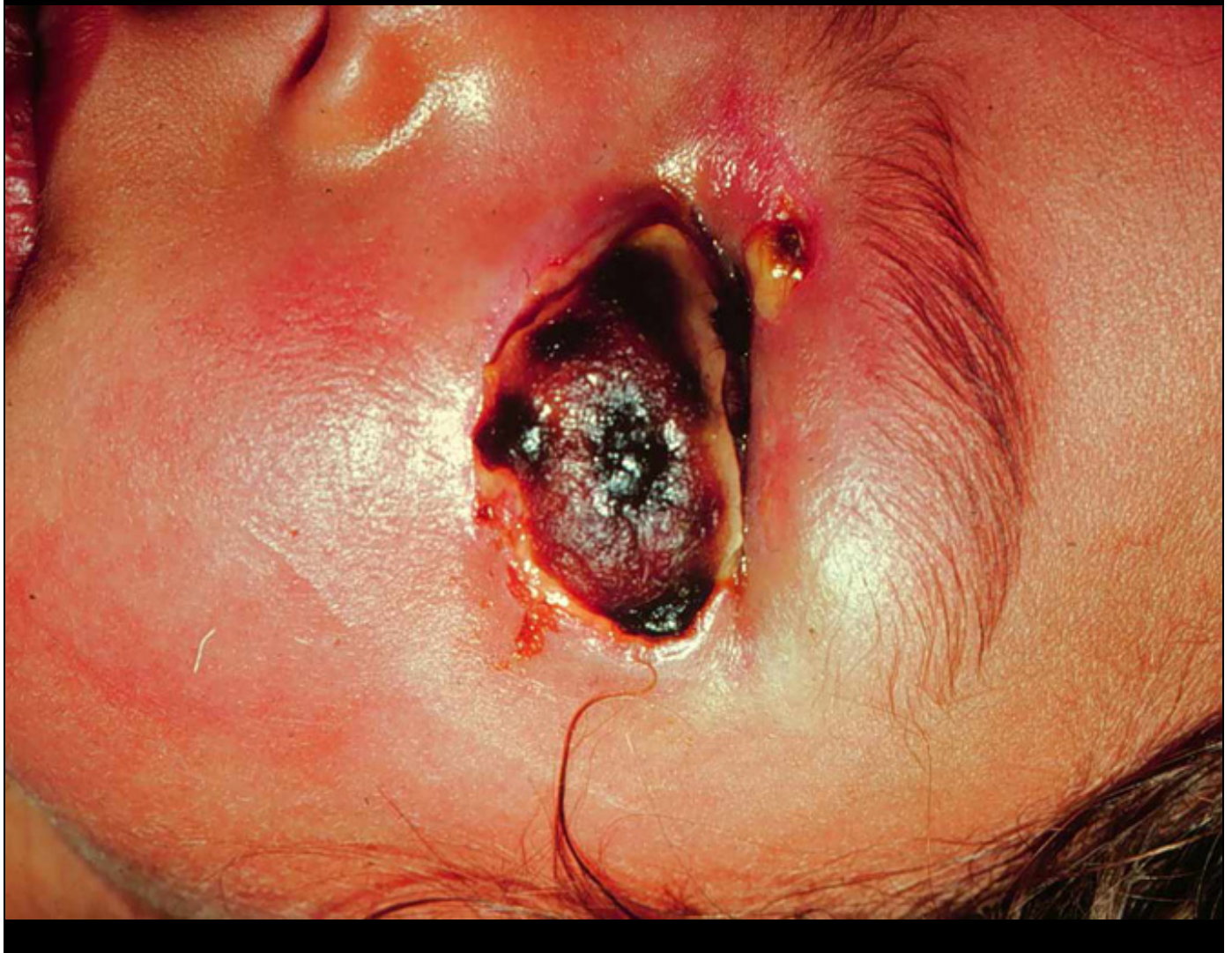

© Copyright [Oculisti OnLine](#)

EyeAtlas

The online Atlas of Ophthalmology

Antrax

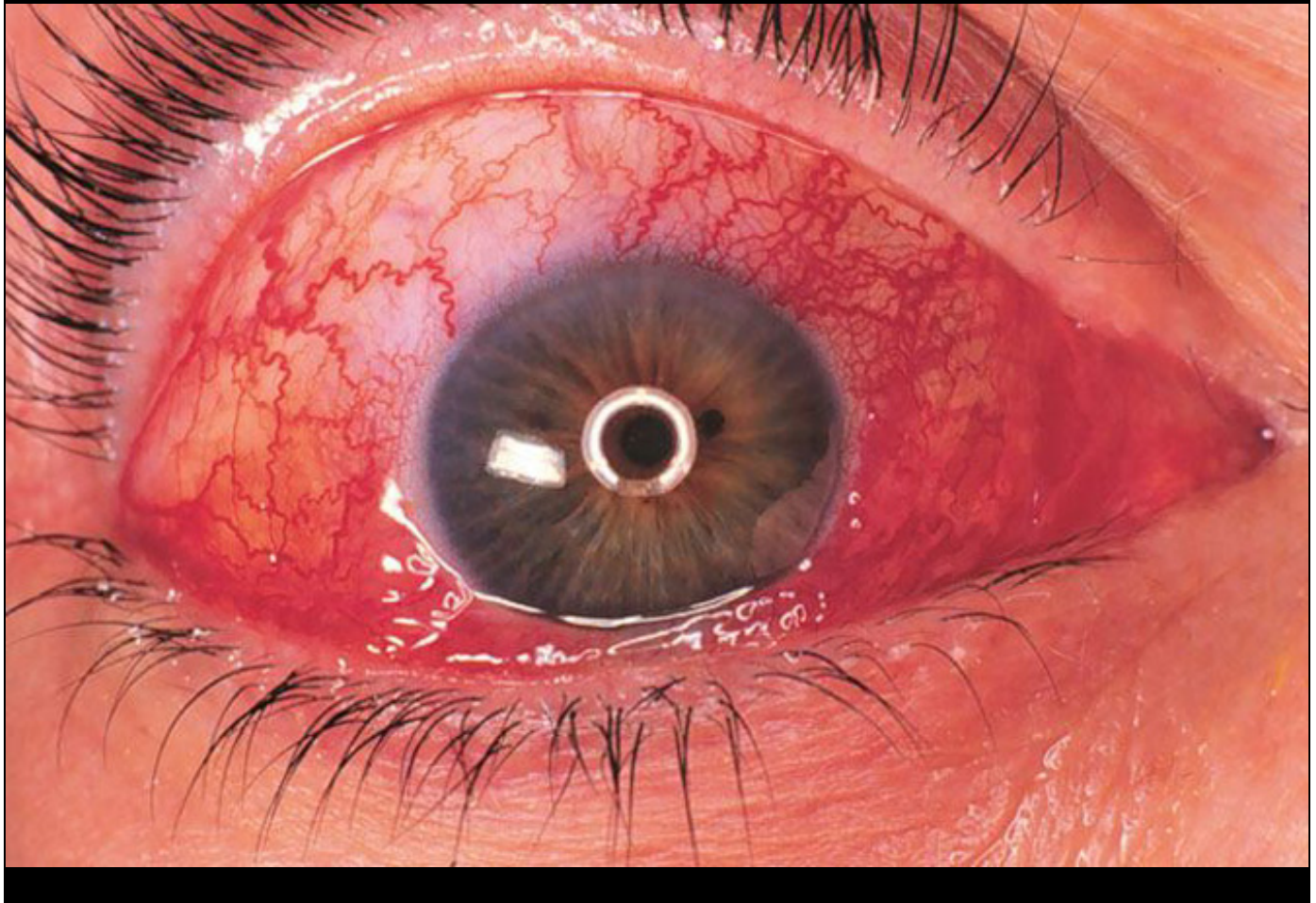


© Copyright [Oculisti OnLine](#)

EyeAtlas

The online Atlas of Ophthalmology

Carotid-cavernous sinus fistula

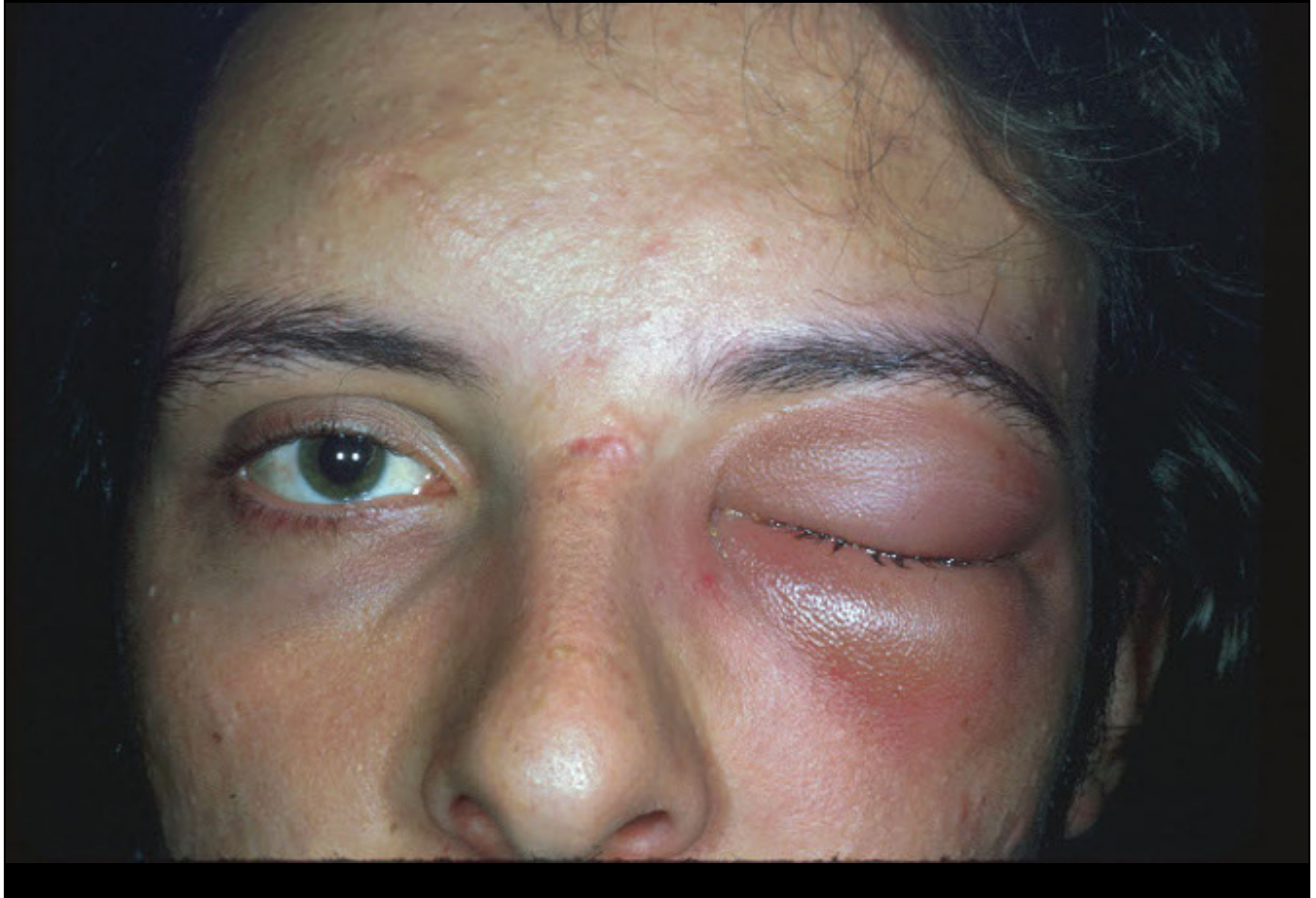

© Copyright [Oculisti OnLine](http://www.eyeatlas.com)

EyeAtlas

The online Atlas of Ophthalmology

Cellulitis

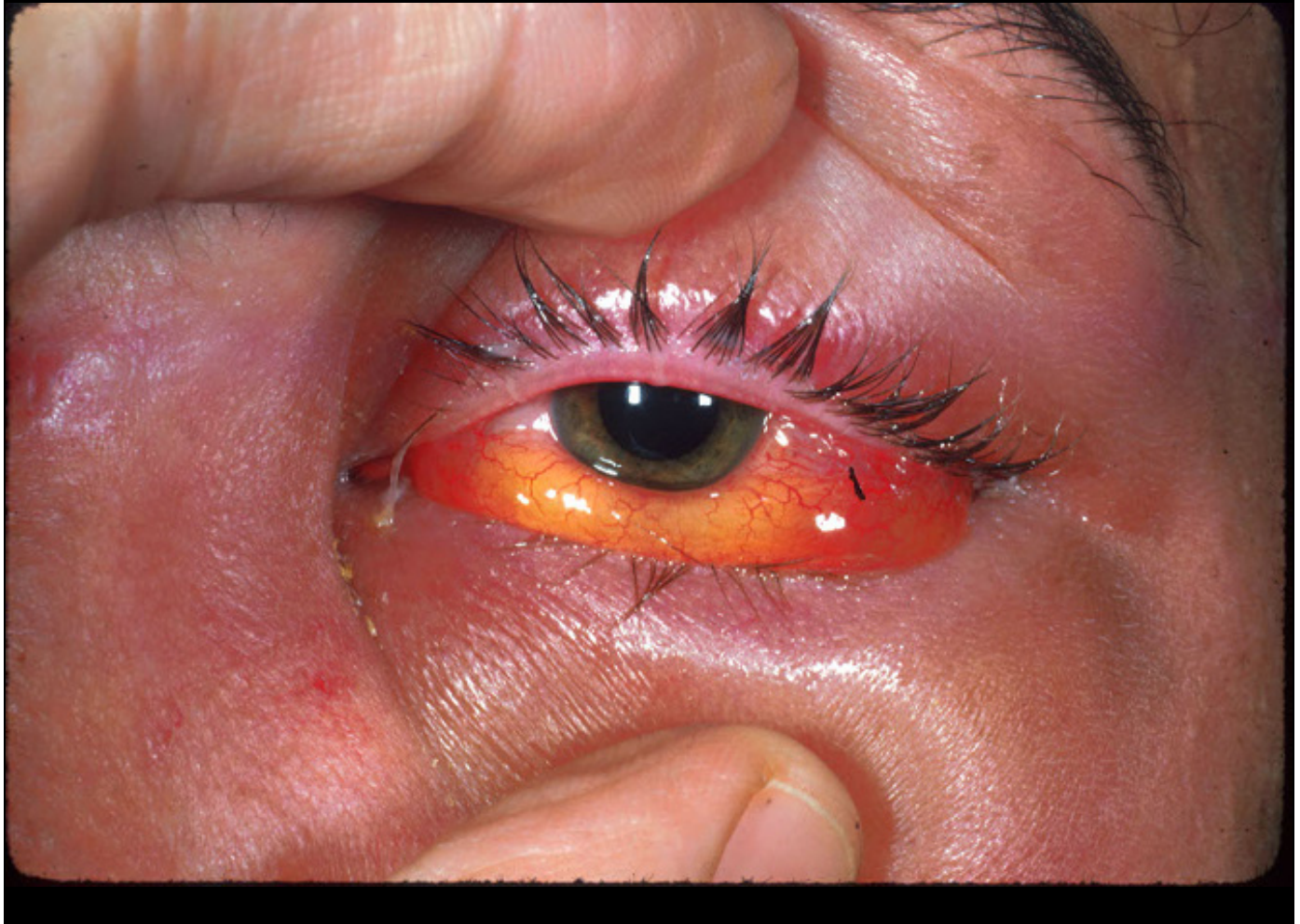

© Copyright [Oculisti OnLine](#)

EyeAtlas

The online Atlas of Ophthalmology

Cellulitis

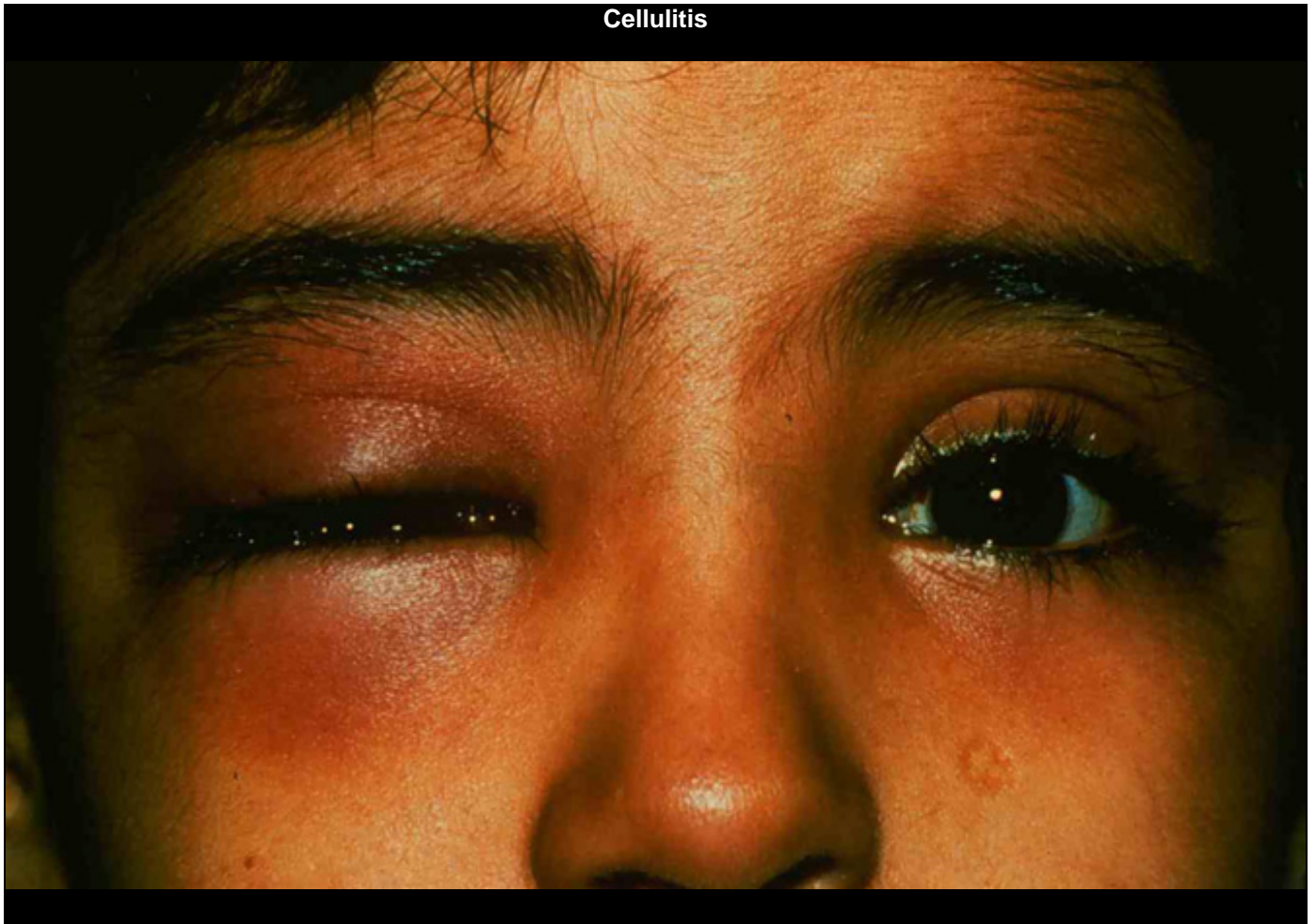


© Copyright [Oculisti OnLine](http://www.eyeatlas.com)

EyeAtlas

The online Atlas of Ophthalmology

Cellulitis

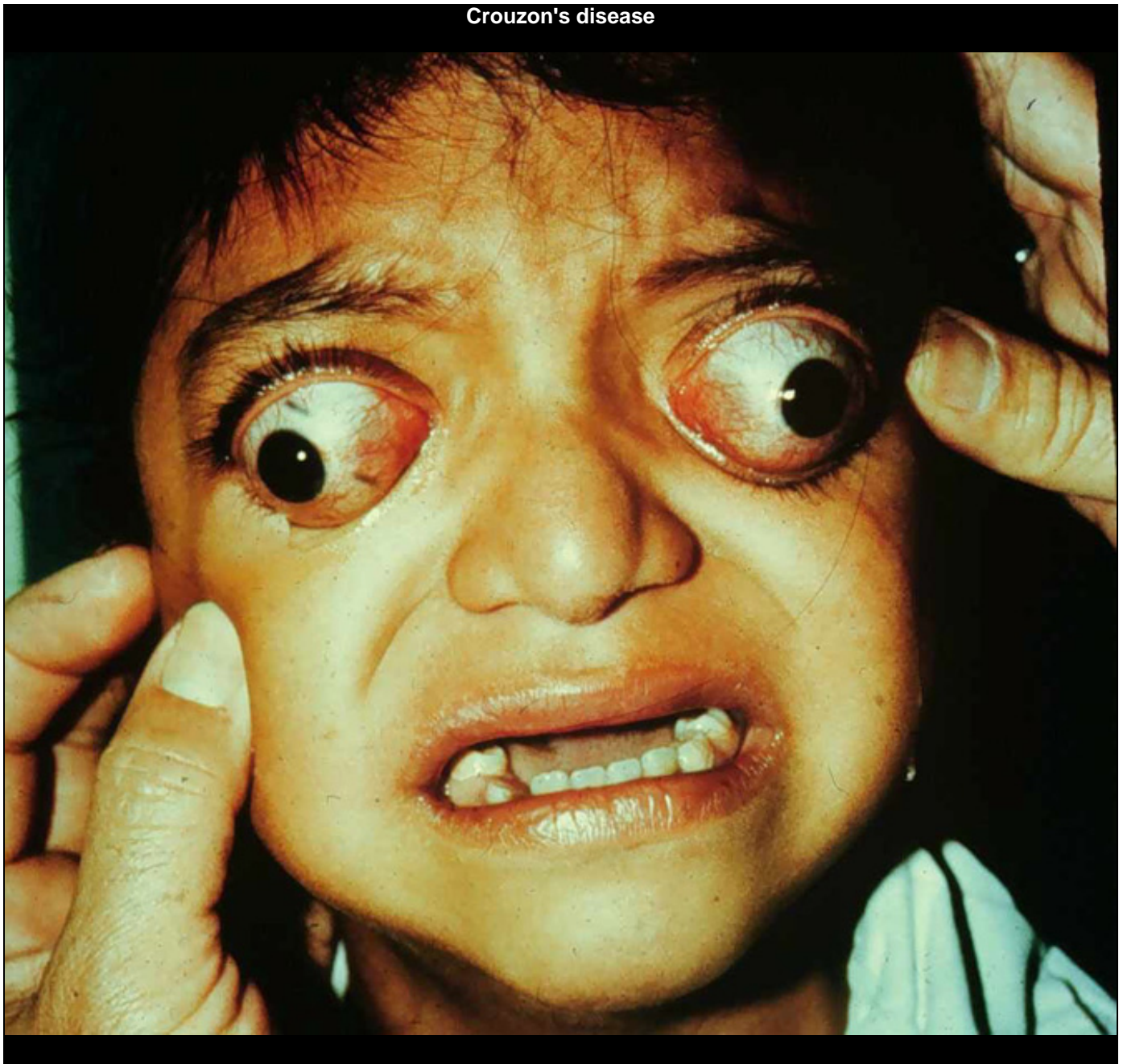


© Copyright [Oculisti OnLine](#)

Eyeatlas

The online Atlas of Ophthalmology

Crouzon's disease

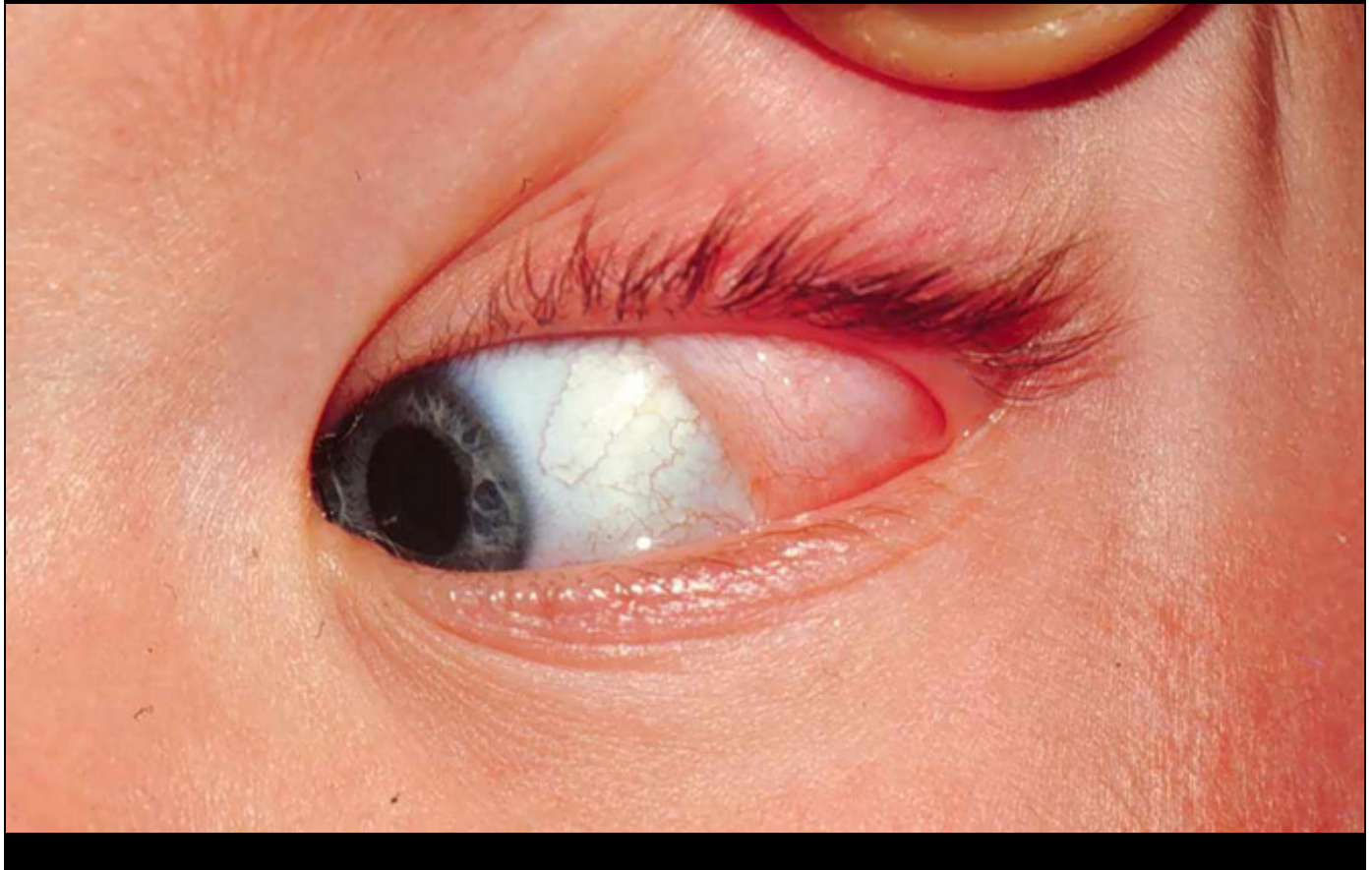

© Copyright [Oculisti OnLine](#)

EyeAtlas

The online Atlas of Ophthalmology

Orbital dermoid

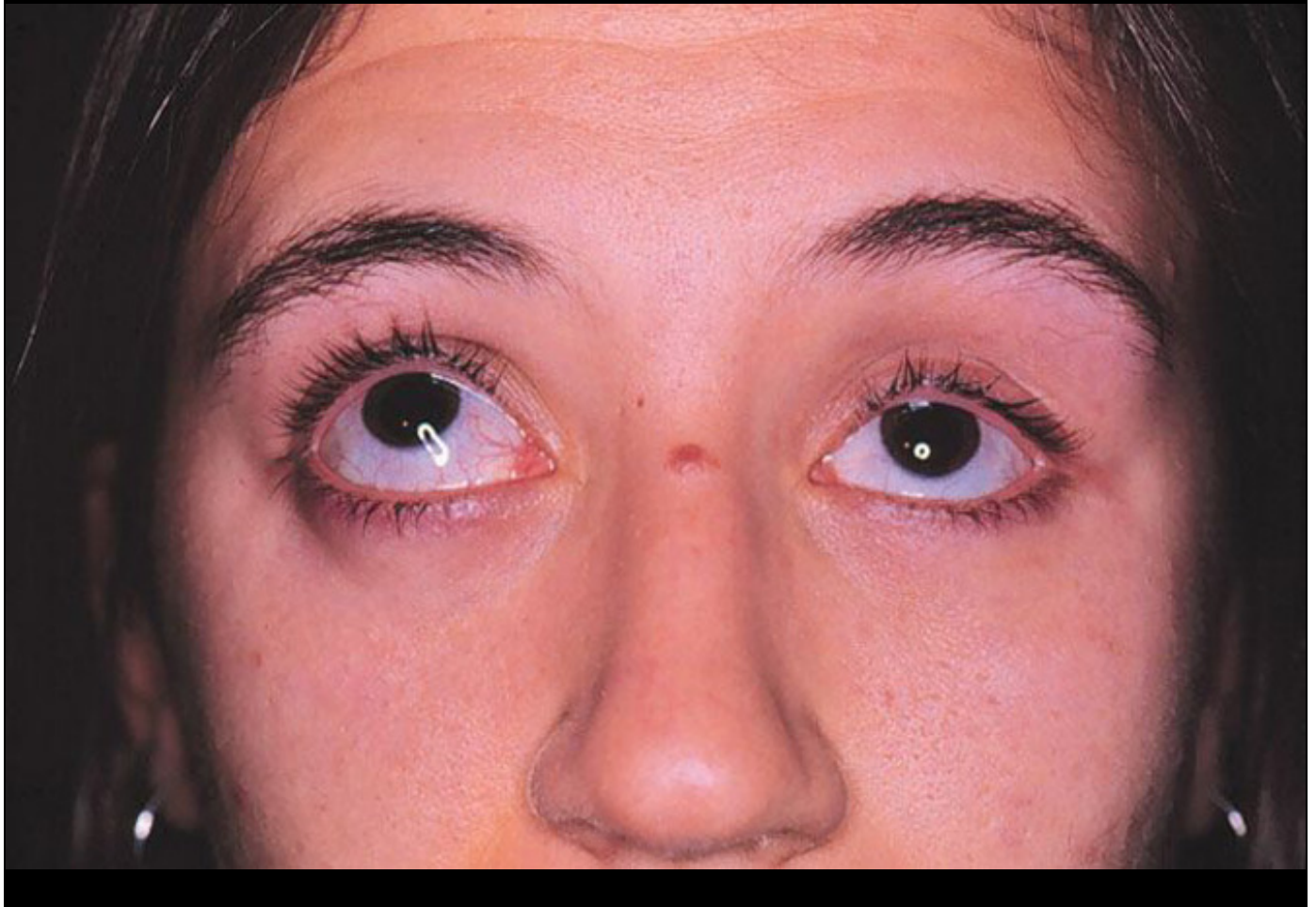

© Copyright [Oculisti OnLine](#)

EyeAtlas

The online Atlas of Ophthalmology

Post traumatic enophtalmos

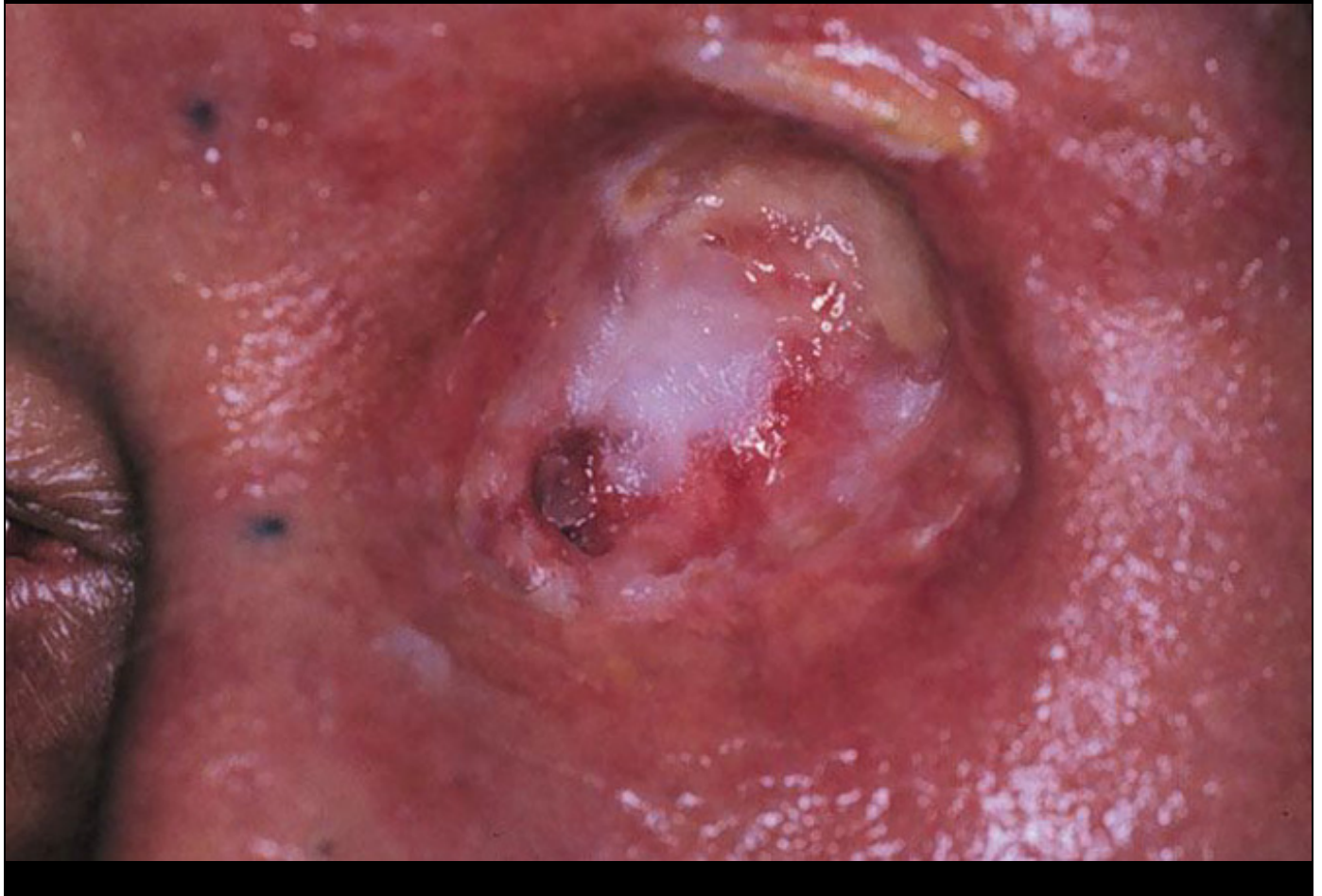

© Copyright [Oculisti OnLine](#)

EyeAtlas

The online Atlas of Ophthalmology

Exenteratio orbitae

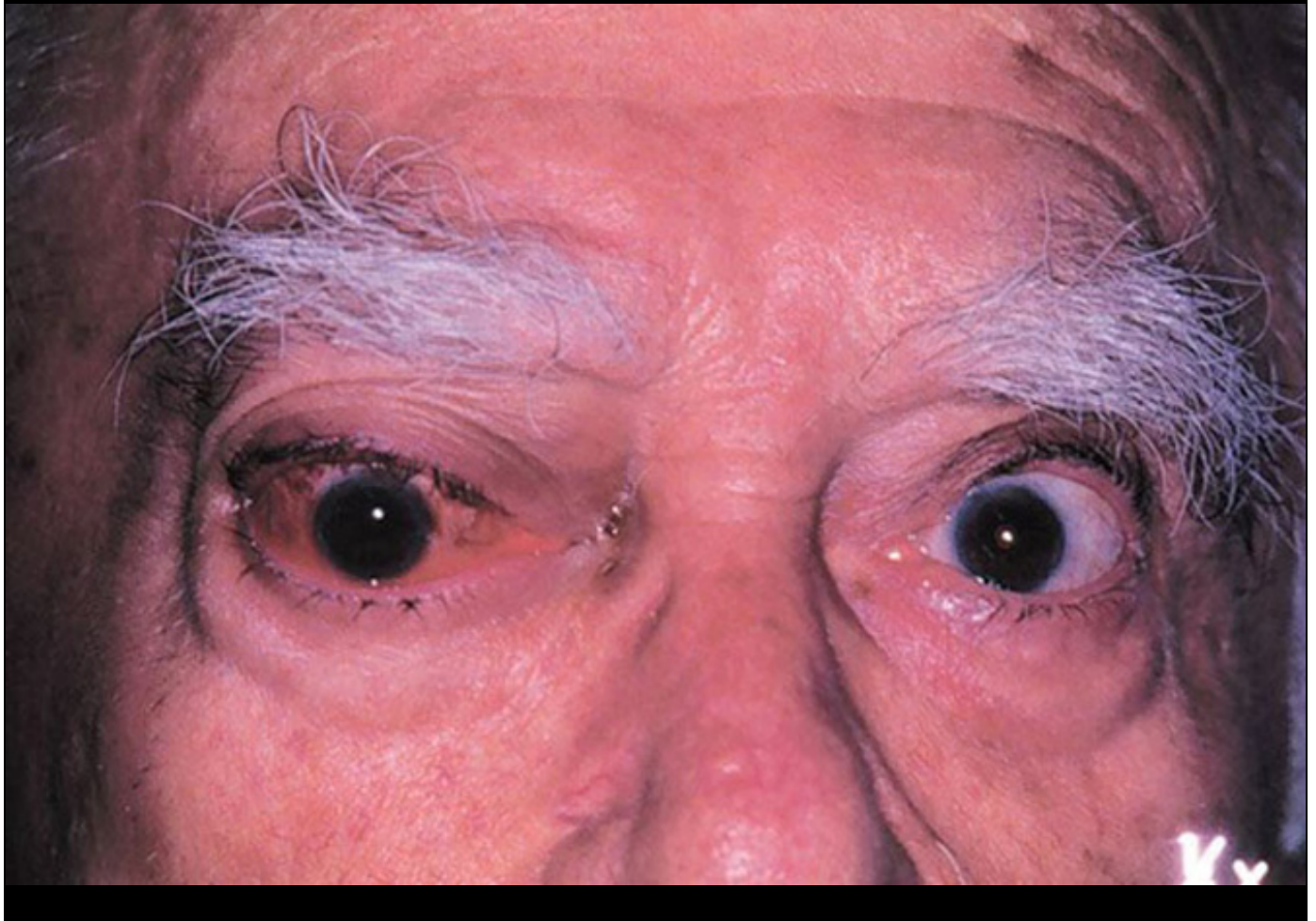

© Copyright [Oculisti OnLine](#)

EyeAtlas

The online Atlas of Ophthalmology

Exophthalmos

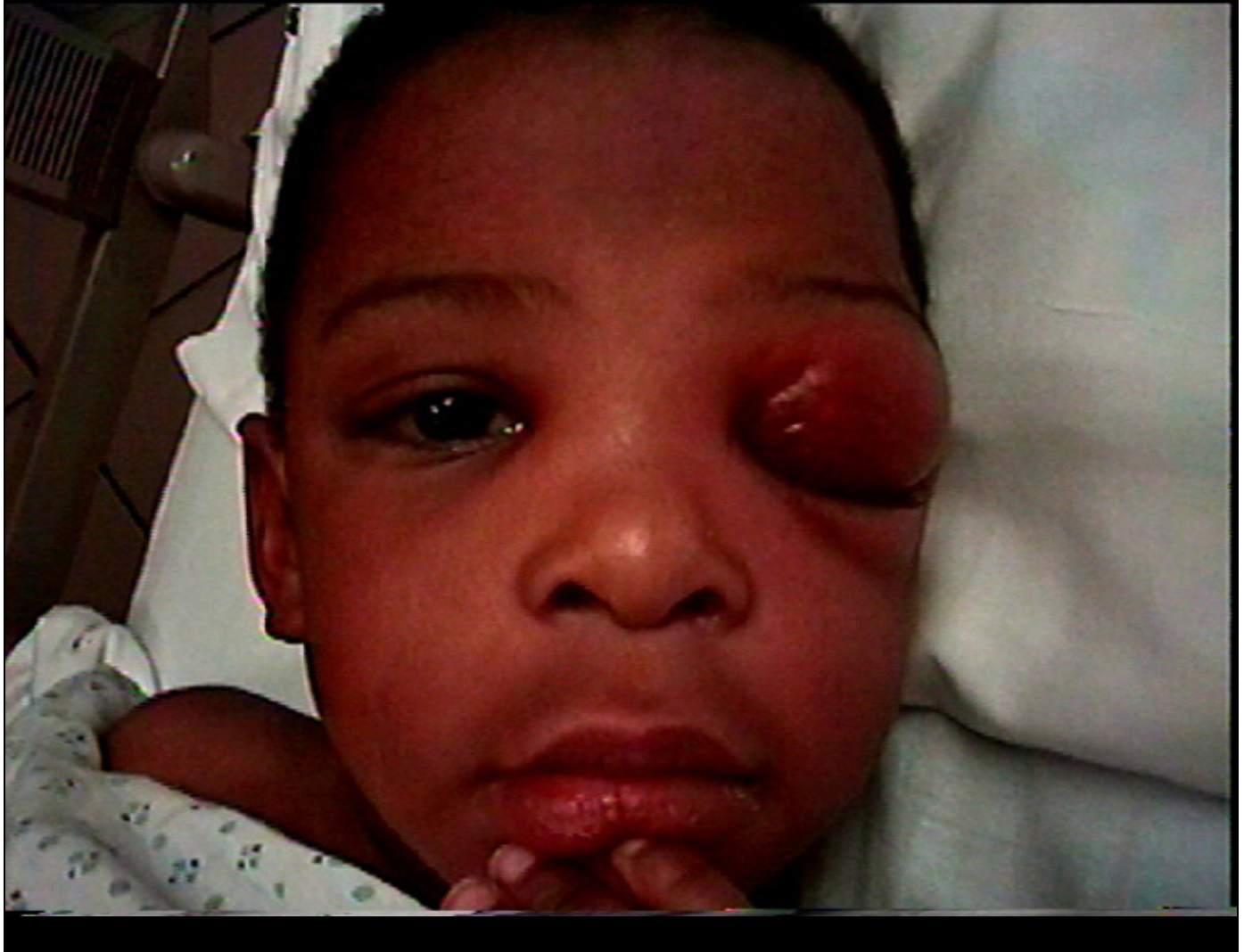

© Copyright [Oculisti OnLine](#)

EyeAtlas

The online Atlas of Ophthalmology

Preseptal cellulitis

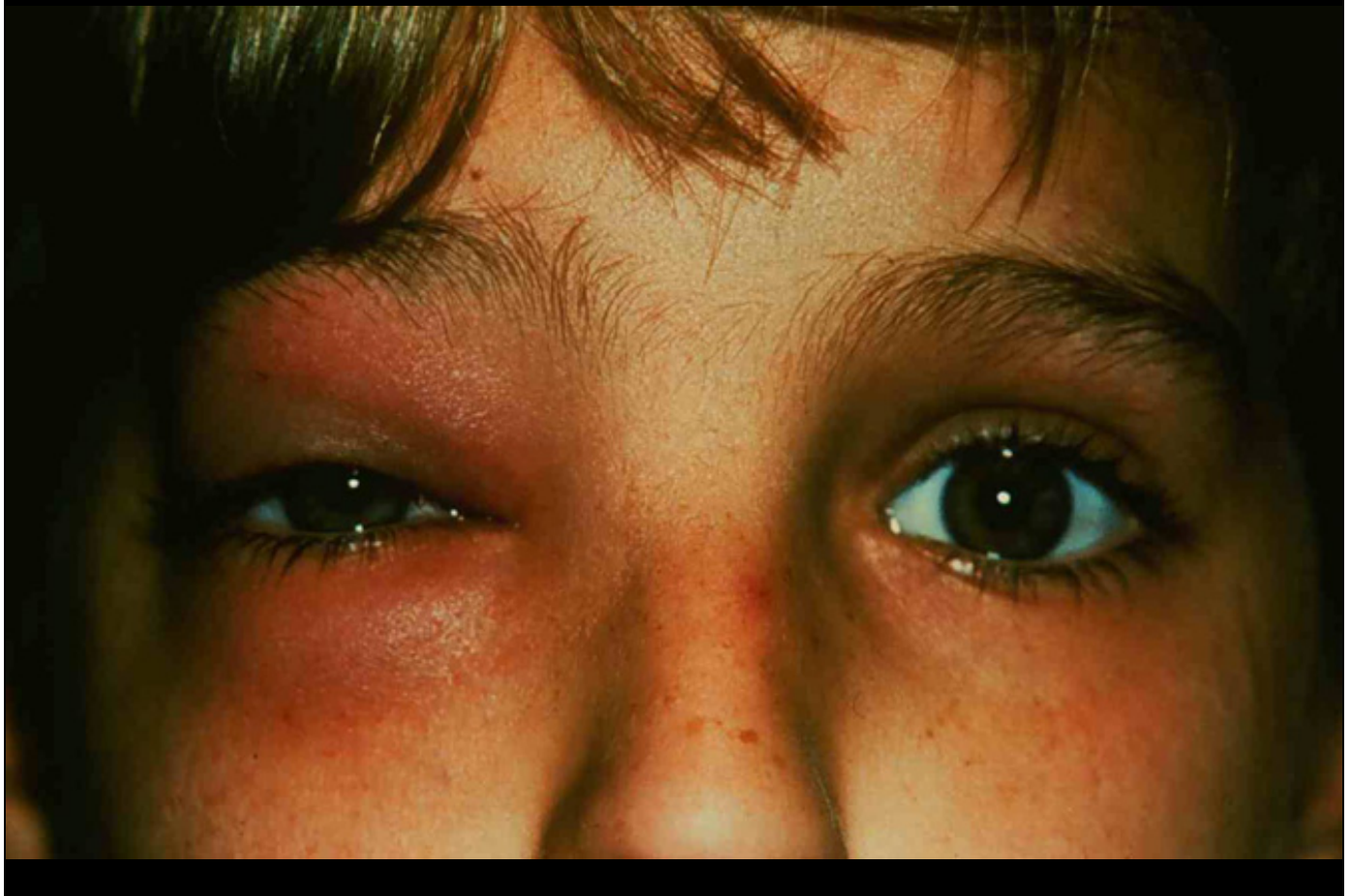

© Copyright [Oculisti OnLine](http://www.eyeatlas.com)

EyeAtlas

The online Atlas of Ophthalmology

Preseptal cellulitis

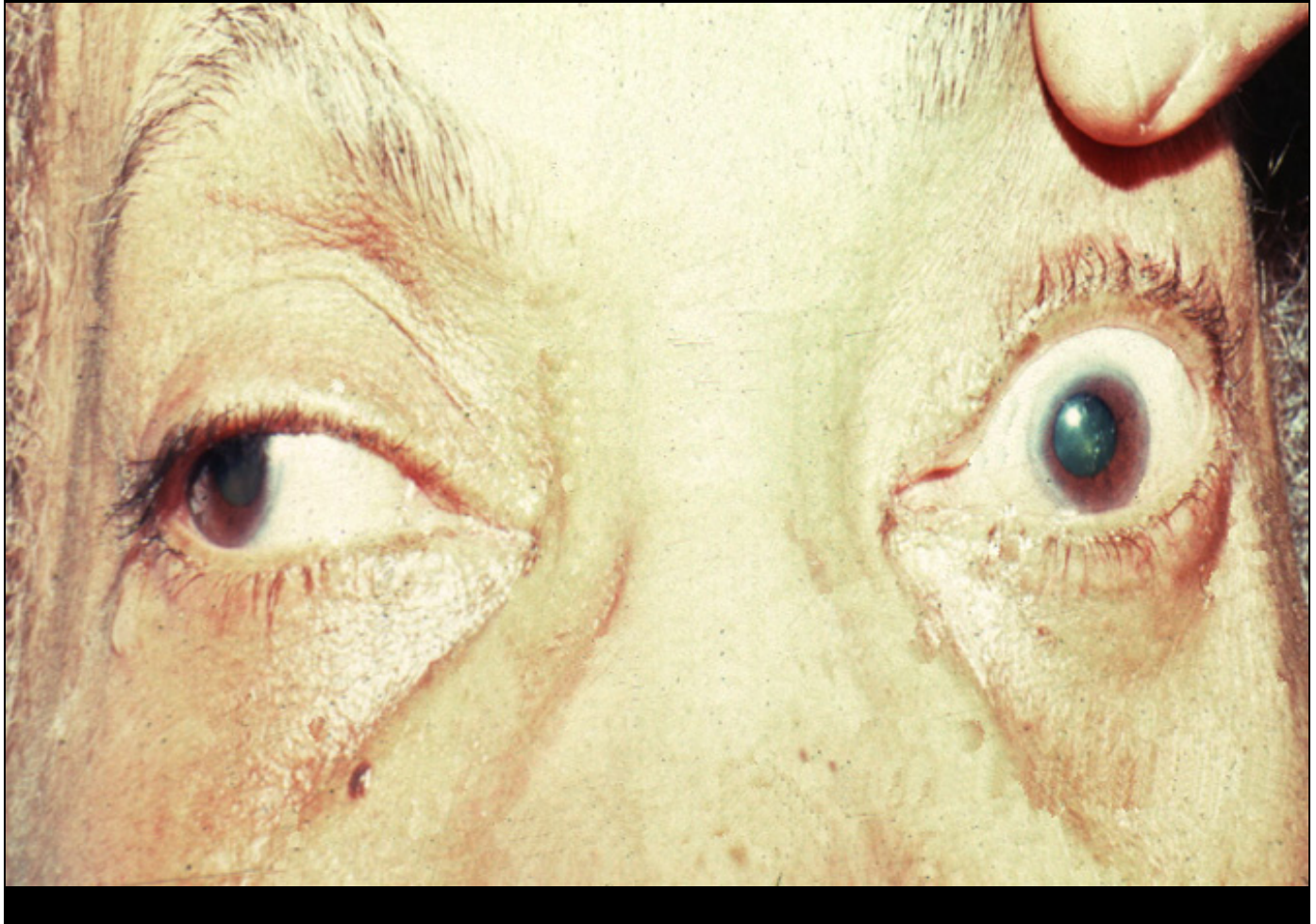

© Copyright [Oculisti OnLine](#)

EyeAtlas

The online Atlas of Ophthalmology

Proptosis caused by arterial aneurysma

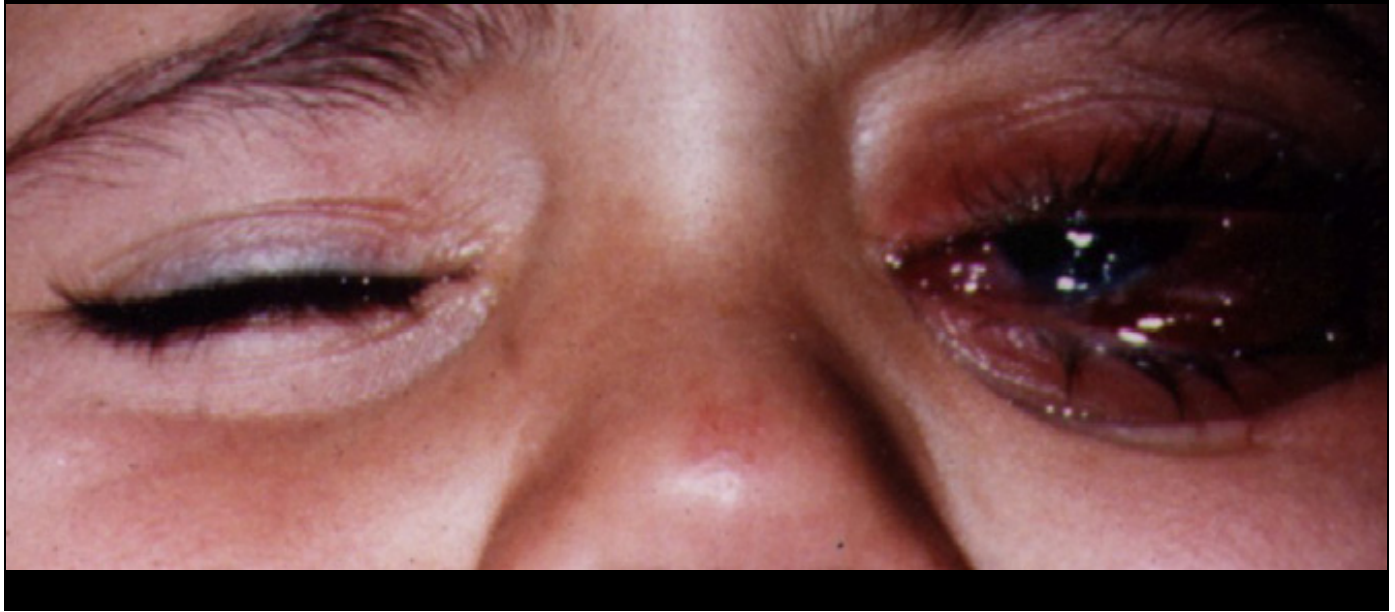

© Copyright [Oculisti OnLine](#)

EyeAtlas

The online Atlas of Ophthalmology

Proptosis caused by leukaemia

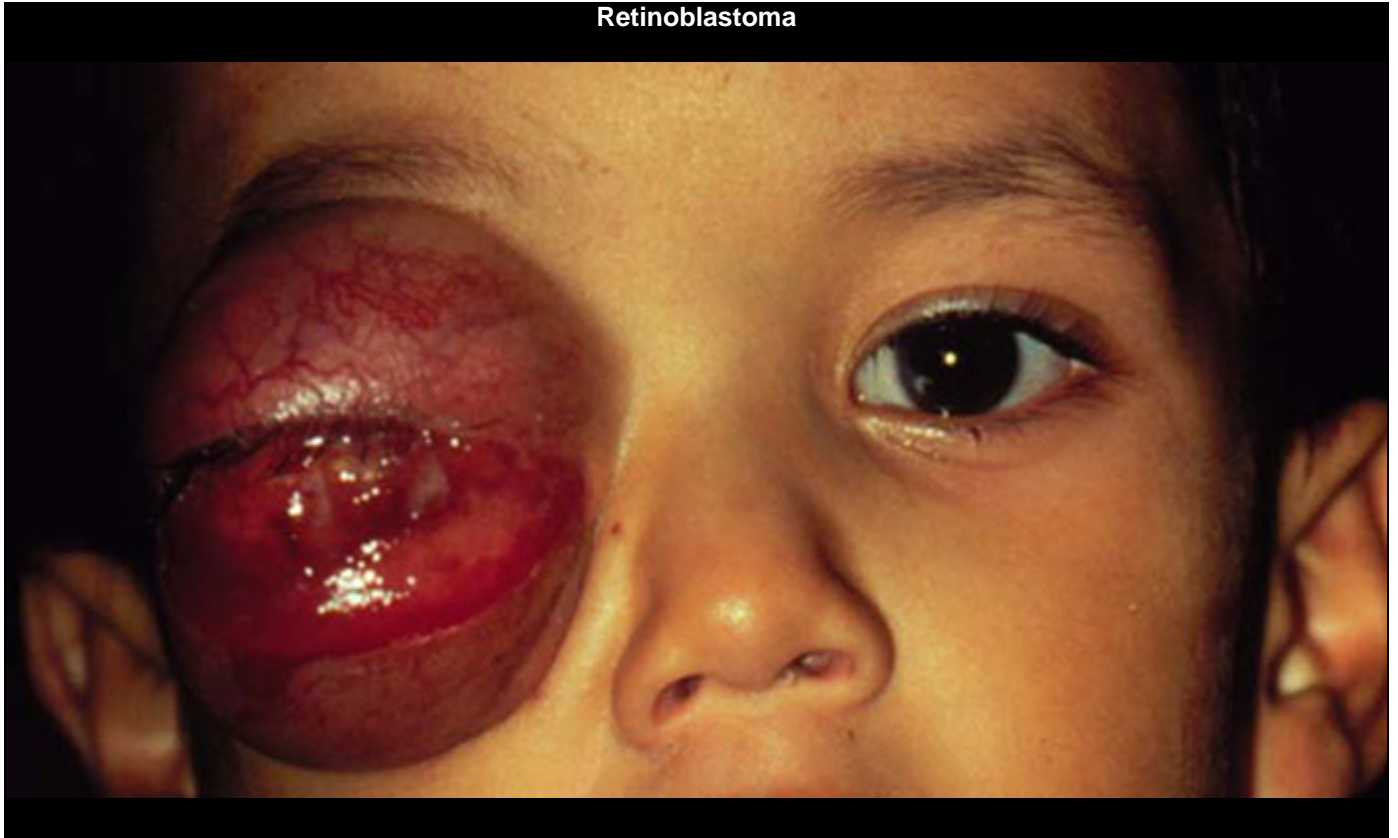

© Copyright [Oculisti OnLine](#)

EyeAtlas

The online Atlas of Ophthalmology

Retinoblastoma

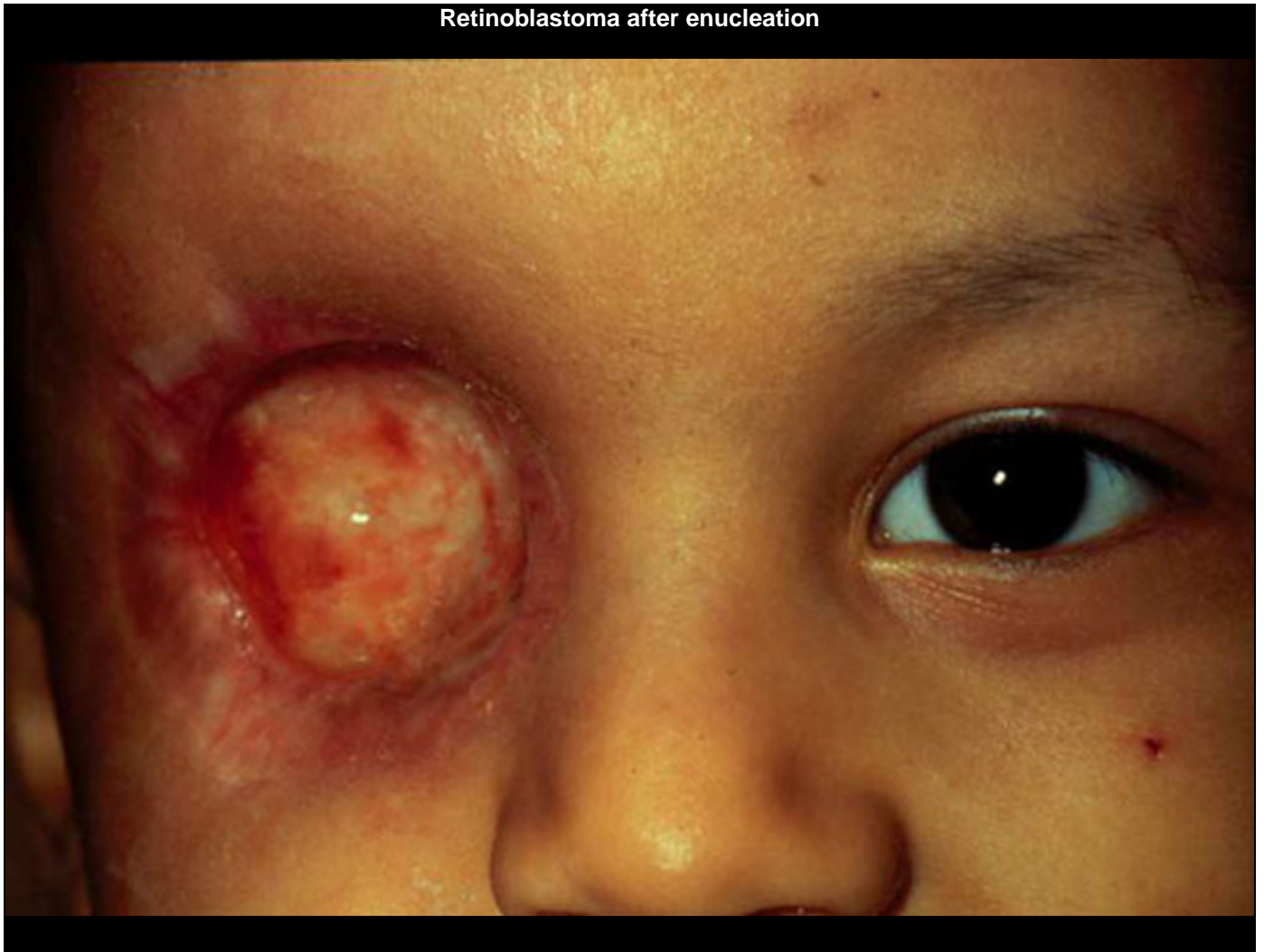

© Copyright [Oculisti OnLine](#)

EyeAtlas

The online Atlas of Ophthalmology

Retinoblastoma after enucleation

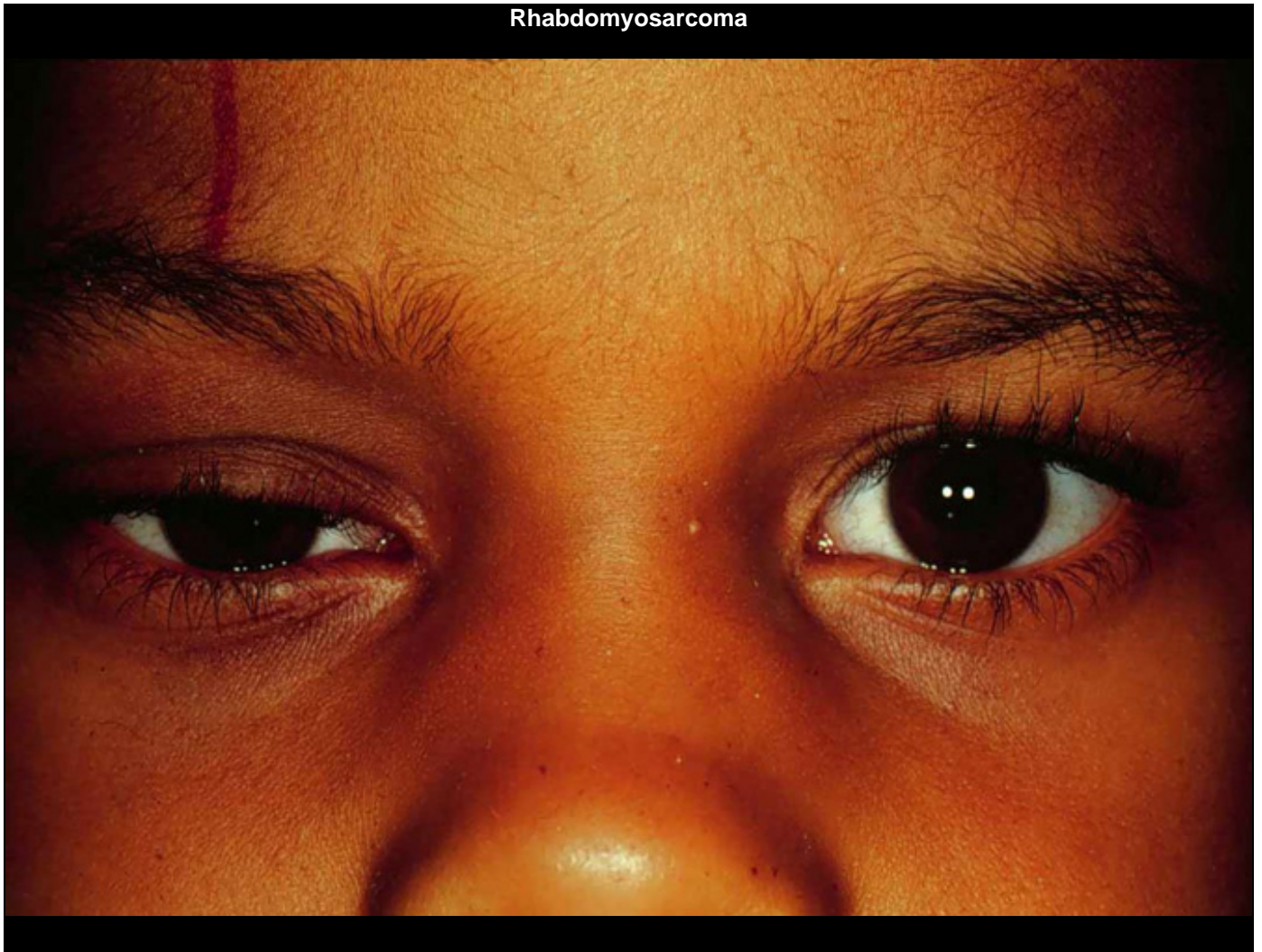

© Copyright [Oculisti OnLine](#)

EyeAtlas

The online Atlas of Ophthalmology

Rhabdomyosarcoma




© Copyright [Oculisti OnLine](#)

EyeAtlas

The online Atlas of Ophthalmology

Rhabdomyosarcoma

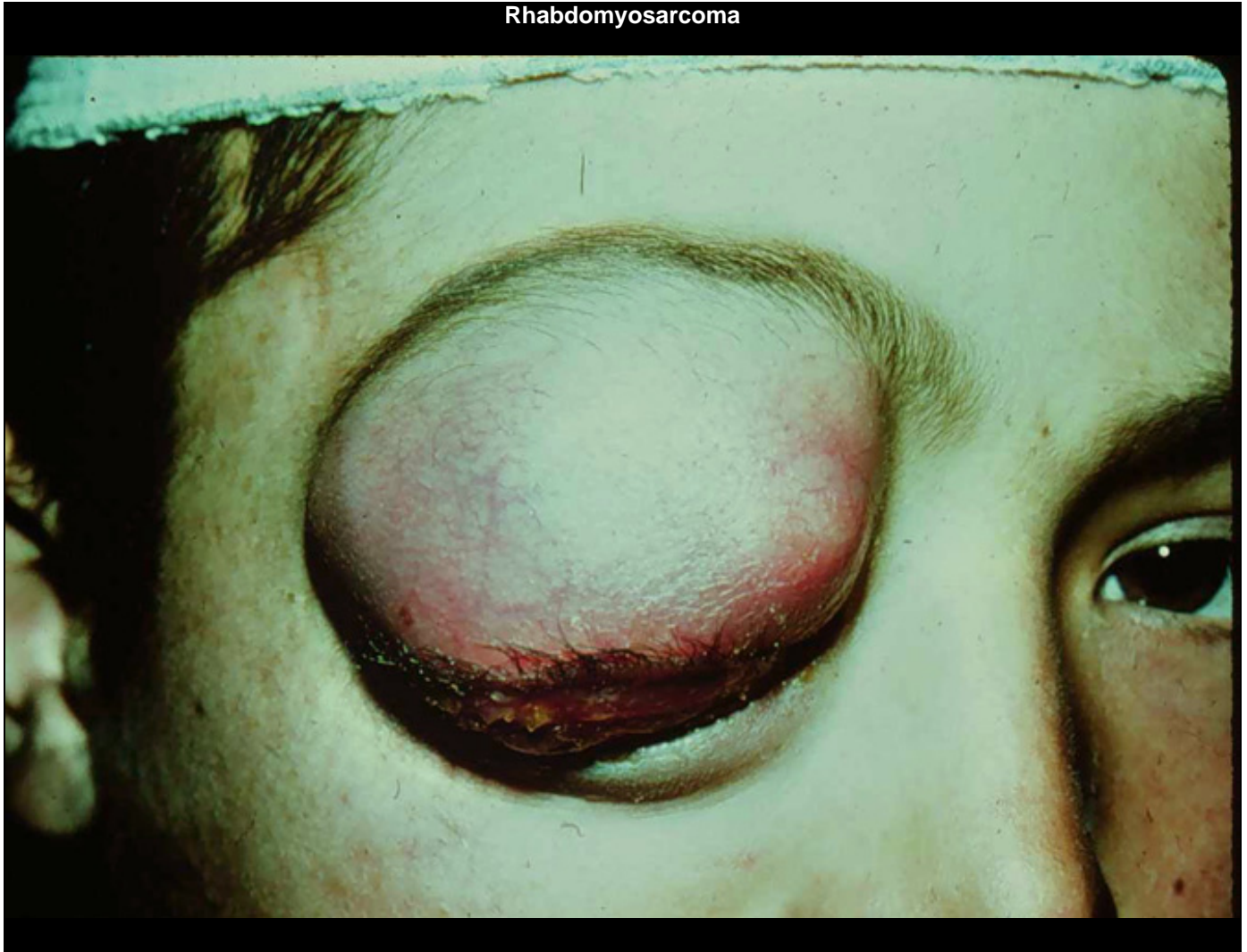

© Copyright [Oculisti OnLine](#)

EyeAtlas

The online Atlas of Ophthalmology

Rhabdomyosarcoma

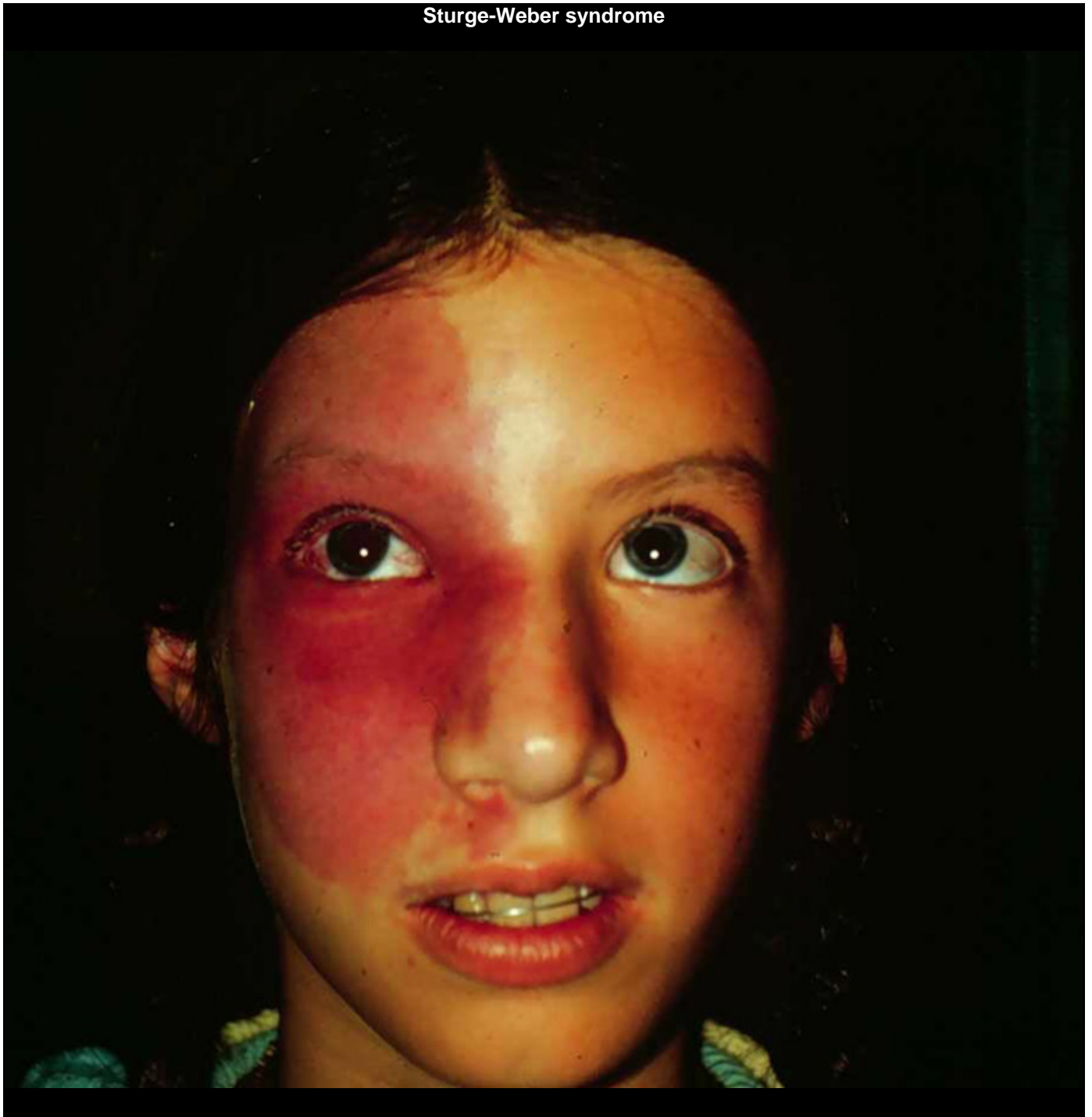


© Copyright [Oculisti OnLine](http://www.eyeatlas.com)

EyeAtlas

The online Atlas of Ophthalmology

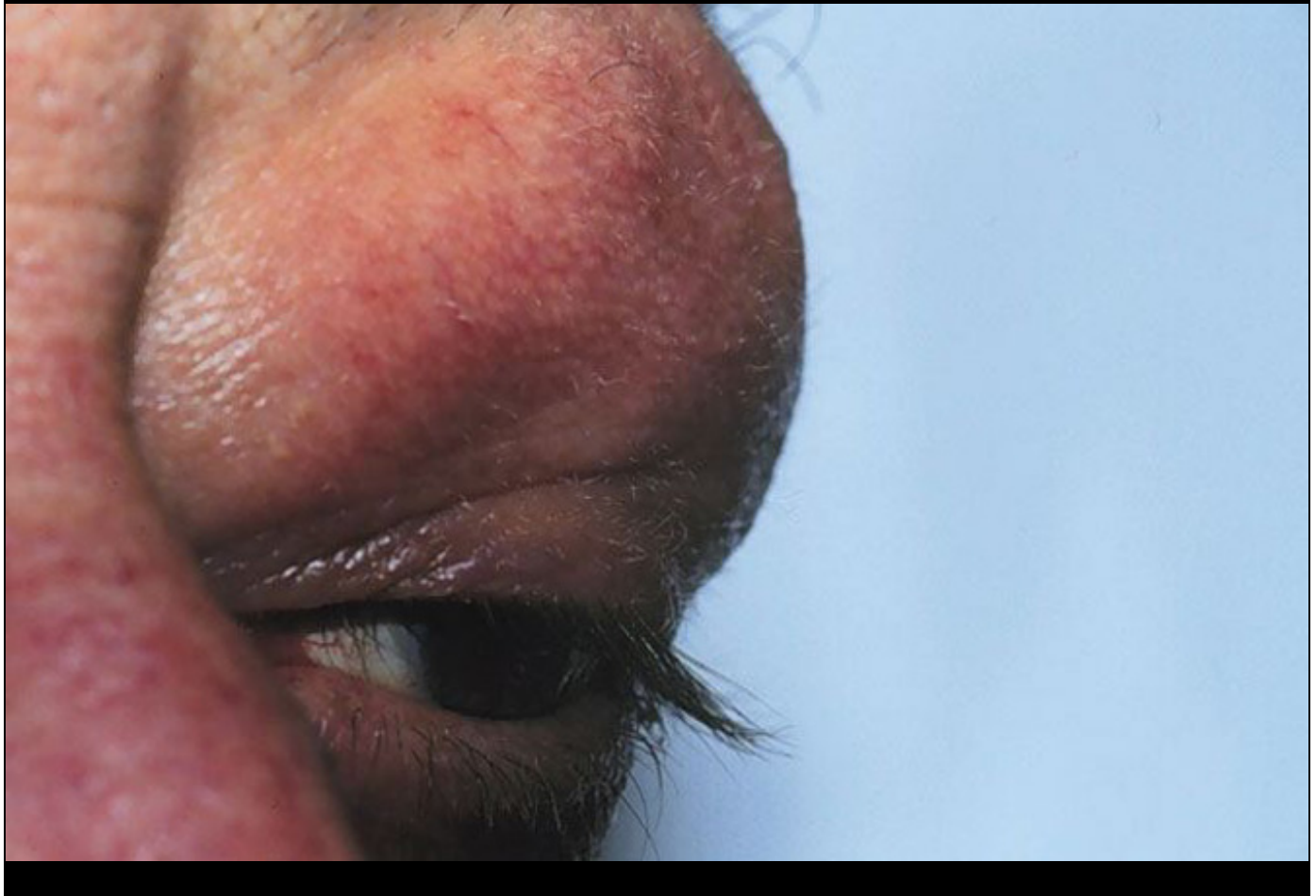Sturge-Weber syndrome



EyeAtlas

The online Atlas of Ophthalmology

Lacrimal gland tumor

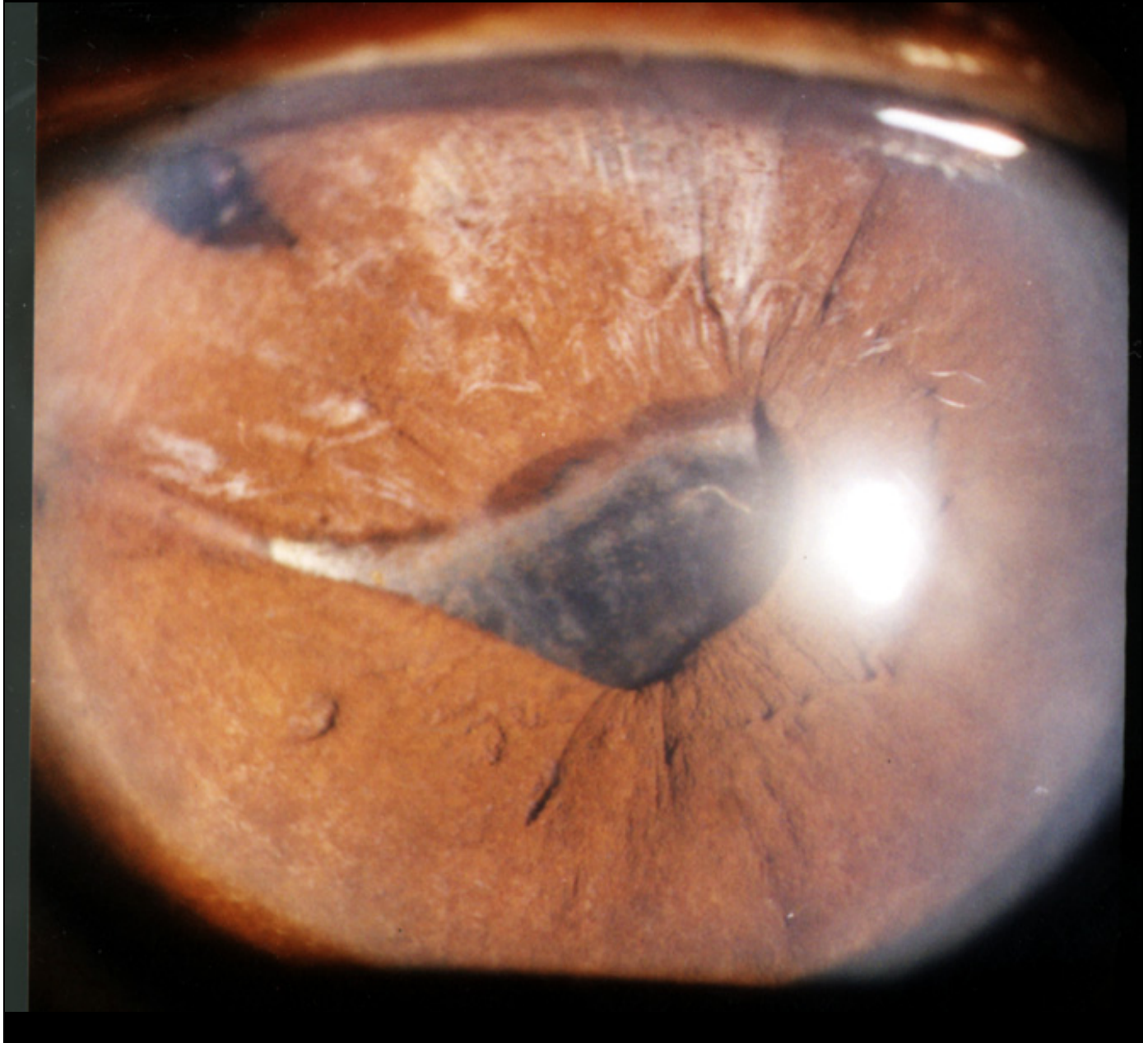

© Copyright [Oculisti OnLine](#)

EyeAtlas

The online Atlas of Ophthalmology

Pupillary block after cataract surgery

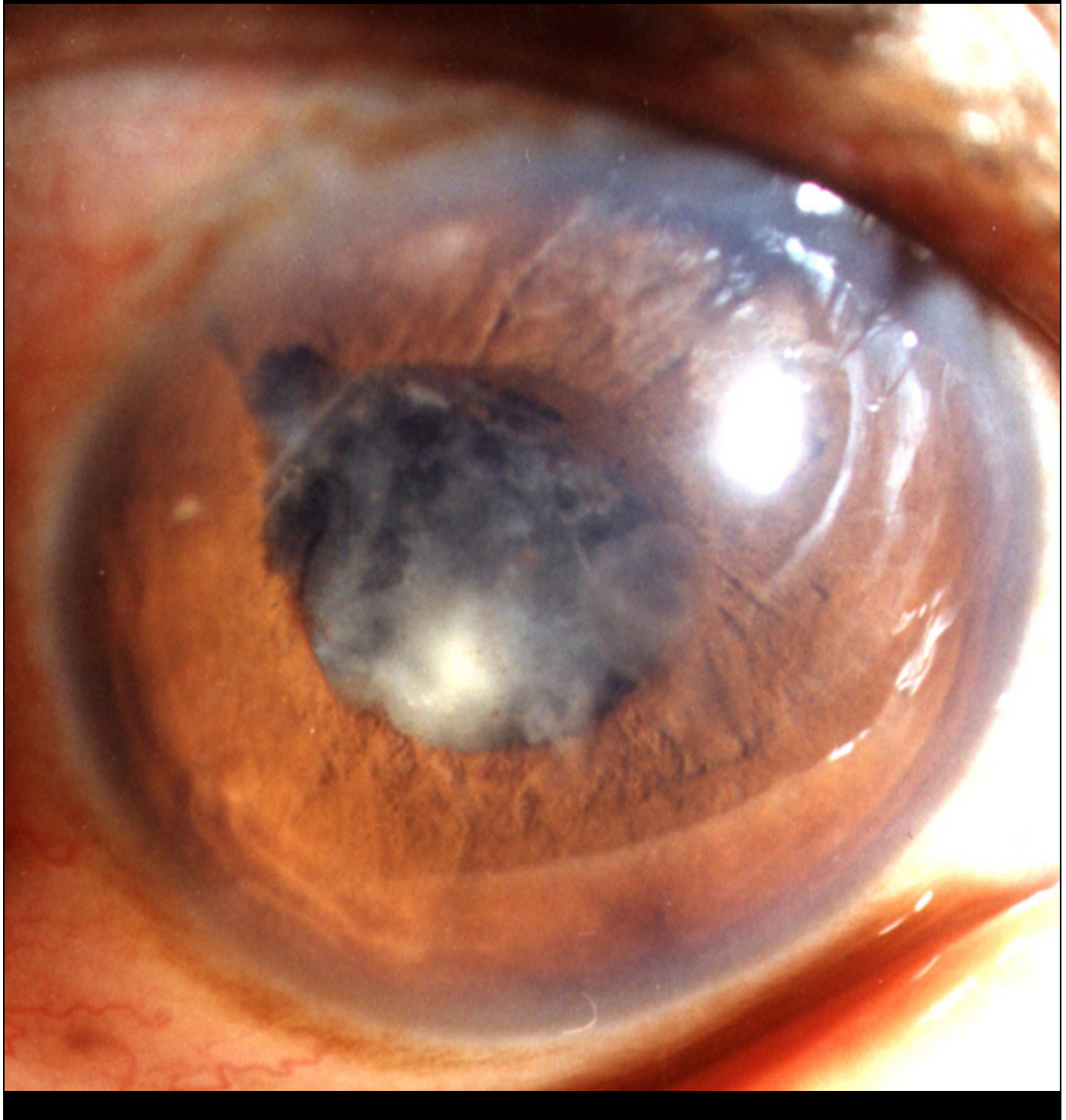


© Copyright [Oculisti OnLine](http://www.eyeatlas.com)

Eyeatlas

The online Atlas of Ophthalmology

Pupillary block after cataract surgery

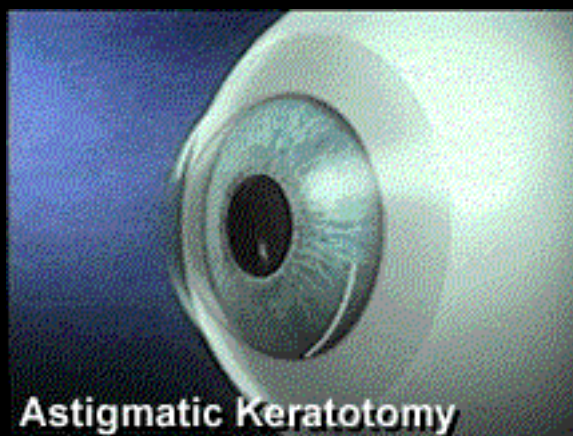


© Copyright [Oculisti OnLine](#)

EyeAtlas

The online Atlas of Ophthalmology

Astigmatic keratotomy (animation)

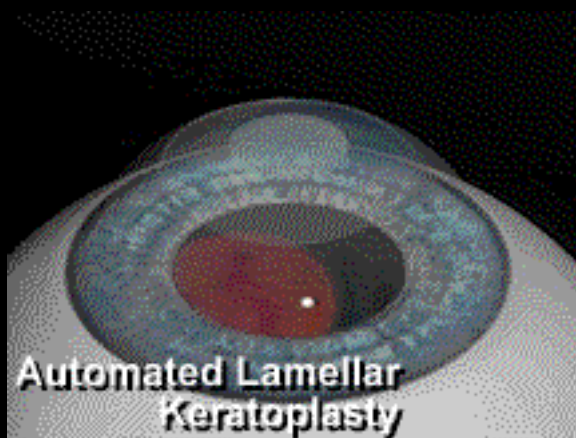


© Copyright [Oculisti OnLine](#)

Eyeatlas

The online Atlas of Ophthalmology

Automated Lamellar Keratoplasty (animation)

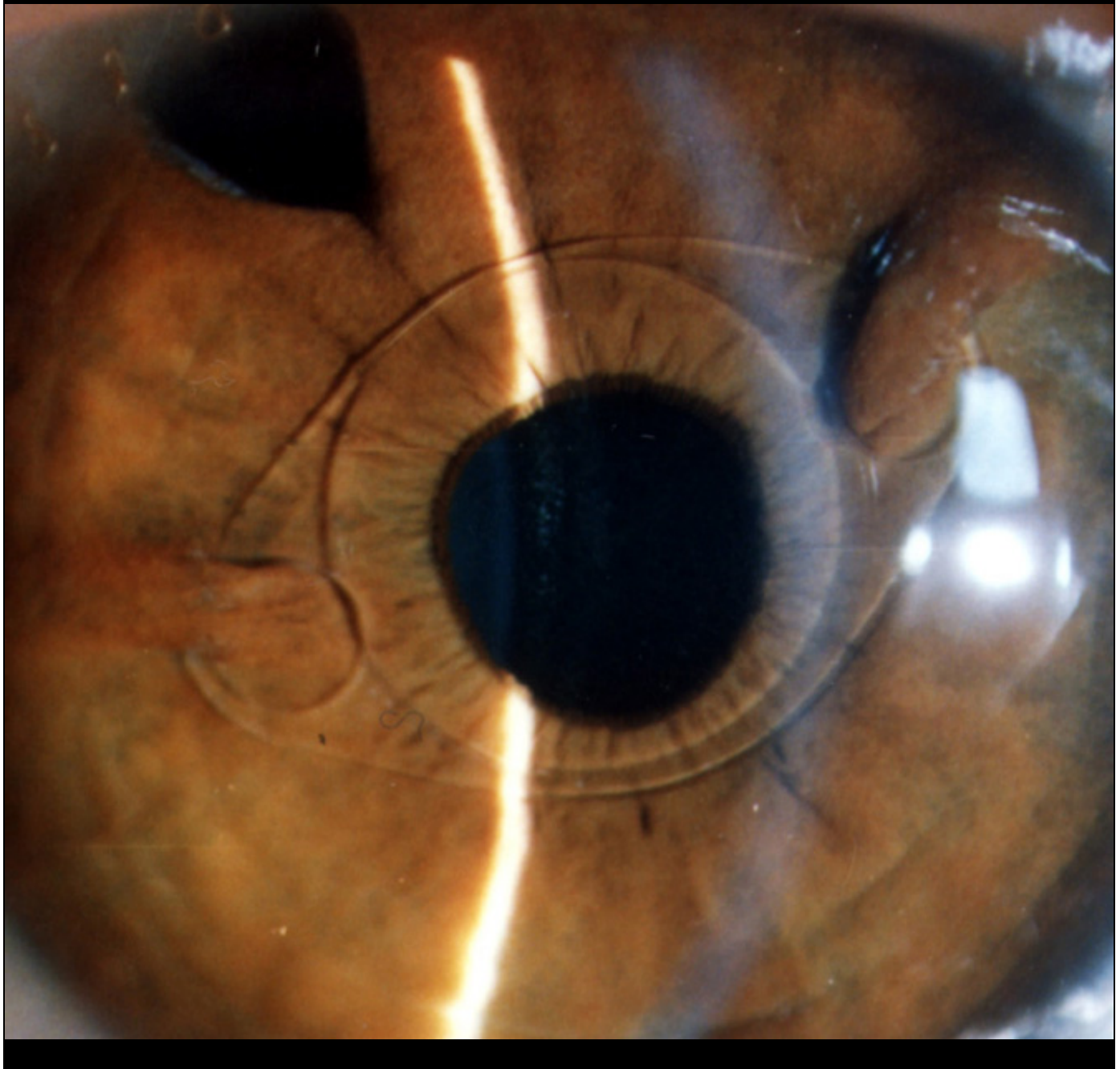


© Copyright [Oculisti OnLine](#)

Eyeatlas

The online Atlas of Ophthalmology

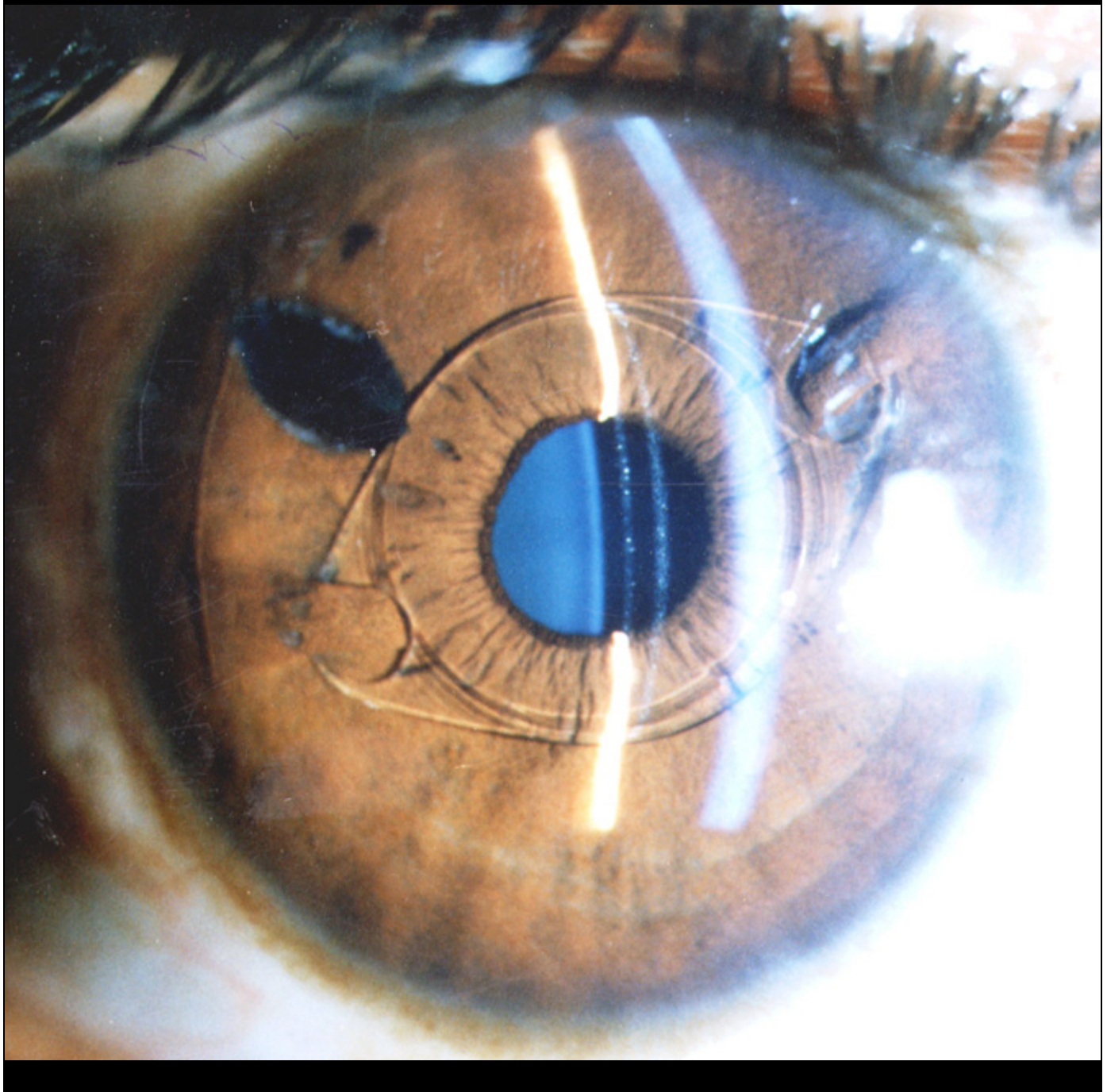
Anterior chamber IOL for hyperopia correction



Eyeatlas

The online Atlas of Ophthalmology

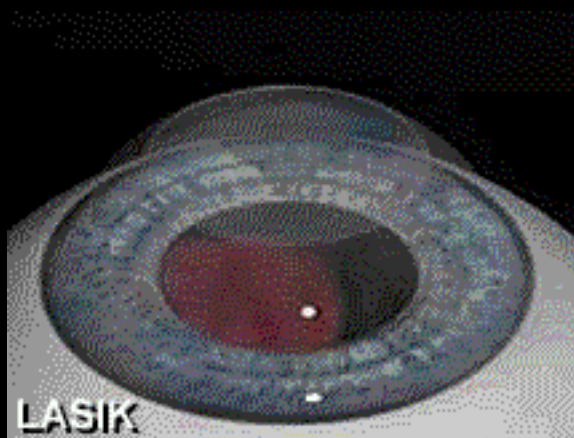
Intraocular lens to correct hyperopia



Eyeatlas

The online Atlas of Ophthalmology

Lasik surgery (animation)

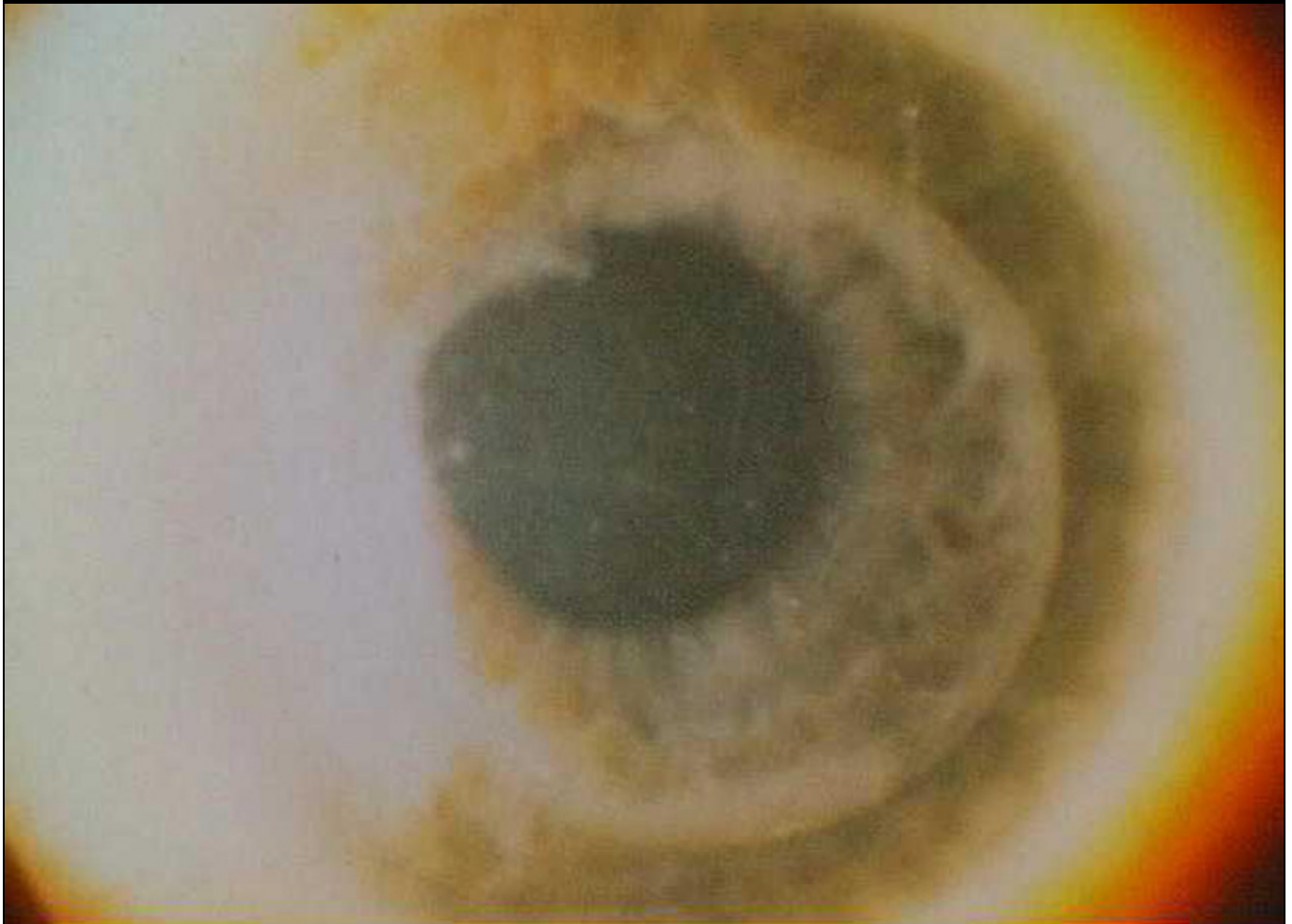


© Copyright [Oculisti OnLine](#)

EyeAtlas

The online Atlas of Ophthalmology

Decentered flap after LASIK



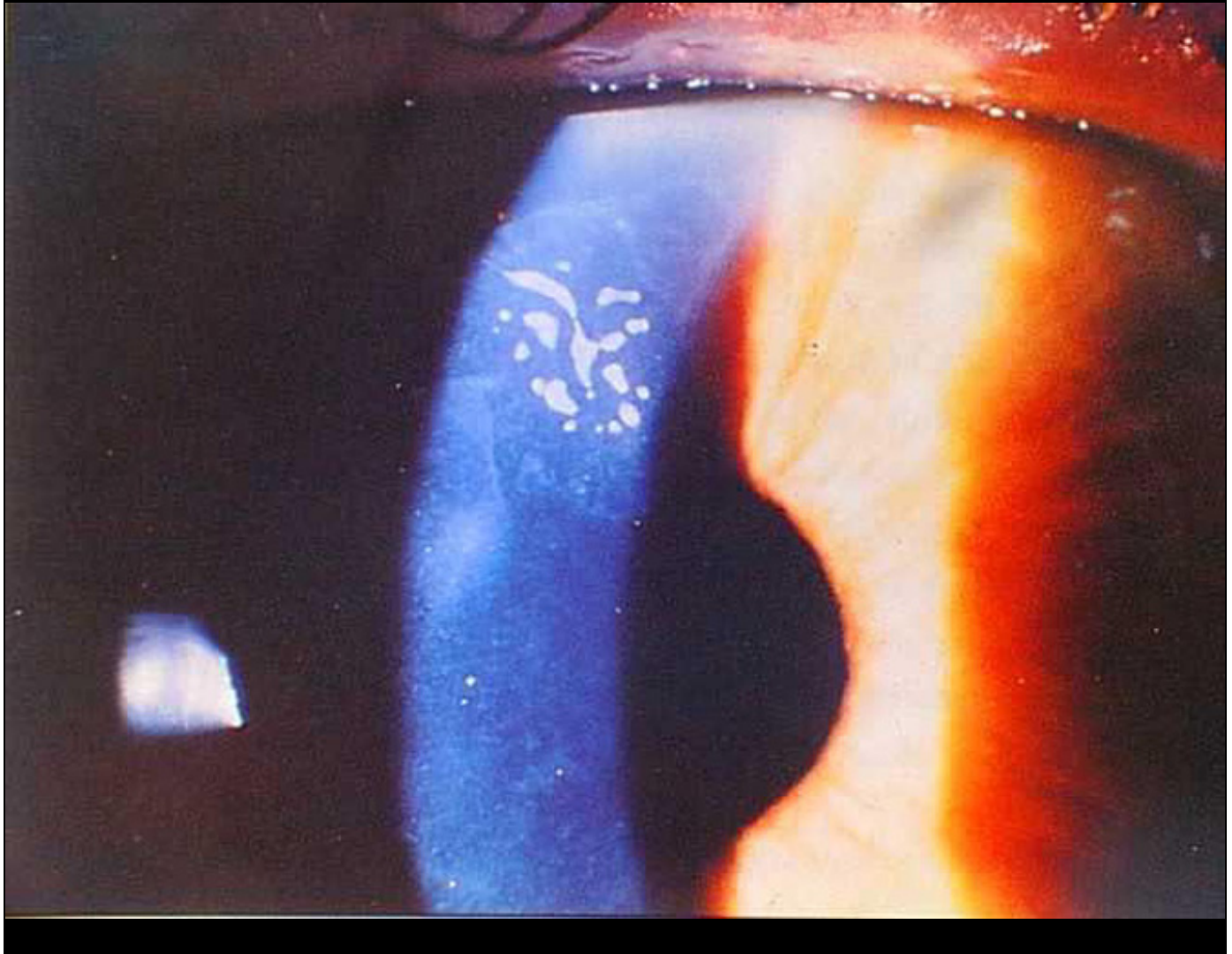


© Copyright Oculisti OnLine

EyeAtlas

The online Atlas of Ophthalmology

Epithelial ingrowth after LASIK

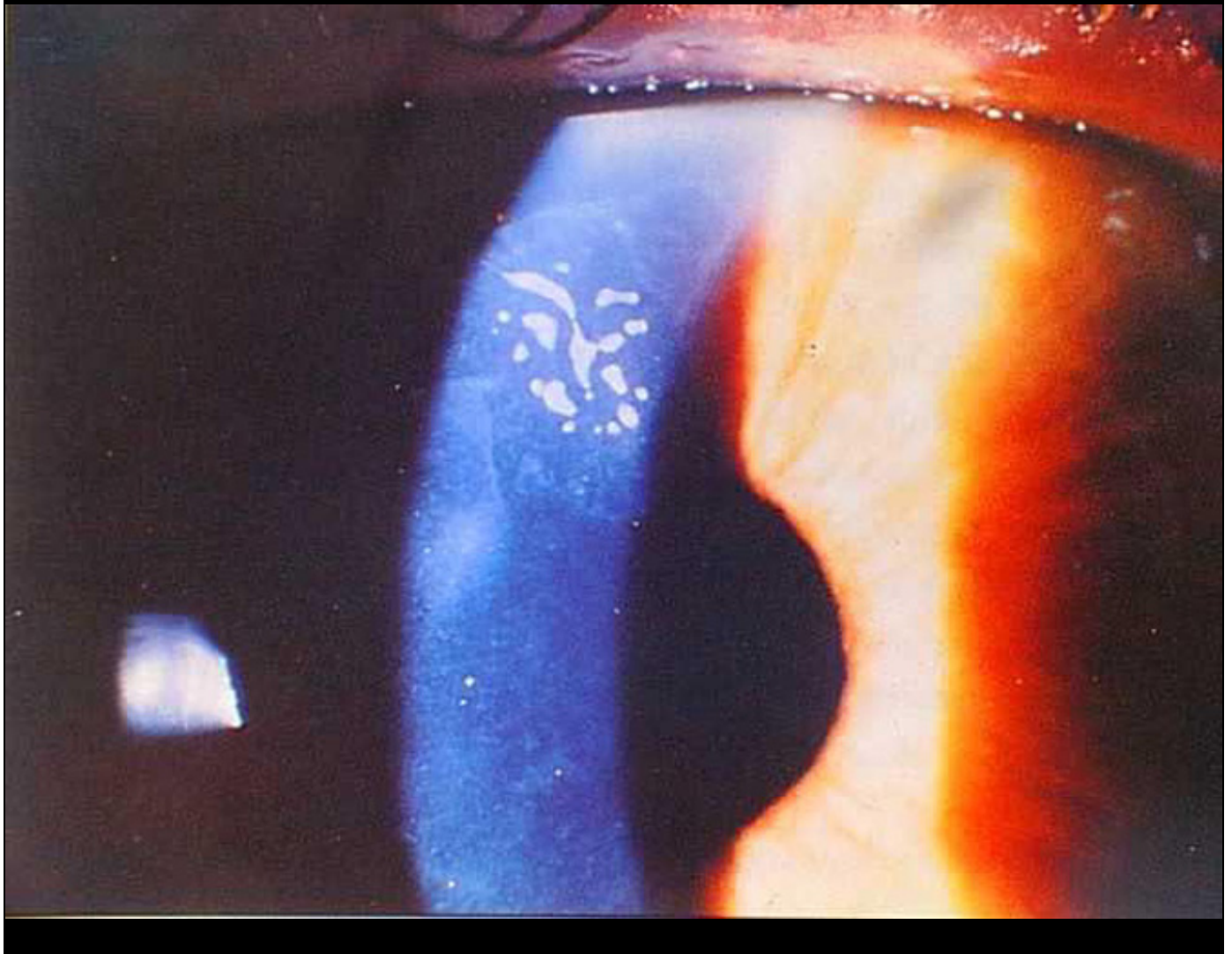


© Copyright [Oculisti OnLine](http://www.eyeatlas.com)

EyeAtlas

The online Atlas of Ophthalmology

Keratitis after LASIK

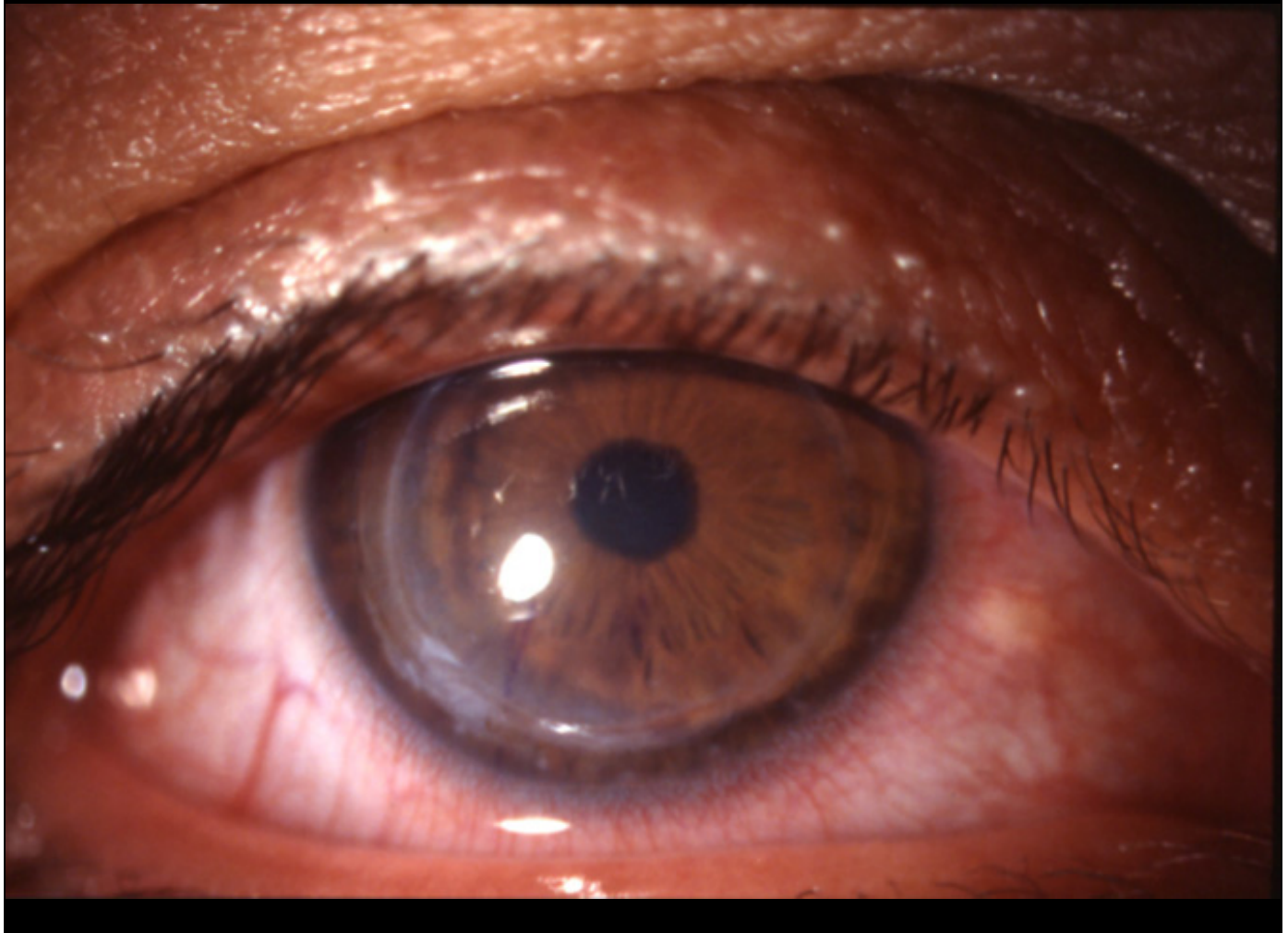


© Copyright [Oculisti OnLine](http://www.eyeatlas.com)

EyeAtlas

The online Atlas of Ophthalmology

LASIK after keratoplasty

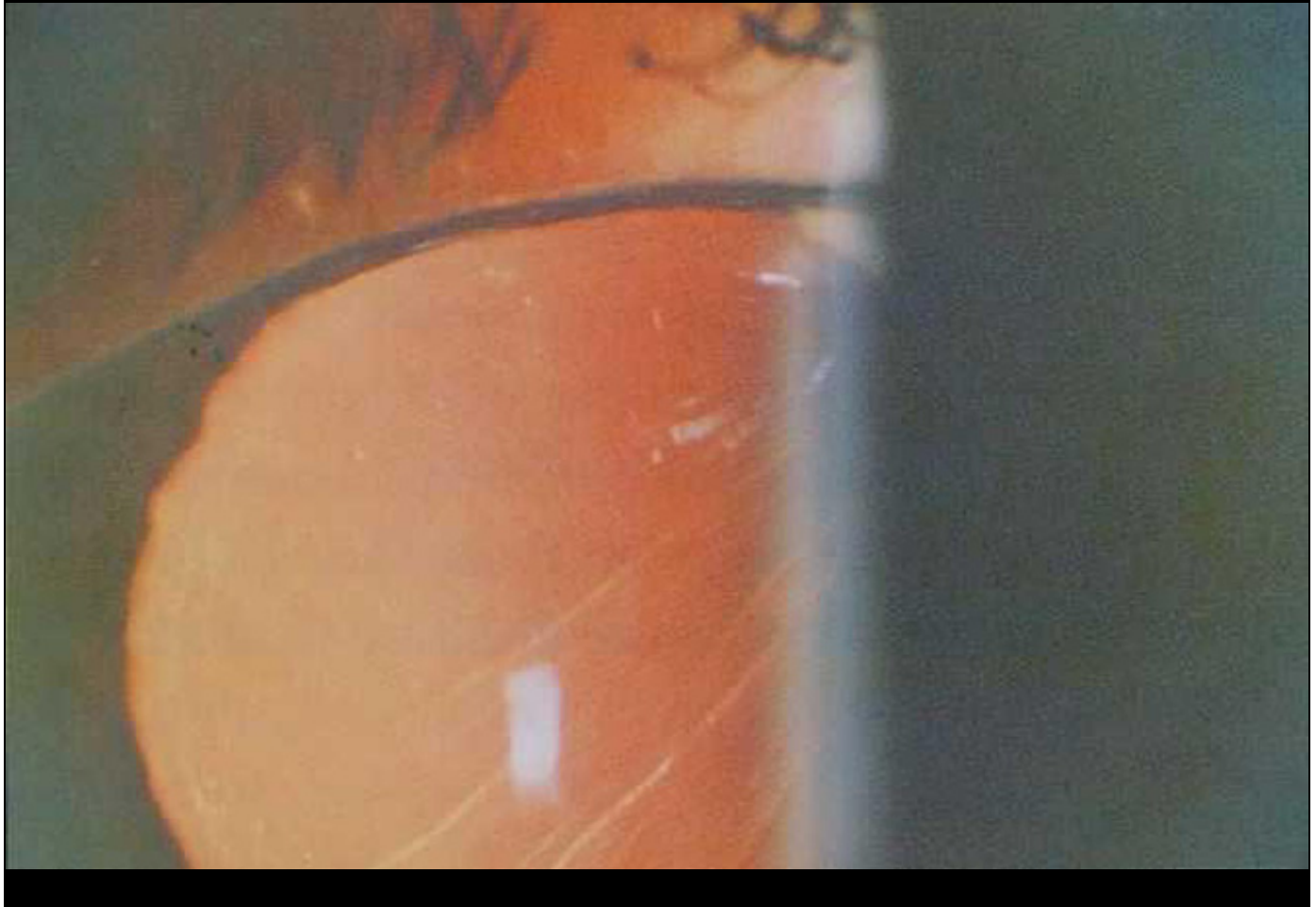


© Copyright [Oculisti OnLine](#)

Eyeatlas

The online Atlas of Ophthalmology

Striae after LASIK

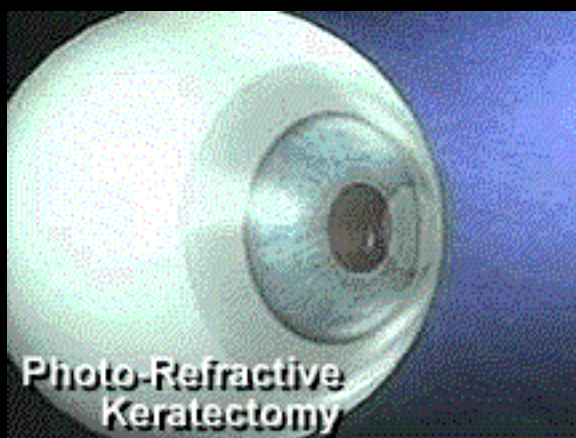


© Copyright [Oculisti OnLine](http://www.eyeatlas.com)

Eyeatlas

The online Atlas of Ophthalmology

PRK surgery (animation)

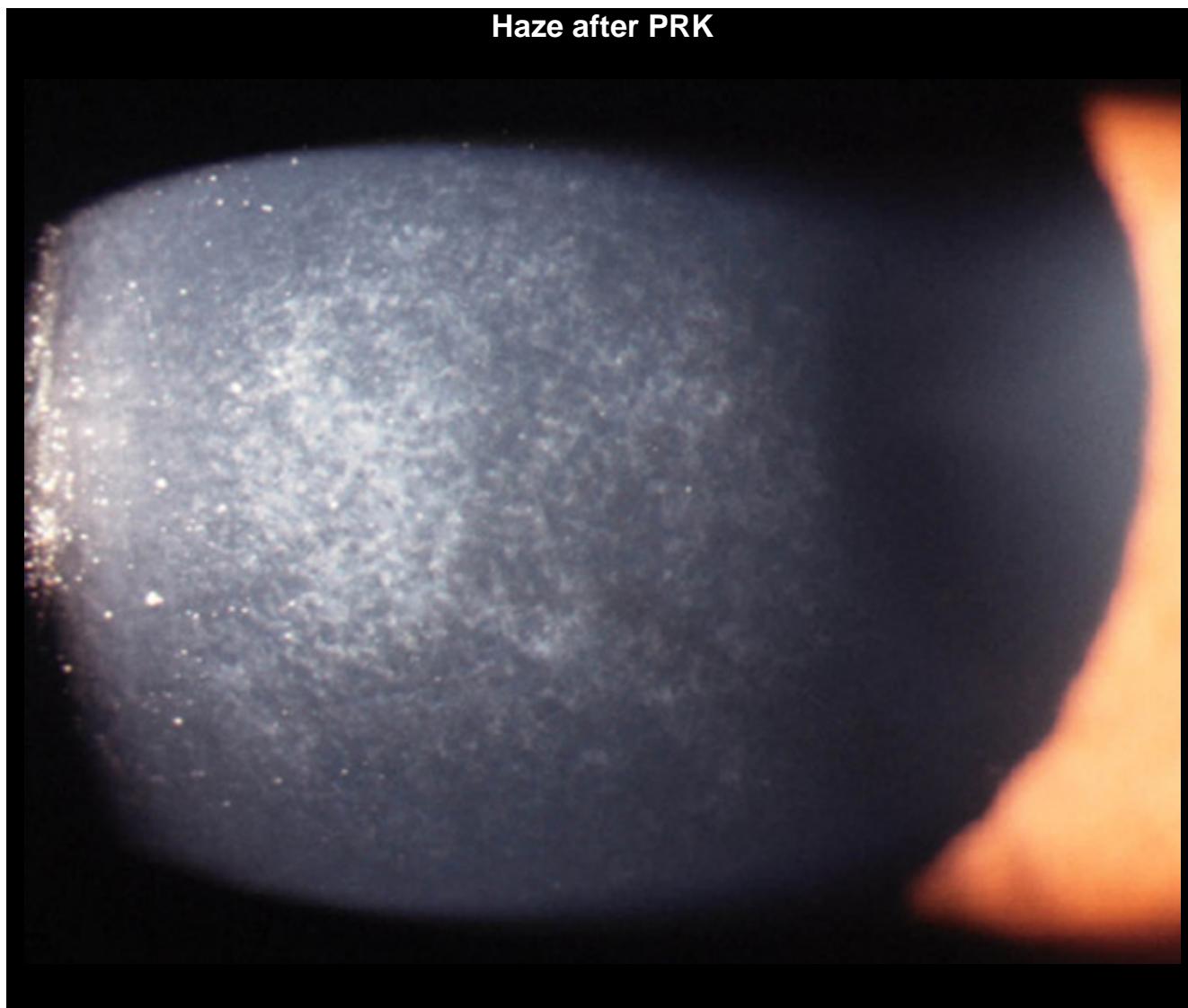


© Copyright [Oculisti OnLine](#)

Eyeatlas

The online Atlas of Ophthalmology

Haze after PRK

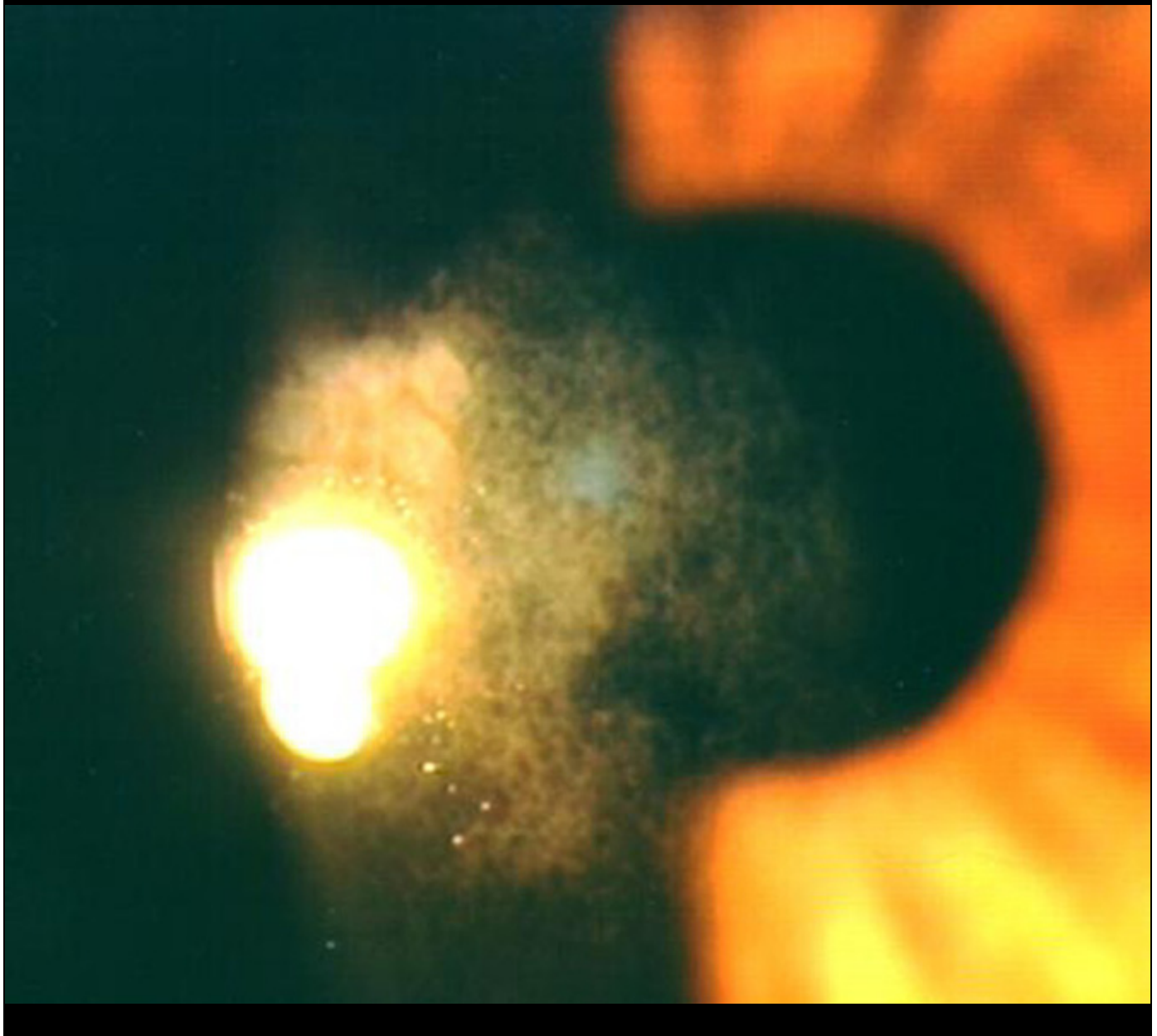

© Copyright [Oculisti OnLine](#)

EyeAtlas

The online Atlas of Ophthalmology

Haze after PRK

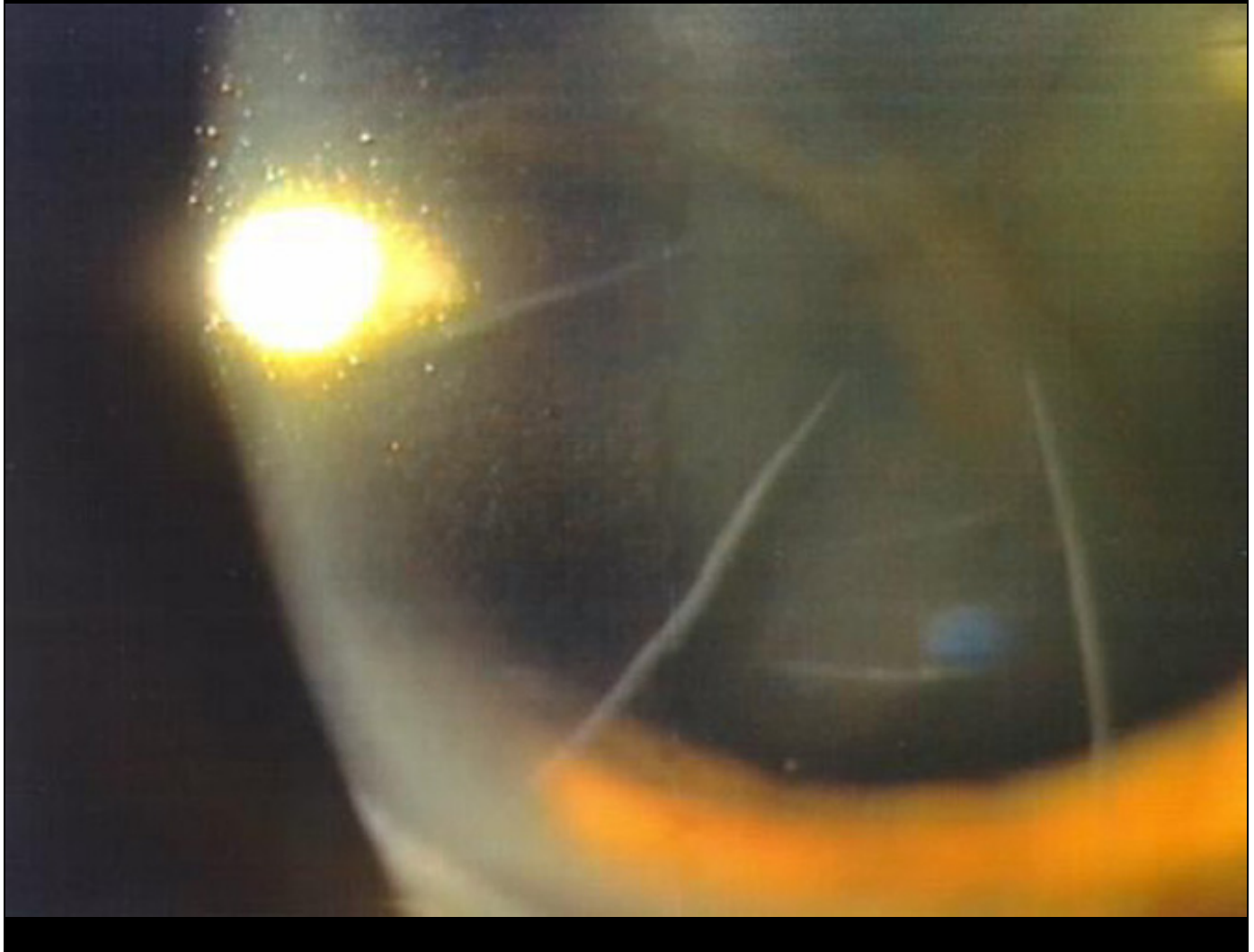


© Copyright [Oculisti OnLine](http://www.eyeatlas.com)

Eyeatlas

The online Atlas of Ophthalmology

Radial keratotomy

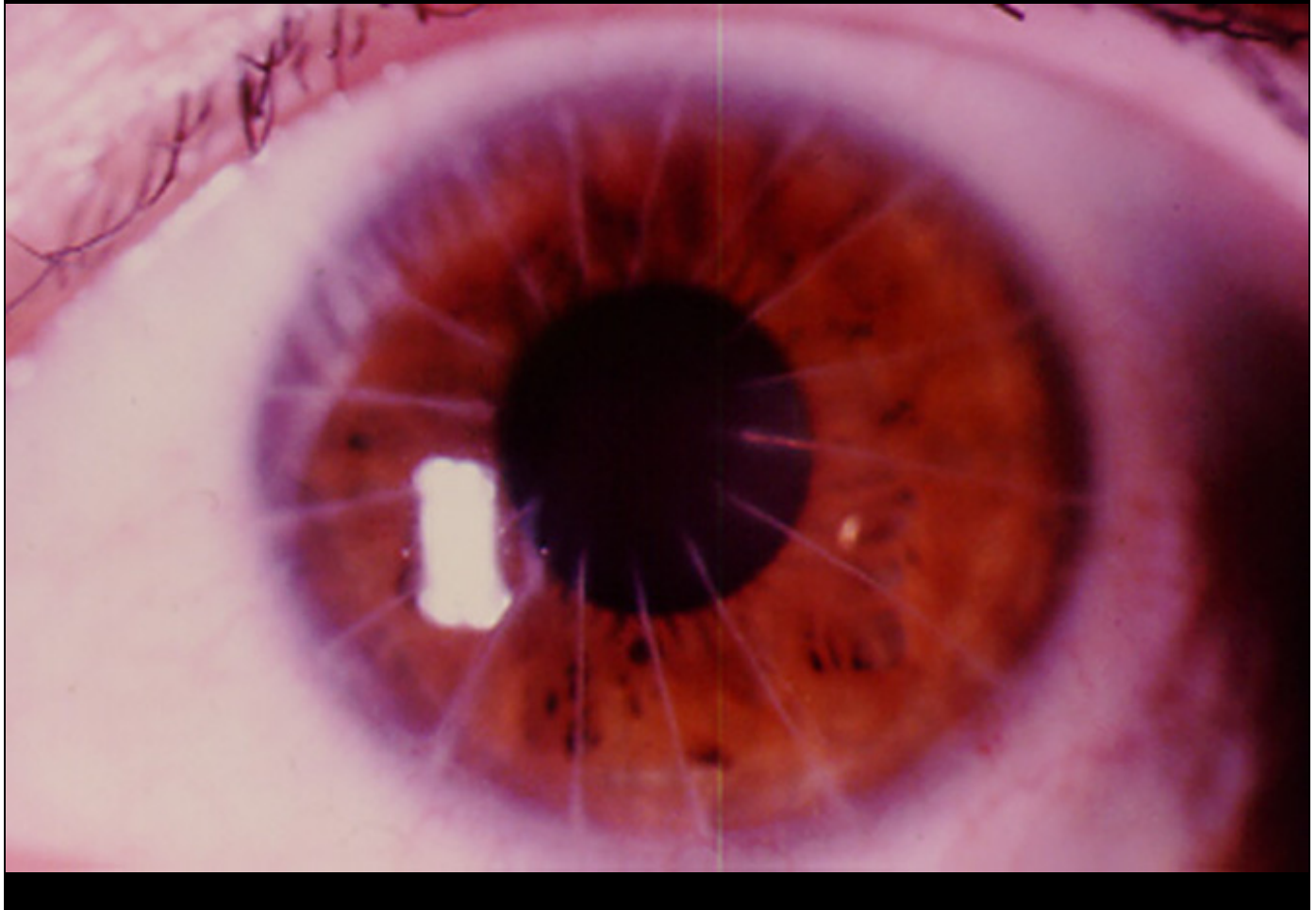


© Copyright [Oculisti OnLine](#)

EyeAtlas

The online Atlas of Ophthalmology

Radial keratotomy

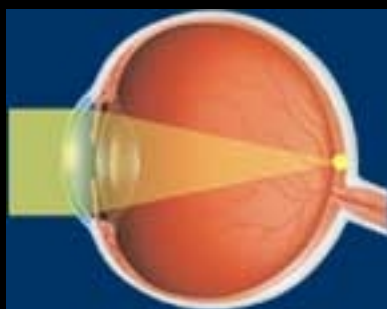


© Copyright [Oculisti OnLine](#)

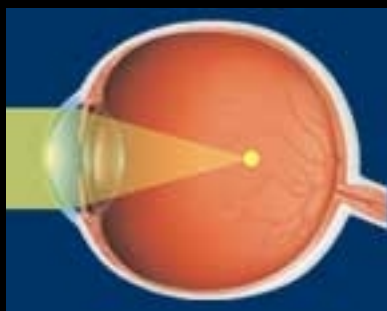
Eyeatlas

The online Atlas of Ophthalmology

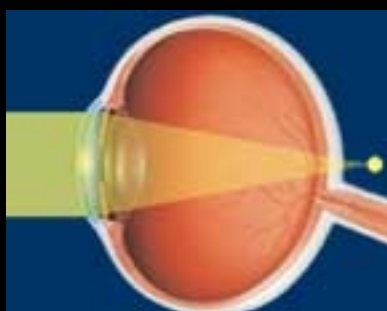
Normal eye



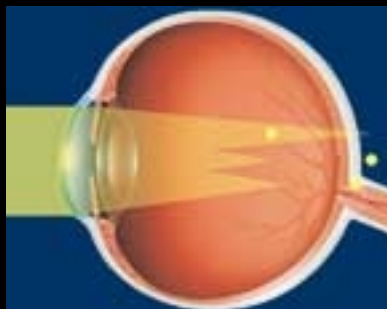
Myopic eye



Hyperopic eye



Astigmatic eye

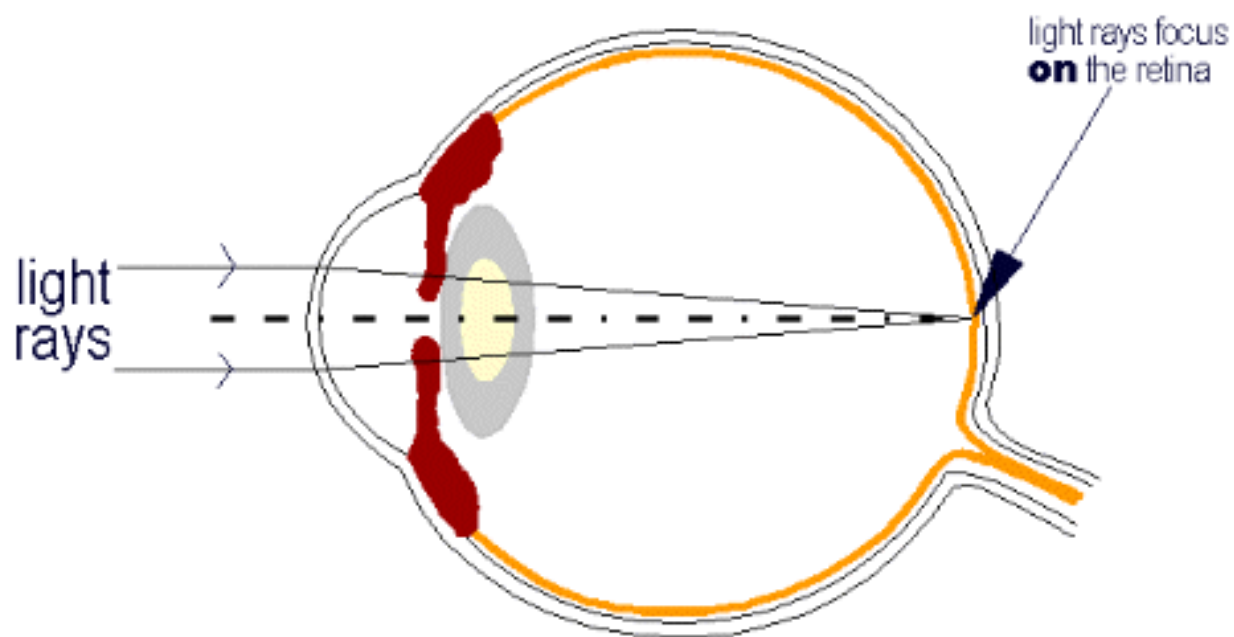


© Copyright [Oculisti OnLine](#)

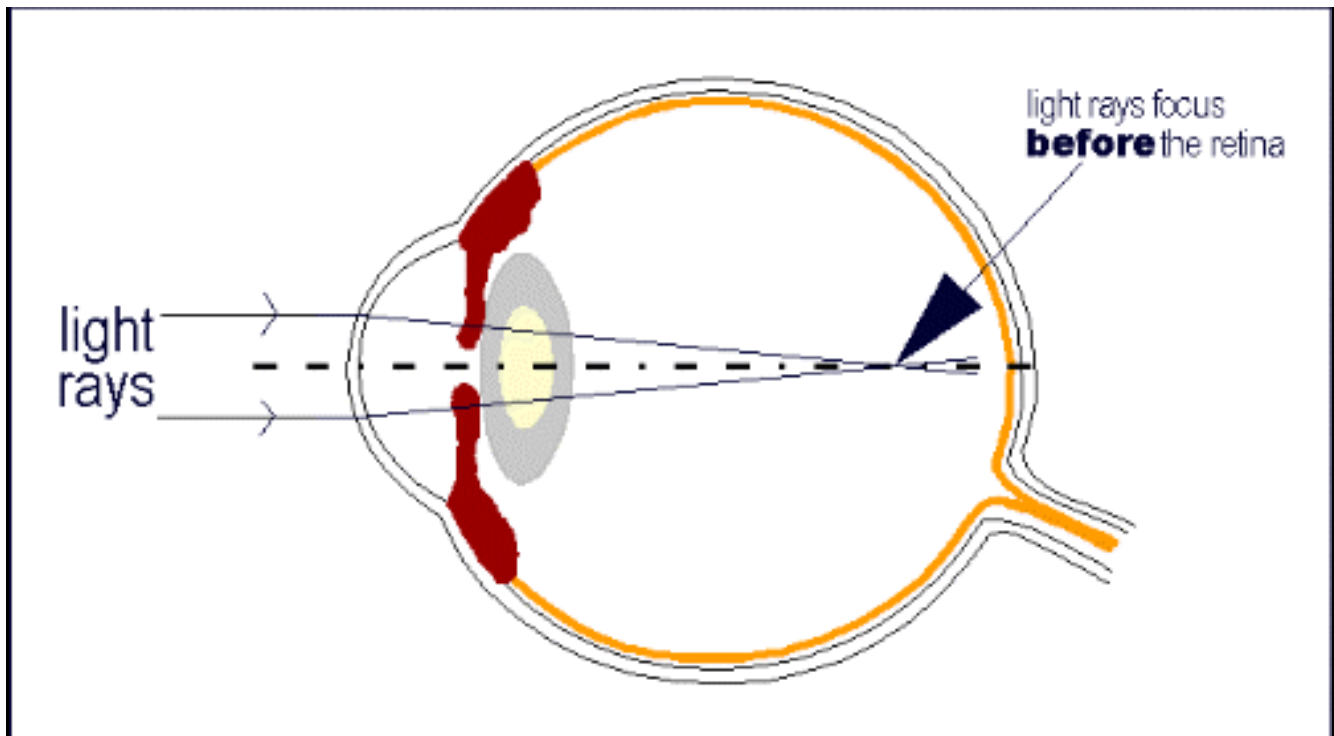
Eyeatlas

The online Atlas of Ophthalmology

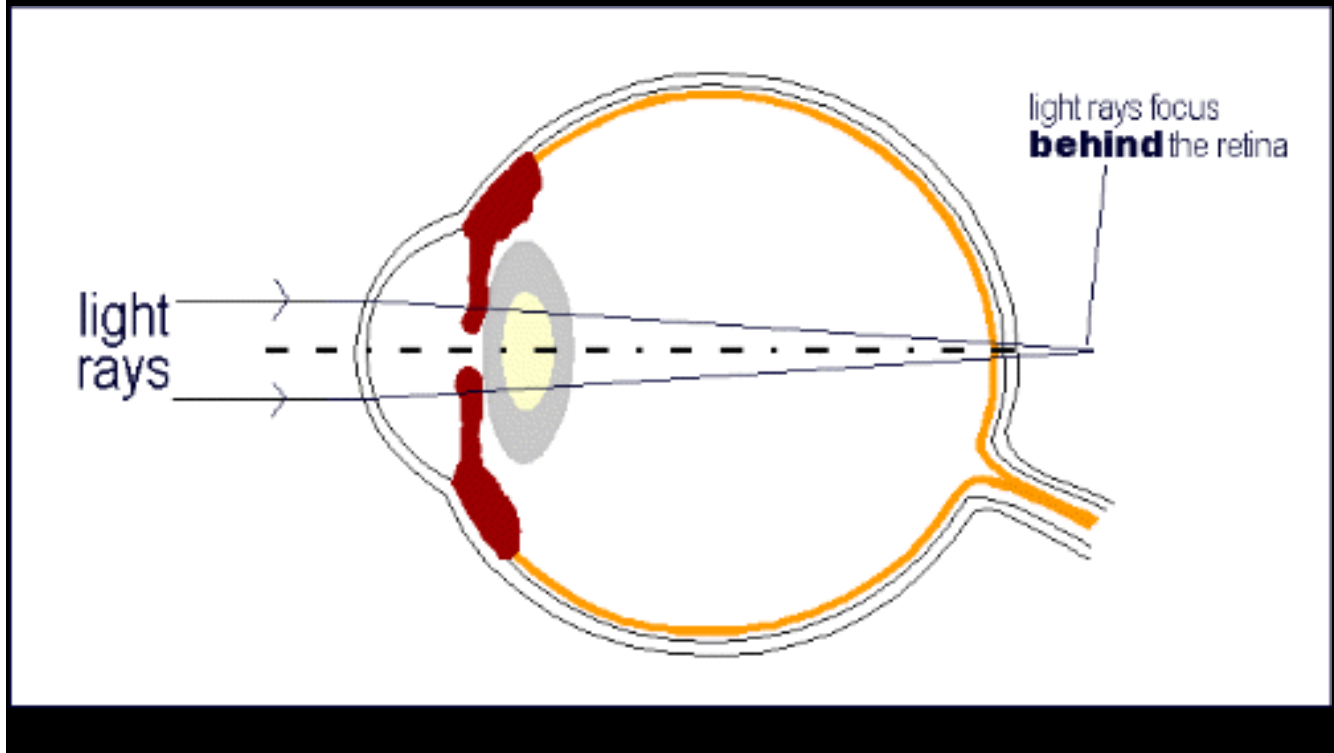
Eye anatomy



Myopia



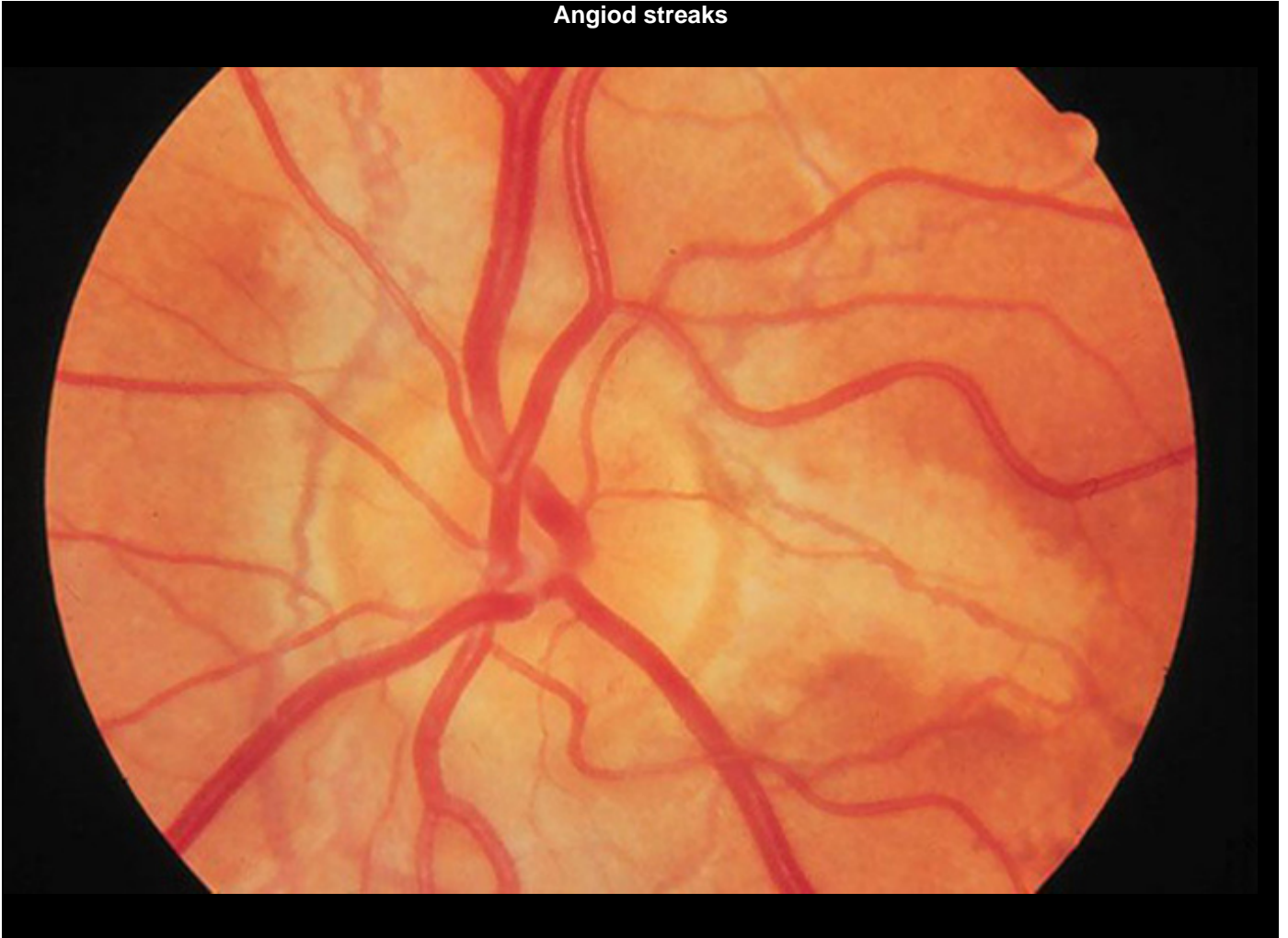
Hyperopia



Eyeatlas

The online Atlas of Ophthalmology

Angiod streaks

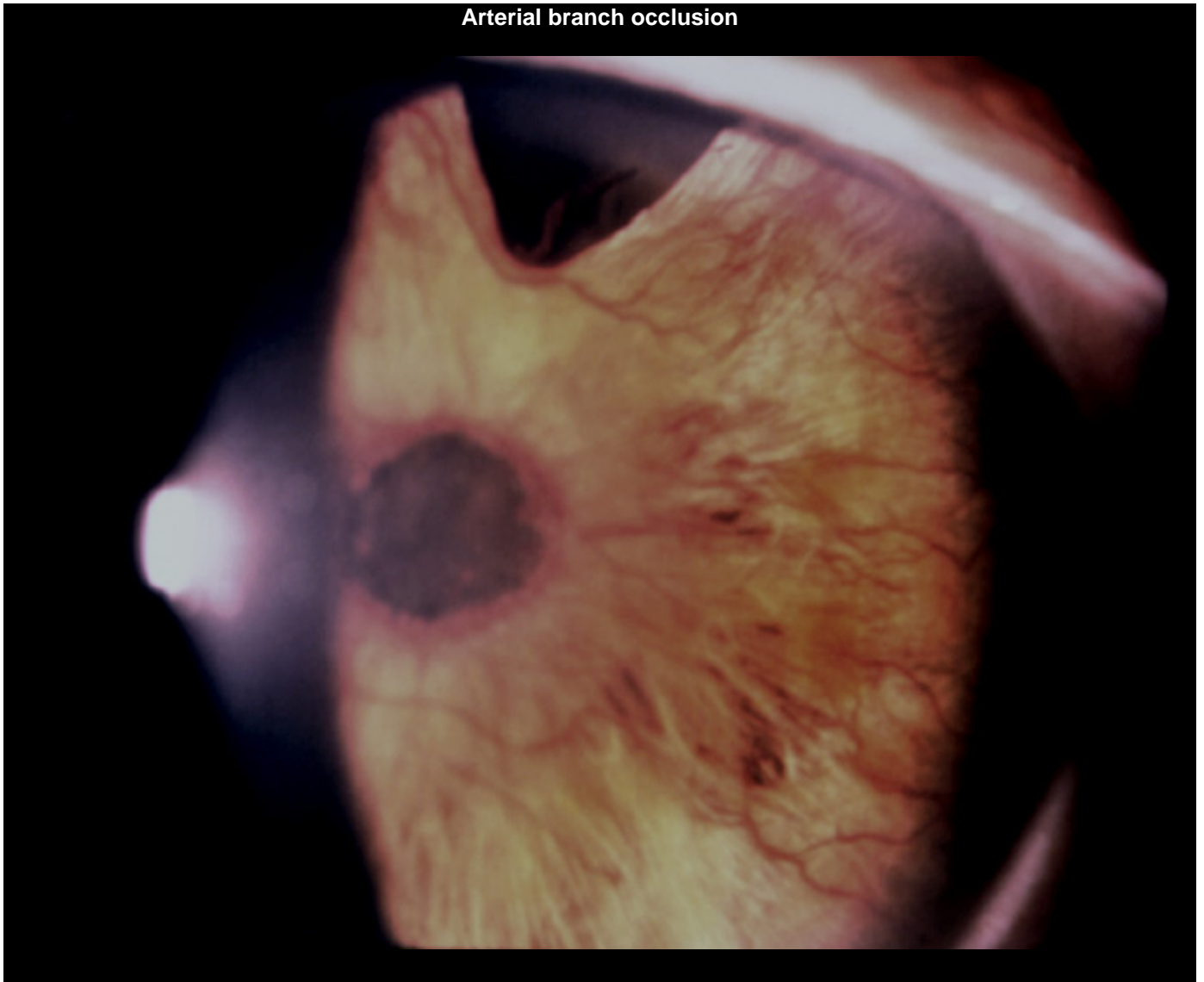


© Copyright [Oculisti OnLine](#)

Eyeatlas

The online Atlas of Ophthalmology

Arterial branch occlusion

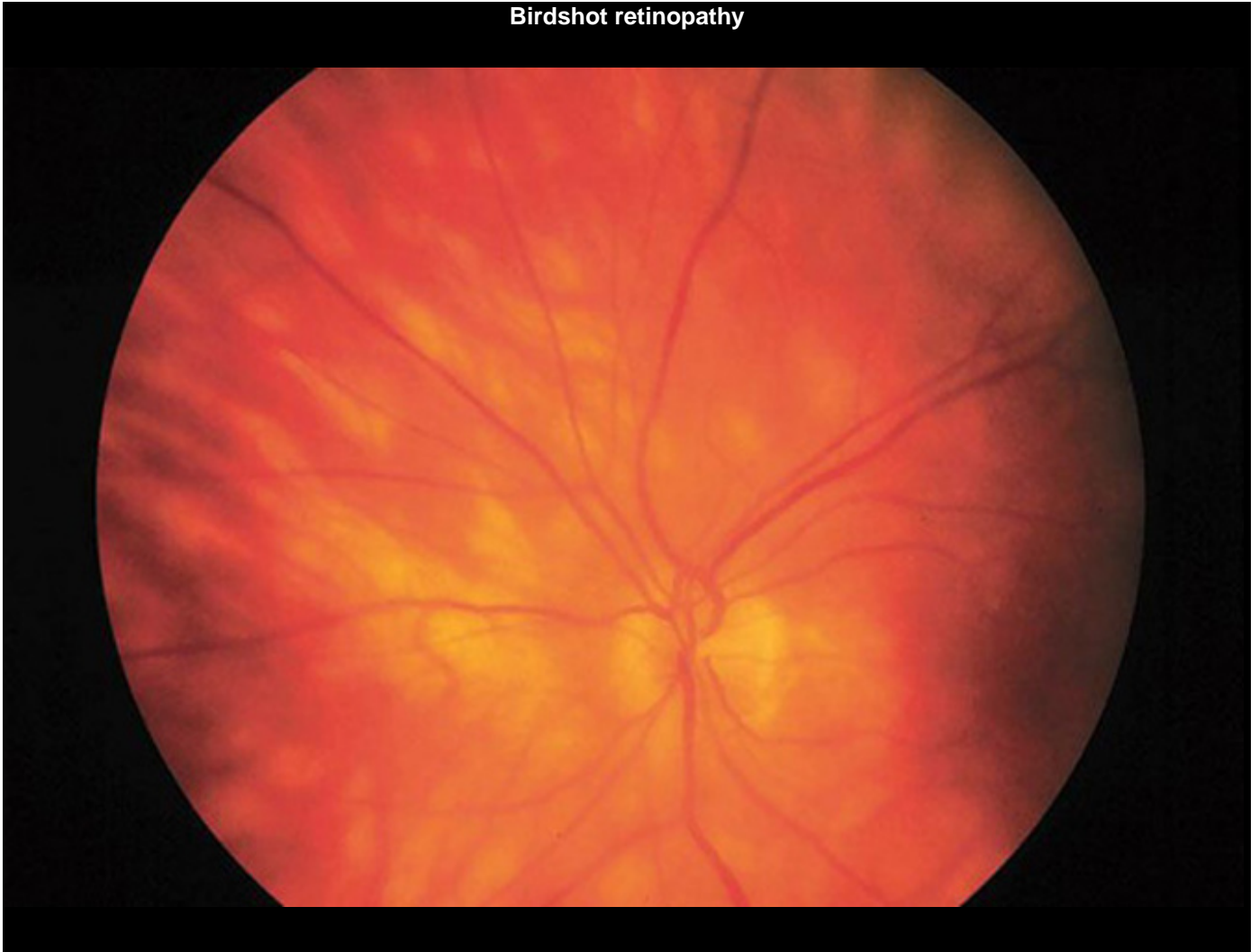

© Copyright [Oculisti OnLine](#)

EyeAtlas

The online Atlas of Ophthalmology

Birdshot retinopathy

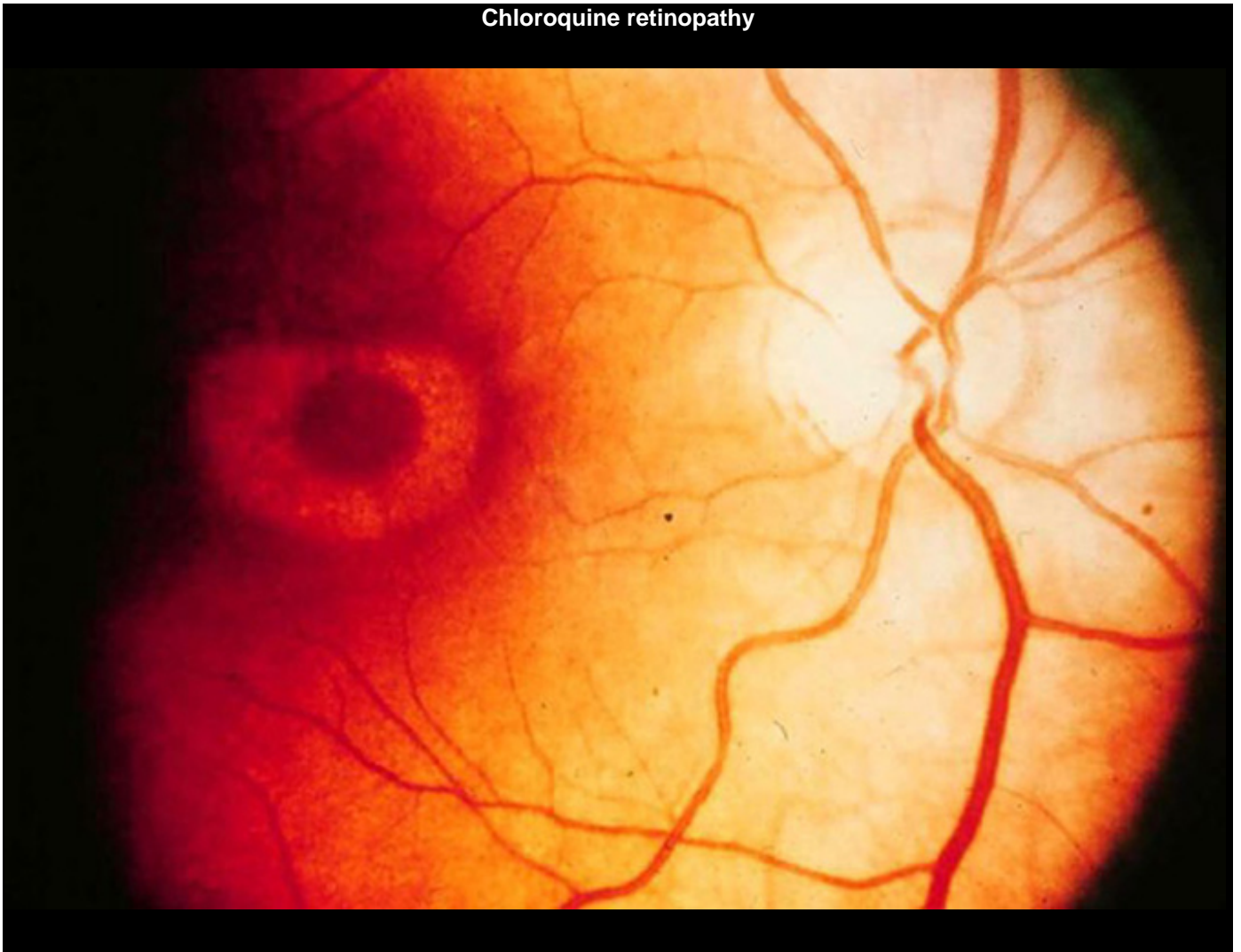


© Copyright [Oculisti OnLine](http://www.eyeatlas.com)

Eyeatlas

The online Atlas of Ophthalmology

Chloroquine retinopathy

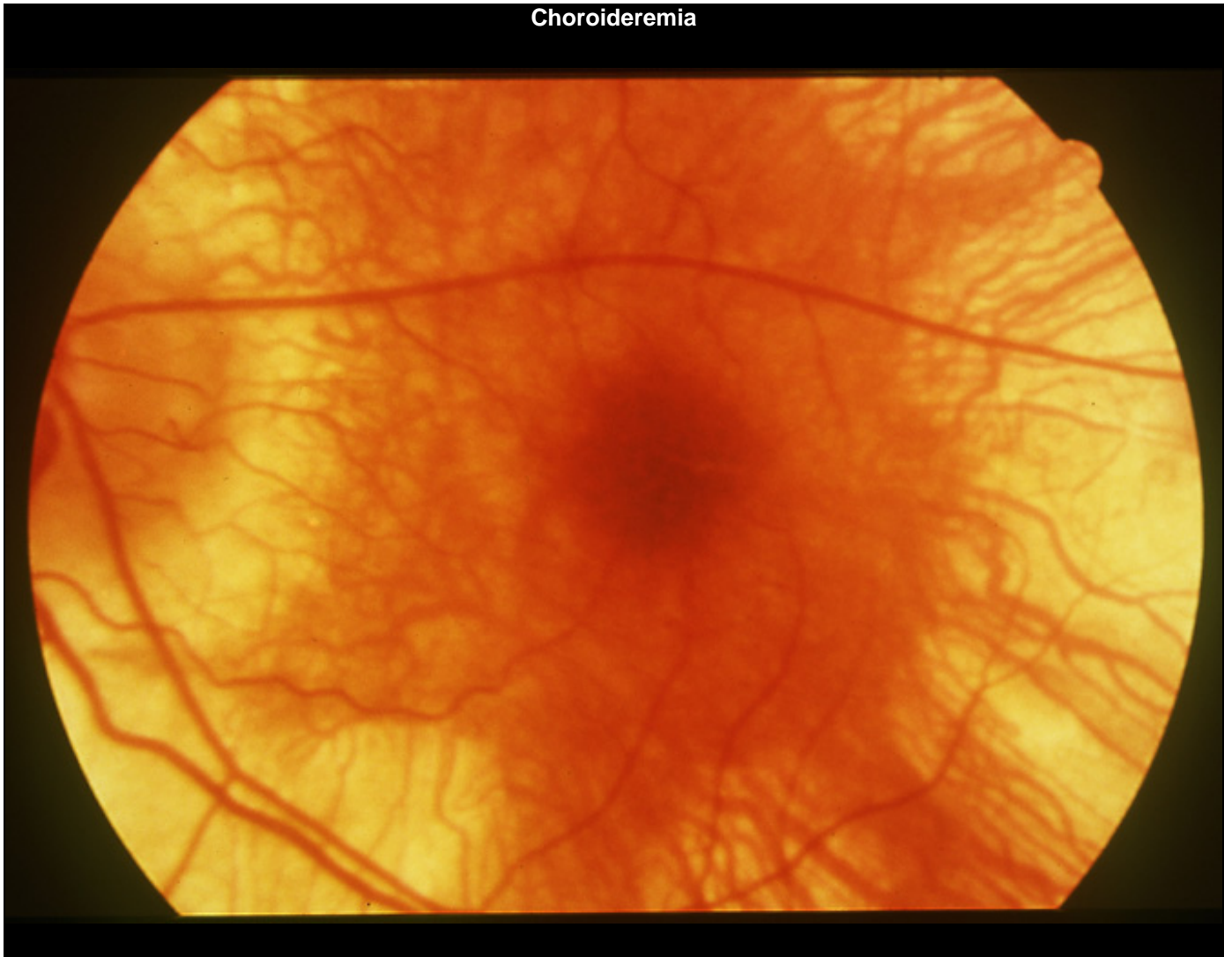


© Copyright [Oculisti OnLine](http://www.eyeatlas.com)

Eyeatlas

The online Atlas of Ophthalmology

Choroideremia

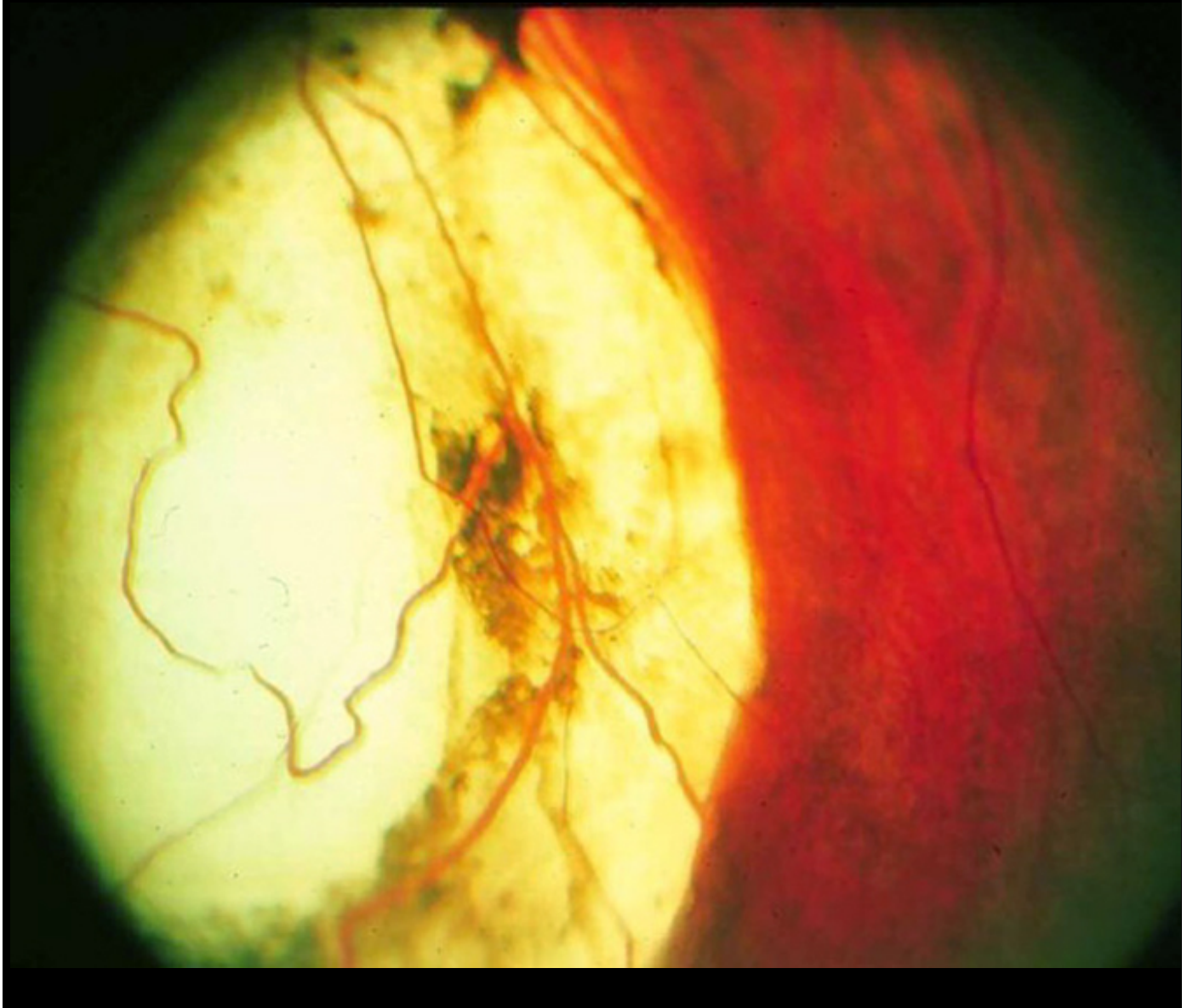

© Copyright [Oculisti OnLine](#)

EyeAtlas

The online Atlas of Ophthalmology

Choroidal coloboma

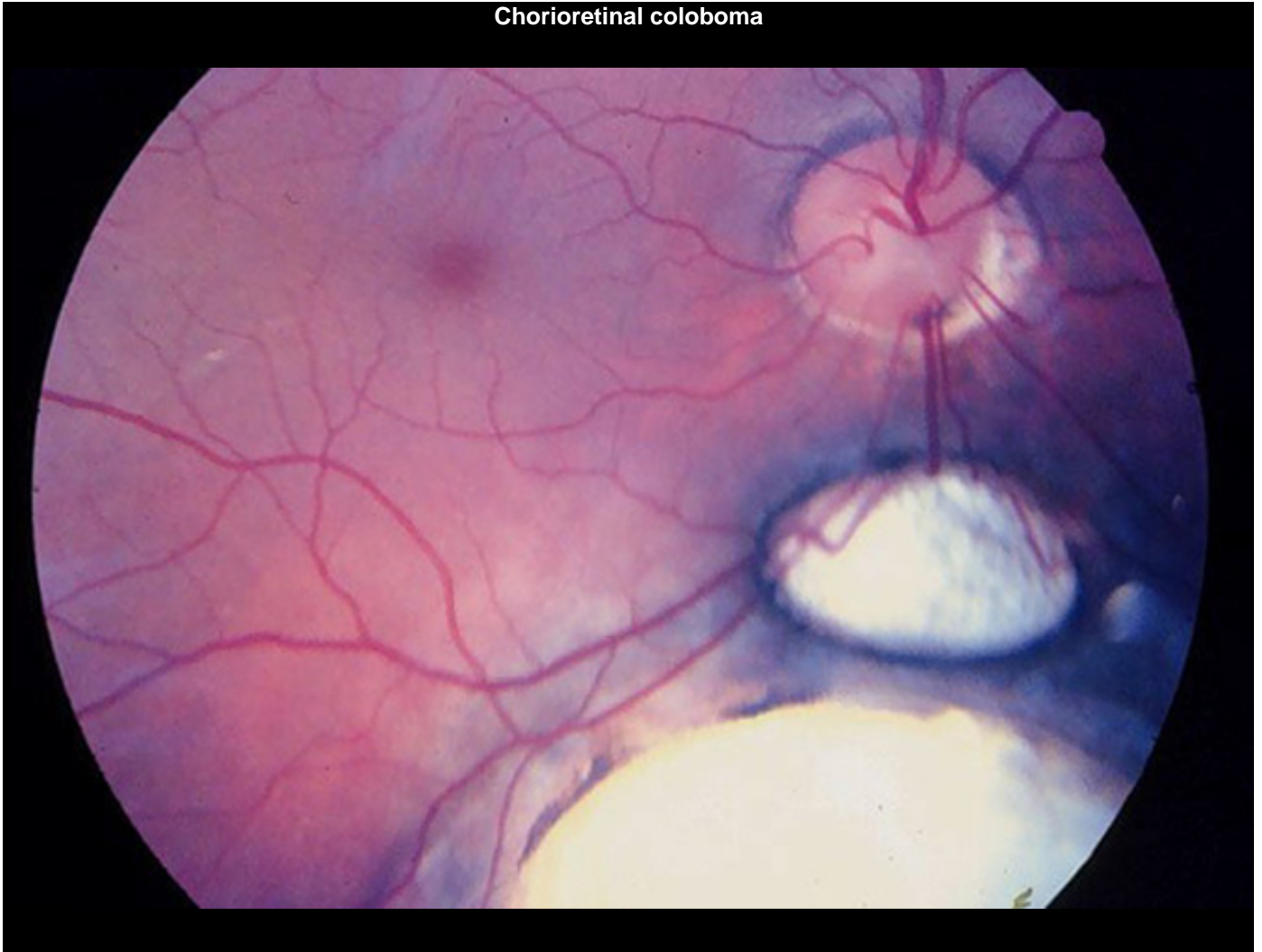


© Copyright [Oculisti OnLine](http://www.eyeatlas.com)

EyeAtlas

The online Atlas of Ophthalmology

Chorioretinal coloboma

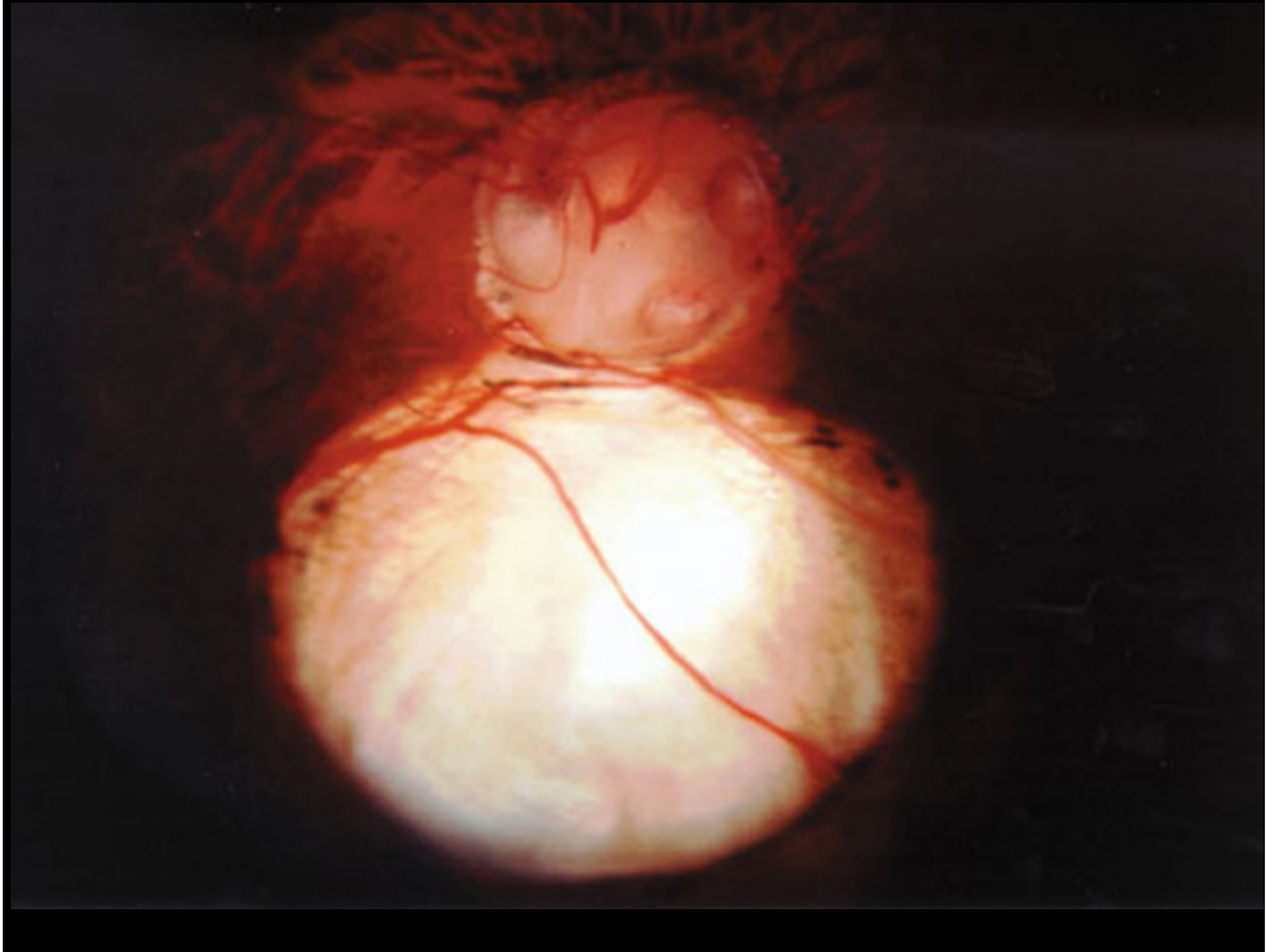


© Copyright [Oculisti OnLine](http://www.eyeatlas.com)

EyeAtlas

The online Atlas of Ophthalmology

Chorioretinal coloboma

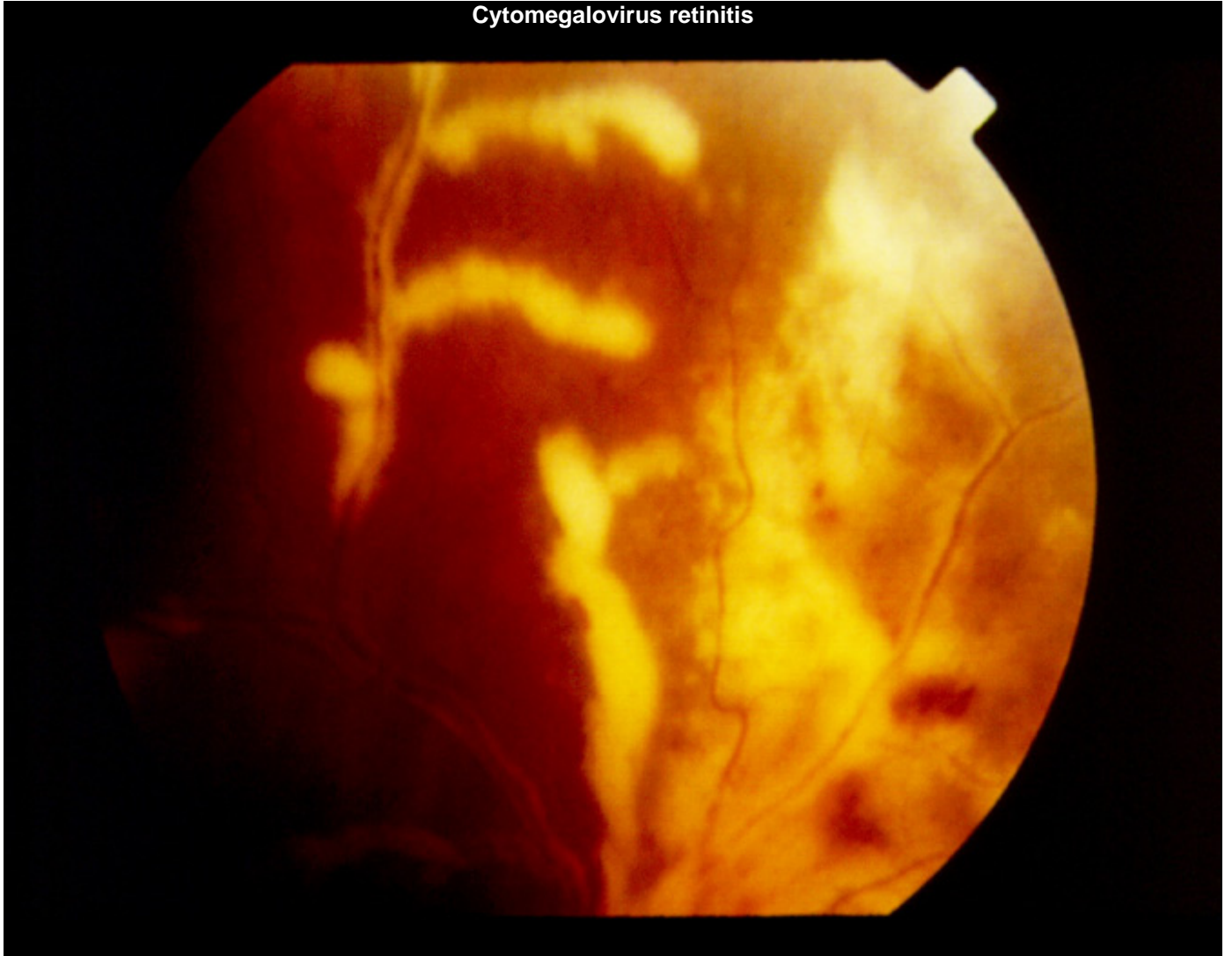


© Copyright [Oculisti OnLine](#)

EyeAtlas

The online Atlas of Ophthalmology

Cytomegalovirus retinitis

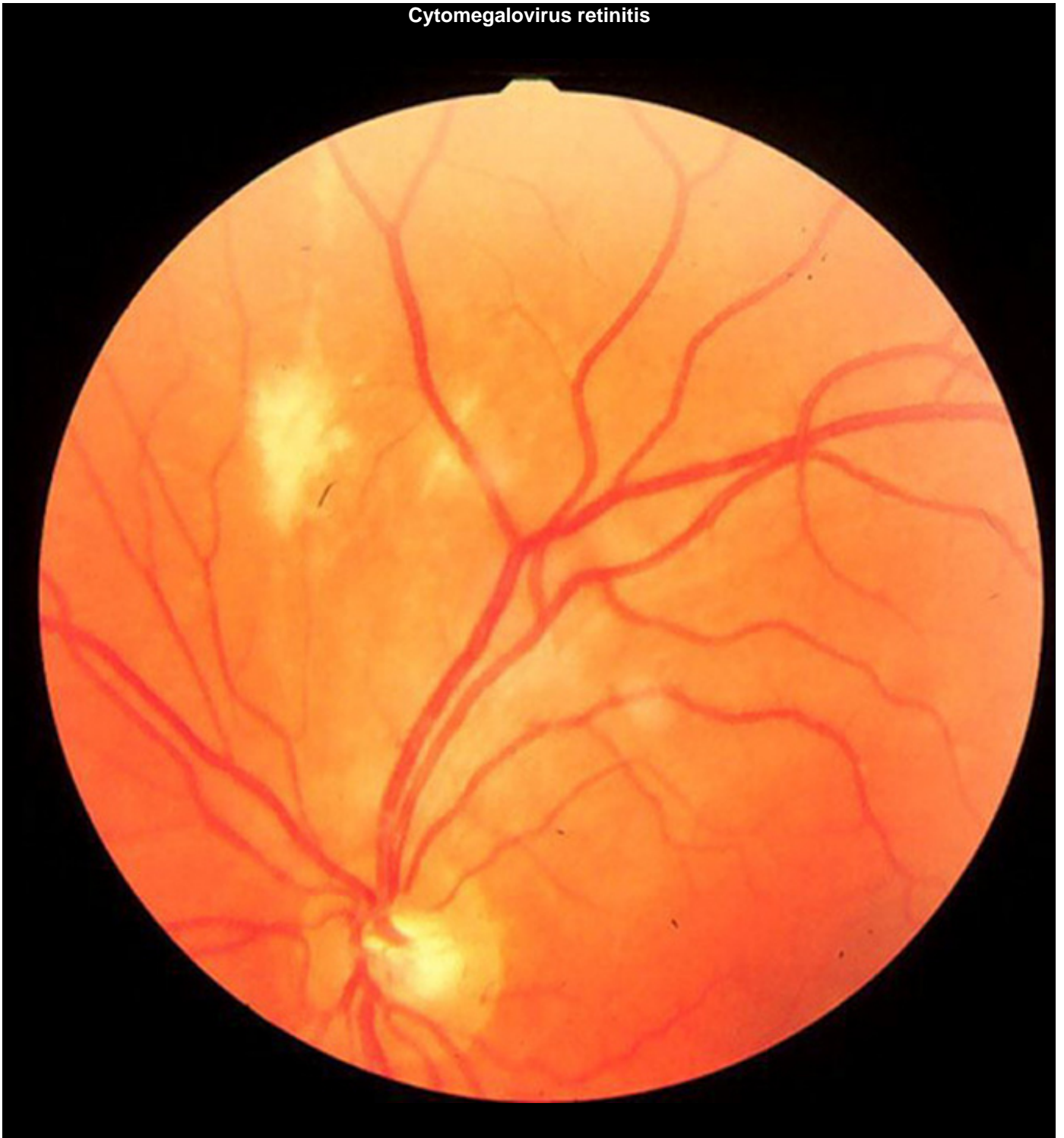

© Copyright [Oculisti OnLine](#)

Eyeatlas

The online Atlas of Ophthalmology

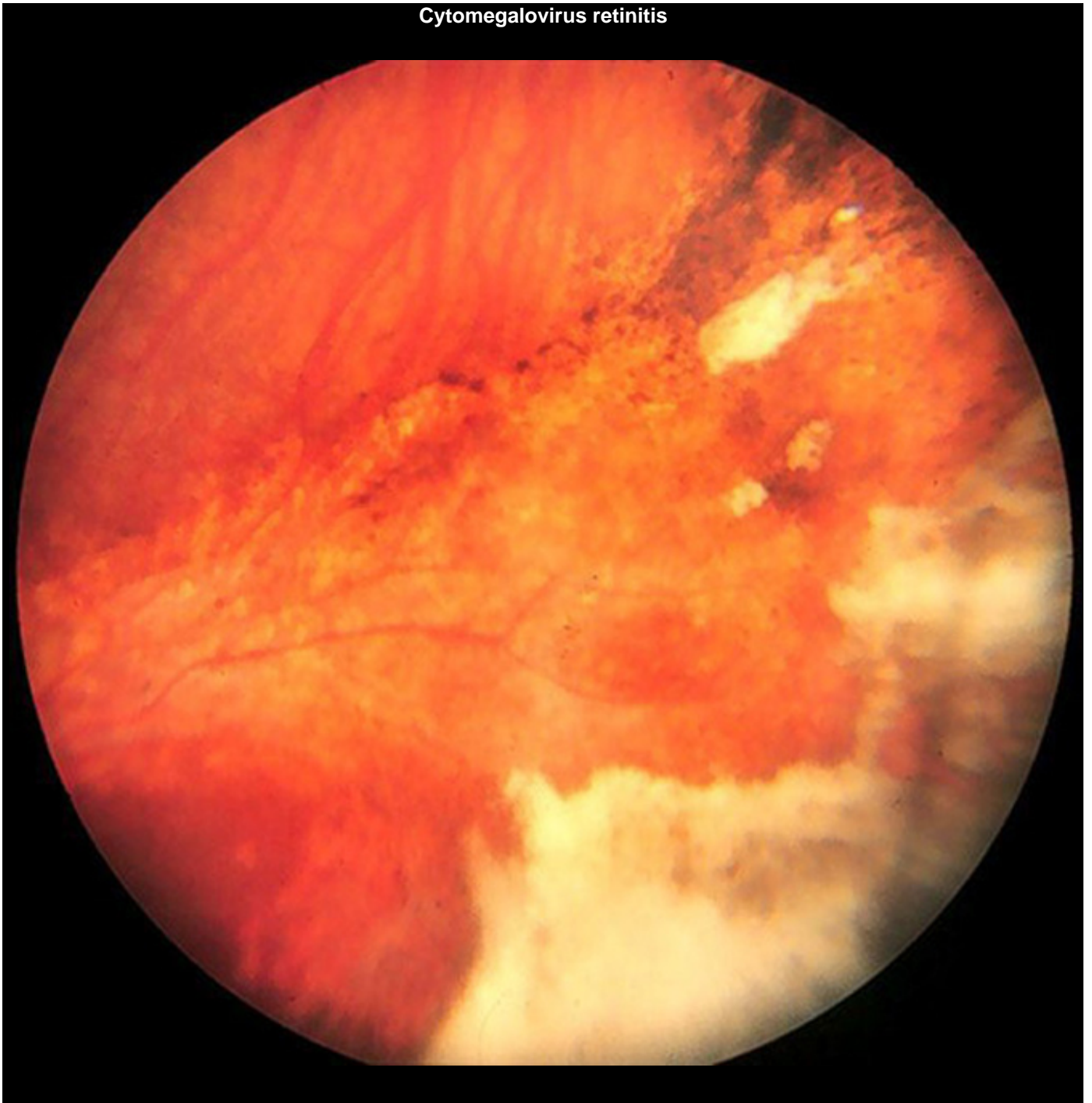
Cytomegalovirus retinitis



EyeAtlas

The online Atlas of Ophthalmology

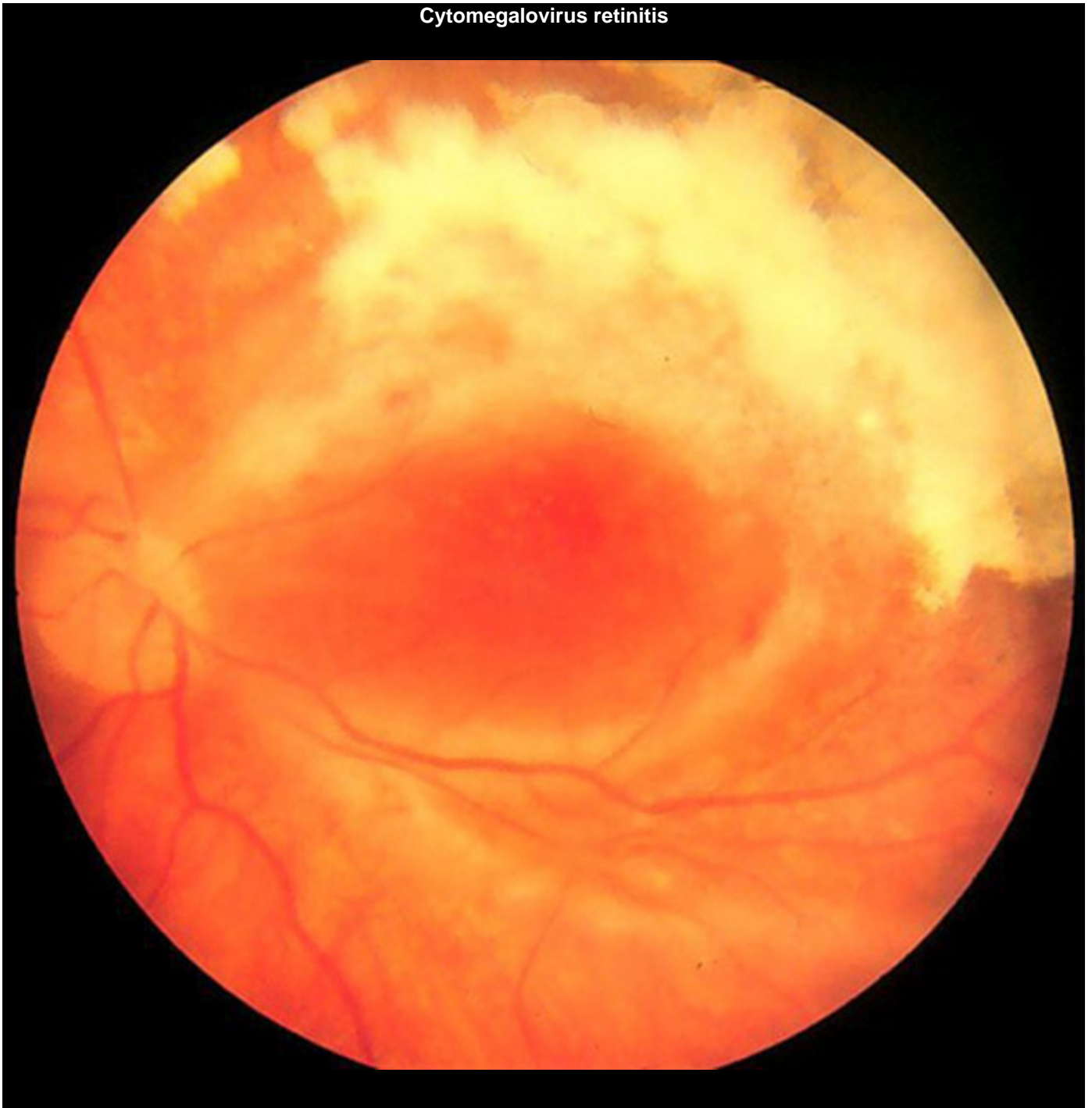Cytomegalovirus retinitis



EyeAtlas

The online Atlas of Ophthalmology

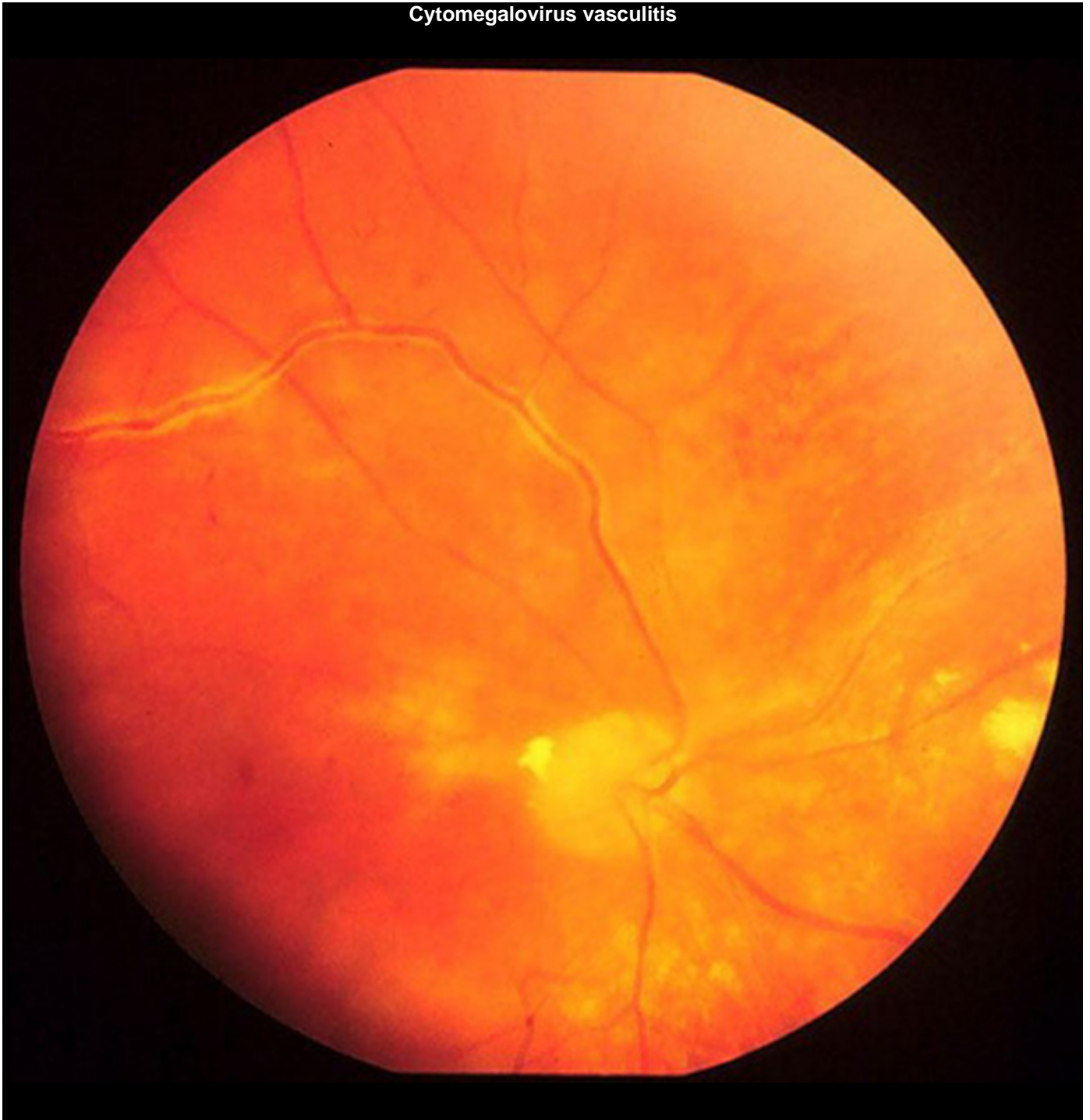Cytomegalovirus retinitis



Eyeatlas

The online Atlas of Ophthalmology

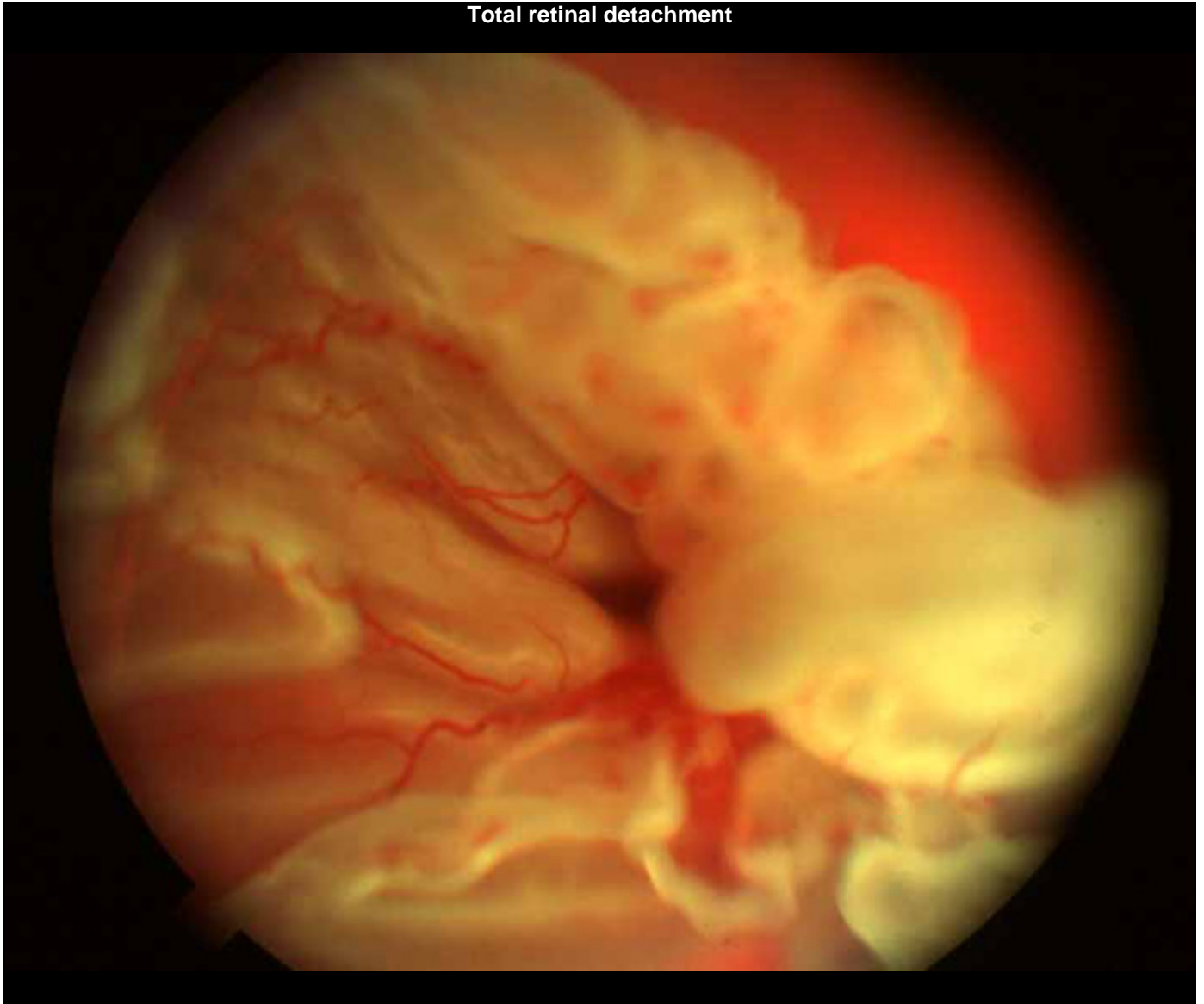
Cytomegalovirus vasculitis



EyeAtlas

The online Atlas of Ophthalmology

Total retinal detachment

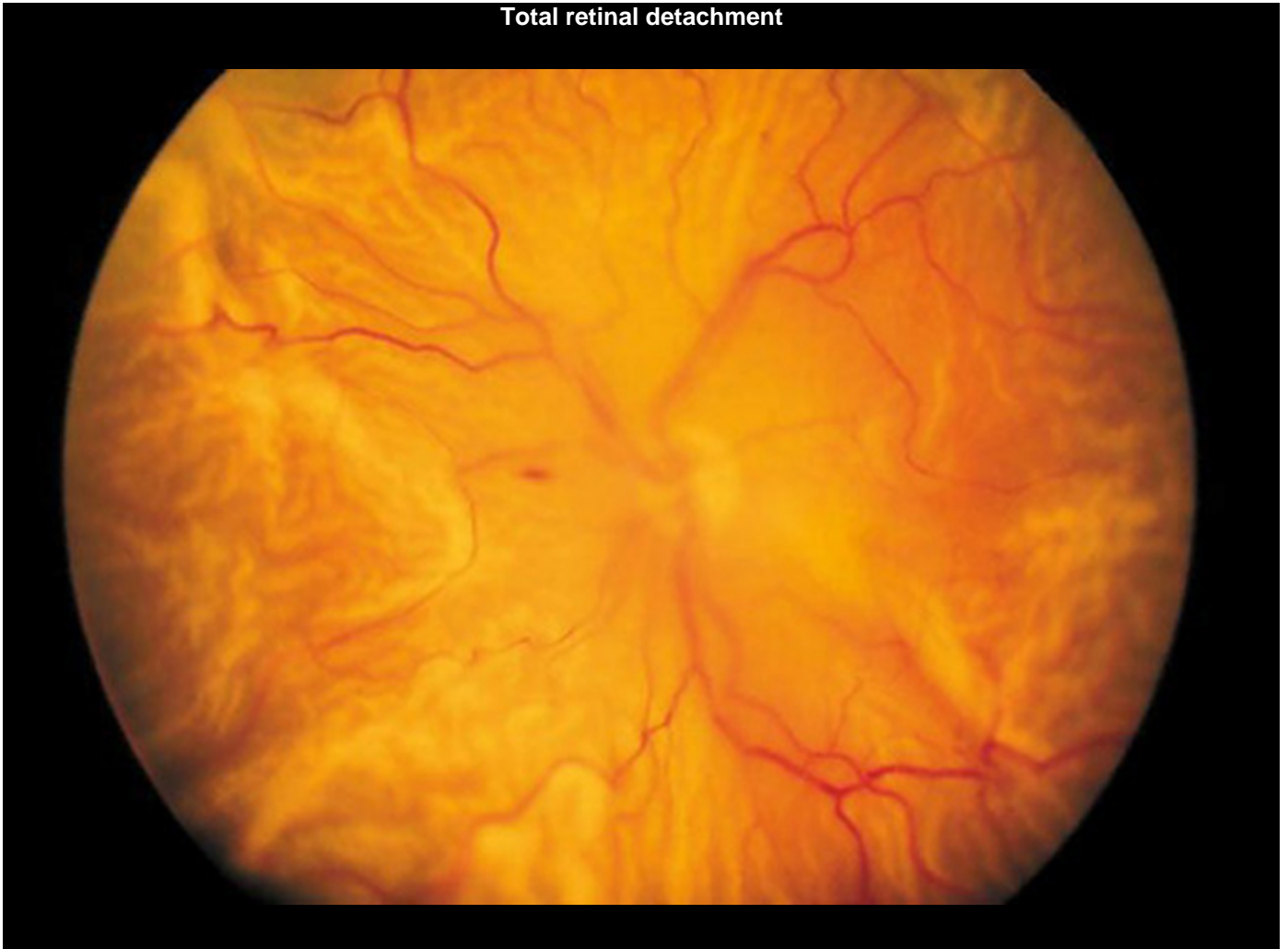

© Copyright [Oculisti OnLine](#)

EyeAtlas

The online Atlas of Ophthalmology

Total retinal detachment

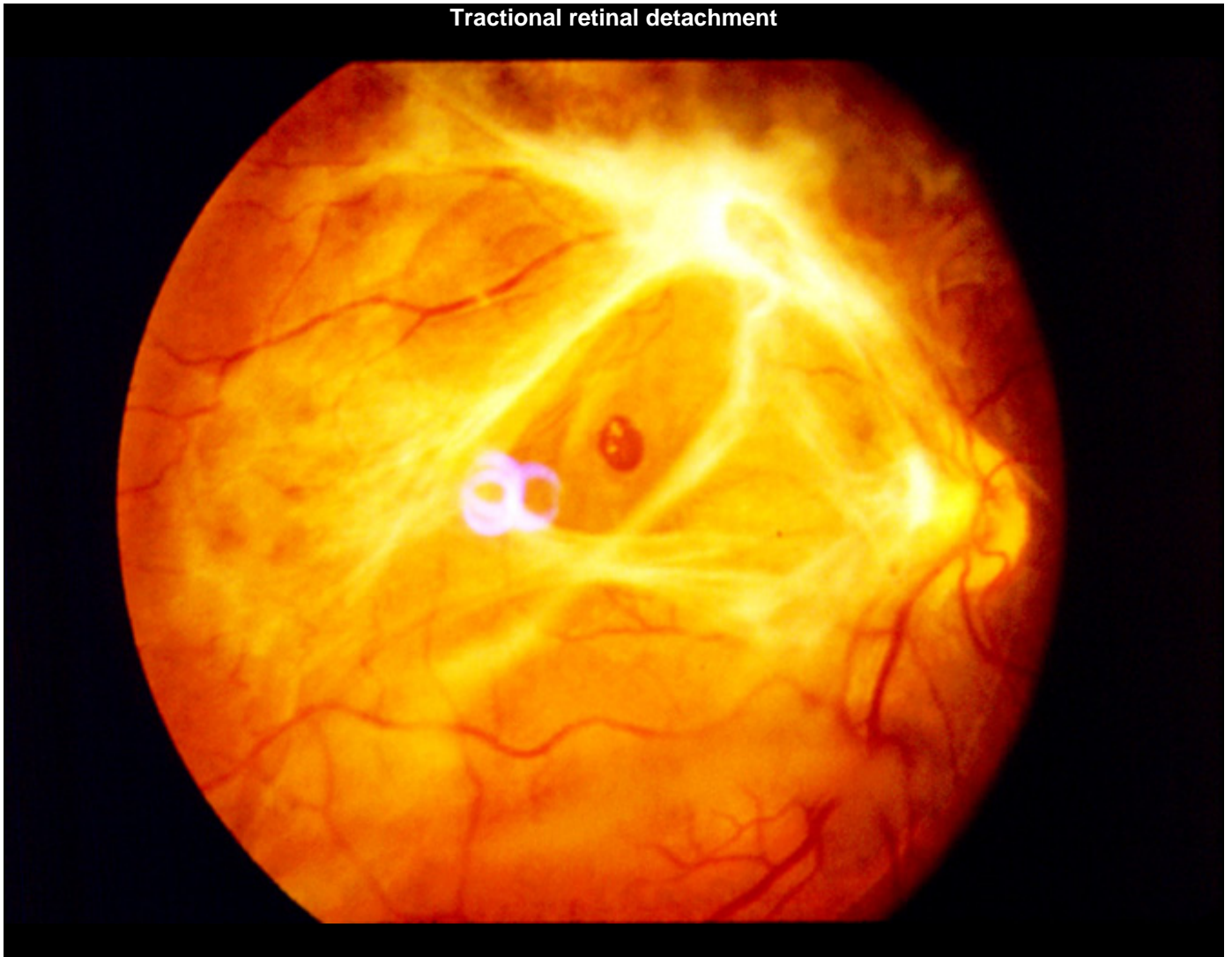


© Copyright [Oculisti OnLine](#)

EyeAtlas

The online Atlas of Ophthalmology

Tractional retinal detachment

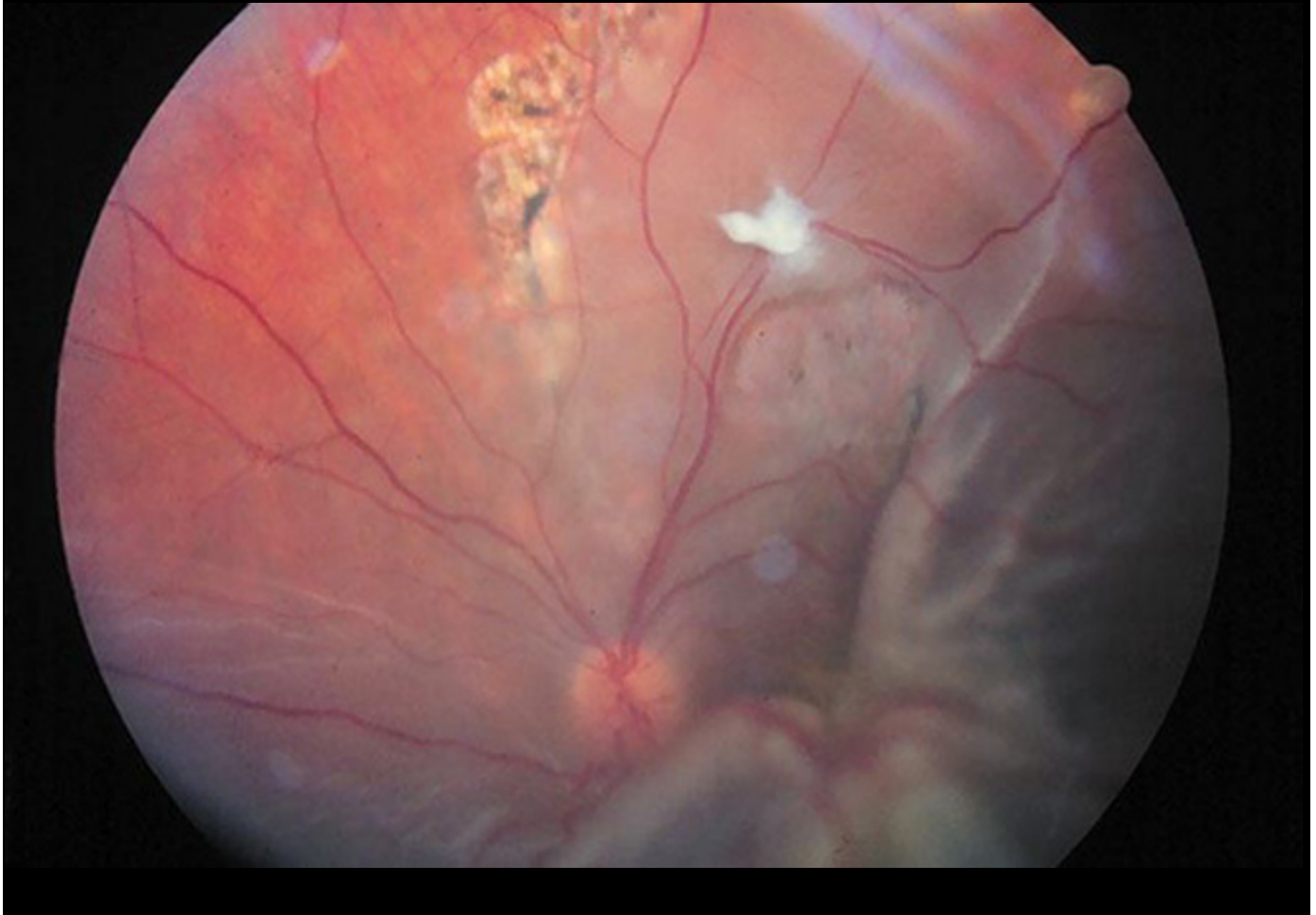

© Copyright [Oculisti OnLine](#)

EyeAtlas

The online Atlas of Ophthalmology

Retinal detachment after Candida infectionß

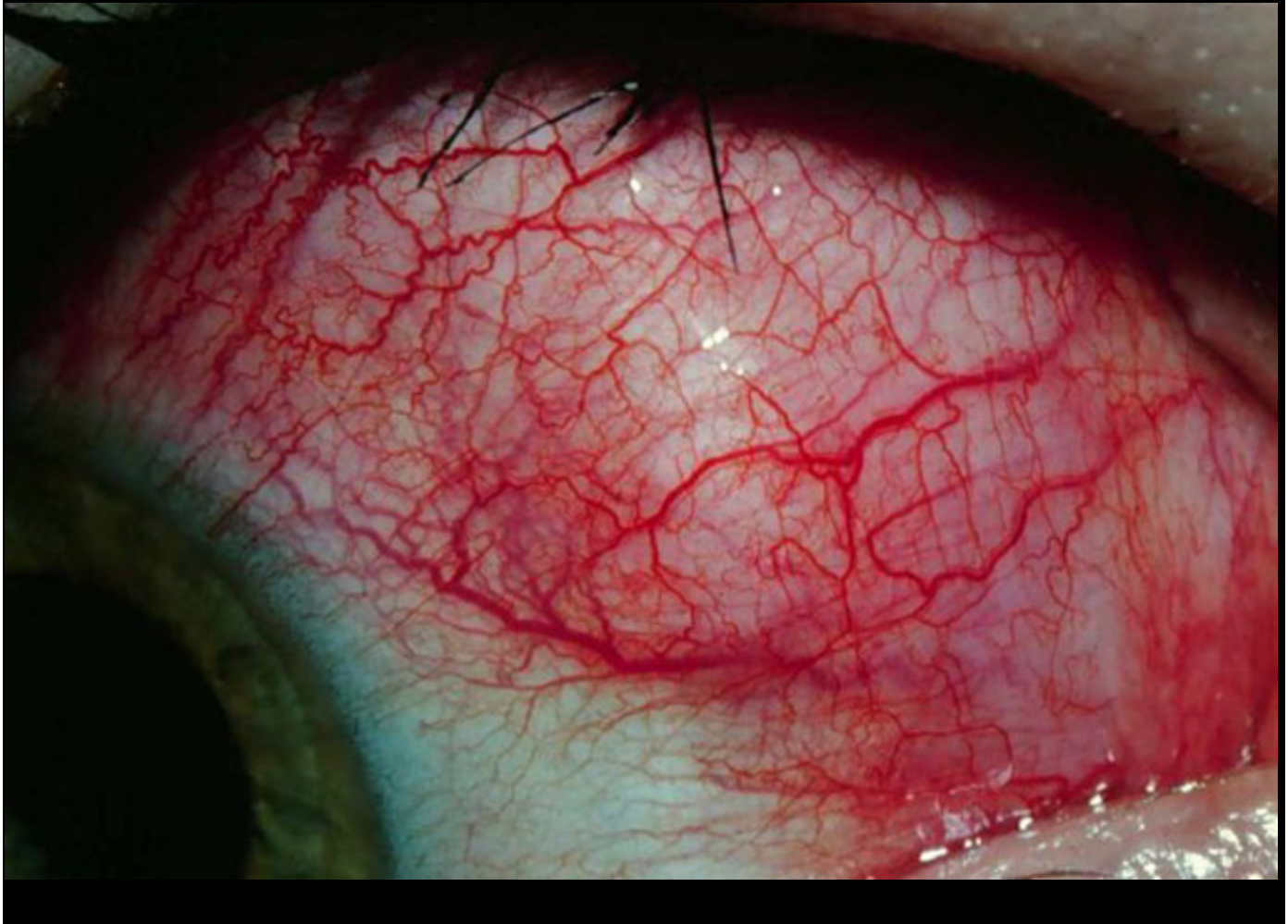


© Copyright [Oculisti OnLine](http://www.eyeatlas.com)

Eyeatlas

The online Atlas of Ophthalmology

Nodular scleritis

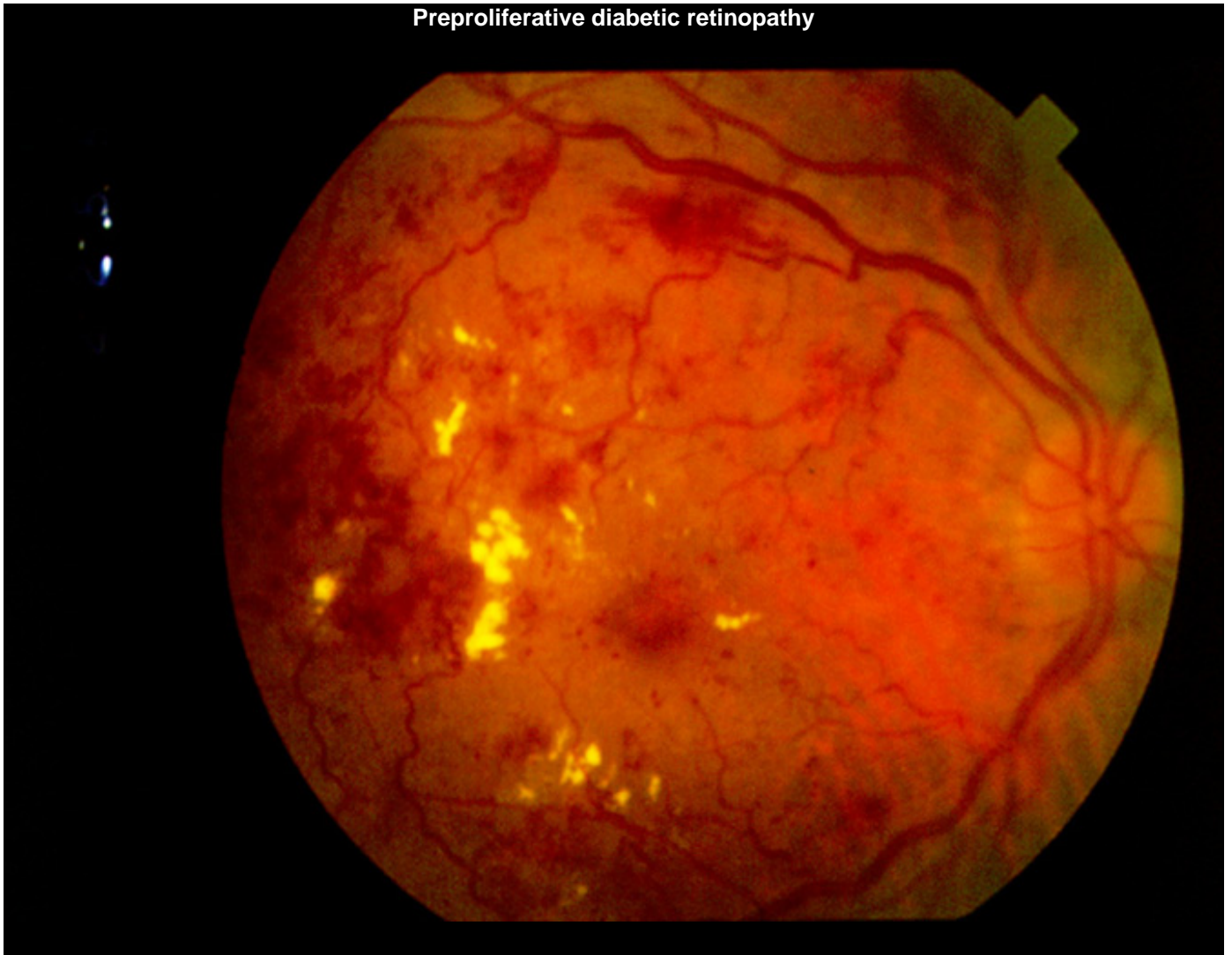


© Copyright [Oculisti OnLine](http://www.eyeatlas.com)

EyeAtlas

The online Atlas of Ophthalmology

Preproliferative diabetic retinopathy

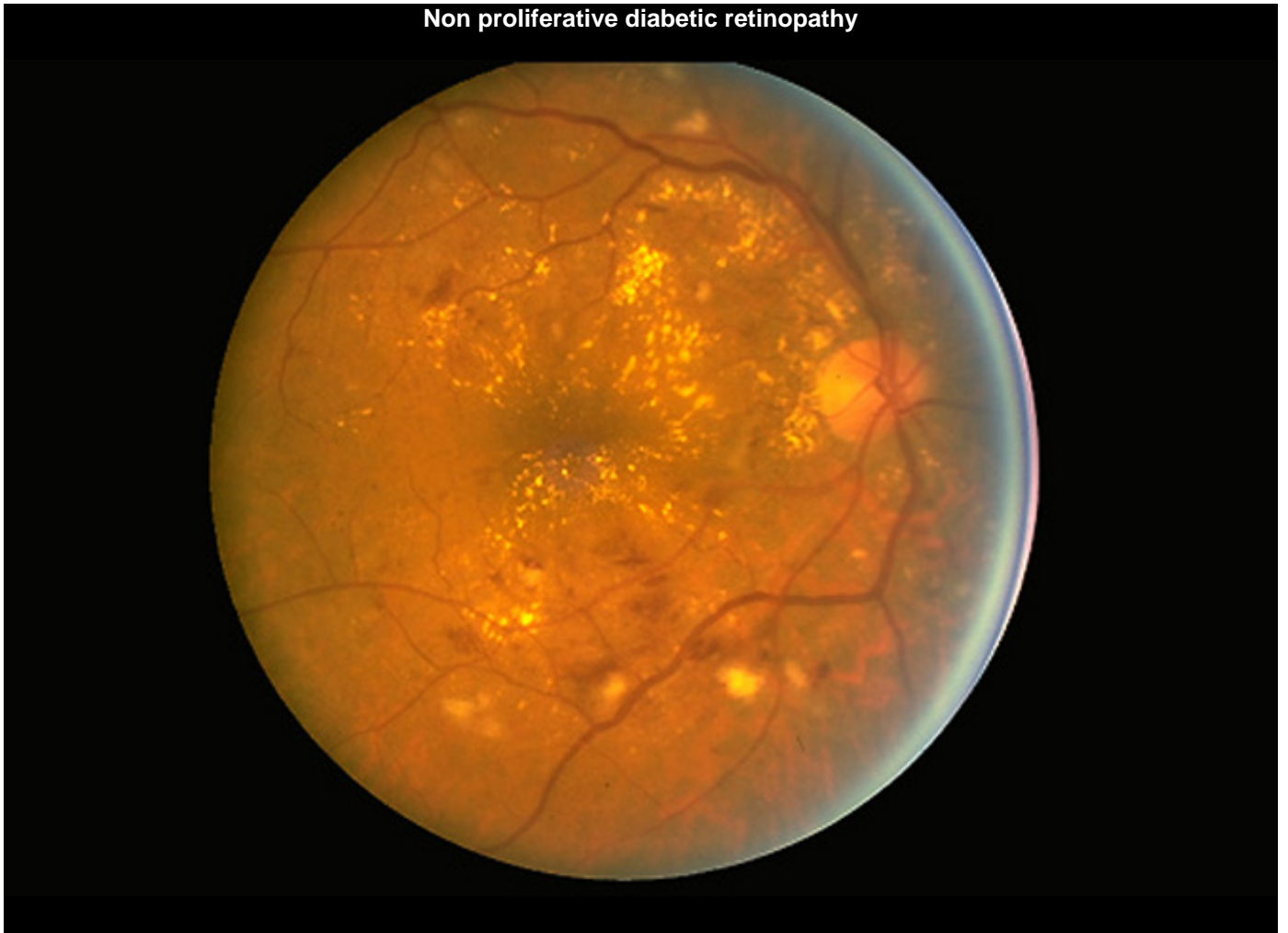


© Copyright [Oculisti OnLine](http://www.eyeatlas.com)

Eyeatlas

The online Atlas of Ophthalmology

Non proliferative diabetic retinopathy

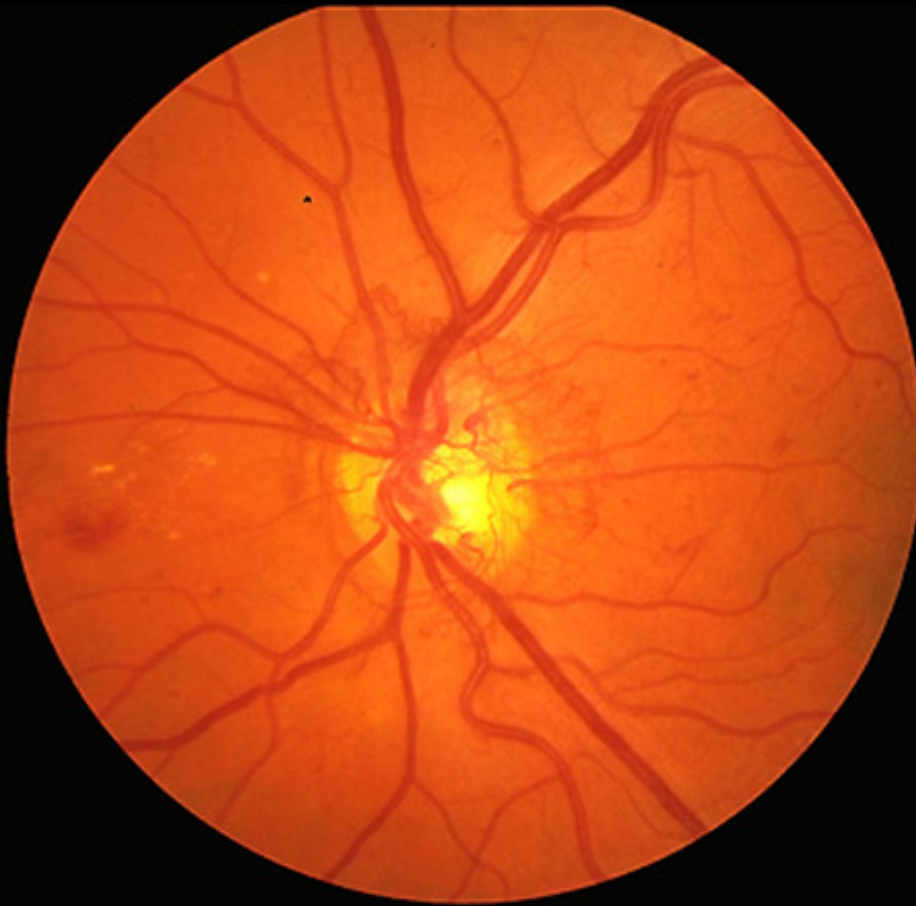

© Copyright [Oculisti OnLine](#)

Eyeatlas

The online Atlas of Ophthalmology

Diabetic proliferative retinopathy

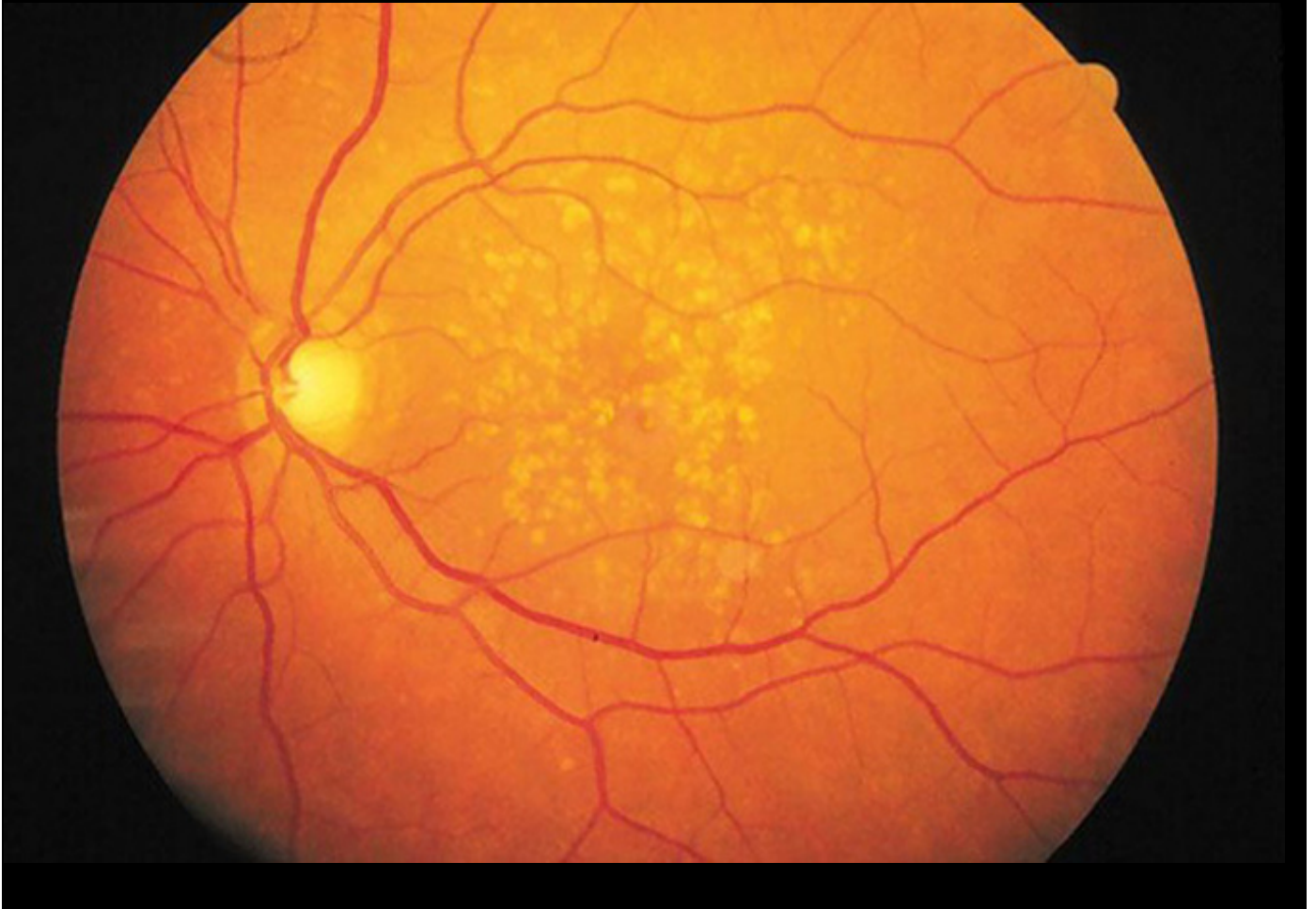

© Copyright [Oculisti OnLine](#)

Eyeatlas

The online Atlas of Ophthalmology

Macular drusen

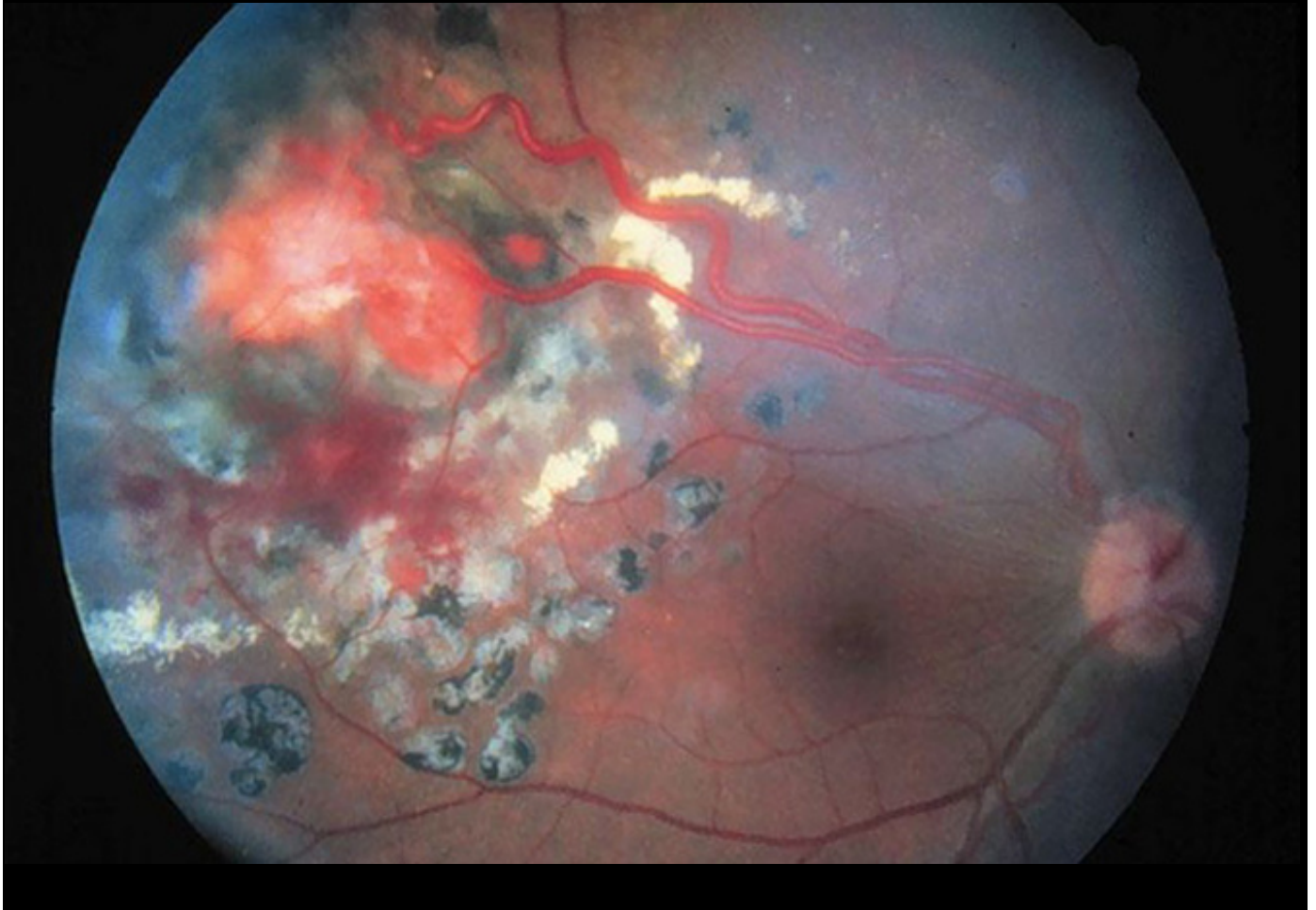


© Copyright [Oculisti OnLine](#)

EyeAtlas

The online Atlas of Ophthalmology

Haemangioma

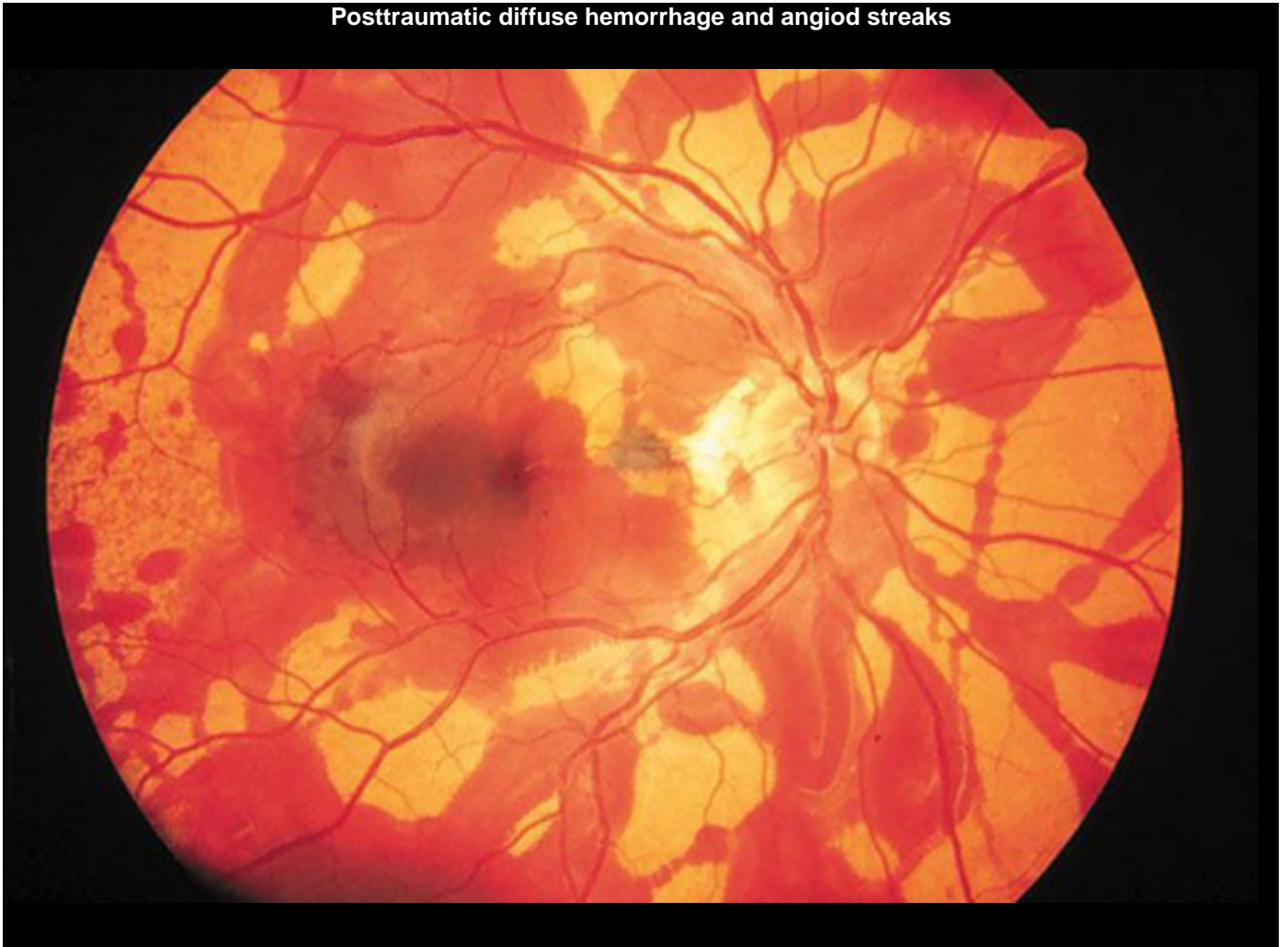

© Copyright [Oculisti OnLine](http://www.eyeatlas.com)

Eyeatlas

The online Atlas of Ophthalmology

Posttraumatic diffuse hemorrhage and angiod streaks

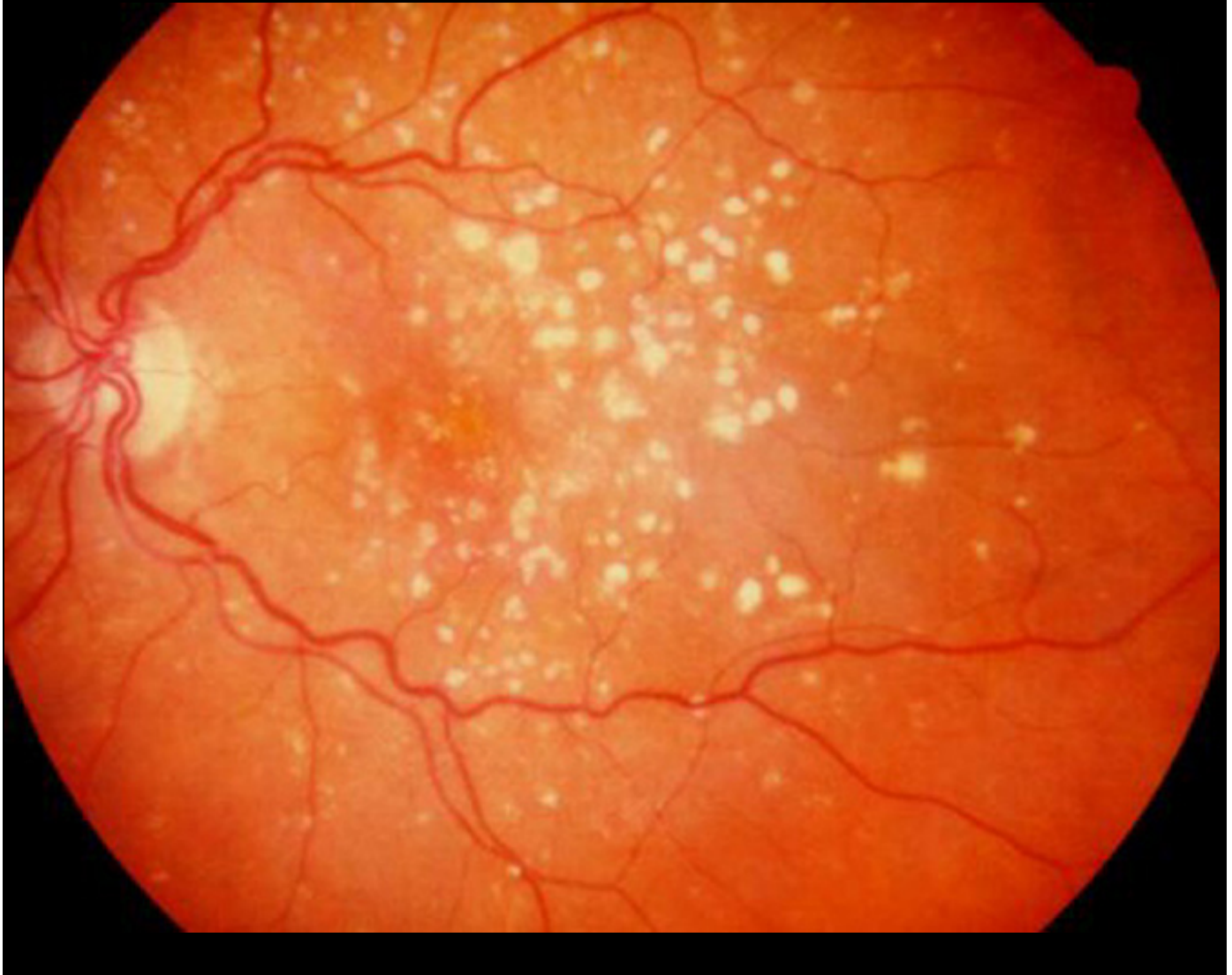


© Copyright [Oculisti OnLine](http://www.eyeatlas.com)

Eyeatlas

The online Atlas of Ophthalmology

Macular degeneration (dry)

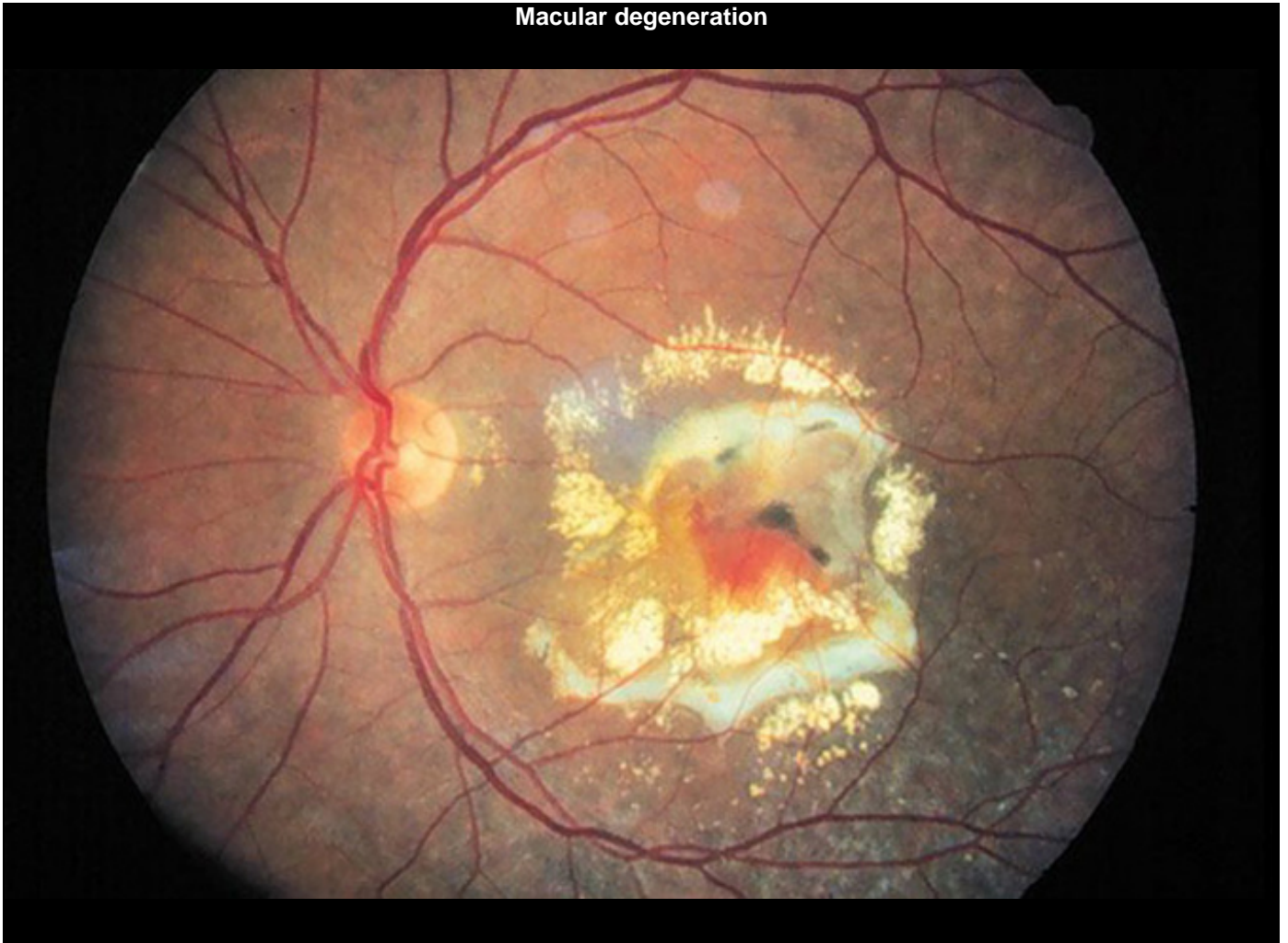

© Copyright [Oculisti OnLine](#)

EyeAtlas

The online Atlas of Ophthalmology

Macular degeneration

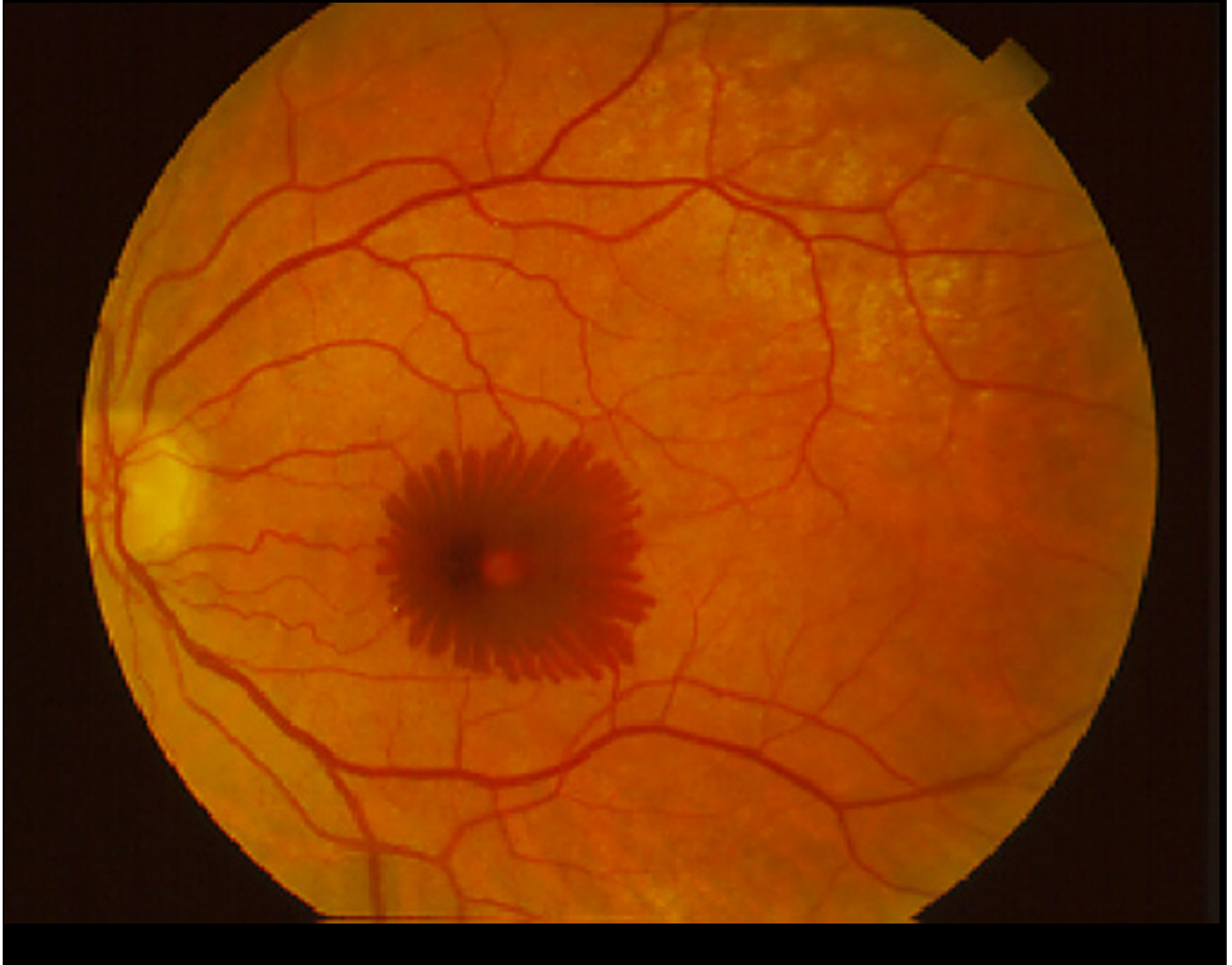

© Copyright [Oculisti OnLine](#)

Eyeatlas

The online Atlas of Ophthalmology

Macular haemorrhage

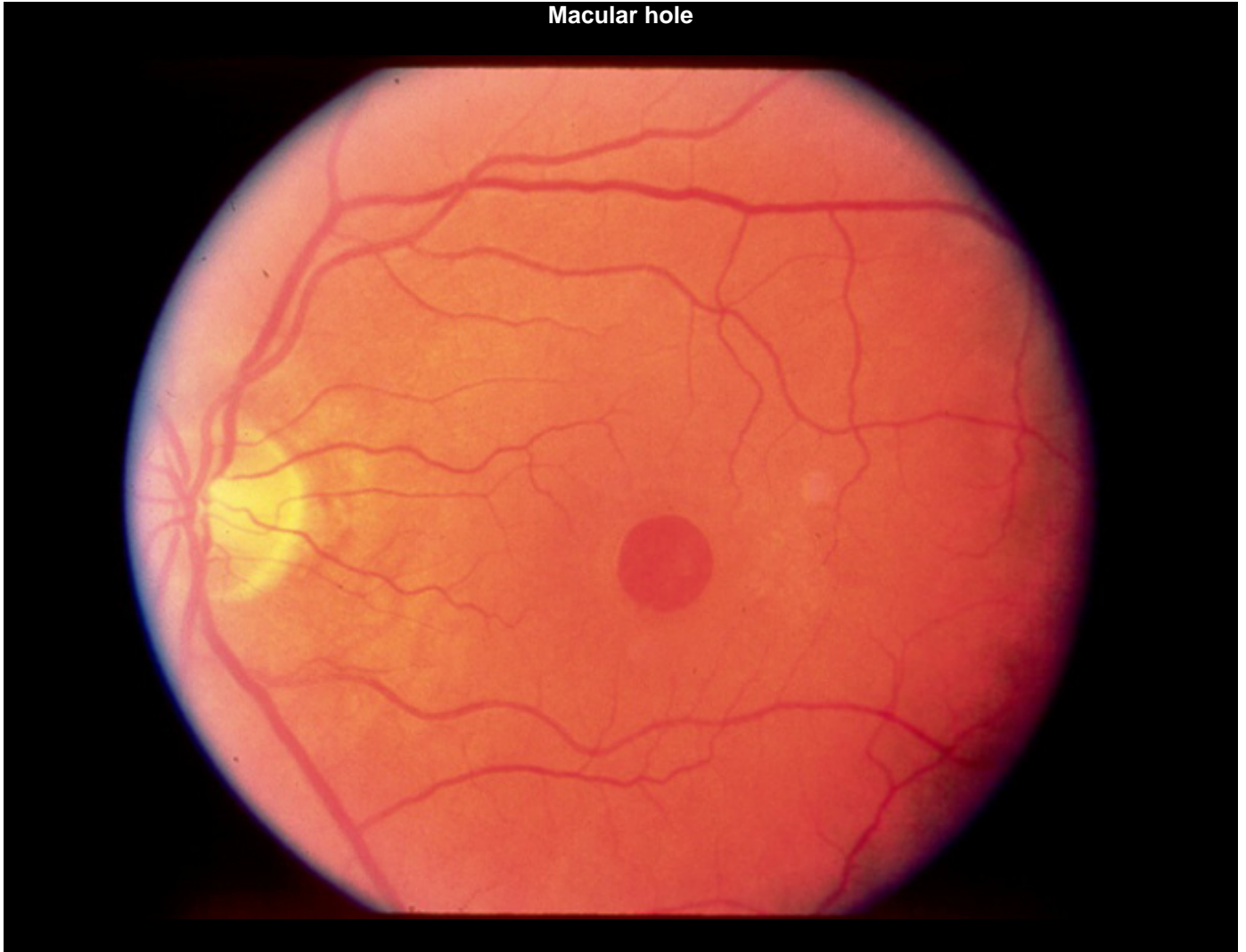

© Copyright [Oculisti OnLine](http://www.eyeatlas.com)

Eyeatlas

The online Atlas of Ophthalmology

Macular hole

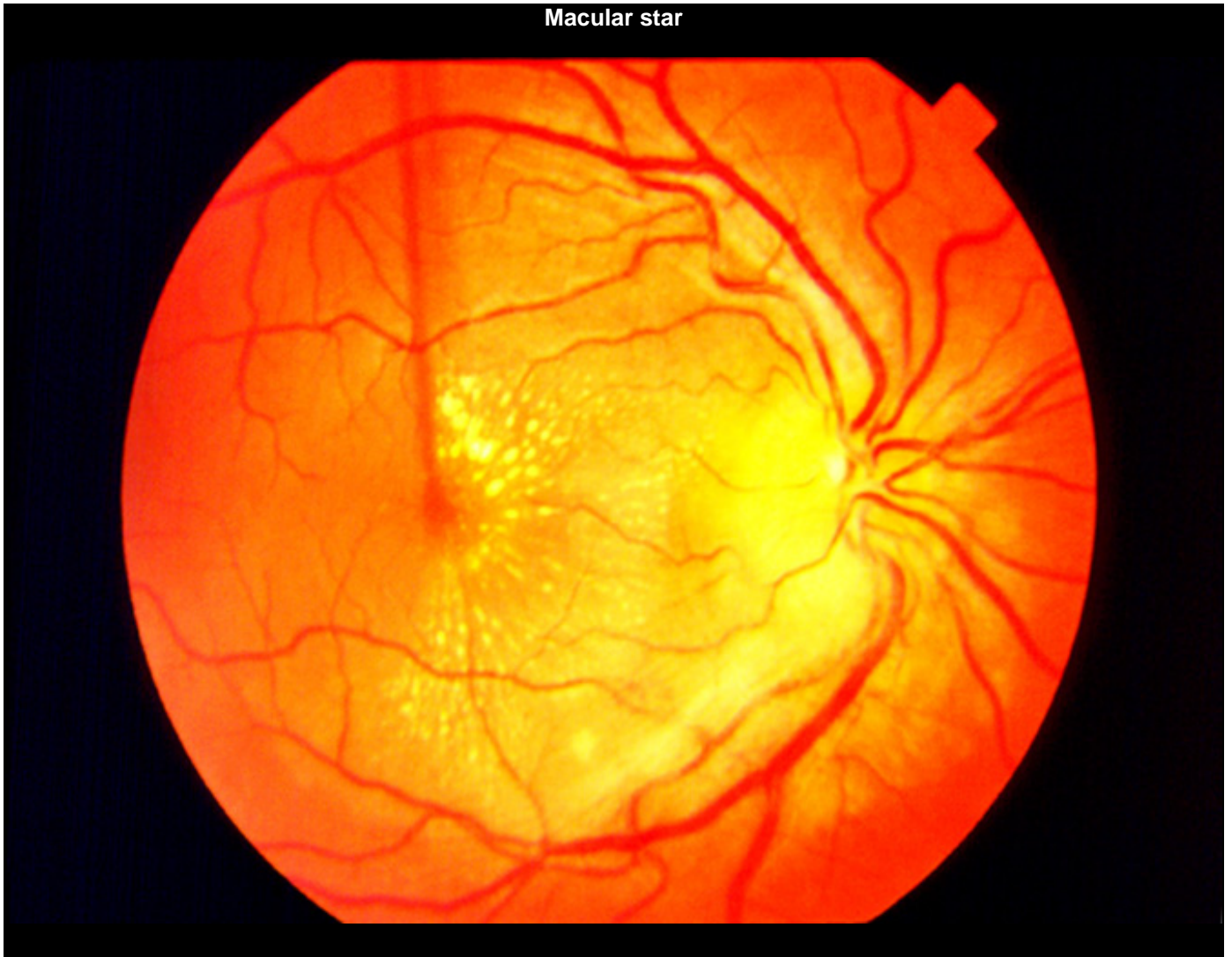


© Copyright [Oculisti OnLine](#)

Eyeatlas

The online Atlas of Ophthalmology

Macular star

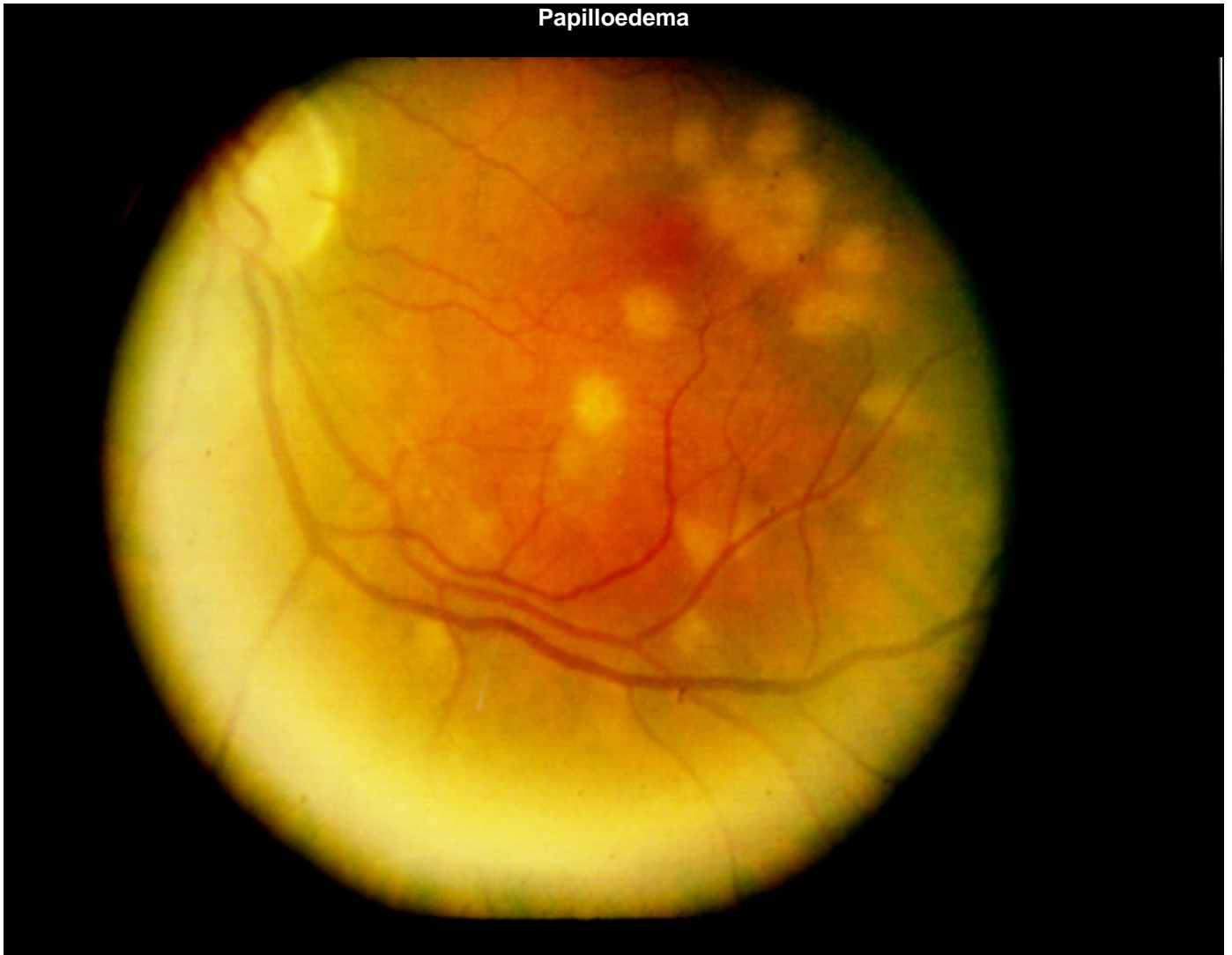


© Copyright [Oculisti OnLine](#)

EyeAtlas

The online Atlas of Ophthalmology

Papilloedema

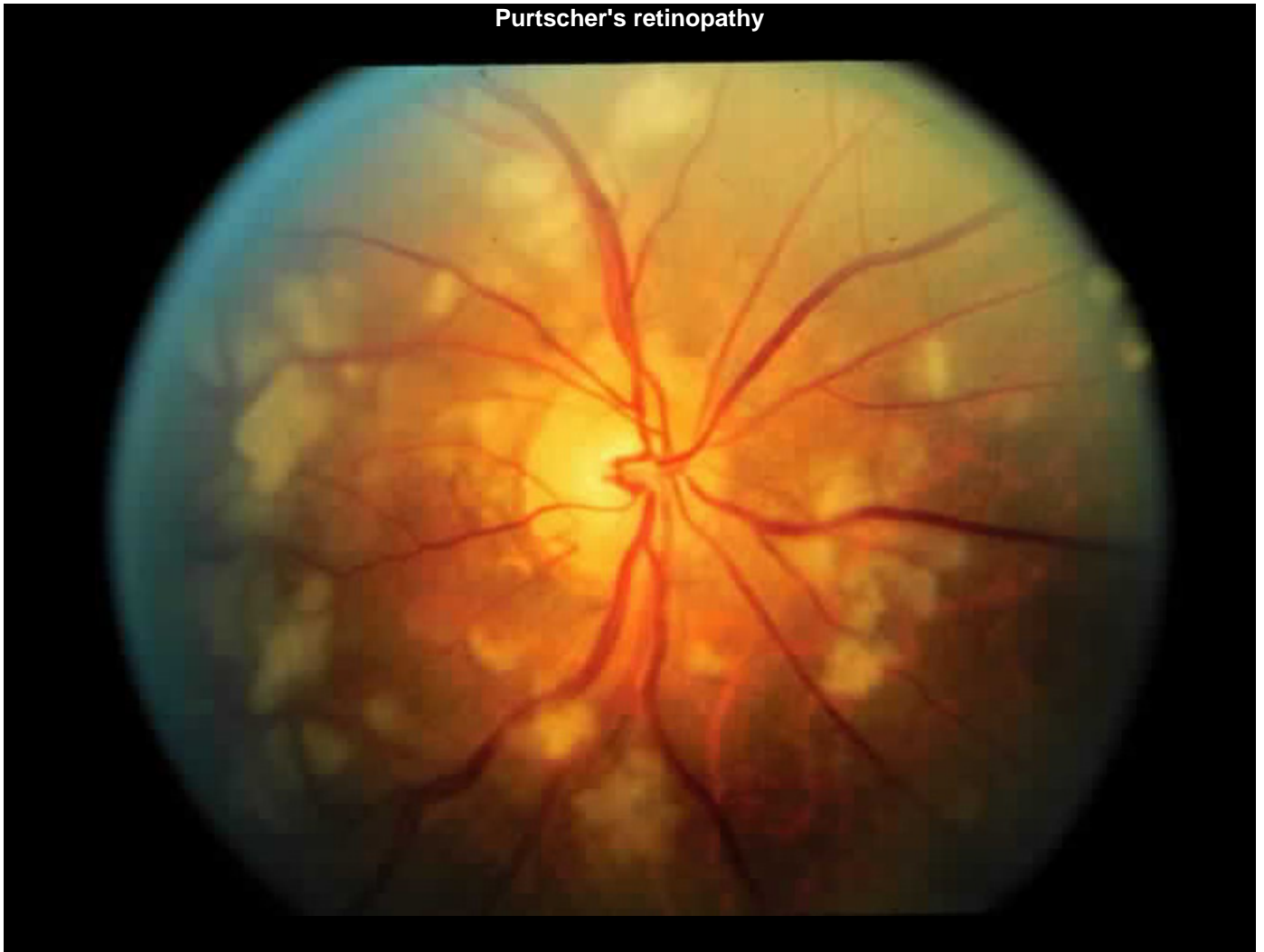


© Copyright [Oculisti OnLine](#)

EyeAtlas

The online Atlas of Ophthalmology

Purtscher's retinopathy

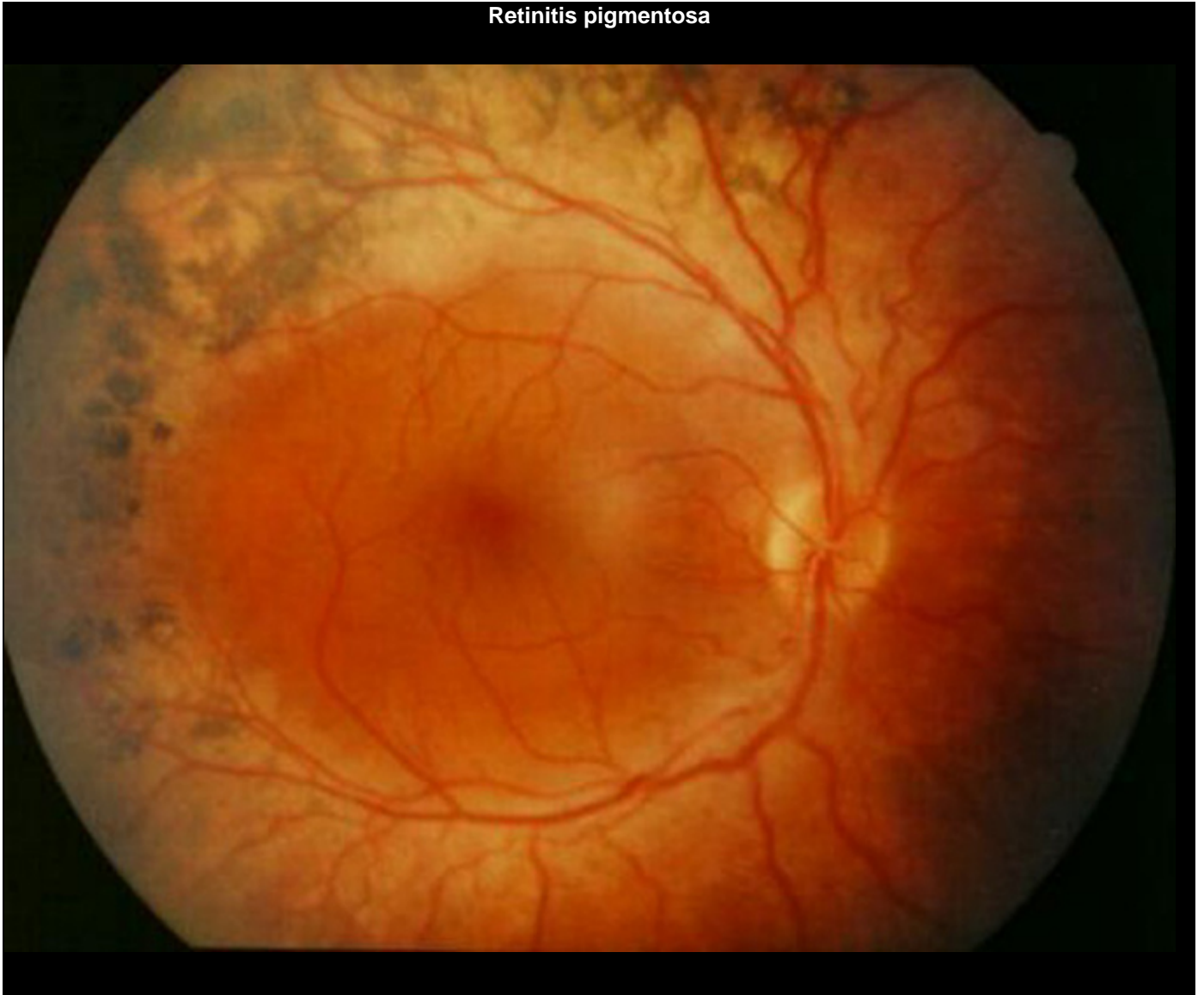


© Copyright [Oculisti OnLine](#)

EyeAtlas

The online Atlas of Ophthalmology

Retinitis pigmentosa

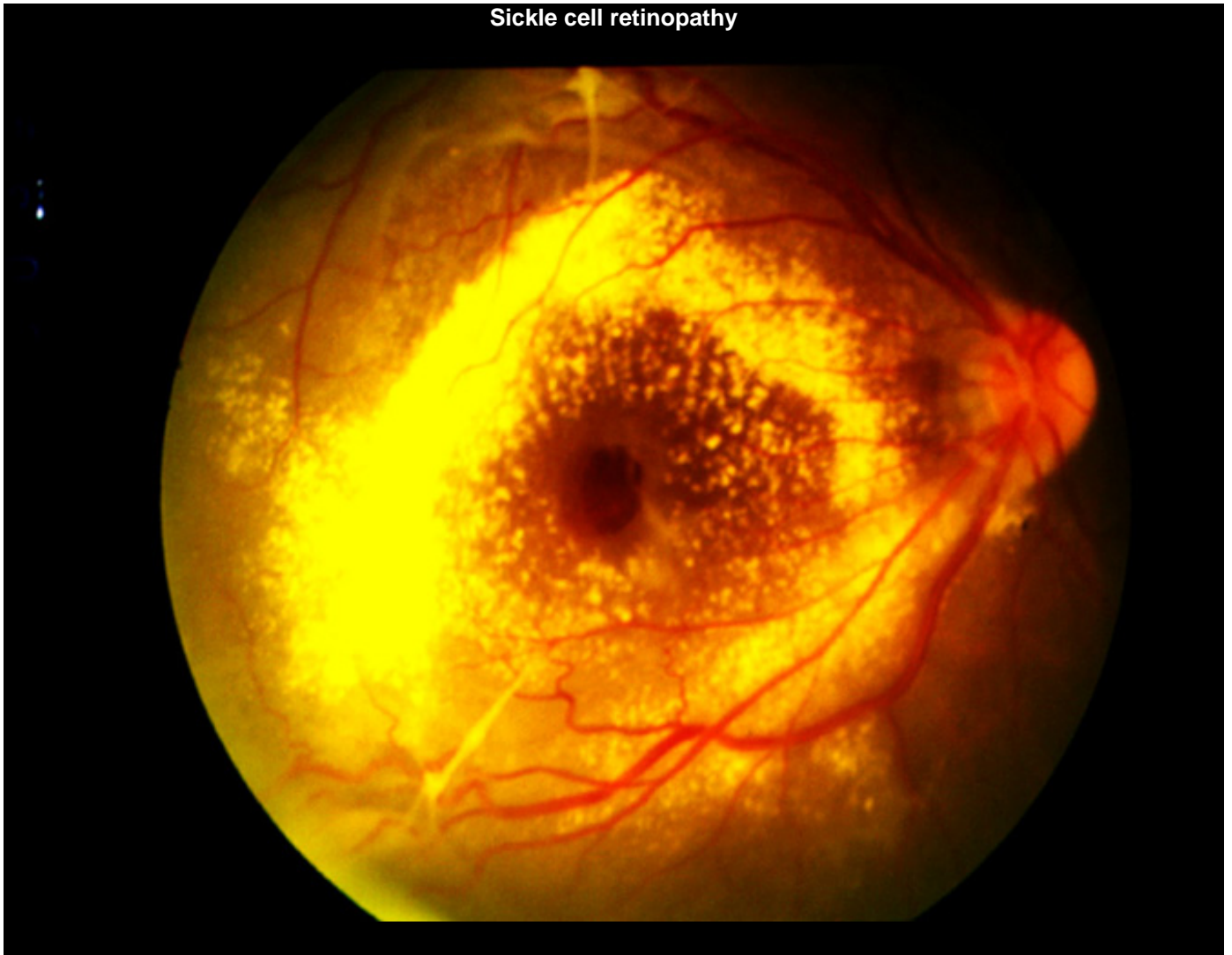


© Copyright [Oculisti OnLine](#)

Eyeatlas

The online Atlas of Ophthalmology

Sickle cell retinopathy

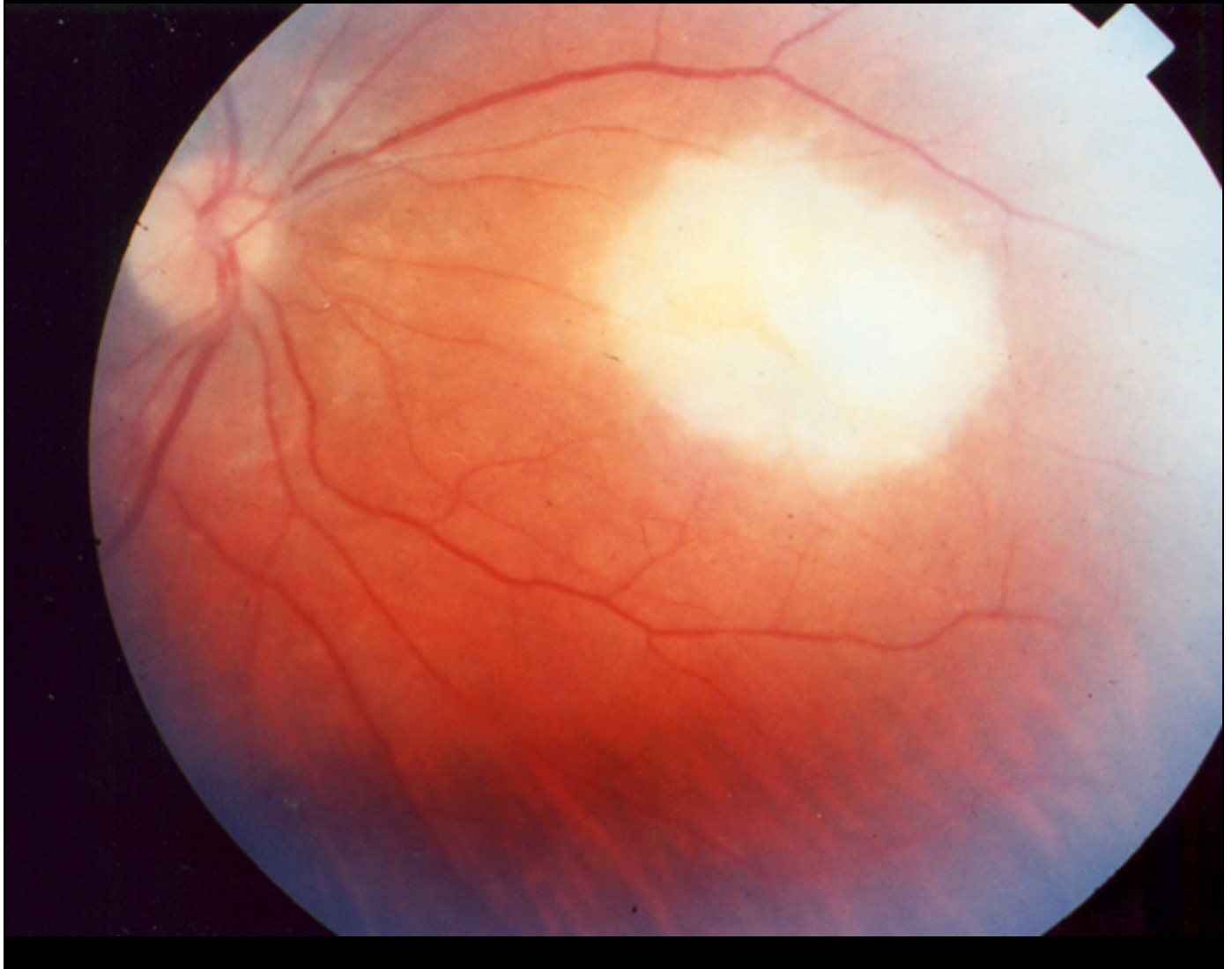


© Copyright [Oculisti OnLine](#)

Eyeatlas

The online Atlas of Ophthalmology

Toxoplasmosis: active macular infection

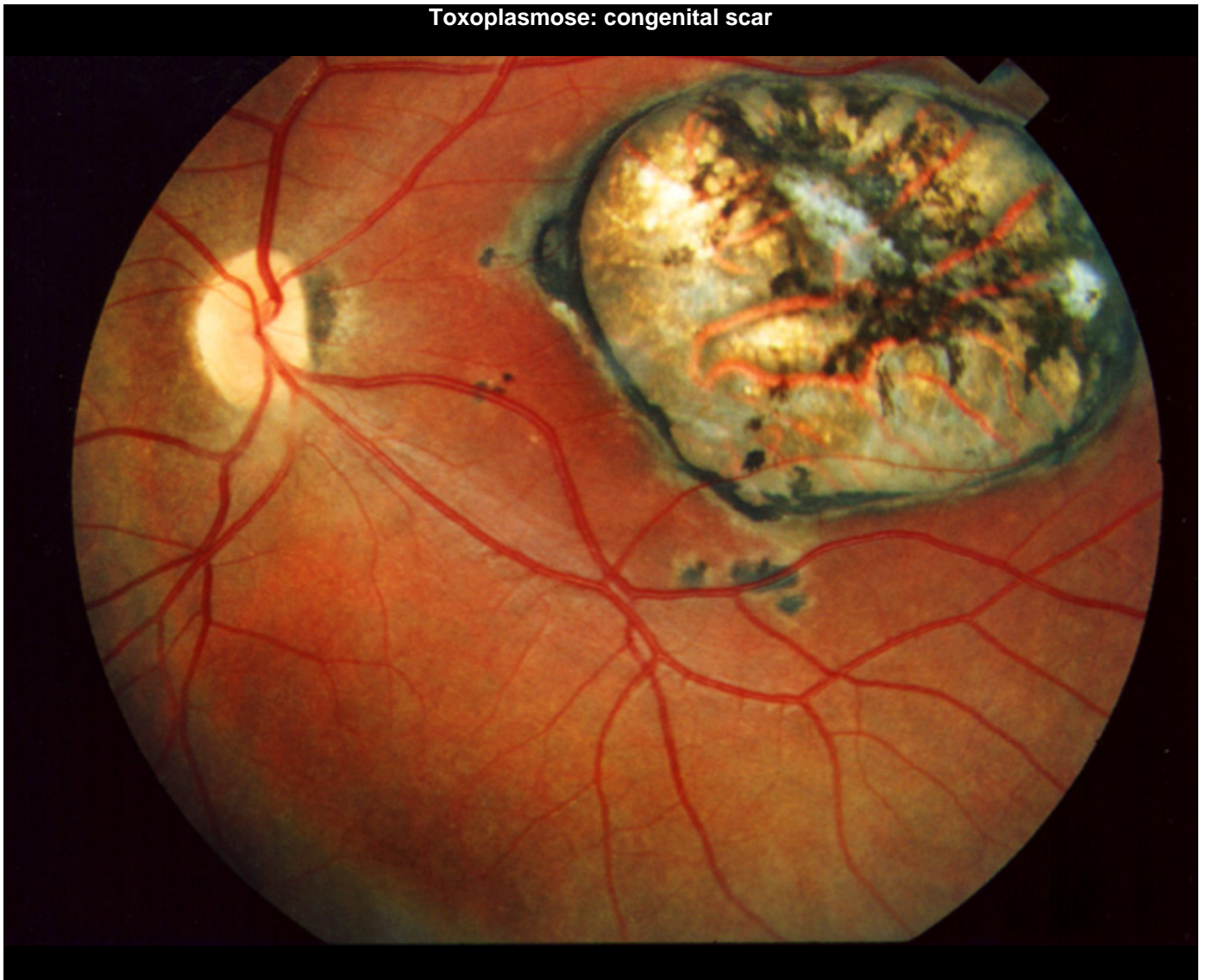


© Copyright [Oculisti OnLine](http://www.eyeatlas.com)

EyeAtlas

The online Atlas of Ophthalmology

Toxoplasmosis: congenital scar

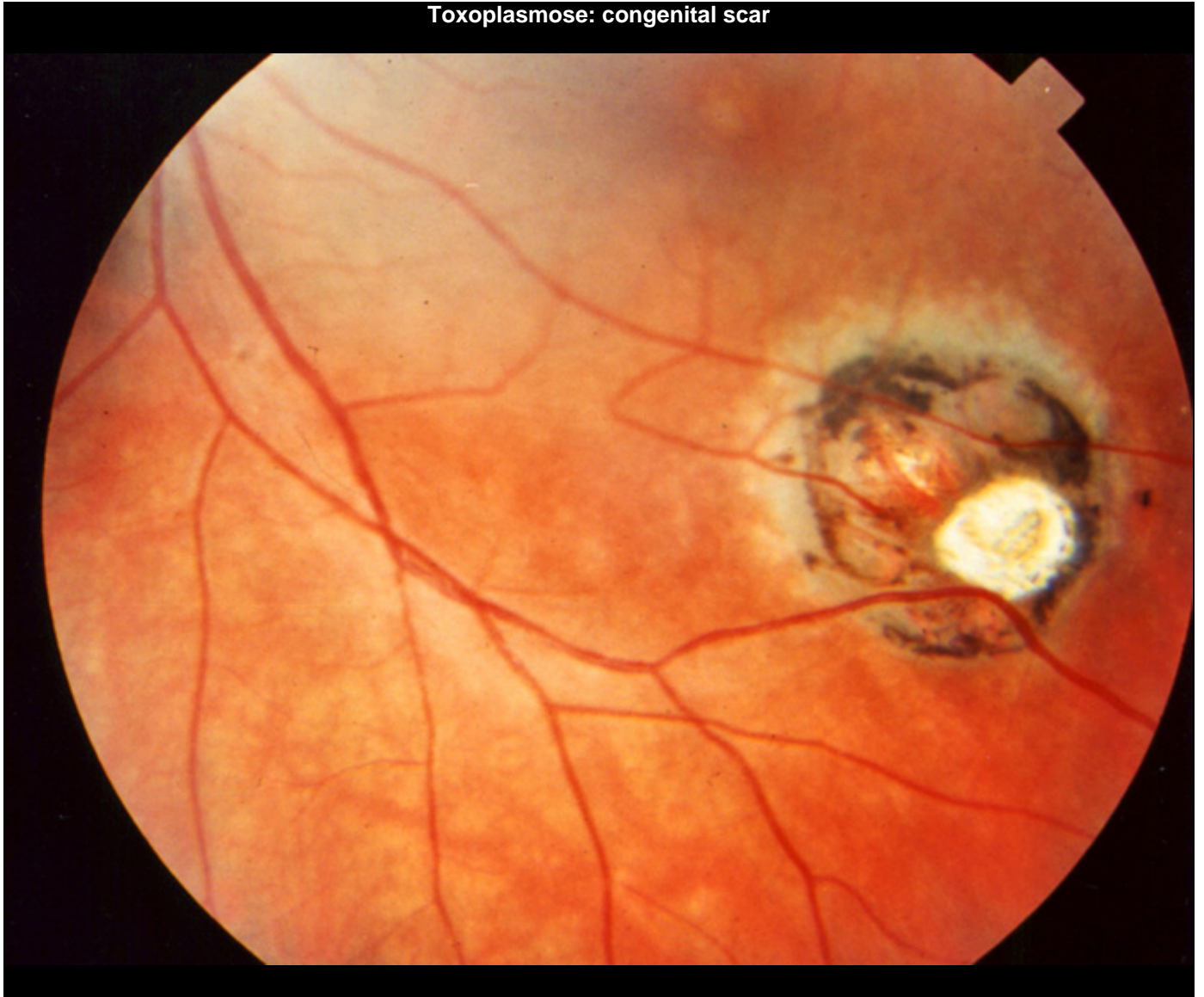


© Copyright [Oculisti OnLine](http://www.eyeatlas.com)

EyeAtlas

The online Atlas of Ophthalmology

Toxoplasmosis: congenital scar

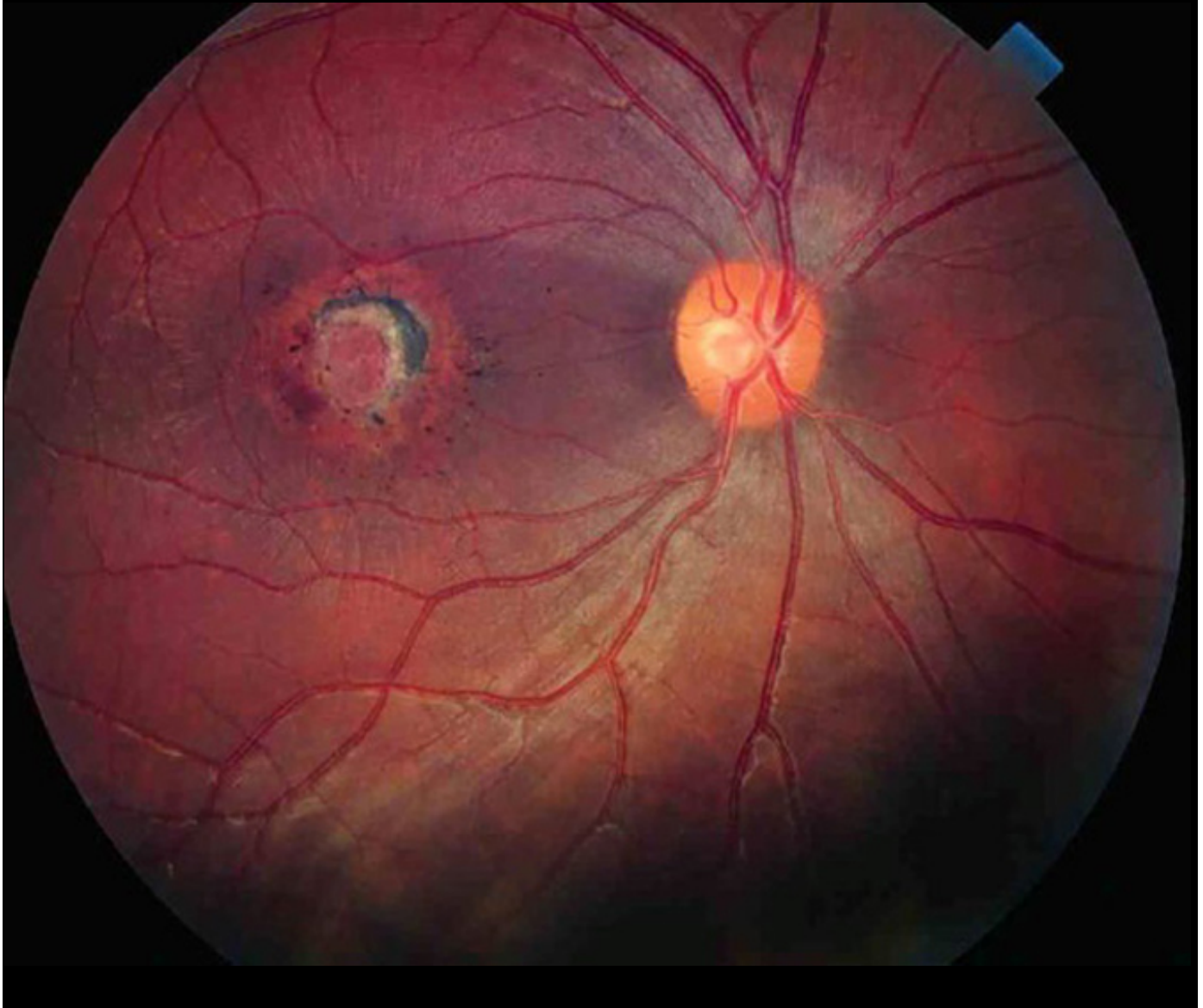


© Copyright [Oculisti OnLine](http://www.eyeatlas.com)

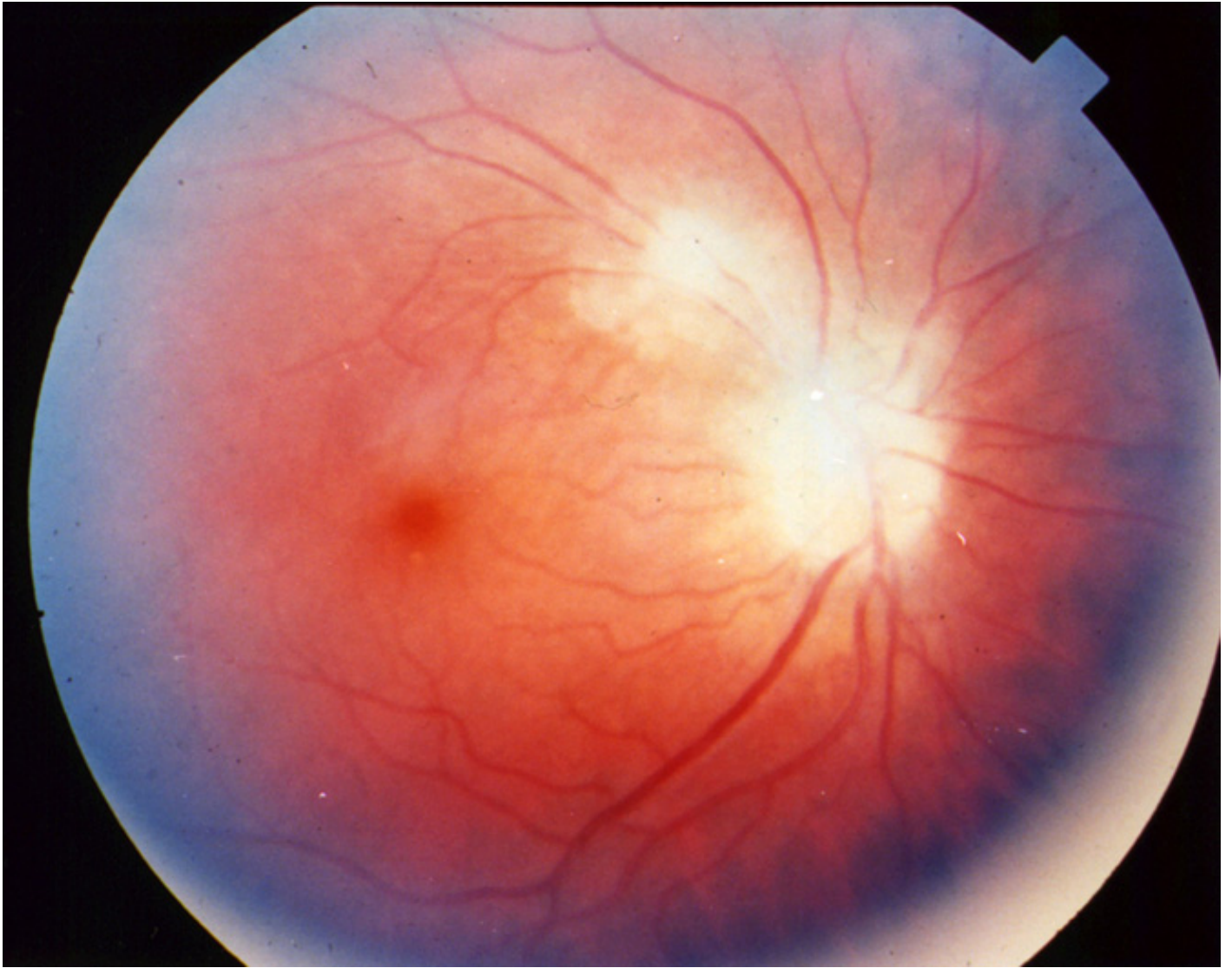
EyeAtlas

The online Atlas of Ophthalmology

Congenital toxoplasmosis



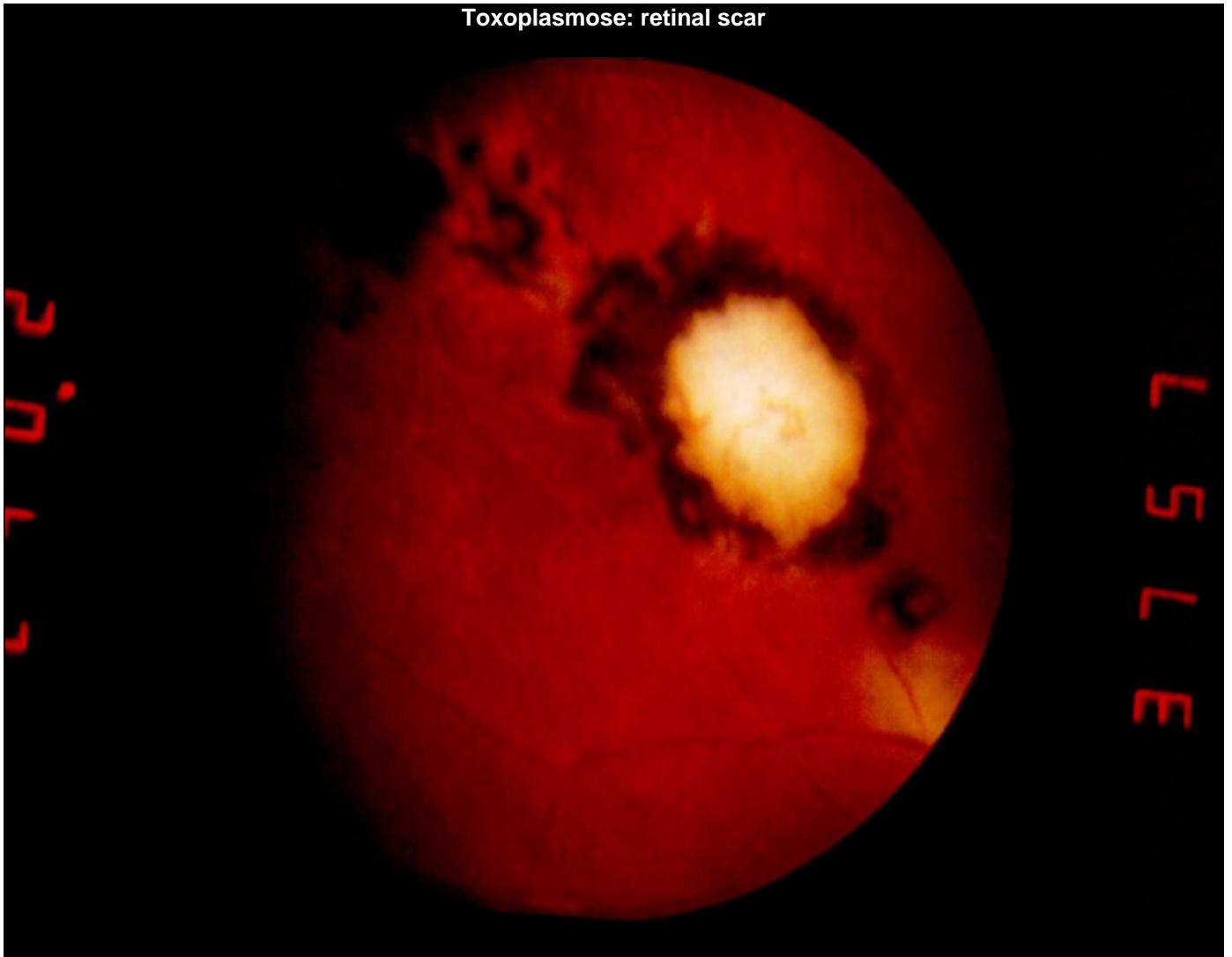
© Copyright [Oculisti OnLine](#)



EyeAtlas

The online Atlas of Ophthalmology

Toxoplasmosis: retinal scar

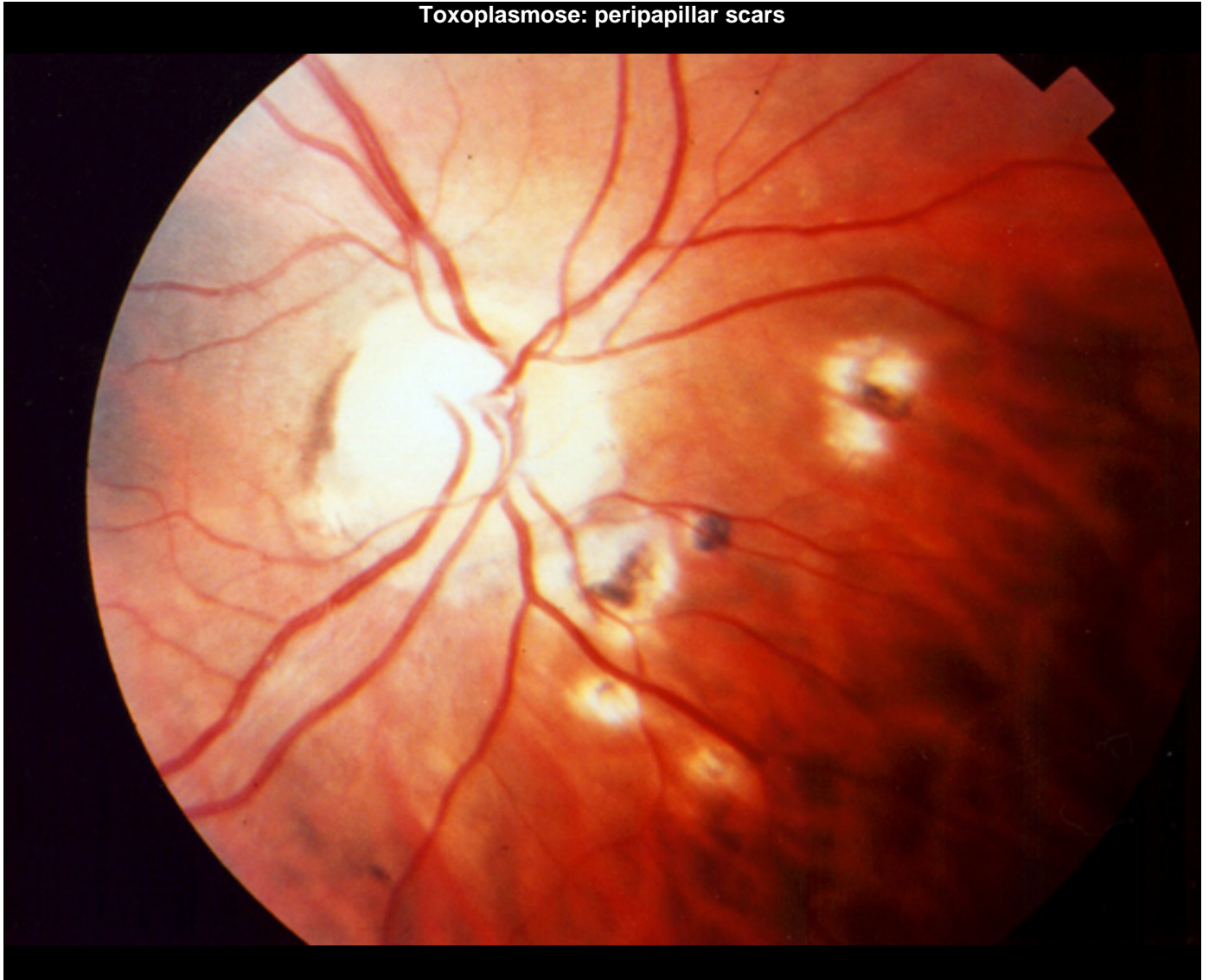

© Copyright [Oculisti OnLine](#)

EyeAtlas

The online Atlas of Ophthalmology

Toxoplasmosis: peripapillary scars

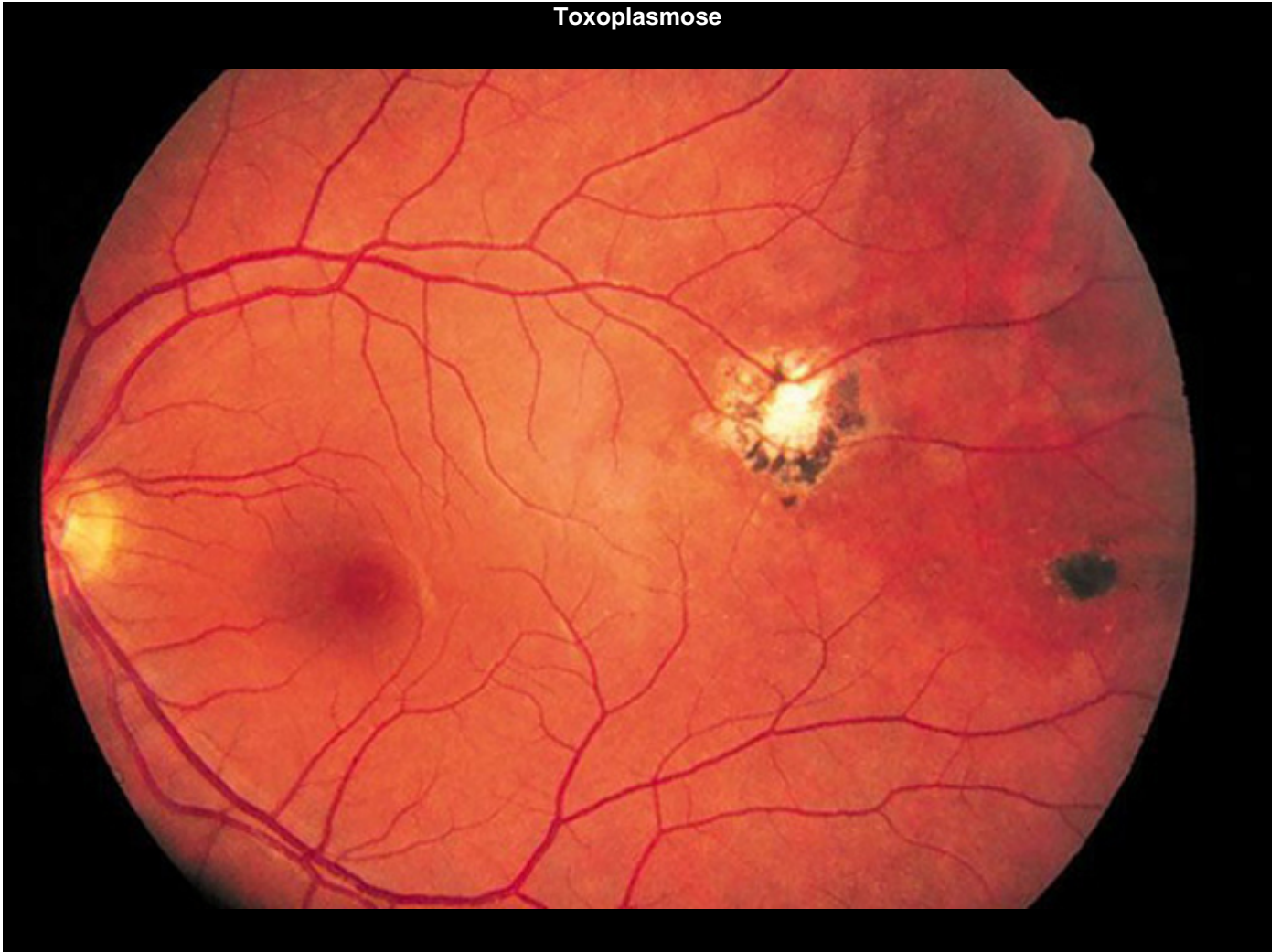


© Copyright [Oculisti OnLine](http://www.eyeatlas.com)

EyeAtlas

The online Atlas of Ophthalmology

Toxoplasmose

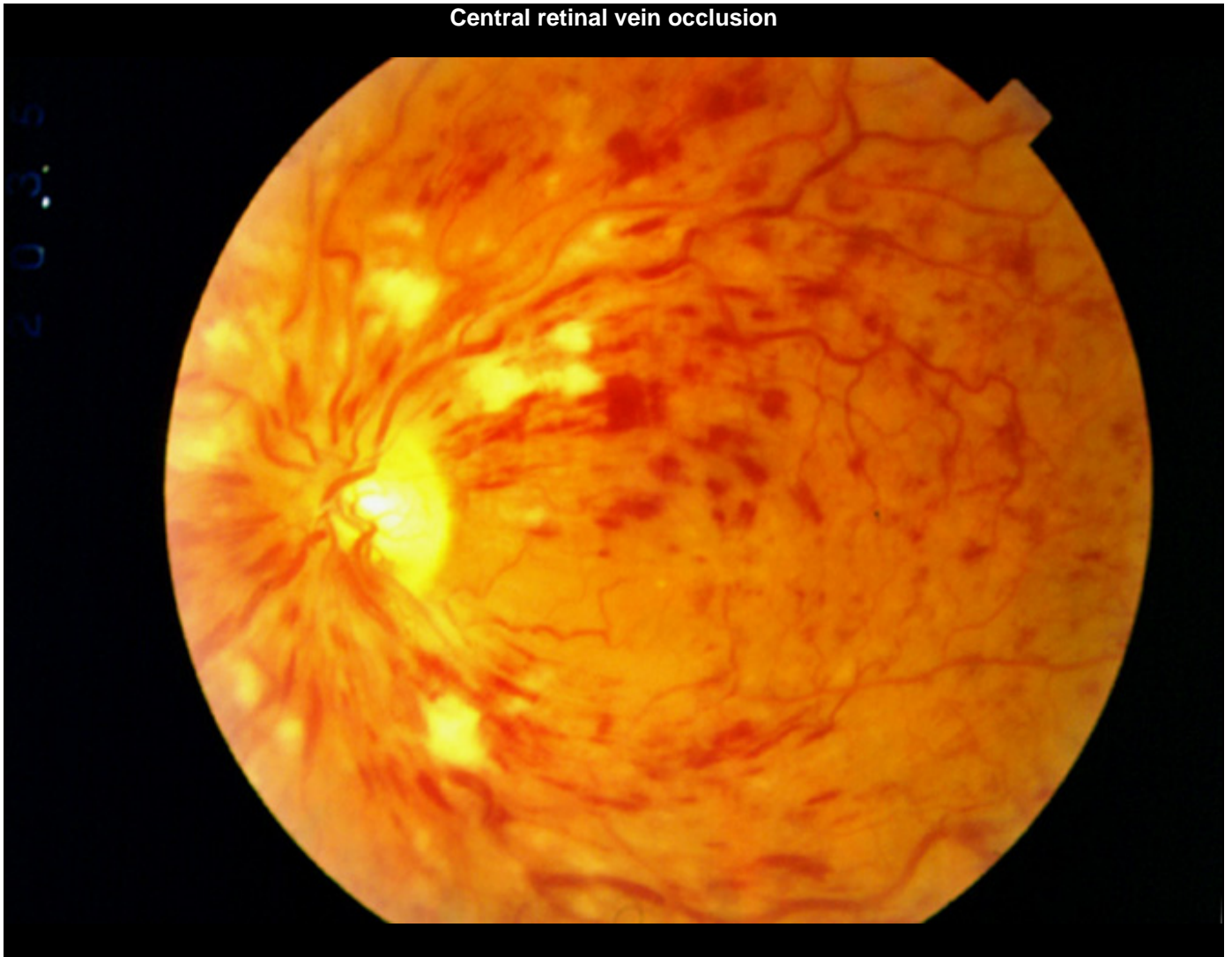


© Copyright [Oculisti OnLine](#)

EyeAtlas

The online Atlas of Ophthalmology

Central retinal vein occlusion

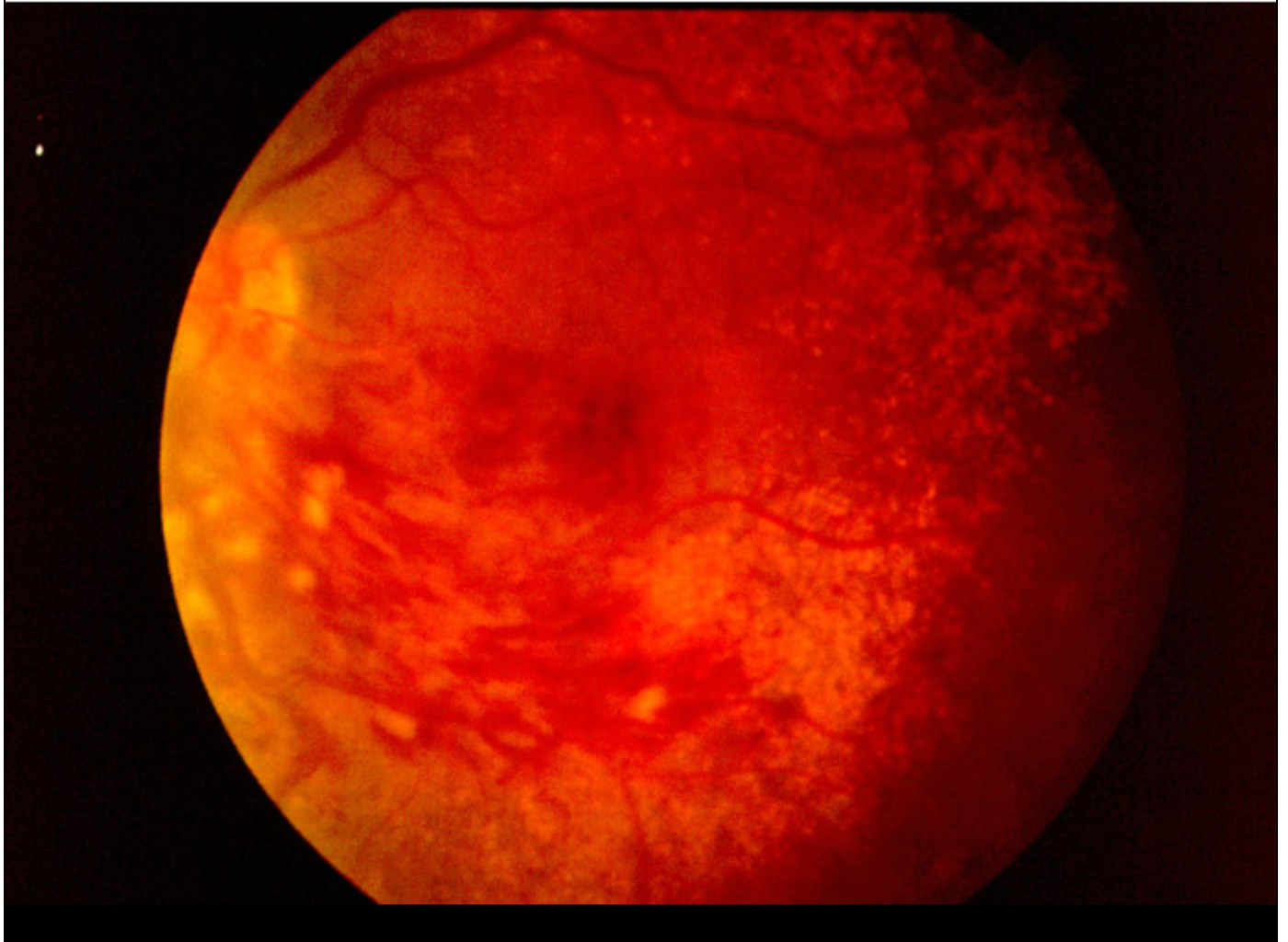


© Copyright [Oculisti OnLine](#)

Eyeatlas

The online Atlas of Ophthalmology

Vein branch occlusion

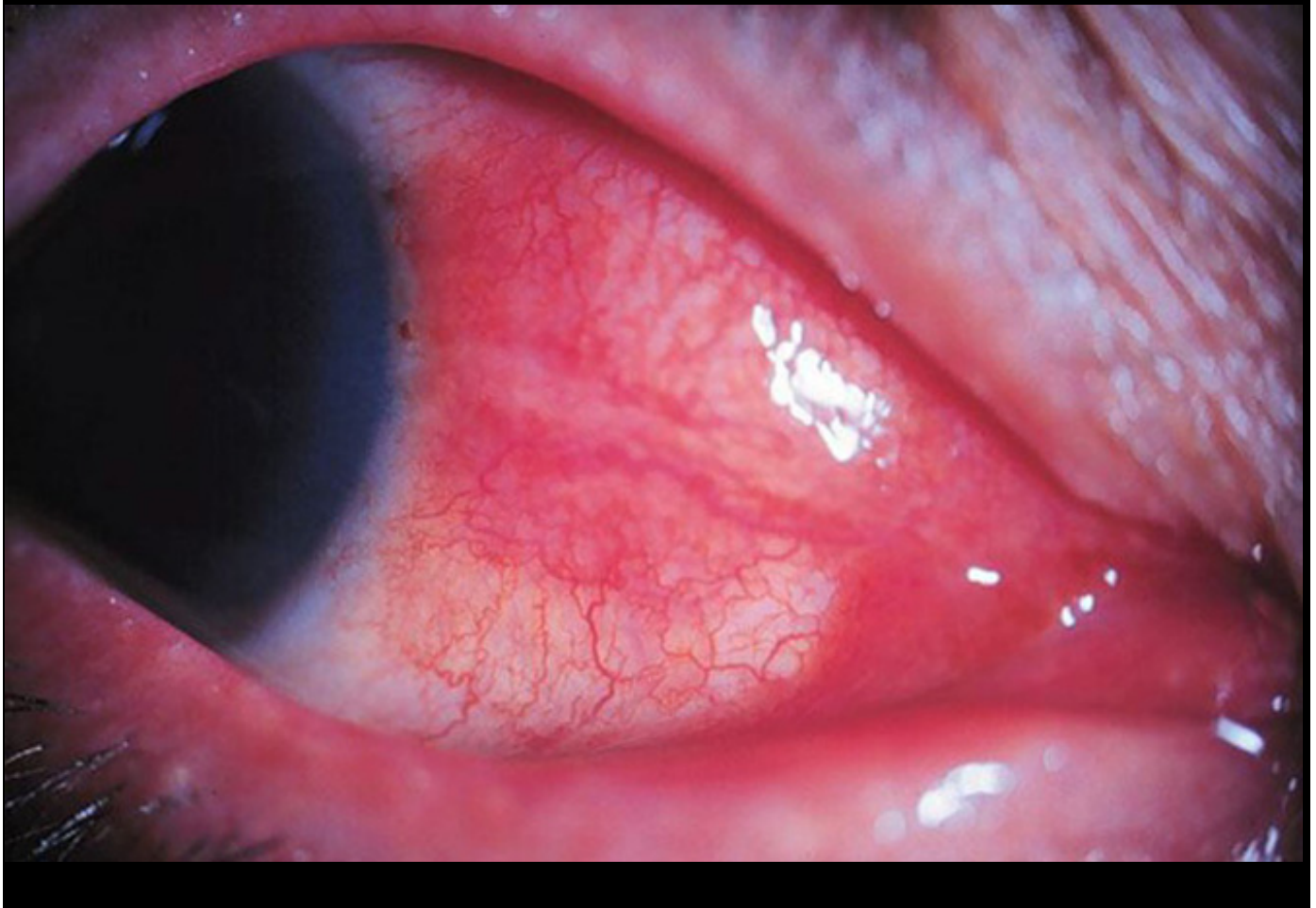


© Copyright [Oculisti OnLine](#)

EyeAtlas

The online Atlas of Ophthalmology

Diffuse episcleritis

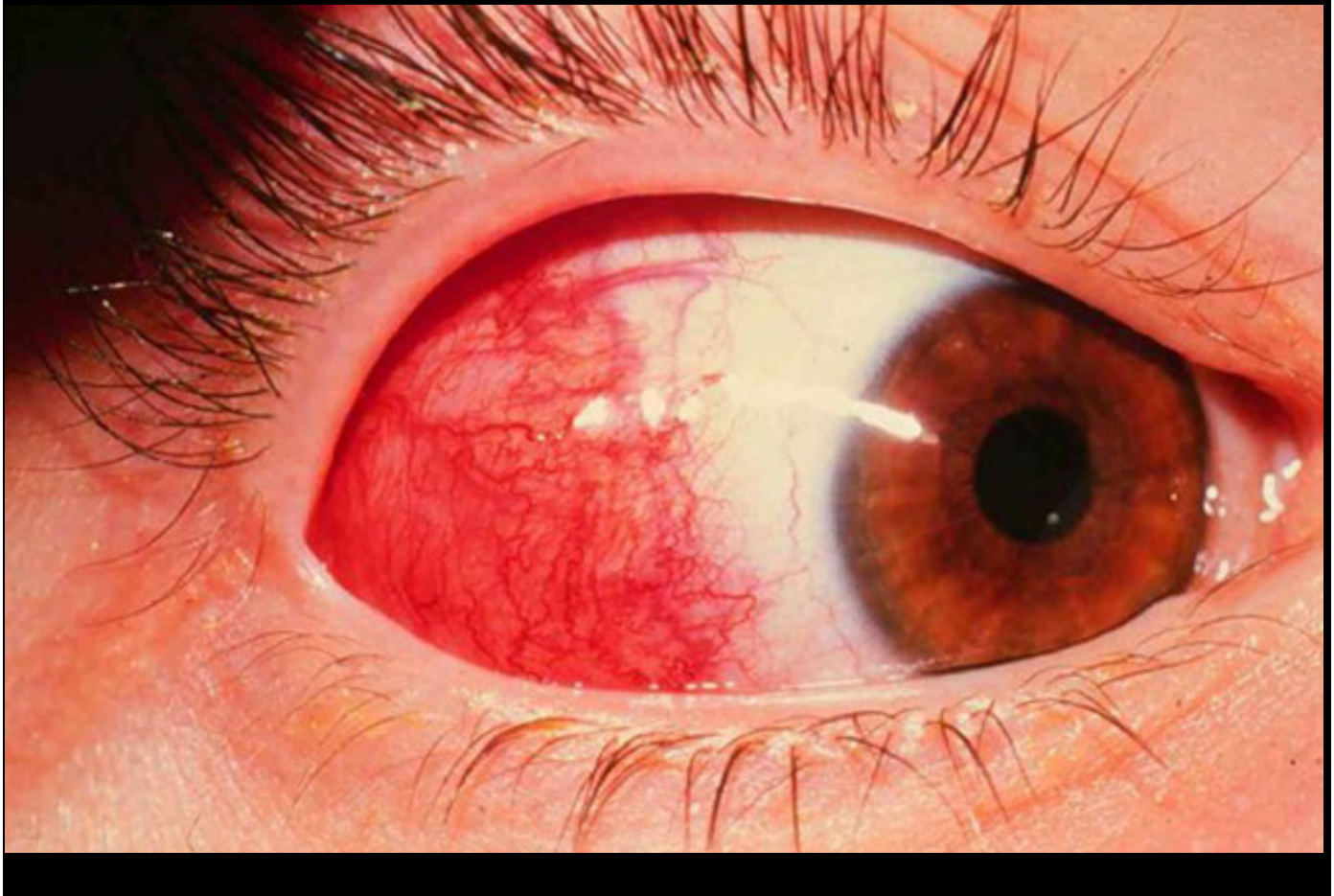


© Copyright [Oculisti OnLine](#)

EyeAtlas

The online Atlas of Ophthalmology

Diffuse episcleritis

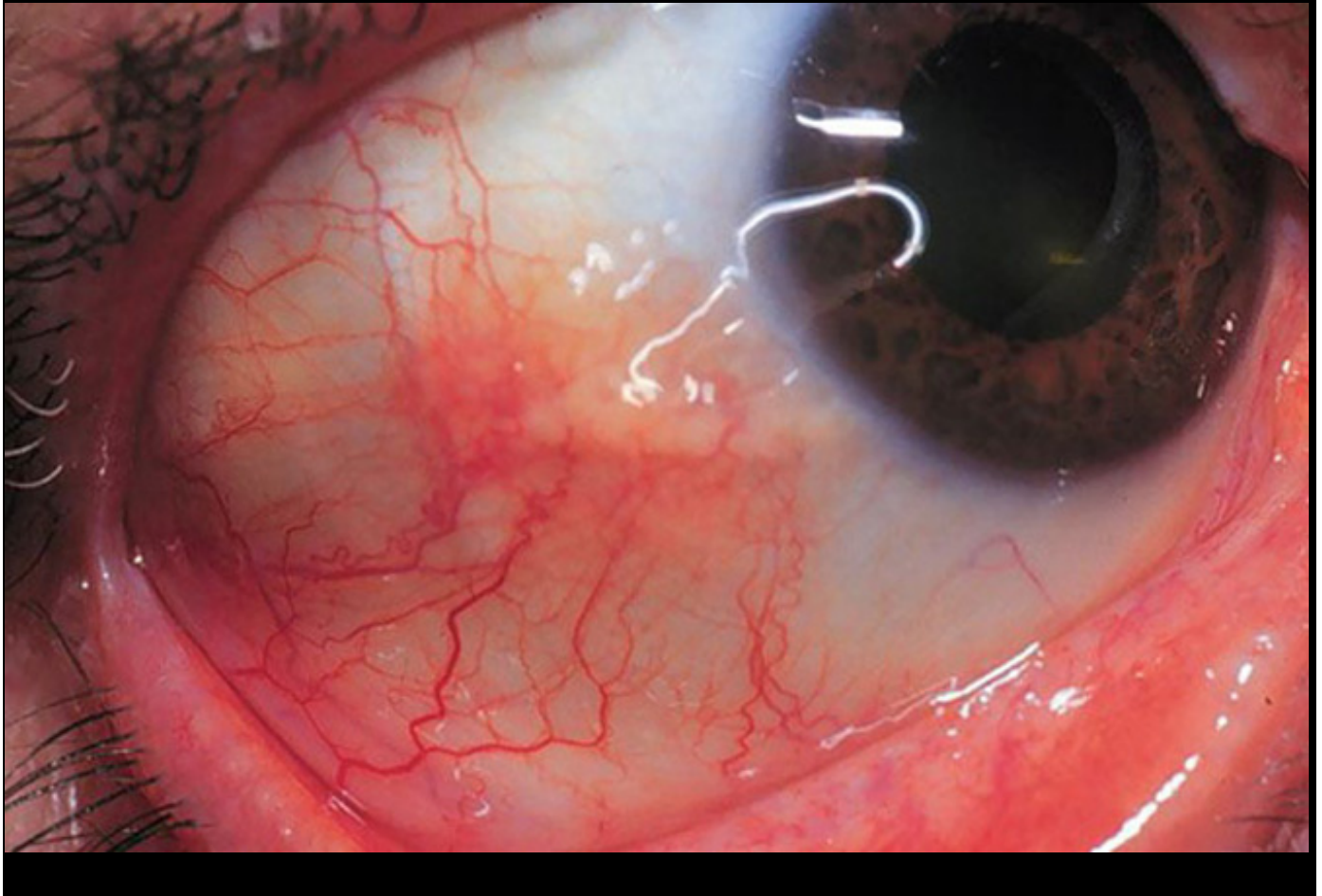


© Copyright [Oculisti OnLine](http://www.eyeatlas.com)

EyeAtlas

The online Atlas of Ophthalmology

Nodular episcleritis

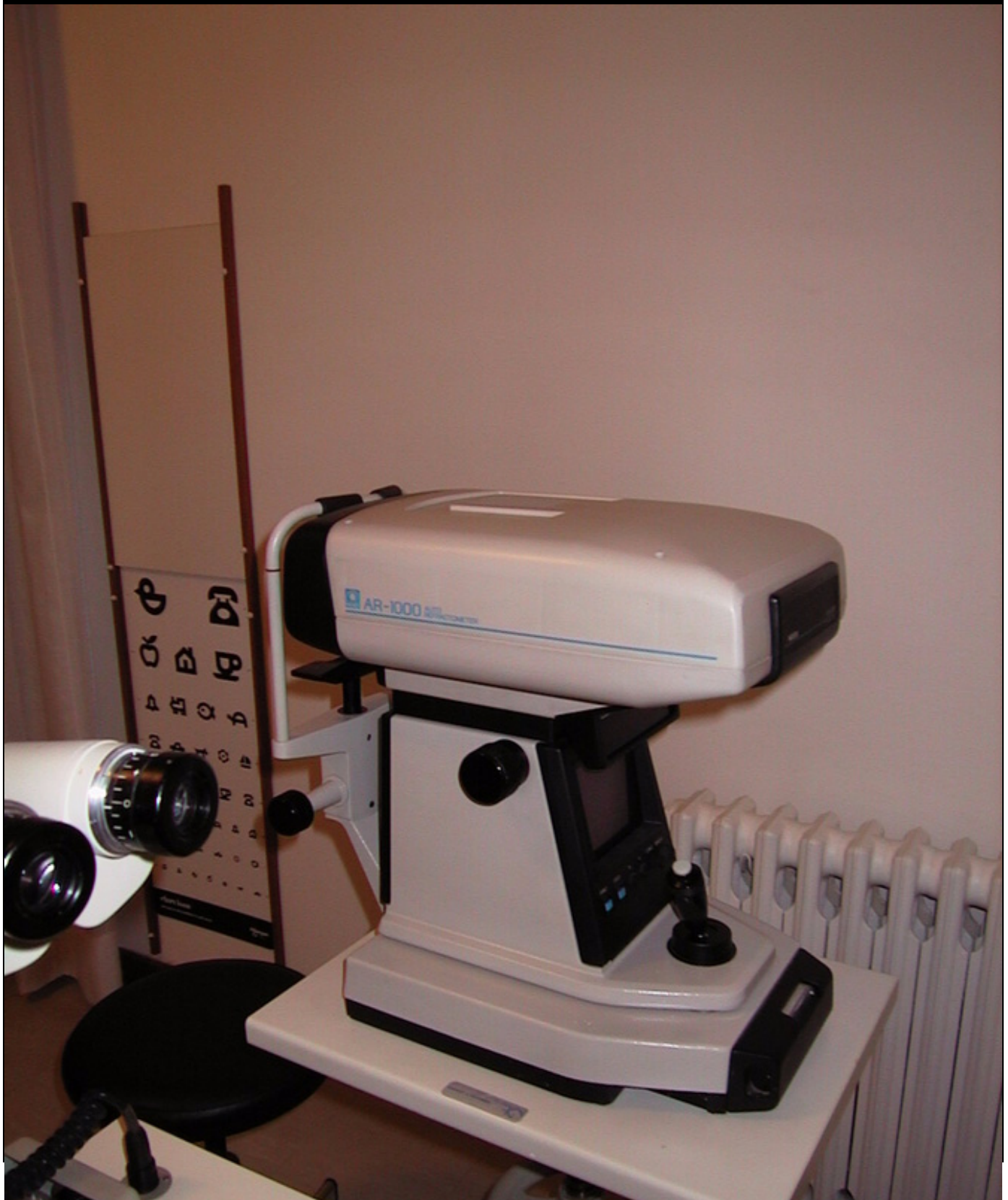

© Copyright [Oculisti OnLine](http://www.eyeatlas.com)

Eyeatlas

The online Atlas of Ophthalmology

Autorefractor





© Copyright [Oculisti OnLine](#)

Eyeatlas

The online Atlas of Ophthalmology

Computerized corneal map

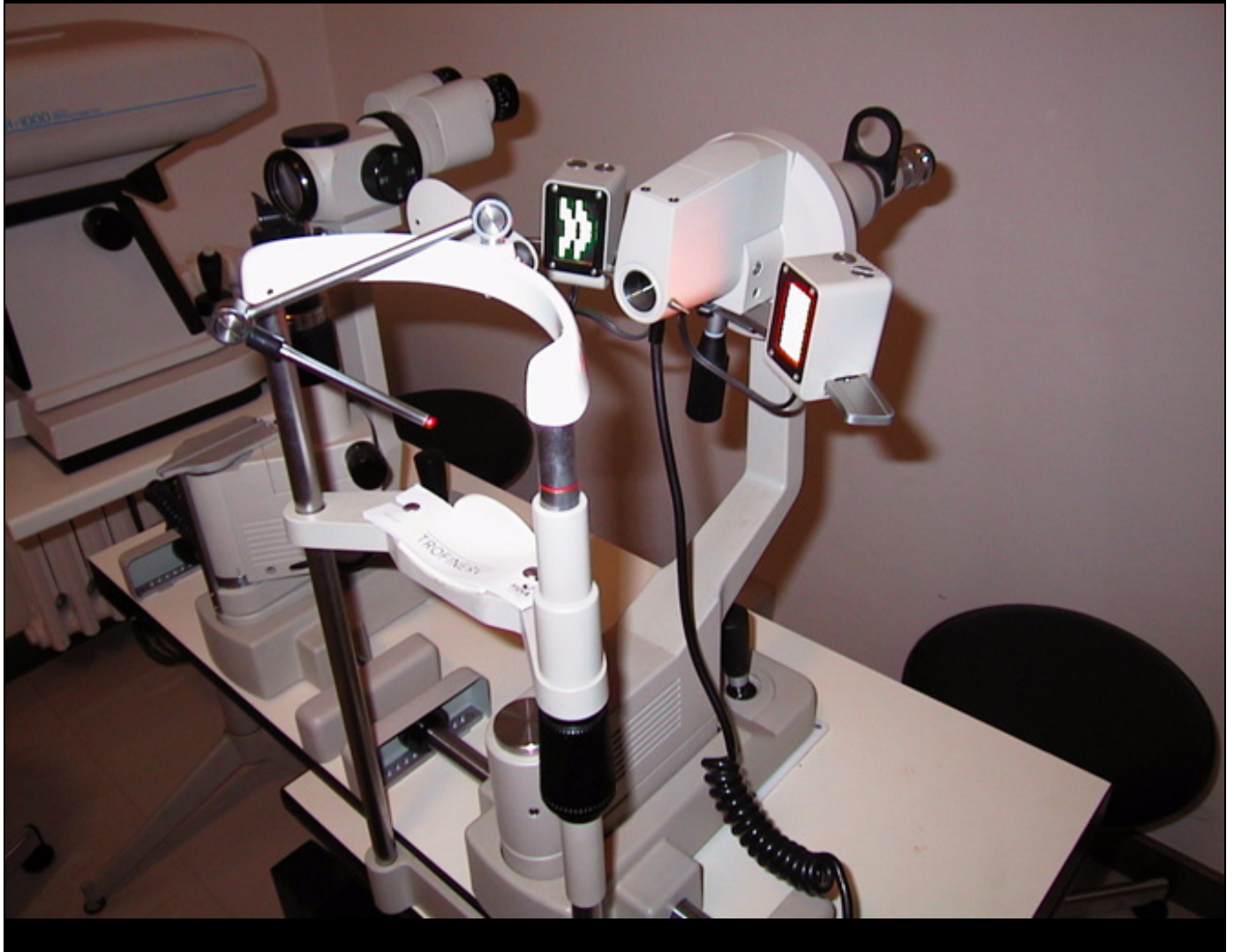

© Copyright [Oculisti OnLine](http://www.eyeatlas.com)

Eyeatlas

The online Atlas of Ophthalmology

Javal ophthalmometer

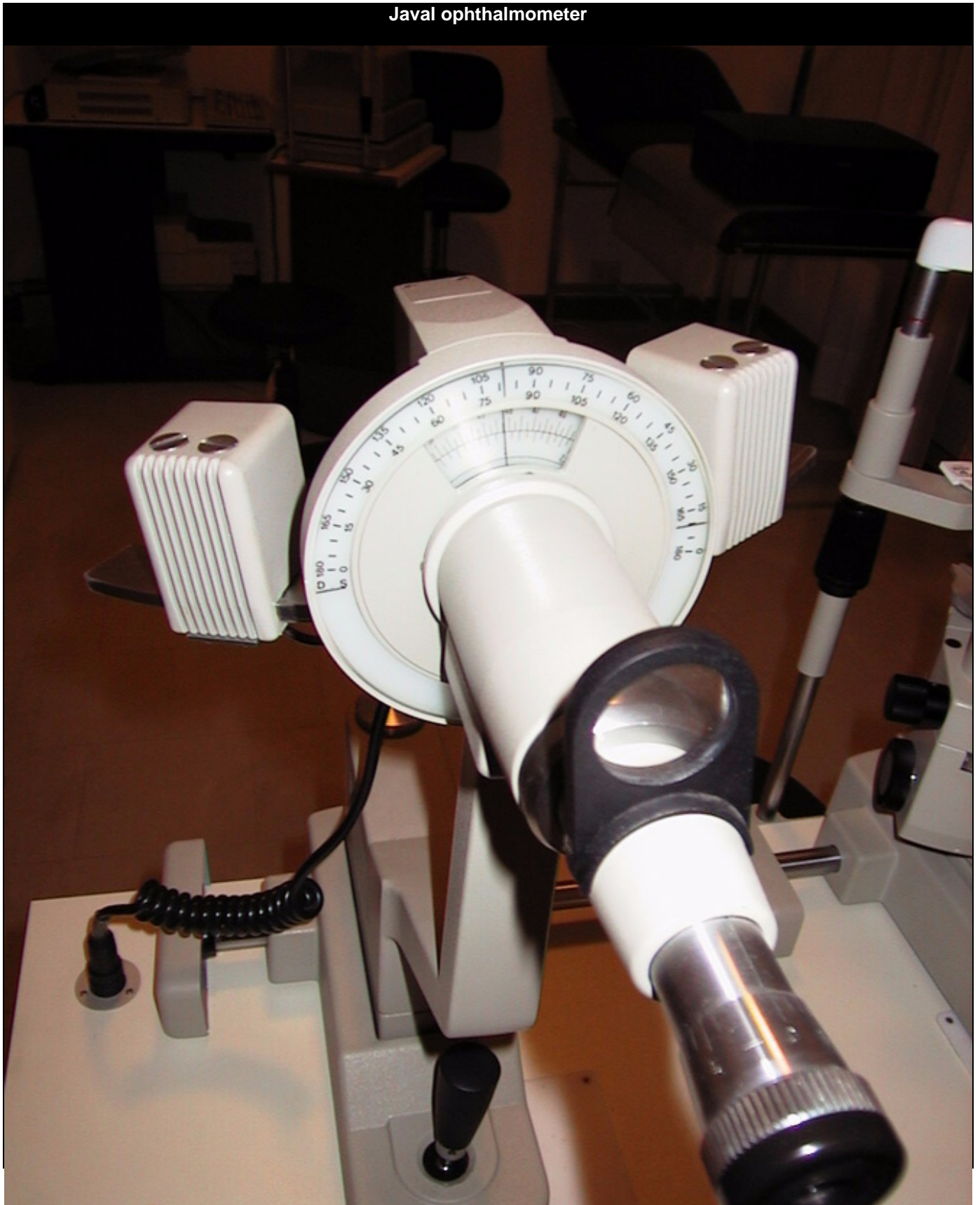



© Copyright [Oculisti OnLine](#)

Eyeatlas

The online Atlas of Ophthalmology

Javal ophthalmometer



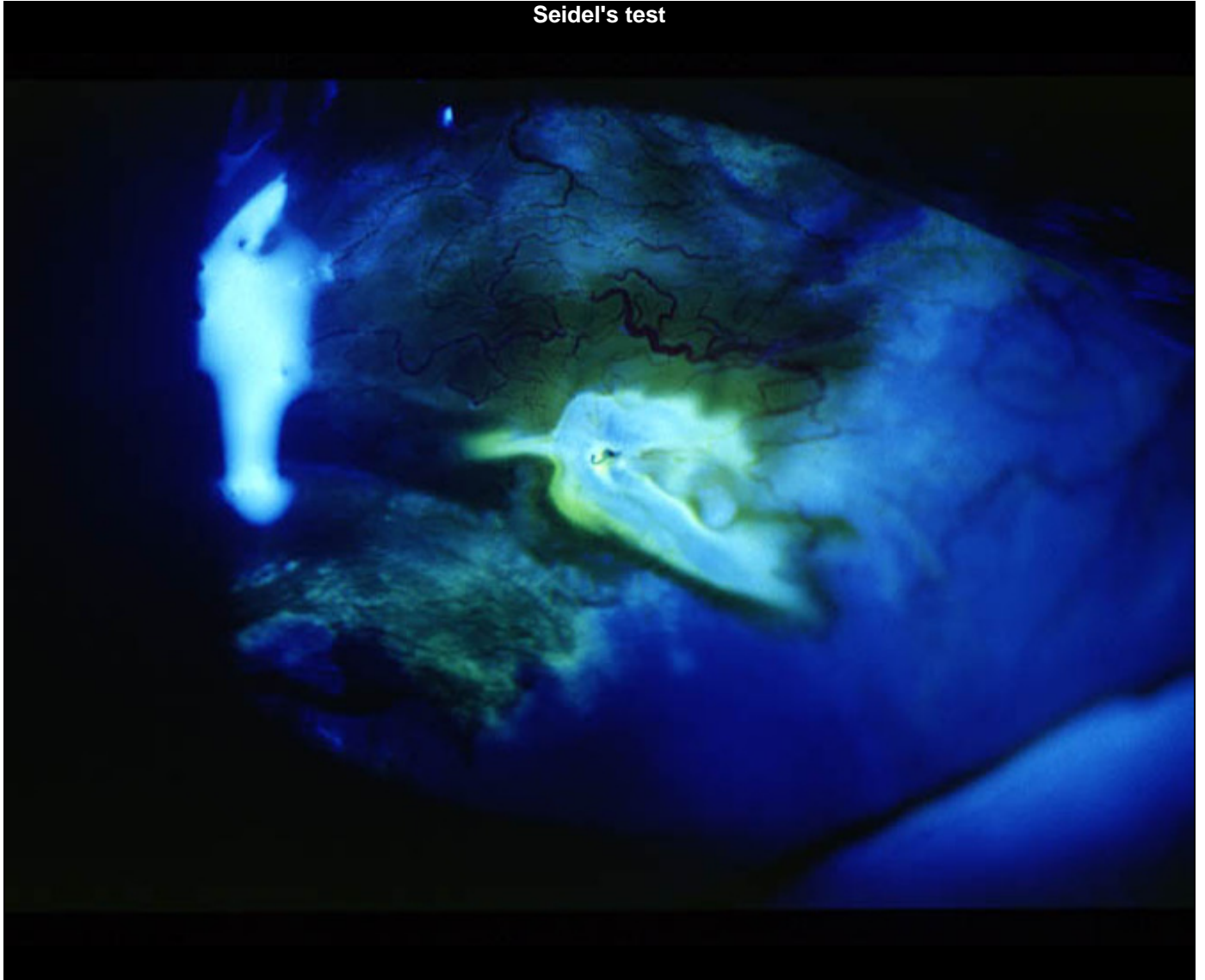


© Copyright [Oculisti OnLine](#)

EyeAtlas

The online Atlas of Ophthalmology

Seidel's test



© Copyright [Oculisti OnLine](#)

EyeAtlas

The online Atlas of Ophthalmology

Slit lamp

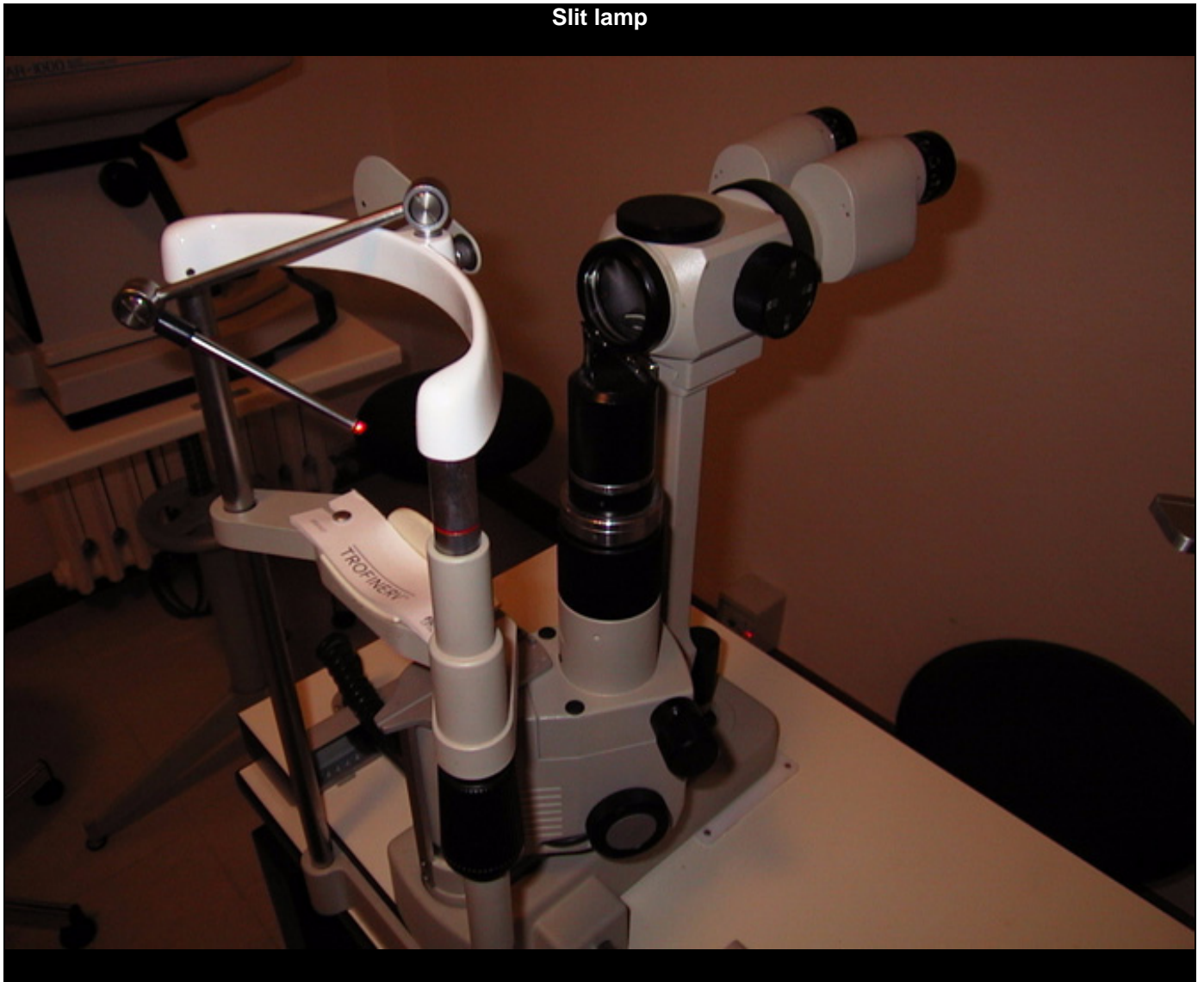

© Copyright [Oculisti OnLine](#)

EyeAtlas

The online Atlas of Ophthalmology

Slit lamp

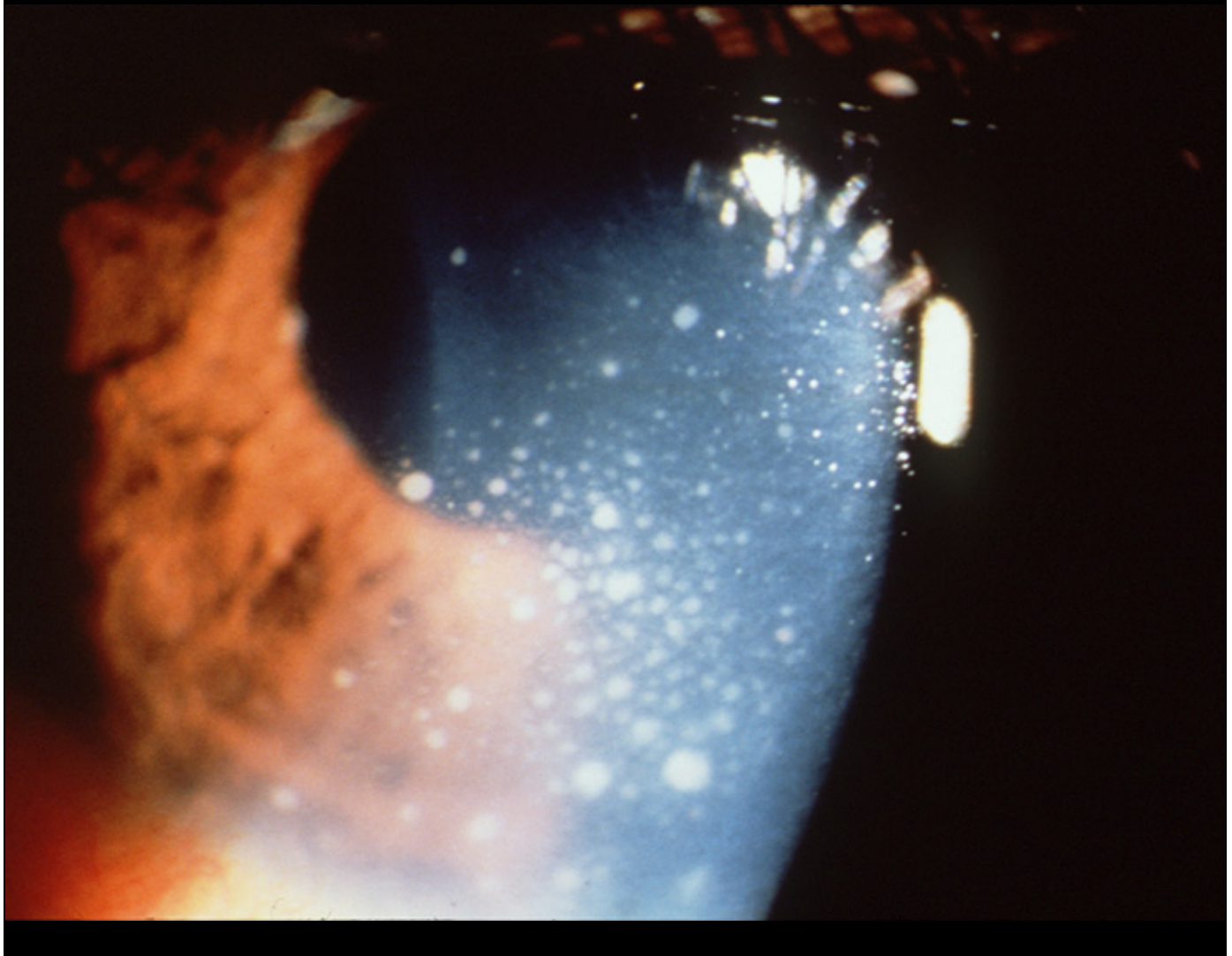


© Copyright [Oculisti OnLine](#)

EyeAtlas

The online Atlas of Ophthalmology

Iridocyclitis, corneal deposits and Busacca's nodules

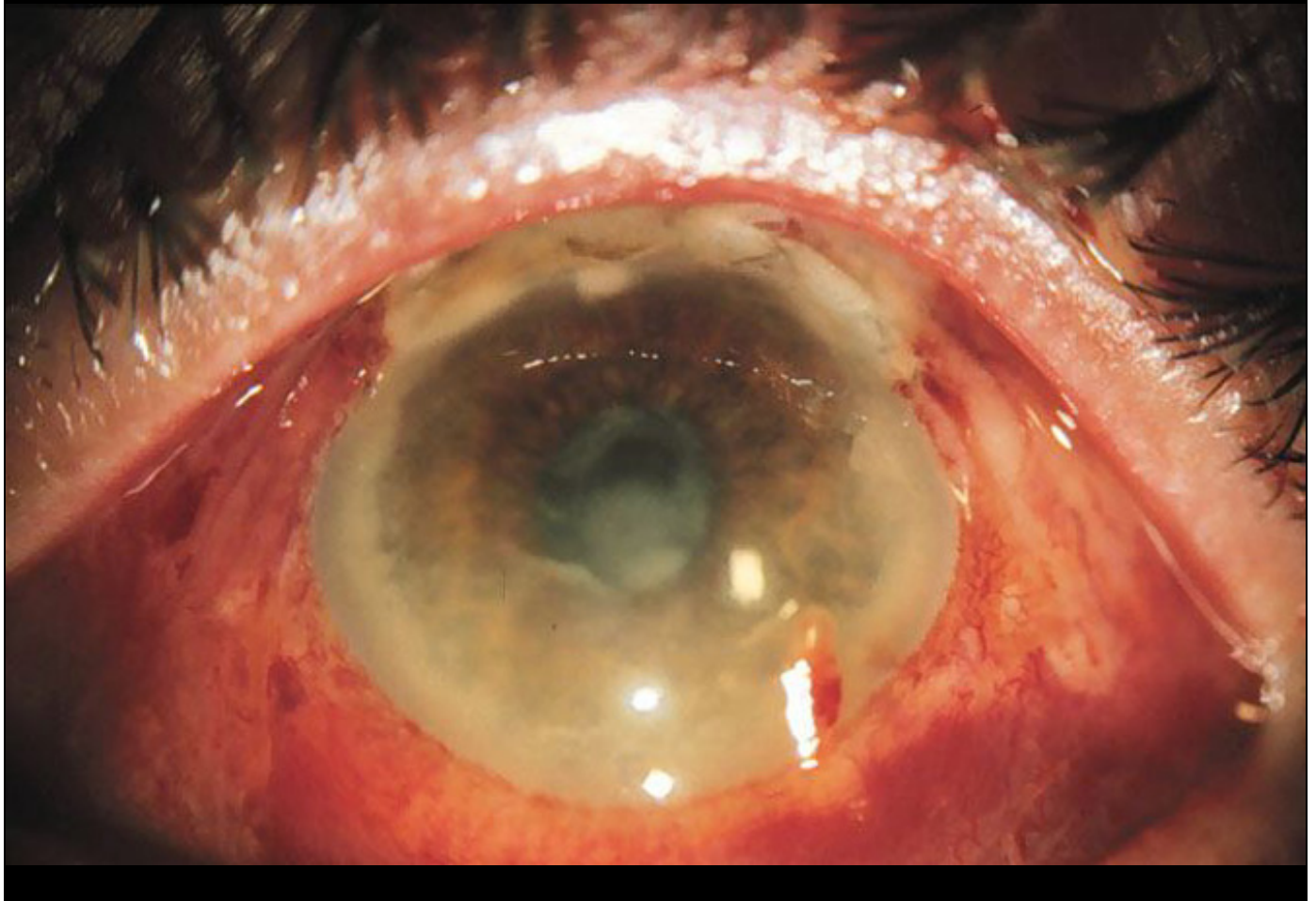


© Copyright [Oculisti OnLine](http://www.eyeatlas.com)

EyeAtlas

The online Atlas of Ophthalmology

Postsurgical endophthalmitis: Pneumococcus

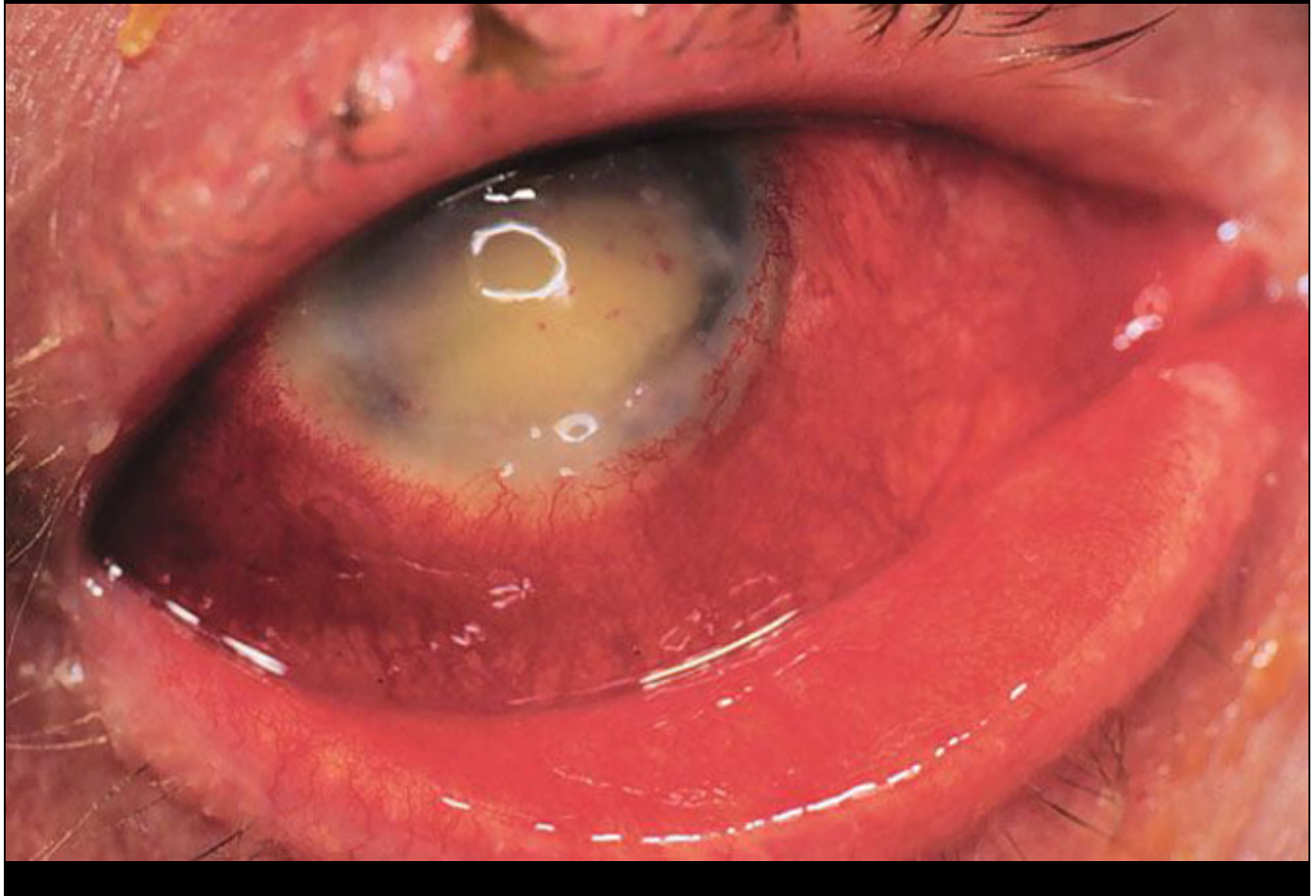

© Copyright [Oculisti OnLine](#)

EyeAtlas

The online Atlas of Ophthalmology

Postsurgical endophthalmitis: Pseudomonas

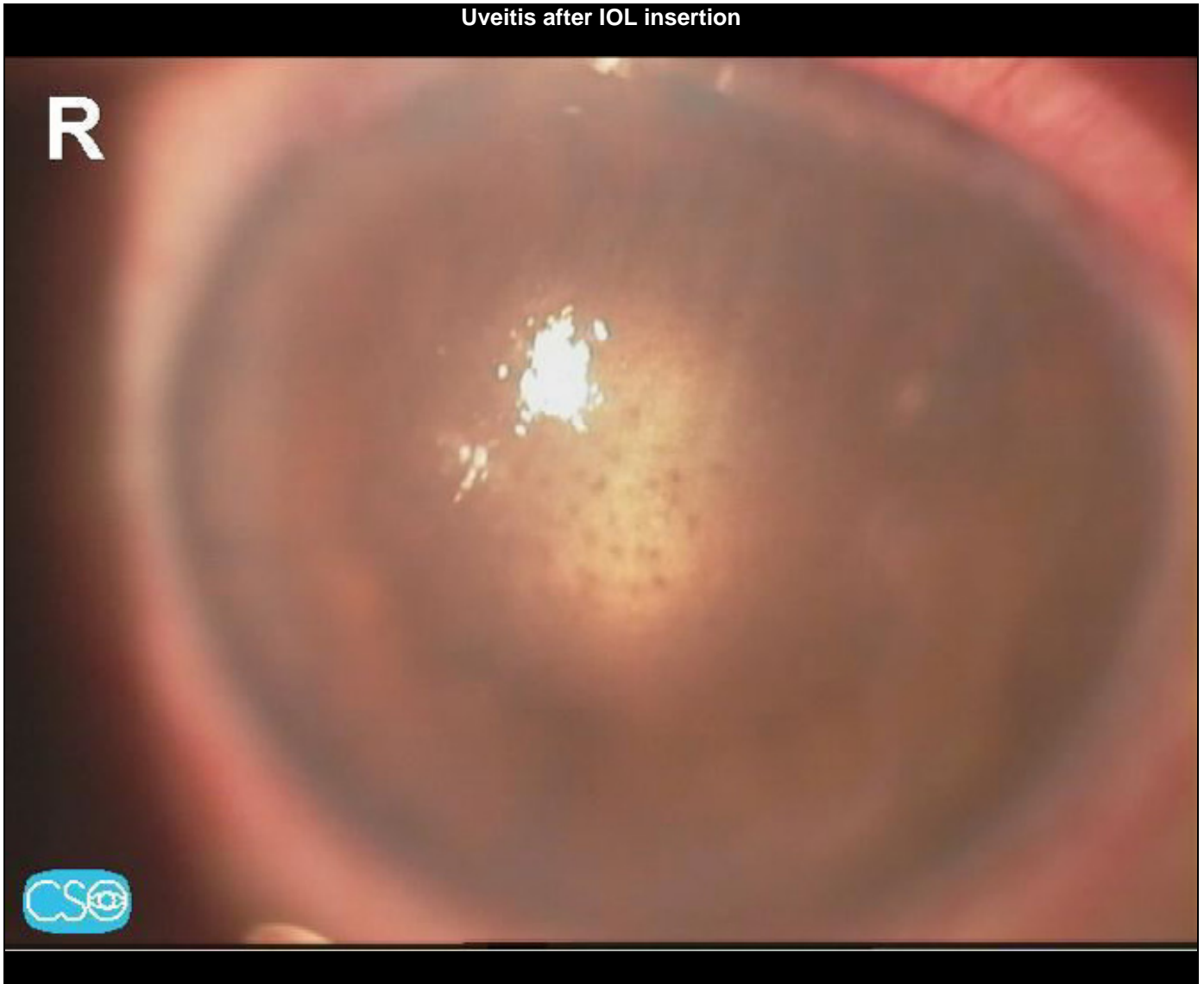

© Copyright [Oculisti OnLine](#)

EyeAtlas

The online Atlas of Ophthalmology

Uveitis after IOL insertion

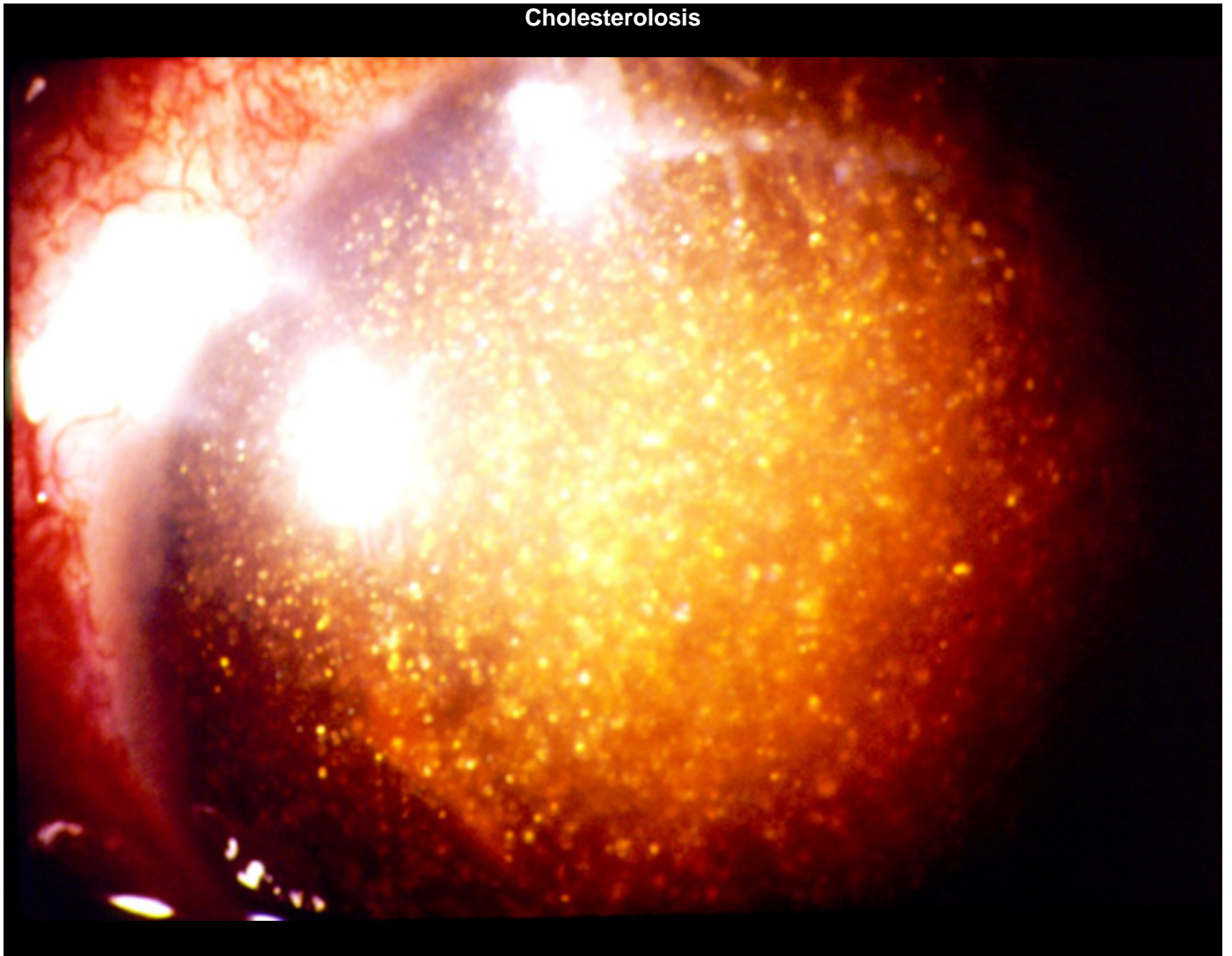


© Copyright [Oculisti OnLine](http://www.eyeatlas.com)

Eyeatlas

The online Atlas of Ophthalmology

Cholesterolosis

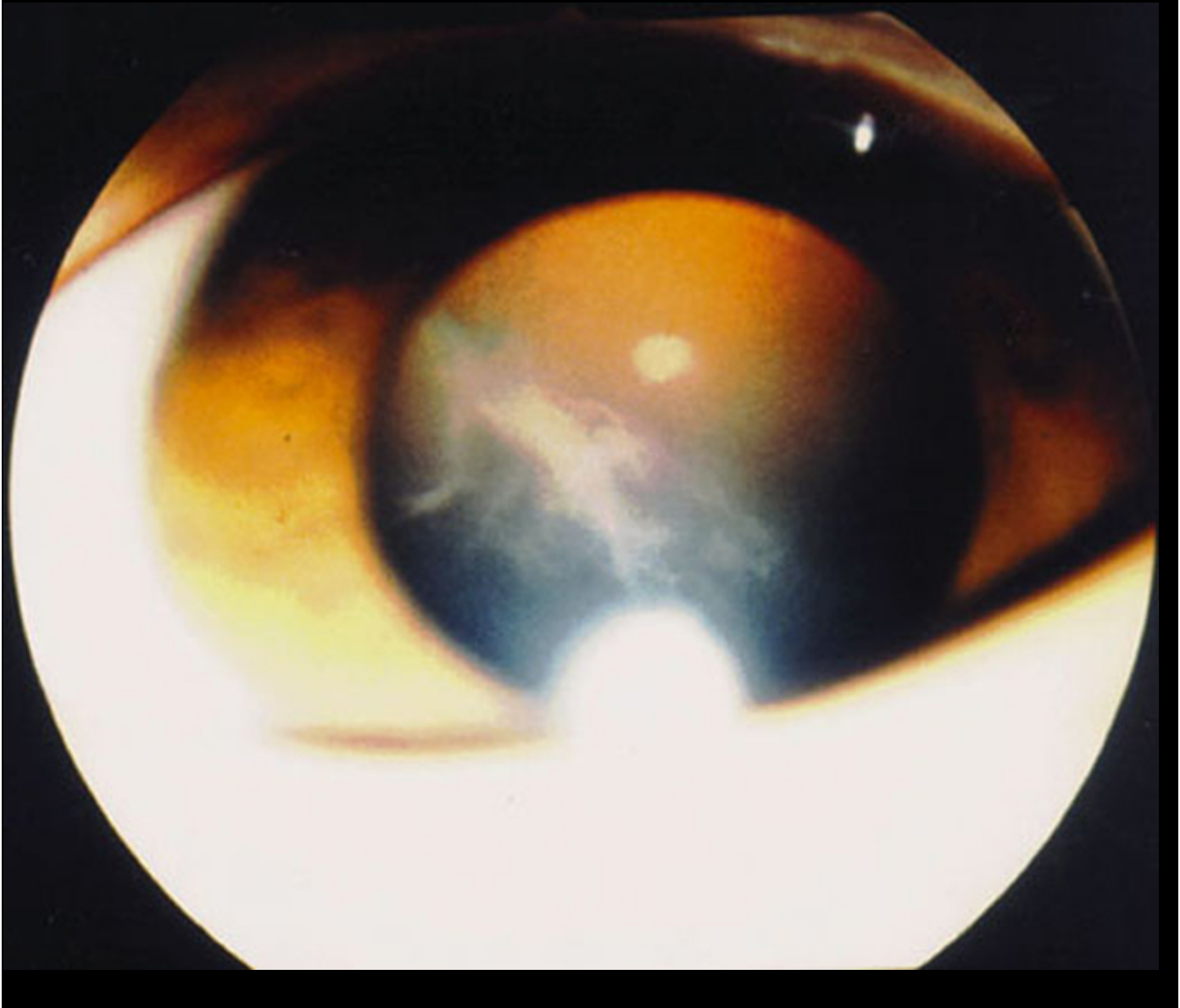


© Copyright [Oculisti OnLine](#)

Eyeatlas

The online Atlas of Ophthalmology

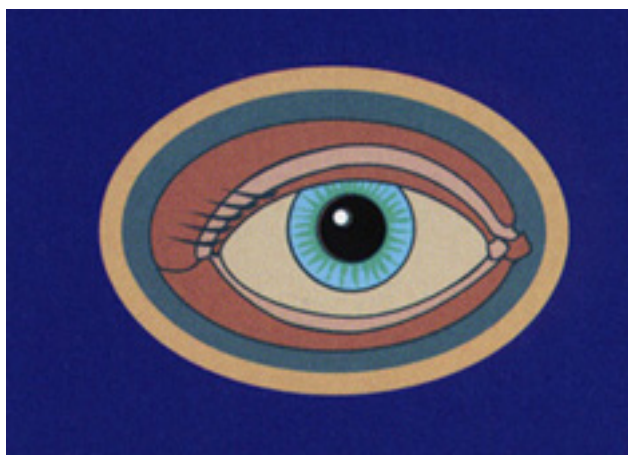
Vitreitis



© Copyright Oculisti OnLine

Eyeatlas

The online Atlas of Ophthalmology



The aim of this site is to furnish to all doctors and ophthalmologists some ophthalmological images useful to prepare congresses, lectures, books, etc.

Best viewed with 1024 x 768 resolution

People can download and use all this images free of charge. Everyone is invited to send good quality images to oculista@inwind.it

The images published on this site have been sent by various ophthalmologists and have been downloaded by Internet.

© Copyright 2001, All Rights Reserved, Oculisti OnLine