

The Bedside and Office Neuro-ophthalmology Examination

James J. Corbett, M.D.¹

ABSTRACT

The neuro-ophthalmologic examination provides an enormous amount of information about the 40% of fibers that provide afferent and efferent limbs of the visual, pupillary, and ocular motor pathways. A few tools and the correct testing approach will maximize the value of this examination. This chapter provides step-by-step examination methods and points out some of the common errors that are made.

KEYWORDS: Relative afferent pupillary defect, Horner's syndrome, Adies tonic pupil, visual acuity, color vision, Amsler grid, optokinetic nystagmus, ophthalmoscopy, visual fields, saccades, pursuit, hippus, Argyll Robertson pupil, pharmacologic blockade, cocaine test, hydroxyamphetamine test, pseudo-Horner's syndrome

Objectives: Upon completion of this article, the reader will understand the bedside neuro-ophthalmologic examination.

Accreditation: The Indiana University School of Medicine is accredited by the Accreditation Council for Continuing Medical Education to provide continuing medical education for physicians.

Credit: The Indiana University School of Medicine designates this educational activity for a maximum of 1.0 hours in category one credit toward the AMA Physicians Recognition Award. Each physician should claim only those hours of credit that he/she actually spent in the educational activity.

Disclosure: Statements have been obtained regarding the author's relationships with financial supporters of this activity. There is no apparent conflict of interest related to the context of participation of the author of this article.

Most of the neurologic examination can be carried out with a dried codfish.

Joseph Michael Foley, 1971

Although the same cannot be said of the neuro-ophthalmologic examination at the bedside or in the office, it is a low-tech, high-yield process that requires only that the examiner have the right equipment and be systematic in the collection of information. There are three neuro-ophthalmologic examinations that need to be made: the afferent visual pathways, testing of which includes visual acuity, visual fields, color, stereovision,

and the examination of the optic fundus; the efferent pathways of ocular motility, testing of which includes saccade, pursuit, vestibulo-ocular and optokinetic testing, cover-uncover testing, and use of "red glass" or even better the Maddox rod to characterize diplopia; and the afferent and efferent limbs of the pupil are tested with light, to a near stimulus, and occasionally with eyedrops.

What is a well-outfitted neuro-ophthalmologic kit (Fig. 1)? For visual acuity testing use a near card (Rosenbaum is preferred; Figs. 1 and 2), and this may be augmented by a pair of 2 to 3+ drugstore reading glasses or "readers" for people who have left their reading glasses at home. A couple of spools of red dye lot-matched

Neurological Office Procedures; Editor in Chief, Karen L. Roos, M.D.; Guest Editor, Karen L. Roos, M.D. *Seminars in Neurology*, Volume 23, Number 1, 2003. Address for correspondence and reprint requests: James J. Corbett, M.D., University of Mississippi Medical Center, Department of Neurology, 2500 North State Street, Jackson, MS 39216. ¹McCarty Professor and Chairman of Neurology, Professor of Ophthalmology, University of Mississippi Medical Center, Department of Neurology, Jackson, Mississippi. Copyright © 2003 by Thieme Medical Publishers, Inc., 333 Seventh Avenue, New York, NY 10001, USA. Tel: +1(212) 584-4662. 0271-8235,p;2003,23,01,063,076, ftx,en;sin00229x.




Figure 1 (1) Amsler grid; (2) Titmus Stereoacuity Chart and polarized glasses; (3) Ishihara color plates; (4) Rosenbaum near acuity card; (5) ophthalmoscope; (6) Finhoff transilluminator head; (7) colored (red) pompoms; (8) Luedde proptometer; (9) occluder and Maddox Rod; (10) OKN tape.

thread or red “pompoms” can be used for visual field color comparison. The ophthalmoscope should have a well-charged battery. The best eyedrops for pupil dilation are 1% tropicamide (Mydracyl). They dilate the iris in 20 to 40 minutes and wear off in 3 to 4 hours. Stereovision is tested using Titmus Stereoacuity Chart (Figs. 1 and 3). This test requires polarized glasses to achieve a three-dimensional effect. Color vision can be tested with Ishihara color plates or Hardy-Rittler-Rand (HRR) plates (Figs. 1 and 4). In the office, color can be tested with the D-15 or D-28 tests, but for practical clinical purposes the Ishihara or HRR plates are fine. Ocular motility testing only requires a finger and a nose for rapid refixation movements and a finger for pursuit testing. Optokinetic testing can be done with a simple optokinetic nystagmus (OKN) tape (Fig. 1), or in the office an OKN drum can be used. Either is effective, but the tape is cheaper and portable. For pupil testing, a bright halogen filament-free light source is useful. A Finhoff transilluminator head (Fig. 1) or a Welch-Allyn pocket light can be used. Many of the throwaway free drug company hand lights have a filament shadow that gives uneven illumination.

TESTING THE AFFERENT VISUAL SYSTEM

Visual Acuity

Visual acuity can be considered as a set of visual functions that include high contrast “Snellen” acuity, variable-contrast (contrast sensitivity) visual acuity, color

visual acuity, and stereo visual acuity. Bedside testing of conventional high-contrast visual acuity needs to be done in a well-lighted setting using a Rosenbaum handheld near card (Fig. 1) and the patient’s best spectacle correction (their glasses). If their reading glasses are not available, it is worthwhile to have a pair of 2 to 3+ reading glasses (obtainable at a drugstore) in your bag to use for more accurate near visual acuity. The most difficult part of the neuro-ophthalmologic examination is trying to obtain an accurate visual acuity. Most neurologists simply hand the near acuity card to the patient and then record the line the patient says he or she can read as their best acuity. The patient needs to be actively urged to try to read the smaller numbers even if they appeared blurred. Patients frequently think they are “cheating” if the images they read are not clear. It is common for a patient to read 20/50 and announce that that is the best they can do, only to be encouraged to read on down to the 20/20 line with some forward/backward adjustment of the card. If they balk simply tell them to guess at the numbers or provide them the first number on the line in question. Each number has a one in nine chance of being correct.

Color Vision

Color testing is performed one eye at a time. It is done with the knowledge that men are more likely to be red-green color-blind than women; 6 to 7% of men and 0.5% of women have some color deficiency ranging

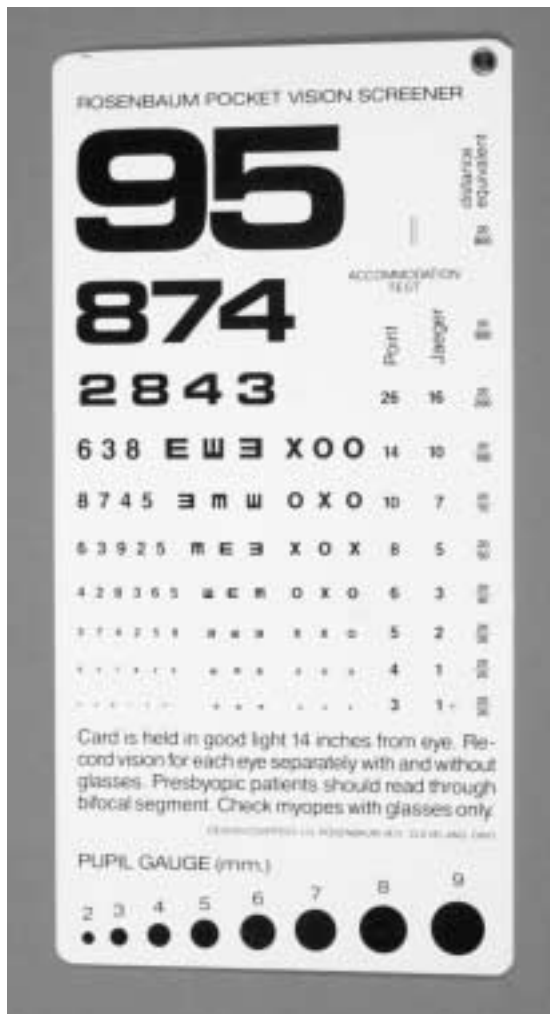

Figure 2 Rosenbaum visual acuity card with sample pupil sizes for more accurate measurement of pupil diameter.

from mild to severe. The least expensive and useful, portable color test is either the Ishihara Color Test (Fig. 1) or the HRR test. These are pseudoisochromatic tests that require intact color vision to see numbers written in colored dots on a background of gray dots of the same size, brightness, and saturation. The first number in the Ishihara book is a 12 and is *not* pseudo-isochromatic. If the 12 cannot be seen the patient is either very seriously visually impaired or has functional visual loss. The color test is generally *not* done to see whether the patient is red-green impaired but to see whether color vision is worse in one eye than in the other. Disease of the cones (macula) or of the optic nerve (of which 80% of the fibers are macular in origin and represent the inner 20 degrees of vision) results in damage to color perception. If color loss is asymmetric, color vision will be worse in the symptomatic eye and will always have other examination correlates (poor visual acuity or a relative afferent pupillary defect, a pale disk, or an abnormal appearance to the macula) that corroborate the loss of color vision.

Stereo visual acuity testing is frequently done using the Titmus Stereoacuity Chart (Figs. 1 and 3). Two images of the same object are stereo-photographed and superimposed with a gradual increase in stereo separation measured in seconds of arc. There are nine little diamonds, each of which consists of four circles, one circle at each corner of the diamond. One of the four circles is three-dimensional and the other three are not. The task is a forced-choice test that asks the patient to identify which of the four circles appears elevated or three-dimensional. These stereo images range from 800 to 40 seconds of arc. The smaller the number in seconds of arc perceived, the better the stereoacuity. Patients who have congenital strabismus or acquired unilateral



Figure 3 Titmus stereoacuity chart and polarized glasses.




Figure 4 Ishihara color plates.

visual loss will have impaired stereoacuity even if their color and conventional visual acuity is normal.

The Amsler grid (Figs. 1 and 5) is ordinarily used to look for evidence of metamorphopsia (distortions in visual perception due to retinal or macular disease) but may be used to detect visual field defects of whatever cause.

Contrast sensitivity acuity (Fig. 6) is done in an office setting with charts prepared with sine wave stripes or letters that vary in contrast. Contrast acuity is a sensitive test of residual visual deficits in patients with optic neuritis in whom high-contrast conventional visual acuity and color vision may be normal. Although

this is a very sensitive and useful test, it is currently rarely used by neurologists, and there is not an easy-to-use bedside form.¹

Ophthalmoscopy

Skilled use of the ophthalmoscope requires practice, and there are many reasons that ophthalmoscopy is either not done or not done well. It is common to hear that nothing can be seen because the pupils are too small, the battery has burned out, or "I'm not very good at it." In our book on ophthalmoscopy, Dr. Digre and I list some of the problems that interfere with the successful per-

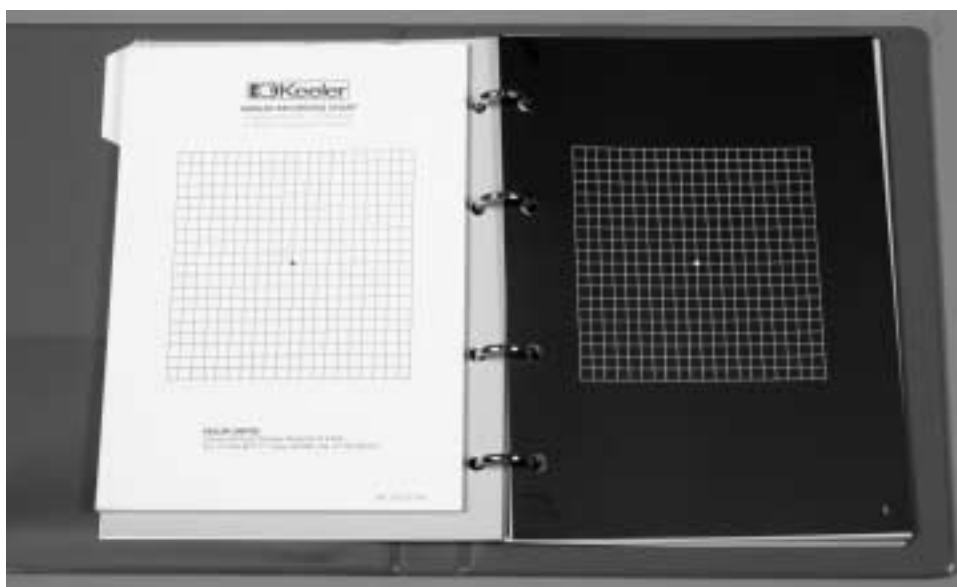

Figure 5 Amsler grid to the right and patient recording pad to the left. The patient is asked: (1) Looking at the spot in the center, can you see all four corners? (2) Are all the lines straight up and down and side to side? (3) Are all the squares present or are there defects? If there are abnormalities in the grid, the patient is asked to draw what they see.




Figure 6 Contrast sensitivity acuity chart and grading form. (Reprinted from Martin and Corbett,¹ with permission of Mosby.)

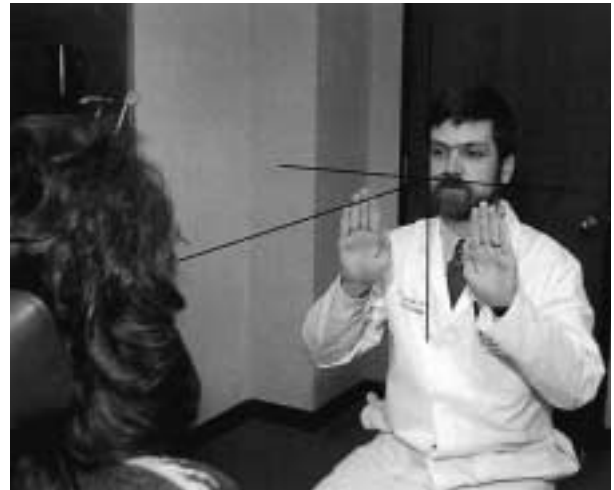

Figure 7 Confrontation fields. (Reprinted from Martin and Corbett,¹ with permission of Mosby.)

formance of viewing of the optic fundus.² These are what D.M. Pirsig in his book *Zen and the Art of Motorcycle Maintenance* called “gumption traps” and we call “gumption blocks”:

Not knowing your own refraction. This makes it hard to have a clear view of another person’s fundus. Furthermore, if they have major refractive error, you actually may need to look through their glasses to get a clear view.

Not dilating the patient. If the pupil is small and you can’t see the fundus, dilate the patient. Use Mydrinacyl 1% drops frequently.

Not realizing where you are focused. A great temptation when trying to see the disk and retina is to dial up and down. Start at 0 and go a bit into the red numbers (minus lenses or myopia) or the green numbers (plus-lenses—less commonly a problem—hyperopia).

Not being close enough with the ophthalmoscope. Remember you are trying to look through a peephole and that is not best done at long distance. Your ophthalmoscope should be 1 to 1½ inches away from the cornea.

Not being confident of your abilities. Mind-set is a large part of doing this examination well. Practice, practice, practice. Use drops.

Not knowing what you are looking for. Familiarize yourself with the appearance of normal disks, disk variants, and common optic nerve and retinal pathology. This can be done by using collections of slides, books, and atlases.¹

Confrontation Visual Fields

Commonly called “confrontational” fields, these are not an affront or challenge to the patient but simply a visual field carried out in front of or confronting the patient.

In the fully awake and alert patient, confrontational visual fields are performed at about 1 m from the patient (Fig. 7). Have the patient cover one eye with their palm (test right eye first then left eye). Have the patient look at your nose and in rapid succession present one, two, or five fingers in each of the four quadrants. Rapid presentation of fingers in each quadrant will frequently pick up a subtle visual field defect by repeated hesitations or “misses” in the same area of the visual field. Follow finger counting by frontal hand comparison. Ask whether the brightness, color, and clarity of the palms of both hands held in the upper and lower quadrants are equal. Finally, color comparison can be done using red pom-poms (Fig. 1) or dye lot-matched spools of red thread. Patients will occasionally make tiny distinctions between colors, which are not very helpful. However, if one red-colored object looks pink, brown-black, or very much darker red than the other, it will be immediately apparent to the patient. If an area of dyschromatopsia is found, move the colored object into the normal seeing area and you will be able to plot out the region of visual field loss easily. Finally, after testing each of the four quadrants, have the patient compare a finger on your nose with a finger held first in the nasal and then in the temporal periphery. The task is to see which finger is brightest and clearest. If there is a central defect in vision the finger on the nose will be dimmer or darker and less well seen than the finger in the periphery. This comparison can also be done with the colored pom-poms. Remember that some patients with profound peripheral visual loss will have preserved central vision. Furthermore, although objects, colors, and finger counting in the periphery may be gone, object movement may be perceived even when statically presented objects or hands are not seen (Riddoch phenomenon). This response to movement but not to static images may give

the mistaken impression that the patient is “functionally” impaired.³

Recording Visual Fields

The visual field recording convention is that the right visual field is to the right on the paper and left to the left, and they are recorded as if you were the patient viewing the world and trying to draw what is seen.¹ Use diagrams to record the results as you would any sensory diagram—the denser the hatching the denser the defect.

Visual field testing in the somnolent patient can be carried out by threat or by drawing one’s hand across the patient’s visual field from the side suspected to be hemianopic to the normal side. The patient will ignore the hand until it is in the seeing field where he or she makes eye movement fixation to pick up the moving hand. OKN can be used and will be abnormal in a patient with a parietal defect, and will be intact in a patient with an occipital visual field defect.¹ Drawing the OKN tape “out of” a parietal field defect will produce a tendency to pursue the OKN target with no saccadic return, whereas with an occipital lobe hemianopia the OKN will have normal pursuit/saccade appearance. Another examination trick that can be used in an aphasic patient is to sit the patient in a chair and have someone stand in front watching his eyes while you, the examiner, bring your hand from the right side and then the left side. When the patient makes an ocular fixation movement it tells you where the edge of the hemianopic defect is. In patients with right parietal defects it may be difficult to tell whether the visual field deficit is due to damage in the geniculocalcarine tract or is related to the patient ignoring the left side of space. Formal visual field examination in patients with parietal defects are almost impossible to perform as it is a psychophysical test that requires optimal patient attention, understanding, and cooperation. C. Miller Fisher is said to have called the response of ophthalmologists to a request for visual fields in a patient with parietal lobe visual loss the “SOB sign,” presumably because the ophthalmologist to whom the patient was referred for visual field testing (and had trouble performing the test) would call and ask “who was the SOB who referred this patient for field testing?”

Table 1 Uses of an OKN Tape

- Separation of parietal from occipital lobe lesions
- Identification of functional visual loss
- Reversal of OKN pursuit and fast phase in congenital nystagmus
- Identification of convergence/retraction saccades in the dorsal midbrain syndrome
- Accentuation of pursuit and saccade deficits in INO

OCULAR MOTILITY TESTING

The only equipment needed for a neurologist to test ocular motility are your fingers, an OKN tape (Figure 1 and Table 1), a Maddox rod (Figs. 1, 8A, and 8B), and a hand light.¹ Remember that you are not simply interested in whether the eyes *can* move to given positions but also in *how* they get there. Systematically test first rapid refixation (saccades), horizontally and vertically; second, smooth pursuit including fixation (which is smooth pursuit at 0 degrees per second velocity); and finally vergence and OKN.

Saccades

Rapid refixation saccades move the eyes from the center (your nose) eccentrically to one side (your finger) and then back to center at command, then to the other side, and back to center. The same is done up and down. Look for hypermetric overshoot, hypometric undershoot with compensatory correctional saccades, lateropulsion, and internuclear ophthalmoparesis, where one or both eyes adduct less quickly than the contralateral eye abducts.⁴ Rapid refixation saccades from side to center in a patient who has only a slight or “recovered” internuclear ophthalmoplegia (INO) will frequently produce a “floating” adducting eye. The eye, as it adducts, lags behind the abducting eye, but when it finally comes to rest, it is fully adducted. The abducting eye overshoots and makes a hypermetric “bounce” of variable amplitude at the same time the adducting eye is floating into position. Hold your finger far enough from the patient’s eyes as you have them follow the finger. If held too close, convergence will obscure the adduction defect seen with an INO.⁵

Slow saccades that do not have a normal initial pulse to the saccade at the onset, move smoothly but slowly.⁴ These are seen with Wilson’s disease, Huntington’s disease, and in patients with spinocerebellar ataxia type 2. As a rule, if you don’t know what name to attach to an eye movement, simply describe what you see. The wrong pigeonhole is worse than the right description.

Pursuit

Pursuit eye movements need to be performed with a target moving very slowly.⁴ Pursuit of 30 degrees per second is the upper limit for persons who are not trained athletes (skaters and ballet dancers, for example). Thus, performing a 90 degree pursuit with your finger at a normal patient’s *upper* limits of performance will take 6 seconds for an excursion from side to center. Look for slowing of pursuit with a need to perform quick little catch-up saccades or the substitution of a series of hypometric saccades for smooth pursuit. Looking for convergence-retraction saccades (“nystagmus”) in the dorsal midbrain syndrome is best done by drawing an OKN drum or tape from above to below with the

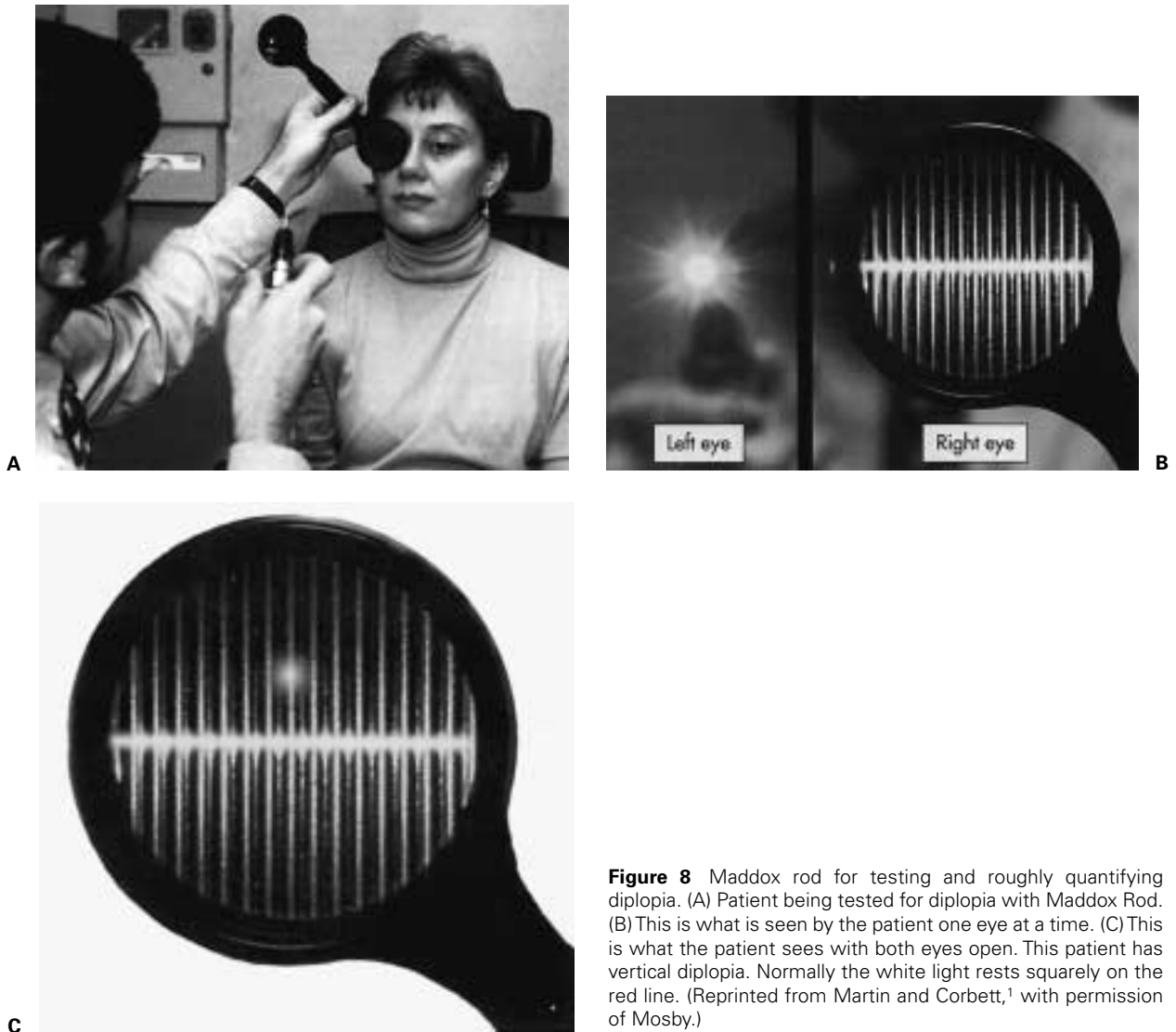


Figure 8 Maddox rod for testing and roughly quantifying diplopia. (A) Patient being tested for diplopia with Maddox Rod. (B) This is what is seen by the patient one eye at a time. (C) This is what the patient sees with both eyes open. This patient has vertical diplopia. Normally the white light rests squarely on the red line. (Reprinted from Martin and Corbett,¹ with permission of Mosby.)

stripes held horizontally. The eye will be seen to retract as attempts at upward saccades are made.

Vergence

Vergence (for all practical purposes convergence) has as its stimulus an object at near or moving toward the patient.⁴ Older patients do this less well than younger patients. The convergence triad of pupil contraction, increased accommodation (the lens gets thicker) and convergence of the globes (dysconjugate adduction), tends to be done poorly in patients older than 40 as the lens becomes less pliable and the image on the retina at near attempts is no longer clear. At that point the patient needs to use plus lenses (reading glasses) to see clearly at near. To test vergence you can use the patient's thumb as the object of regard, which adds proprioceptive input to the vergence effort. You can click your thumb and index fingernails together as you bring them toward the patient, which provides auditory as

well as visual input to the target. Patients with congenital amblyopia (poor vision in one eye secondary to strabismus) will frequently be unable to converge. The weak eye may start to converge and then break convergence and deviate outward. Vergence testing is used primarily to see how well the pupil responds to near effort as compared with the light response. The pupillary response to both light and near should be equal in amplitude.

Light-Near Dissociation

The response of the pupil to convergence effort is better than the response to light as seen in syphilis (Argyll Robertson pupil), the dorsal midbrain syndrome, Adie's syndrome, and when there is bilateral loss of vision as a result of damage to visual pathways anterior to the lateral geniculate nuclei. In each of these circumstances, the light reaction will be poor and the near response will be good.

Maddox Rod for Diplopia

Testing eye muscles one eye at a time is called *duction testing*. Testing both eyes together is called *versions*. When there are deficits in ductions, diplopia is the result. To characterize the diplopia one can use a red glass or even better, and easier for the patient to report, is the use of the Maddox rod (Figs. 1 and 8A to 8C). A Maddox rod is made of a series of parallel prism bars on the end of a paddle (Figs. 1 and 8A). A light shone through these prisms makes a series of in-line red spots that form a dotted red line (Figs. 8B and 8C). The prisms can be turned to produce a horizontal or vertical line. When the Maddox rod is held over the right eye the patient sees a red line (seen with the right eye) and a white spot (seen with the left eye; Fig. 8B).¹ If the eyes are vertically divergent a horizontal line made with the Maddox rod is compared with the light seen out of the opposite eye as either above or below the line. The eyes can then be examined in the nine cardinal positions. Similarly, if the images are horizontally separated, the Maddox rod red line will be vertical and the white light will be seen as either to the right or left of the vertical red line.¹

PUPIL EXAMINATION

The mnemonic PERLA usually means Pupil Exam is the Result of the Last Admission.

H. Stanley Thompson

The most common error made when examining a patient's pupils is asking the patient to look at your forehead and then trying to test the light response. This ba-

sically asks the patient to converge, which will make the pupils smaller than they are when looking at the distance. The correct technique for examining pupils is to have the patient look in the distance at an imaginary object, which will allow the pupils to optimally enlarge. In general, young people have large pupils and with aging the pupils become smaller.⁶ Twenty percent of the population has a pupillary asymmetry of 0.3 mm diameter or more, and this simple anisocoria (reaction to light and near is equal in amplitude but resting size is asymmetrical) should not be alarming (Fig. 9). The one person in five with anisocoria, at any given time in the general population, is only one of many reasons that you should not use the PERLA mnemonic. Even though the pupils are unequal 20% of the time, no one ever writes PURLA. The fact that the pupils react to light does not take into account the possibility of a relative afferent pupillary defect (RAPD), which is an objective sign of damage or disease of the afferent visual pathways. The final reason to not use the PERLA mnemonic is that when you have a patient converge, as a neurologist, you are actually testing the near reaction of the pupil, not accommodation of the lens (Fig. 10A).

Pupils should be examined in a darkened room and the illumination should come from below, thereby eliminating the glare of a reflection spot on the cornea, which makes it difficult to see the pupil reaction to light and near. When looking for an afferent pupil defect, swing the light back and forth from eye to eye at a one second interval (Fig. 10B). The typical pupillary light begins at 0.25 second; the response is maximal within 0.5 second with a slight release within a second, and then a variable amount of instability of contraction occurs referred to as *hippus*. Hippus is normal physiologic pupillary instability and is seen in young and old but

Five Day Prevalence of Anisocoria

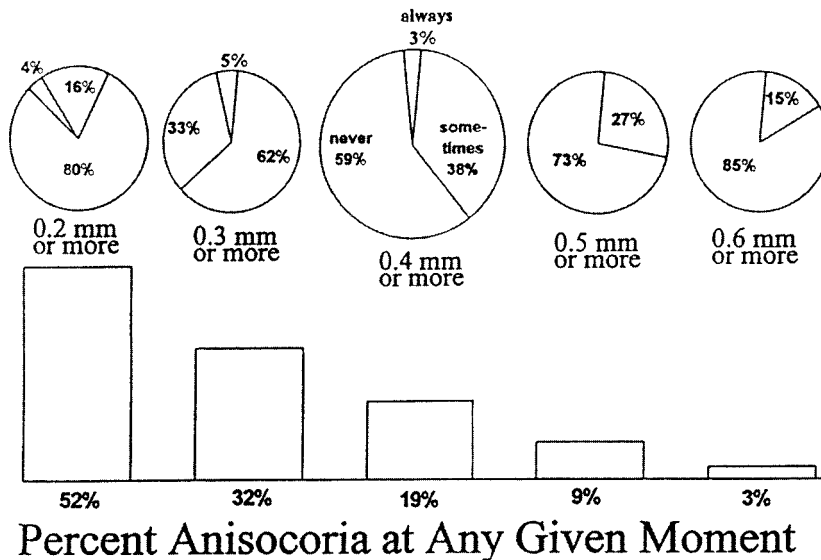


Figure 9 Incidence of simple anisocoria over a 5-day period.

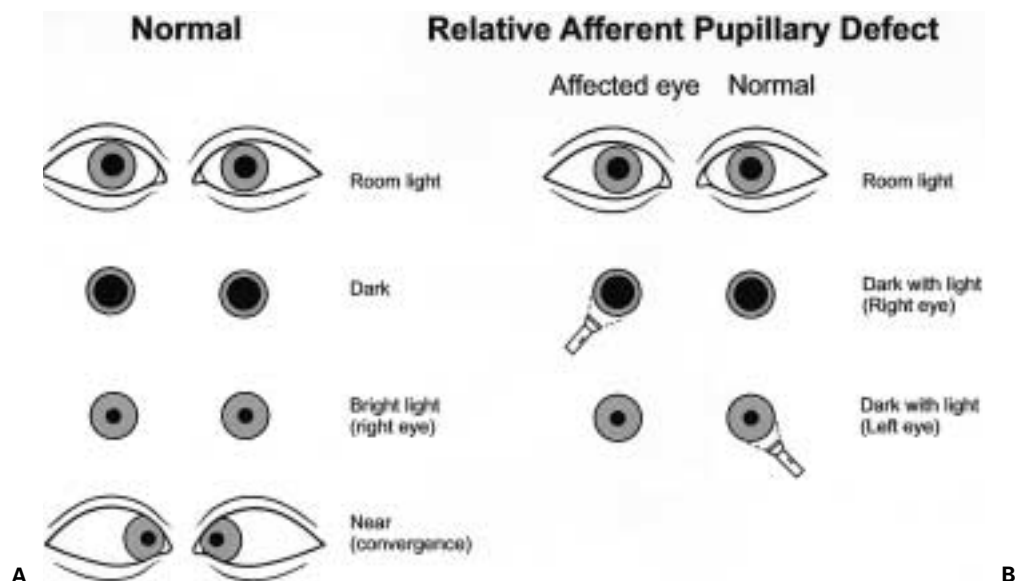


Figure 10 (A) Normal light and near response. (B) Relative afferent pupil defect.

more commonly in young patients with large pupils where small contractions are more easily seen. Aside from being an examination annoyance, it has no clinical significance.

Relative Afferent Pupillary Defect

This important objective sign is seen in patients who have asymmetrical damage to the retina, optic nerve, chiasm, and optic tract (Fig. 10B). It is, in short, the weak constriction of both pupils when a light is shone into the eye with greater visual field loss as compared with a more robust bilateral pupillary constriction when the light is shone into the eye with better vision or no field loss.⁷ These asymmetric light reactions are frequently “graded” by some as 1+ to 4+ as determined by the amplitude of pupillary response. A better method is simply to say that there is or is not RAPD, unless you can measure them with neutral density filters. A patient cannot be said to have bilateral RAPD. It is called *relative* because you are judging the pupil reaction of one eye relative to the other. An RAPD is an objective sign of retinal disease or damage, optic nerve, chiasmal, or

optic tract damage for which there should also be a visual field defect, and/or a pale disk, and/or decreased visual acuity, and/or defective color vision in the affected eye, corroborating the RAPD.

Argyll Robertson Pupil

An Argyll Robertson pupil (Fig. 11) consists of bilateral small pupils that react poorly to light or not at all, and briskly to near. As opposed to longstanding Adie’s pupils (Fig. 12), the near reaction in Argyll Robertson pupils is phasic (brisk to constrict and to redilate). Adie’s tonic pupils constrict slowly and remain tonically constricted.

Defects in the Efferent Pupillary Response

Patients who have efferent defects in the pupil sphincter will have a dilated pupil and those with sympathetic (pupillary dilator) defects will have a small pupil. Thus afferent pupil defects reveal equal-sized pupils that react asymmetrically to light and efferent pupil defects reveal unequal-sized pupils.

Argyll Robertson pupils			Dark	ARGYLL ROBERTSON PUPILS Pupils are small and may be irregular. They react slowly or not at all to light but show a brisk near reaction. Always obtain VDRL and FTA-Abs. Presumptive evidence of syphilis.
			Light	
			Near	

Figure 11 Argyll Robertson pupil.

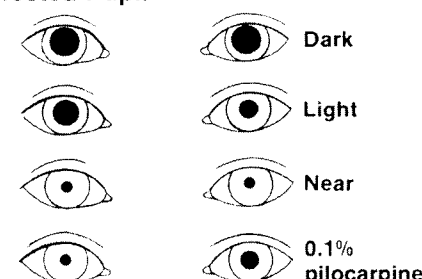
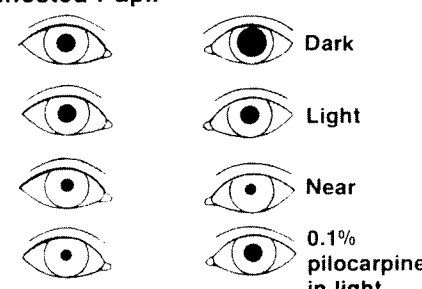
<p>Tonic Pupil (Adie's tonic pupil)</p> <p>Affected Pupil</p> 	<p>ADIE'S</p> <p>Tonic pupil=deneration of sphincter and ciliary muscles. Adie's syndrome=idiopathic tonic pupil. Cholinergic supersensitivity in approx. 75% (use Pilocarpine 0.1% OU). Impaired deep tendon reflexes in about 90%. Segmental light reaction - seen best at slit lamp. Near reaction is strong, slow and tonic.</p>
<p>Long-Standing Adie's pupil</p> <p>Affected Pupil</p> 	<p>LONG-STANDING ADIE'S</p> <p>Adie's pupils get smaller with time, and may be smaller than the unaffected pupil, even in moderate light. Both pupils may be affected in Adie's and frequently are in peripheral neuropathies. These pupils can be distinguished from AR pupils by cholinergic supersensitivity and the tonic near response seen in Adie's syndrome.</p>

Figure 12 Adie's tonic pupil.

Acutely, the pupil affected by Adie's syndrome will be dilated and may have no or poor reaction to light or near (Fig. 12). More often the defect has been present longer than realized and aberrant reinnervation of the sphincter has occurred, giving small segmental "vermiform" segmental reactions to light and a substantial tonic (long-lasting) reaction to near. This is one of the "light-near dissociation" scenarios where the reaction to light is poor or absent but the reaction to near is vigorous and tonic.

Pharmacologic Blockade (Test for Atropinic Block)

A pupil that is fully dilated and does not respond to light or near is usually caused by accidental or rarely deliberate continuation with pupil-dilating drops or other compounds contained in weeds (Jimson weed), beauty

products (some perfumes and antiperspirants) or medication (scopolamine-containing anti-vertigo patches) (Fig. 13).

Pharmacologic blockade may create a brief diagnostic dilemma. The fixed dilated pupil can usually be resolved by history and pharmacologic testing. Accidental or surreptitious deliberate instillation of drugs that cause pupillary dilation occurs most commonly in persons in a medical setting. Nurses, doctors, and other paramedical people who come in contact with those drugs may accidentally rub them into their eye, producing a dilated pupil or, for reasons known only to themselves, may "create" a dilated pupil as a medical problem. One percent pilocarpine should constrict any normal pupil that is dilated due to damage to third nerve but it will not overcome pharmacologic blockade. If the pupil fails to respond to 1% pilocarpine and direct obvious trauma is not the cause of the mydriasis, factitious or ac-

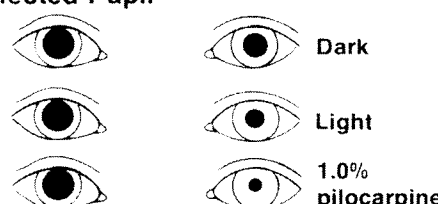
<p>Medication-induced Mydriasis</p> <p>Affected Pupil</p> 	<p>MEDICATION-INDUCED MYDRIASIS</p> <p>May be accidental contamination or deliberate instillation of mydriatics. The pupil does not react to light or near. No reaction to 1% pilocarpine.</p>
---	---

Figure 13 Pharmacologic blockade.

cidental mydriasis can be reasonably suspected. Some perfumes and underarm deodorants contain small quantities of atropinics and topical contact can cause pupil dilation.

It is almost unheard of to have a pupil-only third nerve palsy. Almost always there are other elements of third nerve dysfunction such as slight ptosis, adduction, depression, or elevation defects.

Horner's Syndrome

Sympathetic denervation produces characteristic slight ptosis (in which the lid does not fall over the pupil or visual axis), miosis best seen in a darkened room, "upside-down" ptosis due to denervation of the sympathetically innervated lower lid (thus a narrowed palpebral fissure), and anhidrosis.

The affected pupil is not extremely miotic. Extreme miosis is caused by pupillary spasm seen most commonly with pontine hemorrhage or infarct, whereas Horner's pupil is caused by dilator denervation (Fig. 14).

THE COCAINE TEST

Two drops of 5 to 10% ophthalmic cocaine are placed in both eyes. If more than two drops are used, the corneal epithelium can be disrupted and a brief but painful corneal erosion may result. Using this test, a pupil with sympathetic damage and Horner's syndrome, no matter at what anatomic level, will produce a pupil that dilates poorly to cocaine, whereas the normal pupil dilates quickly. Cocaine blocks the reuptake of norepinephrine at the synaptic cleft. The cocaine test confirms the presence of Horner's syndrome and without it, the diagnosis on clinical criteria alone is presumptive. Damage to any









neuron of the sympathetic arc will give a positive cocaine test.

THE PAREDRIANE TEST

One percent hydroxyamphetamine (Paredrine) releases norepinephrine into the synaptic cleft. If the first or second neurons of the oculosympathetic system have been damaged and the final common pathway is intact, the third-order (ganglion cell) neurons are able to produce, transport, and store norepinephrine. When Paredrine is installed, the pupils dilate because norepinephrine is released. When the third-order neuron (superior cervical ganglion or postganglionic fibers) is damaged, there is no production, transport, or storage of norepinephrine; when Paredrine is installed in the affected eye, the pupil does not dilate. Thus, the cocaine test tells whether or not there is Horner's syndrome, and the Paredrine test can separate a third-neuron Horner's syndrome from first- and second-neuron syndromes. There is no pharmacologic test that can differentiate a first- and second-neuron Horner's syndrome. These must be identified clinically by the associated brain stem (first neuron) or spinal cord and lung apex (second neuron) symptoms and signs.

DILATION LAG

Another simple bedside observation can aid in the identification of Horner's syndrome. The pupillodilator muscle actively dilates the pupil in darkness; damage to the sympathetic nerves results in passive release of the cholinergic sphincter but no active dilation. As a result, the affected pupil dilates less rapidly in the

Horner's Syndrome	Affected Eye	
	 Dark	
	 Light	
	 10% cocaine both eyes	
1st/2nd Neuron Horner's		} 1% Paredrine both eyes
3rd Neuron Horner's		

HORNER'S SYNDROME
 Horner's pupils are miotic but not pinpoint and the ptosis never occludes the visual axis. Anhidrosis depends on the location of the sympathetic lesion. In a fresh case, there is conjunctival injection. 10% cocaine fails to dilate in 1st, 2nd and 3rd neuron damage. Reaction to light and near are normal. The pupil dilates slowly in the dark. 1% Paredrine® fails to dilate 3rd neuron Horner's.

Figure 14 Horner's syndrome.

dark as compared with the unaffected side. This differential speed of dilation is called *dilation lag*. It is best appreciated in photos taken at 5 and 15 seconds after the lights are turned out using a flash camera with a close-up attachment. Clinically, without photos, dilation lag may be hard to judge and is best appreciated in dim lighting in persons with lightly colored irises.

Pseudo-Horner's Syndrome

Of the 20% of persons with simple anisocoria (Fig. 9), some may also happen to have palpebral asymmetry with the narrow fissure on the side of the smaller pupil. A common cause of lid droop is levator disinsertion. The levator muscle inserts into the skin of the palpebral margin of the lid and the tarsal plate. Lid edema, allergic eye rubbing, trauma, following cataract extraction, and long-term contact lens wearing are all risk factors for the development of levator disinsertion. The combination of ptosis and miosis not due to sympathetic nervous system damage is a prolific source of diagnostic error and commonly results in a costly medical diagnostic side trip, including magnetic resonance imaging and carotid angiography, in the investigation of a "Horner's syndrome" that doesn't exist.

The gold standard for the diagnosis of Horner's syndrome is the use of two drops of 5 to 10% cocaine (prepared as ophthalmic drops) in either eye (Fig. 15). It requires a narcotic prescription to have the pharmacy make an ophthalmic solution. It is jokingly said that it is easier to get cocaine on the street than it is to get it in a hospital. That being said, the cocaine test remains, in ad-

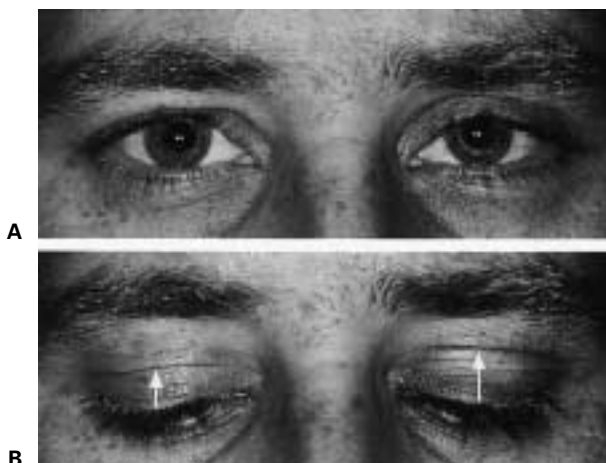

Figure 15 Levator disinsertion. (A,B) Notice the narrowed palpebral fissure and widened lid margin to lid crease. This is a giveaway for a post traumatic ptosis due to levator disinsertion. Looking upward the palpebral fissure widens completely. (Reprinted from Martin and Corbett,¹ with permission of Mosby.)

dition to dilation lag, the best and surest test of the intactness of or defects in sympathetic pupillary function.

Simple Anisocoria and Pseudo-Horner's Syndrome

About 20% of the normal population will have more than 0.4 mm of anisocoria. The pupils are otherwise entirely normal and do not have light–near dissociation or pharmacologic abnormalities or demonstrate dilation lag. Because ptosis from causes other than sympathetic dysfunction and miosis due to simple anisocoria may occur in the same eye, it becomes all the more important to use formal pharmacologic testing to diagnose Horner's syndrome. The combination of drooping eyelid and a smaller pupil on the side of the ptotic eye can be seen in many settings not due to sympathetic damage. Combinations of simple anisocoria and some form of ptosis may create a pseudo-Horner's syndrome.⁸

The pupil of Horner's syndrome is not intensely miotic; instead, the miotic pupil is only smaller relative to the other pupil. Recall that the cause of the miosis is failure of active dilation and *not* spasm of the pupil sphincter. The ptosis of Horner's syndrome is slight in degree and virtually never covers the visual axis.

Pontine miosis is a combination of bilateral Horner's syndrome and disinhibition of the pupillary sphincters, which produces the characteristically tightly miotic (<2.0 mm) pupils seen with pontine hemorrhage or infarct (Tables 2, 3, and 4, and Fig. 15).

Table 2 Causes of Small Pupils

Sympathetic denervation
Dilation lag
Failure to dilate with cocaine
Simple anisocoria
No dilation lag
Normal dilation with cocaine
Iridocyclitis
Cells and flare in anterior chamber
Keratic precipitates
Posterior synechiae
"Stiffness" of iris
Drug-induced iris sphincter spasm
History of exposure to miotic drops
Adie's pupil (old)
Light–near dissociation
Segmental iris sphincter palsy
Tonic near response
Cholinergic supersensitivity
Argyll Robertson pupil
Light–near dissociation
Serologic findings of syphilis

Table 3 Causes of Ptosis

Mechanical
Inflammatory
Edema, allergy, chalazion, hordeolum, blepharitis, conjunctivitis
Cicatricial
Tumor (lid, orbit)
Blepharochalasis-redundant skin
Myogenic
Chronic progressive external
Ophthalmoplegia-gradual and bilateral
Myasthenia gravis-variable and bulbi
Changes from eye to eye
Topical steroid eyedrops
Neurogenic
Horner's syndrome
Oculomotor nerve palsy
Levator dehiscence syndrome
Aging
Inflammation of eye or lids
Surgery
Trauma
Pseudoptosis
Pathologic lid retraction of the opposite eye
Dermatochalasis (redundant lidskin)
Duane's retraction syndrome
Microphthalmos/phthisis
Enophthalmos
Chronic Bell's palsy
Voluntary blepharospasm

Looking for Proptosis

Forward protrusion of the globe is seen with orbital tumors, intracranial masses, carotid cavernous fistulas, Tolosa-Hunt syndrome, and other periorbital and retro-orbital processes. The first examination technique for proptosis consists of placing the index finger from brow

to maxilla to feel the pressure of the globe on the palmar side of your finger. There is a handy small Lucite measuring device called a Ludde proptometer that can be used to quantify proptosis (Figs. 16A and 16B). A more expensive office tool is the Hertel exophthalmometer.

Listening for Bruits

When a patient has a complaint of a subjective bruit, use the bell of your stethoscope and listen over the squamosal portion of the temporal bone and the mastoids, and use the diaphragm to auscultate over the globes. When auscultating the temporalis area, have the patient open his or her mouth to eliminate background muscle contraction noise. When you place the diaphragm on the globe have the patient close both eyes and then have the patient open the unoccluded eye. This will eliminate the noise of eyelid muscular contraction. This auscultation method can be used both for bruits (as seen in carotid artery disease, increased intracranial pressure, or carotid cavernous fistula) and may be used to hear the bursts of muscle contraction in patients with superior oblique myokymia.

SUMMARY OF DIAGNOSTIC PEARLS IN THE NEURO-OPHTHALMOLOGIC EXAM

1. Examine visual acuity at near with the patient's own spectacles or reading glasses.
2. Confrontation fields initially should be done using static images. Explore any field defect from the area of nonseeing into the area of normal vision. Twiddling fingers and other hand motions are used only after one establishes that there is no response to a static object.

Table 4 Eye Drops That Should Be Available

Type of Drop	Use	How to Use
Mydracyl 1%	Dilation of pupil	Two drops followed by another two drops after 5 minutes in each eye
Cocaine 4–10%	Testing integrity of sympathetic innervation of the pupil	Two drops in each eye—no more; too much cocaine will damage the epithelium; measure pupils before drops and 45 minutes after installation
Hydroxyamphetamine 1%	Testing the third neuron of the sympathetic chain	Two drops in each eye; measure pupils before drops and 45 minutes after installation
1% pilocarpine	Used to test for pharmacologic blockade of the pupil sphincter	Two drops in each eye
0.1% pilocarpine	Used to test for sphincter super-sensitivity in pupil sphincter denervation	Two drops in each eye; measure after 45 minutes

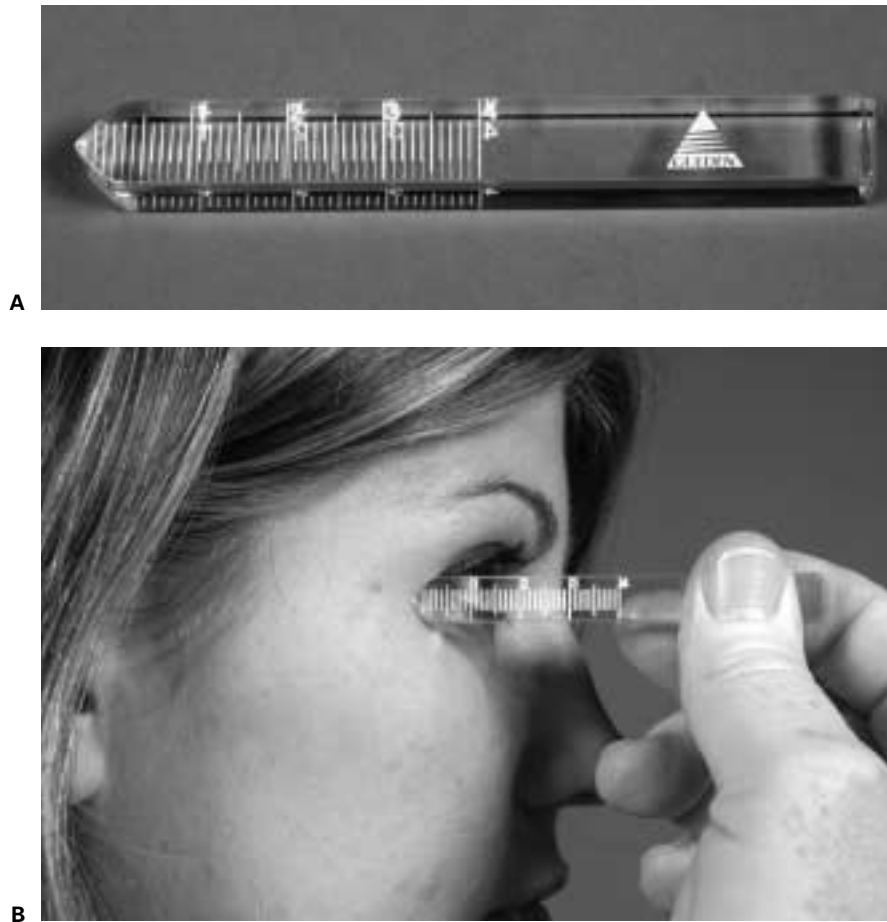


Figure 16 (A,B) Ludde proptometer and its use.

3. Ocular motility testing should provide information about both individual eye muscles and conjugate eye movements. Be sure to examine the patient's eyes in primary position without moving the eyes, to look for nystagmus and square wave jerks. Then examine in all cardinal positions of gaze.
4. When examining eye movements, be sure the object of regard (usually a finger) is not held too close or the patient will add convergence to the various excursions and an internuclear ophthalmoplegia can be missed.
5. Examine pupils for light response with the patient looking at distance. Then have the patient converge and look for the near response. Examine them in bright light and dim illumination.
6. Look for a relative afferent pupillary defect.
7. If there is pupillary asymmetry, try to determine whether it is the larger or smaller pupil that is abnormal. Measure the palpebral fissure width.
8. When the patient has nystagmus or an unusual ocular motility disturbance, describe in simple prose what you see unless you are quite confident as to the

name of the ocular motor problem. Look at what happens with saccades, pursuit, and OKN.

REFERENCES

1. Martin TJ, Corbett JJ. *Neuro-Ophthalmology in Requisites in Ophthalmology Series*. St. Louis: Mosby; 2000
2. Digre KB, Corbett JJ. *Practical Viewing of the Optic Disc*. Philadelphia: Butterworth Heineman; 2002
3. Thompson HS. Functional visual loss. *Am J Ophthalmol* 1985;100:209–213
4. Leigh RJ, Zee DS. *The Neurology of Eye Movements*. 3rd Ed. Oxford, United Kingdom: Oxford University Press; 1999
5. Van Allen MW. Lateral gaze and convergence in internuclear ophthalmoplegia: a note on examination. *Neurology* 1968;16:362–363
6. Loewenfeld IE. Pupillary changes related to age. In: Thompson HS, ed. *Topics in Neuro-Ophthalmology*. Baltimore: Williams and Wilkins; 1979
7. Thompson HS, Corbett JJ. Swinging flashlight test [letter to the editor]. *Neurology* 1989;38:154–156
8. Thompson BM, Corbett JJ, Kline LB, Thompson HS. Pseudo-Horner's syndrome. *Arch Neurol* 1982;39:108–111