

ONMedU, Department of Obstetrics and Gynecology. Lecture № 5-6. Obstetric bleeding during the second half of pregnancy, childbirth and the postpartum period. Algorithm for providing emergency care for obstetric bleeding. Part I, II.

**MINISTRY OF HEALTH OF UKRAINE
ODESSA NATIONAL MEDICAL UNIVERSITY**

International Faculty
Department of obstetrics and gynecology



CONFIRMED by
Vice-rector for scientific and
pedagogical work
Eduard BURIACHKIVSKYI
September 1, 2023

**METHODOLOGICAL RECOMMENDATIONS
FOR LECTURE**

International Faculty, Course V

Discipline "Obstetrics and Gynecology"


Lecture №5-6. Topic: Obstetric bleeding during the second half of pregnancy, childbirth and postpartum period. Algorithm for providing emergency care for obstetric bleeding. Part I, II.

ONMedU, Department of Obstetrics and Gynecology. Lecture № 5-6. Obstetric bleeding during the second half of pregnancy, childbirth and the postpartum period. Algorithm for providing emergency care for obstetric bleeding. Part I, II.

Approved:

Meeting of the Department of Obstetrics and Gynecology of Odesa National Medical University

Protocol No. 1 dated August 28, 2023

Head of the Department of  (Ihor GLADCHUK)

Developer:

Ph.D., DSc.(Med) Professor  (V. Artyomenko)

LECTURE № 5-6:

“OBSTETRIC BLEEDING DURING THE SECOND HALF OF PREGNANCY, CHILDBIRTH AND THE POSTPARTUM PERIOD. ALGORITHM FOR PROVIDING EMERGENCY CARE FOR OBSTETRIC BLEEDING. PART I, II”

RELEVANCE: Etiology and pathogenesis, modern diagnostic methods, volumetric survey of patients, clinical features, classification of placenta previa, premature detachment of a normally located placenta and postpartum haemorrhage. are basic to understand here to provide qualified emergency care, modern principles of prevention and medical rehabilitation of the patients. Unless well studied, this can make impossible to master pathological obstetric care and save both mother and child lives.

LEARNING OBJECTIVE is to gain basic knowledge about the etiology, pathogenesis, clinics, diagnostics and treatment of pathological conditions that may cause obstetric haemorrhage. During the course of teaching the material, students develop clinical thinking on this topic, which allows them to further solve problems associated with obstetric haemorrhage. Get knowledge about modern treatment and prevention principles of pregnant women with ante- intra- and postpartum haemorrhage. Develop a special vigilance in the prevention and early diagnosis of obstetrical haemorrhage in students. Form a sense of moral and legal responsibility for the timeliness and quality of medical care obstetric patients.

BASIC CONCEPTS: Pathological conditions which cause obstetrical bleeding. Modern diagnostic methods of placenta previa and premature detachment of a normally located placenta. Clinical signs of placenta previa and premature detachment of a normally located placenta. Classification of placenta previa and premature detachment of a normally located placenta. Principles of pregnant women with placenta previa and premature detachment of a normally located placenta emergency care. Modern principles of placenta previa and premature detachment of a normally located placenta prevention. Causes, pathogenesis, clinics and diagnostics of postpartum haemorrhage. Modern methods of postpartum haemorrhage treatment and prevention. Active management of 3rd stage of labor. Modern methods of blood loss estimation.

PLAN AND ORGANIZATIONAL STRUCTURE OF THE LECTURE

№	The main stages of the lecture, their content	Type of lecture, equipment of the lecture	Time distribution
1.	<i>Preparatory stage</i>		

ONMedU, Department of Obstetrics and Gynecology. Lecture № 5-6. Obstetric bleeding during the second half of pregnancy, childbirth and the postpartum period. Algorithm for providing emergency care for obstetric bleeding. Part I, II.

	□ Defining of educational goals		3 min
	□ Providing of positive motivation		2 min
2.	<i>The main stage</i>		
	□ Presentation of lecture material	Clinical	90%
	Plan:		
	<ul style="list-style-type: none"> - Placenta previa. Terminology, classification, clinical features, diagnostics, treatment principles, prophylactics, prevention. - Premature detachment of a normally located placenta. Terminology, classification, clinical features, diagnostics, treatment principles, prophylactics, prevention. - Postpartum haemorrhage. Terminology, classification, clinical features, diagnostics, treatment principles, prophylactics, prevention, rehabilitation. Emergency care in severe preeclampsia. - Modern principles in emergency care for obstetrical haemorrhage. 	Multimedia equipment (computer, projector, screen, TV). Power Point presentation	25 min 15 min 20 min 20 min.
3.	<i>The final stage</i> Lecture summary. Answers to questions. Tasks for self-preparation		5 min

EDUCATIONAL MATERIALS

Placenta previa

044.0 – Determined placenta previa without bleeding

044.1 – Placenta previa with bleeding

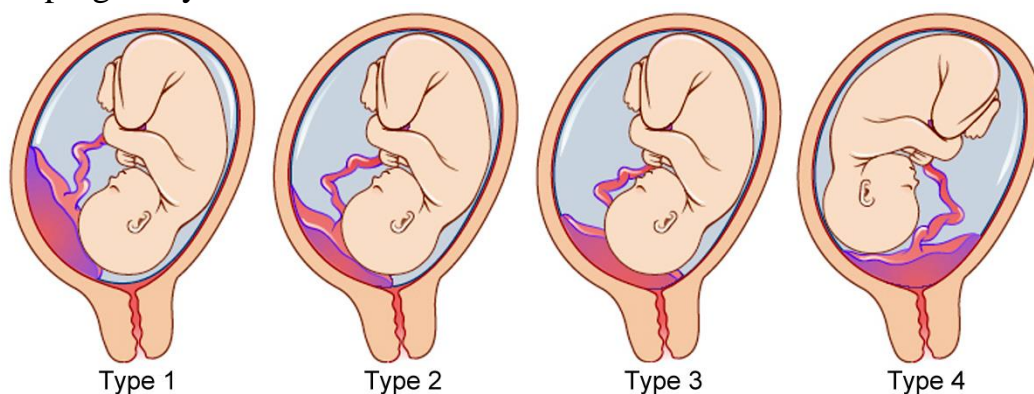
- Placenta previa - pregnancy complication in which placenta is located in the lower uterine segment below the presenting part, blocking all or part of the internal cervical os. During physiological pregnancy, the lower edge of the

placenta does not reach any closer than 7 cm to the internal os. Placenta previa is seen in 0,2-0,8 % of all delivers.

Classification of placenta previa

1. Complete presentation - the placenta completely blocks the internal os.
2. Incomplete presentation - the placenta partially blocks the internal os:
 - a) Lateral presentation - 2/3 of the area of the internal os is blocked;
 - b) Marginal presentation – the edge of the placenta meets the internal os.
3. Low placenta previa (placement) – the placenta is implanted in the lower uterine segment less than 7 cm from the internal os without blocking it.

In connection with migration of the placenta or its growth, the type of presentation can change as the pregnancy continues.



Classifications		
Classical	Contemporary	Ultrasound
Type 1	Marginal	Minor
Type 2	Lateral	
Type 3	Central	Major
Type 4		

ETIOLOGY

The exact cause of implantation of the placenta in the lower segment is not known. The following theories are postulated.

- Dropping down theory: The fertilized ovum drops down and is implanted in the lower segment. Poor decidual reaction in the upper uterine segment may be the cause. Failure of zona pellucida to disappear in time can be a hypothetical possibility. This explains the formation of central placenta previa.
- Persistence of chorionic activity in the decidua capsularis and its subsequent development into capsular placenta which comes in contact with decidua vera of the lower segment can explain the formation of lesser degrees of placenta previa.
- Defective decidua, results in spreading of the chorionic villi over a wide area in the uterine wall to get nourishment. During this process, not only the placenta becomes membranous but encroaches onto the lower segment. Such a placenta previa may invade the underlying decidua or myometrium to cause placenta accreta, increta or percreta

- Big surface area of the placenta as in twins may encroach onto the lower segment.

CAUSE OF BLEEDING: As the placental growth slows down in later months and the lower segment progressively dilates, the inelastic placenta is sheared off the wall of the lower segment. This leads to opening up of uteroplacental vessels and leads to an episode of bleeding. As it is a physiological phenomenon which leads to the separation of the placenta, the bleeding is said to be inevitable. However, the separation of the placenta may be provoked by trauma including vaginal examination, coital act, external version or during high rupture of the membranes. The blood is almost always maternal, although fetal blood may escape from the torn villi especially when the placenta is separated during trauma.

Clinical symptoms

SYMPTOMS: The only symptom of placenta previa is vaginal bleeding. The classical features of bleeding in placenta previa are sudden onset, painless, apparently causeless and recurrent. In about 5% cases, it occurs for the first time during labor, especially in primigravidae. In about one-third of cases, there is a history of “warning hemorrhage” which is usually slight. The bleeding is unrelated to activity and often occurs during sleep and the patient becomes frightened on awakening to find herself in a pool of blood. The bleeding is unassociated with pain unless labor starts simultaneously. Obvious causes for the placental separation such as trauma or hypertension are usually absent. However, preeclampsia may complicate a case of placenta previa. The first bout of bleeding is usually not alarming but subsequent bouts may be heavier than the previous one due to separation of fresh areas of placenta. In majority of cases, bleeding occurs before 38 weeks and earlier bleeding is more likely to occur in major degrees. However, there may not be any bleeding in central placenta previa until labor starts. Anemia, as a result of bleeding.

Abdominal examination:

- The size of the uterus is proportionate to the period of gestation. Note the effective reduction of the antero-posterior diameter of the inlet in contrast to type II anterior placenta previa.
- The uterus feels relaxed, soft and elastic without any localized area of tenderness.
- Persistence of malpresentation like breech or transverse or unstable lie is more frequent. There is also increased frequency of twin pregnancy.
- The head is floating in contrast to the period of gestation. Persistent displacement of the fetal head is very suggestive. The head cannot be pushed down into the pelvis.
- Fetal heart sound is usually present, unless there is major separation of the placenta with the patient in exsanguinated condition. Slowing of the fetal heart rate on pressing

the head down into the pelvis which soon recovers promptly as the pressure is released is suggestive of the presence of low lying placenta especially of posterior type (Stallworthy's sign). But this sign is not always significant because it may be due to fetal head compression even in an otherwise normal case. Frequently, incorrect positioning of the fetus occurs: diagonal, transverse, breeched presentation, incorrect insertion of the head. Premature birth is possible.

Diagnosics

1. Anamnesis.
2. Clinical displays - occurrence of repeated bleeding, not accompanied by pain and increased uterus tonus.

Obstetrical examination:

a) External examination:

- High standing of the presented part;
- Diagonal, transverse fetal position;
- The tonus of the uterus is not increased;

b) Internal examination (**performed only in the conditions of an operation room**):

- Doughy tissue in the fornix, swelling, pulsation of vessels;
- Impossible to palpate the presented part through the fornix.

In case of bleeding of specific character, the presentation is not meaningful because the obstetrical tactics are determined by the volume of blood loss and the condition of the woman.

Distinguishing features of placenta previa and abruptio placentae

	Placenta previa	Abruptio placentae
Clinical features:	(a) Painless, apparently causeless and recurrent	(a) Painful, often attributed to preeclampsia or trauma and continuous
• Nature of bleeding	Bleeding is always revealed	(b) Revealed, concealed or usually mixed
	Bright red	Dark colored
• Character of blood		
• General condition and anemia	Proportionate to visible blood loss	Out of proportion to the visible blood loss in concealed or mixed variety

ONMedU, Department of Obstetrics and Gynecology. Lecture № 5-6. Obstetric bleeding during the second half of pregnancy, childbirth and the postpartum period. Algorithm for providing emergency care for obstetric bleeding. Part I, II.

<ul style="list-style-type: none"> • Features of preeclampsia 	Not relevant	Present in one-third cases
Abdominal examination: <ul style="list-style-type: none"> • Height of uterus 	Proportionate height to gestational age	May be disproportionately enlarged in concealed type
<ul style="list-style-type: none"> • Feel of uterus 	Soft and relaxed	May be tense, tender and rigid
<ul style="list-style-type: none"> • Malpresentation 	Malpresentation is common. The head is high floating	Unrelated, the head may be engaged
<ul style="list-style-type: none"> • FHS 	Usually present	Placenta in upper segment
Placentography (USG)	Placenta in lower segment	Placenta in upper segment
Vaginal examination	Placenta is felt on the lower segment	Placenta is not felt on lower segment. Blood clots should not be confused with placenta

Placenta previa with bleeding is an urgent indication for hospitalization.

Algorithm of examining a pregnant woman with bleeding in the hospital:

- Specify the anamnesis;
- Evaluate the general condition, volume of blood loss;
- General instrumental tests (blood type, Rhesus factor, general blood analysis, coagulogram);
- External obstetrical examination;
- Examination of the uterine cervix and vagina in an operational room with the help of vaginal mirrors to exclude such reasons for bleeding as cervical polyp, cervical cancer, rupture of a varicose node, evaluate vaginal discharge;
- Additional methods of examination (US) if indicated, if there is no need for urgent delivery.

Treatment:

Treatment tactics depend on the volume of blood loss, conditions of the patient and fetus, character of the presented part, term of the pregnancy, maturity of the fetus's lungs.

Principles for conducting patients with placenta previa:

1. In case of small blood loss (250 ml), absence of symptoms of hemorrhagic shock, fetal distress, absence of labor activity, immaturity of the fetus's lungs before 37 weeks term - waiting tactics.
2. Bleeding that has stopped - US, prepare the fetus's lungs. The purpose of waiting tactics – prolong the pregnancy to term of a viable fetus.
3. In case of progressing uncontrollable bleeding (more than 250 ml), accompanied by symptoms of hemorrhagic shock, fetal distress, regardless of the pregnancy term, condition of the fetus (live, distress, dead) - urgent (emergency) delivery.

Clinical variants:

1. Blood loss (up to 250 ml), there are no symptoms of hemorrhagic shock, fetal distress, term of pregnancy - less than 37 weeks:
 - hospitalization;
 - tocolytic therapy when indicated;
 - quicken the maturing of the fetus's lungs before 34 weeks of pregnancy (dexamethasone 6 mg every 12 hours for 2 days);
 - monitoring the woman and fetal condition.
 - If bleeding progresses more than 250 ml – delivery by Cesarean section.
2. Considerable blood loss (more than 250 ml) with premature term of pregnancy – regardless of the presented part – emergency Cesarean section.
3. Blood loss (up to 250 ml) with mature pregnancy:

Under the conditions of an operational room, determine the presentation:

- In case of partial placenta previa, intact amniotic sac and cephalic presentation, active uterine contractions, perform amniotomy. If the bleeding stops, delivery can be performed vaginally. After the birth of the baby - i/m introduction 10 units of oxytocin, carefully observe the contractions of the uterus and character of vaginal discharge. If bleeding continues - Cesarean section;

- During complete or incomplete placenta previa, wrong fetal position (pelvic, diagonal or transverse) perform a Cesarean section;

- During incomplete placenta previa, dead fetus perform amniotomy, if the bleeding stops – vaginal delivery.

4. Blood loss (more than 250 ml) mature pregnancy regardless of the presentation - emergency Cesarean section.

5. Complete placenta previa: diagnosed by US, without bleeding – hospitalization till mature term for delivery, Cesarean section at 37-38 weeks.

In the early postnatal period - careful supervision of the woman's condition. If the bleeding reoccurs after Cesarean section and the volume of blood loss is more than 1% of body weight - urgent relaparotomy, hysterectomy without the appendages, if necessary – ligation of the internal iliac arteries by an expert.

Compensation for the blood loss, treatment of hemorrhagic shock and DIC - syndrome is performed when indicated.

Premature detachment of a normally located placenta

Code number - 045 Premature detachment (tearing away of the placenta)

045.0 Premature detachment of the placenta with coagulation dysfunction

045.8 Other premature detachment of the placenta

045.9 Premature non-specified detachment of the placenta

Premature detachment of a normally located placenta is the premature pathological detachment from the uterine walls during the pregnancy or during the I - II periods of labor.

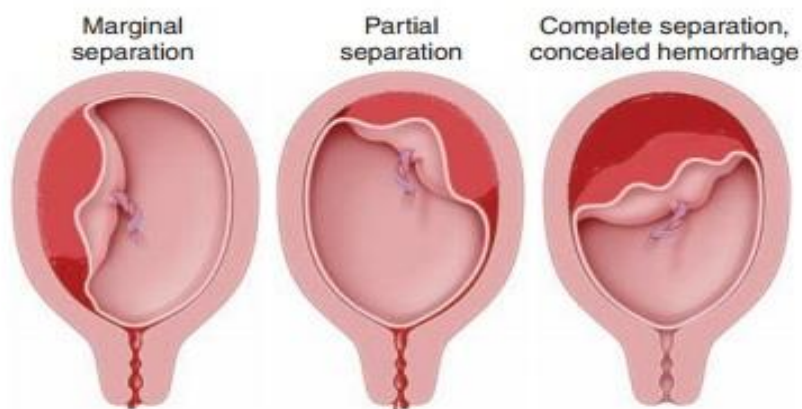


FIGURE 21.3. Types of placental abruption. Note that vaginal bleeding is absent when the hemorrhage is concealed.

ETIOLOGY: The exact cause of separation of a normally situated placenta remains obscure in majority of cases. The prevalence is more with:

- high birth order pregnancies with gravida 5 and above — three times more common than in first birth
- advancing age of the mother

- poor socio-economic condition
- malnutrition
- smoking (vaso-spasm).
- Hypertension in pregnancy is the most important predisposing factor. Pre-eclampsia, gestational hypertension and essential hypertension, all are associated with placental abruption.
- Trauma: Traumatic separation of the placenta usually leads to its marginal separation with escape of blood outside. The trauma may be due to:
 - Attempted external cephalic version specially under anesthesia using great force
 - Road traffic accidents or blow on the abdomen
 - Needle puncture at amniocentesis.
- Sudden uterine decompression: Sudden decompression of the uterus leads to diminished surface area of the uterus adjacent to the placental attachment and results in separation of the placenta. This may occur following—
 - delivery of the first baby of twins
 - sudden escape of liquor amnii in hydramnios and
 - premature rupture of membranes.
- Short cord, either relative or absolute, can bring about placental separation during labor by mechanical pull.
- Supine hypotension syndrome: In this condition which occurs in pregnancy there is passive engorgement of the uterine and placental vessels resulting in rupture and extravasation of the blood.
- Placental anomaly: Circumvallate placenta
- Sick placenta: Poor placentation, evidenced by abnormal uterine artery Doppler waveforms is associated with placental abruption.
- Uterine factor: Placenta implanted over a septum (Septate Uterus) or a submucous fibroid. Torsion of the uterus leads to increased venous pressure and rupture of the veins with separation of the placenta.
- isoimmune conflict between the mother and fetus;
- overdistension of the uterus (hydramnion, multiple pregnancy, large fetus);
- diabetes;
- kidney disease;
- inflammatory processes of the uterus, placenta;

Classification:

1. Complete detachment (the whole placenta detaches).
2. Partial detachment:
 - marginal
 - central

Clinical symptoms:

1. Pain syndrome: sharp pain at the location of the placenta which then extends to the whole uterus, abdomen, back and becomes diffuse. The pain is most expressed during

central detachment and can be not as expressed for marginal detachment. For detachment of a placenta located on the posterior uterine wall, the pain can simulate renal colic.

2. Hypertonus of the uterus up to tetany, which does not decrease with spasmolytic, tocolytic agents.

3. Vaginal bleeding can vary depending on the severity and character (marginal or central) from insignificant to massive. If the hematoma is formed retroplacenta, external bleeding can be absent.

Diagnostics:

1. Condition of the pregnant woman will depend on the size of the detachment, volume of blood loss, occurrences of symptoms of hemorrhagic shock or DIC - syndrome.

2. External obstetrical examination:

- hyper tonus of the uterus;
- the uterus is increased in size, can be deformed with local bulging if the placenta is located on the anterior wall;
- pain, tenderness during palpation;
- difficult or impossible palpation and auscultation of the fetal heart beat;
- occurrence of symptoms of fetal distress or its death.

3. Internal obstetrical examination:

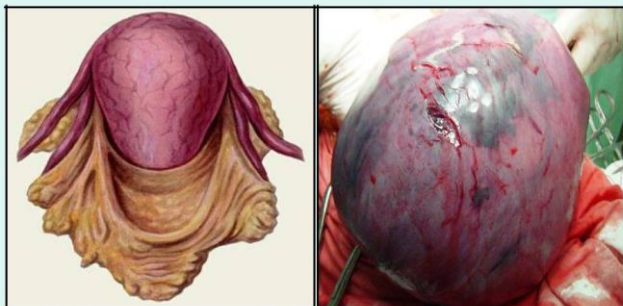- strained amniotic sac;
- amniotic fluid with blood;
- bleeding of from the uterus.

4. US (echo-negative shadow between the uterus and placenta), but this method cannot be absolute diagnostic criterion, because a hypoechogenic zone can be seen in patients without detachments.

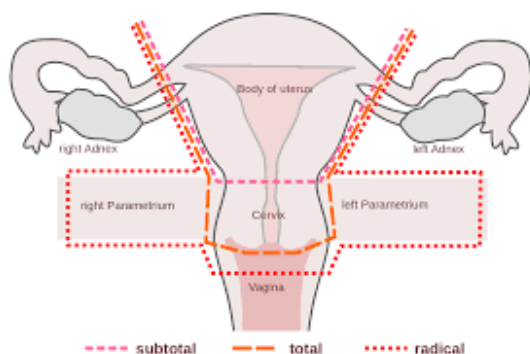
In case of absence of external bleeding the diagnosis of premature detachment of placenta is based on increased uterus tonus, local tenderness, deterioration of the fetal condition. Blood from retroplacental hematomas penetrates the wall of the uterus and forms Couvelaire's uterus (utero-placental apoplexy) which then loses the ability to contract, which leads to the development of bleedings with massive blood loss as a result of coagulopathy and hypotonus.

Treatment:

Unreasonably overdue delivery leads to the death of the fetus, development of Couvelaire's uterus, massive blood loss, hemorrhagic shock and DIC - syndrome, loss of reproductive function.



1. In case of progressing premature detachment of the placenta during the pregnancy, or in the first period of labor, with the occurrence of symptoms of hemorrhagic shock, DIC - syndrome, signs of fetal distress, regardless of the pregnancy term - urgent delivery by Cesarean section. In the presence of signs of Couvelaire's uterus – hysterectomy without the uterine appendages.



2. Restore the blood loss, treatment of hemorrhagic shock and DIC - syndrome.

3. In case of non-progressing detachment of the placenta, possible dynamic supervision for premature pregnancy till 34 weeks (carrying out therapy for the maturing of the fetus's lungs), in establishments where there is round-the-clock watch of qualified OBGYN doctors, anesthesiologists, neonatologists. Monitoring of the woman's condition and fetal condition, CTG, US in dynamics are done.

Features of the Cesarean section:

- prior to the operation - amniotomy (if there are conditions);
- obligatory revision of the uterine walls (especially the external surface) for the purpose of an excluding utero-placental apoplexy;

- in case of diagnosing of Couvelaire's uterus - hysterectomy without the uterine appendages;

- if there is a small area of apoplexy - 2-3 foci of small diameter 1-2 cm, or one - up to 3 cm), and the ability of the uterus to contract, absence of bleeding and signs of DIC - syndrome, if necessary to keep reproduction function (first childbirth, dead fetus), there is questions about preserving the uterus. Surgeons observe the condition of the uterus for some time (10-20 min.) with the abdominal cavity still open, in the absence of bleeding the abdominal cavity is drained for hemostasis control. Such tactics, in unusual cases, are performed only in establishments, in which round-the-clock watch of doctors OBGYN, anesthesiologist is available;

- In the early postoperative period - careful supervision of the woman's condition.

Tactics for placental detachment in the end of the I or during the II stages of labor

- Immediate amniotomy, if the amniotic sac is intact;

- If cephalic fetal presentation – apply obstetrical forceps;

- If breech presentation – extraction of the fetus by the pelvic;

- If transverse position of the second twin – perform obstetrical turn with extraction of the fetus by the leg. In some cases more reliable will be Cesarean section;

- Manual detachment of the placenta and removal of the placenta;

- Contractive agents - i/v 10 units of oxytocin, in the absence of effect - 800 mkg misoprostole (rectal);

- Careful dynamic supervision in the postpartum period;

- Restore the blood loss, treatment of hemorrhagic shock and DIC - syndrome.

Reasons for bleeding in the third stage of labor and early postpartum periods (stages):

1. Anomaly of placental abruption processes:

- Insufficient contractility of the myometrium
- Anomalies of placentation
- Strong attachment of the placenta (partial)
- Placenta adherence (partial)
- Ruptured uterus (complete, incomplete)

2. Anomaly in the processes of expulsion of the placenta:

- hypotension of the uterus
 - delay of the placenta in the lower segment of the uterus
 - incorrect methods of removing the placenta,
 - irrational introduction of uterotonics drugs
3. Trauma to the genital tract, in particular the uterus.
 4. Placental defects, delay of parts of the placenta, its membranes
 5. Hemostasis dysfunction, caused by complicated course of pregnancy and labor (coagulopathy).

Blood loss during labor should be no more than 0,5% of the woman's body weight. This is physiological!

Postpartum bleeding – blood loss more than 0.5% of the woman's body weight after the birth of the baby. Bleedings in some minutes or hours after the delivery - serious and potentially fatal complication. Bleedings can be sudden and profuse, or slow and long.

Classification:

- 072.0 - Bleeding in the third stage of labor
- 072.1 - Other bleedings in the early postpartum period
- 072.2 - Late or secondary postpartum hemorrhage
- 072.3 - Postpartum coagulation disorder

Types of postpartum hemorrhage:

1. Hemorrhage in the third stage of labor.
2. Primary (early) postpartum hemorrhage which occurs in the early postpartum period or within 24 hours after delivery.
3. Secondary (late) postpartum hemorrhage which occurs after 24 hours and up to 6 weeks after delivery.

Risk factors of postpartum hemorrhage:

- burdened obstetrical anamnesis (bleedings in previous deliveries, abortions, miscarriages);
- preeclampsia;
- big fetus;
- polyhydramnios;
- multiple pregnancy;
- uterus myoma;
- seam on the uterus;
- chronic DIC - syndrome;
- thrombocytopathy;
- antenatal death of the fetus.

Bleeding in the third stage of labor

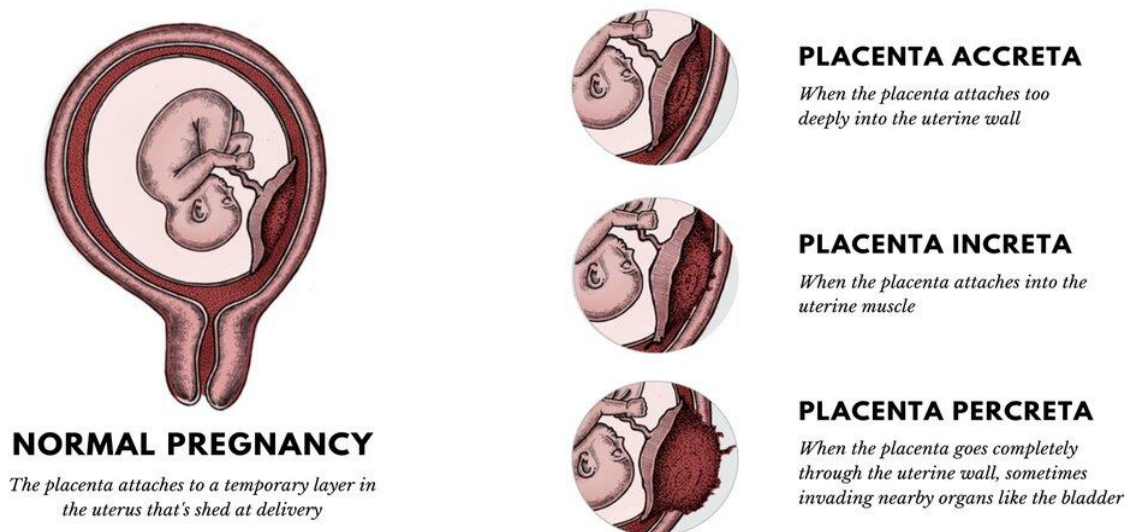
Reasons:

- delay of parts of the placenta or its membranes;
- pathological attachment of the placenta;
- pinching of the placenta.

The amount of blood loss depends on the type of placental attachment disorder: complete, partial adhesion of the placenta.

Classification of anomalies of placentation:

NORMAL PLACENTA VS. PLACENTA ACCRETA SPECTRUM (PAS)



Firm (compact) attachment of the placenta:

placenta accreta - pathological attachment of the placenta to the endometrium (porous layer is absent);

Penetration of the placenta:

placenta increta – penetration into the myometrium;

placenta percreta – invasion of the placenta the whole myometrium

The firm attachment of the placenta or its penetration can be complete (not accompanied by bleeding) and partial (accompanied by considerable bleeding due to detachment of parts of the placenta)

Reasons for pathological attachment of the placenta - changes in the structure of the porous layer of the basal decidual membrane due to:

- chronic endometritis,
- cicatricial and dystrophic changes after previous abortions or intra-uterine interventions,
- insufficient development of the uterus,
- decrease in the activity of trophoblast enzymes,
- pathological location of the placenta.

Clinical displays:

1. There are no signs of detachment of the placenta for 30 minutes without considerable blood loss - pathology of adherent or penetrated placenta.

2. Bleeding begins right after the birth of the afterbirth - delay of parts of the placenta or its membranes.

3. Bleeding begins after the birth of the child without detachment of the placenta – pinched placenta, an incomplete penetration of the placenta.

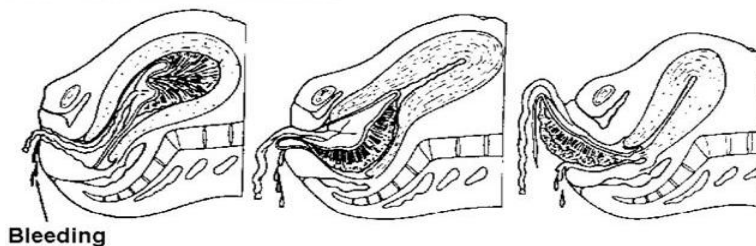
Algorithm for medical help:

1. Catheterization of a peripheral or central vein depending on the volume of blood loss and conditions of the woman.
2. Empty the bladder.
3. Check for signs of detachment of the placenta and deliver the placenta using manual maneuvers.

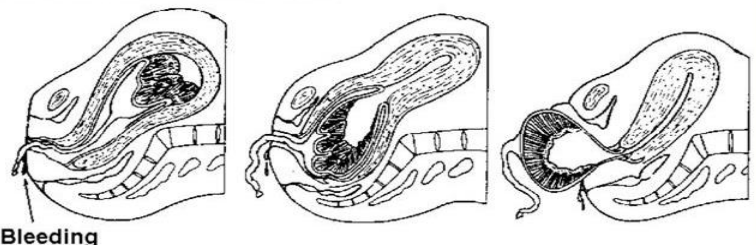
Signs of placental separation:

- The uterus becomes firm, round in shape and rises up.
- Lengthening of the umbilical cord.
- Sudden gush of blood

Duncan mechanism

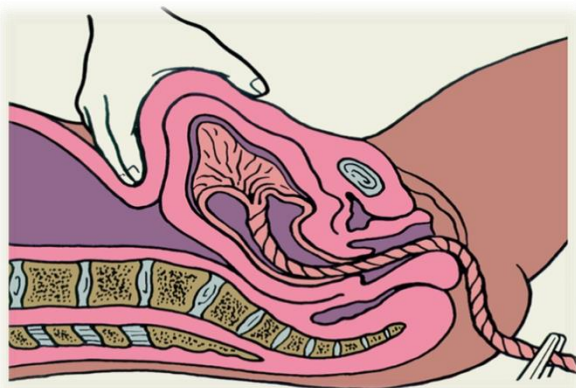


Schultze mechanism

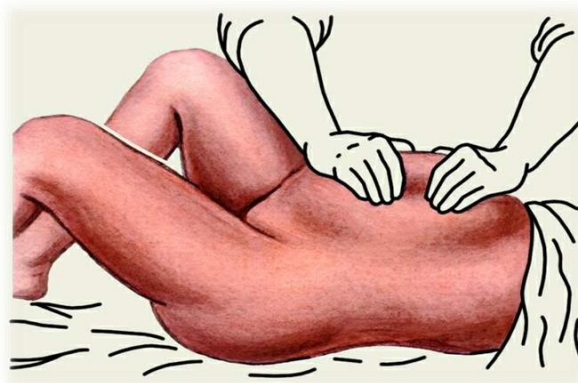

- The time from fetal delivery to delivery of the placenta
- Signs of placental separation:
 - a. The uterus becomes globular in shape and firmer.
 - b. The uterus rises in the abdomen.
 - c. The umbilical cord descends three (3) inches or more further out of the vagina.
 - d. Sudden gush of blood.

4. In case of pinching of the placenta, external massage of the uterus, external maneuvers for delivering the placenta.



Crede-Lazarovich's maneuver



Abuladze's maneuver

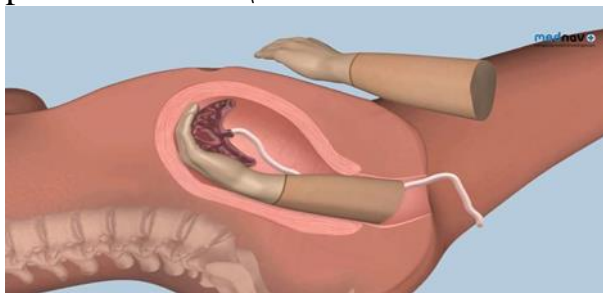
Abuladze's maneuver-after gentle massage of the uterus, take the anterior-abdominal wall with both hands into a longitudinal fold and ask the woman to push.

Crede-Lazarovich's maneuver- take the bottom of the uterus, the thumb is on the front wall of the uterus, the palm is on the bottom, and four fingers are on the back of the uterus.

5. In case of delay of parts of the placenta or its membranes - manual examination of the uterus cavity under intravenous narcosis.

6. If placental separation has not occurred and there is no bleeding, wait 30 minutes; manual detachment of the placenta and delivery of the placenta.

7. If bleeding occurs - urgent manual detachment of the placenta and deliver the placenta under i/v narcosis.



8. Introduction uterotonic agents – 10-20 units of oxytocin i/v in 400 ml of physiological solution by droplets.

9. If true adherence or penetration of the placenta – laparotomy, hysterectomy without the uterine appendages.

10. Evaluate the volume of blood loss and restore the blood volume (treatment of hemorrhagic shock).

Early (primary) postpartum hemorrhage

Reasons for early postpartum hemorrhage:

- hypotonic and atonic uterus (in 90% of the cases);
- delay of parts of the placenta or membranes;
- trauma to the birth canal;
- coagulation disorders (afibrinogenemia, fibrinolysis);
- Blood coagulation disorders

• Reasons of hypotonic and atonic uterus:

- disorder of the functional ability of the myometrium (preeclampsia, endocrinopathy, somatic diseases, tumors of the uterus, seam on the uterus, big fetus, polyhydramnios, multiple pregnancy and others);
- overexcitation with the following exhaustion of the function of the myometrium (prolonged labor), operative labor, taking drugs that reduce the tone of the myometrium (spasmolytic, tocolytics, hypoxia during delivery, etc.);
- disorder of the contractive functions of the myometrium due to disorder of biochemical processes, correlation of neurohumoral factors (estrogen, acetylcholine, oxytocin, choline esterase, progesterone, prostaglandin);
- disorders in the process of attachment, detachment and discharge of the placenta and its membranes;

- idiopathic (not established).

Hemorrhage can be of 2 kinds:

- Bleeding begins immediately after childbirth, massive (after a few minutes > 1000 ml); the uterus remains hypotonic, does not contract, hypovolemia, hemorrhagic shock develops rapidly;

- Bleeding begins after contraction of the uterus, blood flows in small portions, blood loss gradually increases. The alternation of uterine hypotonia with restoration of tone is characteristic. The bleeding stops and starts again.

Steps of management:

1. General observation:

- evaluation of blood loss

- evaluation of the condition of the woman: complaints, BP, pulse rate, color of the skin and mucous membranes, amount of urine, presence and stage of hemorrhagic shock.

2. Urgent laboratory tests:

- determine the level of hemoglobin, hematocrit;

- coagulogram (amount of thrombocytes, prothrombin index, level of fibrinogen, coagulation time of blood);

- blood type and Rhesus factor;

- biochemical test if indicated.

3. Catheterization of peripheral or central vein depending on the size of blood loss and conditions of the woman.

4. Empty the urinary bladder.

5. Begin or continue introducing uterotonics: 10-20 units of oxytocin i/v in 400 ml of physiological solution.

6. Perform manual inspection of the uterine cavity under intravenous narcosis (evaluation of the integrity of the uterine walls, especially the left wall, remove clots of blood or the rest of the placenta or its membranes).

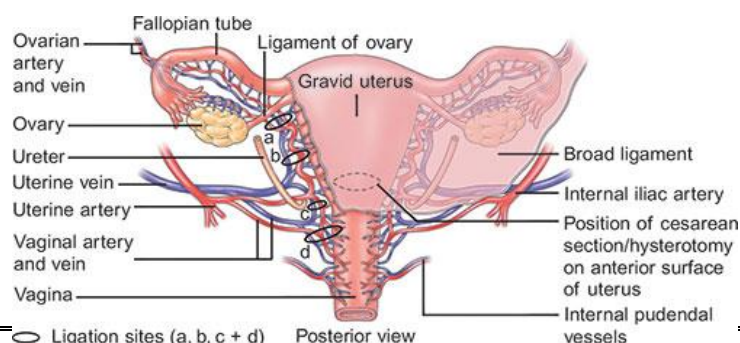
7. Examine the birth canal and restore its integrity.

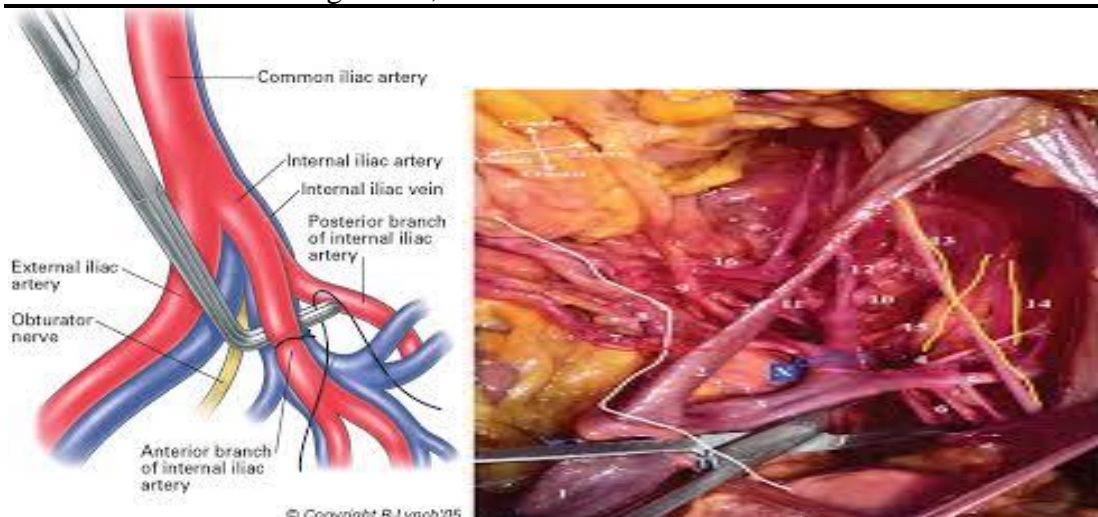
8. External massage of the uterus.

9. In case of continuation of bleeding introduce 800 mkg of misoprostole rectally.

10. Restore blood volume and blood loss (treatment of hemorrhagic shock).

11. If bleeding continues, blood loss is 1,5% or more of the woman's body weight – treatment is operative: hysterectomy without the uterine appendages, if the bleeding continues – ligation of the internal iliac arteries.





12. During preparation for operative treatment, to reduce blood loss, bimanual external or internal compression of the uterus.

13. If bleeding continues after hysterectomy - hard tamponade of the abdominal cavity and vagina (the abdominal cavity is not sutured up until the bleeding stops).

Postpartum secondary (late) hemorrhage

Main causes for late postpartum hemorrhage:

- delay of parts of the placenta or its membranes;
- discharge of necrotic tissue after delivery;
- separation of sutures on the wound on the uterus (after C-section or ruptured uterus).

Late postpartum hemorrhage occurs 7-12 days after delivery.

Steps of management:

1. Evaluation of blood loss
2. Catheterization of peripheral or central vein.
3. Instrumental revision of the uterine cavity under i/v narcosis.
4. I/v introduction of uterotonics (oxytocin 10-20 units in physiological solution - 400,0 or 0,5 mkg of methylergometrine).
5. If the bleeding continues – misoprostol 800 mkg rectally.
6. Restore blood volume.
7. If blood loss > 1,5% of the woman's body weight – laparotomy, hysterectomy, if it still continues – ligation of the internal iliac arteries.

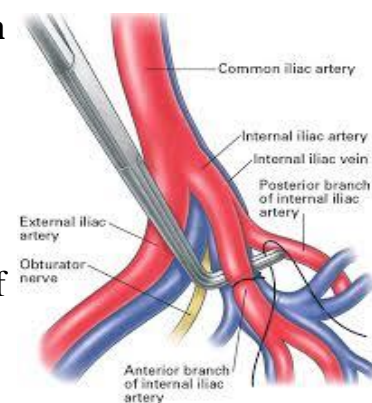
Blood coagulation disorders (postpartum afibrinogenemia, fibrinolysis):

- restore blood volume;
- correct hemostasis.

Prevention of postpartum hemorrhage:

1. During pregnancy:

- evaluate the risk factors for the occurrence of hemorrhage;



Factors which assist in the occurrence of hemorrhage in the postpartum period

Previous pregnancy	Factors, which occurred during the pregnancy	Factors, which occurred during the delivery
Primipara	Complete placental presentation	Stimulation of delivery
More than 5 deliveries in anamnesis	Placental detachment	Long or difficult delivery
Pathology in detachment or discharge of the placenta	Hydramnion	Fast delivery
Operations on the uterus in the anamnesis, including C-sections	Multiple pregnancy	Emergency Cesarean section
Long or difficult delivery in anamnesis	Intrauterine fetal death	Delivery with obstetrical forceps
Background diseases –cardio-vascular diseases, diabetes, coagulation disorders	Severe pre-eclampsia, eclampsia	Chorioamnionitis
Anemia	Hepatitis	DIC – syndrome
Hysteromyoma	Conditions connected with anemia	General or epidural anesthesia

- Diagnostics and treatment of anemia;
- Hospitalization, readiness to give medical help to pregnant women of high risk for hemorrhage: antenatal hemorrhage, hemorrhage in labor, polyhydramnios, multiple pregnancy, big fetus.

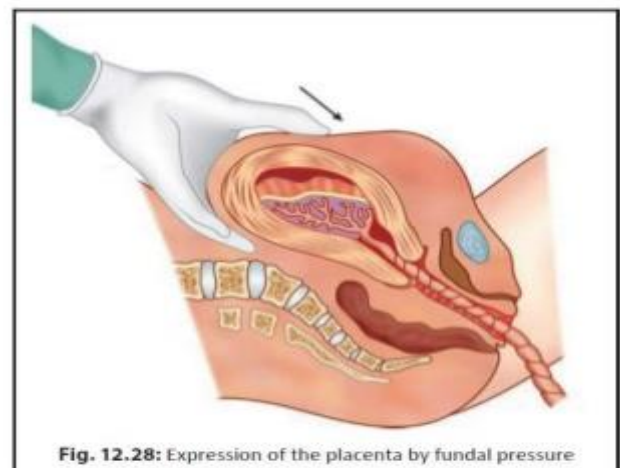
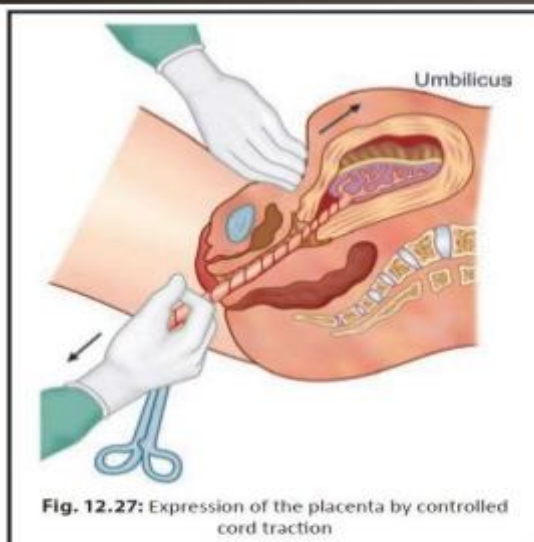
2. During delivery:

- anesthesia during labor;
- avoid prolong labor;
- **Active management of third stage of labor.** The underlying principle in active management is to excite powerful uterine contractions within one minute of delivery of the baby (WHO) by giving parenteral oxytocic. This facilitates not only early separation of the placenta but also produces effective uterine contractions following its separation. The advantages are — (a) to minimize blood loss in third stage approximately to 1/5th and (b) to shorten the duration of third stage to half.

Injection oxytocin 10 units IM (preferred) or methergin 0.2 mg IM is given within 1 minute of delivery of the baby (WHO). The placenta is expected to be delivered soon following delivery of the baby. If the placenta is not delivered thereafter, it should be delivered forthwith by **controlled cord traction (Brandt-Andrews)** technique after clamping the cord while the uterus still remains contracted. If the first attempt fails, another attempt is made after 2–3 minutes failing which another attempt is made at 10 minutes. If this still fails, manual removal is to be done. Oxytocic may be given with crowning of the head, with delivery of the anterior shoulder of the baby or after the delivery of the placenta. If the administration is mistimed as might happen in a busy labor room, one should not be panicky but conduct the third stage with conventional watchful expectancy.

Controlled cord traction (modified Brandt-Andrews method)—The palmar surface of the fingers of the left hand is placed (above the symphysis pubis) approximately at the junction of upper and lower uterine segment (Fig. 12.27). The body of the uterus is pushed upwards and backwards, toward the umbilicus while by the right hand steady tension (but not too strong traction) is given in downward and backward direction holding the clamp until the placenta comes outside the introitus.

Fundal pressure—The fundus is pushed downwards and backwards after placing four fingers behind the fundus and the thumb in front using the uterus as a sort of piston. The pressure must be given only when the uterus becomes hard. If it is not, then make it hard by gentle rubbing. The pressure is to be withdrawn as soon as the placenta passes through the introitus.



- use uterotonic during the third period of labor;
- routine observation and evaluation of the integrity of the placenta and its membranes;
- prevention of trauma during labor.

3. After labor:

- Inspection and examination of the birth canal;
- Attentive supervision throughout 2 hours after delivery;
- In woman of high risk – i/v introduction of 20 units of oxytocin for 2 hours after the delivery.

Methods for determining the volume of blood loss

1. Libov's Method

Volume of blood loss is determined by weighing the napkins used, which are soaked in blood

Volume of blood loss = $B / 2 \times 15\%$ (blood loss less than 1000 ml) or $\times 30\%$ (blood loss more than 1000 ml).

Where B - weight of the napkins, 15 % and 30 % - error size (amniotic fluid, physiological solution).

2. Nelson's formula

The percentage ratio of the total amount of blood loss is figured:

$$\frac{0,036 \times \text{original blood volume}}{\text{body weight}} \times \text{hematocrit}$$

3.	original blood volume (ml/kg) =	$\frac{24}{0,86 \times \text{original hematocrit}} \times 100$	hematocrit
			Volume of blood loss, ml
	1053-1050	38-32	1000
	1049-1044	30-22	1500
	Less than 1044	Less than 22	More than 1500

4. Algover's Shock index

$$\text{Shock index} = \frac{\text{Heart rate}}{\text{BPs}}$$

Normally Algover's index = 1.

By determining the index size it is possible to conclude about the size of blood loss

Algovera's index	Volume of blood loss (% of blood volume)
0,8 and less	10 %
0,9-1,2	20 %
1,3-1,4	30 %

1,5 and more

40 %

NB! Algover's index is not informative in patients with hypertension

5. Moore's hematocrit method

$$BL = BV (n) \times (Ht (n) - Ht (a)) / Ht (n)$$

Where:

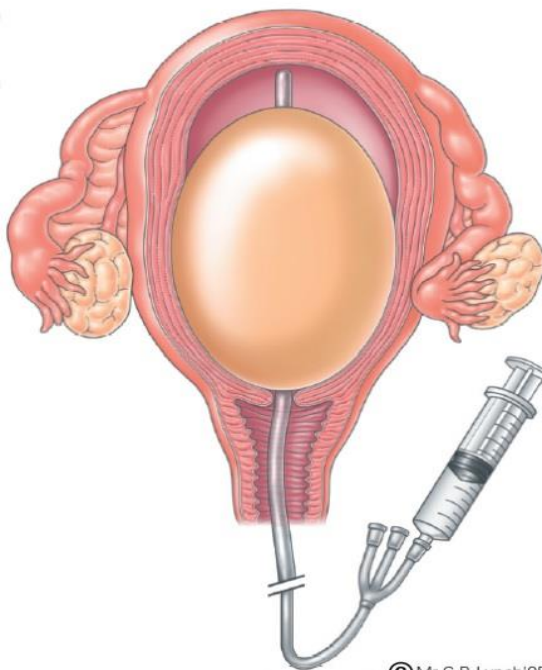
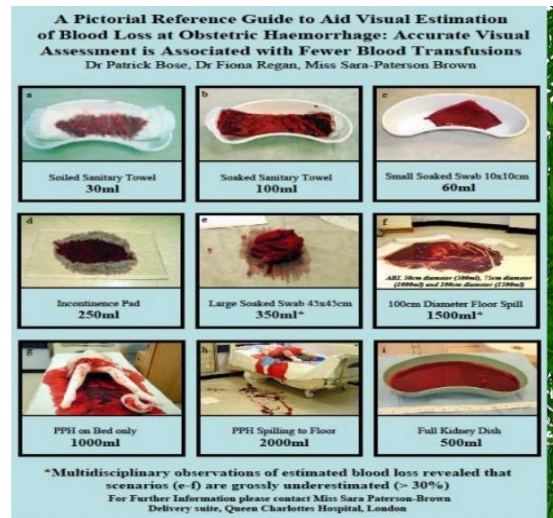
BL – blood loss; BV (n) – normal blood volume; Ht (n) – normal hematocrit (in woman – 42);

Ht (a) – actual hematocrit determined after blood loss is stopped and hemodynamics are stabilized

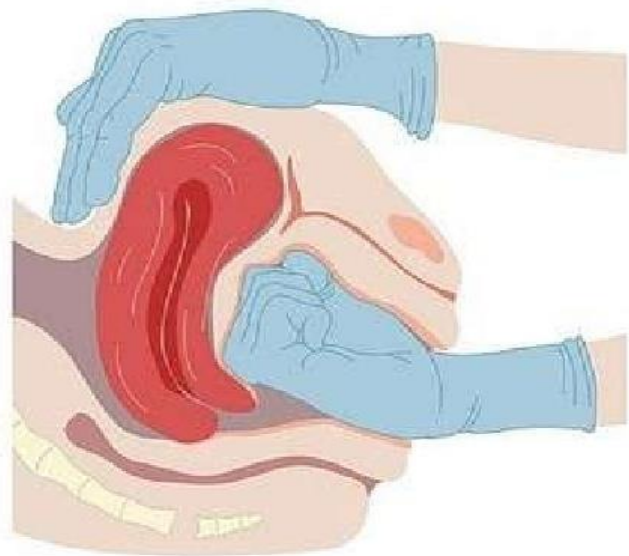
For rough amount of blood loss in pregnant women it is possible to use the modified Moore's formula:

$$BL = M \cdot 75 \cdot \frac{0,42 - Ht (a)}{0,42}$$

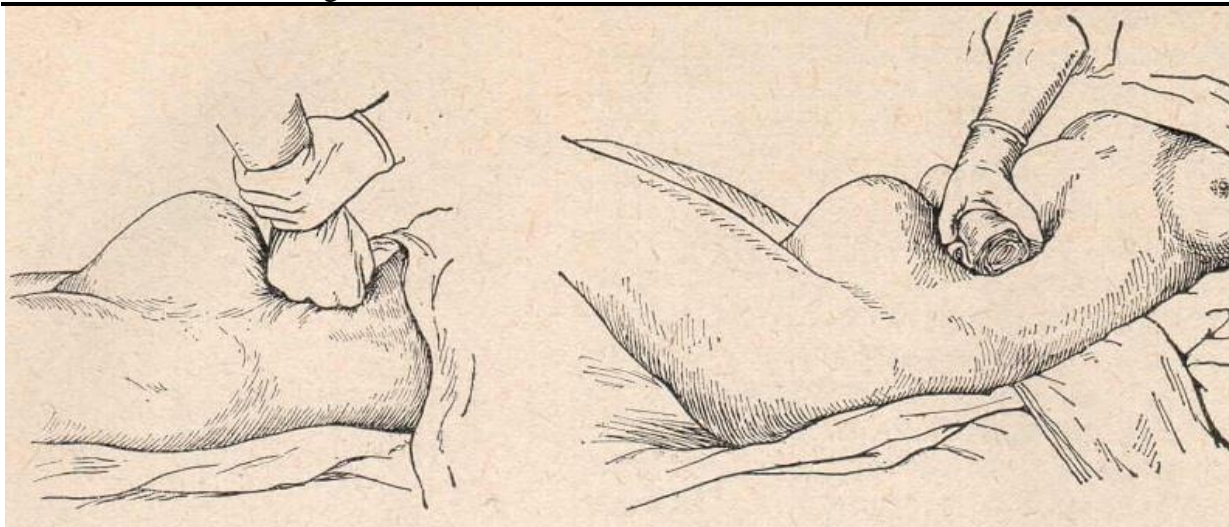
Where: BL – blood loss; (ml); M – woman's body weight (kg); Ht (a)- patient's actual hematocrit (l/l)



Balloon tamponade of uterus



Bimanual compression of the uterus



Compression of the aorta

Coagulopathic bleedings

Any congenital or acquired coagulopathies can lead to profuse postnatal bleeding (delay of dead fetus in the uterus, amniotic fluid embolism, premature detachment of a normally located placenta, rupture of the uterus, sepsis, massive transfusions, severe pre-eclampsia and eclampsia, extra-genital pathology). Therapy can result in disorder in the system of hemostasis during delivery with use of anticoagulants, long hemodilution. It should be remembered, that profuse bleeding can lead to coagulopathy.

Bleeding due to intrauterine death of the fetus

If childbirth does not occur right after death of the fetus, severe coagulopathy can develop, caused by the discharge of thromboplastin from the tissue of the fetus. Treatment is immediate delivery and correction of the coagulation disorder. Induction of labor is conducted by intravenous introduction of oxytocin or prostaglandin. It is necessary to avoid hyperstimulation of labor, especially after 28 weeks, in connection with risk of rupture of the uterus in such patients.

Managing Maternal Haemorrhage

Vital Signs

Airway

- Provide adequate ventilation
- Assess need for intubation

Breathing

- Supplemental O₂ 5-7 L/min by tight face mask

Circulation

- Pallor, delayed capillary refill, and decreased urine output can indicate compromised blood volume without change in BP or HR
- Decreased urine output, decreased BP, and tachycardia may be late signs of compromise

Actions

- Notify team
- Bring cart & medications to patient room

- Activate Massive Transfusion Protocol

Infusions

- Start 2nd large bore IV (16 gauge if possible)
- Ringers Lactate (RL) replaces blood loss at 2:1
- Prepare for transfusion
- Blood coagulation factors
- Warm blood products and infusions to prevent hypothermia, coagulopathy, and arrhythmias

Medication for Uterine Atony

oxytocin (Pitocin) 10-40 units per 500-1000mL solution

methylergonovine (Methergine) 0.2 milligrams IM

Avoid with hypertension prostaglandin f2 alpha (Hemabate) 250 micrograms IM (may repeat in q15 minutes, maximum 8 doses)

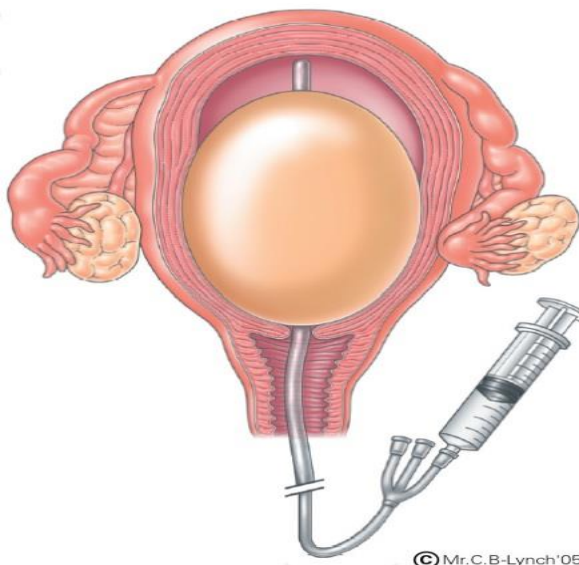
Avoid with asthma; use with caution with hypertension misoprostol (Cytotec) 800-1000 micrograms PR, 600 micrograms PO, or 800 micrograms SL

First stage (blood loss <1000 ml)				
Etiology	Tone	Manual inspection of the uterine walls		simultaneously
	Tissue	One-time		
	Trauma	Suturing, laparotomy		
	Thrombin	Transfusion of coagulation factors		
Priority	Carbetocin, oxytocin	Methylergometrine	prostaglandins	
Primary dose	-Carbetocin-100 mcg i/v once -Oxytocin 10 units i/m	Methylergometrine 0.2 mg i/m or i/v	Misoprostol 800 mcg per rectum	
Repeated absence of bleeding	-Oxytocin 10 units i/v in 500 ml solution 60 min.	Methylergometrine 0.2 mg i/m or i/v every 4 hours	-----	
Max dose	Not more 3 l liq in day, oxytocine	3 doses(1.0 mg)	Misoprostol 800 mcg per rectum	

Contraindication	-----	-preeclampsia -hypertension -heart diseases	-preeclampsia -asthma -glaucoma	
	10 min	10 min	10 min	
Second stage-between conservative and haemostasis				
Balloon tamponade, two handed uterine compression, abdominal aorta compression				

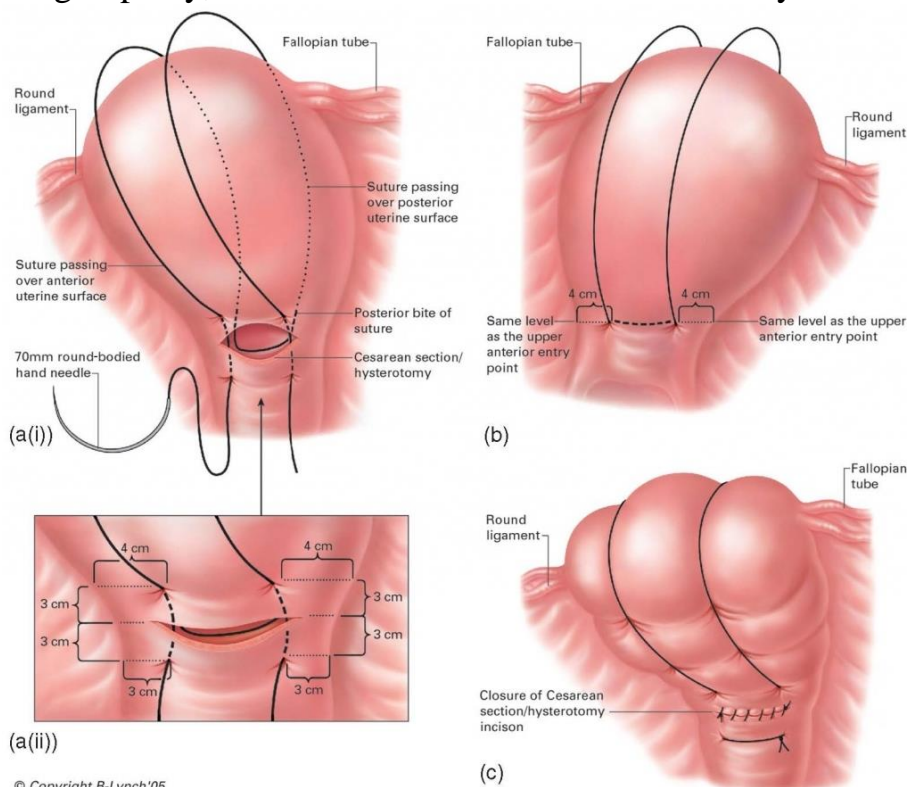
Third stage- surgical - laparotomy		
≥1500 ml	>1500 ml	Angiographic embolization
Injection of prostaglandins in the myometrium, local uterine hypothesis		
Ligatures on ovarian uterine vessels Compression suture on the uterus	Ligation of a lacerated iliac artery, ovarian vessels	
Tight tamponade of the pelvis and vagina	Total subtotal hysterectomy	

Intrauterine balloon tamponade



Surgical Interventions

May be a life-saving measure and should not be delayed pending correction of coagulopathy, the most common reason for the delay



B-lynch suture

Infusion transfusion therapy of obstetric hemorrhage

Blood loss			Total Transfusion of circ-blood	Infusion and transfusion environment					
Volume of Circ-blood	% of W.body	Blood loss (ml)		Crystolloids	colloids		weight	Thromboconcentrat	
					Synthetic (Gelofusine)	Natural plasma			Albumin 10%
10-20%	1-1.5%	500-1000	200-300 (2.5L)	10-15 ml/kg	10 ml/kg	-----	-----	-----	-----
20-30%	1.5-2%	1000-1500	200 (3L)	10 ml/kg	10 ml/kg	5-10 ml/kg	-----	5 ml/kg	-----
30-40%	2-2.5%	1500-2000	180(4L)	7 ml/kg	7 ml/kg	10-15 ml/kg	200 ml	10-20 ml/kg	cryopre
40-70%	2.5-3.6%	2500-3000	170 (5L)	7 ml/kg	10-15 ml/kg	15-20 ml/kg	200 ml	30 ml/kg	Cryopre

>70%	>3.6%	>3000	150 (>6L)	10 ml/kg	20 ml/kg	>20 ml/kg	>200 ml	>30 ml/kg	4-10 un
------	-------	-------	-----------	----------	----------	-----------	---------	-----------	---------

MATERIALS FOR ACTIVATION OF STUDENTS DURING THE LECTURE: QUESTIONS, SITUATIONAL TASKS, ETC.

QUESTIONS:

- What pathological conditions may cause obstetrical bleeding?
- What is the classification of placenta previa, premature detachment of a normally located placenta and postpartum haemorrhage?
- What are modern views on etiology and pathogenesis of placenta previa?
- What are the methods of examination in placenta previa and premature detachment of a normally located placenta?
- What are the principles and methods of treatment of placenta previa and premature detachment of a normally located placenta?
- What is the differential diagnosis of placenta previa and premature detachment of a normally located placenta?
- Obstetrical tactics and treatment of placenta previa and premature detachment of a normally located placenta?
- Prevention and prophylactics of placenta previa and premature detachment of a normally located placenta?
- The classification and reasons of postpartum haemorrhage?
- What are the risk factors for postpartum haemorrhage occurrence?
- Modern methods of blood loss evaluation?
- Emergency help at postpartum haemorrhage?

TEST TASKS

Direction: For each of the multiple-choice questions select the lettered answer that is the one best response in each case.

1. 1. At survey of a placenta which was just born, presence of defect in size of 2x3 cm was fixed. Bleeding is not present. What tactics is most significant?
 - A. External massage of a uterus.
 - B. Assignment of uterotonic agents
 - C. Manual inspection of uterine cavity.
 - D. Observation over the puerperal women
 - E. Instrumental inspection of uterine cavity
2. At twice pregnant women 25 years old in the third stage of labor the bleeding started with placental defect found. At manual uterine inspection small part of the placenta fixed to the myometrium was determined. Tactics of the doctor?
 - A. Laparotomy, a hysterectomy.
 - B. Instrumental extraction of the placental remnant

C. Application of uterotonic agents

D. Blood transfusion.

E. Prophylaxis of a puerperal uterine inflammation

3. At the puerperal women a massive bleeding after natural twins birth occurred. The placenta and birth canal tissues remained intact. The uterine fundus is higher than a an umbilicus, the uterus at a palpation soft, does not react to uterotonics introduction. What is most common reason of bleeding?

A. Damage of uterine cervix

B. Atony of a uterus

C. Uterine rupture

D. A delay of parts of a placenta

E. A hypotonia of a uterus

4. At the parturient woman with the serious form of a preeclampsia right after the newborn birth bleeding began. The placenta is whole, birth canal tissues intact. The uterine fundus is lower than umbilicus 2 cm, dense. At external uterine massagethe bleeding increased, a blood is liquid and without clots. What diagnosis can be assumed?

A. Uterine rupture

B. A hypotonic bleeding

C. Placental parts delay in uterus

D. A coagulopatic bleeding, the DIC syndrome

E. An embolism by amniotic fluid

5. During caesarian section operation due to complete placental presentation, after placenta removal severe bleeding from placental platform site started. The remnants of placental tissue can not be removed manually, uterus is soft, badly contracted. The diagnosis of a true partial increment of placenta is put. Specify the most rational tactics to stop bleeding.

A. To enter intravenously uterotonics.

B. To remove instrumentally the remnants of a placental tissue.

C. To carry out sewing of bleeding sites.

D. To carry out the main vessels ligation.

E. To carry out a hysterectomy without appendages.

6. Primipara, 22 y.o., after delivery of a newborn, 4000 gr, the haemorrhage has started. Bloodloss – 20 % of CBV (Circulating blood volume), BP 100/60 mm, shock index –

1. Your diagnosis:

A. Hemorrhagic shock I degree

B. Hemorrhagic shock III degree

C. Thromboembolic shock

D. Hemorrhagic shock II degree

E. Septic shock

7. In Woman-in-labor in the early puerperal period haemorrhage appeared. Bloodloss is 1500 ml (1,8 %). General state is severe, the consciousness is confused, anergic stupor, anxiety, body t° - 35,7°C, pale skin, acrocyanosis. Tachicardia 130-140 b/min,

CVP (Central venous pressure) – 20 mm, RR (respiration rate) 40 in min, diuresis per hour 15-20 ml/h, Ht –0,25, shock index – 1,4, Hb –70 g/l. What should be the doctor's tactics?

- A. Cold on the lower abdomen.
- B. Laparotomy. Total hysterectomy without appendages.
- C. Manual revision of uterine cavity and massage of the uterus.
- D. Applying of ligating clamps on parametrium.
- E. Introduction of Ether tampon.

8. At multipara with placental presentation the uterine haemorrhage have appeared. total blood loss – 500 ml, BP 100/60 mm, Ps – 100 in 1 min, pale skin. Determine the shock index:

- A. 1.5
- B. 0.5
- C. 1.0
- D. 0.8
- E. 2.0

9. At woman in early puerperal period haemorrhage started. Total blood loss –1000 ml, BP –90/70 mm, Ps – 120 b/min, pale skin, cold sweat, oliguria. Determine the grade of hemorrhagic shock:

- A. 0
- B. I
- C. II
- D. III
- E. IV

10. At woman in early puerperal period haemorrhage started. Total blood loss –1000 ml, BP –90/70 mm, Ps – 120 b/min, pale skin, cold sweat, oliguria. Determine the total volume of infuse therapy in litres in connection with total blood loss:

- A. 2
- B. 1.5
- C. 2.5
- D. 1
- E. 3

Answer key

1	C	6	D
2	A	7	B
3	B	8	C
4	D	9	C
5	E	10	B

EQUIPMENT AND EDUCATIONAL AND METHODOLOGICAL SUPPORT OF THE LECTURE:

- Obstetric models and obstetric instruments (pelvimeter, obstetric stethoscope, centimeter tape).
- Professional algorithms, structural-logical schemes, tables, videos.
- Results of laboratory and instrumental researches, situational tasks, patients, medical histories.
- Multimedia equipment (computer, projector, screen), TV.

RECOMMENDED LITERATURE

Basic:

1. Gladchuk I.Z. Obstetrics: student`s book / Gladchuk I.Z., Ancheva I.A. . – Vinnitsia: Nova Knyha, 2021. – 288 p.
2. Obstetrics and Gynecology: in 2 volumes. Volume 1. Obstetrics: textbook / V.I. Gryshchenko, M.O. Shcherbina, B.M. Ventskiivskyi et al. (2nd edition). – «Medicina», 2018. – 392 p.
3. Hiralal Konar DC Dutta's Textbook of Obstetrics (9th Ed.) / Hiralal Konar (Ed.). – Jp Medical Ltd, 2018. – 700 p.
4. F. Gary Cunningham Williams Obstetrics (26th Edition) / F. Gary Cunningham, Kenneth Leveno, Jodi Dashe, Barbara Hoffman, Catherine Spong, Brian Casey. – McGraw Hill / Medical, 2022. – 1328 p.
5. Jeremy Oats, Suzanne Abraham Llewellyn-Jones Fundamentals of Obstetrics and Gynaecology (10th Ed) / Jeremy Oats, Suzanne Abraham. – Elsevier, 2016. – 384 p.

Additional:

1. The PROMPT-CIPP Editorial Team. (2019). PROMPT-CIPP Course Participant's Handbook: Care of the Critically Ill Pregnant or Postpartum Woman (Critical Car Prompt Practical Obstetric Multi-professional Training). – Cambridge University Press; 1st edition, 2019. – 136 p.
2. L. A. Magee The FIGO Textbook of Pregnancy Hypertension. An evidence-based guide to monitoring, prevention and management. / L. A. Magee, P. Dadelszen, W. Stones, M. Mathai (Eds). – The Global Library of Women's Medicine, 2016. – 456 p.
3. Edwin Chandrachan Handbook of CTG Interpretation: From Patterns to Physiology / Edwin Chandrachan. – Cambridge University Press; 1st edition, 2017. – 256 p.
4. Louise C. Kenny, Jenny E. Myers Obstetrics by Ten Teachers (20th ed) / Louise C. Kenny, Jenny E. Myers. – CRC Press, 2017. – 342 p.

5. J. Studd Current Progress in Obstetrics and Gynaecology. Vol 4. / J. Studd, Seang Lin Tan, F. Chervenak. – TreeLife Media (A Div of Kothari Medical), 2017. – 419 p.
6. J. Studd Current Progress in Obstetrics and Gynaecology. Vol 5. / J. Studd, Seang Lin Tan, F. Chervenak. – TreeLife Media (A Div of Kothari Medical), 2019. – 403 p.
7. J. Studd Current Progress in Obstetrics and Gynaecology. Vol 6. / J. Studd, Seang Lin Tan, F. Chervenak. – TreeLife Media (A Div of Kothari Medical), 2022. – 309 p.
8. Mark Landon Obstetrics: Normal and Problem Pregnancies, 8th Edition / Mark Landon, Henry Galan, Eric Jauniaux, Deborah Driscoll, Vincenzo Berghella, William Grobman, et al. – Elsevier, 2021. – 1280 pp.
9. Mark B. Landon Gabbe's Obstetrics Essentials: Normal & Problem Pregnancies, 1st Edition / Mark B. Landon, Deborah A. Driscoll, Eric R. M. Jauniaux, Henry L. Galan, William A. Grobman, Vincenzo Berghella. – Elsevier, 2019. – 496 pp.
10. Ian M. Symonds, Sabaratnam Arulkumaran Essential Obstetrics and Gynaecology, 6th Edition / Ian M. Symonds, Sabaratnam Arulkumaran. – Elsevier, 2020. – 480 pp.
11. Myra J. Wick Mayo Clinic Guide to a Healthy Pregnancy, 2nd Edition / Myra J. Wick. – Mayo Clinic Press, 2018. – 520 p.

INTERNET SOURCES:

- <https://www.cochrane.org/>
- <https://www.ebcog.org/>
- <https://www.acog.org/>
- <https://www.uptodate.com>
- <https://online.lexi.com/>
- <https://www.ncbi.nlm.nih.gov/>
- <https://pubmed.ncbi.nlm.nih.gov/>
- <https://www.thelancet.com/>
- <https://www.rcog.org.uk/>
- <https://www.npwh.org/>