

ONMedU, Department of Obstetrics and Gynecology. Practical lesson № 20. Contracted pelvis.
Malposition and malpresentation. Breech presentation. Contracted pelvis.

**MINISTRY OF HEALTH OF UKRAINE
ODESA NATIONAL MEDICAL UNIVERSITY**

International Faculty

Department of obstetrics and gynecology



CONFIRMED by
Vice-rector for scientific and
pedagogical work
Eduard BURIACHKIVSKYI
September 1, 2023

**METHODOLOGICAL RECOMMENDATIONS
FOR PRACTICAL CLASS**

International Faculty, Course V


Discipline “Obstetrics and Gynecology”

Practical lesson №20. Topic: Contracted pelvis. Malposition and malpresentation.
Breech presentation. Contracted pelvis.

ONMedU, Department of Obstetrics and Gynecology. Practical class №20. Contracted pelvis.
Malposition and malpresentation. Breech presentation. Contracted pelvis.

Approved:


Meeting of the Department of Obstetrics and Gynecology of Odesa National
Medical University

Protocol No. 1 dated August 28, 2023, 

Head of the Department _____ (Ihor GLADCHUK)

Developer:

Ph.D., assistant professor of
obstetrics and gynecology department



_____ (N. Nastradina)

PRACTICAL CLASS №20.
“CONTRACTED PELVIS. MALPOSITION AND MALPRESENTATION. BREECH PRESENTATION”

LEARNING OBJECTIVE: is to gain basic knowledge about anatomical, physiological and biochemical changes during malposition and malpresentation fetus in labor, be familiar with risk factors for disproportions between pelvic cavity and position, presentation and size of the fetus. Management of all these situations including main part of it: establish whether threatened or ‘real’ disproportion; admit if risk high; check fetal presentation: anterior or posterior *asynclitism*, with one of the parietal bones preceding the sagittal suture (in posterior asynclitism, the posterior parietal bone leads. Significant degrees of asynclitism can result in labor dystocia and a higher risk of operative delivery.

BASIC CONCEPTS: Variation of female pelvis. Classification. Diagnosis of contracted pelvis. Effects of contracted pelvis on pregnancy and labor. Management. Cephalopelvic disproportion (CPD). Diagnosis, management.

Abnormal lie, position and presentation of the baby: classification, diagnosis, management. Extension of the fetal head: classification, diagnosis, management in labor.

Breech presentation: classification, diagnosis. Antenatal management. External cephalic version. Management of vaginal breech delivery. Assisted breech delivery. Management of complicated breech.

EQUIPMENT

- Multimedia equipment (computer, projector, screen), TV.
- Obstetric models and obstetric instruments (pelvimeter, obstetric stethoscope, centimeter tape).
- Professional algorithms, structural-logical schemes, tables, videos.
- Results of laboratory and instrumental researches, situational tasks, patients, medical histories.

EDUCATIONAL TIME – 4 h

1. ORGANIZATIONAL STAGE

- Greetings,
- checking attendees,
- defining of educational goals,
- providing of positive motivation.

Secondary arrest of cervical dilatation (SACD) is much less common than the above, said to affect 6% of nulliparas and only 2% of multiparas. Although the commonest cause of SACD is still inefficient uterine activity, relative disproportion is far more likely to be the explanation than with primary dysfunction labor. Secondary

arrest does not always indicate genuine cephalon-pelvic disproportion, as inadequate uterine contractions can be correct, resulting in spontaneous vaginal delivery. However, a diagnosis of secondary arrest (especially in a multiparous woman) should prompt a search for obvious problems in the passenger (for example, hydrocephalus, brow presentation, undiagnostic shoulder presentation, large baby, malposition) and the passages (for example, a congenitally small pelvis, a deformed pelvis due to fracture following an accident, or masses in the pelvis). Unfavorable pelvic diameters are rarely a cause of cephalon-pelvic disproportion in the developed world. //the fetus is more commonly the cause of relative disproportion by presenting a large diameter of the vertex due to a malposition or deflexion, or both. In such cases, the dystocia may be overcome. If the flexion and rotation to an occipito-anterior position can be encouraged efficient uterine contractions.

2. CONTROL OF BASIC KNOWLEDGE (written work, written testing, online testing, face-to-face interview, etc.)

2.1. Requirements for the theoretical readiness of students to perform practical classes.

Knowledge requirements:

- Communication and clinical examination skills.
- Ability to determine the list of required clinical, laboratory and instrumental studies and evaluate their results.
- Ability to make a preliminary and clinical diagnosis of the disease
- Ability to perform medical manipulations
- Ability to determine the tactics of physiological pregnancy, physiological labor and the postpartum period.
- Ability to keep medical records.

List of didactic units:

- Variation of female pelvis. Classification.
- Diagnosis of contracted pelvis.
- Effects of contracted pelvis on pregnancy and labor. Management.
- Cephalopelvic disproportion (CPD). Diagnosis, management.
- Abnormal lie, position and presentation of the baby: classification, diagnosis, management.
- Extension of the fetal head: classification, diagnosis, management in labor.
- Breech presentation: classification, diagnosis. Antenatal management.
- External cephalic version.
- Management of vaginal breech delivery.
- Assisted breech delivery.
- Management of complicated breech.

2.2. Questions (test tasks, tasks, clinical situations) to test basic knowledge on the topic of the class.

Questions

- Definition of malposition, malpresentation and cephalon-pelvic disproportion,
- current concepts in the pathophysiology of all,
- risk factors for labor and delivery,
- antenatal management,
- deciding mode of delivery,
- conducting a vaginal breech delivery,
- entrapment of the aftercoming head,
- brow and face presentation,
- shoulder presentation,
- instrumental vaginal delivery.

Tests

1. A woman is 40 weeks pregnant. The fetus is in the longitudinal lie and cephalic presentation. Pelvic size: 26-29-31-20. Expected weight of the fetus is 4800 gr. The labor contractions have been lasting for 12 hours, within the last 2 hours they were extremely painful, the parturient woman is anxious. The waters broke 4 hours ago. On external examination the contraction ring is located 2 finger widths above the navel, Henkel-Vasten sign is positive. Fetal heart rate is 160/min., muffled. On internal examination the uterine cervix is fully open, the head is engaged and pressed to the entrance into the lesser pelvis. What is the most likely diagnosis?
 - + A. Threatened uterine rupture
 - B. Anatomically contracted pelvis
 - C. Complete uterine rupture
 - D. Abruptio of normally positioned placenta
 - E. Hyperactive uterine contractions
2. One of the planes of the pelvis is limited behind sacral promontory, in front – crista iliac and superior edge of the pubis symphysis, on each side - lin. terminalis. What is moment of the biomechanism of birth does the fetus make in the given pelvic plane?
 - A. It does not make any of the moments.
 - B. External turn of the head and internal turn of the shoulders.
 - C. Extension of the head.
 - D. Internal turn of the head.
 - + E. Flexion of the head.

3. On the occipital area of the head of a newborn, having a dolichocephalic form, there is a patrimonial tumor with the center at the area of the small fontanel. What head presentation did the birth occur in?
- A. Frontal.
 - B. Anterior type, occipital presentation.
 - C. Facial.
 - + D. Posterior type, occipital presentation.
 - E. Front parietal.
4. During vaginal examination 6 hours after the beginning of patrimonial activity the following was revealed: the cervix is open 5 cm, the fetal head is presented and is pressed to the input of the pelvis. The sagittal suture is in the right diagonal diameter, the small fontanel is to the left, to the side. What moment of the biomechanism of birth is being described?
- +A. Flexion of the head.
 - B. Extension of the head.
 - C. Internal turn of the head.
 - D. Additional flexion of the head.
 - E. Internal turn the shoulders.
5. During vaginal examination, the fetal head is determined; it fills the posterior surface of the symphysis pubis and hollow of the sacrum, an inferior edge of the symphysis pubis, spines of the ischiatic bones, sacrococcygeal joints are accessible with palpation. In what plane of the small pelvis is the head located?
- + A. Plane of the narrow part of the pelvic cavity.
 - B. Plane of the wide part of the pelvic cavity.
 - C. On the input to the pelvis.
 - D. In the input to the pelvis.
 - E. In the exit of the pelvis.
6. Secondary has been in childbirth for 8 hours. Light amniotic fluid was discharged. The fetal position is longitudinal, the fetal head is not determined over the input to the pelvis. Fetal palpitation is clear, rhythmical, 140 b.p.m., over the pubis. Internal obstetrical examination: the cervix is smooth, fully open, the fetal sac is absent. The hollow of the sacrum is completely filled with the head. Spina ischiatic is not reached. The sagittal suture is in the direct diameter of the pelvis. The large fontanel is at the pubis. Contractions have begun. What period of birth is being described?
- A. I period.
 - B. End of the I period.
 - + C. Beginning of the II period.
 - D. End of the II period.
 - E. Beginning of the III period.

7. A woman in her first pregnancy had a live baby boy, weight 3200 g, length 50 cm. The umbilical cord was transected after pulsation of the vessels stopped. When the edge of the palm is pressed on the symphysis, the umbilical cord retreats into the vagina. What sign is used for determining whether the placenta has separated from the uterus?
- A. Alfelda.
 - + B. Kustner-Chukalova.
 - C. Schröder.
 - D. Dovjenko.
 - E. Rogovina.
8. Primipara gave birth to a live mature baby boy with an estimation by the Apgar scale of 9 points. At the present moment, the umbilical cord vessels are not pulsating, the umbilical cord was cut. Bloody discharge from the genital tract is absent. Specify the period of birth:
- A. Early postnatal period.
 - B. Opening.
 - C. Expulsion of fetus.
 - +D. Placental stage.
 - E. Late postnatal period.
9. Data from the internal obstetrical examination of a parturient woman: the cervix uterus is smooth, open 6 cm. The fetal sac is intact. The fetal head is presented, when pressed on, it does not make push back. During palpation of the pelvic, the pubis symphysis, innominate lines, promontory are free. The sagittal suture is in the transverse diameter, the small fontanel is to the right at the pubis. In what plane is the fetal head?
- +A. Pressed to the input of the pelvis.
 - B. On the input of the pelvis.
 - C. Wide part of the pelvic cavity.
 - D. Narrow part of the pelvic cavity.
 - E. Exit of the pelvis.
10. I period of I due labor. Fetal position - longitudinal, the small segment of the head is in the input to the pelvis. Fetal palpitation is clear, rhythmical, 140 b.p.m., to the left below the navel. During internal obstetrical examination, the cervix is smooth, open 6 cm, the small segment of the fetal head is in the input to the pelvis. The sagittal suture is in the right diagonal diameter, the small fontanel is to the left closer to the pubis. Specify the position and type of position.
- A. High direct standing of the sagittal suture.
 - B. I position, posterior type of position.
 - C. II position, anterior type of position.
 - D. II position, posterior type of position.

+E. I position, anterior type of position.

3. FORMATION OF PROFESSIONAL SKILLS (mastering skills, conducting curation, determining the treatment regimen, conducting a laboratory study, etc.).

3.1. Content of tasks (tasks, clinical situations, etc.).

Interactive task:

Students of the group are divided into 3 subgroups of 4-5 people each. We work in women's consultation rooms with patients, we give tasks:

And the I subgroup - to make a preliminary diagnosis.

Subgroup II - to make a plan for the management of a pregnant patient.

Subgroup III – to assess answers of subgroups I and II and makes adjustments.

Test tasks

1. Secondary was delivered to the maternity hospital 6 hours after the beginning of labor. Contractions are 30-35 seconds, every 4 minutes, good force. BP is 120/80 mm hg. Pulse is 80 b.p.m., rhythmical, of satisfactory properties. The fetal heart beat is 146 b.p.m. The fetal position is longitudinal, head presentation, I position, anterior type of position. The small segment of the fetal head is in the input to the pelvis. The height of the contraction ring is 5 cm over the pubis. When should internal obstetrical examination be performed?
 - + A. Upon arrival and after amniotic discharge.
 - B. Every 2 hours.
 - C. At the beginning of the II period of birth.
 - D. When transferred to the postnatal ward.
 - E. At the end of the I period of birth.
2. In what size of the plane of the input to the pelvis is the sagittal suture during anterior position, occipital presentation, I position after performing flexion of the head?
 - A. Direct.
 - B. Left diagonal or direct.
 - C. Right diagonal or direct.
 - +D. Right diagonal or transverse.
 - E. Left diagonal or transverse.
3. What size of the plane of the input to the pelvis is the sagittal suture in during posterior type of position, occipital presentation, I position after flexion of the head?
 - A. Direct.
 - B. Left diagonal or direct.
 - C. Right diagonal or direct.
 - D. Right diagonal or transverse.

- + E. Left diagonal or transverse.
- 4. In what plane of the pelvis does the fetus finishing making the internal turn of its head during anterior type of position, occipital presentation, II position?
 - A. Input to the pelvis.
 - B. The wide part of the pelvic cavity.
 - C. The narrow part of the pelvic cavity.
 - D. When going from the wide part of the cavity to the narrow part of the pelvic cavity.
 - +E. The exit of the pelvis.
- 5. In what diameter of the plane of the exit from the pelvis is the sagittal suture during extension of the head during posterior type of position, occipital presentation, I position?
 - + A. Direct.
 - B. Left diagonal or direct.
 - C. Right diagonal or direct.
 - D. Right diagonal or transverse.
 - E. Left diagonal or transverse.
- 6. In what diameter of the plane of the exit from the pelvis does the fetal shoulders cut through and are born during the anterior type of position, occipital presentation?
 - + A. Direct.
 - B. Right diagonal.
 - C. Left diagonal.
 - D. Transverse.
 - E. Direct and transverse.
- 7. The head of a newborn has a dolichocephalic form, extended from the front to the back. At the occipital area, there is a patrimonial tumour located in the middle between the large and small fontanel. What head presentation did the birth occur in?
 - A. Front parietal.
 - +B. Anterior type, occipital presentation.
 - C. Posterior type, occipital presentation.
 - D. Facial.
 - E. Frontal.
- 8. Primipara, 20 years old, is in the beginning of the I period of physiological birth. Contractions are 15-20 sec., every 10-15 min., weak. Fetal palpitation is not suffering. How much in cm should the cervix be open for the amniotic discharge to be timely?
 - A. 6-8.
 - +B. 8-10.

- C. 4-6.
D. 2-4.
E. 1,5-2.
9. During internal obstetrical examination of a secundipara, the cervix is open 4-5 cm, when pressing with a finger on the fetal head, it pushes away and again returns to its initial position, the pelvis is free. How long is the fetal head permitted to be in this plane, in hours?
A. 5.
+ B. 6.
C. 4.
D. 3.
E. 2.
10. You are observing a parturient woman in the 1 period of birth. During internal obstetrical examination, the sagittal suture is in the right diagonal diameter, the small fontanel is closer to the pubis. How should the parturient woman lay in bed, so that the fetal head would be insert correctly?
+ A. On her left side.
B. On her back.
C. On her right side.
D. It make do difference.
E. She is only allowed to walk.

3.2. Recommendations (instructions) for performing tasks (professional algorithms, orientation maps for the formation of practical skills, etc.)

Pregnancy and delivery in breech presentation

Breech presentation is a presentation that is characterized by pelvic pole position of fetus over pelvic inlet.

Frequency of breech presentation in term labor with one fetus is 3-3,5%.

Classification

I. Frank breech:

- incomplete or extended breech (buttocks presentation);
- Complete or flexed breech (buttocks and feet presentation).

II. Footling breech:

- incomplete (one feet presentation);
- complete (both feet presentation);
- Kneeling presentation.

Diagnostics

Abdominal examination:

- round firm balloting head in the area of uterine fundus;

- irregularly shaped soft unbolting presenting part is palpated over/in pelvic inlet;
- Fetal heartbeat is auscultated on the left or on the right above navel depending on fetal position.

Vaginal examination during labor (Table)

Table

Differential diagnostics of different kinds of presentations based on results of vaginal examination

Presentation	Vaginal examination
Frank breech	<ul style="list-style-type: none">• palpation of a big and soft presenting part• identification of ischial tubers, sacral bone, anal orifice, genitalia• possible identification of inguinal curve in incomplete breech, and feet near buttocks in complete breech• ischial tubes and anus of fetus are in the same plane
Footling breech	<ul style="list-style-type: none">• palpation of heel bone, short even fingers, thumb can't be abducted and its mobility is limited• thumb can't be pressed down to sole
Face presentation	<ul style="list-style-type: none">• identification of firm cylinders and jaws, mouth and nose of fetus• mouth and molar crests have triangular shape
Hand falling in shoulder position or oblique lie	<ul style="list-style-type: none">• thumb is easily pressed down to palm• heel bone can't be palpated

Ultrasound (US) examination is the most informative diagnostic method. It allows not only to identify breech presentation, but also presumed weight, position of a head (defluxion grade), placenta localization, volume of amniotic fluid, cord entanglement, abnormal development, etc. We summarize 4 variants of position of head by the size of an angle between cervical spine and occipital bone, which are very important for the choice of labor management method:

- head is flexed, angle over 110°;
- head is slightly deflexed -I grade of head defluxion, angle 100 - 110°;
- head is mildly deflexed - II grade - 90°-100°;
- Excessive head deflection - III grade of head defluxion, angle less than 90°.

Presumed diagnosis of breech presentation is stated at the term of 30 weeks and final diagnosis – at the term of 37-38 weeks.

The rate of spontaneous turn harshly lessens after the 31st week of pregnancy that is why it is wise to correct fetal position after this term.

Pregnancy care

Antenatal clinic

Necessary recommendations to pregnant women at the term of 30 weeks to induce spontaneous turn of fetus:

- endwise position on the side opposite to fetus;
- Knee-elbow position for 15 min 2-3 times a day.

Complex of corrective gymnastic exercises in one of the existent methodic is prescribed since the 32nd up to the 37th weeks.

Contraindications to gymnastic exercises:

- threatened premature labor;
- placental presentation;
- low insertion of placenta;
- Anatomically contracted pelvis of II - III grade.

External cephalic version **is not performed** at the antenatal clinic.

Necessity of hospitalization to maternity obstetric clinic is determined at the term of 38 weeks basing on the next indications:

- aggravated obstetric-gynecological history;
- feto-maternal disease;
- Extra genital pathology;
- Opportunity to perform external cephalic version.

Maternity obstetric service

Diagnosis specification:

- performing of ultrasound examination;
- evaluation of state of fetus (biophysical profile - BPP, Doppler sonography if necessary);
- estimation of readiness of maternal organism to delivery (Bishops scale);
- estimation of possibility of performing of external cephalic version.

Plan of labor management is formulated in council with anesthesiologist and neonatologist and then negotiated with a patient.

External cephalic version in full-term pregnancy leads to increasing of amount of physiological deliveries in cephalic presentation.

Indications:

- Incomplete breech in full-term pregnancy and alive fetus.

Conditions:

- presumed weight of fetus < 3700,0 g,
- normal sizes of small pelvis;
- empty urinary bladder;
- US after external version is available;
- satisfactory condition of fetus on BPP and absence of abnormal development;
- normal mobility of fetus, enough quantity of amniotic fluid;
- normal uterine tonus, unbroken fetal bladder;

- readiness of operating room to emergency care in the case of complications;
- Skilled qualified specialist acquainted with procedure of version.

Contraindications:

- Fetal-maternal disease when decision making of external version (bleeding, fetal distress, preeclampsia);
- aggravated obstetric-gynecological anamnesis (recurrent miscarriage, perinatal loss, infertility in anamnesis);
- polyhydramnios or oligohydramnios;
- multiple pregnancy;
- anatomically constricted pelvis;
- cicatricial deformity of vagina and cervix;
- III grade of head deflexion on US;
- placental presentation;
- severe extragenital pathology;
- uterine scar, peritoneal commissures;
- hydrocephaly and neck tumors in fetus;
- abnormal development of uterus;
- Tumors of uterus and annexes.

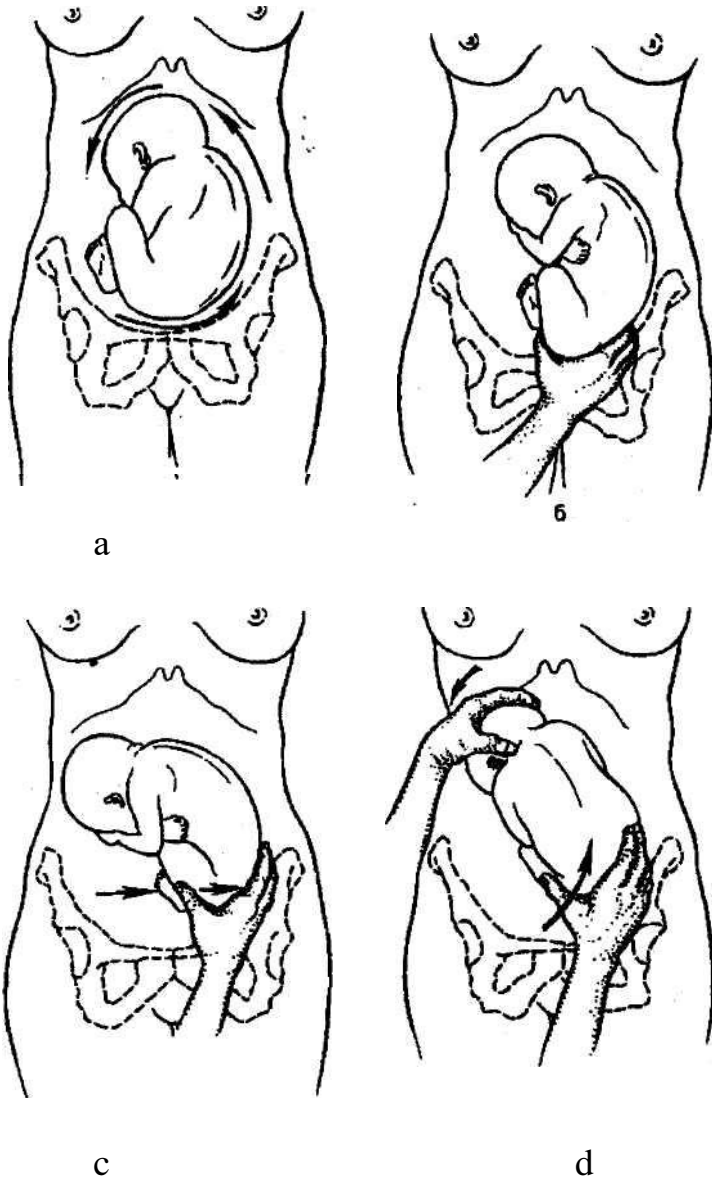
Procedure of external cephalic version:

- advise position with angle of 30-40° in direction of fetal spine;
- breech of fetus is abducted from pelvic inlet by the hands of physician that are inserted between mons pubis and breech of the fetus (a);
- breech of fetus is carefully shifted in direction of fetal position (b, c);
- head is shifted in direction opposite to fetal position (d);
- Version is finished when head is shifted to pelvic inlet and breech to uterine fundus.

If the first try was unsuccessful the second try perform is not reasonable.

Complications:

- abruption placenta;
- fetal distress;
- Rupture of uterus.



Pic. ECV procedure.

Labor management

Birth in time.

Conservative labor management:

- estimate indications, make sure that there are all necessary conditions for safe vaginal delivery and no indications to caesarean section;
- follow the course of the I period of labor by filling in the portogram (do not fill in table 2 in portogram), cardiotocography registration for 15 min every 2 hours;
- in the case of breaking of waters, immediate vaginal examination should be performed to exclude prolapse of funnies;
- II period should be managed with mobilized vein for intravenous infusion of 5 IU of oxytocin in 500,0 ml of normal saline (up to 20 drops per minute);
- Episiotomy if necessary; pudendal anesthesia;

• II period of delivery should be managed in presence of anesthesiologist, neonatologist.

A. Extended and flexed breech (Tsivians manual aid method I)

I.Labour of breech and feet:

- woman should push during the cut of breech;
- if perineum isn't able to spread enough, episiotomy is performed;
- breech appear by itself up to navel;
- both thumbs of physician are on the back surface of thighs, other fingers are on lumbosacral region of fetus;
- carefully hold breech but don't pull

Don't pull fetus for inguinal curve anticipatorily without indications (fetal distress).

Hold fetus by thighs but not by sides and abdomen because liver or kidneys can be damaged.

II.Labour of hands:

- fetus which is born up to navel is taken with the thumbs on breech and sacral region and with other fingers on front surfaces of thighs;
- body is moved down until the lower angle of shoulder blade appears;
- during down-directed traction the front hand is born from under symphysis; after substantive birth of the front hand, breech is lifted to mother's abdomen to let the rear hand appear itself; if the hands of fetus cannot appear unassisted it is accounted to be nuchal arms and classical manual maneuver of shoulder labor should be performed.

Classical manual maneuver of hands labor:

- with one hand (when I position – left hand) grab legs of fetus in the region of podetial joint and lift forward and slightly to the side opposite to the spine of fetus, closer to mother's thigh (if I position – to right thigh);
- insert the second hand in vagina following the back of fetus up to mother's sacral hollow and then follow the hummers up to the elbow and extract rear hand;
- the arm is pulled at elbow;
- the front hand is extracted after its changing to the rear position and also from the side of sacral hollow;
- grab pelvis and front surfaces of thighs of fetus with both hands (thumbs on the breech, 4 fingers of each hand on thighs; don't touch abdomen of the fetus) and turn through 180°;
- back of the fetus is under symphysis;
- The second arm is freed similar to the first from the side of sacral hollow.

III. Labor of the head:

A. In a case of uncomplicated delivery, absence of nuchal arms the head is born in a flexed position:

- physician's arm is put under the body of fetus, so the body lays on an arm and elbow of physician;

- assistant helps labor of the head by maintaining mild pressure over symphysis that prevents head defluxion;
- the body is lowered under the level of perineum for the formation of fixating point in suboccipital fossa with the lower border of symphysis;
- the body is lifted over perineum level;
- Head appears substantively in a flexing position around fixating point.

B. If the classical manual maneuver of hands labor was applied for labor of shoulders and arms, the head is born with the help of Mauriceau maneuver:

- physician's arm is put under the body of fetus, so the body lays on an arm and elbow of physician;
- put index and ring fingers on the cheek-bones of fetus and middle finger into its mouth for abduction of jaw and head flexion;
- use the second hand to hold shoulders of fetus from the back side;
- carefully flex the head to sternum with index and middle fingers until the pressure on jaw results in scalp birth;
- provide traction to your side;
- assistant pushes with palmar surface of his arm over symphysis, fixating the head in flexing position;
- Carefully apply up (forward) traction for the head birth in a flexed position.

B. Footing breech:

In a case of footing breech caesarean section is performed. Vaginal birth is provided only when:

- II period of labor – Tsivians manual aid method II is applied to provide complete cervical dilatation and breech lowering;
- Second fetus birth in the case multiple pregnancy.

Indication to caesarean section:

- presumed weight of fetus is over 3700,0 g;
- footling breech;
- head defluxion of the III grade on US;
- Neck tumors of fetus and hydrocephaly.

Biomechanism of breech labor

I moment – internal breech version. Breech is engaged in its intertrochanteric diameter in one of the oblique diameters of pelvic inlet. Breech descends and performs internal version, intertrochanteric line is set in anterior-posterior diameter of pelvic outlet.

II moment – side flexion in lumbosacral part of spinal cord. Side flexion of fetus takes place according to direction of birth canal. Front breech (which serves as a guiding point) crowns but does not bear because the fixating point is set between anterior iliac spine of fetus and pubic symphysis. Posterior breech is born first, followed afterwards by the front breech and then fetus is born up to its navel.

III moment – internal shoulder version and external corpus version. Shoulders descend into pelvic cavity and are set in anterior-posterior diameter of pelvic outlet.

IV moment – side flexion in cervicothoracic part of spinal cord, during which hands and shoulder girdle are born.

V moment – internal head version. The head descends passing birth canal and is set with sagittal suture in anterior-posterior diameter of pelvic outlet. Suboccipital fossa is fixated under the lower edge of pubic symphysis.

VI moment – head flexion and its birth.

If the state of mother and fetus is satisfactory and sizes of pelvis and fetus are normal, vaginal birth is preferred. It is necessary to divide an act of delivery into 4 stages:

1. Fetus birth up to its navel;
2. Fetus birth from navel to the lower edges of shoulder blades;
3. Shoulder birth;
4. Head birth.

Pregnancy and labor in pelvic bones anomaly

Contracted pelvis can be anatomically contracted when anatomy changes take place, and clinically contracted when functional inequality between the diameters of a head of fetus and mother's pelvis is independent to their sizes.

Etiology

There are different causes of contracted pelvis formation. Amongst them are malnutrition, physical exertions, and chronic diseases in childhood and adolescence. Significant role in skeleton anomalies formation plays rickets in childhood. Rachitic bone deformations predetermining pelvic narrowing. Bone deformations occur not only when the illness is in full bloom but also during suppressed forms when changes in other parts of the skeleton are barely visible.

Tuberculosis of bones and joints also leads to pelvic deformations. Significant deformations may be caused by pelvic bones fractures, dislocations, and vicious union in lower extremities, exostosis, pelvic bones tumors, and deformations in lumbosacral articulation.

Some role is played by mother's malnutrition during pregnancy and diseases which lead to metabolic disorders between mother and fetus.

Hormone misbalances in adolescence also contribute to pelvic bones deformation, because estrogens stimulate pelvic growth in transverse sizes and its ossification, while androgens stimulate skeleton and pelvis elongation.

Anatomically contracted pelvis is classified by form and grade of contraction.

Frequently met types of contracted pelvis:

Generally contracted pelvis:

- infantile pelvis;
- android pelvis;

Dwarf pelvis.

Flat pelvis:

- simple flat pelvis;
- flat rachitic pelvis;
- pelvis with reduced anterior-posterior diameter in the plane with greatest pelvic dimensions;
- Generally contracted flat pelvis.

Seldom met types of contracted pelvis:

1. Obliquely displaced and obliquely contracted pelvis.
2. Dolichopellic pelvis.
3. Choanoid pelvis.
4. Osteocalcin pelvis.
5. Spondylolisthesis pelvis.
6. Pelvis contracted with exostoses, fractures, pelvic bones tumors.
7. Kyphotic pelvis.

There 4 degrees of pelvic constriction:

I degree – true conjugate is 10,5-9 cm

II degree - 9-7,5 cm

III degree - 7-5,5 cm

IV degree – less than 5,5 cm.

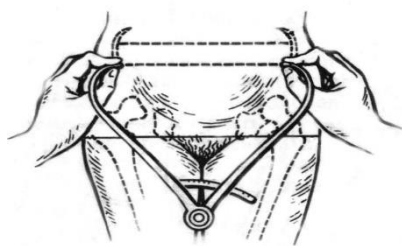
Frequency of occurrence of anatomically constricted pelvis is 2,6-12 %.

Diagnosics of constricted pelvis

Timely diagnostics of constricted pelvis may caution a rate of complications, which can arise during labor or rarely at the end of pregnancy.

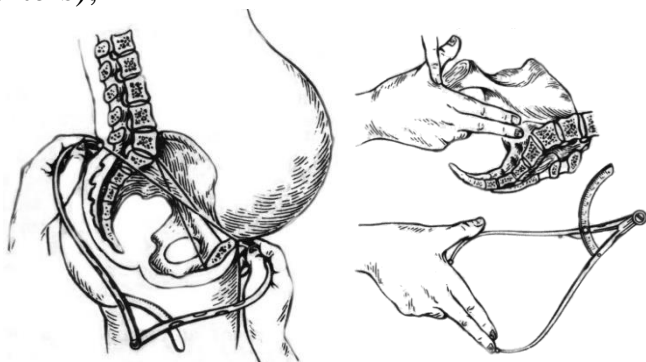
Anamnesis, external examination and vaginal examination are of the main diagnostic significance.

We get important information about rickets, bone tuberculosis, osteomyelitis, traumas, late menarche, obstetric history from anamnesis. During external examination attention is paid to height (pelvis is usually constricted when the height is 145 cm or less), spinal curvatures (kyphosis, scoliosis, lordosis), shortening of lower extremities, immobility in joints, form of lumbosacral rhomb, pendulous abdomen in multipara, peaked abdomen in primipara, signs of infantilism (immature secondary sexual characteristics), intersexuality (tall stature, hypertrichosis, virializing type pillories). General pelvimetry is performed (pic. 1, 2).



Pic. 1. Transverse diameters measurement

1. Distention spinarum = 25-26 cm (distance between anterior superior iliac spines);
2. Distention cristarum = 28-29 cm (distance between the most distant points of iliac crests);
3. Distention trochanterica = 31 cm (distance between the most distant points of trochanters);



Pic. 2. External conjugate and diagonal conjugate measurement

4. Conjugata externa = 20-21 cm
5. Conjugate diagonals is measured during vaginal examination. If promontories can't be reached then conjugate diagonals is assumed to be over 12 cm (12,5-13 cm).
6. Conjugate Vera (true conjugate) is equal to anterior-posterior diameter of pelvic inlet.

Additional external measurement:

lumbosacral rhomb, if normal it has regular shape. Vertical size is 11 cm (is equal to true conjugate), transversal size is 9 cm.

Lateral conjugate – distance between the anterior superior iliac spine and posterior superior iliac spine of the same iliac bone (normally is 14,5-15 cm), it is decreased in contracted pelvis.

Pelvic height – distance between ischial tuberosity and pubic symphysis (normally is less than 11 cm, if it is over 11 cm prolonged labor may take place).

Anterior-posterior and transverse diameters of pelvic outlet.

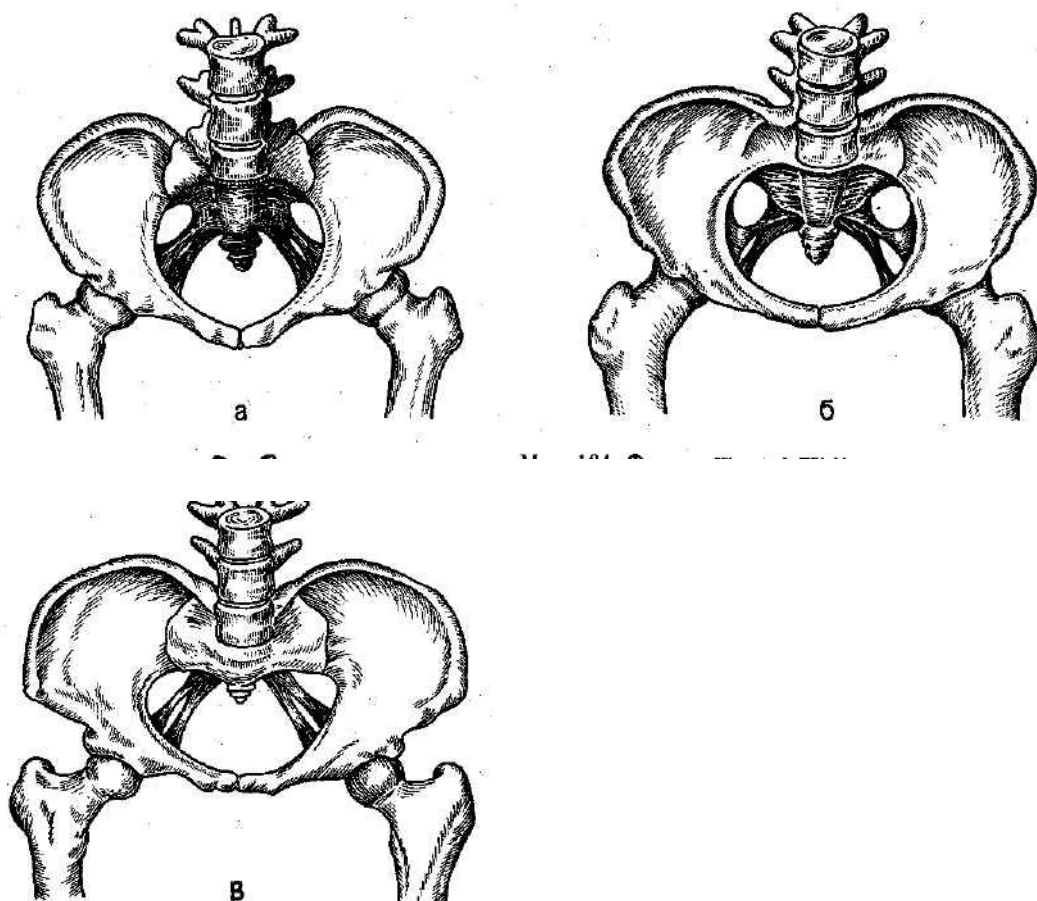
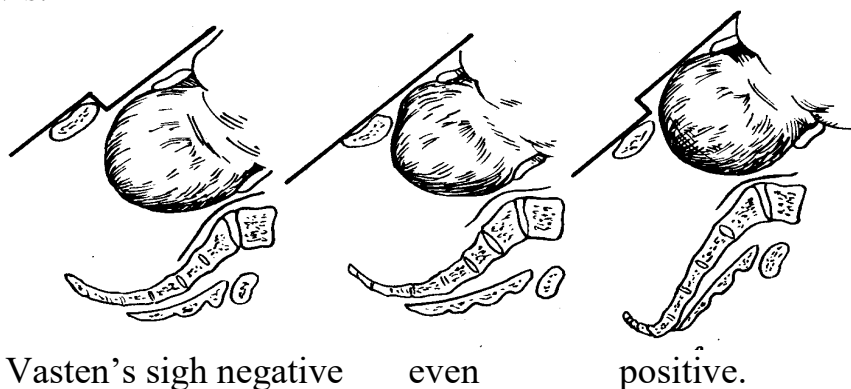
circumference of pelvis is measured with measuring tape pressed under sacrum, between iliac crests on both sides and in the middle of pubic on the front (normally is 85 cm and over)

Pubic symphysis height is measured between its upper and lower edges (normally is 5-6 cm). The higher is pubic symphysis, the lesser is true conjugate.

Oblique diameter – distance between the right anterior superior iliac spine to the left posterior superior iliac spine and opposite. Normally both these sizes are equal to 20-21 cm.

Solov'jev index is estimated by measurement of the circumference of radiocarpal joint. Normally it is 14-18 cm. If it is lower pelvic bones are thin, if it is over 18 cm pelvic bones are thick.

Zangemeister's and Vasten's symptoms are used to estimate match of fetus head to pelvis.



Types of flat pelvises: a – generally contracted flat pelvis; б – simple flat pelvis; B – flat rachitic pelvis.

Generally contracted pelvis

It is characterized by regular shape and equal reduction (in 1-2 cm) of all sizes (anterior-posterior, oblique and transverse), pubic angle is acute (less than 90°), pubic

and sacrum heights are reduced. Average sizes are D.sp. – 24 cm., D.cr. – 26 cm, D.tr. – 28 cm., C.ext. – 18 cm., C.diagonalis – 11 cm, C.vera – 9 cm.

There are different types of generally contracted pelvis:

Infantile pelvis is diagnosed in infantile underdeveloped women. Pelvis has some puerile signs: sacrum is narrow and isn't flexed enough, promontory is high, pubic arc is narrow, pelvic inlet has round or oval form.

Android pelvis is diagnosed in tall women with the signs of intersexuality. Its build is alike to male pelvis: high conoid cavity, narrow pubic arc.

Dwarf pelvis is a marginal variant of generally contracted pelvis. It is diagnosed in women of proportional build with height of 120-149 cm.

Biomechanism of labor is like to the one in breech labor but has some peculiarities.

First peculiarity (in the I moment of biomechanism) – maximal head flexion and head set with its smallest diameter (diameter suboccipitoparietalis – 9 cm) in one of the oblique diameters of pelvic inlet depending on fetus position. Such set is cuneate and unstylistic.

Second peculiarity is significant head configuration (dolichocephalic configuration) because of reduction of all sizes of pelvis.

Third peculiarity is prolonged head defluxion.

Flat pelvis

Flat pelvis is a pelvis with reduced anterior-posterior diameters and normal transversal and oblique diameters. It has different types:

1. Simple flat pelvis is characterized by reduction of all anterior-posterior diameters due to relocation of sacrum closer to pubic. There is no deformation of pelvis and skeleton, build is normal. Sizes: D.sp. - 26 cm, D.cr. - 29 cm, D.tr. - 30 cm, C.ext. - 18 cm, C.diagonalis. – 11 cm, C.vera – 9 cm.

Labor has more favorable prognosis than in cases of any other type of flat pelvis.

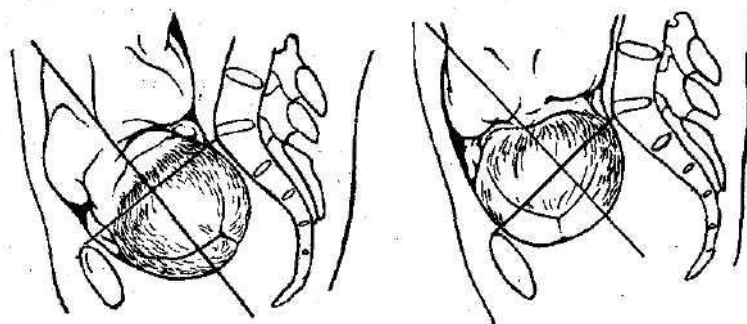
Biomechanism of labor in simple flat pelvis has some peculiarities.

First peculiarity – prolonged high stand of sagittal suture in transverse diameter of pelvic inlet.

Second peculiarity – big fontanel is lower than small fontanel and becomes a guiding point.

Third peculiarity – unstylistic set of a head (Nagele's obliquity, Litzmann's obliquity).

Forth peculiarity – head rotation cannot be performed in pelvic cavity that leads to medium or low transverse stand of a head. If the head is big, clinical discordance may occur.



a

b

Pic 6. asynclitism: a – anterior (Nagele's obliquity); b – posterior (Litzmann's obliquity).

2. Flat rachitic pelvis is characterized by deformation of the upper part of sacrum that leads to reduction of anterior-posterior diameter of pelvic inlet while other diameters are normal or slightly extended, coccyx has beaked forward inclination. Besides, iliac bones are significantly spread, that's why D.sp. and D.cr. are almost equal, ischial tuberosities spread and pubic angle becomes obtuse (over 90°). Sizes: D.sp. – 26 cm, D.cr. – 26 cm, D.tr. – 31 cm, C.ext. – 17 cm, C.diagonalis – 10 cm, C.vera – 8 cm.

Biomechanism of labor in flat rachitic pelvis has its peculiarities.

First peculiarity – prolonged stand of sagittal suture in transverse diameter.

Second peculiarity – head defluxion and big fontanel descending.

Third peculiarity – Nagele's obliquity.

Forth peculiarity – after passing the inlet head quickly descends onto pelvic outlet, simultaneously flexes, performs internal rotation and deflexed.

3. Generally contracted flat pelvis – is a pelvis with reduction of all diameters but anterior-posterior diameters are reduced most of all. Women usually are low. Significant reduction of all diameters, especially of anterior-posterior and external is characteristically. Sizes: D.sp. - 23-24 cm, D.cr. - 24-25 cm, D.tr. - 27-28 cm, C.ext. - 15-16 cm, C.diagonalis – 9 cm, C.vera – 7 cm.

Biomechanism of labor is equal to such in generally contracted pelvis or simple flat pelvis depending on which form dominates.

4. Pelvis with reduced anterior-posterior diameter in the plane with greatest pelvic dimensions is characterized by reduction of anterior-posterior diameter in the plane with greatest pelvic dimensions. This type of contracted pelvis is diagnosed with X-ray.

Dolichopelvic pelvis

It is characterized by reduction of one or more transverse diameters in 0,5 cm or more with normal or extended true conjugate.

Biomechanism of labor in dolichopelvic pelvis:

First peculiarity: high direct stand of a head.

Second peculiarity: if occiput faces front, head flexes intensely and passes all pelvic dimensions without rotation and is born alike to when occipitoanterior position of vertex, if occiput faces back, head rotation may occur in pelvic cavity and delivery may end spontaneously. If the head is big, rotation may not occur and delivery is ended with caesarean section.

Pregnancy and delivery management in contracted pelvis

Pregnant women with anatomically contracted pelvises are hospitalized at the term of 37-38 weeks of pregnancy for the selection of delivery method. Delivery course in contracted pelvis depends on the grade of discordance and complications. Caesarean section is the only option in contraction of the 3rd and 4th degrees. It also can be performed if contraction of the 1st or 2nd degree is combined with other obstetric pathology.

Clinically contracted pelvis occurs during delivery as a result of inequality in diameters of fetal head and mother's pelvis independent to their actual sizes. The main causes of that are anatomically contracted pelvis, big head of fetus, head deflexion, protracted pregnancy, myomas which prevent advance of the head, abnormal development of feminine genitalia and fetus.

Conditions of clinically contracted pelvis diagnostics:

cervical dilatation over 8 cm;

absence of fetal bladder;

empty urinary bladder;

normal uterine contractions.

Symptoms of clinical inequality during delivery:

positive or even Vasten's sign, positive Zangemeister's sign;

symptoms of urinary bladder compression;

hyperextension of uterus, high position of contraction ring;

absence of advance of the head whilst in full cervical dilatation and normal delivery activity;

insufficient attachment of cervix to presenting part;

appearance of bearing-downs whilst in high stand of fetus head;

edema of cervix which may possibly spread onto vagina and vulva.

If two or more signs are present the diagnosis of clinically contracted pelvis is stated and caesarean section is performed. In cases of dead fetus embryotomy is chosen

Problems of macrosomia in obstetrics, macrocosmic pregnancy and delivery

Term 'big fetus' is used if by the end of pregnancy weight of fetus is 4000 g and more in cephalic presentation or 3700 g and more in breech presentation. Fetus weighting over 5000 g is called giant.

Frequency of macrocosmic labor grows and varies between 5,2-14,4%.

Frequency of patrimonial traumatism, including rupture of uterus, hypoxia of fetus, postnatal complications increase in macrocosmic labor. Perinatal lethality of big fetuses is 2-3 times higher than lethality of fetuses with normal weight. Clinically contracted pelvis occurs 6 times more frequent.

Etiology

Acceleration which starts antenatally and is a result of influence of social and economical factors that lead to myodynamia.

Excessive consumption of carbohydrates during pregnancy. Hyperglycemia in mother leads to hyperinsulinemia in fetus and increasement of tissue growth.

Metabolic disorders in maternal organism, particularly diabetes mellitus.

Activity of solar radiation and duration of daylight hours. In spring and summer when there are lots of daylight children are born with greater weight and height then in autumn and winter.

Congenital and constitutional peculiarities of parents.

Increased synthesis of chorionic somatomammotropin which regulates height of a fetus.

Increased synthesis of progesterone or estrogens.

Big fetus diagnostics

Risk group for possible development of big fetus includes:

tall women (170 cm and over);

women wit sedentary lifestyles;

women with obesity;

women with diabetes mellitus or other endocrine diseases;

macrocosmic delivery in anamnesis;

fundal height in term of 20 weeks of pregnancy - 21-22 cm, 28 weeks - 30 cm and more.

Women with Rh-negative blood type.

Ultrasonography and tentative fetus weight calculation are of big diagnostic value.

Pregnancy and delivery management in big fetus

Women pregnant with big fetus have a high risk of obstetric pathology and should be specially registered in antenatal clinic. Other important issues are rational nutrition and optimal physical activity. Drug therapy is targeted on lipid balance normalization. Methionine, niacinamide, oxygen therapy is the most effective. Fentometric should be performed during ultrasonography.

Delivery management

Macrocosmic deliveries are pathological, that's why special attention should be paid to control of the state of fetus, dynamic estimation of uterine contractions, evaluation of clinical equality of diameters of mother's pelvis and head of fetus.

All women with big fetus are hospitalized 1-2 weeks preliminary to labor. In most cases delivery ends unprompted.

Neonatal period is deeply connected with complications which can occur intrapartum – birth injury (fracture of clavicle, humerus, nervous system damage, intracranial damage) and asphyxia.

3.3. Requirements for the results of work.

- to take a medical history (general and specific, such as menstrual, obstetrics) and record information in a standardized proforma (antenatal record book),
- to perform general examination, assess the health status of the mother,
- to determine signs and symptoms of malposition, malpresentation and cephalon-pelvic disproportion, assess their diagnostic value,
- choice of instruments: forceps or ventouse,
- to perform abdominal inspection and assess abdominal enlargement,
- to perform abdominal palpation and note the height of the fundus above the symphysis and girth of abdomen at the level of umbilicus, calculate estimated fetal weight,
- to identify fetal lie, presentation, position, growth pattern, volume of liquor and also any abnormality, detect whether the presenting part is engaged or not,
- to perform auscultation of fetal heart sounds,
- to assess complaints of pregnant women, explain the origins of minor ailments in pregnancy, give advice how to reduce the problem,
- to assess results of clinical general and obstetrical examinations,
- to develop a plan of prenatal care in all of these cases,
- to counsel the women about mode of delivery and expecting outcomes of delivery.

3.4. Control materials for the final stage of the class: tasks, tests, etc.

Test tasks

1. Secundipara with a weight of 80 kg. What is the acceptable amount of blood loss, ml:
 - +A. 400.
 - B. 500.
 - C. 600.
 - D. 700.
 - E. 800.
2. A 23-year-old primigravida at 39 weeks gestation has been admitted to the maternity ward with irregular contractions. The intensity of uterine contractions is not changing, the intervals between them stay long. Bimanual examination reveals that the cervix is centered, soft, up to 1,5 cm long. There is no cervical dilatation. What diagnosis should be made?
 - +A. Pregnancy I, 39 weeks, preliminary period
 - B. Pregnancy I, 39 weeks, labor I, 1 period, the latent phase

- C. Pregnancy I, 39 weeks, labor I, period 1, the active phase
D. Pregnancy I, 39 weeks, birth I, 1 period, the acceleration phase
E. Pregnancy I, 39 weeks, pathological preliminary period
3. A 24-year-old primipara was hospitalized with complaints of discharge of the amniotic waters. The uterus is tonic on palpation. The position of the fetus is longitudinal, it is pressed with the head to pelvic outlet. Palpitation of the fetus is rhythmical, 140 bpm, auscultated on the left below the navel. Internal examination: cervix of the uterus is 2,5 cm long, dense, the external opening is closed, light amniotic waters are discharged. Point out the correct component of the diagnosis:
- +A. Antenatal discharge of the amniotic waters
B. Early discharge of the amniotic waters
C. The beginning of the 1st stage of labor
D. The end of the 1st stage of labor
E. Pathological preterm labor
4. A 20-year-old parturient woman has the I labor stage. The pregnancy is full-term. Labors occur every 3 minutes and last for 55 seconds. Fetus presentation is polar, the head is pressed to the small pelvis entrance. Heart rate of the fetus is 150/min, distinct and rhythmic. Vagina examination: uterus cervix is smoothed out; mouth of the womb is 2 cm open; fetal bladder is intact; the head is presented over the I plane of small pelvis; moderate mucous-bloody discharge is observed. What phase of the I labor stage is it?
- +A. Latent
B. Active
C. Slowing-down
D. Physiological preliminary period
E. Primary uterine inertia
5. A parturient woman is 23 years old. Internal obstetric examination shows the uterine cervix to be completely open. Fetal bladder is absent. Cephalic presentation is observed in the plane of the small pelvic outlet. Sagittal suture is at the longitudinal section of the small pelvic outlet, small fontanel is situated closer to the uterus. What cephalic position will the newborn have during birth in this case?
- +A. Minor oblique lie
B. Longitudinal lie
C. Transverse lie
D. Medium oblique lie
E. Major oblique lie
6. A 20-year-old woman, gravida 2, para 1 has been in labor for 4 hours. Her condition is satisfactory. Moderately painful contractions occur every 3 minutes

and last for 35-40 seconds. The waters have not burst yet. The fetus is in longitudinal position. Fetal heartbeats are 136/min., clear and rhythmic. Major segment of the fetal head is engaged to the pelvic inlet. Vaginal examination shows smooth cervix of 6cm, amniotic sac is intact, sagittal suture is in the left oblique diameter, occipital fontanel is on the right near the symphysis pubis. What stage of the labor is it?

- +A. Active phase of the first stage of normal labor
- B. Latent phase of the first stage of normal labor
- C. The second stage of normal labor
- D. Precursors of childbirth
- E. Preliminary stage

7. It is the 3rd day after the first normal term labor; the infant is rooming in with the mother and is on breastfeeding. Objectively: the mother's general condition is satisfactory. Temperature is 36.4°C, heart rate is 80/min., BP is 120/80 mm Hg. Mammary glands are soft and painless; lactation is moderate, unrestricted milk flow. The uterus is dense, the uterine fundus is located 3 finger widths below the navel. Lochia is sanguine-serous, moderate in volume. Assess the dynamics of uterine involution:

- A. Pathologic involution
- B. Hematometra
- C. Subinvolution
- + D. Physiological involution
- E. Lochometritis

8. A newborn has Apgar score of 9. When should this infant be put to the breast?

- A. On the 2nd day
- B. After 2 hours
- + C. In the delivery room
- D. On the 3rd day
- E. After 12 hours

Questions:

1. What classification of breech presentation is used?
2. What are the diagnostic criteria of breech presentation?
3. What is the difference between delivery in cephalic and breech presentation?
4. What are the moments of labor biomechanism in breech presentation?
5. What hand assistance methods for breech presentation do you know?
6. How are contracted pelvises classified and diagnosed?
7. What are the peculiarities of biomechanism of delivery in different types of contracted pelvis?
8. What are the symptoms of contracted pelvis?

9. What are the causes of macrosomia?
10. What methods are used to diagnose macrosomia?
11. What are pregnancy and delivery peculiarities in big fetus?

4. SUMMING UP

Assessment of the ongoing learning activity at the practical class:

1. Assessment of the theoretical knowledge on the theme:
 - methods: individual survey on the theme, participation of the students in the discussion of problem situations; assessment of performance of tests on the theme;
 - the maximum score – 5, the minimum score – 3, the unsatisfactory score – 2.
2. Assessment of practical skills on the theme:
 - methods: assessment of the solution of situational tasks (including calculation) on the theme;
 - the maximum score – 5, the minimum score – 3, the unsatisfactory score – 2.

Assessment of the individual task:

1. Assessment of the quality of the performance of the individual task:
 - the maximum score – 5, the minimum score – 3, the unsatisfactory score – 2.
2. Assessment of the presentation and defense of an individual task, participation in the assessment of the business plan of the competitors and its critical analysis:
 - the maximum score – 5, the minimum score – 3, the unsatisfactory score – 2.

The score for one practical class is the arithmetic average of all components and can only have an integer value (5, 4, 3, 2), which is rounded statistically.

Criteria for ongoing assessment at the practical class:

“5”	The student is fluent in the material, takes an active part in the discussion and solution of situational clinical problems, confidently demonstrates practical skills during the examination of a pregnant and interpretation of clinical, laboratory and instrumental studies, expresses his opinion on the topic, demonstrates clinical thinking.
“4”	The student is well versed in the material, participates in the discussion and solution of situational clinical problems, demonstrates practical skills during the examination of a pregnant and interpretation of clinical, laboratory and instrumental studies with some errors, expresses his opinion on the topic, demonstrates clinical thinking.
“3”	The student isn't well versed in material, insecurely participates in the discussion and solution of a situational clinical problem, demonstrates practical skills during the examination of a pregnant and interpretation of clinical, laboratory and instrumental studies with significant errors.
“2”	The student isn't versed in material at all, does not participate in the discussion and solution of the situational clinical problem, does not

demonstrate practical skills during the examination of a pregnant and the interpretation of clinical, laboratory and instrumental studies.
--

RECOMMENDED LITERATURE

Basic:

1. Gladchuk I.Z. Obstetrics: student`s book / Gladchuk I.Z., Ancheva I.A. . – Vinnitsia: Nova Knyha, 2021. – 288 p.
2. Obstetrics and Gynecology: in 2 volumes. Volume 1. Obstetrics: textbook / V.I. Gryshchenko, M.O. Shcherbina, B.M. Ventskivskyi et al. (2nd edition). – «Medicina», 2018. – 392 p.
3. Hiralal Konar DC Dutta's Textbook of Obstetrics (9th Ed.) / Hiralal Konar (Ed.). – Jp Medical Ltd, 2018. – 700 p.
4. F. Gary Cunningham Williams Obstetrics (26th Edition) / F. Gary Cunningham, Kenneth Leveno, Jodi Dashe, Barbara Hoffman, Catherine Spong, Brian Casey. – McGraw Hill / Medical, 2022. – 1328 p.
5. Jeremy Oats, Suzanne Abraham Llewellyn-Jones Fundamentals of Obstetrics and Gynaecology (10th Ed) / Jeremy Oats, Suzanne Abraham. – Elsevier, 2016. – 384 p.

Additional:

1. The PROMPT-CIPP Editorial Team. (2019). PROMPT-CIPP Course Participant's Handbook: Care of the Critically Ill Pregnant or Postpartum Woman (Critical Car Prompt Practical Obstetric Multi-professional Training). – Cambridge University Press; 1st edition, 2019. – 136 p.
2. L. A. Magee The FIGO Textbook of Pregnancy Hypertension. An evidence-based guide to monitoring, prevention and management. / L. A. Magee, P. Dadelszen, W. Stones, M. Mathai (Eds). – The Global Library of Women's Medicine, 2016. – 456 p.
3. Edwin Chandrachan Handbook of CTG Interpretation: From Patterns to Physiology / Edwin Chandrachan. – Cambridge University Press; 1st edition, 2017. – 256 p.
4. Louise C. Kenny, Jenny E. Myers Obstetrics by Ten Teachers (20th ed) / Louise C. Kenny, Jenny E. Myers. – CRC Press, 2017. – 342 p.
5. J. Studd Current Progress in Obstetrics and Gynaecology. Vol 4. / J. Studd, Seang Lin Tan, F. Chervenak. – TreeLife Media (A Div of Kothari Medical), 2017. – 419 p.
6. J. Studd Current Progress in Obstetrics and Gynaecology. Vol 5. / J. Studd, Seang Lin Tan, F. Chervenak. – TreeLife Media (A Div of Kothari Medical), 2019. – 403 p.

7. J. Studd Current Progress in Obstetrics and Gynaecology. Vol 6. / J. Studd, Seang Lin Tan, F. Chervenak. – TreeLife Media (A Div of Kothari Medical), 2022. – 309 p.
8. Mark Landon Obstetrics: Normal and Problem Pregnancies, 8th Edition / Mark Landon, Henry Galan, Eric Jauniaux, Deborah Driscoll, Vincenzo Berghella, William Grobman, et al. – Elsevier, 2021. – 1280 pp.
9. Mark B. Landon Gabbe's Obstetrics Essentials: Normal & Problem Pregnancies, 1st Edition / Mark B. Landon, Deborah A. Driscoll, Eric R. M. Jauniaux, Henry L. Galan, William A. Grobman, Vincenzo Berghella. – Elsevier, 2019. – 496 pp.
10. Ian M. Symonds, Sabaratnam Arulkumaran Essential Obstetrics and Gynaecology, 6th Edition / Ian M. Symonds, Sabaratnam Arulkumaran. – Elsevier, 2020. – 480 pp.
11. Myra J. Wick Mayo Clinic Guide to a Healthy Pregnancy, 2nd Edition / Myra J. Wick. – Mayo Clinic Press, 2018. – 520 p.

INTERNET SOURCES:

- <https://www.cochrane.org/>
- <https://www.ebcog.org/>
- <https://www.acog.org/>
- <https://www.uptodate.com>
- <https://online.lexi.com/>
- <https://www.ncbi.nlm.nih.gov/>
- <https://pubmed.ncbi.nlm.nih.gov/>
- <https://www.thelancet.com/>
- <https://www.rcog.org.uk/>
- <https://www.npwh.org/>