


MINISTRY OF HEALTH OF UKRAINE
ODESSA NATIONAL MEDICAL UNIVERSITY

Faculty International

Department of Obstetrics and Gynecology



CONFIRMED by
Vice-rector for scientific and pedagogical work
Eduard BURYACHKIVSKYI
September 1st 2023

**METHODICAL DEVELOPMENT FOR A PRACTICAL LESSON
IN ELECTIVE DISCIPLINE**

Faculty International, 6th year

Elective discipline "**ULTRASOUND DIAGNOSTICS IN OBSTETRICS AND
GYNECOLOGY**"

Practical lesson No4. Topic: "Ultrasound diagnosis of emergency conditions in
gynecological practice. »

ONMedU, Department of Obstetrics and Gynecology. Practical Classes №4. Ultrasound diagnosis
of emergency conditions in gynecological practice.
Discipline: «VLTRAVUKOVA diagnostics into obstetrics and Gynecology»

Approved:

Meeting of the Department of Obstetrics and Gynecology
Odessa National Medical University

Protocol No1 of August 28, 2023

Head of the Department



(Ihor GLADCHUK)

Developers:

Candidate of Medical Sciences, Assistant of the Department of Obstetrics and
Gynecology



(Yulia ONYSHCHENKO)

Practical lesson No 4

Topic: "Ultrasound diagnosis of emergency patients in gynecological practice".

Objective: To improve knowledge about the structural features, the organization of ultrasound diagnostics in emergency conditions, research methods, the study of the features of sonographic manifestations in patients of varying degrees of severity, differential diagnostic signs, modern directions and diagnostic algorithms in emergency conditions, which will allow timely assistance in the event of emergencies in gynecological patients.

Basic concepts: The main parameters of ultrasonic diagnostics in the complex clinical study of gynecological patients in the event of an emergency. Ultrasound criteria for various forms of ectopic pregnancy. Dopplerometry markers in ectopic pregnancy. Ultrasonic markers of ovarian apoplexy. Ultrasound signs of a twist of the legs of an ovarian tumor. Ultrasound signs of pelvioperitonitis. In ZD, signs and dopplerometric criteria for myomatous necrosis. Differential ultrasound diagnosis for abnormal uterine bleeding. An examination plan and parameters are required during ultrasound examination of the pelvic organs.

Equipment: Professional algorithms, structural and logical schemes, tables, dummies, video-photo materials of ultrasound results, results of laboratory and instrumental studies, situational tasks, patients, medical histories.

I. Organizational measures (greetings, checking those present, communicating the topic, the purpose of the lesson, the motivation of higher education students to study the topic).

Clinical analysis of the activities of medical institutions indicates that the most difficult for the doctor are clinical situations that require emergency care. Very often, this is primarily about saving the patient's life, so incorrect or untimely actions, mistakes in the choice of tactics, methods of examination have serious consequences. Properly, correctly and timely provided, rationally planned and carried out by careful methods, emergency assistance can not only save the life of the patient, but also preserve its reproductive function.

2. Control of the reference level of knowledge (written work, written testing, online testing, frontal survey, etc.). Requirements for knowledge:

- communication and clinical examination skills of the patient;
- the ability to determine the main and etiological and pathogenetic and factor and benign neoplasms of the uterus;

- knowledge of ultrasonict classification of benign uterine tumors according to FIGO;
- determining the list of necessary clinical, laboratory and instrumental studies and assessing the interpretation of their results;
- the ability to prescribe appropriate management tactics (principles of surgical interventions, conservative treatment, rehabilitation measures) for suspicious or abnormal ultrasound results. List of didactic units: □ Fertilized egg
 - Free liquid
 - degenerative tumor changes
 - sero-hematometer

2.2. Questions (test tasks, tasks, clinical situations) to test basic knowledge on the topic of the lesson.

Question:

- Ultrasound signs and criteria for different forms of ectopic pregnancy.
- Dopplerography in ectopic pregnancy.
- Ultrasonic criteria of ovarian torsion.
- Ultrasonic markers of ovarian tumor.
- Ultrasonic picture of peritonitis.
- Ultrasonic signs of necrosis and myomatous nodes.

Situational tasks:

Problem 1.

Patient P, 21, was taken by ambulance to the gynecological department. Two hours ago I was healthy, but suddenly there was a sharp pain in the abdomen and over the clavicle, vomiting, nausea, and loss of consciousness began. The last menstruation was 12 days ago, its course was normal. Objectively: pale, flabby, pulse 113-min, blood pressure 78/40 mm. Hg. Art. The abdomen does not take part in the act of breathing. On palpation-sharp pain, especially in the lower areas. Positive signs of muscle tone. The symptom of Shchetkin-Blumberg is positive. Vaginally: the posterior vault is flattened, the uterus of normal conductive ranks, mobile, painful, due to pain, it is difficult to palpate, applications due to sharp tension of the abdominal wall could not be palpated.

Task:

- What diagnostic methods should be carried out first?
- What is the most likely diagnosis?

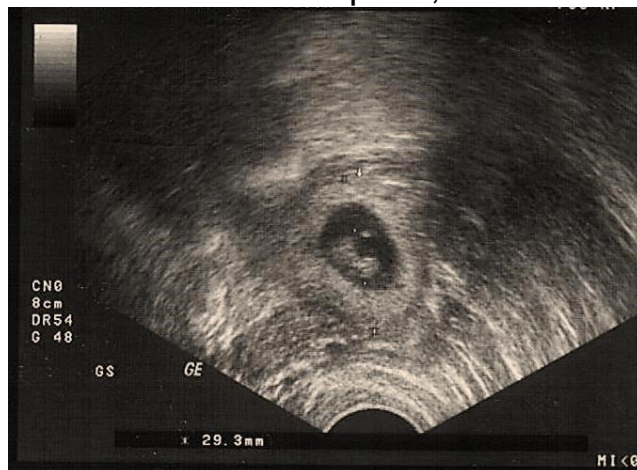Answer:

- Ultrasound examination of the pelvic organs. Laboratory for examination of the patient – blood type and Rh, complete blood count, coagulogram, biochemical blood test Apoplexy of the ovary.
- Intra-abdominal bleeding. Anemia. Hemorrhagic shock ii. Urgent surgical treatment is necessary, at the same time blood transfusion, treatment of shock, anemia are carried out.

Problem 2.

Patient D, 34 years old. Brought to the gynecological department by ambulance, "ambulance". The disease began with acute pain in the lower abdomen, dizziness, against the background of delayed menstruation for 13 days. There was nausea, vomiting, short-term loss of consciousness. The patient is pale, apathetic. Pkls 120 min., breathing 26 min., BP 80/56 mm Hg, body temperature 36.8C. Tension and tenderness in hypogastrium. The symptom of Shchetkin-Blumberg is positive.

When viewed in mirrors: the vaginal mucosa is white and pink, the cervix is somewhat cyanotic, the discharge is dark bloody. The posterior vault of the vagina is smoothed, sharply painful. The uterus in anteflexio, slightly enlarged, shifted to the left, mobility is limited. On the right and back of the uterus is a tightly elastic formation of 8x6 cm, a soft consistency, on the left without features. With a result of laboratory examinations - ESR 15mm / h, leukocytes 12 g / l, erythrocytes 2.5 T / l. Ultrasound OMT - uterus: state of anteflexio, middle position; the shape is correct. Endometrium: vaguely differentiated from myometrium, thickness 16.7 mm, secretory type. On the left in the projection of the fallopian tube is an an-gpoechoic formation with increased blood flow to the KDK. In the back of the uterine space, the free fluid is 130 ml.



Task:

- What is the most likely diagnosis?
- What diagnostic methods should be carried out first?

Answer:

Interrupted tubal pregnancy. Hemorrhoidal shock of the second stage. Urgent laparoscopy is needed, at the same time anti-shock measures.

Test tasks:

- Methods for diagnosing ectopic pregnancy, except for:
 - Progesterone test
 - Uterine probing
 - Pregnancy test
 - ULTRASOUND
 - Bimanual examination
 - Spotting from the genital tract is one of the pathognomonic symptoms:
 - Ectopic Pregnancy
 - Apoplexy of the ovary
 - Abortion that has begun
 - Twisted cyst legs
 - Fibromatous node born
 - Acute Inflammation of Uterine Applications
3. During an ultrasound of the pelvic organs, a 16-year-old girl was found on the right and behind in and behind the uterus of a rounded neoplasm, limitedly mobile, with unequal wall thickness in different places from 2 to 8 mm and the presence of fine contents. The echo density of the wall is low or medium. Probable diagnosis.
- Dermoid cyst
 - Follicular cyst
 - Endometrioid cyst
 - True ovarian tumor

Correct answers: 1 – B, 2 – C, 3 – C.

1. Formation of professional skills and abilities (mastering skills, conducting curation, determining the treatment regimen, conducting laboratory research, etc.).

— **The content of the tasks (tasks, clinical situations, etc.).**

Interactive task:

Students of the group are divided into 3 subgroups in the amount of 4-5 people each. We work in ultrasound diagnostic rooms with pregnant patients, we give tasks:

And the subgroup – assessment of the patient, history taking

Ii subgroup – advising the patient according to ultrasound screenings

Subgroup III – evaluates the correctness of the answer of the I and II subgroups and makes its own adjustments.

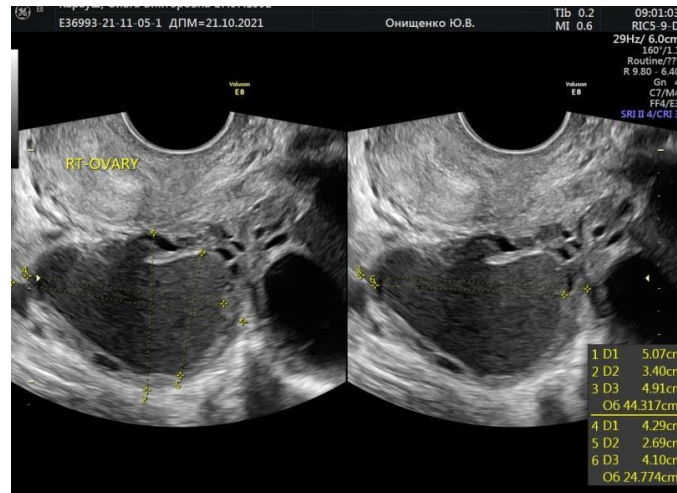Clinical tasks:

Problem 1.

The patient of 32 years entered the clinic with complaints of abdominal discongestion in volume, a feeling of heaviness in the lower abdomen, periodic pain, more on the left. The abdomen increased for the last 2-3 months. The last medical examination is 6 months. back – a tumor of the left ovary 5 cm in diameter. A further examination was proposed, which the patient refused. Menstrual function is not impaired, 1 normal birth. During clinical, laboratory, gynecological, ultrasound examination, a tumor of the left testicle with dimensions of 30 x 45 cm was detected, movement ma, tightly elastic and consistency, moderately painful, according to ultrasound - uneven intensity and solid formation of the type "motleyo pattern". **Task:** Formulate a preliminary diagnosis and determine further treatment tactics **Answer:** Ovarian dysgerminoma. Operative treatment

Problem 2.

A patient of 26 years old turned to the doctor of the LCD about bloody otters of a dark shade, appearing before menstruation in 3 days, pain on the left. Bimanual examination: the uterus is not enlarged, correctly shaped, dense, the applications on the left are enlarged due to cystic formation, sensitive. On ultrasound OMT n ravy ovary at the right rib of the uterus, increased to 50.7x34x49.1mm, volume 44.32 ml due to hyperechoic fine echostructure of formation, size 42.9x26.9x41 mm, volume 24.77 ml with KDK avascular . On the periphery, ovarian tissue containing follicles up to 4-5, 2.0 in size, is visualized; 2,2; 3.1 mm .



Challenge: Establish a diagnosis and determine further treatment tactics

Answer: Cyst of the provous ovary according to the type of endometrioid. Taking into account the size of the cyst, doycylne operative landforging – laparoscopy.

Test tasks:

- In a girl of 1-9 years old, a sonographic examination on the 16th day of the menstrual cycle in the right ovary revealed a hypoechoic formation with a diameter of 55 mm with thin walls. During recto-abdominal examination, in addition to an enlarged right ovary, no pathological changes are noted. Specify the tactics of this patient."
 - Determination of tumor marker CA 125 in the blood
 - Repeated ultrasound and gynecological examination on the 6-9th day of the next menstrual cycle
 - Course of anti-inflammatory therapy D. Immediate surgical treatment
- E.
 - In a patient of 14 years, a tumor-like creature of densely elastic consistency was found to the right and top of the uterus, tuberous with clear contours, painless, mobile, up to 10 cm in diameter.
 - Cyst of the right ovary
 - Fibromatous node of the uterus
 - Cystoma of the right ovary
 - Endometrioma of the ovary
 - Ovarian fibroma

Correct answers: 1 – B, 2 – C.

— **Recommendations (instructions) for the implementation of tasks (professional algorithms, orientation maps for the formation of practical skills and abilities, etc.).**

A person's emergency condition is a sudden deterioration in physical or mental health that poses a direct and imminent threat to the life and health of a person or people around him or her and arises as a result of illness, injury, poisoning or other internal or external causes

Causes of emergency conditions in gynecology

1. Bleeding:

External (AMK, cervical cancer, vaginal cancer).

Internal (ovarian apoplexy, ectopic pregnancy, from the ovaries during oocyte puncture according to the IVF program).

- Circulatory disorders in the internal genital organs:

Torsion of the "legs" of a tumor or tumor-like formation.

Necrosis/myomatous ischemia.

- Acute inflammatory diseases of the internal genital organs:

Piosalpinx.

Pioovar.

Tuboovarial abscess.

Diffuse peritonitis.

Pelvioperitonitis.

Ectopic (ectopic) pregnancy is considered to be pregnancy when the fertile egg is implanted and develops outside the uterine cavity. The clinical course, as well as the diagnosis and treatment of ectopic pregnancy, depend on the localization of the ovum outside the uterus. Modern classification identifies frequent and rare forms of ectopic pregnancy. The most common tubal localization (up to 98.5% of cases). Tubal pregnancy is divided into: pregnancy in the ampoule region of the fallopian tube (43% cases), in the isthmic department (53.8%), in the interstitial department (2.8%). Transitional forms of tubal pregnancy are possible: tubal-abdominal, tubalovarian, fimbrial (0.4%).

Rare forms of ectopic pregnancy include:

- Ovarian (0.1-0.2 % of cases), which is divided into intrafollicular and ovarian forms. Intrafollicular – ectopic pregnancy, when, after the follicle ruptures, the sperm enters its cavity and raises a mature egg there. Ovarian – when the fertile egg is fertilized and grafted on the surface of the ovary. Perhaps ovarian pregnancy occurs more often than is recognized, since during the operation this pathology is regarded as bleeding from a torn corpus luteum.

- Pregnancy in the embryonic corner of the uterus (0.9%). From an anatomical point of view, this localization should be attributed to uterine pregnancy, but according to clinical signs, this pregnancy proceeds as a tubal one and ends, as a rule, with rupture of the fetus and severe bleeding.
- Abdominal pregnancy (0.4%). There are primary and secondary abdominal pregnancy. Under the primary abdominal pregnancy understand the implantation of a fertilized egg on the shoe, omentum and other organs. Secondary ectopic pregnancy is formed as a consequence of tubal pregnancy, when a whole fertile egg leaves the tube and is secondarily grafted in the abdominal cavity, sometimes in such cases abdominal pregnancy can develop by later dates. The most common localization of abdominal pregnancy is rectum-uterine depression.
- Interconnective ectopic pregnancy (0.1%). Sometimes the fertile egg, implanted in the tube, begins to develop towards the parametric space, sinks between the leaves of the wide ligament of the uterus.

Turning to the diagnosis of ectopic pregnancy, I must say that it is not always easy, because the clinical course of ectopic pregnancy is very diverse and depends on the duration of pregnancy, the place of implantation of the egg, as well as on whether it is disturbed or is still progressing.

Cases of undisturbed ectopic pregnancy are diagnosed very rarely, because at the beginning of a progressive ectopic pregnancy does not give any subjective symptoms, except those that are characteristic of a normal pregnancy.

Signs of progressive tubal pregnancy can be manifested in a change in the shape and size of the tube, depending on the fact that the fertilized egg develops in it, in the appearance of pain in the pelvic area. However, we must bear in mind that in the early stages of tubal pregnancy it is not always possible to feel the tube, because only at the end of the second month its value reaches the size of a chicken egg. In addition, The clarity of the study is influenced by the state of the abdominal wall, the thickness of the fat layer, intestinal filling and other random causes. The consistency of this formation is usually soft-elastic due to the presence of fluid in the fruit egg, which is why it is often not possible to contour it. Even if it is possible to determine the above-mentioned changes in the tube, there can still be no certainty that they depend on the fact that a fertilized egg develops in it, and is not the result of inflammatory changes in the appendages or the presence of any tumor. That is why in such cases it is extremely important to carefully collect anamnesis in order to exclude certain diseases.

As for special laboratory tests, such as determining the erythrocyte sedimentation rate, determining leukocytosis, glycosuria, the Ashheim-Tsondek reaction, although they can serve as a differential diagnosis between diseases of the

appendages and pregnancy, they do not provide any strongholds for deciding where this pregnancy develops – in the tube or in the uterus. However, the Ashheim-Tsondex reaction in ectopic pregnancy can be a valuable addition to some clinical examination data.

Diagnosis is also complicated by the fact that in cases of ectopic pregnancy, the uterus increases by the third month in accordance with the gestational age due to the thickening of the muscular wall and the development of a decidual membrane in the uterine cavity and only from the third month the uterus begins to lag behind in growth, while the fertilized egg, which develops in the tube, reaches the size of a goose egg at the end of the twelfth week.

Given the complications that occur when establishing the diagnosis of progressive ectopic pregnancy, it is necessary to make it a rule that in cases suspicious of tubal pregnancy, the patient is best sent for supervision to a hospital, where an ultrasound can be performed and immediate assistance should be provided if this diagnosis is confirmed.

Much more often it is necessary to observe cases of impaired ectopic pregnancy. Already for purely mechanical reasons (insignificant thickness of the pipe wall), tubal pregnancy usually does not develop longer than a few weeks and, therefore, ends quickly. This can happen in two ways: either the wall of the pregnant tube is eaten away by villi (the so-called rupture of the tube), and bleeding into the free abdominal cavity occurs; or the fruit container opens into the lumen of the tube and the egg is pushed through the funnel of the tube partially or completely into the abdominal cavity – a tubal miscarriage. In this case, bleeding also occurs – blood through the tube funnel enters the douglas space, and with severe bleeding into the abdominal cavity.

The main clinical manifestations of tubal abortion.

The clinical picture when the tube ruptures is characteristic and expressive: acute abdominal pain, general weakness, loss of consciousness, paper pallor of the skin, pallor or cyanosis of the mucous lips and nails, cold sweat appears on the skin, frequent pulse up to 100 beats / min. and more, blood pressure drops to 100 mm. Rt. Century. and more. The abdomen is painful on palpation, more from the side where the tube ruptured. Blumberg's symptom is positive, a frenicus symptom appears. Percussion reveals dullness in the suprapubic region and along the flanks of the abdomen. Body temperature is normal. BP decreases, and with the progression of bleeding, a picture of severe hemorrhagic collapse develops. In a vaginal examination, the uterus is somewhat enlarged, soft as during pregnancy, easily mobile, as if floating (Solovyov's symptom). In the area of uterine applications, pastosity is determined or a tumor formation of a doughy consistency

is palpated. The posterior vault is flattened or protruding, the patient feels a sharp pain when the cervix is shifted to the front (a symptom of the Bank). Sharply painful is the posterior vault of the vagina with irradiation into the rectum (cry of the Douglas space); Often there may be no bleeding.

Tube abortion.

Most often there is cramping pain in the lower abdomen, bloody vaginal discharge, short-term moments of loss of consciousness, dizziness. A vaginal examination palpates a slightly enlarged, soft-lasting uterus and a tumor-like utviri in the application area, painful on palpation and sedentary. Sometimes there is a flattening or protrusion of the posterior or lateral vault of the vagina. Spotting is impure, brown in color, sometimes dark, with a tar-like tinge.

Functional and biochemical diagnostic criteria:

- Blood test: decreased hemoglobin level, red blood cell count, moderate leukocytosis.
 - Puncture of the abdominal cavity through the posterior vault of the vagina: blood does not coagulate; with microscopy - red blood cells are located in the form of scattered peas, and not in the form of "coin columns".
3. Ultrasound - the uterus has normal or slightly increased size. Echostructures caused by endometrial hyperplasia are determined in the cavity. In the field of applications - an oval-shaped creature (fertile egg) is filled with liquid contents.
 4. Laparoscopy - purple-cyanotic, oval-shaped fallopian tube.
 5. Conducting a pregnancy test.
 6. Histological examination of the removed contents of the uterus. In response to the result of histological examination - decidual tissue.

Algorithm of actions of the doctor: urgently conduct a differential diagnosis.

It is relatively easy to recognize a rupture of the tube, since it is usually accompanied by symptoms of severe blood loss and hemorrhage in the abdominal cavity. Common symptoms are the phenomena of shock and internal bleeding, namely, sudden dizziness, fainting, pallor of the skin and mucous membranes, cooling of the limbs and tip of the nose, the phenomenon of asphyxia, a drop in pulse and blood pressure. The temperature is usually normal or even below normal. Local phenomena are reduced to tension and sensitivity of the abdominal walls due to irritation of the peritoneum with spilled blood, and this in turn causes a positive symptom of Shchetkin-Blumberg (pain with the rapid removal of the palpable hand from the abdominal wall). Percussion shows dullness in the gentle parts of the abdomen. Internal research does not give a clear idea of the state of the uterus and appendages, since they are surrounded by spilled blood.

Bleeding from the external genital organs may not be, but if it is, it has the character of spotting due to detachment of the decidual membrane from the uterus. From the point of view of differential diagnosis, it is necessary to exclude the possibility of internal bleeding from other organs, as well as breakthrough peritonitis on the basis of gastric and intestinal ulcers, appendicitis, piosalpinx, which broke into the abdominal cavity. In such cases, it is possible to approach the correct diagnosis on the basis of a carefully collected history, the state of temperature, pulse, blood test, erythrocyte coagulation rate and local phenomena. Taking all this into account, they approach the question of whether signs of internal bleeding or signs of peritonitis come to the fore. However, in both cases, surgical care is vital and the patient must be immediately sent to the hospital. It is more difficult to diagnose tubal miscarriage. In cases where there is a delay in menstruation, bloody discharge from the uterus, cramping pains in the lower abdomen, an increase and softening of the uterus, cyanosis of the vaginal mucosa and a tumor in the area of the uterine appendages of an oblong shape and variable consistency, mobile and almost painless when feeling – the diagnosis of tubal miscarriage is almost beyond doubt. If, moreover, a piece of tissue is thrown out of the uterus, which is shaped like a cast of the uterus (decidua graviditatis), then this further confirms the diagnosis. Therefore, in the study it is always necessary to carefully examine the clots taken out of the vagina, among which may be, if not the entire decidual membrane, then its individual pieces, in doubtful cases they should be sent to the laboratory for research.

When examining the patient, you should pay attention to the color of the skin and sclera, because the icteric color indicates internal bleeding. If there are no some of these signs, as well as in cases where these signs are not clearly expressed, the diagnosis may fluctuate between ectopic pregnancy and threatened abortion in the presence of an inflammatory increase in appendages. Such patients, who usually do not have significant internal bleeding, often need long-term inpatient supervision.

The diagnosis is especially complicated in those cases of ectopic pregnancy, when the patient made attempts to terminate the pregnancy by one means or another or curettage was carried out during an unrecognized ectopic pregnancy.

Додаток 1
до Стандартів медичної допомоги
«Ектопічна вагітність»

Ультразвукові критерії ектопічної вагітності*

Локалізація	Критерії
Трубна ЕВ	<ul style="list-style-type: none">- Відсутність плідного яйця у порожнині матки.- Візуалізація утворення чи плідного яйця в ділянці придатків матки, яке при УЗД рухається окремо від яєчника.- Залежно від локалізації трубна ЕВ поділяється на інтерстиціальну, істмічну і ампулярну. Вагітність поблизу матки, але не оточену міометрієм, описують як істмічну, тоді як вагітність, розташовану у фаллопієвій трубі подалі від порожнини матки та близько до яєчника, позначають як ампулярну трубну ЕВ.- При трубній ЕВ слід визначати розміри гематосальпінксу, за його наявності.
Інтерстиціальна ЕВ**	<ul style="list-style-type: none">- Відсутність плідного яйця у порожнині матки.- Продукти зачаття/плідне яйце розташовані латерально в інтерстиціальній (інтрамуральній) частині маткової труби й оточені менш ніж 5 мм міометрія в усіх площинах візуалізації.- Наявність ознаки «інтерстиціальної лінії», яка являє собою тонку ехогенну лінію інтерстиціального сегмента фаллопієвої труби, що прилягає до медіальної сторони гестаційного мішка та латеральної сторони порожнини матки.
Шийкова ЕВ**	<ul style="list-style-type: none">- Відсутність плідного яйця у порожнині матки.- Шийка матки діжкоподібної форми.- Розташування плідного яйця нижче рівня внутрішнього вічка шийки матки.- Відсутність симптому «ковзання».- Наявність кровотоку навколо плідного яйця, визначеного за допомогою кольорової доплерографії.

Локалізація	Критерії
Вагітність у рубці на матці після кесаревого розтину**	<ul style="list-style-type: none"> - Відсутність плідного яйця у порожнині матки. - Плідне яйце чи солідне трофобластичне утворення, які розташовані на передній стінці матки, на рівні внутрішнього вічка у рубці на матці після попереднього кесаревого розтину у нижньому сегменті матки. - Тонкий шар міометрія чи його відсутність між плідним яйцем і сечовим міхуром. - Допплерографічні ознаки трофобластичного / плацентарного кровообігу. - Порожній цервікальний канал.
Інтрамуральна вагітність**	<ul style="list-style-type: none"> - Розташована вище рівня внутрішнього вічка, що відрізняє її від шийкової вагітності і вагітності у рубці на матці після кесаревого розтину. - Локалізується у рубці після попередньої міомектомії, перфорації матки або корпорального кесаревого розтину, іноді – в осередку аденоміозу. - Визначальною ознакою є розширення за межі ендометріально-міометріального з'єднання вище рівня внутрішнього вічка.
Вагітність у додатковому розі матки	<ul style="list-style-type: none"> - Візуалізується одна інтерстиціальна частина маткової труби в основному тілі однорогої матки. - Продукти зачаття/плідне яйце виглядають рухливими, знаходяться окремо від порожнини однорогої матки і повністю оточені міометрієм. - Наявна судинна ніжка, що прилягає до плідного яйця.
Яєчникової ЕВ	<ul style="list-style-type: none"> - Немає специфічних узгоджених критеріїв. - Яєчникова вагітність розташовується повністю або частково в паренхімі яєчника. - Ключовою діагностичною ознакою, але не специфічною, є неможливість відокремити вагітність від яєчника при обережному тиску ультразвуковим датчиком під час обстеження. - Виявлення складного ехогенного утворення у ділянці придатків матки з наявністю вільної рідини у Дугласовому просторі може свідчити про розрив яєчникової ЕВ. - У більшості випадків яєчникова вагітність є іпсилатеральною до жовтого тіла.

Локалізація	Критерії
Абдомінальна ЕВ	<ul style="list-style-type: none"> - Найбільш поширеними місцями для імплантації є широка зв'язка матки, Дугласів простір, міхурово-маткова складка, зовнішня поверхня фаллопієвих труб і тіла матки. - Відсутність плідного яйця в порожнині матки. - Відсутність при УЗД дилатації маткових труб і складних утворень у ділянці придатків матки. - Плідне яйце оточене петлями кишечника й відокремлене від них очеревиною. - Широкий діапазон мобільності, подібної до коливань, що особливо очевидно при обережному натисканні трансвагінальним датчиком у напрямку Дугласового простору. - Допплерівське дослідження допомагає підтвердити наявність перитрофобластичного кровотоку.
Гетеротопічна вагітність	Ультразвукові дані свідчать про наявність маткової і співіснуючої ЕВ.

Примітки:

* Гемоперитонеум слід класифікувати напівкількісно як легкий, коли в Дугласовому просторі наявна лише ехогенна рідина, помірний, коли є видимі згустки крові, і тяжкий, коли згустки крові та ехогенна рідина наявні як у Дугласовому просторі, так і в міхурово-матковій складці.

** Інтерстиціальну, шийкову вагітність, вагітність у рубці на матці після кесаревого розтину та інтрамуральну ЕВ слід описувати як повну або часткову. ЕВ, яка повністю обмежена міометрієм без видимого зв'язку з порожниною матки, слід описувати як повну. ЕВ, яка певною мірою залучає міометрій, але частково знаходиться в порожнині матки, слід позначати як часткову.

Twist the legs of the tumor

One of the relatively frequent and formidable complications of moving puffyn is the torsion of their legs. Subserous fibromatous nodes sitting on the leg are twisted very rarely. Much more often this happens with accessory tumors, in particular with ovarian cysts that have a long leg.

Tumors with a long leg twist more often than tumors with a short and wide leg. Intestinal peristalsis, uneven tumor growth, changes in intra-abdominal pressure, injuries and pregnancy can contribute to the twisting of the legs. Twisting can occur either suddenly, and all phenomena in such cases develop extremely rapidly, or it occurs gradually, obviously due to the fact that in these cases there is neither a sharp violation of blood circulation nor a violation of the nutrition of the tumor. Signs of acute twisting of the legs are quite characteristic. Suddenly, sharp growing pains appear, which are often accompanied by nausea and vomiting. The

stomach becomes tense, flatulence (bloating) appears, due to delayed emptying and accumulation of gases. Pulse becomes frequent and small. All of the above is the result of peritoneal irritation, and the whole picture resembles shock, similar to how it is observed for example, with a pinched hernia, renal colic, etc. Acute torsion of the leg is always accompanied by an increase in the tumor due to venous stagnation, which is formed when the veins passing in the leg of the tumor are compressed. In this case, hemorrhages often occur in the thickness of the tumor, due to the rupture of small capillaries. Sometimes such hemorrhages are so large that they are accompanied by signs of internal bleeding: fainting, general pallor, loss of pulse, cooling of the limbs, etc.

If the twisting continues, then not only the veins are squeezed, but also the arteries that bring blood and, due to the cessation of arterial blood supply, the tumor dies, may undergo suppuration, purulent disintegration (due to the ingress of microbes from the intestines) and lead to fatal peritonitis, if prompt assistance is not provided in a timely manner.

The diagnosis of tumor distortion is made on the basis of the above symptoms. In an internal study, it is usually possible to feel a tumor that comes out of the pelvis, although in acute distortion, these studies can be very unexpressed due to sharp abdominal pain.

In acute cases, until suppuration and necrosis of the tumor has occurred, the temperature in patients is usually normal or subfebrile. Anamnestic data are of great importance, especially if the patient knew earlier about the presence of a tumor. Sometimes patients indicate that the tumor, which they themselves previously probed, suddenly immediately grew due to the development of the symptoms mentioned above.

Treatment of a twisted cyst can only be surgical and the result of the operation will be the better, the sooner it is done.

Ovarian apoplexy

Ovarian apoplexy is a pathological hemorrhage in the ovarian tissue and bleeding from it into the abdominal cavity. Ovarian apoplexy is 0.3% among all patients with gynecological diseases.

Rupture or apoplexy of the ovary is, according to V.A. Solyani, at (1984) 0.8-3.1% of all women who are sent to the hospital with a diagnosis of acute appendicitis. According to A.P. Dotsenko, V.N. Skin (1983), errors in operations for appendicitis due to undiagnosed ovarian apoplexy range from 3 to 34%.

Ovarian apoplexy can be found in girls, girls and women. It occurs on any day of the menstrual cycle, but more often in the middle of the cycle and before

menstruation, sometimes for no reason. In some cases, factors contributing to the disease are detected: violent sexual intercourse, abdominal injury, improper location of the uterus, mental shock, chronic appendicitis.

Apoplexy of the right ovary is more common than the left, which is explained by a stronger blood supply to the right ovary.

A.A. Verbunko, depending on the clinic, divides patients into three groups: - group I includes patients with a mild form of apoplexy. They complain of an attack of sudden pain in the lower abdomen, which lasts from 30 minutes to 3-4 hours. The nature of the pain can be different: constant, paroxysmal, prickly, nausea, pain on palpation under the bosom and groin, peritoneal phenomena and shock are absent;

- Group II – patients with moderate apoplexy. These patients have severe pain in the lower abdomen, general weakness, pallor of the skin, nausea, vomiting, there may be dizziness, shock of the first degree, peritoneal phenomena are often pronounced;

- group III includes patients with severe apoplexy. Patients have constant severe pain in the lower abdomen, which give to the anus, sacrum, armpit, leg. There is nausea, vomiting, bloating, shock of the II-III degree, collapse. The skin is pale, covered with cold sweat, the limbs are cold, the temperature is lowered, the pulse is frequent, weak filling, severe peritoneal phenomena, frenicus symptom, anemia, dullness of the percussion sound in the lower and lateral regions, there may be intestinal paresis and urinary retention.

Vaginal examination helps to establish the gynecological nature of the disease: the uterus is more often of normal size, dense. Applications can be cystically enlarged, painful, the posterior vault hangs. Displacement of the uterus to the side causes severe pain

Requirements for the results of work, including design.

- Consult the patient and determine the general anamnestic parameters necessary for the ultrasound.
- Explain the need for ultrasound examination of the pelvic organs.
- Analyze the results of ultrasound examination based on the results of scans.
- Determine the further tactics of patient management and the need to prescribe further examination.

— Control materials for the final stage of the lesson: tasks, tasks, tests, etc.

Situational tasks:

Patient A, 33 years old. Brought to the hospital due to sharp pains in the lower abdomen, chills, high fever (39C). I fell ill suddenly, when against the background of the last

days of menstruation there were pains in the lower abdomen, more on the right. The pain increased, chills appeared, the body temperature rose to 39°C. She is pale, tongue dry. Pulse 110/min., rhythmic, blood pressure 120/80 mm. Hg. Art. Painfulness in the lower abdomen. The symptom of Shchetkin in the lower parts is positive. Vaginal examination (conducted under anesthesia), the uterus in the correct position, slightly deflected to the left, mobility is limited, not increased. On the right and behind the uterus, a painful formation, which is of irregular shape, is palpated, measuring 7.5x10 cm. Left adnexa without features. The posterior vault is not removed. Blood test - leukocytosis 9.8 G/l.

Task: Your likely diagnosis, treatment tactics.

Answer: Acute salpingitis. Prescribe bed rest, diet, cold on the lower abdomen, antibiotic therapy, vitamins, infusion therapy. With the progression of the disease, the threat of perforation of purulent formation and the appearance of the first signs of peritonitis, surgery is necessary. Otherwise, surgical treatment in remission.

Test tasks KROK-2 (2021)

The patient is worried about acute abdominal pain, fever up to 38.0 °C. Knows about the presence of uterine fibroids for 3 years. Symptoms of peritoneal irritation are positive in the lower abdomen. Leukocytes 10.2 T/l, ESR 28 mm/h. In a bimanual study, the body of the uterus is enlarged to 8-9 weeks of pregnancy, on the front surface - a sharply painful myomatous node measuring 4x4 cm, the appendages of the uterus are not changed. Ultrasound confirms the presence of subserous myomatous node type 7 according to FIGO, with the existing signs of degenerative-dystrophy and calcifications, etc. What is the most likely diagnosis? A. Internal endometriosis.

- Tuboovarian tumor.
- Necrosis of the myomatous node. *
- Acute adnexitis.
- Perimetritis.

4. Summing up (criteria for evaluating learning outcomes).

Current control: oral questioning, testing, evaluation of practical skills, solving situational clinical problems, evaluation of activity in the classroom, etc. ***The structure of the current assessment in the practical lesson:***

- Evaluation of theoretical knowledge on the topic of the lesson;
- methods: survey, solving a situational clinical problem;
- The maximum score is 5, the minimum score is 3, the unsatisfactory score is 2.

- Assessment of practical skills and manipulations on the topic of the lesson:
- methods: assessment of the correctness of practical skills;
- The maximum score is 5, the minimum score is 3, the unsatisfactory score is 2.
- Evaluation of work with the patient on the topic of the lesson:
- methods: assessment of: a) communication skills of communication with the patient, b) the correctness of the appointment and evaluation of laboratory and instrumental studies, c) compliance with the algorithm for conducting a differential diagnosis d) justification of the clinical diagnosis, e) drawing up a treatment plan;
- The maximum score is 5, the minimum score is 3, the unsatisfactory score is 2.

Criteria for the current assessment in a practical lesson:

Score	Evaluation criteria
«5»	The student is fluent in the material, takes an active part in the discussion and solution of a situational clinical problem, confidently demonstrates knowledge of ultrasound screening diagnostics in obstetrics and the correct appointment of laboratory and instrumental studies, expresses his opinion on the topic of the lesson, demonstrates clinical thinking.
«4»	The student is well versed in the material, participates in the discussion and solution of a situational clinical problem, demonstrates knowledge of ultrasound screening diagnostics and the correct appointment of laboratory and instrumental studies with some errors, expresses his opinion on the topic of the lesson, demonstrates clinical thinking.
«3»	The student does not have enough knowledge of the material, uncertainly participates in the discussion and solution of a situational clinical problem, demonstrates knowledge of ultrasound screening diagnostics and the correct appointment of laboratory and instrumental studies with significant errors.
«2»	The student does not own the material, does not participate in the discussion and solution of a situational clinical problem, does not demonstrate knowledge of ultrasound screening diagnostics and the correct appointment of laboratory and instrumental studies.

List of recommended literature.

Main:

- Emergency medicine. Emergency (ambulance) medical care: textbook / I.S. Zozulya, A.O. Volosovets, O.G. Shekera and others. — 5th ed., K. VSV "Medicine", - 2023.- 560 p. ISBN: 978-617-505-917-3
- Obstetrics and Gynecology: in 2 books. - Book 2. Gynecology: textbook (university III-IV r.a.) / ed. V.I. Gryshchenko, M.O. Shcherbyna - 3rd ed., vypr., 2020. – 376 s
- Clinical Obstetrics and Gynecology: 4th Edition/ Brian A. Magovan, Philip Owen, Andrew Thomson. – 2021. – 454 p.
- Boyko V. V, Kharchenko K. V, Manjura O. P, Karacharova I. Y. The role of sonography in the early detection of recurrence of ovarian cancer. Bukovinian Medical Bulletin. 2016;20(3):18-22
- Oxford Textbook of Obstetrics and Gynecology / Sabaratram Arulkumaran, Wiliam Ledger, Lynette Denny, Stergios Doumouchtsis – Oxford University Press, 2020, 928 p. **Additional:**
 - Situational tasks in gynecology: a textbook. / I.Z.Gladchuk, A.G.Volyanska, G.B.Shcherbyna and others.; ed. prof. I.Z.Gladchuk. – Vinnytsia: LLC "Nilan-LTD", 2018.-164 p.
 - Clinical tasks in obstetrics and gynecology for students of IV-VI courses (part I). Methodical development for practical classes in obstetrics and gynecology for students of IV-VI courses of the School of Medicine / O.O. Korchynska, N.Y. Bysaga / ed. rof. Malyara V.A. – Uzhhorod: "Lira", - - 2019.-119s.
 - Clinical tasks in obstetrics and gynecology for students of IV-VI courses (part P). Methodical development for practical classes in obstetrics and gynecology for students of IV-VI courses of the School of Medicine / O.O. Korchynska, N.Y. Bysaga / ed. prof. Malyara V.A. – Uzhhorod: "Lira"- - 2019.-119s.
 - Ra-diol 2019;16(3):403–406.]
<https://doi.org/10.1016/j.jacr.2018.07.004>
 - Current "Clinical Protocols", approved by the order of the Ministry of Health of Ukraine on obstetrics and gynecology.

Online sources for preparation:

- Electronic document "Evidence-based clinical guideline "Ectopic pregnancy", 2022 https://www.dec.gov.ua/wp-content/uploads/2022/09/40273-dn_1730_24092022_dod.pdf"
HYPERLINK https://www.dec.gov.ua/wp-content/uploads/2022/09/40273-dn_1730_24092022_dod.pdf"
HYPERLINK https://www.dec.gov.ua/wp-content/uploads/2022/09/40273-dn_1730_24092022_dod.pdf

content/uploads/2022/09/40273-dn_1730_24092022_dod.pdf"-
HYPERLINK "https://www.dec.gov.ua/wp-

content/uploads/2022/09/40273-
dn_1730_24092022_dod.pdf"dn_1730_24092022_dod.pdf
HYPERLINK "https://www.dec.gov.ua/wp-

- Practical recommendations of the International Society of Ultrasound in Obstetrics and Gynecology (ISUOG). Internet:
www.isuog.org/ISUOGGuidelines HYPERLINK
"http://www.isuog.org/ISUOGGuidelines"
- Ultrasound protocols. Internet-resource: Ukrainian portal of

ultrasound diagnostics. Internet-resource: http://ultrasound.net.ua/
HYPERLINK "http://ultrasound.net.ua/"

- https://medstandart.net/browse/266 – Uterine leiomyoma and benign genital neoplasms
- https://www.cochrane.org/ HYPERLINK "https://www.cochrane.org/"
- https://www.ebcog.org/ HYPERLINK "https://www.ebcog.org/"
- https://www.acog.org/ HYPERLINK "https://www.acog.org/"
- https://www.uptodate.com HYPERLINK
"https://www.uptodate.com/"
- https://online.lexi.com/ HYPERLINK "https://online.lexi.com/"
- https://www.ncbi.nlm.nih.gov/":// HYPERLINK
"https://www.ncbi.nlm.nih.gov/"www HYPERLINK
"https://www.ncbi.nlm.nih.gov/". HYPERLINK
"https://www.ncbi.nlm.nih.gov/"ncbi HYPERLINK
"https://www.ncbi.nlm.nih.gov/". HYPERLINK
"https://www.ncbi.nlm.nih.gov/"nml HYPERLINK
"https://www.ncbi.nlm.nih.gov/". HYPERLINK
"https://www.ncbi.nlm.nih.gov/"nih HYPERLINK
"https://www.ncbi.nlm.nih.gov/". HYPERLINK
"https://www.ncbi.nlm.nih.gov/"gov HYPERLINK
"https://www.ncbi.nlm.nih.gov/"/ HYPERLINK
"https://www.ncbi.nlm.nih.gov/"
- https://pubmed.ncbi.nlm.nih.gov/"://
HYPERLINK "https://pubmed.ncbi.nlm.nih.gov/"pubmed
HYPERLINK "https://pubmed.ncbi.nlm.nih.gov/" . HYPERLINK
"https://pubmed.ncbi.nlm.nih.gov/"ncbi HYPERLINK

["https://pubmed.ncbi.nlm.nih.gov/". HYPERLINK](https://pubmed.ncbi.nlm.nih.gov/)
["https://pubmed.ncbi.nlm.nih.gov/"nlm HYPERLINK](https://pubmed.ncbi.nlm.nih.gov/nlm)
["https://pubmed.ncbi.nlm.nih.gov/". HYPERLINK](https://pubmed.ncbi.nlm.nih.gov/)
["https://pubmed.ncbi.nlm.nih.gov/"nih HYPERLINK](https://pubmed.ncbi.nlm.nih.gov/nih)
["https://pubmed.ncbi.nlm.nih.gov/". HYPERLINK](https://pubmed.ncbi.nlm.nih.gov/)
["https://pubmed.ncbi.nlm.nih.gov/"gov HYPERLINK](https://pubmed.ncbi.nlm.nih.gov/gov)
["https://pubmed.ncbi.nlm.nih.gov/"/ HYPERLINK](https://pubmed.ncbi.nlm.nih.gov/)
["https://pubmed.ncbi.nlm.nih.gov/"](https://pubmed.ncbi.nlm.nih.gov/)

- <https://www.thelancet.com/>
- [https://www.rcog.org.uk/"// HYPERLINK](https://www.rcog.org.uk/)
["https://www.rcog.org.uk/"www HYPERLINK](https://www.rcog.org.uk/www)
["https://www.rcog.org.uk/". HYPERLINK](https://www.rcog.org.uk/)
["https://www.rcog.org.uk/"rcog HYPERLINK](https://www.rcog.org.uk/rcog)
["https://www.rcog.org.uk/". HYPERLINK](https://www.rcog.org.uk/)
["https://www.rcog.org.uk/"org HYPERLINK](https://www.rcog.org.uk/org)
["https://www.rcog.org.uk/". HYPERLINK](https://www.rcog.org.uk/)
["https://www.rcog.org.uk/"uk HYPERLINK](https://www.rcog.org.uk/uk)
["https://www.rcog.org.uk/"/ HYPERLINK](https://www.rcog.org.uk/) ["https://www.rcog.org.uk/"](https://www.rcog.org.uk/)
- [https://www.npwh.org/ HYPERLINK](https://www.npwh.org/) ["https://www.npwh.org/"](https://www.npwh.org/)

