

ONMedU, Department of Obstetrics and Gynecology.
Practical lesson No. 3. " Bimanual vaginal examination".

MINISTRY OF HEALTH OF UKRAINE

ODESA NATIONAL MEDICAL UNIVERSITY

Faculty international

Department of Obstetrics and Gynecology



CONFIRMED by
Vice-rector for scientific and pedagogical work
Eduard BURIACHKIVSKYI
«01»September 2023

**METHODOLOGICAL RECOMMENDATIONS FOR THE PRACTICAL
LESSON FROM ELECTIVE DISCIPLINE**

Faculty international, 5th year

Elective discipline «SIMULATION TRAINING IN OBSTETRICS AND
GYNECOLOGY».

Practical lesson No. 3. " Bimanual vaginal examination".

Methodical recommendations of a practical lesson, EPP "Medicine", 5th year, Faculty international. Elective discipline " Simulation training in obstetrics and gynecology".

ONMedU, Department of Obstetrics and Gynecology.
Practical lesson No. 3. " Bimanual vaginal examination".

Approved

Meeting of the Department of Obstetrics and
Gynecology Odessa National Medical University

Protocol No. 1 of August 28, 2023.

Head of the Department




(Ihor GLADCHUK)

Developed by:
Ph.D., Associate Professor



Shytova G.V.

Ph.D, Associate Professor



Pavlovska O.M.

Ph.D, assistant



Tarnovska G.P.

Ph.D, assistant



Zhovtenko L.V.

Practical lesson №3

Topic: «Bimanual vaginal examination».

Goal. Learn the algorithm of bimanual examination in gynecology for gynecological patients. Perform medical manipulations in the conditions of a medical institution, at home or at work based on a previous clinical diagnosis and/or indicators of the patient's condition, using knowledge about a person, his organs and systems, observing the relevant ethical and legal norms, by making a reasoned decision and using standard methods of drawing up a plan for laboratory and instrumental research in gynecological diseases and during pregnancy. Formation of skills in performing medical manipulations in gynecology.

Basic concepts: algorithm of bimanual examinations in gynecology and obstetrics. Diagnosis of changes of pelvic organs due to inflammatory diseases, tumor, ectopic pregnancy, early term of pregnancy with bimanual examination.

Equipment: Professional algorithms, structural and logical schemes, tables, models, video materials, results of laboratory and instrumental exam, situational tasks, patients, clinical cases.

EDUCATIONAL TIME – 4 h

- **Organizational events (greetings, checking those present, announcing the topic, the purpose of the lesson, motivating students to study the topic).**

Bimanual examination is part of the patient's gynecological examination. With the help of a bimanual examination, diagnostics are carried out: - inflammatory diseases of the internal genital organs, - pregnancy (uterine and ectopic), - tumors and tumor processes of the pelvic organs, - developmental anomalies, abnormalities in the position of the internal genital organs.

- **Control of the reference level of knowledge (written work, written test, online test, interviewed, etc.).**

Requirements for students' theoretical readiness to perform practical classes(knowledge requirements, list of didactic units).

- Knowledge requirements:

- Communication and clinical patient examination skills.
- The ability to determine the list of necessary clinical and laboratory and instrumental studies and evaluate their results.

- Ability to establish a preliminary and clinical diagnosis of the disease
- Perform medical manipulations
- Ability to keep medical records

List of didactic units:

- Collect medical history, medical and life history, special history.
- Practice bimanual and rectal examination methods on the phantom.
- On the phantom, practice the main instrumental methods of examining the patient (puncture of the posterior vault, probing the uterine cavity, functional diagnostic scraping)
- Evaluate the results of bimanual examination.
- Draw up a plan for further examination depending on the results obtained.

Questions (test tasks, problems, clinical situations) to check basic knowledge on the subject of the lesson.

Questions:

- Clinical anatomy of the female genitalia.
- Congenital anatomical abnormalities of female genitalia.
- Tumors of uterus and ovaries.
- Ectopic pregnancy.
- Methods of examination and diagnosis of uterus and adnex pathology.

Situational tasks

1. A 52-year-old woman turned to a doctor at the women's clinic for a professional examination. Menopause 7 years. She did not complain, 2 abortions. She was in the dispensary register for uterine myoma corresponding to 6-7 weeks of pregnancy for 10 years

Bimanually: the vagina is free, the cervix is cylindrical, the mouth is closed. The uterus is enlarged to the 9th week of pregnancy, with a bumpy surface, mobile, painless. Vaults are deep. Appendices are not defined.

- DIFFERENTIAL DIAGNOSIS
- TACTICS

Answer

- Growing myoma of the uterus in postmenopause

- Uterine sarcoma
- Ovarian cyst

Tactics:

- Dispensary observation at the place of residence
- Urgent active treatment
- Ultrasound of the pelvis
- Separate curettage of the uterine cavity and cervical canal

• Patient V., 29 years old, admitted to the gynecologist complaining of the absence of pregnancy in her marriage. It is known from the anamnesis: menstruation from the age of 12, regular, for 4-5 days, after 28 days, painless. The last period was from 15.04 to 19.04., came on time, without any special features. Sexual life since 24 years, married for 5 years, does not use contraceptive methods. 1st pregnancy, ended with a medical abortion at 8 weeks. After that, for the past six years, he has been treated annually for exacerbation of chronic bilateral adnexitis. Her husband is 32 years old, healthy, smokes.

On examination: the external genitalia are formed correctly, the hair is of the female type. The vagina of a barren woman, the mucous membrane is pale pink in color. The cervix is conical in shape, clean, the external opening is slit-like.

Bimanually: Uterus in anteflexio-anteversio, normal size, dense-elastic consistency, limited mobility during palpation, painless. The appendages are heavy on both sides, sensitive to palpation. Vaults are deep, parameters are free.

Presumed diagnosis? What tests should be performed to confirm the diagnosis?

Diagnosis: Secondary infertility, tubular - peritoneal form. Chronic bilateral adnexitis, without exacerbation.

Tactics: metrosalpingographia

• Patient V., 18 years old, admitted to the gynecologist with a complaint of the absence of menstruation, vaginal dryness, impossibility of sexual activity.

From the anamnesis it is known: she was born a premature baby, she was often sick in childhood.

Status praesens: female phenotype, height 165 cm, BMI 21 kg/m². The skin is clean. The mammary glands are hypoplastic. There is no hair growth in the armpits.

On examination: Pubic hair is absent. The labia majora are hypertrophied, rounded formations 2x2 cm are determined in their thickness. The labia minora are hypoplastic.

In the mirrors: the vagina is narrow, shortened, ends blindly.

Bimanually: in the projection of the uterus, the muscular roller is determined, the appendages are not determined.

Estimated diagnosis? What tests are needed to confirm the diagnosis?

Answer:

Diagnosis: Morris Syndrome.

Examination plan: - Ultrasound of the pelvic organs

- karyotype study
- definition of sex chromatin

Treatment: removal of the testicles, HRT.

• Patient V., 45 years old, admitted to a gynecologist with complaints of bloody discharge from the genital tract. From the anamnesis it is known: menstruation from the age of 13, for 4-5 days, after 29 days, moderate, regular, painless. Last year, menstruation became more abundant, longer (up to 10 days). Six months ago, a small uterine fibroid was diagnosed.

On examination: the external genital organs are formed correctly, the hair is of the female type. The vagina giving birth, the mucous membrane is pale pink. The cervix is cylindrical, clean.

Bimanually: Uterus in anteflexio-anteversio, enlarged up to 9 weeks, dense-elastic consistency, palpation is limited mobile, bumpy, painless. Appendages on both sides are not palpable, painless. The vaults are deep, the parameters are free.

What is your diagnosis? What additional examinations need to be performed?

Answer

Diagnosis: uterine fibroids.

- Transvaginal ultrasound
- Hysteroscopy, separate medical and diagnostic curettage of the uterine cavity, cervical canal.

• **Formation of professional abilities and skills (mastery of skills, conducting curation, determining the treatment scheme, conducting laboratory research, etc.).**

— **Content of tasks (tasks, clinical situations, etc.).**

Interactive task:

The students of the group are divided into 3 subgroups of 4-5 people each. We work in women's consultation rooms with gynecological patients, we give tasks: And the subgroup - to make a preliminary diagnosis.

Subgroup II – to draw up a management plan for a gynecological patient.

Subgroup III – evaluates the correctness of the answer of subgroups I and II and makes its corrections.

— **Recommendations (instructions) for performing tasks (professional algorithms, orienting maps for the formation of practical skills and abilities, etc.).**

Vaginal examination.

After the mirror examination, a vaginal examination is performed. It is carried out with the help of fingers inserted into the vagina, with two hands. The labia are parted with the thumb and index finger of the left hand, the middle and index finger of the right hand are inserted into the vagina, sensitivity, width of the entrance to the vagina, elasticity of its walls, the condition of the mucous membrane, the presence of tumors, partitions are assessed.

Next, the vaginal part of the cervix is examined, its shape, size, shape of the external eye, the presence of scars, ruptures after childbirth, and tumors are determined.

Vaginal and abdominal examination.

Then a two-handed (bimanual) combined vaginal-abdominal examination is performed. This is the main gynecological examination, as it allows you to assess the position, size, shape of the uterus, determine the condition of the appendages, pelvic peritoneum and tissue. During a bimanual examination, tissues and organs are palpated not with the tips of the fingers, but, if possible, with the entire surface of the fingers.

Bimanual examination is a continuation of vaginal examination. At the same time, one hand (inner) is in the vagina, and the other (outer) is above the womb.

Research begins with the uterus. Normally, the uterus is located along the midline of the pelvis, at the same distance from the pubic symphysis and the sacrum.

The uterus of an adult woman is pear-shaped, flattened in the anterior-posterior direction, its surface is smooth.

On examination, the uterus is painless, mobile in all directions, its consistency is normally elastic.

After examination of the uterus, the appendages (ovaries and fallopian tubes) are palpated. Normally, they are not palpable. Pipes, ligaments, fiber are not normally defined. Rectal-abdominal examination.

If examination through the vagina is impossible (in girls, with vaginal atresia, tumors), a combined rectal examination is performed.

The research is carried out on a gynecological chair in a sterile rubber glove lubricated with petroleum jelly. A cleansing enema must be prescribed beforehand.

A combined rectal-vaginal-abdominal examination is carried out if there is a suspicion of the presence of pathological processes in the wall of the vagina or the rectum. For this, the index finger is inserted into the vagina, the middle finger of the right hand is inserted into the rectum, and the pelvic organs are palpated through the abdominal wall with the left hand. At this time, all women are examined to rule out rectal cancer.

Additional research methods are used to clarify the diagnosis of gynecological patients, especially women undergoing preventive examinations.

Steps of bimanual examination with

- greet the patient;
- identify the patient (name, age);
- inform the patient about the necessity of conducting the study;
- explain to the patient how the study is conducted;
- obtain permission to conduct research;
- wash hands;
- put on inspection gloves;
- look for changes of external genitalia

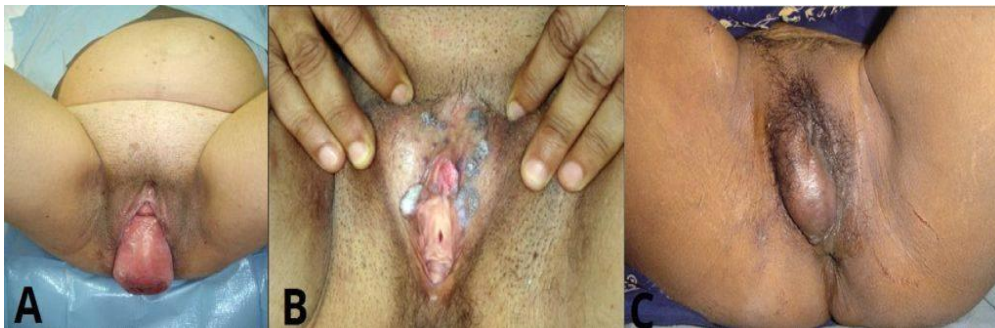

Fig 1 - Signs on external inspection during the bimanual examination. A) Uterine prolapse, b) Genital warts, c) Bartholin's cyst.

- spread the labia majora with the first and second fingers of the left (right) hand, place the middle finger of the "dominant" hand at the level of the posterior adhesion, gently press on it to open the entrance to the vagina;
- carefully and slowly insert the middle finger, then the index finger into the vagina along the back wall to the vault and cervix, bring the fourth and fifth fingers to the palm, bring the thumb to the top;

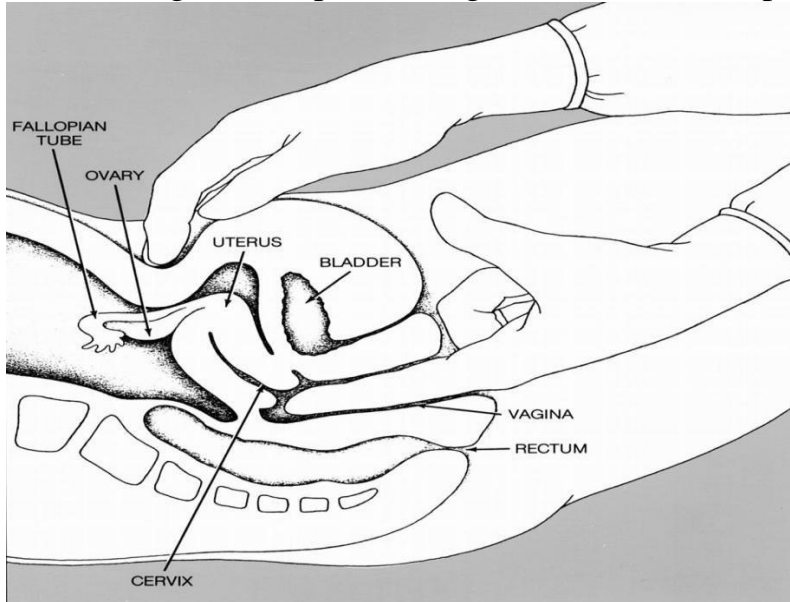


Fig2 – The bimanual examination. One hand lifts the uterus, whilst the other pushes the fundus down.

- determine the length of the vaginal part of the cervix in centimeters;
- determine the consistency of the cervix (dense, soft);
- determine the patency of the external os of the cervical canal (closed, a fingertip passes through);
- assess the painfulness of the cervical excursion;
- gently place the second palm on the stomach (above the symphysis) and moderately press to determine the bottom of the uterine body;
- remove the body of the uterus between two hands and determine:
 - the position of the uterus relative to the cervix (anteflexio, retroflexio);
 - the size of the uterus (normal, reduced, increased);
 - consistency of the body of the uterus (tight-elastic, soft, compacted);

- mobility of the uterine body (relatively mobile, limited mobility);
- sensitivity during palpation (painful, painless);
- place your fingers in the bottom of the right lateral vault and, using both hands, palpate the right vaginal vault and right uterine appendages, determine their size, mobility and painfulness;
- place the fingers in the bottom of the left lateral vault and, using both hands, palpate the left vaginal vault and the left appendages of the uterus, determine their size, mobility and painfulness;
- determine the capacity of the vaginal vaults;

To Complete the Examination

- Thank the patient and allow them to get dressed in private
- Dispose of your gloves and wash your hands
- Once the patient is dressed you can summarise the findings and suggest further investigations

- **Summing up:**

On-going control: oral survey, testing, assessment of performance of practical skills, solution of situational clinical tasks, assessment of activity in class, etc.

The structure of the current assessment in the practical session:

- ***Evaluation of theoretical knowledge on the subject of the lesson:***
- methods: survey, solving a situational clinical problem;
- maximum score – 5, minimum score – 3, unsatisfactory score – 2.
- Evaluation of practical skills and manipulations on the subject of the lesson:
- methods: assessment of correct performance of practical skills;
- maximum score – 5, minimum score – 3, unsatisfactory score – 2.
- Evaluation of work with the patient on the subject of the lesson:
- methods: assessment of: a) communication skills of communicating with the patient, b) the correctness of prescribing and evaluating laboratory and instrumental studies, c) compliance with the differential diagnosis algorithm, d) substantiation of the clinical diagnosis, e) drawing up a treatment plan;
- maximum score – 5, minimum score – 3, unsatisfactory score – 2.

Criteria for current assessment on the practical lesson:

«5»	The student is fluent in the material, takes an active part in the discussion and solution of situational clinical problems, confidently demonstrates practical skills during the examination of a pregnant and interpretation of clinical, laboratory and instrumental studies, expresses his opinion on the
-----	---

	topic, demonstrates clinical thinking.
«4»	The student is well versed in the material, participates in the discussion and solution of situational clinical problems, demonstrates practical skills during the examination of a pregnant and interpretation of clinical, laboratory and instrumental studies with some errors, expresses his opinion on the topic, demonstrates clinical thinking.
«3»	The student isn't well versed in material, insecurely participates in the discussion and solution of a situational clinical problem, demonstrates practical skills during the examination of a pregnant and interpretation of clinical, laboratory and instrumental studies with significant errors.
«2»	The student isn't versed in material at all, does not participate in the discussion and solution of the situational clinical problem, does not demonstrate practical skills during the examination of a pregnant and the interpretation of clinical, laboratory and instrumental studies.

- The student is admitted to the credit if he fulfills the requirements of the educational program and if he received at least 3.00 points for the current educational activity.

Test

At the end of the study of the discipline, the assessment is carried out. Only those students who have no academic debt and have an average score for the current educational activity of at least 3.00 are admitted to the final certification. If the discipline ends with a credit, only the average score of the current performance is calculated, that is, the arithmetic average of all received grades on a traditional scale, rounded to two decimal places, which is

converted according to the 200- point system. At the same time, the average current score is recorded in the corresponding documentation, which is converted on a 200-point scale and a grade is assigned on a 2-point scale (“passed” or “not passed”):

- the grade "passed" is awarded to a student who has completed the curriculum of the discipline and has no academic debt; the level of competence is high (creative);

- the grade "failed" is assigned to a student who has not completed the curriculum of the discipline, has academic debt (average grade below 3.0 and/or missed classes); the level of competence is low (receptive-productive).

RECOMMENDED LITERATURE

Basic:

- Zaporozhan V.M., Mishchenko V.P. Obstetrics and gynaecology in 2 Books

: Book 1 : Obstetrics, 2007. – 373 pp.

- Williams Manual of Obstetrics (24th Ed) F. G. Cunningham, K. J. Leveno,

S. L. Bloom, C. Y. Spong, J. S. Dashe, B. L. Hoffman, B. M. Casey, J. S. Sheffield, McGraw-Hill Education/Medical. – 2014. – 1377 pp.

- Textbook of Gynecology (6th Ed) Dutta DC., Hiralal Konar (Ed.). – JAYPEE BROTHERS MEDICAL PUBLISHERS (P) LTD, 2013. – 702 pp.

- DC Duttas Textbook of Obstetrics including Perinatology and Contraception (8th Ed.) Dutta DC., Hiralal Konar (Ed.). – JAYPEE BROTHERS MEDICAL PUBLISHERS (P) LTD, 2015. – 782 pp.

- Llewellyn-Jones Fundamentals of Obstetrics and Gynaecology (10th Ed). Jeremy Oats, Suzanne Abraham. Elsevier. 2016. – 384 pp.

- The FIGO Textbook of Pregnancy Hypertension. An evidence-based guide to monitoring, prevention and management. L. A. Magee, P. Dadelszen, W. Stones, M. Mathai (Eds), The Global Library of Women’s Medicine. – 2016. – 456pp.

- Mayo Clinic Guide to a Healthy Pregnancy. Roger W. Harms (Ed). Rosetta books, 2011. – 612 pp.

- Best practice in labor and delivery / edited by Richard Warren, S. Arullkumaran. Cambridge University Press. – 2009. – 362 pp.

- Basic Science in Obstetrics and Gynaecology / edited by Philip Bennet, Catherine Williamson. 4th Edition. 2010, Churchill Livingstone Elsevier. – 386 pp.

Additional:

- Maternal-Fetal Medicine. Creasy R.K., Resnik R – 2009. – 1296 pp.

- Gibbs R. S., Karlan B. Y., Haney A. F., Nygaard I. E. Danforth's Obstetrics and Gynecology (10th Ed).- Lippincott Williams & Wilkins. – 2008. – 2225 pp.

- CTG Made Easy / edited by Susan Gauge, Christine Henderson. 3rd Edition,2009.- Elsevier Churchill Livingstone. – 280 pp.

- Obstetrics: Normal and Problem Pregnancies, 7th Edition S. Gabbe, J. R. Niebyl, J. L. Simpson, M. B. Landon, H. L. Galan, E. R. M. Jauniaux, D. A. Driscoll, V. Berghella and W. A. Grobman, Elsevier. – 2017. – 1320 pp.

- Obstetrics by Ten Teachers (20th ed) Louise C. Kenny, Jenny E. Myers. –CRC Press. – 2017. – 342 pp.

- Current Progress in Obstetrics and Gynaecology. Vol 4. Eds. J. Studd, SeangLin Tan, F. Chervenak. – 2017. – 419 pp.

- Recent Advances in Obstetrics and Gynaecology. Vol 26. W. Ledger, J.Clark. – JP Medical. – 2015.– 230 pp.

- Proactive Support of Labor. Reuwer P., Bruinse H., Franx A. – 2015. – 216pp.

INTERNET SOURCES:

- <https://www.cochrane.org/>

- <https://www.ebcog.org/>

- <https://www.acog.org/>

- <https://www.uptodate.com>

- <https://online.lexi.com/>

- <https://www.ncbi.nlm.nih.gov/>

- <https://pubmed.ncbi.nlm.nih.gov/>

- <https://www.thelancet.com/>

- <https://www.rcog.org.uk/>

- <https://www.npwh.org/>