

ONMedU, Department of Obstetrics and Gynecology. Practical lesson No. 5. "External obstetric examination, determination and evaluation of the topography of the fetus in the uterus. Auscultation of the fetus. CTG"

MINISTRY OF HEALTH OF UKRAINE

ODESA NATIONAL MEDICAL UNIVERSITY

Faculty international

Department of Obstetrics and Gynecology



CONFIRMED by
Vice-rector for scientific and pedagogical work
Eduard BURIACHKIVSKYI
«01» September 2023

**METHODOLOGICAL RECOMMENDATIONS FOR THE PRACTICAL LESSON
FROM ELECTIVE DISCIPLINE**

Faculty international, 5th year

Elective discipline «SIMULATION TRAINING IN OBSTETRICS AND
GYNECOLOGY».

Practical lesson № 5 "External obstetric examination, determination and evaluation of
the topography of the fetus in the uterus. Auscultation of the
fetus. CTG"

ONMedU, Department of Obstetrics and Gynecology. Practical lesson No. 5. "External obstetric examination, determination and evaluation of the topography of the fetus in the uterus. Auscultation of the fetus. CTG"

Approved

Meeting of the Department of Obstetrics and Gynecology
Odessa National Medical University

Protocol No. 1 of August 28, 2023.

Head of the Department



(Ihor GLADCHUK)


Developed by:

Ph.D., Associate Professor



Shytova G.V.

Ph.D, Associate Professor



Pavlovska O.M.

Ph.D, assistant



Tarnovska G.P.

Ph.D, assistant



Zhovtenko L.V.

Methodical recommendations of a practical lesson, EPP "Medicine", 5th year, Faculty international.
Elective discipline " Simulation training in obstetrics and gynecology".

ONMedU, Department of Obstetrics and Gynecology. Practical lesson No. 5. “External obstetric examination, determination and evaluation of the topography of the fetus in the uterus. Auscultation of the fetus. CTG”

MINISTRY OF HEALTH OF UKRAINE

ODESA NATIONAL MEDICAL UNIVERSITY

Faculty international

Department of Obstetrics and Gynecology

CONFIRMED by

Vice-rector for scientific and pedagogical work

_____ Eduard BURIACHKIVSKYI

«01»September 2023

**METHODOLOGICAL RECOMMENDATIONS FOR THE PRACTICAL LESSON
FROM ELECTIVE DISCIPLINE**

Faculty international, 5th year

Elective discipline «SIMULATION TRAINING IN OBSTETRICS AND
GYNECOLOGY».

**Practical lesson № 5 “External obstetric examination, determination and evaluation of
the topography of the fetus in the uterus. Auscultation of the
fetus. CTG”**

Approved

Meeting of the Department of Obstetrics and Gynecology
Odessa National Medical University

Protocol No. 1 of August 28, 2023.

Head of the Department

(Igor GLADCHUK)

Developed by:

Candidate of Medical Sciences, Associate Professor

Shytova G.V.

Candidate of Medical Sciences, Associate Professor

Pavlovska O.M.

D., assistant

Tarnovska G.P.

Candidate of Medical Sciences, assistant

Zhovtenko L.V.

Practical lesson № 5

"External obstetric examination, determination and evaluation of the topography of the fetus in the uterus. Auscultation of the fetus. CTG"

LEARNING OBJECTIVE is to gain basic knowledge about methods of obstetrical examination, appropriate prenatal counseling and supervision in order to provide successful obstetric outcome.

BASIC CONCEPTS:

Leopold`s manoeuvres

Fetal orientation

Assessment of fetal head engagement

Determination of estimated fetal weight

Auscultation of the fetal heart tones

CTG

Equipment

- Multimedia equipment (computer, projector, screen), TV.
- Obstetric phantom with fetal doll
- Soft tape measure
- Professional algorithms, structural-logical schemes, tables, videos.
- Results of laboratory and instrumental researches, situational tasks, patients, medical histories.

EDUCATIONAL TIME – 4 h

I. ORGANIZATIONAL STAGE

- greetings,
- checking attendees,
- defining of educational goals,
- providing of positive motivation.

II. CONTROL OF BASIC KNOWLEDGE (written work, written testing, online testing, face-to-face interview, etc.)

2.1. Requirements for the theoretical readiness of students to perform practical classes.

Knowledge requirements:

SC1. Ability to collect medical information about the patient and analyze clinical data

SC 2. Ability to determine the necessary list of laboratory and instrumental studies and evaluate their results

SC 3. Ability to establish a preliminary and clinical diagnosis of the disease

SC 4. Ability to determine the necessary regime of work and rest in the treatment and prevention of diseases

- SC 5. Ability to determine the nature of nutrition in the treatment and prevention of diseases
- SC 6. Ability to determine the principles and nature of treatment and prevention of diseases
- SC 8. Ability to determine tactics and provide emergency medical care
- SC 9. Ability to carry out medical evacuation measures
- SC 14. Ability to plan and carry out preventive and anti-epidemic measures for infectious diseases

List of didactic units:

- Leopold`s manoeuvres
- Fetal orientation
- Assessment of fetal head engagement
- Determination of estimated fetal weight
- Auscultation of the fetal heart tones
- CTG

2.2. Questions (test tasks, tasks, clinical situations) to test basic knowledge on the topic of the class.

Questions:

- Why does external obstetric examination is used in Obstetrics?
- What is the first Leopold`s manoeuver (fundal grip)?
- Why does the first Leopold`s manoeuver (fundal grip) is used in Obstetrics?
- What is the second Leopold`s manoeuver (lateral grip)?
- Why does the second Leopold`s manoeuver (lateral grip) is used in Obstetrics?
- What is the third Leopold`s manoeuver (first pelvic grip)?
- Why does the third Leopold`s manoeuver (first pelvic grip) is used in Obstetrics?
- What is the fourth Leopold`s manoeuver (second pelvic grip)?
- Why does the first Leopold`s manoeuver (second pelvic grip) is used in Obstetrics?
- What is abdominal method of assessment of descent of the fetal head («fifth method»)?
- What is fetal lie?
- What is the difference between longitudinal, transverse and oblique fetal lie?
- What is fetal presentation?
- What is cephalic presentation?
- What is the difference between vertex, median vertex, brow and face presentation?
- What is breech presentation?
- What is the difference between complete and incomplete breech presentation?
- What is fetal position? What is fetal attitude?

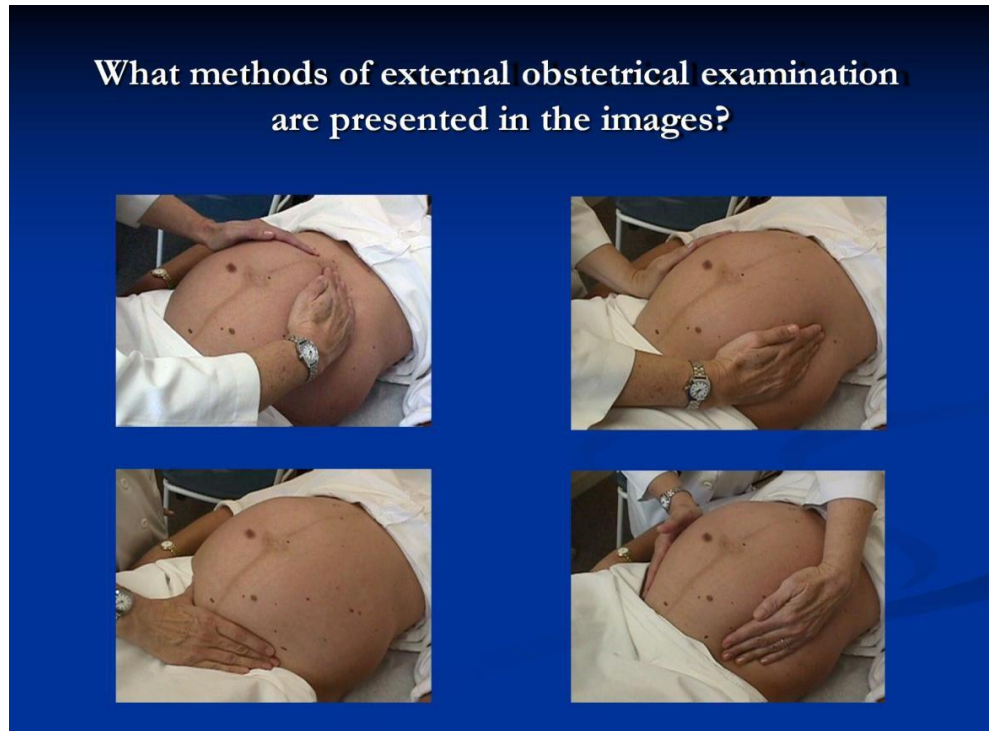
ONMedU, Department of Obstetrics and Gynecology. Practical lesson No. 5. "External obstetric examination, determination and evaluation of the topography of the fetus in the uterus. Auscultation of the fetus. CTG"

What are main rules during auscultation of the fetal heart tones?

What are main rules during fetal monitoring (CTG)?

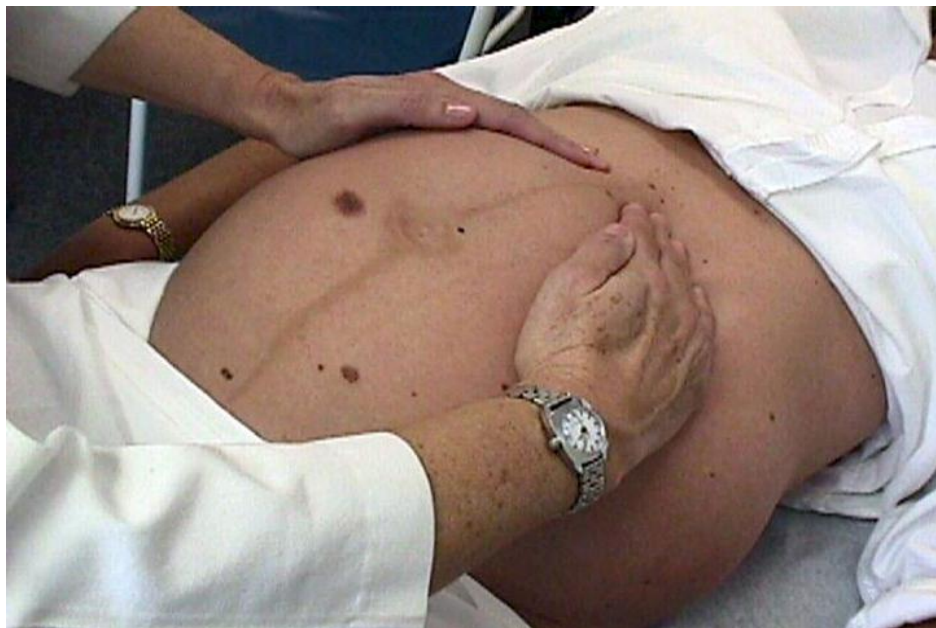Tasks

Task 1



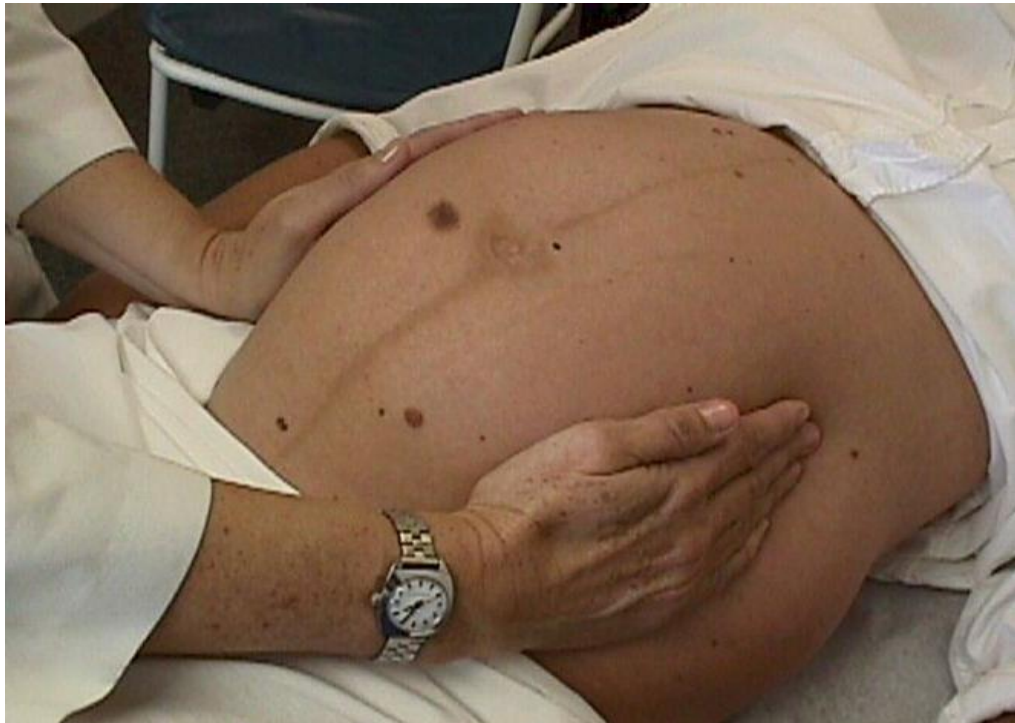Task 2

What method of external obstetrical examination is presented in the figures? Why this method is used in Obstetrics?



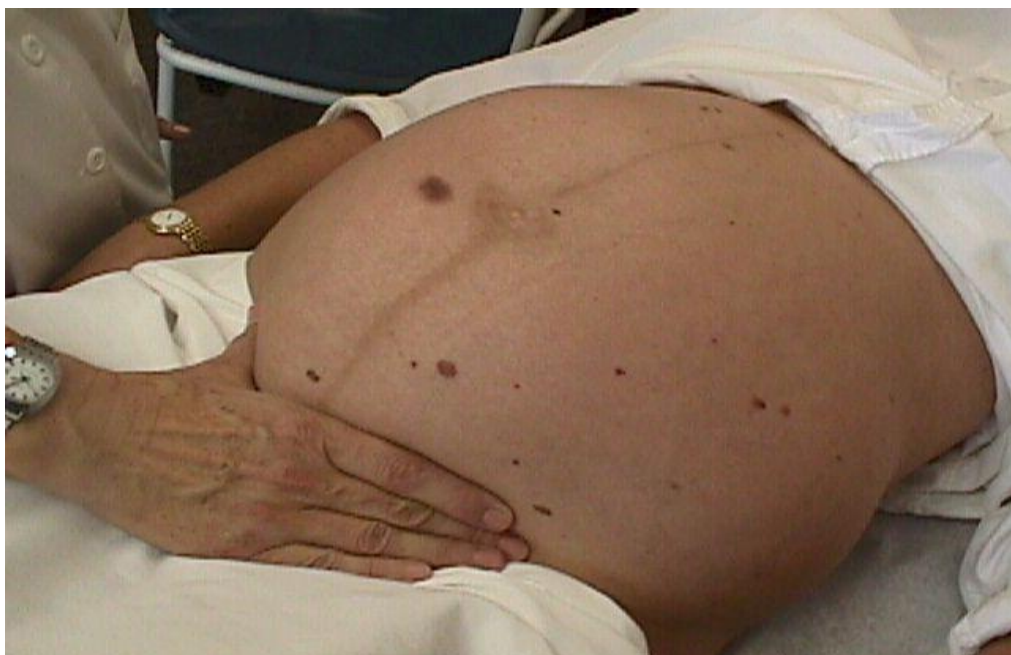Task 3

What method of external obstetrical examination is presented in the figures? Why this method is used in Obstetrics?



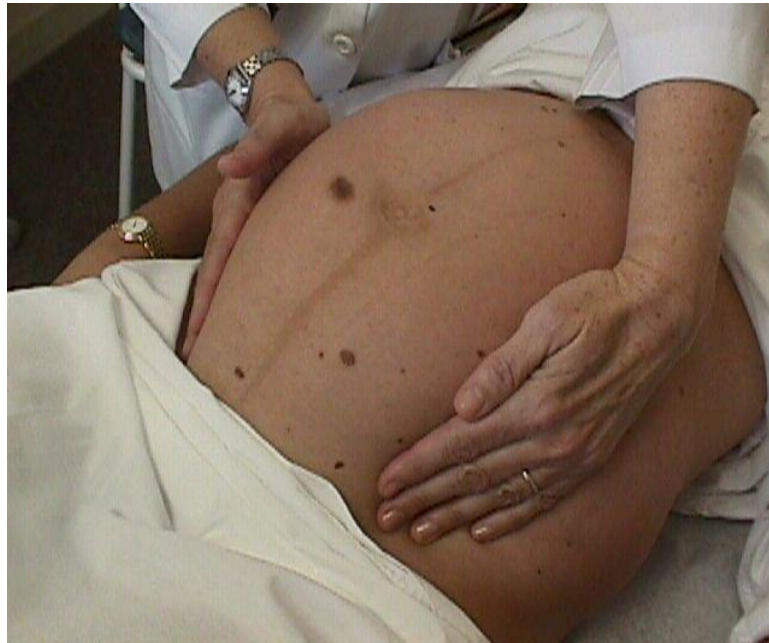Task 4

What method of external obstetrical examination is presented in the figures? Why this method is used in Obstetrics?



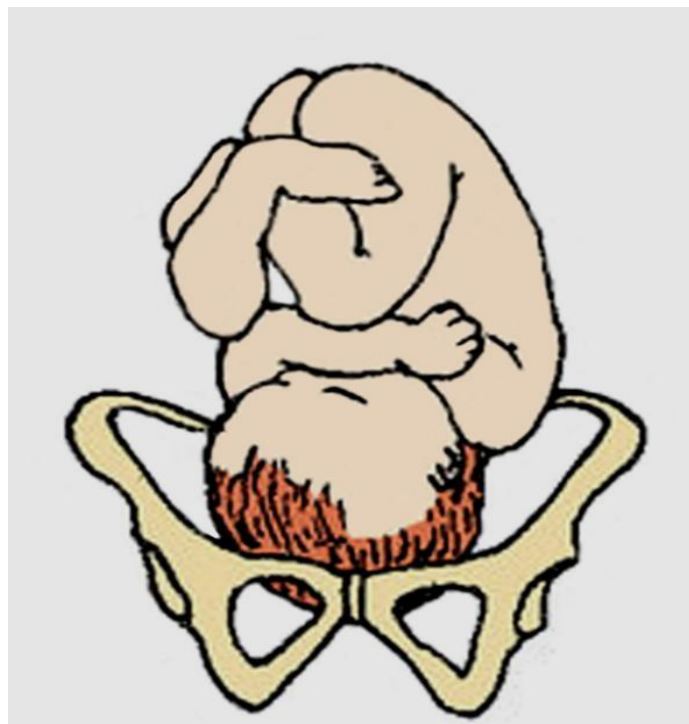
Task 5

What method of external obstetrical examination is presented in the figures? Why this method is used in Obstetrics?



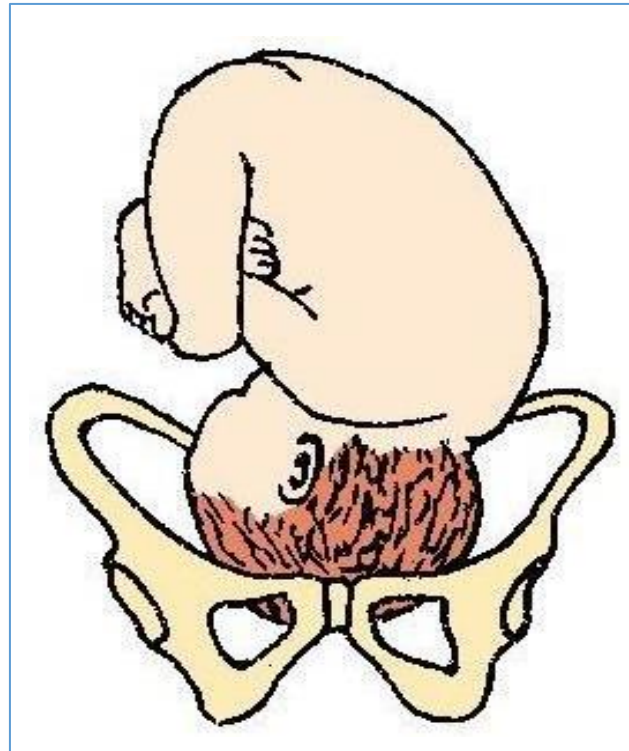
Task 6

Define the fetal lie, presentation and position



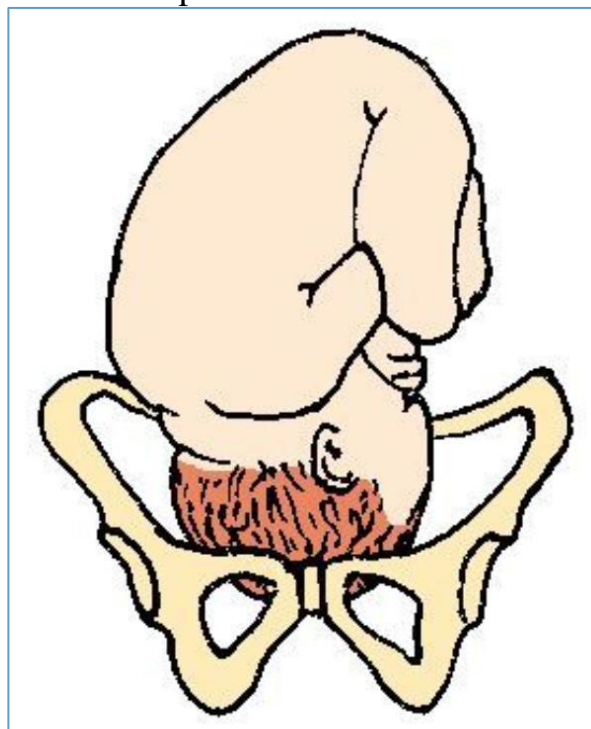
Task 7

Define the fetal lie, presentation and position



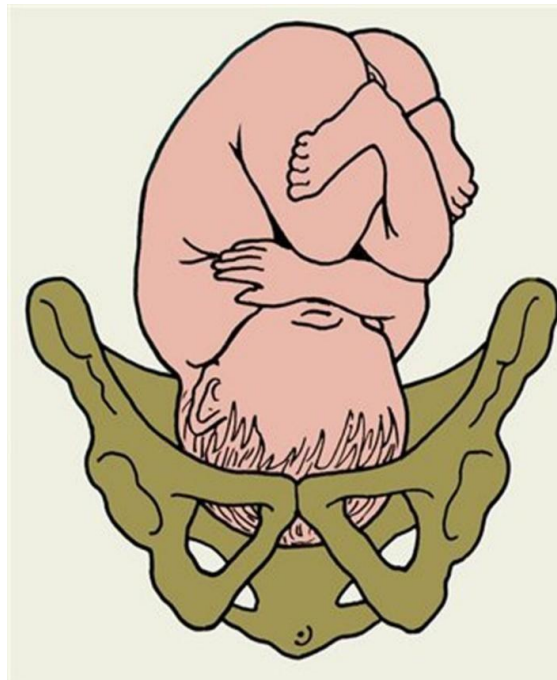
Task 8

Define the fetal lie, presentation and position



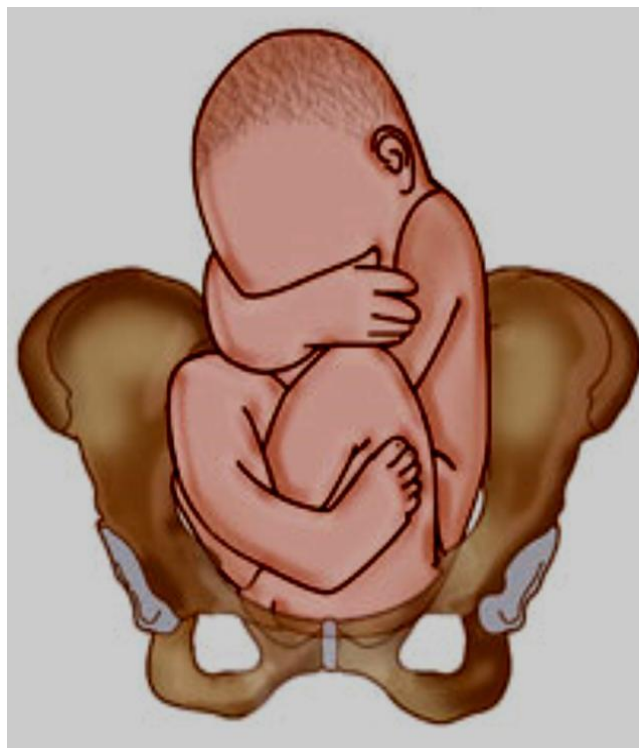
Task 9

Define the fetal lie, presentation and position



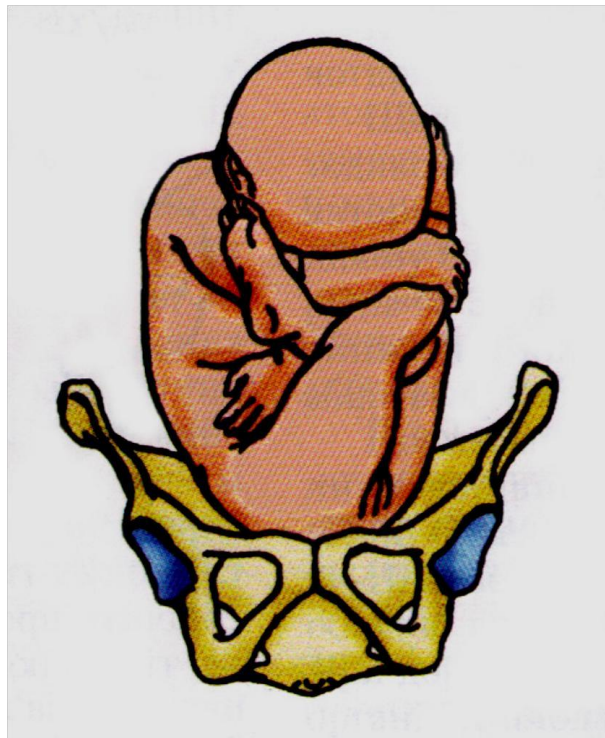
Task 10

Define the fetal lie, presentation and position



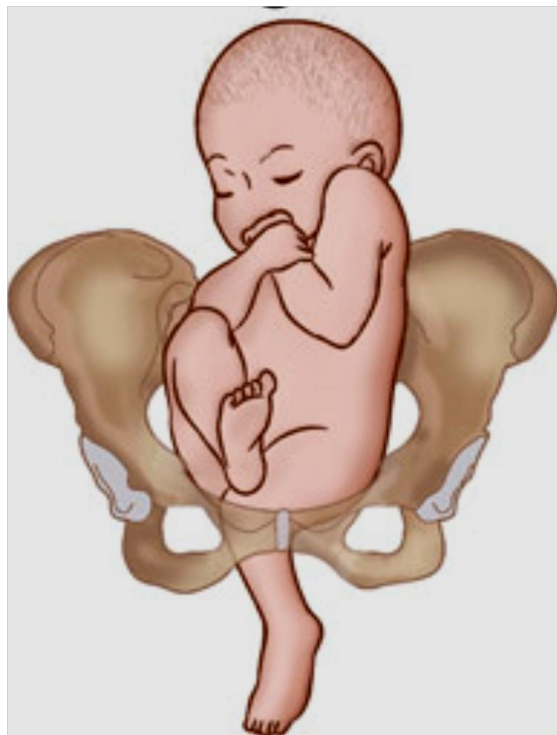
Task 11

Define the fetal lie, presentation and position



Task 12

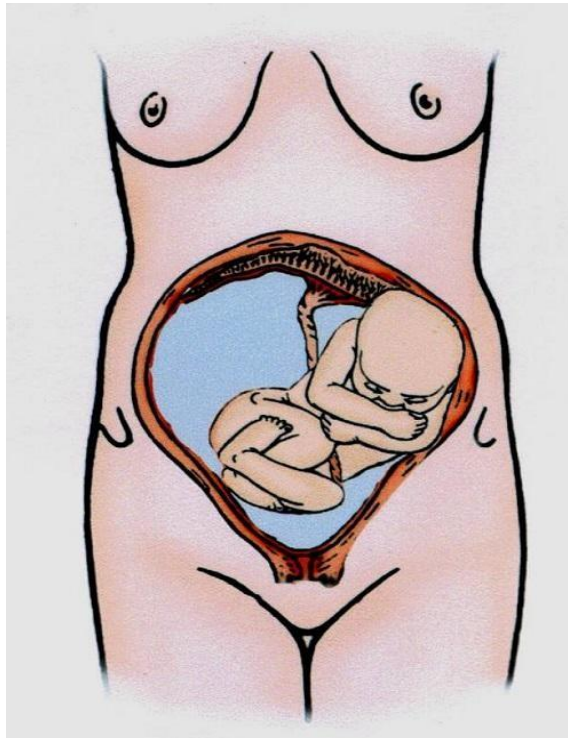
Define the fetal lie, presentation and position



Task 13

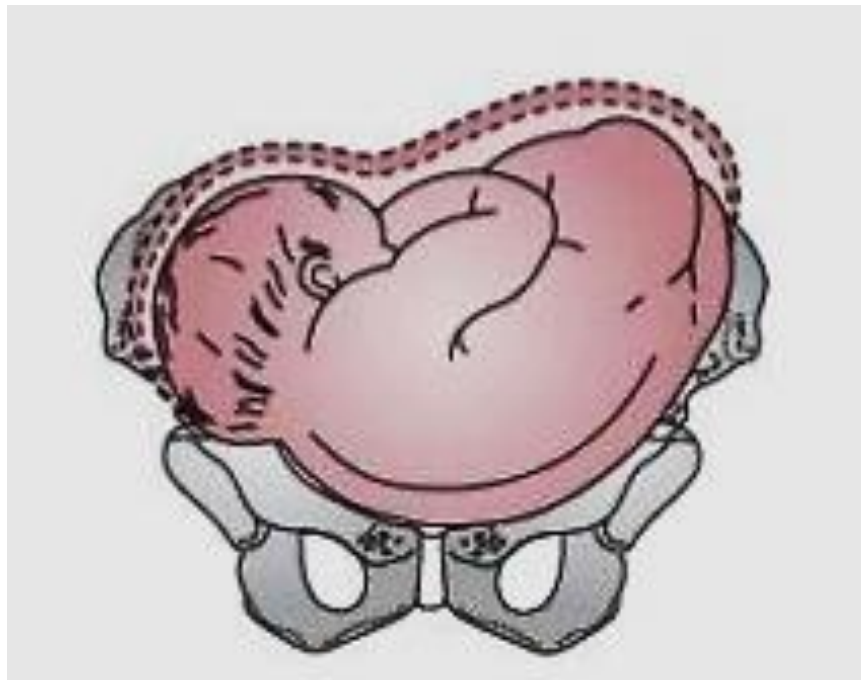
ONMedU, Department of Obstetrics and Gynecology. Practical lesson No. 5. "External obstetric examination, determination and evaluation of the topography of the fetus in the uterus. Auscultation of the fetus. CTG"

Define the fetal lie, presentation and position



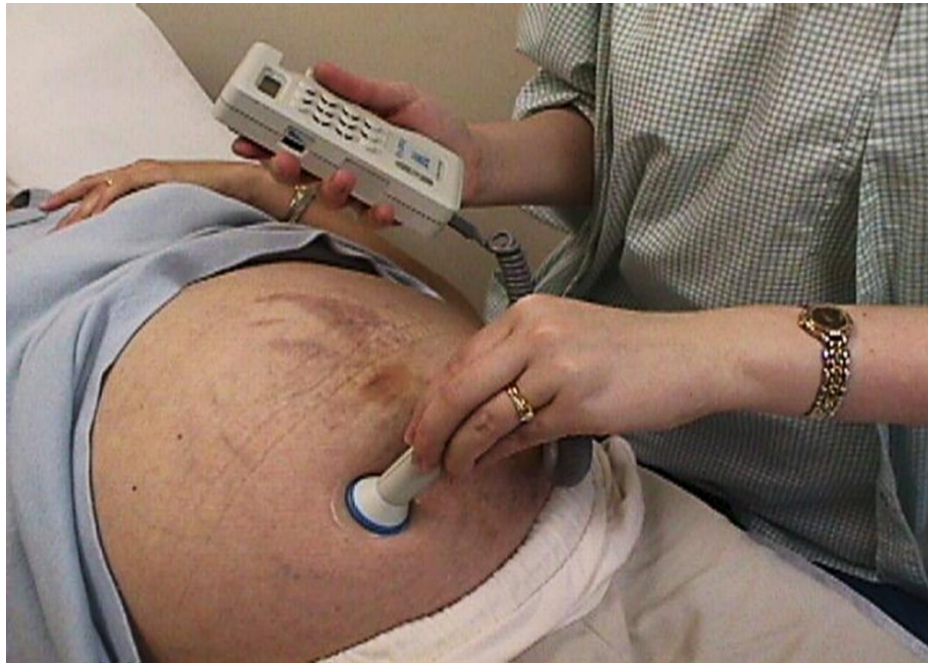Task 14

Define the fetal lie, presentation and position



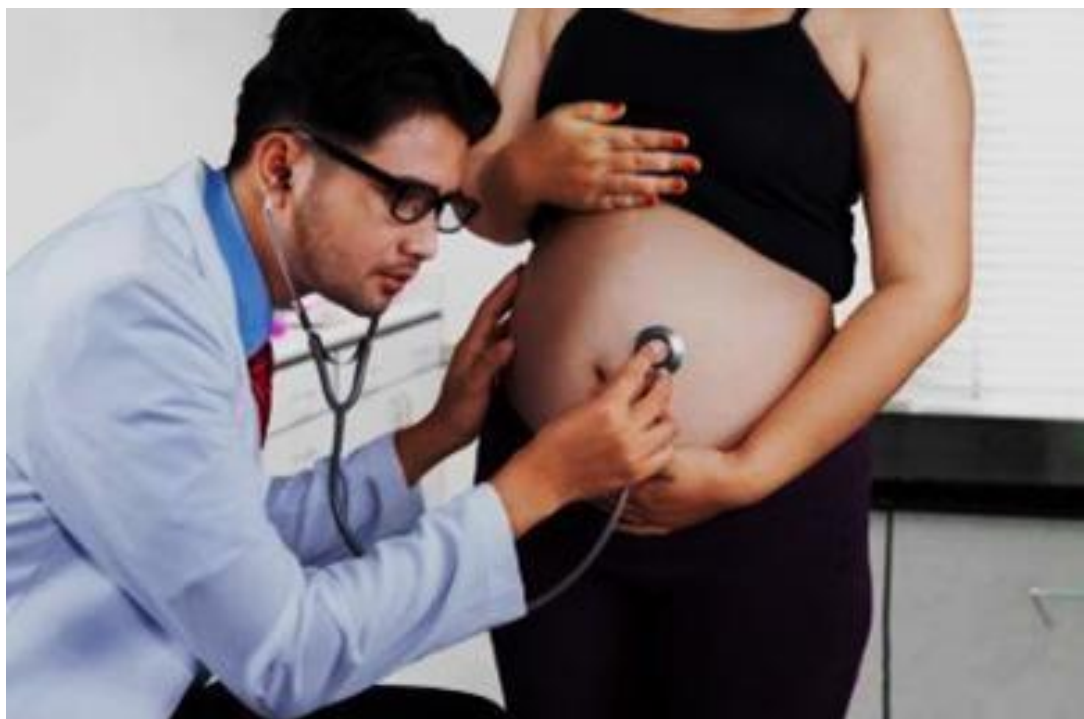Task 15

Identify by the location of the point of auscultation the fetal lie, presentation and position



Task 16

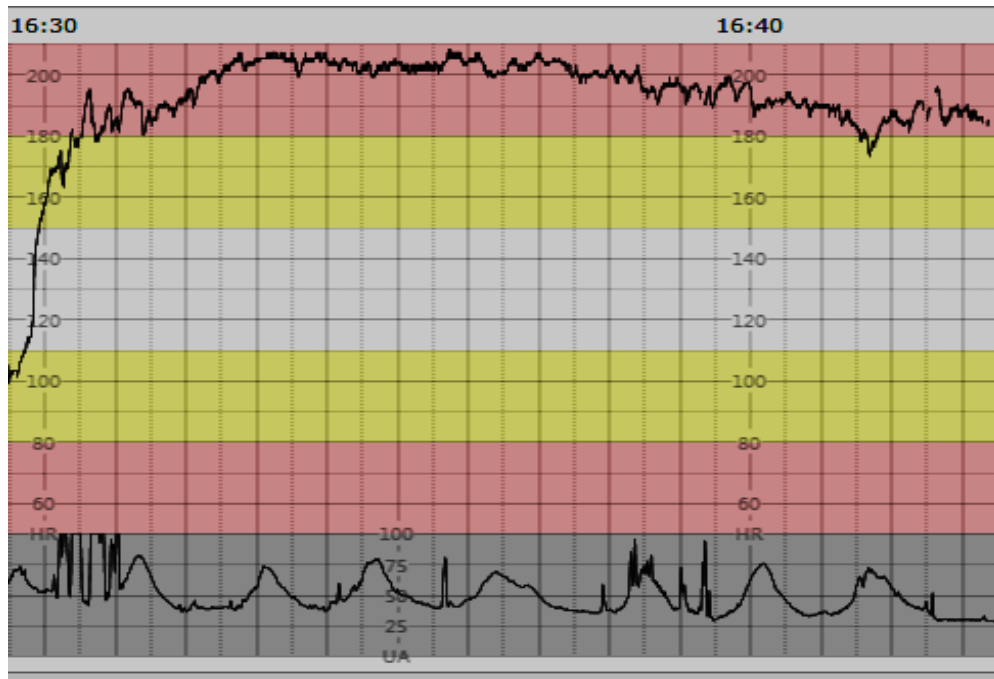
Identify by the location of the point of auscultation the fetal lie, presentation and position



Task 17

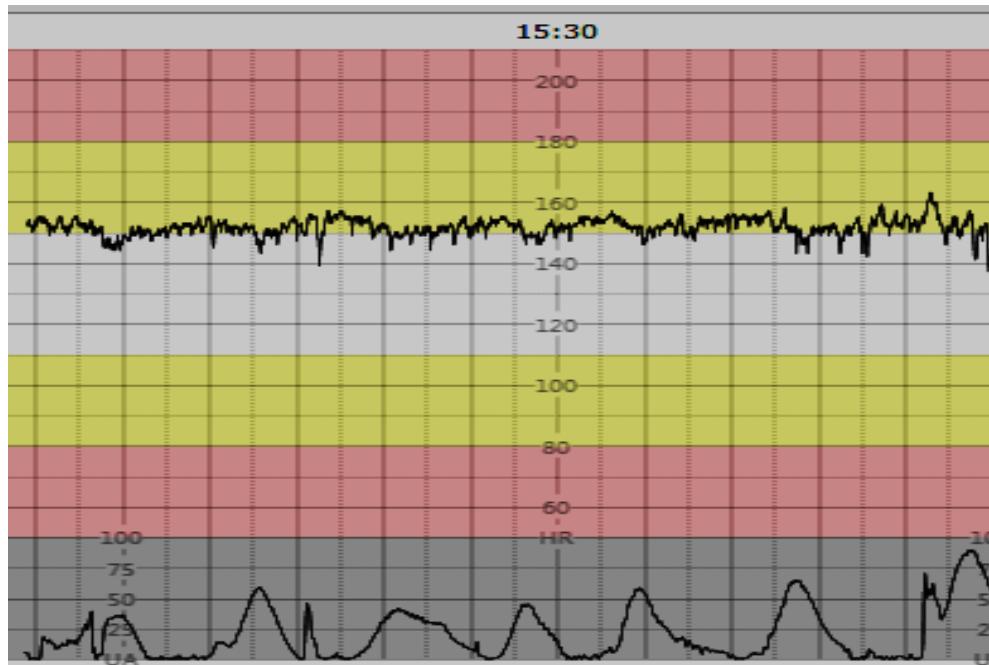
ONMedU, Department of Obstetrics and Gynecology. Practical lesson No. 5. "External obstetric examination, determination and evaluation of the topography of the fetus in the uterus. Auscultation of the fetus. CTG"

Estimate this CTG



Task 18

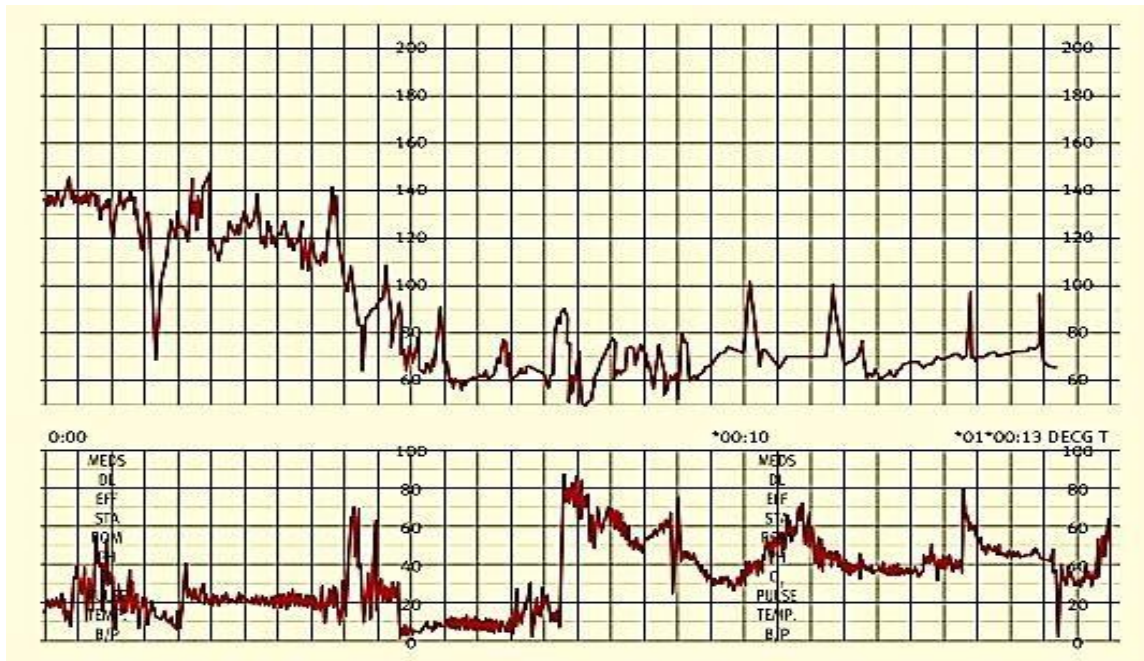
Estimate this CTG



Task 19

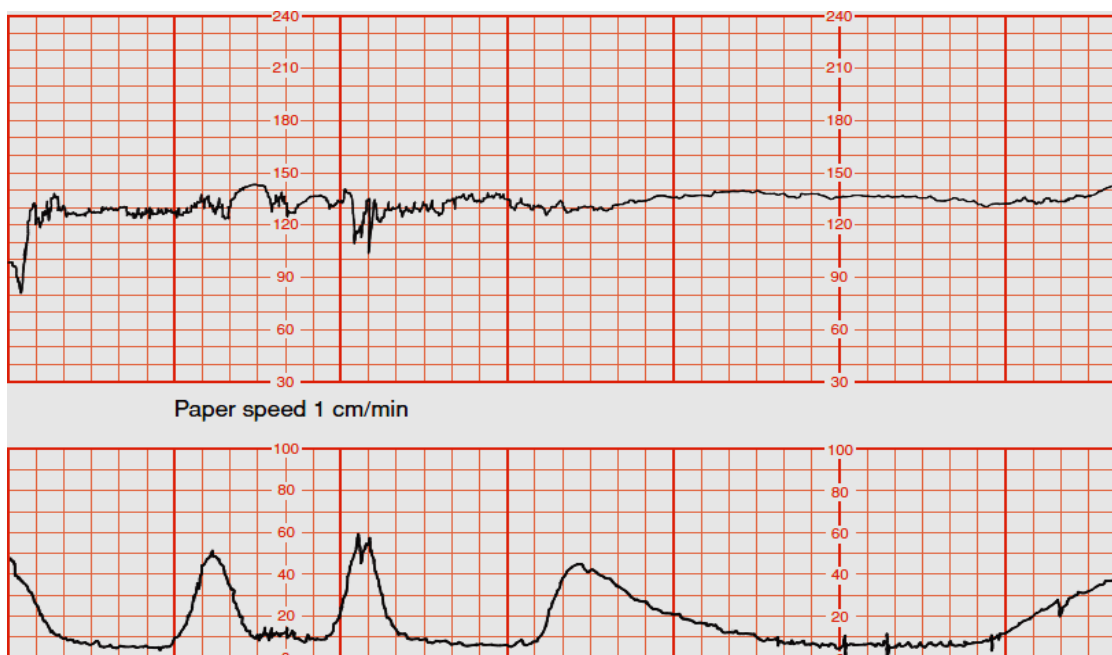
Estimate this CTG

ONMedU, Department of Obstetrics and Gynecology. Practical lesson No. 5. "External obstetric examination, determination and evaluation of the topography of the fetus in the uterus. Auscultation of the fetus. CTG"



Task 20

Estimate this CTG

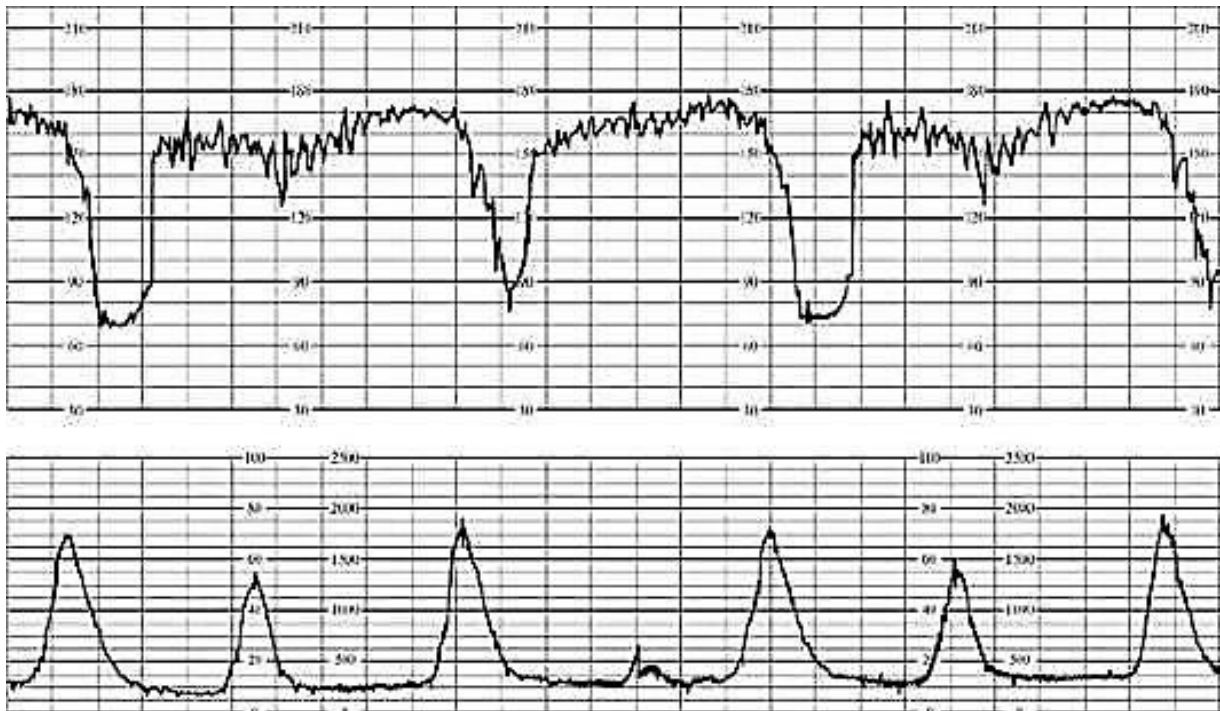


Task 21

Methodical recommendations of a practical lesson, EPP "Medicine", 5th year, Faculty international. Elective discipline " Simulation training in obstetrics and gynecology".

ONMedU, Department of Obstetrics and Gynecology. Practical lesson No. 5. "External obstetric examination, determination and evaluation of the topography of the fetus in the uterus. Auscultation of the fetus. CTG"

Estimate this CTG



III. FORMATION OF PROFESSIONAL SKILLS (mastering skills, conducting curation, determining the treatment regimen, conducting a laboratory study, etc.).

3.1. Content of tasks (tasks, clinical situations, etc.).

Interactive task:

Students of the group are divided into 2 subgroups of 3-4 people each.

Tasks for the students of Subgroup I:

- to perform obstetric grips (Leopold`s maneuvers)
- to define the fetal lie, presentation and position
- to identify by the location of the point of auscultation the fetal lie, presentation and position
- to estimate CTG

Task for the students of Subgroup II:

- to assess answers of the students of Subgroup I and make adjustments.

Clinical situation A

A primigravida has regular uterine contractions for 20 hours. The gestation age is 40 weeks. Labor pains last for 20 seconds every 7-8 minutes. Abdominal circumference is 100 cm, fundal height is 40 cm. Fetal heart rate is 128/min., auscultated on the left below the navel, closer to the linea nigra. Internal obstetric examination: cervical dilation is 6 cm, fetal head enters the pelvic inlet.

ONMedU, Department of Obstetrics and Gynecology. Practical lesson No. 5. "External obstetric examination, determination and evaluation of the topography of the fetus in the uterus. Auscultation of the fetus. CTG"

Define the fetal lie, presentation and position.
Calculate the estimated fetal weight.

Clinical situation B

A 27 y.o. primipara is in labor. The gestational age is 38 weeks. Uterine contractions take place every 1.5-2 minutes, last 45-50 seconds. Uterine activity began 10 hours ago. Fetal heart rate is 114/min., auscultated on the right above the navel, closer to the midline of the abdomen. Internal obstetric examination: the cervix is 1 cm long, dense, cervical dilatation is 2 cm.

Define the fetal lie, presentation and position.

Clinical situation C

A 30-year-old multigravida has been in labor for 20 hours. The gestational age is 37-38 weeks. 2 hours ago the pushing stage began. Uterine contractions take place every 2-3 minutes, last around 30 seconds. Fetal heart rate is rhythmic, 85-90/min. Vaginal examination reveals complete cervical dilatation, the fetus is at +2 station (the fetal head is in the pelvic outlet).

Estimate the fetal condition.

Clinical situation D

A 18 y.o. parturient woman is in labor. The gestational age is 37 weeks. Uterine contractions take place every 3 minutes, last around 40 seconds. Uterine activity began 7 hours ago. Fetal heart rate is 157/min., auscultated on the right below the navel, closer to the lateral abdominal wall. Abdominal circumference is 100 cm, fundal height is 38 cm. Internal obstetric examination: cervical dilatation is 5 cm, the fetus is at -2 station (fetal head is pressed against the pelvic inlet). Amniotic sac is intact.

Define the fetal lie, presentation and position.

Calculate the estimated fetal weight.

Clinical situation E

A 37 y.o. primigravida woman has been having labor activity for 14 hours. Labor pains last for 20-25 seconds every 6-7 minutes. Gestation age is 39-40 weeks. Abdominal circumference is 100 cm, fundal height is 39 cm. The fetus heart rate is 142/min., auscultated on the left above the navel, closer to the midline of the abdomen. Internal obstetric examination revealed cervical effacement opening by 2 cm., the fetus is at -2 station (fetal head is pressed against the pelvic inlet). Fetal bladder is absent.

Define the fetal lie, presentation and position.

Calculate the estimated fetal weight.

Estimate the fetal condition.

Correct answers

ONMedU, Department of Obstetrics and Gynecology. Practical lesson No. 5. "External obstetric examination, determination and evaluation of the topography of the fetus in the uterus. Auscultation of the fetus. CTG"

Task 1 - Obstetric grips (Leopold`s maneuvers)

Task 2 - The first Leopold`s manoeuver (fundal grip); for determination of the uterine height and the gestational age

Task 3 - The second Leopold`s manoeuver (lateral grip); for determination of the fetal orientation in the uterus (fetal lie and fetal position)

Task 4 - The third Leopold`s manoeuver (first pelvic grip); for determination of the fetal presentation and mobility of presenting part

Task 5 - The fourth Leopold`s manoeuver (second pelvic grip); to determine fetal engagement

Task 6 - Longitudinal lie. Vertex presentation. Left occiput posterior (LOP) position.

Task 7 - Longitudinal lie. Vertex presentation. Left occiput anterior (LOA) position

Task 8 - Longitudinal lie. Vertex presentation. Right occiput anterior (ROA) position.

Task 9 - Longitudinal lie. Vertex presentation. Right occiput posterior (ROP) position.

Task 10 - Longitudinal lie. Complete breech presentation. Left sacrum posterior (LSP) position.

Task 11 - Longitudinal lie. Frank breech presentation. Right sacrum posterior (RSP) position.

Task 12 - Longitudinal lie. Single footling breech presentation. Left sacrum posterior (LSP) position.

Task 13 - Oblique lie, left posterior position

Task 14 - Transverse lie. Right acromiodorsoanterior position.

Task 15 - Longitudinal lie. Cephalic presentation. Right occiput anterior (ROA) position.

Task 16 - Longitudinal lie. Breech presentation. Left sacrum anterior (LSA) position.

Task 17 - Expressed tachycardia

Task 18 - Normal rhythm

Task 19 - Expressed bradycardia

Task 20 - Monotonic rhythm

Task 21 - Late decelerations

Clinical situation A - Longitudinal lie. Vertex presentation. Left occiput anterior (LOA) position; 4000 ± 200 g

Clinical situation B - Longitudinal lie. Breech presentation. Right sacrum anterior (RSA) position.

Clinical situation C - Fetal distress

Clinical situation D - Longitudinal lie. Vertex presentation. Right occiput posterior (ROP) position; 3800 ± 200 g

Clinical situation E - Longitudinal lie. Breech presentation. Left sacrum anterior (LSA) position; 3900 ± 200 g; normal rhythm (normal fetal condition)

3.2. Educational materials, recommendations (instructions) for performing tasks

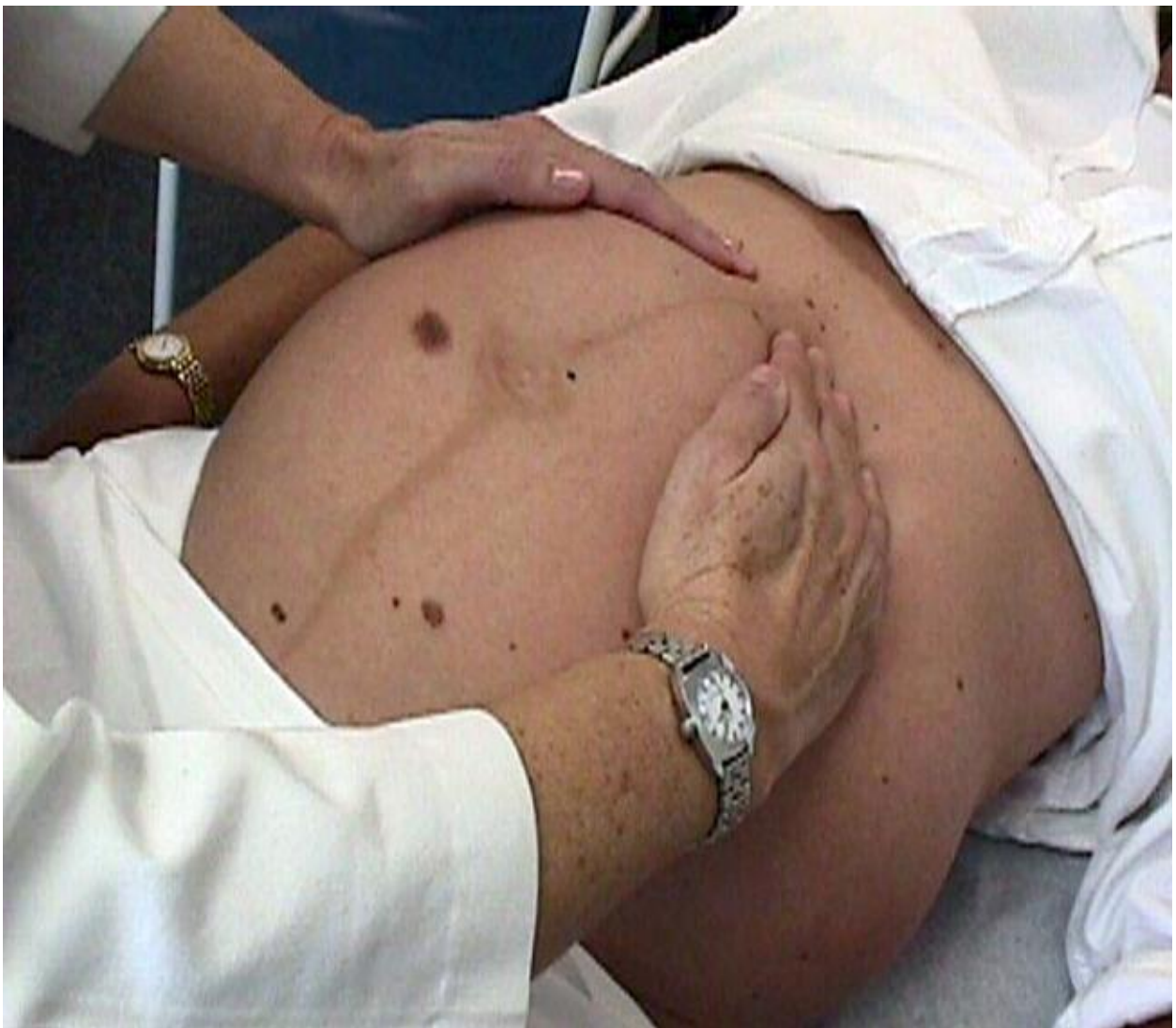External obstetric examination maneuvers (the Leopold's maneuvers)

The first Leopold's maneuver (fundal grip)

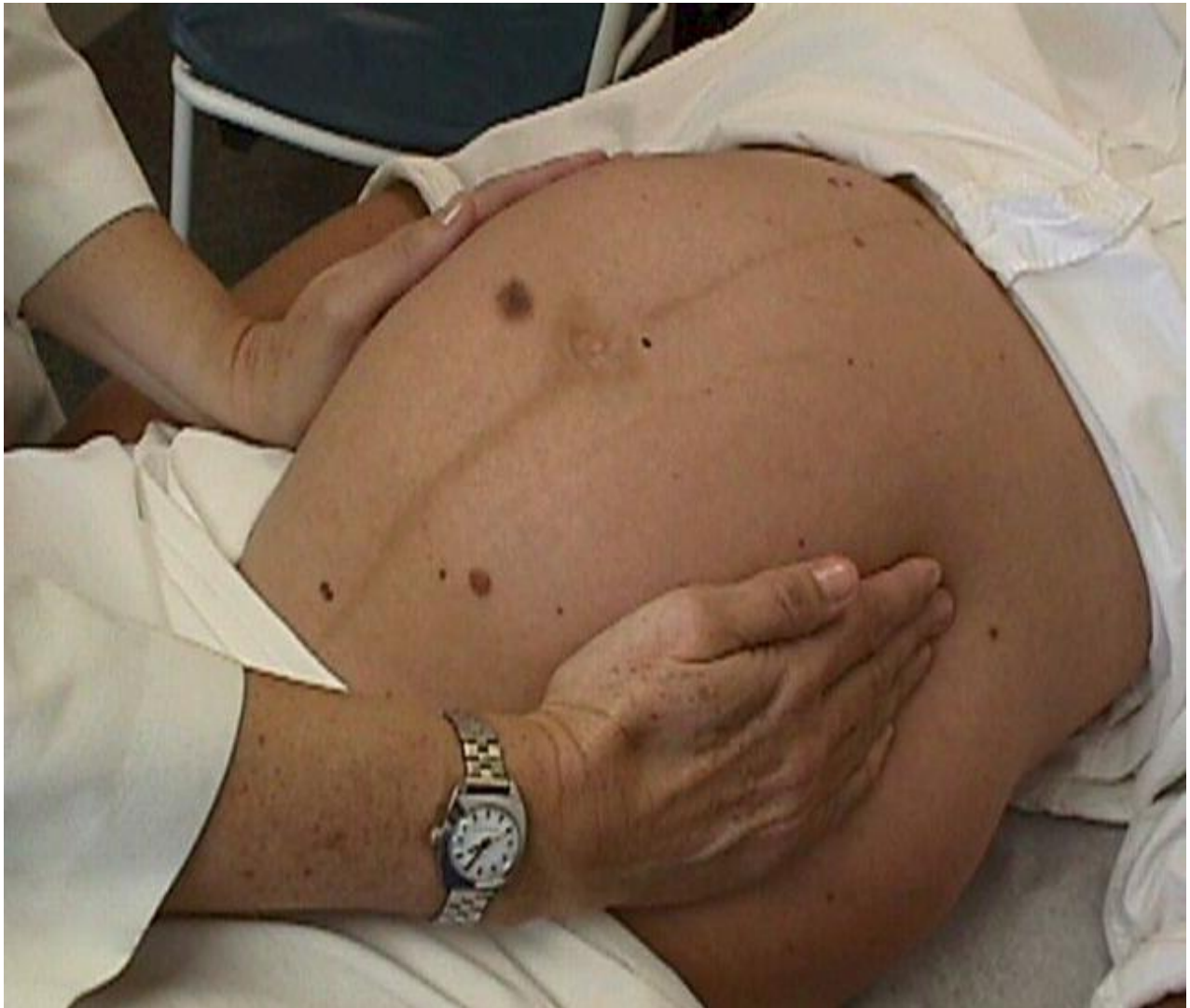The purpose is

- to detect the standing of the fundus of uterus for determination of the gestational age
- to detect the part of fetus located close to the fundus of uterus

The doctor stands on the right of the pregnant woman, facing her, puts both palms on the fundus of uterus, detects the height of its standing over the womb and the part of fetus located close to the fundus of uterus



The second Leopold`s manoeuvre (lateral grip)

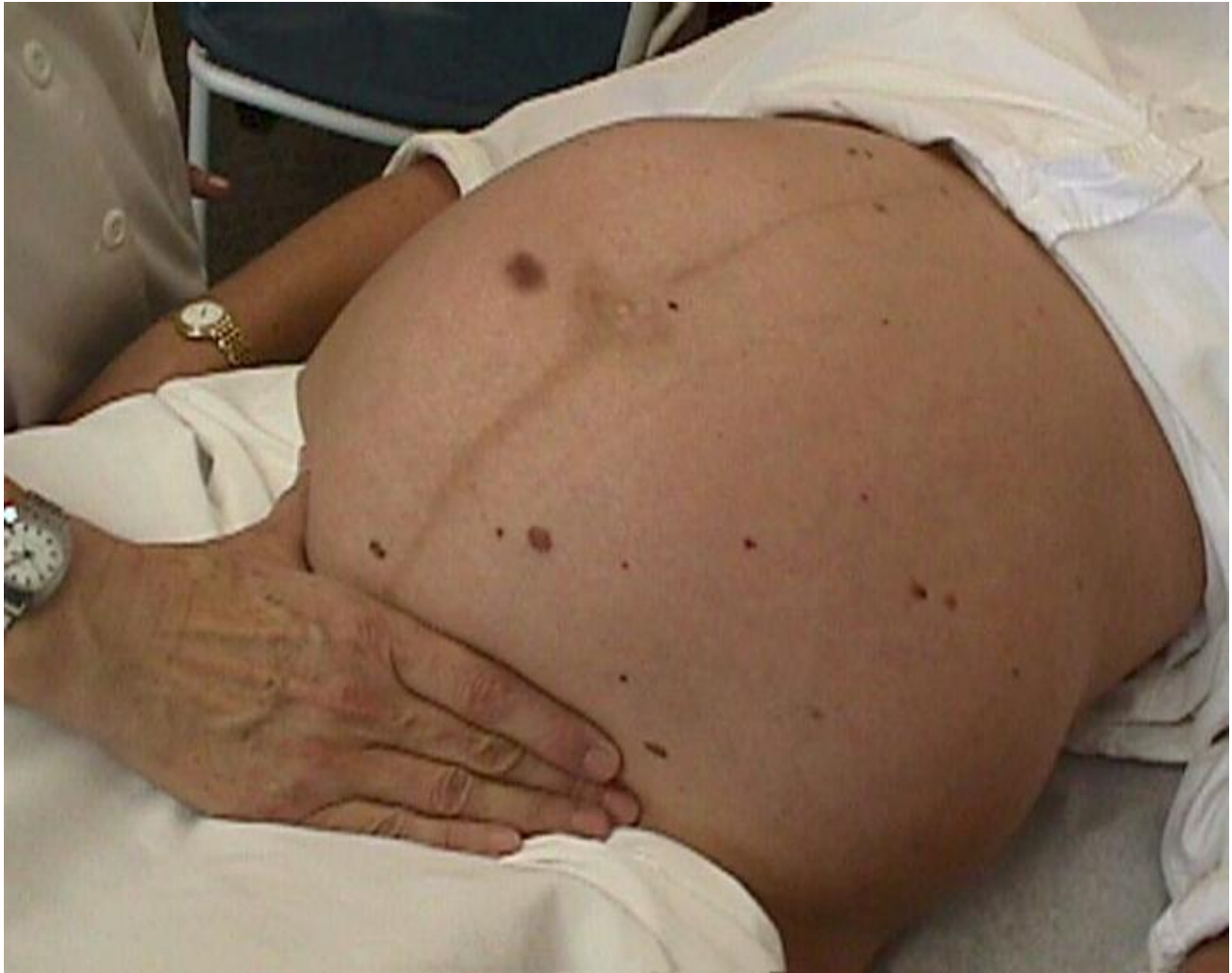

The purpose is

- to detect the fetal orientation in the uterus (fetal lie and fetal position)

Both palms are removed from the fundus of uterus and in turn palpate the parts of fetus directed to the lateral uterine walls. The back and small parts of fetus are found. At irregular position the head is adjacent to one of the lateral uterine walls.

The third Leopold`s manoeuver (first pelvic grip)

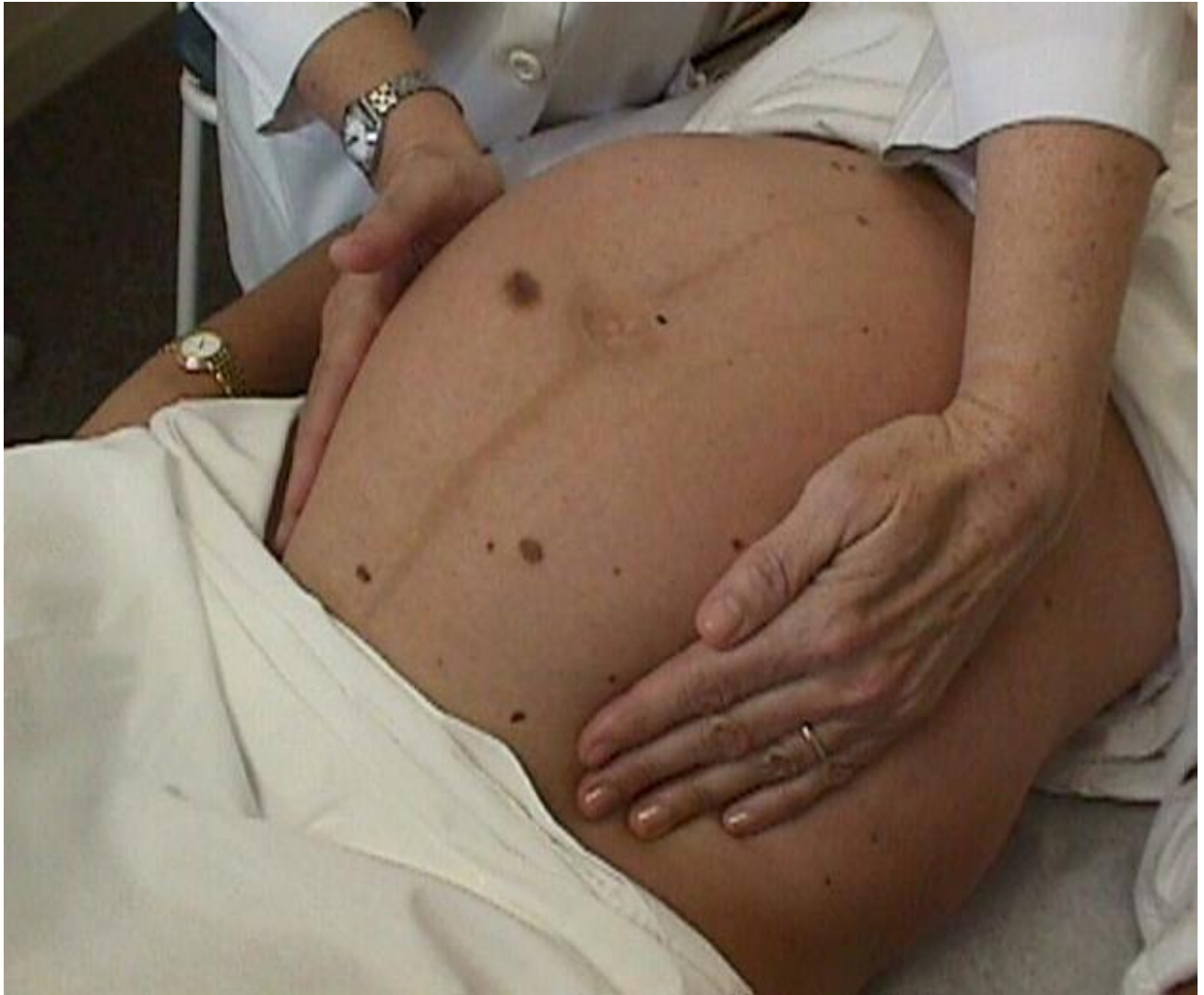

The purpose is

- to detect the character of the presenting part of fetus (presentation)

With one hand, usually the right one, which is lying slightly above the pubis, the presenting part of fetus is covered, after what cautious movements are made with this hand to the right and to the left. At cephalic presentation a dense, spheric part is detected, which has well-defined contours. If the fetal head is not yet fitted into the area of brim, it easily moves between the thumb and the rest of fingers. At pelvic presentation a voluminous soft part is detected, it is not spheric and can't move.

The fourth Leopold's manoeuvre (second pelvic grip)



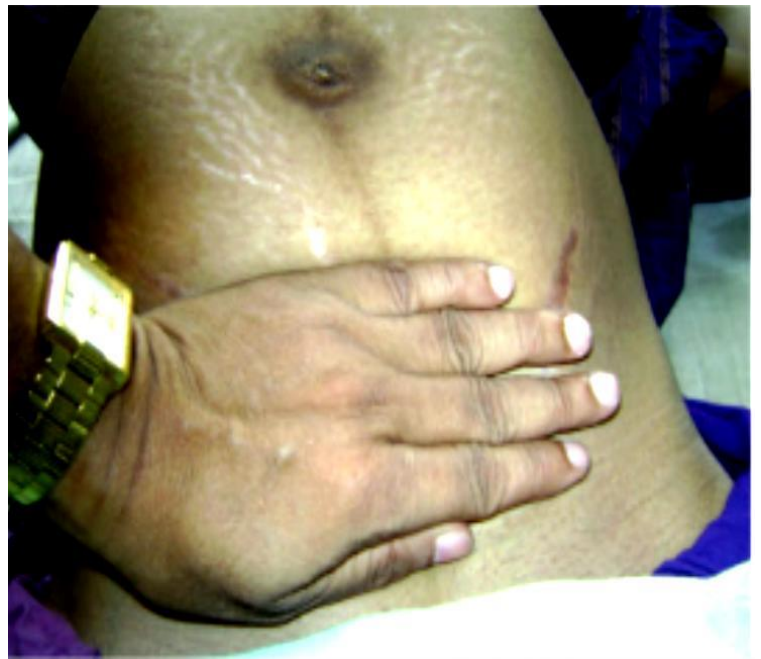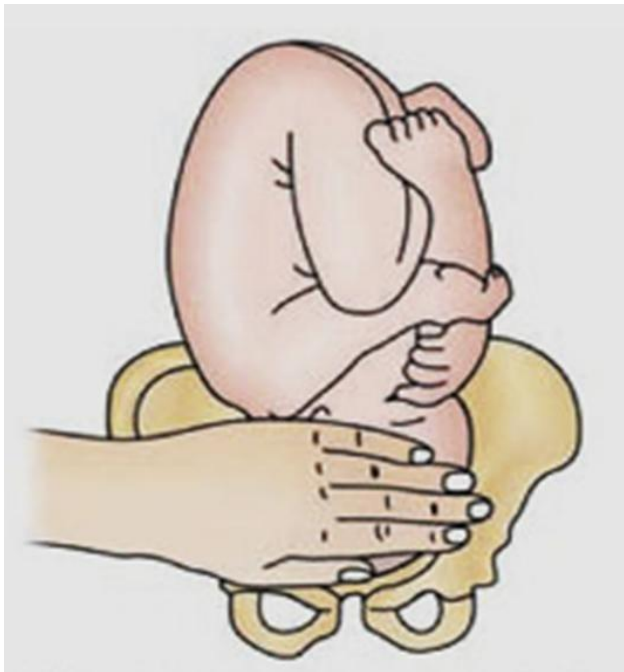
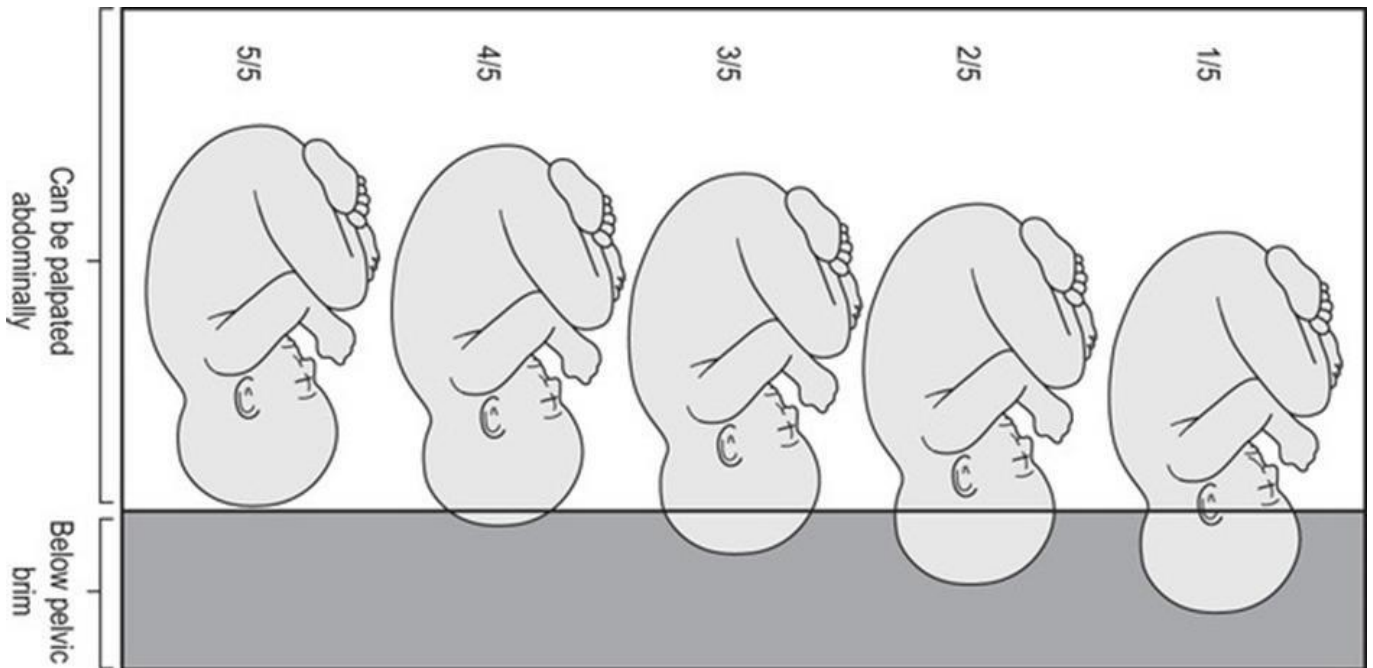
The purpose is

- to detect the level of presenting part standing (of the head in particular) relative to the area of brim and to the degree of its fitting.

The doctor stands on the left, with the face to the lower extremities of the pregnant woman, puts both hands with palms down on the lateral parts of the lower uterine segment and palpates accessible parts of the presenting part of fetus, trying to get with the fingertips between the presenting part and lateral parts of the area of brim

ONMedU, Department of Obstetrics and Gynecology. Practical lesson No. 5. "External obstetric examination, determination and evaluation of the topography of the fetus in the uterus. Auscultation of the fetus. CTG"

Descent of the fetal head determined by abdominal examination («fifth method»)



ONMedU, Department of Obstetrics and Gynecology. Practical lesson No. 5. "External obstetric examination, determination and evaluation of the topography of the fetus in the uterus. Auscultation of the fetus. CTG"

Engagement of the fetal head is measured in fifths, which is the amount of fetal head palpated above the brim of the pelvis.

5/5 The fetal head is five-fifths palpable; that is, the whole head can be palpated above the brim of the pelvis.

4/5 Four-fifths of the fetal head is palpable above the brim of the pelvis; one-fifth is therefore below the pelvic brim.

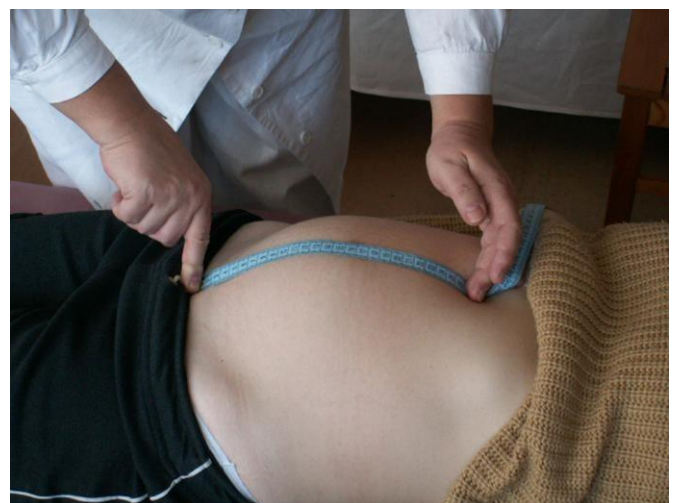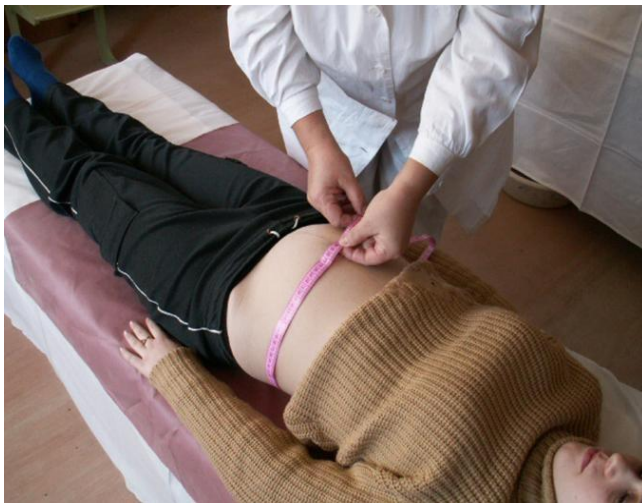3/5 Three-fifths is palpable above the brim of the pelvis and two-fifths below.

2/5 Two-fifths palpable above the brim of the pelvis and three-fifths below.

1/5 One-fifth of the fetal head is palpable above the pelvic brim and four-fifths are below; the head is described as 'deeply engaged'.

It is very important to be able to distinguish between 3/5 and 2/5 head palpable above the pelvic brim. If only 2/5 of the head is palpable, then engagement has taken place and the possibility of disproportion at the pelvic inlet can be ruled out.

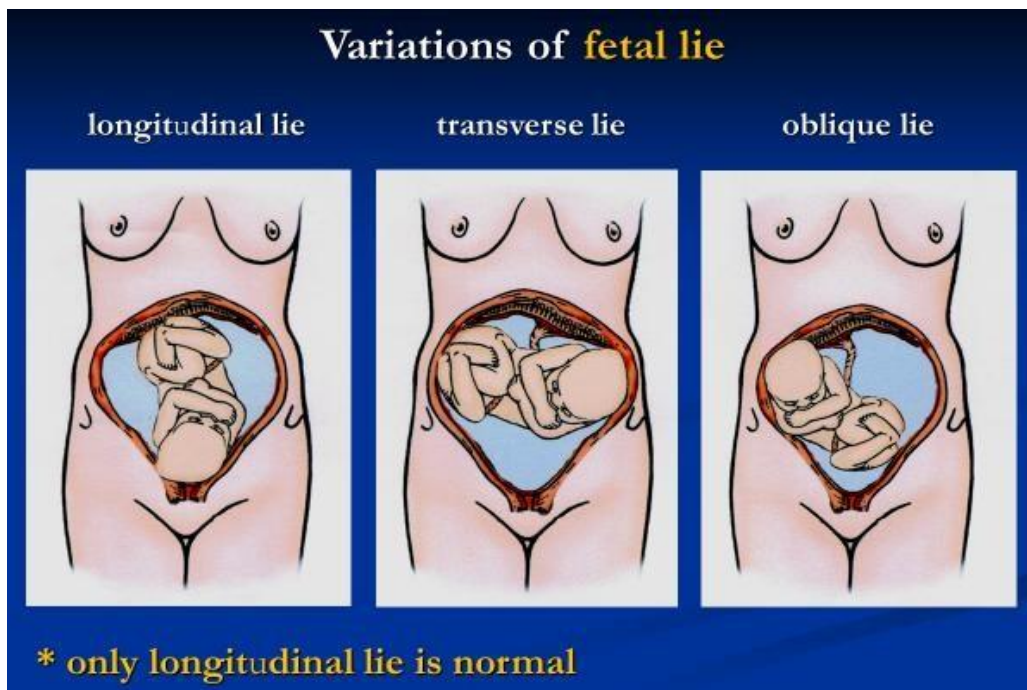
Determination of estimated fetal weight (FW)



FW is calculated by the following formula:

$$FW = AC \text{ (cm)} \times FH \text{ (cm)} \pm 200 \text{ g}$$

More reliably fetal weight is estimated by ultrasonic fetometry



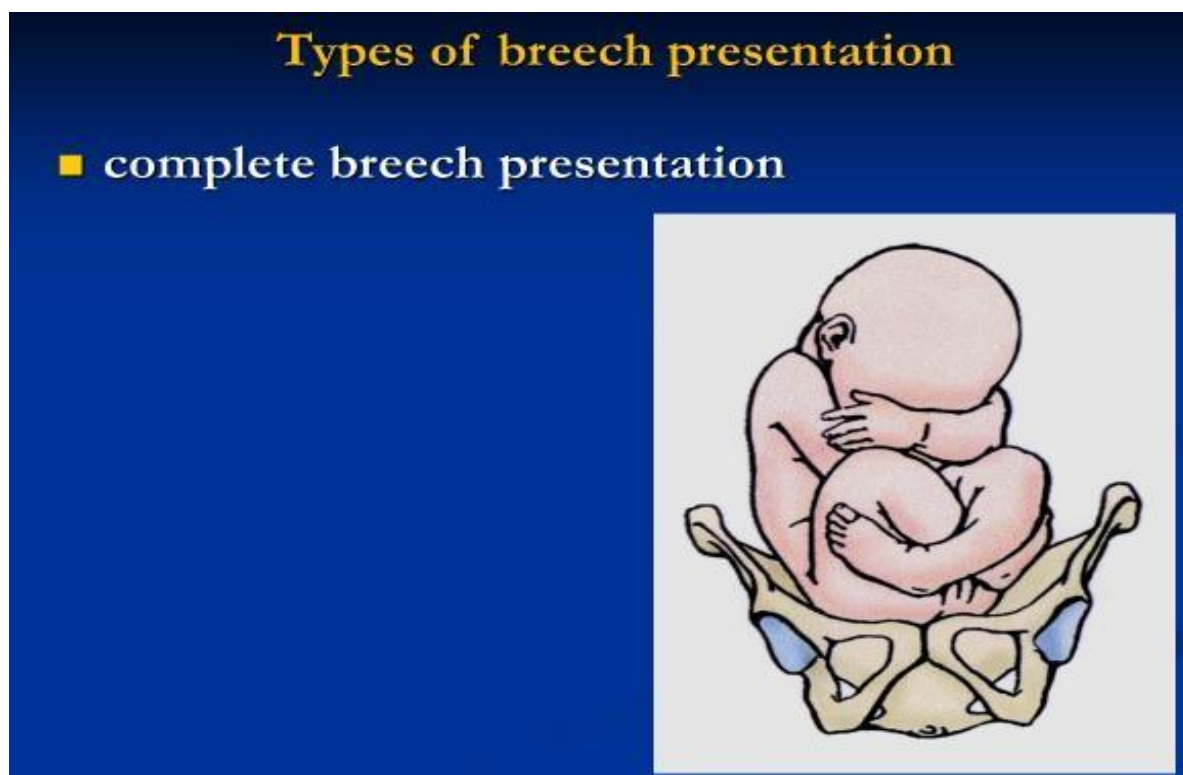
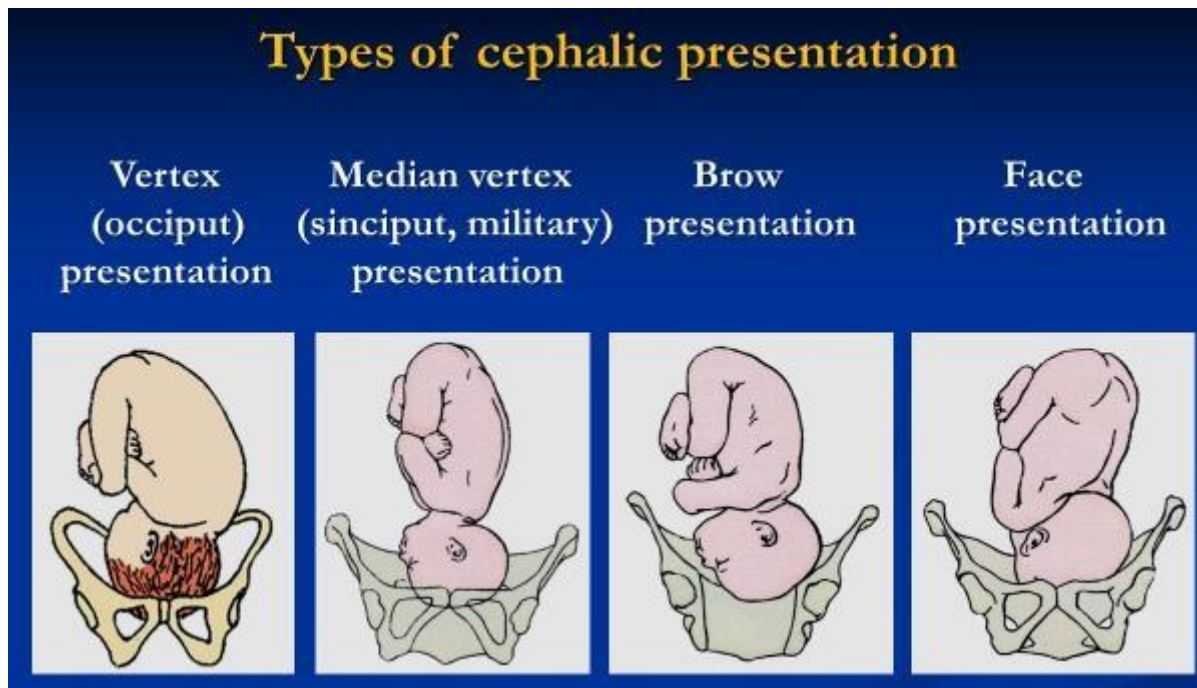
Fetal orientation

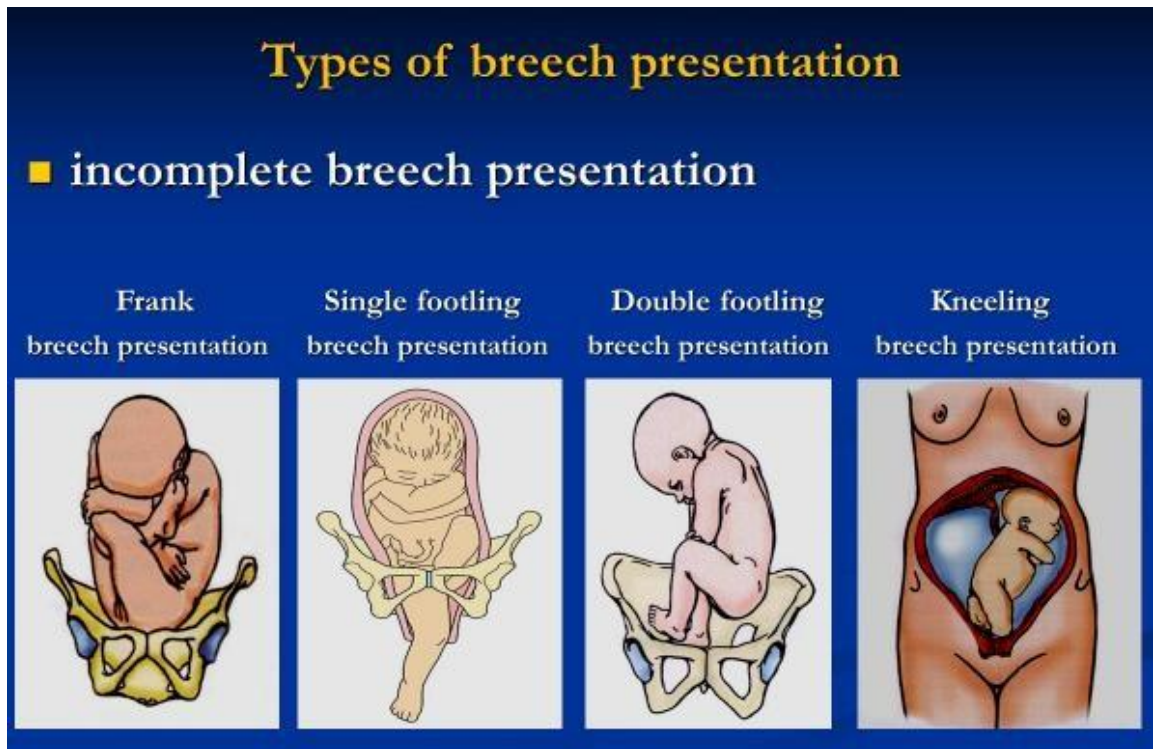
For the determining of the fetal orientation such key terms are used in Obstetrics:

- fetal lie
- fetal presentation
- fetal position

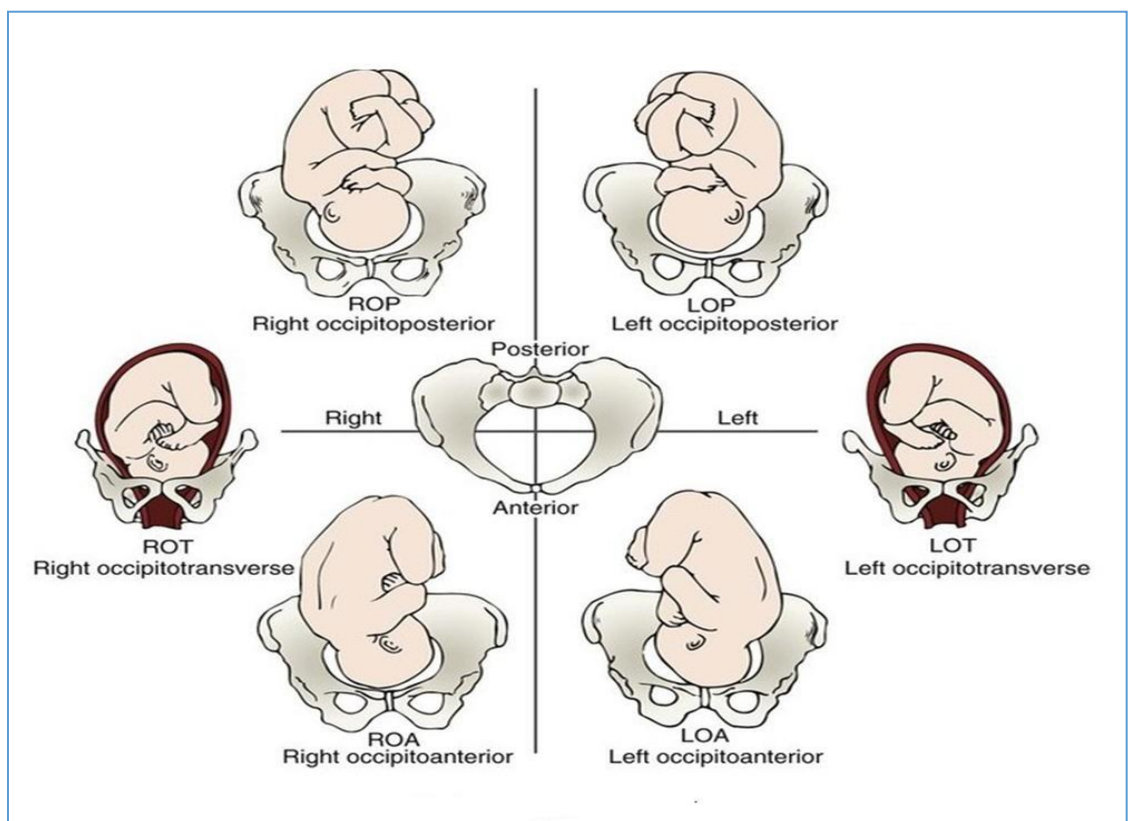
the fetal lie refers to the relationship between the longitudinal axis of the baby with respect to the longitudinal axis of the mother (longitudinal lie, transverse lie, oblique lie)

The fetal presentation refers to the part of the baby that is overlying the maternal pelvis.

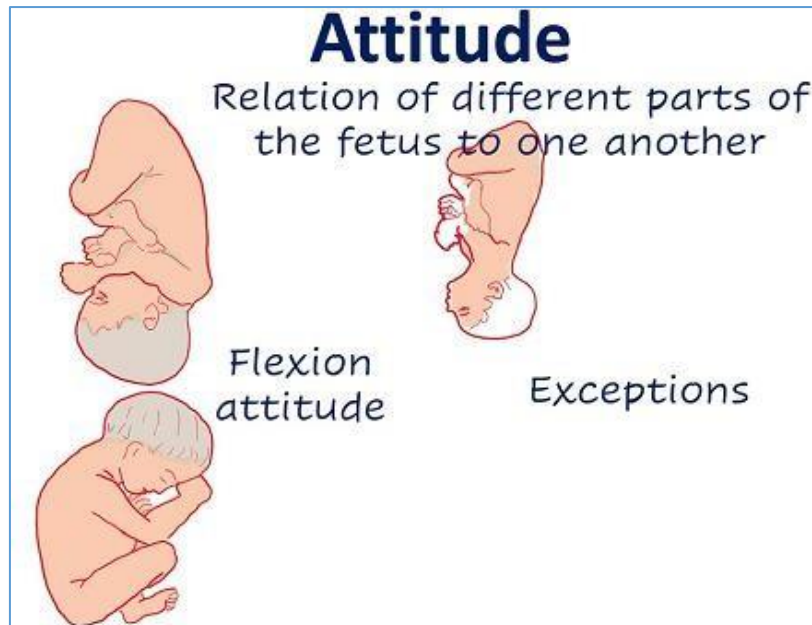




The fetal position is the orientation of the fetal presenting part to the right/left, anterior/posterior/transverse side of the maternal birth canal



The fetal attitude describes the position of the parts of the baby's body. The normal fetal attitude is commonly called the fetal position. The head is tucked down to the chest. The arms and legs are drawn in towards the center of the chest.



Fetal heart rate monitoring

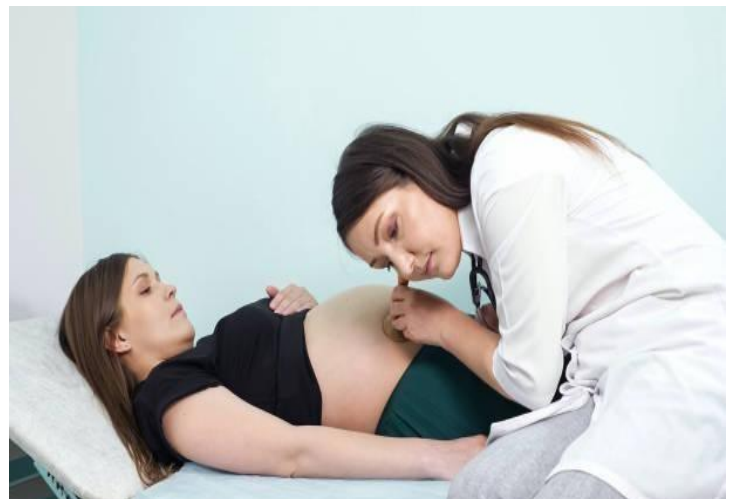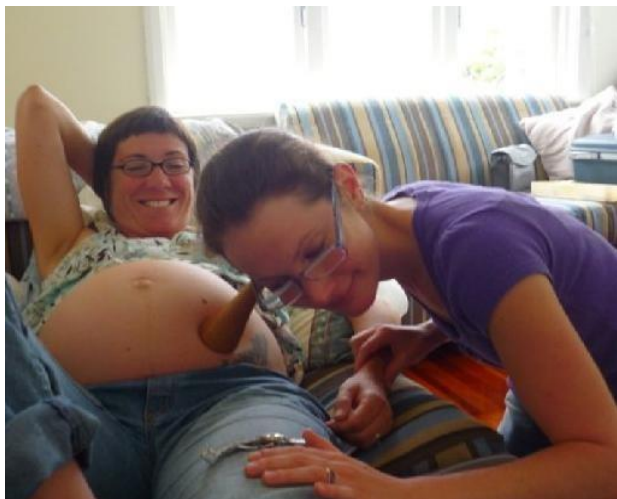Fetal heart rate monitoring is the measuring of the fetal heart rate during pregnancy and the labor by using a special instrument.

Types of fetal heart rate monitoring

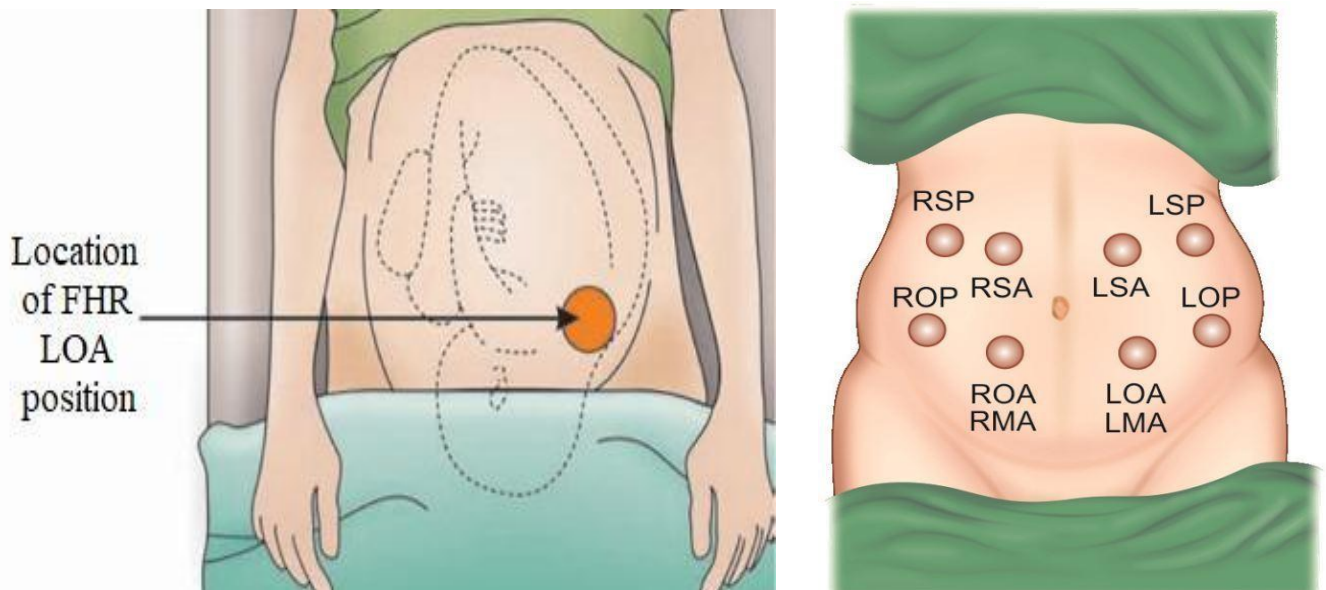
- Intermittent auscultation
- Electronic fetal monitoring

Intermittent auscultation

It is a method of listening to the fetal heartbeats for about 60 seconds by using a fetal stethoscope.

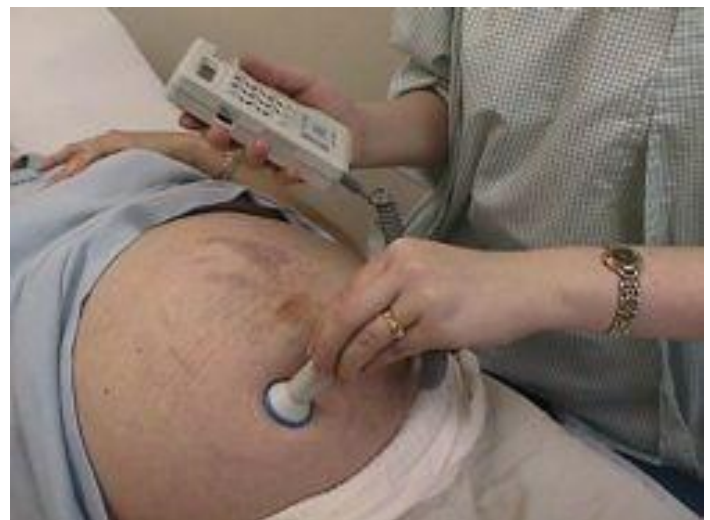
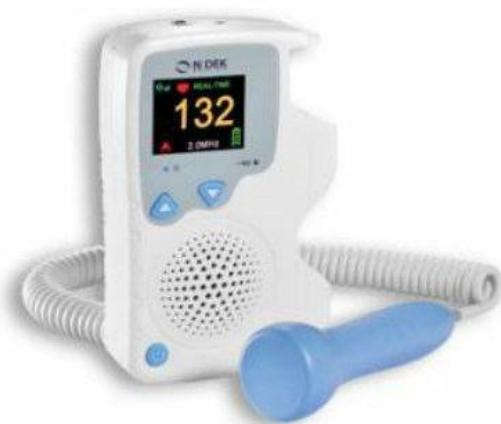
Sites for auscultation of fetal heart tones

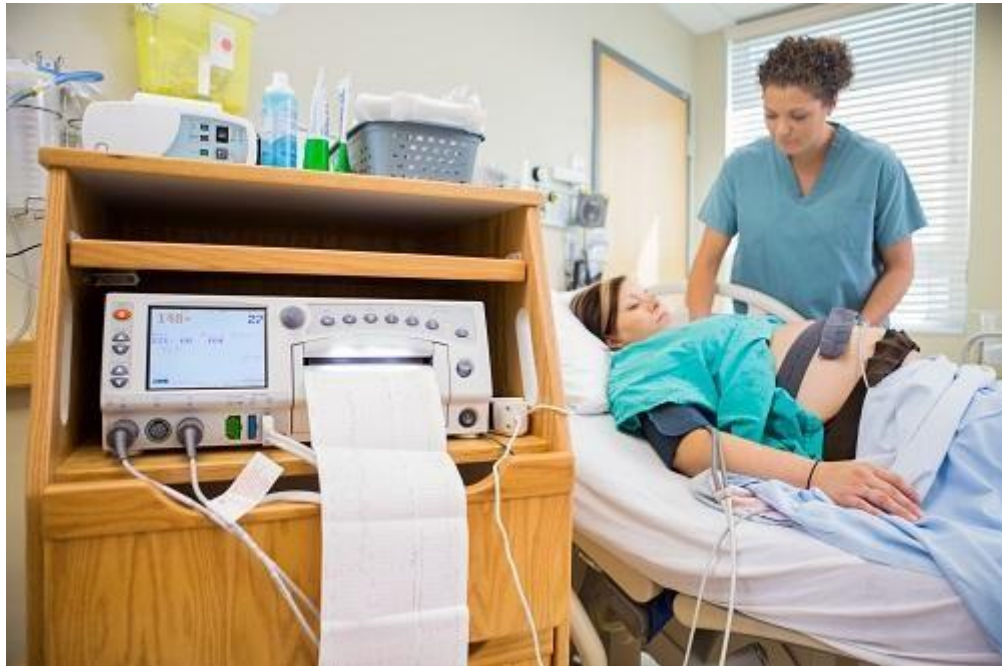

Doppler Fetal Monitor (Ultrasound Transducer)

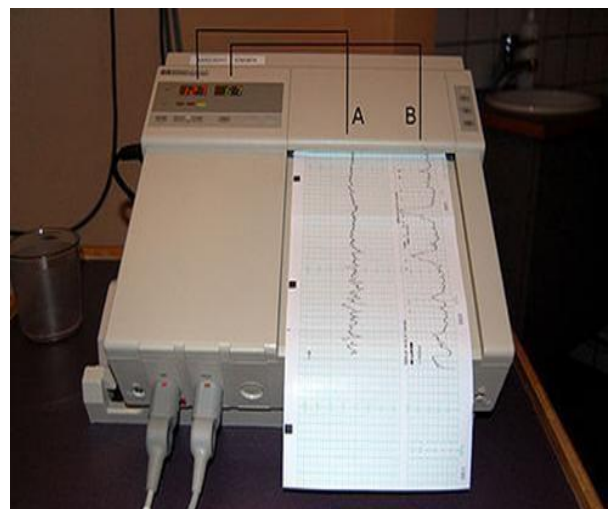
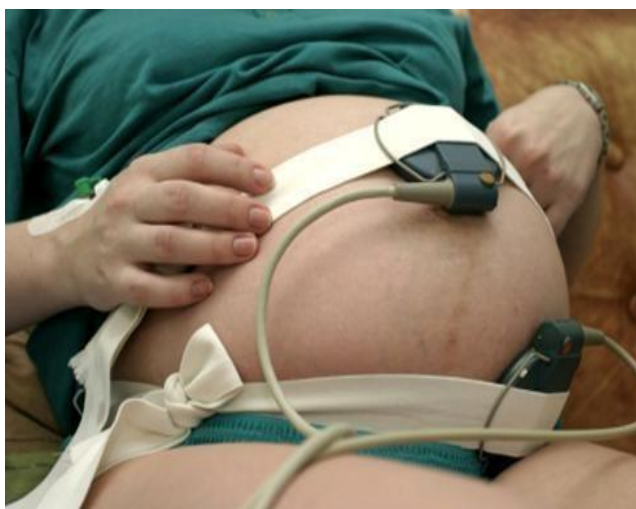A Doppler fetal monitor is a hand-held ultrasound transducer used to detect the fetal heartbeat for prenatal care. It uses the Doppler effect to provide an audible simulation of the heartbeat. Some models also display the heart rate in beats per minute (BPM). Use of this monitor is sometimes known as Doppler auscultation. Hand held Dopplers are pocket-sized, battery-operated devices that send out high-frequency ultrasound waves.



Electronic fetal monitoring



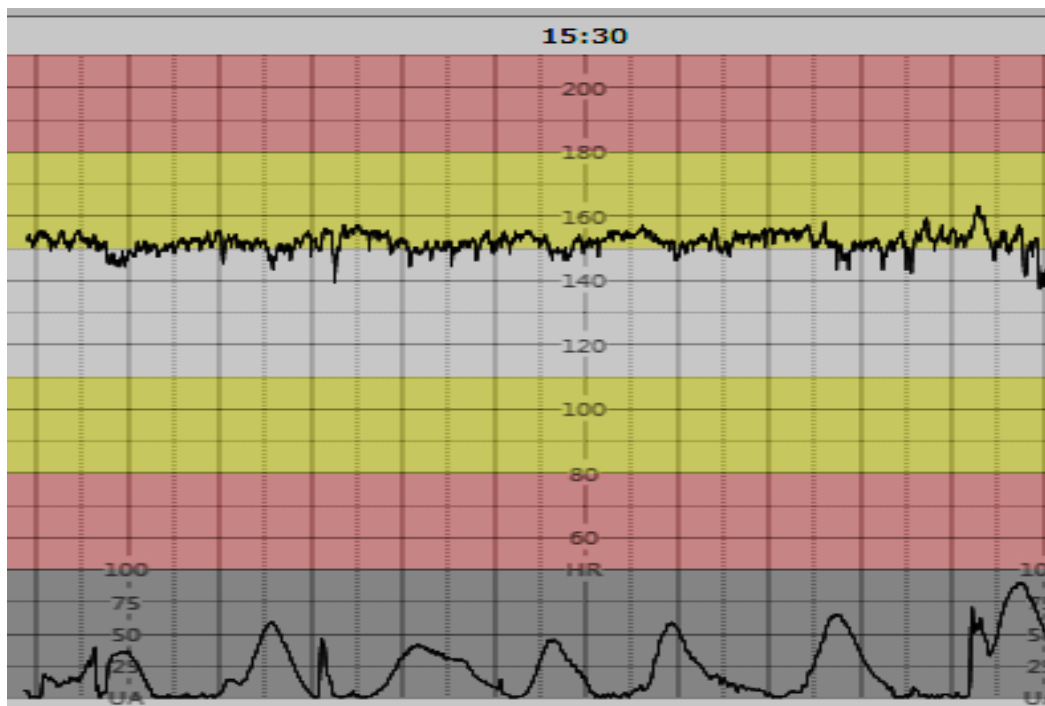
Electronic fetal monitoring, also called cardiotocography (CTG), is when the baby's heart rate is monitored with an ultrasound machine while the mother's contractions are monitored with a pressure sensor. Both of these sensors are linked to a recording machine, which shows a print-out or computer screen of the baby's heart rate and the mother's contractions shown together, often called EFM tracings. The monitor is assessing the baseline fetal heart rate and how it changes with contractions. It records any increases in the fetal heart rate (accelerations) and any decreases (decelerations), as well as the frequency and duration of the mother's uterine contractions



Cardiotocography interpretation begins with the assessment of four basic FHR features:

- Baseline
- Variability
- Accelerations
- Decelerations

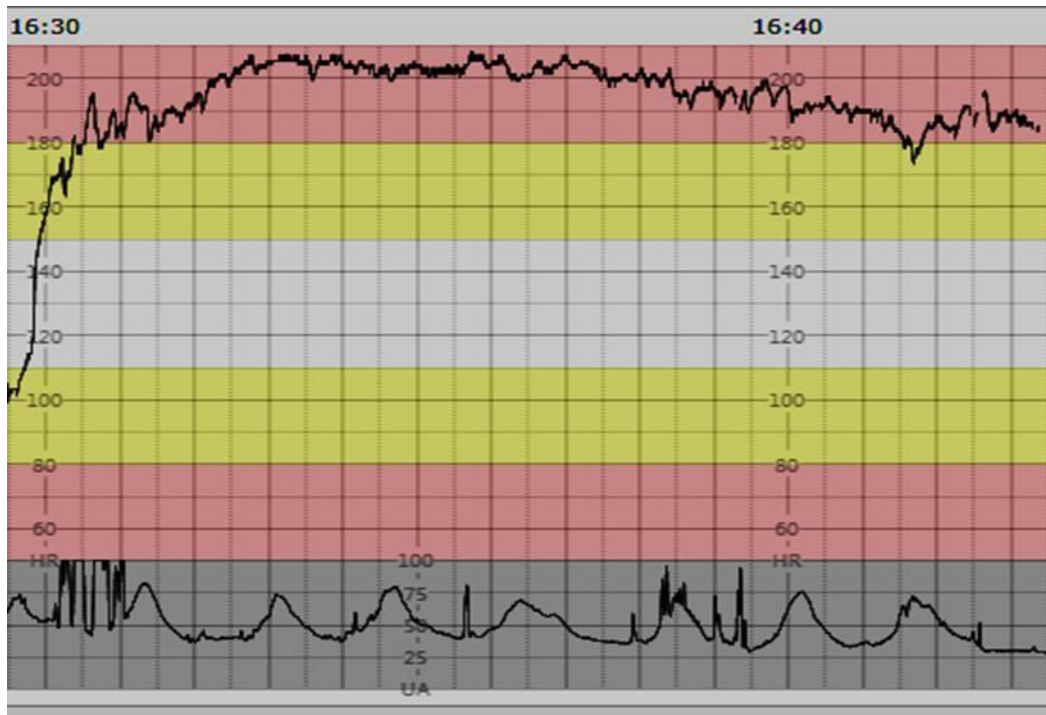
Baseline is defined as the mean level of the most horizontal and less oscillatory FHR segments. It is estimated in 10-minute periods and expressed in beats per minute (bpm). A fetus has a normal baseline if its value lies between 110 and 160 bpm.



Tachycardia refers to a baseline value above 160 bpm lasting more than 10 minutes.

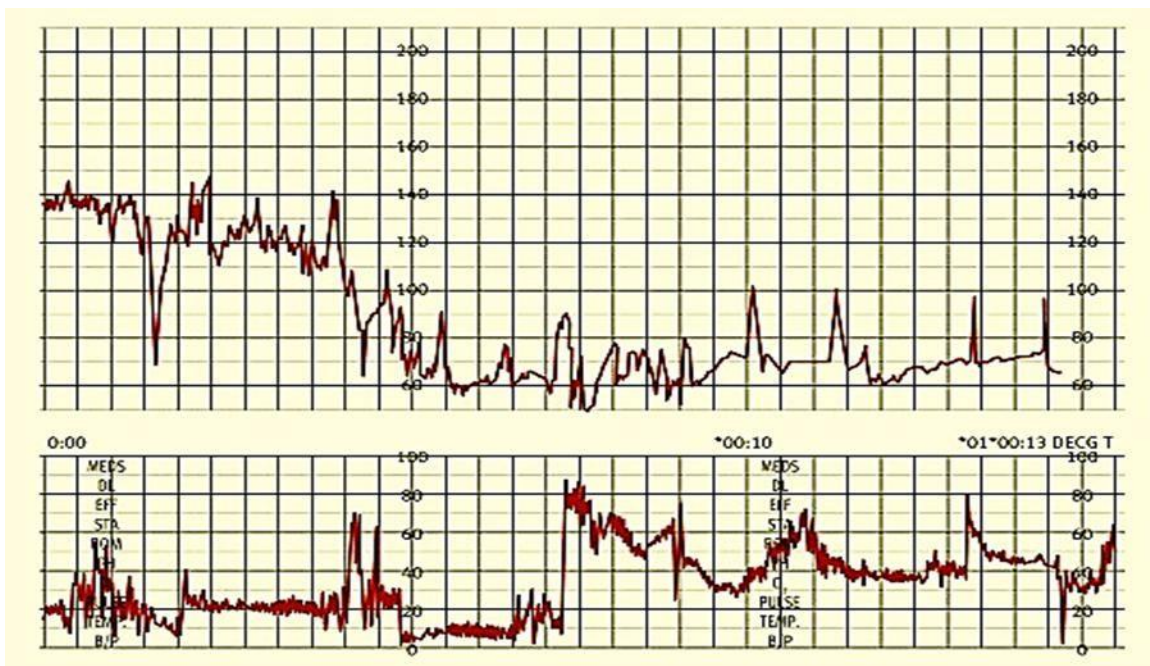
Maternal pyrexia is the most frequent cause, and it may be of extrauterine origin or associated with intrauterine infection. In the initial stages of a non-acute fetal hypoxemia, catecholamine secretion may also result in tachycardia. Other less frequent causes are the administration of beta-agonists, parasympathetic blockers, and fetal arrhythmias such as supraventricular tachycardia and atrial flutter.

Expressed Tachycardia refers to a baseline value ≥ 180 bpm.



Bradycardia is a baseline value below 110 bpm lasting more than 10 minutes. Maternal hypothermia, administration of beta-blockers, and fetal arrhythmias such as atrial-ventricular block are other less frequent causes

Expressed bradycardia refers to a baseline ≤ 100 bpm.

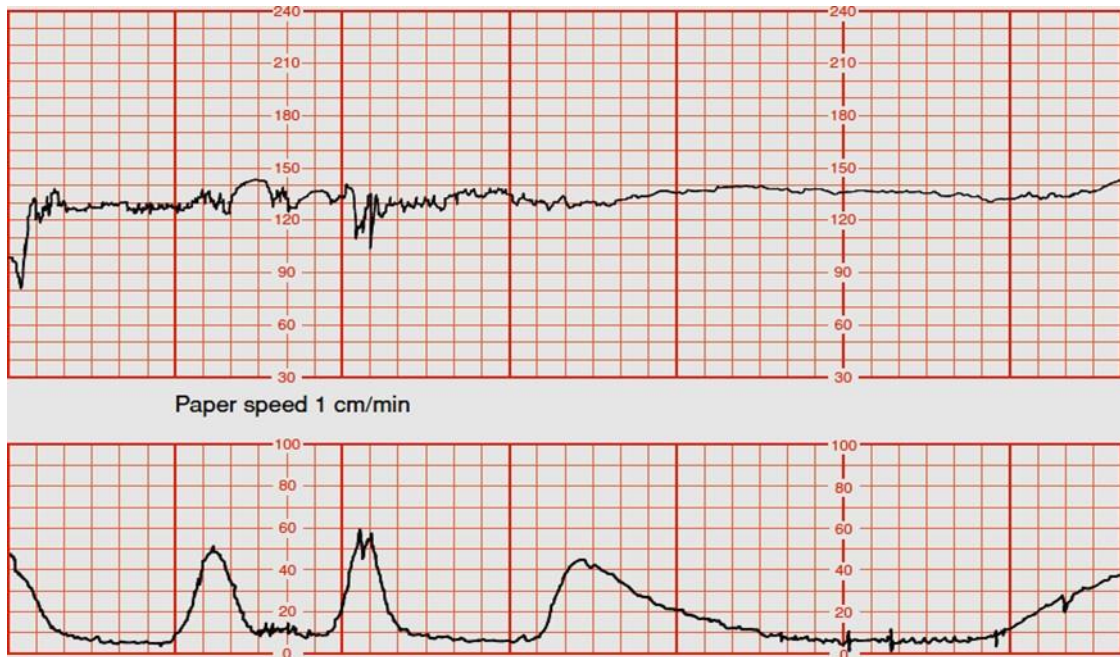


ONMedU, Department of Obstetrics and Gynecology. Practical lesson No. 5. "External obstetric examination, determination and evaluation of the topography of the fetus in the uterus. Auscultation of the fetus. CTG"

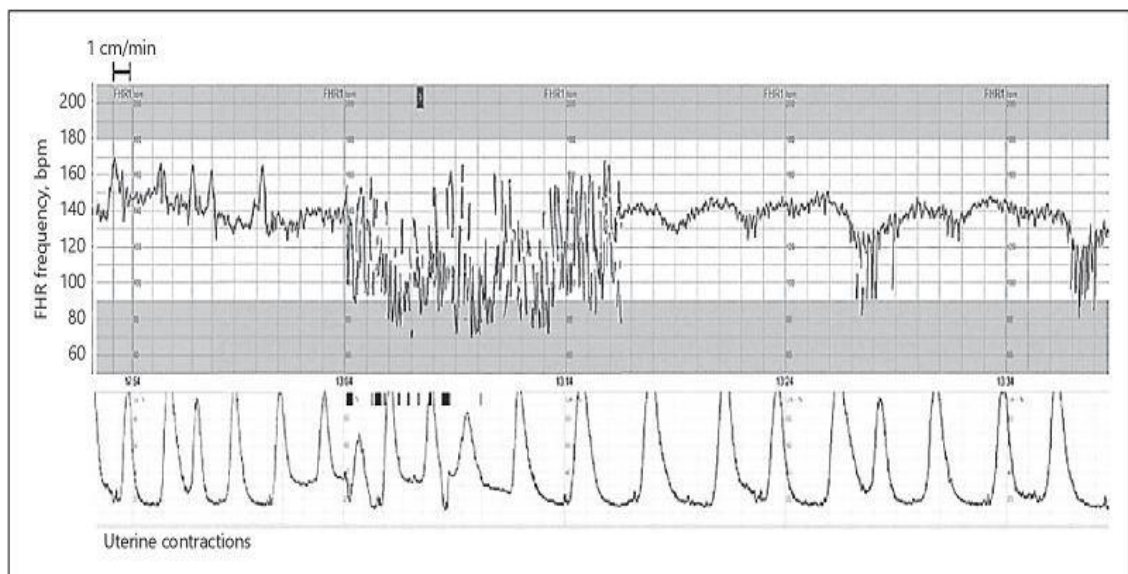
Variability corresponds to the fine oscillations in the FHR signal, and is visually evaluated as the average bandwidth amplitude in 1-minute segments.

Normal variability is defined as a bandwidth amplitude of 5–25 bpm.

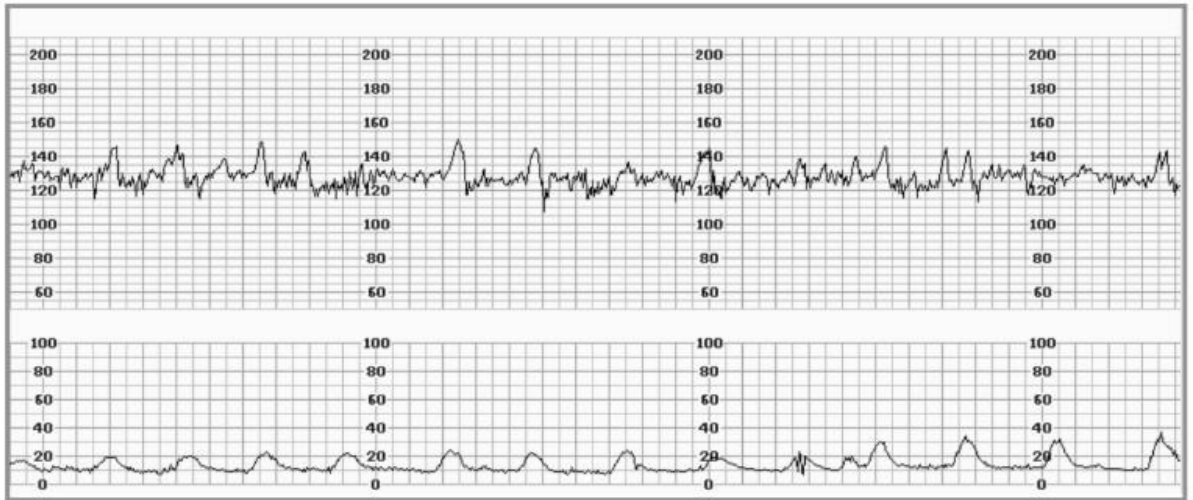
Reduced variability is a bandwidth amplitude below 5 bpm for more than 50 minutes in baseline segments, or for more than 3 minutes during decelerations.



Increased variability (saltatory pattern) corresponds to a bandwidth exceeding 25 bpm for more than 30 minutes.

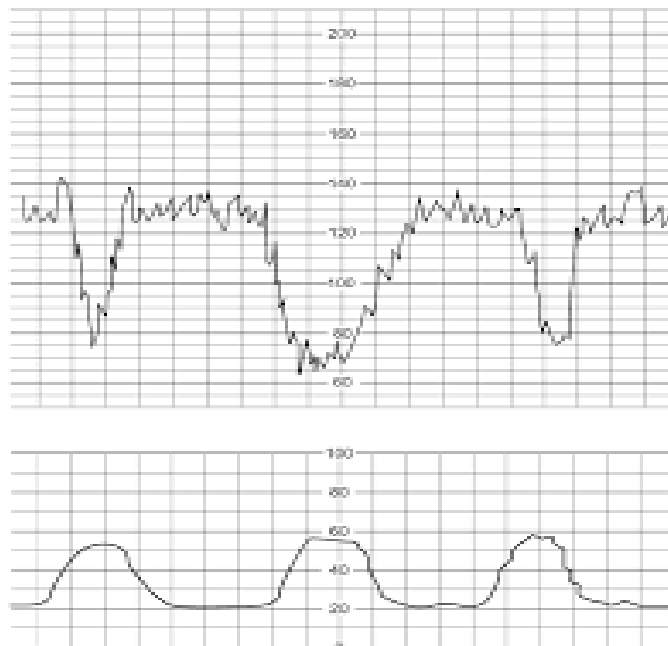


Accelerations are abrupt increases in the FHR above the baseline, of more than 15 bpm amplitude, and lasting more than 15 seconds, but less than 10 minutes.

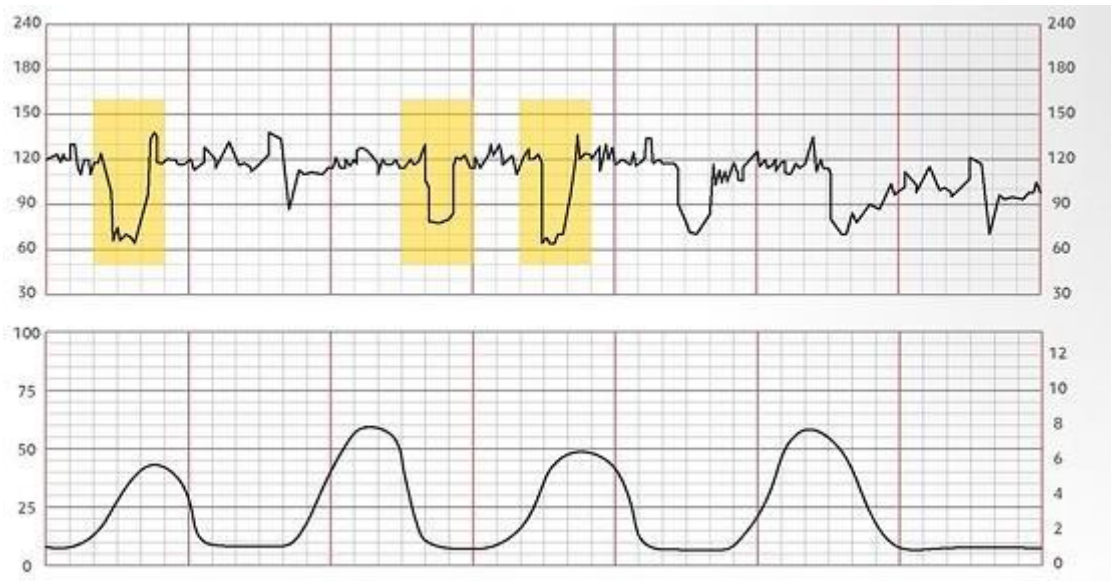

Decelerations are abrupt decreases in FHR below the baseline with an amplitude of more than 15 bpm and duration exceeding 15 seconds. Decelerations may be classified as early, variable, late or prolonged, according to their shape and duration. They are usually associated with uterine contractions, and therefore occur rarely in antepartum cardiotocography.

Early decelerations are shallow, short-lasting, with normal variability within the deceleration, and coincident with contractions. They are believed to be caused by fetal head compression and do not indicate fetal hypoxia.

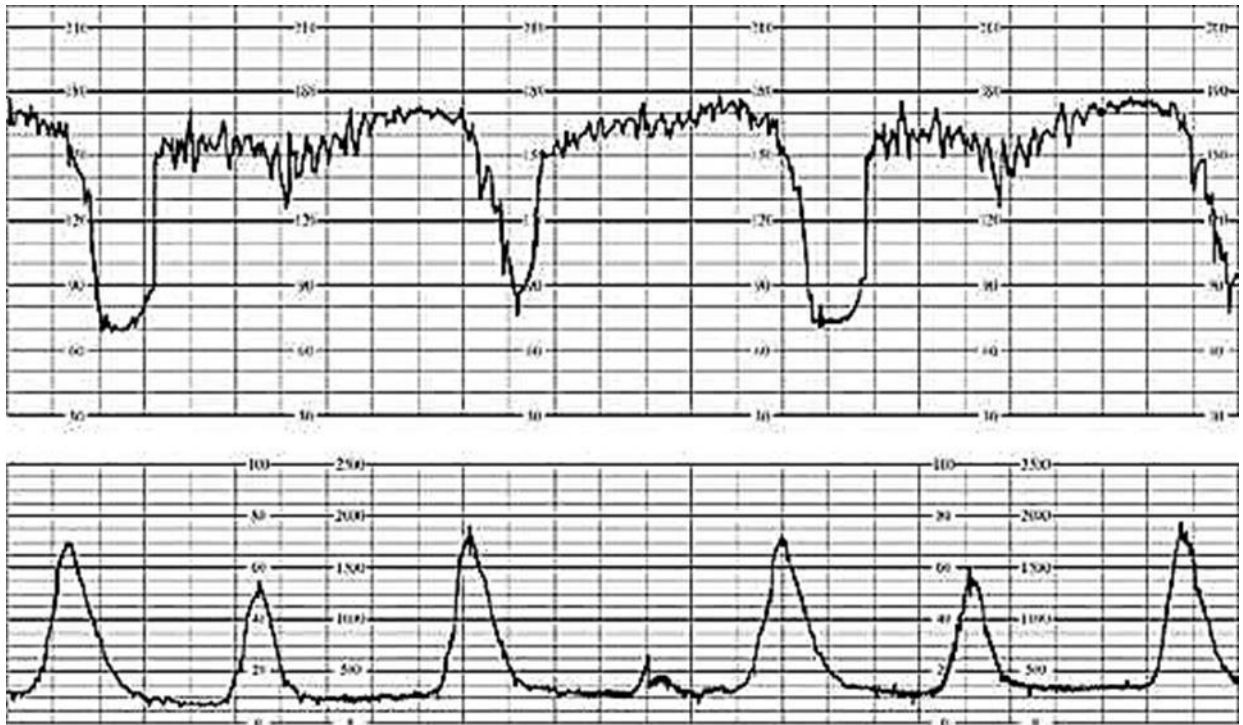


Variable decelerations (V-shaped) exhibit a rapid drop (onset to nadir in less than 30 seconds), good variability within the deceleration, rapid recovery to the baseline, varying in size, shape and relationship to uterine contractions. They translate a baroreceptor-mediated response to increased arterial pressure, as occurs with umbilical cord compression, and on their own are seldom associated with an important degree of fetal hypoxia.

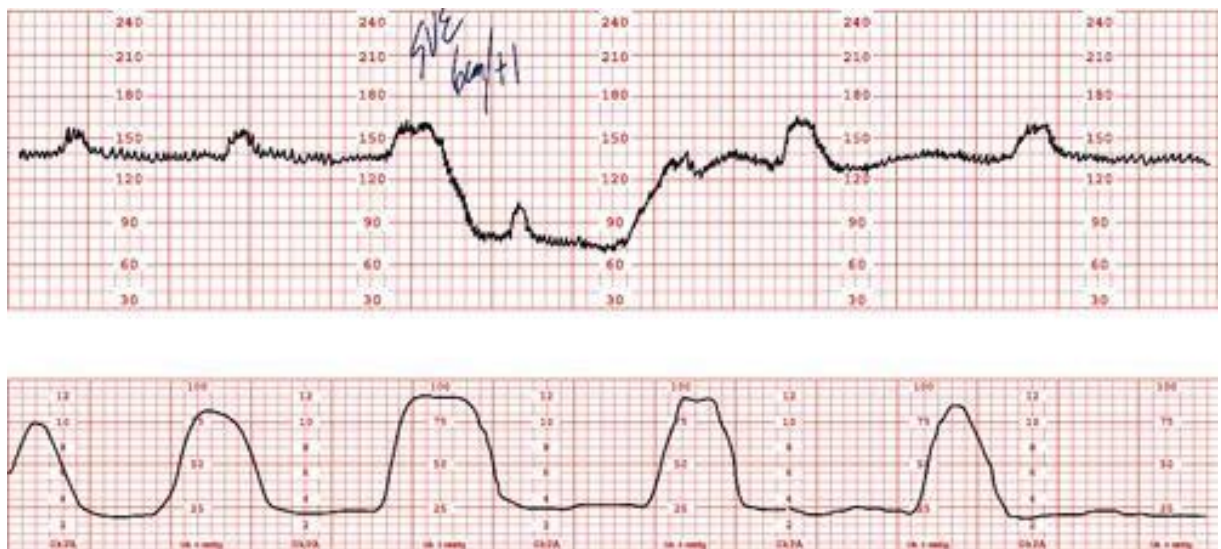

Late decelerations (U-shaped or with reduced variability) have a gradual onset, gradual return to the baseline (>30 seconds), or reduced variability within the deceleration. When contractions are adequately monitored, late decelerations start more than 20 seconds after the onset of a contraction, the nadir is after the acme, and return to the baseline occurs after the end of the contraction. They are indicative of a chemoreceptor-mediated response to fetal hypoxemia. In the presence of a tracing with no accelerations and reduced variability, the definition of late decelerations also includes those with an amplitude of 10–15 bpm.

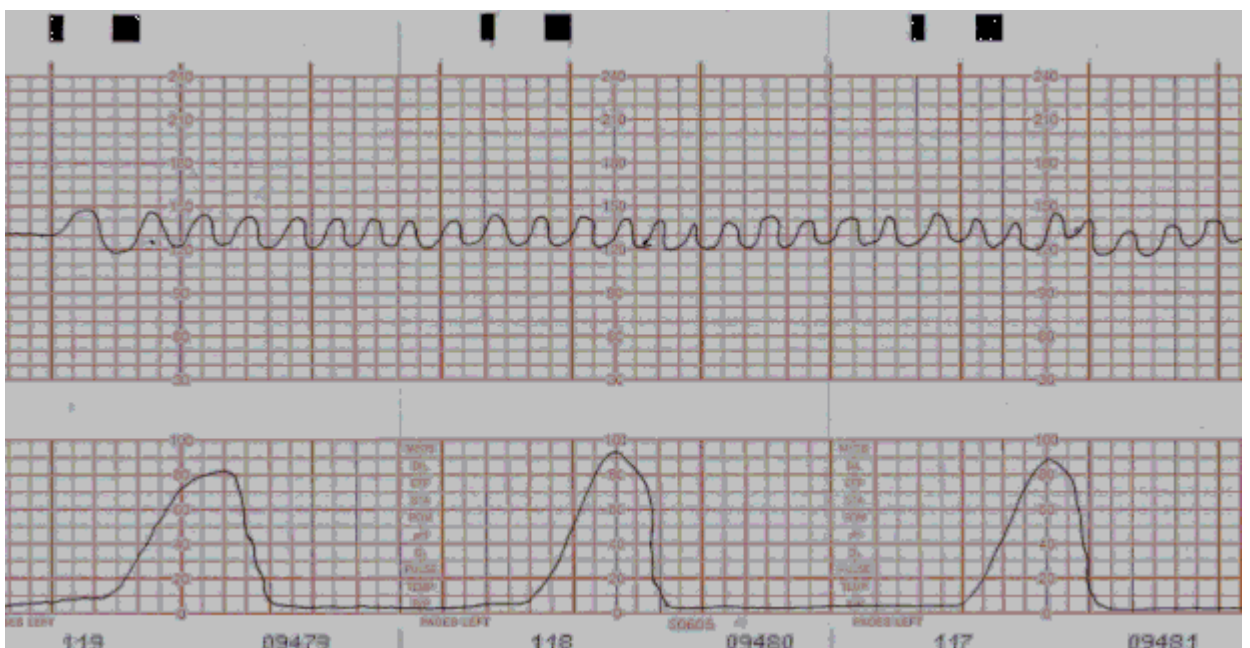
ONMedU, Department of Obstetrics and Gynecology. Practical lesson No. 5. "External obstetric examination, determination and evaluation of the topography of the fetus in the uterus. Auscultation of the fetus. CTG"



Prolonged decelerations last more than 3 minutes and are likely to include a chemoreceptor-mediated component and thus to indicate hypoxemia. Decelerations exceeding 5 minutes, with FHR maintained <80 bpm and reduced variability within the deceleration are usually associated with an episode of acute fetal hypoxia and require emergent intervention.



The **sinusoidal pattern** is a regular, smooth, undulating signal, resembling a sine wave, with an amplitude of 5–15 bpm, and a frequency of 3–5 cycles per minute. This pattern lasts more than 30 minutes. The pathophysiological basis for the sinusoidal pattern is incompletely understood, but it usually occurs in association with severe fetal anemia, as is found in anti-D alloimmunization, fetal–maternal hemorrhage, twin-to-twin transfusion syndrome and ruptured vasa previa. Less frequently, it has been described in cases of acute fetal hypoxia, infection, cardiac malformations, hydrocephalus and gastroschisis.



3.3. Requirements for the results of work.

- to perform
-
-

3.4. Control materials for the final stage of the class: tasks, tests, etc.

Task

A multigravida at 38 weeks of gestation arrived at the maternity ward after the beginning of labor activity. Pelvis size is 26-29-30-20 cm. Fetal heart rate is 136/min., auscultated on the left above the navel, closer to the linea nigra. Internal obstetric examination revealed cervical effacement, opening by 8 cm. Amniotic sac is intact. Fetal buttocks are pressed against the pelvic inlet.

Define the fetal lie, presentation and position.

ONMedU, Department of Obstetrics and Gynecology. Practical lesson No. 5. "External obstetric examination, determination and evaluation of the topography of the fetus in the uterus. Auscultation of the fetus. CTG"

Correct answer:

Longitudinal lie. Breech presentation. Left sacrum anterior (LSA) position.

IV. SUMMING UP

Current control: oral examination, testing, assessment of practical skills, solving situational clinical problems, assessment of activity in the classroom.

Criteria for current assessment on the practical lesson:

1	The student is fluent in the material, takes an active part in the discussion and solution of situational clinical problems, confidently demonstrates practical skills during the examination of a pregnant and interpretation of clinical, laboratory and instrumental studies, expresses his opinion on the topic, demonstrates clinical thinking.
2	The student is well versed in the material, participates in the discussion and solution of situational clinical problems, demonstrates practical skills during the examination of a pregnant and interpretation of clinical, laboratory and instrumental studies with some errors, expresses his opinion on the topic, demonstrates clinical thinking.
3	The student isn't well versed in material, insecurely participates in the discussion and solution of a situational clinical problem, demonstrates practical skills during the examination of a pregnant and interpretation of clinical, laboratory and instrumental studies with significant errors.
4	The student isn't versed in material at all, does not participate in the discussion and solution of the situational clinical problem, does not demonstrate practical skills during the examination of a pregnant and the interpretation of clinical, laboratory and instrumental studies.

RECOMMENDED LITERATURE

Basic:

1. Zaporozhan V.M., Mishchenko V.P. Obstetrics and gynaecology in 2 Books : Book 1 : Obstetrics, 2007. – 373 pp.
2. Williams Manual of Obstetrics (24th Ed) F. G. Cunningham, K. J. Leveno, S. L. Bloom, C. Y. Spong, J. S. Dashe, B. L. Hoffman, B. M. Casey, J. S. Sheffield, McGraw-Hill Education/Medical. – 2014. – 1377 pp.
3. Textbook of Gynecology (6th Ed) Dutta DC., Hiralal Konar (Ed.). – JAYPEE BROTHERS MEDICAL PUBLISHERS (P) LTD, 2013. – 702 pp.
4. DC Duttas Textbook of Obstetrics including Perinatology and Contraception (8th Ed.) Dutta DC., Hiralal Konar (Ed.). – JAYPEE BROTHERS MEDICAL PUBLISHERS (P) LTD, 2015. – 782 pp.
5. Llewellyn-Jones Fundamentals of Obstetrics and Gynaecology (10th Ed). Jeremy Oats, Suzanne Abraham. Elsevier. 2016. – 384 pp.

ONMedU, Department of Obstetrics and Gynecology. Practical lesson No. 5. "External obstetric examination, determination and evaluation of the topography of the fetus in the uterus. Auscultation of the fetus. CTG"

6. The FIGO Textbook of Pregnancy Hypertension. An evidence-based guide to monitoring, prevention and management. L. A. Magee, P. Dadelszen, W. Stones, M. Mathai (Eds), The Global Library of Women's Medicine. – 2016. – 456 pp.
7. Mayo Clinic Guide to a Healthy Pregnancy. Roger W. Harms (Ed). Rosetta books, 2011. – 612 pp.
8. Best practice in labor and delivery / edited by Richard Warren, S. Arullkumaran. Cambridge University Press. – 2009. – 362 pp.
9. Basic Science in Obstetrics and Gynaecology / edited by Philip Bennet, Catherine Williamson. 4th Edition. 2010, Churchill Livingstone Elsevier. – 386 pp.

Additional:

1. Maternal-Fetal Medicine. Creasy R.K., Resnik R – 2009. – 1296 pp.
2. Gibbs R. S., Karlan B. Y., Haney A. F., Nygaard I. E. Danforth's Obstetrics and Gynecology (10th Ed).- Lippincott Williams & Wilkins. – 2008. – 2225 pp.
3. CTG Made Easy / edited by Susan Gauge, Christine Henderson. 3rd Edition, 2009.- Elsevier Churchill Livingstone. – 280 pp.
4. Obstetrics: Normal and Problem Pregnancies, 7th Edition S. Gabbe, J. R. Niebyl, J. L. Simpson, M. B. Landon, H. L. Galan, E. R. M. Jauniaux, D. A. Driscoll, V. Berghella and W. A. Grobman, Elsevier. – 2017. – 1320 pp.
5. Obstetrics by Ten Teachers (20th ed) Louise C. Kenny, Jenny E. Myers. – CRC Press. – 2017. – 342 pp.
6. Current Progress in Obstetrics and Gynaecology. Vol 4. Eds. J. Studd, Seang Lin Tan, F. Chervenak. – 2017. – 419 pp.
7. Recent Advances in Obstetrics and Gynaecology. Vol 26. W. Ledger, J. Clark. – JP Medical. – 2015.– 230 pp.
8. Proactive Support of Labor. Reuwer P., Bruinse H., Franx A. – 2015. – 216 pp.

INTERNET SOURCES:

- <https://www.cochrane.org/>
- <https://www.ebcog.org/>
- <https://www.acog.org/>
- <https://www.uptodate.com>
- <https://online.lexi.com/>
- <https://www.ncbi.nlm.nih.gov/>
- <https://pubmed.ncbi.nlm.nih.gov/>
- <http://eknygos.lsmuni.lt/akuserijaen/Obstetrics/4%20CTG%20engl.html>
- <https://www.glowm.com/article/heading/vol-5--surveillance-of-fetal-wellbeing--antepartum-cardiotocography/id/412143>