

ONMEDU. Discipline "Endoscopic technologies in obstetrics and gynecology"  
Practical lesson No1. Hysteroscopy in the diagnosis of gynecological pathology.

MINISTRY OF HEALTH OF UKRAINE  
ODESSA NATIONAL MEDICAL UNIVERSITY  
International Faculty  
Department of Obstetrics and Gynecology



**CONFIRMED by**

Vice-rector for Scientific and Pedagogical Work  
Eduard BURIACHKIVSKYI

**METHODOLOGICAL RECOMMENDATIONS FOR PRACTICAL  
LESSON ON THE DISCIPLINE**

International Faculty, course VI.

Elective Discipline "Endoscopic technologies in obstetrics and gynecology"

**Practical lesson No1.** Hysteroscopy in the diagnosis of gynecological pathology.

ONMEDU. Discipline "Endoscopic technologies in obstetrics and gynecology"  
Practical lesson No1. Hysteroscopy in the diagnosis of gynecological pathology.

**Approved:**

Meeting of the Department of Obstetrics and Gynecology of Odesa National  
Medical University

Protocol No1 of August 28, 2023

Head of the Department  \_\_\_\_\_ Ihor GLADCHUK

Developers:

PhD, Associate Professor

of the Department of Obstetrics and Gynecology  \_\_\_\_\_ Stepanovichus O.M.

PhD, Assistant

of the Department of Obstetrics and Gynecology  \_\_\_\_\_ Lunko T.A.

## **Practical lesson 1.**

### **Topic: Hysteroscopy in the diagnosis of gynecological pathology.**

**Aim:** To systematize and deepen knowledge on the topic of practical training. To form a clear idea of the examination of the mucous membrane of the uterus, during hysteroscopy. Learn the patient's examination plan before performing diagnostic hysteroscopy. Get acquainted with the types and capabilities of modern hysteroscopic equipment when examining the uterus. Master the basic technique of hysteroscopic intervention in gynecology. Determine indications and contraindications for hysteroscopy . Learn a plan for managing patients in the postoperative period

**Basic concepts:** Diagnostic hysteroscopy. Indications. Contraindications, complications Technique. Hysteroscopic picture of the uterine mucosa, depending on the pathological conditions (hyperplastic processes of the endometrium, submucous uterine fibroids, intrauterine overflows, intrauterine synechiae).

**Equipment:** Professional algorithms, structural and logical schemes, tables, dummies, phantoms of video materials, results of laboratory and instrumental studies, situational problems, patients, medical histories.

**1. Organizational measures** (greetings, checking those present, communicating the topic, the purpose of the lesson, motivating students to study the topic ).

The method of hysteroscopy increases the diagnostic and therapeutic possibility in solving issues of various intrauterine pathology, in patients of different age categories. The clinical experience of medical institutions shows that the most difficult for the doctor are clinical situations that require emergency care. Proper, timely provided, rationally planned and carried out by careful methods, the necessary assistance can not only save the patient's life, but also preserve her reproductive function.

Hysteroscopy is a transcervical examination of the uterine cavity using an endoscope. It allows you to carry out a number of effective surgical interventions for intrauterine pathology simultaneously with its diagnosis. Hysteroscopy is carried out both planned and in emergency conditions. Gas, flushing and contrast hysteroscopy are also distinguished.

Today, the method of hysteroscopy belongs to a procedure with low surgical risk and is based on natural access to the uterus. A method that provides an opportunity to find out and eliminate the presence of some intrauterine problems.

**Equipment:**

Professional algorithms, structural and logical schemes, tables, dummies, video materials, results of laboratory and instrumental studies, situational problems, patients, medical histories.

**Study time:** 4 hours.

**I. Organizational measures** (greetings, checking those present, communicating the topic, the purpose of the lesson, motivating students to study the topic).

The use of the hysteroscopy method in modern gynecological surgery increases the diagnostic and therapeutic possibility in solving issues of intrauterine pathology. Provides an opportunity to assess the patient's condition. Learn the patient's examination plan before choosing a treatment method. To master counseling on the use of modern methods of examination and treatment of patients with complaints of abnormal uterine bleeding of infertility, miscarriage, and various intrauterine pathology.

**Ii. Control of supporting knowledge (written work, written testing, online testing, frontal survey, etc.).**

**2.1. Requirements for the theoretical readiness of students to perform practical classes.**

Requirements for knowledge:

- communication and clinical examination skills of the patient;
- ability to determine the list of necessary clinical, laboratory and instrumental studies and evaluate their results ability to determine the list of necessary clinical, laboratory and instrumental studies and evaluate their results ;
- ability to establish a preliminary and clinical diagnosis of the disease;
- ability to perform medical manipulations;
- ability to advise on precancerous diseases of the female genital organs
- ability to maintain medical records.

**List of didactic units:**

- advising patients on AMK of all ages, infertility, miscarriage, malformations
- general inspection, methods of examination using gynecological examination: in mirrors, bimanual examination, rectovaginal examination
- o theprice of the patient's condition.
- necessary examination, which is carried out in a planned manner before making a decision on the use of an additional method of examination and treatment

**2.2. Questions** (test tasks, tasks, clinical situations) to test basic knowledge on the topic of the lesson.

- **Question:**

Endometrial hyperplastic processes: etiology, pathogenesis, classification, diagnosis, treatment methods, tactics of a general practitioner.

- Prevention of precancerous diseases of the female genital organs
- The concept of "hyperplastic processes of the endometrium."
- Etiology, pathogenesis of endometrial hyperplastic processes.
- Clinical manifestations of endometrial hyperplastic processes.
- Histological classification of hyperplastic processes of the endometrium WHO. Additional methods for diagnosing endometrial hyperplastic processes.
- Therapeutic tactics in the hyperplastic process of the endometrium in the reproductive period.
- Therapeutic tactics in the hyperplastic process of the endometrium in the premenopausal period.
- Indications for surgical treatment of the hyperplastic process of the endometrium

### **Typical situational tasks:**

1. A patient of 32 years complains of pulling pain in the lower abdomen, spotting brown discharge before menstruation, and abundant excretions during the cycle. With a bimanual examination, the uterus is slightly enlarged, more in the area Isthmus, painful during the touch, rounded shape. Appendages on both sides without features. Preliminary diagnosis - internal endometriosis. With ultrasound in the cavity, the echopositive structure is 1.5x1.0. The most informative for diagnosis and treatment tactics in this case.

1.D-z Endometrial polyp.

2. Algorithm of examination: hysteroscopy, polypectomy. According to the results of histological examination, therapeutic measures are prescribed.

### **2. Tipov tests**

- 1. Clinical picture in hyperplastic processes of the endometrium:
  - A. Oligomenorrhea
  - +B. Abnormal uterine bleeding
  - C. Pain syndrome
  - D. Shifting the leukocyte formula to the left
  - E. ESR enhancement
- 2. Endometrial polyposis occurs more often:
  - A. In menopause
  - B. After childbirth
  - +C. In menopause
  - D. During progesterone treatment
  - E. After discontinuation of oral contraceptives

- **iii. Formation of professional skills and abilities (mastering skills, conducting curation, determining the treatment regimen, conducting laboratory research, etc.).**
- **3.1. The content of the tasks (tasks, clinical situations, etc.).**

**Interactive task:**

- Students of the group are divided into 3 subgroups in the amount of 4-5 people each. We work on consultations, with gynecological patients, we give tasks after examining the video material:
- And the subgroup is to make a preliminary diagnosis.
- Ii subgroup – to draw up a plan for the management of a gynecological patient.
- Subgroup III – evaluates the correctness of the answer of the I and II subgroups and makes its own adjustments.

**Atypical situational tasks:**

1 . \* A patient of 35 years old, turned to a gynecological hospital with complaints of periodic pain in the lower abdomen, which increases during menstruation, dark brown spotting from the genital ways in the post-menstrual period. In a bimanual study: the body of the uterus is somewhat enlarged spherical, the appendages are not determined when examining the cervix without features.

1)What is the most likely diagnosis? Adenomyosis.

2(Algorithm of examination : smear for cytomorphology and microscopy, hysteroscopy. Endometrial biopsy

2. In the patientka 48th rock i v, which complains of abundant i and prolonged i menstruac i th, l i kar na p i d- became i data ultrasonic dosl i dzhennya (ultrasound) suggests g iperplase Iu endometrium i i. What methods of research are the most useful to use to clarify the diagnosis?

1. Hysteroscopy, fractional excision of the uterus with subsequent pathohistological research

2. Hormone therapy with progestins or the use of an IUD with levonorgestrel.

**Atypical tests:**

A patient of 60 years complains of the appearance of bleeding from the genital tract. Menopause 8 years. In history: childbirth – 2, artificial abortions – 3. In vaginal examination: external genitalia with signs of age-related involution, the cervix is cylindrical, with no visible pathological changes. From the cervical canal – minor bleeding. The body of the uterus is of normal size, dense, painless on palpation. Appendages without features. The vaginal arches are deep, free. What additional examination methods need to be carried out to clarify the diagnosis?

1. Ultrasound of the pelvic organs,
2. pipel biopsy of the endometrium,
3. гістероскопія.
4. FDV of the uterine mucosa.

The risk factors for endometrial cancer do not include:

- A. Obesity
- B. Anovulatory menstrual cycles
- C. Ovarian tumor
- D. Endogenous estrogens
- E. High progesterone levels

**3.2-. Recommendations (instructions) for the implementation of tasks (professional algorithms, orientation maps for the formation of practical skills and abilities, etc.).**

- Teach to properly collect anamnesis, pay attention to the patient's complaints, which allow you to make a preliminary diagnosis, outline further tactics in different periods of life from the juvenile to postmenopausal period of a woman. The examination is carried out in a planned or urgent manner before making a decision in favor of a particular method examination and treatment of the patient.
- Master the ability to correctly draw up a survey plan, taking into account the invasiveness of the methods, the need for these studies. Conduct modern research methods that allow you to identify and take into account all the smallest details that contribute to the recognition of the disease and allow you to correctly establish the diagnosis for the subsequent appointment of adequate therapy.

Diseases of the genital organs are divided into neoplastic (tumor) and non-neoplastic (background, or pretumor). Non-neoplastic lesions of the external genital organs are also called vulvar dystrophy, which is

**Indications for hysteroscopy:**

- menstrual disorders and uterine bleeding
- adenomyosis
- hypoplasia endometry
- endometrial polyps

- polyps of the cervical canal (cervix )
- synechii (spikes)
- Small fibroids
- Infertility

**Contraindications for hysteroscopy:**

- профузна маткова кровотеча;
- pregnancy;
- acute inflammatory processes of the female genital organs;
- infectious diseases (influenza, sore throat, pneumonia, pyelonephritis , etc.);
- cervical cancer , infiltrative endometrial cancer;
- cerebral stenosis.

Hypoplasia endometry	nephysiological proliferation of the endometrium, accompanied by a structural restructuring of its jelly-zystoy and to a lesser extent stromal components
Atypical endometrial hyperplasia	f cytological atypia: has signs of cellular and nuclear polymorphism along with disorganization of the epithelium of the endometrial glands. Benign neoplasm rising above the surface of the endometrium is formed by a nodular form consisting of the glands of the endometrium and stroma.
Endometrial polyp	Benign neoplasm rising above the surface of the endometrium forming a nodular shape, consisting of the glands of the endometrium and stroma.
Adenomyosis	Internal endometriosis of the uterus body
Uterine fibroids. Submucous variant	Benign neoplasm of the uterus body deforming cavity

- Conduct gynecological examination (in mirrors, bimanual, rectal, rectovaginal).
- Collect a special gynecological history, evaluate the results of laboratory examination.
- To collect material from the vagina, cervix, cervical canal and urethra for cytological and bacterioscopic examination.
- Evaluate the results of cytological, histological, virological and bacteriological studies. Evaluate the
- results of ultrasound examination of the pelvic organs Evaluate the
- protocol of

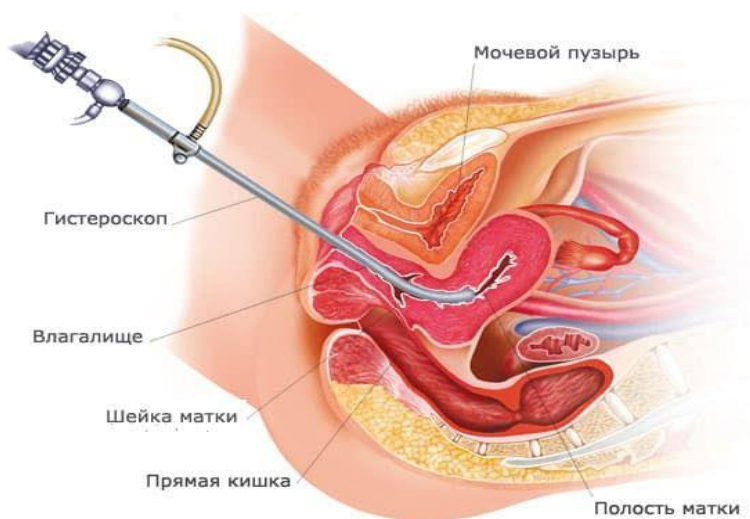


colposcopic examination of the cervix and vulva Make a • plan for examining the patient for various nosological types of infertility, background and precancerous pathology.

Hysteroscopy is a visual inspection of the walls of the uterus and cervical canal using a thin optical device.

The essence of the procedure lies in the fact that an endoscopic device called a hysteroscope is inserted through the cervical canal into the uterine cavity. Thanks to this, the gynecologist can assess the condition of the uterus, tubal corners and cervix in real time .

This method allows you to perform both diagnostic and therapeutic procedures, with minimal trauma, without additional incisions and completely painlessly, since the procedure takes place under intravenous anesthesia.



#### Method of performing diagnostic hysteroscopy:

Diagnostic operations can be performed without the use of anesthesia. Anesthesia is traditionally used during surgical hysteroscopy – intravenous (general) anesthesia. Previously, the patient is asked not to drink or eat, as well as to undergo a standard set of laboratory tests. Hysteroscopic operations are performed on the usual 7-10 days after the onset of menstruation. At this time, the endometrial layer is the smallest, providing maximum visibility.

The patient is placed in a dorsal lithotomy position. External genitals, perineum and arrogance are treated with antiseptic solutions. Vaginal speculum - Simsa, inserted into the posterior vault of the vagina will be pulled down. Remove the cervix. Fix the front lip with ball forceps. After dividing the cervical canal, an endoscope is inserted into the uterine cavity. She allows you to carry out a number

of effective surgical interventions for intrauterine pathology simultaneously with its diagnosis.

Hysteroscopy is carried out both planned and in emergency conditions.

1. Processing the operating field.
2. Exposure of the cervix in the mirrors.
3. Fixation of the cervix by the front lip.
4. Treatment of the cervix and vagina with an antiseptic solution .
5. Probing the uterus .
6. Dilation of the cervical canal by Hegar expanders to No. 8-11.
7. The introduction of a hysteroscope tube into the uterine cavity and its examination.
8. If necessary , manipulation in the uterus .
9. Biopsy. Tool output.

Examination of the uterus should be complete. After the introduction of the hysteroscope tube into the uterine cavity, panoramic hysteroscopy is first performed. In this case, the tube of the instrument is located behind the inner eye of the cervical canal so that the field of view covers the entire uterine cavity. It is necessary to determine its shape, size, the presence or absence of deformations of its walls, pathological formations, the height and color of the mucous membrane , to conduct a detailed examination of the endometrium. Tube hysteroscope close to the center of the bottom of the uterus. In this case, the main landmarks are the eyes of the fallopian tubes. Having examined the endometrium of the bottom of the uterus, proceed to the inspection of the tubal cells. Attention should be paid to their presence, shape, size, nature and height of the endometrium in the area of the tubal angles, the presence or absence of pathological formations. Approaching the end of the hysteroscope to the walls of the uterus, the endometrium and vascular pattern of the surface of the anterior, posterior and lateral walls of the uterus are examined in detail . When pathological formations are detected in the uterus, determine their consistency with the help of hysteroscopic instruments, if necessary – carry out intraoperative correction of pathology. The final stage is an targeted biopsy of the endometrial sites and a final examination of the uterine cavity. At the end of the study, the hysteroscope is removed from the uterus.

### **Algorithm for performing practical skills.**

#### *Bimanual (vaginal) examination:*

- 1) say hello to the patient;
- 2) identify the patient (name, age);
- 3) inform the patient about the need for research;
- 4) explain to the patient how the study is conducted;
- 5) obtain permission to conduct research;
- 6) wash your hands;
- 7) wear inspection gloves;
- 8) with the first and second fingers of the left (right) hand, spread large embarrassing lips, place the middle finger of the "dominant" hand at the level of the posterior adhesion, gently press it to open the entrance to vagina;
- 9) gently and slowly insert the middle finger, then the index finger into the vagina along the back wall to the vault and cervix, the fourth and fifth fingers lead to the palm of your hand, take the thumb away to the top;
- 10) determine the length of the vaginal part of the cervix in centimeters;
- 11) determine the consistency of the cervix (dense, soft);
- 12) determine the patency of the outer eye of the cervical canal (closed, skipping fingertip);
- 13) assess the pain of the excursion of the cervix;
- 14) gently put the second palm on the stomach (above the symphysis) and moderately press to determine the bottom of the uterus body;
- 15) remove the body of the uterus between two hands and determine:
  - the position of the uterus relative to the cervix (anteflexio, retroflexio);
  - body size of the uterus (normal, reduced, increased);
  - the consistency of the body of the uterus (tightly elastic, soft, compacted);
  - mobility of the uterus body (relatively mobile, limitedly mobile);
  - sensitivity on palpation (painful, painless);
- 16) place the fingers in the bottom of the right lateral vault and using both hands to palpate the right vaginal arch and the right applications of the uterus, determine their size, mobility and tenderness;
- 17) place the fingers in the bottom of the left lateral vault and using both hands to palpate the left vaginal vault and the left appendices of the uterus, determine their size, mobility and tenderness;
- 18) determine the capacity of the vaginal arches;
- 19) inform the patient about the results of the study;
- 20) thank the patient;
- 21) remove inspection gloves;
- 22) wash your hands.

**Interactive task:**

Students are divided into 3 brigades in the amount of 3-4 people each. After the above situational task, we give the task:

The first team is to make a preliminary diagnosis and draw up a plan for examining the patient;

The second brigade is to draw up a treatment algorithm;

The third brigade – assesses the correctness of the response of the first and second brigades and makes its own adjustments;

Situational task:

A 41-year-old woman entered the hospital with a complaint of cramping pain in the lower abdomen and bleeding from the vagina. History of 1 birth, 2 medaborts. Objectively: the skin covers are pale; a vaginal examination revealed uterine fibroids up to 8 weeks in pregnancy. Ultrasound revealed deformation of the uterus with a submucous node, which is located in her day. Clinical diagnosis? Examination methods. What treatment should be carried out? 1. Uterine fibroids. Nodular form. Submucous option. 2. Hysteroscopy. resection of the submucous node.

**3.3. Requirements for the results of work, including registration.**

- To advise women on menstrual disorders
- Evaluate the patient.
- Choose a method of treatment in adolescents, in women of reproductive age, in the oral report on the thematic patient.
- Analysis and discussion of the results of the patient's examination.
- Multimedia presentation on the topic of the lesson (review of literature using modern sources; videos, etc.).

**3.4. Control materials for the final stage of the lesson: tasks, tasks, tests, etc.**

**Control of professional skills**

In the gynecological department:

1. Collect anamnesis, perform an objective and gynecological examination of the patient.
2. Establish a preliminary diagnosis.
3. Assign a plan of examination and treatment
4. Conducting hysteroscopy zastasov phantoms.

**4. Summing up (criteria for evaluating learning outcomes).**

**Current control:** oral questioning, testing, evaluation of practical skills, solving situational clinical problems, evaluation of activity in the classroom , etc.

*The structure of the current assessment in the practical lesson:*

1. Evaluation of theoretical knowledge on the topic of the lesson:
  - methods: survey, solving a situational clinical problem;
  - The maximum score is 5, the minimum score is 3, the unsatisfactory score is 2.
2. Assessment of practical skills and manipulations on the topic of the lesson:
  - methods: assessment of the correctness of practical skills;
  - The maximum score is 5, the minimum score is 3, the unsatisfactory score is 2.
3. Evaluation of work with the patient on the topic of the lesson:
  - Methods: assessment: a) communication skills of communication with the patient, b) the correctness of the appointment and evaluation of laboratory and instrumental studies, c) compliance with the algorithm for conducting a differential diagnosis d) justification of the clinical diagnosis, e) drawing up a treatment plan;
  - The maximum score is 5, the minimum score is 3, the unsatisfactory score is 2.

***Criteria for the current assessment in a practical lesson:***

«5»	The student is fluent in the material, takes an active part in the discussion and solution of a situational clinical problem, confidently demonstrates practical skills during the examination of the patient and the interpretation of clinical data, laboratory and instrumental studies, expresses his opinion on the topic of the lesson, demonstrates clinical thinking.
«4»	The student is fluent in the material, participates in the discussion and solution of a situational clinical problem, demonstrates practical skills during the examination of the patient and the interpretation of clinical, laboratory and instrumental studies with some errors, expresses his opinion on the topic of the lesson, demonstrates clinical thinking.
«3»	The student does not have enough knowledge of the material, uncertainly participates in the discussion and solution of a situational clinical problem, demonstrates practical skills during the examination of the patient and the interpretation of clinical data, laboratory and instrumental studies with significant errors.
«2»	The student does not own the material, does not participate in the discussion and solution of a situational clinical problem, does not demonstrate practical skills during the examination of the patient and the interpretation of clinical, laboratory and instrumental research.

## 5. List of recommended literature.

### Basic

1. Obstetrics: student's book = Акушерство: підручник / Gladchuk I.Z., Ancheva I.A. Vinnytsia: Nova Knuya, 2021. –288 p.
2. Obstetrics and Gynecology: in 2 vol.:textbook. Volume 2. Gynecology / V.I. Gryshchenko, M.O. Shcherbina, B.M. Ventskiivskyi et al.; edited by V.I. Gryshchenko, M.O. Shcherbina. — 3th edition. – K.: AUS Medicine Publishing, 2022 – 352 p.
3. Oats, Jeremy Fundamentals of Obstetrics and Gynaecology [Text]: Liewellyn-Jones Fundamentals of Obstetrics and Gynaecology / J. Oats, S. Abraham. – 10<sup>th</sup> ed. – Edinburgh [etc.]: Elsevier, 2017. – VII, 375 p.
4. Llewellyn-Jones Fundamentals of Obstetrics and Gynaecology (10th Ed). Jeremy Oats, Suzanne Abraham. Elsevier. 2016. – 384 pp.
5. Dutta, Durlav Chandra. D. C. Dutta's Textbook of Gynecology including Contraception / D.C. Dutta; ed/ Hiralal Konar. – 7<sup>th</sup>.ed. – New Delhi: Jaypee Brothers Medical Publishers, 2016. – XX, 574 p.

### Additionally:

1. 2011 IFCPC Colposcopic Terminology. Clarification on practical use.- K.. - "Polygraph Plus", 2018.- 62 p.
2. Modern technical teaching aids (see appendix to the work program of the 4th year) Prevention of purulent-septic complications during laparoscopic surgeries on pelvic organs with the risk of vaginal microbiota contamination / Zaporozhan VN, Gladchuk IZ, Rozhkovska NM, Volyanska AG, Shevchenko OI //World of Medicine and Biology.-2020- #1(71). - P.49- 53. (Web of science)

### Electronic information resources

1. <https://www.cochrane.org/>- Cochrane / Cochrane Library
2. <https://www.acog.org/>- The American College of Obstetricians and Gynecologists
3. <https://www.uptodate.com>– UpToDate
4. <https://online.lexi.com/>- Wolters Kluwer Health
5. <https://www.ncbi.nlm.nih.gov/>- National Center for Biotechnology Information / National Center for Biotechnology Information
6. <https://pubmed.ncbi.nlm.nih.gov/>- International Medical Library / National Library of Medicine
7. <https://www.thelancet.com/>- The Lancet
8. <https://www.rcog.org.uk/>- Royal College of Obstetricians & Gynecologists

ONMEDU. Discipline "Endoscopic technologies in obstetrics and gynecology"  
Practical lesson No1. Hysteroscopy in the diagnosis of gynecological pathology.

9. <https://www.npwh.org/>- Nurse practitioners in women's health
10. <http://moz.gov.ua>- Ministry of Health of Ukraine
11. [www.ama-assn.org](http://www.ama-assn.org)– American Medical Association /[American Medical Association](#)
12. [www.who.int](http://www.who.int)- World Health Organization
13. [www.dec.gov.ua/mtd/home/](http://www.dec.gov.ua/mtd/home/)- State Expert Center of the Ministry of Health of Ukraine
14. <http://bma.org.uk>– British Medical Association
15. [www.gmc-uk.org](http://www.gmc-uk.org)- General Medical Council (GMC)
16. [www.bundesaerztekammer.de](http://www.bundesaerztekammer.de)– German Medical Association
17. [www.euro.who.int](http://www.euro.who.int)- European Regional Office of the World Health Organization