

**MINISTRY OF HEALTH OF UKRAINE**  
**ODESA NATIONAL MEDICAL UNIVERSITY**

Faculty of Medicine №2

Department of Neurology and Neurosurgery

**APPROVED BY**

Vice-Rector for Scientific and Educational Work

\_\_\_\_\_ Eduard BURIACHKIVSKYI

«\_\_\_» \_\_\_\_\_ 2023

**TEACHING MATERIAL FOR PRACTICAL CLASSES  
ON THE ACADEMIC SUBJECT**

Faculty, Course: Medical, 5th year

Academic Discipline: **Current Issues in Neurosurgery and Cerebrovascular Pathology**

**Approved by:**

Meeting of the Department of Neurology and Neurosurgery Odesa National Medical  
University

Protocol No. 1 dated "28" 08 2023

Head of the Department



Anatoliy SON

**Developers:**

Son Anatoliy Serhiiiovych, PhD, DSci, Professor, Head of the Department of Neurology and Neurosurgery

Dobrovolskyi Vasyl Vyacheslavovych, PhD, Associate Professor

Babych Eliza Vitaliivna, Assistant Professor

Hnatiuk Iryna Mykhailivna, Assistant Professor

Sarzhyna Kateryna Sviatoslavivna, Assistant Professor

Serbin Ihor Volodymyrovych, Assistant Professor

Yarovaya Ksenia Oleksandrivna, Assistant Professor

## PRACTICAL CLASSES

### *Practical Class No. 1*

**Topic:** Traumatic injuries of the nervous system. Closed traumatic brain injury (TBI).

**Objective:** To acquire knowledge and skills in examining a patient with closed traumatic brain injury, to learn to independently interpret the results of visualization studies, and to form a clear understanding of the sequence of actions in managing a patient with closed traumatic brain injury.

**Key concepts:** Closed traumatic brain injury, Glasgow Coma Scale, dislocation syndrome

**Equipment:** Laptop, multimedia projector.

**Plan:**

1. Organizational activities (greetings, attendance check, announcement of the topic and objectives of the session, motivation of students for studying the topic).
2. Control of the baseline knowledge level (frontal questioning):
  - Anatomical and physiological features of the brain in different age groups.
  - Features of blood supply to the brain, meninges, and skull bones; cerebrospinal fluid system of the brain.
  - Radiological examination methods in a patient with TBI.
  - Focal and diffuse symptoms of TBI.
  - Meningeal symptoms.
  - Groups of drugs for comprehensive TBI therapy: dehydration, hemostatics, hormonal.

**Tests:**

1. In which space of the cranial cavity is cerebrospinal fluid located?  
Answer options:
  - a) Epidural space.
  - b) Subarachnoid space.
  - c) Subdural space.
  - d) Sagittal fissure.
  - e) Tentorium cerebelli.Correct answer: b)
2. Sensory aphasia develops with a lesion in which area of the brain during a contusion?  
Answer options:
  - a) Pole of the frontal lobe.
  - b) Basal parts of the right frontal area.
  - c) Broca's area.
  - d) Wernicke's area.
  - e) Temporal lobe.Correct answer: c)
3. List eight general symptoms of TBI.  
Correct answers: a) Headache.
  - b) Dizziness.
  - c) Nausea.
  - d) Stasis phenomena on the fundus.
  - e) Bradycardia.
  - f) Impaired consciousness.
  - g) Craniographic signs.
  - h) Episindrome.

**Content:**

**Classification of traumatic brain injury:**

Closed TBI

- 1.1 Concussion
- 1.2 Contusion
- 1.3 Compression of the brain
- 1.4 Diffuse axonal injury

Open

2.1 Penetrating

2.2 Non-penetrating

According to severity:

**Mild** GCS 14 or 15 + AND short loss of consciousness (<5 min) OR impaired attention.

**Moderate** GCS 9-13 OR loss of consciousness  $\geq$  5 min OR focal neurological deficit.

**Severe** GCS 3-8.

**Concussion** is a complex of pathophysiological processes affecting the brain, resulting in changes in brain functions induced by non-penetrating biomechanical forces without detected anomalies on standard structural imaging. Neurological symptoms may or may not include loss of consciousness. The onset of symptoms is usually acute, short-term, and spontaneously resolving. Manifestations may include transient disturbances of balance, coordination, memory/cognition, strength, or attention concentration.

Neuropathological changes may occur, but acute clinical symptoms mostly reflect functional changes rather than structural pathology. Diagnosis is based on history and clinical presentation.

Contusion of the brain is characterized by the presence of high-density zones on CT images. It most commonly occurs with rapid slowing of head movement, leading to brain impact on bony prominences (temporal, frontal, occipital bones) by the coup-contrecoup mechanism. Surrounding low-density zones on CT images indicate brain swelling.

Contusion consists of a region of brain tissue necrosis with a perifocal zone where inflammatory reactions, secondary damage, and swelling develop. In the contusion zone, depending on the severity of the injury, there may be small focal hemorrhages, small areas of homogenization of brain tissue, as well as the formation of massive necrotic foci filled with brain detritus, vessel ruptures, bleeding into the destroyed tissue, pronounced swelling of the perifocal zone with a tendency to spread to adjacent areas, sometimes affecting the entire brain.

**Mild contusion** is characterized by loss of consciousness (usually described in minutes), intense headache, dizziness, weakness, ringing in the ears, often amnesia, pronounced nausea, and repeated vomiting. Impairment of vital functions is not characteristic; sometimes there is moderate tachycardia or (rarely) bradycardia, flushing, sleep disturbances, etc. Neurological symptoms typically include spontaneous nystagmus, mild anisocoria, signs of pyramidal deficiency, and mild meningeal symptoms. Neurological symptoms usually completely regress within 2-3 weeks.

Contusion of moderate severity is accompanied by loss of consciousness lasting from several tens of minutes to several hours (usually described in hours). Almost always, amnesia is present, and there is intense and prolonged headache, repeated vomiting, possible mental disorders. Temporary disturbances of vital functions (brady- or tachycardia, increased blood pressure, tachypnea without respiratory rhythm disturbance, subfebrile) are sometimes observed; stem disorders are sometimes observed. Meningeal symptoms are pronounced, and a clear focal symptomatology is revealed, determined by the localization of the contusion focus (motor disturbances, limb paralysis, sensory disorders, etc.). Over 2-5 weeks, neurological symptoms gradually regress, but residual effects are often detected.

**Severe contusion** is accompanied by loss of consciousness (usually described in days, sometimes weeks), psychomotor agitation, pronounced, often threatening disturbances of vital functions, gross neurological symptoms dominated by signs of brainstem injury.

Meningeal symptoms are markedly pronounced, and often generalized or focal seizures may occur. Focal symptoms regress slowly and not completely, with significant residual effects, especially in the motor and psychological domains.

**Basis of diagnosis** – CT of the brain.

### **Diffuse Axonal Injury (DAI)**

Primary injury resulting from TBI with rotational acceleration/deceleration. Severe cases exhibit hemorrhagic foci in the cerebellum and dorsolateral rostral brainstem with microscopic signs of diffuse axonal damage (axonal retraction bulbs, microglial stars, and degeneration of white matter). It can lead to prolonged loss of consciousness in patients who immediately fall into a coma after TBI, even in the absence of intracranial formation or ischemia.

DAI Description	Grade	Опис
Mild		Coma lasting 6-24 hours, followed by mild/moderate memory impairments and limited functional impairment.
Moderate		Coma lasting more than 24 hours, followed by stupor and long-term amnesia. Mild/moderate memory, behavioral, and cognitive impairments.
Severe		Coma lasting months, flexor and extensor motor responses. Impaired functions: cognitive, memory, speech, sensorimotor. Personality disorders. Dysautonomia.

### **Epidural Hematoma**

Fracture of the temporal and parietal bone leads to the rupture of the middle meningeal artery as it exits the bony groove and enters the cranial cavity (pterion). This results in arterial bleeding that gradually detaches the dura mater.

Clinical presentation:

Brief post-traumatic loss of consciousness

"lucid interval" for a few hours

Stupor, contralateral hemiparesis, ipsilateral pupil dilation (due to mass effect)

Headache, vomiting, seizures (may be unilateral), hemihyperreflexia, Babinski sign on one side, increased intracranial pressure, bradycardia.

Brainstem herniation due to hematoma displacement may cause compression of brainstem peduncles and ipsilateral hemiparesis (Kernohan phenomenon).

#### **Diagnosis:**

CT of the brain

A high-density biconvex (lens-shaped) hematoma adhering to the skull. In 11%, it has a crescent shape. May cross the midline but usually limited by skull sutures. Typically has uniform density, well-defined edges on multiple slices, high absorption (undiluted blood), adheres to the inner surface of the skull, and is usually confined to a small segment of the skull.

#### **Treatment:**

Conservative for subacute or chronic epidural hematomas (maximum thickness  $\leq 1$  cm) with minimal neurological symptoms (mild lethargy, headache) without signs of herniation.

Indications for surgical intervention:

Volume of EDH  $> 30$  cm<sup>3</sup> regardless of GCS.

EDH with the following characteristics may be managed conservatively with repeated CT scans and intensive monitoring in a neurosurgical department:

- a) volume  $< 30$  cm<sup>3</sup>
- b) thickness  $< 15$  mm
- c) Midline shift (MLS)  $< 5$  mm
- d) GCS  $> 8$
- e) Absence of focal neurological deficit.

#### **Acute Subdural Hematoma Causes:**

1. Accumulation of blood around the parenchyma (usually frontal or parietal region). Usually, there is no "lucid interval." Focal symptoms occur later and are less pronounced than in epidural hematoma (EDH).

2. Rupture of superficial and bridging vessels due to rapid acceleration/deceleration of head movement. More common "lucid interval."

**Diagnosis:**

CT scan – crescent-shaped area of increased density.

Localization:

Above the dorsal surface of the brain.

- Interhemispheric
- Under the falx cerebri
- In the posterior cranial fossa

**Indications for surgical intervention:**

1. Thickness > 10 mm or midline shift > 5 mm (on CT), regardless of GCS.
2. Thickness < 10 mm and midline shift < 5 mm if:
  - a) GCS decreased by  $\geq 2$  points from injury to hospitalization
  - b) Unequal or fixed and dilated pupils
  - c) ICP > 20 mmHg.
3. Monitor ICP in all patients with acute subdural hematoma and GCS < 9.

**Chronic Subdural Hematoma**

Occurs in elderly individuals (average age 63 years).

Risk factors: alcohol abuse, seizures, CSF shunt, coagulopathies, patients at risk of falls.

Traditionally contains a dark fluid resembling "machine oil" that does not clot. Develops from acute subdural hematomas. Blood within the subdural space triggers an inflammatory response. Over days, fibroblasts penetrate the hematoma and form neo-membranes on the inner (cortical) and outer (dural) surfaces. This is followed by the growth of neocapillaries, enzymatic fibrinolysis, and the thinning of the hematoma. Fibrin breakdown products are incorporated into new clots, inhibiting hemostasis.

Clinical features:

1. Headache
2. Altered consciousness
3. Speech difficulties
4. TIA-like symptoms

**Treatment:**

1. Seizure prophylaxis
2. Reversal of coagulopathy
3. Surgical intervention

Indications:

- Presence of symptoms (hematoma thickness > 1 cm): focal deficit, changes in mental status, seizures.
- Progressive enlargement of hematoma on CT or MRI.

Methods:

- Hematoma evacuation
- Endovascular embolization of the middle meningeal artery.

**Self-Assessment Questions:**

1. Determine the neurosurgical tactics and specify the treatment method for each type of skull fractures:

a) Linear fracture;

b) Depressed fracture:

Closed

Open

c) Comminuted fracture:

Penetrating

Non-penetrating

Correct tactics:

a) Conservative treatment.

b) - Possible conservative tactics depending on the location;

Surgical tactics.

c) Surgical tactics in all cases.

**Materials for independent study:**

List of practical training tasks:

1. Psychoneurological examination of patients with traumatic brain injury.
2. Examination plan for a patient with traumatic brain injury.
3. Reading skull X-rays.
4. Indications and technique of lumbar puncture.
5. Complete the prescription form for a patient with various degrees of traumatic brain

injury.

**Instructional material for acquiring professional skills:**

Professional algorithm for examining a patient with traumatic brain injury:

1. Patient examination.
2. Anamnesis (injury history, heredity).
3. Complaints (headache, vomiting, vision disturbances, seizures).
4. Examination of internal organs (blood pressure and pulse on both arms are mandatory).
5. Assessing the level of consciousness (Glasgow Coma Scale from 3 to 15).
6. Examining the 12 pairs of cranial nerves.
7. Assessing the motor-sensory sphere (reflexes, determining sensory disturbances).
8. Determining statics and coordination.
9. Identifying meningeal syndrome.
10. Local examination of the head.
11. Detecting fluid leakage, blood from the nose, ears.
12. Detecting external soft tissue injuries.
13. Skull X-ray in two projections.
14. Additional diagnostic methods if necessary.

**Professional algorithm for performing a lumbar puncture:**

1. Patient positioned on the right side.
2. Legs bent at the knees and pulled up to the abdomen.
3. Hands treated with an antiseptic, sterile gloves.
4. Field treatment with 5% iodine, then alcohol at the level of 3-5 lumbar vertebrae.
5. Local anesthesia with 0.5% novocaine solution at the level of the interspinous space between the 4th and 5th lumbar vertebrae.
6. Needle control (presence of a mandrel, needle sharpness).
7. Lumbar puncture. Two obstacles felt during puncture (yellow ligament and dura mater) and penetration.
8. Slow withdrawal of the mandrel from the needle, checking for the presence of cerebrospinal fluid.
9. Evacuation of 1-2 ml of cerebrospinal fluid for analysis with the mandrel withdrawn.
10. Needle removal and aseptic dressing.

**Situational tasks:**

1. An unconscious patient is found in the yard with the smell of alcohol from the mouth. Locally - swelling of soft tissues in the right temporal region, anisocoria to the right, areflexia. Determine the examination plan, treatment tactics.

ANSWER: Hospitalization to the Neurosurgical Department, CT, trepanation of the skull, removal of intracranial hematoma.

2. A patient was undergoing treatment for traumatic brain injury - fracture of the left temporal bone. After 10 hours of injury, a sudden deterioration occurred, a coma of 4-5 on the Glasgow Coma Scale, impaired breathing function, periodic tonic seizures, wide pupils, sluggish

photoreaction, the left pupil slightly larger than the right. QUESTION: What may be the cause of the change in the clinical picture? Determine the doctor's tactics.

ANSWER: Increase in the epidural hematoma on the left, displacement of midline structures of the brain. Doctor's tactics - urgent surgery according to vital indications (skull trepanation).

3. A non-conscription 18-year-old experienced traumatic brain injury at the age of 12. In the following years, periodic headaches, two episodes of loss of consciousness occurred. He completed 11 grades and is studying in college. QUESTION: Outline the examination and treatment plan. ANSWER: Psycho-neurological examination, EEG, CT of the brain.

4. Summary.

#### **Main Literature:**

1. Neurosurgery: textbook / [V.O. Pyatikop, I.O. Kutoviy, A.V. Kozachenko et al.]; edited by V.O. Pyatikop - Kyiv, VSV "Medicine", 2019. - 152 p.

2. Neurosurgery: textbook / [V.I. Tsimbalyuk, V.V. Medvedev, M.O. Marushchenko et al.]; edited by academician V.I. Tsimbalyuk. - 2nd edition, revised. - Vinnytsia: Nova Knyha, 2020. - 360 p.

3. Hryhorova I.A., Sokolova L.I., Herasymchuk R.D., Son A.S., et al. Neurology: Educational Manual / edited by I.A. Hryhorova, L.I. Sokolova - 3rd edition - Kyiv, VSV "Medicine", 2020. - 640 p.

4. Topical diagnosis of nervous system pathology. Diagnostic search algorithms. Shkrobot S.I., Saliy Z.V., Budarna O.Yu. Ukrmedknyha, 2018. - 156 p.

5. Methods of examination of a neurological patient: a tutorial / edited by L.I. Sokolova, T.I. Ilyash. Kyiv, 2020. - 144 p.

6. Emergency medicine. Emergency (ambulance) medical care: textbook / I.S. Zozulya, V.I. Bobrova, G.G. Roschin, etc. / edited by I.S. Zozulya. - 3rd edition, revised and supplemented. - Kyiv. - VSV "Medicine", 2017. - 960 p.

7. Negrych T.I., Bozhenko N.L., Matvienko Yu.Sh. Ischemic stroke: secondary inpatient care: a tutorial. Lviv: Danylo Halytsky Lviv National Medical University, 2019. - 160 p.

8. Handbook of Neurosurgery / Greenberg M.S. - Thieme, 2019. - 1784 p. ISBN 9781684201372

9. Neurology - Неврологія: textbook / I.A. Hryhorova, L.I. Sokolova, R.D. Herasymchuk et al.; edited by I.A. Hryhorova, L.I. Sokolova. – Kyiv : AUS Medicine Publishing, 2017. – 624p.

#### **Additional Literature:**

Bozhenko M.I., Negrych T.I., Bozhenko N.L., Negrych N.O. Headache. Educational manual.-K.: Medkniga Publishing House, 2019

#### **Informational resources:**

1. Clinical guidelines and other publications on neurosurgery (State Institution Romodanov Neurosurgery Institute of the National Academy of Medical Sciences of Ukraine)

<https://neuro.kiev.ua/uk/category/publishing-uk/>

2. Clinical guidelines on neurology. (Order of the Ministry of Health of Ukraine No. 487 dated 17.08.2007)

<https://zakon.rada.gov.ua/rada/show/v0487282-07#Text>

#### *Practical Class No. 2*

**Topic:** Open Traumatic Brain Injury (OTBI), Clinic, Diagnosis.

**Objective:** To acquire knowledge and skills in examining patients with open traumatic brain injury, learn to interpret the results of visualization studies, and form a clear understanding of the sequence of actions in managing a patient with OTBI.

**Key concepts:** Open traumatic brain injury, skull bone fracture, Glasgow Coma Scale, dislocation syndrome.



**Equipment:** Laptop, multimedia projector.

**Plan:**

1. Organizational activities (greetings, attendance check, announcement of the topic and goals of the session, motivation for higher education seekers regarding the study of the topic)
2. Control of the baseline knowledge (frontal questioning):
  - Anatomical and physiological features of the brain in different age groups.
  - Blood supply peculiarities of the brain, meninges, and skull bones; cerebrospinal fluid system.
  - Radiological examination methods in patients with OTBI.
  - Focal and general symptoms of OTBI.
  - Meningeal symptoms.

**Content:**

Clinical signs of open OTBI:

- a) Visualization of brain tissue or dura mater in the wound.
- b) Damage to soft tissues of the skull, accompanied by injury to the aponeurotic helmet (galea aponeurotica), where a diastasis - a gaping wound, is observed between the edges of the wound, and the bone surface can be seen in the depth.

Damage to the aponeurotic helmet is sufficient for infection of the intracranial cavity due to the existence of emissary veins (*venae emissariae*: *v. emissaria parietalis*, *v. emissaria mastoidea*, *v. emissaria condylaris*, *v. emissaria occipitalis*) and diploic veins (*venae diploicae*: *v. diploica frontalis*, *v. diploica temporalis anterior*, *v. diploica temporalis posterior*, *v. diploica occipitalis*) that are interconnected and connected to venous sinuses. The existence of anastomoses between the basin of the internal and external jugular veins means that the direction of blood flow depends on the pressure difference in the external jugular vein and inside the skull. Thus, the direction of blood flow in the specified anastomoses can change multiple times, allowing the suction of infected fluid components from the depth of the wound into the system of cerebral sinuses, i.e., inside the skull.

b) Fractures of the skull base containing air-filled sinuses; in this case, nasal (fracture of the body of the sphenoid bone, ethmoid bone) or ear (fracture of the petrous part of the temporal bone) cerebrospinal fluid (CSF) leakage is identified. In the case of a skull base fracture, there is often hemorrhage into the periorbital tissue, under the eyelid skin, and subconjunctivally, manifesting as the characteristic "raccoon eyes" symptom. Bilateral bruising (ecchymosis) in the medial orbits ("raccoon eyes") is a sign of a fracture in the anterior cranial fossa. Bruising or hematoma above the nipple-like projection is a sign of a possible fracture of the zygomatic arch or Battle's sign. If there is rhinorrhea (leakage of fluid from the nose), it is necessary to determine whether this fluid is CSF. For this purpose, the nasal hankie sign is used: if the leaking fluid is nasal secretion, the tissue touched by it becomes stiff after drying; if the fluid is CSF, the density of the tissue does not change significantly after drying. Nasal secretion contains significantly more proteins and proteoglycans than CSF.

**Open Traumatic Brain Injury (TBI)** is classified based on the damage to the dura mater as penetrating (with damage to the dura mater) or non-penetrating (integrity of the dura mater is preserved).

Diagnosis:

CT (Computed Tomography) of the brain.

Surgical treatment of a depressed skull fracture:

**Indications for surgery:**

Open (complex) fractures:

- a) Surgery is recommended for fractures with depression exceeding the thickness of the calvaria (skull cap) and those that do not meet the criteria for non-surgical treatment listed below.
- b) Conservative treatment is considered in cases of:
  - Absence of evidence (clinical or on CT) of penetrating TBI (CNS leakage, intradural pneumocephalus on CT...)

- Absence of significant intracranial hematoma
- Depression less than 1 cm
- Absence of involvement of the frontal sinus
- Absence of infection or significant wound contamination
- Absence of pronounced cosmetic deformity

Closed (simple) fractures with depression can be treated both surgically and conservatively.

Craniotomy Procedure:

Position: (depends on the location of the skull fracture).

Postoperative period: in the intensive care unit.

Procedure: surgical intervention in the area of the skull fracture involves restoring the "cover" of the brain, removing foreign material and damaged brain tissue (i.e., dead brain tissue), eliminating any intracranial hemorrhage, stopping any identified bleeding, and possible installation of intracranial pressure monitoring.

Position: (depends on the location of the skull fracture).

### **Clinical Cases:**

1. During a game, a boy threw a bottle, hitting the side of his 16-year-old friend's head. Within 30 seconds, the victim seemed deaf but fully recovered. Suddenly, he fell into a coma, experiencing decreased sensitivity on the opposite side. Upon arrival at the hospital after 25 minutes, there was no reaction to pain. Pulse: 40 beats/min, no arrhythmia. Arterial pressure on both arms: 170/110 mm Hg. No swelling of optic disc, but venous stasis at the bottom of the eye. Possible diagnosis:

- a) Epileptic seizure.
- b) Impaired thermoregulation.
- c) Increased intracranial pressure.**
- d) Weakness syndrome.
- e) Hydrocephalus formation.

2. During a game, a boy threw a bottle, hitting the side of his 16-year-old friend's head. Within 30 seconds, the victim seemed deaf but fully recovered. Suddenly, he fell into a coma. Decreased sensitivity on the opposite side was observed. Upon arrival at the hospital after 25 minutes, there was no reaction to pain. Pulse: 40 beats/min, no arrhythmia. Arterial pressure on both arms: 170/110 mm Hg. No swelling of optic disc, but venous stasis at the bottom of the eye. What is the fastest treatment for the young person within the next 4 hours:

- a) Craniotomy.**
- b) Antihypertensive therapy.
- c) Pacemaker implantation.
- d) Ventriculoperitoneal shunt.
- e) Lack of treatment for epileptic seizures.

3. A patient suffered a severe traumatic brain injury 3 months ago - an open fracture of the right frontal bone. After initial surgical treatment, the patient's condition improved. There was a defective skin and bone area in the right frontal region covered with granulations and a purulent process. What is the best treatment method for this patient:

- a) Conservative treatment.
- b) Plastic surgery of the skull defect.**
- c) Lumbar puncture.
- d) Dressings with ointments.
- e) Partial removal of brain tissue.

4. A patient was brought to the trauma department in a state of alcohol intoxication and psychomotor agitation. Subcutaneous hemorrhage with a constant fluid leak from the left external auditory canal was found in the left temporal region. The diagnosis of alcohol poisoning was established. Treatment was started 6 hours after hospitalization. Tonic spasms, mydriasis of the left pupil, and a deep coma state were noted. Possible diagnosis:

- a) Alcohol poisoning.
  - b) Concussion.
  - c) Basal skull fracture with epidural hematoma.**
  - d) Acute cerebral circulation disorder.
  - e) Meningoencephalitis.
3. Summary.

**Main Literature:**

1. Neurosurgery: textbook / [V.O. Pyatikop, I.O. Kutoviy, A.V. Kozachenko et al.]; edited by V.O. Pyatikop - Kyiv, VSV "Medicine", 2019. - 152 p.
2. Neurosurgery: textbook / [V.I. Tsimbalyuk, V.V. Medvedev, M.O. Marushchenko et al.]; edited by academician V.I. Tsimbalyuk. - 2nd edition, revised. - Vinnytsia: Nova Knyha, 2020. - 360 p.
3. Hryhorova I.A., Sokolova L.I., Herasymchuk R.D., Son A.S., et al. Neurology: Educational Manual / edited by I.A. Hryhorova, L.I. Sokolova - 3rd edition - Kyiv, VSV "Medicine", 2020. - 640 p.
4. Topical diagnosis of nervous system pathology. Diagnostic search algorithms. Shkrobot S.I., Saliy Z.V., Budarna O.Yu. Ukrmedknyha, 2018. - 156 p.
5. Methods of examination of a neurological patient: a tutorial / edited by L.I. Sokolova, T.I. Ilyash. Kyiv, 2020. - 144 p.
6. Emergency medicine. Emergency (ambulance) medical care: textbook / I.S. Zozulya, V.I. Bobrova, G.G. Roschin, etc. / edited by I.S. Zozulya. - 3rd edition, revised and supplemented. - Kyiv. - VSV "Medicine", 2017. - 960 p.
7. Negrych T.I., Bozhenko N.L., Matvienko Yu.Sh. Ischemic stroke: secondary inpatient care: a tutorial. Lviv: Danylo Halytsky Lviv National Medical University, 2019. - 160 p.
8. Handbook of Neurosurgery / Greenberg M.S. - Thieme, 2019. - 1784 p. ISBN 9781684201372
9. Neurology - Неврологія: textbook / I.A. Hryhorova, L.I. Sokolova, R.D. Herasymchuk et al.; edited by I.A. Hryhorova, L.I. Sokolova. – Kyiv : AUS Medicine Publishing, 2017. – 624p.

**Additional Literature:**

Bozhenko M.I., Negrych T.I., Bozhenko N.L., Negrych N.O. Headache. Educational manual.-K.: Medkniga Publishing House, 2019

**Informational resources:**

1. Clinical guidelines and other publications on neurosurgery (State Institution Romodanov Neurosurgery Institute of the National Academy of Medical Sciences of Ukraine)  
<https://neuro.kiev.ua/uk/category/publishing-uk/>
2. Clinical guidelines on neurology. (Order of the Ministry of Health of Ukraine No. 487 dated 17.08.2007)  
<https://zakon.rada.gov.ua/rada/show/v0487282-07#Text>

*Practical Class No. 3*

**Topic:** Spinal Cord Injury.

**Objective:** To learn to recognize the acute period of spinal cord injury (SCI), acquire skills in providing first aid, and understand the procedure for providing specialized medical care to SCI victims.

**Key Concepts:** Traumatic injuries to the vertebral column and spinal cord.

**Equipment:** Classroom, furniture, equipment:

- PC
- Multimedia projector
- Neurosurgical microscope Mitaka MM51YOH
- Surgical table RAPSODIA WITH MODULAR TABLEWORK
- Head holder DORO

- Electrosurgical unit BOWA ARC 400
- Ultrasonic surgical aspirator CUSA CI C7000
- Surgical aspirator Dominant Flex
- Neuro-monitoring system INOMED XPERT
- Neurosurgical instruments
- Steam sterilizer TICHE
- Steam sterilizer KRONOS B23 with ROSI
- Sealing machine
- Ultrasonic cleaner

**Plan:**

1. Organizational activities (greetings, attendance check, announcement of the topic and goals of the session, motivation of students to study the topic).
2. Control of basic knowledge (written work, written testing, frontal questioning, etc.):
  - Anatomical and physiological features of the spinal cord in different age groups.
  - Features of blood supply to the spinal cord, meninges; cerebrospinal fluid system of the spinal cord.
  - Radiological methods of examination in a patient with SCI.
  - Focal and general symptoms of SCI.
  - Groups of drugs for comprehensive SCI therapy: dehydration, hemostatics, hormonal.

**Content:**

Spinal cord trauma with spinal cord damage is considered one of the most severe injuries to the human body, leading to high mortality rates, reaching 60-70% in some forms of injuries, and resulting in severe disability among survivors, with many becoming disabled (I and II groups). The costs of treating and maintaining one patient with spinal cord and spinal cord injuries in the United States are estimated at up to two million dollars.

Every year in Ukraine, over 2000 people suffer from spinal cord and spinal cord injuries (SCI). Most of these cases involve young people. Spinal fractures with SCI or damage to its roots occur due to the direct application of mechanical force (direct injuries), falls from a height onto the legs or head, and excessive bending or extension of the spine (indirect injuries).

Open spinal injuries with a breach of skin integrity and closed injuries (without a breach of skin integrity) are distinguished. Open penetrating injuries occur with damage to the dura mater. Closed SCI is divided into concussion, contusion, and compression of the spinal cord.

**SC concussions** are characterized by reversible disturbances in the functions of the spinal cord, which completely disappear after treatment within the first five to seven days. Clinically, this manifests as segmental (muscle weakness) or sensory disorders in the area of the injured segments of the spinal cord. Occasionally, there may be conduction disorders such as delayed urination, decreased strength in distal segments, or sensory disorders in the form of hypoesthesia, etc. Thus, a concussion may manifest as partial impairment of spinal cord functions.

**SC contusions** are characterized by the occurrence of both reversible functional and irreversible morphological changes, such as contusion zones of ischemic or hemorrhagic nature. Morphological changes in contusions of the spinal cord can be primary or secondary due to disturbances in blood and cerebrospinal fluid circulation, often leading to a morphological rupture of the spinal cord. Clinically, this is manifested by a syndrome of partial or complete impairment of SC conduction. In contusions, neurological symptoms are persistent and usually do not regress completely. The dynamics of neurological symptoms are crucial.

Compression of the spinal cord can be caused by vertebral fractures, ligament and disc injuries, bleeding (hematomas), swelling, or combinations of these causes. Compression can be posterior, caused by a fracture of the arch, injury to the articular processes, anterior, caused by a fracture of the body, fragments of a damaged disc, thickening of the posterior longitudinal ligament), and internal (intramedullary hematoma), debris, swelling. After traumatic hematomas,

both subdural hematomas and epidural hematomas (hydromas) can have any localization. Often, compression of the spinal cord is caused by several factors, clinically characterized by a syndrome of partial or complete impairment of SC conduction.

Open injuries to the vertebral column and SC, like closed injuries, are divided by the level of injury into injuries of the cervical, thoracic, and lumbar-sacral segments of the spinal cord, as well as the roots of the cauda equina.

Additionally, a distinction is made between gunshot and non-gunshot injuries. Regarding the relation of the wound canal to the vertebral column and SC, the following types of injuries are distinguished:

- Transverse (cross the vertebral canals);
- Blind (end within the vertebral canal);
- Tangential (the wound canal passes, touching one of the walls of the vertebral canal, destroying them but not penetrating the canal);
- Non-penetrating (the wound canal passes through the bony structures of the spine without damaging the walls of the vertebral canal);
- Paravertebral (the wound canal passes near the spine without damaging it).

In case of damage to the dura mater, penetrating injuries occur, while without its damage, injuries are non-penetrating. The nature of the injury is determined during clinical and instrumental examinations, as well as surgical intervention.

Spinal injuries are classified into stable and unstable. Unstable injuries are caused by the rupture of posterior ligaments, the presence of fracture-dislocations of vertebrae, where repeated displacements of vertebrae with additional damage to the spinal cord and its roots are possible.

Unstable spinal injuries include all displacements (dislocations) of vertebrae, fractures and dislocations of articular processes, ruptures of intervertebral discs and their connections with damage to the vertebral bodies. All patients with spinal instability require therapeutic stabilization, splints, braces, and surgical methods.

Stable spinal injuries most often occur with wedge compression fractures of vertebral bodies and fractures of the arches of the proximal 4th lumbar vertebra, as well as fractures of transverse and spinous processes. The final instability of the fracture is determined by additional examination methods: functional spondylography, computed tomography (CT), and (or) magnetic resonance imaging (MRI).

Vascular post-traumatic disorders play a crucial role in the pathogenesis of spinal disorders, further developing in ischemic, less frequently hemorrhagic types. Even minor compression of the spinal cord causes disruption of cerebral blood flow. In adjacent segments under these conditions, hypoxic-ischemic phenomena intensify.

It is worth noting that nerve cells located in close proximity to the focus of injury are in a state of inhibition, i.e., in a functionally suppressed state. Prolonged functional impairment of the spinal cord's neuronal apparatus leads to the subsequent development of organic changes.

Injuries to the spine and spinal cord can be multiple (injuries in two different sections of the vertebral column) and associated (in case of injury to other organs and systems). In the case of fractures of the body, arches, and (or) articular processes, fractures of the vertebrae are interpreted as multiple.

**Closed spinal injuries include:**

- Injuries to the spine without impairment of spinal cord or its roots functions (uncomplicated).
- Injuries to the spine with impairment of spinal cord and its roots functions (complicated).
- Spinal cord injuries without traumatic changes to the vertebral column (concussion, contusion, hemorrhages).

**Characteristics of spinal injuries:**

- Ligamentous apparatus injuries.

- Vertebral body injuries (cracks, compression, fragmentary, transverse, longitudinal, explosive, detachment of articular processes).
- Fractures of the posterior semicircle of vertebrae (arches, spines, transverse, articular processes).
- Fracture-dislocations with damage to ligamentous-articular complex.
- Fractures of bodies and arches with or without displacement.

**By the localization of injuries:**

- Cervical
- Thoracic
- Lumbar
- Lumbosacral sections of the spine
- Injuries to the roots of the cauda equina.

The frequency of spinal injuries depends on the anatomical and physiological features of the spine, its connections, and mobility. Most often, V, VI, and VII vertebrae are injured in the cervical, XI and XII in the thoracic, and I and V in the lumbar sections. Accordingly, the spinal cord is damaged at these levels. In children, spinal cord injuries without radiological changes in the bone structure are quite common (18-20%).

Depending on the degree of spinal cord conduction disturbance, complete and partial spinal cord injuries are distinguished.

Signs of spinal cord injury (SCI) include: local pain and deformation, reduced or absent sensitivity below the level of injury, impaired movement in the upper and lower limbs (for lower section injury), in the lower limbs (for thoracic and lumbar section injuries), and dysfunction of pelvic organs. Pathological changes in SCI are caused by mechanical (immediately after trauma) factors. Circulatory disorders occur immediately after trauma and often progress, ischemia is more pronounced than hemorrhage, and secondary compressive damages may occur.

The assessment of the functional state of patients with spinal cord injury (SCI) should be conducted using the Frankel classification:

**Group A:** Patients with anesthesia and paralysis below the level of injury.

**Group B:** Patients with incomplete sensory loss below the level of injury, with no movement.

**Group C:** Patients with complete sensory loss, weak movements, but insufficient muscle strength for walking.

**Group D:** Patients with incomplete sensory loss below the level of injury, with movement and sufficient muscle strength for walking with assistance.

**Group E:** Patients without sensory or motor deficits below the level of injury.

Currently, the organization of urgent and specialized medical care for SCI victims in Ukraine is not well-established. Many patients are delayed in regional and local hospitals, where trophic disorders and infectious-inflammatory complications develop soon after the injury. As a result, surgeries need to be postponed, leading to negative consequences.

The primary goal of the medical staff providing assistance for injuries is to prevent further damage, prevent secondary changes due to compression and ischemia of the spinal cord, and maintain optimal conditions for its functioning.

**Treatment** of patients with SCI begins at the pre-hospital stage. The main task at this stage is not to worsen the patient's condition during transportation to the hospital. Pre-hospital care includes preserving or normalizing vital functions (breathing, hemodynamics), immobilizing the spine, administering neuroprotective agents such as methylprednisolone.

Patients with SCI are recommended to be transported directly to specialized neurosurgical or trauma departments of regional hospitals. A neurosurgeon must examine the patient, and diagnostic procedures such as spondylography, CT, or MRI of the spine are performed.

All patients without CT or MRI are prescribed a lumbar puncture, during which cerebrospinal fluid pressure is measured, and cerebrospinal fluid dynamic tests are conducted to

detect the patency of subarachnoid spaces. The disruption of their permeability indicates spinal cord compression, requiring immediate decompression. In the case of cervical spine trauma, cerebrospinal fluid dynamic tests have relative value, as the patency of subarachnoid spaces is often preserved with posterior or anterior compression of the spinal cord. If possible, a CT or MRI is performed.

The treatment of patients with SCI is incredibly complex, long-term, and is carried out directly during the patient's examination. In the case of spinal shock, atropine, dopamine, saline solutions (3-7% sodium chloride solution), reopolyglukin, hemodez are administered, and lower limbs are bandaged. The conducted examinations indicate the need for the administration of large doses (30 mg/kg body weight).

Methylprednisolone (Solumedrol) intravenously within the first 8 hours – initially 5.0 mg/kg every 4 hours for 48 hours. Methylprednisolone acts on the injured spinal cord by:

Inhibiting lipid peroxidation caused by free radicals.

Inhibiting lipid hydrolysis.

Maintaining blood supply to the spinal cord tissues and aerobic energy metabolism.

Improving the entry of calcium into cells (prolongs the activation of neutral proteases – supports the integrity of neurofilaments).

Enhancing the excitability of neurons and impulse conduction.

Methylprednisolone, as an inhibitor of lipid peroxidation, is significantly more effective than regular prednisolone or dexamethasone. To reduce brain swelling, hypertonic saline solutions are used alongside. Vitamin E (5 ml intramuscularly 2-3 times a day) is used as an antioxidant. To increase the brain's resistance to hypoxia, Difenin, Seduxen, and Relanium are prescribed.

In case of a cervical spine injury, immediate skeletal traction from the occipital protuberances or application of halo devices is performed, which reduces spinal cord compression in up to 80% of cases, or closed reduction of fracture-dislocations is carried out.

Literature data and our observations indicate the necessity of early decompression of the spinal cord in case of its compression. Early decompression of the spinal cord is a mandatory condition for successful treatment of patients with spinal cord injury.

Surgical interventions in spinal cord injuries are indicated in 68% of cases. The decompression of the spinal cord operation is completed with stabilization of the spine by anterior or posterior spondylodesis. Additionally, if necessary, a reconstructive stabilizing operation may be performed at specialized centers.

**Contraindications** to surgery are shock, combined with injuries that need to be energetically and quickly eliminated. The following indications for surgery should be followed:

- Deformation of the spinal cord canal, determined during X-ray examination, CT, or MRI, indicating spinal cord compression or narrowing of the spinal cord canal by 30% or more.
- Presence of bone or muscle-tissue fragments in the spinal cord canal.
- Partial or complete blockage of cerebrospinal fluid pathways.
- Progression of secondary respiratory failure due to ascending linear spinal cord swelling.
- Clinical and angiographic data indicating compression of major brain vessels (anterior artery syndrome, venous outflow complications).
- Instability of the vertebral-motor segment threatening the development of neurological symptoms.

The choice of the spinal cord decompression method depends on the nature of the spinal cord injury and the level of compression. Early spinal cord decompression is mandatory and can be achieved by repositioning, corporectomy, laminectomy (lateral, ventral-lateral, ventral), depending on the nature of the spine injury. It is essential to note that spinal cord decompression should be complete. The operation should end with spinal cord revision and dura mater plastic surgery.

Intercorporal or interspinous, or interlaminar spondylodesis is usually performed. Refusal of early operations in case of spinal cord compression is harmful and unacceptable for the patient,

as it leads to multiple organ failure: bedsores and infectious-inflammatory processes in the urogenital and respiratory systems appear early. Consequently, surgical intervention is postponed, prolonging the duration of treatment and delaying the rehabilitation period.

In case of trauma to the cervical spinal cord, compression leads to increased ischemia and brain swelling, resulting in the most widespread swelling of the spinal and medullary cord, as well as respiratory disturbances.

Adequate elimination of spinal cord compression and vertebral deformity in the early stages after injury, reliable internal fixation of the damaged spinal segment, and effective prevention of bedsores and urological complications ensure a favorable course of the disease. Subsequently, comprehensive rehabilitation for such patients should be timely.

**Algorithm for examination and sequence of assistance provision in the acute period of spinal cord injury (SCI):**

- I. 1) Hospitalization in the neurosurgical department;
- 2) Assessment of the condition according to Frankel;
- 3) Complete blood count and urine analysis, biochemical blood analysis, determination of blood type and Rh factor;
- 4) Spondylography;
- 5) Lumbar puncture with cerebrospinal fluid examination, myelography;
- 6) If possible, perform MRI or CT. Consultations with a therapist and urologist.

II. Normalization of breathing and hemodynamics, catheterization of the urinary bladder, central vein catheterization. In case of spinal shock, lower limbs are immobilized, atropine is administered, and hypertonic (3-7%) saline solution is infused. In the presence of spinal cord compression, early decompressive-stabilizing surgery is indicated (within the first 6-12 hours). Within the first 8 hours, administer methylprednisolone at a dose of 30 mg/kg/body weight as a single dose, then 15 mg/kg after 2-4 hours, followed by 5 mg/kg every 4 hours for 2 days. Vitamin E – 5 ml intramuscularly, Difenin – 500 (Relanium, Seduxen, Thiopental Sodium, Sibazon), Nimotop, broad-spectrum antibiotics, patient repositioning every 30-40 minutes, analgesics, neuroprotectors, magnesium sulfate, piracetam 10-12 g/day, Cerebralizin – 15-25 ml intravenously in 200 ml isotonic NaCl solution, symptomatic treatment. After 8-12 weeks, transfer the patient to rehabilitation in the neurological department or rehabilitation centers.

**Combined spine and spinal cord injury.**

Hospitalization in the neurosurgical department, assessment of the condition according to Frankel. Complete blood count and urine analysis, biochemical blood analysis, determination of blood type, Rh factor, spondylography, lumbar puncture with examination of cerebrospinal fluid dynamics, myelography, if possible, MRI or CT. Consultations with a therapist, urologist. Clarification of the nature and localization of the extravertebral component.

In the case of hypovolemic shock – shock therapy. Urgent surgeries for hemothorax, damage to internal organs. Normalization of breathing, hemodynamics, catheterization of the urinary bladder, central vein. In the case of spinal shock – immobilization of the lower limbs, administration of atropine, hypertonic (3-7%) saline solution. In the presence of spinal cord compression – early decompressive-stabilizing surgery. In the first 8 hours – methylprednisolone at a dose of 30 mg/kg as a single dose, after 2-4 hours – 15 mg/kg, then 5 mg/kg every 4 hours for 2 days. Vitamin E – 5 ml intramuscularly, Difenin – 500 (Relanium, Seduxen, Thiopental Sodium, Sibazon), Nimotop, broad-spectrum antibiotics, patient repositioning every 30-40 minutes, analgesics, neuroprotectors, magnesium sulfate, piracetam, Yumex Cerebralizin – 15-25 ml intravenously in 200 ml isotonic sodium chloride solution, protecting the spinal and brain from secondary post-traumatic changes, symptomatic treatment. In case of shock – shock therapy, followed by decompressive-stabilizing surgery. As early as possible – decompression of the spinal cord and stabilization of the spine. Early rehabilitation at the rehabilitation center. Patients with SCI have a significant risk (up to 50%) of thromboembolic complications (deep vein thrombosis of the calf and pulmonary embolism). Prevention of these complications includes bandaging of the lower limbs, massage, activation of patients, administration of Fraxiparine at 0.3 ml per day



subcutaneously on the anterior-lateral surface of the abdomen for 7 days, from the 6th day, switch to Ticlid – 1 tablet twice a day during meals for 2-3 months. In case of prolonged bed rest, thromboembolism prophylaxis is carried out at all stages of traumatic spinal cord injury.

### **Surgical tactics in the treatment of complicated and remote spinal trauma.**

After severe SCI, about 80% of patients survive. These patients require medical care at all stages of traumatic spinal cord injury. In the remote period of SCI, changes are observed not only at the site of injury but also in distant areas. To diagnose the level, degree, and length of spinal cord and spine damage in the remote period after injury, contrast X-ray, radionuclide, and immunological examinations, as well as MRI, are used. These examinations should be conducted dynamically during the course of traumatic spinal cord injury.

After diagnostic examination, a staged treatment plan for spinal patients is developed. Thus, obvious impairments of the cardiovascular, respiratory, immune, and urinary systems, digestive tract, require appropriate correction, which can be identified as the 1st stage of therapeutic methods. At this stage, it is necessary to prepare patients for reconstructive surgeries on the spine and spinal cord if indicated. Indications for surgery include deformity of the spinal canal and compression of the spinal cord, which hinder the implementation of further rehabilitation methods. The 2nd stage of corresponding treatment in the remote period of SCI should include operative interventions of decompressive-stabilizing nature on the spine and reconstructive ones on the spinal cord according to the indicators. Secondary trauma to the spinal cord, which inevitably occurs during surgical interventions, will lead to edema, hypoxia, and impaired liquor circulation of nervous structures. All methods aimed at reducing and eliminating these negative phenomena constitute the 3rd stage of treatment. Not all patients show the restoration of impaired functions after the 3rd stage of treatment, so such patients continue to require long-term treatment (medication, functional and physiotherapeutic, prosthetic-orthopedic assistance). All these methods constitute the 4th stage of treatment.

At the 1st stage, the general condition of spinal patients is assessed (function of the cardiovascular, respiratory, urinary, and other systems). Patients with inflammatory processes in the respiratory tract are prescribed detoxification and anti-inflammatory therapy, broad-spectrum antibiotics. In case of inflammation in the urinary system, the species composition and dynamics of urine microflora, as well as the sensitivity of microorganisms to antibiotics, are determined. Antibiotics corresponding to the antibioticogram are applied. Patients need to flush the urinary bladder with disinfectant solutions (Bifuran, Furacilin) 1-2 times a day. At the end of the second irrigation, a solution of Collargol (Protargol) is introduced into the urinary bladder for 30-40 minutes.

At this stage, prevention and treatment of trophic skin disorders (bedsores, etc.) are carried out. Patients require constant care (changing body position every 2-3 hours, rubbing the skin with camphor alcohol, gentle massage). Special beds with rotating frames, special mattresses, soft pads (preferably with straw) are widely used.

Comprehensive treatment includes the use of detoxification, dehydration, anti-inflammatory, general strengthening therapy, as well as drugs that improve blood and lymph circulation. Ultraviolet irradiation of bedsores with suberythral doses (1-3 biodoses) and UHF in weak thermal doses are performed. Local and general laser therapy and electrical stimulation of bedsores are widely used to accelerate the preparation of wound surfaces for subsequent surgical treatment.

Para-articular ossification in the area of hip and knee joints significantly complicates the further rehabilitation of spinal patients. The goal of rehabilitation is set as follows: if a patient has partial impairment of spinal cord functions and there is hope for the restoration of movements in the lower limbs, joint mobilization is used to allow the patient to move independently, maneuver in a wheelchair (i.e., sit). The system of treatment of para-articular ossification includes resection of heterotopic ossification and arthroplasty.

The condition of the immune system is of great importance for further rehabilitation. Cellular and humoral immunity is most reduced at 2-3 months after the injury. Therefore,

performing plastic surgeries on the spine and spinal cord during this period puts spinal patients in quite complex conditions. Performing the operation 2-3 months after the injury is not desirable because poor results are possible.

In the presence of purulent complications and toxic-septic conditions to eliminate secondary immunodeficiency, T-activin (1 ml; 0.1% solution subcutaneously or intramuscularly every other day, total dose – 500 mcg) is used in combination with immunoglobulin (25 ml intravenously with an interval of 24 and 48 hours). The total dose for the course of treatment is 75 ml.

The use of laser irradiation of blood and cerebrospinal fluid has a positive effect on the course of the disease. Improvement in general condition, appetite, regeneration, and cleansing of bedsores is observed after 3-4 treatment sessions, and body temperature decreases.

In the case of stabilization of the general condition of the patient (i.e., correction of respiratory, cardiovascular, urinary, and immune system disorders, digestive tract disorders), elimination of trophic skin disorders, and mobilization of large joints of the lower limbs, it is necessary to proceed to the second stage of treatment – reconstruction of the spinal canal.

In case of compression of the spinal cord by anterior structures (vertebral bodies and discs) in the cervical spine and blockage of the subarachnoid space, determined by X-ray radionuclide studies on MRI, anterior spinal cord decompression is performed with subsequent corpectomy with a bone graft.

In case of spinal cord compression in the cervical spine by posterior elements, decompressive laminectomy is performed.

In the thoracic spine, depending on the nature of the spinal cord compression, anterior, posterior, or total decompression is performed.

In the early postoperative period, correction of disorders of the cardiovascular, respiratory, immune, and urinary systems, digestive tract disorders, and metabolic and electrolyte balance disorders in spinal patients is carried out. It is essential during this period to prevent and treat hypoxia and tissue edema of the spinal cord. It is important to preserve the functioning of those structures of the spinal cord that have been affected but can still regain their function.

It is necessary to use antispasmodics, anticoagulants, anti-edema therapy, nootropics, cerebrolysin at doses of 15-25 ml intravenously for 20-25 days, antihypoxants, and antioxidants.

Not all patients experience the restoration of lost functions after the three stages of treatment. Therefore, prolonged medication and physiotherapeutic treatment are continued, along with providing prosthetic and orthopedic assistance. All these methods constitute the fourth stage. Medications such as GABAergic substances (nootropil, cerebrolysin - at doses of 15-25 ml intravenously), anticholinesterase drugs (galantamine, prostigmine, etc.), bioenergetic metabolism activators (ATP riboxin, cocarboxylase, vitamins of group B), anabolic hormones (retabolil, nerobol), tissue therapy (aloe extract, plasmol, cartilage) are prescribed.

Vascular drugs include cavinton, lisinon, actovegin, cinnarizine, euphyllin, papaverine, ticlid, trental, etc. To reduce pain and spastic syndrome, ganglioblockers, prostaglandin inhibitors, mydocalm, sodium oxybutyrate are applied.

In the rehabilitation of spinal patients, the normalization of pelvic organ functions and the establishment of controlled acts of urination and defecation play a crucial role.

In the remote period after spinal cord injury, measures are mandatory for preventing thromboembolic complications (patient activation massage, fraxiparin, ticlid, etc.).

#### **Medico-social expertise.**

In the case of spinal concussion, treatment continues, on average, for up to 3 weeks. The total duration of temporary disability is up to 2-3 months, taking into account the possibility that the connective tissue apparatus may have been damaged at the time of the spinal concussion.

Individuals engaged in physical labor are recommended for light-duty work (up to 1 year). In some cases, they are transferred to disability groups 3 (up to 1 year).

**Contusion of the spinal cord** often accompanies fractures of the bony skeleton (vertebral bodies, arches, articular processes). The expert assessment depends on the degree and nature of

bone damage and spinal cord injury. Fractures of the vertebral bodies combined with fractures of the articular processes are unstable. In this case, the duration of temporary disability is up to 7 months, necessary for the consolidation of cancellous bone.

**Mild spinal cord contusion:** duration of inpatient treatment - up to 1 month, after discharge - outpatient treatment of spinal functions. Sometimes patients are transferred to disability group 3 (up to 1 year). The terms of restoration of lost functions are 3-4 weeks.

**Moderate spinal cord contusion:** duration of inpatient treatment is 1.5-2 months. In case of a favorable clinical course, outpatient treatment by sick leave is prescribed for up to 8 months. Then disability group 3 is assigned, less often group 2, after specifying the prognosis of the traumatic disease of the spinal cord. The restoration of lost functions begins from 3-4 weeks, lasting for a month or a year.

**Severe spinal cord contusion:** duration of inpatient treatment up to 3-4 months. The onset of restoration of impaired functions is from 3-4 months, but it continues for years and does not always result in complete recovery. After inpatient treatment, disability group 1 is assigned initially for 1 year, pending clarification of the prognosis of the traumatic disease of the spinal cord. Subsequently, disability for these patients may be extended up to 3 years, and only after 5 years of observation and establishing the unpromising recovery of impaired functions, permanent disability may be recommended.

In the case of hematomyelia, the clinical and labor prognosis is unfavorable, so temporary disability is extended up to 4 months. Disability groups 1 and 2 are often assigned to these patients for up to 1 year. Subsequently, after specifying the clinical prognosis, these terms may be extended or assigned indefinitely.

In case of hemorrhages into the spinal canal with adhesive processes in the cauda equina, temporary disability is extended up to 4-6 months. After that, disability group 3 is often assigned based on residual phenomena, less often group 2 (with arachnoiditis, cauditis, or deep paralysis with pain syndrome). Dynamic observation and treatment are carried out for 3-5 years, after which the disability group may be assigned indefinitely.

All victims of spinal cord injury require medical and social rehabilitation. Early medical rehabilitation begins in the acute period of injury in the hospital, where urgent surgery and treatment aimed primarily at complications (bedsores, contractures, urinary fistulas, etc.) are carried out. In the acute stage of traumatic spinal disease, patients are transferred to a specialized rehabilitation department - the second stage lasts for 1-2 months.

Afterward, the individuals affected are sent for sanatorium and resort treatment to specialized sanatoriums (such as Saky, Sloviansk in Donetsk Oblast, Solonyi Liman in Dnipropetrovsk Oblast, etc.).

The fourth stage of rehabilitation is vocational placement. Patients are provided with the opportunity to work in specially created conditions.

#### **Clinical Tasks:**

1. An 18-year-old boy is brought to the emergency department after a diving accident. He is conscious and alert, cranial nerves are intact, he can move his shoulders but cannot move his arms and legs. Superficial and pain sensation is absent from the level of C7. The correct approach to treatment includes:

- a) Naloxone hydrochloride
- b) Intravenous methylprednisolone**
- c) Oral dexamethasone
- d) Phenytoin 100 mg
- e) Hyperbaric oxygen therapy

2. A 28-year-old patient suffered a severe spinal cord injury while diving headfirst into water. On examination, tetraparesis, sensory disturbances in the upper and lower extremities, dysfunction of pelvic organs, and urinary retention are observed. What pathology can be suspected in the patient? What diagnostic methods are most informative for establishing a diagnosis?

- a) Vertebral column injury with spinal cord involvement**

- b) Traumatic brain injury
- c) Peripheral nervous system injury
- d) Lumbar puncture
- e) X-ray

**f) CT, MRI**

3. A 40-year-old patient is diagnosed with a severe spinal cord injury due to a road traffic accident: fracture-dislocation of vertebrae C6-C7, compressive-burst fracture of vertebrae C6-C7. Decompression surgery of the spinal cord and spondylolisthesis using a titanium fixation system was performed. What preventive measures should be taken for the patient?

- a) Trophic disorders
- b) Infectious-inflammatory processes
- c) Dysfunction of pelvic organs
- d) Thromboembolic complications
- e) **All of the above**

4. A patient is stabbed during a brawl. During the examination, the patient complains of pain in the thoracic spine, weakness in the left leg, and numbness in the right leg. Objectively: a 2 cm incised wound paravertebrally in the area of Th3 spine on the left, monoparesis of the left leg, decreased sensitivity to pain and temperature on the right below the level of the Th5 segment. What pathological condition can be suspected in the patient?

ANSWER: Brown-Séquard syndrome

3. Summary.

**Main Literature:**

1. Neurosurgery: textbook / [V.O. Pyatikop, I.O. Kutoviy, A.V. Kozachenko et al.]; edited by V.O. Pyatikop - Kyiv, VSV "Medicine", 2019. - 152 p.
2. Neurosurgery: textbook / [V.I. Tsimbalyuk, V.V. Medvedev, M.O. Marushchenko et al.]; edited by academician V.I. Tsimbalyuk. - 2nd edition, revised. - Vinnytsia: Nova Knyha, 2020. - 360 p.
3. Hryhorova I.A., Sokolova L.I., Herasymchuk R.D., Son A.S., et al. Neurology: Educational Manual / edited by I.A. Hryhorova, L.I. Sokolova - 3rd edition - Kyiv, VSV "Medicine", 2020. - 640 p.
4. Topical diagnosis of nervous system pathology. Diagnostic search algorithms. Shkrobot S.I., Saliy Z.V., Budarna O.Yu. Ukrmedknyha, 2018. - 156 p.
5. Methods of examination of a neurological patient: a tutorial / edited by L.I. Sokolova, T.I. Ilyash. Kyiv, 2020. - 144 p.
6. Emergency medicine. Emergency (ambulance) medical care: textbook / I.S. Zozulya, V.I. Bobrova, G.G. Roschin, etc. / edited by I.S. Zozulya. - 3rd edition, revised and supplemented. - Kyiv. - VSV "Medicine", 2017. - 960 p.
7. Negrych T.I., Bozhenko N.L., Matvienko Yu.Sh. Ischemic stroke: secondary inpatient care: a tutorial. Lviv: Danylo Halytsky Lviv National Medical University, 2019. - 160 p.
8. Handbook of Neurosurgery / Greenberg M.S. - Thieme, 2019. - 1784 p. ISBN 9781684201372
9. Neurology - Неврологія: textbook / I.A. Hryhorova, L.I. Sokolova, R.D. Herasymchuk et al.; edited by I.A. Hryhorova, L.I. Sokolova. – Kyiv : AUS Medicine Publishing, 2017. – 624p.

**Additional Literature:**

Bozhenko M.I., Negrych T.I., Bozhenko N.L., Negrych N.O. Headache. Educational manual.-K.: Medkniga Publishing House, 2019

**Informational resources:**

1. Clinical guidelines and other publications on neurosurgery (State Institution Romodanov Neurosurgery Institute of the National Academy of Medical Sciences of Ukraine)

<https://neuro.kiev.ua/uk/category/publishing-uk/>

2. Clinical guidelines on neurology. (Order of the Ministry of Health of Ukraine No. 487 dated 17.08.2007)

<https://zakon.rada.gov.ua/rada/show/v0487282-07#Text>

*Practical Class No. 4*

**Topic:** Traumatic Injuries of the Peripheral Nervous System

**Objective:** To acquire knowledge and skills in the diagnosis and treatment of traumatic injuries to peripheral nerves. To learn how to provide qualified medical assistance at different stages, determine indications for surgical treatment using microsurgical techniques.

**Key Concepts:** Compressive-ischemic (tunnel) neuropathies, basic principles and methods of operative interventions for peripheral nerve injuries depending on the type, level, and mechanism of damage, principles of postoperative patient care.

**Equipment:** Classroom, furniture, equipment:

PC

Multimedia projector

Neurosurgical microscope Mitaka MM51YOH

Surgical table RAPSODIA WITH MODULAR TABLEWORK

Head fixation device DORO

Electrosurgical unit BOWA ARC 400

Ultrasonic surgical aspirator CUSA CI C7000

Surgical aspirator Dominant Flex

Neuromonitoring system INOMED XPERT

Neurosurgical instruments

Steam sterilizer TICHE

Steam sterilizer KRONOS B23 with ROSI

Sealing machine

Ultrasonic cleaner

**Plan:**

1. Organizational activities (greetings, attendance check, announcement of the topic and goals of the session, motivation of students to study the topic).

2. Control of basic knowledge (written work, written testing, frontal questioning, etc.):

- Anatomy and physiology of the peripheral nervous system
- Concepts of "tunnel" syndromes
- Mechanism of peripheral nervous system injury in trauma

**Content:**

Peripheral nerve injuries are classified into open and closed. The former includes: incised, chopped, punctured, torn, crushed, and lacerated wounds; the latter includes contusion, bruising, compression, stretching, rupture, and dislocation. From a morphological standpoint, a complete and partial anatomical rupture of the peripheral nerve is distinguished.

Nerve injuries manifest as a complete or partial block of conductivity, leading to varying degrees of motor, sensory, and autonomic nerve function impairment. In cases of partial nerve damage, symptoms of irritation in the sensitivity and autonomic reaction sphere may occur (hyperpathia, causalgia, hyperkeratosis).

**Neuropraxia** (praxis – action, apraxia – inability, inactivity) is a temporary loss of physiological function – nerve conductivity – after mild injury. Anatomical changes primarily involve the myelin sheaths, and clinically, predominantly motor disturbances are observed. Sensory side effects, such as paresthesia, are mainly noted on the sensory side. Vegetative disorders are absent or not pronounced. Recovery occurs within a few days. This form corresponds to a concussion (according to Doynikov).

**Axonotmesis** is a more complex form of injury resulting from compression or stretching. Anatomical continuity of the nerve is preserved, but morphologically, Wallerian degeneration occurs, with the precise location of the injury being crucial.

Neuropraxia and axonotmesis are treated conservatively.

**Neurotmesis** signifies a complete nerve rupture or severe damage with a rupture of individual nerve bundles, making regeneration impossible without surgical intervention.

The process of nerve fiber decay described by the French scientist Waler in 1850 is now referred to as Wallerian degeneration. The reverse process – nerve regeneration – occurs under the condition of precise matching of bundles (sensory and motor) of both nerve segments, proceeding quite slowly (at a rate of approximately 1 mm per day).

The clinical and electrophysiological picture of peripheral nerve injuries significantly depends on the time elapsed since the trauma. Considering the peculiarities of Wallerian degeneration, this period is advisable to divide into two periods: acute and distant.

The acute trauma period is characterized by the decisive importance of factors related to trauma as a whole rather than specific manifestations of nerve damage. This period lasts 15-20 days, during which even after a complete rupture, the distal segment retains the ability to conduct, making most electrophysiological examination results in the acute period less informative.

The distant trauma period is characterized by the formation of basic pathomorphological changes in nerve fibers caused by Wallerian degeneration and begins from the third to fourth week after the trauma.

The most informative sign of nerve damage during the acute trauma period is sensory impairment in the innervation zone.

The best treatment results are achieved when adequate surgical treatment is performed on the day of trauma. However, conducting surgery is only possible under certain conditions: availability of trained specialists, necessary equipment, including microsurgical instruments, suture material, magnification optics, proper anesthesiological support, and the absence of complications from the wound and the patient's somatic condition.

Conducting operations on nerves in the absence of the mentioned conditions generally leads to unsatisfactory outcomes. Therefore, in general surgical facilities, when dealing with peripheral nerve injuries, it is sufficient to: control bleeding, implement anti-infective measures, suture the wound, and subsequently refer the patient to the microsurgery department.

The diagnosis of nerve injury is based on general clinical data and the results of electrophysiological studies. The location of the limb injury with neurological symptoms allows suspicion of peripheral nerve damage.

#### **Diagnosis:**

Patient history largely helps specify the nature and mechanism of nerve damage. Examination of the injured limb and localization of the wound enable conclusions about which nerves are affected and refine the degree of damage.

The primary function of a nerve is conduction. Nerve damage manifests as a syndrome of complete or partial impairment of its functions. The degree of loss is determined by symptoms of movement loss, sensory disturbances, and autonomic nerve function.

Motor disturbances in complete injuries of major nerves or limbs present as peripheral muscle paralysis (loss of tone, areflexia, atrophy). However, when assessing motor disorders, the possibility of compensatory strengthening of synergistic muscle function should be considered, masking the manifestations of lost motor functions.

Sensory examinations often play a crucial role in diagnosing nerve damage. Anesthesia in the innervation zone is characteristic of an anatomical rupture of the nerve trunk or complete dissection.

Trophic disorders in nerve injuries manifest as disruptions in sweat secretion (anhidrosis, hypo- or hyperhidrosis), hyperthermia in the innervation zone immediately after trauma, followed by temperature decrease, changes in hair growth in the form of partial alopecia (hypotrichosis) or increased growth (hypertrichosis), skin thinning, and disappearance of folds.

Palpation and percussion along the nerve trunk aid in specifying the level and type of damage. In the acute trauma period, tapping at the level of damage causes referred pain. In a more distant term, palpation allows the identification of neuroma in the central segment of the injured

nerve. The appearance of tenderness during palpation and percussion along the course of the peripheral segment of the injured nerve is a characteristic sign of nerve regeneration after suturing (Tinel's sign).

**Treatment:**

The type and degree of nerve damage determine the further treatment strategy: conservative or surgical.

The primary method for treating traumatic peripheral nerve injuries is surgical. Surgical treatment aims at:

Neurolysis – releasing the nerve from surrounding tissues causing compression (hematoma, scars, bone fragments, callus). The procedure involves cautiously isolating the nerve from surrounding scar tissue, which is then removed, avoiding damage to the epineurium if possible.

Internal neurolysis, or endoneurolysis – isolating nerve bundles from intraneural scars after epineurial incision, aiming to decompress the bundles and clarify the nature of fiber damage. To prevent the formation of new adhesions and scars, the nerve is placed in a new bed prepared from undamaged tissues, and meticulous hemostasis is performed.

**Nerve suturing** - Indications for nerve suturing include complete or partial nerve rupture with a significant impairment of conductivity. Primary nerve suturing, performed simultaneously with primary surgical wound treatment, and delayed suturing, performed 2-4 weeks after wound treatment, are distinguished. Modern surgical procedures on peripheral nerves require an operating microscope, microsurgical instruments, and suture materials ranging from 6/0 to 10/0. During epineurial suturing, precise alignment of the transverse cuts of the central and peripheral segments of the severed nerve trunk is necessary.

In the last decade, with the development of microsurgery, perineural (interfascicular) suturing is also used for nerve end anastomosis. It is possible to combine these two suturing techniques. Bundle matching and suture placement are performed exclusively under a microscope. The procedure is concluded with immobilization of the limb using a plaster cast in a state where the nerve experiences the least tension and pressure. Immobilization is maintained for two to three weeks.

**Questions for self-assessment.**

- What are open and closed traumatic injuries to the peripheral nervous system?
- Name the symptoms of traumatic injury to the peripheral nervous system.
- Based on what examinations is the diagnosis of traumatic injury to the peripheral nervous system made?
- What surgical procedures are used in the treatment of traumatic injury to the peripheral nervous system?

**Materials for self-assessment of training quality**

Test tasks for self-assessment.

1. The nuclei of which cranial nerves are damaged in Weber's alternating syndrome?

A. Abducens

B. Accessory

**C. Oculomotorius**

D. Trigeminal

E. Glossopharyngeal

2. What is characteristic of central paralysis of the facial nerve?

A. Loss of pupillary reflex

B. Trophic disorders of the muscles of the tongue

C. Damage to the chewing group of muscles

**D. Damage to the mimic muscles of the lower half of the face**

E. Damage to the mimic muscles of the entire half of the face

3. A 42-year-old patient is diagnosed with a spiral fracture of the middle third of the shaft of the right humerus. In addition to the "classic" picture of a fracture in this localization, there is

an inability to actively extend the wrist, actively abduct the 1st finger, and loss of sensitivity on I-II and partially III fingers. Determine the adequate treatment strategy.

**A. Open reposition, nerve revision, stabilization of fragments**

B. Closed single-stage reposition with subsequent external immobilization

C. Closed reposition and fixation of fragments using external fixation devices

D. Skeletal traction

4. After a stab wound to the anterior forearm, atrophy of the muscles of the thenar eminence with flattening of the palm ("monkey hand"), hypoalgesia, and hyperpathia in the area of the palm surface of the I-III fingers and the corresponding part of the palm are observed. Which nerve is damaged?

A. Ulnar

B. Radial

C. Medial cutaneous nerve of the brachium

D. Musculo-cutaneous

**E. Median**

5. Patient M., 27 years old, who had been in the cold for a long time, noticed after sleep the inability to close his left eye, tearing from it, hyperacusis, and taste disturbance on the anterior 2/3 of the tongue. Examination revealed smoothing of the left nasolabial fold, lowering of the left corner of the mouth, absence of the left corneal reflex, and the "sail" symptom on the left. What is your diagnosis?

A. Neuralgia of the left trigeminal nerve

**B. Neuritis of the left facial nerve**

C. Neuritis of the right facial nerve

D. Tumor of the left cerebellopontine angle

E. Tumor of the right cerebellopontine angle

6. While opening a radial tenobursitis, the surgeon inadvertently extended the incision into the proximal third of the extensor tendon, as a result of which the patient lost the ability to oppose the first finger. Which nerve branch did the surgeon cut?

A. Posterior interosseous

B. Ulnar

C. Anterior interosseous

D. Radial

**E. Median**

7. In a patient with a fracture of the diaphysis of the humerus. Which nerve may be damaged?

A. Ulnar

B. Radial

C. Medial cutaneous nerve of the arm

D. Musculo-cutaneous

E. Median

8. In a patient after a trauma to the forearm, there is a violation of the function of the muscles of the flexor group of the lateral group. Which nerve is damaged?

A. N. cutaneus antebrachii

**B. N. medianus**

C. N. musculocutneus

D. N. radialis

E. N. ulnaris

9. Which muscle does not participate in the formation of the foramen quadrilaterum?

**A. M. biceps brachii**

B. M. subscapularis

C. M. teres major

D. M. teres minor



E. M. triceps brachii

10. In a patient, there is a disturbance of sensitivity on the lateral surface of the forearm. Which nerve is damaged?

A. N. Axillaris

B. N. medianus

**C. N. musculocutaneus**

D. N. radialis

E. N. ulnaris

11. In a patient, there is a dysfunction of the sublingual salivary gland. Which nerve enhances its secretion?

A. N. auricularis major

B. N. auricularis minor

C. N. petrosus major

**D. N. petrosus minor**

E. N. petrosus profundus

12. Patient A., brought by an ambulance to the hospital with a cut wound of the forearm. Upon examination, the absence of all types of sensitivity on the surface of the palm of the 1st, 2nd, 3rd, and radial half of the 4th finger of the hand is established. Active flexion of the 2nd and 3rd fingers is impossible. Indicate the correct diagnosis.

A. Damage to the ulnar nerve and flexor tendon of the 2nd and 3rd fingers

B. Damage to the radial nerve

C. Damage to the radial nerve and flexor tendons of the 2nd and 3rd fingers

**D. Damage to the median nerve and flexor tendons of the 2nd and 3rd fingers**

E. Damage to the flexor tendons of the 2nd and 3rd fingers

13. In a patient, there is a cut wound of the lower third of the left shoulder. After the injury, the left hand hangs down. The patient cannot extend the hand, abduct the thumb, and extend the fingers. Which nerve is damaged near the patient?

A. Ulnar nerve

B. Axillary nerve

C. Brachial plexus

**D. Radial nerve**

E. Median nerve

4. Summary

#### **Main Literature:**

1. Neurosurgery: textbook / [V.O. Pyatikop, I.O. Kutoviy, A.V. Kozachenko et al.]; edited by V.O. Pyatikop - Kyiv, VSV "Medicine", 2019. - 152 p.

2. Neurosurgery: textbook / [V.I. Tsimbalyuk, V.V. Medvedev, M.O. Marushchenko et al.]; edited by academician V.I. Tsimbalyuk. - 2nd edition, revised. - Vinnytsia: Nova Knyha, 2020. - 360 p.

3. Hryhorova I.A., Sokolova L.I., Herasymchuk R.D., Son A.S., et al. Neurology: Educational Manual / edited by I.A. Hryhorova, L.I. Sokolova - 3rd edition - Kyiv, VSV "Medicine", 2020. - 640 p.

4. Topical diagnosis of nervous system pathology. Diagnostic search algorithms. Shkrobot S.I., Saliy Z.V., Budarna O.Yu. Ukrmedknyha, 2018. - 156 p.

5. Methods of examination of a neurological patient: a tutorial / edited by L.I. Sokolova, T.I. Ilyash. Kyiv, 2020. - 144 p.

6. Emergency medicine. Emergency (ambulance) medical care: textbook / I.S. Zozulya, V.I. Bobrova, G.G. Roschin, etc. / edited by I.S. Zozulya. - 3rd edition, revised and supplemented. - Kyiv. - VSV "Medicine", 2017. - 960 p.

7. Negrych T.I., Bozhenko N.L., Matvienko Yu.Sh. Ischemic stroke: secondary inpatient care: a tutorial. Lviv: Danylo Halytsky Lviv National Medical University, 2019. - 160 p.

8. Handbook of Neurosurgery / Greenberg M.S. - Thieme, 2019. - 1784 p. ISBN 9781684201372

9. Neurology - Неврологія: textbook / I.A. Hryhorova, L.I. Sokolova, R.D. Herasymchuk et al.; edited by I.A. Hryhorova, L.I. Sokolova. – Kyiv : AUS Medicine Publishing, 2017. – 624p.

**Additional Literature:**

Bozhenko M.I., Negrych T.I., Bozhenko N.L., Negrych N.O. Headache. Educational manual.-K.: Medkniga Publishing House, 2019

**Informational resources:**

1. Clinical guidelines and other publications on neurosurgery (State Institution Romodanov Neurosurgery Institute of the National Academy of Medical Sciences of Ukraine)

<https://neuro.kiev.ua/uk/category/publishing-uk/>

2. Clinical guidelines on neurology. (Order of the Ministry of Health of Ukraine No. 487 dated 17.08.2007)

<https://zakon.rada.gov.ua/rada/show/v0487282-07#Text>

*Practical Class No. 5*

**Topic:** Brain Tumors

**Objective:** To provide learners with the opportunity to directly observe the main clinical signs of brain tumors at the patient's bedside. Using a specific case of a patient with a brain tumor, examine global and focal symptoms. Analyze the diagnostic features of auxiliary examination methods for brain tumors. Discuss the process of establishing and formulating a diagnosis. Surgical treatment of brain tumors, including radical and palliative operations. Combined treatment of malignant tumors.

**Key Concepts:** hypertensive syndrome, dislocation syndromes, radical and palliative surgical treatment of brain tumors, combined treatment of brain tumors, radiosurgical treatment

**Equipment:** Classroom, furniture, equipment:

PC

Multimedia projector

Neurosurgical microscope Mitaka MM51YOH

Surgical table RAPSODIA WITH MODULAR TABLEWORK

Head fixation device DORO

Electrosurgical unit BOWA ARC 400

Ultrasonic surgical aspirator CUSA CI C7000

Surgical aspirator Dominant Flex

Neuromonitoring system INOMED XPERT

Neurosurgical instruments

Steam sterilizer TICHE

Steam sterilizer KRONOS B23 with ROSI

Sealing machine

Ultrasonic cleaner

**Plan:**

1. Organizational activities (greetings, attendance check, announcement of the topic and goals of the session, motivation of students to study the topic).

2. Control of basic knowledge (written work, written testing, frontal questioning, etc.):

- Classification of Brain Tumors Based on Localization.

- Classification of Brain Tumors Based on Histological Structure.

- What are the main clinical symptoms of brain tumors?

- What are the pathophysiological mechanisms underlying the development of hypertensive syndrome?

- Name the main clinical signs of hypertensive syndrome.

- What underlies the occurrence of primary and secondary focal symptoms in brain tumors?
- What auxiliary research methods are used in the diagnosis of brain tumors?
- What changes in the fundus of the eye can be observed in brain tumors?
- What contrast imaging methods are used in the diagnosis of brain tumors?
- What is the basis for the rehabilitation and readaptation of patients operated on for brain tumors?
- Which histobiological types of brain tumors are most commonly encountered?
- What is the sequence of using auxiliary diagnostic methods when suspecting a brain tumor?
- What should be done to improve the condition of a patient with a posterior cranial fossa tumor when the cerebellar tonsils are herniating into the foramen magnum?
- List the types of treatment for brain tumors.
- In which cases are palliative surgeries indicated for patients?
- What methods are used for the rehabilitation of patients after the removal of a brain tumor?

**Content:**

**Classification (5th edition, 2021)**

**Gliomas, glioneuronal tumours, and neuronal tumours**

Adult-type diffuse gliomas

- astrocytoma, IDH-mutant
- oligodendroglioma, IDH-mutant, and 1p/19q-codeleted
- glioblastoma, IDH-wildtype

Paediatric-type diffuse low-grade gliomas

- diffuse astrocytoma, MYB- or MYBL1-altered
- angiocentric glioma
- polymorphous low-grade neuroepithelial tumour of the young
- diffuse low-grade glioma, MAPK pathway-altered

Paediatric-type diffuse high-grade gliomas

- diffuse midline glioma, H3 K27-altered
- diffuse hemispheric glioma, H3 G34-mutant
- diffuse paediatric-type high-grade glioma, H3-wildtype and IDH-wildtype
- infant-type hemispheric glioma

Circumscribed astrocytic gliomas

- pilocytic astrocytoma
- high-grade astrocytoma with piloid features
- pleomorphic xanthoastrocytoma
- subependymal giant cell astrocytoma
- chordoid glioma
- astroblastoma, MN1-altered

Glioneuronal and neuronal tumours

- ganglioglioma
- desmoplastic infantile ganglioglioma (DIG) / desmoplastic infantile astrocytoma
- dysembryoplastic neuroepithelial tumour
- diffuse glioneuronal tumour with oligodendroglioma-like features and nuclear

clusters (provisional inclusion)

- papillary glioneuronal tumour
- rosette-forming glioneuronal tumour
- myxoid glioneuronal tumour
- diffuse leptomeningeal glioneuronal tumour
- gangliocytoma

- multinodular and vacuolating neuronal tumour
- dysplastic cerebellar gangliocytoma (Lhermitte-Duclos disease)
- central neurocytoma
- extraventricular neurocytoma
- cerebellar liponeurocytoma

#### Ependymal tumours

- supratentorial ependymoma
  - supratentorial ependymoma, ZFTA fusion-positive
  - supratentorial ependymoma, YAP1 fusion-positive
- posterior fossa ependymoma
  - posterior fossa ependymoma, group PFA
  - posterior fossa ependymoma, group PFB
- spinal ependymoma
  - spinal ependymoma, MYCN-amplified
- myxopapillary ependymoma
- subependymoma

#### Choroid plexus tumours

- choroid plexus papilloma
- atypical choroid plexus papilloma
- choroid plexus carcinoma

#### Embryonal tumours

##### Medulloblastoma

- medulloblastomas, molecularly defined
  - medulloblastoma, WNT-activated
  - medulloblastoma, SHH-activated and TP53-wildtype
  - medulloblastoma, SHH-activated and TP53-mutant
  - medulloblastoma, non-WNT/non-SHH
- medulloblastomas, histologically defined

##### Other CNS embryonal tumours

- atypical teratoid/rhabdoid tumour
- cribriform neuroepithelial tumour (provisional inclusion)
- embryonal tumour with multilayered rosettes (ETMR)
- CNS neuroblastoma, FOXR2-activated
- CNS tumour with BCOR internal tandem duplication
- CNS embryonal tumour

#### Pineal tumours

- pineocytoma
- pineal parenchymal tumour of intermediate differentiation
- pineoblastoma
- papillary tumour of the pineal region
- desmoplastic myxoid tumour of the pineal region, SMARCB1-mutant

#### Cranial and paraspinal nerve tumours

- schwannoma
- neurofibroma
- perineurioma
- hybrid nerve sheath tumour
- malignant melanotic nerve sheath tumour
- malignant peripheral nerve sheath tumour
- cauda equina neuroendocrine tumour

#### Meningiomas

- meningioma

#### Mesenchymal, non-meningothelial tumours

### Soft tissue tumours

- fibroblastic and myofibroblastic tumours
- solitary fibrous tumour
- vascular tumours
- haemangiomas and vascular malformations
- haemangioblastoma
- skeletal muscle tumours
- rhabdomyosarcoma
- uncertain differentiation
- intracranial mesenchymal tumour, FET-CREB fusion-positive (provisional inclusion)
- CIC-rearranged sarcoma
- primary intracranial sarcoma, DICER1-mutant
- Ewing sarcoma

### Chondro-osseous tumours

- chondrogenic tumours
- mesenchymal chondrosarcoma
- chondrosarcoma
- notochordal tumours
- chordoma (including poorly differentiated chordoma)

### Melanocytic tumours

- diffuse meningeal melanocytic neoplasms
- meningeal melanocytosis
- meningeal melanomatosis
- circumscribed meningeal melanocytic neoplasms
- meningeal melanocytoma
- meningeal melanoma

### **Hematolymphoid tumours**

#### Lymphomas

- CNS lymphomas
- primary diffuse large B-cell lymphoma of the CNS
- immunodeficiency-associated CNS lymphoma
- lymphomatoid granulomatosis
- intravascular large B-cell lymphoma
- Miscellaneous rare lymphomas in the CNS
- MALT lymphoma of the dura
- other low-grade B-cell lymphomas of the CNS
- anaplastic large cell lymphoma (ALK+/ALK-)
- T-cell and NK/T-cell lymphomas

#### Histiocytic tumours

- Erdheim-Chester disease
- Rosai-Dorfman disease
- juvenile xanthogranuloma
- Langerhans cell histiocytosis
- histiocytic sarcoma

### **Germ cell tumours**

- mature teratoma
- immature teratoma
- teratoma with somatic-type malignancy
- germinoma
- embryonal carcinoma
- yolk sac tumour

- choriocarcinoma
- mixed germ cell tumour

### **Tumours of the sellar region**

- adamantinomatous craniopharyngioma
- papillary craniopharyngioma
- pituicytoma, granular cell tumour of the sellar region, and spindle cell oncocytoma
- pituitary adenoma (pitNET)
- pituitary blastoma

### **Metastases to the CNS**

- metastases to the brain and spinal cord parenchyma
- metastases to the meninges

Clinical picture:

Progressive focal neurological deficit (68%): usually motor weakness (45%)

Headache: 54%

Seizures: 26%

Focal Syndromes:

Frontal lobe: abulia, dementia, personality changes. Often without lateralization, but apraxia, hemiparesis, or dysphasia may occur.

Temporal lobe: auditory or olfactory hallucinations, déjà vu, memory impairment.

Contralateral upper quadrantanopia (visual field examination).

Parietal lobe: contralateral motor or sensory disturbances, homonymous hemianopia. Agnosias (involving the dominant hemisphere) and apraxias.

Occipital lobe: contralateral visual field deficits, alexia (especially involving the splenium of the corpus callosum).

Posterior fossa: cranial nerve dysfunction, ataxia (trunk or limbs).

Diagnosis:

Magnetic Resonance Imaging (MRI) with contrast is the optimal method for evaluating brain tumors. Computed Tomography (CT) has significantly lower soft tissue resolution and is primarily used in emergencies, for detailed study of bone structures, or in patients with contraindications to MRI.

High-grade Glioma:

High-grade gliomas typically appear hypointense on T1-weighted images and show heterogeneous enhancement after contrast administration. The intense tumor can be differentiated from the surrounding hypointense signal of edema on T1-weighted images. Typically, there is vasogenic edema, manifested as hyperintense signal in white matter on T2/FLAIR sequences. Glioblastomas often have a thick ring-enhancing border along the tumor margins, with no enhancement in the center, indicating necrosis or cystic changes. High-grade gliomas often exhibit signs of increased vascularity and blood volume, as well as increased permeability on perfusion imaging sequences. High signal intensity of choline, decreased N-acetylaspartate (NAA), and increased lactate on magnetic resonance spectroscopy (MRS) are also notable features.

Low-grade glioma — In adults, low-grade gliomas typically appear hyperintense on T2/FLAIR images, involving both the cortex and adjacent white matter. Vasogenic edema is usually absent. Most low-grade gliomas do not enhance, although the presence or absence of enhancement is not a reliable indicator of tumor malignancy. Sometimes, calcification may be present, which is specific but not sensitive for the histology of oligodendroglioma.

Treatment:

The treatment of brain tumors is comprehensive and includes surgical, chemotherapeutic, and (or) radiotherapeutic methods. This is primarily due to the lack of a clear capsule in the majority of neuroepithelial intracranial tumors, which precludes the possibility of total removal of the tumor cell mass during surgical intervention. Surgical treatment can be radical, aimed at the maximum complete removal of the tumor, or palliative, reducing intracranial volume to prolong the patient's life. Total and subtotal removal are distinguished among radical interventions based

on the completeness of the removal. Partial removal forms the basis for one of the types of palliative interventions known as internal decompression. It is important to note that current surgical treatment of brain tumors considers the rapid elimination of a significant mass of tumor cells through microsurgical removal and destruction of the tumor (actual surgical interventions) or by initiating radiation necrosis and apoptosis of tumor cells (radiosurgical interventions).

The performance of surgical interventions for the removal of brain tumors requires the use of modern equipment, such as surgical microscopes, systems of intraoperative neurovisualization (installations for intraoperative X-ray, MRI, and CT visualization), and stereotactic devices. Mechanical methods (microsurgical instruments), thermodestruction (laser thermodestruction, cryodestruction), and ultrasound destruction-aspiration are used for tumor removal during open (transcranial) interventions.

Radiosurgical destruction of brain tumors is achieved by a single targeted intensive irradiation of the tumor node transcutaneously using radiosurgical installations. There are two types of such installations that differ in the method of obtaining and the spectrum of radiation emission:

Gamma Knife technology - the source of gamma radiation is radioactive cobalt; the core of the installation is a hemisphere with over 200 collimator openings; radioactive cobalt is located around the perimeter, in several fragments behind the hemisphere. The collimator openings are selected so that gamma rays passing through them intersect in a limited volume of space - the focus. Thus, at the point of intersection of the rays, the maximum dose of radiation exposure is achieved. The patient's head is immobilized in a special frame fixed to a movable table, on which the patient is placed in a lying position. Since the focus of the rays is stationary, irradiation of the required area inside the brain is carried out by moving the patient. Each beam, passing through the tissues of the head, causes their slight irradiation, which, as is known, can have a negative effect only when a certain level is reached. This level is achieved in the focus zone of the rays, so that a dose of approximately 15-20 Gy is applied to the tumor. The focusing error of gamma rays in the "Gamma Knife" installations is minimal and does not exceed 1.5 mm.

Linear accelerator technology - a linear accelerator is used as a source of radiation, generating high-energy X-rays; a multi-leaf collimator forms a beam of radiation, shaping it according to the shape of the tumor. This method allows for precise dose distribution, adapting to the shape of the tumor and minimizing exposure to healthy tissues.

The maximum linear size of the tumor subject to radiosurgical destruction should not exceed 3-3.5 cm.

Chemotherapy and radiotherapeutic methods induce the cessation of the mitotic activity of tumor cells and their time-stretched, mainly apoptotic, death. This is most important for increasing the radical nature of the performed surgical treatment: destroying tumor cells at the periphery or at a distance from the tumor focus. Radiation therapy is used in the context of treating tumors with a high degree of anaplasia or after subtotal removal of certain types of brain tumors. Traditional, hyperfractionated, photodynamic therapy, brachytherapy, and boron-neutron capture therapy are also available.

The total radiation dose during the course of radiotherapy is up to 60 Gy. The course of radiation therapy is prescribed 2 weeks after tumor removal and lasts for 6 weeks with daily fractionated irradiation doses of 180-200 mGy.

The most radiosensitive tumors of the brain are germinoma, primary CNS lymphoma, medulloblastoma, and pituitary adenomas.

Chemotherapy, depending on the method of drug administration, can be systemic, regional, intra-arterial (selective), or intrathecal. A mandatory condition for conducting a course of chemotherapy is the pre-testing of the tumor for sensitivity to chemotherapeutic drugs. Glioblastoma, primary CNS lymphomas, and tumor infiltrations of the brain meninges are the most chemosensitive.

## **Materials for Self Control**

### **CLINICAL TASKS**

1. A 34-year-old female experienced a disruption in her menstrual cycle, followed by amenorrhea diagnosed as early menopause by doctors a year later. Subsequently, her vision began to decline, and the patient underwent inpatient and outpatient treatment for 2 years, but her vision progressively worsened. After 2 years, the visual acuity was 0.03 in the right eye, 0.02 in the left eye, due to primary optic nerve atrophy. Moderate headaches developed, intensifying in the morning. Provide a preliminary diagnosis and determine the examination plan.

ANSWER: Preliminary diagnosis: pituitary tumor. Most likely, pituitary adenoma. Ophthalmological examination is recommended for further diagnosis, specifying visual fields, performing MRI of the brain with contrast focusing on the sella turcica, EEG, and ACTH.

2. A 62-year-old male noticed a limited swelling (4x4 cm) that appeared 2 months ago, immobile and densely adhered to the underlying tissues in the occipital region. The patient consulted a district surgeon who attempted to remove the soft tissue tumor in the occipital area on an outpatient basis. The tumor was partially excised, and the patient was transferred to a neurosurgical clinic. What mistake did the doctor make during the examination and treatment of this patient?

ANSWER: The mistake was insufficient initial examination of the patient. Attempting to remove a tumor intimately adhered to the skull bones resulted in incomplete excision, leading to the possibility of worsened general condition and the risk of bleeding during and after surgery (early complication) and brain swelling.

3. A 38-year-old female experienced a gradual decline in vision in her right eye, under observation by an ophthalmologist. Over time, visual acuity in the right eye decreased due to primary atrophy of the optic nerve. Four months ago, protrusion of the right eyeball appeared and progressed. On examination, there is exophthalmos on the right, visual acuity is 0.05 in the right eye and 1.0 in the left eye. Primary atrophy of the right optic nerve and stasis of the left optic nerve disc are noted. Provide a tentative diagnosis, and use additional diagnostic methods.

ANSWER: The patient likely has a lesion in the basal regions of the right frontal lobe, most probably a tumor. Additional diagnostic methods recommended are MRI of the brain, ACTH, and right carotid angiography.

4. A 52-year-old male complained of seizures in the right extremities that started two years ago. During the first year, there were three attacks, followed by headaches and weakness in the right arm 30 minutes after the onset of the seizure. For the past six months, the patient has been experiencing seizures with convulsions and loss of consciousness, preceded by numbness and convulsions in the right hand. On examination, slight lagging of the right hand during Barré's test, dominance of tendon reflexes on the right side in hemitype, and decreased pain sensitivity on the right are noted. Provide a diagnosis and determine the treatment.

ANSWER: The patient likely has a tumor in the left frontal-temporal lobes. Recommended treatment after examination is cranioplasty, tumor removal. In case of malignancy, chemotherapy and radiotherapy are indicated.

5. A 62-year-old patient is in a severe condition with pronounced headache, morning vomiting, and limited movements in the left limbs. He has been unwell for two weeks, and his condition is progressively worsening. The patient has been smoking since the age of 20. Over the past year, he has been troubled by persistent coughing. The patient is malnourished, with pale-gray skin, and reduced memory. Develop a plan for examining the patient, determine the nature of the pathology, and propose treatment.

ANSWER: The patient most likely has lung cancer with metastases to the brain. A comprehensive somatic oncological examination is required, as well as chest X-ray. If a single metastasis is detected in the right hemisphere of the brain and there are no contraindications from the lungs, the recommended treatment is the removal of a single metastasis with subsequent chemotherapy and radiotherapy. Symptomatic treatment. In the presence of multiple metastases, surgical treatment is not indicated. Chemotherapy and symptomatic treatment are conducted.

6. A 42-year-old female presented to the clinic complaining of a headache worsening in the morning, accompanied by vomiting, unsteadiness when walking, and loss of hearing in the



right ear. A change in body position causes a "curtain" sensation in front of the eyes. She has been ill for about 5 years. Initially, she experienced a noise in the right ear, sought consultation and treatment from ENT specialists but saw no improvement. Her hearing in the right ear began to decline, and a year ago, complete deafness occurred. Over the past year, she has been troubled by persistent headaches in the early morning hours. Currently, she experiences constant headaches. The above symptoms have appeared. Determine the type of brain lesion.

ANSWER: The patient most likely has a vestibular schwannoma involving the right auditory nerve.

#### **Materials for self-study:**

Professional algorithm for examining a patient with a brain tumor:

1. Patient examination.
2. History (history of trauma, family history).
3. Complaints (headache, vomiting, vision disturbances, seizures).
4. Objective examination of internal organs (mandatory blood pressure and pulse on both arms).
5. Assessment of the level of consciousness (Glasgow Coma Scale from 3 to 15).
6. Examination of the 12 pairs of cranial nerves.
7. Evaluation of the motor-sensory sphere (reflexes, assessment of sensory disorders).
8. Assessment of statics and coordination.
9. Identification of meningeal syndrome.
10. Local examination of the head.
11. Detection of fluid leakage, blood from the nose, ears.
12. Identification of external soft tissue injuries.
13. Skull X-ray in two projections.
14. Additional research methods if necessary.

#### **Instructional materials for acquiring professional skills:**

1. Professional algorithm for performing a lumbar puncture:
2. Position the patient on the right side.
3. Legs bent at the knees and pulled up to the abdomen.
4. Sterilize hands, wear sterile gloves.
5. Process the area with 5% iodine, then alcohol at the level of the 3-5 lumbar vertebrae.
6. Local anesthesia with a 0.5% novocaine solution at the level of the intervertebral cleft between the 4th and 5th lumbar vertebrae.
7. Needle control (presence of a manometer, sharpness of the needle).
8. Lumbar puncture. During the puncture, feel two obstacles (yellow ligament, dura mater), observe for vomiting.
9. Slow withdrawal of the manometer from the needle, check for the presence of cerebrospinal fluid.
10. With the extended manometer, evacuate the cerebrospinal fluid for analysis.
11. Needle removal and aseptic dressing.

#### **Summary**

##### **Main Literature:**

1. Neurosurgery: textbook / [V.O. Pyatikop, I.O. Kutoviy, A.V. Kozachenko et al.]; edited by V.O. Pyatikop - Kyiv, VSV "Medicine", 2019. - 152 p.
2. Neurosurgery: textbook / [V.I. Tsimbalyuk, V.V. Medvedev, M.O. Marushchenko et al.]; edited by academician V.I. Tsimbalyuk. - 2nd edition, revised. - Vinnytsia: Nova Knyha, 2020. - 360 p.
3. Hryhorova I.A., Sokolova L.I., Herasymchuk R.D., Son A.S., et al. Neurology: Educational Manual / edited by I.A. Hryhorova, L.I. Sokolova - 3rd edition - Kyiv, VSV "Medicine", 2020. - 640 p.

4. Topical diagnosis of nervous system pathology. Diagnostic search algorithms. Shkrobot S.I., Saliy Z.V., Budarna O.Yu. Ukrmedknyha, 2018. - 156 p.
5. Methods of examination of a neurological patient: a tutorial / edited by L.I. Sokolova, T.I. Ilyash. Kyiv, 2020. - 144 p.
6. Emergency medicine. Emergency (ambulance) medical care: textbook / I.S. Zozulya, V.I. Bobrova, G.G. Roschin, etc. / edited by I.S. Zozulya. - 3rd edition, revised and supplemented. - Kyiv. - VSV "Medicine", 2017. - 960 p.
7. Negrych T.I., Bozhenko N.L., Matvienko Yu.Sh. Ischemic stroke: secondary inpatient care: a tutorial. Lviv: Danylo Halytsky Lviv National Medical University, 2019. - 160 p.
8. Handbook of Neurosurgery / Greenberg M.S. - Thieme, 2019. - 1784 p. ISBN 9781684201372
9. Neurology - Неврологія: textbook / I.A. Hryhorova, L.I. Sokolova, R.D. Herasymchuk et al.; edited by I.A. Hryhorova, L.I. Sokolova. – Kyiv : AUS Medicine Publishing, 2017. – 624p.

**Additional Literature:**

Bozhenko M.I., Negrych T.I., Bozhenko N.L., Negrych N.O. Headache. Educational manual.-K.: Medkniga Publishing House, 2019

**Informational resources:**

1. Clinical guidelines and other publications on neurosurgery (State Institution Romodanov Neurosurgery Institute of the National Academy of Medical Sciences of Ukraine)  
<https://neuro.kiev.ua/uk/category/publishing-uk/>
2. Clinical guidelines on neurology. (Order of the Ministry of Health of Ukraine No. 487 dated 17.08.2007)  
<https://zakon.rada.gov.ua/rada/show/v0487282-07#Text>

*Practical Class No. 6*

**Topic:** Hydrocephalus

**Objective:** To acquire knowledge and skills for examining patients with hydrocephalus, learn to independently interpret results of visualization studies, and develop a clear understanding of the sequential management of patients with hydrocephalus (conservative and surgical treatment).

**Key Concepts:** Hydrocephalus, hypertensive-hydrocephalic syndrome, normotensive hydrocephalus

**Equipment:** Classroom, furniture, equipment:

PC

Multimedia projector

Neurosurgical microscope Mitaka MM51YOH

Surgical table RAPSODIA WITH MODULAR TABLEWORK

Head fixation device DORO

Electrosurgical unit BOWA ARC 400

Ultrasonic surgical aspirator CUSA CI C7000

Surgical aspirator Dominant Flex

Neuromonitoring system INOMED XPERT

Neurosurgical instruments

Steam sterilizer TICHE

Steam sterilizer KRONOS B23 with ROSI

Sealing machine

Ultrasonic cleaner

**Plan:**

1. Organizational activities (greetings, attendance check, announcement of the topic and goals of the session, motivation of students to study the topic).
2. Control of basic knowledge (written work, written testing, frontal questioning, etc.):

- Physiology of cerebrospinal fluid formation, circulation, and properties.
- Structure of the ventricles of the brain.
- Concept of normal intracranial pressure, Monro-Kellie doctrine.
- Lumbar puncture, indications, and procedure.
- 3. Development of professional skills and abilities (mastering skills, conducting care, determining treatment plans, performing laboratory tests, etc.):
  - Define the concept of hydrocephalus.
  - Classify hydrocephalus (pathophysiological mechanisms).
  - Etiology.
  - Clinical signs in children and adults.
  - CT/MRI criteria for hydrocephalus, calculation methods.
  - Differential diagnosis.
  - Concept of chronic and acute hydrocephalus.
  - Normotensive hydrocephalus.
  - Methods of conservative treatment.
  - Surgical treatment methods and indications.
  - Prognosis

### **Content**

Hydrocephalus is the abnormal accumulation of cerebrospinal fluid in the ventricles of the brain.

### **Pathogenesis:**

Hydrocephalus is caused by subnormal cerebrospinal fluid reabsorption or, rarely, hyperproduction of cerebrospinal fluid.

Subnormal reabsorption of fluid has two main functional subdivisions:

Obstructive hydrocephalus (non-communicating): blockage proximal to the arachnoid granulations. On CT or MRI, there is an enlargement of the ventricles proximal to the blockage (e.g., obstruction of the Sylvian aqueduct → lateral and 3rd ventricle enlargement disproportionate to the 4th ventricle, sometimes called triventricular hydrocephalus).

Communicating hydrocephalus (or non-obstructive): defects in fluid reabsorption.

Hyperproduction of fluid: rare, as seen in some vascular plexus papillomas.

### **Etiology:**

Congenital:

- a) Chiari type 2 malformation and/or myelomeningocele (usually occur together).
- b) Chiari type 1 malformation: may arise from obstruction at the outlet of the 4th ventricle.
- c) Primary aqueductal stenosis (usually manifests in childhood, rarely in adulthood).
- d) Secondary aqueductal gliosis: due to intrauterine infection or hemorrhage from the embryonic matrix.
- e) Dandy-Walker malformation: atresia of the foramina of Luschka and Magendie. The frequency of this in hydrocephalic patients is 2.4%.
- f) X-linked hereditary disease: rare.

Acquired:

- a) Infectious (most common cause of communicating hydrocephalus):
  - Post-meningitis, especially purulent and basal, including tuberculous and cryptococcal.
  - Cysticercosis.
- b) Post-hemorrhagic (second most common cause of communicating hydrocephalus):
  - After subarachnoid hemorrhage.
  - Post-intraventricular hemorrhage: many develop transient hydrocephalus.
- c) Secondary to space-occupying lesions:
  - Non-neoplastic: e.g., vascular malformation.
  - Neoplastic: most cause obstructive hydrocephalus, blocking the pathways of cerebrospinal fluid, especially tumors around the aqueduct (e.g., medulloblastoma). Colloid cysts may block

fluid flow through the foramen of Monro. Pituitary tumors: suprasellar expansion of the tumor or expansion from pituitary apoplexy.

d) Postoperative period: 20% of pediatric patients develop persistent hydrocephalus (requiring shunting) after posterior fossa tumor removal.

e) Neurosarcooidosis.

f) "Constitutional ventriculomegaly": asymptomatic, requires no treatment.

g) Spinal cord tumor-related: due to increased protein, increased venous pressure, previous bleeding in some cases.

**Clinical presentation in adults:**

Increased intracranial pressure: optic disc edema, increased blood pressure, nausea/vomiting, gait changes, upward gaze paralysis, and/or abducens paralysis.

**In children:**

Abnormal head circumference.

The cranial vault expands faster than facial growth.

Irritability, poor head control, nausea/vomiting.

Full and bulging fontanelle.

Frontal bossing (protrusion of the forehead).

Enlargement and bulging of scalp veins due to retrograde flow from intracranial sinuses, as a result of increased intracranial pressure.

The "Macewen sign": a cracked pot sound on percussion over excessively dilated ventricles.

Paralysis of the 6th (abducens) nerve: the long intracranial course makes this nerve highly sensitive to pressure.

"Setting sun sign" (upward gaze paralysis): Parinaud syndrome from pressure on the midbrain.

Hyperactive reflexes.

Irregular breathing with apneic episodes.

Separation of cranial sutures (visible on skull X-ray).

**Diagnostic criteria (MRI, CT):**

1. Both lateral ventricles' size is  $\geq 2$  mm in width, and the foramina of Monro and the interhemispheric fissure are not visualized.

OR

2. Both lateral ventricles are  $\geq 2$  mm, and the ratio of the widest distance between the anterior horns (FH) to the internal diameter between the inner surfaces of the skull at this level (ID) is  $> 0.5$ .

Other signs indicating hydrocephalus:

1. "Ballooning" of the frontal horns of the lateral ventricles ("Mickey Mouse" appearance) and/or the 3rd ventricle. (The 3rd ventricle should normally be slit-like).

2. Periventricular low density on CT or periventricular high-intensity signal on T2WI on MRI indicates transependymal fluid absorption (fluid stasis in the brain adjacent to the ventricles).

3. Ratio:

FH/ID

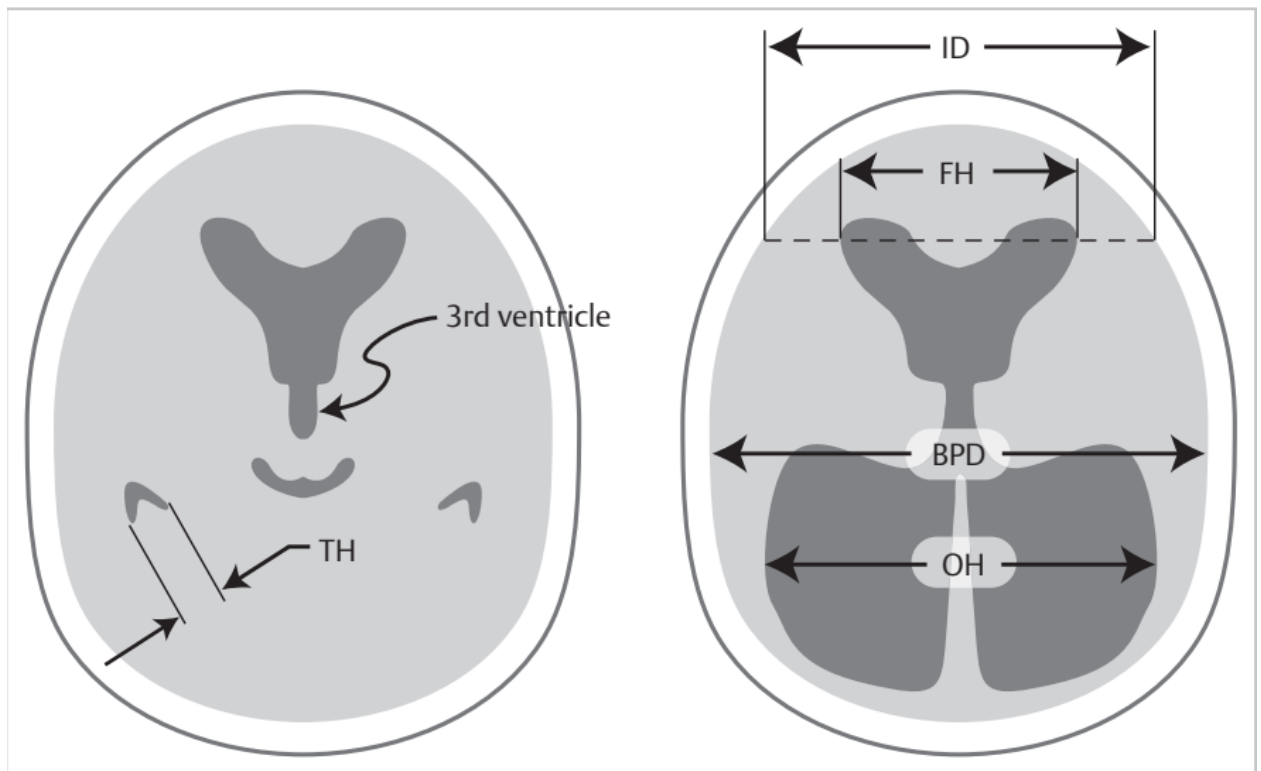
$< 40\%$ : normal

$40-50\%$ : borderline normal

$50\%$ : suggestive of hydrocephalus

4. Evans Index or Ratio: the ratio of FH to the maximum biparietal diameter (BPD) measured on the same CT slice.

A value  $> 0.3$  indicates hydrocephalus.



Handbook of Neurosurgery / Greenberg M.S. – Thieme, 2019. – 1784 p. ISBN 9781684201372

5. Sagittal MRI can reveal the thinning of the corpus callosum (typically present in chronic hydrocephalus) and/or an upward flexion of the corpus callosum.

#### **Treatment**

Diuretic Therapy:

1. Acetazolamide (carbonic anhydrase inhibitor): 25 mg/kg/day orally, divided into 3 doses, with an increase of 25 mg/kg/day every day until reaching 100 mg/kg/day.
2. Simultaneously initiate the administration of furosemide: 1 mg/kg/day orally, divided three times a day.
3. Monitor for electrolyte imbalance and side effects of acetazolamide, such as lethargy, tachypnea, diarrhea, and paresthesia (e.g., tingling in the fingertips).
4. Perform weekly ultrasound or CT scans and insert a ventricular shunt in case of progressing ventriculomegaly. Otherwise, maintain therapy for 6 months, then taper the dose over 2–4 weeks. Resume treatment for 3–4 months if progressive hydrocephalus is observed.

#### **Surgical Treatment:**

- Third ventriculostomy: currently, preference is given to the endoscopic method.
- Shunting: ventriculoperitoneal, ventriculoatrial.
- Obstruction removal: e.g., opening a stenosed Sylvian aqueduct.
- Plexectomy of vascular plexus: may reduce the rate but does not completely halt cerebrospinal fluid production.

#### **Tasks for Self-Control.**

Task 1.

A 30-year-old patient complained of severe headaches, mainly in the early morning hours, with nausea, vomiting, blurred vision, memory loss, and emotional lability. These complaints developed gradually over 2-3 months.

From the history, it is known that a year ago, the patient was treated in the neurosurgical department for closed head injury. Brain contusion. Subarachnoid hemorrhage. Linear fracture of the right temporal bone. The patient was discharged in satisfactory condition, and subsequently experienced moderate headaches.

Objective study: Clear consciousness, no meningeal signs, no cranial nerve dysfunction, increased tendon and periosteal reflexes (D=S), positive Babinski sign on both sides, Romberg's sign instability. Ophthalmic examination: Stagnant discs of the optic nerves. According to Echo-encephalography, the midline shift is not present.

What late complication can be suspected in the patient? What diseases should be considered in the differential diagnosis?

Task 2.

The mother of a 9-month-old child consulted a doctor due to recurrent vomiting that appeared a month ago. At the age of 6 months, the child fell from a couch about 60 cm high, hitting the head. Swelling of the occipital area and repeated vomiting occurred within a day after the trauma. A month later, the cranial part of the head began to enlarge, the fontanel increased in size. During the examination, the child appeared malnourished, the cranial part of the head was enlarged, the skin was thin, transparent, veins on the head were dilated, and the fontanel was tense.

Provide a preliminary diagnosis. What diagnostic methods should be applied?

Task 3.

The mother of a 6-month-old infant turned to a neurosurgeon with complaints of developmental delay, progressive enlargement of the head circumference, poor sleep, and irritability. It is known from the history that the child had meningoencephalitis at the age of 2 months.

Objective study: The child is restless, holds the head uncertainly, does not sit, the head is symmetrical, head circumference is 50 cm, thin skin with many dilated subcutaneous veins, enlarged fontanel, not pulsating, slightly exophthalmic eyeballs, positive Grefe's sign. Tendon and periosteal reflexes are within the age norm. Fundus examination reveals angiopathy of the retinal vessels.

What pathology can be suspected in the child? What are the pathogenetic mechanisms of this process?

Task 4.

The mother of a 7-month-old infant consulted a neurosurgeon with complaints of the child's lethargy, vomiting, poor appetite, irritability, and limited movements in the left limbs. From the history, it is known that at the age of 4 months, on the background of progressive post-hemorrhagic hydrocephalus, a cerebrospinal fluid shunting system was installed on the right side. Subsequently, there was a regression of neurological symptoms and ventriculodilatation according to neurosonography (NSG) data. The above symptoms appeared within the last day.

Objective study: The child is sleepy, holds the head uncertainly, does not sit, the head is symmetrical, head circumference is 50 cm, enlarged fontanel, not pulsating. Tendon and periosteal reflexes are increased on the left, hemiparesis on the left. When pumping the cerebrospinal fluid shunting system, the valve "sticks."

What condition can be suspected in the child's development? What are the likely causes of this condition?

Task 5.

A 9-year-old child presents with clinical symptoms of hypertensive-hydrocephalic syndrome. From the history, it is known that the girl had ventriculitis 6 months ago. MRI revealed progressive hydrocephalus with a sharp expansion of the lateral ventricles and aqueductal stenosis. What are the optimal surgical treatment options for hydrocephalus in this case?

**Answers**

Task 1. Post-traumatic hydrocephalus. Differential diagnosis should include arachnoiditis, post-traumatic encephalopathy, and the formation of meningeal-brain scar.

Task 2. Post-traumatic hydrocephalus. Neurosonography, CT, MRI of the brain.

Task 3. Post-inflammatory hydrocephalus. Formation of post-inflammatory arachnoiditis and, as a result, disruption of cerebrospinal fluid absorption.

Task 4. Dysfunction of the cerebrospinal fluid shunting system. Most often, shunt dysfunctions occur due to mechanical damage to the system, thrombosis, or fibrin clot obstruction, inflammatory complications, etc.

Task 5. In this case, ventriculoperitoneostomy is a possible option, and in some cases, ventriculoatriostomy.

#### 4. Summary

##### **Main Literature:**

1. Neurosurgery: textbook / [V.O. Pyatikop, I.O. Kutoviy, A.V. Kozachenko et al.]; edited by V.O. Pyatikop - Kyiv, VSV "Medicine", 2019. - 152 p.

2. Neurosurgery: textbook / [V.I. Tsimbalyuk, V.V. Medvedev, M.O. Marushchenko et al.]; edited by academician V.I. Tsimbalyuk. - 2nd edition, revised. - Vinnytsia: Nova Knyha, 2020. - 360 p.

3. Hryhorova I.A., Sokolova L.I., Herasymchuk R.D., Son A.S., et al. Neurology: Educational Manual / edited by I.A. Hryhorova, L.I. Sokolova - 3rd edition - Kyiv, VSV "Medicine", 2020. - 640 p.

4. Topical diagnosis of nervous system pathology. Diagnostic search algorithms. Shkrobot S.I., Saliy Z.V., Budarna O.Yu. Ukrmedknyha, 2018. - 156 p.

5. Methods of examination of a neurological patient: a tutorial / edited by L.I. Sokolova, T.I. Ilyash. Kyiv, 2020. - 144 p.

6. Emergency medicine. Emergency (ambulance) medical care: textbook / I.S. Zozulya, V.I. Bobrova, G.G. Roschin, etc. / edited by I.S. Zozulya. - 3rd edition, revised and supplemented. - Kyiv. - VSV "Medicine", 2017. - 960 p.

7. Negrych T.I., Bozhenko N.L., Matvienko Yu.Sh. Ischemic stroke: secondary inpatient care: a tutorial. Lviv: Danylo Halytsky Lviv National Medical University, 2019. - 160 p.

8. Handbook of Neurosurgery / Greenberg M.S. - Thieme, 2019. - 1784 p. ISBN 9781684201372

9. Neurology - Неврологія: textbook / I.A. Hryhorova, L.I. Sokolova, R.D. Herasymchuk et al.; edited by I.A. Hryhorova, L.I. Sokolova. – Kyiv : AUS Medicine Publishing, 2017. – 624p.

##### **Additional Literature:**

Bozhenko M.I., Negrych T.I., Bozhenko N.L., Negrych N.O. Headache. Educational manual.-K.: Medkniga Publishing House, 2019

##### **Informational resources:**

1. Clinical guidelines and other publications on neurosurgery (State Institution Romodanov Neurosurgery Institute of the National Academy of Medical Sciences of Ukraine)

<https://neuro.kiev.ua/uk/category/publishing-uk/>

2. Clinical guidelines on neurology. (Order of the Ministry of Health of Ukraine No. 487 dated 17.08.2007)

<https://zakon.rada.gov.ua/rada/show/v0487282-07#Text>

#### *Practical Class No. 7*

**Topic:** Vascular Pathology of the Brain Accompanied by Intracranial Hemorrhage

**Objective:** To acquire knowledge on the etiology, pathogenesis, and clinical presentation of acute cerebrovascular events of the hemorrhagic type, as well as to develop skills in its diagnosis.

**Key Concepts:** Acute cerebrovascular events of the hemorrhagic type, hypertensive vasculopathy, cerebral amyloid angiopathy, subarachnoid hemorrhage.

**Equipment:** laptop, multimedia projector.

##### **Plan:**

1. Organizational activities (greetings, attendance check, announcement of the topic and goals of the session, motivation of students to study the topic).

2. Control of basic knowledge (written work, written testing, frontal questioning, etc.):

- Blood supply to the brain.
- Clinical manifestations of hemorrhagic stroke.
- Diagnosis of hemorrhagic stroke.

### **Content**

The cause of hemorrhagic stroke is the leakage of blood beyond the vessel lumen into the brain substance. Hemorrhagic strokes account for up to 15% of all strokes. The mortality rate for non-traumatic intracerebral hemorrhages within the first month is 40-60%.

Risk factors include:

- Age: Incidence significantly increases after 55 years, doubling with each decade until >80 years, where it becomes 25 times higher than the previous decade.
- Gender: More common in males.
- Race: In the United States, intracerebral hemorrhage affects Blacks more than Whites, possibly associated with a higher prevalence of hypertension among Blacks. Incidence may also be higher among Asians.
- Previous stroke (of any type) increases the risk by 23 times.
- Alcohol consumption:
  - a) Recent intake: Moderate or excessive alcohol consumption in the 24 hours or week before intracerebral hemorrhage is an independent risk factor.
  - b) Chronic consumption: Drinking >3 drinks per day increases the risk of intracerebral hemorrhage approximately sevenfold.
  - c) In patients with excessive alcohol consumption, intracerebral hemorrhages were more often localized in cerebral regions than typical "hypertensive bleeds" in the basal ganglia.
- Smoking: Increases the risk of subarachnoid hemorrhage and ischemic stroke but likely does not increase the risk of intracerebral hemorrhage.
- Drugs: Cocaine, amphetamines, phencyclidine.
- Liver dysfunction: Hemostasis may be disturbed due to thrombocytopenia, insufficient coagulation factors, and hyperfibrinolysis (may influence increased risk of intracerebral hemorrhage with chronic ethanol consumption).

### **Etiology:**

1. "Hypertension" (debatable as a cause or consequence) but is a risk factor:
  - a) Acute hypertension (eclampsia, cocaine).
  - b) Chronic hypertension: May induce degenerative changes in vessels.
2. Possibly related to a sudden increase in blood flow to the brain (general or local), especially in areas previously experiencing ischemia:
  - a) After carotid endarterectomy.
  - b) After correction of congenital heart defects in children.
  - c) Previous stroke (embolic or other): Hemorrhagic transformation can occur in 43% of strokes within the first month. It may occur within  $\leq 24$  hours after a stroke in patients with negative CT performed within 6 hours. Two types:
    - Type 1: Diffuse or multifocal. Heterogeneous or speckled appearance within the stroke. Less hyperdense than the primary intracerebral hemorrhage.
    - Type 2: Large hematoma. Likely a unifocal source. Similar hyperdensity to the primary intracerebral hemorrhage and may extend beyond the primary boundaries of the stroke. Unlike type 1, classically associated with anticoagulant therapy and prone to occur within the first few days after the stroke, often associated with clinical deterioration. It can be challenging to distinguish from the primary intracerebral hemorrhage and is often misdiagnosed as such.
  - d) Migraine: during or after a migraine attack (likely a very rare event).
  - e) After AVM removal surgery: "breakthrough of normal perfusion pressure." Some cases may be associated with incomplete AVM removal.
  - f) Physical factors: after strenuous physical activity, exposure to cold.
3. Congenital vascular anomalies
  - a) AVM: rupture.



- b) Rupture of aneurysms:
  - Saccular ("berry") aneurysms: (i) Aneurysms of the Circle of Willis: aneurysms that have become adherent to the brain surface due to fibrosis from inflammation or previous hemorrhages may cause intracerebral hemorrhage upon rupture instead of the typical subarachnoid hemorrhage (SAH). (ii) Aneurysms distal to the Circle of Willis (e.g., aneurysms of the middle cerebral artery).
  - Microaneurysms (Charcot-Bouchard).
- c) Rupture of venous angioma: significant intracerebral hemorrhage from these common lesions is a very rare event.
- 4. "Arteriopathies":
  - a) Amyloid angiopathy: usually leads to recurrent lobar hemorrhages.
  - b) Fibroid necrosis (sometimes seen in amyloid angiopathy).
  - c) Lipohyalinosis.
  - d) Cerebral arteritis (including necrotizing angiitis).
- 5. Brain tumors (primary or metastatic).
- 6. Coagulation or blood clotting disorders:
  - a) Leukemia.
  - b) Thrombocytopenia:
    - Thrombotic thrombocytopenic purpura.
    - Aplastic anemia.
- c) Patients taking anticoagulant therapy constitute 12-20% of intracerebral hemorrhage patients.
- d) Patients receiving thrombolytic therapy:
  - For acute ischemic stroke: the relative incidence of symptomatic intracerebral hemorrhage within 36 hours after rtPA treatment is 6.4% (compared to 0.6% in patients receiving placebo).
  - For acute myocardial infarction or other thromboses: the incidence is approximately 0.36-2%. The risk increases with higher doses than the recommended 100 mg of alteplase (Activase®, recombinant tissue plasminogen activator (rt-PA)) in elderly patients, those with anterior myocardial infarction or higher Killip class, and with bolus administration (compared to infusion). When using heparin as an adjunct, higher doses were associated with a greater risk of intracerebral hemorrhage. Intracerebral hemorrhage is presumed to occur in patients with a certain predisposing congenital vascular anomaly. Emergency coronary angioplasty is safer than rt-PA when available.
- e) Aspirin therapy:
  - Taking one aspirin tablet every other day is associated with an increased risk of intracerebral hemorrhage, with an incidence of 0.2-0.8% per year.
  - Aspirin 100 mg/day does not increase the risk of significant intracerebral hemorrhage in patients over 60 years with mild or moderate head injury (GCS  $\geq$  9).
- f) Vitamin E supplements: associated with a decreased incidence of 1 ischemic stroke among 476 individuals and an increased incidence of 1 intracerebral hemorrhage among 1250 patients taking vitamin E.
- 7. CNS infection:
  - a) Particularly fungal infections that damage blood vessels.
  - b) Granulomas.
  - c) Herpetic encephalitis.
- 8. Thrombosis of veins or sinuses of the meninges.
- 9. Medication-related:
  - a) Substance abuse:
    - Alcohol.
    - Drug abuse, especially sympathomimetics (cocaine, amphetamines).
  - b) Medications that increase blood pressure:

Alpha-adrenergic agonists (sympathomimetics), including phenylephrine, ephedrine, and pseudoephedrine.

10. Post-traumatic.

11. Pregnancy-related: The risk of intracerebral hemorrhage in pregnant and postpartum women (up to 6 weeks after delivery) is approximately 1 in 9,500 births:

a) Most commonly associated with eclampsia or late preeclampsia. Eclampsia mortality is around 6%, with intracerebral hemorrhage being the most common direct cause.

b) Postpartum intracerebral hemorrhage (median 8 days, range 3–35 days) with or without eclampsia. When associated with vasculopathy, the term postpartum cerebral angiopathy is used.

c) Vascular findings:

- Some cases are associated with isolated cerebral vasculopathy in the absence of systemic vasculitis.

- Some cases show findings (such as patchy signal enhancement in the occipital lobes) suggestive of cerebrovascular dysautoregulation.

- Some cases do not exhibit vascular-related anomalies.

12. Postoperative:

a) After carotid endarterectomy.

b) After craniotomy:

- At the craniotomy site: identified risk factors include residual astrocytoma after partial removal, after craniotomy for AVM.

- Remote from the craniotomy site.

13. Idiopathic.

### **Mechanisms of Brain Injury**

There are several mechanisms of brain injury in intracerebral hemorrhage (ICH). Among them:

- Primary mechanical damage to brain parenchyma occurs due to the spread of hematoma and perifocal edema. Both the hematoma's volume and edema lead to mass effect and increased intracranial pressure (ICP), which, in turn, can result in reduced cerebral perfusion and ischemic injury, especially in cases of very large ICH, leading to brain herniation.

- Secondary brain injury arises from the disruption of the blood-brain barrier after the initial hemorrhage and involves excitotoxic and inflammatory processes. However, the precise mechanism or mechanisms underlying this remain undefined.

### **Clinical Presentation**

Average, young age

Acute onset during physical or psychological stress

Loss of consciousness, lethargy, often in a comatose state

Arterial hypertension

Tachycardia/bradycardia, tense pulse

Flushed face

Marked meningeal symptoms

Frequent seizures

Blood in the cerebrospinal fluid (CSF)

Hemorrhagic stroke more commonly occurs during the day, during periods of active activity, under stress, or physical or emotional strain. The onset is rapid, occurring instantly or within minutes, rarely hours. The global symptoms often predominate over focal ones. Sudden severe headache is observed (sometimes resembling a blow to the head, hence the old term "apoplexy"), vomiting, facial flushing, psychomotor agitation, disturbance, often loss of consciousness, and labored breathing. Focal symptoms, resulting from compression of brain tissue by the hematoma, include central hemiparesis (hemiplegia) of the limbs contralateral to the bleeding area and language impairment. Hemiparesis, despite being central, may be accompanied by various changes in muscle tone—reduction, elevation, paroxysmal elevation with the onset of

hypertonic seizures. Seizures are observed within the first hour after the onset of hemorrhagic stroke, with generalized epileptic seizures occurring in 10% of cases. Meningeal syndrome is often detected. In cases where blood breaks into the ventricular system, tonic seizures, respiratory and cardiovascular function disturbances occur, and the condition often ends in death within a day. Massive intracerebral hemorrhages with cortical localization contribute to crescentic and tentorial herniation, and in advanced cases, herniation of the cerebellar tonsils into the foramen magnum.

Spontaneous (non-traumatic) subarachnoid hemorrhage (SAH) in 70-80% of cases is caused by the rupture of an aneurysm of one of the major intracerebral arteries, 5-10% - arteriovenous malformation (AVM). Rarely, spontaneous SAH occurs with disorders of the blood clotting system, taking anticoagulants. Focal symptoms result from ischemic disorders that arise from prolonged spasm of arterial vessels. The most typical symptoms are damage to the cranial nerves, paralysis and paresis of the limbs, and sensory disturbances. In some cases, triggering factors precede the rupture of an aneurysm, but in most cases, the rupture occurs without an identified trigger. Some cases of aneurysm rupture occur during sleep. Physical exertion is one of the triggers. Others include consumption of caffeine, acute feelings of anger or shock, and sexual activity.

The rupture of an aneurysm leads to the release of blood directly into the cerebrospinal fluid (CSF) under pressure. Blood quickly spreads within the CSF, rapidly increasing intracranial pressure. Blood often spreads into the intraventricular space but can also extend into the brain parenchyma or, less commonly, into the subdural space, depending on the location of the aneurysm. The bleeding usually lasts only a few seconds, but recurrences often occur, mostly within the first day.

In addition to recurrences, secondary events after an aneurysm rupture contribute to brain injury:

- Hydrocephalus after subarachnoid hemorrhage is considered to be caused by blocking the movement of cerebrospinal fluid by blood products or adhesions, or by a decrease in the absorption of cerebrospinal fluid in the pacchion granulations. The former occurs as an acute complication, and the latter develops two weeks or later and is more likely associated with dependence on shunting.

- Vasospasm is considered a result of the release of spasmogenic substances during the lysis of thrombi in the subarachnoid space, causing damage to the endothelium and contraction of smooth muscles. Vascular endothelium produces nitric oxide, which tonically dilates cerebral vessels; damage to the endothelium can affect the production of nitric oxide, leading to vasoconstriction and impaired response to vasodilators. Additionally, increased release of the potent vasoconstrictor endothelin may play a key role in the development of vascular vasospasm after subarachnoid hemorrhage. Vasospasm, in turn, can cause regional cerebral hypoperfusion and distant cerebral ischemia and infarction.

Elevated intracranial pressure (ICP) arises from several factors, including the volume of bleeding, acute hydrocephalus, reactive hyperemia after bleeding or ischemia, and vasodilation of the distal arterioles of the brain.

Common risk factors for the rupture of saccular aneurysms include arterial hypertension, smoking, and alcohol abuse. The immediate cause of rupture is a sudden increase in arterial pressure.

The patient's life in the case of an aneurysm rupture is divided into three periods: prehemorrhagic, hemorrhagic, and posthemorrhagic.

The prehemorrhagic period is often asymptomatic (with small aneurysms) or may present as a space-occupying lesion (with large aneurysms). The hemorrhagic period is characterized by subarachnoid hemorrhage (SAH) clinical features. The posthemorrhagic period involves the development of consequences after the rupture (death, vegetative state, varying degrees of disability, satisfactory recovery, recurrent rupture of the same aneurysm).

In some cases, the rupture of a saccular aneurysm can lead to subarachnoid-paranchymal hemorrhage (simultaneous SAH and bleeding into the brain parenchyma in the area where the

aneurysm is adjacent to the brain). Occasionally, after the rupture of an aneurysm, the formation of open or occlusive hydrocephalus is possible.

The rupture of a saccular aneurysm and SAH most commonly occurs during active physical or emotional stress, suddenly, without warning signs. The age of patients varies, but it most often occurs between 25 and 50 years.

The first symptom is a sudden, sharp, intense headache (85-100% of cases), described by patients as an extraordinarily strong blow to the head or the sensation of hot liquid flowing in the head. Nausea, vomiting, and photophobia often accompany the pain. Consciousness disturbances occur in 50-60% of cases, and epileptic seizures occur in 10% of patients within the first day.

Meningeal signs are detected only 3-12 hours after the onset of the disease.

Focal symptoms with SAH are observed in the early and subacute periods. The first phase of focal symptoms (manifested in the first days of the disease) is associated with the effect of blood clots on various parts of the brain and cranial nerves. Possible damage to the oculomotor and abducent nerves, hemiparesis (blood clot in the lateral sulcus area with an aneurysm rupture of the middle cerebral artery), rarely - lower paraparesis (with rupture of the anterior communicating artery aneurysm). The development of focal symptoms in the first days after SAH may be potentiated by the primary spasm of cerebral arteries, caused by the action of blood breakdown products in the subarachnoid space.

The second phase of focal symptoms is more pronounced, and its onset is associated with the formation of secondary spasm of cerebral arteries (usually starting 4-6 days after SAH with a peak at 5-14 days), which occurs in 30% of patients.

Arterial spasm leads to ischemic stroke in 50% of cases, significantly worsening the patient's condition and prognosis. In 20% of patients, arterial spasm after SAH is the cause of death. The pathogenesis of spasm is similar to the one described above.

During the first days after SAH, there may be a moderate increase in body temperature (up to 37-38 °C) and arterial hypertension (detected in 50% of patients during the first day, regressing over the next few days).

Severity of patients' condition during acute subarachnoid hemorrhage (SAH) according to W. Hunt and R. Hess:

Severity Grade	Clinical Criteria
I	Asymptomatic course, minimal headache, or neck muscle stiffness.
II	Mild to moderate headache, presence of meningeal syndrome. No focal neurological symptoms, except possible involvement of cranial nerves.
III	Severe meningeal syndrome. Decreased consciousness (11-14 points on the Glasgow Coma Scale). Moderately pronounced focal symptoms.
IV	Severe meningeal syndrome. Consciousness reduced to the level of stupor (9-10 points on the Glasgow Coma Scale). Pronounced focal symptoms.
V	Unconsciousness, coma of varying depth (3-8 points on the Glasgow Coma Scale). No reaction to external stimuli or decerebrate rigidity.

### Diagnosics

Method of choice - CT (in the absence of CT - MRI), which can be complemented by angiography (conventional, digital subtraction, three-dimensional computed), transcranial Doppler. In the absence of CT (MRI), diagnostic lumbar puncture is performed (in the absence of signs of increased intracranial pressure). The Glasgow Coma Scale is used to assess the depth of consciousness impairment.

Domain	Score
--------	-------

1. Eye Opening:	
Spontaneous	4
To verbal command	3
To pain	2
None	1
2. Motor Response of Limbs (on the less affected side):	
To command	6
Localizes - purposeful movement	5
Withdrawal from pain	4
Abnormal flexion (decorticate)	3
Abnormal extension (decerebrate)	2
No response	1
3. Verbal Response:	
Oriented	5
Confused conversation	4
Inappropriate words	3
Incomprehensible sounds	2
No response	1
Total Glasgow Coma Scale Score: Highest score - 15; Lowest score - 3	

Levels of consciousness in comparison with the severity of the patient's condition according to the Glasgow Coma Scale:

Level of consciousness	Glasgow Coma Scale (in points)
Clear consciousness	15
Mild impairment	13—14
Moderate impairment	11—12
Sopor	9—10
Coma I (moderate)	7—8
Coma II (deep)	5—6
Coma III (terminal)	3—4

### Materials for self-assessment of training quality:

1. A 57-year-old man with a history of hypertension developed sudden severe headache, facial hyperemia, speech disturbances, weakness in the right limbs, and hyperthermia after physical exertion. A hyperdense lesion up to 4 cm in diameter was found on computed tomography in the left temporal region. What is the most likely pathology?

Hemorrhagic stroke.

2. A 52-year-old patient complains of episodes of weakness in the left limbs twice a week. Neurologically, there are no signs of intracranial or focal symptoms. Auscultation over the right carotid arteries reveals a systolic murmur. What should be done first to determine the cause of limb weakness episodes?

Duplex Doppler ultrasound of the brachiocephalic vessels.

3. A 40-year-old patient complains of severe headache and photophobia. He fell ill a day ago when he suddenly experienced severe headache and briefly lost consciousness. Examination reveals a Glasgow Coma Scale score of 14 and prominent meningeal signs. What should be done first for a preliminary diagnosis?

Computed tomography of the brain.

4. A 60-year-old patient is admitted to the neurosurgical department three hours after a sudden loss of consciousness. Examination shows a Glasgow Coma Scale score of 7, leftward

gaze, left-sided mydriasis, absent movements in the right limbs, and blood pressure of 200/120 mmHg. What is your diagnosis?

Hemorrhagic stroke.

5. A 33-year-old patient suddenly experiences severe headache, weakness in the right limbs, and speech disturbances. Examination six hours later reveals a Glasgow Coma

Summary

#### **Main Literature:**

1. Neurosurgery: textbook / [V.O. Pyatikop, I.O. Kutoviy, A.V. Kozachenko et al.]; edited by V.O. Pyatikop - Kyiv, VSV "Medicine", 2019. - 152 p.
2. Neurosurgery: textbook / [V.I. Tsimbalyuk, V.V. Medvedev, M.O. Marushchenko et al.]; edited by academician V.I. Tsimbalyuk. - 2nd edition, revised. - Vinnytsia: Nova Knyha, 2020. - 360 p.
3. Hryhorova I.A., Sokolova L.I., Herasymchuk R.D., Son A.S., et al. Neurology: Educational Manual / edited by I.A. Hryhorova, L.I. Sokolova - 3rd edition - Kyiv, VSV "Medicine", 2020. - 640 p.
4. Topical diagnosis of nervous system pathology. Diagnostic search algorithms. Shkrobot S.I., Saliy Z.V., Budarna O.Yu. Ukrmedknyha, 2018. - 156 p.
5. Methods of examination of a neurological patient: a tutorial / edited by L.I. Sokolova, T.I. Ilyash. Kyiv, 2020. - 144 p.
6. Emergency medicine. Emergency (ambulance) medical care: textbook / I.S. Zozulya, V.I. Bobrova, G.G. Roschin, etc. / edited by I.S. Zozulya. - 3rd edition, revised and supplemented. - Kyiv. - VSV "Medicine", 2017. - 960 p.
7. Negrych T.I., Bozhenko N.L., Matvienko Yu.Sh. Ischemic stroke: secondary inpatient care: a tutorial. Lviv: Danylo Halytsky Lviv National Medical University, 2019. - 160 p.
8. Handbook of Neurosurgery / Greenberg M.S. - Thieme, 2019. - 1784 p. ISBN 9781684201372
9. Neurology - Неврологія: textbook / I.A. Hryhorova, L.I. Sokolova, R.D. Herasymchuk et al.; edited by I.A. Hryhorova, L.I. Sokolova. – Kyiv : AUS Medicine Publishing, 2017. – 624p.

#### **Additional Literature:**

Bozhenko M.I., Negrych T.I., Bozhenko N.L., Negrych N.O. Headache. Educational manual.-K.: Medkniga Publishing House, 2019

#### **Informational resources:**

1. Clinical guidelines and other publications on neurosurgery (State Institution Romodanov Neurosurgery Institute of the National Academy of Medical Sciences of Ukraine)

<https://neuro.kiev.ua/uk/category/publishing-uk/>

2. Clinical guidelines on neurology. (Order of the Ministry of Health of Ukraine No. 487 dated 17.08.2007)

<https://zakon.rada.gov.ua/rada/show/v0487282-07#Text>

#### *Practical Class No. 8*

**Topic:** Principles of treating cerebrovascular pathology accompanied by intracerebral hemorrhage.

**Objective:** To familiarize with conservative and surgical treatment methods for cerebrovascular pathology accompanied by intracerebral hemorrhage.

**Key concepts:** aneurysm clipping, aneurysm coiling, hematoma evacuation, craniectomy.

**Equipment:** Classroom, furniture, equipment:

PC

Multimedia projector

Neurosurgical microscope Mitaka MM51YOH

Surgical table RAPSODIA WITH MODULAR TABLEWORK

Head fixation device DORO  
Electrosurgical unit BOWA ARC 400  
Ultrasonic surgical aspirator CUSA CI C7000  
Surgical aspirator Dominant Flex  
Neuromonitoring system INOMED XPERT  
Neurosurgical instruments  
Steam sterilizer TICHE  
Steam sterilizer KRONOS B23 with ROSI  
Sealing machine  
Ultrasonic cleaner

**Plan:**

1. Organizational activities (greetings, attendance check, announcement of the topic and goals of the session, motivation of students to study the topic).
2. Control of basic knowledge (written work, written testing, frontal questioning, etc.):
  - What are the main types of cerebrovascular diseases you know?
  - Primary types of intracranial hemorrhages.
  - What are the clinical signs of intracranial hemorrhage?
  - What signs indicate compression of the brain?
  - What auxiliary diagnostic methods are used for intracranial hemorrhages?
  - What can cause compression of the brain?
  - Optimal timing for surgical treatment of intracranial hemorrhages.
  - Rehabilitation and readaptation of patients.
  - Indications and contraindications for the use of paraclinical examination methods.
  - Indications and contraindications for surgical treatment of intracerebral hemorrhages.
  - Methods of surgical treatment of intracerebral hemorrhages.

**Content**

Conservative treatment:

1. Patients should initially be treated in the intensive care unit or stroke unit.
2. Hypertension may contribute to further bleeding, especially within the first hour.

Patients with systolic blood pressure (SBP) of 150–200 mm Hg and no contraindications to acute blood pressure (BP) management: lowering SBP to 140 is safe and improves functional outcomes.

Patients with SBP > 200 mm Hg: Consider rapid BP reduction using continuous intravenous administration and BP monitoring.

3. Intubation in the case of stupor or coma.
4. Maintenance of normothermia.
5. Antiepileptic drugs:

Seizures (clinical and subclinical) are treated with appropriate antiepileptic medications. Prophylactic antiepileptic drugs are not recommended.

Antiepileptic medication options:

Levetiracetam has a very favorable therapeutic/toxic profile. Dose: 500 mg twice daily.

OR Phenytoin: Loading dose of 17 mg/kg slowly IV over 1 hour, then 100 mg every 8 hours.

6. Hemostasis:

Monitoring: international normalized ratio (INR) (or prothrombin time (PT)), activated partial thromboplastin time (aPTT), platelet count (PC), platelet function analysis (PFA).

Correction of coagulopathy.

Platelets: correction of thrombocytopenia.

In severe deficiency of coagulation factors or severe thrombocytopenia: replenish missing factors or administer platelets.

Patients taking vitamin K antagonists (VKAs) (e.g., warfarin) with elevated INR:

- a) Discontinue VKAs.

- b) Replenish vitamin K-dependent clotting factors.
- c) Correction of INR.
  - Consider the use of prothrombin complex concentrate (PCC).
  - **✗** Not recommended: recombinant activated factor VII (rFVIIa) (does not restore all clotting factors and may not restore hemostasis in vivo, even when INR is normalized, and thromboembolic complications may occur).
- d) Administer intravenous vitamin K.

Patients taking dabigatran, rivaroxaban, or apixaban: consider treatment with activated PCCs with bypassing activity inhibitors to factor VIII (FEIBA), other PCCs, or recombinant activated factor VII.

Patients taking heparin: consider reversal with protamine sulfate.

- 7. Steroids: **✗** not recommended for ICH (exception: if underlying tumor is detected).
- 8. External ventricular drain (EVD): for hydrocephalus (**✗**, but not for intraventricular hemorrhage-related hydrocephalus), some cases of intracerebral hemorrhage, or for ICP monitoring.

**✗** Check hemostasis system before placement.

- 9. Monitor electrolyte levels and osmolality:
  - a) Monitor for hyponatremia.
  - b) Maintain euglycemia: avoid hyper- or hypoglycemia.
- 10. Cardiovascular system: systematic screening for ischemia or myocardial infarction is recommended. ECG and cardiac enzymes should be regularly monitored.
- 11. Swallowing: screen for dysphagia before initiating oral intake per os.
- 12. CTA or catheter angiography: primarily for excluding vascular anomalies, aneurysms (less common cause of ICH), and tumors (which are usually better diagnosed on contrast CT or MRI).

### Surgical Treatment

#### Indications

Cerebellar hemorrhage with neurological deterioration or brainstem compression and/or obstructive hydrocephalus due to intraventricular clot:

- a) Surgical clot removal should be performed as soon as possible.
- b) **✗** Initial treatment with external ventricular drainage (EVD) instead of surgical removal is not recommended.

2. Supratentorial ICH: the benefit of surgical intervention is not well established. Potential exceptions:

- a) Early evacuation of ICH is equivocal compared to evacuation with patient deterioration.
- b) Patients with deterioration: ICH evacuation may be considered a life-saving measure.
- c) Comatose patients or those with large ICH and significant midline shift or uncontrollable intracranial hypertension: decompressive craniotomy with or without ICH evacuation may reduce mortality.
- d) Minimally invasive ICH evacuation using stereotactic or endoscopic aspiration with or without thrombolytics is of uncertain efficacy.

#### Surgical Methods for Intracerebral Hemorrhage

- Positioning: lateral oblique with the affected side up.
- If speed is critical, a middle skin incision is preferred as it can be quickly opened with minimal risk of encountering the vertebral artery.
- Prefer craniectomy (without bone flap replacement) over craniotomy for postoperative swelling accommodation.
- Prophylactic Frazier burr hole is recommended for rapid treatment if postoperative hydrocephalus develops or ventricular catheter placement for ICP monitoring and potential postoperative CSF drainage.



- In cases of ventricular system breach, surgical microscope should be used to track the clot to the fourth ventricle, which is then cleared of the clot.

### **Subarachnoid Hemorrhage**

#### Endovascular Aneurysm Treatment

Aneurysm occlusion:

a) "Coiling" using electrolytically detachable coils.

b) Onyx HD 500 is used for wide-necked or giant internal carotid artery aneurysms.

c) "Flow diversion" using "closed-cell stents" (densely meshed stents), promoting aneurysm thrombosis.

"Trapping": effective treatment requires occluding both distal and proximal arteries, typically through endovascular techniques, sometimes through direct surgical methods (ligation or clipping), or a combination. It may also involve vascular bypass (e.g., EC-IC bypass) to ensure blood supply beyond the trapped segment.

Proximal ligation (so-called Hunter ligation) is useful for giant aneurysms. For non-giant aneurysms, it provides little benefit and adds a risk of thromboembolism (which can be mitigated by closing the common carotid artery instead of the internal carotid artery). It may also increase the risk of developing aneurysms in the contralateral circulation.

Clipping: the surgical gold standard. Surgical placement of a clip on the neck of an aneurysm to exclude it from circulation without occluding normal vessels.

Wrapping or covering of an aneurysm: although this should never be the primary goal of surgery, situations may arise where little else can be done (e.g., fusiform aneurysms of the trunk, aneurysms with a large number of branches originating from the dome):

a) muscle: the first method used for surgical treatment of aneurysms;

b) cotton or gauze;

c) plastic resin or other polymer;

d) teflon and fibrin glue.

#### **Clinical tasks and self-assessment tests:**

1. A 36-year-old patient lost consciousness while working in the garden and was brought to the clinic in a severe condition. According to relatives, he was practically healthy prior to this incident and had no complaints. There are no detected traumatic brain injuries. There is no focal neurological symptomatology. The patient presents with a disorder of consciousness resembling stupor and stiffness of the neck muscles. Blood pressure is 200/110 mmHg. Lumbar puncture reveals cerebrospinal fluid heavily tainted with blood, with a pressure of 200 mm H<sub>2</sub>O. What is the most likely cause of the condition?

a) Hemorrhagic stroke

b) Rupture of arteriovenous malformation of the brain

**c) Ruptured cerebral artery aneurysm, subarachnoid hemorrhage**

d) Traumatic brain injury

e) Intracranial hemorrhage into a tumor

2. Aneurysms typically occur:

a) In childhood

b) In adolescence

c) From adolescence to 40 years

**d) After 40 years**

e) Equally often throughout life

3. A 15-year-old student lost consciousness during physical education class, predominantly experiencing seizures in the right limbs. He was brought to the emergency department. On examination, he presents with a disorder of consciousness after coma type I. The coma type, restoration of tendon reflexes, pathological reflexes, recurrent periodic seizures in the limbs, pronounced stiffness of the neck muscles, and positive Kernig-Brudzinski signs are noted. Blood pressure is 170/100 mmHg. What is the preliminary diagnosis?

a) Hemorrhagic stroke

b) Rupture of arteriovenous malformation of the brain

**c) Ruptured cerebral artery aneurysm**

d) Traumatic brain injury

e) Intracranial hemorrhage into a tumor

4. A 35-year-old patient is examined 6 hours after the onset of illness: stupor, meningeal syndrome, and central hemiparesis on the right are observed. CT shows a hematoma in the left sulcus (volume 45 cm<sup>3</sup>), and angiography reveals an arterial aneurysm of the left middle cerebral artery. What type of surgery is indicated for the patient?

**a) Clipping of the aneurysm of the left middle cerebral artery and removal of the hematoma**

b) Occlusion of the aneurysm of the left middle cerebral artery with a balloon catheter

c) Occlusion of the aneurysm of the left middle cerebral artery with platinum coils

d) Excision of the aneurysm of the left middle cerebral artery

e) Left extracranial-intracranial microanastomosis (bypass)

5. A 42-year-old patient is examined 2 days after the onset of illness: dullness, hemihypesthesia on the left, and central hemiparesis on the left are observed. CT shows a hematoma in the right temporal lobe (volume 50 cm<sup>3</sup>), and angiography reveals an arteriovenous malformation in the right temporal lobe. What type of surgery is indicated for the patient?

a) Extirpation of the arteriovenous malformation and removal of the hematoma

b) Embolization of the arteriovenous malformation

c) Occlusion of the arteriovenous malformation with a balloon catheter

d) Occlusion of the arteriovenous malformation with platinum coils

e) Thrombosis of the arteriovenous malformation using gamma knife therapy

4. Summary

**Main Literature:**

10. Neurosurgery: textbook / [V.O. Pyatikop, I.O. Kutoviy, A.V. Kozachenko et al.]; edited by V.O. Pyatikop - Kyiv, VSV "Medicine", 2019. - 152 p.

11. Neurosurgery: textbook / [V.I. Tsimbalyuk, V.V. Medvedev, M.O. Marushchenko et al.]; edited by academician V.I. Tsimbalyuk. - 2nd edition, revised. - Vinnytsia: Nova Knyha, 2020. - 360 p.

12. Hryhorova I.A., Sokolova L.I., Herasymchuk R.D., Son A.S., et al. Neurology: Educational Manual / edited by I.A. Hryhorova, L.I. Sokolova - 3rd edition - Kyiv, VSV "Medicine", 2020. - 640 p.

13. Topical diagnosis of nervous system pathology. Diagnostic search algorithms. Shkrobot S.I., Saliy Z.V., Budarna O.Yu. Ukrmedknyha, 2018. - 156 p.

14. Methods of examination of a neurological patient: a tutorial / edited by L.I. Sokolova, T.I. Ilyash. Kyiv, 2020. - 144 p.

15. Emergency medicine. Emergency (ambulance) medical care: textbook / I.S. Zozulya, V.I. Bobrova, G.G. Roschin, etc. / edited by I.S. Zozulya. - 3rd edition, revised and supplemented. - Kyiv. - VSV "Medicine", 2017. - 960 p.

16. Negrych T.I., Bozhenko N.L., Matvienko Yu.Sh. Ischemic stroke: secondary inpatient care: a tutorial. Lviv: Danylo Halytsky Lviv National Medical University, 2019. - 160 p.

17. Handbook of Neurosurgery / Greenberg M.S. - Thieme, 2019. - 1784 p. ISBN 9781684201372

18. Neurology - Неврологія: textbook / I.A. Hryhorova, L.I. Sokolova, R.D. Herasymchuk et al.; edited by I.A. Hryhorova, L.I. Sokolova. - Kyiv : AUS Medicine Publishing, 2017. - 624p.

**Additional Literature:**

Bozhenko M.I., Negrych T.I., Bozhenko N.L., Negrych N.O. Headache. Educational manual.-K.: Medkniga Publishing House, 2019

**Informational resources:**

1. Clinical guidelines and other publications on neurosurgery (State Institution Romodanov Neurosurgery Institute of the National Academy of Medical Sciences of Ukraine)  
<https://neuro.kiev.ua/uk/category/publishing-uk/>
2. Clinical guidelines on neurology. (Order of the Ministry of Health of Ukraine No. 487 dated 17.08.2007)  
<https://zakon.rada.gov.ua/rada/show/v0487282-07#Text>

*Practical Class No. 9***Topic:** Cerebrovascular Disease Accompanied by Ischemic Stroke.**Objective:** To familiarize oneself with the modern classification, etiopathogenesis, clinical presentation, and diagnostic methods of acute cerebral ischemia.**Key Concepts:** Vascular atherosclerosis, ischemic stroke, stenosis, vascular thrombosis, and embolism in the vessels of the brain.**Equipment:** Classroom, furniture, equipment:

PC

Multimedia projector

Neurosurgical microscope Mitaka MM51YOH

Surgical table RAPSODIA WITH MODULAR TABLEWORK

Head fixation device DORO

Electrosurgical unit BOWA ARC 400

Ultrasonic surgical aspirator CUSA CI C7000

Surgical aspirator Dominant Flex

Neuromonitoring system INOMED XPERT

Neurosurgical instruments

Steam sterilizer TICHE

Steam sterilizer KRONOS B23 with ROSI

Sealing machine

Ultrasonic cleaner

**Plan:**

1. Organizational activities (greetings, attendance check, announcement of the topic and goals of the session, motivation of students to study the topic).

2. Control of basic knowledge (written work, written testing, frontal questioning, etc.):

Control Questions:

- Anatomy and physiology of the cerebrovascular system.
- Main causes of ischemic stroke.
- Risk factors for ischemic stroke.
- Pathogenesis of ischemic stroke according to different etiologies.
- Symptoms of involvement of different functional areas of the brain.

**Content****Etiology:**

- Atherosclerotic and atherothrombotic stenoses and occlusions of the major arteries supplying the brain.
- Arterio-arterial embolism (emboli form as fragments of thrombotic deposits on the surface of an atherosclerotic plaque located most proximally or due to erosion of its contents [Stage 4 of atherosclerosis] and migrate to the intracranial arteries).
- Cardiogenic embolism (emboli form in the heart chamber during atrial fibrillation, as a result of the presence of artificial valves, in rheumatic endocarditis, dilated cardiomyopathy, myocardial infarction, and during atrial fibrillation).
- Dissection of the walls of the major neck arteries.
- Lipohyalinosis of small cerebral arteries leading to the development of microangiopathy.
- Rheological changes in blood (in vasculitis, coagulopathies).

- Scar traumatic and external inflammatory lesions of blood vessels, fibromuscular dysplasia, as well as pathological bends, loops of vessels (rarely).

There are three main subtypes of cerebral ischemia:

- Thrombosis, localized artery obstruction in situ. Obstruction may result from arterial wall diseases, such as atherosclerosis, dissection, or fibromuscular dysplasia.
- Embolism - obstruction of an artery by particles of substrates originating from elsewhere.
- Systemic hypoperfusion - general blood circulation disturbance manifested in the brain and other organs.

Blood disorders are not typically the primary cause of stroke. However, increased blood clotting can lead to thrombus formation and subsequent cerebral embolism in the presence of endothelial damage located in the heart, aorta, or large arteries supplying the brain.

Pathologies affecting large extracranial vessels include:

- Atherosclerosis
- Dissection
- Takayasu's arteritis
- Giant cell arteritis
- Fibromuscular dysplasia

Pathologies affecting large intracranial vessels include:

- Atherosclerosis
- Dissection/vasculitis
- Non-inflammatory vasculopathy
- Moyamoya disease
- Vasoconstriction

Small vessel diseases affect the intracerebral arterial system, particularly the central (penetrating) arteries branching from the distal vertebral artery, basilar artery, middle cerebral artery, and the arteries of the Circle of Willis. These arteries thrombose due to:

- Lipohyalinosis (accumulation of lipid hyaline distally due to hypertension) and fibrinoid degeneration

- Atheroma formation at their origin or in the parent large artery

Embolic strokes are categorized into four categories:

- With a known cardiac source
- Those with possible cardiac or aortic sources based on transthoracic and/or transesophageal echocardiography results
- Those with arterial sources (embolism between arteries)
- Those with truly unknown sources, with negative embolic source tests

Cardioembolic strokes typically occur suddenly, though sometimes they are accompanied by interruptions or fluctuations in symptoms. Symptoms may completely resolve as emboli can migrate and fragment, especially those composed of thrombi. When this occurs, infarction usually also occurs but is silent; the infarct area is smaller than the ischemic area that caused symptoms. This process is often referred to as a transient ischemic attack (TIA) due to embolism, although it is more accurately called an embolic infarction or stroke in which symptoms disappear within 24 hours.

**The TOAST** classification divides ischemic strokes into five subtypes based on clinical features and results of ancillary investigations, including brain visualization, neurovascular assessments, cardiac tests, and laboratory assessments of prothrombotic status.

The five TOAST subtypes of ischemic stroke are:

- Large artery atherosclerosis
- Cardioembolism
- Small vessel occlusion
- Stroke of other determined etiology
- Stroke of undetermined etiology

Cerebral autoregulation is disrupted in certain conditions, including ischemic stroke. When cerebral perfusion pressure drops, cerebral blood vessels dilate to increase cerebral blood flow. If the drop in perfusion pressure exceeds the brain's compensatory capacity, cerebral blood flow decreases. Initially, the oxygen extraction fraction increases to maintain the level of oxygen delivery to the brain. As cerebral blood flow continues to decline, other mechanisms come into play.

Suppression of protein synthesis occurs at flow rates below 50 ml/100 g per minute. At 35 ml/100 g per minute, protein synthesis ceases completely, and glucose utilization temporarily increases. At 25 ml/100 g per minute, glucose utilization sharply declines, initiating anaerobic glycolysis, leading to tissue acidosis due to lactate accumulation. Electrical neuronal failure occurs at 16-18 ml/100 g per minute, and failure of membrane ionic homeostasis occurs at 10-12 ml/100 g per minute. This level usually marks the threshold for infarction development.

In individuals with hypertensive disease, autoregulation is adjusted to occur at higher arterial pressures. Lowering arterial pressure to normal levels can actually exacerbate the impairment of autoregulation occurring during a stroke and lead to further decreases in cerebral blood flow.

#### **Risk Factors:**

- Most thrombotic and embolic strokes associated with atherosclerosis occur in elderly patients. Individuals under 40 years old rarely have severe atherosclerosis unless they also have significant risk factors such as diabetes, hypertension, hyperlipidemia, smoking, or a strong family history. Cardiac embolism is also commonly seen in young individuals with heart disease.

- Pre-menopausal women have a lower frequency of atherosclerosis than men of the same age if they do not have major stroke risk factors. While data is limited, stroke prevalence may increase in women aged 45 to 54.

- Black and Asian populations, as well as adult women, have a lower frequency of extracranial carotid and vertebral artery occlusive diseases than white adult men.

- Small vessel strokes, strokes of undetermined origin, and large vessel strokes are more common among black individuals than whites.

- Heart diseases, including atrial fibrillation, valve diseases, recent myocardial infarction, and endocarditis, increase the likelihood of stroke due to embolism.

- Arterial hypertension

- Smoking

- Diabetes mellitus

- Elevated total cholesterol and decreased high-density lipoproteins have been associated with an increased risk of ischemic stroke and large artery stroke.

- Cocaine use

#### **Clinical Course of Symptoms and Signs.**

The most important aspect for differentiating stroke subtypes is the speed and progression of symptoms and signs, as well as their disappearance. Each subtype has a characteristic course:

- Embolic strokes usually occur suddenly. Deficits indicate a focal loss of brain function, which is usually maximal at the onset. Rapid recovery also more strongly suggests embolism.

- Symptoms associated with thrombosis often fluctuate between normal and abnormal or progress stepwise or intermittently with some periods of improvement.

- Occlusion of central arteries typically causes symptoms that develop over a short period of time, hours, or at most a few days.

#### **Key Symptoms:**

- Facial, arm, and leg weakness on one side of the body without sensory, visual, or cognitive impairments (pure motor stroke) indicates thrombotic stroke in the central artery basin or a small intracerebral hemorrhage.

- Large focal neurological deficits, which start suddenly or progress rapidly, are characteristic of embolism or intracerebral hemorrhage.

- Speech abnormalities indicate involvement of the anterior circulation, as do the presence of motor and sensory signs on one side of the body.
- Dizziness, ataxia, diplopia, deafness, cross symptoms (one side of the face and the other side of the body), bilateral motor and/or sensory signs, and hemianopsia indicate involvement of the posterior circulation.
- Sudden onset of impaired consciousness without focal neurological symptoms is characteristic of subarachnoid hemorrhage.

### **Diagnosis:**

When evaluating acute stroke, visualizing studies are necessary to exclude hemorrhage as the cause of deficit and to assess the extent of brain damage and identify the vessel involvement responsible for ischemic deficit. Modern CT and MRI technologies can differentiate brain tissue with irreversible infarction from potentially salvageable tissue, thus allowing better selection of patients likely to benefit from therapy.

#### **Changes in Parenchyma on CT:**

In hyperacute ischemic stroke, a head CT may either not show signs of ischemic changes or may demonstrate early signs of infarction, including:

- Loss of differentiation of gray-white matter in the basal ganglia (e.g., lentiform nucleus darkening)
- Loss of the insular ribbon or darkening of the Sylvian fissure
- Cortical hypoattenuation and effacement of sulci

**Feature of hyperdense artery on CT** — hyperdensity of the artery on non-contrast CT may indicate the presence of thrombus within the artery lumen. This can be seen on non-contrast CT in 30–40 percent of patients with MCA stroke. This finding is highly specific for MCA occlusion and may be observed both in proximal MCA occlusions (first branch) and more distal MCA occlusions (e.g., Sylvian point sign). Similarly, a thrombus in the basilar artery may manifest as hyperdensity of this artery on non-contrast CT.

#### **Parenchymal Changes on DWI**

- In acute ischemic stroke associated with cytotoxic edema, reduced water diffusion in the infarcted tissue causes enhancement (hyperintensity) of the signal on DWI and a corresponding decrease in signal intensity on ADC maps.
- In vasogenic edema, DWI signal enhancement may be observed due to T2 shine-through, but since water diffusion increases, a corresponding enhanced signal is also seen on the ADC map.

### **Vascular Imaging**

Neurovascular imaging using CTA or MRA can evaluate the aortic arch and extracranial (external carotid and vertebral) and intracranial (internal carotid, basilar, and Willis circle) large vessels. This is important for determining the presence of large vessel occlusion in patients with acute stroke who may benefit from mechanical thrombectomy, as well as for correctly assessing the stroke mechanism.

## **3. Materials for self-assessment**

### **Clinical Cases and Tests**

1. A 65-year-old patient complains of sudden onset of paralysis of the right upper and lower limbs, as well as speech disturbance. Examination reveals loss of sensation and muscle weakness on the right side of the body. The clinical picture suggests:

- a) Hemorrhagic stroke.
- b) Ischemic stroke.**
- c) Transient ischemic attack (TIA).
- d) Neurological disorder not related to stroke.

2. Which of the following mechanisms can lead to the formation of thrombus in vessels and contribute to ischemic stroke?

- a) Vasculitis.
- b) Embolism.

**c) Atherosclerosis.**

d) Hypertension.

Types of Ischemic Strokes:

3. Which types of ischemic strokes can occur due to blood flow blockage in different arteries of the brain?

a) Lacunar stroke.

b) Cortical stroke.

c) Posterior circulation stroke.

**d) All of the above.**

4. Which of the following factors can increase the risk of developing ischemic stroke due to arterial atherosclerosis?

**a) Hyperglycemia.**

b) Hypothyroidism.

c) Hypertriglyceridemia.

d) Low blood pressure.

5. A 65-year-old patient is hospitalized with sudden onset weakness on the right side of the body and speech impairment. His medical history includes hypertension and type 2 diabetes. Examination reveals loss of strength in the right arm and leg, aphasia. What diagnostic test should be performed to confirm a possible ischemic stroke?

a) Electrocardiogram (ECG).

**b) Magnetic resonance imaging (MRI) of the brain.**

c) Laboratory tests for blood sugar levels.

d) Chest X-ray.

6. Some ischemic strokes may occur due to involvement of the middle cerebral artery. What symptoms may occur with involvement of this region?

a) Sensory disturbances in the facial area.

b) Weakness of leg muscles.

**c) Aphasia.**

d) Visual disturbances.

7. A 60-year-old patient has a history of atrial fibrillation. During lunch, he suddenly lost the ability to speak and exhibited weakness in his right leg. Objectively: speech impairment, absence of movement in the right side of the body. What additional symptoms may support suspicion of an ischemic stroke?

**ANSWER:**

Coordination disturbance.

Decreased sensitivity in the right foot.

Aphasia.

8. A 45-year-old woman, who takes oral contraceptives, suddenly lost vision in one eye due to emotional stress, and experienced weakness in one arm and leg on the same side of the body. What possible complications are identified in this patient, and what laboratory and instrumental studies may be useful for diagnosis?

**ANSWERS:**

Complications: Ischemic stroke

Laboratory studies: Coagulogram, complete blood count.

Instrumental studies: CT, MRI of the brain

4. Summary.

**Main Literature:**

1. Neurosurgery: textbook / [V.O. Pyatikop, I.O. Kutoviy, A.V. Kozachenko et al.]; edited by V.O. Pyatikop - Kyiv, VSV "Medicine", 2019. - 152 p.

2. Neurosurgery: textbook / [V.I. Tsimbalyuk, V.V. Medvedev, M.O. Marushchenko et al.]; edited by academician V.I. Tsimbalyuk. - 2nd edition, revised. - Vinnytsia: Nova Knyha, 2020. - 360 p.

3. Hryhorova I.A., Sokolova L.I., Herasymchuk R.D., Son A.S., et al. Neurology: Educational Manual / edited by I.A. Hryhorova, L.I. Sokolova - 3rd edition - Kyiv, VSV "Medicine", 2020. - 640 p.
4. Topical diagnosis of nervous system pathology. Diagnostic search algorithms. Shkrobot S.I., Saliy Z.V., Budarna O.Yu. Ukrmedknyha, 2018. - 156 p.
5. Methods of examination of a neurological patient: a tutorial / edited by L.I. Sokolova, T.I. Ilyash. Kyiv, 2020. - 144 p.
6. Emergency medicine. Emergency (ambulance) medical care: textbook / I.S. Zozulya, V.I. Bobrova, G.G. Roschin, etc. / edited by I.S. Zozulya. - 3rd edition, revised and supplemented. - Kyiv. - VSV "Medicine", 2017. - 960 p.
7. Negrych T.I., Bozhenko N.L., Matvienko Yu.Sh. Ischemic stroke: secondary inpatient care: a tutorial. Lviv: Danylo Halytsky Lviv National Medical University, 2019. - 160 p.
8. Handbook of Neurosurgery / Greenberg M.S. - Thieme, 2019. - 1784 p. ISBN 9781684201372
9. Neurology - Неврологія: textbook / I.A. Hryhorova, L.I. Sokolova, R.D. Herasymchuk et al.; edited by I.A. Hryhorova, L.I. Sokolova. – Kyiv : AUS Medicine Publishing, 2017. – 624p.

#### **Additional Literature:**

Bozhenko M.I., Negrych T.I., Bozhenko N.L., Negrych N.O. Headache. Educational manual.-K.: Medkniga Publishing House, 2019

#### **Informational resources:**

1. Clinical guidelines and other publications on neurosurgery (State Institution Romodanov Neurosurgery Institute of the National Academy of Medical Sciences of Ukraine)  
<https://neuro.kiev.ua/uk/category/publishing-uk/>
2. Clinical guidelines on neurology. (Order of the Ministry of Health of Ukraine No. 487 dated 17.08.2007)  
<https://zakon.rada.gov.ua/rada/show/v0487282-07#Text>

#### *Practical Class No. 10*

**Topic:** Principles of treating cerebrovascular pathology accompanied by acute ischemic stroke.

**Objective:** To familiarize with conservative and surgical treatment methods for acute ischemic stroke.

**Key concepts:** thrombolysis, mechanical thrombectomy.

**Equipment:** Classroom, furniture, equipment:

PC

Multimedia projector

Neurosurgical microscope Mitaka MM51YOH

Surgical table RAPSODIA WITH MODULAR TABLEWORK

Head fixation device DORO

Electrosurgical unit BOWA ARC 400

Ultrasonic surgical aspirator CUSA CI C7000

Surgical aspirator Dominant Flex

Neuromonitoring system INOMED XPERT

Neurosurgical instruments

Steam sterilizer TICHE

Steam sterilizer KRONOS B23 with ROSI

Sealing machine

Ultrasonic cleaner

**Plan:**



1. Organizational activities (greetings, attendance check, announcement of the topic and goals of the session, motivation of students to study the topic).
2. Control of basic knowledge (written work, written testing, frontal questioning, etc.):  
Control questions:

- What are the anatomical and physiological properties of the cerebrovascular system?
- What are the main causes of ischemic stroke?
- What are the risk factors for ischemic stroke?
- What is the pathogenesis of ischemic stroke under different etiologies?
- Symptoms of involvement of different functional areas of the brain
- Diagnosis of ischemic stroke

### **Content**

All patients with acute ischemic stroke should be assessed to determine eligibility for reperfusion therapy with intravenous thrombolysis using recombinant tissue plasminogen activator (tPA; alteplase or tenecteplase) and/or mechanical thrombectomy.

Aspirin and other antiplatelet agents should not be used alone or in combination within the first 24 hours after intravenous thrombolysis treatment. In other cases, in the absence of contraindications or a known cardiac source requiring anticoagulation, antiplatelet therapy with aspirin alone or dual antiplatelet therapy (DAPT) should be initiated as soon as possible after the diagnosis of transient ischemic attack (TIA) or ischemic stroke.

### **Aspirin Only**

Indications for Aspirin Use.

Early monotherapy with aspirin (162–325 mg per day) is indicated for patients with TIA or acute ischemic stroke who do not have a known cardioembolic source at the time of presentation in the following clinical situations:

- Low-risk TIA
- Moderate to severe ischemic stroke, as defined by a National Institutes of Health Stroke Scale (NIHSS) score  $>5$ . For patients already receiving aspirin or clopidogrel antiplatelet therapy at the time of stroke onset, we continue the existing antiplatelet regimen when the NIHSS assessment is  $>5$ .

### **Indications for DAPT**

For patients with TIA or acute ischemic stroke who do not have a known cardioembolic source at the time of presentation and are able to swallow, short-term DAPT with aspirin and clopidogrel is indicated in the following clinical situations:

- High-risk TIA, defined as an ABCD2 score  $\geq 4$ .
- Minor ischemic stroke, defined by an NIHSS score  $\leq 5$ .
- Stroke due to atherosclerosis of the intracranial large artery, as evidenced by ischemic stroke associated with atherosclerotic stenosis of the intracranial large artery from 70 to 99 percent.

### **Regimen**

Aspirin (loading dose 160–325 mg, then 50–100 mg daily) plus clopidogrel (loading dose 300–600 mg, then 75 mg daily) for short-term DAPT. An alternative is aspirin (300–325 mg on the first day, then 75–100 mg daily) plus ticagrelor (loading dose 180 mg, then 90 mg twice daily).

- Duration – DAPT duration is typically limited to 21 days for patients with high-risk TIA or minor ischemic stroke but may be extended to 90 days for patients with atherosclerotic stenosis of the intracranial large artery from 70 to 99 percent. After this, antiplatelet therapy with aspirin alone, clopidogrel, or extended-release dipyridamole with aspirin should be continued indefinitely.

### **Thrombolysis**

#### **"Time is Brain."**

The sooner intravenous thrombolysis (IVT) treatment with alteplase is initiated after an ischemic stroke, the greater the likelihood that it will be beneficial. Eligible patients should begin

treatment as soon as possible within the respective 3- or 4.5-hour time window from stroke onset; treatment should not be delayed until the end of the time window.

**Mechanical thrombectomy (MT)** also depends on time, with clear benefit for patients with acute ischemic stroke caused by occlusion of the intracranial large artery in the proximal anterior circulation who receive treatment within 6 hours of symptom onset. Beyond 6 hours, MT may be an option in stroke centers for selecting patients with anterior circulation stroke based on visualization, whose symptoms began 6–24 hours before treatment.

**Inclusion Criteria for Thrombolytic Therapy**

- Clinical diagnosis of ischemic stroke resulting in measurable neurological deficit
- Symptoms onset within <4.5 hours before treatment initiation; if the exact onset time of the stroke is unknown, it is determined as the last time the patient was known to be at their normal or baseline neurological level

- Age  $\geq 18$  years

**Exclusion Criteria**

Ischemic stroke or severe head trauma within the past three months

Previous intracranial hemorrhage

Intracranial neoplasm

Malignancy of the gastrointestinal tract

Gastrointestinal bleeding within the last 21 days

Intracranial or spinal surgery within the last three months

Symptoms suggestive of subarachnoid hemorrhage

Persistent elevation of blood pressure (systolic  $\geq 185$  mm Hg or diastolic  $\geq 110$  mm Hg)

Active internal bleeding

Findings consistent with infective endocarditis

Stroke known or suspected to be associated with aortic arch dissection

Acute hemorrhagic diathesis

Hematologic

Platelet count  $< 100,000/\text{mm}^3$ \*

Current use of anticoagulants with INR  $> 1.7$  or PTT  $> 15$  seconds or aPTT  $> 40$  seconds\*

Therapeutic doses of low-molecular-weight heparin received within 24 hours; this exclusion does not apply to prophylactic doses (e.g., for VTE prevention)

Current use (i.e., last dose within 48 hours in a patient with normal kidney function) of direct thrombin inhibitor or direct factor Xa inhibitor with laboratory evidence of anticoagulant effect using tests such as aPTT, INR, TT

CT Features:

- Signs of hemorrhage

- Large areas of marked hypodensity consistent with irreversible damage

Only minor and isolated neurological signs or symptoms that are rapidly improving

Serum glucose level ( $< 2.8$  mmol/L)

Significant trauma within the last 14 days

Major operation within the previous 14 days

Gastrointestinal bleeding (remote) or genitourinary bleeding in the medical history

Seizures at stroke onset with postictal neurological deficits

Pregnancy

Arterial puncture in a non-compressible site within the previous seven days

Large ( $\geq 10$  mm), untreated intracranial aneurysm without rupture

Untreated intracranial vascular malformation

**Additional considerations for treatment from 3 to 4.5 hours from symptom onset**

Age  $> 80$  years

Use of oral anticoagulants regardless of INR

Severe stroke (NIHSS score  $> 25$ )

Combination of prior ischemic stroke and diabetes mellitus

The alteplase dose is calculated as 0.9 mg/kg of actual body weight with a maximum dose of 90 mg.

Ten percent of the dose is administered as an intravenous bolus over one minute, and the remainder is given over one hour.

### **Mechanical Thrombectomy Criteria**

Brain imaging using non-contrast CT or diffusion-weighted magnetic resonance imaging (DWI) excludes hemorrhage and corresponds to an assessment of early CT (ASPECTS)  $\geq 3$ .

- CT angiography (CTA) or MR angiography (MRA) demonstrates proximal occlusion of the large vessel (including internal carotid artery or middle cerebral artery extending to the proximal M2 segment) in the anterior circulation as the cause of ischemic stroke.

- The patient has a constant, potentially disabling neurological deficit; some recommendations require a National Institutes of Health Stroke Scale (NIHSS) score  $\geq 6$  points.

- Thrombectomy can be initiated within 24 hours after the patient was last seen well.

Catheterization is usually performed with femoral artery puncture. The catheter is directed into the internal carotid artery (ICA) and then to the site of occlusion of the intracranial large artery. Then a stent retriever is inserted through the catheter to reach the clot. The stent retriever is deployed and captures the thrombus, which is removed as the device is withdrawn. The initial goal is to achieve reperfusion - antegrade reperfusion in more than half of the previously occluded ischemic target territory or complete antegrade reperfusion of the previously occluded ischemic target territory.

Both second-generation stent retrievers and catheter-based aspiration devices can be used for MT.

### **Post-Reperfusion Treatment**

The optimal range of blood pressure during MT is insufficiently defined; there is no proven benefit – and potential harm – from aggressive early blood pressure reduction after reperfusion. Earlier data supported maintaining SBP  $< 160$ – $170$  mmHg for patients with successful reperfusion (i.e., mTICI 2b or 3) and a target SBP level of 170 mmHg for patients with less successful reperfusion (i.e., mTICI 0–2a). More intensive blood pressure lowering (e.g., achieving SBP  $< 140$  mmHg) may be harmful.

### **3. Clinical Tasks**

1. A 65-year-old patient presented to the emergency department with sudden onset weakness on the right side of the body and slurred speech. Upon examination, right-sided hemiparesis and facial droop were observed. The patient has a history of hypertension and hyperlipidemia. What initial steps should be taken for managing this patient with suspected ischemic stroke?

2. A 55-year-old woman is hospitalized with confirmed ischemic stroke. She is within the thrombolytic therapy window. Discuss the indications, contraindications, and potential risks associated with tissue plasminogen activator (tPA) administration in acute ischemic stroke. What factors will influence your decision to administer or withhold tPA in this case?

3. A 70-year-old patient recently experienced an ischemic stroke involving the left hemisphere. The patient's condition is now stable and ready for rehabilitation. Outline the key components of post-stroke treatment plan, including pharmacological interventions, rehabilitation strategies, and preventive measures to reduce the risk of recurrent strokes.

4. A 60-year-old man with diabetes mellitus and atrial fibrillation suffered an ischemic stroke in the territory of a large vessel. Discuss an individualized treatment plan regarding both acute phase and long-term management. Consider anticoagulant therapy, antiplatelets, blood pressure control, and lifestyle modification.

5. A 75-year-old patient is discharged from the hospital after an ischemic stroke. Develop a comprehensive secondary stroke prevention plan considering the patient's comorbidities such as diabetes mellitus and hypertension. Include pharmacological and non-pharmacological measures to minimize the risk of recurrent strokes.

ANSWERS:

1. Initial steps for treating this patient with suspected ischemic stroke include:  
 Immediate assessment of vital functions.  
 Non-contrast head CT or MRI of the brain to rule out hemorrhagic stroke.  
 Evaluation of eligibility for intravenous thrombolysis (tPA) within the appropriate time window.  
 Blood pressure control, glucose level monitoring, and supportive therapy.
2. Indications for tPA in acute ischemic stroke:  
 Onset of symptoms within the last 4.5 hours.  
 Absence of contraindications such as recent surgery, bleeding disorders, or active bleeding.  
 Absence of comorbidities in the medical history that increase the risk of bleeding.  
 Contraindications include recent major surgeries, bleeding disorders, recent intracranial hemorrhage, or active bleeding.
3. Key components of post-stroke treatment:  
 Antiplatelet therapy (aspirin or clopidogrel).  
 Blood pressure control.  
 Statin therapy.  
 Rehabilitation, including physical and occupational therapy.  
 Prevention and treatment of complications such as deep vein thrombosis and pneumonia.
4. Individualized treatment plan:  
 Anticoagulation for atrial fibrillation (warfarin or direct oral anticoagulants).  
 Antiplatelet therapy (aspirin or clopidogrel) if anticoagulant is contraindicated.  
 Blood pressure control using antihypertensive medications.  
 Diabetes management with glycemic control.  
 Lifestyle changes including smoking cessation, regular physical exercise, and a heart-healthy diet.
5. Comprehensive secondary stroke prevention:  
 Continuation of anticoagulant or antiplatelet therapy.  
 Aggressive blood pressure regulation.  
 Lipid-lowering therapy with statins.  
 Diabetes management.  
 Lifestyle modifications including smoking cessation, weight control, and regular physical exercise.  
 Regular monitoring and surveillance for potential complications.

#### 4. Summary.

#### **Main Literature:**

1. Neurosurgery: textbook / [V.O. Pyatikop, I.O. Kutoviy, A.V. Kozachenko et al.]; edited by V.O. Pyatikop - Kyiv, VSV "Medicine", 2019. - 152 p.
2. Neurosurgery: textbook / [V.I. Tsimbalyuk, V.V. Medvedev, M.O. Marushchenko et al.]; edited by academician V.I. Tsimbalyuk. - 2nd edition, revised. - Vinnytsia: Nova Knyha, 2020. - 360 p.
3. Hryhorova I.A., Sokolova L.I., Herasymchuk R.D., Son A.S., et al. Neurology: Educational Manual / edited by I.A. Hryhorova, L.I. Sokolova - 3rd edition - Kyiv, VSV "Medicine", 2020. - 640 p.
4. Topical diagnosis of nervous system pathology. Diagnostic search algorithms. Shkrobot S.I., Saliy Z.V., Budarna O.Yu. Ukrmedknyha, 2018. - 156 p.
5. Methods of examination of a neurological patient: a tutorial / edited by L.I. Sokolova, T.I. Ilyash. Kyiv, 2020. - 144 p.
6. Emergency medicine. Emergency (ambulance) medical care: textbook / I.S. Zozulya, V.I. Bobrova, G.G. Roschin, etc. / edited by I.S. Zozulya. - 3rd edition, revised and supplemented. - Kyiv. - VSV "Medicine", 2017. - 960 p.

7. Negrych T.I., Bozhenko N.L., Matvienko Yu.Sh. Ischemic stroke: secondary inpatient care: a tutorial. Lviv: Danylo Halytsky Lviv National Medical University, 2019. - 160 p.
8. Handbook of Neurosurgery / Greenberg M.S. - Thieme, 2019. - 1784 p. ISBN 9781684201372
9. Neurology - Неврологія: textbook / I.A. Hryhorova, L.I. Sokolova, R.D. Herasymchuk et al.; edited by I.A. Hryhorova, L.I. Sokolova. – Kyiv : AUS Medicine Publishing, 2017. – 624p.

**Additional Literature:**

Bozhenko M.I., Negrych T.I., Bozhenko N.L., Negrych N.O. Headache. Educational manual.-K.: Medkniga Publishing House, 2019

**Informational resources:**

- Clinical guidelines and other publications on neurosurgery (State Institution Romodanov Neurosurgery Institute of the National Academy of Medical Sciences of Ukraine)  
<https://neuro.kiev.ua/uk/category/publishing-uk/>
- Clinical guidelines on neurology. (Order of the Ministry of Health of Ukraine No. 487 dated 17.08.2007)  
<https://zakon.rada.gov.ua/rada/show/v0487282-07#Text>

*Practical Class No. 11*

**Topic:** Pathology of spinal cord vessels.

**Objective:** To familiarize with the etiology, pathogenesis, clinical presentation, diagnostic methods, and treatment of pathology of spinal cord vessels.

**Key concepts:** spinal cord blood supply disorders

**Equipment:** Classroom, furniture, equipment:

PC

Multimedia projector

Neurosurgical microscope Mitaka MM51YOH

Surgical table RAPSODIA WITH MODULAR TABLEWORK

Head fixation device DORO

Electrosurgical unit BOWA ARC 400

Ultrasonic surgical aspirator CUSA CI C7000

Surgical aspirator Dominant Flex

Neuromonitoring system INOMED XPERT

Neurosurgical instruments

Steam sterilizer TICHE

Steam sterilizer KRONOS B23 with ROSI

Sealing machine

Ultrasonic cleaner

**Plan:**

1. Organizational activities (greetings, attendance check, announcement of the topic and goals of the session, motivation of students to study the topic).
2. Control of basic knowledge (written work, written testing, frontal questioning, etc.):  
Control questions:
  - Anatomical and physiological properties of the vascular system of the spinal cord.
  - Main causes of disruption of spinal cord blood circulation.
  - Pathogenesis of spinal cord blood circulation disorders.
  - Symptoms of spinal cord blood circulation disorders.

**Content**

A wide range of diseases can cause spinal cord infarction. Diseases or procedures related to the thoracoabdominal segment of the aorta are common identifiable causes. Other spinal cord

anomalies such as vascular malformations or fibrocartilaginous embolism can also result in spinal cord infarction. Other embolic and thrombotic conditions that may lead to brain infarction can also cause spinal cord infarction. The underlying mechanisms can be categorized as follows:

- Arterial occlusion due to arteriosclerosis, vasculitis, infection, embolic occlusion, thrombosis

- Systemic hypoperfusion

- Venous infarction

#### **Aortic surgery.**

Surgery for the repair of thoracic and thoracoabdominal aortic aneurysms is the most common cause of spinal cord infarction.

Spinal cord ischemia following surgical intervention on the thoracic aorta may be clinically apparent immediately after the operation or following a period of normal neurological functioning. Delayed spinal cord ischemia has been reported as late as 27 days after surgical intervention.

#### **Aortic dissection.**

Acute dissection of the descending aorta is often a catastrophic event associated with high mortality rates (10 to 50 percent). Those who survive the acute episode often experience complications due to acute occlusion of branches, including the celiac, superior mesenteric, and renal arteries, as well as the radicular artery supplying the spinal cord.

Typically, spinal cord infarction in this case involves the mid and lower thoracic levels. Severe "tearing" pain and abnormal distal pulses are indicative of this diagnosis.

#### **Fibrocartilaginous embolism.**

Fibrocartilaginous embolism (FCE) is a rare phenomenon that can cause spinal cord infarction. FCE is associated with herniation of intervertebral discs. A wide age range of patients (7 to 78 years) may be affected by this phenomenon. Neck pain usually precedes neurological symptoms by 15 minutes to 48 hours. Magnetic resonance imaging (MRI) may show a disrupted intervertebral disc at the corresponding level. As the upper part of the cervical spinal cord is involved, mortality rates are relatively high.

Vascular malformation - the most common manifestation of spinal vascular malformation is progressive stepwise myelopathy. However, in some patients, the manifestations may be more acute or stroke-like.

#### **Clinical Presentation**

Spinal cord infarction typically presents with acute bilateral weakness of the lower limbs. However, in some patients, there may be acute weakness in the arms and legs or loss of sensation in the extremities; specific symptoms vary depending on the location of the lesion along the spine and the involved vascular territory.

While the onset of spinal cord infarction can be sudden, similar to cerebral infarction, in a significant portion of patients, symptoms may worsen over several hours.

Triggers may include heavy lifting, Valsalva maneuver, or other physical activities.

#### **Neurological Signs**

- Weakness and/or numbness - bilateral weakness with or without sensory disturbances is a common feature of many cases of spinal cord infarction since a single anterior spinal artery supplies segments of the spinal cord on both sides. The severity of motor and sensory impairments can vary widely from complete paralysis to mild weakness.

Paraplegia (legs) is most commonly encountered, but cervical spinal cord infarction may result in additional weakness in the arms and even respiratory failure.

- Pain. Back or neck pain often accompanies spinal cord ischemia and typically arises at the level of the lesion.

- Reflex disturbances - tendon reflexes at the level of the lesion and below are usually diminished or acutely absent. Within days or weeks, reflexes may become hyperactive below the level of injury, but may remain absent at the level of injury when damage occurs to cells in the anterior horns or nerve roots involved in a particular reflex loop.

- Autonomic dysfunction - hemodynamic instability, including hypo- or hypertension, may occur during acute spinal cord infarction of the cervical or upper thoracic segments. It is important to understand that hypotension can be both a cause and a manifestation of spinal cord ischemia.

Acute spinal cord infarction may also cause fever, bladder/bowel dysfunction, or sexual dysfunction. Chest pain with changes on electrocardiography (ECG) has been reported in a patient with spinal cord infarction from C7 to T1 due to autonomic dysfunction.

### **Diagnosis**

MRI is the preferred imaging modality for excluding compressive causes of myelopathic symptoms and can provide confirmatory evidence of spinal cord infarction. It can also help determine the underlying etiology. In most cases, this examination should be performed urgently, although it may be delayed if the patient requires emergency aortic surgery or other life-saving interventions.

Patients suspected of having spinal cord infarction should undergo spinal MRI with gadolinium contrast.

MRI changes associated with spinal cord ischemia include:

- Focal spinal cord edema
- Hyperintensity on T2-weighted and STIR images
- Restricted diffusion on diffusion-weighted images (DWI)
- Enhancement on post-contrast images

### **Treatment**

Identify the main high-risk causes requiring urgent treatment:

- Aortic dissection, aneurysm, or thrombosis (e.g., hemodynamic instability, severe chest/back pain, decreased/asymmetric peripheral pulses)
- Vertebral artery dissection (e.g., rostral spinal cord infarction, associated brainstem symptoms)
- Infective endocarditis (e.g., fever, new heart murmur)
- Bacterial meningitis (e.g., fever, meningismus)

Treat the underlying cause.

Treatment of spinal cord hypoperfusion:

- Correction of systemic hypotension
- Attempt to raise arterial pressure with vasopressors
- Lumbar drainage with targeted intracranial pressure

Glucocorticoids: Avoid glucocorticoids for most patients with spinal cord infarction.

Glucocorticoids are not recommended for acute ischemic stroke of the brain, and their benefit in ischemic spinal cord injury is unproven. Additionally, glucocorticoids may worsen neurological deficits in patients with suspected spinal cord infarction who are later found to have myelopathy due to a spinal arteriovenous fistula.

Cryptogenic spinal cord infarction - initiate antiplatelet therapy with aspirin at a dose of 81 mg daily.

### **Clinical tasks**

1. A 50-year-old patient suddenly developed severe back pain followed by weakness and loss of sensation in both legs. The patient has difficulty walking and complains of urinary retention. Conduct a focused neurological examination and propose the most likely diagnosis. What initial tests would you order to confirm the diagnosis of spinal cord infarction?

2. Based on clinical data, spinal cord infarction is suspected in a patient. Outline the visualization methods that can help confirm the diagnosis and assess the extent of spinal cord injury. Discuss the advantages and disadvantages of each visualization method.

3. A 45-year-old patient is hospitalized with suspected spinal cord infarction. In addition to imaging studies, what laboratory tests would you order to confirm the diagnosis, exclude potential causes, and guide patient management?

4. Spinal cord infarction has been diagnosed in a patient, and treatment has been initiated. Outline potential complications associated with spinal cord infarction and propose specific laboratory or diagnostic tests for monitoring these complications during the course of treatment.

5. A 55-year-old patient is undergoing treatment for spinal cord infarction. What clinical and laboratory parameters would you monitor to assess the patient's response to treatment and adjust the treatment plan accordingly?

**ANSWERS:**

1. Diagnosis: Acute spinal cord infarction.

Focused neurological examination:

Motor function: Assess muscle strength and tone in both legs.

Sensory function: Evaluation of sensation in different dermatomes.

Reflexes: Check deep tendon reflexes, including knee and Achilles reflexes.

Coordination: Assess gait and coordination.

Sphincter function: Inquire about urinary and fecal incontinence.

Initial tests:

Spinal MRI: for visualization of the spinal cord and confirmation of infarction.

CT angiography: to detect vascular anomalies or occlusions.

Complete blood count: rule out infection or inflammatory conditions.

Erythrocyte sedimentation rate (ESR) and C-reactive protein (CRP): assessment of inflammatory states.

2. MRI (magnetic resonance imaging): advantages include excellent soft tissue resolution; limitations include availability and contraindications (e.g., pacemakers).

CT (computed tomography): advantages include widespread availability; limitations include radiation exposure and the need for contrast.

CT angiography: for vascular supply assessment; advantages include rapid acquisition; limitations include contrast use.

3. Laboratory tests:

C-reactive protein (CRP) and erythrocyte sedimentation rate (ESR): elevated levels may indicate inflammatory or autoimmune diseases.

Complete blood count (CBC): Check for signs of infection.

Coagulation profile (PT/INR, aPTT): evaluation of coagulation status.

Blood glucose level: rule out diabetes, which can contribute to vascular problems.

Lipid profile: Assess cardiovascular risk factors.

4. Potential complications:

Urinary tract infections (UTIs): monitor for signs of infection (fever, dysuria) and perform urine culture.

Deep vein thrombosis (DVT) and pulmonary embolism (PE): if suspected, perform lower extremity ultrasound and chest CT angiography.

Pressure ulcers: regular skin checks and preventive measures.

5. Monitoring parameters:

Neurological examination: regularly assess motor and sensory function.

MRI or CT: periodic imaging to visualize changes in the spinal cord.

Blood pressure monitoring: maintain optimal arterial pressure to ensure adequate perfusion.

Rehabilitation progress: assess improvements in walking, coordination, and activities of daily living.

Monitoring of side effects: check for adverse effects of medications, such as anticoagulants.

4. Summary

**Main Literature:**

1. Neurosurgery: textbook / [V.O. Pyatikop, I.O. Kutoviy, A.V. Kozachenko et al.]; edited by V.O. Pyatikop - Kyiv, VSV "Medicine", 2019. - 152 p.



2. Neurosurgery: textbook / [V.I. Tsimbalyuk, V.V. Medvedev, M.O. Marushchenko et al.]; edited by academician V.I. Tsimbalyuk. - 2nd edition, revised. - Vinnytsia: Nova Knyha, 2020. - 360 p.
3. Hryhorova I.A., Sokolova L.I., Herasymchuk R.D., Son A.S., et al. Neurology: Educational Manual / edited by I.A. Hryhorova, L.I. Sokolova - 3rd edition - Kyiv, VSV "Medicine", 2020. - 640 p.
4. Topical diagnosis of nervous system pathology. Diagnostic search algorithms. Shkrobot S.I., Saliy Z.V., Budarna O.Yu. Ukrmedknyha, 2018. - 156 p.
5. Methods of examination of a neurological patient: a tutorial / edited by L.I. Sokolova, T.I. Ilyash. Kyiv, 2020. - 144 p.
6. Emergency medicine. Emergency (ambulance) medical care: textbook / I.S. Zozulya, V.I. Bobrova, G.G. Roschin, etc. / edited by I.S. Zozulya. - 3rd edition, revised and supplemented. - Kyiv. - VSV "Medicine", 2017. - 960 p.
7. Negrych T.I., Bozhenko N.L., Matvienko Yu.Sh. Ischemic stroke: secondary inpatient care: a tutorial. Lviv: Danylo Halytsky Lviv National Medical University, 2019. - 160 p.
8. Handbook of Neurosurgery / Greenberg M.S. - Thieme, 2019. - 1784 p. ISBN 9781684201372
9. Neurology - Неврологія: textbook / I.A. Hryhorova, L.I. Sokolova, R.D. Herasymchuk et al.; edited by I.A. Hryhorova, L.I. Sokolova. – Kyiv : AUS Medicine Publishing, 2017. – 624p.

**Additional Literature:**

Bozhenko M.I., Negrych T.I., Bozhenko N.L., Negrych N.O. Headache. Educational manual.-K.: Medkniga Publishing House, 2019

**Informational resources:**

1. Clinical guidelines and other publications on neurosurgery (State Institution Romodanov Neurosurgery Institute of the National Academy of Medical Sciences of Ukraine)  
<https://neuro.kiev.ua/uk/category/publishing-uk/>
2. Clinical guidelines on neurology. (Order of the Ministry of Health of Ukraine No. 487 dated 17.08.2007)  
<https://zakon.rada.gov.ua/rada/show/v0487282-07#Text>

*Practical Class No. 12*

**Topic:** Spinal Cord Tumors.

**Objective:** To acquire knowledge about the classification of spinal cord tumors. To learn how to independently examine patients with spinal cord tumors and master the algorithms for diagnosis and treatment.

**Key concepts:** spinal cord, classification of spinal cord tumors.

**Equipment:** Classroom, furniture, equipment:

PC

Multimedia projector

Neurosurgical microscope Mitaka MM51YOH

Surgical table RAPSODIA WITH MODULAR TABLEWORK

Head fixation device DORO

Electrosurgical unit BOWA ARC 400

Ultrasonic surgical aspirator CUSA CI C7000

Surgical aspirator Dominant Flex

Neuromonitoring system INOMED XPERT

Neurosurgical instruments

Steam sterilizer TICHE

Steam sterilizer KRONOS B23 with ROSI

Sealing machine  
Ultrasonic cleaner

**Plan:**

1. Organizational activities (greetings, attendance check, announcement of the topic and goals of the session, motivation of students to study the topic).
2. Control of basic knowledge (written work, written testing, frontal questioning, etc.):

Control Questions:

- Spinal cord: anatomy and physiology.
- Localization of spinal cord tumors.
- Clinical presentation of spinal cord tumors.
- Diagnosis of spinal cord tumors.

**Test Questions for Assessing Basic Knowledge on the Topic:**

There is involvement of the thoracic spine. There is an abnormal signal within the spinal cord (which narrows at the level of involvement) with extension through the neural foramen. This is best described as:

- A. extradural
- B. intradural extramedullary
- C. intradural intramedullary
- D. leptomeningeal

What is the most common type of intramedullary (spinal) tumor in adults?

- A. astrocytoma
- B. ependymoma
- C. ganglioglioma
- D. hemangioblastoma

Which of these extramedullary lesions are typically observed in vertebral segmentation anomalies?

- A. dermoid cyst
- B. epidermoid cyst
- C. meningioma
- D. neuroenteric cyst
- E. neuroendocrine tumor

**Content**

Spinal cord is a part of the central nervous system located within the spinal canal of the vertebral column. It extends from the corticomedullary junction at the foramen magnum to the tip of the conus medullaris inside the lumbar cistern. It is lined by the spinal meninges and housed within the spinal dural sac.

**Anatomy**

The spinal cord is approximately 42-45 cm in length, ~1 cm in diameter, and weighs about 35 grams. Like the brain, it consists of gray and white matter, but unlike the brain, the gray matter is located on the inner side of the cord, while the tracts of white matter are on the outside. Along its length, paired dorsal and ventral nerve roots enter its dorsolateral and ventrolateral surfaces, respectively.

The spinal cord is divided into cervical, thoracic, and lumbar segments, ending at the conus medullaris approximately at the level of the L1 vertebral body in adults. The spinal cord is segmental, with nerve roots emerging from it. There are a total of 31 pairs of nerve roots:

- 8 cervical
- 12 thoracic
- 5 lumbar
- 5 sacral
- 1 coccygeal

### **Internal Structure**

A transverse section of the spinal cord reveals a peripheral mass of white matter surrounding a central mass of gray matter shaped like an "H" or butterfly with a small central canal lined by ependyma and filled with cerebrospinal fluid. The cord is not completely divided into left and right halves by the shallow posterior median sulcus and the deep anterior median fissure.

#### **Gray Matter**

The gray matter contains cell bodies of neurons and glia and is expanded in the cervical and lumbosacral regions to provide fibers to the major nerve plexuses. It is divided into anterior, posterior, and lateral horns and the periependymal gray matter:

- Anterior horns
- contain motor neurons for skeletal muscles
- send efferent fibers through the ventral nerve roots
- Lateral horns
- contain autonomic neurons for pelvic and visceral organs
- present only in the thoracic region
- Posterior horns
- contain somatosensory neurons
- receive primary afferents from the dorsal roots of spinal nerves
- Periependymal gray matter
- divided into ventral and dorsal gray horns

#### **White Matter**

The white matter contains nerve fibers or tracts and is divided into anterior, dorsal, and lateral columns (also known as funiculi), as well as the anterior spinal cord.

- Columns
- anterior columns mainly contain spinothalamic tracts responsible for pain, temperature, crude (indiscriminate) touch, and pressure sensations
- dorsal columns contain ascending fibers responsible for vibration, conscious proprioception, and fine (discriminative) touch sensations
- lateral columns mainly contain corticospinal tracts, which are the major motor pathways connecting the cerebral cortex to spinal motor neurons
- anterior spinal cord lies between the far posterior part of the anterior median fissure anteriorly and the gray matter ventral horn posteriorly.

In general, fibers located dorsally process and transmit sensory information, fibers located laterally are preganglionic visceral motor neurons, and somatic motor fibers are located anteriorly.

There are two main types of brain and spinal cord tumors:

- Tumors that originate in the brain or spinal cord are called primary brain (or spinal) tumors.
- Tumors that begin elsewhere in the body and then spread to the brain or spinal cord are called metastatic or secondary brain (or spinal) tumors.

In adults, metastatic brain tumors are actually more common than primary brain tumors, and they are treated differently. This information pertains to primary brain tumors.

Unlike cancers that start in other parts of the body, tumors that begin in the brain or spinal cord rarely spread to distant organs. However, brain or spinal cord tumors are rarely considered benign (non-cancerous). They can still cause harm by growing and spreading into neighboring areas, where they can destroy normal brain tissue. And if they are not completely removed or destroyed, most brain or spinal cord tumors will continue to grow and eventually become life-threatening.

#### **Classification**

Brain and spinal cord tumors can be either benign or malignant (cancerous).

Benign tumors grow in place and do not invade surrounding tissues. They may need to be removed due to their size and location if they press on adjacent tissues or cause symptoms similar

to malignant tumors. Although they may require ongoing observation, after removal, they typically do not recur.

Malignant tumors usually grow rapidly and invade surrounding tissues. They require treatment and careful monitoring. Malignant brain and spinal cord tumors rarely spread to other parts of your body, but they can recur after treatment. Metastases are also considered malignant.

### **Types of Tumors**

According to the World Health Organization, there are over 120 types of central nervous system tumors.

Gliomas are the most common type of brain tumor in adults. They originate in the glial cells that support nerves in the brain and spinal cord.

Glioblastoma is the most common type of glioma. It typically forms in the brain, the largest part of your brain. It can also start in your spine. Glioblastomas create their own blood vessels and can grow rapidly, affecting neighboring areas.

### **Spinal Tumors**

Most tumors affecting the bones and cartilage cells in your spine have spread (metastasized) from another part of the body, usually through the bloodstream. In women, most tumors spread from the breasts or lungs. In men, most tumors spread from the prostate or lungs.

Sometimes spinal tumors start in the spine itself. Types of benign tumors include osteoid osteoma, osteoblastoma, and giant cell tumors. Malignant tumors include chondrosarcoma and Ewing sarcoma.

### **Intradural-Extramedullary Tumors**

These tumors arise from the dura mater, a thick, three-layer membrane that surrounds the cerebrospinal fluid and spinal cord. Most of them are benign meningiomas and nerve sheath tumors—schwannomas and neurofibromas.

### **Intramedullary Tumors**

These tumors originate from the supporting cells of the spinal cord. Most of these tumors are astrocytomas (more common in children) or ependymomas (more common in adults). Vascular tumors called hemangioblastomas can also arise here and are typically associated with an inherited condition called von Hippel-Lindau disease.

### **Risk Factors**

Most brain tumors occur in people without any known risk factors. If you've been diagnosed with a brain or spinal tumor, it's not your fault. Most of these tumors are caused by cancer spreading from other parts of your body or by changes in genes that control brain cell growth. Other risk factors include:

- Genetic conditions. Some people with genetic disorders such as neurofibromatosis, von Hippel-Lindau disease, Li-Fraumeni syndrome, and retinoblastoma are at higher risk. In rare cases, brain and spinal cord tumors may develop in family members who do not have these syndromes. Schwannomas may also have a genetic trigger.

- Radiation therapy. People who have undergone radiation therapy to the head for other types of cancer are at increased risk of brain and spinal cord tumors.

- Family history. Most people with brain tumors do not have a family history of the disease. In rare cases, brain or spinal cord tumors may be hereditary.

- Weak immune system. People with a weak immune system have a higher risk of developing central nervous system lymphoma (CNS). This applies to people with HIV/AIDS or those who have undergone organ transplantation.

### **Clinical Manifestations of Spinal Tumors**

Back pain that does not decrease during rest is the most common symptom of spinal tumors. Most back pains are not caused by a tumor. However, if there is a history of cancer, it is important to seek medical help for back pain, as other types of cancer typically spread to your spine.

- Sciatica or pain radiating from the lower back, buttocks, and back of the legs
- Numbness in the legs, arms, or chest
- Difficulty walking

- Scoliosis or spinal curvature due to a tumor deforming the spine
- Dysfunction of the bladder or bowels
- Paralyzes, paresis.

New growths of the spinal canal encompass a variety of tumors that arise or involve the spinal cord and spinal nerves.

### **Pathology**

They can be divided according to the tissue/structure of origin in the spinal canal. Spinal body tumors are considered separately:

#### **Spinal Cord (Intramedullary)**

- Spinal ependymoma
- Spinal astrocytoma (diffuse)
- Spinal pilocytic astrocytoma
- Spinal hemangioblastoma
- Metastases to the spinal cord (intramedullary)
- Spinal leptomeningeal metastases (they can mimic exophytic tumors)
- Spinal primitive neuroectodermal tumors
- Spinal lymphoma/leukemia
- Spinal ganglioglioma

#### **Intradural-Extramedullary**

- Spinal meningioma
- Tumors of the spinal nerve sheath
- Spinal schwannoma
- Spinal neurofibroma
- Spinal leptomeningeal metastases

#### **Cauda Equina and Filum Terminale**

- Myxopapillary ependymoma
- Tumors of the spinal nerve sheath
- Spinal schwannoma
- Spinal paraganglioma
- Spinal lymphoma/leukemia
- Metastases

### **Diagnosis**

MRI or CT with contrast

### **Treatment**

Strategic goals of surgical treatment: maximal radical tumor removal while preserving the vascular network of the spinal cord, its tissue, and roots. In most cases, surgical intervention for spinal cord tumor removal involves laminectomy at the appropriate level. Surgical interventions for craniospinal and other variants of tumors with dual localization have their own characteristics.

I. For extradural tumors, the dura mater is not incised. The tumor node is removed in parts or as a whole block, with the capsule.

For root neuromas associated with the tumor, coagulation and sectioning are performed, followed by tumor removal. Neuromas of the "hourglass" type are difficult to remove. In such cases, combined approaches are used: from the side of the spinal canal and from the side of the thoracic or abdominal cavity. For the prevention of recurrence, the area of the spinal cord associated with the tumor is removed or coagulated during the removal of meningiomas. To remove tumors located subdurally, the dura mater is incised. The defect in the dura mater after tumor removal is hermetically closed with a preserved membrane or fascia.

II. Intramedullary tumors do not have clear boundaries, they spread along the rostro-caudal axis, so their total removal is often impossible. Removal of intramedullary spinal cord tumors must be performed exclusively using microsurgical techniques, especially for tumors with a cystic component. The operation involves a midline incision of the posterior surface of the spinal cord (myelotomy), emptying of cysts, and partial removal of the tumor to decompress the spinal cord

and restore cerebrospinal fluid circulation. However, myelotomy is a spinal cord injury, the consequences of which are sometimes unpredictable. Therefore, removal of intramedullary tumors, especially in the cervical region, is associated with the risk of significant iatrogenic worsening of deficits and even patient death.

III. Radical surgical removal within healthy tissues is the optimal method for treating primary benign spinal tumors.

A. Ventral approaches with subsequent corpectomy and fixation of the affected spinal segment are used to remove the affected vertebral body.

B. Percutaneous vertebroplasty is the optimal method for treating hemangiomas. In recent times, radiation therapy has lost priority due to frequent recurrences and high radioresistance of hemangiomas.

IV. Radiosurgery and radiation therapy as the main method of treatment are indicated for patients with difficult-to-reach tumor localization, such as at the level of C1-C2, as well as for highly vascularized tumors with significant spread. Radiation therapy leads to a reduction in tumor size, clearer demarcation from adjacent tissues, which subsequently facilitates surgical intervention.

V. Combined treatment for primary malignant tumors is applied after maximal radical surgical removal of the tumor. Chondrosarcomas are prone to frequent recurrences and resistant to radiation therapy. A favorable prognosis is possible only with radical tumor removal. After the removal of malignant tumors, it is advisable to undergo radiation and chemotherapy (the radiation dose is selected depending on the histological type of the tumor), as well as radiosurgical treatment.

3. Questions (test tasks, problems, clinical situations) to assess basic knowledge on the topic of the session:

What is the most common type of spinal tumor?

- a) Ependymoma
- b) Oligodendroglioma
- c) Astrocytoma**
- d) Meningioma

Which spinal tumor is most commonly associated with neurofibromatosis type 2 (NF2)?

- a) Schwannoma**
- b) Ependymoma
- c) Meningioma
- d) Hemangioblastoma

A tumor of the spinal cord arising from the arachnoid membrane is called:

- a) Schwannoma
- b) Ependymoma
- c) Meningioma**
- d) Neurofibroma

Which imaging modality is typically used to assess spinal tumors?

- a) Magnetic resonance imaging (MRI)**
- b) Computed tomography (CT)
- c) X-ray
- d) Ultrasound (US)

4. Summary

#### **Main Literature:**

1. Neurosurgery: textbook / [V.O. Pyatikop, I.O. Kutoviy, A.V. Kozachenko et al.]; edited by V.O. Pyatikop - Kyiv, VSV "Medicine", 2019. - 152 p.

2. Neurosurgery: textbook / [V.I. Tsimbalyuk, V.V. Medvedev, M.O. Marushchenko et al.]; edited by academician V.I. Tsimbalyuk. - 2nd edition, revised. - Vinnytsia: Nova Knyha, 2020. - 360 p.

3. Hryhorova I.A., Sokolova L.I., Herasymchuk R.D., Son A.S., et al. Neurology: Educational Manual / edited by I.A. Hryhorova, L.I. Sokolova - 3rd edition - Kyiv, VSV "Medicine", 2020. - 640 p.
4. Topical diagnosis of nervous system pathology. Diagnostic search algorithms. Shkrobot S.I., Saliy Z.V., Budarna O.Yu. Ukrmedknyha, 2018. - 156 p.
5. Methods of examination of a neurological patient: a tutorial / edited by L.I. Sokolova, T.I. Ilyash. Kyiv, 2020. - 144 p.
6. Emergency medicine. Emergency (ambulance) medical care: textbook / I.S. Zozulya, V.I. Bobrova, G.G. Roschin, etc. / edited by I.S. Zozulya. - 3rd edition, revised and supplemented. - Kyiv. - VSV "Medicine", 2017. - 960 p.
7. Negrych T.I., Bozhenko N.L., Matvienko Yu.Sh. Ischemic stroke: secondary inpatient care: a tutorial. Lviv: Danylo Halytsky Lviv National Medical University, 2019. - 160 p.
8. Handbook of Neurosurgery / Greenberg M.S. - Thieme, 2019. - 1784 p. ISBN 9781684201372
9. Neurology - Неврологія: textbook / I.A. Hryhorova, L.I. Sokolova, R.D. Herasymchuk et al.; edited by I.A. Hryhorova, L.I. Sokolova. – Kyiv : AUS Medicine Publishing, 2017. – 624p.

#### **Additional Literature:**

Bozhenko M.I., Negrych T.I., Bozhenko N.L., Negrych N.O. Headache. Educational manual.-K.: Medkniga Publishing House, 2019

#### **Informational resources:**

- Clinical guidelines and other publications on neurosurgery (State Institution Romodanov Neurosurgery Institute of the National Academy of Medical Sciences of Ukraine) <https://neuro.kiev.ua/uk/category/publishing-uk/>
- Clinical guidelines on neurology. (Order of the Ministry of Health of Ukraine No. 487 dated 17.08.2007) <https://zakon.rada.gov.ua/rada/show/v0487282-07#Text>

#### *Practical Class No. 13*

**Topic:** Osteochondrosis

**Objective:** To gain an understanding of the clinical presentation of osteochondrosis, and to acquire knowledge of indications and principles of treatment.

**Key concepts:** degenerative disc disorders, intervertebral disc herniation, protrusions, vertebroplasty.

**Equipment:** Classroom, furniture, equipment:

PC

Multimedia projector

Neurosurgical microscope Mitaka MM51YOH

Surgical table RAPSODIA WITH MODULAR TABLEWORK

Head fixation device DORO

Electrosurgical unit BOWA ARC 400

Ultrasonic surgical aspirator CUSA CI C7000

Surgical aspirator Dominant Flex

Neuromonitoring system INOMED XPERT

Neurosurgical instruments

Steam sterilizer TICHE

Steam sterilizer KRONOS B23 with ROSI

Sealing machine

Ultrasonic cleaner

**Plan:**

1. Organizational activities (greetings, attendance check, announcement of the topic and goals of the session, motivation of students to study the topic).
2. Control of basic knowledge (written work, written testing, frontal questioning, etc.):

## Control Questions:

- Anatomy and physiology of the spine
- Degenerative spine disorders, age-related features
- Clinical course of osteochondrosis
- Diagnosis of osteochondrosis

**Content**

Osteochondrosis is a medical condition typically caused by the normal aging process, during which anatomical changes occur and one or more intervertebral discs of the spine may lose function.

**Pathogenesis**

The intervertebral disc consists of three layers: I) the fibrous ring with its outer and inner parts, II) the central pulpy nucleus, and III) the terminal plates. The disc is an avascular structure, composed of fibrous tissue and cartilage. Microscopically, it consists of few fibroblast-like cells arranged within the extracellular matrix, which comprises the majority of the disc structure. Both cells and matrix are essential for the normal function of the intervertebral disc.

Many mechanical factors, depending on the duration, severity, type, and location of the load, influence the condition of the intervertebral disc and, consequently, the biological response to these factors. The boundary between the disc's annulus and its nucleus becomes more distinct during growth. Degenerative processes involve structural damage to the intervertebral disc and changes in the quantity and composition of cells. With aging and progressive degeneration, the nucleus is primarily affected, becoming more fibrous and less elastic. Tiny concentric fissures occur in the outer part of the disc, from where they extend into the nucleus.

The amount of fibrous tissue increases, and the composition and quantity of proteoglycans change, affecting the number of cells due to apoptosis. Various factors such as mechanical, traumatic, genetic, and dietary play important roles in the degenerative process. Fibers in the fibrous ring become increasingly disoriented, and the network of elastin and collagen fibers gradually breaks down. Cells in the nucleus undergo apoptosis and subsequently necrosis, while they also tend to proliferate excessively. These degenerative cascades are common, and in the adult intervertebral disc, up to 50% of cells may be necrotic.

The loss of proteoglycans is the primary factor in disc degeneration. These large molecules degrade into smaller fragments, which are lost from the disc tissue. This results in a decrease in the osmotic pressure in the disc matrix and the loss of water molecules, affecting the mechanical properties of the disc. Since degenerated intervertebral discs contain less water and, therefore, have a lower ability to withstand pressure, they protrude and lose height. The loss of proteoglycan also affects the movement of other molecules into and out of the disc matrix. Serum proteins and cytokines diffuse into the matrix, affecting cells and accelerating the degeneration process.

The degenerative changes in the intervertebral disc are associated with damage to adjacent structures such as ligaments, joints, and spinal muscles. This leads to functional changes and increased susceptibility to injury. Due to overload, the degenerated intervertebral disc is below the norm, and the apophyseal joints must bear greater loads. This results in osteoarthritis degeneration. The strength of the yellow ligaments decreases, leading to their hypertrophy and bulging into the spinal canal, causing narrowing and compression of neural structures. The causes of pain in the degenerative process are complex and in many cases involve a combination of structural and mechanical deformation, as well as the activity of inflammatory mediators. Spinal nerve roots are often involved in the degenerative cascade, which causes chronic pain primarily through their compression and partly through the ingrowth of tiny nerve endings into the degenerated disc and their activation by the constant release of inflammatory mediators.

**Clinical Presentation**



Patients with **cervical radiculopathy** typically present with various signs and symptoms, such as neck pain and unilateral arm pain with numbness, weakness, or reflex changes. The main signs and symptoms of patients include arm pain in 97–99%, sensory deficit in 85–91%, reflex deficit in 71–84%, neck pain in 56–80%, motor deficit in 64%–70%, shoulder pain in 37–52%, anterior chest pain in 18%, and headache in 10%.

**Lumbar radiculopathies** of L2, L3, and L4 are considered a group. This group has pronounced innervation overlap of the muscles of the anterior thigh. Acute trauma spreading to L2, L3, and L4 is most commonly manifested when the patient feels back pain radiating anteriorly to the thigh, which may progress to the knee and possibly radiate medially to the shin or foot. During examination, patients may experience weakness during knee extension, adduction, and/or thigh flexion. Decreased sensitivity along the front of the thigh along the pain area is often observed in patients. Patients may have a reduced patellar reflex (L4). Actions that may exacerbate symptoms include coughing, leg straightening, or sneezing.

For **L5 radiculopathy**, patients often complain of acute back pain radiating down the side of the leg to the foot. During examination, there may be decreased muscle strength in dorsiflexion of the big toe (long extensor of the big toe), foot eversion, inversion, toe extension, and foot dorsiflexion. Chronic L5 radiculopathy may cause atrophy of the short toe extensor muscle (a marker of L5 radiculopathy on EMG) and the anterior tibialis muscle. Severe L5 radiculopathy may affect the small and medium gluteal muscles, causing weakness in leg abduction.

**S1 radiculopathy** causes pain radiation from the lower back or buttocks to the back of the patient's leg, foot, or perineum. Weakness in plantar flexion may be observed during examination. Loss of sensation along the back of the calf and the lateral side of the foot may also be present. The Achilles reflex (S1) may also be lost or weakened.

Pronounced patterns of motor deficit characteristic of L5 or S1 radiculopathy aid in the diagnosis compared to other radiculopathies. L4 and S1 nerve roots have their distinct innervation for testing sensation and muscle strength.

Examination findings that aid in the diagnosis of radiculopathy include the inability of the patient to rise from a chair, a history of knee bending and toe scrunching during locomotion. Examination findings suggest weakness of the quadriceps or four-headed muscle, weakness of the four-headed and anterior tibialis muscles, respectively. Decreased deep tendon reflexes for L4 and L5 are also helpful in confirming the diagnosis of lumbar radiculopathy.

Straight leg raise may be useful in lumbar radiculopathy diagnosis. The mechanism of pain during straight leg raising lies in the increased tension of the dura mater applied to the lumbar spine during the test. During the examination, patients lie on their back. The physician flexes the patient's quadriceps with leg extension and also dorsiflexes the patient's foot on the side of the symptoms. Pain or reproduction of paresthesias is considered a positive test (Lasègue's sign). The crossed sign alleviates this basic root pain by bending the patient's knee on the side of the injury. The straight leg raise test is most helpful in diagnosing L4 and S1 radiculopathies.

The contralateral straight leg raise test is a passive flexion of the quadriceps with the leg extended and the foot dorsiflexed on the unaffected leg by the physician. This test is positive if the unaffected leg reproduces root symptoms in the affected extremity of the patient. However, the straight leg raise test is more sensitive but less specific than the contralateral straight leg raise test.

The deep tendon reflex of the patellar tendon for L5 radiculopathy has also been a useful test. Tapping or semi-percussion, or semi-tendinous tendon proximal to the popliteal fossa, elicits the reflex. Asymmetry of the reflex between the legs suggests radiculopathy.

For non-radicular back pain, pain is localized to the spinal or paraspinal areas.

### **Diagnostic Investigations**

MRI can be used to differentiate between the nucleus and the annulus; thus, it allows the differentiation of localized and uncontained disc herniations. With this information, pathological discs can be described as protruding discs, extruded disc herniations, or migrated discs.

MRI can show annular ruptures and posterior longitudinal ligaments. Thus, it can be used for the classification of herniations, from simple annular herniations to extruded intervertebral disc herniations and disc herniations with a free fragment.

In the absence of MRI, computed tomography (CT) is accurate for diagnosing disc herniations due to contrast between disc herniation material, perineural fat, and adjacent posterior-lateral edges of vertebral bones. However, MRI remains the method of choice for diagnosing lateral herniations.

CT has several advantages over MRI. These include lower cost, less stress for patients with claustrophobia, and better detection of subtle bony changes (e.g., spondylolysis, early degenerative changes of facet joints). CT is also better suited for evaluating bone integrity after fusion.

Inflammatory causes of back pain can be excluded using acute-phase reactant tests such as erythrocyte sedimentation rate and C-reactive protein level. Complete blood count (CBC), including platelet count, should be obtained. Seronegative spondyloarthropathies (SNSA) are common causes of back pain, so they should be ruled out (HLA-B27). Testing for rheumatoid factor (RF) and testing for antinuclear antibodies (ANA) are good screening tools for autoimmune diseases.

## **Treatment**

### **Conservative Management**

#### **Patient Education on Back Pain**

The goal is to teach patients to independently manage back pain. Firstly, knowledge of normal spine anatomy and biomechanics, as well as injury mechanisms, is imparted. Then the diagnosis is explained to the patient using spine models. A neutral or balanced position, which varies from patient to patient, is sought.

At the patient's school, they are taught basic body mechanics, such as proper posture for standing, standing at a table or drawing board, sitting, tooth brushing, face washing, pushing and pulling loads, lifting loads, getting up and getting out of bed, sleeping, getting into a car, and sitting in a car. Patients are also taught proper and improper approaches to sitting, bending forward, lying down, coughing, or sneezing when experiencing back pain.

#### **Exercises**

Different types of exercises are prescribed for each patient depending on the diagnosis. Floor exercises include abdominal stretching, modified seated positions, knee-to-chest or hip stretches, sitting lifts, mountain and valley exercises, knee-to-elbow exercises, hamstring stretching, flexion exercises, and flexion flexibility exercises. Swimming exercises are among the best measures for treating back pain. Aerobic exercises improve endurance if performed regularly (i.e.,  $\geq 3$  times per week). Relaxation exercises are useful for relieving muscle tension, which can exacerbate back pain.

#### **Medications**

These include muscle relaxants, nonsteroidal anti-inflammatory drugs (NSAIDs), and analgesics. Physical Modalities These include the use of ice packs, heating pads, electrical stimulation, phonophoresis, iontophoresis, relaxation, and biofeedback.

#### **Injections**

Epidural steroid injections are most commonly used for therapeutic purposes. The type and dosage of steroid used are highly varied. The response to epidural injections varies, and many experts believe that injections have only short-term value. Even if a favorable response is observed, no more than four injections should be given per year. Immediate pain relief can be achieved by adding 4-6 mg preservative-free morphine to an epidural steroid injection. Pruritus is a reliable sign of epidural anesthesia.

Patients should be monitored for 24 hours after epidural steroid-morphine injections for signs of respiratory depression or urinary retention, even if these side effects are rare. If morphine is to be avoided, lidocaine or bupivacaine can be administered in combination with steroid to achieve immediate pain control, albeit short-lived.

#### **Surgical Treatment: Lumbar Procedures**

Surgical procedures on the lumbar spine, most commonly performed for the treatment of degenerative disc disease, are divided into two categories:

**Decompression** - involves the removal of bone or disc material around the compressed nerve root to alleviate nerve compression and provide more space for their recovery; the procedure is performed by laminectomy and discectomy

**Spinal fusion** - involves the use of a bone graft to fuse one or more vertebrae and stop movement in the painful segment of the spine to halt or reduce pain occurring in the joint.

Evidence of moderate quality was found for the following outcomes:

There were no significant differences in Odom's criteria between autograft iliac crest and metallic cage methods.

Fusion with a bone graft was more effective than discectomy alone.

The complication rate did not significantly differ only for autograft iliac crest and discectomy.

### **Lumbar Discectomy**

During surgery, the affected level is identified using a posterior midline approach. The incision of the yellow ligament begins at the midline, where it deviates from the dura mater. The yellow ligament is cut with a single piece to open the intervertebral space on one side. The opening is expanded by cutting pieces of the lamina. Difficulty retracting the root indicates that it is compressed by a herniated intervertebral disc or stuck in a narrowed lateral recess.

After identifying the nerve root, it is retracted and a cruciate incision is made in the annulus. Free disc fragments are extracted with pituitary rongeurs. The nerve root should be freely movable and easily retractable; otherwise, it may still be compressed or there may be lateral stenosis. In the latter case, lateral recess and nerve root canal must be enlarged (see below). A free fat graft is placed on the exposed dura mater to prevent adhesions.

After surgery in the intensive care unit, neurological examination is conducted, the results of which serve as the baseline. In case of difficulties with urination, a urinary catheter is used. After the operation, the patient can stand and walk for a long time. Usually, the patient can go home within 1-5 days after the surgery. Some surgeons also perform lumbar discectomy on an outpatient basis.

From this point on, exercises for the core muscles begin (pelvic tilts and semi-squats). Observation initially occurs at intervals of 2 to 6 weeks. Light work can begin at 2-8 weeks, while heavy work can start at 12-16 weeks.

Lumbar laminotomy for single-level central and lateral stenosis involves accessing the stenotic level through single-level bilateral minimal partial laminotomy. A probe is inserted into the lateral canal to determine its size. The medial third of the lower articular process is removed using an osteotome or rongeur. The medial and anterior portions of the upper articular process are removed using an electroinstrument, Kerrison's knife, or osteotome and mallet. For lateral stenosis, it is usually necessary to remove a larger portion of the upper articular process until the diameter of the lateral canal reaches 6 mm. At the end of the procedure, a free fat graft is placed between the dura mater and the back muscles to prevent adhesions.

Lumbar laminectomy for multilevel central and lateral stenosis, if conservative measures are ineffective, is essentially the same as for single-level stenosis. The dura mater is often exposed slightly above or slightly below the lesion due to the normal intervertebral disc space. Then the hole is widened, as described above, and the medial portions of the lower and upper facets are removed. The exposure is then extended longitudinally using a Kerrison's spatula, being careful not to damage the dura mater. The laminectomy should be as short as possible. However, prolonged laminectomy does not make the spine unstable provided that two-thirds of all facet joints are preserved.

Postoperative care is similar to that after discectomy, but these patients usually experience less postoperative discomfort. Approximately 70-80% of patients who undergo laminectomy experience significant improvement in function and noticeable reduction in pain and discomfort.

The results of laminectomy are much better for relieving leg pain caused by spinal stenosis than for relieving back pain.

**The risks and complications** of laminectomy include:

- Nerve root damage (1 in 1000 cases)
- Urinary or bowel incontinence (1 in 10,000 cases)
- Leakage of cerebrospinal fluid (1-3%)
- Infection (1%)
- Postoperative instability at the operated level (5-10%)
- Complications of general anesthesia, such as myocardial infarction, thrombosis, stroke, pneumonia, or pulmonary embolism

**Posterior lateral fusion of the lumbar spine** involves placing bone graft material in the posterolateral part of the spine (the area adjacent to the spine).

During the operation, bone graft material is taken from the posterior crest of the ilium. The posterior facets and transverse processes are completely exposed from the bony prominence. Additional removal provides more bone exposure and stimulates new bone formation. The cortical-cancellous bone graft "chip" is lifted from the posterior surface of the transverse process with an acutely curved trough.

Additionally, a high-speed burr can be used for decortication. Using the same technique, the upper and posterior surfaces of the vertebrae are decorticated to obtain a free cancellous bone graft. Then the graft is placed on and between the exposed surfaces. The large muscles of the back that attach to the transverse processes are elevated to create a bed onto which the bone graft is placed. Then the back muscles are returned over the bone graft, and the tension created holds the bone graft in place. Finally, a free fat graft is placed and sutured to the exposed dura mater to prevent adhesions to the bone graft.

Postoperative care lasts approximately 5-10 days. A spinal fixator is usually used.

Two key patient-controlled factors that determine fusion success are (1) smoking cessation and (2) limited movement.

The risks of this type of surgical intervention include:

- Non-union
- Infection
- Bleeding
- Solid fusion without reduction of back pain
- The rate of non-union ranges from 10-40%; Risk factors include previous surgery, smoking, obesity, multilevel fusion surgery, and previous radiotherapy for cancer.
- The frequency of infection and bleeding is 1-3%.

**Posterior lumbar interbody fusion (PLIF)** has the advantage over anterior lumbar interbody fusion (ALIF) in that either decompression or discectomy can be performed using the same approach. Unlike posterior lateral fusion, PLIF achieves spinal fusion by directly inserting bone graft material into the disc space. A large bone graft is taken from the posterior crest of the ilium through a transverse incision. The ligamentum flavum is completely excised.

When the surgery is performed for disc disease, the intervertebral space is expanded by removing the upper and lower edges of adjacent vertebral bodies, performing partial medial facetectomy, and distraction using a laminar spreader. A rectangle of the annulus is excised. The bony protrusion of the upper edge of the lower vertebral body is removed, clearing the path to the diseased disc. Then the endplates and disc material are removed. Corticocancellous bone blocks taken from the iliac crest are trimmed to the measured size of the disc space and compressed into place. The same maneuver is repeated on the opposite side. Finally, a free fat graft is sutured to adjacent soft tissues to cover the dura mater.

- Braces are not mandatory after surgery. PLIF has several drawbacks, including:

- Firstly, not as much disc space can be removed using a posterior approach.
- Secondly, anterior access provides much more complete evacuation of the disc space and therefore increases the surface area available for fusion.
- Thirdly, a much larger bone graft can be inserted from the anterior approach.
- Fourthly, in cases of spinal deformity (e.g., isthmic spondylolisthesis), it is more difficult to reduce the deformity with only a posterior approach.
- And finally, although the risk is small, posterior placement of bone graft may allow it to migrate back into the canal and create nerve compression.

The main risk for this type of operation is non-fusion. Non-fusion rates range from 5-10%, lower than for posterior lateral fusion.

#### Anterior lumbar interbody fusion (ALIF)

ALIF is similar to PLIF, except that in ALIF, the disc space is fused by approaching the spine through the abdomen rather than the back.

An anterior retroperitoneal or transperitoneal approach is performed, major vessels are moved aside. A scalpel is used to elevate the anterior longitudinal ligament and anterior fibrous ring. The disc material is removed piecemeal using curettes and pituitary rongeurs up to the posterior longitudinal ligament. When the disc is completely cleared from behind and from the side, endplates are cut with osteotomes to bleeding cancellous bone. When bleeding stops, iliac crest grafts are punched into the space. The anterior ligament and ring are replaced and sutured. Oral intake is postponed after surgery until bowel sounds return or gas is passed. Postoperative care is the same as for other fusions.

One of the advantages of the ALIF approach is that, unlike the PLIF or posterior lateral fusion approaches, it does not disrupt either the back muscles or the nerves. Another advantage is that placing the graft in the anterior part of the spine compresses it, and bone during compression better adheres according to Wolff's law. However, due to its dependence on compression for achieving strong fusion, osteoporosis is a contraindication for ALIF.

#### **The main risks** of ALIF include:

- Blood loss due to damage to major blood vessels such as the aorta and vena cava (1-15%)
- Retrograde ejaculation in males
- Non-fusion (5-10%)
- Infection
- Bleeding (1-3%)

#### **Transforaminal lumbar interbody fusion (TLIF)**

TLIF, a modification of PLIF developed by Harms, is becoming an increasingly popular method for treating degenerative disc disease, spondylolisthesis, adult degenerative scoliosis, spinal stenosis, and recurrent disc herniation.

In TLIF, the approach to the spine is posterior, with access to the disc through the path through the far lateral part of the vertebral foramen. This allows for complete removal of the disc and placement of interbody support transforaminally with reduced risk of nerve damage, while allowing for posterior decompression and interbody fusion.

TLIF has been used since the 1940s to treat degenerative disc disease. It provides good exposure with reduced risk, especially in cases of repeated spinal surgeries, when the presence of scar tissue greatly complicates PLIF. PLIF provides good posterior decompression; however, the disc is not removed, and the segment is not effectively immobilized.

LIF is also a viable alternative to anterior-posterior circumferential and anterior lumbar interbody fusion. The approach involves unilateral or bilateral laminectomy with lower

facetectomy, discectomy, arthrodesis, pedicle screw fixation, and insertion of titanium or carbon cages with autologous bone. Fusion can be single or multilevel. The goal is to support and fuse the anterior column.

Results from several published series have shown excellent outcomes with few complications. Complications include:

- CSF leak
- Transient neurological complications
- Minor wound infections

In some series, radiographic fusion was demonstrated in 74-93% of patients, with no deaths or serious hardware failures. Of these patients, 90% stated they would undergo the procedure again. TLIF has become a safe interbody fusion technique with good clinical results.

Preoperative and postoperative care is the same as with PLIF.

**Lateral lumbar interbody fusion (LLIF)**, also sometimes referred to as extreme lateral interbody fusion (XLIF), involves accessing the disc space through a lateral retroperitoneal transpsoas corridor. It is best suited for conditions requiring access to the intervertebral disc space from T12-L1 to L4-L5. Neuromonitoring is necessary for access to the disc space.

LLIF can be performed with rapid postoperative mobilization and is capable of achieving aggressive deformity correction with high fusion rates and complete disc space clearance. However, this is associated with the risk of potential damage to the lumbar plexus, psoas muscle, or bowel, especially at the L4-L5 level. Vascular injury, which is difficult to control, may also occur.

**Oblique lumbar interbody fusion (OLIF)** involves minimally invasive access to the disc space through a corridor between the peritoneum and the lateral edge of the vertebra. It is similar to LLIF in several aspects but does not traverse or cut the lateral bone. It is suitable for levels from L1 to S1. Neuromonitoring is not required. Like LLIF, OLIF can be performed with rapid postoperative mobilization and achieve aggressive deformity correction with high fusion rates and complete disc space clearance. Since the incision is made anterior to the psoas muscle, damage to the lumbar plexus or psoas muscle is unlikely. However, OLIF carries the risk of possible sympathetic dysfunction or vascular injury.

### **Spinal fusion tools**

Bone better fuses in an environment with as little motion as possible. The role of spinal fusion instrumentation is to reduce motion in the affected segment and provide additional stability to the spine.

Below are three main types of instruments for spine surgery:

Pedicle screws provide fixation to the vertebral segment and limit its movement. Anterior interbody cages are devices inserted into the intervertebral disc space through anterior access. They can be made of allograft bone, titanium, or carbon/polyetheretherketone (PEEK) (radiolucent cages). Posterior interbody cages are also made for insertion into the intervertebral disc space, but they are modified for insertion through posterior access. They can be made of the same materials as anterior cages.

### **Total disc replacement (TDR)**

Total disc replacement (TDR), or total disc replacement (TDR), is an alternative to spinal fusion and is used for discogenic back pain with or without radicular symptoms. The primary goal of an artificial disc is to replace the diseased disc while preserving the natural anatomical structure of the spine. The indications for implantation of an artificial disc are quite similar to those for lumbar spine fusion and include the following:

#### **Degenerative disc disease** (usually at one level)

Age 18-60 years

Primary symptom of back pain, not leg pain

Minimum of 6 months of conservative treatment

Patient is a candidate for spine surgery (e.g., lumbar fusion)

There are two types of artificial discs: (1) total disc prosthesis designed to replace the entire disc, and (2) nucleus prosthesis designed to replace the soft inner core of the disc. The outer shell of the disc is made of metal, and the inner core is made of rubbery polyethylene.

**Surgical treatment:** procedures on the cervical spine

The goal of surgical intervention in cervical radiculopathy is to achieve adequate decompression of the nerve roots. The following options are available:

- Anterior cervical discectomy (ACD)
- ACD and synthesis (ACDF)
- ACDF with internal fixation (cage)
- Posterior foraminotomy

The choice of procedure depends on several factors, including the location of nerve compression, presence of deformity or instability, and potential comorbidities. Generally, anterior pathology such as central intervertebral disc herniation and anterior osteophytes are treated anteriorly, while posterior pathology such as posterior lateral osteophytes/disc herniations can be treated with posterior access.

The goal of surgical intervention in degenerative cervical disc disease with myelopathy is adequate decompression of the spinal cord. Literature on spondylotic myelopathy does not clearly demonstrate the superiority of either anterior or posterior access. Surgical options include:

- Single- or multilevel ACDF
- Single- or multilevel anterior corpectomy with fusion
- Laminectomy with fusion or without it

**Laminoplasty:** The choice of approach depends on the localization of the pathology, risks, and benefits of each procedure, as well as the geometry of the spinal canal.

#### **Procedures for Patients with Radiculopathy**

**Anterior Cervical Discectomy (ACD):** ACD involves nerve root decompression through anterior discectomy. The debate lies in whether interbody fusion is necessary after single-level ACD. While initially ACD involved fusion procedures, complications such as graft complications and donor site morbidity prompted some surgeons to perform simple discectomy. Discectomy may be considered for patients with normal cervical lordosis, minimal axial pain, and anomalies limited to one level. Literature has reported high rates of improvement with discectomy alone, although nowadays most surgeons routinely use fusion.

Possible risks and complications of ACD include:

- Nerve root injury
- Spinal cord injury (~1 in 10,000 cases)
- Bleeding
- Infection
- Graft displacement
- Tracheal or esophageal injury
- Persistent pain

Injury to the recurrent laryngeal nerve during the procedure may cause hoarseness, and esophageal retraction sometimes causes temporary swallowing difficulties.

**Anterior Cervical Discectomy and Fusion (ACDF):** Interbody fusion typically prevents recurrent radiculopathy due to foraminal stenosis and the potential for late kyphosis development due to disc space collapse. The combination of discectomy and fusion should be performed for all patients, especially if multiple levels are involved or if instability is documented at any level. Complications associated with non-fusion are much higher than the minor risk of fusion-related complications.

For single-level fusion, autologous bone provides a fusion rate of 95%. To prevent complications from the donor site, alternatives include using allograft bone tissue, bovine cancellous bone, and synthetic materials. The main risk of fusion surgery is nonunion. Overall,

allograft bone heals less well than autograft bone, but both yield good results when used in the anterior cervical spine.

If the graft is used without instrumentation, the risk of its displacement or extrusion is 1-2%. If this occurs, another operation is performed to reinsert the bone graft, and instruments (plating) can be used to hold it in place.

A hybrid surgical approach has been described, involving ACDF and cervical disc arthroplasty, which appears to be a safe and effective procedure for select patients with multilevel degenerative cervical disc disease. Anterior cervical discectomy and fusion with internal fixation (plating)

Cover can be beneficial in patients requiring multi-level procedures, with documented instability, in smokers, in patients with a history of nonunion, and in patients with adjacent-level fusion. In addition, no brace is needed with the plate, allowing for quicker return to work and resumption of daily activities.

**Posterior Cervical Foraminotomy:** Nerve root decompression can be achieved posteriorly by performing a foraminotomy. The keyhole method, developed by Scoville for nerve root decompression, involves removing one or more hemilaminae with excision of osteophytes and disc fragments. This is most commonly used in soft posterior lateral disc herniations, thus obviating the need for fusion. High success rates have been reported.

#### **Procedures for Patients with Myelopathy**

**Single- or Multilevel ACDF:** ACDF at one or multiple levels can be performed in myelopathy when the pathology is limited to intervertebral spaces and does not involve vertebral bodies. Although multilevel corpectomy is also an option in these cases, multilevel ACDF has the advantage of segmental fixation and lordosis restoration.

Jackson et al. evaluated 7-year neurological and clinical outcomes in patients with multilevel degenerative cervical disc disease receiving treatment on two adjacent levels TDA or ACDF and observed for 7 years. They found that two-level TDA provides better long-term neurological outcomes than ACDF. In the TDA group, there were fewer neurological deteriorations, fewer side effects, fewer subsequent surgeries, and reduced neck and arm pain while preserving the range of motion.

**Single- or Multilevel Cervical Corpectomy with Fusion:** Corpectomy involves removing vertebral bodies and disc spaces from both ends to achieve complete spinal canal decompression. For multiple segments of spondylotic myelopathy, corpectomy with strut grafting may be performed. Multilevel corpectomy, to prevent kyphotic deformity and restore stability, requires anterior fusion.

**Anterior Plate:** Anterior plates are recommended for corpectomy and multilevel procedures to reduce the risk of graft extrusion and pseudoarthrosis. With longer fusion durations, the frequency of complications related to graft and instrumentation increases. In such cases, posterior stabilization is recommended to improve stability, fusion rate, and reduce complications associated with the graft and instrumentation.

**Cervical Corpectomy:** Corpectomy is a technically more complex surgical intervention. The risks are similar to those of discectomy, but since corpectomy is a more extensive procedure, the risks are higher. The most concerning risk is spinal cord injury leading to quadriplegia. To mitigate this risk, spinal cord function can be monitored during surgery using somatosensory evoked potentials.

Another risk is injury to the vertebral artery, which can cause a stroke.

**Cervical Laminectomy with Fusion or Without:** Laminectomy may be necessary if patients have congenital cervical stenosis or if the disease process involves more than three levels or multiple unstable levels. Patients with kyphosis may require anterior fusion to prevent further progression of kyphotic deformity. Laminectomy may be used if the majority of spinal cord compression occurs posteriorly.

Like with cervical corpectomy, the primary risk of posterior cervical laminectomy is worsening neurological function after surgery. Intraoperative somatosensory evoked potentials



can reduce this risk. Other risks include dural tear, infection, bleeding, increased pain, and spine instability.

If laminectomy is performed, fusion is recommended to prevent kyphotic progression. Other indications for posterior fusion include signs of instability on preoperative dynamic radiographs, failure of anterior fusion, or decompression with bilateral facetectomy. Most experience with posterior fusion involves autologous bone from spinous processes or iliac crest, but allograft bone has also been used.

**Cervical Laminoplasty:** The laminoplasty technique was developed mainly by Japanese surgeons primarily for treating ossification of the posterior longitudinal ligament. It involves osteoplastic expansion of the spinal canal by performing laminectomy on one side to create "doors". The purpose of this procedure is to reduce instability after laminectomy, as mentioned earlier. Although this technique is not used frequently, successful treatment of cervical spondylosis has been reported.

Other Procedures:

**Cervical Keyhole Foraminotomy:** Indicated for lateral disc herniations with radicular pain. This is an effective way to decompress the lateral soft disc without the risk of anterior access. Bone grafting is not required. The use of an operating microscope helps achieve good results.

**Dynamic Cervical Disc Arthroplasty:** A device used to achieve anterior decompression without cervical fusion. Second-generation implants, introduced since 2008 and mainly developed to overcome the drawbacks of fusion in a less invasive manner while providing normal motion and preserving biomechanics. Additionally, the device imposes some limitations on rotation and translation, preventing further degeneration of small joints.

**Questions (test tasks, problems, clinical situations) to assess knowledge on the topic of the session:**

1. A patient presents with acute low back pain, paresthesias in the buttocks and thighs. Which of the following physical examination maneuvers helps confirm the diagnosis of compression of the lumbar nerve roots with radiculopathy in the patient?

- A. "Heel-to-buttock" test.
- B. Babinski reflex positive
- +C. Straight leg raise maneuver
- D. Kernig's sign

2. A 55-year-old patient underwent laminectomy and medial facetectomy at the level of L4-L5 due to disc herniation and facet hypertrophy with foraminal stenosis. After the surgery, the patient complains of constant pain at the surgical site, especially during movement. The patient has no fever or wound drainage. Erythrocyte sedimentation rate and C-reactive protein level are within normal limits. What is the next step in managing this patient?

- A. Increase the dose of analgesics
- B. Antibiotics
- C. MRI of the spine
- +D. Dynamic radiography of the lumbosacral spine.

Excessive decompression of the spine may weaken the facet joints and the intervertebral part, leading to instability. Joint instability leads to characteristic localized pain, especially during movement, due to irritation of the Luschka nerve. The basis for diagnosing joint instability is performing dynamic radiographic images during flexion and extension.

3. A 39-year-old man presents with neck stiffness, bilateral arm pain, difficulty buttoning his shirt, and instability. He has 4+/5 strength in the upper extremities and hyperreflexia in the biceps, brachioradialis, and patellar reflexes. He also has bilateral positive Hoffman's signs. An MRI is shown below. What is the most rational next step in managing this patient?

- +A. CT of the spine
- B. HLA-B27 status
- C. Posterior cervical laminectomy
- D. Anterior corpectomy and bone graft fusion

Clinical and radiological signs of the patient indicate cervical myelopathy due to ossified posterior longitudinal ligament (OPLL). CT of the spine is the most rational next step in managing a patient with such clinical characteristics. CT of the spine helps diagnose and classify patterns of vertebral body and disc space involvement, thereby assisting in formulating appropriate surgical intervention for the patient. Anterior or posterior surgical approaches in treating OPLL depend on its subtypes classified based on CT findings. It also depends on the patient's age, neurological status, comorbidities, and cervical lordosis.

4. A 42-year-old right-handed woman with no significant past medical history presents to the office three days after being rear-ended while driving her car. She reports no loss of consciousness after the accident and denies any serious symptoms immediately following the accident. However, two days later, she developed progressive neck pain radiating to the third finger of her left hand. She denies any gait disturbances or urinary retention and states she has no trouble writing. She describes the pain as sensations of burning pins and needles. Vital signs are normal, physical examination reveals decreased sensation along the dorsal surface of the forearm and left third finger. Motor examination of the right upper extremity and lower extremities is normal, as is light touch sensation testing in the extremities and trunk. Reflexes at the biceps and patellar tendons are 2+ and symmetric. Which of the following movements is expected to be weak upon motor examination of her left upper extremity?

- A. Wrist flexion
- B. Wrist extension
- C. Elbow flexion
- +D. Elbow extension

The test describes an individual involved in a minor motor vehicle accident with pain radiating down the arm in a dermatomal pattern. The patient presents with pain radiating to the 3rd dermatome, likely C7. To have wrist flexion affected, it would need to implicate C8, which would radiate to the 5th finger. Wrist extension is primarily innervated by the C6 nerve root, which has a dermatomal pattern radiating to the 1st finger. The patient has pain radiating to the 3rd dermatome, corresponding to a C7 disorder; thus, wrist extension should be preserved. Elbow flexors are primarily innervated by C6 with some innervation from C5. If either of these nerve roots were affected, pain would not radiate to the 3rd finger. Radicular pain in this case describes pain radiating to the 3rd dermatome consistent with a C7 radiculopathy, making it unlikely to cause any motor weakness in elbow extension. The clinical vignette illustrates an individual with a probable C7 radiculopathy. Pain from a C7 radiculopathy typically radiates to the 3rd finger and possibly the 2nd finger. C7 radiculopathy may cause weakness in elbow extension as the radial nerve is a branch of C7, which then supplies the triceps.

#### 4. Summary

Degenerative disc diseases remain a serious healthcare problem, still not adequately studied and addressed. Besides standard conservative and surgical treatments, promising are regenerative therapy approaches, although they are still in the experimental phase.

#### **Main Literature:**

1. Neurosurgery: textbook / [V.O. Pyatikop, I.O. Kutoviy, A.V. Kozachenko et al.]; edited by V.O. Pyatikop - Kyiv, VSV "Medicine", 2019. - 152 p.
2. Neurosurgery: textbook / [V.I. Tsimbalyuk, V.V. Medvedev, M.O. Marushchenko et al.]; edited by academician V.I. Tsimbalyuk. - 2nd edition, revised. - Vinnytsia: Nova Knyha, 2020. - 360 p.
3. Hryhorova I.A., Sokolova L.I., Herasymchuk R.D., Son A.S., et al. Neurology: Educational Manual / edited by I.A. Hryhorova, L.I. Sokolova - 3rd edition - Kyiv, VSV "Medicine", 2020. - 640 p.
4. Topical diagnosis of nervous system pathology. Diagnostic search algorithms. Shkrobot S.I., Saliy Z.V., Budarna O.Yu. Ukrmedknyha, 2018. - 156 p.

5. Methods of examination of a neurological patient: a tutorial / edited by L.I. Sokolova, T.I. Ilyash. Kyiv, 2020. - 144 p.
6. Emergency medicine. Emergency (ambulance) medical care: textbook / I.S. Zozulya, V.I. Bobrova, G.G. Roschin, etc. / edited by I.S. Zozulya. - 3rd edition, revised and supplemented. - Kyiv. - VSV "Medicine", 2017. - 960 p.
7. Negrych T.I., Bozhenko N.L., Matvienko Yu.Sh. Ischemic stroke: secondary inpatient care: a tutorial. Lviv: Danylo Halatsky Lviv National Medical University, 2019. - 160 p.
8. Handbook of Neurosurgery / Greenberg M.S. - Thieme, 2019. - 1784 p. ISBN 9781684201372
9. Neurology - Неврологія: textbook / I.A. Hryhorova, L.I. Sokolova, R.D. Herasymchuk et al.; edited by I.A. Hryhorova, L.I. Sokolova. – Kyiv : AUS Medicine Publishing, 2017. – 624p.

**Additional Literature:**

Bozhenko M.I., Negrych T.I., Bozhenko N.L., Negrych N.O. Headache. Educational manual.-K.: Medkniga Publishing House, 2019

**Informational resources:**

1. Clinical guidelines and other publications on neurosurgery (State Institution Romodanov Neurosurgery Institute of the National Academy of Medical Sciences of Ukraine)  
<https://neuro.kiev.ua/uk/category/publishing-uk/>
2. Clinical guidelines on neurology. (Order of the Ministry of Health of Ukraine No. 487 dated 17.08.2007)  
<https://zakon.rada.gov.ua/rada/show/v0487282-07#Text>

*Practical Class No. 14*

**Topic:** Functional and Restorative Neurosurgery.

**Objective:** To gain an understanding of the principles of stereotactic surgery and indications for its use in brain diseases; to acquire knowledge of general concepts regarding the principles and indications for surgical treatment of epilepsy, Parkinsonism, cerebral palsy in children, etc.; to gain an understanding of the principles and main types of surgical interventions in restorative neurosurgery.

**Key concepts:** Stereotactic neurosurgery, restorative neurosurgery.

**Equipment:** Classroom, furniture, equipment:

PC

Multimedia projector

Neurosurgical microscope Mitaka MM51YOH

Surgical table RAPSODIA WITH MODULAR TABLEWORK

Head fixation device DORO

Electrosurgical unit BOWA ARC 400

Ultrasonic surgical aspirator CUSA CI C7000

Surgical aspirator Dominant Flex

Neuromonitoring system INOMED XPERT

Neurosurgical instruments

Steam sterilizer TICHE

Steam sterilizer KRONOS B23 with ROSI

Sealing machine

Ultrasonic cleaner

**Plan:**

1. Organizational activities (greetings, attendance check, announcement of the topic and goals of the session, motivation of students to study the topic).
2. Control of basic knowledge (written work, written testing, frontal questioning, etc.):

Control questions:

- What is stereotactic surgery?
- What is the significance of restorative surgery?

### **Content**

#### **Deep Brain Stimulation (DBS)**

DBS is a surgical treatment that involves the implantation of a medical device called a "brain stimulator," which delivers electrical impulses to specific parts of the brain.

#### **Applications**

- Parkinson's disease;
- Epilepsy;
- Essential tremor;
- Dystonia;
- Tourette syndrome;
- Chronic pain;
- Depression;
- Obsessive-compulsive disorder, etc.

#### **Mechanism of Action of DBS**

DBS can operate through local and network electrical and neurochemical stimulation effects, modulation of oscillatory activity, synaptic plasticity, neuroprotection, and neurogenesis. DBS works not only by inhibiting but also by exciting basal ganglia circuits. It can inhibit neuronal networks at the target. On the other hand, it can also activate efferent axons. It can suppress pathological rhythms and engage neuronal networks with broad connections, leading to favorable effects. High-frequency stimulation can induce global hyperpolarization of the cell membrane, resulting in reduced excitability. Additionally, stimulation can "silence" the output from the abnormally functioning structure. Antidromic and orthodromic depolarization currents can modulate neuron activity in places distant from the stimulation target. Finally, disruption of pathological network activity induced by stimulation may explain the effect of DBS on disorders of abnormal movements. It has also been reported that DBS creates information damage in the chain and can control network activity by engaging neurochemical modulation, such as dopamine and gamma-aminobutyric acid (GABA) regulation through glia induced by stimulation.

#### **Advantages**

- Minimally invasive procedure
- Effectiveness
- Reversibility
- Adjustability
- Ability to intervene in targets that cannot or should not be treated with neuroablative surgery, providing a unique opportunity to study human basal ganglia physiology

#### **Disadvantages**

- Device cost
- Servicing cost
- Increased risk of infection due to the presence of implanted equipment

#### **DBS Procedure**

The DBS system consists of an electrode implanted into the target brain structure, such as the nucleus subthalamicus (STN), globus pallidus internus (GPi), and ventral intermediate (VIM) nucleus of the thalamus. The lead is connected to an implanted pulse generator (IPG), which is the power source of the system, typically implanted in the subclavian region of the upper chest. The lead and IPG are connected by an extension, which tunnels through the neck subcutaneously.

The DBS system implantation is performed in 2 stages:

- During the first stage, the DBS electrode is stereotactically implanted into the target nucleus.
- In the second stage, the DBS electrode is subcutaneously connected to the IPG, which is inserted into a "pocket" under the skin of the chest wall, like a cardiac pacemaker.

In DBS for Parkinson's disease, as in most stereotactic movement disorder procedures, the first stage is performed while the patient is awake to provide neurological status monitoring. On the morning of the procedure, a stereotactic frame is placed on the patient's head, and targeted MRI is performed.

A combination of microelectrode recording and macroelectrode stimulation is used for physiological refinement of the desired target. After implantation of the DBS electrode, it is secured to the skull using a cap with a hole.

After implantation of the DBS electrode, a CT scan is performed to confirm the absence of bleeding in the brain, and an MRI is performed to confirm the correct electrode placement. The second stage of the operation, implantation of the IPG under general anesthesia, will be performed on the patient 1-2 weeks later.

The electrode is thin (approximately 1.3 mm in diameter) and flexible, so it moves atraumatically with the brain. The device can be programmed for monopolar or bipolar stimulation using any of the 4 electrode contacts, individually or in combination.

After proper patient selection and accurate electrode placement, competent programming of the implanted device is crucial to optimizing DBS therapy. Therapeutic electrical parameters can be established approximately 2 weeks later using a transcutaneous programmer.

The primary goals of programming are to maximize symptom suppression and minimize adverse effects; minimizing battery drainage is a secondary goal. These goals can be achieved by following a systemic, multi-step approach. The ability to perform monopolar or bipolar stimulation using any of the 4 electrode contacts (or their combinations) offers the treating physician great therapeutic flexibility, allowing individualized stimulation for each patient. Additionally, stimulation parameters can be adjusted at any time if necessary.

DBS provides monopolar or bipolar electrical stimulation of the target brain area. The amplitude, frequency, and pulse width of the stimulation can be adjusted to control symptoms and minimize side effects. The patient can turn the stimulator on or off using the Access Review Therapy Controller or a portable magnet. Typical stimulation parameters are an amplitude of 1–3 V, a frequency of 135–185 Hz, and a pulse width of 60–120 msec.

It has been hypothesized that DBS works by disrupting abnormal brain circuits and thus reducing symptoms of Parkinsonism. The response to DBS is as good as the patient's optimal "on" time, except for tremor, which may demonstrate more improvement than with medication alone; however, after DBS, the amount of daily "on" time is significantly extended. DBS requires regular monitoring to adjust stimulation parameters to account for changes in symptoms due to disease progression and side effects.

Traditional DBS surgery is performed while patients are awake. With advancements in high-resolution brain imaging, asleep MRI-guided electrode implantation for DBS (asleep DBS) has been developed, allowing anatomical verification of the target during surgery. Additionally, studies have shown that microelectrode recording and intraoperative MRI are effective in ensuring adequate electrode placement in DBS surgery. Other advancements include mini-frames, robotic-assisted stereotactic systems (Rosa) for DBS surgery, and rechargeable pulse generators. Directed DBS with novel electrode designs, capable of controlling stimulation current for better and specific targeting, as well as closed-loop DBS systems, are currently under development.

### **Targets for DBS**

Implantation of DBS leads in the globus pallidus internus (GPi) along with subthalamic stimulation is used to control the core symptoms of Parkinson's disease (rigidity, bradykinesia, dyskinesias, less commonly tremor). Dorsal GPi stimulation improves akinesia and rigidity but may worsen dyskinesias. In contrast to dorsal GPi stimulation, ventral GPi stimulation is more effective in treating dyskinesias induced by levodopa but may exacerbate akinesia and gait disturbances.

Pallidal stimulation is indicated for patients responsive to levodopa and those with refractory motor fluctuations leading to disability and levodopa-induced dyskinesia. Exclusion criteria include significant cognitive, mood, or behavioral disorders.

Both pallidal and subthalamic stimulation are comparable in improving motor symptoms and cost-effectiveness. Subthalamic stimulation has shown the best reduction in medication, improvement in "off" time, and tremor. Pallidal stimulation is the treatment of choice for axial symptoms.

The large size of the GPi dictates higher stimulation amplitudes and pulse widths, thus leading to more frequent battery changes, unlike subthalamic nucleus stimulation. The risk of current spread to neighboring areas is higher with subthalamic stimulation due to the small size of the stimulating target (which may worsen cognitive and psychiatric parameters).

Thalamic stimulation is a preferred procedure for disabling tremor. Implantation is done in the ventral intermediate nucleus.

Pedunculopontine nucleus stimulation is a promising approach for treating refractory gait freezing and falls but is still under investigation.

### **Parkinson's Disease (PD)**

PD is a debilitating chronic neurodegenerative disorder clinically characterized by akinesia, tremor, rigidity, and postural instability, primarily due to degeneration of dopaminergic neurons in the substantia nigra. Levodopa and dopamine agonists are available for dopaminergic replacement therapy, resulting in effective relief of motor symptoms in the early stages of the disease. However, this treatment is eventually hampered by increasing motor complications such as wearing-off phenomena and sudden off-states, as well as troublesome dyskinesias. Before the advent of levodopa, ablative surgeries on lesions—such as pallidotomy and thalamotomy—were used as the ultimate solution for refractory symptoms. While these surgeries resulted in symptom improvement, they often came with the risk of irreversible and serious side effects, such as dysarthria or hemiparesis. Bilateral surgical intervention significantly increased complication rates and was therefore rarely performed.

DBS of the thalamic motor nuclei, specifically the ventral intermediate nucleus (VIM), was first used in 1986 for refractory tremor in PD. DBS of various basal ganglia nuclei has since evolved into a highly effective treatment for several movement disorders. In PD, effective and safe targets for DBS have been found in the globus pallidus internus (GPi) and subthalamic nucleus (STN). Compared to lesioning procedures, chronic DBS using standard stimulation parameters for PD does not result in tissue damage or causes minimal tissue damage and is therefore largely reversible. Additionally, bilateral DBS can be implemented without a significant increase in side effects. Adjustment of stimulation parameters postoperatively and throughout the course of the disease is possible. In various randomized controlled trials, DBS has demonstrated better functional outcomes with fewer side effects, thus almost entirely replacing surgical interventions in industrialized countries. However, due to economic constraints in some countries, lesioning may still be the only option.

### **Epilepsy**

Epilepsy is a common neurological disorder affecting 0.5% to 1% of the population. Over 30% of all epilepsy patients suffer from uncontrolled seizures or have unacceptable medication-related side effects. For patients with refractory seizures, alternative treatment options are available. Adding recently developed antiepileptic drugs to the treatment regimen may lead to seizure freedom in this population. However, the likelihood of seizure freedom using this strategy is limited and approximately 6% compared to placebo. Surgical intervention for epilepsy leads to long-term seizure freedom in approximately 58% to 65% of surgical candidates. For the rest, there are few options, and neuromodulation may become an alternative treatment.

Both extracranial (vagus nerve stimulation) and intracranial (DBS) and cortical (neocortex and cerebellar cortex) neuromodulation are used in the treatment of epilepsy. Intracranial stimulation involves the direct application of electrical current to structures within the central nervous system using implanted (DBS) or subdural (cortical stimulation) electrodes connected to an implanted pulse generator.

The exact mechanism of action of DBS still requires clarification. Several mechanisms of action have been proposed. With continuous application of current through electrodes, target brain

structures may be functionally suppressed. This is done reversibly, as stimulation can be stopped at any time. The inhibitory effect depends on the target structures, i.e., the location of the implanted electrodes in the brain. Stimulation of electrodes placed in the seizure onset zone (e.g., in the hippocampus) may lead to "local" suppression of the hyperexcitable area and seizure suppression. Stimulation of electrodes placed in key structures responsible for seizure propagation (e.g., in the thalamus) may additionally lead to suppression of seizure spread based on connections between the stimulation site and other parts of the central nervous system. This may become a plausible hypothesis when key structures in epileptogenic networks are involved.

**3. Questions (test tasks, problems, clinical situations) for testing knowledge on the topic of the lesson:**

1. Which of the following is NOT a component of DBS equipment?

- A. Lead
- B. Implanted pulse generator
- C. Extension
- + D. Circulator

2. A 60-year-old man presented to the clinic with exacerbation of tremor. He was diagnosed with essential tremor. The patient has been compliant with his medications; however, he denies any resolution of symptoms. After exhausting numerous pharmacological options, the clinician suggests DBS. Which structure should be targeted when performing DBS for the treatment of essential tremor?

- + A. Ventral intermediate thalamus
- B. Red nucleus
- C. Nucleus tractus solitarius
- D. Lamina terminalis

3. A 65-year-old patient with a history of Parkinson's disease presented to the clinic with worsening motor symptoms. The patient has exhausted treatment options and now demands DBS. Which mechanism may help alleviate the symptomatic burden of Parkinson's disease?

- + A. Subthalamic nucleus stimulation
- B. Cingulate gyrus stimulation
- C. Posterior column stimulation
- D. Ventrolateral prefrontal cortex stimulation

4. Summary

**Main Literature:**

1. Neurosurgery: textbook / [V.O. Pyatikop, I.O. Kutoviy, A.V. Kozachenko et al.]; edited by V.O. Pyatikop - Kyiv, VSV "Medicine", 2019. - 152 p.

2. Neurosurgery: textbook / [V.I. Tsimbalyuk, V.V. Medvedev, M.O. Marushchenko et al.]; edited by academician V.I. Tsimbalyuk. - 2nd edition, revised. - Vinnytsia: Nova Knyha, 2020. - 360 p.

3. Hryhorova I.A., Sokolova L.I., Herasymchuk R.D., Son A.S., et al. Neurology: Educational Manual / edited by I.A. Hryhorova, L.I. Sokolova - 3rd edition - Kyiv, VSV "Medicine", 2020. - 640 p.

4. Topical diagnosis of nervous system pathology. Diagnostic search algorithms. Shkrobot S.I., Saliy Z.V., Budarna O.Yu. Ukrmedknyha, 2018. - 156 p.

5. Methods of examination of a neurological patient: a tutorial / edited by L.I. Sokolova, T.I. Ilyash. Kyiv, 2020. - 144 p.

6. Emergency medicine. Emergency (ambulance) medical care: textbook / I.S. Zozulya, V.I. Bobrova, G.G. Roschin, etc. / edited by I.S. Zozulya. - 3rd edition, revised and supplemented. - Kyiv. - VSV "Medicine", 2017. - 960 p.

7. Negrych T.I., Bozhenko N.L., Matvienko Yu.Sh. Ischemic stroke: secondary inpatient care: a tutorial. Lviv: Danylo Halytsky Lviv National Medical University, 2019. - 160 p.

8. Handbook of Neurosurgery / Greenberg M.S. - Thieme, 2019. - 1784 p. ISBN 9781684201372

9. Neurology - Неврологія: textbook / I.A. Hryhorova, L.I. Sokolova, R.D. Herasymchuk et al.; edited by I.A. Hryhorova, L.I. Sokolova. – Kyiv : AUS Medicine Publishing, 2017. – 624p.

**Additional Literature:**

Bozhenko M.I., Negrych T.I., Bozhenko N.L., Negrych N.O. Headache. Educational manual.-K.: Medkniga Publishing House, 2019

**Informational resources:**

1. Clinical guidelines and other publications on neurosurgery (State Institution Romodanov Neurosurgery Institute of the National Academy of Medical Sciences of Ukraine)

<https://neuro.kiev.ua/uk/category/publishing-uk/>

2. Clinical guidelines on neurology. (Order of the Ministry of Health of Ukraine No. 487 dated 17.08.2007)

<https://zakon.rada.gov.ua/rada/show/v0487282-07#Text>

*Practical Class No. 15*

**Topic:** Surgical Treatment of Pain Syndromes.

**Objective:** to gain an understanding of the indications for surgical treatment of pain syndromes and the techniques involved.

**Key concepts:** neurolysis, radiofrequency neurotomy, neuromodulation.

**Equipment:** Classroom, furniture, equipment:

PC

Multimedia projector

Neurosurgical microscope Mitaka MM51YOH

Surgical table RAPSODIA WITH MODULAR TABLEWORK

Head fixation device DORO

Electrosurgical unit BOWA ARC 400

Ultrasonic surgical aspirator CUSA CI C7000

Surgical aspirator Dominant Flex

Neuromonitoring system INOMED XPERT

Neurosurgical instruments

Steam sterilizer TICHE

Steam sterilizer KRONOS B23 with ROSI

Sealing machine

Ultrasonic cleaner

**Plan:**

1. Organizational activities (greetings, attendance check, announcement of the topic and goals of the session, motivation of students to study the topic).

2. Control of basic knowledge (written work, written testing, frontal questioning, etc.):

Control questions:

- Anatomy and physiology of the peripheral nervous system and spinal cord.

- Nociceptive system.

**Content**

For some patients with chronic pain who do not achieve satisfactory pain relief through conventional first-line approaches, interventional therapy can provide a safe and effective option. Interventional therapy encompasses invasive analgesic methods, including injections, ablative techniques, infusion therapy, neuromodulation, and some minimally invasive surgical methods.

**Sympathetic Nerve Blocks and Neurolysis**



Sympathetic nerve blockade may be considered when pain is potentially mediated or exacerbated by abnormal sympathetic activity, which is believed to be associated with common pathways between pain-transmitting nerves and autonomic fibers. Symptoms may be diffuse and disproportionate to the pain expected based on normal somatic anatomy (e.g., typical dermatomal pattern or distribution).

### **Anatomy**

Sympathetic axons emerge from their nuclei in the spinal cord at levels T1–L2 or L3 and proceed to form paravertebral or prevertebral ganglia. Paravertebral ganglia compose the sympathetic trunk along the vertebral column and converge at the celiac plexus level, forming an unpaired ganglion. Prevertebral ganglia exist in the preaortic, superior mesenteric, and inferior mesenteric plexuses. Both efferent sympathetic fibers and afferents from internal organs pass through sympathetic ganglia.

In the cervical and lumbar regions, sympathetic ganglia and plexuses are separate from somatic nerves, so sympathetic blocks can achieve analgesia without blocking somatic sensation. This is not the case in the thoracic region, where injections near the paravertebral chain are less common and pose an increased risk due to the proximity to somatic nerves, neuroaxial structures, and pleura.

### **Neurolytic Procedures**

Neurolytic procedures induce analgesia by disrupting afferent nerve pathways or sympathetic ganglia involved in pain transmission.

#### **Mechanism**

For neurolytic procedures, nerve tissue can be destroyed by heat (thermal radiofrequency) or the introduction of neurolytic agents (water, hypertonic solution, glycerol, phenol, or alcohol). All neurolytic methods lead to some degree of Wallerian degeneration (i.e., degeneration of nerve axons distal to the site of destructive injury). However, if the axolemma is intact, nerve regeneration occurs, resulting in sensory recovery approximately three to six months later.

#### **Method Selection:**

- Thermal ablation is associated with less risk of complications than chemical ablation but often provides less durable benefits during nerve regeneration.

- Chemical neurolysis with alcohol or phenol dehydrates nerve tissue and causes necrosis and demyelination in addition to Wallerian degeneration, resulting in longer-lasting effects. These agents are more commonly used for palliative care as there is an increased risk of pain with deafferentation.

#### **Indications**

Both somatic and sympathetic neurolytic blocks and procedures can be performed for various conditions. Neurolytic blocks should be considered only when more conservative therapy has failed.

**Neurolysis** is most frequently performed for oncology patients with advanced disease or those suffering from intractable pain unresponsive to more conservative therapy.

**Radiofrequency Neurotomy (RFN)** and Chemical Neurolysis have also been performed for chronic non-oncologic pain, including facet joint pain (medial branch neurolysis), chronic shoulder, knee, and hip pain, and trigeminal neuralgia.

Radiofrequency Neurotomy (radiofrequency ablation) uses radio waves to heat a small area of nerve tissue for its destruction. One type of device (cooled radiofrequency) used for medial branch RFN passes cool water through the probe and creates a larger lesion than standard RFN.

#### **Contraindications**

Radiofrequency procedures are contraindicated in patients with infection at the injection site or systemic infection. Relative contraindications include fractures, tumors/masses/apparatus, radiculopathy, infection, and coagulopathy.

The risk of serious bleeding depends on the target structure. For example, cervical medial branch RFN is considered a procedure of moderate risk, while lumbar medial branch RFN is considered a low-risk procedure. Most peripheral nerve RFN procedures are considered low risk.

## Indications

The most common indications for RFN include axial neck or back pain when facet joints have been identified as the etiology of pain (e.g., non-radicular axial low back pain with possible paraspinal tenderness at the facet joint level). Other indications include knee, hip, or sacroiliac joint pain, which may result from degenerative changes such as osteoarthritis. Targets for knee, hip, and sacroiliac joint pain are knee articular nerves, branches of the femoral and sciatic nerves in the thigh, and lateral branches of nerves in the sacroiliac joint, respectively. Since regenerating nerves can lead to pain recurrence, a patient who responded to a previous ablation may be eligible for a repeat ablation/neurotomy of the same targets later.

## Neuromodulation

Neuromodulation in the context of pain treatment involves the application of electrical stimulation to nerves to modulate pain signaling. Neuromodulation is increasingly used for pain treatment, and neuromodulation technology is rapidly evolving.

## Spinal Cord Stimulation

Spinal Cord Stimulation (SCS) is a neuromodulation technique used to treat neuropathic and sympathetically mediated chronic pain. SCS involves the percutaneous or surgical implantation of electrodes into the epidural space, powered by an implanted pulse generator (battery).

## Dorsal Root Ganglion Stimulation

Dorsal Root Ganglion Stimulation (DRGS) involves the insertion of leads through the epidural space into the intervertebral foramina, where the roots of spinal nerves and DRGs emerge from the nervous system. DRGs consist of sensory cell bodies located in the epidural space, surrounded by minimal cerebrospinal fluid. Thus, very low electrical currents are required for stimulation, lower than those needed for spinal cord stimulation.

## Indications for Stimulators

DRG stimulation is used for focal neuropathic pain syndromes, with the most compelling evidence of benefit for complex regional pain syndrome of the lower limbs and limited evidence for use in diabetic and other peripheral neuropathies.

### 3. Questions (Test tasks, problems, clinical situations) for assessing knowledge on the topic:

1. What surgical procedure involves the removal or destruction of part of a nerve to alleviate chronic pain?
  - a) **Neurectomy**
  - b) Neurolysis
  - c) Neurorrhaphy
  - d) Neurostimulation
2. What is the primary mechanism of action of injuring the dorsal roots in surgical treatment of chronic pain?
  - a) Removal of spinal cord tumors
  - b) **Interruption of pain signals in the spinal cord**
  - c) Stimulation of sensory nerves
  - d) Restoration of damaged nerve roots
3. Which neurosurgical procedure involves implanting electrodes into the central nervous system to modulate pain signals?
  - a) Rhizotomy
  - b) Cordotomy
  - c) **Deep Brain Stimulation (DBS)**
  - d) Sympathectomy
4. What is the purpose of percutaneous cordotomy in the treatment of chronic pain?
  - a) Disrupting pain signals in peripheral nerves

**b) Cutting or damaging fibers of the spinothalamic tract**

c) Stimulating sensory nerves in the spinal cord

d) Removing spinal cord tumors

Summary.

**Main Literature:**

1. Neurosurgery: textbook / [V.O. Pyatikop, I.O. Kutoviy, A.V. Kozachenko et al.]; edited by V.O. Pyatikop - Kyiv, VSV "Medicine", 2019. - 152 p.
2. Neurosurgery: textbook / [V.I. Tsimbalyuk, V.V. Medvedev, M.O. Marushchenko et al.]; edited by academician V.I. Tsimbalyuk. - 2nd edition, revised. - Vinnytsia: Nova Knyha, 2020. - 360 p.
3. Hryhorova I.A., Sokolova L.I., Herasymchuk R.D., Son A.S., et al. Neurology: Educational Manual / edited by I.A. Hryhorova, L.I. Sokolova - 3rd edition - Kyiv, VSV "Medicine", 2020. - 640 p.
4. Topical diagnosis of nervous system pathology. Diagnostic search algorithms. Shkrobot S.I., Saliy Z.V., Budarna O.Yu. Ukrmedknyha, 2018. - 156 p.
5. Methods of examination of a neurological patient: a tutorial / edited by L.I. Sokolova, T.I. Ilyash. Kyiv, 2020. - 144 p.
6. Emergency medicine. Emergency (ambulance) medical care: textbook / I.S. Zozulya, V.I. Bobrova, G.G. Roschin, etc. / edited by I.S. Zozulya. - 3rd edition, revised and supplemented. - Kyiv. - VSV "Medicine", 2017. - 960 p.
7. Negrych T.I., Bozhenko N.L., Matvienko Yu.Sh. Ischemic stroke: secondary inpatient care: a tutorial. Lviv: Danylo Halytsky Lviv National Medical University, 2019. - 160 p.
8. Handbook of Neurosurgery / Greenberg M.S. - Thieme, 2019. - 1784 p. ISBN 9781684201372
9. Neurology - Неврологія: textbook / I.A. Hryhorova, L.I. Sokolova, R.D. Herasymchuk et al.; edited by I.A. Hryhorova, L.I. Sokolova. – Kyiv : AUS Medicine Publishing, 2017. – 624p.

**Additional Literature:**

Bozhenko M.I., Negrych T.I., Bozhenko N.L., Negrych N.O. Headache. Educational manual.-K.: Medkniga Publishing House, 2019

**Informational resources:**

1. Clinical guidelines and other publications on neurosurgery (State Institution Romodanov Neurosurgery Institute of the National Academy of Medical Sciences of Ukraine)  
<https://neuro.kiev.ua/uk/category/publishing-uk/>
2. Clinical guidelines on neurology. (Order of the Ministry of Health of Ukraine No. 487 dated 17.08.2007)  
<https://zakon.rada.gov.ua/rada/show/v0487282-07#Text>