

ONMedU, Department of Obstetrics and Gynecology. Practical lesson No. 5. Operative laparoscopy in emergency conditions in gynecology

---

MINISTRY OF HEALTH OF UKRAINE

ODESSA NATIONAL MEDICAL UNIVERSITY

Faculty international

Department of Obstetrics and Gynecology



**CONFIRMED by**  
Vice-rector for scientific and  
pedagogical work  
Eduard BURIACHKIVSKYI  
August 29, 2024

**METHODOLOGICAL RECOMMENDATIONS FOR PRACTICAL CLASS**  
**from elective discipline**

Faculty international, 6th year

Elective discipline **"ENDOSCOPIC TECHNOLOGIES IN OBSTETRICS AND GYNECOLOGY"**

**Practical lesson No. 5.** "Operative laparoscopy in emergency conditions in gynecology".

---

Methodological recommendations for practical lesson, EPP "Medicine", 6th year, Faculty international . Elective discipline "Endoscopic technologies in obstetrics and gynecology".

ONMedU, Department of Obstetrics and Gynecology. Practical lesson No. 5. Operative laparoscopy in emergency conditions in gynecology

---

**Approved:**

Meeting of the Department of Obstetrics and Gynecology  
of Odesa national medical university

Protocol No. 1 dated August 29, 2024

Head of the department \_\_\_\_\_ (Ihor HLADCHUK)

**Developer:**

Ph.D., Assistant Professor of  
Department of Obstetrics and Gynecology \_\_\_\_\_ Bykova N.A.

---

Methodological recommendations for practical lesson, EPP "Medicine", 6th year, Faculty international . Elective discipline "Endoscopic technologies in obstetrics and gynecology".

### *Practical lesson 5*

**Topic: " Operative laparoscopy in emergency conditions in gynecology ".**

**Aim:** To systematize and deepen knowledge on the topic of practical training. To teach conduct assessment conditions of the patient with new and detailed conditions in gynecology. Learn the examination plan patients with emergency. To form a clear idea about the examination before urgent surgical interventions. Learn the methods diagnostics, which are used to establish the causes of " acute " abdomen in gynecology. Get acquainted with the capabilities of modern endoscopic equipment in the diagnosis and treatment of emergency conditions in gynecology. Master the basic technique of endoscopic interventions in emergency gynecology. Determine indications and contraindications for operative laparoscopy in emergency conditions. Know the types of operative laparoscopic interventions in emergency situations. To study the main stages of operative laparoscopy in emergency conditions. Learn the plan for managing patients in the postoperative period.

**Basic concepts:** Ectopic pregnancy, ovarian apoplexy. Clinic, diagnostics, management tactics. Emergency aid. Preoperative preparation and management of the postoperative period.

**Equipment:** Professional algorithms, structural and logical schemes, tables, models, video materials, results of laboratory and instrumental studies, situational problems, patients, case histories.

#### **1. Organizational measures (greetings, inspection those present, message of the topic, purpose of the lesson, motivation students of studying the topic).**

The clinical experience of treatment and prevention institutions shows that the most difficult for a doctor are clinical situations that require urgent care. Proper and timely emergency care, rationally planned and carried out with careful methods, can not only save the patient's life, but also preserve her reproductive function.

Laparoscopy one of the methods modern surgery, in which (without major dissection abdominal wall ), with the help of special optical devices (which are introduced into the abdomen cavity through small incisions skin ), an examination is carried out bodies abdominal cavity \_ Laparoscopy also refers to the modern ones methods diagnostics infertility \_ Hard name any \_ from pathologies pelvic organs, diagnosis and treatment which cannot be performed by laparoscopy.

Laparoscopic gynecology - a new method of effective treatment different gynecological diseases that \_ allows shorten the recovery period patients and not to leave cosmetic defects on the body after carrying out operations. Modern state of the art allows to apply laparoscopy as for diagnostic goals **and** for operative intervention.

**2. Reference level control knowledge (written work, written testing, online, frontal testing poll etc. ).**

— **Requirements for theoretical readiness students to perform practical classes.**

**Knowledge requirements: \_**

- Skills communication and clinical examination the patient
- Ability determine list necessary clinical and laboratory and instrumental research and evaluate their results.
- Ability establish preliminary and clinical diagnosis disease
- Ability diagnose urgent state
- Ability determine tactics and provide emergency medical help
- Execute medical manipulation
- Ability to conduct medical documentation

**List didactic units:**

- Ectopic pregnancy. Clinic, diagnostics, management tactics
- Ovarian apoplexy. Clinic, diagnostics, management tactics.
- Ectopic pregnancy. Emergency aid.
- Ovarian apoplexy. Emergency aid.
- Preoperative preparation.
- Management of the postoperative period.

— **Questions (test tasks, tasks, clinical situations ) for verification basic knowledge on the subject of the lesson.**

**Question:**

1. Diseases that lead to urgent conditions in gynecology
2. Diagnostic methods used to establish the causes that led to urgent conditions in gynecology
3. Etiology, classification, clinical signs, methods of examination, methods of treatment of ovarian apoplexy.
4. Ectopic pregnancy, etiology, pathogenesis, diagnostic methods, differential diagnosis, clinic, treatment, prevention.
5. Indications, contraindications, conditions and technical features of operative laparoscopy in ovarian apoplexy.
6. Indications, contraindications, conditions and technical features of operative laparoscopy in case of ectopic pregnancy.
7. Therapeutic and diagnostic endoscopic methods in emergency conditions in gynecology.
8. Preparation and postoperative management of gynecological patients during urgent surgical interventions.

**Typical situational tasks:**

**Task 1.** A 26-year-old woman was brought to the hospital with complaints of sudden pain in the lower abdomen radiating to the thigh and rectum, nausea, dizziness, bloody dark discharge from the genital tract for a week, delay of menstruation for 4 weeks. The skin is pale. Symptoms of irritation of the peritoneum are determined in the lower abdomen, more on the right. When examined in mirrors: cyanosis of the mucous membrane of the vagina and cervix. Bimanual examination: the uterus and its appendages are not clearly defined due to sharp pain. The symptom of a "floating uterus" is detected, the posterior vault of the vagina is bulging and sharply painful. HCG test is positive. As a result of the preliminary clinical, laboratory and instrumental examination, a preliminary diagnosis was made: Right-sided broken tubal pregnancy by the type of tubal rupture. Intra-abdominal bleeding.

**1. What volume of surgery is planned to be carried out in the treatment of this patient?**

**Standards of answers:** 1. Laparoscopy, right-sided tubectomy, sanitation and drainage abdominal cavity

**Task 2.** D. 26 years old. Brought to the gynecological department department by ambulance assistance on 05/20/22 at 10 a.m. Two hours ago she was healthy, but suddenly appeared abrupt pain in the stomach and supraclavicular area, began vomiting, nausea, loss consciousness \_ The last menstruation was 05/06/22, expired her was normal \_ Objectively: pale, lethargic, pulse 116 bpm, BP – 70/40mm. mercury Art. The belly is swollen, in act breath does not take part. During palpation sharply painful, especially in the lower ones areas. It is noted here tension abdominal muscles Shttkin-Blumberg symptom positive \_ Bimanual: rear vault overhangs, the uterus is normal size, movable, painful, due to pain hard palpable, applications in connection with sharp tension it was not possible to palpate the abdominal wall. Analysis blood: ESR 10 mm/h, leukocytes  $9 \cdot 10^9 / l$ .

Diagnosis ? Management and treatment plan.

**Answer standard:** Apoplexy ovary, mixed form. Intra-abdominal bleeding \_ Anemia. Hemorrhagic shock of the II century. Necessary urgent laparoscopy. Resection ovary, hemotransfusion, treatment of shock, anemia are performed at the same time.

**Typical test tasks:**

1. Patient P., 23 years old, was urgently delivered from complaints of pain in the lower abdomen, more from the right, with irradiation in the rectum, dizziness. The above mentioned complaints appeared suddenly at night The last menstruation 2 weeks ago. Objectively: leather cover pale, pulse - 92 beats / min., t - 36.6 C, arterial pressure 100/60 mm Hg. Art. Stomach something tense, slightly painful in the lower departments, symptoms irritation peritoneum weakly positive. Hemoglobin 98 g/l. What treatment method is most appropriate for this patient?

A. Laparoscopy, ovariectomy.

- B. Conservative treatment.
- C. Laparoscopy, ovary resection.
- D. \_ Laparotomy, ovariectomy.
- E. Laparoscopy, adnexectomy.

2. A 28- year -old female patient, delivered from complaints of acute pain in the lower part of the abdomen It was short term dizziness \_ Delay menstruation 2 months. Skin pale, BP-90/50 mm Hg. art., pulse-110 bpm/ min. Stomach sharply painful in the lower departments. With vaginal examination: the uterus is enlarged. Promtov 's positive symptom. Case of the application increased, sharply painful \_ Rear vault hangs over Was exhibited as usual \_ diagnosis: Right-sided broken tubal pregnancy by type of pipe break. Hemoperitoneum. Hemorrhagic shock of the II century. Anemia. Which operative approach is the most expedient to perform in the treatment of this patient?

- A. Abdominal.
- V. Endoscopic.
- S. Vaginal.
- D. \_ Simultaneous

3. A 17-year-old woman is bothered by sharp pain in the lower abdomen. Marks delay of menstruation for 2 weeks. Sex life during the year. She protected herself from pregnancy by interrupting sexual intercourse. Objectively: pale. Body temperature  $36.6^{\circ}\text{C}$ , blood pressure 95/60 mm Hg, pulse 90 bpm. During a bimanual examination, a slightly enlarged uterus is determined, cervical excursions are painful, the appendages are not clearly contoured, the posterior vault is bulging. Discharge from the genital tract is dark-bloody, scanty. The most informative method:

- A. Ultrasound examination of the pelvic organs.
- B. General blood test.
- C. Puncture of the abdominal cavity through the posterior vault of the vagina.
- D. Colposcopy.
- E. Laparoscopy.

Answers: 1 - C; 2 – B; 3 – E.

**3. Formation of professional abilities and skills (mastery of skills, conducting curation, determining the treatment scheme, conducting laboratory research, etc.).**

— **Content tasks (tasks, clinical situations etc. ).**

**Interactive task:**



Students are divided into 3 teams of 3-4 men each. After the given situational problem, we give the task:

The first team is to make a preliminary diagnosis and make a plan for examining the patient.

The second team is to draw up a treatment algorithm

The third team evaluates the correctness of the answers of the first and second teams and makes its corrections

### **Unusual situational tasks**

**Problem 1.** A 32-year-old woman was brought to the hospital with complaints of sudden pain in the lower abdomen radiating to the thigh and rectum, nausea, dizziness, bloody dark discharge from the genital tract for a week, delayed menstruation for 5 weeks. The skin is pale. Symptoms of irritation of the peritoneum are determined in the lower abdomen, more on the right. In the mirrors: cyanosis of the mucous membrane of the vagina and cervix. Bimanual examination: the uterus and its appendages are not clearly defined due to sharp pain. The symptom of a "floating uterus" is detected, the posterior vault of the vagina is bulging and sharply painful.

#### **1. Previous diagnosis?**

#### **2. Examination plan, treatment plan?**

**Answer 1.** Violated ectopic pregnancy by type of fallopian tube rupture. Intra-abdominal bleeding.

2. Ultrasound of the pelvic organs, determination of hCG in blood plasma, detailed blood analysis, general analysis of urine, laparoscopy. Operative treatment in emergency order. Tubectomy or tubotomy with enucleation of the fetal egg.

**Task 2.** An 18-year-old woman was admitted to the hospital with complaints of gradually increasing pain in the lower abdomen for 12 hours, weakness, nausea.

From the anamnesis: menstruation from the age of 14 to 3-4/26-28. Last menstruation 2 weeks ago. Sex life during the year. Not pregnant. Prevented pregnancy by interrupted sexual intercourse.

Objectively: the skin and mucous membranes are pale, T-36.6 ° C, BP-95/60 mm Hg. art., pulse-90 beats /min. The abdomen is tense, painful in the lower parts. Positive symptoms of irritation of the peritoneum in the lower abdomen are determined.

In the mirrors: the mucous membrane of the vagina and cervix is bluish.

Bimanual examination: The uterus is slightly enlarged, its displacement is painful. The appendages are not clearly contoured due to the sensitivity of the study, the posterior arch is bulging. Discharges from the genital tract are dark-bloody, scanty.

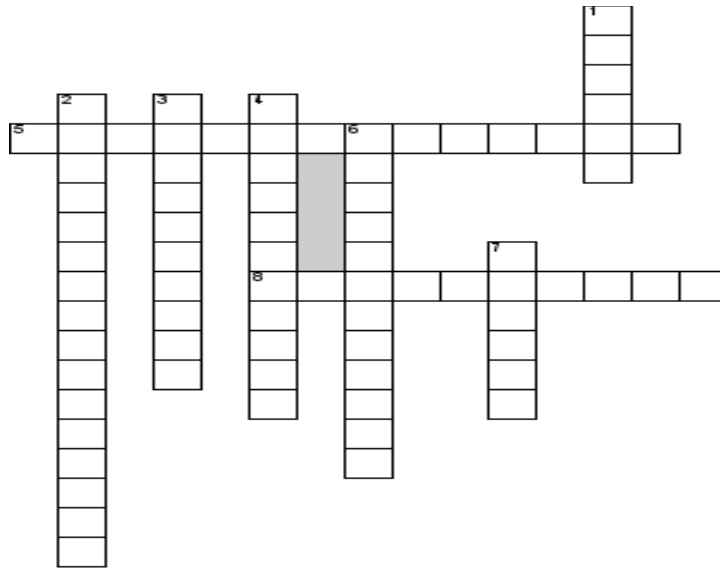
Make an algorithm of the doctor's actions.

#### **Answer standard:**

1. Urgent hospitalization in the gynecological department

2. Intensive therapy
3. Therapeutic and diagnostic laparoscopy.

### Unusual test tasks:



#### Horizontally

5. Characteristic changes of the endometrium during ectopic pregnancy
8. Bleeding with a violation of the integrity of the ovarian tissue, accompanied by bleeding into the abdominal cavity, is this?

#### Vertically

1. Occurs when blood circulation in the tumor is disturbed, does the inflammatory process occur a second time?
2. Pelvic peritonitis
3. Sharply painful menstruation
4. Symptom of intra-abdominal bleeding
6. Operative access for intra-abdominal bleeding
7. Changes in the blood formula during intra-abdominal bleeding

Answers: 5- decidualization ; 8- apoplexy; 1- necrosis; 2 pelvioperitonitis ; 3- dysmenorrhea; 4- Kuhlenkampf ; 6-laparoscopy; 7-anemia.

— **Recommendations (instructions ) regarding implementation tasks (professional algorithms, orienting cards for formation practical skills and abilities etc. ).**

Table. Diagnostic signs of various forms of tubal pregnancy

Clinical	Progressive ectopic	Tubal miscarriage	Rupture of the
----------	---------------------	-------------------	----------------



<b>signs</b>	<b>pregnancy</b>		<b>fallopian tube</b>
<b>Signs of pregnancy</b>	Positive	Positive	Positive
<b>General condition sick</b>	Satisfactory	It periodically worsens, short-term loss of consciousness, long periods of a satisfactory state	Colaptoid condition, clinic of massive blood loss, progressive deterioration of the condition
<b>Pain</b>	Missing	The nature of attacks that are periodically repeated	Appears in the form of an acute attack
<b>Allocation</b>	Absent or minor bleeding	Dark-colored blood discharge appears after an attack of pain	Absent or minor bleeding
<b>Vaginal research</b>	The uterus does not correspond to the period of delay of menstruation, a retort-shaped formation is determined next to the uterus, painless, vaults are free	The same, soreness when the uterus is displaced, education without clear contours, posterior vault smoothed out	The same symptoms of a "floating uterus", tenderness of the uterus and appendages on the affected side, overhang of the posterior vault
<b>Additional examination methods</b>	Ultrasound, determination of the $\beta$ hCG level, laparoscopy	Laparoscopy	Not held

#### Blood group determination algorithm.

Neobh and dny toolkit	White enamel plate, set standard serum, glass or 3 glasses sticks _	
Sequence of actions	<ol style="list-style-type: none"> <li>1. On a white enameled plate, apply one drop of standard serums of two series in the recesses with the corresponding markings-0(I); A(II); B(III).</li> <li>2. In a separate depth apply sprat drops of blood the patient</li> <li>3. To each drops serum add one at a time drops of blood patient and stir separate glass stick or by the edge glass _</li> <li>4. They read the result. If agglutination not in any drops, group of blood patient - the first; if agglutination absent in the second drops-group of</li> </ol>	When mixing blood, it is important to use a different edge of the glass for each drop.

	blood - second; if the third group of blood sick the third When appropriate of blood patients until four groups agglutination appears in everyone drops _	
--	---	--

### **Execution algorithm practical skills \_**

#### *Bimanual (vaginal ) examination:*

- 1) greet the patient ;
- 2) identify patient (name, age );
- 3) to inform the patient about the need carrying out research ;
- 4) to explain to the patient, how the research is conducted ;
- 5) get permission to carry out research ;
- 6) wash hands;
- 7) put on examination gloves;
- 8) first and second fingers spread the left (right ) hand big labia, average place the finger of the " dominant " hand at the same level of the posterior commissure, carefully click on it to \_ open entrance to the vagina ;
- 9) carefully and slowly enter the medium finger, then indicatory finger in the vagina along the back wall to vault and cervix, fourth and fifth bring the fingers to the palm, the thumb lead to the top;
- 10) to determine length vaginal parts cervix in centimeters;
- 11) to determine consistency cervix (dense, soft );
- 12) to determine permeability external eye cervical canal (closed, passes tip finger );
- 13) to evaluate pain excursions cervix ;
- 14) second palm carefully put on the stomach (above the symphysis ) and moderately press to determine the bottom of the uterine body ;
- 15) bring out the body of the uterus between with two hands and determine:
  - relative position of the uterus cervix (anteflexio, retroflexio );
  - dimensions uterine bodies (normal, reduced, enlarged );
  - consistency body of the uterus (dense-elastic, soft, compacted );
  - personalty body of the uterus (relatively mobile, limited mobile );
  - sensitivity during palpation (painful, painless );
- 16) to place fingers in the bottom of the right lateral arch and using palpate the right vaginal area with both hands vault and right appendages of the uterus, determine their size, mobility and soreness ;
- 17) to place fingers in the bottom left lateral vault and using palpate both hands the left vaginal vault and left appendages of the uterus, determine their size, mobility and soreness ;
- 18) to determine capacity vaginal vault ;
- 19) to inform the patient about the results research ;
- 20) thank the patient ;

- 21) withdraw inspection gloves;
- 22) wash hands

I perform laparoscopy in the classical way methodology, which includes the following the main ones stages:

- processing operating field
  - imposition uterine cannulas
  - imposition pneumoperitoneum
  - introduction the first trocar and the beginning of the examination bodies abdominal cavities
- (diagnostic stage laparoscopy )
- introduction additional trocars for manipulators
  - deepened revision bodies abdominal cavities
  - operative stage laparoscopy
  - final stage laparoscopy - removal of the macropreparation, washing abdominal cavities, control of hemostasis, removal of gas and instruments
- imposition single seams or brackets in places punctures on the skin.

When performing laparoscopy adhere to general rules of conduct operational manipulations.

To control hemostasis during laparoscopic procedures interventions use the same methods as in open surgery: electrocoagulation of blood vessels, clipping them, sewing and applying knotted seams, sewing with the help of sewing machines.

In the majority cases creation pneumoperitoneum perform in a closed way with the help of needles Veresha, which is injected into the abdomen cavity slightly below the umbilicus a ring The trocar is inserted through the incision skin, with moderate pressure, at an angle of 90 ° to the peritoneum, and at this moment turn upwards by 45 in one movement. After introduction of the main trocar stylet it taken out and in the abdomen cavity a laparoscope is inserted. The patient is transferred to the position Trendelenburg and examined abdominal cavity, including the upper floor.

is open laparoscopy consists of the following stages: 1) mini-laparotomy, 2) introduction of a special trocar through a mini-laparotomy hole in the abdomen cavity, 3) fixations trocar sleeves to the front abdominal walls for her sealing, 4) creation pneumoperitoneum through the trocar sleeve.

**Laparoscopic tubectomy:** Operation technique: a pneumoperitoneum is typically created. Additional trocars are introduced in the iliac and inguinal regions. After tightening with forceps, the fallopian tube is clamped with branches dissector and bipolar current is applied to it in the coagulation mode. At the same time, the fallopian tube is cut along the upper edge of the mesosalpinx with simultaneous hemostasis. The fallopian tube is pulled out of the

abdominal cavity with a soft clamp through the extended contraperture to the left or right. Then the abdominal cavity and small pelvis are cleaned with an isotonic solution of sodium chloride, and cosmetic sutures are placed on the skin.

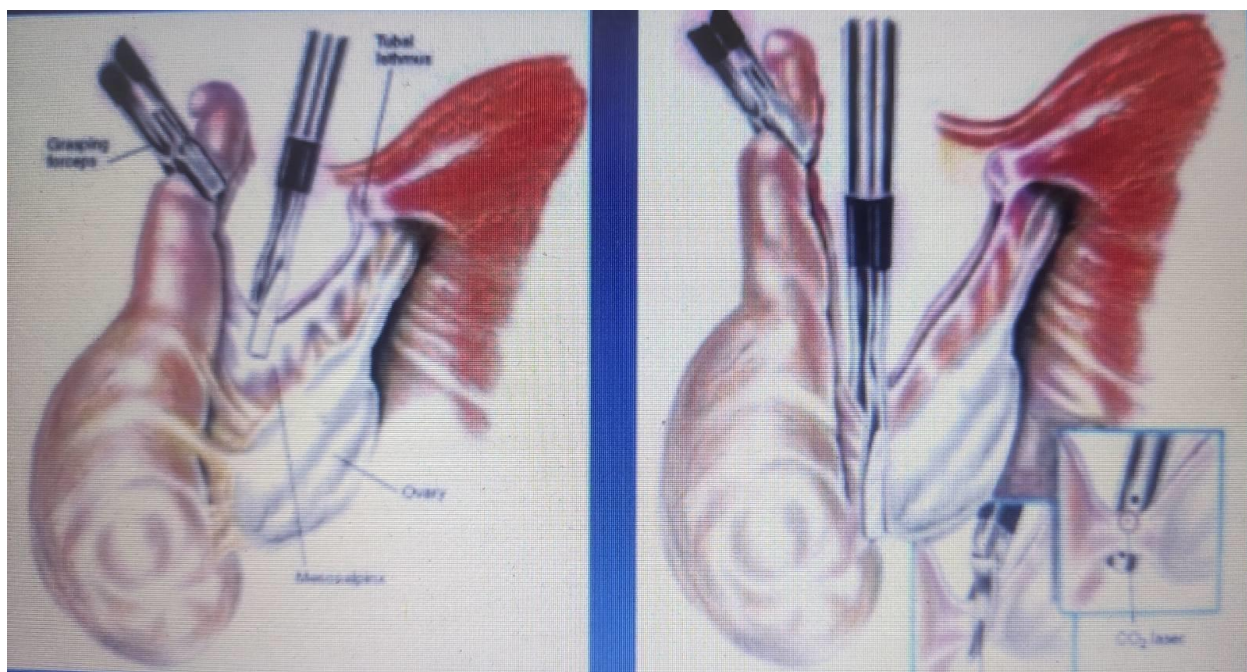


Fig. 1. Laparoscopic tubectomy. Stages of the operation.

### **Laparoscopic tubotomy with evacuation of the fetal egg**

It is performed in case of ampullary tubal pregnancy if it is possible to preserve the fallopian tube (ectopic pregnancy progressing or interrupted according to the type of tubal abortion). Typically, a laparoscopy is performed, 2 trocars and a camera are inserted. After evacuation of the hemoperitoneum the ampullary part of the fallopian tube is fixed atraumatically clamp distal to the ovule. The fallopian tube is pulled out and its lumen is opened in the transverse direction with a hook above the fetal egg.

The fertilized egg is removed, the fallopian tube is washed with a physiological solution of sodium chloride. The need to use electrocoagulation for the purpose of hemostasis is determined by the presence of bleeding from the edges of the cut of the tube or the place of implantation of the fertilized egg.



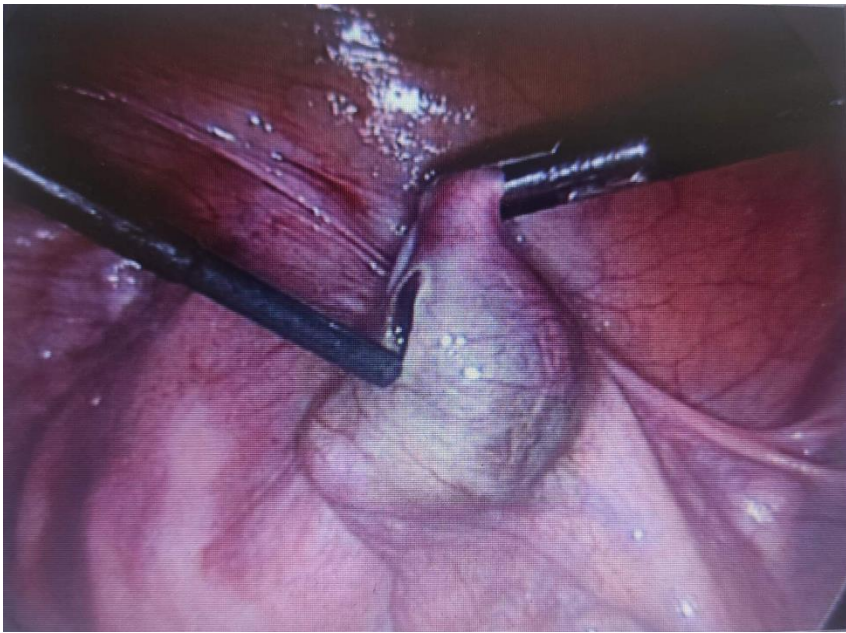

Fig. 2. Laparoscopic tubotomy, evacuation of the fertilized egg. Operation stage.

### **Resection of the ovary**

It is carried out in case of ovarian apoplexy, polycystic ovary syndrome with the aim of creating benign ovarian formations. Excision of the ovary area is carried out with the help of a needle monopolar electrode. For subsequent hemostasis, a bipolar or argon plasma coagulator is used.

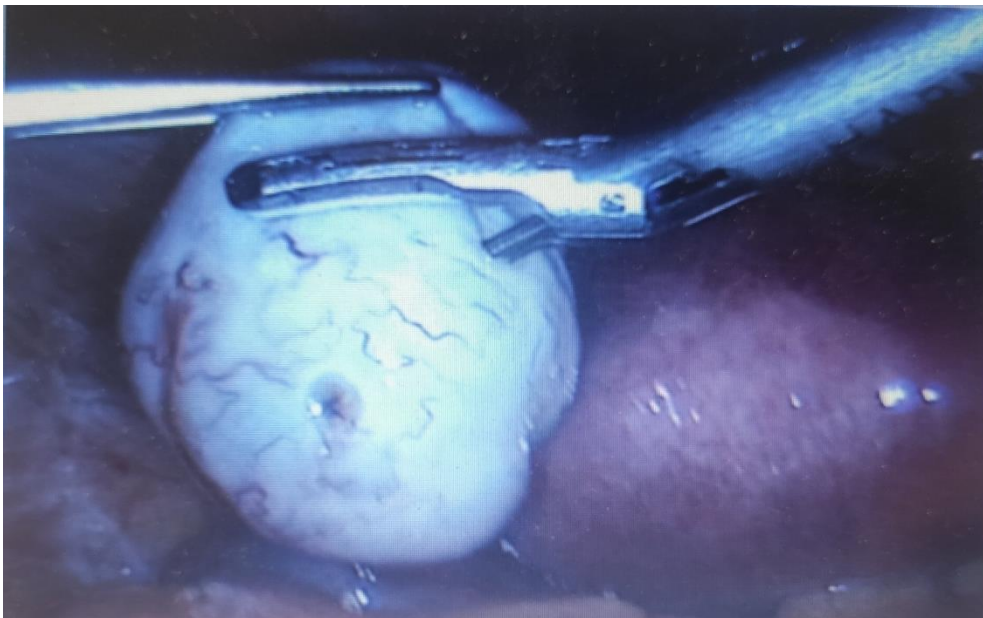

Fig. 3. Laparoscopic resection of the ovary. Operation stage.

### **Requirements for results work, including to registration.**

1. Correctly collect the anamnesis of a patient with an "acute" abdomen.
2. Identify complaints that characterize the basis of the disease.

3. Determine, based on the anamnesis of the disease, the data of subjective and objective research, the signs and features necessary to identify the causes that led to the "acute" abdomen in gynecology.
4. Correctly interpret the data of laboratory and instrumental research methods.
5. Make a plan for the examination of a patient with ovarian apoplexy.
6. Make a plan for the examination of a patient with an ectopic pregnancy.
7. Carry out a differential diagnosis of "acute" abdomen.
8. Establish a diagnosis and make a treatment plan for a patient with ovarian apoplexy.
9. Establish a diagnosis and make a treatment plan for a patient with an ectopic pregnancy.
10. To be able to prepare the patient and postoperative management of gynecological patients during urgent surgical interventions.
11. To provide recommendations on the choice of the method of surgical treatment and the volume of surgical intervention in patients with ovarian apoplexy.
12. To provide recommendations on the choice of surgical treatment method and volume of surgical intervention in patients with tubal ectopic pregnancy.
13. Analysis and discussion of the results of the patient's examination.

— **Control materials for the final stage of the lesson: problems, tasks, tests, etc.**

**Unusual situational tasks:**

**Task 1** Patient B., 21 years old, came to the gynecological department with complaints of sharp pain in the lower abdomen radiating to the anus, dizziness that appeared suddenly after coitus. At home there was a short-term loss of consciousness.

Medical history: menstruation since the age of 13, established after 2 years, 7 days each, cycle 28–34 days, painless, moderate, irregular. Last menstruation 2 weeks ago. Ago.

Objective examination: general condition of the patient of moderate severity. The skin and visible mucous membranes are pale. The tongue is clean, moist. Body temperature is 37.1 °C. Pulse - 84 beats/min, rhythmic, blood pressure - 100/65 mm Hg. Art. The abdomen is moderately distended, moderately painful on palpation in the hypogastric region. Symptoms of peritoneal irritation are positive. Abdominal percussion - dulling of the sound. Pasternacki's symptom is negative on both sides. Physiological parameters are normal.

Gynecological examination. The cervix is not changed. The outer eye is closed. Bimanual examination: excursions of the cervix are sharply painful, Promptov's symptom is positive. The body of the uterus is in the anteflexio position, not enlarged, dense, sensitive to palpation, mobile. In the area of the right appendages of the uterus, a tugoelastic mass measuring 5\*6\*5 cm is palpable, sharply painful, sharply painful. The left uterine appendages are not palpable. The



posterior vault of the vagina overhangs and is sharply painful upon palpation. Discharge from the genital tract is bloody, scanty. General blood analysis: hemoglobin – 94 g/l, erythrocytes –  $2.9 \cdot 10^{12}/l$ , leukocytes –  $5.4 \cdot 10^{12}/l$ .

**Make a diagnosis.**

**Additional examination methods?**

**A treatment plan?**

Standards of answers. Apoplexy of the right ovary, hemorrhagic form. Intra-abdominal bleeding. Hemorrhagic shock of the 1st degree. Anemia I st.

2. Survey plan: \_general clinical and biochemical laboratory tests (general blood test, general urine test, blood group and Rhesus factor, biochemical blood test, coagulogram ), electrocardiogram; Ultrasound of the pelvic organs; express test with urine for hCG, laparoscopy

3. Treatment tactics depends from general condition of the patient, volume intra-abdominal bleeding, indicators hemodynamics. About the extent of surgical intervention in this women - laparoscopy, resection the left ovary \_ Sanitation and drainage abdominal cavity \_

**Task 2.** A 13-year-old girl complains of spasm -like pain in the lower abdomen, which appeared suddenly during physical education, nausea, vomiting.

From the anamnesis: menstruation since the age of 12, not established, abundant, painful. As a child, she suffered from childhood infections. Denies gynecological diseases.

Objectively: the skin and mucous membranes are pink. Pulse - 82 beats per minute, blood pressure - 100\60 mm Hg. Body temperature - 38°C. When palpating the abdomen, the Stotkin-Blumberg symptom is positive in the right iliac region.

Virgo ! Gastrointestinal- rectal examination is impossible due to its sharp pain.

**What studies are most informative for making a diagnosis?**

**Reply**

1. Ultrasound of the pelvic organs.
2. Laparoscopy of the pelvis and abdominal cavity.
3. Computed tomography of the pelvic organs.

**Task 3.** A 34-year-old patient came to the hospital with complaints of acute pain in the lower abdomen, nausea, vomiting. 6 months ago, during the examination, the gynecologist suspected the presence of a right ovarian cyst, but the patient refused the examination. Last menstruation 3 weeks ago, on time. She considers herself sick for 2 weeks, when cramp -like pain in the lower abdomen first appeared. There was no dizziness, she did not return to the doctor.

From the anamnesis: she was treated for inflammation of the uterine appendages.

Objectively: general condition of moderate severity. Temperature 37.7 ° C, pulse 86 bpm. AT-130/90mm Hg. Art. The tongue is coated, the abdomen is

moderately distended, the Shchotkin - Blumberg symptom is positive in the lower abdomen.

Bimanual examination: attention is drawn to sharp pain when the cervix is displaced. To the right of the uterus, a 4x5 cm, painful, elastic mass can be palpated. On the left, applications are not defined. Vaults are deep, palpation of the right vault is painful. Vaginal discharge - white, moderate. Preliminary diagnosis: Torsion of the pedicle of the tumor of the right ovary. What volume of surgery should be performed in the treatment of the patient?

**Answer standard:** In this clinical case, treatment should be started with laparoscopy. The scope of the operation depends on the state of the applications and structures that have fallen into disarray. Detorsion is performed and the condition of applications after detorsion is evaluated. In the absence of signs of necrosis and the appearance of positive nutritional characteristics: pink color of the mucous membrane, moisture of the mucous membrane, pulsation of blood vessels - at this stage, the surgical intervention is completed. If signs of necrosis appear - adnexectomy. If the omentum or loops of intestines are twisted, their viability and further tactics are evaluated. In the case of necrosis - resection of the omentum, resection of the intestine with anastomosis.

### **Test tasks KROK-2:**

1. ( 2018) A woman was delivered by ambulance with cramp-like pain in the right iliac region that arose after a delay in menstruation, radiating into the rectum. bloody secretions from the genital tract. Objectively: heart rate contractions - 100/min., arterial pressure - 90/60 mm Hg. The skin is pale. Stomach painful on palpation, positive symptom of Shtokkin-Blumberg. With gynecological research - landslides neck painful, right appendages enlarged, painful, rear vault overhangs, selection bloody \_ Put previous diagnosis:

- A. Sharp right-sided adnexitis
- B. Appendicitis
- C. Abortion in progress
- D. Apoplexy of the right ovary
- E. Pozamatkova pregnancy that \_ interrupted

2) A woman complains of a sudden pain in the lower abdomen radiating to the anus, nausea, dizziness, bloody dark secretions from the genital tract for a week, delay of menstruation for 4 weeks. Symptoms irritation peritoneum positive \_ In the mirrors: bluishness mucous shells vagina and cervix. With bimanual research the symptom " uterus that floats, swelling and soreness \_ rear and right side the vault vagina \_ Most probable diagnosis ?

- A. Acute appendicitis.
- B. Apoplexy ovary \_
- S. Sharp right-sided adnexitis.
- D. Twist the legs tumors ovary \_
- E. Violated ectopic pregnancy \_

3 ) A woman disturbs acute abdominal pain, increase \_ temperature body up to 38.0°C. Knows about availability uterine fibroids for 3 years. Symptoms irritation peritoneum positive in the lower ones departments of the abdomen. Leukocytes 10.2 T/l, ESR 28 mm/h. With bimanual research the body of the uterus is enlarged to 8-9 weeks pregnancy, on the front surface - sharply excruciating fibroid node the size of 4x4 cm, the appendages of the uterus have not changed. Ultrasonic research confirms availability subserous fibroid node \_ Which diagnosis most likely ?

- A. Internal endometriosis \_
- V. Tuboovarian a tumor
- S. Myomatous necrosis node \_
- D. Acute adnexitis.
- E. Perimetritis.

4 ) In the gynecological department a 20- year -old patient came with complaints about sharp pain in the lower abdomen after physical load \_ The last menstruation 2 weeks ago. With vaginal examination of the uterus is not enlarged, painless, on the left appendage sharply painful during palpation that \_ makes it difficult research. Promtov's symptom positive \_ Rear vault looming, painful. Pulse 96 bpm, blood pressure 100/60 mm Hg. About which Are we talking about pathology ?

- A. Sharp nearside salpingo-oophoritis.
- B. Apoplexy the left ovary \_
- S. Pyosalpinx to the left
- D. Disrupted left-sided tubal pregnancy.
- E. Tumor the left ovary

5 ) (2019) The patient is 39 years old with complaints of acute pain in the lower abdomen, vomiting, accelerated urination \_ During examination: abdomen moderately inflated, positive symptom of Shtotkin-Blumberg. Pulse 88 per minute, body temperature 37°C. With bimanual examination: the body of the uterus is dense, not enlarged, mobile, painless, on the right and in front palpable from the uterus formation 6x6 cm in size, tight elastic consistency, sharp painful when shifting ; appendages are not defined on the left ; vault free ; selection mucous \_ An additional research method ?

- A. X- ray television hysterosalpingography.
- B. Excretory urography.
- C. Transvaginal e hography.
- D. Puncture abdominal cavity through the back vault vagina \_
- E. Computer room tomography

#### 4. Summary results (criteria assessment results training ).

**Current control:** oral survey, testing, evaluation implementation practical skills, solutions situational clinical tasks, assessment activity in class etc. \_

***The structure of the current evaluation in the practical lesson:***

1. Assessment theoretical knowledge on the topic of the lesson:
  - methods: survey, solution situational clinical tasks ;
  - the maximum score is 5, the minimum rating - 3, unsatisfactory rating - 2.
2. Rating practical skills and manipulations on the topic of the lesson:
  - methods: assessment correctness implementation practical skills ;
  - the maximum score is 5, the minimum rating - 3, unsatisfactory rating - 2.
3. Assessment work from the patient on the subject of the lesson:
  - methods: assessment: a) communicative skills communication with the patient, b) correctness assignments and evaluations laboratory and instrumental studies, c) compliance with the algorithm of conducting differential diagnosis d) rationale clinical diagnosis, e) drawing up a treatment plan ;
  - the maximum score is 5, the minimum rating - 3, unsatisfactory rating - 2.

***Current assessment criteria for practical lesson:***

"5"	The student is free owns material, accepts active participation in discussion and decision-making situational clinical problems, for sure demonstrates practical skills during the inspection patients and interpretations data clinical, laboratory and instrumental studies, expresses his opinion on the topic of the lesson, demonstrates clinical thinking _
"4"	The student has a good command material, takes part in the discussion and decision situational clinical problems, demonstrates practical skills during the inspection patients and interpretations data clinical, laboratory and instrumental research with some mistakes, expresses his opinion on the topic of the lesson, demonstrates clinical thinking _
"3"	A student is not enough owns material, uncertain participates in discussion and decision - making situational clinical problems, demonstrates practical skills during the inspection patients and interpretations data clinical, laboratory and instrumental studies with significant by mistakes
"2"	The student does not own material, does not take part in the discussion and decision situational clinical problem, does not demonstrate practical skills during the inspection patients and interpretations data clinical, laboratory and instrumental of research.

**5. List of recommended literature.**

**Basic:**

1. Clinical Obstetrics and Gynecology: 4th Edition / Brian A. Magowan, Philip Owen, Andrew Thomson. - 2021. - 454 p.
2. Obstetrics and gynecology: nats. textbook for medical universities of the 1st and 5th levels of accreditation in 4 volumes// National textbook in 4

- volumes / V.M. Zaporozhan, T.F. Tatarchuk, I.Z. Gladchuk, V.V. Podolsky, N.M. Rozhkovska., Marichereda V.G., Volyanska A.G..-K.: VSV "Medicine", 2017. - 696 с.
3. Obstetrics and Gynecology=Акушерство і гінекологія: in 2 volumes. — Volume 2. Gynecology=Гінекологія: Підручник для мед. ун-тів, інст., акад. — 3-тє вид., стер. Рекомендовано МОЗ / За ред. В.І. Грищенка, М.О. Щербини. — К., 2022. — 352 с.
  4. Oats, Jeremy Fundamentals of Obstetrics and Gynecology [Text]: Liewellyn-Jones Fundamentals of Obstetrics and Gynecology / J. Oats, S. Abraham. — 10<sup>th</sup> ed. — Edinburgh [etc.]: Elsevier, 2017. — VII, 375 p.
  5. Williams Manual of Obstetrics (24th Ed) F. G. Cunningham, K. J. Leveno, S. L. Bloom, C. Y. Spong, J. S. Dashe, B. L. Hoffman, B. M. Casey, J. S. Sheffield, McGraw-Hill Education/Medical. — 2014. — 1377 pp.

**Additional:**

1. Textbook of Gynecology (6th Ed) Dutta DC., Hiralal Konar (Ed.). — JAYPEE BROTHERS MEDICAL PUBLISHERS (P) LTD, 2013. — 702 pp.
2. DC Duttas Textbook of Obstetrics including Perinatology and Contraception (8th Ed.) Dutta DC., Hiralal Konar (Ed.). — JAYPEE BROTHERS MEDICAL PUBLISHERS (P) LTD, 2015. — 782 pp.
3. Llewellyn-Jones Fundamentals of Obstetrics and Gynaecology (10th Ed). Jeremy Oats, Suzanne Abraham. Elsevier. 2016. — 384 pp.
4. Basic Science in Obstetrics and Gynaecology / edited by Philip Bennet, Catherine Williamson. 4th Edition. 2010, Churchill Livingstone Elsevier. — 386 pp.
5. Oats, Jeremy Fundamentals of Obstetrics and Gynaecology [Text]: Liewellyn-Jones Fundamentals of Obstetrics and Gynaecology / J.Oats, S.Abraham. — 10<sup>th</sup> ed. — Edinburgh [etc.]: Elsevier, 2017. — VII, 375 p.
6. Dutta, Durlav Chandra. D. C. Dutta's Textbook of Gynecology including Contraception / D.C. Dutta; ed/ Hiralal Konar. — 7<sup>th</sup>.ed. — New Delhi: Jaypee Brothers Medical Publishers, 2016. — XX, 574 p
7. Zaporozhian V.M. Simulation medicine. Experience. Acquisition. Prospects: practice. advisor / V.M. Zaporozhian, O.O. Tarabrin. — Sumy: University. Book, 2018. — 240 p.
8. Gynecology: a guide for doctors./ V.K. Likhachev. — Vinnytsia: Nova Kniga, 2018. - 688 p.
9. Infertility and benign disease dairy glands / National Academy of Sciences of Ukraine, Ministry of Health of Ukraine, Institute of Pediatrics, Obstetrics and Gynecology, UMSA; under the editorship A.G. Kornatska, T.F. Tatarchuk, O.D. Dubenko. — K.; Poltava, 2017. — 271 p.

10. Family Planning: A Universal Guide for Family Planning Providers. Updated 3rd edition 2018. Copenhagen: WHO Regional Office for Europe; 2021
11. Active " Clinical protocols ", approved by the order of the Ministry of Health of Ukraine for Obstetrics and Gynecology.

**Electronic information resources:**

1. <https://www.cochrane.org/>
2. <https://www.ebcog.org/>
3. <https://www.Acog.org/>
4. <https://www.update.com>
5. <https://online.Lexi.com/>
6. <https://www.ncbi.nlm.nih.gov/>
7. <https://pubmed.ncbi.nlm.nih.gov/>
8. <https://www.thelancet.com/>
9. <https://www.rcog.org.uk/>
10. <https://www.npwh.org/>