

ONMedU , Department of Obstetrics and Gynecology. Practical lesson 8. Colposcopy in the diagnosis of cervical pathology.

ONMedU , Department of Obstetrics and Gynecology. Practical lesson 8. Colposcopy in the diagnosis of cervical pathology.

MINISTRY OF HEALTH OF UKRAINE

ODESSA NATIONAL MEDICAL UNIVERSITY

International Faculty

Department of Obstetrics and Gynecology



CONFIRMED by

Vice-rector for Scientific and Pedagogical Work

Eduard BURJACHKIVSKYI

August 29, 2024

**METHODOLOGICAL DEVELOPMENT TO PRACTICAL LESSON
FROM ELECTIVE DISCIPLINE**

Faculty international, course VI .

Elective discipline "Endoscopic technologies of obstetrics and gynecology"

Practical lesson 8. Topic Colposcopy in diagnostics of cervical pathologies

ONMedU , Department of Obstetrics and Gynecology. Practical lesson 8. Colposcopy in the diagnosis of cervical pathology.


ONMedU , Department of Obstetrics and Gynecology. Practical lesson 8. Colposcopy in the diagnosis of cervical pathology.

Approved:

Meeting of the Department of Obstetrics and Gynecology


Odessa National Medical University

Protocol No. 1 dated August 29, 2024

Head of the Department _____  (Igor GLADCHUK)

Developers:

PhD, Assistant

of the Department of Obstetrics and Gynecology _____  Lunko T.A.

Practical lesson 8

Topic Colposcopy in the diagnosis of cervical pathology.

Aim: Familiarization with the capabilities of modern endoscopic equipment (colposcope) in the diagnosis of diseases of the female genital organs (vulva , vaginal walls and cervix). Mastering the basic technique of colposcopy (simple and common). Determination of indications and contraindications for colposcopy. Learn how to assess the patient's condition by asking for help , draw up an examination plan using modern diagnostic methods, analyze data from laboratory and instrumental examination methods for precancerous and malignant diseases of the female reproductive system, and determine a preliminary diagnosis:

Basic concepts: Precancerous diseases of the cervix: classification. Simple and advanced colposcopy. Conducting principles. Colposcopy during pregnancy. Features of the condition of the cervix during pregnancy. Differential colposcopic diagnosis: cervical decidualosis, cervical cancer.

Equipment: Teach conduct assessment patients and medical staff criteria acceptability examination methods. Learn the examination plan female patients To master consulting. Bring conduct selection modern method of examination in different categories of population with precancerous and malignant diseases of genital organs. Professional algorithms, structural and logical schemes, tables, dummies and phantoms, video materials, results of laboratory and instrumental studies, situational problems, patients, medical histories,

I. Organizational measures (greetings, inspection those present , message of the topic, purpose of the lesson , motivation students of studying the topic).

The clinical experience of treatment and prevention institutions shows that the most difficult for a doctor are clinical situations that require urgent care. The correct, timely, rationally planned and careful assistance provided can not only save the patient's life, but also preserve her reproductive function.

Precancerous diseases of the genital organs (female genital organs) are considered an urgent and multifaceted problem of modern medicine. In the structure of oncological morbidity, tumors of the female genital organs make up 20-30%. According to the Cancer Committee of the International Federation of Obstetricians and Gynecologists, stage 1 is determined in only 20% of newly diagnosed patients, the other 80% of patients consult a doctor at more advanced stages of the process, radical treatment is threatened by a large number of relapses and metastases or is impossible at all. uterus, the initial stage of treatment leads to

recovery in 98-100% of cases, in some patients it allows to preserve the generative function. Therefore, the prevention of precancerous conditions is the most important urgent task of health care. Only with early stages of malignant tumors, but also with benign tumors, as well as with pre-tumor diseases, makes an important contribution to solving the problem of malignant tumors of the genital organs.

II. Support control knowledge (written work, written testing , online, frontal testing poll etc.).

2.1. Requirements for theoretical readiness students to perform practical classes.

Knowledge requirements:

- skills communication and clinical examination the patient;
- ability determine list necessary clinical and laboratory and instrumental research and evaluate their the results ability determine list necessary clinical and laboratory and instrumental research and evaluate their results;
- ability establish preliminary and clinical diagnosis disease;
- ability perform medical manipulations;
- ability conduct consulting on issues precancerous diseases of female genital organs
- the ability to conduct medical documentation.

List didactic units:

- consulting on issues pro -cancer diseases of the cervix, external genital organs,
- general review m methods examination using gynecological examination: in mirrors, bimanual examination, rectovaginal examination
- Condition assessment mucous membrane of the patient 's cervix .
- necessary examination, which is carried out in a planned manner before acceptance decision of using additional method of examination and treatment
- **2.2. Questions (test tasks, tasks, clinical situations) for verification basic knowledge on the subject of the lesson .**

Questions:

- Classification of precancerous cervical diseases
- Etiopathogenetic factors that determine development pathology cervix Papillomavirus infection
- Precancerous diseases of the cervix: etiology, clinic, diagnosis, treatment
- Methods diagnostics precancerous diseases cervix - Colposcopy. Schiller's test.
- Treatment tactics for precancerous lesions diseases cervix, indications for radical methods treatment _
- Vaccination against HPV infection

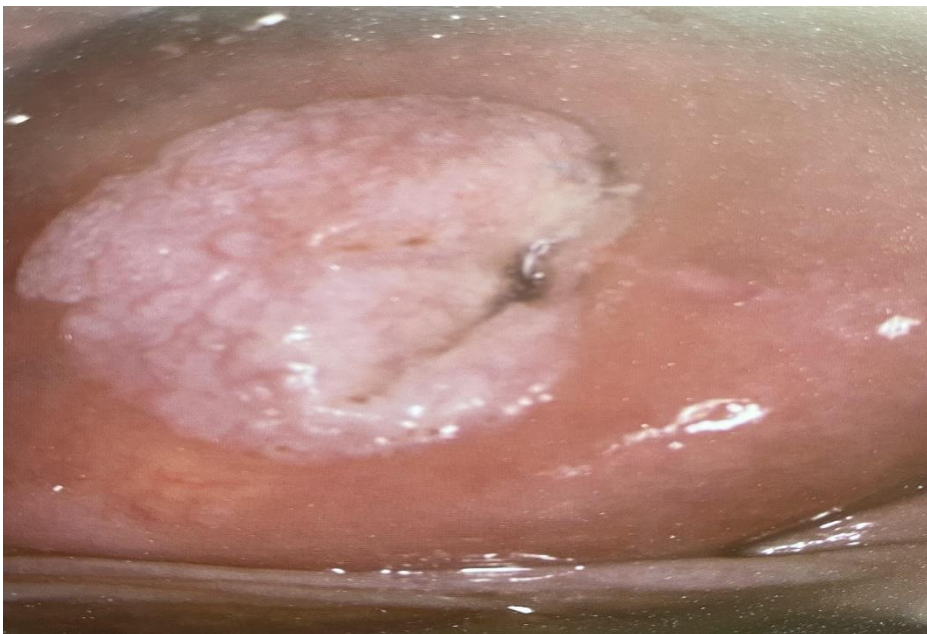Typical situational tasks:

1. The patient is 45 years old has complaints of discharge from the vagina of a watery nature and contact bloody. Last cancer examination 5 years ago, revealed erosion cervix, treated fat tampons. In the mirrors: the cervix is hypertrophied, the cervix is marked on both lips growth, which bleed when touched. Vaginal: the body of the uterus is somewhat increased, mobile, painless, appendages are not determined. Vault vagina, parameters - free. Which of the methods is the most valuable for confirmation diagnosis?

D-z: Colposcopy with targeted biopsy. Smear for cytomorphological examination. Targeted biopsy of the cervix.

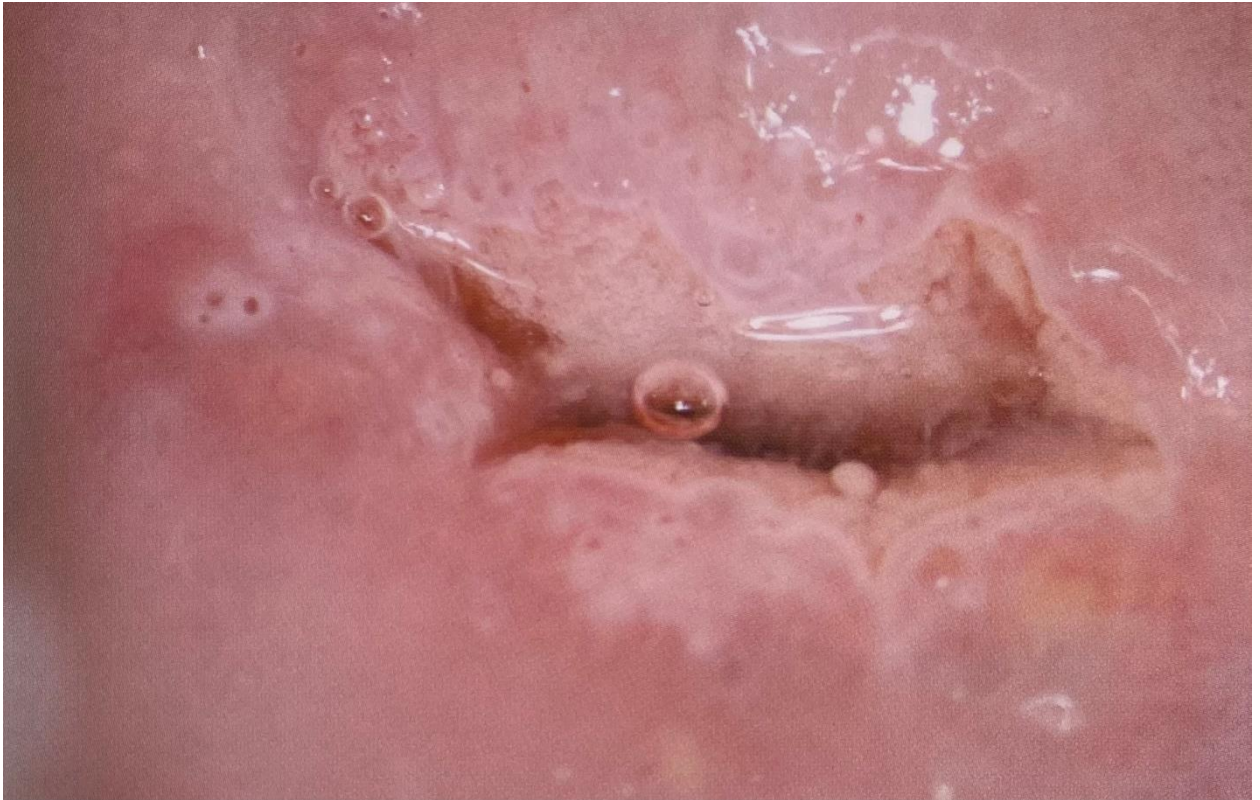2. Clinical case No. 1

A test with a 5% solution of acetic acid was performed for 30-40 seconds Adequate colposcopic picture. The joint line is visualized completely in the cervical canal. Type 2 transformation zone. Localization of the lesion within the transformation zone in 4 quadrants, 50% of the cervix. Anomalous colposcopic picture of the II degree and a non-specific sign: Rough keratosis, rough leukoplakia, dense acetic - white epithelium.



Colposcopic picture corresponds to: Dysplasia epithelium of the cervix, severe intraepithelial carcinoma (HSIL , CIN 3), leukoplakia

Recommended: targeted biopsy of the cervix.



Adequate colposcopic picture. The joint line is visualized completely at the level of the outer eye. Type 1 transformation zone. A normal colposcopic picture of the cervix , covered with BPE, is visualized circularly metaplasia , single islanders cylindrical epithelium.

colposcopic picture tells: Variant of the norm.

2. Typical tests

1. A 22-year-old girl came to the doctor for a routine examination. She smokes 1 pack of cigarettes a day for 5 years. Has one permanent sexual partner, uses condoms. My paternal grandfather died of a heart attack at the age of 60. During the physical examination, the pulse is 78/min., the respiratory rate is 14/min., the blood pressure is 110/70 mm Hg. During auscultation of the heart, a systolic murmur is heard in the II intercostal space to the left of the sternum. Which doctor's recommendation would be most appropriate for this patient?

- A. Colposcopy with biopsy
- B. Pass a Pap test
- C. Screening for hyperlipidemia
- D. Pass a Pap test and take an HPV test
- E. Learn to self-examine the mammary glands

2. In a 30-year-old patient, at the regular preventive examination at the gynecologist, the vaginal part of the cervix was found to have fine points formation

in the form of "eyes" of dark bluish color. Doctor assumes endometriosis vaginal parts of the cervix. What is the research method will be the most informative for confirmation diagnosis ?

- A. Colposcopy , targeted biopsy of the cervix
- B. Hormonal examination
- S. Ultrasound of the pelvic organs
- D. Scraping of the mucous walls of the uterine cavity
- E. Hysteroscopy

III. Formation professional ability, skills (mastery skills, conducting curation, definition schemes treatment, laboratory research, etc.).

- 3.1. Content tasks (tasks, clinical situations etc.).

- Interactive tasks:

- students groups divide into 3 subgroups of 4-5 people each. We work in the office of pathology of the cervix, we consult with patients colpophotogramiz archive, we give tasks :
- And the subgroup - put previous diagnosis, during colposcopy
- second subgroup is to draw up a management plan gynecological patient after colposcopy.
- III subgroup - evaluates correctness answers of subgroups I and II and adds his own corrections.

Atypical situational tasks:

1. * A 35-year-old patient went to the gynecological office hospital with complaints about periodicals lower back pain departments of the abdomen, which are increasing during menstruation, dark brown smearing selection with sexual ways. With bimanual examination: the body of the uterus is several increased, appendages are not determined, during examination cervix in mirrors discovered blue eyes.

1) Which one diagnosis most likely ?

External cervical endometriosis

2) Examination algorithm: examination of the cervix in mirrors, smears for microscopy and cytomorphology, colposcopy is common. Biopsy of the cervix.

Atypical tests:

1. To which histological classification does simple leukoplakia of the cervix belong?

- Precancerous diseases
 - F new disease
 - Cervical cancer
 - Adenomatosis
 - Adenomyosis
2. Select true treatment tactics for benign and polypoid formations cervix
- + Polypectomy,
- R is separate diagnostic scraping
 - Observation
 - Colposcopy, cytology, bacterioscopy
 - Local therapy, and antibacterial therapy
 - Endometrial scraping

III

3.2. Recommendations (instructions) for performing tasks (professional algorithms, orienting maps for the formation of practical skills and abilities, etc.).

- To learn how to collect an anamnesis correctly, to pay attention to the patient's complaints, which make it possible to make a preliminary diagnosis, to plan further tactics in different periods of a woman's life, from the juvenile to the postmenopausal period. The examination is carried out in a planned or urgent manner before acceptance decision in favor of whether another method of examination and treatment of the patient.
- Master the ability to correctly draw up an examination plan, taking into account the invasiveness of the methods, the need for these studies. To carry out modern research methods that allow you to identify and take into account all the smallest details that contribute to the recognition of the disease and allow you to correctly establish a diagnosis for the further appointment of adequate therapy.

Diseases of the genital organs are divided into neoplastic (tumor) and non-neoplastic (background or pre-tumor). Non-neoplastic lesions of the external genitalia are also called dystrophy of the vulva .

Precancerous diseases of the cervix	Dysplasia of the cervical epithelium - focal or single or multiple pathological processes in which hyperplasia, proliferation, violation of differentiation, maturation and rejection of epithelial cells that do not go beyond the basement membrane are noted.
-------------------------------------	--

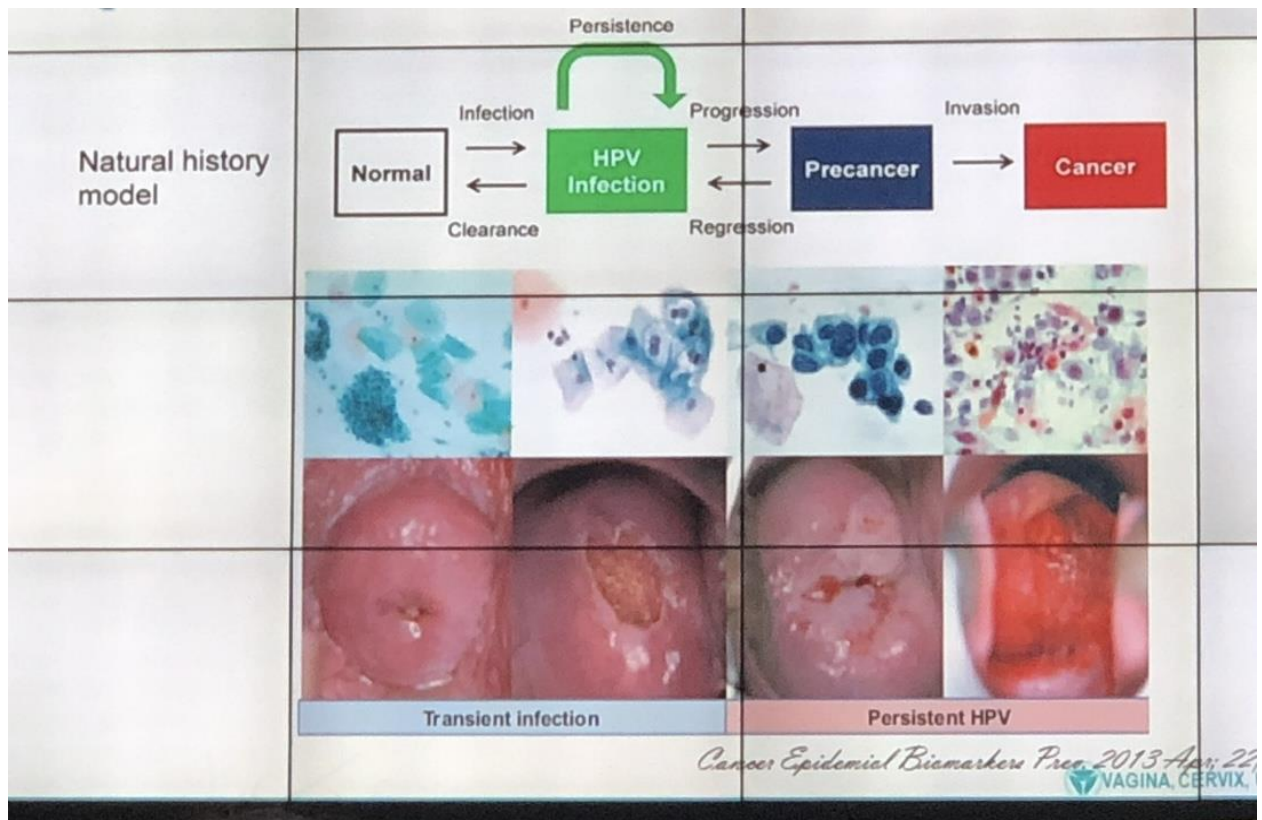
Ectopia of the cervix	displacement of the cylindrical epithelium on the displacement of the cylindrical epithelium on the vaginal portion of the cervix.
Polyp of the cervical canal	this is a focal proliferation of the connective tissue of the endocervix, covered with cylindrical epithelium and protruding into the lumen of the cervical canal or beyond it and are connective tissue growths covered with epithelium. Cervical papilloma is a form of cervical lesion and including rites epithelium _
Papilloma neck	the form of the lesion of the cervix and is characterized by focal growths of the stroma and multilayered epithelium with keratinization. Viral infections and chlamydia play a certain role in their occurrence
Candyoma of the cervix	abnormal growths of multi-layered flat epithelium according to the type of acanthosis (immersion of keratinized epithelial islands in the underlying tissue between the connective tissue papillae) with elongated papillae.
Dysplasia epithelium of the cervix (cervical intraepithelial neoplasia, CIN, cervical intraepithelial neoplasia, CIN	characterized by pronounced proliferation of atypical epithelium of the cervix with a violation of its stratification without involvement of the stroma and surface epithelium in the process, a pathological process of keratinization of the surface layers of a multilayered fold
Leukoplakia	Leukoplakia development is based on histological changes: hyperkeratosis, parakeratosis, acanthosis. who the epithelium of the cervix
Dysplasia vulva (vulvar intraepithelial neoplasia, vulvar intraepithelial neoplasia, VIN	characterized by violation maturation and normal keratinization cells without invasion into the stroma

- Conduct gynecological examination (in mirrors, bimanual, rectal, rectovaginal).
- Collect special gynecological history, evaluate results of laboratory examination

- Conduct pick up material from the vagina, cervix, cervical canal and urethra for cytological and bacterioscopic research.
- Evaluate the results cytological, histological, virological and bacteriological of research/
- Evaluate results of ultrasound examination pelvic •organs.

Evaluate the colposcopic protocol research cervix and vulva

- Make an examination plan the patient with different background and precancerous nosological types pathology



Precancerous diseases of the cervix

The group of precancerous conditions includes focal single or multiple proliferations with the phenomena of cell atypia

1. Dysplasia,
2. Leukoplakia with atypia of cellular elements,
3. Adenomatosis
4. Cervical polyp

Classification precancerous became cervix

Dysplasia epithelium of cervix (cervical intraepithelial neoplasia, CIN, cervical intraepithelial neoplasia, CIN) is characterized pronounced proliferation atypical epithelium cervix with a violation him layers without involvement in the process stroma and process keratinization superficial layers multilayered flat epithelium cervix

Cervical intraepithelial neoplasia - (CIN) is distributed:

CIN I weak, CIN II moderate, CIN III severe

According to the BETESDA classification (TBS):

Precancerous changes

CIN 1+PVI (koilocytosis , atypia, flat condyloma) = LSIL	LSIL - squamous cell low- grade intraepithelial lesions
CIN II - III cr.in situ = H-SIL	H-SIL - squamous cells high- grade intraepithelial lesions

Normal differentiation and stratification is disturbed due to hyperplasia of basal and parabasal cells without further differentiation. Consequently, cellular and tissue atypia appears.

Risk factors for the development of cervical dysplasia :

- Early onset of sexual life (14-17 years old), when the epithelium of the cervix is immature and easily exposed to oncogenic influences.
- Frequent change sexual partners.
- Abortions and childbirth at a young age (traumatization cervix).
- Diseases which _ are transmitted sexually (papillomavirus VPH type 16-18, trichomoniasis, chlamydia, ureaplasmosis, gonorrhea, etc.).
- Smoking.

Deciduous cervix of a pregnant woman . Physiological changes occur during pregnancy, resulting in changes in cytological, histological and colposcopic pictures. Such changes caused by pregnancy can be the cause of diagnostic errors. Increased vascularization of the stroma leads to blueness of the cervix. In the II trimester of pregnancy, more than 90% of patients . Vascularization is well visualized during colposcopy, sometimes colposcopically resembling the pathology of a high-grade abnormality. There is hyperplasia and hypertrophy of the papillae of the mucous cervical canal and an increase in the secretory activity

of the cylindrical epithelium with the formation of thick mucus. In the endocervix, folding increases, new crypts appear.

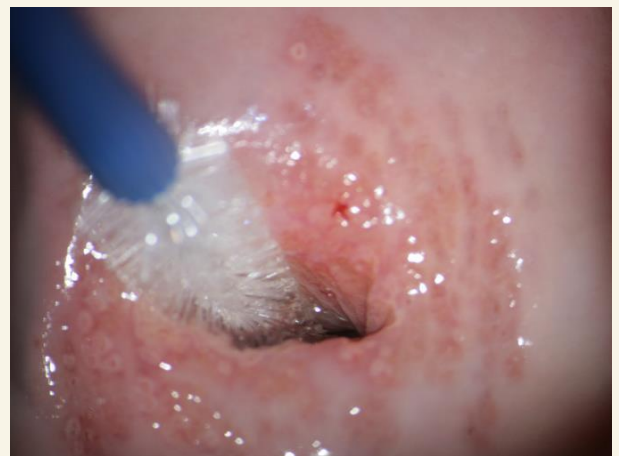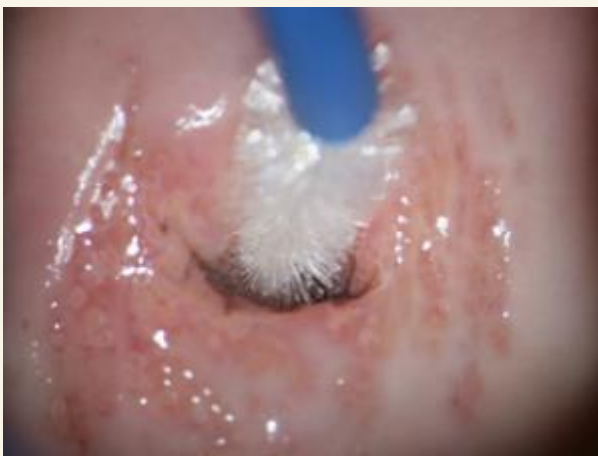The purpose of colposcopy in a pregnant woman is to rule out the presence of invasive cancer, to determine the need for targeted biopsy, since cervical cancer during pregnancy poses a threat to the health of the mother and child.

IV. Summing up (criteria for evaluating learning outcomes).

Diagnostic methods:

1. Review in mirrors:
2. Cytomorphological smear investigation
 - classic (exocervix and endocervix)
 - based on liquid cytomorphology.

This is a painless procedure. The doctor removes the cervix in mirrors, then uses a soft brush to make circular tangential movements along the epithelium of the cervical transformation zone.



The process of taking a cytological smear. Zone of transformation of the cervix 1st type. The junction line of multilayered flat and cylindrical epithelium is visualized completely.

After that, the resulting cell material is transferred from the brush to glass or into a container with a special solution and sent to the laboratory. In the laboratory, after preparing and staining the drug, the cytologist examines the structure of the cells and gives a conclusion — whether the smear is normal or pathological.

Bethesda 2001 class	Interpretation	Correspondence to the type of	Tactics
---------------------	----------------	-------------------------------	---------

		smear	
Negative for intraepithelial lesions and neoplasia (NILM)	The normal condition of the squamous epithelium corresponding to the age and condition of the woman (pregnancy, post-partum state, menopause, puberty, taking hormonal drugs, intrauterine spiral) without visible epithelial changes suspicious for dysplastic. This category also includes inflammatory and reactive changes in the squamous epithelium caused by bacterial, fungal or viral (herpes simplex virus) agents. This category also includes the shift of bacterial flora towards vaginosis.	I or II	A routine gynecological screening program is recommended, with a repeat Pap smear every 1 year for women under 30 years of age and 2 years for women over 30 years of age.
Atypical squamous cells with unspecified features (ACS – US)	Changes in the squamous epithelium that cannot be related to the inflammatory process or the action of any of the factors described above, but do not fully correspond to the picture of the dysplastic process. This category belongs to reversible changes, probably associated with HPV infection.	II - III a	Follow-up with a repeat Pap test after 6 months is recommended. A capsid test for predicting regression of dysplasia.
Low-grade squamous intraepithelial lesions (LSIL)	Changes in the squamous epithelium with signs of mild dysplasia. This category belongs to the reverse changes caused by HPV infection.	IIIa	Follow-up with a repeat Pap test after 6 months is recommended. A capsid test for predicting regression of dysplasia
Atypical squamous cells, HSIL cannot be ruled out, (ACC – H)	Changes in the squamous epithelium with indeterminate, when severe dysplasia cannot be excluded. This category belongs to non-reversible changes caused by HPV infection and requires radical treatment tactics.	III	Follow-up with a repeat Pap test after 6 months is recommended. A capsid test for predicting regression of dysplasia.
High-grade squamous intraepithelial lesions (HSIL)	Changes in the squamous epithelium of a severe degree of damage. This category includes severe dysplasia, as well as carcinoma in situ. These are irreversible conditions that require surgical intervention, the volume of which is determined on the basis of a histological conclusion.	III-IV	Colposcopy with the selection of biopsies of dysplastic areas of the cervix for further histological analysis with the determination of the prevalence of dysplasia, control of the presence/absence of invasion and the extent of surgical treatment is recommended.

Examination of the cervix with abnormal cellular morphology of the Papanicolaou smear includes the following methods:

- simple and extended colposcopy ;
- targeted biopsy of the cervix;

ONMedU , Department of Obstetrics and Gynecology. Practical lesson 8. Colposcopy in the diagnosis of cervical pathology.

- scraping of the mucous membrane of the cervical canal (endocervical curettage);
- targeted and widespread cone -shaped biopsy of the cervix

simple colposcope and I — examination of the cervix p and sl i you are far from being separated from surfaces and without the use of honey and stone products .

The river is wide the colposcope and I are carried out afterwards I will apply

on the vaginal part of the cervix 3% solution vinegar acids (acetic acid coagulates protein and abnormal cells, which contain more protein, look acetic -white), and after 2% solution Lugol After treatment with 3% solution vinegar acids and unchanged epithelium changes to bl i du coloring, when applying no 2% solution Lugol (**Shiller** 's test) surface pubic parts on the cervix is different painted in dark brown and black. Normally iodine-positive, if not stained iodine-negative.

Target biopsy : Taking material from a pathological area of the surface of the cervix

is carried out using a conchotome, under colposcopic control research.

Methods treatment diseases cervix

1. Conservative - a course of anti-inflammatory therapy.
2. Surgical: • local destruction (argon plasma coagulation , diathermocoagulation, cryodestruction , laser destruction);
 - radical surgical intervention (excision of pathological areas of the cervix, amputation of the cervix, trachelectomy , hysterectomy).
3. Combined

Primary prevention of RSHM consists in carrying out measures against persons who do not have signs disease, for the purpose of prevention him development in the future.

Primary prevention of RSM is vaccination teenage girls before puberty life _ Vaccines: Cervarix (2 x valent), Gardaxil (4-9 valent).

Secondary prevention of RSHM consists in the early detection and treatment of women who have precancerous changes on the cervix in order to prevent, in the future, the development of invasive cancer.

Tertiary prevention of RSM is complex or combined treatment, which includes surgical intervention in combination with radiation and chemotherapy.

Execution algorithm practical skills

Review cervix in mirrors, sampling material for cytomorphological research.

- 1) greet the patient;
- 2) identify patient (name, age);
- 3) inform the patient about the need carrying out research;
- 4) explain to the patient, how the research is conducted;
- 5) get permission to carry out research;
- 6) wash hands;
- 7) wear inspection gloves;
- 8) take gynecological a mirror in the dominant hand;
- 9) fingers second hand carefully to breed labia, slowly enter closed mirror in the vagina without touching urethra and clitoris;
- 10) gynecological mirror unfold in the vagina and open for inspection cervix;
- 11) assess the condition of the vagina parts cervix and walls vagina:
 - color and condition of the mucous membrane shells vagina (hyperemia, swelling)
 - the nature of the vagina secretions (physiological, pathological)
 - the shape of the cervix (conical, cylindrical)
 - length vaginal parts cervix (cm)
 - external form eye cervical canal (round, slit-like, availability gaps)
 - nature of secretions from the cervical canal (mucous, bloody, purulent, watery)
- to take substantive glass that III (exocervix) and II (endocervix) are marked;
- carry out a collection material for cytomorphological research:
 - Air spatula (or with a cytobrush bent at 90°) scrape from surface cervix by conducting complete rotation (360°), apply the material to the object glass with a broad stroke, thin and uniform stroke under marked III (exocervix);
 - insert the cytobrush into the cervical canal, rotate its 360° 2-3 times, collected material rotational movements around own axes apply to substantive glass under with the mark T (endocervix);
 - carefully remove mirror;
 - inform the patient about the results research;
 - to thank the patient;
 - remove inspection gloves;
 - wash your hands.

Interactive tasks:

students divide into 3 brigades with 3-4 men each. After given situational tasks we give tasks:

The first team is to put previous diagnosis and make an examination plan female patients;

The second team is to draw up a treatment algorithm;

The third team evaluates rights and wrongs answers the first and the second brigades and makes its own corrections;

Situational task:

The patient is 48 years old puts forward complaints about contacts bleeding _ When looking in mirrors discovered hypertrophy cervix/ The last has appearance " flowery cabbage ", easily injured, dense. With bimanual reviews: vault shortened, the body of the uterus is immobile. Which reliable diagnosis?

1. Examination plan. (Examination in mirrors, colposcopy , targeted biopsy, cone biopsy, FDV of the uterine lining.)
2. Clinical diagnosis (D-z : Cervical cancer)
3. Treatment measures.

Tests:

The patient is 45 years old complains about contacts bleeding during the last 5 months. When examined in mirrors: the cervix is hypertrophied, has appearance floral cabbage, bleeds when touched with a probe. Bimanual research: neck dense consistency. The body of the uterus is not enlarged, it is mobile. The appendages are not palpable. parameters are free Vault deep _ Which most likely diagnosis?

- A. * Cervical cancer
- B. Cancer of the body of the uterus
- C. Fibromatous node that is born
- D. Cervical pregnancy
- E. Polyposis cervix

3.3. Requirements for work results, including to registration

- Counsel women on issues of pathological secretions during sexual intercourse
- Assess the patient.

- treatment method for teenagers, for women of reproductive age, for Oral report about the thematic patient.
- Analysis and discussion of the results of the patient's examination.
- Multimedia presentation on the topic of the class (literature review using modern sources; video films, etc.).

3.4. Control materials for the final stage of the lesson: problems, tasks, tests, etc.

Professional control skill

In the gynecological department departments:

1. Collect history, perform objective and gynecological examination female patients , to conduct a colposcopic examination.
2. Install previous diagnosis, make a colposcopic diagnosis.
3. To appoint a plan of examination and treatment

4. Summing up (criteria for evaluating learning outcomes).

Current control: oral survey, testing, assessment of performance of practical skills, solution of situational clinical tasks, assessment of activity in class, etc.

The structure of the current evaluation in the practical lesson:

1. Assessment theoretical knowledge on the topic of the lesson:
 - methods: survey, solution situational clinical tasks;
 - the maximum score is 5, the minimum rating - 3, unsatisfactory rating - 2.
2. Rating practical skills and manipulations on the topic of the lesson:
 - methods: assessment correctness implementation practical skills;
 - the maximum score is 5, the minimum rating - 3, unsatisfactory rating - 2.
3. Assessment work from the patient on the subject of the lesson:
 - methods: assessment: a) communicative skills communication with the patient, b) correctness assignments and evaluations laboratory and instrumental studies, c) compliance with the algorithm of conducting differential diagnosis d) rationale clinical diagnosis, e) drawing up a treatment plan;
 - the maximum score is 5, the minimum rating - 3, unsatisfactory rating - 2.

Current assessment criteria for practical lesson:

«5»	The student is fluent in the material, takes an active part in the discussion and solution of situational clinical problems, confidently demonstrates practical skills during the examination of a pregnant and interpretation of clinical, laboratory and instrumental studies, expresses his opinion on the topic, demonstrates clinical thinking.
«4»	The student is well versed in the material, participates in the discussion

	and solution of situational clinical problems, demonstrates practical skills during the examination of a pregnant and interpretation of clinical, laboratory and instrumental studies with some errors, expresses his opinion on the topic, demonstrates clinical thinking.
«3»	The student isn't well versed in material, insecurely participates in the discussion and solution of a situational clinical problem, demonstrates practical skills during the examination of a pregnant and interpretation of clinical, laboratory and instrumental studies with significant errors.
«2»	The student isn't versed in material at all, does not participate in the discussion and solution of the situational clinical problem, does not demonstrate practical skills during the examination of a pregnant and the interpretation of clinical, laboratory and instrumental studies.

5. List of recommended literature.

1. Clinical obstetrics and gynecology: teaching manual: trans. 4th English edition / Bryan A. Magova, Philip Owen, Andrew Thomson; Science editor. translation. Mykola Shcherbina. - K.: VSV "Medicine", 2021. - X, 454 p.
2. Endoscopic surgery: teaching manual / V.M. Zaporozhan, V.V. Hrubnik, Yu.V. Hrubnik, A.V. Malinovsky, etc .; edited by V.M. Zaporozhan, V.V. Hrubnik. -K.: VSV "Medicine", 2019. - 592 p.
3. 2011 IFCPC colposcopic terminology. Clarification on practical use. - K.. - "Polygraph plus", 2018. - 62 p.
4. Obstetrics and gynecology: in 4 volumes. - Volume 3. Non-operative gynecology textbook (university I V r.a.) / V.M. Zaporozhian, I.B. Vovk, I.Yu. Gordienko and others; under the editorship V.M. She is pregnant. - 2014. - 928 p.
5. Obstetrics and gynecology: in 2 books. – Book 2. Gynecology: a textbook (University of the III-IV years) / under the editorship of V.I. Hryshchenko, M.O. Shcherbiny - 2nd ed., reprint, 2017. – 376 p.
6. Oats, Jeremy Fundamentals of Obstetrics and Gynecology [Text]: Liewellyn - Jones Fundamentals of Obstetrics and Gynecology / J. Oats, S. Abraham. – 10th ed. – Edinburgh [etc.]: Elsevier, 2017. – VII, 375 p.

Additional:

1. Gynecology: a guide for doctors./ V.K. Likhachev . – Vinnytsia : Nova Kniga, 2018. - 688 p.

2. Diagnostics of obstetric and gynecological endocrine pathology: [educational manual for intern doctors and trainee doctors of institutions (faculty) post-diploma . of Education of the Ministry of Health of Ukraine] / edited by V.K. Likhacheva ; V.K. Likhachev , L.M. Dobrovolska, O.O. Taranovska and others; UMSA (Poltava). – Vinnytsia: E.V. Maksimenko Publisher, 2019. – 174 p.
3. Zaporozhian V.M. Simulation medicine. Experience. Acquisition. Prospects: practice. advisor / V.M. Zaporozhian, O.O. Tarabrin. – Sumy: University. Book, 2018. – 240 p.

Internet sources:

1. <https://www.cochrane.org/>
2. <https://www.ebcog.org/>
3. <https://www.acog.org/>
4. <https://www.uptodate.com>
5. <https://online.lexi.com/>
6. <https://www.ncbi.nlm.nih.gov/>
7. <https://pubmed.ncbi.nlm.nih.gov/>
8. <https://www.thelancet.com/>
9. <https://www.rcog.org.uk/>
10. <https://www.npwh.org/>
11. <https://www.update.com>
12. <https://online.lexi.com/>

