

ONMedU, Department of Obstetrics and Gynecology. Practical lesson № 11. Maternal pelvis. The fetus as an object of labor.

**MINISTRY OF HEALTH OF UKRAINE
ODESA NATIONAL MEDICAL UNIVERSITY**

International Faculty

Department of obstetrics and gynecology

  **CONFIRMED by**
Vice rector for scientific and pedagogical work
Eduard B. BACHKIVSKIY
29» August, 2024

**METHODOLOGICAL RECOMMENDATIONS
FOR PRACTICAL CLASS**

International Faculty, Course V

Discipline "Obstetrics and Gynecology"

Practical lesson №11. Topic: Maternal pelvis. The fetus as an object of labor.

Methodological recommendations for practical lesson. «Health care», master's degree in the specialty "Medicine". Discipline "Obstetrics and Gynecology"

ONMedU, Department of Obstetrics and Gynecology. Practical lesson № 11. Maternal pelvis. The fetus as an object of labor.


Approved:

Meeting of the Department of Obstetrics and Gynecology of Odesa National Medical University

Protocol No. 1 dated August 29, 2024.

Head of the Department  (Ihor GLADCHUK)

Developer:

Ph.D., assistant professor of
obstetrics and gynecology department  (G.Kozhukhar)

Methodological recommendations for practical lesson. «Health care», master's degree in the specialty "Medicine". Discipline "Obstetrics and Gynecology"

Practical class №11.

MATERNAL PELVIS. THE FETUS AS AN OBJECT OF LABOR.

LEARNING OBJECTIVE is to gain basic knowledge about structure of bony pelvis and soft tissues of female pelvis, their physiological changes during pregnancy and labor, formation of birth canal, peculiarities of fetal skull. In addition, in order to make recommendations for management of labor, it is important to understand how they can impact on the course of labor.

BASIC CONCEPTS: Pelvis from anatomical and obstetric points of view. Pelvic floor. The structure of the fetal head. The dimensions of the fetal head and body. Signs of fetal maturity. Measurement and evaluation of the pelvis.

EQUIPMENT

1. Multimedia equipment (computer, projector, screen), TV.
2. Obstetric models and obstetric instruments (pelvimeter, obstetric stethoscope, centimeter tape).
3. Professional algorithms, structural-logical schemes, tables, videos.
4. Results of laboratory and instrumental researches, situational tasks, patients, medical histories.

EDUCATIONAL TIME – 4 h

1. ORGANIZATIONAL STAGE

1. Greetings,
2. checking attendees,
3. defining of educational goals,
4. providing of positive motivation.

The reproductive organs in female are those which are concerned with copulation, fertilization, growth and development of the fetus and its subsequent exit to the outer world. Knowledge about their physiological changes during pregnancy and labor, formation of birth canal is the basic one in obstetrics. Unless well studied, this can make impossible to master physiological and pathological obstetrics at all.

5. **CONTROL OF BASIC KNOWLEDGE** (written work, written testing, online testing, face-to-face interview, etc.)

2.1. Requirements for the theoretical readiness of students to perform practical classes.

Knowledge requirements:

1. Communication and clinical examination skills.
2. Ability to determine the list of required clinical, laboratory and instrumental studies and evaluate their results.
3. Ability to make a preliminary and clinical diagnosis of the disease
4. Ability to perform medical manipulations
5. Ability to determine the tactics of physiological pregnancy, physiological labor and the postpartum period.
6. Ability to keep medical records.

List of didactic units:

1. Pelvis from anatomical and obstetric points of view.
2. Pelvic floor.
3. The structure of the fetal head.
4. The dimensions of the fetal head and body.
5. Signs of fetal maturity.
6. Measurement and evaluation of the pelvis.

2.2. Questions (test tasks, tasks, clinical situations) to test basic knowledge on the topic of the class.**Questions:**

1. The anatomy of bony pelvis.
2. The boundaries of a true and a false pelvis, their obstetric functions.
3. Measurements of the pelvic diameters, measurement of diagonal conjugate.
4. The anatomy of the muscular pelvic floor and the perineum, their functions and changes during pregnancy and parturition.
5. Three parts of uterus, their obstetric functions.
6. Formation of the birth canal during labor.
7. Peculiarities of fetal skull, the importance of sutures and fontanelles.
8. The diameters of the skull.
9. Mechanism and importance of moulding.
10. The mechanism of formation of caput succedaneum.

Test tasks

Direction: For each of the multiple-choice questions select the lettered answer that is the one best response in each case.

1. The posterior rectus fascia (sheath) ends at the
 - (A) insertion of the rectus muscles
 - (B) insertion of the anterior rectus sheath
 - (C) arcuate line (semicircular line, linea semicircularis, line of Douglas)
 - (D) area approximately 3-4 cm below the umbilicus
 - (E) area approximately 2-3 cm above the pubic symphysis
2. Sacrospinous ligament
 - (A) a thick band of fibers filling the angle created by the pubic rami
 - (B) passes from the anterior superior iliac spine to the pubic tubercle
 - (C) triangular and extends from the lateral border of the sacrum to the ischial spine
 - (D) attaches to the crest of the ilium and the posterior iliac spines superiorly with an inferior attachment to the ischial tuberosity
 - (E) passes over the anterior surface of the sacrum
3. Sacrotuberous ligament
 - (A) a thick band of fibers filling the angle created by the pubic rami
 - (B) passes from the anterior superior iliac spine to the pubic tubercle

- (C) triangular and extends from the lateral border of the sacrum to the ischial spine
- (D) attaches to the crest of the ilium and the posterior iliac spines superiorly with an inferior attachment to the ischial tuberosity
- (E) passes over the anterior surface of the sacrum

4. Ilioinguinal ligament

- (A) a thick band of fibers filling the angle created by the pubic rami
- (B) passes from the anterior superior iliac spine to the pubic tubercle
- (C) triangular and extends from the lateral border of the sacrum to the ischial spine
- (D) attaches to the crest of the ilium and the posterior iliac spines superiorly with an inferior attachment to the ischial tuberosity
- (E) passes over the anterior surface of the sacrum

5. Arcuate ligament

- (A) a thick band of fibers filling the angle created by the pubic rami
- (B) passes from the anterior superior iliac spine to the pubic tubercle
- (C) triangular and extends from the lateral border of the sacrum to the ischial spine
- (D) attaches to the crest of the ilium and the posterior iliac spines superiorly with an inferior attachment to the ischial tuberosity
- (E) passes over the anterior surface of the sacrum

6. Formed by the superior and inferior pubic rami and covered by a central membrane through which a nerve, artery, and vein pass

- (A) obturator foramen
- (B) greater sciatic foramen
- (C) lesser sciatic foramen
- (D) sacrospinous ligament
- (E) sacral foramina

7. The internal pudendal vessels and pudendal nerve exit the pelvis but then reenter through this structure

- (A) obturator foramen
- (B) greater sciatic foramen
- (C) lesser sciatic foramen
- (D) sacrospinous ligament
- (E) sacral foramina

8. Divides and demarcates the greater and lesser sciatic foramen

- (A) obturator foramen
- (B) greater sciatic foramen
- (C) lesser sciatic foramen
- (D) sacrospinous ligament

(E) sacral foramina

9. The piriformis muscle, gluteal vessels, and posterior femoral cutaneous nerves pass through this structure

- (A) obturator foramen
- (B) greater sciatic foramen
- (C) lesser sciatic foramen
- (D) sacrospinous ligament
- (E) sacral foramina

10. Four anterior and four posterior openings through which pass small nerves

- (A) obturator foramen
- (B) greater sciatic foramen
- (C) lesser sciatic foramen
- (D) sacrospinous ligament
- (E) sacral foramina

11. Which of the following statements is FALSE?

- (A) The ischium has a body and two rami
- (B) The internal surface of the body of the ischium provides attachments for the levator ani muscle and coccygeus muscle
- (C) The superior ramus is located cephalad to the inferior ramus in the standing position
- (D) The superior ramus forms the dorsolateral portion of the obturator canal
- (E) The ischial tuberosity is the lowest portion of the pelvis in the erect or sitting posture and bears the weight of the human frame in the sitting position

12. Regarding the pubis, which of the following statements is FALSE?

- (A) The pubis has a body and two rami
- (B) The superior edge of the body of the pubis, lateral to the midline, has a raised area called the anterior iliac crest a common landmark
- (C) The inferior ramus is the attachment of the adductor magnus and brevis, and obturator internus muscles
- (D) The inferior rami form the lower portion of the pubic arch
- (E) Inferiorly, the pubic bone is the attachment for the urogenital diaphragm

13. The sacrum

- (A) is formed from 11 or 12 small fused vertebrae
- (B) has an uppermost anterior portion called the obstetrical conjugate
- (C) in women has a concave pelvic surface
- (D) is separated from the vertebrae that make up the coccyx by the sacrococcygeal joint
- (E) most often is the limiting factor in determining the size of the pelvic outlet

14. Which of the following is a muscle of the external genitalia?

- (A) the gluteus
- (B) the sartorius
- (C) the superficial transverse perineal
- (D) the deep transverse perineal
- (E) the levator ani

15. The term pudenda includes the

- (A) mons pubis
- (B) vulva
- (C) labia
- (D) external genitalia
- (E) all the above

16. The term perineum describes

- (A) the entire area between the thighs from the symphysis to the coccyx, bounded inferiorly by the skin and superiorly by the levator muscles of the pelvic diaphragm
- (B) the anus and perianal area
- (C) the superficial skin layer of the vulva
- (D) the tendon joining the muscles deep to the external genitalia
- (E) bulbocavernosus, ischiocavernosus, and transverse perineal muscles as a complex

17. The clitoris

- (A) consists of a single crurum, a short body, and the glans clitoris, with overlying skin called the prepuce
- (B) is attached to the pubic bone by a suspensory ligament
- (C) contains within the shaft the corpora cavernosa, a collection of dense connective tissue that serves as support for the anterior-inferior portion of the vagina
- (D) is supplied very sparsely with nerves originating primarily from the terminal branch of the ilioinguinal nerve in most women
- (E) plays a secondary role in erotic stimulation in most women when compared to the role of the vagina

18. Which of the following statements regarding the muscles of the external genitalia is TRUE?

- (A) The bulbocavernosus muscle surrounds the distal vagina and vestibule on each side as a single continuous strip of muscle, much like other sphincters
- (B) The ischiocavernosus muscle takes origin from the ischial tuberosity and inferior ischial ramus and inserts upon the inferior pubic ramus on each side of the pelvis
- (C) The superficial transverse perineal muscle arises from the ischial tuberosity and inferior ischial ramus and inserts between the posterior vagina and anterior rectum

- (D) The perineal body serves as a central connection for all the superficial muscles of the external genitalia except the transverse perineal muscle which inserts directly on the external anal sphincter
- (E) The muscles of the external genitalia are usually spared at the time of episiotomy when the levator ani muscle is routinely divided

19. Which of the following statements about the vagina is FALSE?

- (A) The vagina is a 7-10 cm canal connecting the internal and external genitalia from the vestibule to the uterine cervix
- (B) It is a hollow, distensible, fibromuscular tube with the apex (vault) having an H-shaped lumen and the external opening being flattened in the dorsal-ventral dimension
- (C) The body of the vaginal tube is flattened in its normal resting state
- (D) The mid-portion of the vaginal axis is nearly perpendicular to the lower sacrum in the adult human female in a standing position
- (E) The posterior fornix (back wall of the vagina) is approximately 2 cm longer than the front wall and is directly connected to the peritoneal pouch (posterior cul de sac, retrouterine space, or pouch of Douglas) directly behind the uterus

20. When the infantile uterus is examined, one finds that

- (A) the cervix is larger than the corpus (body of the uterus)
- (B) the position is always anteflexed
- (C) the cervix is the same size as the corpus
- (D) the body is larger than the cervix
- (E) it is as large as the adult organ in the immediate newborn period

21. The portio vaginalis of the cervix is that part which

- (A) extends cephalad from the vagina
- (B) protrudes into the vagina
- (C) forms an internal isthmus
- (D) is normally covered with endocervical epithelium
- (E) all the above

22. Which of the following statements regarding the uterus is FALSE?

- (A) The uterus has a body (corpus), composed mainly of smooth muscle, and a cervix, composed mainly of connective and elastic tissues, that are joined by a transitional portion (isthmus)
- (B) It is an estrogen-dependent organ measuring about 7.5 cm long by 5 cm in width, and 4 cm anterior to posterior diameter in an adult female
- (C) After puberty the uterus weighs about 50 grams in the nullipara and 70 grams in the multipara
- (D) It lies between the bladder anteriorly and the pouch of Douglas in front of the rectum posteriorly, with the cervical portion extending into the abdomen and into the vagina
- (E) The opening at the distal tip of the cervix is called the internal os

23. The uterus and adnexa are normally mobile structures, but they do have some relatively fixed anatomic characteristics. Which, if any, of the following statements about their relationship and/or positions is FALSE?

- (A) Antelexion means that the uterus is bent forward on itself
- (B) The ovaries can be normally found caudad to the cervix
- (C) The round ligaments are normally attached to the uterus anterior to the insertion of the fallopian tubes
- (D) Adnexa refers to the tube, ovary, and their connecting structures
- (E) All statements are true

24. Regarding the anatomy of the fallopian tube, which of the following statements is FALSE?

- (A) Fallopian tubes are a conduit from the peritoneal to the uterine cavity
- (B) Each fallopian tube traverses the superior portion of the broad ligament attached by a mesentery (mesosalpinx)
- (C) The fallopian tube has four distinct areas in its 8-12 cm length: the portion that runs through the uterine wall (interstitial or cornual portion), the part immediately adjacent to the uterus (isthmic portion), the mid-portion of the tube (ampulla), and the distal portion containing the finger-like fimbria that expels the ovum (infundibular portion) to begin its passage toward the ovary
- (D) The longest of the fimbriae (fimbria ovarica) is attached to the ovary
- (E) Each tube is covered by peritoneum and consists of three layers: serosa, muscularis, and a nonciliated mucosa

25. Which of the following statements about the ovary is FALSE?

- (A) The ovaries normally change in size through-out a woman's lifetime
- (B) The ovary is supported in its normal anatomic position by the infundibulopelvic ligament and the ovarian ligament
- (C) The ovary produces both hormones and germ cells
- (D) The ovary lies in the ovarian fossa of the true pelvis, overlying the iliac vessels
- (E) The ovary produces the estrogens and androgens that regulate sexual desire in the human female

26. The pelvic peritoneum covers all of the following pelvic structures EXCEPT the

- (A) fimbria of the fallopian tube
- (B) uterine fundus
- (C) round ligament
- (D) uterorectal pouch of Douglas
- (E) uterosacral ligament

27. Which of the following statements regarding the female urethra is FALSE?

- (A) The urethra is a hollow, multi-layered tube 2.5 to 5 cm long, connecting the bladder with the outside world
- (B) The urethral-vesical junction is located at the level of the mid-trigone
- (C) There is no true anatomic sphincter within the urethra
- (D) The lower two-thirds of the urethra is contiguous with the anterior vaginal wall
- (E) The intrinsic “increased” resting tone of the urethra provides part of the continence mechanism for urinary control

28. The nerve supply to the vulva may be characterized as being

- (A) mediated via the pudendal nerve
- (B) a complex arrangement of Meissner’s corpuscles
- (C) most dense of the prepuce of the clitoris
- (D) derived mainly from the nerves of spinal cord segments S-2,3,4
- (E) all the above

29. Which of the following statements regarding the innervation of the vagina is true?

- (A) The upper two-thirds of the vagina is largely innervated by sympathetic fibers from the presacral nerve
- (B) The vagina receives only parasympathetic fibers from the hypogastric plexus and pelvic splanchnic nerves. It is one of the few organs without sympathetic innervation
- (C) The upper vagina has more touch and pain fibers than the lower vagina
- (D) The vagina has more nerve endings per surface area than the clitoris, and therefore is probably the major organ involved in achievement of female orgasm

30. Branches of the internal iliac artery include all of the following EXCEPT the

- (A) pudendal artery
- (B) obturator artery
- (C) superior gluteal artery
- (D) ovarian artery
- (E) inferior vesical artery

31. Which of the following statements regarding the vessels of the vagina is FALSE?

- (A) The arterial supply of the vagina comes from the cervicovaginal branch of the uterine artery, inferior vesical, middle hemorrhoidal, and internal pudendal arteries
- (B) Venous drainage of the vagina is accomplished through an extensive plexus rather than through well-defined channels
- (C) The lymphatic drainage is such that the superior portion of the vagina (along with the cervix) drains into the external iliac nodes, the middle portion

into the internal iliac nodes, and the lower third mainly into the superficial inguinal nodes and internal iliac nodes

(D) Being a relatively avascular organ, the vagina is predisposed to atrophic changes in older patients

32. Opens the abdomen through the linea alba and can be extended from symphysis pubis to xiphoid without dividing the muscles of the abdomen

- (A) midline incision
- (B) Pfannenstiel incision
- (C) Maylard incision
- (D) Cherny incision
- (E) paramedian incision

33. A low transverse incision extended downward and through the anterior rectus fascia, with the anterior rectus sheath separated from the underlying muscles, from the pubis to near the level of the umbilicus

- (A) midline incision
- (B) Pfannenstiel incision
- (C) Maylard incision
- (D) Cherny incision
- (E) paramedian incision

Answer key

1.	A	12.	B	23.	B
2.	C	13.	C	24.	C
3.	D	14.	C	25.	E
4.	B	15.	E	26.	A
5.	A	16.	A	27.	B
6.	A	17.	B	28.	E
7.	C	18.	C	29.	A
8.	D	19.	D	30.	D
9.	B	20.	A	31.	D
10.	E	21.	B	32.	A
11.	B	22.	E	33.	B

11. FORMATION OF PROFESSIONAL SKILLS (mastering skills, conducting curation, determining the treatment regimen, conducting a laboratory study, etc.).

3.1. Content of tasks (tasks, clinical situations, etc.).

Interactive task:

Students of the group are divided into 3 subgroups of 3-4 people each. They work in the classroom, reception department of the maternity hospital, labor & delivery ward, neonatal department with pregnant and newborns.

Tasks:

1. Subgroup I - to perform external pelviometry, measuring of diagonal conjugate, calculation of true conjugate, to assess measurements of the true and the false pelvis.
2. Subgroup II - to assess grade and type of moulding in cephalic presentations.
3. Subgroup III – to assess answers of subgroups I and II and makes adjustments.

Tests:

Direction: For each of the multiple- choice questions select the lettered answer that is the one best response in each case.

1. A healthy 167 sm tall, adult female is most likely to have a pelvic inlet that would be classified as which of the following Caldwell-Moloy types?

- (A) android
- (B) platypelloid
- (C) anthropoid
- (D) gynecoid
- (E) triangular

2. The human pelvis is a complex structure that permits upright posture and being capable with childbirth despite the relatively large fetal head. Which option includes all of the bones that make up the pelvis?

- (A) trochanter, hip socket, ischium, sacrum, and pubis
- (B) ilium, ischium, pubis, sacrum, and coccyx
- (C) ilium, ischium, and pubis
- (D) sacrum, ischium, ilium, and pubis
- (E) trochanter, sacrum, coccyx, ilium, and pubis

3. During normal delivery, an infant must pass through the maternal true pelvis. Which of the following most accurately describes the characteristics of the true pelvis?

- (A) It has an oval outlet.
- (B) It has four defining planes: an inlet, a cavity, a midplane, and an outlet.
- (C) It has an inlet made up of a double triangle.
- (D) It is completely formed by two fused bones.
- (E) It lies between the wings of the paired ileum.

4. The part of the pelvis lying above the linea terminalis has little effect on a woman's ability to deliver a baby vaginally. What is the name of this portion of the pelvis?

- (A) true pelvis
- (B) midplane
- (C) outlet
- (D) false pelvis
- (E) sacrum

5. The plane from the sacral promontory to the inner posterior surface of the pubic symphysis is an important dimension of the pelvis for normal delivery. What is the name of this plane?

- (A) true conjugate
- (B) obstetric conjugate
- (C) diagonal conjugate
- (D) bi-ischial diameter
- (E) oblique diameter

6. Under the influence of relaxin and the pressure of pregnancy the junction between the two pubic bones may become unstable near the time of delivery. This will result in a waddling gait in the woman to minimize discomfort. What is this junction called?

- (A) sacroiliac joint
- (B) symphysis
- (C) sacrococcygeal joint
- (D) piriformis
- (E) intervertebral joint

Answer key

- | | |
|----|---|
| 1. | D |
| 2. | B |
| 3. | B |
| 4. | D |
| 5. | B |
| 6. | B |

3.2. Educational materials, recommendations (instructions) for performing tasks

External pelvimetry

Assessment of the false pelvis can be done using external calipers.

Time: The assessment is done at any gestational age or at the beginning of labor.

Procedures: The patient should empty the bladder. The examination is done with the patient in dorsal position. To measure external conjugate ask patient to turn to her right side with flexed right thigh and knee and extended left leg.

Steps: Following pelvic measurements should be taken (Fig. 1):

1. the interspinous diameter– the distance between antero-superior spines of iliac bones, 25-26 cm,
2. the intercrystal diameter – the distance between the furthest points of iliac crests, 27-28 cm,
3. the intertrochanteric diameter – the distance between the greater trochanters of femoral bone, 30-31 cm

4. the external conjugate – the distance between suprasacral fossa beneath the spinous process of L5 and upper edge of symphysis pubis, 20-21 cm

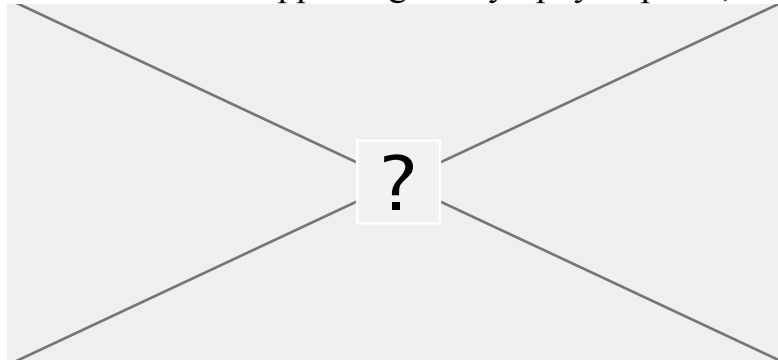


Fig.1: External pelvimetry

Measurement of diagonal conjugate

Time: It is measured clinically during pelvic assessment in late pregnancy or in labor.

Procedures: The patient is to empty the bladder and placed in dorsal position.

Steps: Two fingers are introduced into the vagina taking aseptic precautions. The fingers are to follow the anterior sacral curvature. In normal pelvis, it is difficult to feel the sacral promontory or at best can be felt with difficulty. However, in order to reach the promontory, the elbow and the wrist are to be depressed sufficiently while the fingers are mobilized in upward direction. The point at which the bone recedes from the fingers is the sacral promontory. The fingers are then mobilized under the symphysis pubis and a marking is placed over the gloved index finger by the index finger of the left hand.

The internal fingers are removed and the distance between the marking and the tip of the middle finger gives the measurement of diagonal conjugate. For practical purpose, if the middle finger fails to reach the promontory or touches it with difficulty, it is likely that the conjugate is adequate for an average size head to pass through.

Fig.2: Measurement of diagonal conjugate

Internal pelvimetry

Assessment of the pelvis can be done by bimanual examination.

Time: In vertex presentation, the assessment is done at any time beyond 37th week but better at the beginning of labor. Because of softening of the tissues, assessment can be done effectively during this time.

Procedures: The patient is to empty the bladder. The pelvic examination is done with the patient in dorsal position taking aseptic preparations.

Steps: The internal examination should be gentle, thorough, methodical and purposeful. It should be emphasized that the sterilized gloved fingers once taken out should not be reintroduced.

Sacrum — The sacrum is smooth, well curved and usually inaccessible beyond lower three pieces. The length, breadth and its curvature from above down and side to side are to be noted.

Sacrosciatic notch — The notch is sufficiently wide so that two fingers can be easily placed over the sacrospinous ligament covering the notch. The configuration of the notch denotes the capacity of the posterior segment of the pelvis and the side walls of the lower pelvis.

Ischial spines — Spines are usually smooth (everted) and difficult to palpate. They may be prominent and encroach to the cavity thereby diminishing the available space in the mid pelvis.

Ilio-pectineal lines — To note for any beaking suggestive of narrow fore pelvis (android feature).

Sidewalls — Normally they are not easily palpable by the sweeping fingers unless convergent.

Posterior surface of the symphysis pubis — It normally forms a smooth rounded curve. Presence of angulation or beaking suggests abnormality.

Sacrococcygeal joint — Its mobility and presence of hooked coccyx, if any, are noted.

Pubic arch — Normally, the pubic arch is rounded and should accommodate the palmar aspect of three fingers. Configuration of the arch is more important than pubic angle.

Diagonal conjugate — After the procedure, the fingers are now taken out (see above).

Pubic angle: The inferior pubic rami are defined and in female, the angle roughly corresponds to the fully abducted thumb and index fingers. In narrow angle, it roughly corresponds to the fully abducted middle and index fingers.

Transverse diameter of the outlet (TDO) — It is measured by placing the knuckles of the first interphalangeal joints or knuckles of the clinched fist between the ischial tuberosities.

Anteroposterior diameter of the outlet—The distance between the inferior margin of the symphysis pubis and the skin over the sacrococcygeal joint can be measured either with the method employed for diagonal conjugate or by external calipers.




Fig. 3. Internal pelvimetry

DIAMETERS OF SKULL: The engaging diameter of the fetal skull depends on the degree of flexion present. The anteroposterior diameters of the head which may engage are:

Diameters	Measurement in cm	Attitude of the head	Presentation
1. Suboccipito-bregmatic — extends from the nape of the neck to the center of the bregma	9.5 cm	Complete flexion	Vertex
2. Suboccipito-frontal — extends from the nape of the neck to the anterior end of the anterior fontanelle or center of the sinciput	10 cm	Incomplete flexion	Vertex
3. Occipito-frontal — extends from the occipital eminence to the root of the nose (Glabella)	11,5 cm	Marked deflexion	Vertex
4. Mento-vertical — extends from the midpoint of the chin to the highest point on the sagittal suture	14 cm	Partial extension	Brow

5. Submento-bregmatic — extends from junction of floor of the mouth and neck to the center of the bregma	9.5 cm	Complete extension	Face
--	--------	--------------------	------

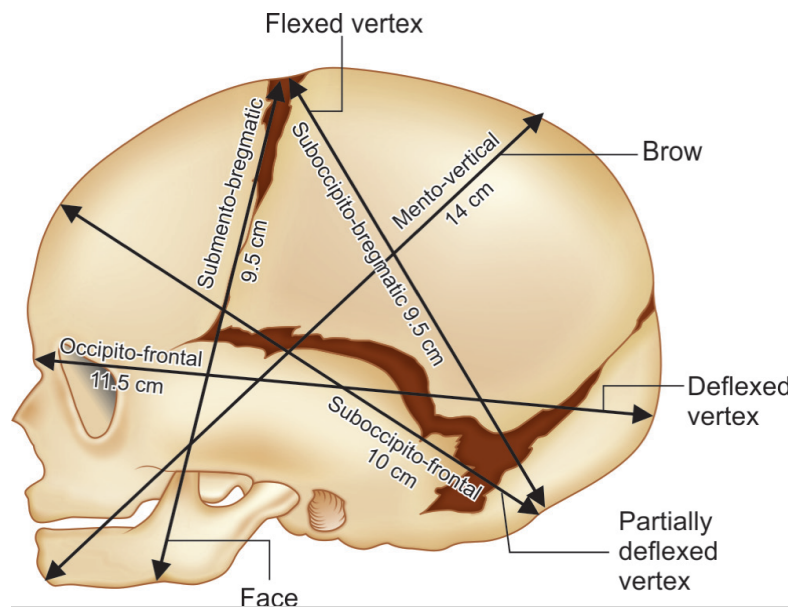


Fig. 4: The important landmarks of fetal skull

MOULDING: It is the alteration of the shape of the forecoming head while passing through the resistant birth passage during labor. There is, however, very little alteration in size of the head, as volume of the content inside the skull is incompressible although small amount of cerebrospinal fluid and blood escape out in the process. During normal delivery, an alteration of 4 mm in skull diameter commonly occurs.

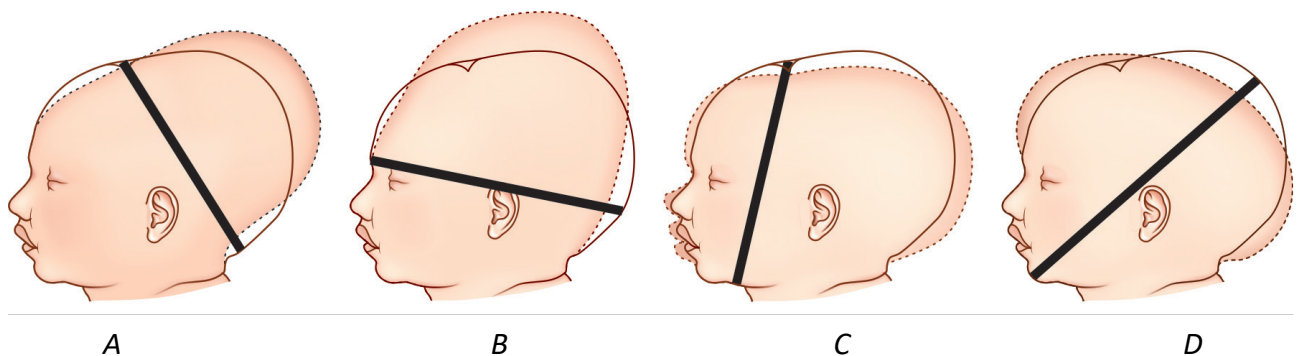


Fig. 5: Types of moulding in cephalic presentations (shown by dotted line: (A) Vertex presentation with well flexed head; (B) Vertex presentation with deflexed head (sugar loaf head); (C) Face presentation; (D) Brow presentation

Grading : There are three gradings. Grade-1 — the bones touching but not overlapping, Grade-2 — overlapping but easily separated and Grade-3 — fixed overlapping.

Importance:

— Slight moulding is inevitable and beneficial. It enables the head to pass more easily, through the birth canal.

- Extreme moulding as met in disproportion may produce severe intracranial disturbance in the form of tearing of tentorium cerebelli or subdural hemorrhage.
- Shape of the moulding can be an useful information about the position of the head occupied in the pelvis.

CAPUT SUCCEDANEUM: It is the formation of swelling due to stagnation of fluid in the layers of the scalp beneath the girdle of contact. The girdle of contact is either bony or the dilating cervix or vulval ring.

The swelling is diffuse, boggy and is not limited by the suture line. It may be confused with cephalhematoma. It disappears spontaneously within 24 hours after birth.

Fig. 6: Formation of caput succedaneum

3.3. Requirements for the results of work.

1. To perform external pelvimetry, measuring of diagonal conjugate, calculation of true conjugate.
2. To assess measurements of the true and the false pelvis,
3. To predict the likelihood of a successful vaginal delivery and make recommendations for management of labor based on their findings,
4. To assess grade and type of moulding in cephalic presentations.
5. To prepare an oral report on the thematic patient.
6. Analysis and discussion of the results of the patient's examination.
7. Multimedia presentation on the topic of the class (review of literature using modern sources; videos, etc.).

3.4. Control materials for the final stage of the class: tasks, tests, etc.

Tests

1. What is the uterine corpus mainly composed of?
 - (A) fibrous tissue
 - (B) estrogen receptors
 - (C) smooth muscle
 - (D) elastic tissue
 - (E) endometrium
2. The levator ani is the major component of the pelvic diaphragm, which is commonly compromised during pregnancy and delivery with resulting prolapse of

uterus, bladder/urethra, and /or rectum. This is especially true if obstetric lacerations are not repaired keeping the normal anatomical relationships in mind. Which of the following is the best description of the levator ani?

- (A) a superficial muscular sling of the pelvis
- (B) a tripartite muscle of the pelvic floor penetrated by the urethra, vagina, and rectum
- (C) is made up of the bulbocavernosus, the ischiocavernosus, and the superficial transverse perineal muscle
- (D) a muscle that abducts the thighs
- (E) is part of the deep transverse perineal muscle

3. Which of the following is the best description of the pelvic diaphragm?

- (A) made up mainly by the coccygeus
- (B) covered on one side by fascia and on the other by peritoneum
- (C) a muscle innervated by L2, L3, and L4
- (D) an extension of the sacrococcygeal ligament
- (E) synonymous with the pelvic floor

4. During delivery, which of the following muscles is most likely to be obviously torn?

- (A) ischiocavernosus muscle
- (B) bulbocavernosus muscle
- (C) superficial transverse perineal muscle
- (D) levator ani muscle
- (E) coccygeus

5. When performing clinical pelvimetry in a normal gynecoid pelvis, the diagonal conjugate should be at least how many centimeters?

- (A) 7.5
- (B) 9.5
- (C) 10.5
- (D) 12.5
- (E) 14.5

6. A newborn is noted to have a darkened swelling of the scalp that does not cross the midline. This is most likely which of the following?

- (A) caput succedaneum
- (B) cephalhematoma
- (C) subarachnoid hemorrhage
- (D) subdural hemorrhage
- (E) moulding

7. In a female, which of the following best describes the urogenital diaphragm?

- (A) includes the fascial covering of the deep transverse perineal muscle
- (B) encloses the ischiorectal fossa
- (C) is synonymous with the pelvic diaphragm
- (D) is located in the anal triangle
- (E) envelops the Bartholin's gland

8. Regarding the female pelvis in comparison with male pelvis, which of the following statements is FALSE?

- (A) Parallel sidewalls and a round inlet
- (B) The bones are comparatively lighter, shorter, less dense, more pliable, and less tightly connected
- (C) The joints are larger and less mobile
- (D) The sacrum is wider and shorter and the pubic arch broader
- (E) The internal diameters are generally 0.5-2.5 cm larger

9. A 153 cm woman has an estimated fetal weight by ultrasound of 4,000 g. To estimate the pelvic capacity, you perform clinical pelvimetry. Which of the following does this procedure measure?

- (A) true conjugate
- (B) transverse diameter of the inlet
- (C) shape of the pubic arch
- (D) flare of the iliac crests
- (E) elasticity of the levator muscles

10. You estimate that the pelvic outlet is adequate, but there may be a problem in the midpelvis. The interspinous diameter of a normal pelvis should be at least how many centimeters?

- (A) 5
- (B) 6–8
- (C) 9–10
- (D) 11-12
- (E) The interspinous diameter is not a clinically important assessment

11. To appreciate how different positioning of the presenting part can impact the second stage of labor, one needs to understand the pelvic axis. During the delivery, the fetal head follows the pelvic axis. What is the best way to describe this axis?

- (A) a straight line in parallel to the vaginal canal
- (B) a curve first directed anteriorly and then caudad
- (C) a curve first directed posteriorly and then caudad
- (D) a curve first directed posteriorly and then cephalad
- (E) a straight line perpendicular to the vaginal canal

12. A 21-year-old G1P0 patient has made it to second stage after a slightly prolonged active phase. She has been pushing effectively for 2 hours without descent from 0 station. As you evaluate for reasons that are preventing descent you check for the positioning of the vertex presentation. This is important since there is great variation in the diameter of the vertex depending on the positioning and in turn the fetal ability to negotiate the pelvic axis and descend in second stage. The greatest diameter of the normal fetal head is which of the following?

- (A) occipito-frontal
- (B) mento-vertical (occipito-mental)
- (C) suboccipito-bregmatic
- (D) bitemporal
- (E) biparietal

Answer key

2.	B	8.	C
3.	E	9.	C
4.	C	10.	C
5.	D	11.	C
6.	B	12.	B

8. SUMMING UP

Assessment of the ongoing learning activity at the practical class:

1. Assessment of the theoretical knowledge on the theme:
 1. methods: individual survey on the theme, participation of the students in the discussion of problem situations; assessment of performance of tests on the theme;
 2. the maximum score – 5, the minimum score – 3, the unsatisfactory score – 2.
2. Assessment of practical skills on the theme:
 1. methods: assessment of the solution of situational tasks (including calculation) on the theme;
 2. the maximum score – 5, the minimum score – 3, the unsatisfactory score – 2.

Assessment of the individual task:

1. Assessment of the quality of the performance of the individual task:
 1. the maximum score – 5, the minimum score – 3, the unsatisfactory score – 2.
2. Assessment of the presentation and defense of an individual task, participation in the assessment of the business plan of the competitors and its critical analysis:
 2. the maximum score – 5, the minimum score – 3, the unsatisfactory score – 2.

The score for one practical class is the arithmetic average of all components and can only have an integer value (5, 4, 3, 2), which is rounded statistically.

Criteria for ongoing assessment at the practical class:

- 5 The student is fluent in the material, takes an active part in the discussion and solution of situational clinical problems, confidently demonstrates practical skills during the examination of a pregnant and interpretation of clinical, laboratory and instrumental studies, expresses his opinion on the topic, demonstrates clinical thinking.
- 4 The student is well versed in the material, participates in the discussion and solution of situational clinical problems, demonstrates practical skills during the examination of a pregnant and interpretation of clinical, laboratory and instrumental studies with some errors, expresses his opinion on the topic, demonstrates clinical thinking.
- 3 The student isn't well versed in material, insecurely participates in the discussion and solution of a situational clinical problem, demonstrates practical skills during the examination of a pregnant and interpretation of clinical, laboratory and instrumental studies with significant errors.

- 2 The student isn't versed in material at all, does not participate in the discussion and solution of the situational clinical problem, does not demonstrate practical skills during the examination of a pregnant and the interpretation of clinical, laboratory and instrumental studies.

RECOMMENDED LITERATURE

Basic:

1. Gladchuk I.Z. Obstetrics: student's book / Gladchuk I.Z., Ancheva I.A. . – Vinnitsia: Nova Knyha, 2021. – 288 p.
2. Obstetrics and Gynecology: in 2 volumes. Volume 1. Obstetrics: textbook / V.I. Gryshchenko, M.O. Shcherbina, B.M. Ventskivskyi et al. (2nd edition). – «Medicina», 2018. – 392 p.
3. Hiralal Konar DC Dutta's Textbook of Obstetrics (9th Ed.) / Hiralal Konar (Ed.). – Jp Medical Ltd, 2018. – 700 p.
4. F. Gary Cunningham Williams Obstetrics (26th Edition) / F. Gary Cunningham, Kenneth Leveno, Jodi Dashe, Barbara Hoffman, Catherine Spong, Brian Casey. – McGraw Hill / Medical, 2022. – 1328 p.
5. Jeremy Oats, Suzanne Abraham Llewellyn-Jones Fundamentals of Obstetrics and Gynaecology (10th Ed) / Jeremy Oats, Suzanne Abraham. – Elsevier, 2016. – 384 p.

Additional:

1. The PROMPT-CIPP Editorial Team. (2019). PROMPT-CIPP Course Participant's Handbook: Care of the Critically Ill Pregnant or Postpartum Woman (Critical Car Prompt Practical Obstetric Multi-professional Training). – Cambridge University Press; 1st edition, 2019. – 136 p.
2. L. A. Magee The FIGO Textbook of Pregnancy Hypertension. An evidence-based guide to monitoring, prevention and management. / L. A. Magee, P. Dadelszen, W. Stones, M. Mathai (Eds). – The Global Library of Women's Medicine, 2016. – 456 p.
3. Edwin Chandrachan Handbook of CTG Interpretation: From Patterns to Physiology / Edwin Chandrachan. – Cambridge University Press; 1st edition, 2017. – 256 p.
4. Louise C. Kenny, Jenny E. Myers Obstetrics by Ten Teachers (20th ed) / Louise C. Kenny, Jenny E. Myers. – CRC Press, 2017. – 342 p.
5. J. Studd Current Progress in Obstetrics and Gynaecology. Vol 4. / J. Studd, Seang Lin Tan, F. Chervenak. – TreeLife Media (A Div of Kothari Medical), 2017. – 419 p.
6. J. Studd Current Progress in Obstetrics and Gynaecology. Vol 5. / J. Studd, Seang Lin Tan, F. Chervenak. – TreeLife Media (A Div of Kothari Medical), 2019. – 403 p.
7. J. Studd Current Progress in Obstetrics and Gynaecology. Vol 6. / J. Studd, Seang Lin Tan, F. Chervenak. – TreeLife Media (A Div of Kothari Medical), 2022. – 309 p.

8. Mark Landon Obstetrics: Normal and Problem Pregnancies, 8th Edition / Mark Landon, Henry Galan, Eric Jauniaux, Deborah Driscoll, Vincenzo Berghella, William Grobman, et al. – Elsevier, 2021. – 1280 pp.
9. Mark B. Landon Gabbe's Obstetrics Essentials: Normal & Problem Pregnancies, 1st Edition / Mark B. Landon, Deborah A. Driscoll, Eric R. M. Jauniaux, Henry L. Galan, William A. Grobman, Vincenzo Berghella. – Elsevier, 2019. – 496 pp.
10. Ian M. Symonds, Sabaratnam Arulkumaran Essential Obstetrics and Gynaecology, 6th Edition / Ian M. Symonds, Sabaratnam Arulkumaran. – Elsevier, 2020. – 480 pp.
11. Myra J. Wick Mayo Clinic Guide to a Healthy Pregnancy, 2nd Edition / Myra J. Wick. – Mayo Clinic Press, 2018. – 520 p.

INTERNET SOURCES:

1. <https://www.cochrane.org/>
2. <https://www.ebcog.org/>
3. <https://www.acog.org/>
4. <https://www.uptodate.com>
5. <https://online.lexi.com/>
6. <https://www.ncbi.nlm.nih.gov/>
7. <https://pubmed.ncbi.nlm.nih.gov/>
8. <https://www.thelancet.com/>
9. <https://www.rcog.org.uk/>
10. <https://www.npwh.org/>