

MINISTRY OF HEALTH OF UKRAINE
ODESA NATIONAL MEDICAL UNIVERSITY

Faculty international

Department of Obstetrics and Gynecology



CONFIRMED by
Vice-rector for scientific and pedagogical work
Eduard BURIACHKIVSKYI
29 August 2024

METHODOLOGICAL RECOMMENDATIONS
FOR THE PRACTICAL LESSON FROM ELECTIVE DISCIPLINE

Faculty international, 5th year

Elective discipline «SIMULATION TRAINING IN OBSTETRICS AND GYNECOLOGY».

Practical lesson No. 6. "Providing manual assistance during physiological childbirth».

Approved

Meeting of the Department of Obstetrics and Gynecology
Odessa National Medical University

Protocol No. 1 of August 29, 2024.

Head of the Department



(Igor GLADCHUK)

Developed by:

Candidate of Medical Sciences, Associate Professor

Candidate of Medical Sciences, Associate Professor

D., assistant


Candidate of Medical Sciences, assistant



Shytova G.V.

Pavlovska O.M.

Tarnovska G.P.



Zhovtenko L.V.

Practical lesson No. 6

"Providing manual assistance during physiological childbirth "

The purpose of the training is to gain basic knowledge of physiological labor management, the mechanism of labor in the occiput anterior presentation.

BASIC CONCEPTS:

Normal physiological labor.

Clinical course and management of physiological labor.

The mechanism of labor in the anterior occiput presentation Amniotomy.

Manual assistance in the 2nd period of labor. Perineotomy and episiotomy.

Active introduction of third period of labor.

Signs of separation of a normally located placenta . Partogram.

EQUIPMENT

- Multimedia equipment (computer, projector, screen), TV
- Midwifery models and obstetric instruments
- Professional algorithms, flowcharts, tables, videos
- Results of laboratory and instrumental studies, case studies, patients, medical histories.

Class time - 4 hours

• ORGANIZATIONAL STAGE

- greeting
- visitor verification
- defining educational goals
- providing positive motivation

- **CONTROL OF BASIC KNOWLEDGE**(written work, written test, online test, face-to-face interview, etc.)

- **Requirements for theoretical readiness of higher education students to perform practical classes.**

Knowledge requirements:

1. Ability to collect medical information about the patient and analyze clinical data
2. Ability to determine the necessary list of laboratory and instrumental tests and evaluate their results
3. Ability to establish a preliminary and clinical diagnosis of the disease
4. Ability to determine the necessary regime of work and rest in the treatment and prevention of diseases
5. Ability to determine the nature of nutrition in the treatment and prevention of diseases
6. Ability to identify the principles of treatment and prevention of diseases
8. Ability to determine the tactics and provide emergency medical care
9. Ability to carry out medical evacuation measures
14. Ability to plan and implement preventive and anti-epidemic measures against infectious diseases

List of didactic units:

- Normal physiological labor.
- The position of the fetus in the uterine cavity.
- Clinical course and management of physiological labor.
- The mechanism of delivery in the anterior occiput presentation
- Amniotomy.
- Manual assistance in the 2nd period of labor.
- Perineotomy and episiotomy.
- Active introduction of the third period of labor.
- Signs of separation of a normally located placenta . Partogram.

- **Questions (quizzes, tasks, clinical situations) to test basic knowledge on the topic of the lesson.**

Question:

- What is a normal (physiological) labor?
- What are the precursors of labor?
- What is regular labor?
- What is the biomechanism of labor?
- What is the leading point in the anterior occiput presentation?
- What is the first moment of the biomechanics of childbirth in the anterior presentation?
- What is the third point of the biomechanics of childbirth in the anterior presentation?
- What is the fourth point of the biomechanics of labor in the anterior occiput presentation?
- What is the biomechanics of shoulder birth?

labor?
10. What are the periods of

11. What are the features of the management of the second stage of labor?

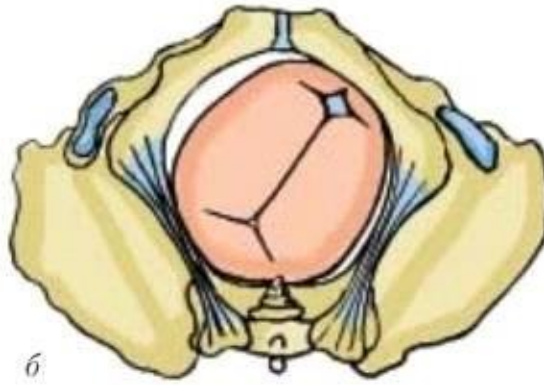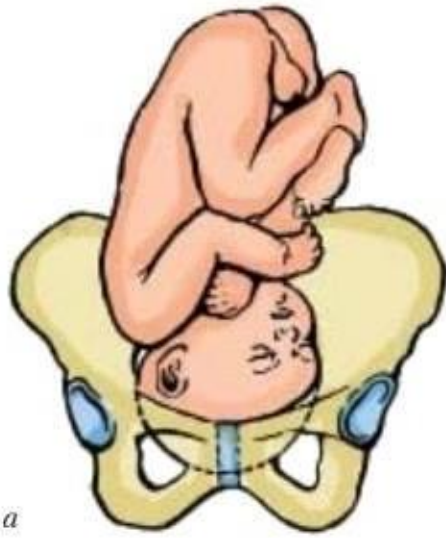
12) What is the characteristic of the third period of labor, its duration?

13) What is the active tactic of managing the third period of labor? 14. What are the mechanisms of placental detachment ?

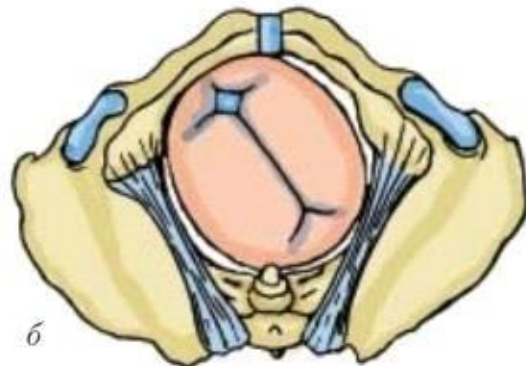
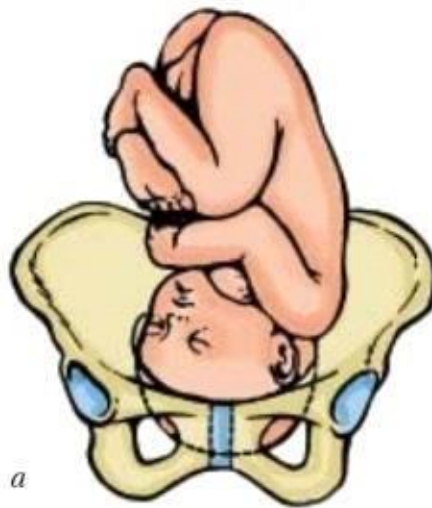
15. What is a partogram?

Objectives.

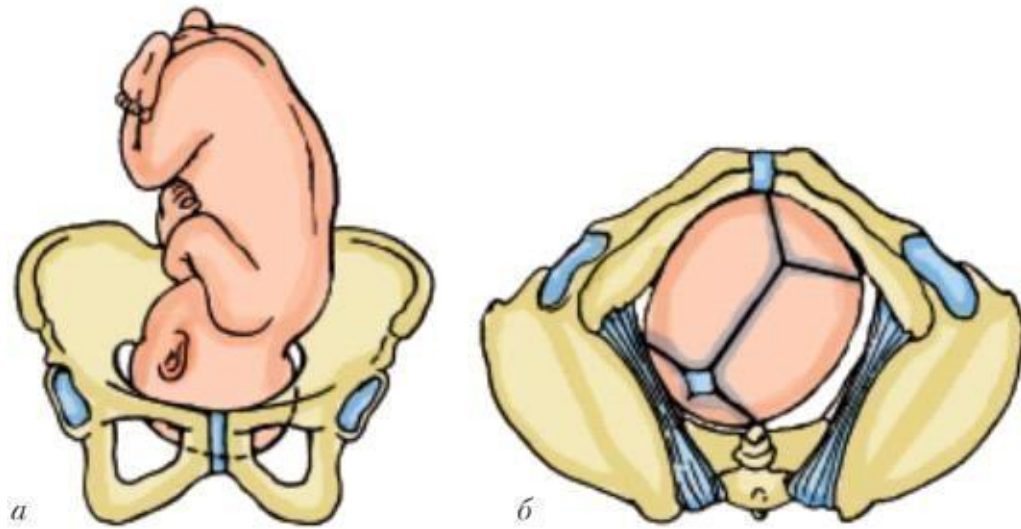
- Determine the position of the fetus in the uterus.



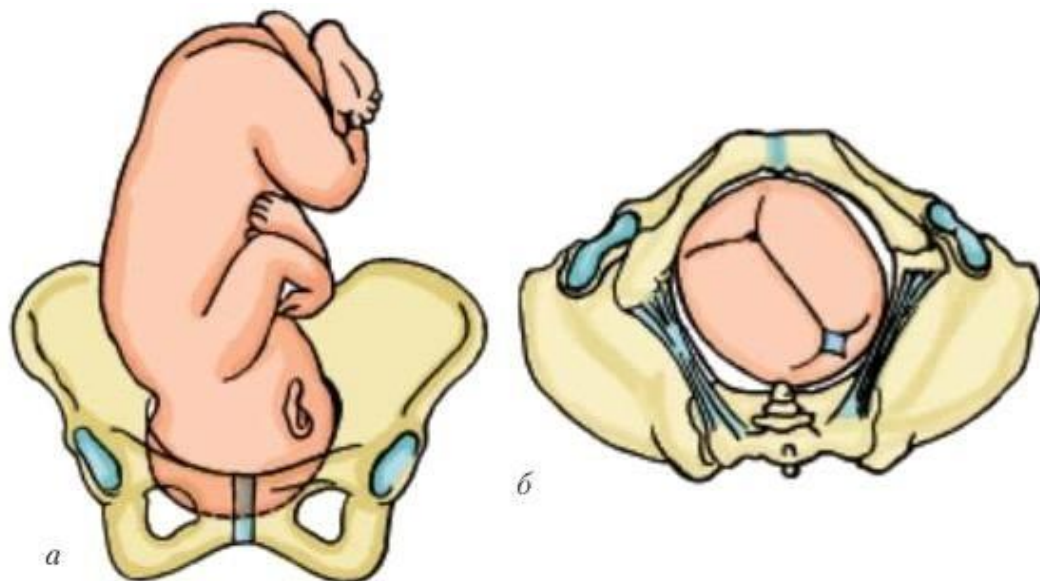
- Determine the position of the fetus in the uterus.



- Determine the orientation of the fetus in the uterus.



- Determine the position of the fetus in the uterus.



- **PROFESSIONAL SKILLS DEVELOPMENT (mastering skills, conducting supervision, determining treatment regimens, conducting laboratory tests, etc.)**

- **Content of the assignments (tasks, clinical situations, etc.). Interactive task:**

The group of higher education applicants is divided into 2 subgroups of 3-4 people each.

Assignments for students of subgroup I:

- Determine the rate of cervical dilatation, period and phase of labor

- Assignments for students of subgroup II:

- evaluate the responses of higher education students of the first subgroup and make adjustments.

Clinical situation A

A 23-year-old first-time pregnant woman was admitted to the maternity hospital with a full-term pregnancy and complaints of contractions that began 4 hours ago. The contractions lasted for 20-25 seconds and repeated every 4-5 minutes. The general condition of the woman in labor is satisfactory. Body temperature is 36.70°C. Blood pressure is 120/80 mm Hg, and her heart rate is 80 beats per minute.

The fetal position is longitudinal, with the back turned to the left half of the uterus, and the head is anterior, located 4 fingers above the symphysis. The fetal heartbeat is clear, rhythmic, at 156 beats per minute.

Internal obstetric examination: the vagina is free, the cervix is smoothed, the margin is thin, and the external os has a diameter of 2 cm. The fetal bladder is intact, the head is present, and the caput is inaccessible. The terminal lines and the inner surface of the symphysis are partially palpable, except for the upper edge.

Question.

- What is the diagnosis?
- Does the rate of cervical dilatation conform to the period and phase of labor?

Clinical situation B

Patient P., in her second delivery at 38 weeks of pregnancy, was admitted to the maternity hospital after 5 hours of regular contractions. Her first delivery was normal two years ago. Her temperature is 36.8°C, blood pressure is 120/80 mm Hg.

The fetal position is longitudinal, in the first position, with the head pressed against the entrance to the small pelvis. The fetal heart rate is 162 beats per minute.

Internal obstetric examination: the vagina is free, the cervix is shortened to 0.5 cm with thick cervical crests, and the pharynx is open by 2.5 cm. The fetal bladder is intact, and the fetal head is located in the first plane of the pelvis.

Questions.

- Diagnosis.
- The duration and name of the first period of labor.
- The mechanism of cervical smoothing and dilatation in this woman in labor. The pattern of cervical opening.
- Anterior and posterior amniotic fluid. When amniotic fluid discharge is considered as “in time”?
- How long is the first period of labor for women who give birth again?
- Does the rate of cervical dilatation conform to period and phase of labor?

Correct answers

Task 1 -

Longitudinal position, head (occipital) presentation, second position, posterior view (a);

View from the pelvic exit - arrowhead suture in the right oblique dimension, small parietal to the right posteriorly (b)

Task 2 -

Longitudinal position, head (occipital) presentation, first position, posterior view (a);

View from the pelvic exit - arrowhead suture in the left oblique dimension, small parietal to the left posteriorly (b)

Task 3 -

Longitudinal position, head (occipital) presentation, first position, front view (a);

View from the pelvic exit - arrowhead suture in the right oblique dimension, small parietal from left to right anterior (b)

Task 4 -

Longitudinal position, head (occipital) presentation, second position, anterior view (a);

View from the pelvic exit - arrowhead suture in left oblique dimension, small parietal fossa to the right anterior (b)

Clinical Situation A

- Pregnancy I, at 39-40 weeks. Longitudinal fetal position, Occiput anterior position, first pregnancy, urgent labor, latent phase of the first period of labor.
- In this woman the rate of cervical dilatation corresponds to the latent phase of the first period of labor. The cervix has taken 4 hours to become smooth, and the uterine os is dilated to 2 cm.

Clinical Situation B

- Second pregnancy, at 38 weeks. Longitudinal fetal position, head presentation, second birth, timely labor, latent phase of the first period of labor.

2. The first period of labor, also known as the period of cervical dilatation, begins with the onset of regular contractions and continues until full cervical dilatation. In the active phase of the first period of labor, the anterior part of the fetus advances. Physiological labor is characterized by the synchronization of cervical dilatation and the advancement of the anterior part.

3. In women who are giving birth again the mechanism of cervical smoothing and dilatation occurs as follows: Cervical smoothing and dilatation take place simultaneously during contractions.

4. The fetus's head descends into the birth canal, touches the lower segment of the uterus from all sides, and pushes it against the entrance to the pelvis forming a sealing ring. This ring separates the amniotic fluid into anterior and posterior compartments during labor. Amniotic fluid is considered to be discharged on time if the rupture of the amniotic sac occurs during the active phase of the first period of labor.

5. The average duration of the first period of labor in women who have previously given birth is 7-9 hours.

6. The rate of cervical dilatation corresponds to the latent phase of the first period of labor.

3.2 Training Materials and Recommendations (Instructions) for Completing Tasks

Normal (physiological) labor refers to labor with spontaneous onset and progressive labor activity in a pregnant woman between 37 and 42 weeks' gestation. The labor is considered normal when the fetus is in an occiput position, and both the mother and newborn are in satisfactory condition after delivery. When labor begins, a pregnant woman is referred to as a laboring woman.

- **Precursors of Childbirth:**
 - Prolapse of the uterine fundus.
 - Increased uterine response to mechanical stimuli.
 - Discharge of the mucus plug from the cervical canal.
 - Weight loss by 1-1.5 kg.
 - Reduction in the amount of amniotic fluid.
 - Engagement of the fetal head in first-time mothers.
- **The preliminary period** is characterized by mild, sporadic cramping pain in the lower abdomen and lower back. These sensations occur against the backdrop of normal uterine tone and can last up to 6-8 hours. During this preliminary phase, the cervix softens, smoothes, and begins to open.

Additionally, there is a deployment of the lower uterine segment and a lowering of the anterior part of the fetus.

Determining the Onset of Labor

Contractions are involuntary contractions of the uterine muscles. The intervals between contractions are referred to as pauses.

Regular labor is characterized by the presence of 1-2 or more uterine contractions within 10 minutes, each lasting 20 seconds or more, leading to structural changes in the cervix, including smoothing and opening.

A woman's biological readiness for childbirth is assessed by the degree of cervical maturity, which includes the following factors:

- Consistency of the cervix
- Length of its vaginal part
- Patency of the cervical canal
- Position of the cervix in relation to the pelvic axis
- Condition of the external os (opening of the cervix)
- Location of the anterior part of the fetus

Assessment of the degree of cervical "maturity" according to the Bishop scale

Feature.	Degree of "maturity"		
	0 points	1 point	2 points
Position	Back	Ahead	Middle

Length	>2	1-2	<1
Consistency of the cervix	Dense	Softened	Soft
Condition of the outer eye (cm)	Closed	Open by 1cm	Open by >2cm

Location of the underlying part	Movable above the entrance to the pelvis	Pressed against	Pressed or fixed at the entrance to the pelvis
---------------------------------	--	-----------------	--

- 0-2 points indicate an "immature" cervix.
- 3-5 points suggest a cervix that is "not mature enough."
- 6 points indicate a "mature" cervix.

Physiology of Childbirth

Labour is typically divided into three periods:

- **The First Period** - Cervical Dilation
- **The Second Period** - Fetal Delivery
- **The Third Period** - Postpartum

When labor begins, a pregnant woman is referred to as a woman in labor.

The first period of labor can be further divided into two consecutive phases:

- **Latent Phase:** This phase spans from the onset of regular contractions until the cervix is dilated to 3 cm in first-time mothers or 4 cm in subsequent births. The latent phase usually lasts approximately 6-8 hours for first-time mothers and 4-5 hours for those who have given birth before.
- **Active Phase:** This phase begins when cervical dilatation is at 3-4 cm and continues until it reaches full dilation at 10 cm. In the active phase, the typical rate of cervical dilatation considered normal is 1 cm per hour, both for first-time and repeat mothers. **The active phase can be further divided into three sub-phases:**
 - **Acceleration:** In first-time mothers, this phase lasts up to 2 hours, while for repeat mothers, it lasts up to 1 hour.
 - **Maximum Dilation:** This phase has the same duration as the acceleration phase, depending on whether it's the mother's first delivery or a subsequent one.
 - **Deceleration:** In first-time mothers, the deceleration phase lasts 1-2 hours, whereas for repeat mothers, it lasts 0.5-1 hour.

The first period of labor is defined from the onset of regular contractions, which are uncontrollable rhythmic contractions of the uterine muscle, until full cervical dilation of 10 cm.

Regular labor is a contractile activity characterized by 2-5 contractions in 10 minutes, leading to structural changes in the cervix, including smoothing and opening.

Uterine activity can be determined by palpating the uterus for 10 minutes. The presence of 2 or more uterine contractions within 10 minutes, each lasting 20 seconds or more, is considered a sign of labor.

The assessment of the effectiveness of contractions is based on their strength, duration, and frequency, as well as the cervical dilatation in the dynamics and signs of head advancement relative to the plane of entry into the pelvis.

During the active phase of the first period of labor, the effective contractile activity of the uterus should exhibit the following characteristics: 3-4 contractions in 10 minutes, each lasting more than 40 seconds.

Nevertheless, the most objective criterion for assessing the effectiveness of labor in the first stage is cervical dilatation.

The second period, also known as the period of expulsion, extends from the moment of full cervical dilatation until the birth of the child. It's crucial to differentiate between the early phase of the second period, which ranges from full dilatation to the commencement of pushing, and the active phase, which encompasses the actual pushing phase.

Key concepts of the second period of labor include:

- **Contractions:** These are rhythmic combinations of contractions involving the uterine muscles, abdominal muscles, diaphragm, and pelvic floor.

Glans insertion - the appearance of the glans from the vulvar ring only during thrusting;

Glans eruption - the glans remains in the vulvar ring after the cessation of the thrust.

The maximum allowable duration of the second period for women giving birth for the first time and those who have given birth previously is 2 and 1 hour, respectively, without epidural anesthesia, and 3 and 2 hours with epidural anesthesia.

Most of this time is spent in the early phase, during which the head gradually progresses through the birth canal to the pelvic floor, initially without active pushing. Subsequently, pushing gradually emerges and intensifies with each contraction. It's important not to compel a woman to push during the early phase. Organizing pushing during this phase, provided fetal and maternal conditions are normal, can lead to fatigue, disruption of the internal rotation of the fetal head, trauma to the birth canal, fetal head, fetal cardiac issues, and unnecessary medical interventions.

Full (spontaneous and active) intense pushing typically occurs only when the head reaches the pelvic floor, marking the active phase.

The third period, (**postpartum period**) spans from the birth of the fetus until the placenta separates from the membranes. If there are no signs of bleeding, this period should not exceed 30 minutes.

Mechanisms of Normal Placental Detachment

- The separation of the placenta from the center, resulting in the formation of a retroplacental hematoma and the fetal surface emerging outward, is referred to as the Schultze mechanism.

Центральне відділення плаценти (варіант Шульце): ретроплацентарна гематома	Відділення плаценти з краю (варіант Дункана)
	

- When the placenta detaches from the edge instead of the center, this detachment mechanism is known as Duncan's.

The integrity of the afterbirth is assessed visually. Blood loss during the postpartum period, which amounts to 0.5% of the laboring woman's weight but does not exceed 500 ml, is considered physiological. The only objective method for quantifying blood loss is through measurement.

Active management of the third period of labor:

The implementation of active management of the third period of labor during each delivery can reduce the incidence of postpartum bleeding caused by uterine atony by 60%, in addition to decreasing postpartum blood loss and the need for blood transfusion.

Standard components of active management of the third period of labor include:

- Administration of uterotonics.
- Controlled traction of the umbilical cord to deliver the placenta while supporting the uterus manually.
- Uterine massage through the anterior abdominal wall after the delivery of the placenta.

Guidelines for administering uterotonics: within the first minute after the birth of the child, palpate the uterus to rule out the presence of a second fetus. If there is no second fetus, administer 10 U of oxytocin intramuscularly. Oxytocin is the preferred uterotonic, as its effects become evident within 2-3 minutes, and it can be used in all women.

If oxytocin is not available, 0.2 mg of ergometrine can be used intramuscularly. Ensure that the woman is informed about the potential side effects of these drugs.

Do not use ergometrine in women with pre-eclampsia, eclampsia, or hypertension.

Controlled traction of the umbilical cord involves the following steps:

- - Clamp the umbilical cord closer to the perineum with a clamp and hold the clamped umbilical cord and clamp in one hand.
- -Place the other hand directly over the woman's pubis and hold the uterus away from the womb.
- -Gently pull the umbilical cord and wait for a strong uterine contraction (typically 2-3 minutes after oxytocin administration).
- -Simultaneously with a strong contraction of the uterus, encourage the woman to push and gently pull the umbilical cord downward (traction) to deliver the placenta, while maintaining counter-traction with the other hand in the opposite direction to the traction (pushing the uterus away from the womb).

If the placenta does not descend (i.e., is not born) within 30-40 seconds of controlled traction, stop the traction on the umbilical cord but continue to gently hold it in slight tension. The other hand should remain above the womb, holding the uterus. Wait for a strong uterine contraction before repeating the controlled traction of the umbilical cord with counter-traction on the uterus. Never pull up on the umbilical cord without using counter-traction on the well-contracted uterus above the womb, as traction without a uterine contraction can lead to uterine prolapse.

After the birth of the placenta, hold it with both hands, gently turn it, twist the membranes, and slowly pull the placenta down to complete the labor.

In case of ruptured membranes, carefully examine the vagina and cervix with sterile gloves. If membranes are found, use a window clamp to remove any remaining debris.

Examine the placenta thoroughly to ensure its integrity. If a section of the maternal surface is missing or there is a section of torn membranes with blood vessels, there is reason to suspect placental abruption, and appropriate measures should be taken.

Uterine massage: After the delivery of the placenta, immediately massage the uterus through the woman's anterior abdominal wall until it becomes firm. Subsequently, palpate the uterus every 15 minutes for the first 2 hours to ensure that it remains firm. If necessary, repeat the massage.

If signs of placental abruption are present, the woman should be encouraged to push, which may lead to the delivery of the placenta.

Signs of placental abruption include:

- **Schroeder's sign:** The bottom of the uterus rises and is located above and to the right of the navel, resulting in an hourglass shape when the placenta has separated and descended into the lower segment or vagina.
- **Chukalov-Küstner sign:** When pressing the palm's edge on the suprapubic area during placental separation, the uterus rises, and the umbilical cord does not retract into the vagina.
- **Alfeld's sign:** The ligature on the umbilical cord, located at the woman's labia, descends 8-10 cm below the Boulevard ring during placental separation.
- **Dovzhenko's sign:** A woman is asked to breathe deeply, and if the umbilical cord does not retract into the vagina as she exhales, the placenta has separated.
- **Klein's sign:** The woman in labor is asked to push, and if the umbilical cord does not retract into the vagina, the placenta has separated.

External methods are employed to remove the separated placenta.

Abuladze's method involves the following steps:

- 1. After emptying the bladder, grasp the anterior abdominal wall with both hands, creating a fold to firmly hold the rectus abdominis muscles.
- 2. Subsequently, instruct the woman in labor to push. The placenta is easily delivered as a result of the significant reduction in the volume of the abdominal cavity.

The Krede-Nazarovich method is performed in the following sequence:

- 1)Begin by emptying the bladder.

- 2) Position the bottom of the uterus in the midline.
- 3) Gently stroke the uterus to reduce its size.
- 4) Wrap the uterine floor with your hand so that the palm's surface, with four fingers, is against the posterior wall of the uterus, and the thumb rests on the anterior wall (as shown in Fig. 34).
- 5) Simultaneously, apply pressure to the uterus with the entire hand in two directions: use your fingers to press from front to back and your palm to press from top to bottom toward the pubis until the afterbirth is expelled from the vagina.

If there are no signs of placental abruption or external bleeding within 30 minutes after the birth of the fetus, manual separation and removal of the afterbirth is performed.

In the presence of bleeding, manual separation and removal of the placenta should be carried out immediately under adequate anesthesia.

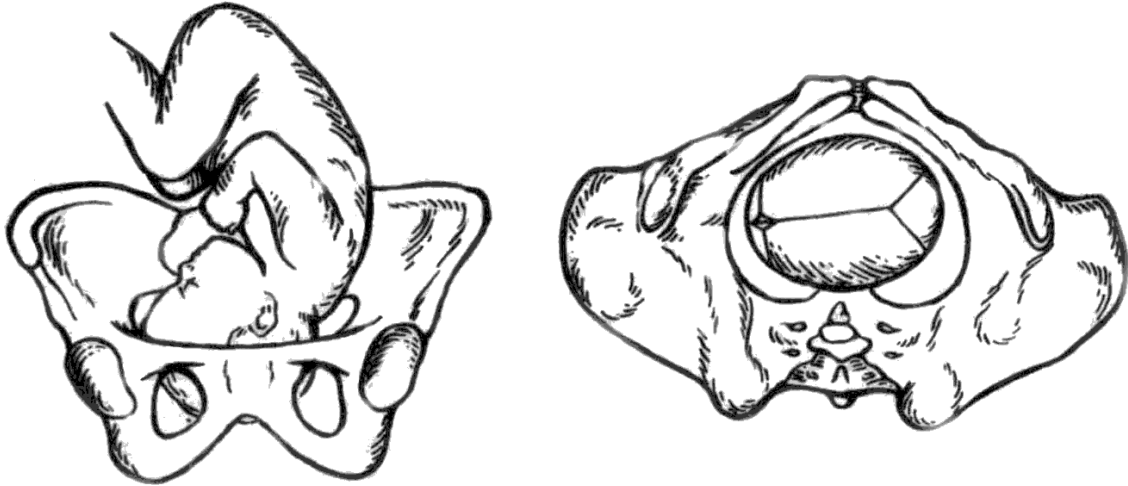
Once the placenta is isolated, it is essential to thoroughly examine it to ensure the integrity of both the placenta and membranes.

Examination of the birth canal after delivery, using vaginal mirrors, is only performed in the presence of bleeding, after surgical vaginal delivery, or when the physician is uncertain about the condition of the birth canal (such as in cases of rapid delivery or deliveries that occur outside of the hospital).

Biomechanics of Childbirth in the Anterior Presentation

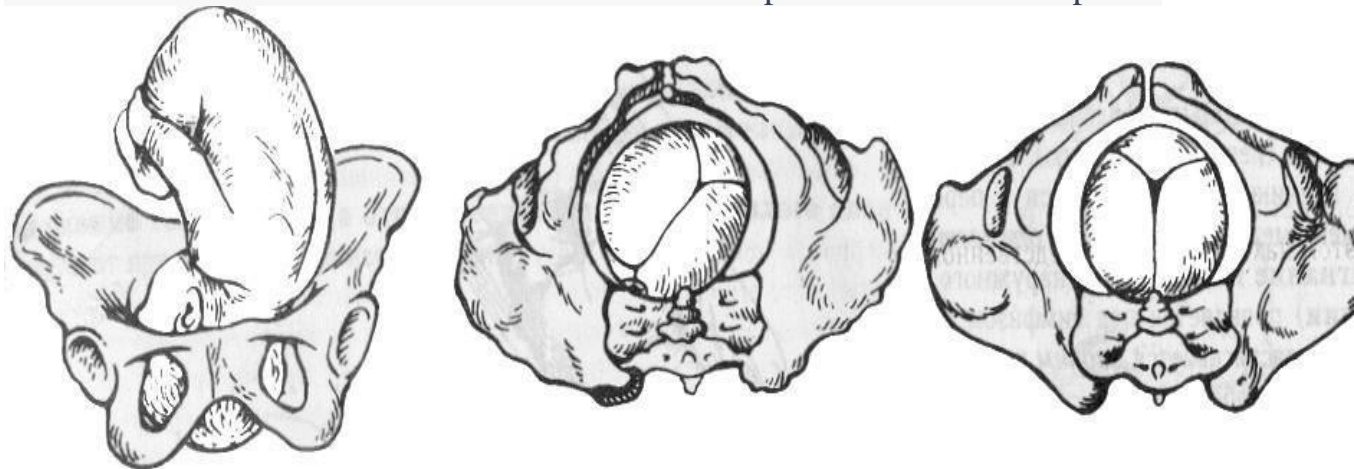
The biomechanism of labor in the anterior presentation comprises four key aspects.

The first step involves flexing the fetal head and lowering it to align with the plane of entry into the pelvis.



This represents the rotation of the head around its transverse axis. Consequently, with the flexion of the head, the smaller fontanelle moves to the lower pole of the anterior part, approaching the leading edge of the pelvis and becoming the "leading point." This head flexion allows the smallest circumference to pass through the pelvis, which corresponds to the small oblique dimension and measures approximately 32 cm.

The second aspect involves the internal rotation of the head as it traverses from the wider to the narrower part of the pelvis



- During this stage, the head slowly rotates around its axis, positioning the back of the head towards the symphysis pubis and the face towards the sacrum. As part of this process, the sagittal suture gradually changes its orientation, shifting from a transverse position to an oblique one, and then

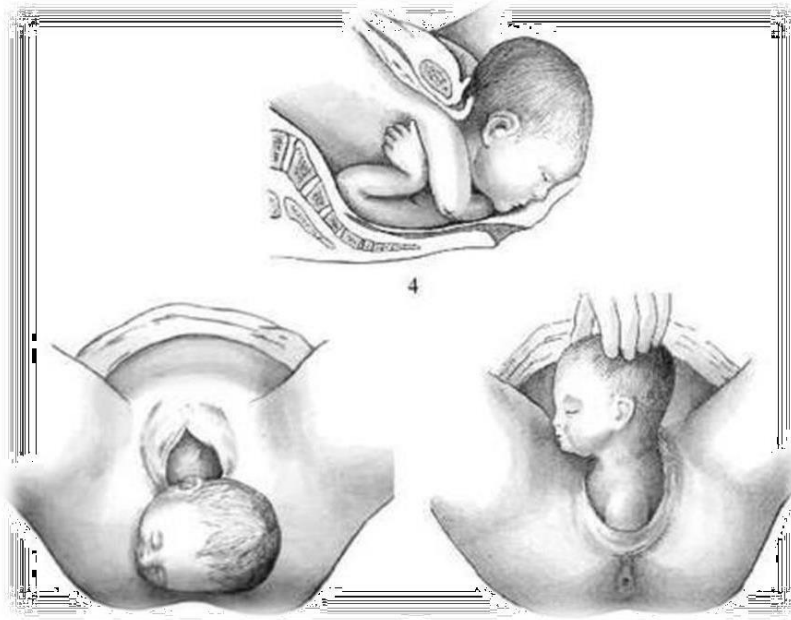
from oblique to a straight alignment as it proceeds through the pelvic outlet. This alteration in the position of the sagittal suture occurs due to the left oblique dimension of the pelvis.

The third aspect involves the extension of the head within the pelvic outlet.



The sagittal suture aligns with the straight dimension of the pelvic outlet. The fixation point forms between the midpoint of the lower edge of the pubic symphysis and the occipital fossa. Around this point, the head extends, and clinically, this is accompanied by the emergence of the forehead, face, and chin during childbirth.

The fourth aspect involves the internal rotation of the shoulders and the external rotation of the head.



As the head descends and emerges, the trunk moves towards the pelvis, with the transverse dimension of the shoulders aligning with one of the oblique dimensions of the pelvic entrance. Upon reaching the pelvic floor, the shoulders undergo an internal rotation, similar to that of the fetal head. Once this rotation is completed, the shoulders are positioned in the straight dimension within the pelvic exit plane. This rotation of the shoulders is then transferred to the head, constituting the fourth step in the biomechanism of labor.

The head rotates to face the mother's thigh: in the first position - to the right, for the second position - to the left.

ASSESSMENT OF LABOR PROGRESS

To assess the progress of labor, the following factors are determined:

1. Rate of Cervical Dilatation: This is assessed through an internal obstetric examination conducted every 4 hours.

An additional internal examination is carried out if indicated:

- Spontaneous rupture of fetal membranes.
- Abnormal fetal heart rate (less than 110 or more than 170 beats per minute).
- Prolapse of the umbilical cord.
- Suspected malpresentation or fetal head malposition.
- Delayed labor progress.
- Cases of bleeding (examination in the operating room).

2. Frequency and Duration of Contractions

3. Presence of Fetal Head Advancement into the Pelvic Cavity

External Methods of Assessing Cervical Dilatation:

The degree of cervical dilatation can only be estimated approximately using external methods. During labor, it is roughly assessed by the height of the contractile ring, which represents the boundary between the contractile muscle and the stretching lower segment of the uterus. Typically, the cervix dilates during labor by an amount roughly equivalent to the width of the transverse fingers of the contractile ring positioned above the pubic arch.

Internal Methods for Assessing Cervical Dilatation:

In order to determine the dynamics of cervical dilatation and the position of the fetal head during labor, internal obstetric examinations are conducted:

- Upon the woman's admission to the maternity ward.
- Every 4 hours during the first stage of labor.
- After the rupture of amniotic fluid (for the timely diagnosis of possible umbilical cord prolapse and small fetal parts in the amniotic fluid).
- Additional internal obstetric examinations in the first stage of labor are allowed only if indicated due to the increased risk of ascending infection of the birth canal.

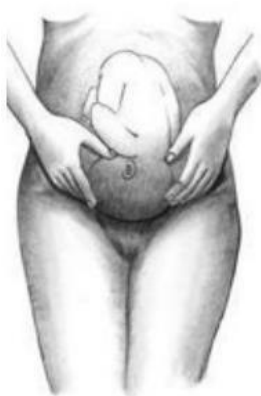Additional Internal Examinations in the First Stage of Labor May Be Performed If Indicated:

- Every 4 hours during the first stage of labor and every hour during the second stage.

- After the rupture of the amniotic membrane.
- In cases of a pathological fetal heart rate (less than 100 or more than 180 beats per minute) to investigate reasons that might explain signs of fetal distress.
- If there is umbilical cord prolapse from the vagina.
- In cases of multiple pregnancies after the birth of the first fetus.
- When the fetus is in an incorrect position or if the fetal head is suspected to be poorly positioned at the entrance to the pelvis in extension, to clarify the obstetric situation.
- In instances of delayed progress of labor due to ineffective uterine contractions.
- Before amniotomy and prior to oxytocin stimulation.
- When early delivery is required due to severe pre-eclampsia, antenatal fetal death, or other pathologies.
- When making a decision on operative vaginal delivery (e.g., obstetric forceps, vacuum extraction, or pelvic extraction of the fetus).
- In cases of bleeding after 22 weeks of pregnancy (conducted in the operating room).

Assessing the Degree of Head Engagement Using External Methods

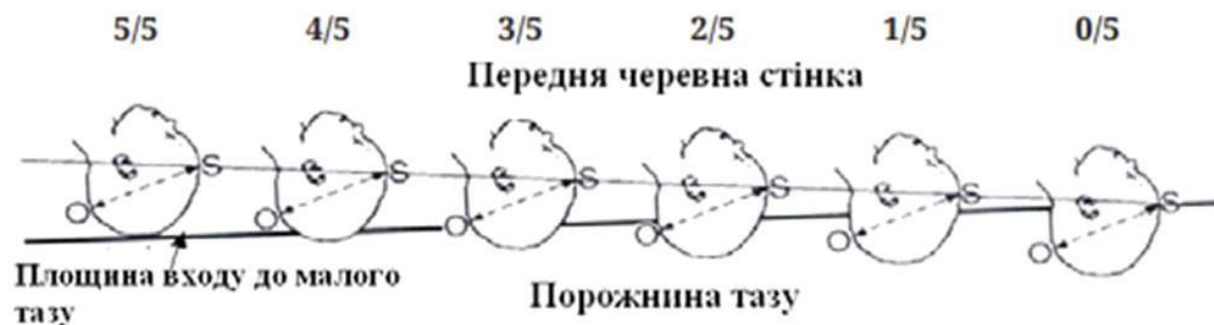The degree of head engagement can be determined using the IV Leopold technique.



Positioning and Assessing the Fetal Head Using External Methods

The doctor stands to the right, facing the pregnant woman's legs. Palms of both hands are placed on the lower segment of the uterus, one on the right and one on the left, with fingertips reaching the symphysis pubis. This technique allows for the determination of whether the fetal head is located above the entrance to the pelvis or has descended through the plane of the pelvic inlet or a significant segment.

An alternative method is abdominal palpation, which assesses the height of the fetal head based on the number of finger-widths above the symphysis:



- **5/5** the fetal head is positioned 5 finger-widths above the symphysis, signifying that the fetal head is above the entrance to the pelvis.
- **4/5** width of 4 fingers implies the head is pressing against the pelvic entrance.
- **3/5** width of 3 fingers suggests that the head with a small segment is in the entrance to the pelvis.
- **2/5** width of 2 fingers indicates the head along with a large segment, is in the pelvic entrance.
- **1/5 to 0/5** width of 1 finger implies that the head is situated within the pelvic cavity.

External palpation of the fetal head should be conducted immediately before performing an internal obstetric examination. This helps prevent errors in determining the head's position in cases of significant edema in the anterior part of the fetal head.

Assessment of the Degree of Head Engagement by Internal Obstetric Examination

- ***Head Above the Pelvic Entrance:*** The pelvis is free, the head is positioned high and doesn't obstruct the palpation of the pelvic line and the caput. The sagittal suture is transverse and equidistant from the symphysis and the caput, with both the large and small parietal bones at the same level.
- ***Head with a Small Segment in the Pelvic Entrance:*** The sacrum is free, and the caput can be reached with a bent finger (if accessible). The internal surface of the symphysis is accessible for examination. The small parietal is lower than the large parietal, and the sagittal suture is slightly oblique.
- ***Head with a Large Segment in the Pelvic Entrance:*** The head occupies the upper third of the symphysis and the sacrum. The caput is inaccessible, but the ischial spines are easily palpable. The head is curved, the small parietal is lower than the large parietal, and the sagittal suture is in one of the oblique dimensions.
- ***Head in the Wide Part of the Pelvis:*** The caput has passed the plane of the broad part of the pelvis, with the greatest circumference. Two-thirds of the inner surface of the pubic symphysis and the upper half of the sacrum are occupied by the caput. The fourth and fifth sacral vertebrae and ischial spines are palpable. The sagittal suture is in one of the oblique dimensions, and the small parietal is lower than the large parietal.
- ***Head in the Narrow Part of the Pelvis:*** The upper two-thirds of the sacrum and the entire inner surface of the pubic symphysis are occupied by the head. The ischial spines are challenging to reach. The head is close to the pelvic floor, and its internal rotation is not yet complete. The sagittal suture is in one of the oblique dimensions, close to the straight one, with the small parietal lower than the large parietal.
- ***Head at the Pelvic Outlet:*** The sacral fossa is completely filled with the head, and the ischial spines are not detectable. The sagittal suture is in the direct dimension of the pelvic exit, with the small fontanelle lower than the large fontanelle. The position of the fetal head during internal examination can also be determined in relation to the level of the ischial bones (position "0"). The "-" sign indicates the head is above the ischial bones (closer to the

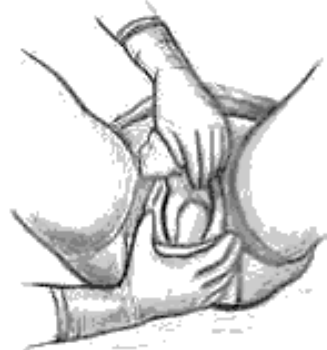
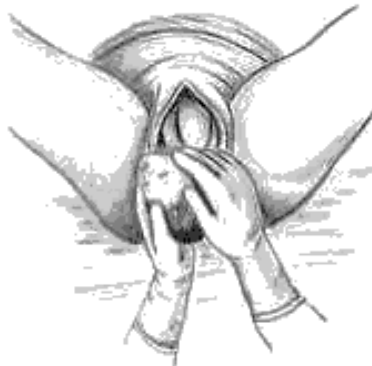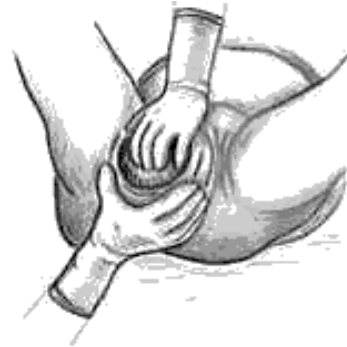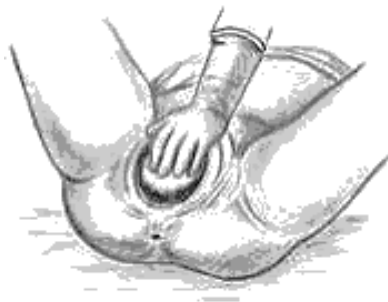pelvic entrance), while the '+' sign means the fetal head is located below the ischial bones (closer to the pelvic exit).

The head position is determined as follows:

- H: Head above the pelvic entrance.
- 2: Head pressed against the entrance to the pelvis.
- 1: Head with a small segment at the entrance to the pelvis.
- 0: Head with a large segment at the entrance to the pelvis.
- +1: Head in the broad part of the pelvis.
- +2: Head in the narrow part of the pelvis.
- +3: Head at the exit from the pelvis.

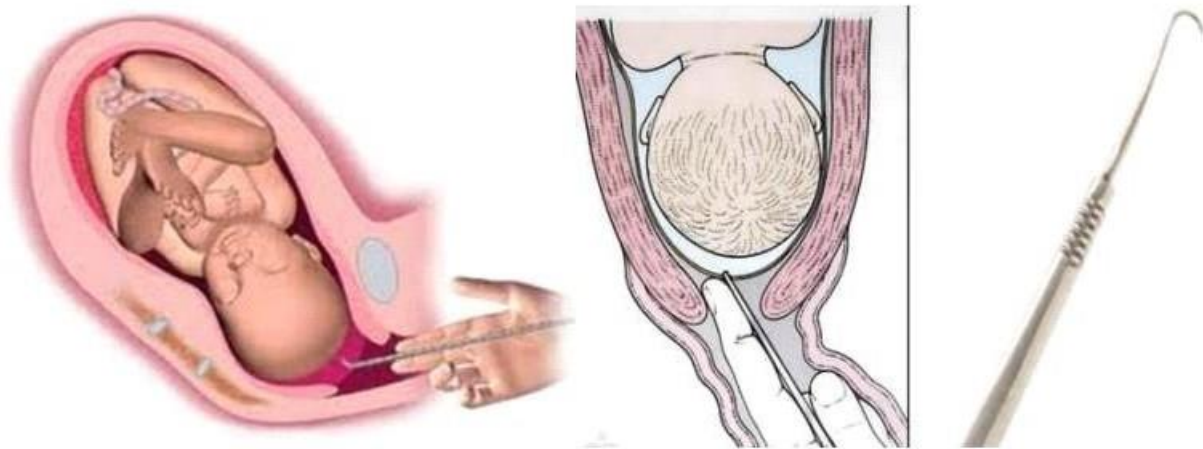
The delivery of the fetal head requires careful manual assistance, aimed at preserving not only the integrity of the woman's perineum but also preventing intracranial, spinal, and other fetal injuries.

Perineal Protection consists of five techniques:



- Preventing premature extension of the fetal head: The palm of the left hand rests on the pubis, and the fingers gently restrain the rapid advancement of the head by applying pressure.
- Reducing tension in the perineal tissue: The palm surface of the right hand is placed on the perineum, and the fingers shift the tissue of the labia majora toward the perineum to alleviate tension.
- Clearing the fetal head from the labia: After the fixation point is established, use gentle outward force to move the side edges of the vulvar ring away from the head, allowing it to unfold.
- Assisting with the internal rotation of the shoulders and external rotation of the head: Grasp the newborn's head with both hands so that the palms rest on the area of the ears. Gently pull the head downward until the anterior shoulder comes under the pubic arch.
- Releasing the shoulder girdle: Use the left hand to grasp the head and pull it back towards the womb. Simultaneously, use the right hand to carefully free the perineal tissue from the posterior shoulder.

Amniotomy is a procedure used to induce and regulate labor activity.



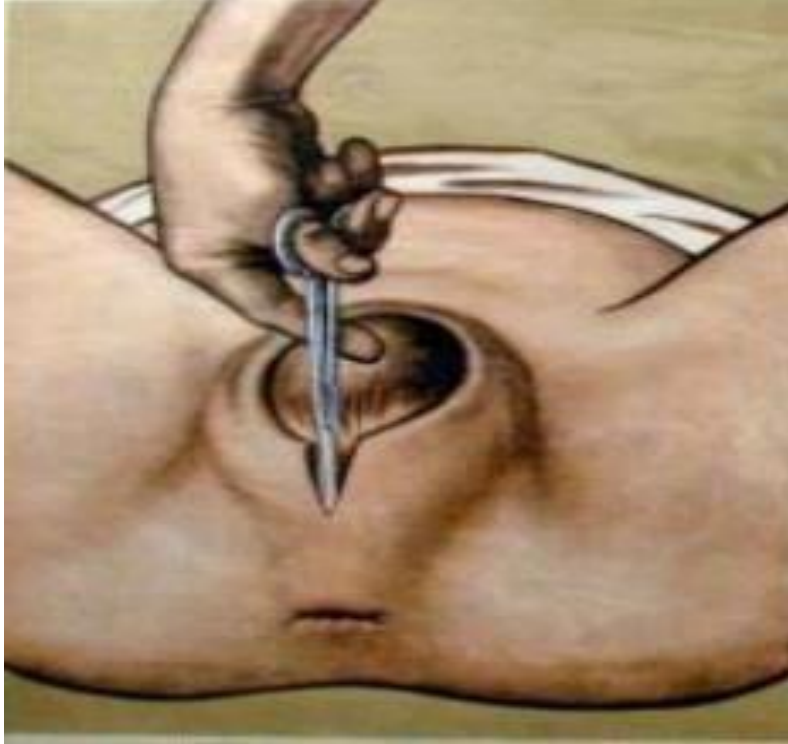Method:

- 1. Antiseptic Treatment of the External Genitalia: Begin by performing antiseptic treatment of the external genitalia of a pregnant or postpartum woman.

- 2. Intra-Obstetric Examination: Conduct an intra-obstetric examination to determine the presence of amniotic fluid and assess its tension.
- 3. Insert the Amniotomy Hook: Gently insert the amniotomy hook into the vagina, positioning it in a way that the tip of the instrument reaches the amniotic fluid.
- 4. Rotate the Instrument: Rotate the instrument around its axis, ensuring that the sharp part of the hook engages the amniotic membrane.
- 5. Break the Membrane: Carefully break the amniotic membrane.
- 6. Dilate the Opening: Use the middle and index fingers to dilate the opening by gently separating the amniotic membrane from the anterior part.
- 7. Assess the Amniotic Fluid: Evaluate the quantity and quality of the amniotic fluid.
- 8. Confirm Proper Positioning: Ensure that the anterior part is pressed against the plane of entry into the pelvis and verify that no umbilical cord loops are detected in front of the anterior part.

Perineotomy and Episiotomy - aimed at avoiding perineal tears and traumatic brain injury during childbirth.

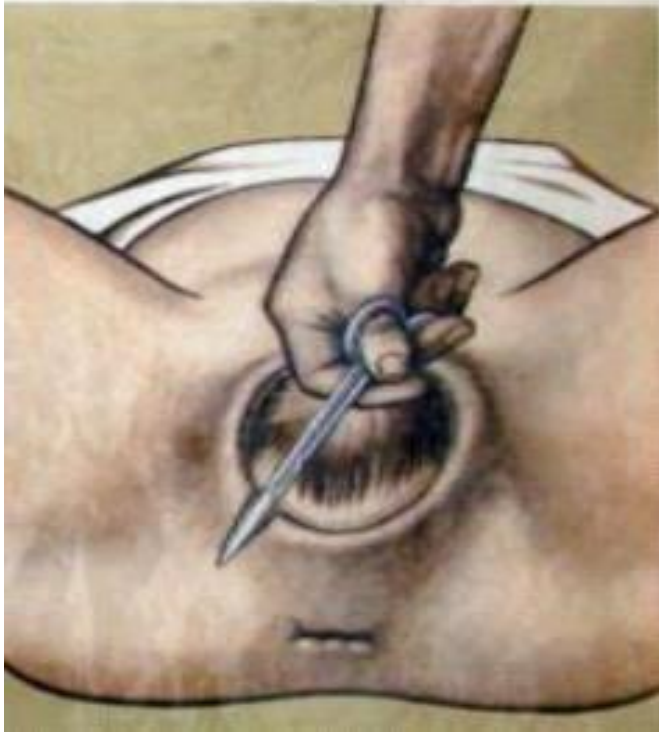Perineotomy: The incision is made along the midline of the perineum, where there are fewer vessels and nerve endings. This incision dissects through the skin, subcutaneous fat, posterior vaginal wall, fascia, bulbocavernosus muscle, and superficial and deep transverse perineal muscles.



Methodology:

- After treating the external genitalia, insert the scissors blade behind the posterior vaginal wall.
- Make a 1.5-2 cm incision in the perineum, starting from the posterior vaginal wall and extending toward the anus.

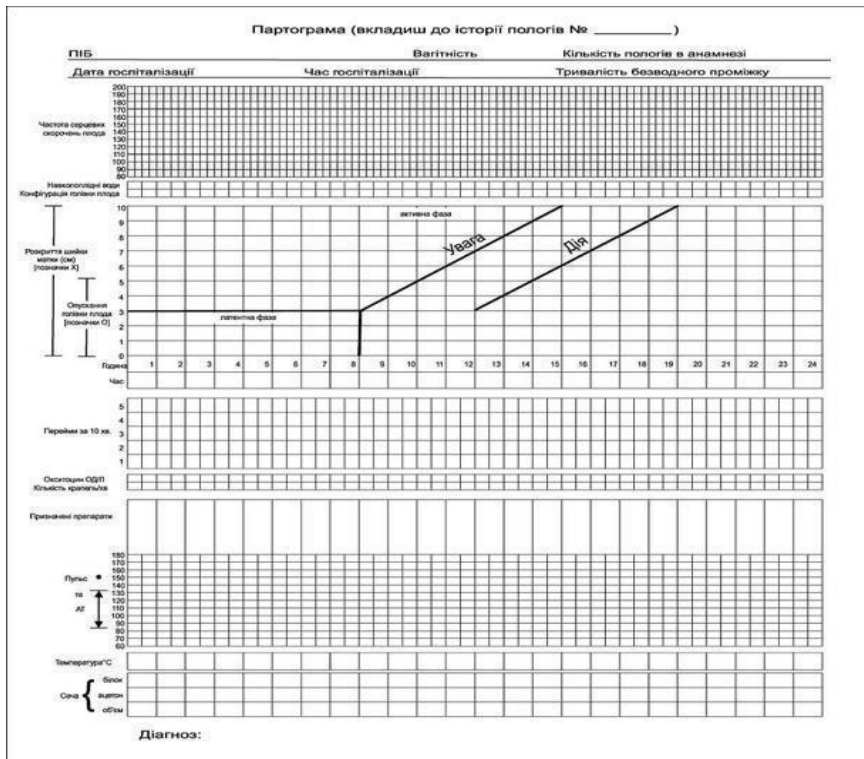
Episiotomy: An incision is made on one side, extending through the labia majora toward the ischial tuberosity.

**Method:**

- After treating the external genitalia, move the scissors upward along the posterior vaginal wall by 2 cm.
- Make a 1.5-2 cm long incision in the perineum, extending from the labia to the ischial tuberosity.

Features of Maintaining a Partogram:

Observation of the first stage of labor and monitoring the condition of the mother and fetus is carried out using a partogram, which graphically displays the following indicators on a time axis:



The

- course of childbirth:
 - Degree of cervical dilatation determined by internal obstetric examination (performed every 4 hours)
 - Fetal head descent determined by abdominal palpation (performed every 4 hours)
 - Frequency (per 10 minutes) and duration (in seconds) of contractions (measured every 30 minutes)
- The condition of the fetus:
 - Fetal heart rate, assessed by auscultation or handheld Doppler (monitored every 15 minutes)
 - Degree of fetal head engagement (assessed every 4 hours)
 - Condition of the amniotic sac and amniotic fluid (evaluated every 4 hours)
- The condition of the woman in labor:
 - Pulse and blood pressure (checked every 2 hours)
 - Temperature (monitored every 4 hours)
 - Urine: volume; presence of protein or acetone, as indicated (measured every 4 hours)

Advantages of the Partogram:

- Effective monitoring of labor
- Timely detection of deviations from the normal course of labor
- Assisting in making necessary and appropriate interventions.

Performance Requirements:

- -Assess cervical dilatation and fetal head descent.
- -Perform an amniotomy.
- -Understand the biomechanics of delivery in the anterior presentation.
- -Understand the biomechanics of delivery in the posterior breech position.
- -Provide manual assistance in the second stage of labor.
- -Perform perineotomy and episiotomy.
- -Implement active management of the third stage of labor.
- -Recognize the signs of normal placental separation and assess placental integrity.
- -Perform a postpartum examination of the birth canal.
- -Know how to complete a partogram.

Control Materials for the Final Stage of the Class: tasks, tests, etc.

Objectives:

A 26-year-old woman in labor, S., was admitted to the maternity hospital with active labor activity and gave birth to a live full-term boy weighing 3000 g and measuring 50 cm in height within 3 hours. Fifteen minutes after the birth, the baby started bleeding, and the blood loss amounted to 120 ml, which is ongoing.

Data on the signs of placental separation:

- The clamp applied to the umbilical cord near the labia has dropped by 10 cm.
- The uterus is flat, narrow, the fundus has risen above the navel, and it has deviated to the right.
- The umbilical cord does not retract into the vagina during deep breaths.

- The umbilical cord lengthened during pushing and did not shorten at the end of the push.
- The umbilical cord does not retract into the vagina when pressed with the edge of the hand on the abdomen.
- The umbilical veins do not fill when pressed on the uterus.

The Correct Answer:

- This is the on-time first stage of labor.
- The placenta has detached from the uterine wall.
- Numerical indications of signs of placental separation: 2-1-4-5-3-6.
- To remove the detached membranes from the uterine cavity, the woman in labor should be asked to push. If there is no effect, the following methods of placental removal should be used in the following order: Abuladze, Krede-Nazarovich, Guenther, and manual removal.
- Abuladze's method of afterbirth extraction: After urination, place the uterus in a central position, massage it to promote reduction, and then grasp the anterior abdominal wall in a large longitudinal fold with both hands. Suggest that the woman in labor push to assist in afterbirth extraction.

IN SUMMARY

Current control methods include oral questioning, testing, assessment of practical skills, solving situational clinical problems, and evaluating classroom activity.

1	<ul style="list-style-type: none"> • The applicant for higher education demonstrates a comprehensive understanding of the material. • Actively participates in discussions and the solution of situational clinical problems. • Confidently demonstrates practical skills during the examination of a pregnant woman and in interpreting the results of clinical, laboratory, and instrumental studies. • Expresses their own well-informed opinion on the topic. • Demonstrates strong clinical thinking.
---	---

2	<ul style="list-style-type: none"> • he applicant for higher education has a solid grasp of the material. • Actively participates in discussions and the solution of situational clinical problems. • Demonstrates practical skills during the examination of a pregnant woman and in interpreting the results of clinical, laboratory, and instrumental studies with some minor mistakes. • Expresses their opinion on the topic. • Demonstrates good clinical thinking.
3	<ul style="list-style-type: none"> • The applicant for higher education has some knowledge of the material but may lack depth. • Participation in discussions and solving situational clinical problems may be uncertain. • Demonstrates practical skills during the examination of a pregnant woman and interpretation of results of clinical, laboratory, and instrumental studies with significant errors.
4	<ul style="list-style-type: none"> • The student does not possess the necessary knowledge of the material. • Does not participate in discussions or the solution of situational clinical problems. • Fails to demonstrate practical skills during the examination of a pregnant woman or interpretation of the results of clinical, laboratory, and instrumental studies.

RECOMMENDED READING

Basic:

- Zaporozhan V.M., Mishchenko V.P. Obstetrics and Gynaecology in 2 books: Book 1: Obstetrics, 2007. - 373 c.
- "Williams' Manual of Obstetrics (24th edition) F. G. Cunningham, K. J. Leveno, S. L. Bloom, C. Y. Spong, J. S. Dashe, B. L. Hoffman, B. M.

Casey, J. S. Sheffield, McGraw-Hill Education/Medical. - 2014. - 1377 pp.

- Textbook of Gynaecology (6th edition) Dutta DS, Hiralal Konar (eds). - JAYPEE BROTHERS MEDICAL PUBLISHERS (P) LTD, 2013. - 702 c.
- Dutta DS Textbook of Obstetrics including Perinatology and Contraception (8th ed.) Dutta DS, Hiralal Konar (eds.). - JAYPEE BROTHERS MEDICAL PUBLISHERS (P) LTD, 2015. - 782 c.
- Llewellyn-Jones Fundamentals of Obstetrics and Gynaecology (10th edition). Jeremy Oates, Suzanne Abraham. Elsevier. 2016. - 384 c.
- FIGO textbook "Hypertension in pregnancy. An evidence-based guide to monitoring, prevention and treatment. L. A. Magee, P. Dadd, W. Stones, M. Mathai (eds.), Global Library of Women's Medicine. - 2016. - 456 c.
- The Mayo Clinic Guide to Healthy Pregnancy. Roger W. Harms (ed.). Rosetta Books, 2011. - 612 pages.
- Best practices in labour and delivery / edited by Richard Warren, S. Arulkumaran. Cambridge University Press. - 2009. - 362 c.
- Basic Sciences in Obstetrics and Gynaecology / edited by Philip Bennett, Katherine Williamson. 4th edition. 2010, Churchill Livingstone Elsevier. - 386 pages. Additionally:
- Maternal and Fetal Medicine. Creasy R.K., Resnick R. - 2009. - 1296 c.
- Gibbs RS, Karlan BJ, Haney AF, Nigam IE Danforth's Obstetrics and Gynaecology (10th ed.) - Lippincott Williams & Wilkins. - 2008. - 2225 c.
- CTG Made Easy / edited by Susan Gage, Christine Henderson. 3rd edition, 2009 - Elsevier Churchill Livingstone. - 280 pages.
- Obstetrics: Normal and Problematic Pregnancy, 7th edition by S. Gabbe, J. R. Nihil, J. L. Simpson, M. B. Landon, H. L. Galan, E. R. M. Jongeau, D. A. Driscoll, V. Bergella, and W. A. Grobman, Elsevier. - 2017. - 1320 c.
- Midwifery from Ten Teachers (20th edition) by Louise K. Kenny, Jenny E. Myers. - CRC Press. - 2017. - 342 c.
- Modern progress in obstetrics and gynaecology. Vol. 4. Eds. J. Studd, Seang Lin Tan, F. Chervenak. - 2017. - 419 c.
- Recent advances in obstetrics and gynaecology. Vol. 26. W. Ledger, J. Clark. - JP Medical. - 2015. - 230 c.

- Proactive labour support. Ruwer P., Bruins H., Franks A. - 2015. - 216 c.

INTERNET SOURCES:

- <https://www.cochrane.org/>
- <https://www.ebcog.org/>
- <https://www.acog.org/>
- <https://www.uptodate.com>
- <https://online.lexi.com/>
- <https://www.ncbi.nlm.nih.gov/>
- <https://pubmed.ncbi.nlm.nih.gov/>
- <https://www.thelancet.com/>
- <https://www.rcog.org.uk/>
- <https://www.npwh.org>