

# **PART VII**

---

## **DENTAL ANATOMY, HISTOLOGY, AND OCCLUSION**

Knowledge of the characteristics of maxillary versus mandibular teeth, permanent versus primaries, and unusual characteristics of individual teeth is essential clinically, as well as on the NBDE exam.

### GENERAL CHARACTERISTICS AND NOTES OF MAXILLARY VERSUS MANDIBULAR TEETH

- A. All teeth are wider faciolingually than mesiodistally except for:
1. Maxillary central and lateral incisors
  2. Mandibular 1st, 2nd, 3rd molars
- B. Anterior maxillary teeth are wider in a mesiodistal direction than their counterparts in the mandibular arch.
- C. Mandibular molars are wider in a mesiodistal direction than maxillary molars.
- D. Maxillary molars are wider in a faciolingual direction than mandibular molars.
- E. Premolars all have single roots, except for maxillary 1st premolar, which has two roots.
- F. Molars:
1. Maxillary molars—3 roots; 2 facial, 1 lingual (palatal)
  2. Mandibular molars—2 roots; 1 mesial, 1 distal
- G. Maxillary posteriors—Occlusal tables more centered in a faciolingual direction, centered over the root trunk; buccal and lingual cusps equally displaced from midline in faciolingual direction; from the occlusal, equal amounts of buccal and lingual surfaces can be seen.

**Mandibular posteriors**—Occlusal table is somewhat lingually displaced, the buccal cusp being more towards the middle of the tooth in the faciolingual direction and the lingual cusp almost in line with the lingual

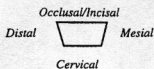
profile of the root. In the arch the mandibular posteriors are lingually inclined. When viewed from the occlusal surface, more buccal surface (up to 2/3) than lingual surface can be seen.

- H. **Maxillary posteriors**—Buccal height of the contour is low, and lingual height of the contour is relatively high on the crown.
- I. **Smallest tooth**—Mandibular central incisor
- J. **Longest tooth**—Maxillary canine

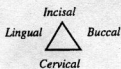
### FUNDAMENTAL GEOMETRIC SHAPES OF CROWNS

#### A. Axial views

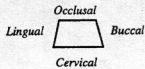
1. All teeth are fundamentally **trapezoidal** when viewed facially or lingually. The long side of **trapezoid** becomes occlusal or incisal, and short side cervical.
2. **Incisors and canine**, when viewed from **mesial or distal**, are **triangular** in shape.
3. **Maxillary posteriors**, when viewed from **mesial or distal**, are fundamentally **trapezoidal** with the long side on the cervical.
4. **Mandibular posteriors**, when viewed from **mesial or distal**, are **rhomboidal**, with the lingual-occlusal and the buccal-cervical angles being acute.
5. Illustrations of the above are shown below.



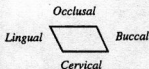
1. **Facial or Lingual View of All Teeth**



2. **Mesial or Distal View of Anterior Teeth**



3. **Mesial or Distal View of Maxillary Posterior Teeth**



4. **Mesial or Distal View of Mandibular Posterior Teeth**

Figure 1-1.

## B. Occlusal views

Table 1-1.

Maxillary	Crown Profile	Occlusal Table
1st premolar	hexagonal	trapezoidal
2nd premolar	diamond (ovoid)	rectangular
First molar	rhomboid	rectangular
Second molar	rhomboid	rectangular
Third molar	heart	rectangular

Table 1-2.

Mandibular	Crown Profile	Occlusal Table
1st premolar	hexagonal	trapezoidal
2nd premolar	diamond (ovoid)	rectangular
First molar	rhomboid	rectangular
Second molar	rhomboid	rectangular
Third molar	heart	rectangular

**HEIGHTS OF CONTOURS—General Points**

- A. Generally the **mesial height** of contour is more incisal or occlusal than the distal, except for the mandibular central incisor, premolars, and possibly the molars.
- B. The **lingual height** of contour of the mandibular posteriors is much more occlusal than that of the maxillary posteriors.
- C. The **facial height** of contour of the maxillary posteriors is generally more occlusal than that of the mandibular posteriors.
- D. The **facial and lingual heights** of contour generally have a convexity of approximately 0.5 mm, except for the lingual of the mandibular posteriors, where it may measure up to 1.0 mm.

**NOTE**

*Knowing heights of contour is an aid in understanding contact relationships as well.*

**HEIGHTS OF CONTOURS**

Table 1-3.

<b>Maxillary</b>				
	<b>Lingual</b>	<b>Facial</b>	<b>Mesial</b>	<b>Distal</b>
<b>Central incisor</b>	Cervical 1/3	Cervical 1/3	Incisal 1/3	Junc. of middle & incisal 1/3s
<b>Lateral incisor</b>	Cervical 1/3	Cervical 1/3	Junc. of middle & incisal 1/3	Middle 1/3
<b>Canine</b>	Cervical 1/3	Cervical 1/3	Junc. of middle & incisal 1/3	Junc. of middle & occlusal 1/3
<b>First premolar</b>	Junc. of cervical & middle 1/3	Cervical 1/3	Junc. of middle & occlusal 1/3	Junc. of middle & occlusal 1/3
<b>Second premolar</b>	Junc. of cervical & middle 1/3	Cervical 1/3	Junc. of middle & occlusal 1/3	Junc. of middle & occlusal 1/3
<b>First molar</b>	Junc. of cervical & middle 1/3	Cervical 1/3	Junc. of middle & occlusal 1/3	Middle 1/3
<b>Second molar</b>	Junc. of cervical & middle 1/3	Cervical 1/3	Middle 1/3	Middle 1/3
<b>Third molar</b>	Junc. of cervical & middle 1/3	Cervical 1/3	Middle 1/3	Middle 1/3
<b>Mandibular</b>				
	<b>Lingual</b>	<b>Facial</b>	<b>Mesial</b>	<b>Distal</b>
<b>Central incisor</b>	Cervical 1/3	Cervical 1/3	Incisal 1/3	Incisal 1/3
<b>Lateral incisor</b>	Cervical 1/3	Cervical 1/3	Incisal 1/3	Incisal 1/3
<b>Canine</b>	Cervical 1/3	Cervical 1/3	Incisal 1/3	Junc. of middle & incisal 1/3
<b>First premolar</b>	Junc. of cervical & middle 1/3	Cervical 1/3	Junc. of middle & occlusal 1/3	Junc. of middle & occlusal 1/3
<b>Second premolar</b>	Middle 1/3	Cervical 1/3	Junc. of middle & occlusal 1/3	Junc. of middle & occlusal 1/3
<b>First molar</b>	Middle 1/3	Cervical 1/3	Junc. of middle & occlusal 1/3	Middle 1/3
<b>Second molar</b>	Middle 1/3	Cervical 1/3	Middle 1/3	Middle 1/3
<b>Third molar</b>	Middle 1/3	Cervical 1/3	Middle 1/3	Middle 1/3

## CONTACT AREAS (CA)

- A. Are **influenced** by the size, form, and alignment of the teeth.
- B. **Function to**
1. Stabilize the arch
  2. Prevent food impaction between the teeth
  3. Protect the interproximal gingival tissues
- C. **Incisal/occlusal-gingival placement** is at the mesial and distal heights of contour; generally the mesial CA is more occlusal or incisal than the distal, except for the **mandibular central incisor**, premolars, and possibly the molars.
- D. **Faciolingual placement:** Anterior teeth are centered faciolingually; in posterior teeth, placement may be more facial, in the buccal 1/3.

## EMBRASURES

- A. **Defined as the gap between two adjacent teeth, as the teeth curve away from the contact area.** The embrasure form is dependent upon the size, shape, and form of the teeth. There are four embrasures per contact area: lingual, facial, incisal/occlusal, and gingival.
- B. **Functions of the embrasure:**
1. Act as spillways for food, etc., from the occlusal surfaces
  2. Make the teeth more self-cleansing
- C. **Notes on embrasures:**
1. Maxillary anteriors: The lingual is greater than facial.
  2. Mandibular anteriors: The facial is greater than lingual.
  3. Posteriors: Generally, lingual is greater than the facial (except maxillary molars).
  4. The incisal/occlusal embrasure is smaller than the gingival.
  5. The incisal embrasure may be missing between the mandibular central incisors due to the high placement of the mesial contact areas.

## CERVICAL LINE CURVATURES

- A. The junction of enamel and cementum is called the **CEJ** or cervical line, with the mesial curvature being greater. This curvature gets less distinct as you go toward the posterior. The molar's CEJ is relatively straight.
- B. **Facial and lingual cervical lines** curve toward the root apex, usually fairly equally, except for mandibular central and lateral incisors, where the lingual curvature is greater.

### NOTE

*Adequate contact between restorations promotes the health of both gingival and periodontal tissues. Poor contact can manifest in follow-up visits as inflamed gingiva, bleeding, and increased loss of bone.*

**NOTE:** The greatest curvature of cervical line is on the mesial surface, and the greatest mesial CEJ curvature of all teeth is on the maxillary central incisor (approximately 3.5 mm).

### **GENERAL CONSIDERATIONS OF THE PULP:**

---

- A. Pulp cavity can be broken down into **pulp chambers** and **pulp canals**.
- B. **Pulp chamber**—generally in the crown portion of the tooth. It is a singular chamber in all teeth and extends into the root trunk, generally 1–2 mm below the cervical line. The chamber outline follows the outline of the tooth.
- C. **Pulp horns** are projections of the pulp chamber into the major cusps of the teeth; pulp horns are also found in the **mamelons** of the **maxillary incisors** when the teeth are young.

### **GENERAL CHARACTERISTICS OF ROOTS**

---

- A. **Single rooted teeth:** All anteriors, maxillary second premolar, mandibular first and second premolar
- B. **Two rooted teeth:** Maxillary first premolars, mandibular molars
- C. **Three rooted teeth:** Maxillary molars
- D. **Most roots** generally have one canal **except** for the following teeth, which have two canals:
  - 1. Maxillary first premolar regardless of whether it has one or two roots
  - 2. Maxillary second premolar
  - 3. Maxillary molars (mesiobuccal root)
  - 4. Mandibular central incisor (occasionally)
  - 5. Mandibular lateral incisor (occasionally)
  - 6. Mandibular canine (occasionally)
  - 7. Mandibular first premolar (occasionally)
  - 8. Mandibular second premolar (rarely)
  - 9. Mandibular molars (mesial root)

## E. Frequently asked root cross-sections:

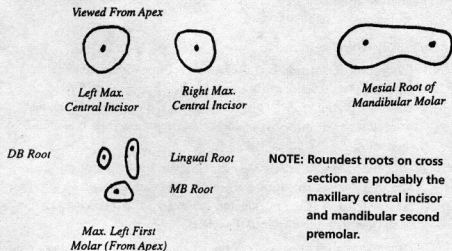


Figure 1-2.

**NOTE**

Root shape is crucial when extracting teeth. Teeth with rounded single roots can be rotated, for example, while double rooted teeth cannot. Forceps are designed to fit the particular common root types.

**INCISORS****A. Maxillary incisors vs. mandibular incisors**

1. Maxillary incisors are larger than the mandibular incisors.
2. Maxillary incisors have wider mesiodistal than labiolingual diameter.
3. Mandibular incisors have wider labiolingual than mesiodistal diameter.
4. Maxillary incisors have more distinct lingual anatomy.
5. Maxillary incisors may have lingual pits not found on mandibular incisors.
6. Maxillary incisors have rounder roots on cross-section.
7. All incisors **except** the mandibular central have rounder distoincisoral angles than mesioincisoral angles (mandibular central is symmetric).
8. Mandibular incisor's incisal edge is lingual to labiolingual midpoint.
9. Maxillary incisor's incisal edge is centered labiolingually.
10. Facial embrasure is greater than lingual embrasure in mandibular incisors.
11. Lingual embrasure is greater than facial embrasure in maxillary incisors.
12. Heights of contour are more incisal on mandibular incisors.
13. Mandibular incisor's labial surface is straighter and flatter than maxillary incisor's.
14. Smallest tooth: mandibular central incisor.
15. Bilaterally symmetric: mandibular central incisor.



16. Most distinct lingual anatomy: maxillary lateral incisor.
17. Incisal edge not perpendicular to labiolingual bisecting line: mandibular lateral incisor.

**B. Maxillary central incisor**

1. **Widest incisor** mesiodistally, wider mesiodistally than labiolingually. The **facial or labial surface** has lobulated appearance. The surface itself is a gradual convex surface to the incisal edge. The **incisal edge is straight with three mammelons**, and placed on the labiolingual midpoint.
2. The mesial contour is relatively straight with the height of contour at the incisal edge. The distal is more rounded with a height of contour at the junction of the middle and incisal 1/3s. The **mesioincisal angle is sharper than the distoincisal angle**.
3. The **lingual surface** has distinct **mesial and distal marginal ridges, lingual fossa and cingulum** and may have **lingual pit**. The lingual height of contour is low on the cingulum area in the cervical 1/3 of the tooth.
4. The **root is conical, straight, and round on cross-section** (may show a little convergence toward the lingual with the mesial being longer than the distal).

Max. R  
Central Incisor




Figure 1-3.

**NOTE**

The maxillary lateral incisor is the most variable of teeth, ranging from absent, to peg-shape, to normal incisor shape. Its lingual surface can be flat, bulbous, or deeply pitted. It is the incisor most likely to need a lingual restoration.

**C. Maxillary lateral incisor**

1. **Characterized by its roundness** of the distoincisal and mesioincisal angles.
2. Wider mesiodistally than labiolingually.
3. The labial or facial surface may be lobulated and slightly convex.
4. The mesial contour is convex with a height of contour at the junction of the middle and incisal 1/3s. The **distal is more convex with a height of contour in the middle 1/3 of the crown**.
5. The **distoincisal angle is more rounded than the mesioincisal angle**.
6. Lingual surface has very distinct lingual anatomy, mesial and distal marginal ridges, cingulum, lingual fossa, and central pit. (Anatomy may be more distinct than maxillary central incisor.)

- Incisal edge may have mammelons and is placed in the labiolingual midpoint.
- Root may be more ovoid than central but is still comparatively round.

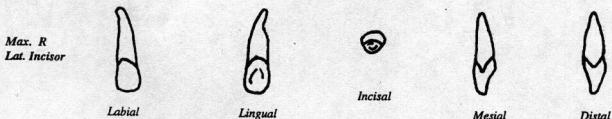


Figure 1-4.

Table 1-4.

Maxillary central incisor	Maxillary lateral incisor
Crown: Not as rounded as lateral	Crown: Characterized by its roundness; slightly more round on mesioincisal and distinctly so on the distoincisal angles.
Distinct lingual anatomy	More distinct lingual anatomy
Round root on cross section	Ovoid root on cross-section
More distinct mammelons on the incisal edge.	Mammelons may be present only on newly erupted tooth.

#### D. Mandibular central incisor

- Narrowest of all teeth, bilaterally symmetric**, and forming almost 90° angles with the incisal edge; **mesial and distal profiles mirror one another** being straight; height of contour at incisal edge.
- The facial surface is flat.
- The lingual surface has very **indistinct lingual anatomy**.
- The **incisal edge is lingual to the labiolingual midpoint** and the edge is **perpendicular to a line dividing the tooth labiolingually**.
- Root is very ovoid on cross-section and wider labiolingually than mesiodistally.**

#### NOTE

*The mandibular central is the most symmetrical of all teeth.*

*R Mand.  
Central Incisor*




Figure 1-5.

**E. Mandibular lateral incisor**

1. Very similar to mandibular central incisor except in the following ways:
  - a. Wider mesiodistally than central and not bilaterally symmetric.
  - b. The mesial contour is **straight with a height of contour at the incisal edge**. The distal contour is **more convex with a more rounded disto-incisal angle**. The distal height of contour is in the incisal 1/3.
  - c. Lingual anatomy again is indistinct.
  - d. The **incisal edge is lingual to the labiolingual midpoint** of the crown, but the edge itself is not at **right angles** to a line bisecting the crown. However, it follows the arch curvature, making the distal end more lingually placed.
  - e. The root itself is very ovoid, being wider labiolingually than mesiodistally, and may have mesial and distal depressions.

*Max. R  
Lat. Incisor*



Figure 1-6.

Table 1-5.

Mandibular Central Incisor	Mandibular Lateral Incisor
Smallest tooth	Not as small as central
Bilaterally symmetric	Not symmetric
Mirror mesial and distal axial surfaces	Disto-incisal angle more round than sharp mesio-incisal angle
Incisal edge is perpendicular to a labiolingual bisecting line	Incisal edge not perpendicular to a labiolingual bisecting line.

## CANINES

### A. Maxillary canine

1. **Longest tooth in the mouth** is long and pointed, with **buccal cusp tip centered** in mesiodistal diameter. The incisal edge consists of the buccal cusp tip and the mesial and distal ridges. The **incisal edge is generally centered over the tooth labiolingually**.
2. The mesial incisal angle is sharper or less round than the distoincisor angle. The **buccal surface** is marked by a **3-lobed appearance** with a prominent middle or central lobe running from the cusp tip to the cervical line. The height of contour on the buccal is at or about the junction of the middle and cervical 1/3.
3. The mesial contour is only slightly convex and may be flat to concave in the cervical 1/3 with a height of contour almost at the incisal edge at the junction of the middle and incisal 1/3s. The **distal contour is very bulbous or convex**, with a height of contour in the middle of the crown.
4. The **lingual anatomy is very distinct with prominent distal and mesial marginal ridges, lingual cingulum, and a lingual ridge** running from the cusp tip to the cingulum which divides the lingual fossa into a distal and mesial fossa. **Lingual pit** may be found. The lingual height of contour is low in the cingulum near the cervical line.
5. The **root** is characterized by a **mesial and distal concavity** with the **distal being more distinct**.
6. Looking down on this tooth from the incisal we can see that the distal half of the labial profile is round and the mesial half is flattened or even a little concave.

### NOTE

*Special properties of individual teeth (e.g., maxillary canine is the longest) are NBDE favorites.*

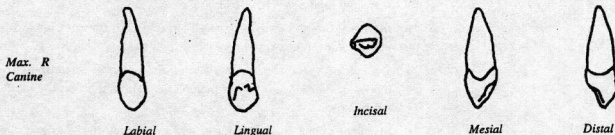


Figure 1-7.


### B. Mandibular canine

1. Once again it is a long pointed tooth in which the total length is less than the **maxillary canine** but the **crown itself is longer**. The mesioincisal angle is again sharper than the distoincisor angle. The **tooth is narrower in a mesiodistal diameter than the maxillary canine**. The **mesial profile is very straight** with a height of contour near the incisal

edge in the incisal 1/3 of the tooth. The **distal profile** is bulbous and the height of contour is at the junction of the middle and incisal 1/3s.

2. The **crown** itself seems to be **distally inclined** with the cusp tip being **distally displaced**. The **incisal edge** is **lingual to the labiolingual mid-point**.
3. Again we find a trilobed buccal surface with a height of contour in the lower 1/3 of the crown. The **lingual anatomy** is **less distinct than that of the maxillary canine**, having a distal and mesial marginal ridge, cingulum, and lingual ridge. **Rarely is a lingual pit found on this tooth.**
4. The **root** has both a mesial and distal depression or concavity.

Mand. R  
Canine



Labial



Lingual



Incisal



Mesial



Distal

Figure 1-8.

### C. Maxillary vs. mandibular canine

1. Maxillary canine is wider mesiodistally.
2. Maxillary canine is longer (total length).
3. Mandibular canine has a longer crown.
4. Maxillary canine has more distinct lingual anatomy.
5. Maxillary canine may have a lingual pit.
6. Maxillary canine crown is generally in line with the root while the mandibular canine's crown appears distally bent.
7. The contact areas and the mesial and distal heights of contours are higher or more incisal on the mandibular canine than on the maxillary canine.
8. Maxillary canine crown is shorter and fatter than the long and slim mandibular canine crown.
9. Maxillary canine incisal edge is in the labiolingual midpoint. The mandibular canine incisal edge is lingual to the labiolingual midpoint.

## PREMOLARS

### A. Maxillary vs. mandibular premolars

1. Approximately same size mesiodistally and in total length; maxillary premolars have a greater faciolingual diameter

2. Maxillary premolars have more distinct lingual cusps than the mandibular premolars.
3. Maxillary occlusal table centered faciolingually; mandibular occlusal table is lingually displaced.
4. Mandibular buccal cusps are more towards the faciolingual midpoint.
5. Maxillary buccal surface is straighter from height of contour to cusp tip; mandibular buccal surface is more convex.
6. Maxillary buccal height of contour in cervical or lower 1/3 of crown; mandibular buccal height of contour in cervical or lower 1/3 of crown but even lower than maxillary, at about the cervical line.
7. Lingual height of contour of mandibular premolars is more occlusal (or higher) in the upper middle 1/3; maxillary lingual height of contour at or about the junction of the cervical and middle 1/3s of the crown
8. Mandibular premolars have rounder roots on cross-section. Maxillary premolars have mesial root concavities.

**Maxillary  
first  
premolar**

1. Two roots
2. Prominent mesial concavity
3. Mesial intra-radicular groove
4. Distally displaced buccal cusp and mesially displaced lingual cusp
5. Mesial marginal developmental groove

**Mandibular  
first  
premolar**

6. Mesial lingual developmental groove
7. Most resembles canine
8. Lingual cusp-like cingulum
9. Transitional tooth
10. Greatest discrepancy of size of buccal and lingual cusps
11. Lingually slanted occlusal table
12. Transverse ridge.

**Mandibular  
second  
premolar**

13. Central pit
14. Three cusps
15. Roundest root on cross-section

Figure 1-9.

**NOTE**

*The maxillary first premolar and its intra-radicular groove is an NBDE favorite. Root planing of the mesial side, and adapting a matrix band on the mesial side, can both be difficult because of this groove.*

**B. Maxillary first premolar**

1. 2 roots (one buccal, one lingual), 2 cusps
2. **Broad-shouldered** tooth from the buccal with markedly convex mesial and distal contours. **Buccal surface** has a prominent buccal ridge running axially, bordered by depressions giving the buccal surface a 3-lobed appearance; **buccal surface is wider than lingual surface**; **marked mesial concavity** in an axial direction which progresses onto the root as the **mesial intra-radicular groove**, giving the correct impression of **two roots** (only premolar which normally has 2 roots); buccal cusp is slightly larger than the lingual cusp; buccal cusp is distally placed (mesial cusp ridge longer than distal cusp ridge) and lingual cusp is slightly mesial to the midpoint.
3. **Mesial marginal developmental groove**, an extension of the central groove, interrupts the mesial marginal ridge and progresses down on the mesial surface, renders the crown slightly concave lingual to the contact area on the mesial surface.
4. **Hexagonal crown profile** from the occlusal view. Mesial and distal surfaces converge towards the lingual, resulting in a **trapezoidal occlusal table**.

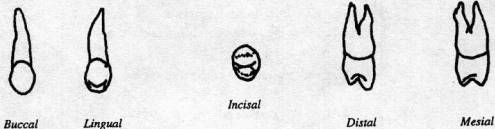*Max. R  
First Premolar*

Figure 1-10.

**C. Maxillary second premolar**

1. 1 root, 2 cusps
2. **Narrow-shouldered** tooth from buccal, slightly smaller than first premolar; buccal surface has relatively indistinct lobes; a slight mesial concavity or even convexity may be seen on the mesial surface. The mesial marginal ridge is not interrupted by a groove.
3. Cusps are of more equal height and width and the tips are centered on the tooth in a mesiodistal direction.
4. From the occlusal, ovoid or diamond profile and **rectangular occlusal table** with little lingual convergence.

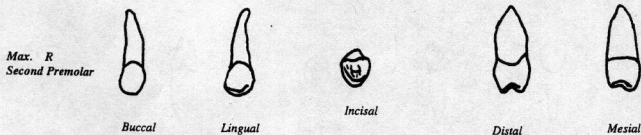


Figure 1-11.

Table 1-6.

Maxillary First Premolar	Maxillary Second Premolar
1. Broad shouldered	1. Narrow shouldered
2. Prominent buccal lobes	2. Less prominent buccal lobes
3. Buccal cusp-distal and lingual cusp-mesial	3. Buccal and lingual cusps centered mesiodistally
4. Slightly larger buccal than lingual cusp	4. Buccal and lingual cusp equal
5. Prominent mesial axial concavity	5. Less prominent mesial axial concavity
6. Lingual convergence	6. Little lingual convergence
7. Hexagonal occlusal profile	7. Ovoid to diamond occlusal profile
8. Trapezoidal occlusal table	8. Rectangular occlusal table
9. 2 roots	9. 1 root
10. Mesial marginal developmental groove	
11. Mesial intra-radicular groove	

## D. Mandibular first premolar

- 1 root, 2 cusps
- May be viewed as a **transitional tooth, resembling a canine; buccal cusp much larger than lingual cusp** (which may resemble a cingulum).
- Occlusal table is lingually inclined**, only posterior tooth with this trait; tooth is very asymmetric in the mesial and distal profiles with a prominent mesial bulge.
- Mesiolingual groove** produces a slight concavity at about the mesiolingual line angle of the tooth.
- From the occlusal; **prominent transverse ridge** from the buccal cusp tip to the lingual cusp. The mesial marginal ridge is much less distinct than the distal marginal ridge. **Profile is diamond-shaped**, with convergence to the lingual.
- Root is relatively round and conical.



*Mand. R  
First Premolar*



*Buccal*



*Lingual*



*Occlusal*



*Mesial*



*Distal*

Figure 1-12.

**NOTE**

Know the premolars well. A surprisingly large number of dental anatomy questions involve these teeth.

**E. Mandibular second premolar**

1. 1 root, 2 or 3 cusps
2. Buccal width and lingual width nearly equal in size; **buccal and lingual cusps are more equal in size**; may have 1 or 2 lingual cusps. If 2 lingual cusps, the mesiolingual is larger than the distolingual and separated by lingual groove extending from the central pit.
3. Little occlusal surface is seen from the lingual in either case.
4. Tooth is square in outline from the occlusal and may have different occlusal patterns: "Y" for 3-cusped tooth or "H" for 2-cusped tooth.
5. Root is conical and roundest of all the premolars on cross section.

*Mand. R  
Second Premolar*



*Buccal*



*Lingual*



*Occlusal*



*Mesial*



*Distal*

Figure 1-13.

Table 1-7.

Mandibular First Premolar	Mandibular Second Premolar
1. Wider buccal than lingual surfaces	1. Equal buccal and lingual surfaces
2. Buccal cusp much greater than lingual	2. Buccal cusp almost equal to lingual
3. Lingual convergence	3. Little lingual convergence
4. Diamond occlusal profile	4. Square occlusal outline
5. Round root on cross section	5. Rounder root on cross section
6. Resembles canine	6. Resembles premolar
<b>Unique Characteristics</b>	<b>Unique Characteristics</b>
7. Mesiolingual developmental groove	7. May have 2 or 3 cusps (if 3, 2 are lingual with ML bigger than DL, and have lingual groove)
8. Transverse ridge	8. Central pit
9. Lingually inclined occlusal table	9. "Y" occlusal pattern for 3 cusps
10. Lingual cusp-like cingulum	10. "H" occlusal pattern for 2 cusps

## MOLARS

Table 1-8.

Maxillary Molars	Mandibular Molars
1. 3 roots	1. 2 roots
2. 3 <u>major</u> cusps	2. 4 <u>major</u> cusps
3. Buccal cusps unequal	3. Buccal cusps equal
4. Lingual cusps unequal	4. Lingual cusps equal
5. Occlusal table centered labiolingually	5. Occlusal table lingually placed
6. Equal amounts of buccal and lingual surfaces may be seen from occlusal	6. More buccal surface than lingual surface may be seen from occlusal
7. Lingual height of contour in middle 1/3 just above junction of middle and cervical 1/3s	7. Lingual height of contour in middle 1/3 just below the junction of the middle and occlusal 1/3s
8. Wider faciolingually than mesiodistally	8. Wider mesiodistally than faciolingually
9. Distolingual groove	9. Buccal pit

### A. Maxillary first molar

- 3 roots (1 lingual, 2 buccal); 4 cusps (2 buccal, 2 lingual); 5th minor cusp (cusp of Carabelli) on surface of mesiolingual cusp.
- From the buccal surface we can see the **larger mesiobuccal cusp**. The **buccal surface** is convex in its lower 1/3, **height of contour being in the lower 1/3**, and becomes relatively straight from the height of contour to the cusp tip. Contrast this to the lingual surface, which is **convex** throughout, with the **height of contour being in the lower middle 1/3**. From the lingual we can see the larger mesiolingual cusp

#### NOTE

*Carabelli cusp (5th cusp of maxillary first molar), located on the mesiolingual cusp, is highly variable, from full cusp to barely visible. It is sometimes referred to as the Carabelli trait.*



and smaller distolingual cusp separated by a deep lingual groove, which is an extension of the distolingual groove.

3. **Mesial contour** is flat to concave in its lower 1/3 and becomes highly convex at its height of contour.
4. **Distal surface** is convex throughout except for a concave to flat area immediately above the distobuccal root.
5. **Occlusal view:** equal amounts of the buccal and lingual surface can be seen. The outline of the crown is rhomboidal with the mesiobuccal and distolingual angles being acute while the distobuccal and mesiolingual are obtuse.
6. The **distobuccal** and **mesiolingual cusps** are linked via an **oblique ridge**, giving the mesial area of the tooth a triangular appearance with the mesiobuccal, mesiolingual, and distobuccal cusps (sometimes called the "trigon"). The distal portion of the tooth, separated by the oblique ridge, is made up of the distolingual cusp and the distal marginal ridge.
7. The mesial marginal ridge is longer and more distinct than the distal marginal ridge.
8. Mesial to the oblique ridge we find in a **central fossa** a **central groove** running from the central pit to the mesial pit in the **mesial triangular fossa**. Also extending from the central pit is the **buccal groove**, which runs between the buccal cusps. A **distal groove** also extends from the central pit distolingually toward the oblique ridge. From the distal to the oblique ridge we find the **distal triangular fossa** containing the **distal pit**. From the distal pit runs the **distolingual groove**, which carries onto the lingual surface as the **lingual groove** separating the two lingual cusps.
9. **Roots**
  - a. **Lingual (palatal) is largest**, followed by the **mesiobuccal**, then the smallest, **distobuccal**. **Buccal roots** are joined in a **common root trunk**, which extends 2.5–3.5 mm from the cervical line. The root trunk may have a **deep developmental groove** extending from the cervical line to the bifurcation of the buccal roots. The mesiobuccal root extends vertically with a distal incline at the apex, and the distobuccal root inclines mesially in the apical region, giving the "plier-handled" appearance.
  - b. The lingual root has its greatest diameter in a mesiodistal direction. The apex of the lingual root is in line with the lingual groove in the midpoint of the crown.
  - c. The **lingual root** has a **vertical depression on its lingual surface** extending from the cervical line.
  - d. **All roots can be seen from the buccal**, with the mesiobuccal and distobuccal having the "plier-handled" appearance, and the lingual root seen between them.

- e. From the lingual, the massive lingual root, the mesial contour of the mesiobuccal, and the distal contour of the distobuccal root can be seen.
- f. From the mesial only the mesiobuccal and lingual roots can be seen.
- g. From the buccal and lingual, the roots are well within the confines of the crowns in a mesiodistal direction; from the mesial or distal, the mesiobuccal root projects past the buccal surface of the crown, and the lingual border of the lingual root projects past the lingual crown contour.

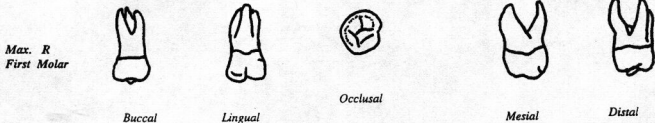


Figure 1-14.

#### B. Maxillary second molar

- Smaller than, and similar to, first molar, except for the following:
  - Distobuccal cusp is relatively smaller.
  - Distolingual cusp is smaller (may be absent).
  - Mesiobuccal and distolingual angles are more acute; the mesiolingual and distobuccal angles are more obtuse.
  - Absence of cusp of Carabelli.
  - More supplemental grooves on the occlusal surface.

#### C. Maxillary second molar roots

- Mesiobuccal root as well as the distobuccal root are inclined distally; they are parallel. Lingual root may be distally inclined, putting the apex in line with the distolingual cusp tip.
- The roots are within the crown profiles from all angles.

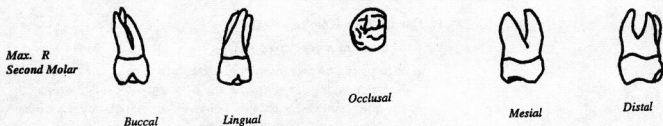


Figure 1-15.

**NOTE**

This tooth, as well as the maxillary lateral incisor, is known for extreme variability of form. Pointed, peg-like maxillary third molars are not uncommon. Fused pointed roots can make extraction of these teeth (sometimes) easier than expected.

**D. Maxillary third molar**

1. Variable, distolingual cusp is usually missing, and the distobuccal cusp is much smaller and may be missing.
2. **Crown is triangular or heart-shaped** from the occlusal due to the loss of the distolingual cusp. The oblique ridge may be small to missing.
3. The **roots** are usually very short and very distally inclined, and the lingual root is usually fused to the buccal roots.

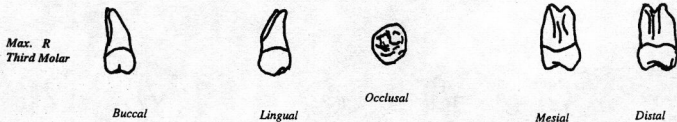


Figure 1-16.

Table 1-9.

First	Second	Third
4 cusps (MB, ML, DB, DL)	4 cusps $\pm$	3 cusps $\pm$
Carabelli cusp	No Carabelli cusp	No Carabelli cusp
Mesiolingual and mesiobuccal cusps very large	ML and mesiobuccal cusps smaller than first	ML and mesiobuccal cusps are smaller than second
Distobuccal cusp large	DB cusp smaller	DB cusp smallest (may be missing)
Distolingual cusp smaller	DL cusp smaller (may be missing)	DL cusp usually missing
Rhomboidal from occlusal (MB and DL angles acute, ML and DB angles obtuse)	Rhomboidal (MB and DL angles more acute, ML and DB more obtuse)	Triangular or heart-shaped
Buccal roots plier-handled, lingual root straight	All roots distally inclined	Roots very distally inclined; lingual root may be fused to buccal roots

**E. Mandibular first molar**

1. 2 roots (one mesial, one distal), 5 cusps (3 buccal, 2 lingual)
2. 3 cusps can be seen from the buccal surface, mesiobuccal being the largest, then the distobuccal cusp, and the smallest being the distal. On the buccal surface can be seen 2 grooves: the mesiobuccal groove separating the mesiobuccal and distobuccal cusps and the distobuccal groove separating the distobuccal and distal cusps. The mesiobuccal

- groove ends in a **buccal pit** on the buccal surface. **Height of contour** on the buccal surface is **low**—in the **cervical or gingival 1/3 of the crown** (the height of contour is characterized as a **buccal cervical ridge**). The buccal surface is relatively flat above the height of contour.
- The **mesial surface** of the crown is concave in the lower 1/3 of the crown and highly convex in the upper 2/3 of the crown; the **distal surface** is convex throughout.
  - The **buccal surface is wider than the lingual surface**, and thus the buccal crown profile can be seen from the lingual. A **lingual groove** can be seen on the lingual surface separating the **two equally-sized lingual cusps**. The **lingual height of contour is high in the middle 1/3 of the crown**. The lingual surface is relatively straight in the lower 1/3 of the crown and highly convex in its upper 2/3 of the crown.
  - Occlusal view.** Distal marginal ridge (between the distal and distolingual cusps) is smaller than the mesial marginal ridge. **Both marginal ridges are cut through by developmental grooves.**
  - Crown is pentagonal; buccal surface is bi-planar and wider than the lingual surface; 2/3 of buccal surface and 1/3 of lingual surface can be seen from the occlusal.
  - 3 fossae: central with central pit, extending from this pit are the mesiobuccal and lingual grooves and through it runs a central groove that terminates in the mesial and distal pits. The distobuccal groove originates from the central groove, distal to the central pit.
  - Two mesial triangular fossae with mesial pit.**
  - Three distal triangular fossae with distal pit.**
  - Mesial and distal roots are joined at a common root trunk; both roots curve slightly distally and are quite blunt. The mesial root apex lies under the mesiobuccal cusp. The mesial root is the broadest root in the arch in a buccolingual direction. The mesial root has on its mesial surface a distinct proximal root concavity.
  - Distal root is slightly smaller than the mesial and it too may have a shallow proximal root concavity.

*Mand. R*  
*First Molar*



*Buccal*



*Lingual*



*Occlusal*



*Mesial*



*Distal*

Figure 1-17.

**F. Mandibular second molar**

1. 2 roots (one mesial, one distal), 4 cusps (2 buccal, 2 lingual)
2. Similar to **first molar** **except** in the following ways:
3. Smaller than first; distal cusp is missing; the lingual and buccal surfaces are more equal in length; the distal and mesial surfaces are more equal in length; only one buccal groove.
4. Crown contours are similar to first molar.
5. Occlusal view: crown is rectangular in outline; we can see a central fossa with a central pit; central groove, buccal and lingual grooves radiating from the central pit.
6. Mesial triangular fossa with mesial pit.
7. Distal triangular fossa with distal pit.
8. No developmental grooves can be seen interrupting the marginal ridges.
9. Roots are similar to first except they are more distally inclined and somewhat closer together, with a more pointed apex; proximal root concavities usually not seen on either root.

*Mand. R  
Second Molar*



*Buccal*



*Lingual*



*Occlusal*



*Mesial*



*Distal*

*Figure 1-18.*

**G. Mandibular third molar**

1. **Highly variable**, may resemble first or second molar; usually much shorter and more bulbous, **ovoid occlusal table**, and crown outline.
2. **Roots are short, sometimes fused, and very distally inclined.**

*Mand. R  
Third Molar*



*Buccal*



*Lingual*



*Occlusal*



*Mesial*



*Distal*

*Figure 1-19.*



Table 1-10. Mandibular molars.

First	Second	Third
5 cusps	4 cusps	4 cusps
2 buccal grooves (MB and DB)	Single buccal groove	Single buccal groove
Pentagonal shape (occlusal)	Rectangular shape	Ovoid shape
Biplanar buccal surface	Single plane buccal surface	Single plane buccal surface to buccal roots
Buccal surface wider than lingual surface	Buccal and lingual surfaces equal	Variable
Mesial surface wider than distal	Mesial and distal surfaces equal	Variable
Mesial and distal marginal grooves	No marginal grooves	No marginal grooves
Mesial and distal root concavities	No root concavities	No root concavities
Distally inclined roots	More distinctly distally inclined roots	Extremely distally inclined roots
Rounded apex of root	Pointed apex	Short roots and fused

### CALCIFICATION AND ERUPTION OF PERMANENT TEETH

Table 1-11. Mandibular molars.

	First evidence of Calcification	Eruption	Root Completion
<b>Maxillary</b>			
Central incisor	3-4 mos.	7-8 yr.	10 yr.
Lateral incisor	1 yr.	8-9 yr.	11 yr.
Canine	4-5 mos.	11-12 yr.	14 yr.
First premolar	1 1/2 yr.	10-11 yr.	12 1/2 yr.
Second premolar	2 yr.	10-12 yr.	13 yr.
First molar	Birth (8 mos. pren.)	6 yr.	9-10 yr.
Second molar	2 1/2-3 yr.	12-13 yr.	15 yr.
Third molar	7-8 yr.	17-21 yr.	18-25 yr.
<b>Mandibular</b>			
Central incisor	3-4 mos.	6-7 yr.	9 yr.
Lateral incisor	3-4 mos.	7-8 yr.	10 yr.
Canine	4-5 mos.	9-10 yr.	13 yr.
First premolar	1 3/4-2 yr.	10-12 yr.	12 1/2 yr.
Second premolar	2 1/2 yr.	11-12 yr.	13 1/2 yr.
First molar	Birth (8 mos. pren.)	6 yr.	9-10 yr.
Second molar	2 1/2-3 yr.	11-13 yr.	14-15 yr.
Third molar	8-10 yr.	17-30 yr.	18-25 yr.

**NOTE**

Maxillary first molars, mandibular first molars, and mandibular central incisors often erupt at nearly the same time.

**NOTE**

Adequate systemic fluoride intake is crucial from the prenatal period through the completion of calcification.

**Calcification order:** Mandibular first molar; maxillary first molar; mandibular central incisor; maxillary central incisor, mandibular lateral incisor; mandibular canine; maxillary canine; maxillary lateral incisor; maxillary first premolar; mandibular first premolar; maxillary second premolar; mandibular second premolar; maxillary and mandibular second molar; maxillary and mandibular third molar.

**NOTE:** Calcification of the permanent teeth begins at birth with the first molars, and completion of the enamel takes roughly 4-5 years. It is during this time that teeth are susceptible to enamel defects from external sources.

**Eruption order:** Mandibular first molar; maxillary first molar; mandibular central incisor; maxillary central incisor; mandibular lateral incisor; maxillary lateral incisor; mandibular canine, maxillary first premolar; maxillary second premolar; mandibular first premolar; maxillary canine; mandibular second premolar; mandibular and maxillary second molars; mandibular and maxillary third molars.

**NOTE:** (1) Those teeth that replace the primary teeth cause their loss just prior to eruption.  
(2) Root formation is not complete until a significant time after eruption.

Table 1-11. Eruption of primary teeth.

Maxillary		Mandibular	
Central incisor	7.5 mos.	Central incisor	6 mos.
Lateral incisor	7 mos.	Lateral incisor	9 mos.
Canine	18 mos.	Canine	14 mos.
First molar	14 mos.	First molar	12 mos.
Second molar	24 mos.	Second molar.	20 mos.

## PRIMARY TEETH

### A. Generalities

1. Primary teeth are smaller than the permanent.
2. Crown itself is a smaller percentage of the tooth than in the permanent teeth, i.e., the crown-to-root ratio is smaller in primary teeth.
3. Crowns appear not only shorter, but fatter than the permanent teeth.
4. Molar roots are long and slender with little or no root trunk; roots themselves have marked bowing and flaring.
5. The anterior teeth are constricted at the cervical line, producing conspicuous lingual and facial cervical bulges.

6. Molars have a facial bulge but lack a conspicuous lingual bulge.
7. Cervical ridges are therefore more pronounced than in permanent teeth.
8. Facial and lingual surfaces from the heights of contour to the occlusal or incisal edge are flatter than in the permanent. No mammelons can be seen on the 1<sup>st</sup> anteriors.
9. The enamel is thinner in the primary teeth.
10. Teeth are conspicuously whiter than the permanent teeth.
11. Multiple diastemas or gaps between the teeth are normally found in the primary arch.
12. The primary arch is more circular than the permanent arch.
13. All the teeth in the primary dentition are replaced by the same teeth in the permanent, except the primary molars, which are replaced by the permanent premolars.
14. The primary teeth generally resemble the teeth that replace them except for the primary molars; the primary mandibular and maxillary second molars resemble the permanent mandibular and maxillary first molars and the primary mandibular and maxillary first molars resemble nothing in the permanent dentition.

### **PRIMARY ANTERIOR TEETH**

#### **A. Maxillary primary central** (Replaced by maxillary permanent central incisor)

Similar to the **maxillary permanent central** **except** in the following ways:

1. Follows the noted General Characteristics mentioned above
2. Labial surface is smoother with no mammelons.
3. Cingulum may be more prominent.
4. **Cervical constricture:** facial and lingual cervical bulges
5. Height of crown less than mesiodistal diameter.

#### **B. Maxillary primary lateral incisor** (Replaced by maxillary permanent lateral incisor)

Similar to the **maxillary permanent lateral** **except** in the following ways:

1. Follows the noted General Characteristics mentioned above.
2. Labial surface smoother.
3. More distinct lingual anatomy.
4. **Cervical constricture:** facial and lingual cervical bulges.

---

#### **NOTE**

*The small size (and nearness of the pulp) in primary teeth make restoration more difficult, and pulp exposure more likely.*

---

#### **NOTE**

*The primary maxillary incisors are most damaged by baby bottle tooth decay (BBTD).*

**C. Maxillary primary canine** (Replaced by maxillary permanent canine)

Similar to the **maxillary permanent canine** except in the following ways:

1. Follows the noted General Characteristics mentioned above.
2. Diamond-shaped crown from facial.
3. Labial surface smoother.
4. Prominent cingulum: cusped appearance.
5. Mesial and distal contacts at same level.
6. Longer mesial incisal slope than distal incisal slope.
7. Height of crown less than mesiodistal diameter.

**D. Mandibular primary central** (Replaced by mandibular permanent central)

Similar to the **mandibular permanent central**, except in the following ways:

1. Labial surface is smooth and unmarked and flat.
2. Prominent cingulum on lingual.
3. Often a developmental groove or depression on distal of root.
4. Cervical constriction: facial and lingual cervical bulges.

**E. Mandibular primary lateral** (Replaced by mandibular permanent lateral incisor)

Similar to the **mandibular permanent lateral incisor**, except in the following ways:

1. Prominent cingulum on lingual.
2. Cervical constriction: facial and lingual cervical bulges.

**F. Mandibular primary canine** (Replaced by mandibular permanent canine)

Similar to the **mandibular permanent canine**, except in the following ways:

1. Arrow-shaped from the facial.
2. Smooth labial surface.
3. Longer distal incisal ridge than mesial incisal ridge.

## **PRIMARY POSTERIOR TEETH**

---

**A. Maxillary primary first molar** (Replaced by maxillary first premolar)

Resembles nothing in the permanent dentition.

1. Most atypical of all molars: resembles a premolar as well as a molar.
2. Basically a 2-cusped tooth; **mesiobuccal** and **mesiolingual cusp**; may have a small distobuccal cusp and rarely a small distolingual cusp; a

parastyle, i.e., a nodule resembling an extremely small cusp may be present on the mesial ridge of the **mesiobuccal cusp**.

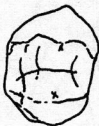- From the **occlusal** the peripheral outline is trapezoidal, with the tooth converging lingually and distally; buccal surface longer than the lingual and mesial longer than the distal.
- Occlusal table outline** is rectangular; with a deep prominent **buccal developmental groove** separating the two buccal cusps; the groove terminates in a central pit.
- Frequently, but not always, an oblique ridge from the mesiolingual cusp to the distobuccal cusp area.
- Heights of contour are low and prominent with a distinct buccal cervical ridge; this is not unique, however.
- Roots:** 3 roots very divergent and without root trunk, looks like "Elephant Charging" when viewed from lingual and inverted.



Lingual



Mesial



Occlusal

Figure 1-20.

## NOTE

Primary first molars are highly unusual in shape, while primary second molars strongly resemble permanent first molars.

**B. Maxillary primary secondary molar** (Replaced by the second maxillary premolar)

Resembles the maxillary permanent first molar except in the following ways:

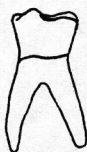- Squatter and more bulbous in appearance.
- More prominent cervical bulges.
- Very little root trunk.

**C. Mandibular primary first molar** (Replaced by first mandibular premolar)

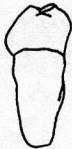Resembles nothing in the permanent dentition.

- Look more like a molar than does the maxillary primary first molar.
- Generally has 4 cusps, 2 buccal, and 2 lingual with the mesiobuccal and ML being the largest, and a **transverse ridge** between the mesiobuccal and ML cusps.
- Mesial profile straight and distal profile highly convex.

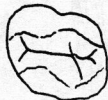4. From the **occlusal** the peripheral outline is trapezoidal, with the tooth converging lingually and distally; buccal surface longer than the lingual and mesial longer than the distal.
5. Buccal profile has a very low and prominent buccal cervical ridge (very unique), giving tooth a pregnant appearance.
6. Relatively deep buccal groove separating buccal cusps and a shallow lingual groove separating lingual cusps; may have mesial marginal groove.
7. From the occlusal the tooth is rhomboidal in peripheral outline due to the **buccal cervical ridge**, which is mainly under the mesiobuccal cusp area; occlusal table is rectangular.
8. Has central pit from which radiates a central groove, which goes to a mesial pit, and buccal and lingual grooves.
9. 2 roots with the mesial root being larger.



Mesial



Lingual



Occlusal

Figure 1-21.

**D. Mandibular primary second molar** (Replaced by the mandibular permanent second premolar)

Resembles the **mandibular primary first molar** except in the following ways:

1. Follows noted General Characteristics mentioned above.
2. 2 roots more divergent and without root trunk.
3. Cervical bulges.
4. All three buccal cusps (mesiobuccal, distobuccal, and distal) are equal in size, whereas distal cusp is smallest in permanent first molar.
5. Buccal cusps over roots and lingual outline is beyond the root outline.

**NOTE**

*Isomorphy of the primary second molars and permanent first molars is an NBDE favorite.*

**ISOMORPHY**

There is a remarkable resemblance between the maxillary and mandibular second primary molars and the first permanent molars even down to the smallest detail.

Table 1-13.

**Frequently Asked on NBDE 1**

Maxillary first primary molar most resembles premolar.

Mandibular first primary molar has most unique buccal cervical bulge or ridge.

Mandibular first primary molar has prominent transverse ridge.

Mandibular first and maxillary first primary molars resemble nothing in permanent dentition.

Mandibular second and maxillary second primary molars resemble the mandibular first and maxillary first permanent molars respectively.

**OCCLUSION—Arch-to-Arch Relationship**

A. When the two arches come together, each tooth opposes 2 teeth in the opposite arch, with the exception of the **mandibular central incisor** and the **maxillary third molar**, each of which only oppose one tooth.

**1. The maxillary arch**

Each tooth in the maxillary arch opposes 2 teeth in the mandibular arch—its counterpart in the mandibular arch plus the tooth distal to its counterpart, e.g., first maxillary premolar opposes the first mandibular premolar (its counterpart) plus the second mandibular premolar (tooth distal to its counterpart). The only exception to this rule is the maxillary third molar, which opposes only the mandibular third molar.

**2. The mandibular arch**

Each tooth in the mandibular arch opposes 2 teeth in the maxillary arch—its counterpart in the maxillary arch plus the tooth mesial to its counterpart, e.g., first mandibular molar opposes the first maxillary molar (its counterpart) plus the second maxillary premolar (tooth mesial to its counterpart). The only exception to this rule is the mandibular central incisor, which opposes only the maxillary central incisor.

B. When the arches come together, the posterior teeth contact while the anterior teeth are just out of contact. The maxillary anteriors overlap the mandibular anteriors with a vertical and horizontal component. Vertical overlap is overbite and horizontal overlap is overjet.

C. The tip of the **maxillary canine** is placed in the **labial embrasure** (not in contact) between the mandibular canine and the mandibular first premolar, and the mandibular canine is in the **lingual embrasure** (not in contact) between the maxillary canine and the maxillary lateral incisor.

**NOTE**

*The general relationships described on this page are critical in answering most occlusion questions.*

## CONCEPTS AND DEFINITIONS

### A. Supporting cusp (holding or occluding cusp):

Generally the cusp of a tooth that contacts the opposing arch on the marginal ridges or the central fossa area (buccal cusps of the mandibular posteriors and the lingual cusps of the maxillary posteriors). They are responsible for supporting the forces of occlusion.

### B. Guiding cusp:

Generally the cusps of a tooth that are not in contact in occlusion but outside the occluding area and are opposing embrasures or grooves in the opposing dentition (buccal cusps of the maxillary posteriors and lingual cusps of the mandibular posteriors).

### C. Guiding inclines:

The inclines or slopes of the guiding cusps from the guiding cusp tip towards the center of the tooth (the lingual inclines of the buccal cusps of the maxillary posteriors and the buccal inclines of the lingual cusps of the mandibular posteriors).

### D. Functional Outer Aspect (FOA):

The outside 1–2 mm of the supporting cusp, which makes contact with the guiding inclines of the guiding cusps of the opposing dentition when in occlusion (i.e., 1–2 mm wide strip from the buccal cusp tips of the mandibular posteriors on the buccal surface and 1–2 mm wide strip from the lingual cusp tips of the maxillary posteriors on the lingual surface).

### E. Posterior teeth in general:

The buccal cusps of the mandibular posteriors and the lingual cusps of the maxillary posteriors are the holding or supporting or occluding cusps and they contact marginal ridges and central fossae in the opposing arch. The buccal cusps of the maxillary posteriors and the lingual cusps of the mandibular posteriors are the guiding cusps and oppose the embrasures and grooves of the opposing dentition.

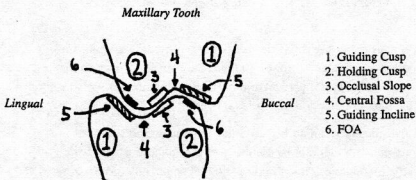


Figure 1-22.



Therefore, on each posterior tooth we should expect 3 areas of contact during occlusion: the FOA of the holding cusp contacting the guiding incline(s) of the guiding cusp in the opposing dentition; the occlusal slope of the holding cusp contacting the occlusal slope of the opposing holding cusp; and the guiding incline(s) of the guiding cusp contacting the FOA of the holding cusp of the opposing dentition.

### SUMMARY OF HOLDING CUSPS

- A. Holding cusps contact the marginal ridges and the central fossae of the opposing dentition.
1. **Maxillary holding cusps** (lingual cusps)
  2. **First maxillary premolar** (lingual cusp): Contacts the distal marginal ridge (DMR) of the first mandibular premolar plus the mesial marginal ridge (MMR) of the second mandibular premolar
  3. **Second maxillary premolar** (lingual cusp): Contacts DMR of the second mandibular premolar plus the MMR of the first mandibular molar
  4. **First maxillary molar** (lingual cusps)
    - a. **Mesiolingual cusp** occludes in the central fossa of the first mandibular molar
    - b. **Distolingual cusp** occludes in the DMR of the first mandibular molar plus the MMR of the second mandibular molar
  5. **Second maxillary molar** (lingual cusps):
    - a. **Mesiolingual cusp** occludes in the central fossa of the second mandibular molar
    - b. **Distolingual cusp** occludes on the DMR of the second mandibular molar plus the MMR of the third mandibular molar
  6. **Third maxillary molar** (lingual cusps)
    - a. **Mesiolingual cusp** occludes in the central fossa of the third mandibular molar
    - b. **Distolingual cusp** usually missing

### GENERAL RULE OF MAXILLARY POSTERIOR HOLDING CUSPS

The holding cusps of the maxillary posteriors occlude on the distal marginal ridge of its counterpart in the mandibular arch plus the mesial marginal ridge of the tooth distal to its counterpart with the exception of the **mesiolingual cusps** of the molars, which occlude in the central fossae of their counterpart molars in the mandibular arch.

**A. Mandibular holding cusps (buccal cusp)**

1. **First mandibular premolar** (buccal cusps) contacts the MMR of the first maxillary premolar and slightly out of contact with the DMR of the maxillary canine
2. **Second mandibular premolar** (buccal cusps) contacts the DMR of the first maxillary premolar plus the MMR of the second maxillary premolar
3. **First mandibular molar** (buccal cusps)
  - a. Mesiobuccal cusp contacts the DMR of the second maxillary premolar plus the MMR of the maxillary first molar
  - b. Distobuccal cusp contacts the central fossae of the first maxillary molar
  - c. Distal cusp occludes in the distal triangular fossa of the first maxillary molar.
4. **Second mandibular molar**
  - a. Mesiobuccal cusp occludes on the DMR of the maxillary first molar plus the MMR of the maxillary second molar
  - b. Distobuccal cusp occludes in the central fossa of the second maxillary molar
5. **Third mandibular molar** (buccal cusps)
  - a. Mesiobuccal cusp occludes on the DMR of the maxillary second molar plus the MMR of the maxillary third molar
  - b. Distobuccal cusp occludes in the central fossa of the third maxillary molar

**GENERAL RULE FOR MANDIBULAR POSTERIOR HOLDING CUSPS**

These holding cusps occlude on the mesial marginal ridge of their counterpart in the maxillary arch plus the distal marginal ridges of the tooth mesial to its counterpart, with the exception of the **distobuccal cusp** of the molars, which occludes in the central fossa of the counterpart molar in the maxillary arch and distal cusp of the mandibular first molar, which occludes in the distal triangular fossa of the maxillary first molar and the buccal cusp of the mandibular first premolar, which only contacts the MMR of the maxillary first premolar.

**A. Summary of guiding cusps:**

Guiding cusps generally oppose embrasures or grooves in the opposing dentition.

1. **Maxillary posterior guiding cusps** (buccal cusps)
  - a. **Maxillary first premolar** (buccal cusp) opposes the facial embrasure between the mandibular first premolar and the mandibular second premolar

- b. **Maxillary second premolar** (buccal cusp) opposes the facial embrasure between the mandibular second premolar and the mandibular first molar
- c. **Maxillary first molar** (buccal cusps)
  - Mesiobuccal cusp opposes the mesiobuccal groove of the first mandibular molar
  - Distobuccal cusp opposes the distobuccal groove of the first mandibular molar
- d. **Maxillary second molar**
  - Mesiobuccal cusp opposes the buccal groove of the second mandibular molar
  - Distobuccal cusp opposes the facial embrasure between the second mandibular molar and third mandibular molar
- e. **Maxillary third molar**
  - Mesiobuccal cusp opposes the buccal groove of the third mandibular molar

### **GENERAL RULE OF MAXILLARY GUIDING CUSPS**

- A. The buccal cusps of the maxillary posterior teeth oppose the facial embrasure between its counterpart in the mandibular dentition and the tooth distal except for the mesiobuccal cusps of the molars, which oppose the buccal groove of its counterpart mandibular molar and the distobuccal cusp of the maxillary first molar, which opposes the distobuccal groove of the mandibular first molar.
- B. **Mandibular posterior guiding cusps** (lingual cusps)
  - 1. **First mandibular premolar** (lingual cusp)—very small cusp not really acting as guiding cusp will oppose the lingual embrasure between the maxillary canine and maxillary first premolar
  - 2. **Second mandibular premolar** (lingual cusp) opposes the lingual embrasure between the maxillary first premolar and maxillary second premolar
  - 3. **First mandibular molar**
    - a. **Mesiolingual cusp** opposes the lingual embrasure between the maxillary second premolar and the maxillary first molar
    - b. **Distolingual cusp** opposes the lingual groove of the maxillary first molar
  - 4. **Second mandibular molar**
    - a. **Mesiolingual cusp** opposes the lingual embrasure between the maxillary first and maxillary second molars
    - b. **Distolingual cusp** opposes the lingual groove of the maxillary second molar

5. **Third mandibular molar**

- a. **Mesiolingual cusp** opposes the lingual embrasure between the maxillary second and the maxillary third molars

**GENERAL RULE OF MANDIBULAR GUIDING CUSPS**

- A. The lingual cusps of the mandibular posterior teeth oppose the lingual embrasure between its counterpart in the maxillary dentition and the tooth mesial, except the distolingual cusps of the molars, which oppose the lingual grooves of their maxillary counterpart molar.
- B. **Anterior teeth** do not occlude or touch in normal occlusion. The maxillary anteriors overlap the mandibular anteriors. This in essence places the labioincisal angle of the mandibular incisors in opposition to the upper (incisal) lingual aspect of the maxillary incisors (i.e., the mesial and distal marginal ridge and lingual fossa). This makes the upper lingual angle of the maxillary incisors like a guiding slope and the labioincisal angle and incisal 1–2 mm of the labial surface of the mandibular incisors in essence a FOA.

**SUMMARY OF OPPOSITION**

- A. **Mandibular central incisor**—the labioincisal angle opposes the mesial marginal ridge of the maxillary central incisor as well as the maxillary central's lingual fossa.
- B. **Mandibular lateral incisor**—the labioincisal angle opposes the distal marginal ridge of the maxillary central, and the mesial marginal ridge of the maxillary lateral as well as the lingual fossa.
- C. **Mandibular canine**—the cusp tip is located in the lingual embrasure between the maxillary canine and the maxillary lateral incisor
- D. **Maxillary central incisor**—overlaps (vertically and horizontally) the mandibular central and lateral incisors, and its lingual surface is in opposition to them.
- E. **Maxillary lateral incisor**—overlaps the mandibular lateral and canine, and the lingual surface may be considered in opposition to them.
- F. **Maxillary canine**—cusp tip is located in the facial embrasure between the mandibular canine and first premolar.

**ARCH CLASSIFICATIONS (Angle Classification)**

- A. **Class I. The mesiobuccal cusp** of the first maxillary molar is **opposite** the **mesiobuccal groove** of the mandibular first molar and the **maxillary canine** is in the labial embrasure between the mandibular canine and the mandibular first premolar. In reality, the **Class I** type of occlusion

**NOTE**

Detailed information on angle classification is not needed until NBDE II. Know the classes as described here.

- described by Angle is a malocclusion. Even though the normal cuspgroove relationship is present, anterior crowding may be present. Normal occlusion is not classified by Angle's system. **Class I** occlusion is often called **neuroocclusion**.
- B. **Class II.** Mandible is small or **micrognathic**. The **mesiobuccal cusp** of the first maxillary molar is **anterior** to the **mesiobuccal groove** of the mandibular first molar and the maxillary canine is **anterior** to the **labial embrasure** of the mandibular canine and the mandibular first premolar, often called **distocclusion**. Lower arch is distal to upper arch. Angle Class II is divided into two divisions.
- C. **Class III.** Mandible is large or **prognathic**. The **mesiobuccal cusp** of the first maxillary molar is **posterior** to the **mesiobuccal groove** of the mandibular first molar and the maxillary canine is posterior to the labial embrasure of the mandibular canine and the mandibular first premolar, often called **mesiocclusion**. The lower teeth are mesial to the upper teeth.

## FUNCTIONAL CONTACTING MOVEMENTS

### A. Concepts and definitions

1. **Working side:** When the mandible is moved to the left or right, the side to which the mandible is moved is called the working side.
  2. **Non-working side:** The side from which the mandible is moved is called the non-working or balancing side.
- B. When interpreting mandibular contacting movement, remember the **maxillary teeth** are stationary and the **mandible** moves. If given a diagram of the maxillary arch with mandibular cusp pathways shown, the movement indicated would be the true movement of the mandible. If a diagram of mandibular teeth was shown and maxillary cusp pathways illustrated, the movement of the maxillary cusps would be opposite the movement of the mandible.

## PROTRUSIVE CONTACTING MOVEMENT (Protrusive Glide)


- A. The mandible moves directly forward, and the **condyles** on both sides move simultaneously **forward** and **downward** on the articular eminence (see section on TMJ).
- B. The **mandibular holding cusps**, if drawn on maxillary teeth, would move directly **forward** in the central area of maxillary teeth (see Figure 1-23).
- C. The **maxillary holding cusps**, if drawn on the mandibular teeth, would seem to move **backward** in the central area of the mandibular teeth (see Figure 1-24).

---

### NOTE

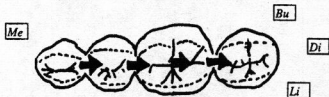
*Anatomically speaking, protrusion is caused by coordinated contraction of both lateral pterygoids.*

This is one situation where the anterior teeth would touch. The mandibular incisors labioincisal angle (FOA) would ride upon the lingual surface of the maxillary incisors.



Maxillary Teeth With Mandibular Cusps  
Pathways Traced In a Protrusive Movement

Figure 1-23.



Mandibular Teeth With Maxillary Cusps  
Direction Traced During Protrusive Movement

Figure 1-24.

### LATERAL CONTACTING MOVEMENT

- A. This occurs when the mandible moves to the left or right without going forward. The side to which the mandible is moving is the **working side** and the side away from which the mandible is moving is the **non-working or balancing side**. Direction of tooth movement is different on both the working and non-working sides due to the movement of the condyle.
- B. On the **working side**, the side to which the mandible is moving, the condyle primarily rotates and the cusps move in an almost pure **lateral direction**. The mandibular cusps, if shown on a diagram of maxillary teeth, move towards the buccal surface of the maxillary teeth (Figure 1-25), away from the midline; the maxillary cusps drawn on the mandibular teeth show the opposite movement, i.e., towards the lingual surface of the mandibular teeth (towards the midline) (Figure 1-26).

NOTE: On the working side the guiding cusps move through or into the embrasures and grooves they oppose in the opposite dentition and the holding cusps also move through embrasures and/or grooves—the cusps do not become tip to tip.

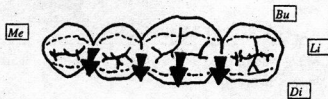**NOTE**

Anatomically speaking, movement of the mandible to the LEFT is caused by contraction of the RIGHT lateral pterygoid.



Maxillary Teeth With Mandibular Cusps  
Pathway Traced In a Working Movement

Figure 1-25.



Mandibular Teeth With Maxillary Cusps  
Traced During Working Movement

Figure 1-26.

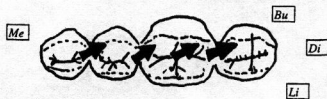
- C. On the **non-working side**, the side from which the mandible is moving, the condyle moves forward and downward and medially on the articular eminence. Consequently, the cusps have a lateral component of motion as well as an anterior-posterior component of motion, and arrows would show diagonal movements across a tooth surface.
- D. The mandibular holding cusps, if represented on a maxillary teeth diagram, would move towards the lingual surface of the maxillary teeth, toward the midline as well as forward so that the mandibular holding cusp would travel up the distal occlusal slope of the maxillary holding cusp which is immediately mesial to it (Figure 1-27); the maxillary cusps would show the opposite movement, i.e., the cusps would move towards the buccal surface of the mandibular teeth and posteriorly so that the maxillary holding cusp would seem to travel up the mesial occlusal incline of the mandibular holding cusp immediately buccodistal to it, seemingly coming cusp tip to cusp tip (see Figure 1-28).

NOTE: The balancing side or non-working side should not contact during the lateral contacting movements due to the mandibular condyles moving downward on the articular eminence.



Maxillary Teeth With Mandibular Cusps  
Tracing a Mesiolingual Pathway  
In a Balancing Excursion

Figure 1-27.



Mandibular Teeth With Maxillary Cusps  
Tracing a Distobuccal Pathway  
In a Balancing Excursion

Figure 1-28.

### LATERAL PROTRUSIVE MOVEMENT

- A. This combination of the lateral and protrusive movements also has a working and non-working side.
- B. **Working side:** The condyle rotates as well as moves forward and downward. The mandibular cusps move toward the buccal surface of the maxillary teeth, away from the midline, and the cusps also move forward creating a diagonal line across the maxillary occluding surface. The cusps seem to move towards the maxillary guiding cusps located immediately mesiobuccally (Figure 1-29). The maxillary working side holding cusps move in the opposite direction, i.e., towards the midline, towards the lingual surface of the mandibular teeth, as well as posteriorly. The maxillary holding cusps seem to move towards the mandibular guiding cusp located immediately distolingually. (Figure 1-30)



Maxillary Teeth With Mandibular Cusps  
Tracing a Mesiobuccal Pathway In a  
Working Lateral-Protrusive Excursion

Figure 1-29.



Mandibular Teeth With Maxillary Cusps  
Tracing a Distolingual Pathway In a  
Working Lateral-Protrusive Excursion

Figure 1-30.

- C. **Non-working side:** The condyle moves anteriorly, downward, and medially. The cusps would combine the movement of nonworking lateral plus protrusive.
- D. This would produce movement of the cusps not unlike the pure non-working lateral, the only difference being that the diagonal line created



by this movement may point more anteriorly, i.e., a line at less of an angle away from the central area of the arch than would be found in the pure non-working lateral excursion.

## SUMMARY

The following diagrams summarize contacting movements.

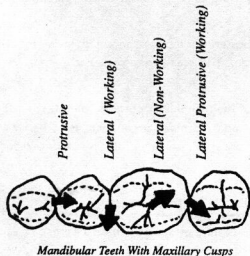


Figure 1-31.

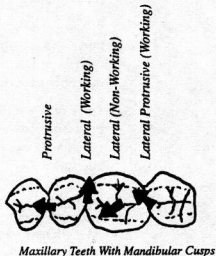


Figure 1-32.

**Retrusive movement** is a movement toward centric relation (CR). Just remember that its direction is the opposite of the protrusive movement.

## TEMPOROMANDIBULAR JOINT

- The **mandibular condyle** is an oblong process wider medio-laterally than antero-posteriorly with a rounded posterior aspect and concave anterior aspect (**fovea pterygoidea**). Its articulating surface, the **superior anterior aspect**, is slightly convex. The condyle as well as the articular tubercle is covered by a rather thick layer of fibrous avascular tissue. The **articular eminence** is located anterior to the rather thin-boned articular fossa of the temporal bone.
- Interposing between these two articulating surfaces is a **flexible fibrous articulating disc**. The disc itself is attached laterally to the condyle of the mandible.
- Condylar movement during mandibular contacting movements may be summarized as follows:
- Retrusive movement:** Both condyles move upward and back into the mandibular fossa.

### NOTE

*Fibers from the upper head of the lateral pterygoid muscle insert into the disc.*

- E. **Protrusive movement:** Both condyles move forward and down the articular eminence.
- F. **Lateral contacting movement:** Working side: condyle merely rotates; non-working side: condyle moves forward, downward on the articular eminence, and also medially.
- G. **Lateral-protrusive movement:** Working side: condyle rotates, moves forward and downward on the articular eminence; non-working side: condyle moves forward, downward on the articular eminence, and also medially.
- H. **Curve of Spee:** The anterior-posterior relation of the teeth viewed from the lateral (i.e., from the side). The maxillary arch is convex and the mandibular arch is concave.
- I. **Curve of Wilson:** The tilting of the mandibular posteriors lingually make the mandibular arch concave and the maxillary arch convex when the arches are viewed from the front (the maxillary posteriors tilt facially or buccally).

### ANGULATION OF TEETH IN THE ARCH

- A. All teeth have various degrees of inclination, away from a perpendicular to the occlusal plane.
- B. **Facial-lingual tilt:** The maxillary central incisor has the greatest inclination of all teeth tilting facially followed by the maxillary lateral incisor and then the mandibular incisors. In fact, all teeth tilt facially, except the second mandibular premolars and the mandibular molars, which tilt lingually. The premolars have characteristically the least tilt of all teeth and are called the straightest teeth in the mouth (perpendicular to the occlusal plane). **Mesial-distal tilt:** All teeth tilt mesially except for the maxillary central and the mandibular central and lateral incisors, which may have an ever-so-slight distal tilt. The maxillary canine has the greatest degree of mesial tilt and the premolars are again very straight with little tilt.

### ROOT ANGULATION

- A. All mandibular roots are generally angled distally and the posterior roots are inclined facially.
- B. All maxillary roots are generally angled distally and all posterior roots are inclined lingually, except the distobuccal root of the first maxillary molar, which is inclined buccally.

## RECORDING MANDIBULAR MOVEMENTS

### A. Posselt's envelope of motion

Posselt's envelope of motion defines the border movements of the mandible. To arrive at this diagram we could put a metallic pellet in the mandible between the two central incisors and record the position of the pellet when the mandible moves. The tracing records the anterior-posterior and inferior-superior positions. Remember that this is a recording of mandibular motion viewed from the lateral.

Starting with the I.C. position, notice that this is the highest position of the mandible and it is seen when the teeth are in maximum intercuspation. This intercuspal position is also known as centric occlusion.

Position RC is the most retruded position of the mandible (retruded contacting position, centric relation). In 90% of the population, the I.C. (or centric occlusion) is approximately 1.25 mm anterior to the centric relation and in the other 10%, I.C. corresponds to RC. Notice that when going to this RC position, the mandible must move downward as well as posteriorly from its height in the intercuspal position. This is due to the holding cusps of the mandibular teeth sliding on the mesial inclines of maxillary cusps located posterior to them.

B. The mandibular condyles are capable of two types of opening movement when in retruded contacting position: a pure rotational component and a translational movement. The rotatory movement accounts for the first 20 or so mm of mandibular opening and then ligaments, etc., become taut. For further opening, the ligaments must be made loose, and this is done by the mandibular condyles moving down the articular eminence. The mandible opens further (translational movement) to its maximal opening (40–50 mm separation of the anterior teeth).

C. The pure rotatory movement from RC is curve "A"; the translational movement is curve "B."

D. The line which connects the position of maximal opening to PCP (curve "C") is the protrusive opening path.

E. Actually, this line describes the curve made if the mandible was placed as far forward as possible, and then opened as far as possible.

F. Point PCP (protruded contact position) describes the most protruded or anterior position of the mandible. If you put your jaw in this position, notice that the incisors would not be in an edge to edge relationship but instead the mandibular incisors would be more anterior than the maxillary incisors.

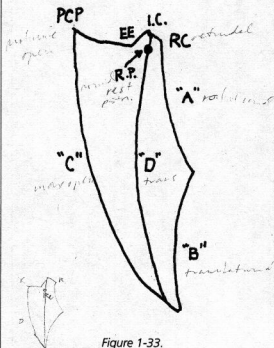


Figure 1-33.

### NOTE

Expect at least one question on the Posselt envelope of motion. Remember that the outline is the extreme position of all movements. The mandible can take any position within this outline.

- G. From PCP, remaining in tooth contact, the mandible is pulled backward until the incisors are edge to edge (we arrive at position EE). Notice that the mandible must move down so that the incisors can come edge to edge.
- H. Moving from EE to I.C., the mandibular cusps slide up the distal inclines of the maxillary cusps anterior to them. Curve "D" describes the mandibular path when opening to the position of maximum opening. This curve is not pure rotatory motion, but is **translational movement**. It is not a border movement because it occurs within the envelope of motion. Point R.P. is the normal **rest position** of the mandible. In rest, the teeth are not contacting. This position is also known as the **postural position** or **physiologic rest position**. The distance from R.P. to I.C. is called freeway space. That is, it represents the space between the teeth when the mandible is in the postural position (2–3 mm).

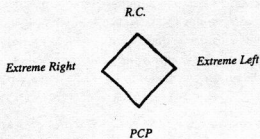


Figure 1-34.

Figure 1-34 represents the mandibular contacting border movements. It is actually a tracing of the mandible when starting in RC, the retruded contracting position, and then moving to the extreme right (right lateral contacting position); then moving to PCP (protruded contact position) and then to the extreme left (left lateral contacting position) and finally back again to RC.

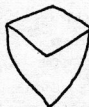

Figure 1-35.

Figure 1-35 represents the same movement as above but here in the lateral contacting positions the mandible is opened to its maximum. We define this diagram to be an anterior view of the border movements.

The chewing stroke or masticatory stroke, when seen from the anterior on the lateral, is well within the borders of the mandibular movement. It is described as a pear or tear-shaped movement. When chewing, the chewing is usually unilateral, favoring a particular side. This accounts for the displacement towards one side of the inferior portion of this movement.

## PERIODONTIUM

- A. The periodontium, or the tissue that invests and surrounds the tooth, can be artificially divided into the **gingival unit** and the **attachment apparatus**.
- B. The **gingival unit** consists of the **free gingiva**, **attached gingiva**, and **alveolar mucosa**. This gingival unit has a lining epithelium of either **masticatory mucosa**, which is thick keratinized epithelium with a dense collagenous connective tissue corium, or **lining mucosa**, which is thin, non-keratinized epithelium with a loose connective tissue corium containing elastic fibers and may have some muscle fibers. **Masticatory mucosa** is found in the free and attached gingiva, hard palate, dorsum of the tongue, and lining mucosa is found elsewhere in the oral cavity.

### NOTE

*Much more knowledge of the periodontium is required for NBDE II (later). For now, know this anatomic background.*

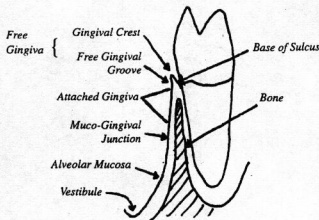


Figure 1-36.

Briefly, the **free gingiva** is that part of the gingiva located above the base of the **gingival sulcus** (in other words above that area where the gingiva is attached to the tooth). The **free gingival groove** corresponds to this attachment so the free gingiva may be considered to extend from the free gingival groove (or base of the **gingival sulcus**) to the **gingival crest**. It usually measures less than 3 mm in height. The free gingiva located interproximally is called the **papilla**. The form of the papillae depends upon the size and shape of the gingival embrasure and the **contact area**.

The **attached gingiva** is that part of the gingiva below the free gingival groove and above the **mucogingival junction**. The width of the attached gingiva varies from area to area within the mouth.

- C. The **alveolar mucosa** is below the **mucogingival junction**; it looks red or dark *in vivo* because of the thinness of the epithelium overlying the vascular corium.
- D. The **attachment apparatus** consists of the **alveolar bone**, **cementum** of the tooth, and the **collagen fiber attachment**.
- E. The **alveolar bone** may be characterized by plates of **compact bone** with inner **trabecular** or **spongy bone**. The compact bone is pierced by numerous channels for blood vessels, nerves, lymphatics, etc. It is also called the **cribriform plate**. The compact bone, which lines the **alveolar socket**, acts as the attachment for collagen fibers running from **cementum**. Where these collagen fibers or **Sharpey's Fibers** are incorporated into the compact bone, the bone is known as **bundle bone**. The height of the alveolar bone interdentally depends on the level of the **cervical line** of the tooth. Normally, the **crest of bone** is approximately **1 mm below this line**.
- F. The **cementum**, which invests the **root structure** of the tooth, has similar densities to compact bone and acts as the **origin** of the collagen fibers of the **principal groups** in the **periodontal ligament**.

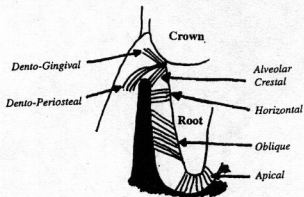


Figure 1-37.

The **principal fiber group** is made up of **collagen fibers** running from the **cementum** of the root into various locations.

1. **Dento-gingival group** runs from the cementum into the free gingiva.
2. **Dento-periosteal group** runs from the cementum apically, over the alveolar crest of bone to the **mucoperiosteum** of the attached gingiva.
3. **Transseptal group** runs from the cementum, over the alveolar crest bone to the cementum of the adjacent tooth.
4. **Circular fibers** are not attached in cementum. They run in the free gingiva around the tooth in a circular manner.

G. The **periodontal fiber group** is also made up of collagen fibers. They comprise the **alveolar-dental group**. These fibers run from the cementum to the alveolar bone. (The fibers we discussed previously did not attach to the alveolar bone.)

1. **Alveolar crestal** fibers run from the supra-alveolar cementum down to the alveolar crest.
2. **Horizontal** fibers run straight across from cementum to alveolar bone.
3. **Oblique** fibers (largest group) run from the cementum, apically, from the root to the bone.

NOTE: The PDL does not have a uniform width throughout its length. Its narrowest section is in the middle 1/3 of the root. It is wider in the apical 1/3 and cervical 1/3.

NOTE: The **trabecular bone** of the **alveolus** becomes thicker and more uniform upon stimulation (i.e., occlusal forces working on tooth).

### **SWALLOWING (Deglutition)**

---

A. The act of swallowing (deglutition) is generally broken down into 3 phases:

1. Voluntary (oral)
2. Pharyngeal
3. Esophageal

### **VOLUNTARY STAGE**

---

- A. After the bolus is prepared by mastication in order for swallowing to be initiated, the **oral cavity** must be sealed. This is normally done by closing the lips.
- B. The mandible is stabilized by contraction of the **masseter**, internal (medial) pterygoid, and temporal muscles. This sometimes results in tooth contact, but not always. One of the only times that teeth would normally come together occurs during this process.
- C. The **nasal cavity** is sealed by raising the soft palate.
- D. The bolus on the tongue is carried to the posterior area of the oral cavity by raising the posterior part of the tongue. The bolus then slides into the oral pharynx and the involuntary or reflex stages of swallowing take place (i.e., the pharyngeal and esophageal).

NOTE: Tongue thrusting, a habit that may be developed to seal the oral cavity if the lips are unable to accomplish this necessary step in deglutition, may cause abnormal tongue pressure on the maxillary anteriors, causing an anterior open bite.

### ADDITIONAL NOTES—MISCELLANEOUS AREAS

A. Teeth normally only contact during swallowing, and this contact is not necessary for swallowing.

B. **Root canal orifices of maxillary 1st molar**

1. Lingual orifice is located slightly distobuccal to the mesiolingual cusp tip.
2. Distobuccal orifice is under the buccal groove.
3. Mesio Buccal orifice is under the mesial slope of the mesiobuccal cusp.
4. Lines connecting the orifices make a triangle with the apex pointing lingually.

The line connecting the lingual orifice to the mesiobuccal is longest. Next comes the lingual orifice to distobuccal orifice, and finally the mesiobuccal to distobuccal orifice is the shortest line.

C. **Type of caries**

1. Pit and fissure (on occlusal surface or lingual or buccal pits)
2. Smooth surface (interproximal or smooth lingual and buccal surfaces)

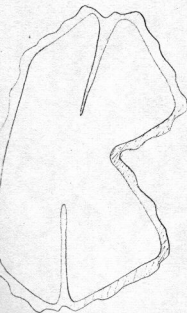
D. **Type of restorations (classifications)**

1. Occlusal surface of all teeth and lingual surfaces of maxillary anteriors
2. Proximals of posterior teeth (molars and premolars)
3. Proximal of anterior teeth, not including incisal angle
4. Proximal, including the incisal angle, of anterior teeth
5. Smooth surfaces on gingival 1/3 of crown
6. Cusp tip

### MUSCLES OF MASTICATION

Four muscles are considered to be the primary muscles of mastication. Three others (to be listed later) also insert on the mandible and produce motion of the mandible.

- A. The **temporalis** fibers arise from beneath the fascia overlying the lateral side of the temporal bone. They pass below the zygomatic arch and insert on the coronoid process of the mandible. Anterior and middle sections elevate the mandible, while posterior sections retract it.
- B. The **masseter** arises from the zygomatic arch (medial and lateral sections) and inserts in periosteum of the lateral side of the angle of the mandible. It elevates the mandible.
- C. The **medial pterygoid** arises from the medial surface of the pterygoid plate, the pyramidal process of the palatine bone, and the tubercle of the maxilla. It inserts in the medial side of the periosteum of the angle of the mandible. It elevates the mandible.





- D. One head of the **lateral pterygoid** arises from the **infratemporal surface of the sphenoid bone** and inserts into the **temperomandibular joint capsule and disc (superior head)**. The other head arises from the **lateral surface of the pterygoid plate** and inserts on the **condyle of the mandible (inferior head)**. The lateral pterygoids **protrude, depress (open), and move the mandible from side to side**. Both lateral pterygoids acting together **protrude** the mandible, while **one** acting alone moves the mandible forward and laterally to the **opposite side (left lateral pterygoid contraction moves the mandible to the right)**.

The **masseteric sling consists** of the **medial pterygoid** (medially) and **masseter** (laterally). It supports the mandible and provides powerful closing (elevating) action.

NOTE: All four muscles are innervated by the **mandibular division of the trigeminal nerve (V3)**.

All four muscles insert in the general area of the **ramus** of the mandible.

The lateral surface of the medial pterygoid contacts the **parotid gland, inferior alveolar artery, lingual nerve, inferior alveolar nerve, and chorda tympani nerve**, which all run alongside it.

- E. The **digastric** has two sections: the **anterior belly**, which arises from the **trochlea of the hyoid bone** and inserts into the **digastric fossa of the mandible**, and the **posterior belly**, which arises from the **mastoid process** and passes through the trochlea of the hyoid bone. The anterior section is innervated by the **mylohyoid branch of the mandibular nerve (V3)**. The posterior section is innervated by the **digastric branch of the facial nerve (VII)**. It can **depress (open) and retract** the mandible.
- F. The **mylohyoid** arises from both sides of the mandible, on the **mylohyoid line**. The two sections meet in a **midline fibrous raphe**, which connects to the **hyoid bone**. The mylohyoid forms a **sling under the floor of the mouth**. The mylohyoid is innervated by the **mylohyoid branch of the mandibular nerve (V3)**. It can **depress (open) the mandible**.
- G. The **geniohyoid** arises from the **hyoid bone** and inserts into the **midline of the mandible**. It is innervated by **fibers of C1 carried by the hypoglossal nerve (XII)**. It can help **retract** the mandible.

### INNERVATIONS OF IMPORTANT ORAL STRUCTURES

- A. Tongue: The sensory (**non-taste**) innervation of the anterior two-thirds of the tongue is by the **lingual branch of the mandibular nerve (V3)**. The taste sensation of the anterior two-thirds is by the **chorda tympani of the facial nerve (VII)** (except for the vallate papillae). Taste to the posterior one-third of the tongue and the vallate papillae and general sensation to the posterior third is provided by the **lingual branch of the glossopharyngeal nerve (IX)**. Some taste sensation to the posterior region of the

#### NOTE

Expect a number of questions in Dental Anatomy and Anatomic Sciences concerning the four major muscles of mastication.



**NOTE**

*Innervations are NBDE favorites!*

valleculae is provided by the **superior laryngeal nerve of the vagus nerve (X)**. Motor innervation to the entire tongue is provided by the **hypoglossal nerve (XII)**.

- B. Teeth:** Lower molar and premolar teeth are innervated by branches of the **inferior alveolar nerve of the mandibular nerve (V3)**. Lower incisors are innervated by the **incisal branches** of the same nerve. In the maxilla, there is overlap of innervation but generally the third through first molars receive innervation from the **posterior superior alveolar nerve of the maxillary nerve (V2)**. The first molar and premolars receive innervation from the **middle superior alveolar nerve of the maxillary nerve**. Canines and incisors are innervated by the **anterior superior alveolar nerve of the maxillary nerve**.
- C. Supporting tissue:** On the lower arch, lingual gingiva and supporting tissues are innervated by the **lingual nerve of the mandibular nerve (V3)**. Buccal surfaces in the molar region are innervated by branches of the **inferior alveolar nerve**, as well as branches of the **buccal nerve**. Those supporting tissues in the buccal areas anterior to the molars are innervated by branches of the **mental nerve**.

On the upper arch, the buccal supporting tissues are innervated by the **anterior, middle, and posterior superior alveolar nerves**, while those areas on the lingual (palatal) side are innervated by the **greater palatine nerve**, except in the incisal area, where they are innervated by the **nasopalatine nerve**.

### **SALIVARY GLANDS**

Saliva contains water, sodium, potassium, calcium, chloride, other mineral salts, immunoglobulins (especially secretory IGA), amylase, and mucopolysaccharides. It serves to lubricate, aid swallowing, digest starch to maltose, buffer acids, and cleanse the teeth and other oral structures.

**NOTE**

*Injections of anesthetic near the parotid can diffuse through the gland to the nearby facial nerve (VII).*

- A. Parotid:** This is the **largest** of the salivary glands and contains primarily **serous** (watery, non-mucous type) acini (secretory units). It has the **highest level of amylase** of any salivary gland. It produces approximately 30% of the total salivary volume. The parotid duct (**Stensen's duct**) opens into the oral cavity near the **upper second molars**. Innervation to the gland is as follows: Secretomotor nerve fibers originate in the **glossopharyngeal nerve (IX)**, pass in the **tympnic branch**, the **lesser petrosal nerve**, and synapse in the **otic ganglion**. **Postganglionic fibers** reach the gland in the **auriculotemporal nerve**. **Sympathetic fibers** reach the gland by travelling with the external carotid artery.
- B. Sublingual:** The **smallest** of the three major glands, with the **lowest amylase content** and the **highest mucus content**. It empties through 10 to 20 ducts in the floor of the mouth (Plica sublingualis). It is innervated by preganglionic fibers from the **chorda tympani** of the **facial nerve (VII)**.

They synapse in the **submandibular ganglion** and postganglionic fibers travel directly to the gland. Sympathetic fibers reach the gland by traveling with the facial artery.

- C. Submandibular: Intermediate between the parotid and sublingual in size (about half the size of the parotid), and composition (**mixed serous and mucous**). The sublingual duct (**Wharton's duct**) opens into the floor of the mouth on the sublingual papilla. Its innervation is the **same as that of the sublingual**.

## DEVELOPMENT AND GROWTH OF UPPER AND LOWER JAWS

- A. **Background.** Bones of the skull develop either by **endochondral ossification** replacing the cartilage or by **intramembranous ossification** in the mesenchyme.

1. The **endochondral bones** are:

- a. The bones at the base of the skull

- (1) Ethmoid bone
- (2) Inferior concha
- (3) Body, lesser wings, basal part of greater wings, and lateral plate of the pterygoid process of the sphenoid bone; petrosal part of temporal bone; basilar, lateral, and squamous portion of the occipital bone

2. The **intramembranous bones** are:

- a. Frontal bones
- b. Parietal bones
- c. Squamous and tympanic parts of temporal bone
- d. Parts of the greater wings and medial plate of the pterygoid process of the sphenoid bone
- e. Upper part of the squamous portion of the occipital bone

**Remember:** All the bones of the upper face develop by intramembranous ossification. The mandible develops as **intramembranous bone** lateral to the cartilage of the mandibular arch (Meckel's cartilage), except for the condyle, which is endochondral.

- B. The **maxilla**. The human maxilla is a derivative of two bones: the maxilla proper and the premaxilla. The premaxilla carries the maxillary incisor teeth and forms the anterior portion of the hard palate.

The upper jaw grows downward and forward due to appositional growth at the sutures of the maxillae and palatine bones.

- C. The **mandible**. Remember that the mandible, as well as the maxilla, is a derivative of branchial arch I. The mandible is first seen in the sixth week of embryonic life as a thin plate of bone lateral to Meckel's cartilage. The mandible develops by intramembranous ossification. Right through fetal life the mandible is a paired bone. Right and left mandibles are joined in

the midline by fibrocartilage in the **mandibular symphysis**. At the end of year one, the fibrocartilage ossifies and the mandible becomes one bone.

The lower jaw grows downward and forward due to appositional growth at the posterior border of the ramus of the mandible.

## TOOTH DEVELOPMENT

A. **Background.** The first sign of tooth development occurs at about 6 weeks of embryonic life. The embryo is now 11 mm long. There is a thickening of the oral epithelium. This thickening forms a band that runs along the outline of the future dental arches. This band or thickening is continuous around each arch and is called the dental lamina.

At certain points along the dental lamina there are further bulblike thickenings corresponding roughly to the location of the 20 maxillary and mandibular deciduous teeth. These bulblike thickenings are referred to as tooth buds.

A tooth bud consists of three parts:

1. Enamel organ—derivative of oral ectoderm. It produces tooth enamel.
2. Dental papilla—derivative of mesenchyme. It produces pulp and dentin.
3. Dental sac—derivative of mesenchyme. It produces cementum and periodontal ligament. *PDL*

**Remember:**

Enamel is an ectodermal derivative.

Dentin is a mesodermal (mesenchymal) derivative.

B. The **stages of tooth development** are named according to the shape of the epithelial part of the tooth and are: the **bud, cap, and the bell stages**.

1. **Bud stage.** This is the stage already mentioned, where there are ovoid swellings at 10 different points on each arch corresponding to the positions of the deciduous teeth.
2. **Cap stage.** The bud stage proliferates and expands; however, it does not expand everywhere equally. The result is a shallow invagination on the deep surface of the bud.

The following are seen during the cap stage:

a. **Outer and inner enamel epithelium**

- 1) Outer enamel epithelium = cuboidal cells on periphery of cap stage
- 2) Inner enamel epithelium = tall cells on concavity of cap

b. **Stellate reticulum.** Cells that lie between the inner enamel epithelium and outer enamel epithelium begin to separate by an increase in intercellular fluid and arrange themselves into a network. This network is called the stellate reticulum.

c. **Enamel knot.** Densely packed cells in center of enamel organ.



d. **Dental papilla.** As the epithelium of the enamel organ proliferates, the mesenchyme, partially enclosed by the invaginated portion of the inner enamel epithelium, proliferates. This mesenchyme further condenses to form the dental papilla.

**The dental papilla is the formative organ of the dentin and primordium of the pulp.**

e. **Dental sac.** As the enamel organ and dental papilla are developing, there also occurs a condensation of the mesenchyme surrounding these two structures. Gradually there appears a dense fibrous layer referred to as the dental sac.

**The dental sac derivatives are cementum and the periodontal ligament (PDL).**

3. **Bell stage.** As the invagination of the epithelium develops further and deepens, the enamel organ develops a bell-shaped appearance.

The following are seen during the bell stage:

- a. **Inner enamel epithelium.** Cells of the inner enamel epithelium will differentiate into ameloblasts.
- b. **Stratum intermedium.** Several layers of squamous cells between the inner enamel epithelium and the stellate reticulum. Their function is not clear but they seem to be essential if enamel is to be formed.
- c. **Stellate reticulum.** Looks the same as in the cap stage but has expanded more.
- d. **Outer enamel epithelium.** These cells eventually flatten to low cuboidal cells.
- e. **Dental lamina.** All teeth except for the permanent molars; there is a proliferation of the dental lamina to give rise to the enamel organs of the permanent teeth.
- f. **Dental papilla.** Cells close to the inner enamel epithelium within the dental papillae differentiate into odontoblasts. The odontoblasts will lay down the dentin.
- g. **Dental sac.** The dental sac now shows a circular arrangement of its fibers and resembles a capsular structure. When the root develops, fibers of the dental sac will differentiate into the periodontal fibers that will become embedded in cementum and alveolar bone.
- h. **Vestibular lamina.** There occurs an epithelial thickening, labial and buccal, to the dental lamina. This is the vestibular lamina. It will hollow and form the oral vestibule between the alveolar portion of the jaws and the lips and cheeks.

The sequence is as follows:

- (1) Cells of the inner enamel epithelium differentiate into ameloblasts (morphogenic stage).
- (2) Some protein factor is transported from the ameloblasts across the basement membrane into the dental papilla (organizing stage).

m. 2. 3. 4. 5. 6. 7. 8. 9. 10. 11. 12. 13. 14. 15. 16. 17. 18. 19. 20. 21. 22. 23. 24. 25. 26. 27. 28. 29. 30. 31. 32. 33. 34. 35. 36. 37. 38. 39. 40. 41. 42. 43. 44. 45. 46. 47. 48. 49. 50. 51. 52. 53. 54. 55. 56. 57. 58. 59. 60. 61. 62. 63. 64. 65. 66. 67. 68. 69. 70. 71. 72. 73. 74. 75. 76. 77. 78. 79. 80. 81. 82. 83. 84. 85. 86. 87. 88. 89. 90. 91. 92. 93. 94. 95. 96. 97. 98. 99. 100.

m. 2. 3. 4. 5. 6. 7. 8. 9. 10. 11. 12. 13. 14. 15. 16. 17. 18. 19. 20. 21. 22. 23. 24. 25. 26. 27. 28. 29. 30. 31. 32. 33. 34. 35. 36. 37. 38. 39. 40. 41. 42. 43. 44. 45. 46. 47. 48. 49. 50. 51. 52. 53. 54. 55. 56. 57. 58. 59. 60. 61. 62. 63. 64. 65. 66. 67. 68. 69. 70. 71. 72. 73. 74. 75. 76. 77. 78. 79. 80. 81. 82. 83. 84. 85. 86. 87. 88. 89. 90. 91. 92. 93. 94. 95. 96. 97. 98. 99. 100.

m. 2. 3. 4. 5. 6. 7. 8. 9. 10. 11. 12. 13. 14. 15. 16. 17. 18. 19. 20. 21. 22. 23. 24. 25. 26. 27. 28. 29. 30. 31. 32. 33. 34. 35. 36. 37. 38. 39. 40. 41. 42. 43. 44. 45. 46. 47. 48. 49. 50. 51. 52. 53. 54. 55. 56. 57. 58. 59. 60. 61. 62. 63. 64. 65. 66. 67. 68. 69. 70. 71. 72. 73. 74. 75. 76. 77. 78. 79. 80. 81. 82. 83. 84. 85. 86. 87. 88. 89. 90. 91. 92. 93. 94. 95. 96. 97. 98. 99. 100.

- (3) Cells of the dental papilla differentiate into odontoblasts under the influence of this inducing factor.
- (4) The odontoblasts begin to lay down pre-dentin.
- (5) Through a reciprocal factor transported across the basement membrane, the ameloblasts can now lay down their initial enamel, which will later mineralize to form enamel (formative stage).

C. **Root formation.** The development of the roots begins after enamel and dentin formation has reached the future CEJ (cemento-enamel junction). The enamel organ plays a crucial role in root formation. The enamel organ forms the **epithelial root sheath of Hertwig**. The components of this root sheath are fused inner and outer enamel epithelium only. There is no stratum intermedium or stellate reticulum present. The root sheath molds the shape of the roots and initiates dentin formation. When the cells of the root sheath have induced the differentiation of connective tissue cells into odontoblasts and the first layer of dentin has been laid down, the root sheath loses its continuity and begins to degenerate. It does not disappear altogether, however, and remnants of the root sheath of Hertwig are called the **Rests of Malassez**. These rests may form granulomas in pathological processes or they form cementicles if they become calcified. The rests of Malassez will only be found in the periodontal ligament.

How is cementum formed? Remember that cementum is a derivative of the dental sac, which is a derivative of mesenchyme. It is formed when cells of the primitive periodontal connective tissue come into contact with the dentin after the root sheath of Hertwig has broken up. These cells, similar to fibroblasts, differentiate into cementoblasts and begin to lay down cementoid, which subsequently mineralizes to form cementum. Some of the cells in the apical 1/3 of the root structure become entrapped in their own secretions. This region of mature cementum will contain cells within it and will hence be referred to as cellular cementum. The occlusal 2/3 of the root structure usually possesses acellular cementum.

**TOOTH COMPONENTS: ENAMEL, DENTIN, CEMENTUM, AND PULP**

- A. **Enamel**—hardest structure of the body; an ectodermal derivative; laid down first as "enamelin" by the ameloblasts.
  1. Color: yellow white to grayish white.
  2. Chemical composition: 96% inorganic (main constituent = hydroxyapatite); 1% organic; 3% water.

The enamel forms a protection over the entire surface of the crown. It is well-adapted to bear up under masticatory stresses. Enamel is a brittle structure as well as being very hard. Enamel has been shown to be permeable and this permeability decreases as one gets older.

**NOTE**

Dentin is much more "bone-like" histologically than is enamel.

The enamel consists of thin rods or prisms that stand upright on the surface of the dentin. After a wavy course, they reach the enamel surface and are perpendicular to the enamel surface at every point on the crown. Every rod runs through the entire thickness of the enamel layer. The enamel rods or prisms and the "interprismatic" substance have been shown to be composed of apatite crystals and a bit of organic material. The more or less regular change in the direction of the enamel rods is responsible for the appearance of Hunter-Schreger bands or the Lines of Schreger.

In a cross-section of the crown, the enamel shows concentric lines, which are brown in transmitted light and colorless in reflected light. In longitudinal section they run obliquely inward from the surface and toward the root. These are the lines of Retzius or incremental lines of Retzius. They illustrate the incremental pattern of enamel, i.e., the successive apposition of layers of enamel during formation of the crown. The incremental lines of Retzius have been compared to the growth rings on a tree.

Other enamel structures with which to be familiar are:

- a. **Perikymata.** These are transverse, wavelike grooves thought to be external manifestations of the striae (lines) of Retzius. They are continuous around the tooth and lie parallel to each other and to the CEJ.
  - b. **Enamel spindles.** Some dentinal tubules penetrate a short distance into the enamel and end blindly. These spindle-shaped odontoblastic processes are called enamel spindles.
  - c. **Tomes processes.** The surfaces of the ameloblasts facing the developing enamel are not smooth. There is an interdigitation of the cells and the enamel rods they produce. This interdigitation is due to the fact that the long axes of the ameloblasts are not parallel to the long axes of the rods. The projections of ameloblasts into the enamel matrix are referred to as **Tomes processes**. Local disturbances of the enamel during development cause the enamel lamellae and tufts.
  - d. **Enamel lamellae.** Thin structures of organic material (very little mineral content) extending from the surface of the enamel toward and sometimes into the dentin. These usually develop in areas of tension between enamel prisms.
  - e. **Enamel tufts.** These extend from the dentinoenamel junction (DEJ) into the enamel for one-fifth to one-third of its thickness. The tuft shape, however, is an optical illusion due to the projection onto one plane of fibers lying in different planes. Tufts are basically hypocalcified enamel rods and interprismatic substance.
3. Age changes in enamel.
- a. Attrition or wear of occlusal surfaces and proximal contact points due to mastication

---

**NOTE**

*Age changes in enamel are commonly asked about.*

- b. Flattening of perikymata and disappearance of the rod ends
- c. Eventual disappearance of the perikymata
- d. Decreased permeability of enamel
- e. Teeth become darker and more resistant to decay.

Remember that enamel development occurs in two phases: *DEF:*

- 1) Matrix formation — *enamel hypoplasia*
- 2) Maturation — *enamel hypocalcification*

If there are developmental disturbances in matrix formation, enamel hypoplasia will result, i.e., a defect in enamel itself.

If there are developmental disturbances in maturation, or if maturation is lacking or not complete, enamel will be hypocalcified, i.e., a deficiency in the mineral content of the enamel.

**B. Dentin**—mesodermal derivative from dental papilla; laid down first as pre-dentin by odontoblasts; harder than compact bone although it resembles bone in its structure, chemical nature, and development.

- 1. Color: yellowish to semitransparent in fresh condition
- 2. Chemical composition: 70% inorganic material; 30% organic material and water

Unlike enamel, which is very hard and brittle, dentin is subject to slight deformation and is somewhat elastic. It is harder than compact bone, yet softer than enamel. In ground sections of dentin, the dentin has a radially striated appearance. This is due to the presence of dentinal tubules. The course of the dentinal tubules is somewhat curved and resembles an "S" shape. They start at right angles from the pulp surface and then follow their "S" shaped course.

Remember: The tubules are farther apart in the peripheral layers of dentin (near the enamel and cementum). The dentinal tubules house the odontoblastic processes (Tomes fibers). You should be familiar with the following terms:

- a. **Peritubular dentin.** The zone of dentin immediately surrounding the odontoblastic process. This stains darker in a histological preparation. It is thought that this dentin is more mineralized than is the intertubular dentin.
- b. **Intertubular dentin.** The main bulk of dentin is composed of intertubular dentin. Even though it is fairly mineralized, greater than one-half of its volume is taken up by organic matrix. (The matrix of dentin is basically collagenous fibers enveloped in an amorphous ground substance.)
- c. **Incremental lines of Von Ebner.** Seen as fine lines that in cross-section run at right angles to the dentinal tubules. They correspond to the lines of Retzius in enamel and represent the incremental apposition of the dentin layers. Also known as imbrication lines.



d. **Contour lines of Owen.** Sometimes the incremental lines mentioned above are accentuated due to disturbances in the mineralization process. These lines are known as the contour lines of Owen. An exaggerated incremental line or contour line of Owen due to the trauma of birth is known as the **neonatal line**.

e. **Interglobular dentin.** You may remember that the odontoblasts first produce a matrix material known as pre-dentin, which will subsequently mineralize. (The first sign of pre-dentin formation is the laying down of a fan-like arrangement of collagen fibers known as Korff's fibers.) This mineralization begins in small globular areas that normally fuse to form a uniformly calcified dentin layer. If fusion of these globular areas does not take place, there will be hypomineralized or unmineralized regions between the globules referred to as interglobular dentin.

Note: Interglobular dentin is found mainly in the crown near the dentinoenamel junction (DEJ). This does not interfere with the course of the dentinal tubules.

f. **Tomes granular layer.** Minute areas of interglobular dentin in the dentin subjacent to cementum.

Dentin is sensitive to touch, to cold, and to acid-containing foods. Only occasional nerve fibers penetrate the dentin and extend for short distances. These are small unmyelinated nerve fibers that are in close contact with the odontoblastic process.

3. **Age and functional changes in dentin.** Remember that the dentin houses the odontoblastic processes and is certainly a vital tissue. The effects of aging or pathologic processes are seen by deposition of new layers of dentin (reparative dentin) and by alteration of the original dentin (sclerotic dentin).

You must be familiar with the following:

a. **Secondary dentin.** Remember that dentin deposition may continue throughout life. The dentin formed in later life is separated from that previously formed by a darkly stained line. The tubules of this secondary dentin are more wavy but less numerous than the original dentin. They are also naturally found closer to the pulp tissues.

b. **Reparative dentin.** Remember that dentin is a vital tissue. If by excess wear, erosion, caries, operative procedures, etc., the odontoblastic processes are cut or damaged, the damaged odontoblast may degenerate or it may continue to form hard dentin as a protection from further injury. If the odontoblast degenerates, it may be replaced by an undifferentiated cell from the pulp, which will produce new dentin. The dentin that these odontoblasts lay down is reparative dentin. The tubules of this dentin are twisted and fewer of them exist.

---

#### NOTE

*The pulp is <sup>a</sup>living tissue and can produce new dentin through stimulation of odontoblasts at any age.*



**NOTE**

The compact bone containing Sharpey's fibers is often termed "bundle bone."

- c. **Sclerotic dentin.** Seen in the teeth of elderly people. This dentin is **transparent** and results from calcium salts being deposited in or around degenerating odontoblastic processes. The calcium salts may even obliterate the tubules.
- C. **Cementum**—a mesodermal derivative; derives from dental sac; laid down first as cementoid by cementoblasts
1. Color: light yellow, lacks luster that enamel possesses
  2. Chemical composition: 45–50% inorganic (mainly hydroxyapatite); 50–55% organic material and water
  3. There are two types of cementum:
    - a. **Acellular cementum**—occlusal 2/3 of root structure. Consists of calcified intercellular substance and embedded Sharpey's fibers. Cementoblasts line its structure.
    - b. **Cellular cementum**—found in apical 1/3 of root. The cells included in cellular cementum are cementocytes. They lie in spaces called lacunae. The cell body has long processes ("canaliculi") extending from it. These processes may branch and anastomose with neighboring cells. There are no Haversian systems in cementum, however.
  - c. **Secondary cementum**—due to severe trauma or pathological processes, cementum may resorb. If it does, cells of the PDL differentiate into cementoblasts and lay down secondary cementum. Secondary cementum can be resorbed more easily. Secondary cementum resembles cellular cementum in some ways.  
Remember: Cellular cementum, secondary cementum, and bone are similar in that they contain cells in lacunae, have canaliculi that extend primarily toward the nutritional source and can be resorbed. Cementum, however, resorbs less than bone.
4. The **cemento-enamel junction (CEJ)**
    - a. In 30% of teeth, the cementum meets the cervical end of enamel in a sharp line.
    - b. In 60% of teeth, the cementum overlaps the cervical end of enamel for a short distance.
    - c. In 10% of teeth, other aberrations of the CEJ can be observed.
  5. **Function of cementum**
    - a. Anchors tooth to the bony socket by attachment of fibers (Sharpey's fibers)
    - b. Compensates by means of its growth for loss of tooth substance due to occlusal wear
    - c. Contributes, via growth, to the continuous occlusomesial eruption of the teeth  
Remember that cementum is not resorbed under normal conditions, whereas bone is resorbed constantly with the apposition of new bone. Both cementum and bone resorb on the pressure side (side to which tooth is moved) and are laid down on the tension

side (side from which tooth is moved away) of tooth movement.

To repeat, cementum is more resistant to resorption than is bone.

6. **Hypercementosis.** This is an abnormal thickening of cementum. This is seen occasionally in connection with chronic periapical inflammation. A thickening of cementum is also observed on teeth that are not in function (hypofunction)

D. **Pulp**—of mesodermal origin; derives from dental papilla. The pulp contains most of the cellular and fibrous elements that are present in loose connective tissue.

**The primary function of the pulp is the production of dentin.**

- The pulp has the following functions:
  - Nutritive.** Pulp provides nourishment to dentin via the odontoblasts and processes.
  - Sensory.** Nerves of pulp contain both sensory and GVE (general visceral efferent or sympathetic) fibers. The sensory fibers of the pulp mediate the sensation of pain only. Sympathetics go to the smooth muscle of the pulpal blood vessels.
  - Defensive.** It was noted that cells of the pulp could, if provoked, differentiate into odontoblasts and produce reparative dentin. The pulp can also respond to injury by an inflammatory process. Remember that the pulp is a non-expandable tissue. The walls of the pulp chamber are made of rigid dentin. If there is severe inflammation and there is enough edema and exudative fluid, the pulp may "strangle" its own blood vessels and necrose. This is an example of where the protective wall around the pulp can be seen as a disadvantage.
- In the **embryonic pulp**, the fibers are argyrophilic. There are no mature collagenous fibers. As the development of the tooth germ progresses, the pulp becomes increasingly vascular and fibroblasts differentiate from the primitive mesenchymal cells.
- In **adult pulp**, one sees cells, fibroblasts, and an intercellular substance. This intercellular substance consists of collagenous and argyrophilic fibers and ground substance. **There are no elastic fibers in the pulp.** There are defense cells (histiocytes) in the pulp, and remember that the odontoblasts are a part of the dental pulp. There are numerous capillary and nerve plexi found in the pulp.
- Blood and lymph vessels.** Pulp is extremely vascular. The vessels enter the pulp through the apical foramen. The vessels of the pulp communicate with the vessels of the PDL via accessory canals. Lymph vessels are also found in the pulp.
- Nerves.** Usually nerve bundles follow blood vessels. Most nerve fibers entering the pulp are myelinated. They mediate pain. The unmyelinated fibers belong to the sympathetic nervous system and regulate the lumen size of the blood vessels.

---

#### NOTE

*Due to the type of sensory nerve fibers in the pulp, cold, heat, chemicals, and touch sensation are all interpreted as pain.*

Remember that the pulp cannot differentiate between heat, touch, cold, pressure, or chemicals. **The result is pain only.**

6. Age changes within the pulp
  - a. **Pulpstones** (denticles) seem to be normal structures seen frequently in the adult pulp. Classified as true denticles, false denticles, or diffuse calcifications. **True denticles** show real dentin structure with tubules, etc. **False denticles** do not show the structure of dentin. They only show concentric layers of calcified tissue. **Diffuse calcifications** can be large and are very amorphous calcifications usually associated with collagen fiber bundles or blood vessels. Pulpstones may also be classified as **free** (surrounded by pulp tissue completely), **attached** (fused to dentin), or **embedded** (surrounded entirely by dentin).

### **THE TEMPOROMANDIBULAR JOINT**

The temporomandibular joint is a bilateral diarthrosis between the **articular tubercle eminence** of the temporal bone and the condyle of the mandible. It is a ginglymoarthrodial joint (a sliding, hinge joint).

A fibrous plate, the **articular disc**, is interposed on either side between the articular surfaces of the two bones. The articular surface of the temporal bone is concave in its posterior portion and convex in the anterior portion. The articular surfaces of the mandibular condyles are arc-shaped with their axes placed medially and slightly posterior.

Remember: The articulating surfaces of the temporomandibular joint are covered by a fibrous connective tissue—NOT by hyaline cartilage (as are most other articulations in the human body).

The nerves of the TMJ are derived from the **auriculotemporal branch** and **masseteric branch** of the mandibular division of the fifth cranial nerve (trigeminal). The arterial supply to the joint itself is from the superficial temporal branch of the external carotid artery.

#### **A. Bone structure**

1. **Condyle**. Cancellous bone covered by a thin layer of compact bone. Marrow is red except in older individuals where it may be replaced by fatty marrow.
2. **Glenoid (mandibular) fossa**. Roof of fossa consists of a thin layer of compact bone.
3. **Articular tubercle**. Consists of spongy bone covered with a thin layer of compact bone.

Remember that the walls of the mandibular fossa are thin and may be perforated by the condyles in severe trauma.

- B. **Articular disc.** Composed of dense fibrous connective tissue with a few elastic fibers present. With increasing age, cartilage may be seen in the disc as well. The center of the disc is very dense connective tissue; no blood vessels.

NOTE: The fibrous tissue covering the articular eminence and mandibular condyle as well as the large central dense area of the disc lacks blood vessels and nerves. The posterior border of the disc is connected to the capsule by loose connective tissue. Its medial and lateral corners are directly attached to the poles of the condyle.

The articular space is divided into two compartments by the disc—a lower compartment between the condyle and the disc (hinge movement, rotation) and an upper compartment between the disc and the temporal bone (sliding movement, translation). The disc is shaped like an erythrocyte—biconcave with the central portion thin and the anterior and posterior borders thickened. **Note that some of the fibers of the lateral pterygoid muscle attach to the anterior border of the disc.**

- C. **Articular capsule.** This is a fibrous sac strengthened laterally by the temporomandibular ligament. The inner surface of the capsule is lined by a **synovial membrane**. Remember that the synovial membrane (mesothelial cells that secrete hyaluronic acid-synovial fluid) lines the joint spaces both upper and lower. The capsule contains numerous blood vessels that form a capillary network close to its surface.
- D. The ligaments associated with TMJ
1. Disc. Already discussed
  2. Capsule. Already discussed
  3. **Temporomandibular (lateral) ligament.** Consists of two short fibrous bands attached to the lateral surface of the zygomatic arch and to the tubercle on its inferior border **superiorly**, and to the lateral surface and posterior border of the neck of the mandible **inferiorly**.
  4. **Sphenomandibular ligament.** Thin band that is attached to the spine of the sphenoid bone and descends to the lingula of the mandibular foramen.
  5. **Stylomandibular ligament.** Extends from near the apex of the styloid process of the temporal bone to the angle and posterior border of the ramus of the mandible.

---

**NOTE**

*The TMJ ligament's function is not totally clear. Some view their function as protective; others claim that the ligaments serve as limits to excessive mandibular movement.*

## THE ATTACHMENT APPARATUS

The attachment apparatus consists of:

1. Cementum
  2. The periodontal ligament
  3. The alveolar bone
1. Cementum

We have already discussed cementum. Let us turn our attention to the other two topics here.

2. The Periodontal Ligament (PDL)

The periodontal ligament (also referred to as the periodontal membrane) is the connective tissue that surrounds the root of the tooth and attaches the root of the tooth to the bony alveolus. Remember that the PDL is continuous with the gingival connective tissue. The functions of the PDL are:

1. **Formative**—The cementoblasts, fibroblasts and osteoblasts derive from cells in the PDL
2. **Supportive**—maintains tooth in its position and normal relationship
3. **Sensory**—extremely good innervation in PDL
4. **Nutritive**—extremely good blood supply within the PDL

Remember the PDL derives from mesoderm and is a direct derivative of the dental sac.

The main structural elements within PDL are the **principal fibers**. These principal fibers are all attached to the cementum. The fibers are collagen fibers and they cannot be lengthened. **There are no elastic fibers in the PDL.** The apparent "elasticity" of the PDL is due to the wavy course of the fibers from bone and cementum. The fiber bundles run directly from bone to cementum. The bundles are spliced and chemically bound all together from shorter fibers in the **Intermediate Plexus**, which is approximately midway between the bone and cementum. This allows for the continuous eruption of a tooth during its functional stage. **Fiber types are described in "Periodontium" section.**

**Blood supply of the PDL:** From 3 main sources.

1. Periosteal blood supply from alveolar bone—**major source**
2. Arteries of gingiva, which anastomose with PDL—**minor source**
3. Arteries of the periapical area, which arise from vessels going to the pulp

**Lymphatics of the PDL**—These follow the blood vessels. The flow of lymph is from the ligament toward and into the alveolar bone.

**Nerves of the PDL**—Nerves follow the path of blood vessels. There are different types of nerve endings in the PDL, including free nerve endings that are receptors for pain. Many nerve endings are receptors for proprioceptive stimuli. Remember that proprioceptive information regulates the masticatory musculature and protects the tooth from a sudden overload due to severe masticatory stresses.

Remember that the Epithelial Rests of Malassez are found in the PDL. These are the remnants of the epithelial root sheath of Hertwig. These may become ill-defined calcified masses or cementicles. The epithelial masses also might have the potential to form granulomas or cysts.

**The PDL is narrowest in the middle region of the root and widest in its cervical region.**

What happens to the Periodontal ligament during loss of function or during occlusal trauma?

Table 1-14.

<b>In loss of function</b>	<p>The PDL narrows</p> <p>The regular arrangement of the fibers is lost</p> <p>The PDL is changed into a thin membrane with irregularly arranged collagenous fibers</p> <p>The cementum may become thicker (hypercementosis)</p>
<b>In occlusal trauma</b>	<p>Alveolar bone is resorbed</p> <p>The PDL is widened (PDL space is increased)</p> <p>Tooth becomes loose</p> <p>If trauma is removed, some repair will usually take place.</p>

## THE ALVEOLAR PROCESS

The alveolar process is that part of the mandible and maxilla that forms and supports the sockets of the teeth. There is no anatomic boundary between the body of the maxilla or mandible and their respective alveolar processes.

There are 2 parts of the alveolar process:

- 1. Alveolar bone proper**—consists of thin lamellar bone that surrounds the root of the tooth and gives attachment to the principal fibers of the PDL.
- 2. Supporting alveolar bone**—this surrounds the alveolar bone proper and gives support to the socket.

The supporting alveolar bone is divided into two parts:

- 1. Cortical plates**—compact bone. These form the outer and inner plates of the alveolar processes.

2. **Spongy bone**—fills in the area between the cortical plates and alveolar bone proper.

Remember that the marrow spaces of the alveolar process may contain **hematopoietic marrow**, but usually they are found to contain **fatty marrow**. Hematopoietic marrow may be found in the adult in the condylar process, the angle of the mandible, the maxillary tuberosity, and in other areas.

The alveolar bone proper forms the inner wall of the socket and is perforated by many small openings that carry branches of the interalveolar nerves and blood vessels into the PDL. Therefore it is also called the **cribriform plate**. The alveolar bone proper consists of both lamellated bone and bundle bone. (Bundle bone is that bone in which the principal fibers of the PDL are attached [Sharpey's fibers].)

Remember that the bone of the alveolar housing is like any other bone. It is constantly undergoing the processes of resorption and apposition. We discussed both these processes previously in our discussion of bone histology.

## **ORAL MUCOUS MEMBRANE**

The oral cavity is lined throughout by a mucous membrane. Even though the mucous membrane is **roughly** similar in all places, the structure does differ slightly in different areas to correlate with the functions of these areas.

The oral mucous membrane is composed of surface epithelium and underlying lamina propria. Under this mucous membrane is the submucosa, which also differs from place to place depending on the function of the particular area. Let's discuss the surface epithelium. The epithelium may be categorized as **keratinized** or **non-keratinized**. A full keratinization potential does not present in mucosal cells under normal conditions except in **masticatory mucosa**, although it may be expressed in any area under irritation. Because the keratinization potential does not present in the majority of mucosal cells, the stratum granulosum and corneum are not seen.

The layers of the epithelium are as follows:

1. **Basal cell layer**—A single layer of high cuboidal cells, which rest on a **basement lamina** consisting of an amorphous relatively thick mass called the **lamina densa**. The **lamina densa** is separated from the basal cells by a space 250-450Å wide called the **lamina lucida**. There are anchoring fibrils, which are believed to connect the lamina densa to the underlying connective tissue. The basal cell layer is the "**mitotic**" layer of cells.



2. **The spinous cell layer (prickle cell layer)**—The cells of this layer are irregularly polyhedral and larger in non-keratinized areas than in keratinized zones. The name “prickle cell layer” came to exist due to the artifact induced by the fixative, in which desmosomal attachments remain intercellularly, but the remainder of the cell membrane “pulls away” from the approximating cell. The spinous cell has a vesicular nucleus and one or more nucleoli and is involved in synthesis.

Toward the surface, the polyhedral cells of the prickle cell layer flatten and widen considerably. **No further changes occur in the non-keratinizing epithelium.** If the epithelium is keratinized, the cells of the prickle cell layer flatten and pass first into the:

3. **Stratum Granulosum**—Flattened cells contain granules analyzed to contain keratohyaline.
4. **Stratum Lucidum**—There is no discernable stratum lucidum in the oral cavity. This layer appears in the epidermis of thick skin (palms, soles) and not in oral mucous membrane.
5. **Stratum Corneum**—Cells have lost their nuclei. They are very flattened and filled with keratin.

To recap what we have just said:

**Keratinized Epithelium—**

- Stratum basale (basal cell layer)
- Stratum spinosum (prickle cell layer)—well developed
- Stratum granulosum
- Stratum corneum

**Non-Keratinized Epithelium—**

- Stratum basale
- Stratum spinosum—not particularly well developed.

Keratinization potential is expressed in the **masticatory mucosa**.

Table 1-15.

Masticatory Mucosa	Nonmasticatory Mucosa
Hard Palate	Soft Palate
Attached gingiva	Ventral surface of tongue
	Floor of mouth
Free gingiva (some)	Alveolar mucosa
	Cheek, Lip
	Free gingiva (some)

Keratinization potential may also be expressed in areas of irritation as we mentioned before. There is no keratinization potential expressed on any mucosa that abuts against a hard surface. For example, the oral sulcular epithelium abuts against a hard surface—tooth structure—and there is no keratinization here.

The **lamina propria** is a layer of dense connective tissue of variable thickness. Its papillae, which indent the epithelium, carry both blood vessels and nerves. Between the connective tissue papillae are the **epithelial rete pegs**. The papillae of the lamina propria vary considerably in length and width in different areas. The arrangement of the papillae increases the area of contact between the blood vessels and epithelium.

The **submucosa** consists of connective tissue of varying thickness and density. It attaches the mucous membrane to the underlying structures. Glands, blood vessels, nerves, and adipose tissue are present in this layer.

It is important for you to note the difference between the skin of the lip and mucous membrane. The transition zone between these two is the **vermillion border of the lip**.

Table 1-16.

The Skin of the Lip	The Transition Zone
Keratinized epithelium of moderate thickness	Keratinization ends here
Papillae of connective tissue—few and short	Long papillae carrying large capillary loops close to surface
Sebaceous glands in association with hairs	Few sebaceous glands
Sweat gland present	

Remember the epithelium of the mucous membrane of the lip is not keratinized.

Let's now talk of our 3 classifications of mucosa:

1. Masticatory Mucosa
2. Lining Mucosa
3. Specialized Mucosa

**Masticatory Mucosa**—By definition this is the attached gingiva and the hard palate. Both have thick and keratinized epithelium; thick, dense and firm lamina propria; and immovable attachment to deep structures. Remember that gingiva can be either orthokeratinized (true keratin) or parakeratinized (the keratinized cells retain their nuclei). In the gingiva one cannot distinguish a well-defined submucosa. There is instead a dense, inelastic connective tissue of the lamina propria that fuses with the periosteum of the alveolar bone.

There is a **definite submucosa** in the hard palate except for a narrow area along the midline (the palatine raphé). Even though there is a submucosa, the mucous membrane is **immovably** attached to the periosteum of the maxillary and palatine bones. The reason for this is that

there are dense bands of fibrous tissue that join the lamina propria to the periosteum. The submucous space in the palate is filled with **adipose tissue** anteriorly and with **glands** posteriorly.

Let's now discuss the **gingiva** in more detail.

The gingiva is the tissue that surrounds the tooth. It is very well adapted to the forces of friction and pressure in the masticatory process. The gingiva is bound to tooth structure via a fibrous attachment. It is also bound to alveolar bone by dense fibrous connective tissue bundles. Note the **mucogingival junction** that separates the gingiva from **alveolar mucosa**. Note the **free gingival groove** that divides **free gingiva** from the **attached gingiva**. This groove develops at the level a bit apical to the bottom of the **gingival sulcus**. Be able to identify the **oral sulcular epithelium**, the area of the **epithelial attachment**, and the **interdental papillae**. Just a note on the **interdental papilla**. This fills the space between two adjacent teeth. It is tent-shaped. The buccal and lingual corners are high, whereas the central part resembles a valley. This central concave area is called the **col**. The col area is covered by **non-keratinized epithelium** and is susceptible to periodontal breakdown and disease.

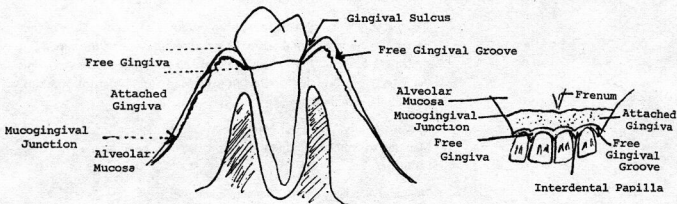


Figure 1-38. The gingival and mucosal units.

In health the gingiva appears to have a "stippled" or orange peel appearance. This is due to the presence of numerous rete pegs and connective tissue papillae in between.

The color of the gingiva is normally a "coral" color or pink color. This color really depends on the thickness of the epithelium. The color depends also on the activity of the **melanocytes**, which lie dispersed between the cells of the basal cell layer. In histologic section, the **melanocyte** is described as a "clear cell." Melanocytes supply preformed **melanosomes** to adjacent keratinocytes via **dendritic processes**. Each

*gingiva btkb → Melanin*

melanocyte is responsible for pigment in a certain area. Remember the **number of melanocytes per unit of mucosa (or skin) does not vary between races and the difference in pigmentation is due to the degree of synthetic activity of the cells.**

The melanocyte derives from the melanoblast, a cell that originates in the primitive neural crest region. Melanin is a derivative of the chemical breakdown of tyrosine.

The **lamina propria** of the gingiva is dense connective tissue that is not very vascular. **Macrophages** are present in the perivascular loose connective tissue of **normal gingiva**.

The gingiva contains dense collagen fiber bundles designated:

- a. **Gingival ligament**—From cervical cementum into the lamina propria of the gingiva. These fibers are the most numerous of gingival fibers.
- b. **Circular fiber group**—These fibers circle the tooth and intermesh with other fibers.
- c. **Alveologingival group**—From alveolar crest and extend into lamina propria.
- d. **Dentoperiosteal group**—From cementum into the periosteum of the alveolar crest and oral surfaces of the alveolar bone.

Blood supply of gingiva—Chiefly from branches of alveolar arteries that penetrate the interdental septa. These anastomose with the superficial branches of arteries that supply the oral and vestibular mucosa or gingiva. **The lymph vessels of the gingiva lead to submental and submandibular lymph nodes.**

Nervous innervation—The gingiva is well supplied with nerve endings. Meissner's corpuscles and Krause corpuscles have been seen in the gingival tissues.

#### **The gingival sulcus and the dentogingival junction**

The gingival sulcus—a shallow furrow that is found between the gingival margin and the tooth surface. The sulcus is bounded on one side by "**sulcular epithelium**"—this is the non-keratinized extension of the oral epithelium into the sulcus. The bottom of the sulcus is formed by the coronal surface of the **junctional epithelium**.

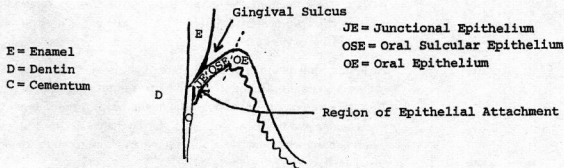


Figure 1-39. The gingival sulcus.

The junctional epithelium unites the gingival connective tissue to the enamel surface from the neck (cervix) of the tooth to the bottom of the gingival sulcus.

The histogenesis of the **dentogingival junction** is as follows:

After the enamel matrix has been completely deposited, the ameloblasts become shortened. The epithelial cells derived from the enamel organ, including the reduced ameloblasts and cells adjacent to their proximal surface, form the **reduced enamel epithelium**. Just before eruption, the tooth is completely covered with reduced enamel epithelium. As the tooth erupts and approaches the oral epithelium, the outer cell layers of the reduced enamel epithelium begin to divide. These epithelial cells have a very high turnover rate. As the crown is about to break into the oral cavity, the reduced enamel epithelium appears to fuse with the oral epithelium. Soon after, the epithelium over the enamel becomes entirely made up of **junctional epithelium**, which is produced primarily by proliferation of the outer cells of the reduced enamel epithelium. The reduced ameloblasts become very flat and look like squamous epithelial cells. They cannot divide and are eventually displaced by the outer cells of the reduced enamel epithelium that gives rise to most of the junctional epithelium. Remember that when reduced ameloblasts can no longer be recognized as such within the epithelium lining, the enamel surface, the epithelium, is now called the junctional epithelium.

A **dental cuticle** is sometimes seen between the junctional epithelium and the adjacent tooth surface. This appears to be the last product secreted by the **reduced ameloblasts**.

The connection between the enamel and epithelium has been an area of dispute for many years. Electron microscopy has helped out considerably. It appears now that at the end of enamel maturation the plasma membrane of the ameloblasts in contact with the enamel surface develops **hemidesmosomes**. The space between the cell membrane and the enamel surface is occupied by a **basement lamina** joining the cells to the enamel.

NOTE: The hemidesmosomes and basement lamina are referred to as the epithelial attachment. This attachment is normally at the level of the CEJ.

A similar attachment is found between the external surface of the reduced enamel epithelium and the surrounding connective tissues. Therefore, the basement lamina next to the tooth is the **internal basement lamina** and the basement lamina facing the connective tissue is the **external basement membrane**. So, in summary, from tooth to connective tissue we have the following:

external surface/dental cuticle/internal basement lamina/junctional epithelium/external basement lamina/gingival connective tissue.

The junctional epithelium is thin and non-keratinized. It lacks well defined epithelial ridges. It is for this reason that the junctional epithelium is susceptible to breakdown by bacterial metabolites. Sulcular fluid also escapes through the junctional epithelium, and this is looked upon as an inflammatory exudate rather than a physiologic secretion. This fluid contains inflammatory cells from the gingival tissues. Lymphocytes and plasma cells are routinely seen in the connective tissues at the bottom of the gingival sulcus. This certainly is evidence of a defense reaction in response to the constant presence of bacteria in the gingival sulcus and of a barrier against the invasion of bacteria and penetration of their harmful metabolites.

Finally, remember that there will be an apical movement of the epithelial attachment from the CEJ in periodontal disease.

**HARD PALATE**—The epithelium of the hard palate is keratinized and possesses long rete pegs. The hard palate contains a defined submucosa; however, the tissue is immovable because it is tightly bound down to the underlying periosteum. Remember that the anterior part of the hard palate contains much adipose tissue and the posterior part of the hard palate is full of glands.

## THE LINING MUCOSA

All zones of lining mucosa are characterized by thick non-keratinized epithelium and thin lamina propria. In those regions where the lining mucosa pulls away from the moveable lips and cheeks, the submucosa is quite loose. However, when the lining mucosa covers muscles on the lips, cheeks, and ventral surface of the tongue, the submucosa is fixed to the epimysium or fascia of respective muscles. The mucous membrane on the oral surface of the soft palate is highly vascularized and therefore very red in color. The papillae of the connective tissue are few and short. There is a distinct zone in the lamina propria where elastic fibers are located. The lamina propria is full of glands and the tissue is very loose in general. The alveolar mucosa is lining mucosa and you should be aware of the differences between alveolar mucosa and attached gingiva. The

Prof. D. Esser S.

alveolar mucosa is separated from the attached gingiva by the scalloped mucogingival junction.

Table 1-17.

Attached Gingiva	Alveolar Mucosa
• Stippled, firm, thick	• Thin, loosely attached to periosteum
• No separate submucosa	• Well-defined submucosa
• Immoveable	• Moveable
• No glands	• Many small glands present
• Epithelium thick and Keratinized	• Epithelial ridges low
• Epithelial ridges high	• Epithelium thin, non-keratinized

## THE SPECIALIZED MUCOSA

We must discuss here the dorsal lingual mucosa. We have talked already of the embryological development of the tongue. The dorsal surface of the tongue is rough and irregular. A V-shaped line divides it into an anterior part or body, and a posterior part or base. The anterior part of the tongue is about two-thirds of its length and the posterior part about one-third of the tongue's length.

On the anterior part of the tongue are the filiform papillae. These are numerous fine pointed cone-shaped papillae. They consist of a core of connective tissue with a covering epithelium that is highly keratinized and forms the apex of the papillae. They may appear white due to heavy keratinization. Filiform papillae contain no taste buds.

Found among the filiform papillae are isolated mushroom-shaped fungiform papillae. These are round reddish prominences. The reason they are red is because of the rich capillary network visible through the thin epithelium. Fungiform papillae contain a few taste buds.

In front of the V-shaped sulcus terminalis are 8 to 10 vallate papillae. They have a deep circular furrow around them. On the lateral surface of the vallate papillae are numerous taste buds. There are pure serous glands located here: Von Ebner's glands.

The foramen cecum is located at the angle of the "V"-shaped terminal sulcus. This represents the remnant of the thyroglossal duct.

On the posterior 1/3 of the dorsum of the tongue, one sees round or oval prominences called lingual follicles. Each one contains one or more lymph nodules with germinal centers. The lingual follicles are collectively referred to as the lingual tonsil. On the lateral surface of the posterior third of the tongue are the foliate papillae, which also contain taste buds.

alveolar mucosa is separated from the attached gingiva by the scalloped mucogingival junction.

Table 1-17.

Attached Gingiva	Alveolar Mucosa
• Stippled, firm, thick	• Thin, loosely attached to periosteum
• No separate submucosa	• Well-defined submucosa
• Immoveable	• Moveable
• No glands	• Many small glands present
• Epithelium thick and Keratinized	• Epithelial ridges low
• Epithelial ridges high	• Epithelium thin, non-keratinized

## THE SPECIALIZED MUCOSA

We must discuss here the dorsal lingual mucosa. We have talked already of the embryological development of the tongue. The dorsal surface of the tongue is rough and irregular. A V-shaped line divides it into an anterior part or body, and a posterior part or base. The anterior part of the tongue is about two-thirds of its length and the posterior part about one-third of the tongue's length.

On the anterior part of the tongue are the filiform papillae. These are numerous fine pointed cone-shaped papillae. They consist of a core of connective tissue with a covering epithelium that is highly keratinized and forms the apex of the papillae. They may appear white due to heavy keratinization. Filiform papillae contain no taste buds.

Found among the filiform papillae are isolated mushroom-shaped fungiform papillae. These are round reddish prominences. The reason they are red is because of the rich capillary network visible through the thin epithelium. Fungiform papillae contain a few taste buds.

In front of the V-shaped sulcus terminalis are 8 to 10 vallate papillae. They have a deep circular furrow around them. On the lateral surface of the vallate papillae are numerous taste buds. There are pure serous glands located here: Von Ebner's glands.

The foramen cecum is located at the angle of the "V"-shaped terminal sulcus. This represents the remnant of the thyroglossal duct.

On the posterior 1/3 of the dorsum of the tongue, one sees round or oval prominences called lingual follicles. Each one contains one or more lymph nodules with germinal centers. The lingual follicles are collectively referred to as the lingual tonsil. On the lateral surface of the posterior third of the tongue are the foliate papillae, which also contain taste buds.