

ODESSA NATIONAL MEDICAL UNIVERSITY

LIBRARY OF THE MEDICAL STUDENT

The series was founded in 1999 in honor of the 100th anniversary of Odessa State Medical University (1900-2000)

**METHODS OF OBJECTIVE EXAMINATION OF A
PATIENT IN THE CLINIC OF INTERNAL DISEASES
A TEACHING AID**

Edited by Professor AA Yakymenko

*Recommended by the Ministry of Education and Science
of Ukraine*

Odessa

Odessa Medical University 2014

UDC 616.1 / .4-071

BBK 54.1-4

M 54

A series "Library of the medical student"

It was established in 1999

Authors: O.O. Yakymenko, O.E. Kravchuk, V.V. Klochko, D.M. Sebov, L.N. Yefremenkova

Reviewers: V.Z.. Netyazhenko – head of the Chair of internal medicine N 1 of the National Medical University named after O. O. Bohomolets, Honored Worker of Science of Ukraine, corresponding member of NAMS of Ukraine, DM, Professor
M.S. Racin - Professor of the Chair of internal medicine with nursing of the Ukrainian Medical Dental Academy, DM, Professor

Recommended by the Ministry of Education and Science of Ukraine as a teaching aid for students of higher education of IV level of accreditation (Minutes № 1/11-20298 of 12.23.2013)

© O.O. Yakymenko, A.E. Kravchuk, V.V. Klochko et al., 2014

© Odessa National Medical University, 2014

ISBN 978-966-7733-47-6 (series)

ISBN 978-966-443-070-5

Foreword

This teaching aid is intended for students of III-V years of the medical faculty, II-IV years of Dentistry Faculty of Medical Universities. It contains the main sections of the curriculum of propaedeutics of internal medicine. The teaching aid presents the methods of physical examination of patients with pathology of major organs and systems in original, laconic and consistent manner. Based on these brief physical examination schemes one may establish a preliminary diagnosis fast and efficient that is of practical importance not only for students but also for family practitioners.

The publication of this aid is published in proper time: it summarizes modern methods of physical examination as required by the Ukrainian propaedeutical school.

The teaching aid is prepared by the department of propaedeutics of internal medicine and therapy of Odessa National Medical University edited by Honored Scientist of Ukraine, Professor O.O.Yakymenko.

All comments and suggestions on improving the quality of the teaching aid will be accepted by the authors with gratitude and studied attentively.

PART 1

GENERAL EXAMINATION OF THE PATIENT

Examination is the first stage of objective physical examination of the patient, which requires no special equipment. It can be performed in any conditions and the results can become the important diagnostic criteria.

Basic requirements to examination:

- Examination is carried out in the daylight, under direct and lateral or fluorescent light;
- The patient should be completely naked or gradually bare his body during examination;
- Examination is carried out according to a definite plan.

Types of examination. Examination of the patient can be:

- a) general (general condition, the state of mind, position in bed, general constitution of the body, nourishment, state of the skin and its appendages, visible mucous membranes, bone -muscular system and lymph glands are estimated);
- b) local (the parts of the body, namely the head, face, neck, chest, abdomen, extremities are examined).

The main parameters of estimation of the patient during examination can be seen in Tabl.1.1.

Table 1.1.

The main parameters of the patient's estimation

Parameter	Estimation
General condition of the patient	satisfactory of moderate severity severe
State of mind	stupor sopor coma delirium hallucinations
Position in bed	active passive

<p>General constitution of the body</p>	<p>forced asthenic normal asthenic hypersthenic</p>
<p>Height</p>	<p>dwarf short middle tall giant</p>
<p>Body weight</p>	<p>reduced normal excessive</p>
<p>Skin and its appendages color</p> <p>humidity turgor swelling rash nail changes hair changes</p>	<p>normal or altered (pale, red, bronze, cyanosis, jaundice, depigmentation)</p> <p>normal, increased, dry satisfactory, low no, there is (localization) no, there is (which one?) no, there is (which one?) no, there is (which one?)</p>
<p>Organs of movement muscles</p> <p>extremity</p> <p>spine</p> <p>joints</p>	<p>pain, loss of strength atrophy tone (saved, reduced, increased) tremor, convulsions changes: there are (deformations), no</p> <p>changes: there are (deformations), no</p> <p>changes: there are (deformations, defiguration), no</p>

Lymph nodes (submandibular, cervical – frontal, posterior, supraclavicular, inguinal)	changes: there are (visible and palpable, from one or both sides), no pain: there is no consistency, mobility
Head	size
Face	shape changes: there are, no expression features
Eyes	changes: there are, no
Nose	changes: there are, no
Mouth	form and function of the mouth changes: there are, no
Teeth	changes: there are, no
Gums	changes: there are, no
Throat	changes: there are, no
Ears	changes: there are, no
Tonsils	changes: there are, no
Neck	change, shape disorder: there are, no
Vessels	throbbing, swelling of the neck vessels size
Thyroid	degree of enlargement

PART 2

RESPIRATORY ORGANS

2.1. PLAN OF THE OBJECTIVE EXAMINATION OF THE RESPIRATORY ORGANS

1. Examination of the chest:

- a) Determination of the chest form;
- b) Determination of the respiration type;
- c) Determination of participation of the auxiliary muscles in respiration;

- d) Determination of the rate, rhythm, depth of respiration;
 - e) Determination of the chest halves participation in respiration.
2. Chest palpation:
- a) Determination of chest resistance and tenderness;
 - b) Determination of the intercostal space and edge tenderness, intercostal space resistance;
 - c) Determination of vocal fremitus.
3. Lung percussion:
- a) Comparative (determination of the percussion sound and its change in symmetric points);
 - b) Determination of the apex height (in the front, in the back, width of Krening's fields, position of the lower edge during quiet breathing and its mobility).
4. Lung auscultation:
- a) Determination of the main sounds and their changes;
 - b) Determination of the pathological sounds (if they are present);
 - c) Determination of bronchophony.

2.2. CHEST EXAMINATION

Determination of the chest shape is carried out as follows (Fig. 2.1).

Deformation and asymmetry is characteristic of the pathological forms, the absence of it – of the norm. While determining the chest shape, take into account the structural features of the normal chest and character of the pathological chest deformations.

Chest deformations lead to disorder of the lung exertion, increased pressure in the chest cavity and pulmonary circulation, bronchopulmonary diseases and development of the chronic pulmonary heart.

Determination of the pathological forms of chest is made by the following stages.

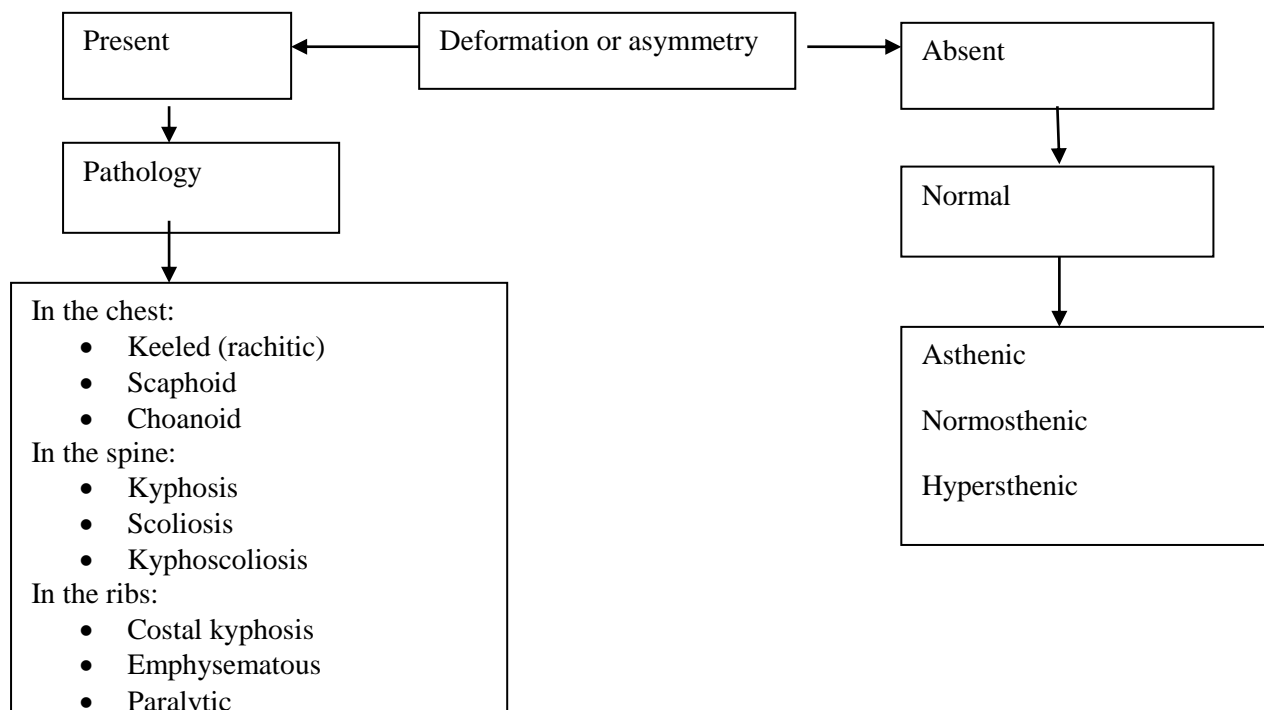


Fig. 2.1. The algorithm of the chest shape determination

Step 1. Determine the chest symmetry, that is:

- Shape similarity of both parts of the chest;
- Clavicle symmetry according to the acromion clavicle and sternal clavicle articulation;
- Scapulae symmetry according to the spine and scapular angles;
- Presence of costal kyphosis.

Step 2. Determine the spinal curvature:

- Curvature backward – kyphosis – kyphotic chest
- Curvature forward – lordosis
- Curvature sideward– scoliosis-scoliotic chest (Fig.2.2.)
- Curvature backward and sideward– kyphoscoliosis – kyphoscoliotic chest (Fig.2.3.)

Step 3. Determine the anterior-posterior and transverse chest size and their ratio (transverse size prevails over the anterior-posterior one in case of the norm), the direction of the ribs relatively the spine and horizontal space, epigastric angle (Fig.2.4.), intensity of the sub-and-supraclavicular fossae, intercostal spaces:

- Anterior- posterior size is close to the transverse one;
- The ribs are located nearly horizontally;
- The epigastric angle is more than 90° ;

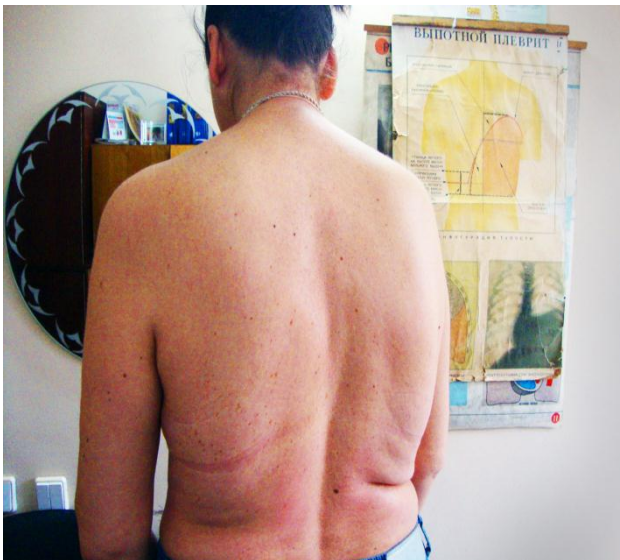

Fig.2.2. Scoliosis-scoliotic chest

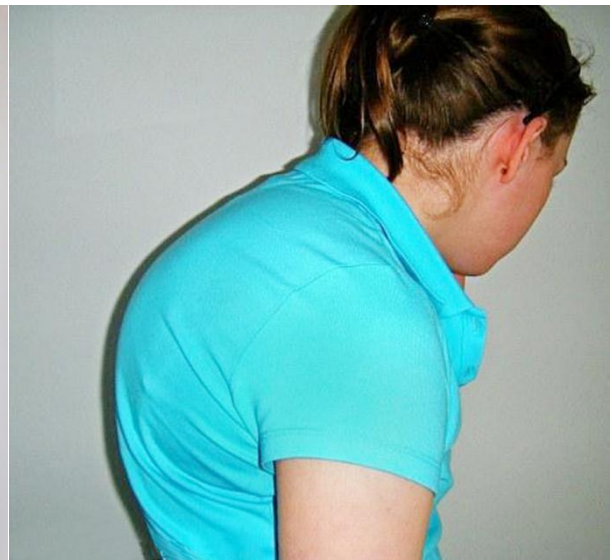

Fig.2.3. Kyphoscoliotic chest

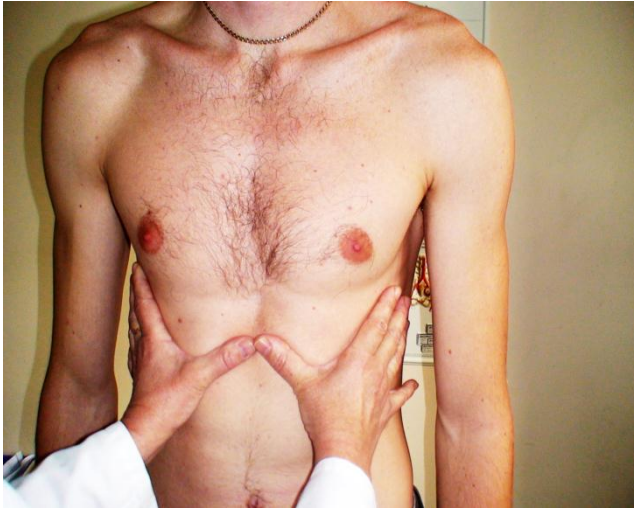


Fig.2.4. Determination of the epigastric angle.

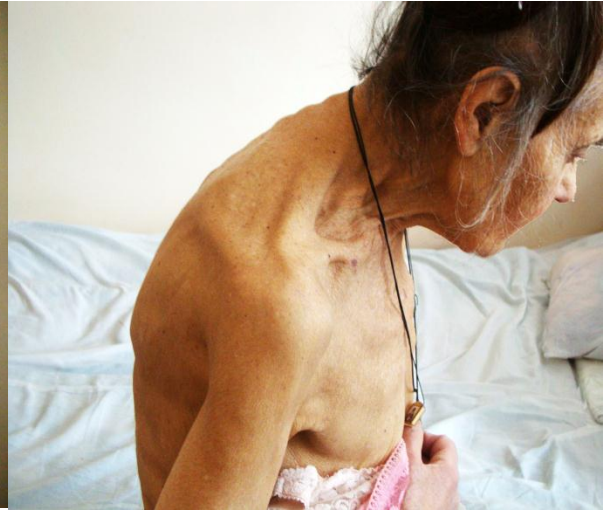

Fig.2.5. Paralytic type of the chest

- The sub-and-supraclavicular fossae, intercostal spaces are smoothed or projected (the chest looks like at the moment of inspiration)
- Emphysematous chest (like a barrel);
- Asymmetric position of the scapulae and clavicles;
- Retraction of the sub-and-supraclavicular fossae, intercostal spaces;
- Atrophy of the chest muscles –paralytic type of the chest (Fig.2.5.).

Step 4. Determine the deformation of the breastbone (sternum) and costal sternal joints:

- Impression in the middle of the sternum in the upper and middle one third (scaphoid chest);
- Impression in the lower one third of the sternum in the form of watering can (the chest of “shoemaker”);
- The sternum projects forward like a keel, enlargement of the anterior - posterior part of the chest, the ribs are connected with the sternum arisways, costal cartilages are thickened at the site of the bone (rachitic beads) –keeled chest (rachitic, keeled chest).

Besides all these steps, we do the following:

Step 1. Determine the deformation and asymmetry of the chest according to the following criteria.

Normosthenic chest

1. Proportional correlation of the anterior - posterior and transverse sizes (0.65-0.75).
2. Moderately expressed sub-and-supraclavicular fossae.
3. Epigastric angle is up to 90°.
4. Proportional correlation of the chest and abdominal sections of the trunk.

5. Scapulae are adjacent to the chest; the intercostal space is moderately expressed.

Asthenic chest

1. Decreased correlation of the anterior - posterior and transverse sizes (lower than 0.65).
2. Expressed sub-and-supraclavicular fossae.
3. Epigastric angle is lower than 90° .
4. The chest part of the trunk prevails over the abdomen.
5. Scapulae are apart from the chest, the intercostal space is widened, and the ribs are not connected with the costal arch.

Hypersthenic chest

1. Increased correlation of the anterior - posterior and transverse sizes (higher than 0.75).
2. Poorly expressed sub-and-supraclavicular fossae.
3. Epigastric angle is higher than 90° .
4. The abdominal part of the trunk prevails over the chest.
5. Scapulae are adjacent to the chest, the intercostal space is narrow.

Step 2. Determine the type of breathing.

- Expansion of the chest volume is promoted by the intercostal muscles (the chest is mainly enlarged forward and sideward) – chest type of breathing;
- Expansion of the chest volume is promoted by the diaphragm (abdomen volume is predominantly expanded) – abdominal type of breathing;
- Expansion of the chest volume is promoted by the intercostal muscles and diaphragm (abdomen and chest volume are approximately equally expanded) – mixed type of breathing;

Step 3. Determine the participation of the auxiliary muscles in breathing.

Step 4. Determine the participation of both halves of the chest in breathing.

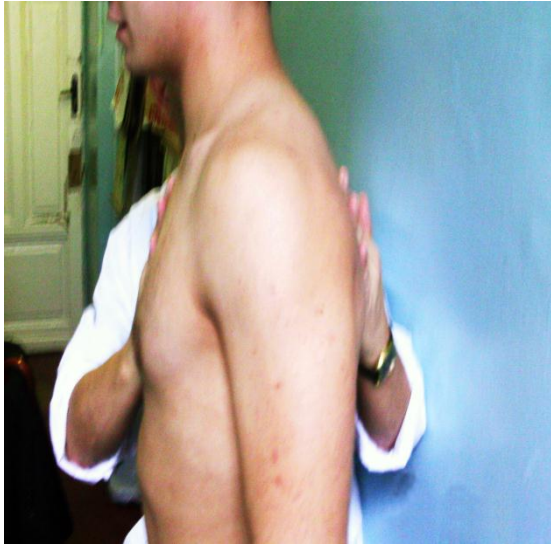Step 5. Determine the rate, rhythm, depth of breathing and participation of the chest halves in breathing

The example of the record of examination results in the medical history:

The chest is of the physiological form, normosthenic, type of breathing is mixed, the auxiliary muscles don't take part in breathing, both halves of the chest participate in breathing equally, breathing is rhythmic, of medial depth, 16 movements per minute.

2.3. CHEST PALPATION

Step 1. Determine the resistance and tenderness of the chest. To do this, squeeze the chest with the hands (putting the palms down, fingers up) in the anterior - posterior and lateral directions with necessary force for some deformation of the chest (it is measured by force, which must be applied for this).



This method allows to detect the chest pain (Fig. 2.6).

Step 2. Determine the tenderness of the intercostal spaces and ribs, intercostal spaces resistance:

Palpate the ribs and intercostal spaces using topographic lines with necessary force for some deformation of the intercostal spaces and ribs (putting the palms down, palpating with the

fingers).

Fig.2.6. Determination of the chest resistance.

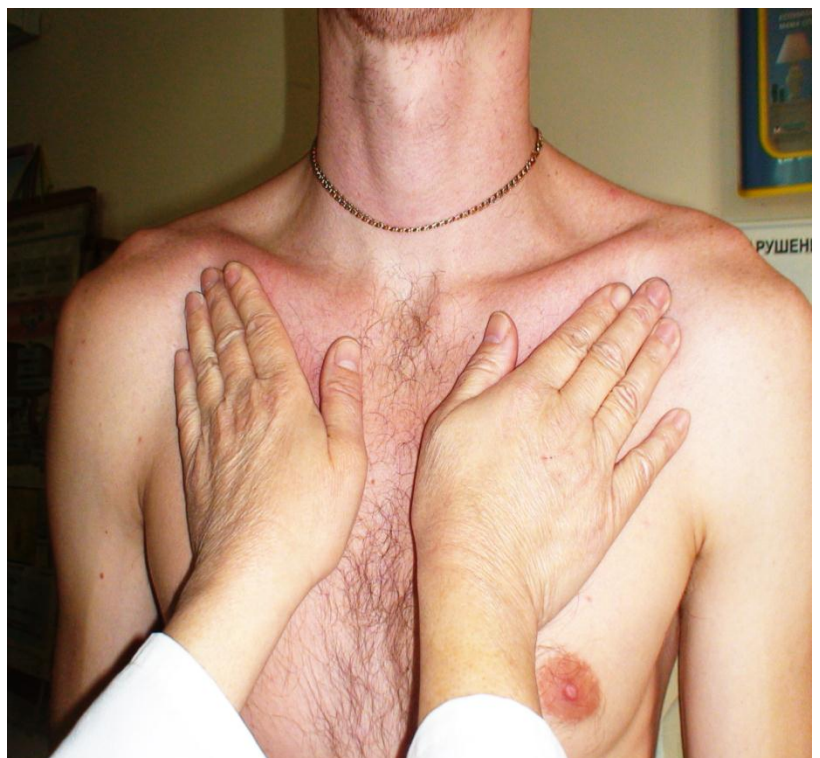


Fig.2.7. Determination of the vocal fremitus on the front surface of the chest.

Step 3. Determine the vocal fremitus:

1. Put the palms (palms down, fingers up, without imposing them on the collarbone) on the front surface of the chest on the right and left side at the same time, don't pull down the palms lower than II intercostal space, ask the patient to say "three hundred thirty-three" (Fig. 2.7).
2. Ask the patient to raise his hands behind his head.
3. Put your palms with the fingers to the back on the lateral surface of the chest, ask the patient to say "three hundred thirty-three".

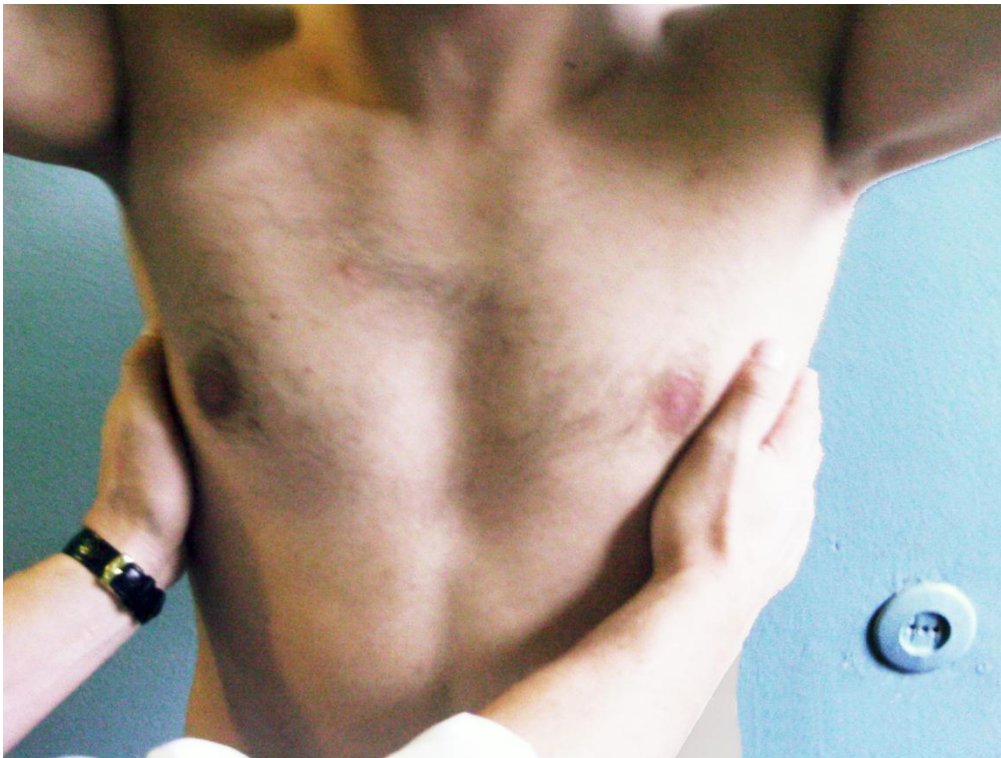


Fig. 2.8. Determination of the vocal fremitus on the lateral surfaces.

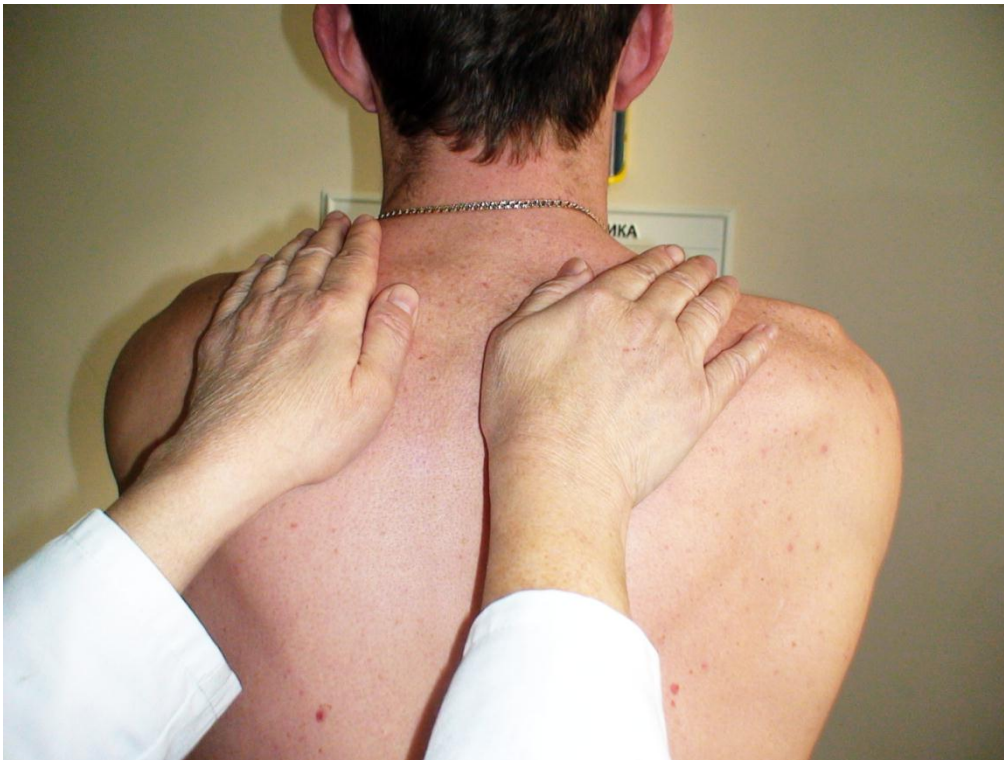

Fig. 2.9. Determination of the vocal fremitus on the posterior surface of the chest over the lung apices.

4. Ask the patient to put the arms down along the body.
5. Put the palm (base down, fingers up) on the posterior surface of the chest over the apices of the right and left lungs simultaneously, ask the patient to say "three hundred thirty-three" (Fig. 2.9).
6. Ask the patient to lay his hands upon the chest.
7. Put the palm (base down, fingers up) on the back of the chest between the scapulae, ask the patient to say "three hundred thirty-three" (Fig. 2.10).

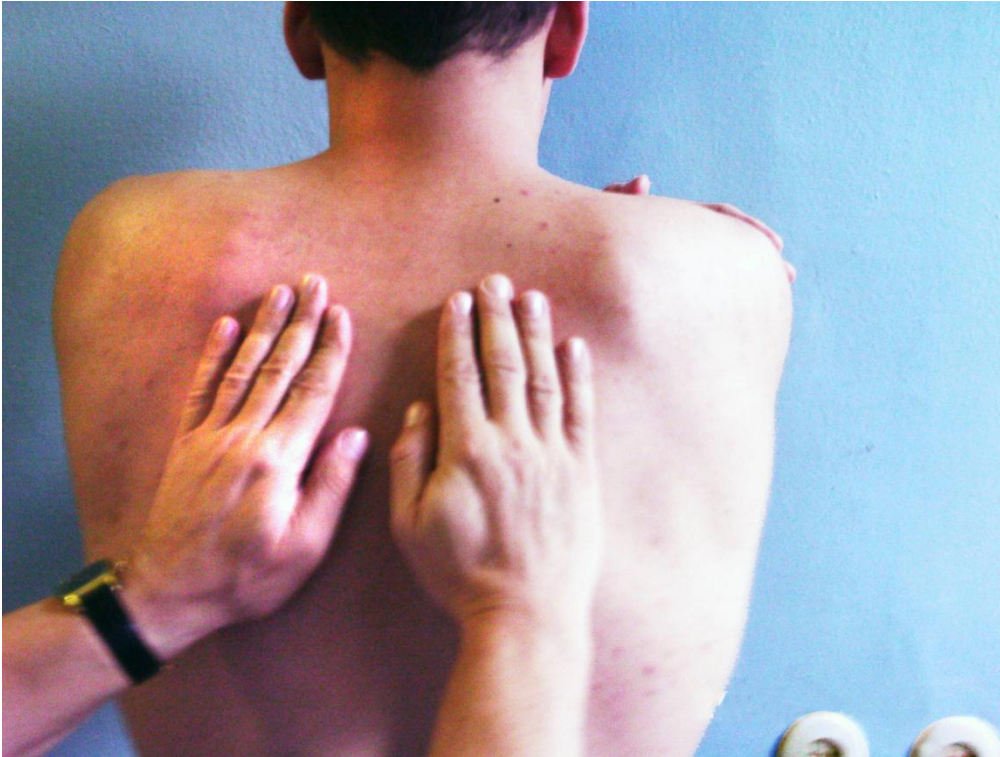

Fig.2.10. Determination of the vocal fremitus on the posterior surface of the chest between the scapulae.

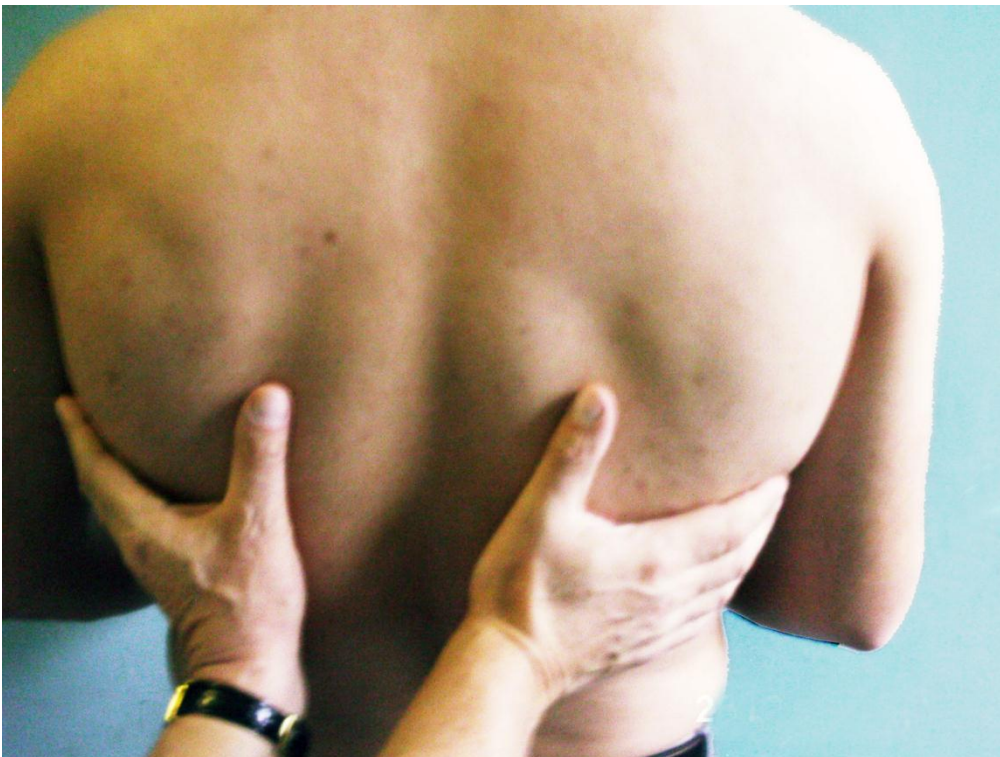


Fig.2.11. Determination of the vocal fremitus on the posterior surface of the chest under the scapulae.

8. Ask the patient to put the arms down along the body.

9. Put the palms under the scapulae (the base of the palms is placed medially, fingers - laterally), ask the patient to say "three hundred thirty-three" (Fig. 2.11).

The example of the record of the chest palpation results in the medical history:

The chest is of the usual resistance, pain during palpation is not determined, the palpation of the ribs and intercostal spaces doesn't cause pain, the intercostal spaces are of usual resistance, and vocal fremitus is the same on both sides.

2.4. PERCUSSION OF THE LUNGS

Comparative lung percussion

Determine the percussion sound over the right and left lungs, its characteristics and changes during percussion in the symmetric parts (over the lungs the clear (pulmonary) sound is normally determined, and it is expected to be determined during percussion).

Step 1. Determine the percussion sound over the front surfaces of the chest.

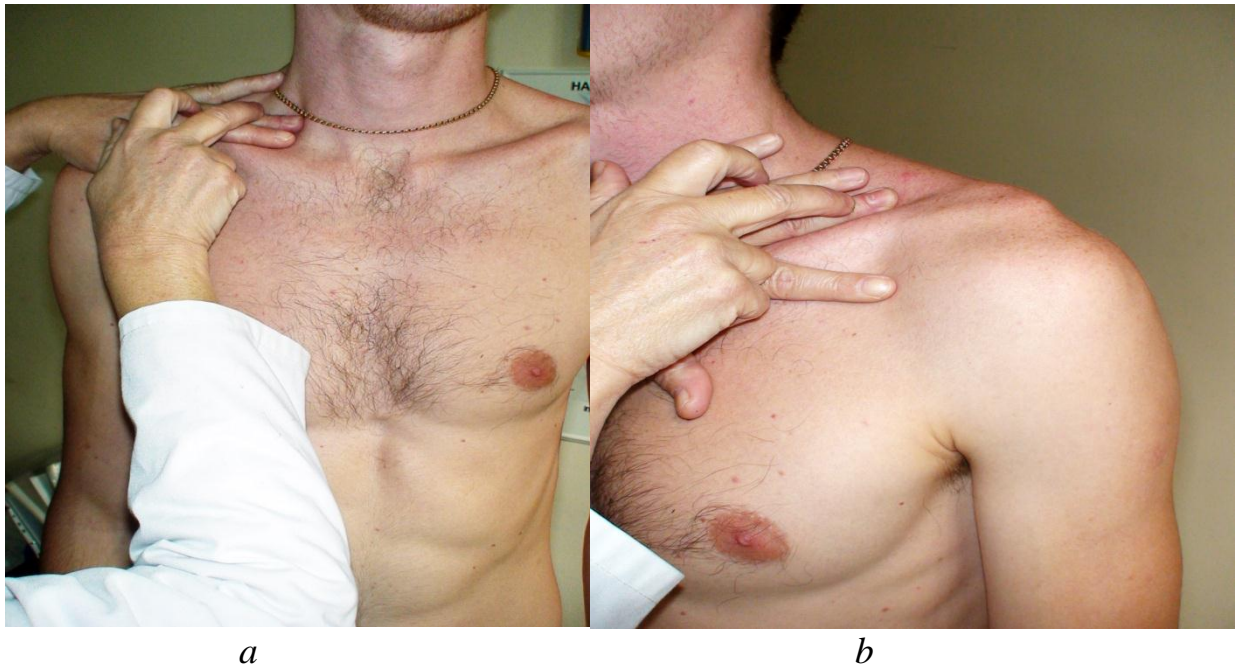


Fig.2.12. Comparative percussion over the clavicles (a,b).

1. A pleximeter should be placed over the clavicle on the right, parallel to it, make percussion on the right and left to compare the percussion sound (Fig. 2.12, b).
2. The collarbone is used as a pleximeter. It is necessary to make percussion on the right and left to compare the percussion sound (Fig. 2.13).

3. A pleximeter should be placed in I intercostal space along the midclavicular line on the right, make percussion on the right and left to compare the percussion sound (Fig. 2.14).

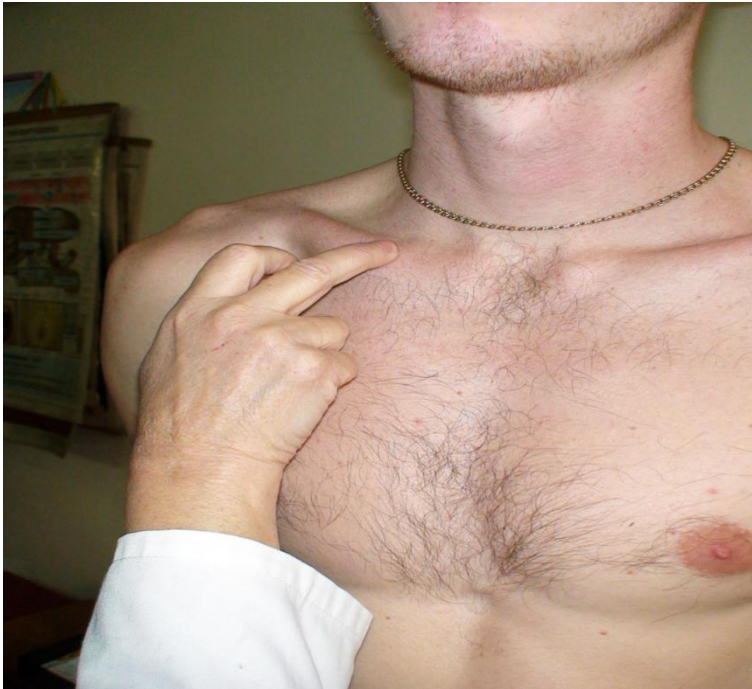

Fig.2.13. Comparative percussion of the clavicle.

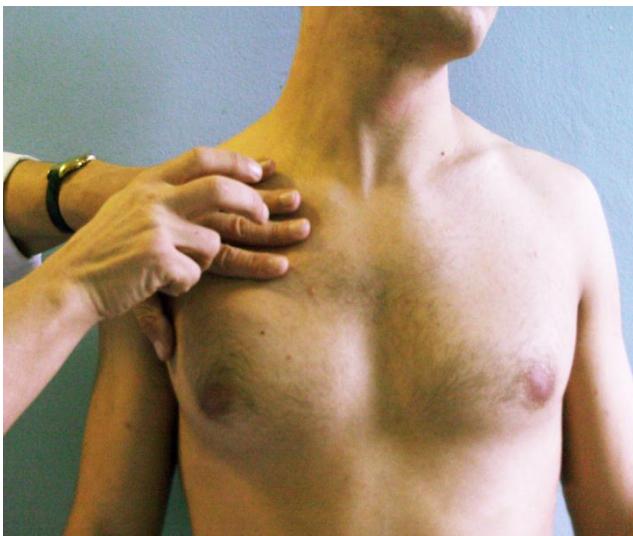

Fig.2.14. Comparative percussion of the midclavicular line in I intercostal space.

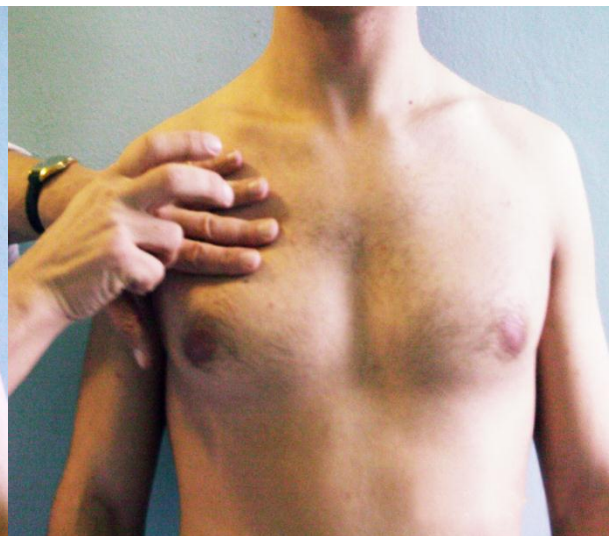


Fig.2.15. Comparative percussion of the midclavicular line in II intercostal space.

4. A pleximeter should be placed in the II intercostal space along the midclavicular line on the right, make percussion on the right and left to compare the percussion sound (Fig. 2.15).

Step 2. Determine the percussion sound over the lateral surfaces of the chest:

1. Ask the patient to raise his hands behind his head.
2. A pleximeter should be placed in the intercostal space at the lower edge of the axillary fossa on the right middle axillary line, make percussion down within the lungs (normally VIII intercostal space) to compare the percussion sound on the left and right (Fig. 2.16, b)

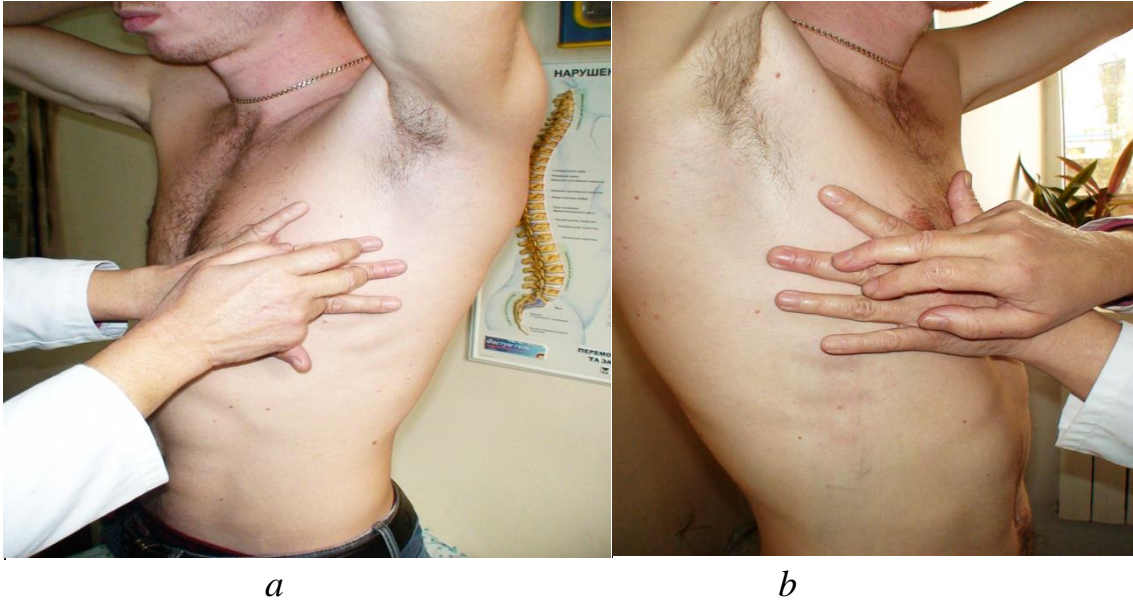


Fig.2.16. Comparative percussion on the middle axillary line on the left and right (a,b).

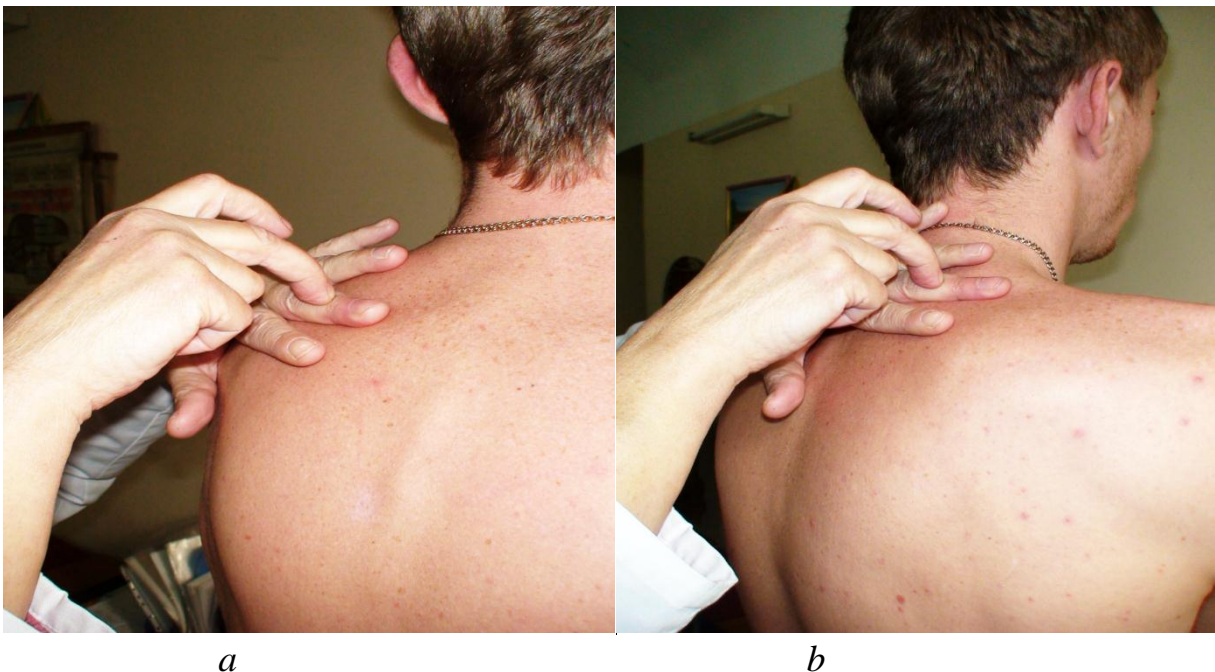


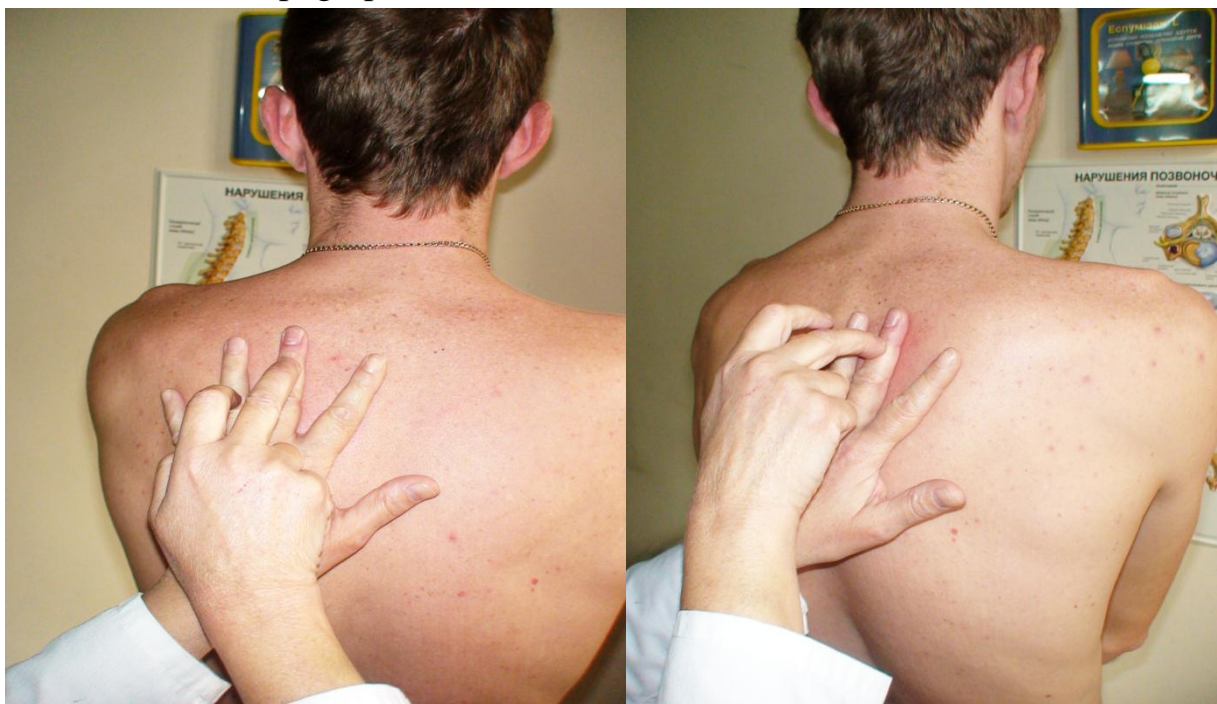Fig. 2.17. Comparative percussion over the blade spine on the left and right (a, b)

Step 3. Determine the percussion sound over the posterior surfaces of the chest:

1. A pleximeter should be placed over the blade spine on the right, parallel to it, make percussion on the left and right to compare the percussion sound (Fig. 2.17a, b).
2. Ask the patient to cross the arms in the front of the chest to spread the scapulae.
3. A pleximeter should be placed between the scapulae on the right, parallel to the spine, perpendicular to the intercostal space, make the percussion down to the scapular angles to compare the percussion sound on the left and right (Fig. 2.18, a-g).
4. Ask the patient to put the arms down along the trunk.
5. A pleximeter should be placed in the intercostal space under the scapular angle on the right, in the scapular line, make percussion down to the lungs (normally X intercostal space) to compare the percussion sound on the left and right (Fig. 2.19, b).

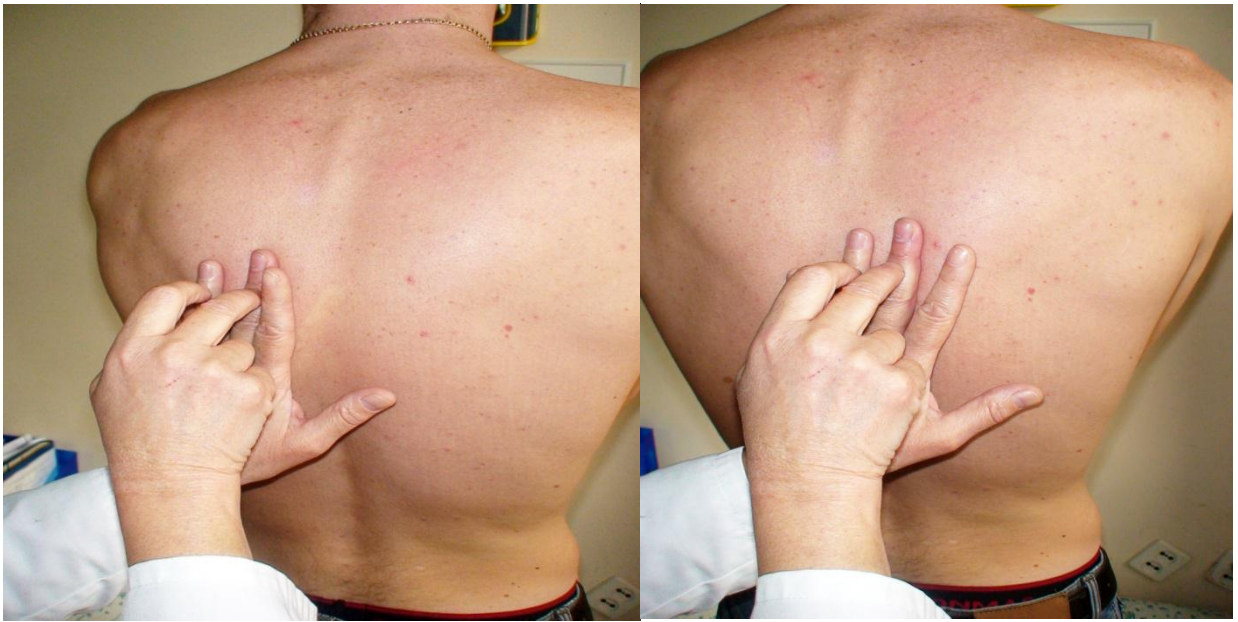The example of the record of the lung comparative percussion results in the medical history:

There is clear a percussion sound over the lungs (if it changes, character, the lung and region where there are changes orienting by the topographic lines and ribs should be indicated).



a

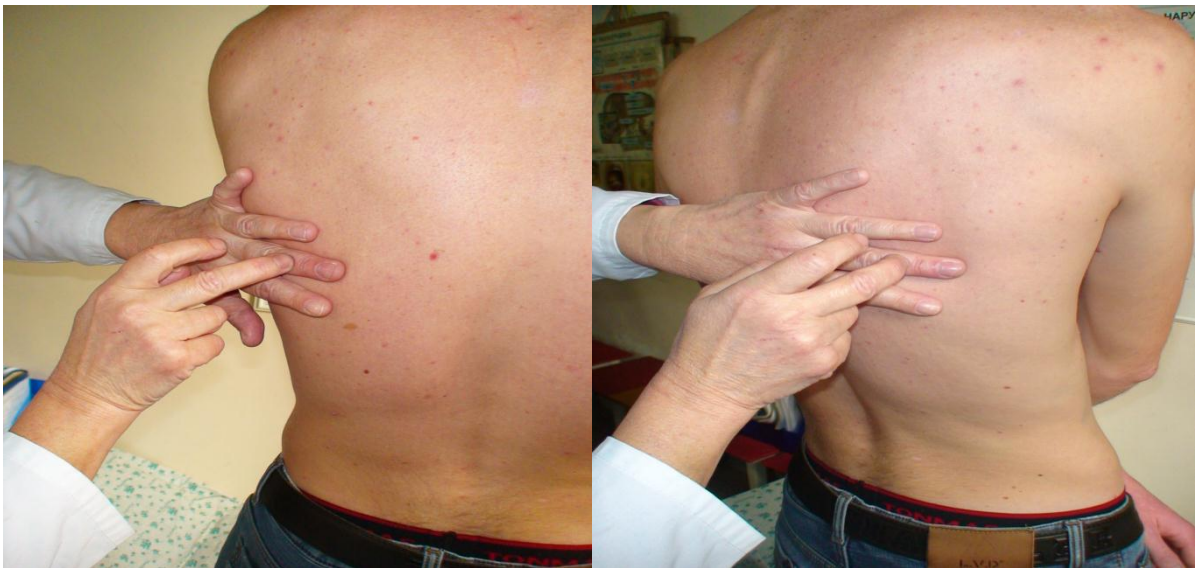b



c

g

Fig.2.18. Comparative percussion between the scapulae on the left and right (a-g).



a

b

Fig.2.19. Comparative percussion below the scapulae on the left and right (a, b).

Topographic percussion of the lungs

Step 1: Determine the height of the lung apices in the front, on the right and left:

1. A pleximeter should be placed over the clavicle, parallel to it, make the percussion upward and slightly medially until the appearance of the dull sound (Fig. 2.20 a, b).

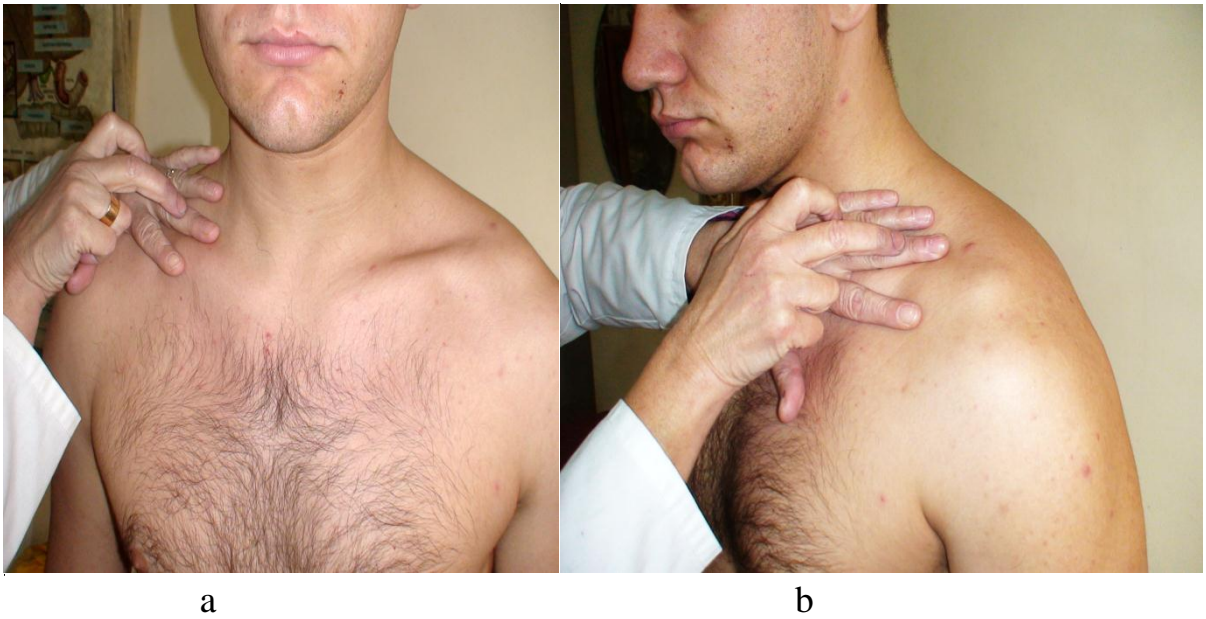


Fig.2.20. Determination of the height of the lung apices on the right and left (a, b).

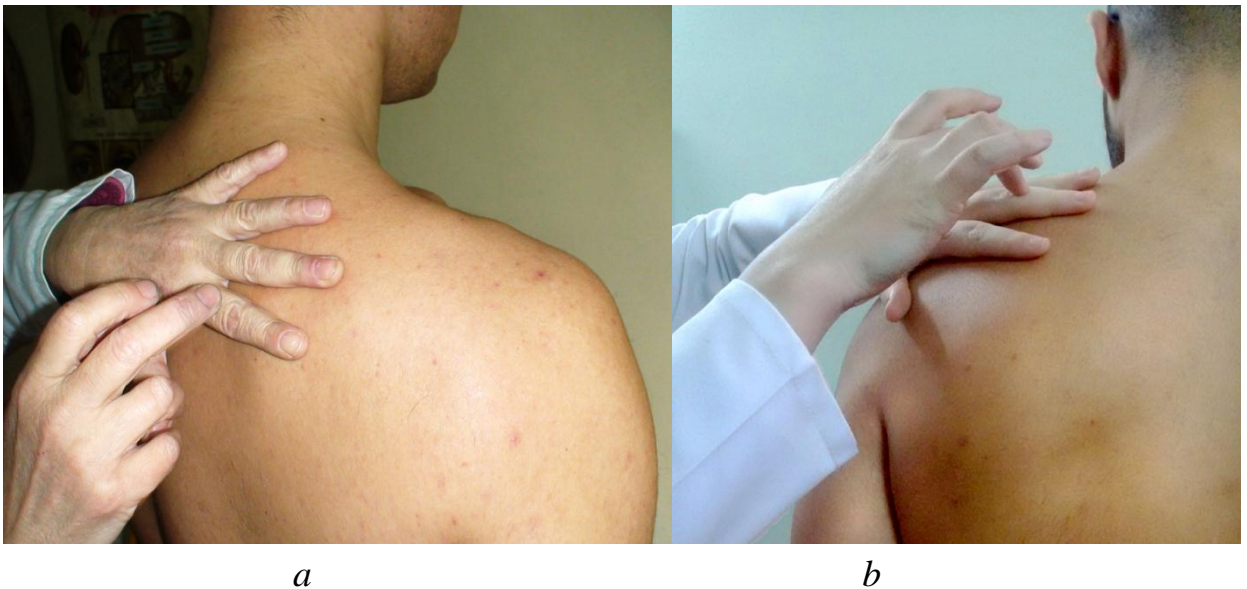


Fig.2.21. Determination of the height of the lung apices over the scapular spine on the right and left (a, b).

2. Using a dermatograph, make a mark on the edge of the pleximeter directed to the clear sound.
3. Using a ruler or a measuring tape measure the distance from the upper edge of the clavicle to the mark.

Step 2. Determination of the height of the lung apices from behind, on the right and left.

1. A pleximeter should be placed over the scapular spine, parallel to it, make percussion upward and slightly medially (toward the spinous processes of the cervical vertebrae VII) until the appearance of the dull sound (Fig. 2.21, b).

2. Using a dermatograph, make a mark on the edge of the pleximeter directed to the clear sound.

3. Determine the compliance of the mark level to the level of the spinous processes of the cervical vertebra VII (Fig. 2.22).

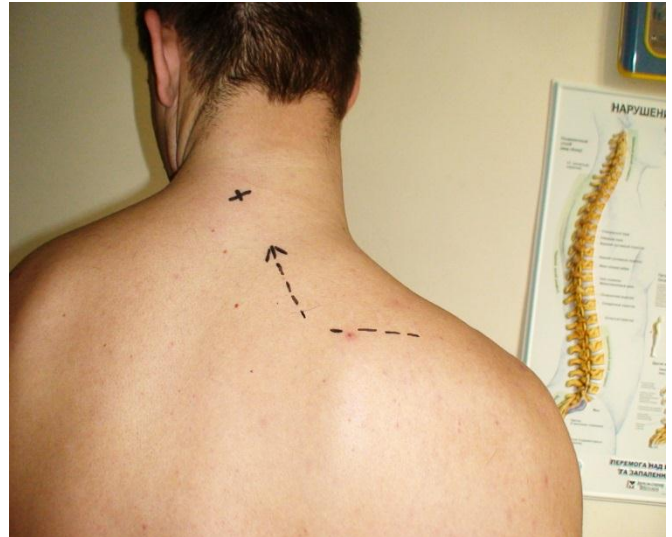

Fig.2.22. Determination of the height of the lung apices.

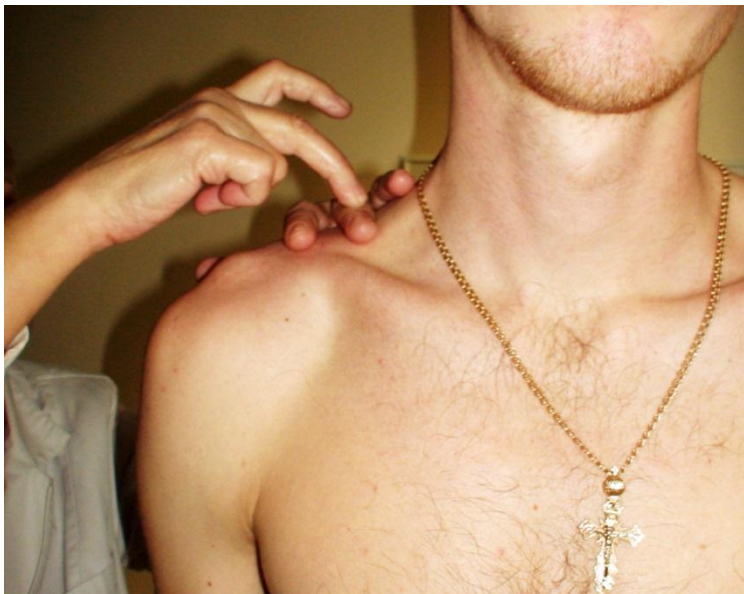

Fig.2.23. Determination of the width of Krening's fields from behind.

Step 3. Determination of the width of Krening's fields from behind on the right and left:

1. Place the pleximeter in the middle of the upper edge of the trapezoid muscle (it is necessary to pull the muscle edge back a little bit so that percussion was made in the area with the least muscle mass); make percussion in the medial direction until the appearance of the dull sound (Fig. 2.23).

2. Using a dermatograph, make a mark on the edge of the pleximeter directed to the clear sound.

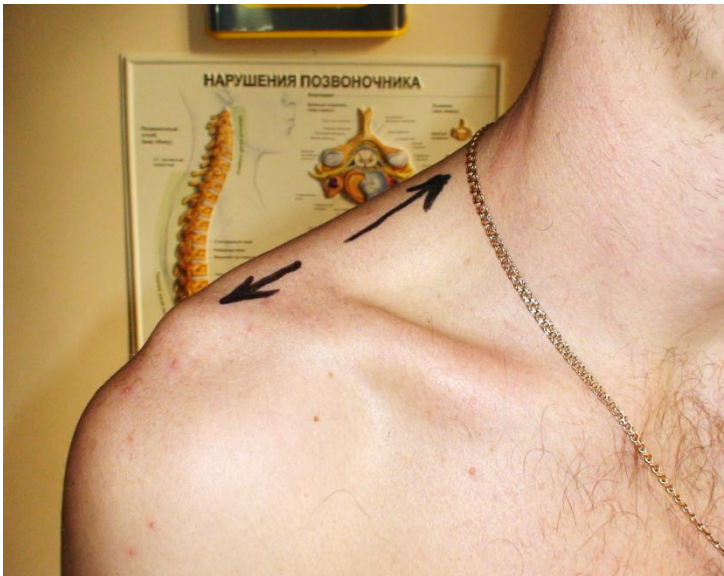


Fig. 2.24. Determination of the distance between the marks.

3. Repeatedly place the pleximeter in the middle of the upper edge of the trapezoid (it is necessary to pull the muscle edge back a little bit so that percussion was made in the area with the least muscle mass); make percussion in the lateral direction until the appearance of the dull sound.

4. Using a dermatograph, make a mark on the edge of the

pleximeter directed to the clear sound.

5. Using a ruler or a measuring tape, measure the distance between the marks, which will be Krening's fields (Fig. 2.24).

Step 4: Determination of the lower border of the lungs during the quiet breathing:

1. Place the pleximeter in I intercostal space on the parasternal line on the right (it passes vertically midway between the sternal and midclavicular line, the sternal line runs along the edge of the sternum, midclavicular one divides the collarbone in half); make percussion, placing the pleximeter in the intercostal space until the appearance of the dull sound.

2. Using a dermatograph, make a mark on the edge of the pleximeter directed to the clear sound.

3. Determine the marked intercostal space; make a conclusion as to its compliance with the normal range.

4. Place a pleximeter in I intercostal space on the midclavicular line on the right (it runs vertically and divides the collarbone in half); make percussion, placing the pleximeter in the intercostal space until the appearance of the dull sound.

5. Using a dermatograph, make a mark on the edge of the pleximeter directed to the clear sound.

6. Determine the marked intercostal space; make a conclusion as to its compliance with the normal range.

7. Ask the patient to raise his right hand behind the head.

8. Place a pleximeter in the intercostal space at the lower edge of the right axillary fossa on the anterior axillary line (it passes vertically in front of the axillary fossa);

make percussion, placing the pleximeter in the intercostal space until the appearance of the dull sound.

9. Using a dermatograph, make a mark on the edge of the pleximeter directed to the clear sound.

10. Determine the marked intercostal space; make a conclusion as to its compliance with the normal range.

11. Place the pleximeter in the intercostal space at the lower edge of the axillary fossa on the right middle axillary line (it passes vertically in the middle of the axillary fossa); make percussion, placing the pleximeter in the intercostal space until the appearance of the dull sound.

12. Using a dermatograph, make a mark on the edge of the pleximeter directed to the clear sound.

13. Determine the marked intercostal space; make a conclusion as to its compliance with the normal range.

14. Place a pleximeter in the intercostal space at the lower edge of the right axillary fossa on the posterior axillary line (it passes vertically along the back edge of the axillary fossa); make percussion, placing the pleximeter in the intercostal space until the appearance of the dull sound.

15. Using a dermatograph, make a mark on the edge of the pleximeter directed to the clear sound.

16. Determine the marked intercostal space; make a conclusion as to its compliance with the normal range.

17. Place a pleximeter in the intercostal space on the right shoulder line at the scapular angle (it passes vertically through the scapular angle); make percussion, placing the pleximeter in the intercostal space until the appearance of the dull sound.

18. Using a dermatograph, make a mark on the edge of the pleximeter directed to the clear sound.

19. Determine the marked intercostal space; make a conclusion as to its compliance with the normal range.

20. Place a pleximeter in I intercostal space on the paraspinal line on the right (it passes vertically, connecting lateral vertebral processes); make percussion, placing the pleximeter in the intercostal space until the appearance of the dull sound.

21. Using a dermatograph, make a mark on the edge of the pleximeter directed to the clear sound.

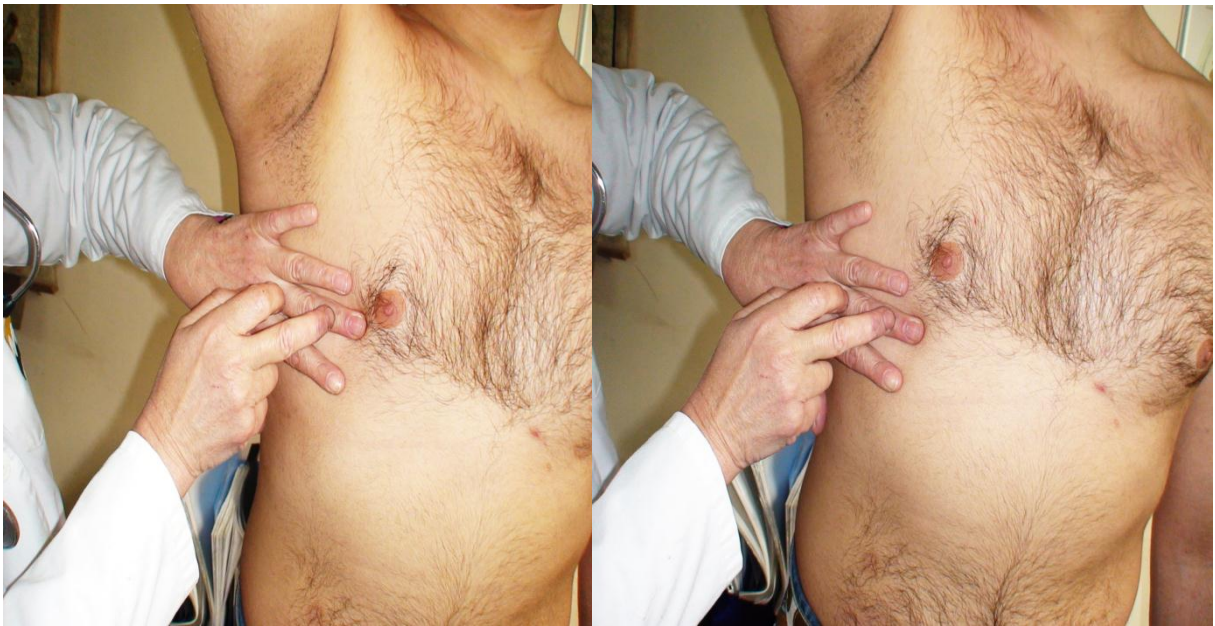22. Determine the level where the mark is located; make a conclusion as to its compliance with the normal range.

Step 5. Determine the mobility (excursion) of the lower edge of the lungs while inhaling and exhaling and total mobility in the midclavicular line:

1. Place a pleximeter in II intercostal space on the midclavicular line on the right, make percussion, placing the pleximeter in the intercostal space until the appearance of the dull sound.
2. Using a dermatograph, make a mark on the edge of the pleximeter directed to the clear sound.
3. Ask the patient to take a deep breath in and hold it.
4. Make percussion down until the appearance of the dull sound.
5. Using a dermatograph, make a mark on the edge of the pleximeter directed to the clear sound.
6. Place a pleximeter on the first mark, made in determination of the lower edge of the lungs during quiet breathing.
7. Ask the patient to take a deep breath in and hold it.
8. Make percussion upward until the appearance of the clear sound (percussion should be made from the dull to clear sound, violating a general rule of percussion - percuss from the clearer sound to more dull).
9. Using a dermatograph, make a mark on the edge of the pleximeter directed to the clear sound.
10. Using a ruler or a measuring tape, measure the distance from the middle to the lower mark, determining the mobility of the lower edge of the lungs on inhalation in centimeters.
11. Using a ruler or a measuring tape, measure the distance from the middle to the lower mark, determining the mobility of the lower edge of the lungs on exhalation in centimeters.
12. Sum up the figures obtained calculating the mobility of the lower edge of the lungs on inhalation and exhalation in centimeters (total mobility).

Step 6. Determine the mobility (excursion) of the lower edge of the lungs while inhaling and exhaling and total mobility in the middle axillary line:

1. Ask the patient to raise his right hand behind his head.
2. Locate plesymetr in intercostal space at the lower edge axillary fossa on the right middle axillary line, make a first Kusiya, setting plesymetr intercostal space to the appearance of dull sound (Fig. 2.25, a, b).
3. Use dermatograph make a mark on the edge plesymetries aimed to clear sound.



a

b

Fig. 2.25. Determine the mobility on the lower edge of the lungs right middle axillary line (a, b)

4. Ask the patient to take a deep breath and hold up breathing.
5. Make percussion down to the appearance of dull sound.
6. Using a dermatograph, make a mark on the edge plesymmetries aimed to clear sound.
7. Arrange plesymetr at the first mark, taken at defining the lower edge of the lungs during quiet breathing.
8. Ask the patient to take a deep breath and hold up breathing.
9. Make percussion up to the emergence of a clear sound.
10. With dermatograph make a mark on the edge plesymmetries aimed to clear sound.
11. Ruler or tape measure distance the average marks to the bottom, defining in centimeters the mobility of the lower edge of the lungs on inhalation.
12. Ruler or tape measure distance the average marks to the bottom, defining in centimeters the mobility of the lower edge of the lungs exhale.
13. To make the figures obtained by calculating in inches the mobility of the lower edge of the lungs on inhalation and exhalation (total mobility).

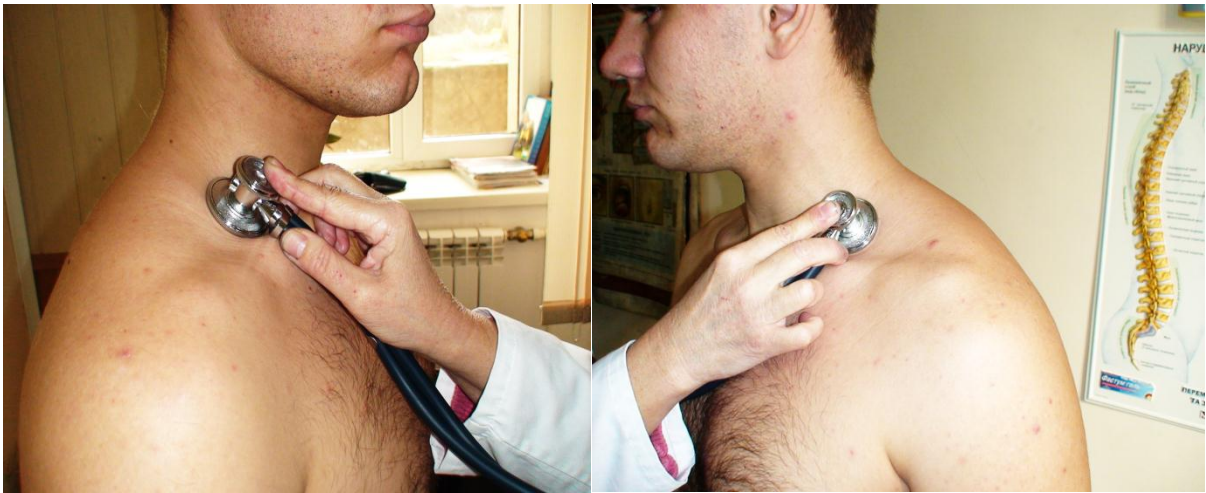Step 7. Determine the mobility (tour) of the lower edge of the lungs while inhaling and exhaling and total mobility in the middle blade (scapularis) line:

1. Locate plesymetr intercostal space in the case on the blade lines and percussion make, setting in inter-plesymetr to the appearance of dull sound.
2. Using a dermohraf, make a mark on the edge plesymmetries aimed to clear sound.
3. Ask the patient to take a deep breath and hold up breathing.
4. Make percussion down to the appearance of dull sound
5. Using a dermohraf, make a mark on the edge plesymmetries aimed to clear sound.
6. Locate plesymetr at the first mark, taken at defining the lower edge of the lungs during quiet breathing.
7. Ask the patient to take a deep breath and hold up breathing.
8. Make percussion up to the emergence of a clear sound.
9. Using a dermohraf, make a mark on the edge plesymmetries aimed to clear sound.
10. Ruler or tape measure distance the average marks to the bottom, defining in centimeters the mobility of the lower edge of the lungs on inhalation.
11. Ruler or tape measure distance the average marks to the bottom, defining in centimeters the mobility of the lower edge of the lungs exhale.
12. To make the figures obtained by calculating in inches the mobility of the lower edge of the lungs on inhalation and exhalation (total mobility).

2.5. AUSCULTATION OF THE LUNGS

Step 1. Auscultation of the front surface of the chest (the 2nd-3rd respiratory cycles are auscultated during the quiet and if it is necessary the deep and forced breathing):

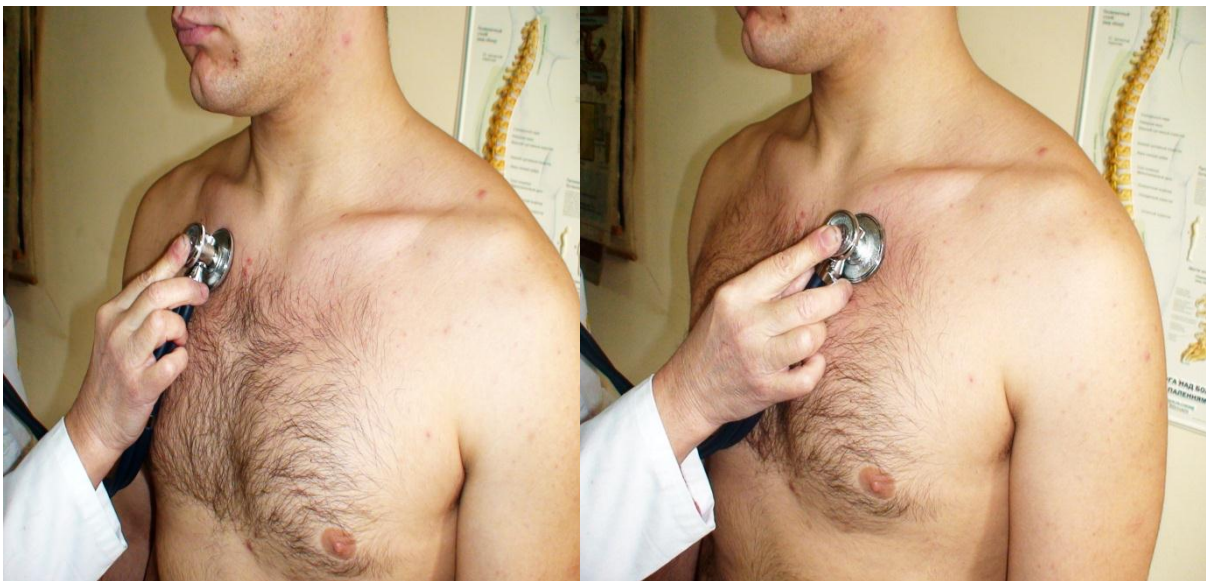1. Place a phonendoscope over the clavicle on the right, make auscultation on the right and left to determine and compare the respiratory sounds (Fig. 2.26 a, b).



a

b

Fig.2.26. Auscultation of the lungs over the clavicle on the right and left (a, b)



a

b

Fig. 2.27. Auscultation of the lungs in I intercostal space on the midclavicular line on the right and left (a, b)

2. Place a phonendoscope in I intercostal space on the midclavicular line on the right, make auscultation on the right and left to determine and compare the respiratory sounds (Fig. 2.27 a, b).
3. Place a phonendoscope in II intercostal space on the midclavicular line on the right, make auscultation on the right and left to determine and compare the respiratory sounds (Fig. 2.28, b).

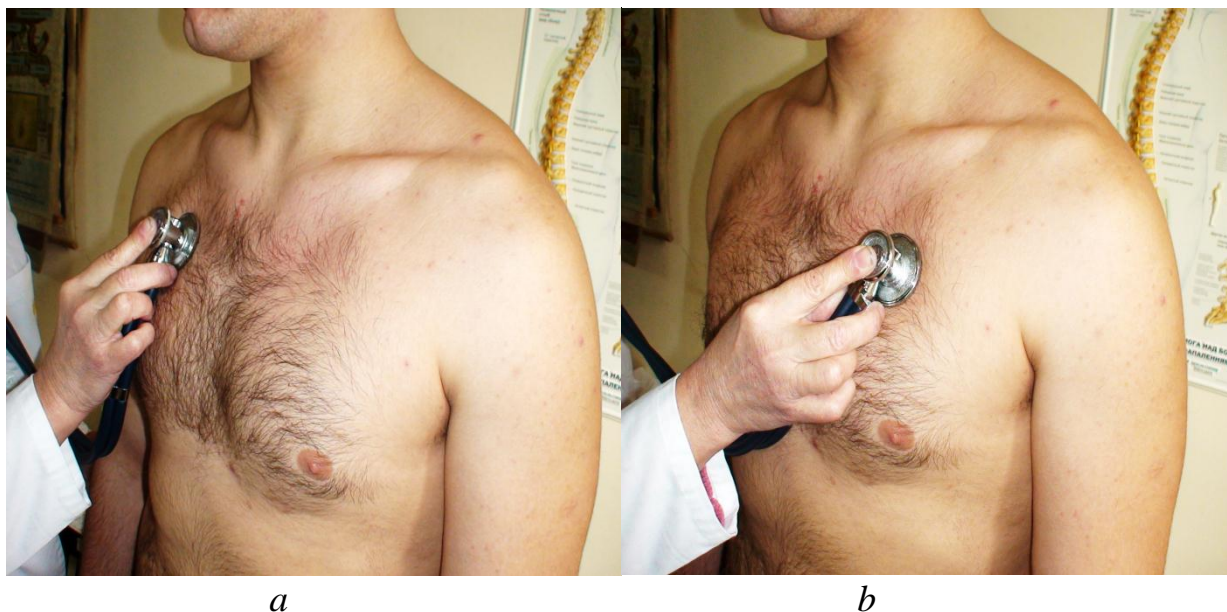

Fig. 2.28. Auscultation of the lungs in II intercostal space on the midclavicular line on the right and left (a, b)

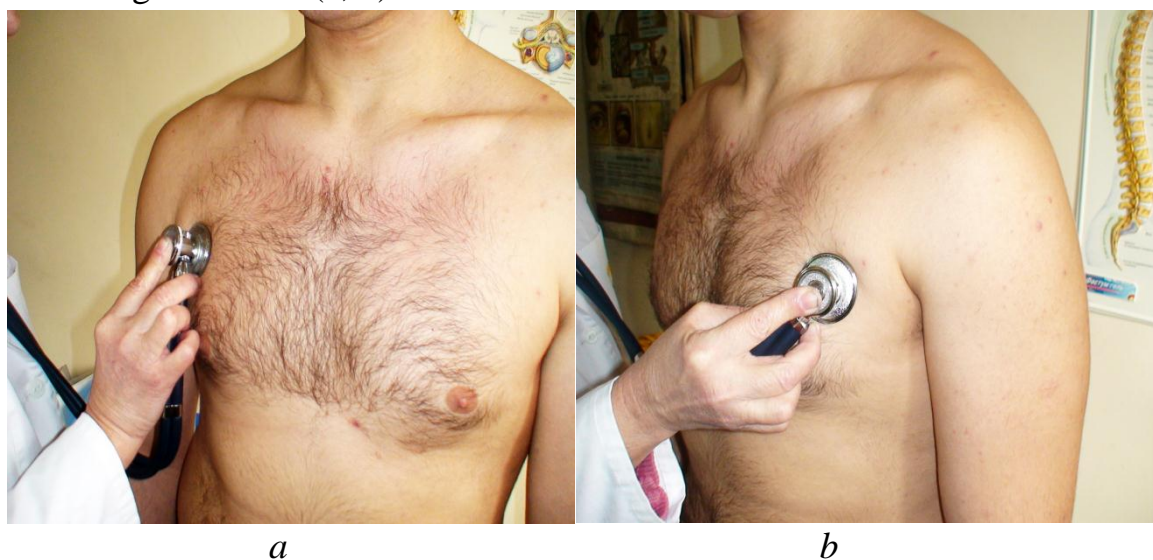
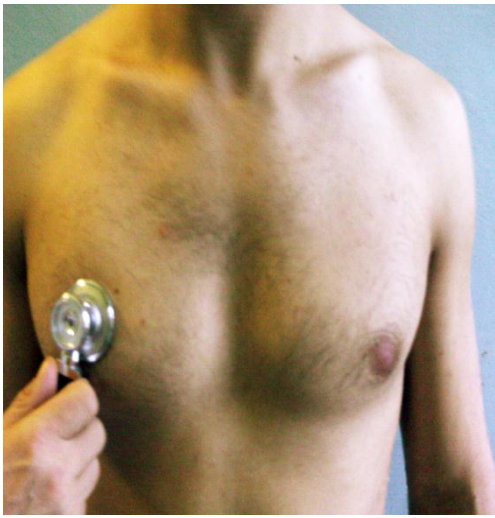
Fig. 2.29. Auscultation of the lungs in III intercostal space on the midclavicular line on the right and left (a, b)

4. Place a phonendoscope in III intercostal space on the midclavicular line on the right, make auscultation on the right and left to determine and compare the respiratory sounds (Fig. 2.29, b).



5. Place a phonendoscope in IV intercostal space on the midclavicular line on the right, make auscultation on the right to determine and compare the respiratory sounds from above and below (Fig. 2.30).

6. Place a phonendoscope in V intercostal space on the midclavicular line on the right, make auscultation on the right to determine and compare the respiratory sounds from above and below (Fig. 2.31).

Fig.2.30. Auscultation of IV intercostal space on the midclavicular line on the right.

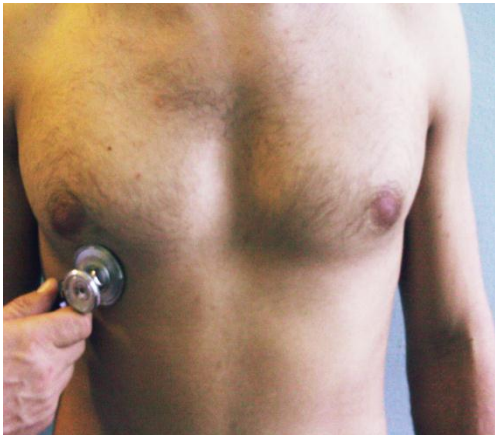
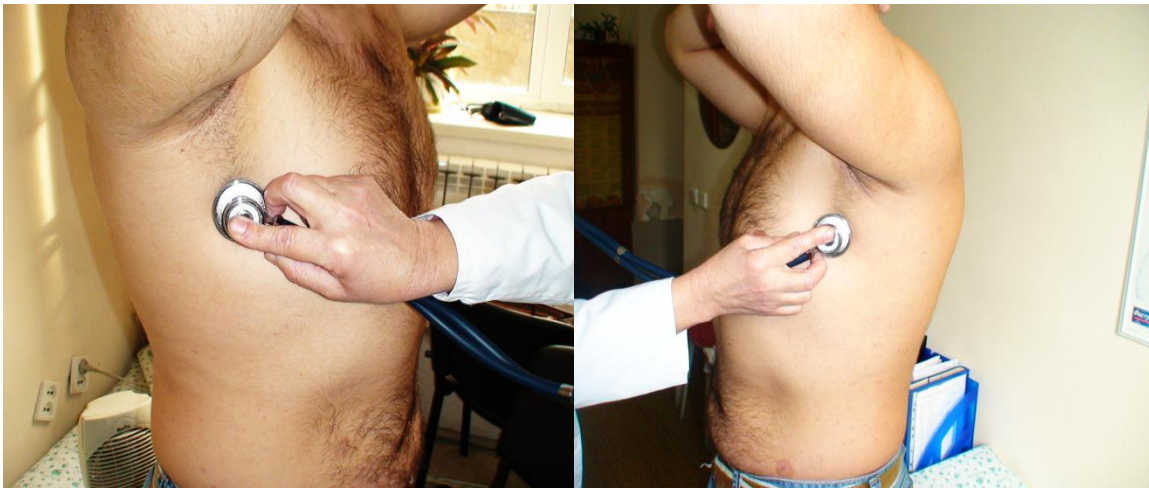
Fig.2.31. Auscultation of V intercostal space on the midclavicular line on the right.

Step 2. Auscultation of the lateral surfaces of the lungs:

1. Ask the patient to raise his hands behind the head.
2. Place a phonendoscope in the intercostal space at the lower edge of the axillary fossa on the middle axillary line on the right, make auscultation on the right and left to determine and compare the respiratory sounds (Fig. 2.32 a, b).

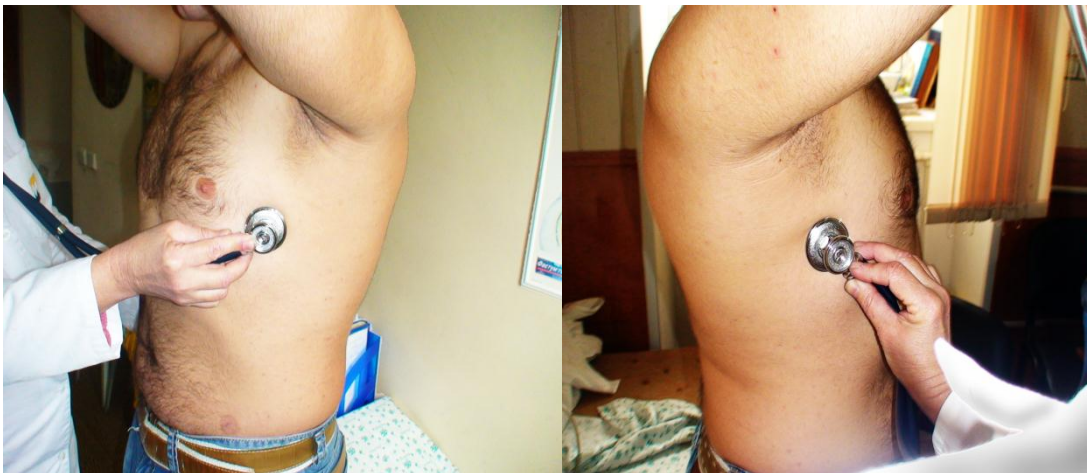

a

b

Fig. 2.32. Auscultation of the lungs in the middle axillary line on the right and left (a, b)

2. Place a phonendoscope alternately in the intercostal space in the middle axillary line on the right and left, make auscultation of the lungs outlined during the topographic percussion (to VII intercostal space in the norm) to determine and compare the respiratory sounds (Fig. 2.33, and a, b).



a

b

Fig. 2.33. Auscultation of the lungs in the middle axillary line on the right and left within the lungs outlined during the topographic percussion (a, b)

4. Ask the patient to put the arms down along the body.

Step 3. Auscultation of the posterior surface of the chest:

1. Place a phonendoscope over the ostium of the right scapula, parallel to it, make auscultation on the right and left to determine and compare the respiratory sounds (Fig. 2.34, b).

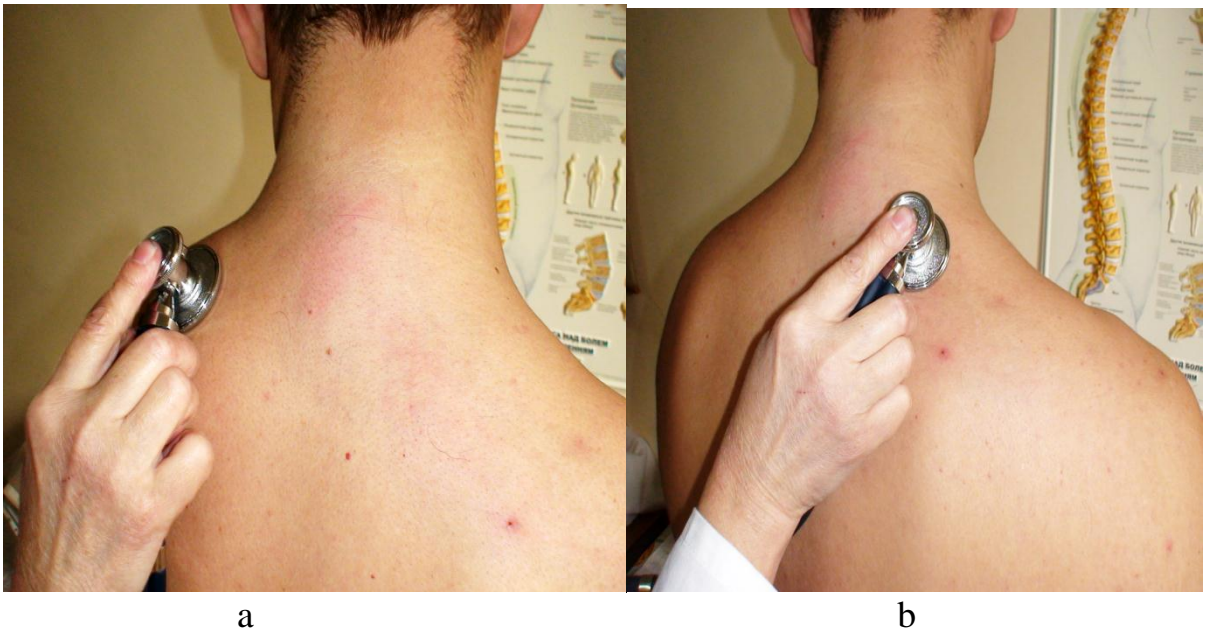

Fig.2.34. Auscultation over the scapular ostium on the right and left (a, b)

2. Ask the patient to put together his hands on the front surface of the chest to pull apart the scapulae.
3. Place a phonendoscope between the scapulae on the right, make auscultation down the scapular lines on the right and left to determine and compare the respiratory sounds (Fig. 2.35 a, b).

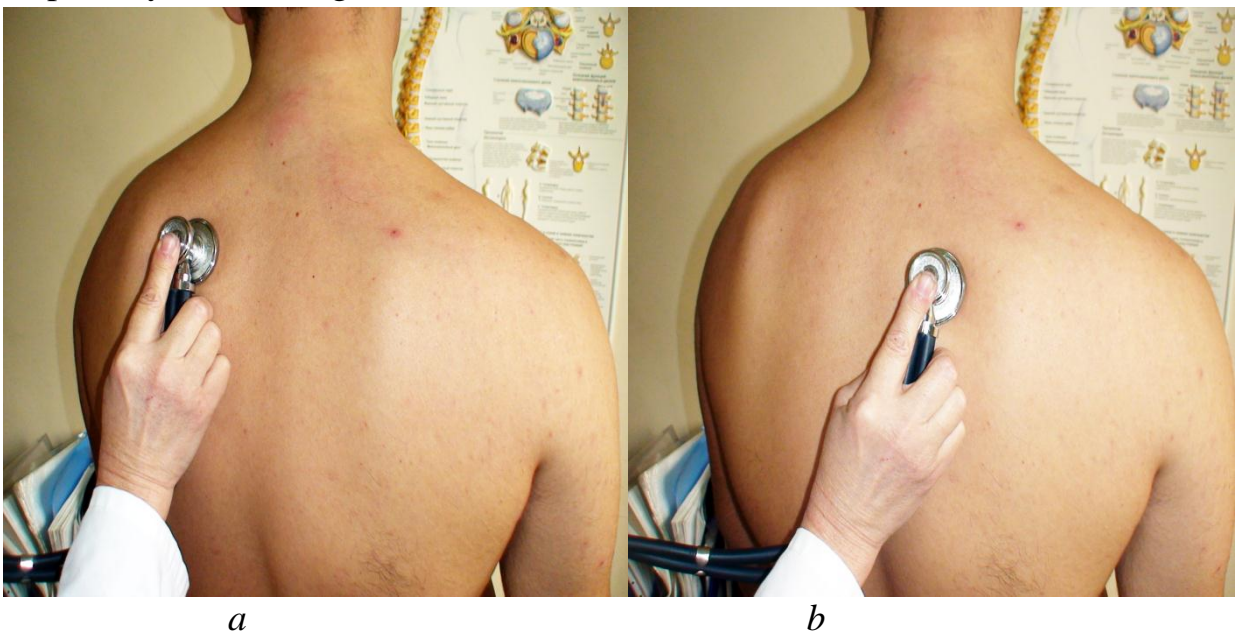

Fig.2.35. Auscultation of the lungs between the scapulae on the right and left (a,b)

4. Ask the patient to put the arms down along the body.
5. Place a phonendoscope under the scapular angle on the right, make auscultation on the right and left sides of the lungs outlined during the topographic percussion to determine and compare the respiratory sounds (Fig. 2.36 a, b).

Step 4. Bronchophony.

It is made by the same procedure as the vocal fremitus (it is auscultation equivalent of the vocal tremor), while the patient is asked to whisper the words that contain hissing sounds.

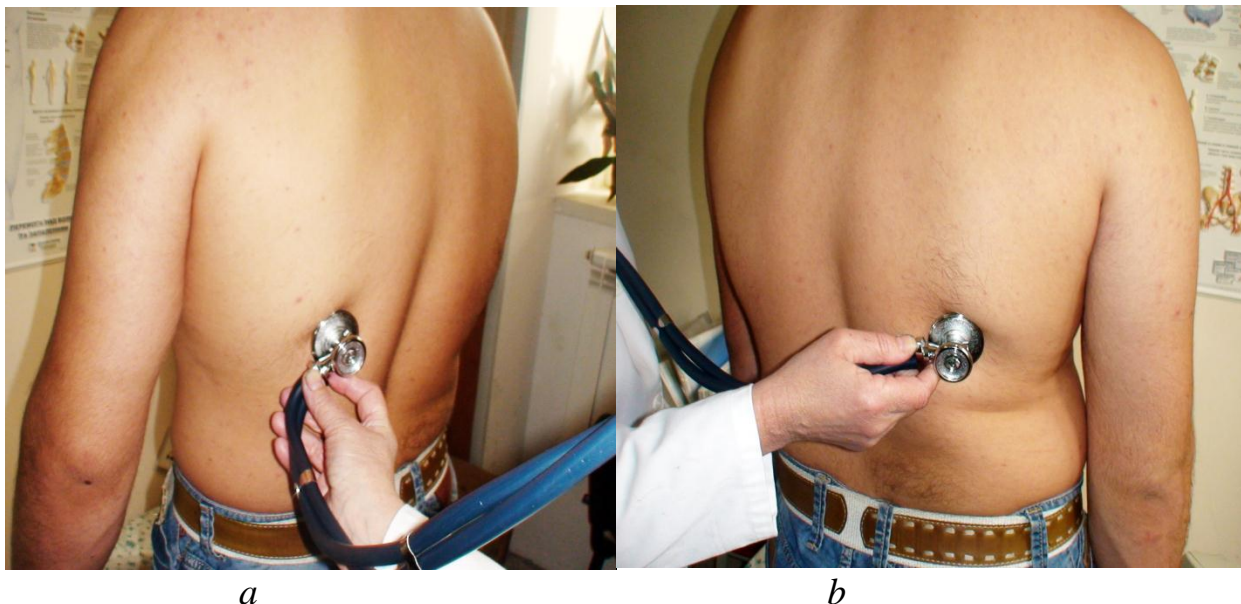


Fig.2.36. Auscultation under the scapular angle (a, b)

The example of the record of examination results in the medical history:

The breathing is vesicular over the lungs (if it changes, note the character of the change, the lung and place where there are changes being guided by the topographic line and ribs), there are no accessory sounds (if they are present, note their character and localization being guided by the topographic line and ribs), bronchophony is the same in the symmetric areas.

PART 3

THE CARDIOVASCULAR SYSTEM

3.1. A PLAN OF OBJECTIVE EXAMINATION OF THE CARDIOVASCULAR SYSTEM

1. Examination of the pericardial area and neck:

- a) Specific visible deformations - heart hump;
- b) Physiological pulsation – apex beat;
- c) Pathologic pulse - cardiac beat, retrosternal pulse, epigastric pulsation, carotid dance.

2. Palpation of the precardial area:

- a) Palpation of the apex beat;
- b) Palpation in pathological conditions - cardiac beat, "heart murmur."
- 3. Percussion of the borders of the heart and vascular bundle:
 - a) Percussion of the borders of cardiac dullness (relative and absolute);
 - b) Percussion of the vascular bundle.
- 4. Auscultation of the heart and blood vessels:
 - a) Auscultation of the basic sounds of the heart;
 - b) Auscultation of the modified basic sounds of the heart;
 - c) Auscultation of the additional and abnormal heart sounds;
 - d) Auscultation of the heart sounds.
- 5. Pulse palpation:
 - a) Characteristics of the pulse;
 - b) Pulse on the radial artery;
 - c) Changes of the pulse properties in pathological conditions;
- 6. Measurement of the blood pressure:
 - a) Characteristics of the arterial pressure (AP);
 - b) Determination of AP by Korotkov's method;
 - c) Determination of AP by Riva Rocchi method.

3.2. EXAMINATION OF THE PRECARDIAC AREA AND NECK

Specific deformations

Cardiac hump is a chest bulging, which has developed as a result of enlargement of the heart in childhood when the ribs are more pliable.

Physiological pulsation

Apex beat is a limited pulsation caused by the beat of the heart apex against the chest wall located in V intercostal space on the left, by 1-2 cm to the middle from the left mid-clavicular line in the norm.

Pathologic pulsations

Cardiac beat is a rather prevalent pulsation to the left from the sternum, caused by the contraction of the hypertrophied right ventricle (Fig. 3.1).

Epigastric pulsation is the pulsation in right ventricular hypertrophy (Fig. 3.2).

Retrosternal and aortic pulsation (II intercostal space on the right) is the pulsation in aneurysm of the ascending part and the aortic arch (Fig. 3.3).

Pulsation of the neck vessels is a marked pulsation of the carotids ("carotid dance") that develops in the aortic valve insufficiency, in the tricuspid valve insufficiency it is possible to detect pulsation of the jugular veins (**pathologic positive venous pulse**). In aortic insufficiency there is also detected **positive**

pseudocapillar pulse of Quincke - pulsation synchronous with the cardiac activity of the small white spot that appears while pressing the end of the nail.

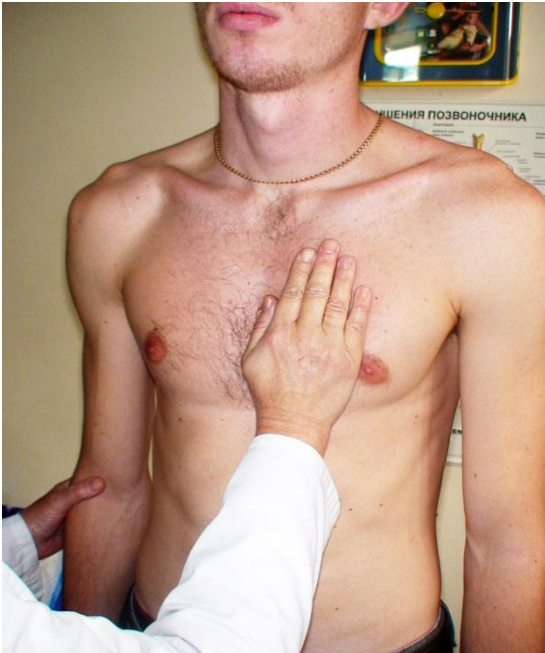

Fig.3.1. Determination of the cardiac beat

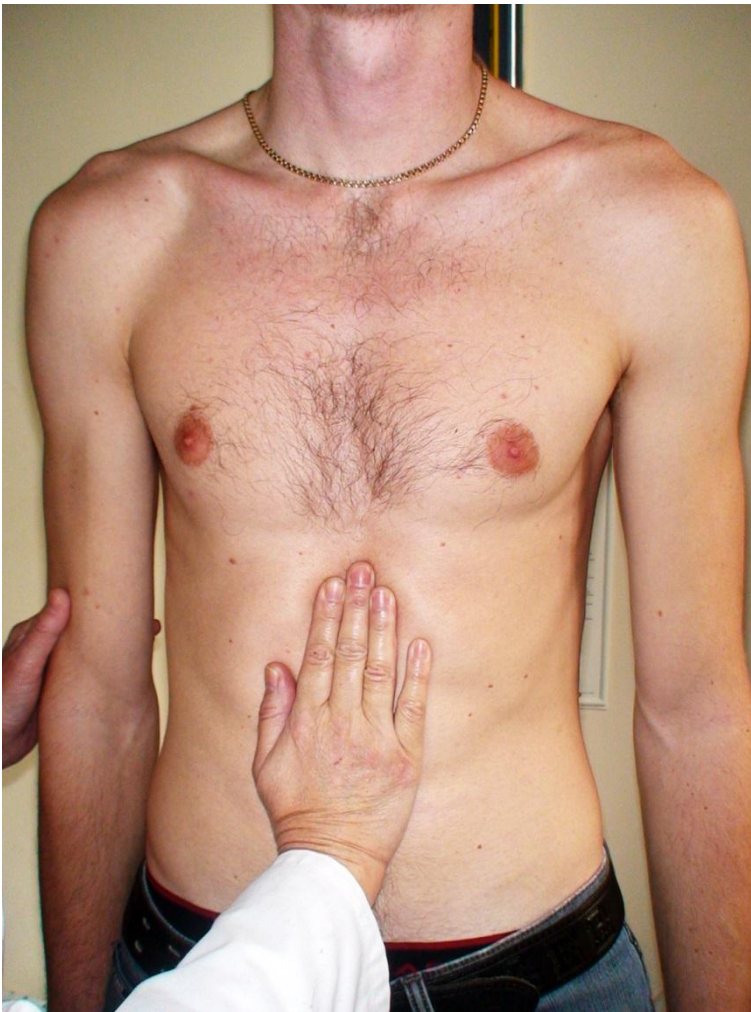
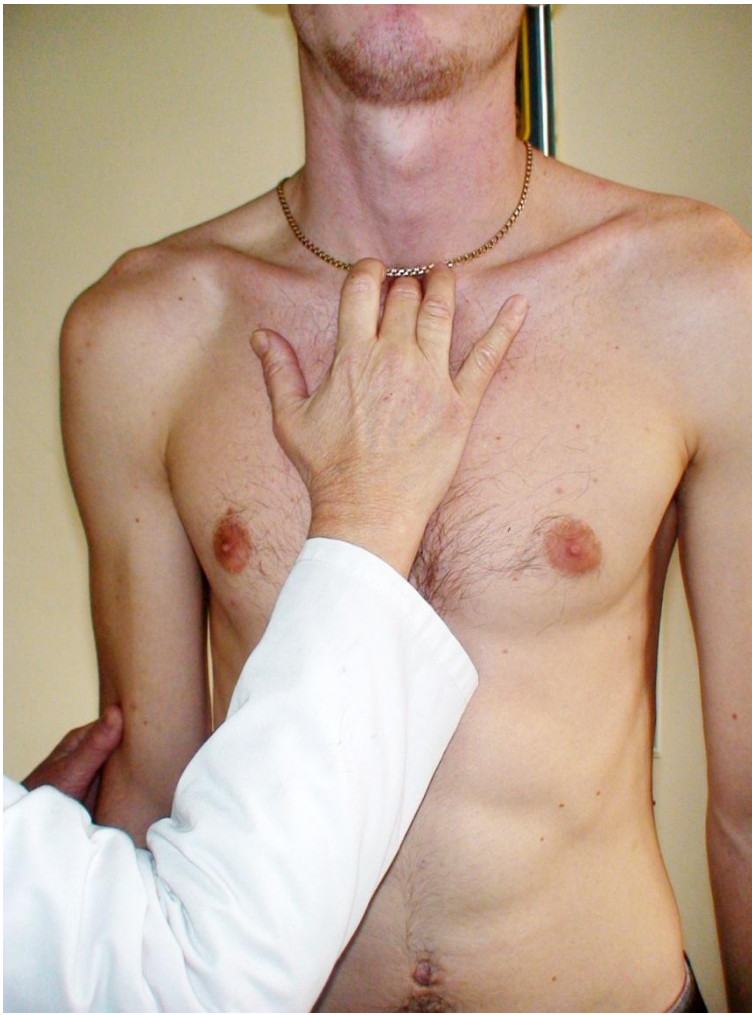
Fig.3.2. Determination of the epigastric pulsation

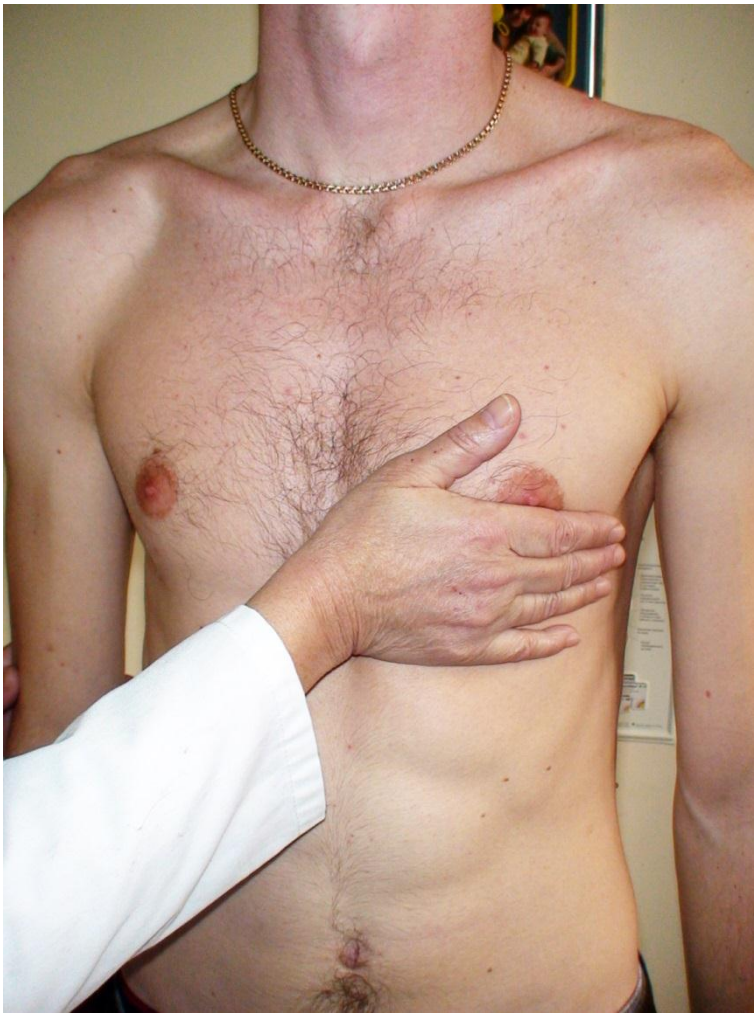

*Fig.3.3.*Determination of the retrosternal pulsation

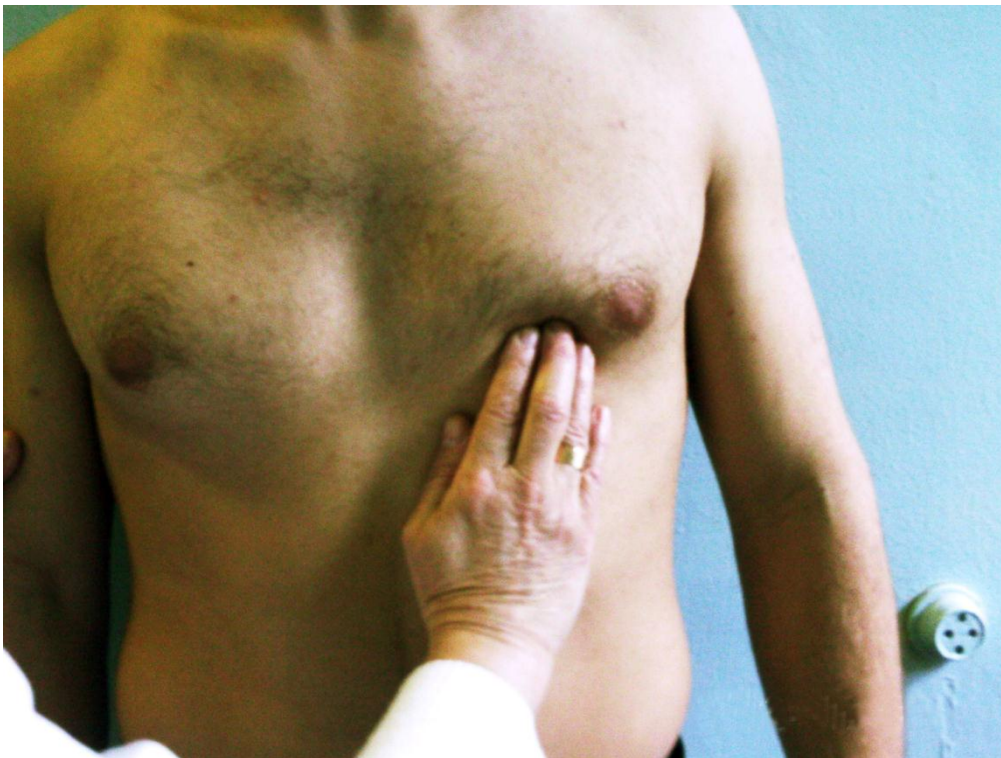3.3. PALPATION OF THE PRECARDIAC AREA AND NECK

Palpation of the apex beat

1. Place the basis of the palm of the right hand on the sternum of the patient, fingers are directed to the axillary area between III and VI ribs (**oriented palpation**; Fig. 3.4).



*Fig.3.4.*Determination of the apex beat, oriented palpation



*Fig.3.5.*Determination of the apex beat, specifying palpation

2. Feeling the apex beat, specify its localization with the tips of three bent fingers perpendicular to the surface of the chest in the place of the pre-recorded beat (**specifying palpation**; Fig. 3.5).

3. Determine the location, width or area, strength, height, resistance of the apex beat.

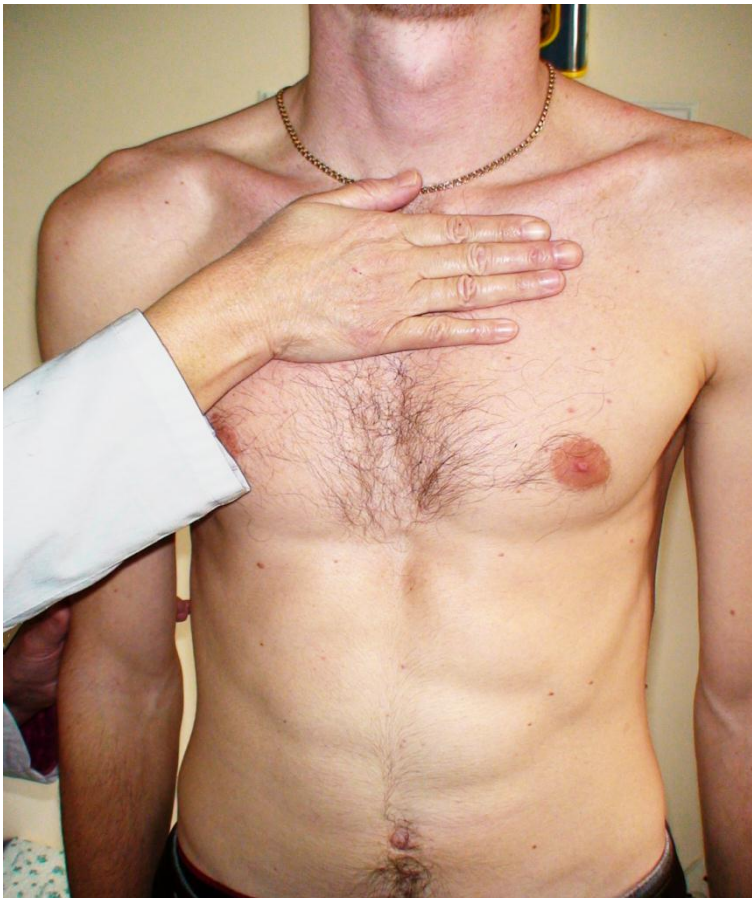Normally it is localized in V intercostal space at the distance of 1-2 cm from the middle of the left midclavicular line, its width is 1.5-2.0 cm; it has a moderate amplitude and power.

Palpation in pathological conditions

Cardiac beat caused by the contraction of the right ventricle is normally not palpable. It is determined on palpation of the entire area of the sternum, in hypertrophy of the right ventricle - in defects of the mitral valve, pulmonary artery, in pulmonary hypertension.

"Heart murmur" is the trembling of the chest, resulting from accelerated blood flow through a narrow opening.

Systolic "murmur", the trembling at the base of the heart, is a sign of stenosis of the aortic ostium (Fig. 3.6).



*Fig.3.6.*Determination of systolic “murmur”

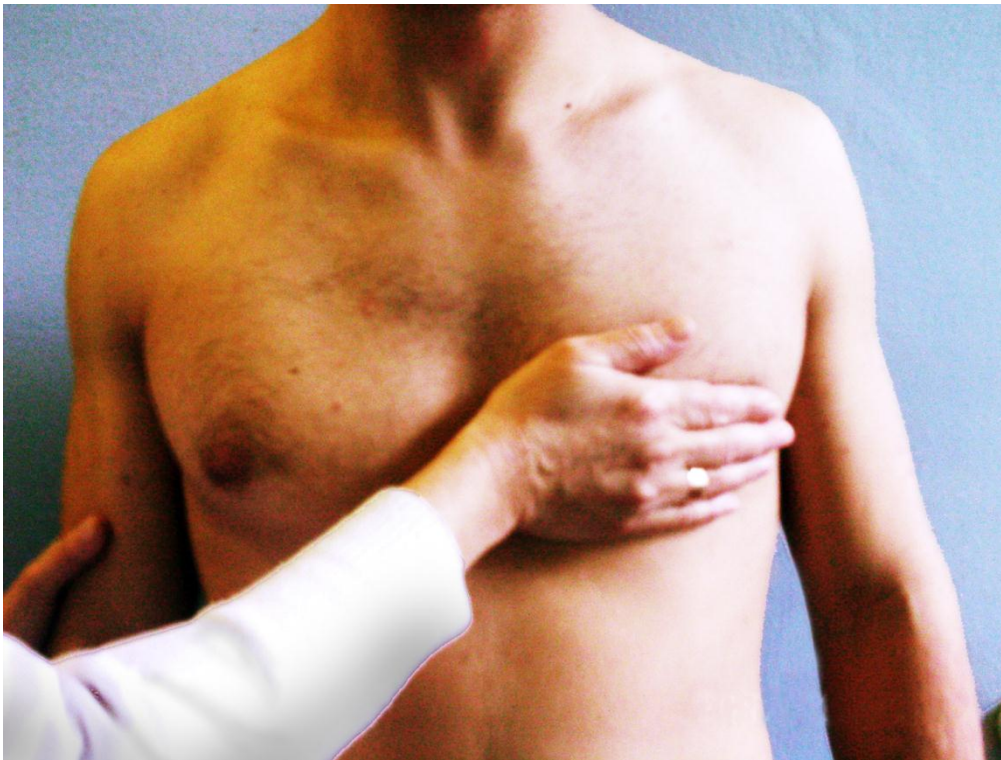


Fig.3.7. Determination of diastolic “murmur”

Diastolic "murmur", trembling at the apex of the heart, is a sign of mitral stenosis (Fig. 3.7).

3.4. PERCUSSION OF THE BORDERS OF THE HEART AND VASCULAR BUNDLE

Step 1. Percussion of the borders of the heart

To determine the diaphragm height make percussion with the blows of medial force along the right midclavicular line from top to bottom on the intercostal space, beginning from II, until the appearance of the dull sound - the lower border of the right lung (Fig. 3.8-3.13).

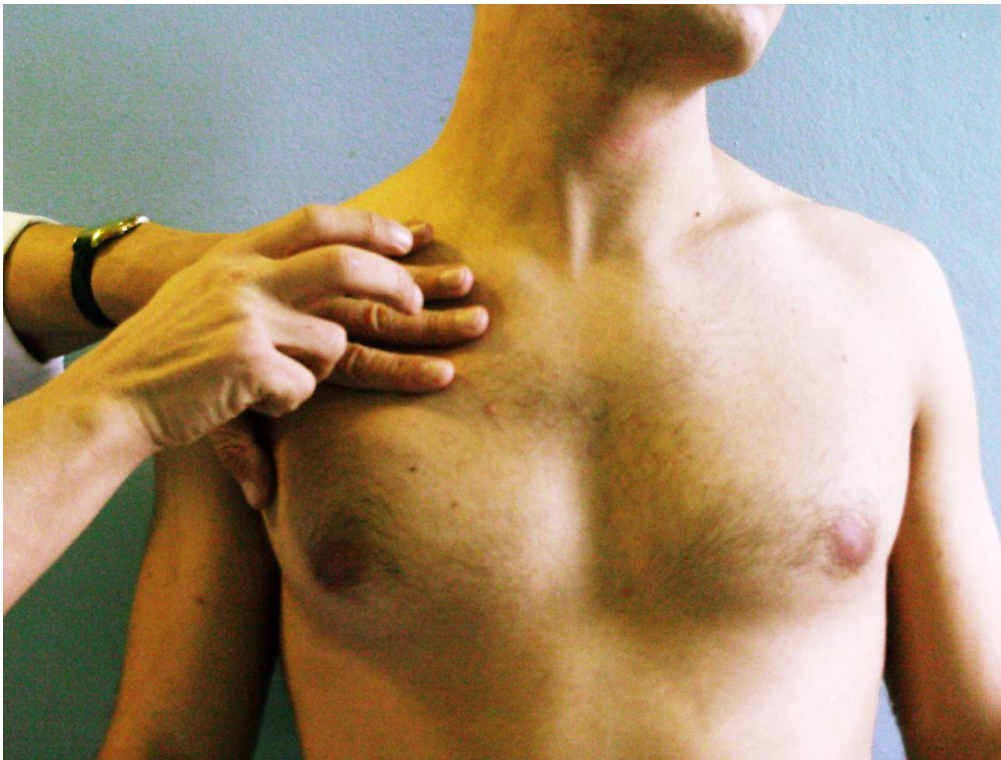

Fig.3.8. Determination of the diaphragm height, percussion in II intercostal space along the right midclavicular line.

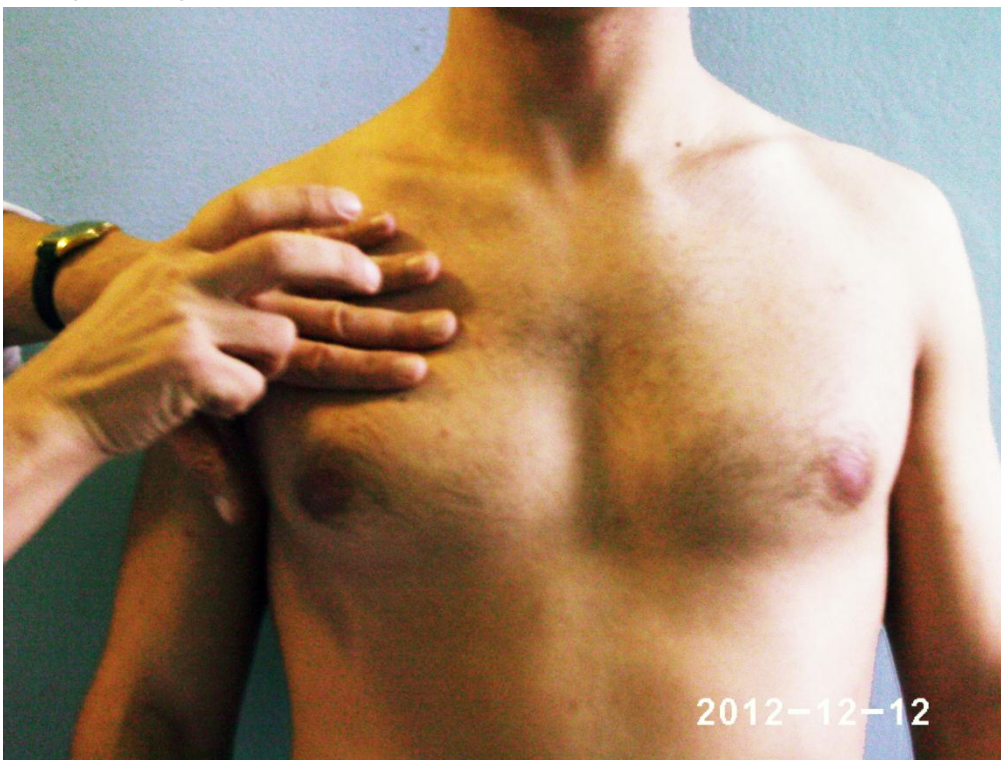


Fig.3.9. Determination of the diaphragm height, percussion in III intercostal space along the right midclavicular line.

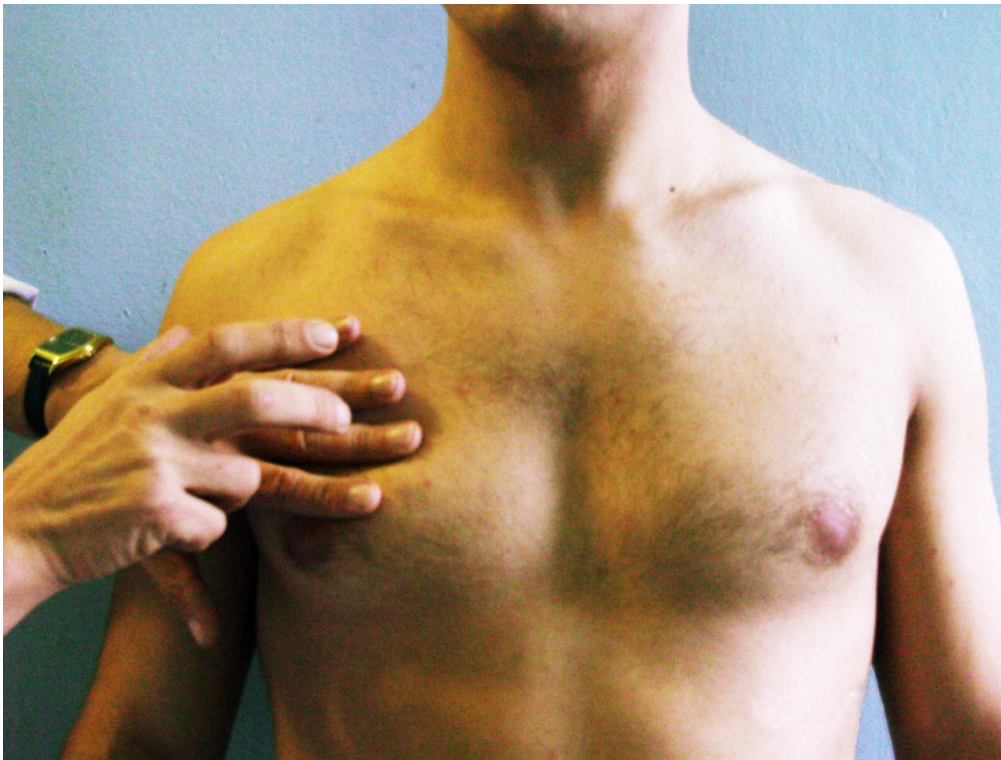


Fig.3.10. Determination of the diaphragm height, percussion in IV intercostal space along the right midclavicular line.

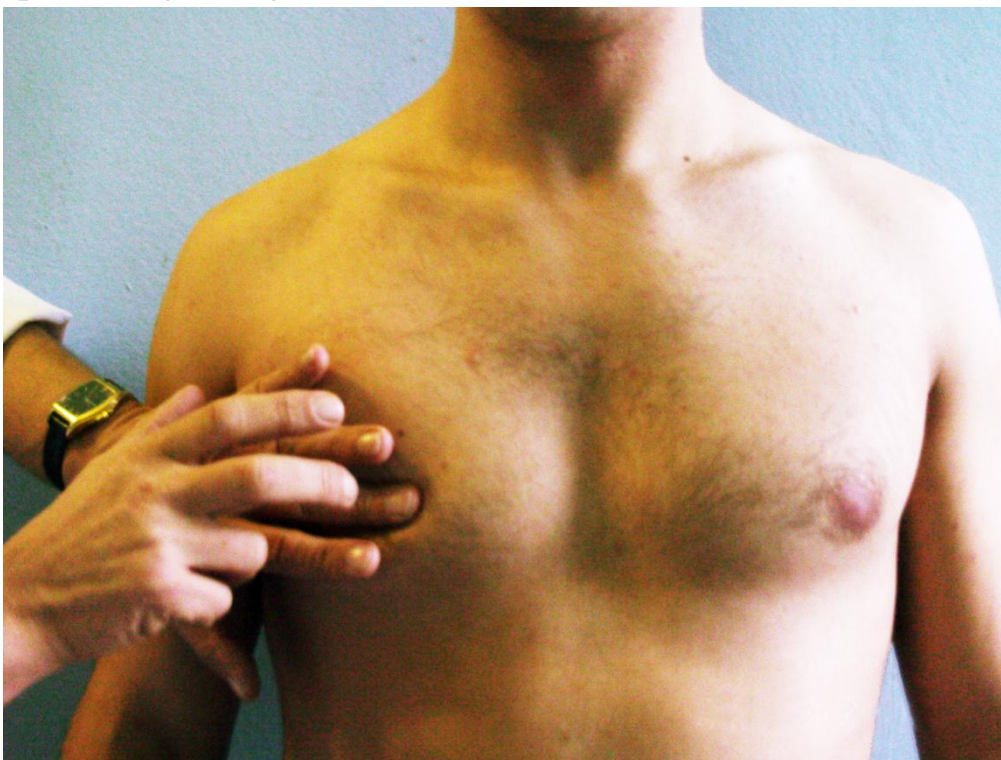


Fig.3.11. Determination of the diaphragm height, percussion in V intercostal space along the right midclavicular line.

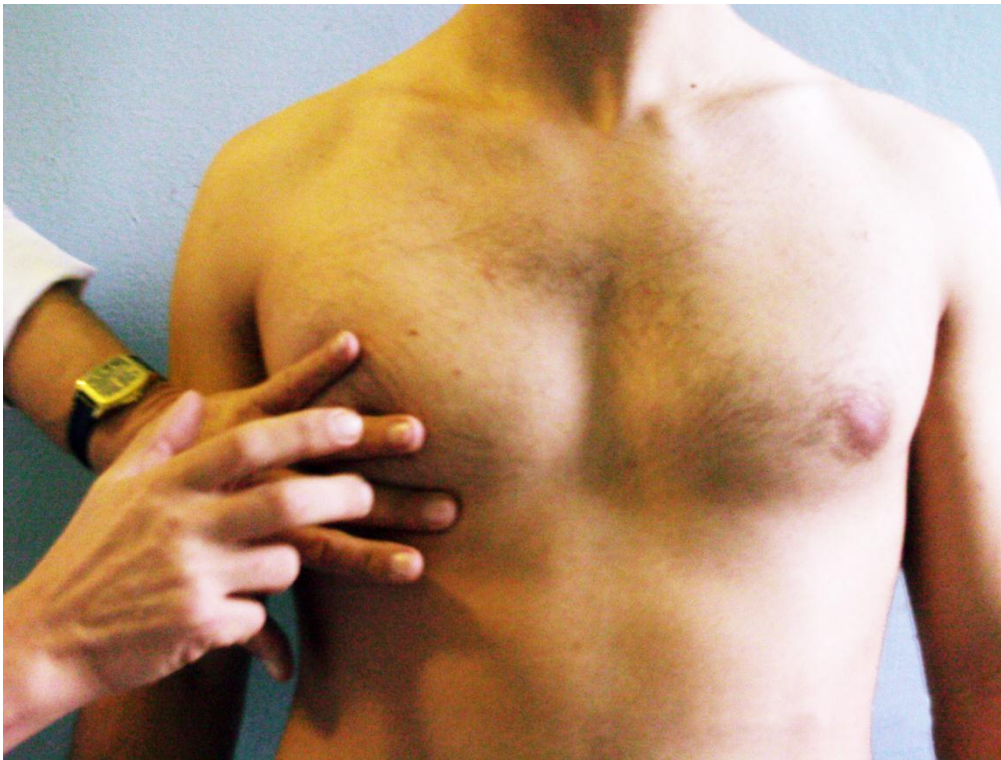

Fig.3.12. Determination of the diaphragm height, percussion in VI intercostal space along the right midclavicular line.

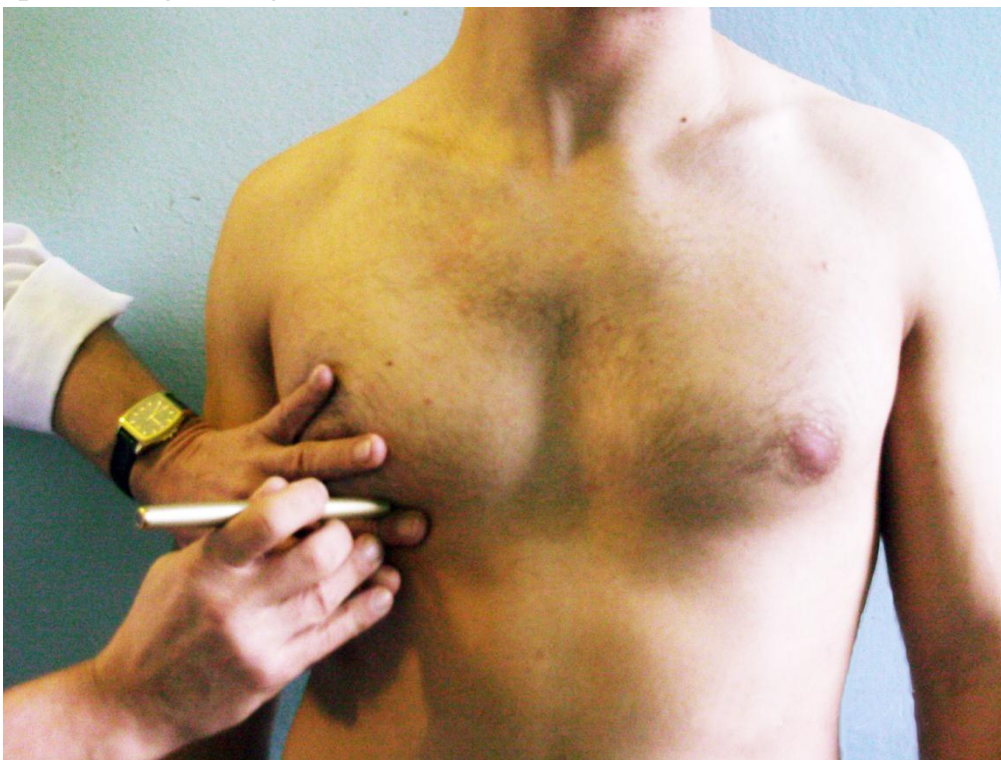


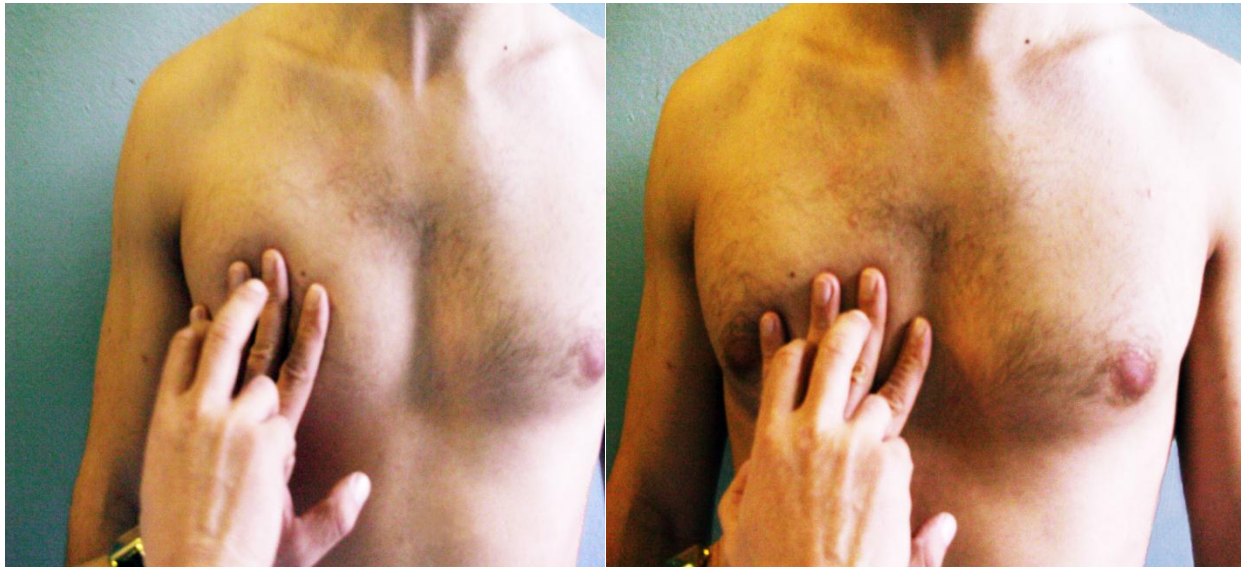Fig.3.13. Determination of the diaphragm height that is connected with the lower border of the right lung.

Step 2. Determination of the right border of the relative dullness of the heart.

1. A finger-pleximeter is raised by two ribs higher (or one intercostal space), placing it parallel to the right border of the heart. Make percussion gradually

moving the finger across the intercostal space in the direction of the heart until the appearance of the dull sound (Fig. 3.14, b).

2. Along the outer border of the finger, a mark is made on the skin of the chest wall using a dermatograph – this is the right border of the relative dullness of the heart. Normally, it is located by 0.5-1.5 cm outwards from the right border of the sternum (Fig. 3.15).



a

b

Fig.3.14. Determination of the right border of the relative dullness of the heart. Percussion until the appearance of the dull sound (a, b)

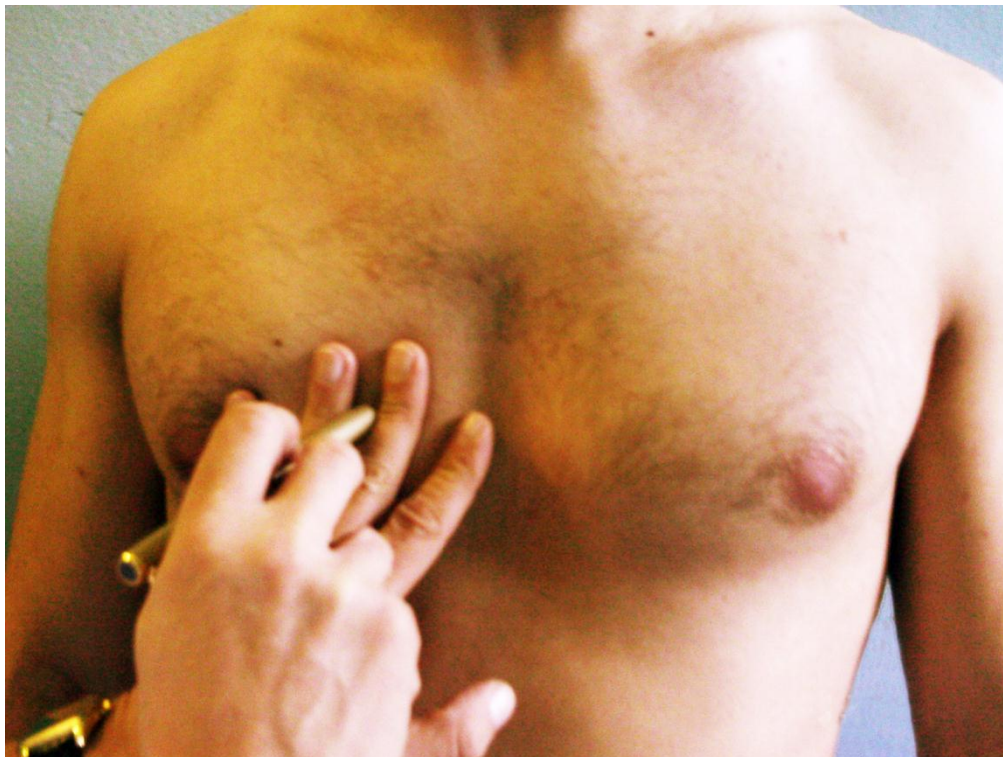


Fig.3.15. Determination of the right border of the relative heart dullness. Mark the border with a dermatograph.

Step 3. Determination of the right border of the absolute dullness of the heart.

Using the quiet percussion, continue percussing to the middle until the appearance of the dull sound. The border is determined along the outer edge of the finger, facing the area of the relative dullness of the heart. This is the right border of the absolute dullness of the heart. Normally, the right border of the relative dullness of the heart is on the left border of the sternum (Fig. 3.16, b).

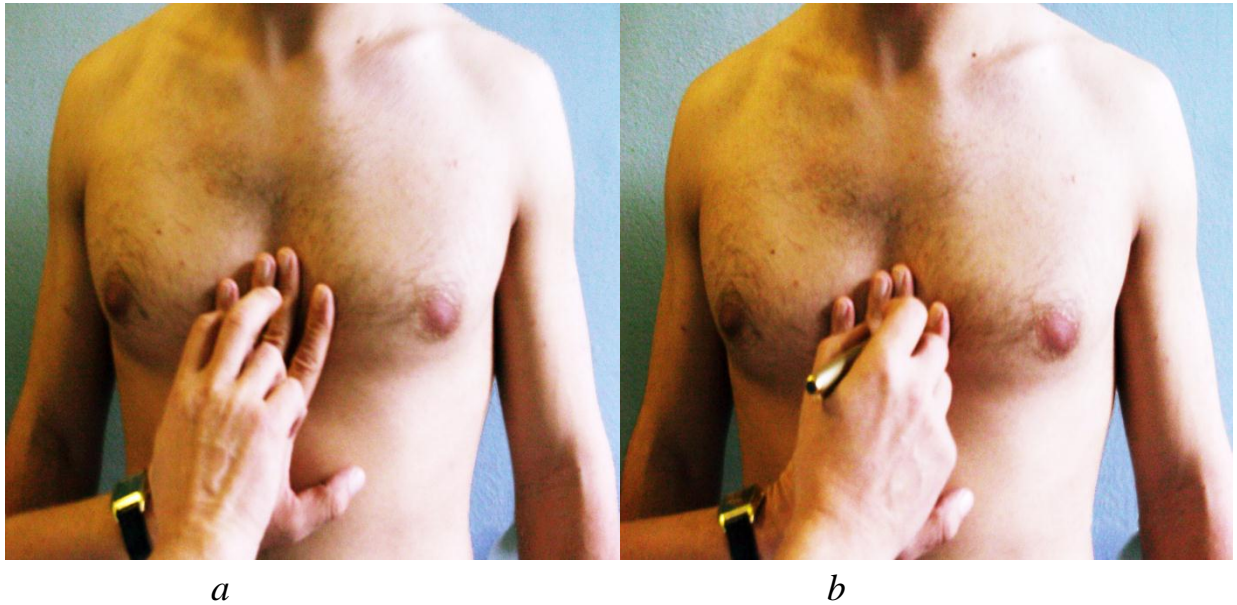


Fig.3.16. Determination of the right border of the absolute heart dullness (a, b)

Step 4. Determination of the upper border of the relative dullness of the heart.

Percussion is made along the left parasternal line. A finger-pleximeter is placed parallel to the ribs; make percussion from I intercostal space downwards. In case of the dull percussion sound, determine the border of the dullness, which is located along the upper edge of the finger, facing the clear pulmonary sound. Normally, the upper border of the relative heart dullness is located along the lower edge of III rib, it is formed by the pulmonary artery and left atrial auricle (Fig. 3.17, 3.18).

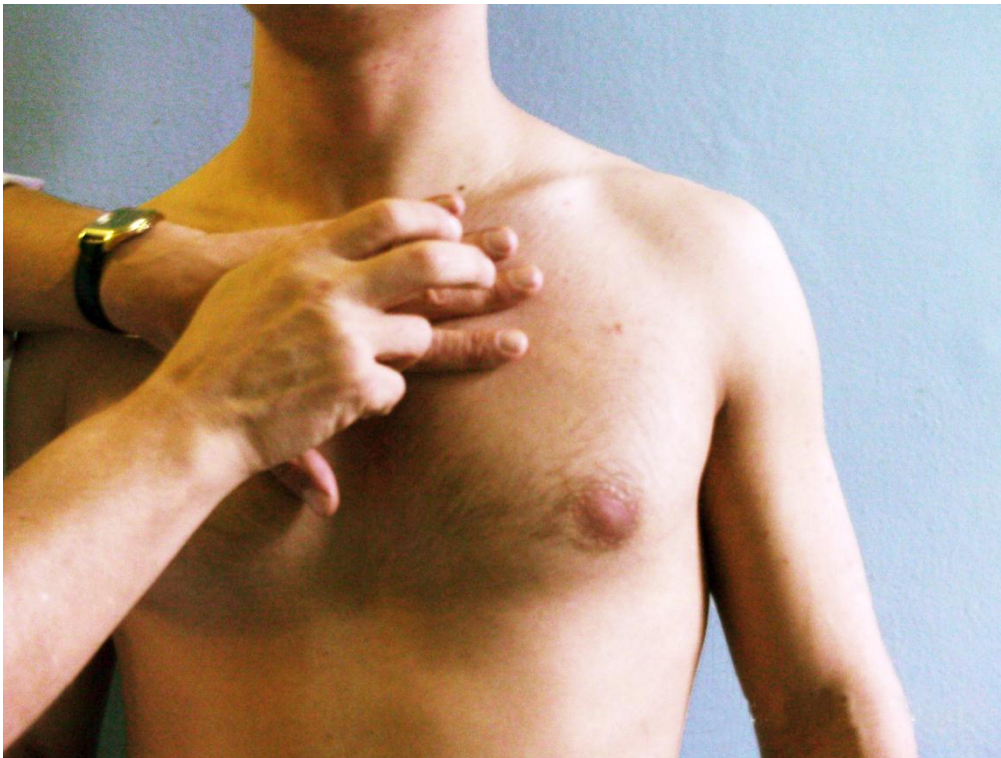


Fig.3.17. Determination of the upper border of the relative heart dullness.

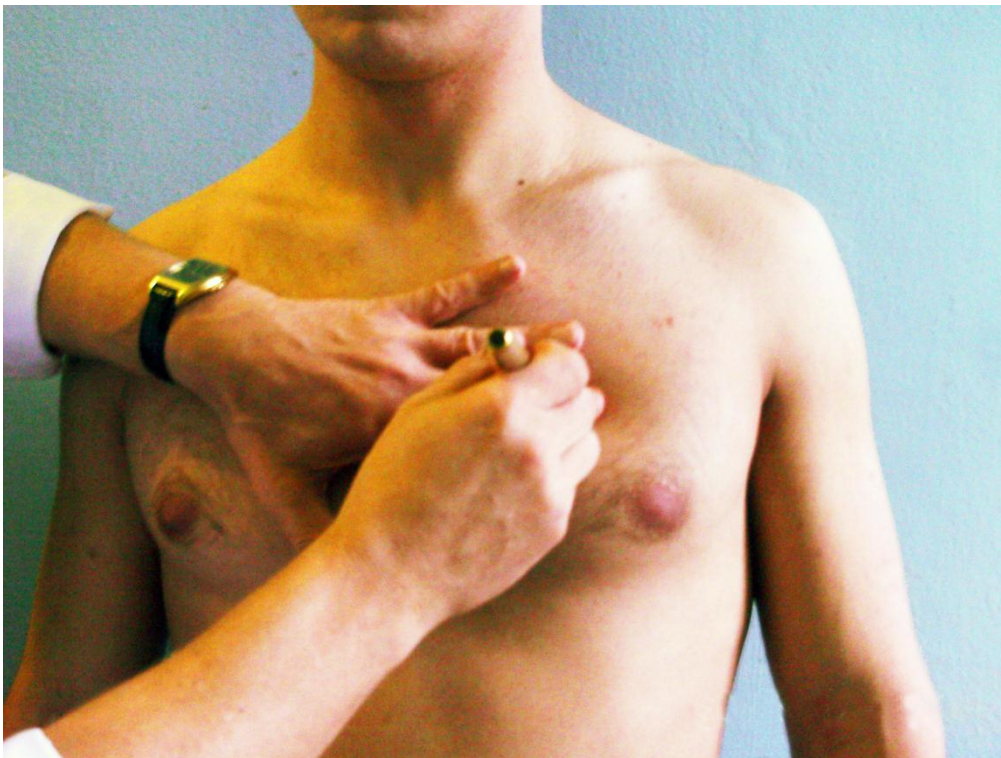


Fig.3.18. Determination of the upper border of the relative heart dullness along the lower edge of III rib.

Step 5. Determination of the upper border of the absolute dullness of the heart.

Continue the quiet percussion moving the finger downward until the appearance of the dull sound. Normally, the upper border of the absolute heart dullness is located along the lower edge of IV rib (Fig. 3.19).

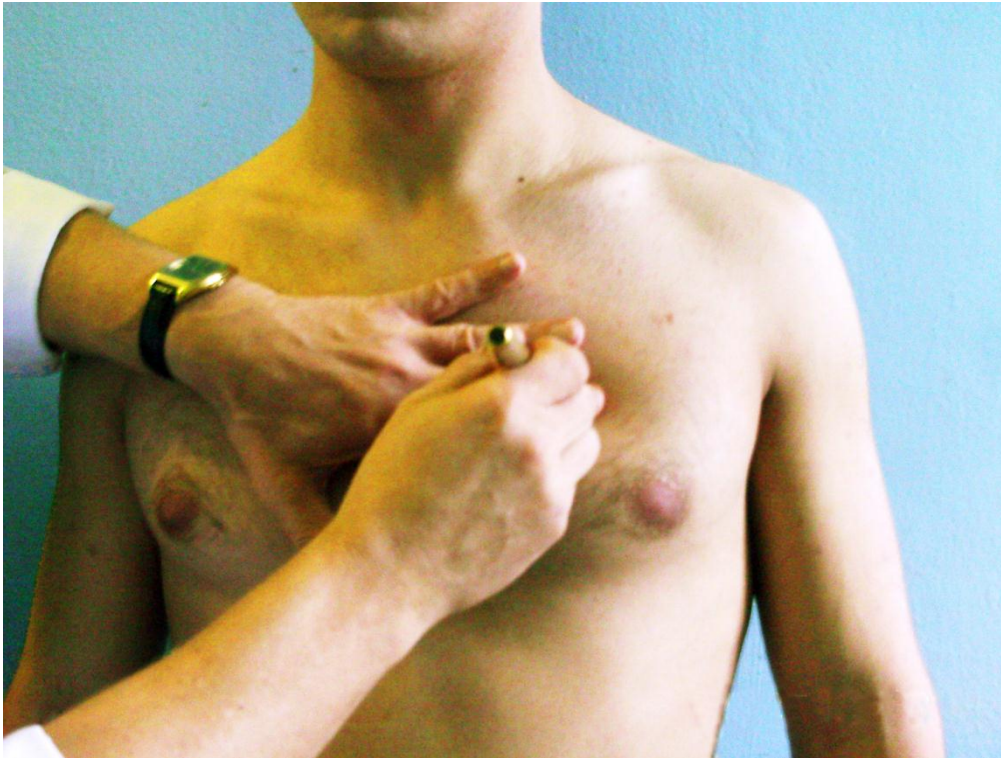


Fig.3.19. Determination of the upper border of the absolute dullness of the heart

Step 6. Determination of the left border of the heart

Percussion is made in the same intercostal space where the apex beat is located (normally in V intercostal space on the left), as the latter is formed by the left ventricle and is connected with the left border of the relative dullness of the heart. At first, find the apex beat by palpation, then put a finger-pleximeter (about 5 cm) outwards from it, parallel to the marked borders and make percussion toward the sternum - the place of transition of the clear pulmonary sound into the dull one (Fig. 3.20, a, b).

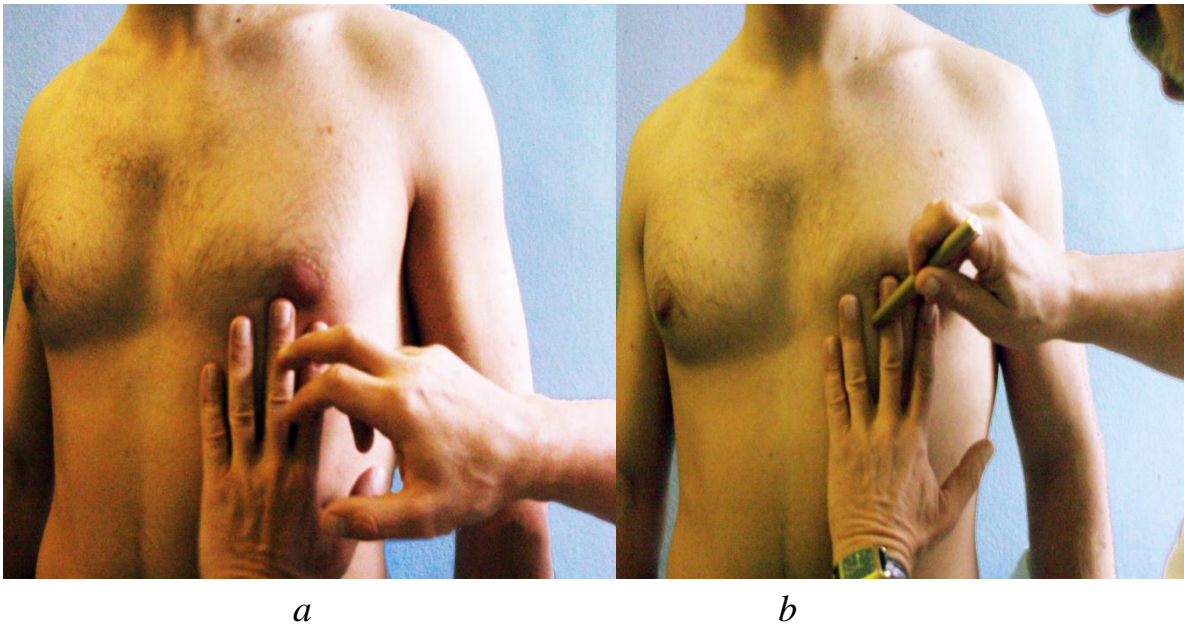


Fig.3.20. Determination of the left border of the heart dullness.

Step 7. Percussion of the vascular bundle

1. The width of the vascular bundle is determined in II intercostal space on the right and left, making quiet percussion from the midclavicular line in the direction of the sternum, and the finger-pleximeter is placed parallel to the sternum (Fig. 3.21).
2. In case of appearance of the dull percussion sound, make a mark on the edge of a finger, facing the clear pulmonary sound (Fig. 3.22).
3. Normally, the right and left borders of the vascular bundle dullness are connected with the edges of the sternum, and its width is 5.0-6.0 cm; dilatation on the right is observed in case of aortic aneurysm, on the left – in case of pulmonary artery aneurysm (Fig. 3.23).

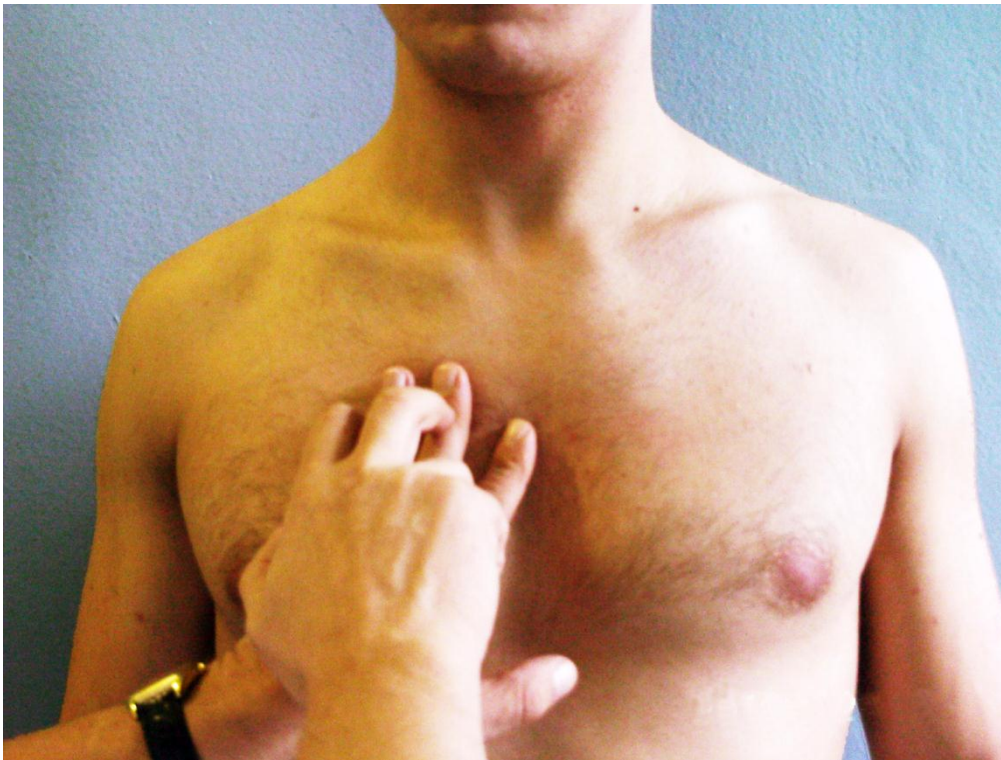


Fig.3.21. Localization and direction on the vascular bundle percussion.



Fig.3.22. Determination of dilatation of the vascular bundle (on the left)

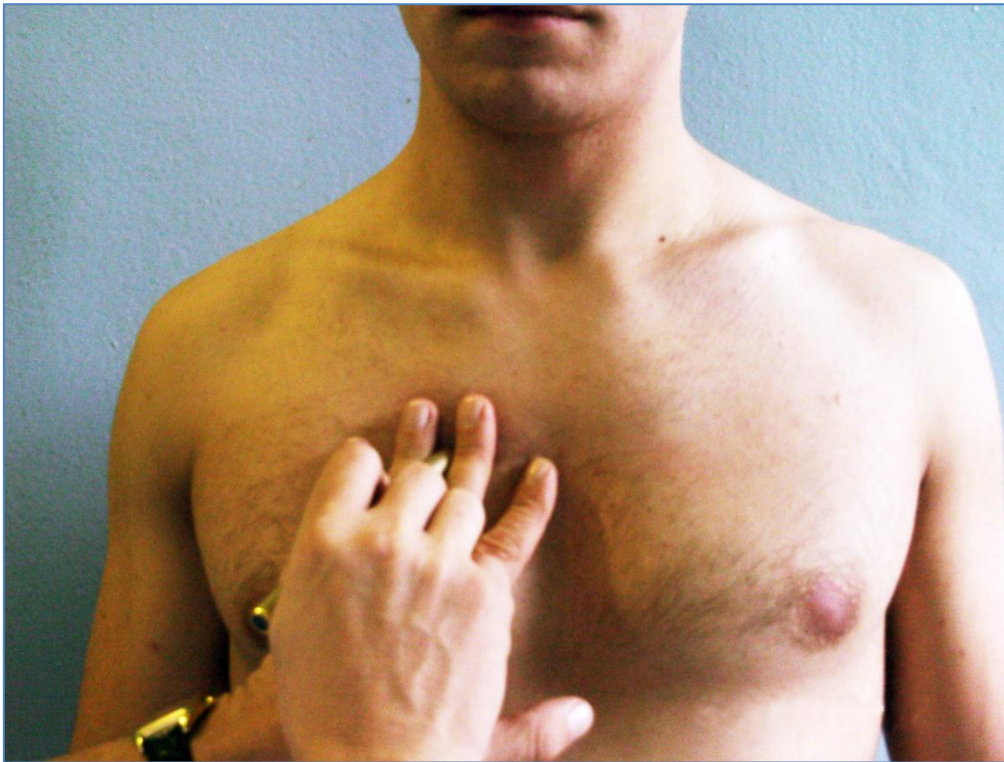


Fig.3.23. Determination of dilatation of the vascular bundle (on the right)

3.5. Auscultation of the heart and blood vessels

Auscultation of the basic heart sounds

There are five main points of the heart auscultation:

The first point - the place of auscultation of the mitral valve (apex, apex beat, Fig. 3.24).

The second point - the point of the aorta (II intercostal space to the right of the sternum; Fig. 3.25).

The third point - the point of the pulmonary valve (II intercostal space to the left of the sternum; Fig. 3.26).

The fourth point - the point of the tricuspid valve (at the base of the xiphoid process of the sternum; Fig. 3.27).

The fifth point - Botkin - Erb (to the left of the sternum, in the place of attachment of III-IV ribs, additional point for auscultation of the aortic valve, Fig. 3.28).

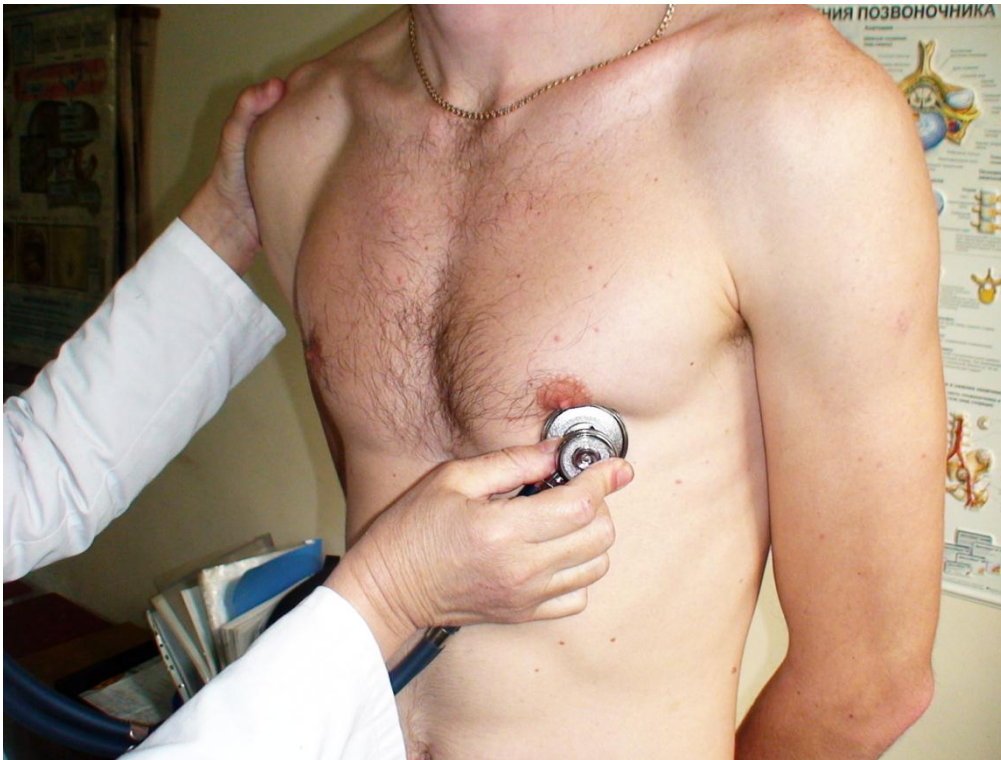

Fig.3.24. Determination of the first point of the heart auscultation

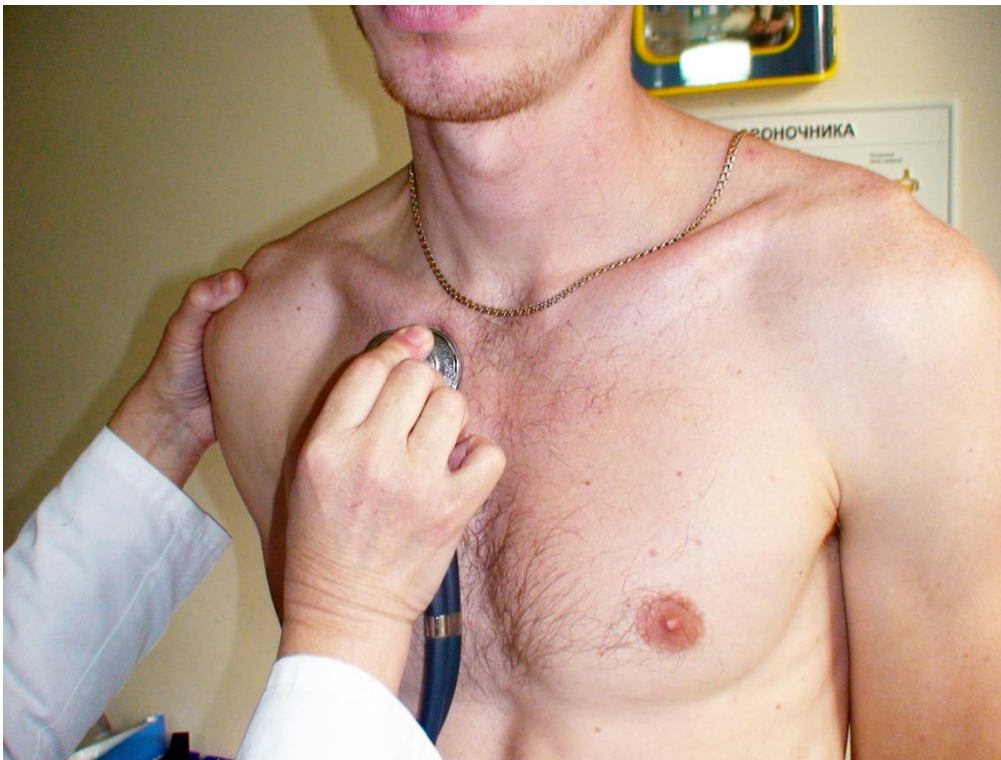

Fig.3.25. Determination of the second point of the heart auscultation

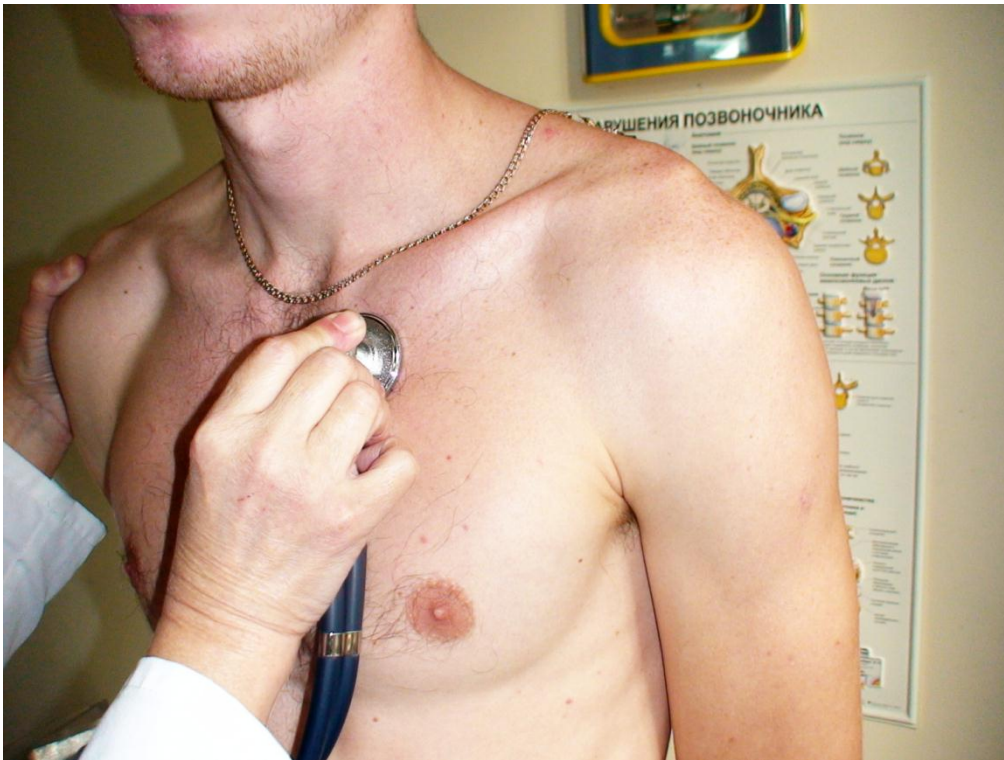

Fig.3.26. Determination of the third point of the heart auscultation

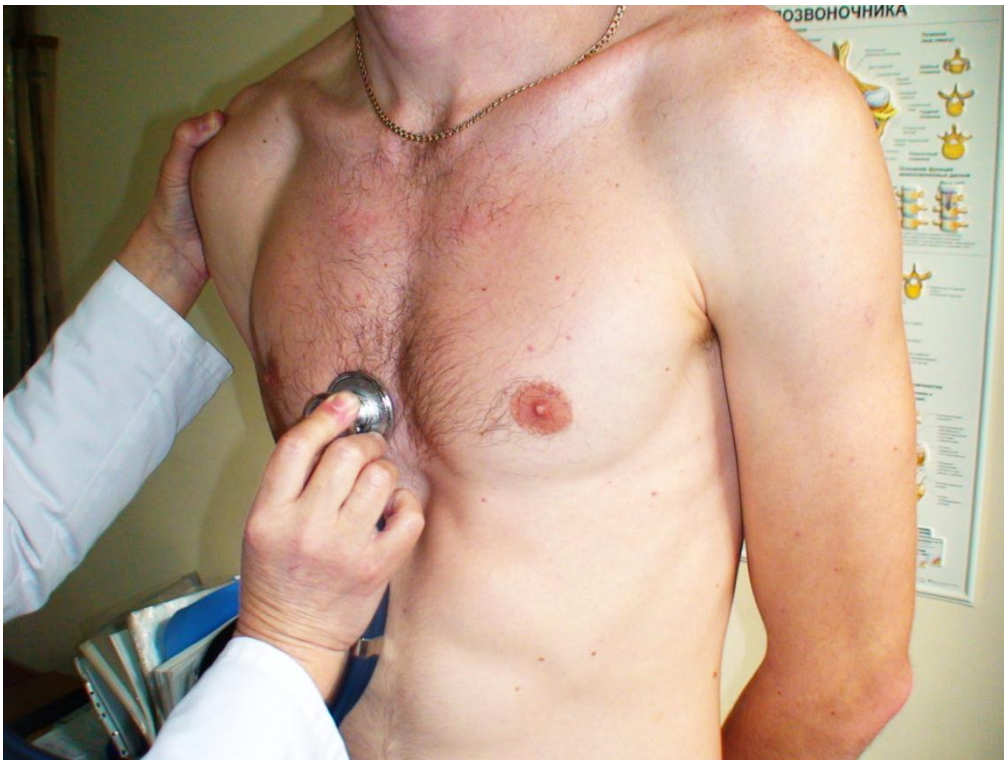

Fig.3.27. Determination of the fourth point of the heart auscultation

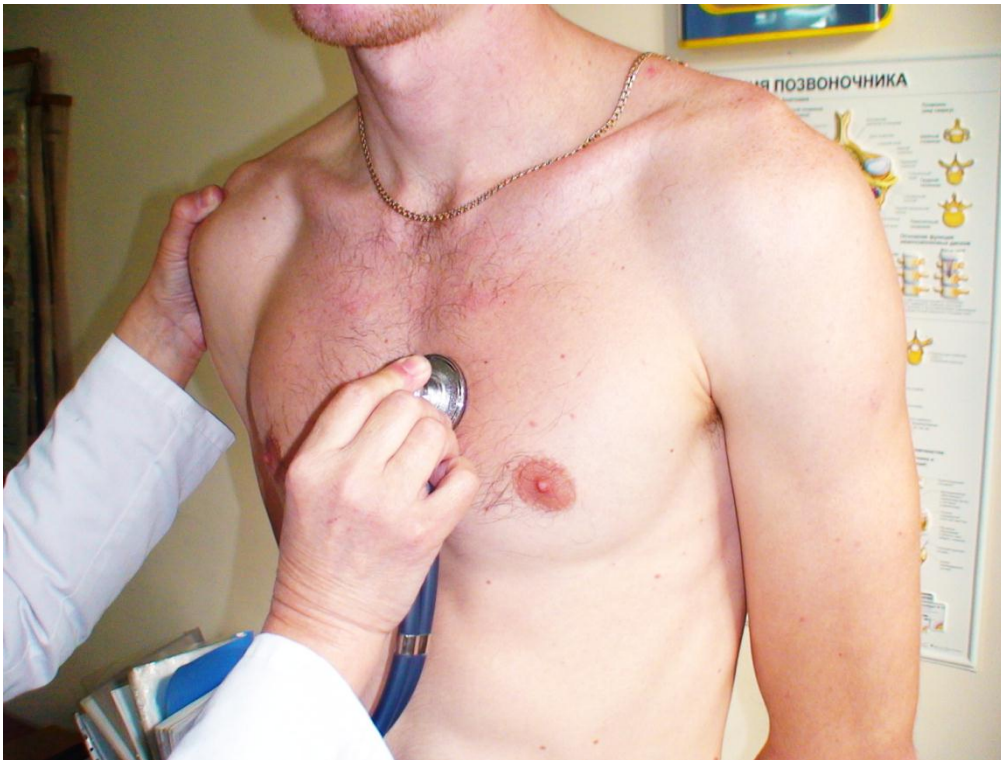

Fig.3.28. Determination of the fifth point of the heart auscultation

Heart rhythm is normally binomial (two sounds are auscultated):

- I sound develops at the beginning of the ventricular systole (systolic); duration is normally 0.08-0.14 sec. Components:

- 1) valvular - closing and tension of the atrioventricular valves in the isometric contraction phase;
- 2) muscular (ventricular) – tension of the ventricles of the myocardium during I period of the closed valves (i.e during isometric contraction);
- 3) vesicular-fluctuation of the initial parts of the aorta and pulmonary artery at the initial period of expulsion.
- 4) atrial, precedes a valve component conditioned by the atrial contractions.

- **II sound** occurs at the beginning of diastole of the ventricles (diastolic); normal duration is 0.05-0.08 sec.

Components:

- 1) valvular - closing and tension of the aortic valves and pulmonary artery;
- 2) vascular – fluctuations of the walls of the initial parts of the aorta and pulmonary artery; affection of the heart muscle (myocardial infarction, myocarditis).

Standard differences of I and II sound at the apex:

- a) I sound is more noisy, lower, longer (on an average 0.11 sec), followed by a short pause (0.23 sec);
- b) I sound coincides with the apical thrust and carotid pulse;

c) II sound at the apex is quiet, high, shorter (on an average 0.07 sec), followed by a long pause (0.43 sec).

Physiological III and IV sounds are heard rarely:

- **III sound** occurs in protodiastole, its appearance is caused by passive ventricular distension during their fast filling with blood. This is a weak, low and dull sound that appears in 0.12-0.15 sec after II sound.
- **IV sound** occurs in the phase of presystole (i.e. at the end of the ventricular diastole caused by fluctuations in the ventricular wall during their active fast filling with blood at the moment of the atrial contraction.

Physiological III and IV sounds can be heard in children, adolescents, rarely in adults. As a rule, they are evidence of severe affection of the heart muscle (myocardial infarction, myocarditis) in elderly people.

Auscultation of the changed basic heart sound

Auscultation of the heart can determine the change in intensity (strengthening or weakening) of both sounds observed in certain pathological conditions (Table. 3.1).

For evaluation of the heart and subsequent prediction of the course of the disease, auscultation is of great importance for characteristic of the additional (pathological) heart sounds (Table. 3.2, 3.3).

Table 3.1.

Auscultation characteristic of the basic (physiological) heart sounds as to the change of intensity

Auscultation characteristic	Strengthening (the accent over the point of auscultation)	Weakening (the component, which is weakened)
I sound (over the apex)	<ul style="list-style-type: none"> - Mitral stenosis (flapping I sound) - Tricuspid stenosis - Tachycardia of different genesis, extrasystole (hemodynamically important combined with insufficient filling of the ventricles during diastole) - A syndrome of untimely excitation of the ventricles. - “Canon sound” of Strazhesko (simultaneous excitation of the 	<ul style="list-style-type: none"> - Mitral or tricuspid insufficiency (valvular) - Aortal insufficiency (muscular) Stenosis of the aortal ostium and pulmonary artery (muscular)

	atria and ventricles in complete atrioventricular blockade.	
II sound (over the aorta)	<ul style="list-style-type: none"> -Increased arterial pressure in the systemic circulation (hypertension, symptomatic arterial hypertension) - Changes in the structure of the aortic wall and valves (atherosclerosis, calcinosis, increased sometimes up to metallic tint) -Temporary intensified II sound over the aorta due to emotional and physical exertion) 	<ul style="list-style-type: none"> - Aortic regurgitation Stenosis of the aortal ostium -Weakness of the left ventricular muscle (myocardial infarction, myocarditis, etc) Arterial hypotensions
III sound (over the pulmonary artery)	<ul style="list-style-type: none"> -Mitral defects with pulmonary hypertension -Congenital defects (atresia of Botallo's duct, interventricular and interatrial septum) -Left ventricular insufficiency -Acute and chronic "pulmonary heart" 	<ul style="list-style-type: none"> -Defects of the pulmonary artery – stenosis of the ostium or valvular insufficiency -Insufficiency (weakness) of the right ventricle

Table 3.2.

Characteristic of auscultation phenomenon

Auscultation phenomenon	Characteristic of phenomenon	Rhythm which appears in this phenomenon
Click of mitral valve opening	It occurs in 0.07-0.13 sec after appearance of II sound, it is pathognomic for mitral stenosis	Triple rhythm of mitral stenosis ("quail" rhythm) is a combination of flapping I sound, II sound and a sound of mitral valve opening
III sound (pathological)	It occurs at the beginning of diastole in 0.12-0.20 sec after appearance of II sound/ It is caused by additional fluctuations of the cardiac	Protodiastolic gallop rhythm. It occurs in a reduced tone of the left ventricle myocardium (acute myocardial infarction, cardiomyopathies, etc)

	muscle in protodiastole	
IV sound (pathological)	It occurs in presystole (presystolic phase of diastole) in acceleration of the atria contraction	Presystolic gallop rhythm. It occurs in mitral stenosis, atrioventricular block.
III and IV sounds	Summarized sound, which merge (especially in tachycardia), it is characterized by strengthening of both (III and IV) sounds	Mesodiastolic gallop rhythm
Systolic click	A short additional high frequency sound, it occurs during systolic (short) pause. It is registered in 0.08 sec and longer after appearance of the first fluctuations of I sound.	Early (systolic) click – a sound of extension of the aorta or pulmonary artery. It occurs in atherosclerosis, nonspecific aortitis, etc. Middle systolic (mesosystolic) and late systolic click is heard in prolapse of the mitral valve
Embriocardia	It resembles sounds of the fetus heart or ticking of the watch. It is characterized by sounds of the similar sonority and the same duration of pauses between them	Pendulum-like rhythm. It is observed in acute cardiac insufficiency, attack of paroxysmal tachycardia, high fever.

Table 3.3.

Auscultation characteristic of the additional (pathological) heart sounds

Auscultation characteristic	Splitting (prolongation between the components of the sound up to 0.03 sec), doubling (a pause between the components is 0.03-0.06 sec)
I, II sounds (physiological states)	In children, teenagers and patients with labile nervous system it occurs due to phases of respiration (it is better detected during deep breathing in)
I sound (pathological states)	In asynchronous contraction of the ventricles, asynchronous closing of the atrioventricular valves:

	hypertrophy and dilatation of the left ventricle, blockade of the bundle of His.
II sound (pathological states)	In asynchronous closing of the valves of the aorta and pulmonary artery: -mitral stenosis or insufficiency; -nonunion of the interatrial septum- stenosis of the ostium of the pulmonary artery

3.6. PALPATION OF THE PULSE

Characteristics of the pulse

Pulse is a fluctuation of the artery walls due to the heart contraction, expulsion of the blood in the arterial system and change of the pressure in it in systole and diastole. Spread of the pulse wave is caused by the ability of the artery walls to elastic extension and collapse. During pulse feeling such properties are determined:

- 1) rate;
- 2) rhythm;
- 3) filling;
- 4) tension;
- 5) value;
- 6) form;
- 7) state of the vessel wall.

The pulse rate usually corresponds to the number of the heart contractions and it is 60-90 per min in the norm.

The pulse on the radial artery

Step 1. Feeling of the pulse on the radial artery should be started simultaneously on both hands, because in pathological cases, there may be a noticeable difference in pulse filling, tension and value.

Step 2: The hand of the examined person is enclosed in the area of the radial-carpal joint so that the thumb is located on the back of the forearm and other fingers - over the artery (Fig. 3.29, a, b).

Step 3: After determining the artery it is pressed against the adjacent bone, which facilitates establishing the pulse properties.

Step 4. If there is no difference in the pulse, it is felt on one hand. If there are different pulses, it is taken on the hand where the pulse waves are better felt.

Step 5. The pulse can also be taken in the carotid, temple, popliteal, posterior tibial artery, back foot artery and so on. The pulse on these arteries of the lower

extremities is very important because weakening and sometimes its absence is observed in patients with obliterating endarteriitis, atherosclerosis and diabetes mellitus (Fig. 3.30-3.35).

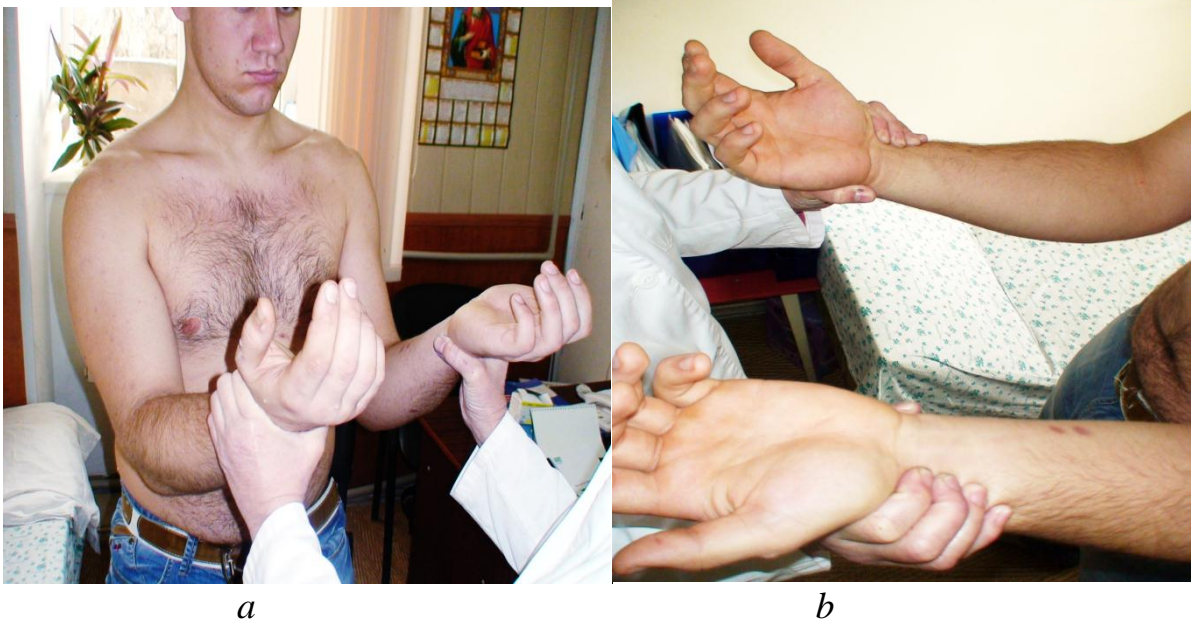

Fig. 3.29. Taking the pulse on radial artery right and left hand(a, b).



Fig. 3.30. Taking the pulse on the temple artery.

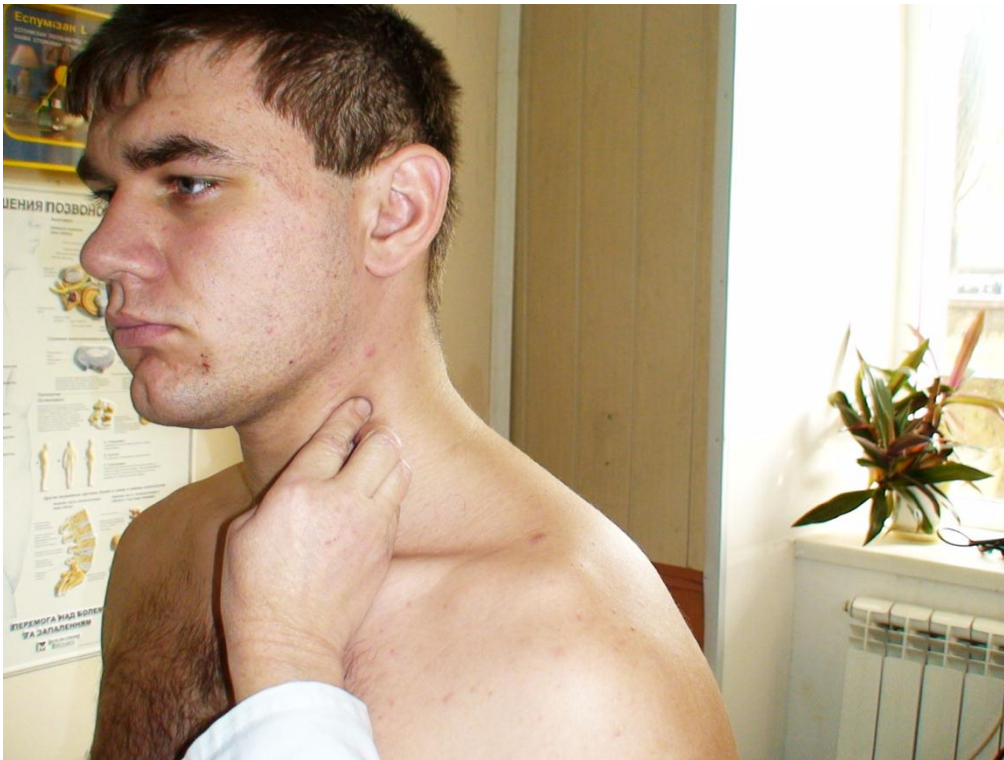

Fig. 3.31. Taking the pulse on the carotid artery.

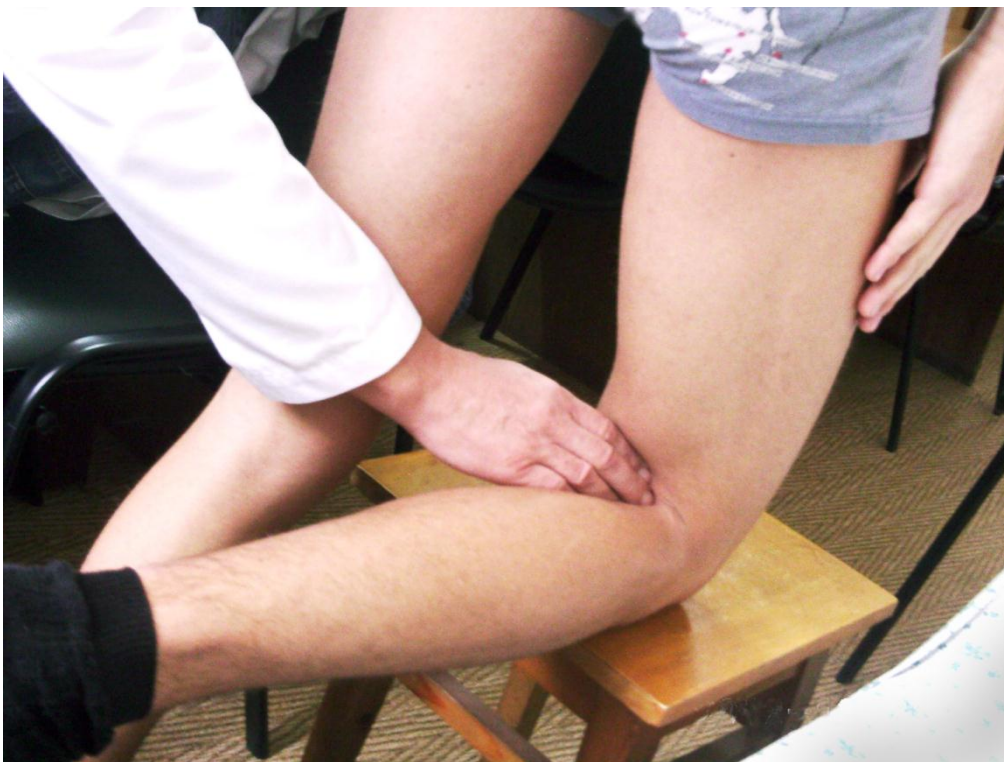

Fig. 3.32. Taking the pulse on the popliteal artery.

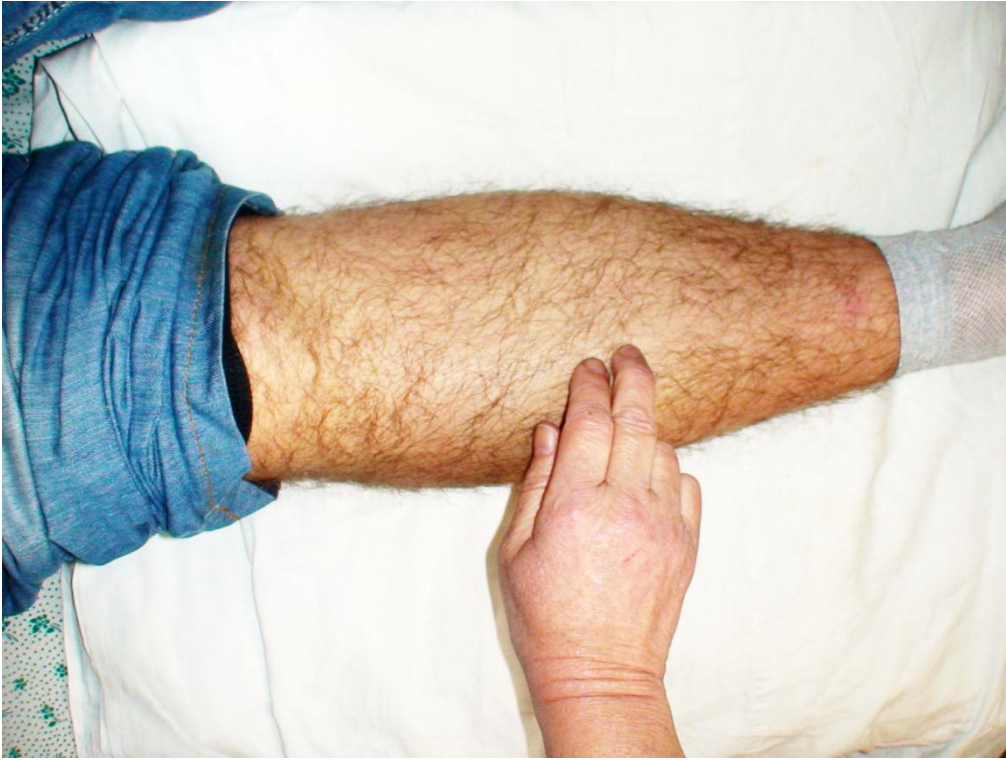

Fig. 3.33. Taking the pulse on the tibial artery.

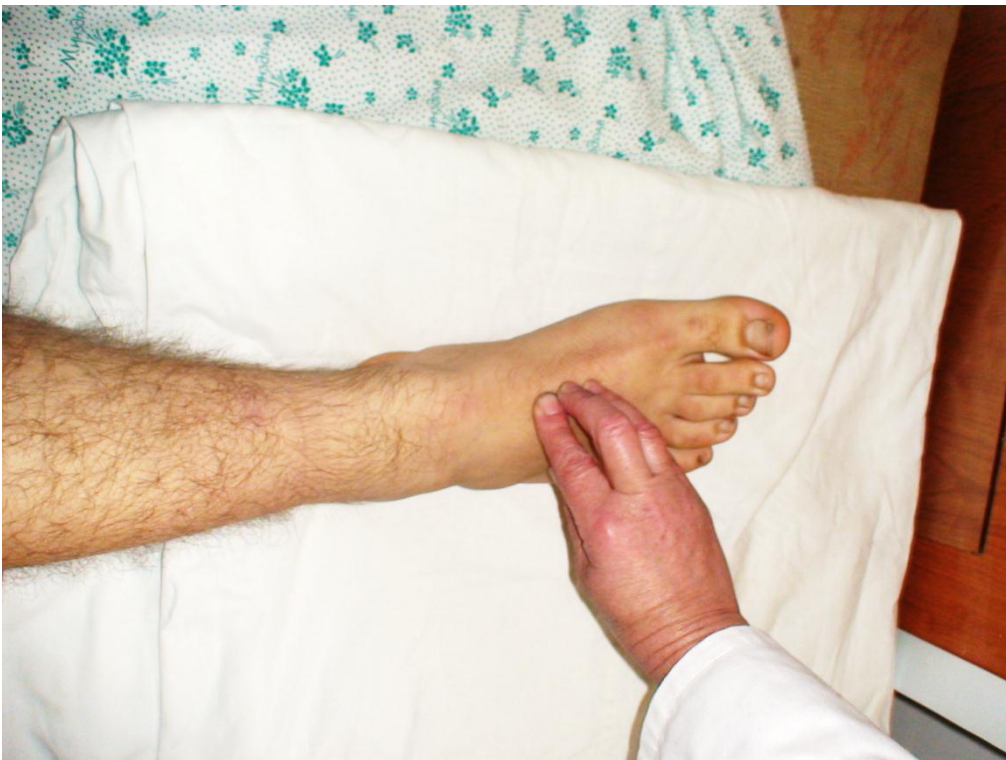

Fig. 3.34. Taking of the pulse of the back foot artery.

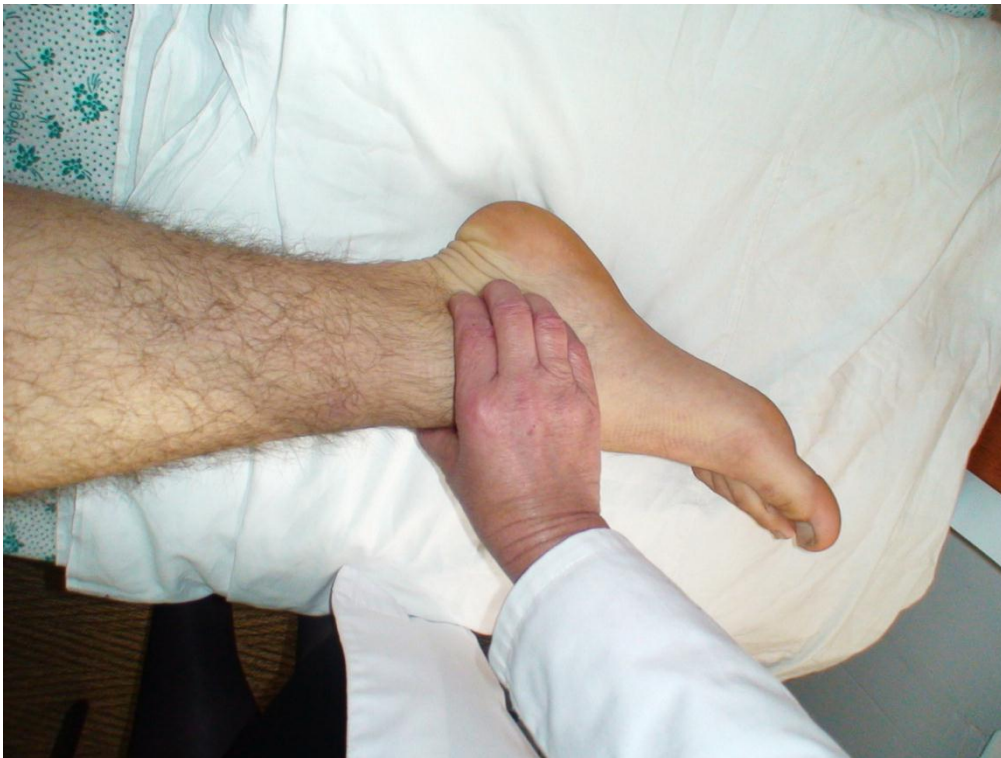

Fig. 3.35. Taking of the pulse on the tibial artery.

Changes in the pulse properties in pathological conditions

1. The difference between the pulse waves on the hands appear in the presence of stenosis of the left atrioventricular ostium: sharply enlarged left atrium compresses the left subclavian artery and the pulse on the left hand becomes weaker (a symptom of Popov - Saveljev). Absence of the pulse on one hand is a characteristic sign of nonspecific aortoarteritis (Takayasu's disease), in the development of which there is obliterating thromboangiitis of the aortic arch and arteries going away from it. The pulse on any peripheral artery may not be available in case of sudden obstruction caused by embolism.
2. **Pulse deficit** is a difference between the peripheral pulse rate and the number of heart contractions. It is caused by arrhythmias and high heart contraction rate, and therefore the two rapid consequent contractions may cause only one pulse wave. The pulse deficit occurs most frequently in fibrillation.
3. Sometimes one may observe pulsation of the jugular vein simultaneously with the heart activity. This phenomenon is called **venous pulse**, it may be physiological (slightly noted in the horizontal position and it disappears completely in the vertical position); it appears at the expense of accelerated blood movement during the ventricular systole. In presence of the tricuspid valve insufficiency the reverse wave of the blood from the right ventricle into the atrium detain the blood flow from the basic veins into the atria during heart systole and the veins, in particular, the jugular ones swell simultaneously with ventricular systole - this is a pathological positive venous pulse. The venous pulse may be mistaken with

fluctuations of the jugular veins caused by pulsation of the carotid arteries (**negative conductive venous pulse**). To differentiate these phenomena it is necessary to occlude the vein by a finger and conductive fluctuations of the swollen peripheral part become more pronounced, and in case of real venous pulse the pulsation of this part stops.

3.7. MEASUREMENT OF ARTERIAL PRESSURE

Character of the arterial pressure

1. There are systolic AP (maximal), diastolic (minimal) and sphygmic AP.

Systolic AP is a pressure occurring in the arterial system after the ventricular systole.

During diastole AP decreases and is maintained at the definite level (**diastolic AP**) at the expense of the elastic contraction of the arterial walls and support of the arterioles thanks to which the blood movement into the arterioles, capillaries and veins continues. The difference between the maximal and minimal pressure is called sphygmic pulse.

2. According to the WHO standards the normal level of the systolic pressure in adults does not exceed 140 mm Hg (18.6 gPa) and diastolic pressure – 90 mm Hg (12 gPa).

Today we distinguish **optimum pressure** (less than 120/80 mm Hg), **normal pressure** (up to 130/85 mm Hg) and **high normal pressure** (up to 140/90 mm Hg). Arterial pressure higher than 140/90 mm Hg is considered as **arterial hypertension** (AH). The reduction of the systolic blood pressure less than 100 mm Hg (13.3 gPa) and diastolic - lower than 60 mm Hg (8 gPa) is called **arterial hypotension**.

3. Deviations of AP from the norm are observed in the development of many diseases.

Most sustained increase in AP is noted in presence of essential hypertension as well as diseases during the development of which hypertension is one of the symptoms and is called symptomatic. Among numerous symptomatic AP the most common is nephrogenic or renal hypertension; endocrinopathic AP develops in certain diseases of the endocrine glands (pituitary tumors and cortex of the adrenal glands, pheochromocytoma, diffuse toxic goiter, etc.); there is also hemodynamic hypertension; AP can occur when organic affection of the central nervous system occurs - brain tumors, traumatic cranio- cerebral injury, etc.

A significant increase in the pulse pressure as a result of a small increase in the systolic pressure and a sharp reduction of the diastolic one (down to 0) is characteristic of insufficiency of the aortic valves. The increased pulse pressure

due to the increased systolic and reduced diastolic blood pressure is observed in patients with atherosclerosis of the aorta.

Lowering of AP (hypotension) maybe manifested as constitutional feature in people with asthenic physical structure.

As a pathological symptom hypotension is observed in presence of many acute and chronic infectious diseases, Addison's disease and hypothyroidism. The sudden drop in AP results from major blood loss, shock, collapse, myocardial infarction.

The decrease in the pulse pressure is observed in patients with myocarditis, exudative and constrictive pericarditis, in a sharp decrease in the cardiac output and the corresponding fall in the systolic pressure. The pulse pressure is also reduced in case of stenosis of the aortic ostium.

To measure arterial pressure we use auscultation (Korotkov's) and palpation (Riva Rocchi) methods.

Taking the arterial pressure by Korotkov

Step 1. The room where the pressure determination of AP is made, should be quiet and quite warm. Usually AP is determined through the brachial artery.

Step 2. Before the examination the patient is recommended to rest for 10-15 minutes, sitting in a chair or lying down. When taking AP the patient should sit or lie quietly, not talking and not following the course of the determination.

Step 3. A cuff is applied to the naked shoulder of the patient so that its edge where is a rubber tube was turned down and was located 2-3 cm above the elbow. The cuff is fixed on the shoulder so tightly that only one finger can pass between it and the skin.

Step 4. The patient puts his hand palm up. A sleeve of the shirt or blouse, if not removed, should not press down on the arm; muscles should be relaxed.

Step 5. Pulsation of the brachial artery is palpated in the bend of the elbow, a phonendoscope is applied tightly, but without pressure, the valve on the tank should be closed to stop the air outside the balloon and gradually air is boosted into the cuff and pressure gauge at the same time. Under the pressure of the air mercury rises in the manometer in a glass tube or pointer in the spring gauge starts to deviate. The numbers on the scale show height of pressure in the cuff, i.e. the force with which the artery is compressed through the soft tissue, in which the pressure is measured.

Step 6. Boosting of the air in the cuff is made until sound or noise arisen in the ulnar artery disappears, and then the pressure in the cuff is increased by 15-20 mm Hg. Then open the valve of the balloon slightly and slowly letting go the air from the cuff. Simultaneously the artery is auscultated by the phonendoscope watching the scale readings.

Step 7. When the pressure in the cuff and manometer becomes a little smaller than the maximum pressure in the artery, the sound is heard over the artery - this is the beginning of the first phase of Korotkov's sound effects. Readings of the manometer at the moment of the sound appearance mean height of the systolic (maximum) AP. The moment of extinction of sounds corresponds to the diastolic (minimum) pressure.

Step 8. Taking blood pressure is recommended to repeat 2-3 times without removing the hand cuff at the interval of at least 5 minutes. The lowest readings are taken for the value of the blood pressure. (Fig. 3.36).

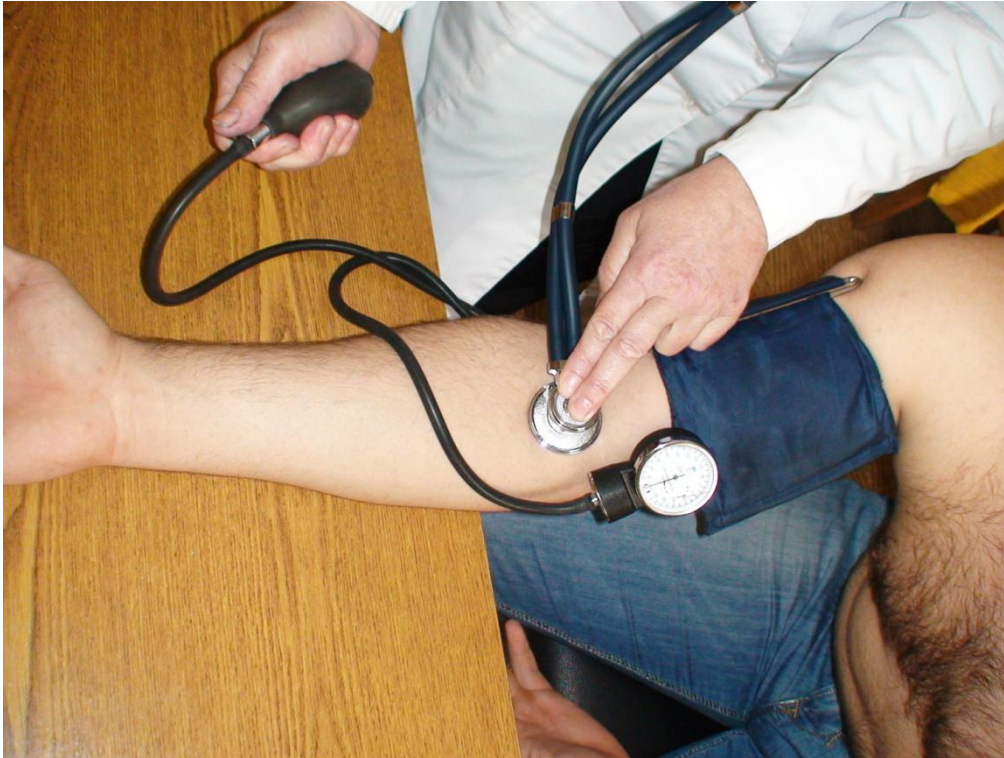

Fig. 3.36 Taking the arterial pressure by Korotkov's method.

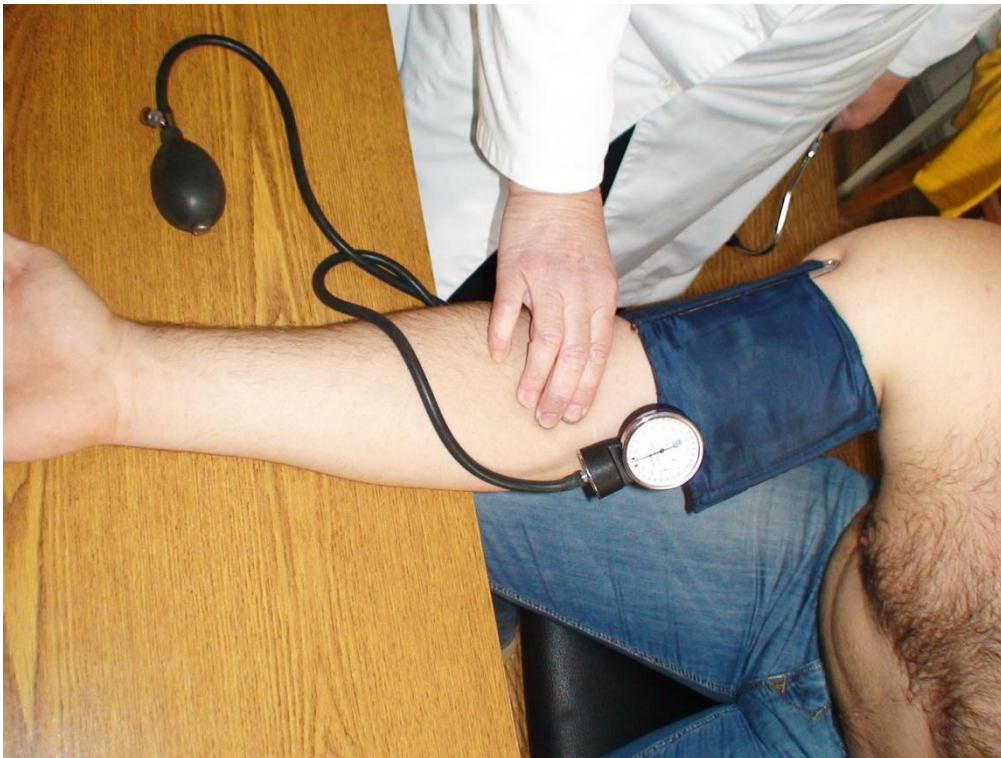

Fig. 3.37. Determination of the arterial pressure by palpation

Taking of the arterial pressure by Riva Rocchi method

A palpation method of Riva Rocchi determines only the systolic pressure. This method is useful for rapid determination of the level of the systolic blood pressure (Fig. 3.37).

Step 1. Find a pulsation in the radial artery.

Step 2. Pump the air into the cuff until the pulse disappearance on the radial artery.

Step 3. The air is letting go very slowly until the pulse appears again on the radial artery. The level of mercury at this point corresponds to a height of the systolic blood pressure.

Part 4

Digestive organs

4.1 PLAN OF OBJECTIVE STUDY OF THE DIJESTIVE ORGANS

1. Examination of the abdomen:

a) division of the abdomen into regions;

b) shape of the abdomen;

c) properties of the abdomen wall.

2. Palpation of the abdomen:

a) superficial (oriented);

b) deep, methodic, sliding palpation according to V.P. Obratzsov and M.D. Strazhesko method.

3. Percussion of the abdomen:

a) percussion in the presence of gas in the abdominal cavity;

b) percussion in the presence of fluid, tumours, inflammatory infiltrates.

4. Auscultation of the abdomen (identification of free fluid in the abdomen):

a) percussion method of identification of free fluid;

b) fluctuation (shakiness) method.

4.2. EXAMINATION OF THE ABDOMEN

Division of the abdomen into regions

The anterior surface of the abdomen is divided into three areas – the upper, the middle and the lower ones with the help of horizontal lines.

The upper area of the abdomen, or epigastrium, is confined inferiorly with the line, connecting the lowest ends of both tenth ribs. The middle area of the abdomen, or mesogastrium, is confined inferiorly with the line, connecting both anterior upper spines of the iliac bones. The lower area of the abdomen, or hypogastrium, is located directly under the mesogastrium.

Each area of the abdomen is divided into three parts by vertical midclavicular lines. Thus, there are two hypochondriac regions in the epigastrium area, located on both sides of it – the right and the left ones (reg. hypochondriaca dextra et sinistra), and between them in the middle there is the epigastrium region (reg. epigastrica).

In the mesogastrium area there are iliac or side regions (reg. iliaca dextra et sinistra) on both sides, and between them there is the umbilical region (reg. umbilicalis).

The hypogastrium has the right and the left inguinal regions (reg. inguinalis dextra et sinistra) on both sides, between them there is the pubic region (reg. suprapubica; Fig .4.1).

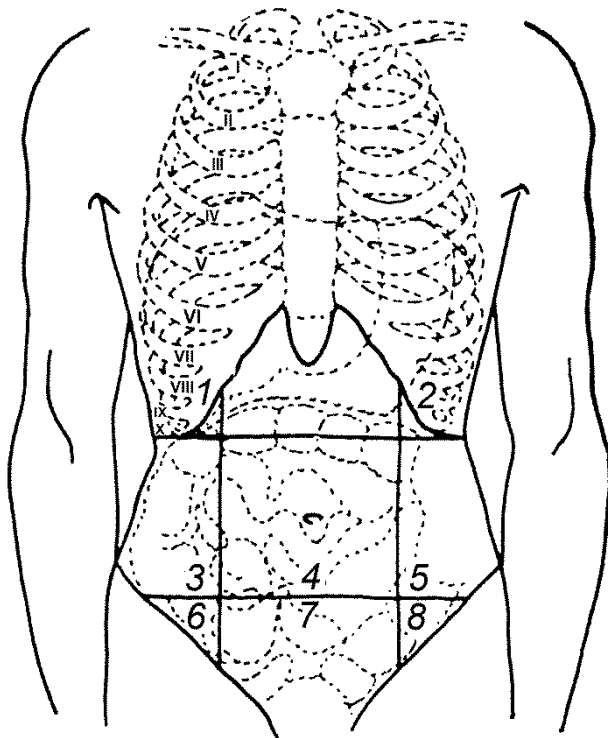


Fig .4.1 The scheme of the base division of the abdomen into regions (after A.L. Myasnikov): 1,2- hypochondriac, 3,5 – iliac; 4 – umbilical; 6,8, - inguinal; 7- pubic

Shape of the abdomen

During examination of the abdomen it is necessary to pay attention to its shape, properties of the abdomen wall, mobility of the anterior abdominal wall on breathing, discernible intestinal peristalsis, bulging of some of its parts.

The abdomen is enlarged: edema of the abdominal wall; flatulence (accumulation of gasses in the intestines); ascites (accumulation of inflammatory or hydroptic fluid in the abdomen (Fig . 4.2.); obesity.

In obesity the navel is evenly pulled in (Fig .4.3, a, b), the abdomen is evenly enlarged.

In flatulence: the navel is smoothed, the abdomen is bulging – in the form of semicircle, the abdominal wall is smooth, rigid.

In ascites: in prone position in the middle the abdomen is flat; the fluid is in the lateral parts of the abdomen, it is the so called frog abdomen. In apparent ascites the navel is bulging.

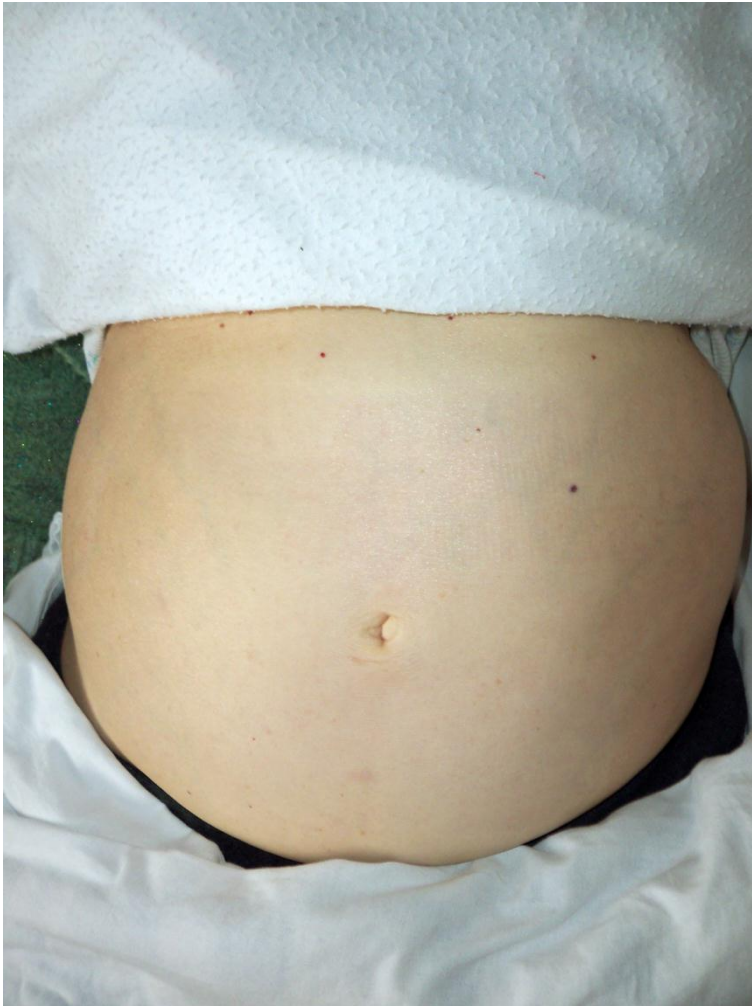
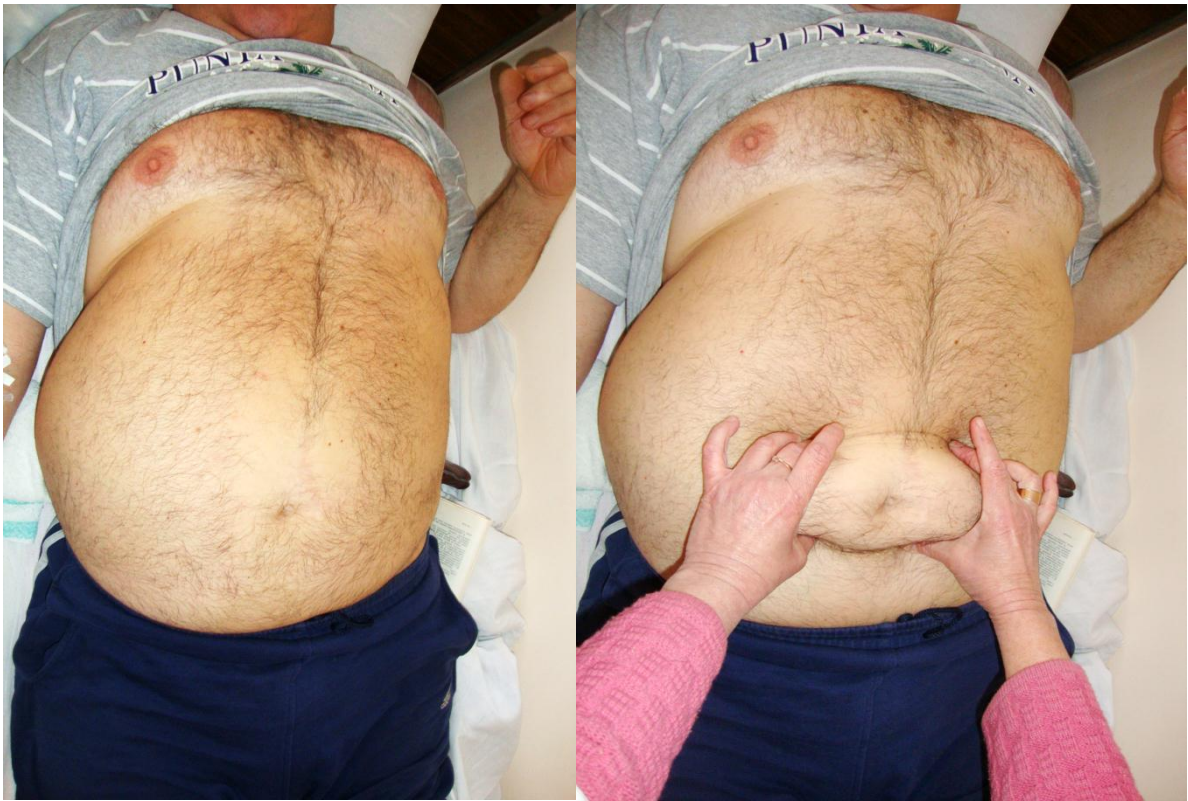

Fig . 4.2. Abdomen in ascites



a

b

Fig . 4.3. abdomen in obesity (a,b)

Sunken abdomen: more often in vomiting, diarrhea, malnutrition, acute meningitis, peritonitis (rigidity of abdominal muscles; Fig .4.4).

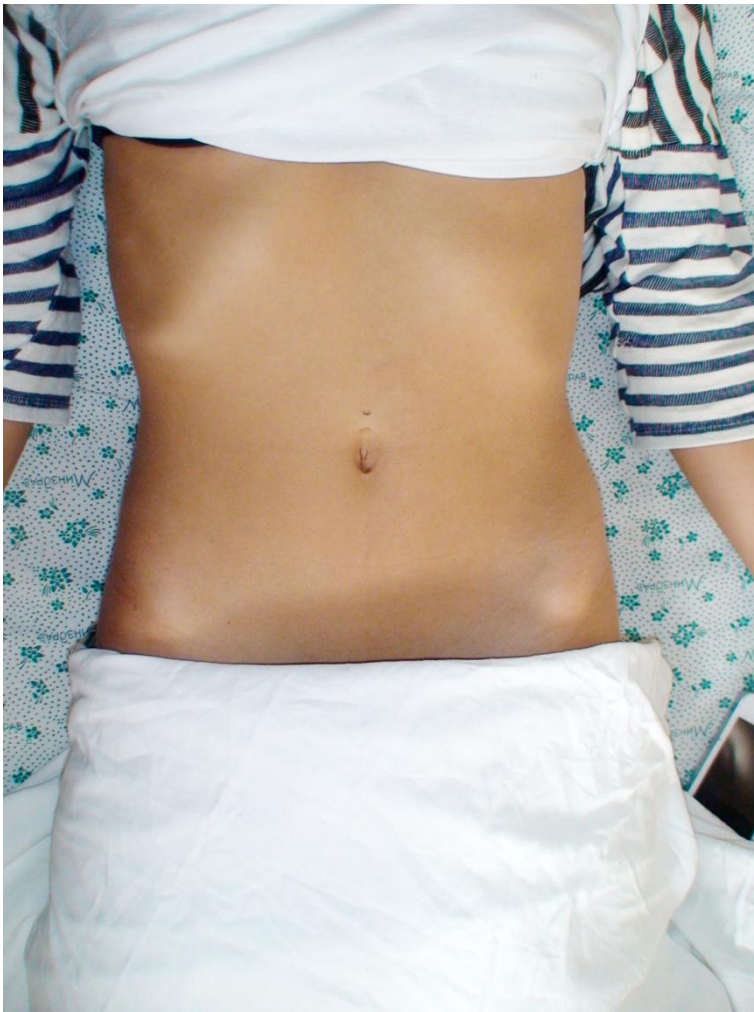

Fig .4.4. Sunken abdomen

Property of the abdominal wall

It is necessary to pay attention to the property of the abdominal wall: hernias; venous network on the abdominal skin (disturbance in the circulation in the superior vena cava, inferior vena cava, portal vein (arachnogastrica); striae cutis distensae; surgical scars; pigmentation; respiratory excursions; epigastric pulsation (the right ventricle of the heart, the abdominal aorta, the liver).

4.3. PALPATION OF THE ABDOMEN

Step 1. Provide relaxation of the abdominal muscles of the patient. For this the patient must lie on a comfortable flat bed in a warm room, and the doctor must sit on the right side of the patient, with the seat of the chair at the same level as the bed, the doctor's hands must be warm and dry.

Step 2. Slightly bent fingers of the right hand are put on the left inguinal region (in case there is no pain; Fig . 4.5).

Step 3. The anterior abdominal wall of this region is carefully, superficially examined, step-by-step, without penetrating too deep. Attention is paid to the condition of the skin, the subcutaneous tissue and the muscles of the abdominal wall; the presence of changes in the skin or the subcutaneous tissue, rigidity of the anterior abdominal wall muscles or its tenderness are registered.

Step 4. The hand is moved to the right inguinal region (Fig .4.6).

Step 5. The anterior abdominal wall of this region is carefully, superficially examined, step-by-step, without penetrating too deep. Attention is paid to the condition of the skin, the subcutaneous tissue and the muscles of the abdominal wall, tenderness of the region.

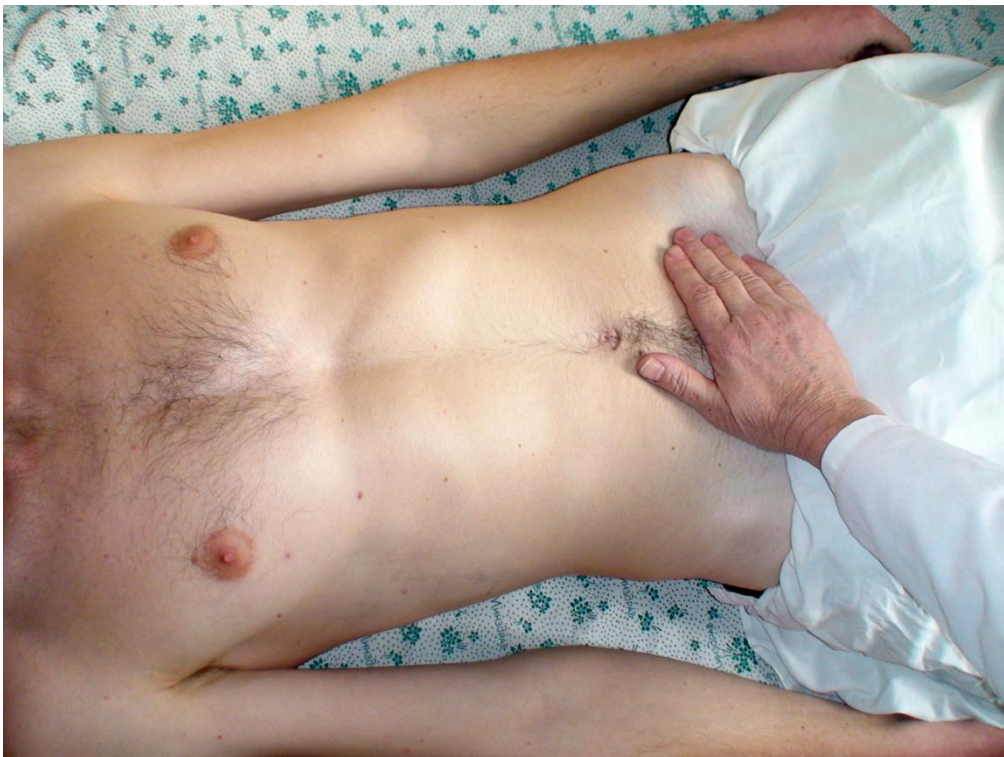

Fig . 4.5. Superficial palpation in the left inguinal region

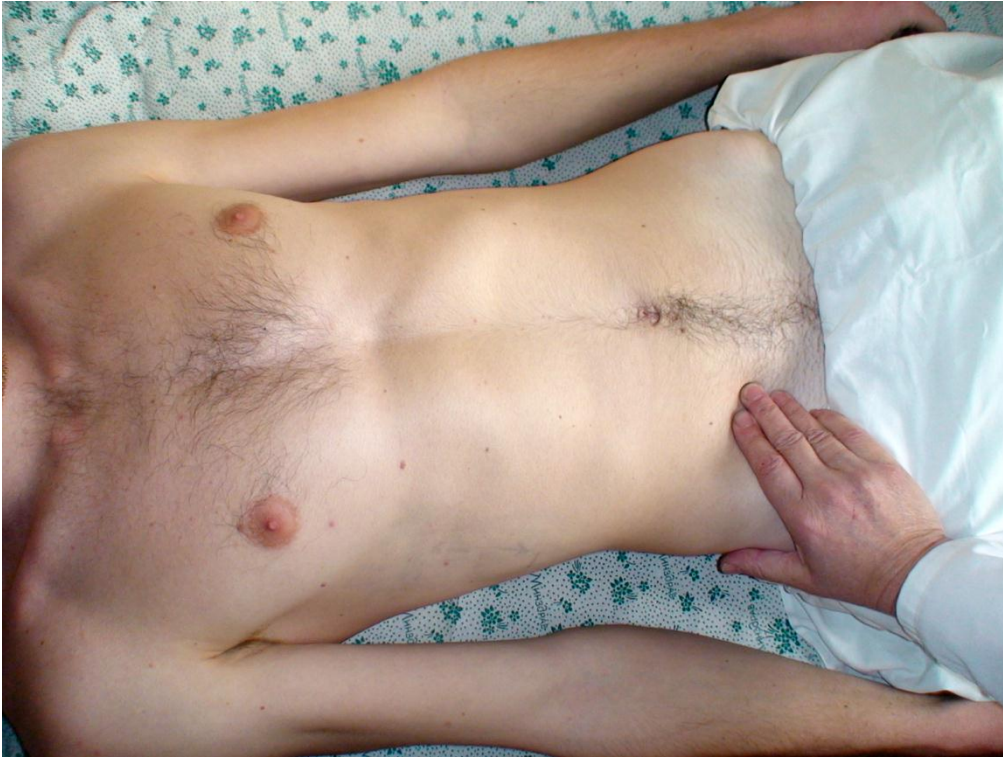

Fig . 4.6. Superficial palpation in the right inguinal region

Step 6. The hand is moved to the left lateral region of the abdomen (Fig .4.7).

Step 7. The same as at steps 3 and 5.

Step 8. The hand is moved to the right lateral region of the abdomen (Fig .4.7).

Step 9. The same as at steps 3 and 5.

Step 10. The hand is moved to the umbilical area (Fig . 4.9).

Step 11. The anterior abdominal wall of this region is carefully, superficially examined, step-by-step, without penetrating too deep. Attention is paid to the condition of the skin, the subcutaneous tissue and the muscles of the abdominal wall, tenderness of the muscular wall, and also to the condition of the abdominal raphe and the umbilical ring, presence of myotaxis and hernial bulging.

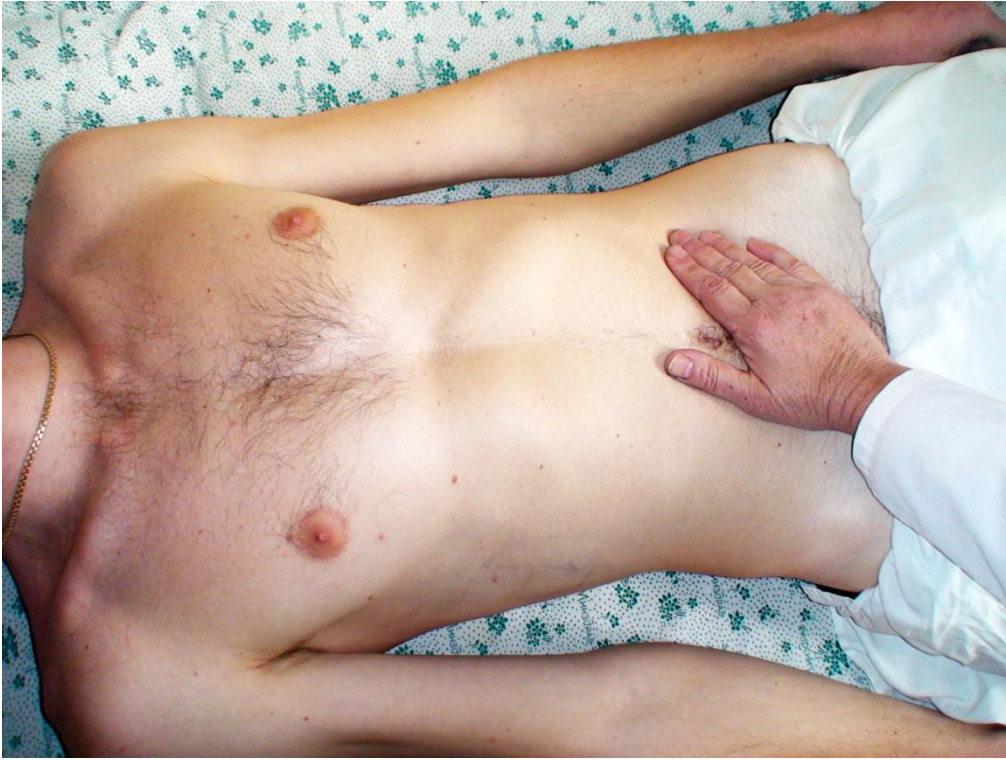

Fig .4.7. Superficial palpation of the left lateral region of the abdomen

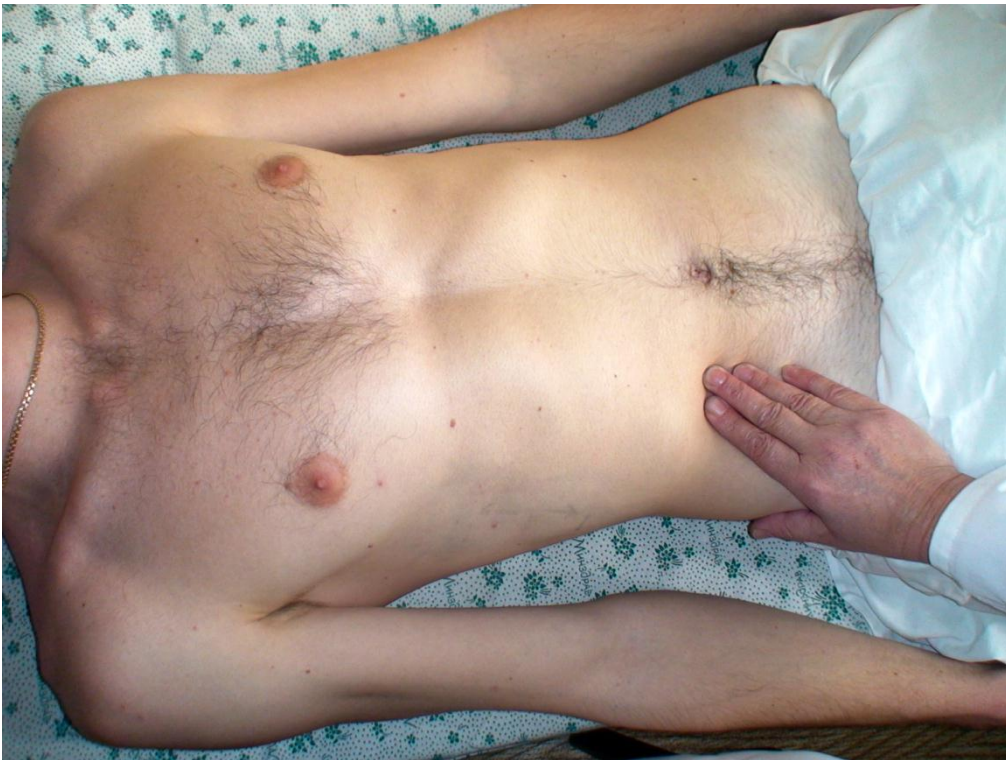

Fig . 4.8. Superficial palpation of the right lateral region of the abdomen

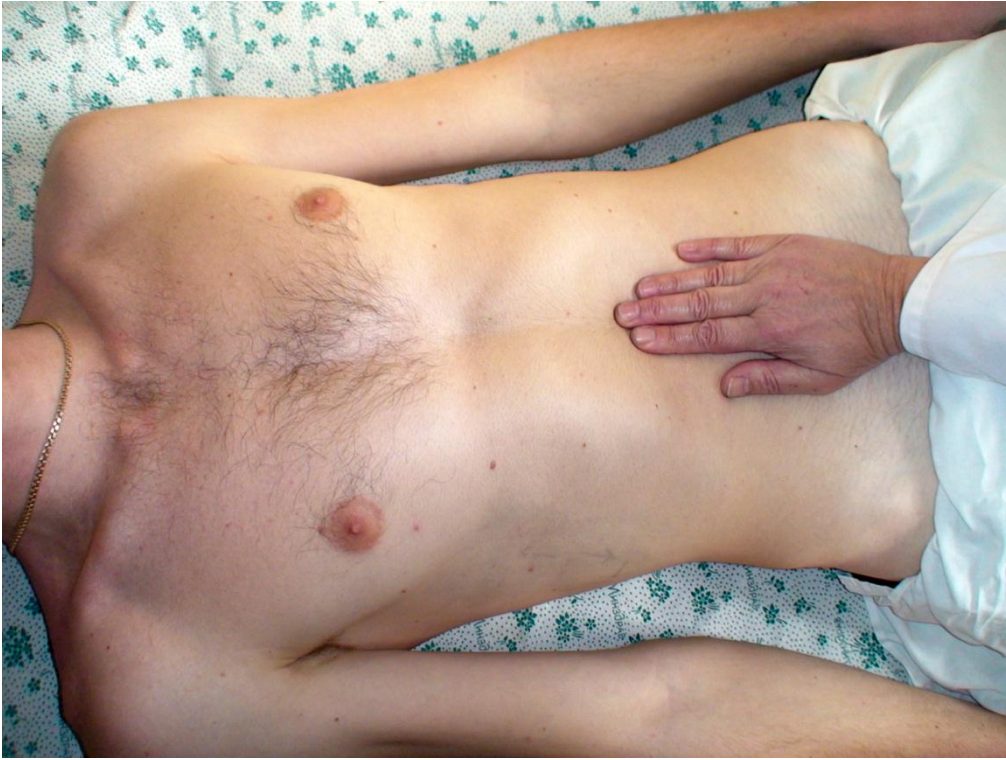

Fig . 4.9. Superficial palpation of the umbilical area of the abdomen

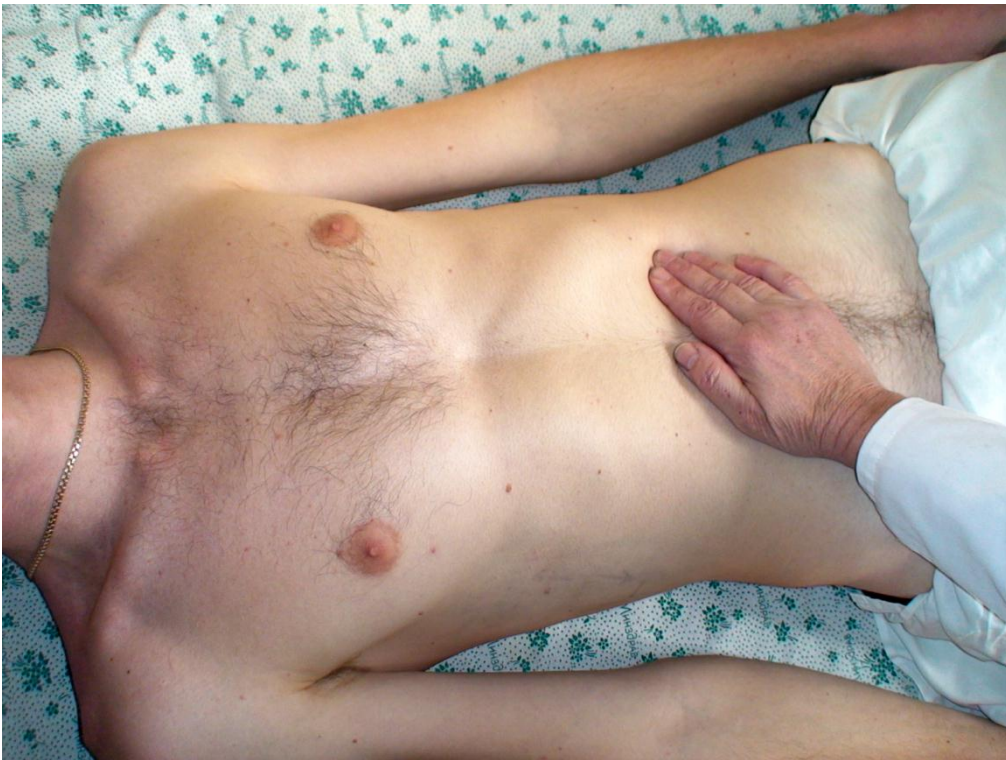

Fig . 4.10. Superficial palpation of the left hypochondriac region

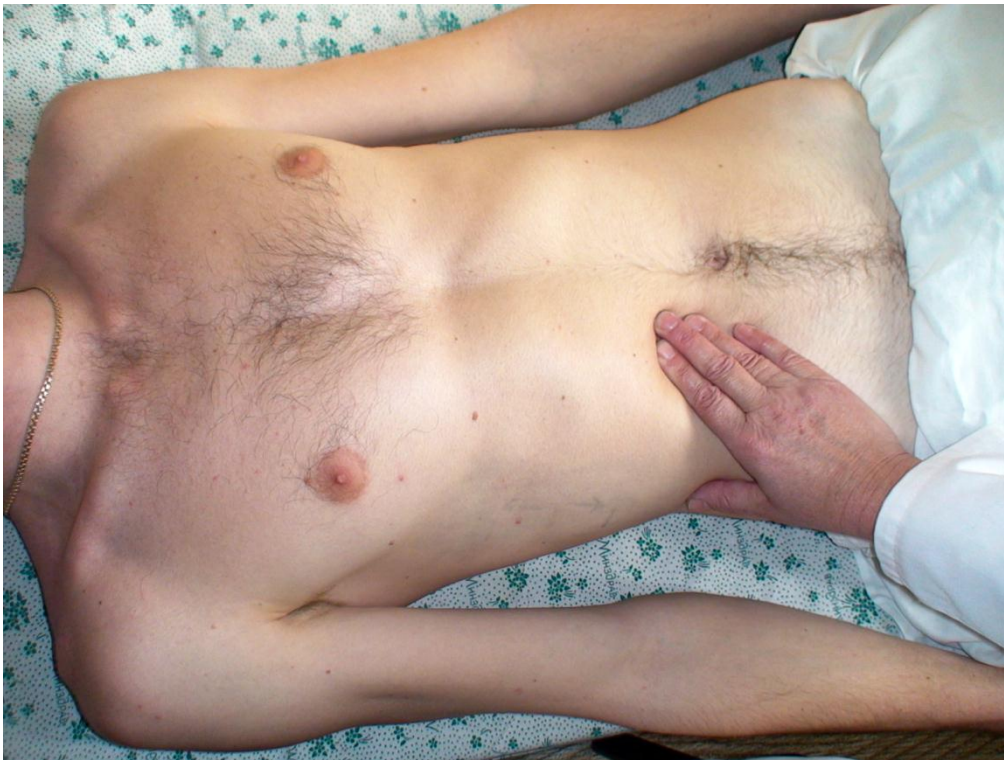

Fig . 4.11. Superficial palpation of the right hypochondriac region

Step 12. The hand is moved to the left hypochondriac region (Fig .4.10).

Step 13. The anterior abdominal wall of this region is carefully, superficially examined, step-by-step, without penetrating too deep. Attention is paid to the condition of the skin, the subcutaneous tissue and the muscles of the abdominal wall.

Step 14. The hand is moved to the right hypochondriac region (Fig . 4.11).

Step 15. The anterior abdominal wall of this region is carefully, superficially examined, step-by-step, without penetrating too deep. Attention is paid to the condition of the skin, the subcutaneous tissue and the muscles of the abdominal wall.

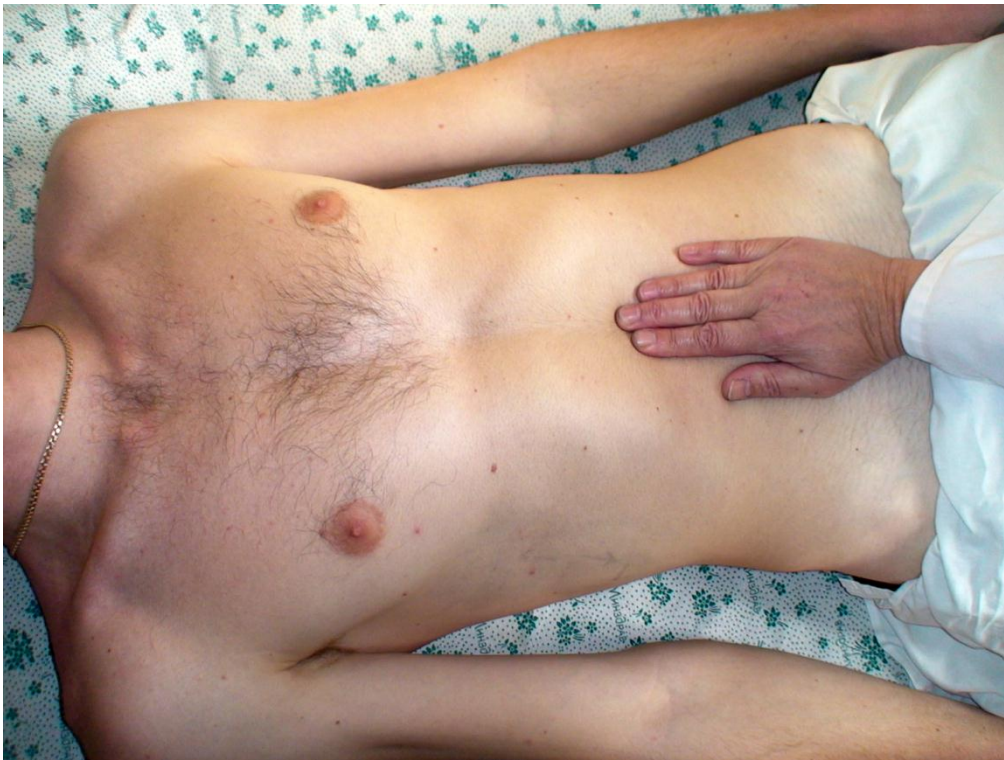

Fig .4.12. Superficial palpation of epigastrium region

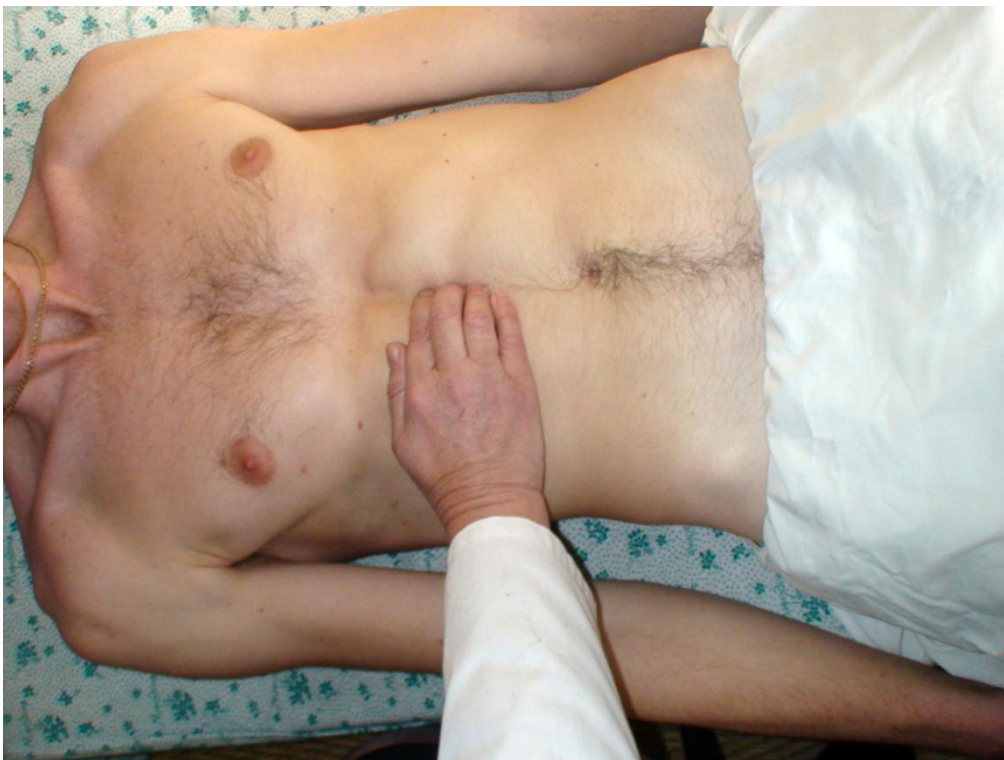

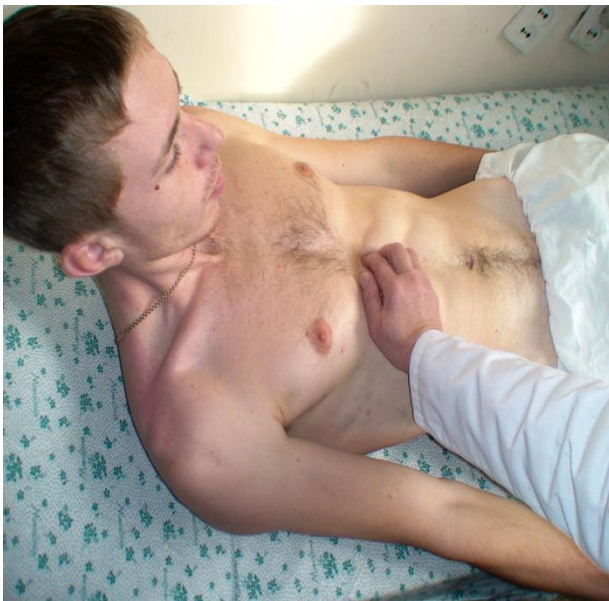Fig .4.13. Superficial palpation along the abdominal raphe

Step 16. The hand is moved to the epigastrium region (Fig . 4.12).

Step 17. The anterior abdominal wall of this region is carefully, superficially examined, step-by-step, without penetrating too deep. Attention is paid to the condition of the skin, the subcutaneous tissue and the muscles of the abdominal wall, tenderness of the muscular wall and also the condition of the abdominal raphe, presence of myotasis and hernial bulging (Fig . 4.13).

Step 18. The patient is asked to raise the upper limb girdle without the help of the arms, then palpation with bent fingers of the right hand is carried out along the abdominal raphe, in order to identify a hernia of the abdominal raphe. (Fig . 4.14, a-d).

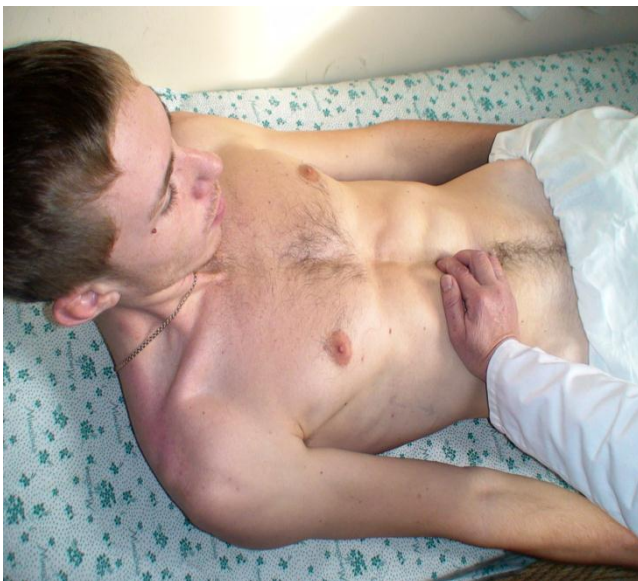Note: The painful region of the abdomen is palpated lastly.



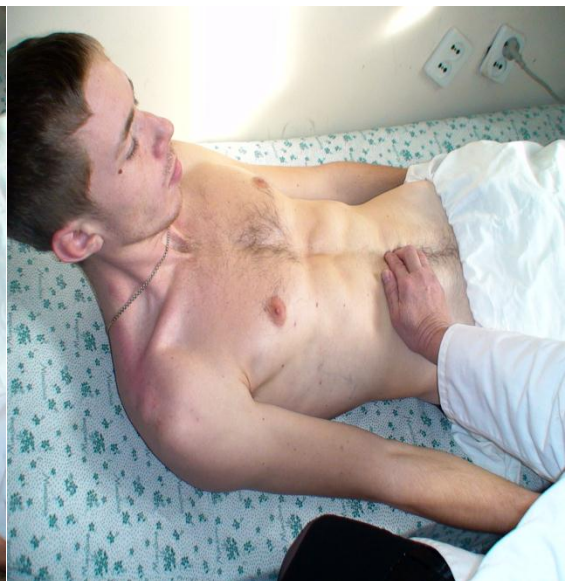a



b



c



d

Fig . 4.14. Superficial step-by-step palpation along the abdominal raphe with raised upper limb girdle without the help of the arms (a-d)

Deep, methodic, sliding palpation according to V.P. Obratzsov and M.D. Strazhesko method

There are four steps for palpation of each organ.

Step 1. Position of the doctor's hands: the right hand is put flat on the anterior abdomen wall perpendicularly to the axis of the examined intestine or the edge of the investigated organ.

Step.2. Shifting of the skin and making a skin fold, in order not to limit movements of the hands by skin tension.

Step 3. Immersion of the hand deep the abdomen; step-by-step, using relaxation of the abdomen wall on breathing-out, the hand is immersed deep the abdomen up to the posterior abdomen wall or the investigated organ.

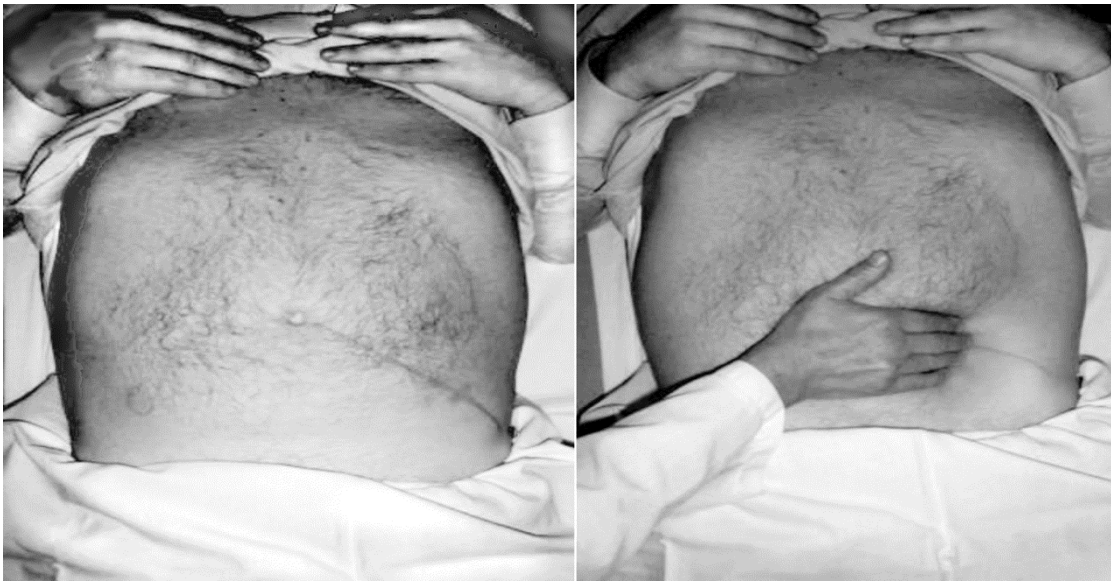Step 4. Sliding with fingertips in the transverse direction to the axis of the investigated organ, doing this the organ is pressed to the posterior abdomen wall, and, continuing the sliding, the fingertips roll over the palpated intestine or the curve of the stomach.

The order of intestinal areas investigation

Step 1. Palpation of the sigmoid colon is carried out superiorly from the middle, to the left down and outward, sideway on to the axis of the colon, which is located athwart in the left iliac region on the border of the middle and external thirds of the line, connecting the navel with the anterior upper spine of the left ileum. Palpation is carried out according to the 4-step scheme given above (Fig . 4.15,a,b).

Step 2. Palpation of the cecum is carried out from the left superiorly from the middle, to the right down and outward. It is located in the right iliac region, on the border of the middle and external thirds of the line, connecting the navel with the anterior upper spine of the right ileum. Palpation is carried out according to the 4-step scheme given above (Fig . 4.16).

Step 3. The end-point part of the ileum is stretching from below, from the left portion of the small pelvis and it is connected to the cecum, which is located deep in the right ileac cavern below the line, connecting the navel with the anterior upper spine of the right ileum. Palpation is carried out according to the 4-step scheme given above.



a

b

Fig . 4.15. Palpation of the sigmoid colon (a,b)

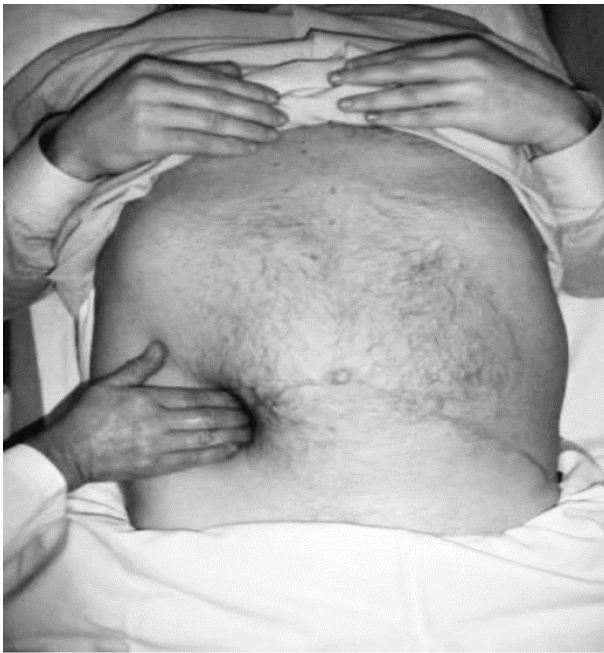

Fig . 4.16. Palpation of the cecum

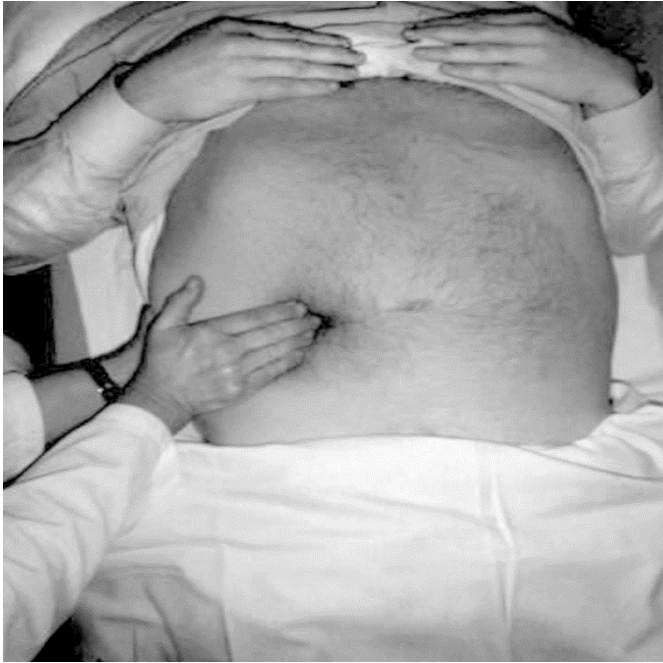

Fig . 4.17. Palpation of the ascending colon

Step 4. The ascending colon is located in the right lateral region of the abdomen. The left hand is laid under the region athwart to the right, the right hand, having made a skin fold, presses the anterior abdomen wall until the feeling of touch with the left hand; the right hand slides outward perpendicularly to the axis of the colon and palpates the colon. (Fig .4.17).

Step 5. The descending colon is located in the left lateral region of the abdomen. The left hand is laid under the region athwart to the left, the right hand, having made a skin fold, presses the anterior abdomen wall until the feeling of touch with the left hand; the right hand slides outward perpendicularly to the axis of the colon and palpates the sought colon (Fig .4.18).

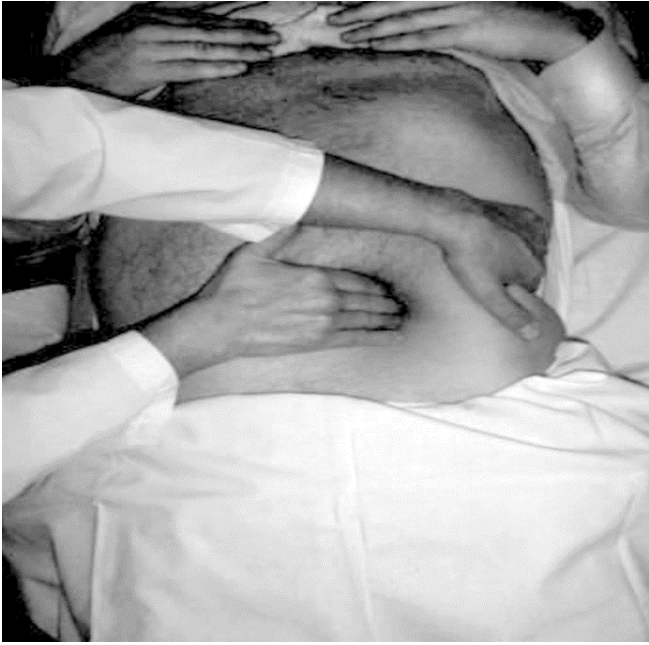

Fig .4.18. Palpation of the descending colon

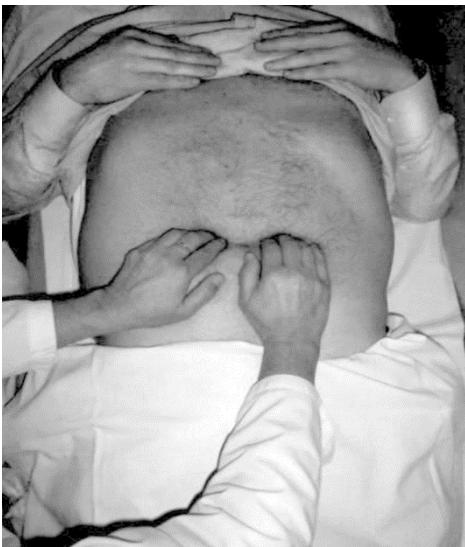

Fig .4.19. Determining the borders of the stomach by means of palpation.

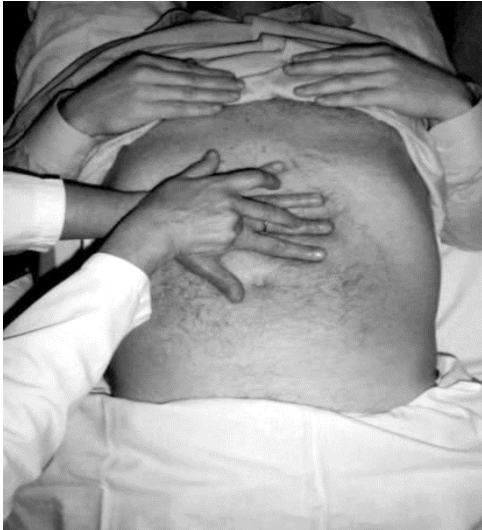

Fig .4. 20. Determining of the borders of the stomach by means of percussion

Step 6. *Palpatory method of determining the lower border of the stomach.*

The greater curvature of the stomach is located on the both sides of the abdominal midline – 2-3 centimeters above the navel. Four put together and half bent fingers of the right hand pull the abdominal skin up on the patient's breathing- in. On breathing out the fingertips dip into the abdominal cavity, reaching the spine, and slide top down. The greater curvature of the stomach is felt like a swab, lying on the spine and on both sides of it (Fig . 4.19).

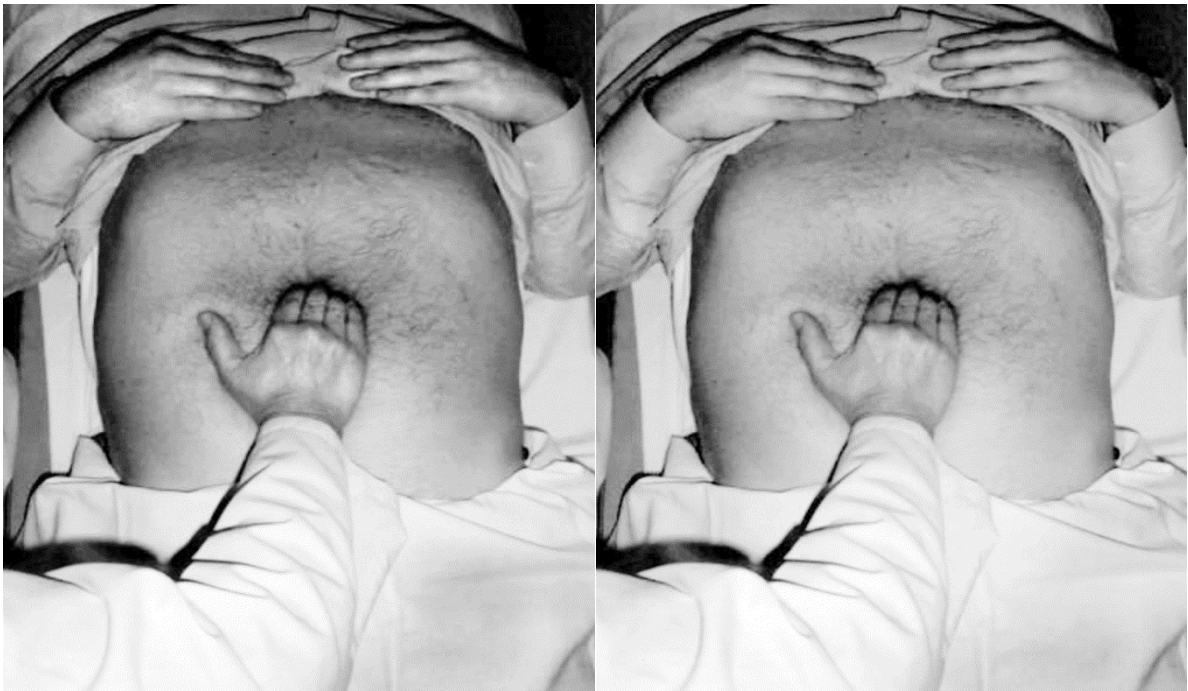
Step 7. *The percussion method of determining the lower border of the stomach.*

A slight percussion is carried out downward from the left hypochondrium. The area of the low tympanitis of the stomach is distinguished from the high tympanitis of the intestines (Fig . 4.20).

Step 8. *Palpatopercussion (after V.P. Obratsov).*

The lower border of the stomach is determined by the splashing sound, if there is some gas and fluid in the stomach at the same time. The patient must be given some liquid to drink immediately before the investigation.

The patient lies on the back. The medial border of the left hand presses on the epigastrium area (with the gas located in front of the fluid). Four half bent fingers of the right hand make short balloting taps top down on the abdominal raphe. The lower border of the stomach is determined where there is the lowest point of the splashing sound. The splashing sound after 7-8 hours after taking the liquid is the sign of pyloric stenosis (Fig .4.21, a,b).



a

b

Fig . 4.21. Determining the borders of the stomach by the palpatopercussion method after V.P. Obrastsov

Step 9. The auscultatory method of determining the borders of the stomach.

The patient lies on the back. The stethoscope is located under the left costal arch, under the Traube's space.

At the same time the skin of the abdomen wall is rubbed with a finger moving away from the stethoscope. The frolement in the stethoscope disappears, as soon as the finger gets out of the borders of the stomach area (Fig .4.22).

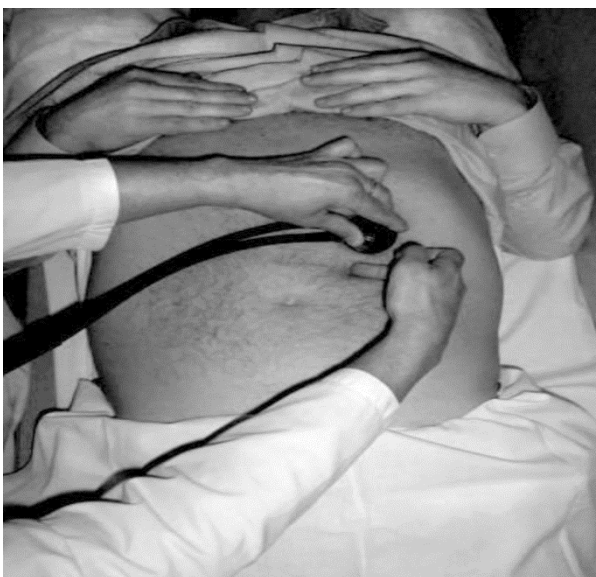

Fig . 4.22. Determining the borders of the stomach by the auscultatory method

Step 10. Palpation of the transverse colon, located 2-3 cm below the lower border of the stomach.

Both hands with bent fingers are put 2-3 cm below the lower border of the stomach on both sides of the abdominal raphe. A skin fold is made and gradually, using the relaxation of the abdominal wall during breathing out, hands dip into the abdomen up to the posterior wall. The hands slide on the posterior wall downward till the feeling of the colon and roll over it (Fig . 4.23).

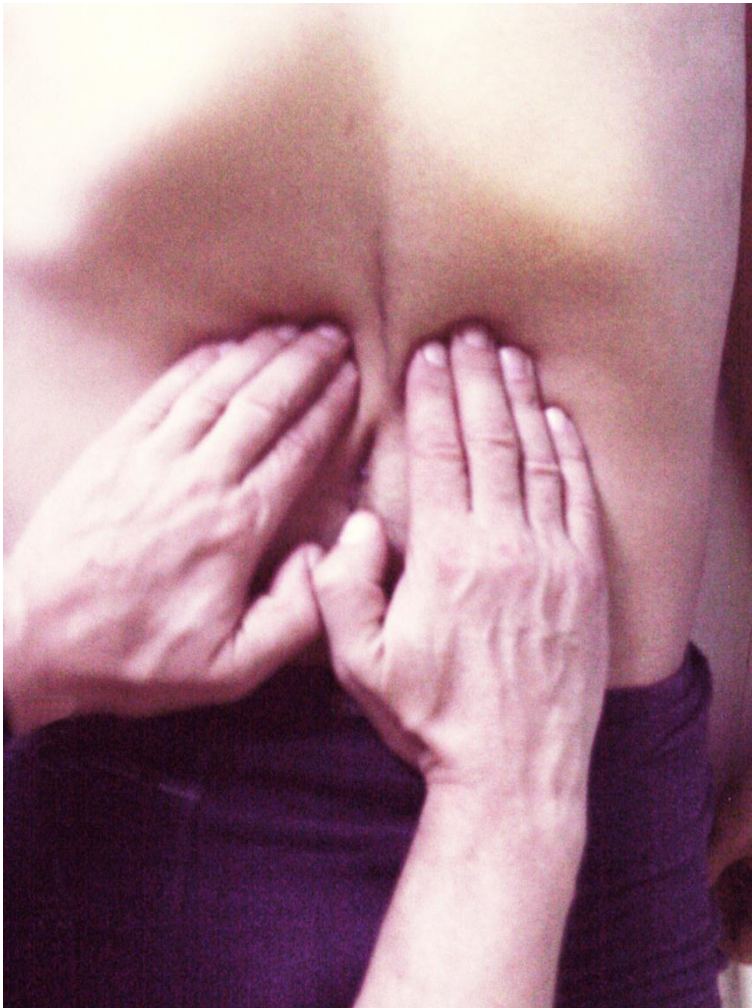

Fig . 4.23. Palpation of the transverse colon

4.4. PERCUSSION OF THE ABDOMEN

Step 1. The patient is in the supine position.

Step 2. Percussion over all the abdominal area is carried out. In case of air accumulation in the abdominal area (pneumoperitoneum) the percussion sound is a resonant tympanitis over the whole abdomen. The hepatic dullness disappears (percussion of the chest to the right and anteriorly in the area of VII-X ribs).

In case of flatulence (accumulation of gases in the intestines) a steady resonant tympanitis is identified.

In decrease of gasses content in the intestines and in fullness of the intestinal content the sound is flat.

Limited areas of the flatness or areas of absolute flatness occur in case of tumours or inflammatory infiltrates. In case of ascites (presence of fluid in the abdominal cavity) – over the abdominal cavity the sound is flat.

4.5. AUSCULTATION OF THE ABDOMEN

Step 1. The patient is in the supine position.

Step 2. Auscultation over the regions of the abdomen (intestinal murmur, peritoneal murmur) by means of locating the stethoscope on the abdominal wall (pic. 4.24).

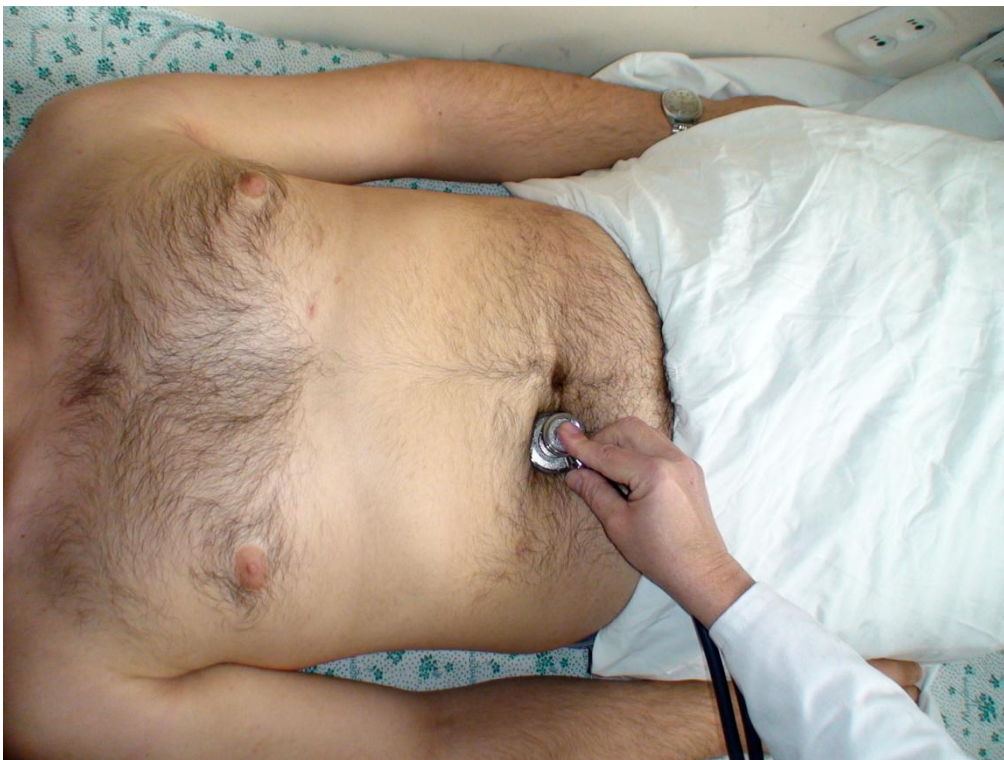

Fig . 4.24. Auscultation of the abdomen.

4.6. IDENTIFICATION OF FREE FLUID IN THE ABDOMINAL CAVITY

The percussion method

Step 1. The patient is in the upright position.

Step 2. The pleximeter-finger is placed horizontally on the midline.

Step 3. Percussion is carried out top down till the tympanic sound becomes flat (level of fluid).

Step 4. The patient is in the supine position. The doctor sits to the right of the patient.

Step 5. The pleximeter-finger is placed near the navel and percussion is carried out downward till the tympanic sound becomes flat (Fig.4.25,4.26).

Fluid fluctuation method

Step 1. The doctor sits to the right of the patient.

Step 2. The doctor puts the palm of the left hand on the lateral surface of the right half of the patient's abdomen.

Step 3. With the fingers of the right hand short taps are made on the lateral surface of the left half of the abdomen. In case of fluid in the abdominal cavity the left hand feels beats.

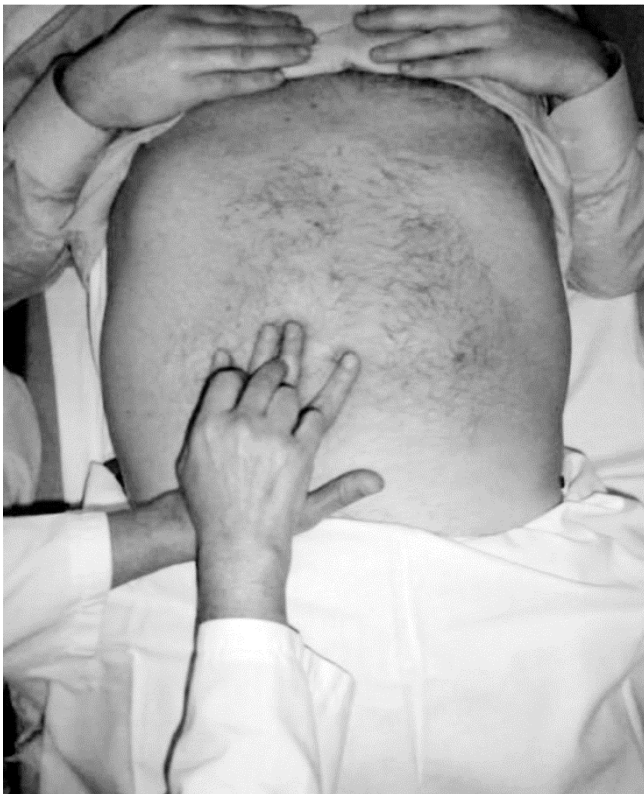

Fig.4.25. Identification of free fluid in the abdominal cavity by means of percussion

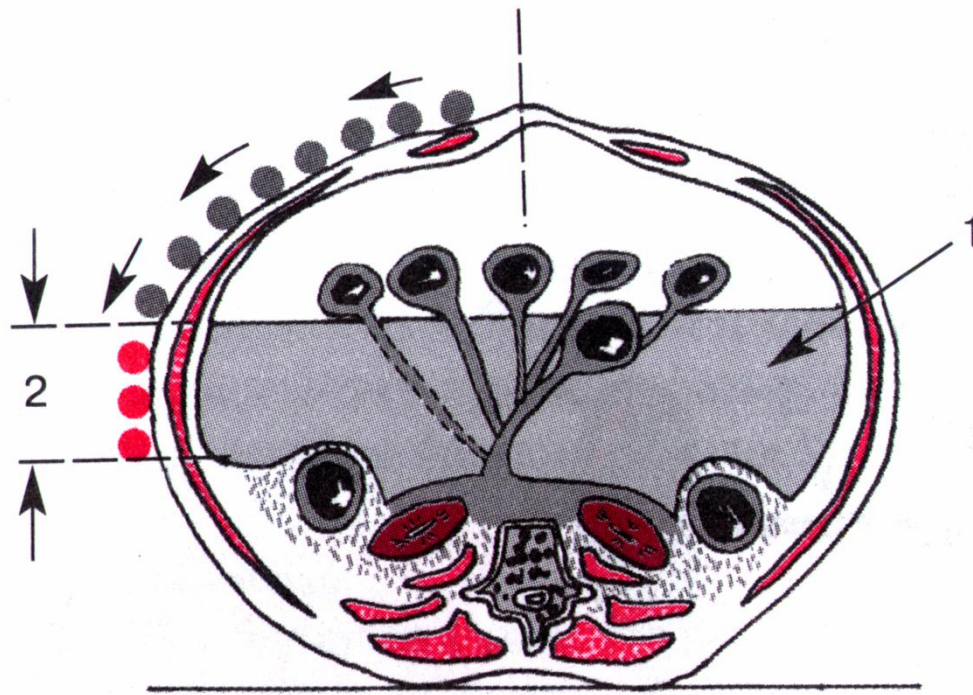


Fig .4.26. Sketch of identification of free fluid in the abdominal cavity by means of percussion

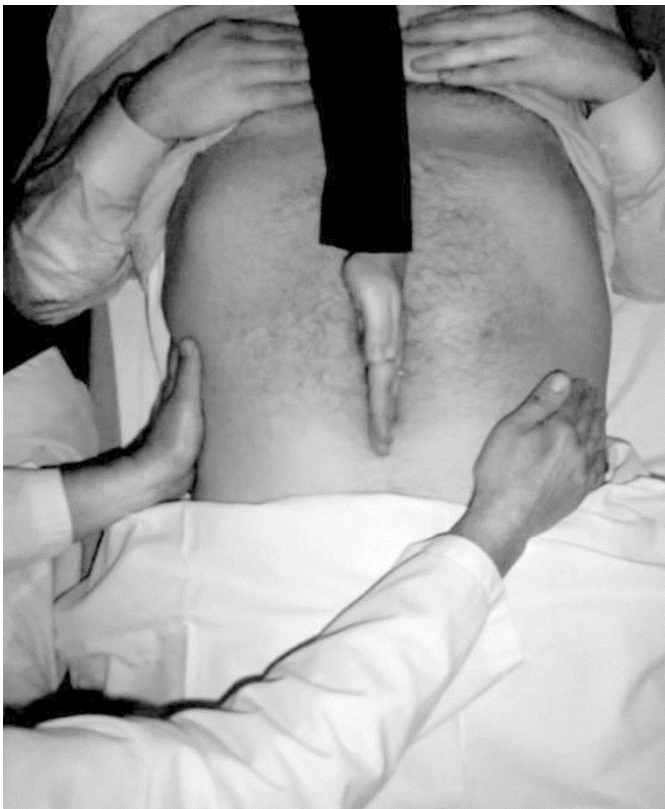

Fig .4.27. Identification of free fluid in the abdominal cavity by means of fluctuation

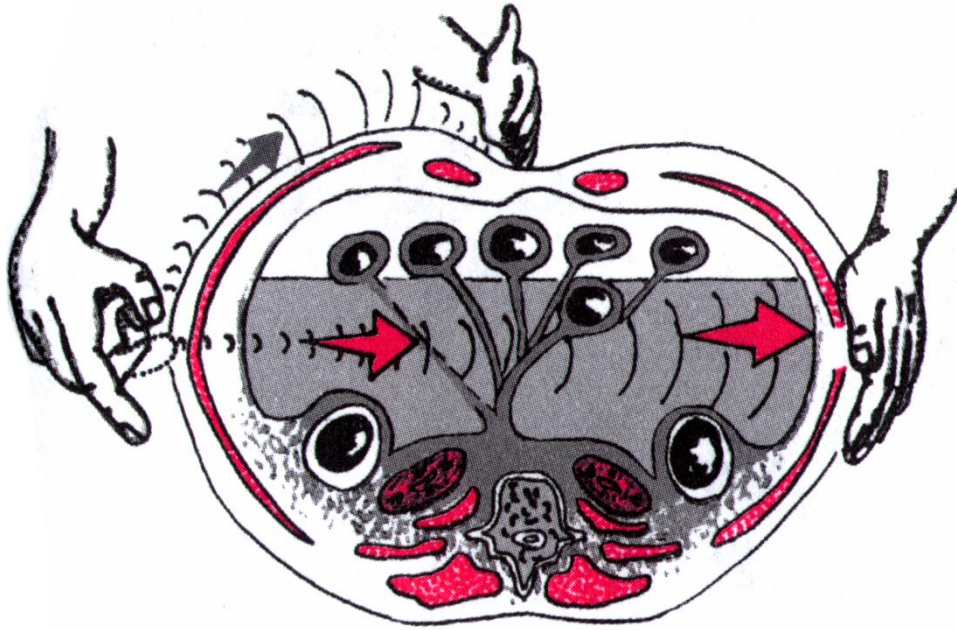


Fig .4.28. Sketch of identification of free fluid in the abdominal cavity by means of fluctuation

For differential diagnostics between the false and true fluctuation the doctor's assistant should put his palm on its sharp vertically along the abdominal midline (Fig. 4.27, 4.28).

Part 5.

EXAMINATION OF THE LIVER

5.1. PLAN OF LIVER EXAMINATION

1. Examination of the patient with the diseases of the liver and bile ducts
2. Percussion of the liver borders
3. Palpation of the liver

5.2. EXAMINATION OF THE PATIENT WITH THE DISEASES OF THE LIVER AND BILE DUCTS

Examination of the skin

In the presence of jaundice attention should be paid to the colour of the skin (lemon-yellow, green-yellow, yellow-green, orange-yellow). Pay attention to the colour of the sclerae and the soft palate (stained in accumulation of bilirubin);

scratches on the skin (itching in hepatic and obstructive jaundice); minor telangiectasia (“spider naevus”) in hepatic cirrhosis.

Examination of the abdomen

Examination is carried out in the plantigrade and recumbent position. Asymmetric enlargement of the abdomen in the right hypochondrium – means enlargement of the liver or the gall bladder. Symetric enlargement of the abdomen – means accumulation of fluid in the abdominal cavity in portal hypertension.

Widening of the venous network on the anterior abdomen wall – means portal hypertension in hepatic cirrhosis, compression or thrombosis of the portal vein (“arachnogastric”).

5.3. PERCUSSION OF LIVER BORDERS AFTER M.G. KURLOV

Step 1. Identification of the upper border of the liver on the right midclavicular line. The pleximeter-finger is placed on the midclavicular line in the III intercostal space.

Step 2. Light percussion is carried out, moving the pleximeter-finger downward till occurrence of a flat sound.

Step 3. With the help of a pencil for dermatographs a mark is made at the upper edge of the pleximeter-finger (the upper border of the relative hepatic dullness; Fig .5.1).

Step 4. The pleximeter-finger is placed on the same line at the level of the navel, parallel to the costal arch.

Step 5. Light percussion is carried out, bottom-up till occurrence of a flat sound.

Step 6. The border is identified at the lower edge of the finger. Normally the lower border of the liver gets in line with the lower edge of the costal arch (Fig .5.2).

Step 7. Conventional identification of the upper border of the liver on the anterior midline. The overlap point of the anterior midline and the line, drawn horizontally from the upper border of the liver along the midclavicular line to the sternum, is identified (Fig .5.3).

Step 8. The lower border of the liver is identified at the midline. The pleximeter-finger is moved upward from the navel till occurrence of the flat sound.

Step 9. A mark is made at the lower edge of the finger. Normally the mark is located between the middle third of the section, which separates the ensiform cartilage from the navel (Fig . 5.4.).

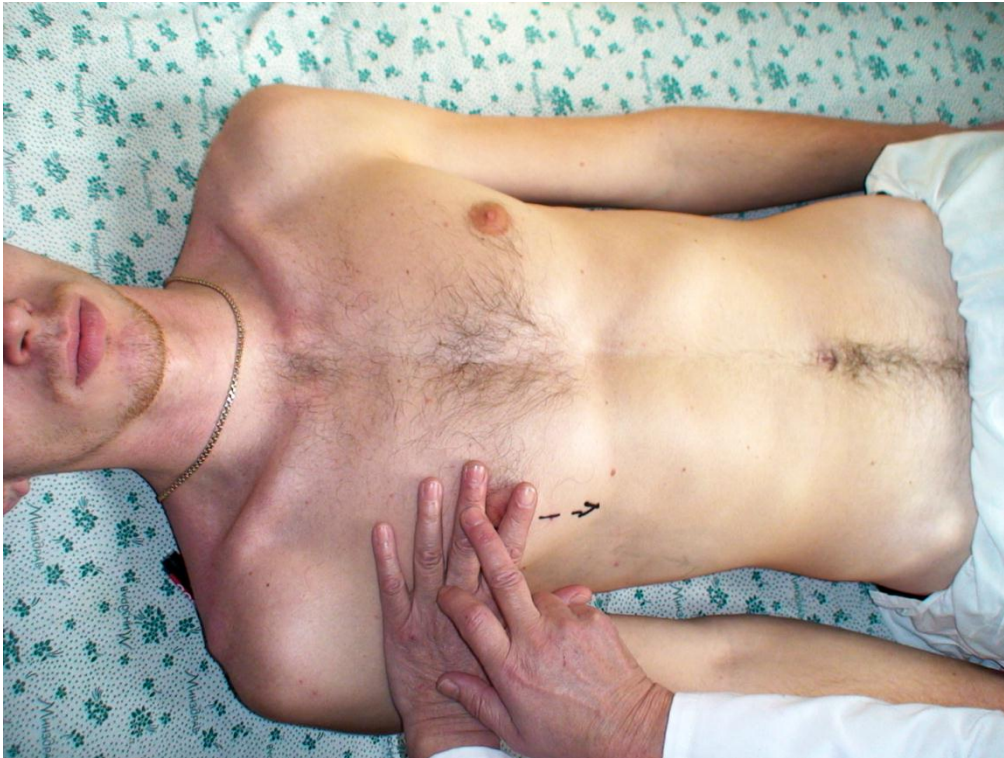

Fig . 5.1. Identification of the upper border of the liver at the right midclavicular line

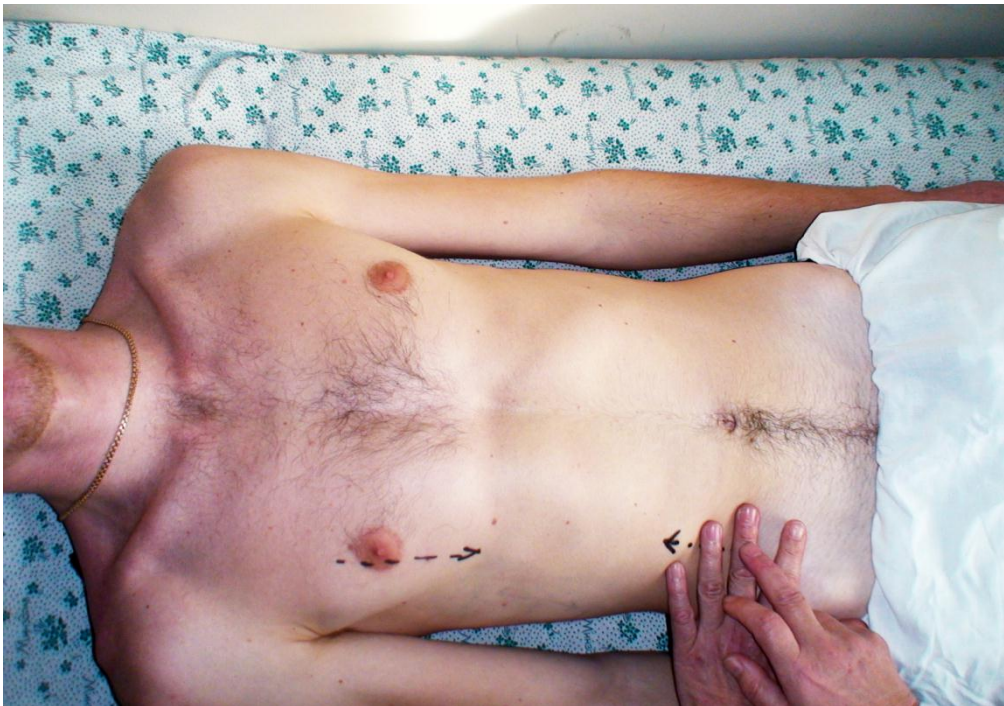

Fig . 5.2. Identification of the lower border of the liver at the right midclavicular line

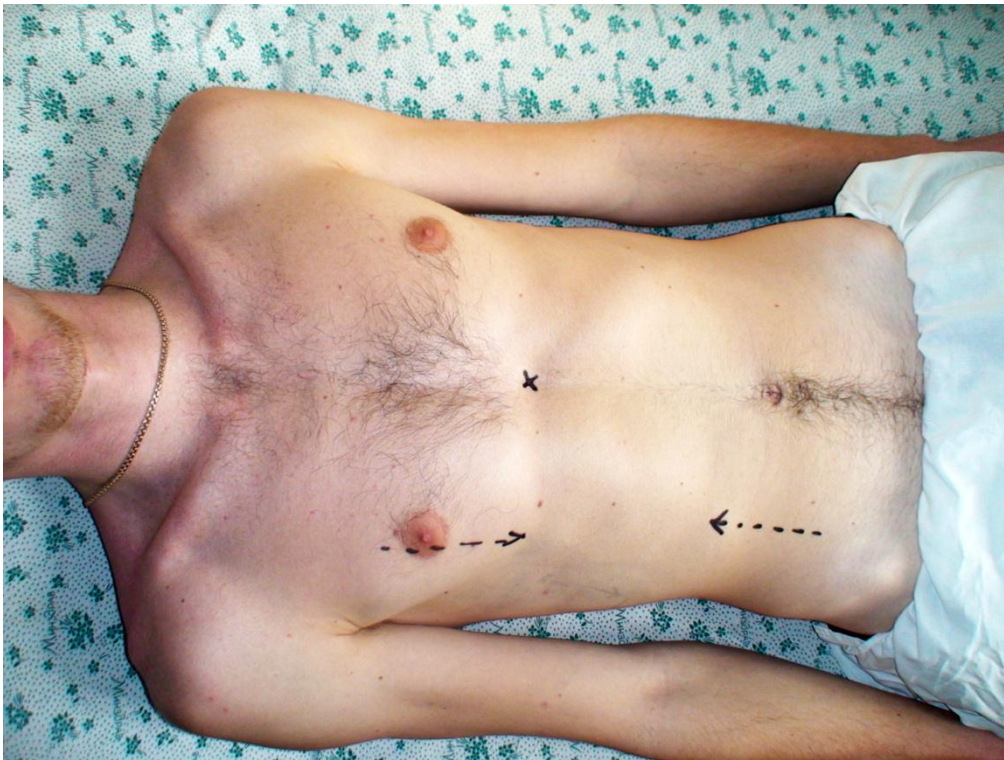


Fig . 5.3. Identification of the upper border of the liver at the anterior midline

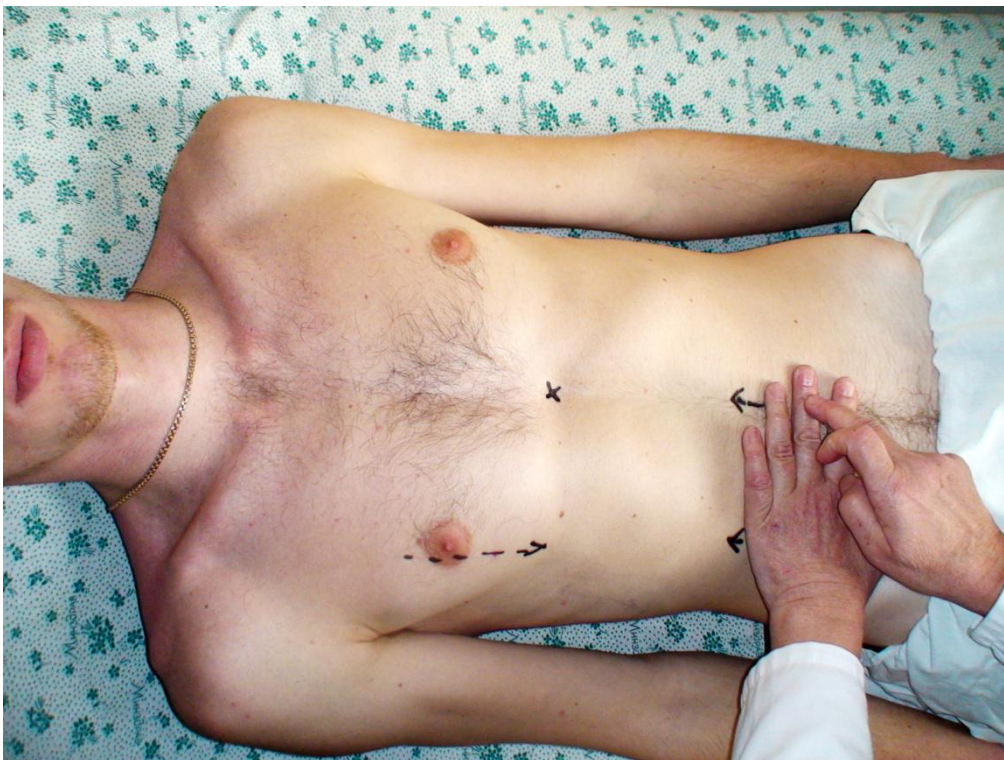


Fig . 5.4. Identification of the lower border of the liver at the anterior midline

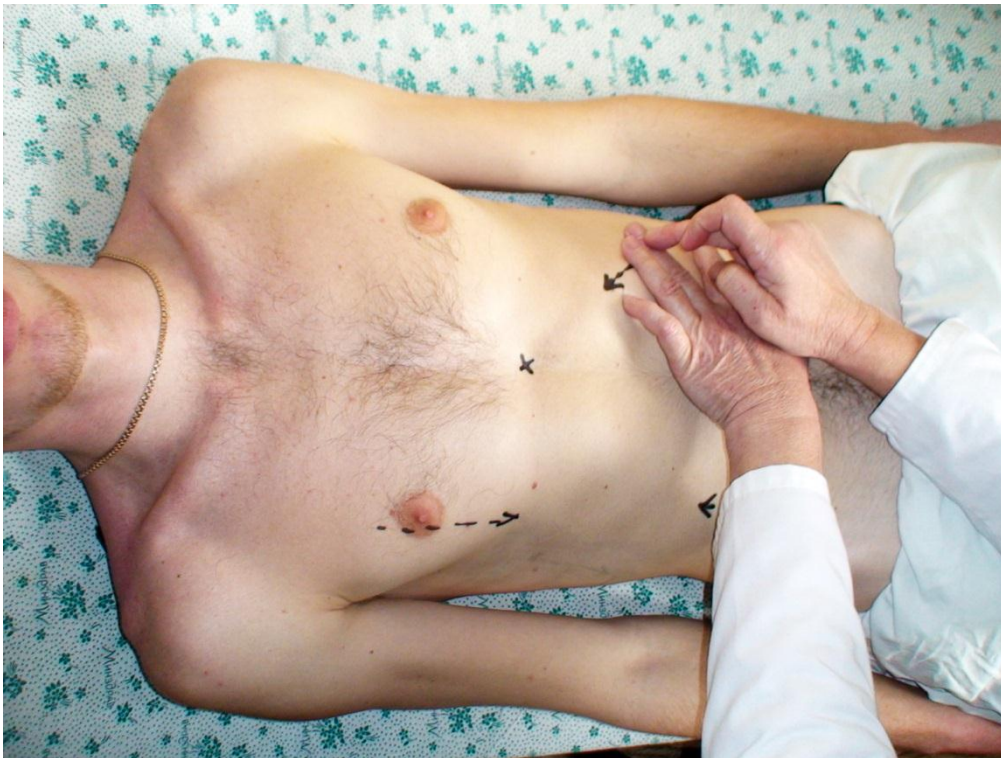

Fig . 5.5. Identification of the lower border of the liver at the left costal arch

Step 10. Identification of the lower border of the liver. The pleximeter-finger is placed perpendicular to the left costal arch at the level of the IX rib.

Step 11. Light percussion is carried out upward to the sternum till occurrence of a flat sound.

Step 12. With the help of a pencil for dermatographs a mark is made at the external edge of the finger. Normally, the lower border of the liver on the line of the left costal arch is located at the level of VII-VIII ribs (Fig .5.5).

Step 13. Measurement of three liver sizes is carried out. The first one is the distance from the upper border to the lower edge of the liver on the right midclavicular line (normally it is (9+-1)cm).

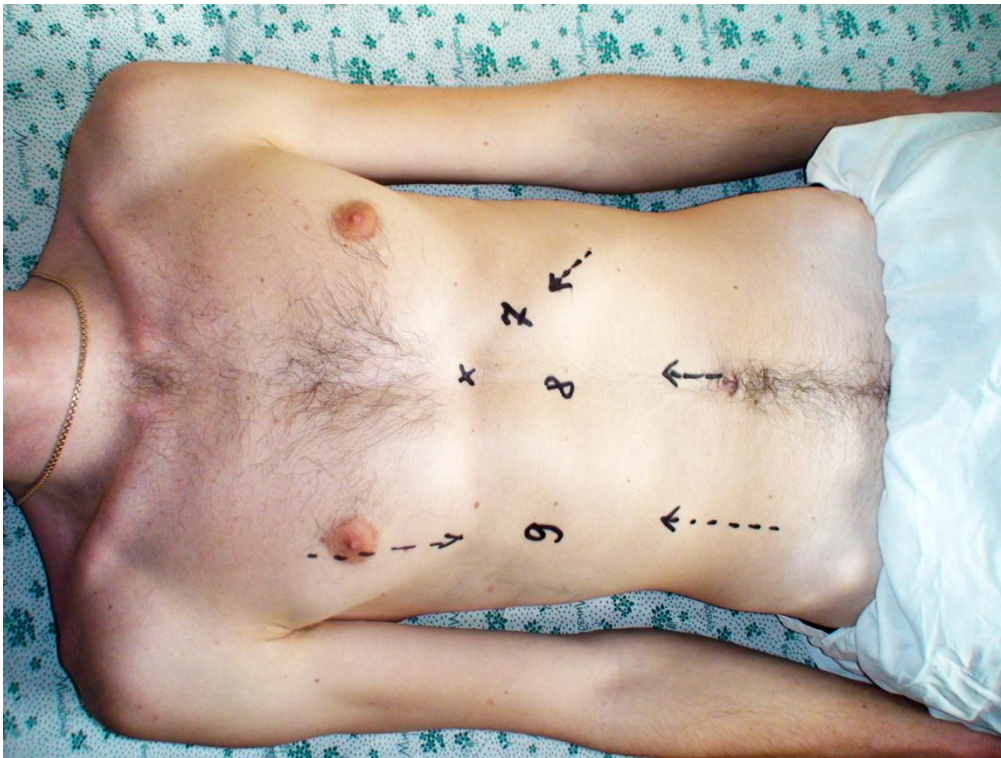


Fig .5.6. Measurement of three liver sizes

Step 14. Measuring of the second size is carried out on the anterior midline: from the upper one identified conventionally, to the lower border (normally it is (8 ± 1) cm).

Step 15. The third size of the liver is measured on the left costal arch, it is a segment that starts from the lower edge of the liver at the level of VII-VIII ribs and stretches to the upper conventional point on the anterior midline (normally it is (7 ± 1) cm; Fig . 5.6).

5.4. PALPATION OF THE LIVER

Step 1. The doctor sits to the right of the patient. The thumb of the left hand is put on the right costal arch, and the other four fingers are placed under the right lumbar region.

Step 2. The palm of the right hand is placed 4 cm. below the costal arch.

Step 3. On breathing out, the doctor dips his fingers into the abdominal cavity.

Step 4. On breathing in the patient pushes the doctor's fingers out.

Step 5. The doctor places the right palm closer to costal arch and again dips his fingers into the abdominal cavity on exhalation.

Step 6. On breathing in the patient pushes the doctor's fingers out. At this, the doctor feels with his fingers the edge of the liver, which can be firm and sharp (cirrhosis) or soft and large due to cardiac congestion (Fig. 5.7).

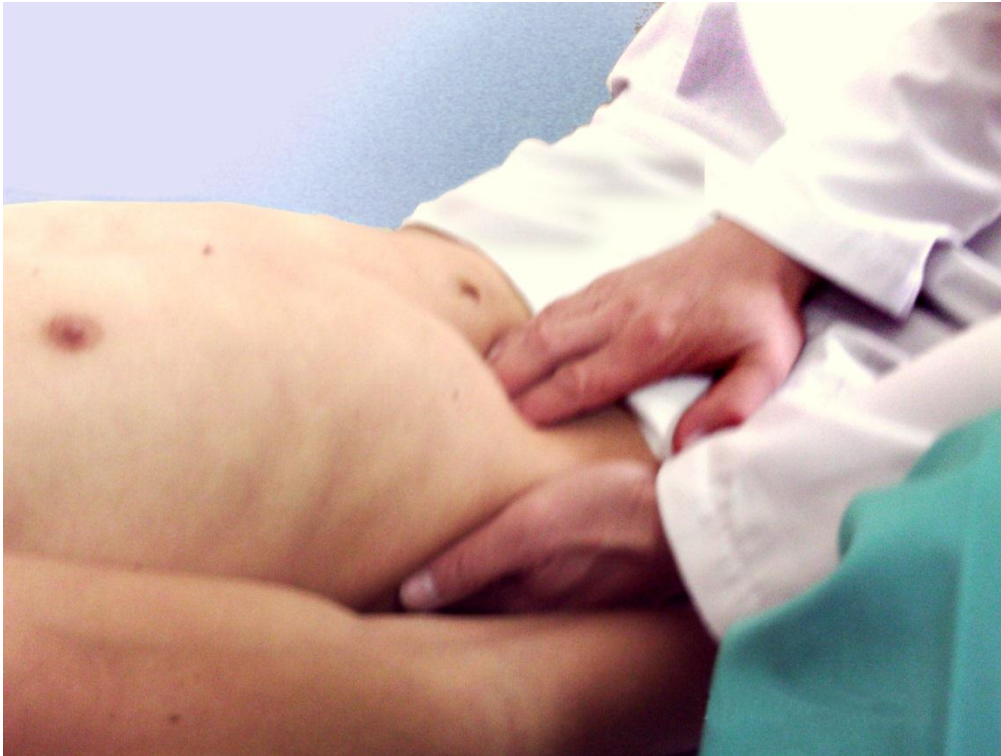

Fig. 5.7. Palpation of the liver

Part 6

URINARY SYSTEM

6.1. PLAN OF EXAMINATION OF THE URINARY SYSTEM

1. Examination
2. Palpation of the kidneys and the urinary bladder:
 - a) identification of Pasternatskiy symptom;
 - b) identification of the tapping on the lumbar region symptom.
3. Percussion of the kidneys and the urinary bladder.
4. Auscultation of the abdomen in the region near the kidneys.

6.2. EXAMINATION OF A PATIENT WITH A PATHOLOGY OF THE URINARY SYSTEM

Identification of the shape and size of the abdomen

In the presence of ascites in patients with the nephrotic syndrome the abdomen gets bulging or sharply enlarged due to congestion of transudate in the abdominal cavity and edema of the anterior abdominal wall. With a significant enlargement of a kidney (a large cyst or a tumour, hydronephrosis) asymmetry of the abdomen can be observed.

During the examination of the hypogastrium it is possible to identify a greatly stretched bladder that rises above the pubis, being replete with urine in certain diseases of the urinary tract or the central nervous system.

Examination of the lumbus

In case of accumulation of pus in the paranephric body (paranephritis) in the lumbar area there can be marked swelling with erythema - smoothing of the lumbus on the affected side. It can cause a specific position of the patient – lying with a bent in the thigh and knee joints leg on the affected side.

Examination of the genital organs

On examination of the genital organs, edema of the scrotum can be identified, because renal edemas are first of all located in places with quaggy subcutaneous tissue.

6.3. PALPATION OF THE KIDNEYS AND THE URINARY BLADDER

Identification of the location, shape, size, consistency, tenderness of the kidneys

Usually healthy kidneys, which are normally located, are not palpated. However, in thin people, especially with asthenic constitution, normal kidneys can be palpated, especially the right one, which is located lower. The kidneys are palpated on their falling or enlargement (at least 1.5-2 times). Before the study the intestines should be cleaned.

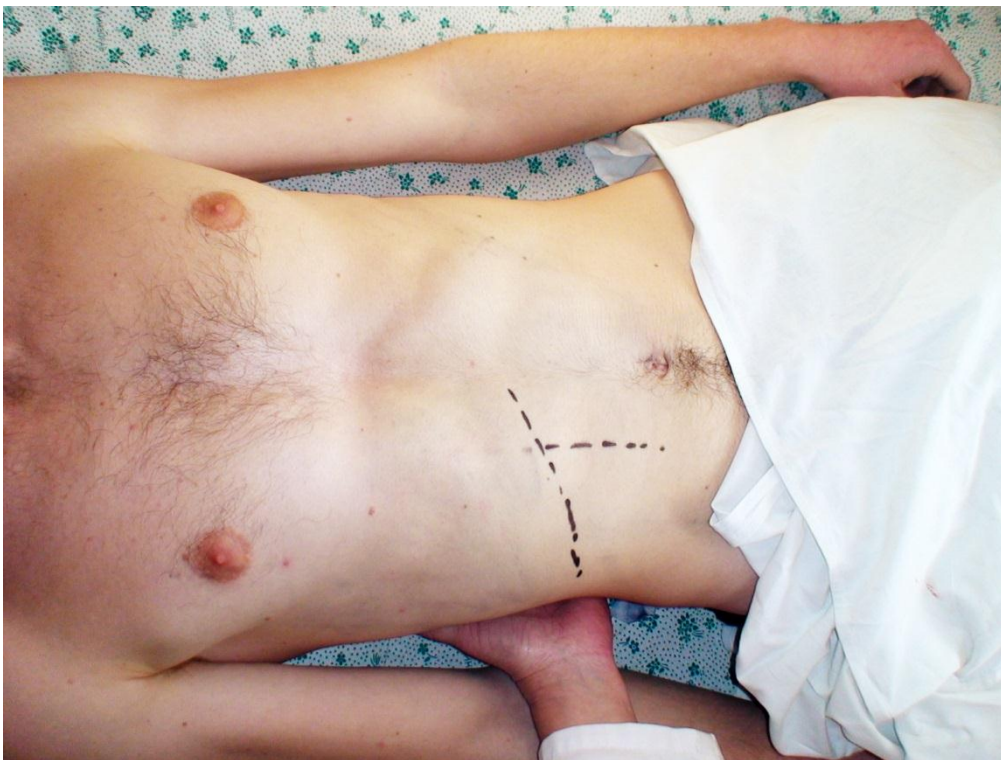
The patient must lie on his back, legs outstretched. The doctor puts his left hand with straight and put together fingers under the lumbar region and supports it.

Sometimes the best results can be achieved by palpation a kidney with the patient lying on the side with half bent legs in the thigh and knee joints. The actions of the doctor are the same as described above.

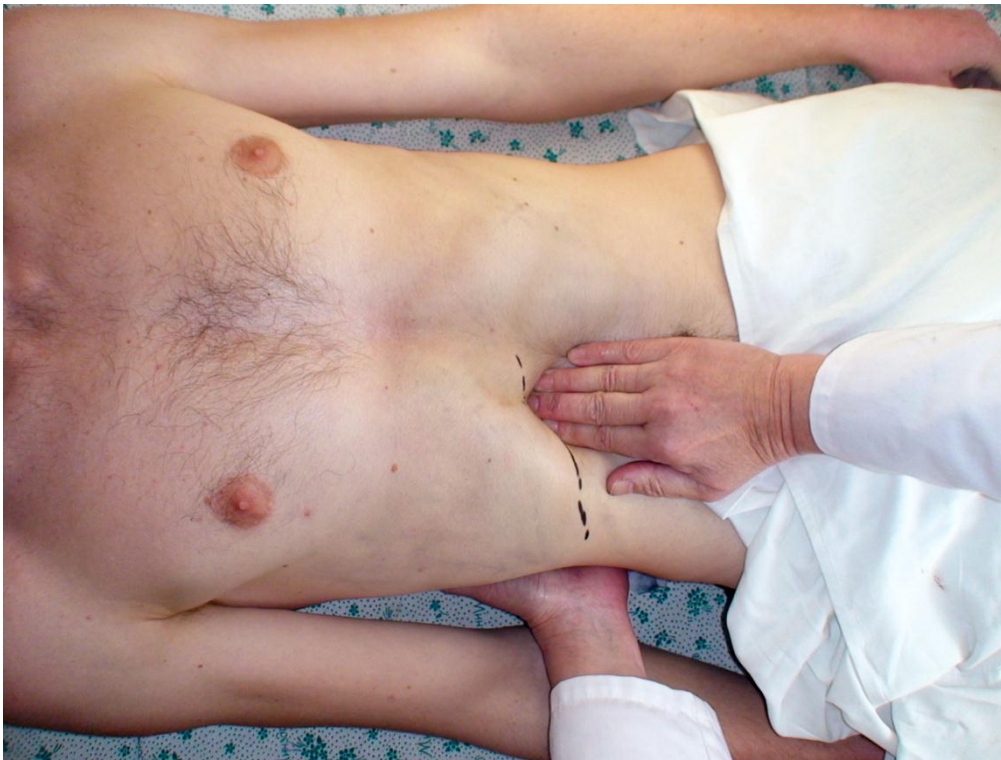Beside the method of bimanual palpation, another method is also important - ballottement. This study is carried out the same way as in the above-described method, but the fingers of the left hand make rhythmical pushes in the in the corner between the iliac muscles of the back and the lowest rib, from one hand towards the other. These pushes are felt by the fingers of the right hand that is placed in front of the left one, as a kind of fluctuation of the kidney. The ballottement symptom is indicative only of a kidney to distinguish it from other organs.

Falling of kidneys is usually combined with an increase in their mobility. There are three degrees of nephroptosis:

- In the I degree, only the lower extremity of the kidney is palpated;
- In the II degree – 2/3 or the whole kidney;
- In the III degree, the kidney is movable, it is easily displaced on palpation to the other part of the abdominal cavity (Fig. 6.1, a,b).



a



b

Fig. 6.1. Palpation of a kidney (a,b)

Identification of the size of the urinary bladder and homogeneity of its wall

The bladder is normally not palpable. In the case of urinary retention (adenoma or prostate cancer, spinal cord lesions, paresis of the bladder) the bladder bottom is palpated above the pubis as a soft elastic formation, in which fluctuation may arise. Occasionally, tumors of the bladder wall can be palpated.

Identification of tender point, associated with diseases of the urinary system

On palpation, in addition, you can reveal tender points:

- a) costovertebral (in the corner between the XII rib and the spine);
- b) upper ureteral (near the outer edge of rectus abdominis muscle at the level of the navel);
- c) lower ureteral (at the intersection of the iliac line with vertical line that passes through the spines of pubic bone – this point corresponds to the entering of the ureter into the pelvic cavity).

6.4. PERCUSSION OF THE KIDNEYS AND THE URINARY BLADDER

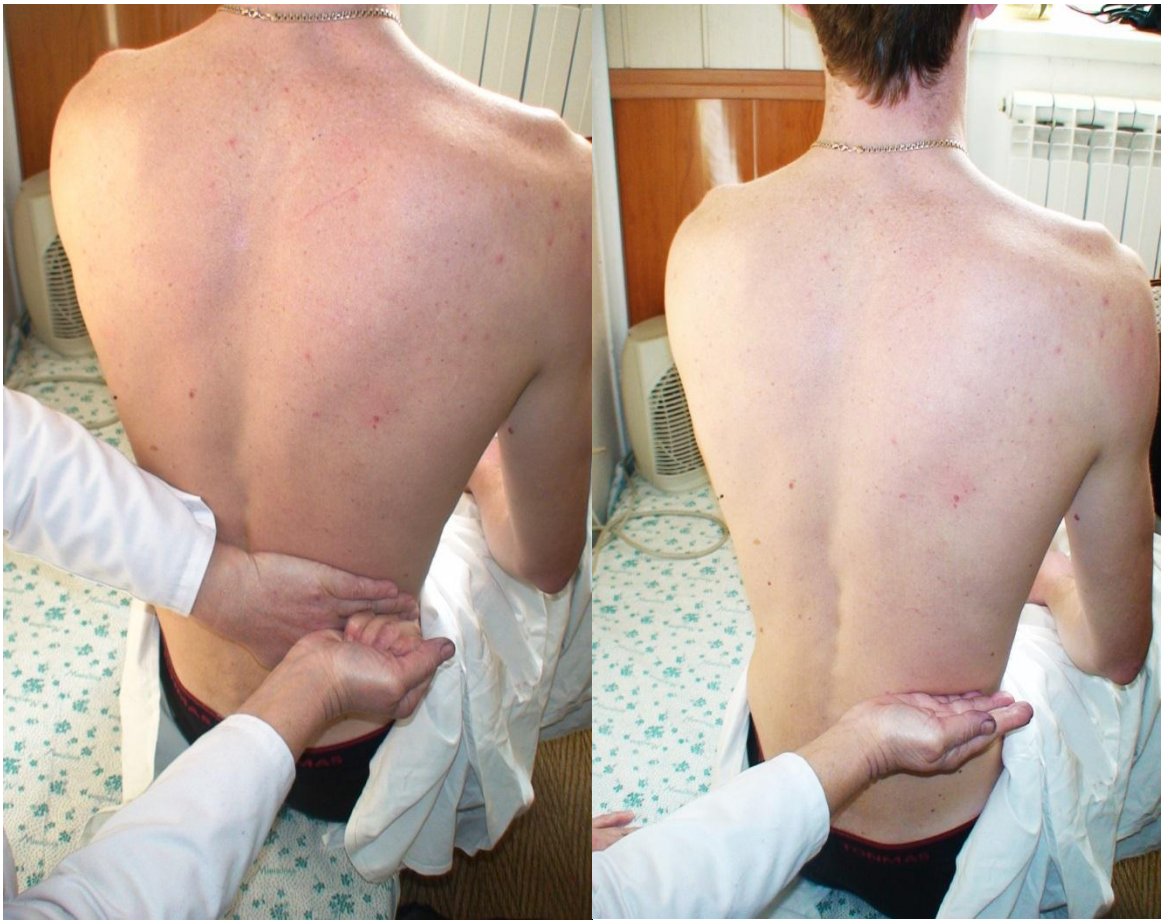Percussion of the kidneys gives little information. In healthy people, in the place of the kidneys location a tympanic sound is heard, which is caused by the presence in front of the kidneys of intestinal loops. Development of large tumors or multicystic kidney disease cause a change in the shape of the kidneys, their size and consistency, and over them a flat or dull percussion sound arises.

Identification of Pasternatskiy symptom

To determine Pasternatskiy symptom, first, a slight bump is made with the edge of the hand or the fist of the right hand on the left hand dorsal surface that is flat against the lower part of the chest above the lumbar region. This "control" bump is necessary for the patient to get used to the feeling that he will get from the bump in the lumbar area next to the spine and laterally, at the projection of the kidneys.

The intensity of the pain sensation allows to evaluate Pasternatskiy symptom as "weak", "moderate" or "strong positive", which, to a certain extent, corresponds to the severity of the pathological process in the kidneys. Positive "lateral"

Pasternatskiy symptom is observed in the presence of acute pyelonephritis, aggravation of chronic perinephritis and paranephritis, acute glomerulonephritis, urolithiasis, renal tuberculosis and other diseases. Positive "medial" Pasternatskiy symptom is more often in patients with radiculitis, myositis than in patients with kidney disease (Fig. 6.2, a,b).



a

b

Fig. 6.2. Identification of Pasternatskiy symptom (a,b)

Percussion of the urinary bladder

The bladder is not normally detectable by percussion. In the case of urinary retention (adenoma or cancer of the prostate, damage of the spinal cord, bladder paresis) in this region a dull sound is heard on percussion.

Part 7

CIRCULATORY SYSTEM

7.1. PLAN OF THE CIRCULATORY SYSTEM INVESTIGATION

1. Examination of the circulatory system organs:
 - a) examination of the skin;
 - b) examination of the mouth cavity;
 - c) examination of the lymph nodes;
 - d) examination of the abdomen.
2. Palpation of the lymph nodes.
3. Palpation of the spleen.
4. Percussion of the spleen according to V. P. Obratsov and M. D. Strazhesko method.
5. Percussion of bones.

7.2. EXAMINATION OF CIRCULATORY SYSTEM ORGANS

Skin examination

Attention is paid to the color of the skin and visible mucous membranes (examination under diffuse lighting).

Pale skin is observed in reduction in the number of red blood cells and hemoglobin (anemia, leukemia).

Cherry-red color of the skin appears in the increase in the number of red blood cells and hemoglobin.

Hemorrhages on the skin can occur in hemorrhagic diathesis (petechia, hematomas).

Dry skin, brittle hair and early graying are characteristic in iron deficiency.

Examination of the mouth cavity

The tongue is examined (atrophic - in B-12 folic acid deficiency anemia); gums and oral pharynx (acute necrotizing ulcerative gingivitis in acute leukemia).

Examination of the lymph nodes

Enlarged lymph nodes visible during the examination may be a sign of the following diseases: chronic leukemia, lymphogranulomatosis, lymphosarcoma, cancer metastasis, tuberculosis.

Examination of the abdomen

Enlarged abdomen in enlargement of the liver and spleen (chronic myeloid leukemia, lymphocytic leukemia, osteomyelofibrosis).

7.3. PALPATION OF LYMPH NODES

Lymph nodes are palpated bimanually.

Step 1. Palpation of the occipital lymph nodes.

Step 2. Palpation of the back of the neck lymph nodes on the back surface of the Sternocleidomastoid muscles.

Step 3. Palpation of anterior cervical lymph nodes on the anterior surface of the Sternocleidomastoid muscles.

Step 4. Palpation of submandibular lymph nodes.

Step 5. Palpation of supraclavicular lymph nodes.

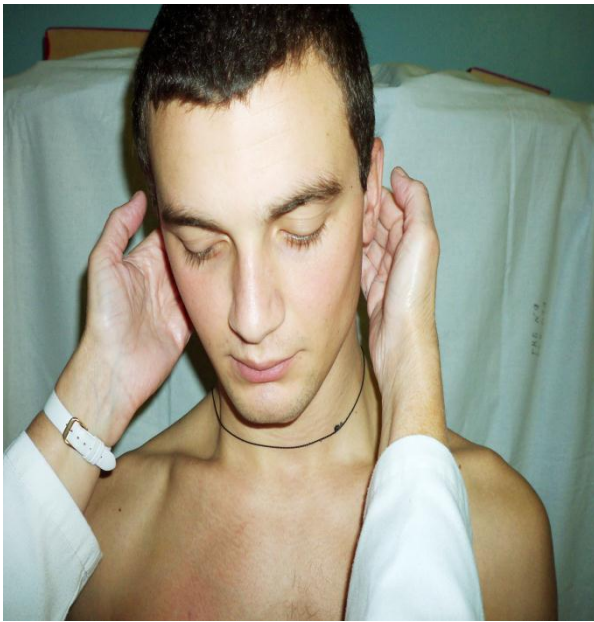
Step 6. Palpation of deltoideopectoral lymph nodes (in the infraclavicular regions).

Step 7. Palpation of the axillary lymph nodes (in the axillary cavities).

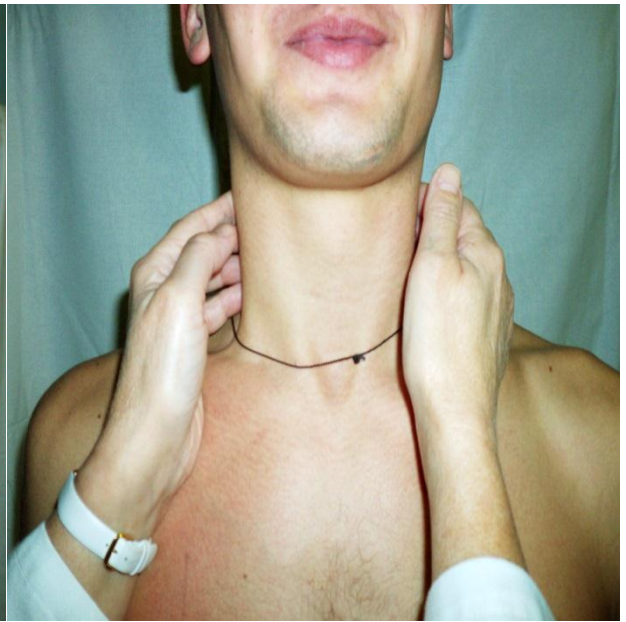
Step 8. Palpation of the axillary lymph nodes (in the axillary triangles).

Normally, lymph nodes are not palpable.

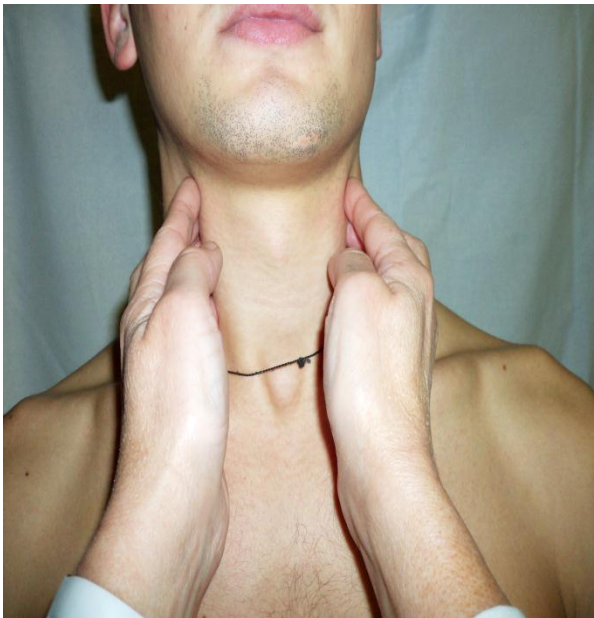
If the lymph nodes are palpable, then attention is paid to their size, texture, tenderness, mobility, skin color on them, the nature of the location (single or packages of several lymph nodes; Fig. 7.1, a-f).



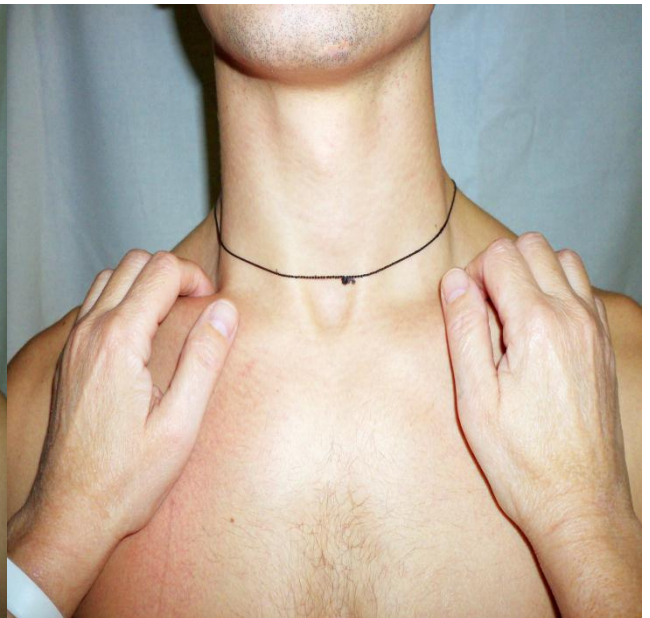
a



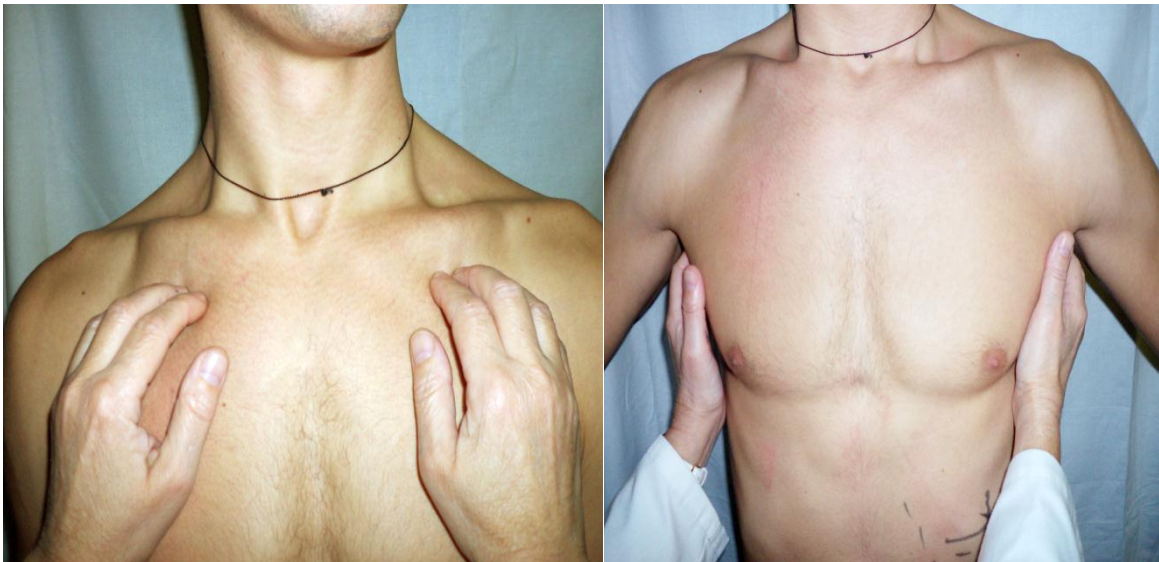
b



c



d



e

f

Fig. 7.1. Palpation of lymph nodes: a – occipital; b - back of the neck; c - anterior cervical; d – supraclavicular; e – deltoideopectoral; f – axillary

7.4. PALPATION OF THE SPLEEN

The spleen is palpated when the patient lies on his back or on the right side.

Step 1. The doctor puts his left hand flatwise on the left half of the chest in the area of VII-X ribs and gently presses it (fixation of the left half of the chest).

Step 2. The right hand with slightly bent fingers is put parallel to the rib edge in the area of X rib, at the rib edge.

Step 3. During exhalation fingers are dipped into the abdominal cavity.

Step 4. The patient is asked to take a breath. If the spleen is enlarged, it is possible to palpate its lower edge. The fingers remain motionless in the study (Fig. 7.2).

During palpation of the spleen attention is paid to its size, tenderness, texture, front surface mobility. Normally, the spleen is not palpable. The sudden enlargement of the spleen occurs in acute diseases (relapsing fever, malaria, typhoid and typhus fever, sepsis, viral hepatitis).

Chronic enlargement of the spleen is observed in diseases of the blood forming organs (chronic myeloid leukemia, chronic lymphocytic leukemia, erythremia, Werlhof's disease, cirrhosis, compression of the splenic vein, heart diseases - infectious endocarditis, congestive spleen). The spleen is mild in acute infectious diseases.

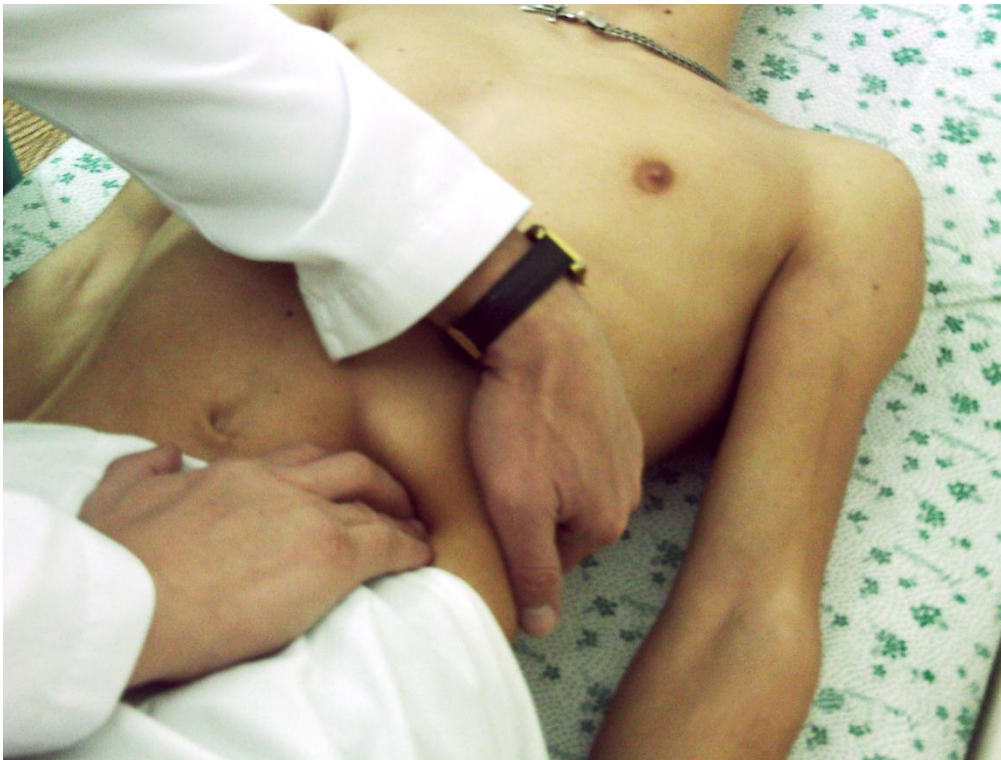

Fig. 7.2. Palpation of the spleen

7.5. PERCUSSION OF THE SPLEEN ACCORDING TO V.P. OBRAZTSOV AND M.D. STRAZHESKO METHOD

Step 1. Place the pleximeter-finger on the left middle axillary line at the level of VIII intercostal space, parallel to the costal arch (Fig. 7.3).

Step 2. Conduct a light percussion top down till the appearance of a flat sound.

Step 3. Make a mark at the edge of the finger, turned to the clear sound (Fig. 7.4).

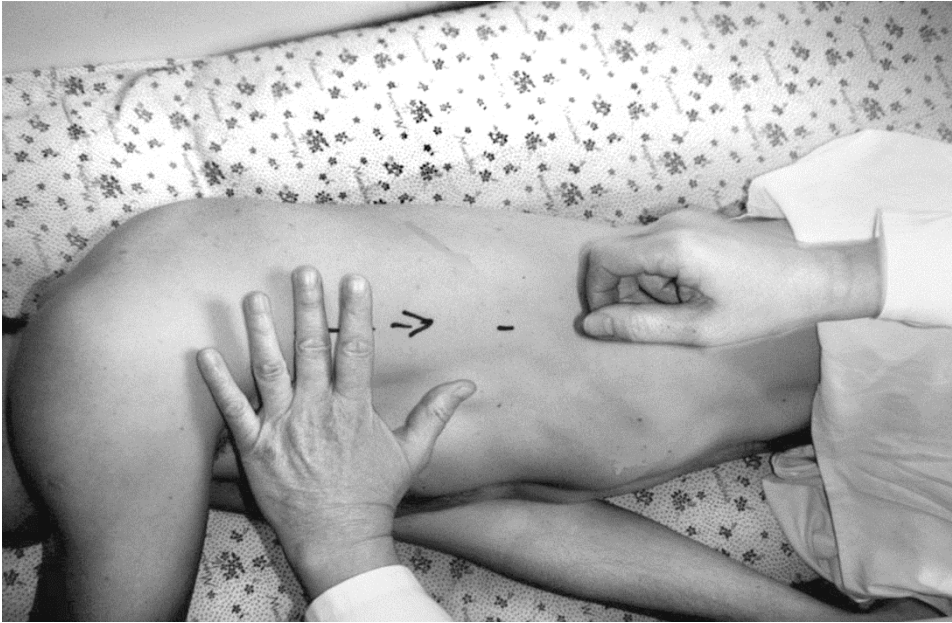

Fig. 7.3. Percussion of the spleen on the left middle axillary line (step 1)

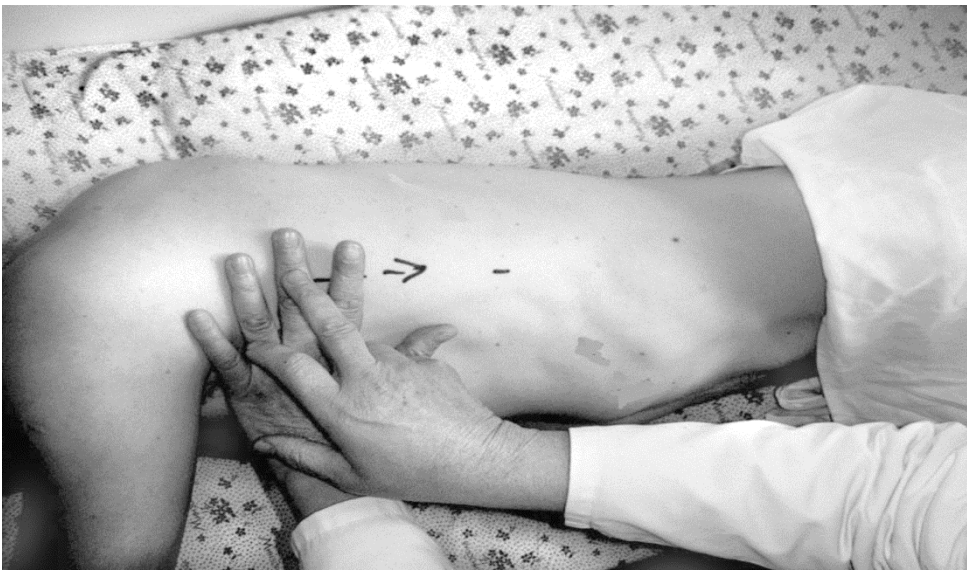

Fig. 7.4. Percussion of the spleen on the left middle axillary line (step 3)

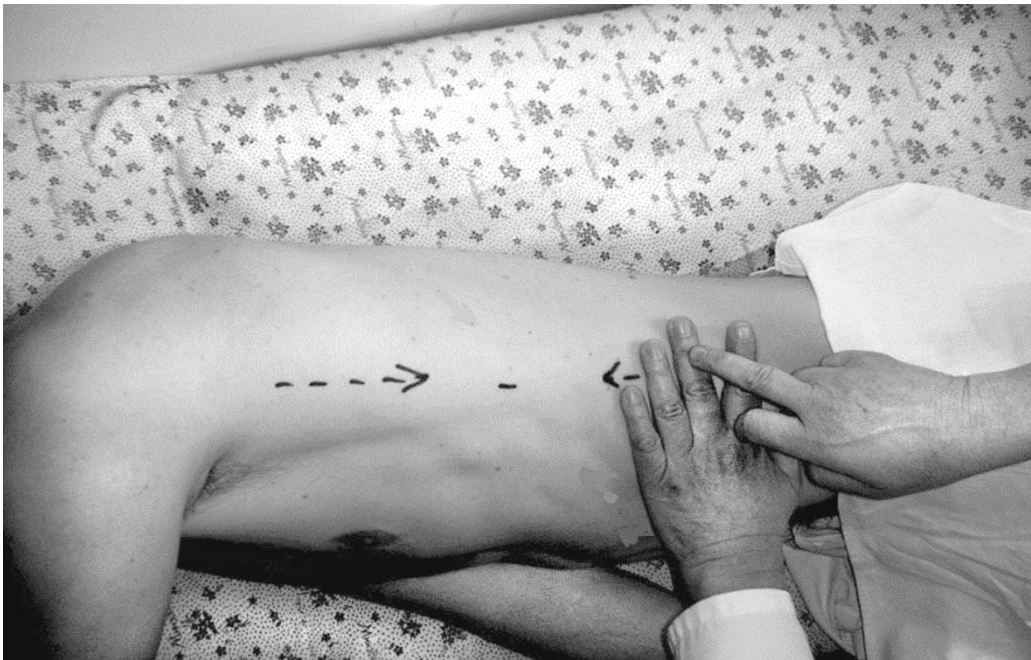

Fig. 7.5. Percussion of the spleen on the left middle axillary line (step 4)

Step 4. Continue the percussion on the left middle axillary line till the appearance of a tympanic sound (Fig. 7.5).

Step 5. Make a mark on the edge of the finger, facing the tympanic sound. Measure the distance between the two marks. Normally, the width of the spleen width between IX and XI ribs is 4-6 cm (Fig. 7.6).

Step 6. Determine the length of the spleen: light percussion is carried out from the edge of the costal arch along the X rib till the appearance of a flat sound (Fig. 7.7).

Step 7. Make a mark at the edge of the pleximeter-finger, facing the clear sound (Fig. 7.8).

Step 8. The pleximeter-finger is moved to the back axillary line and along the the X rib percussion is conducted toward the abdomen till the appearance of a flat sound (Fig. 7.9).

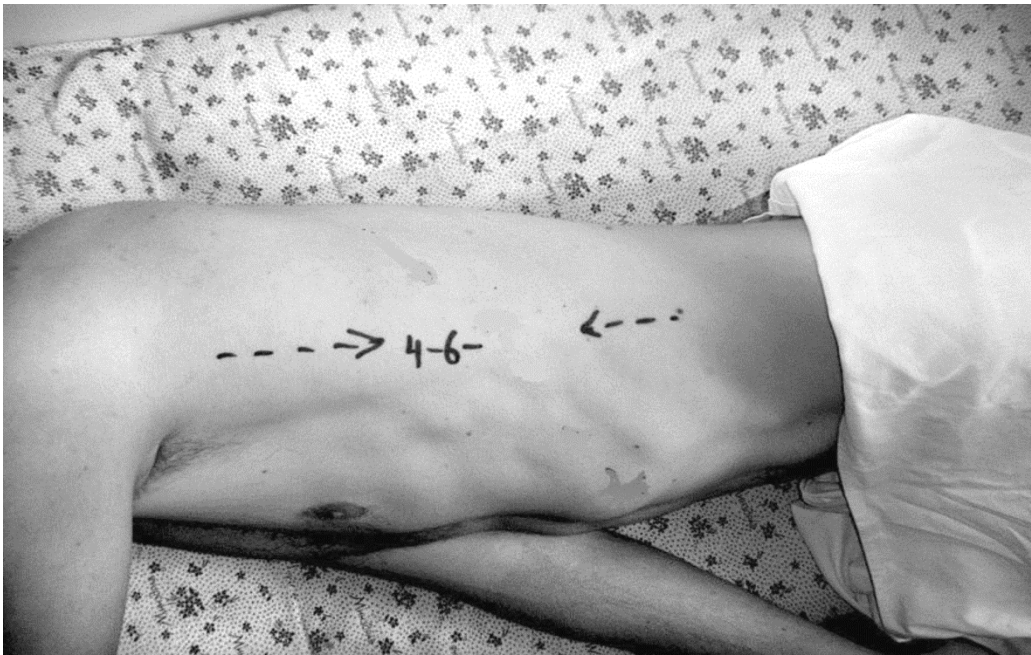


Fig. 7.6. Identification of the spleen width

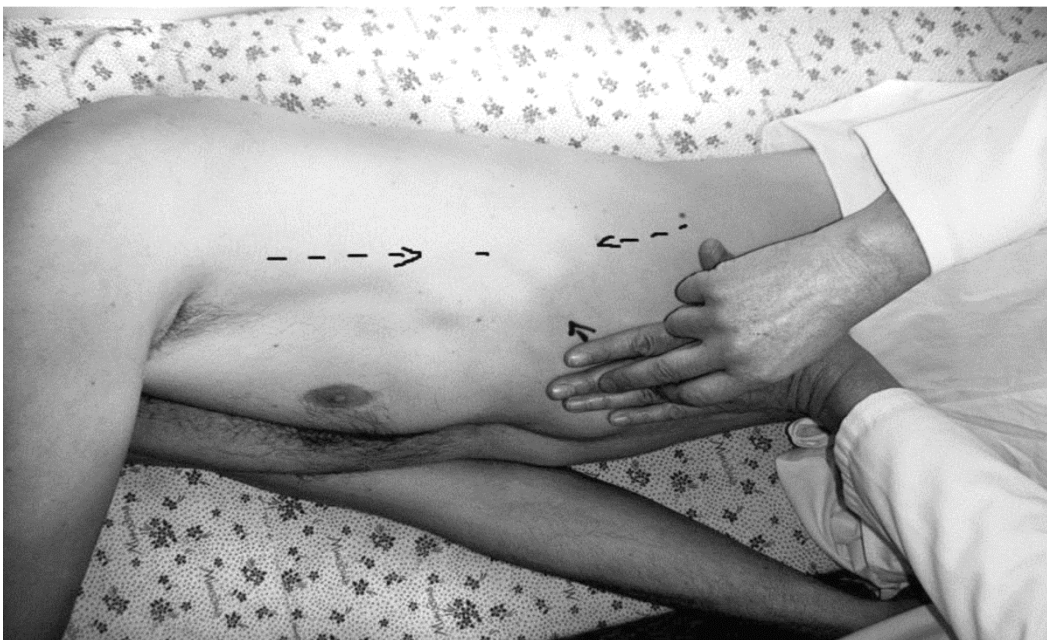


Fig. 7.7. Percussion of the spleen from the edge of the costal arch along X rib (step 6)

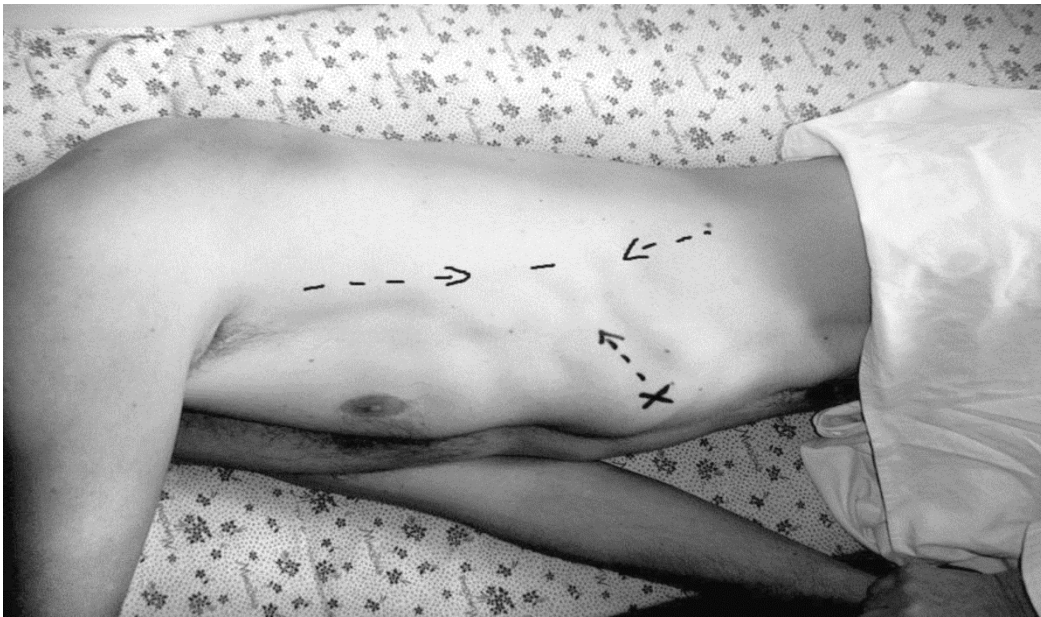

Fig. 7.8. Percussion of the spleen from the edge of the costal arch along X rib (step 7)

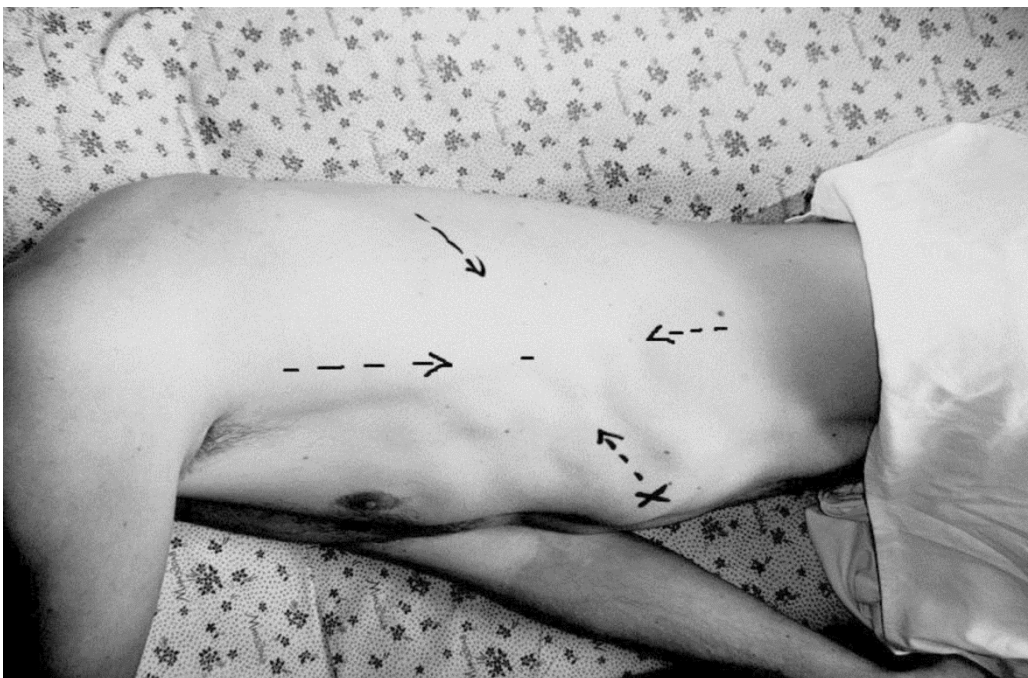

Fig. 7.9. Percussion of the spleen from the posterior axillary line and along X rib toward the abdomen (step 8)

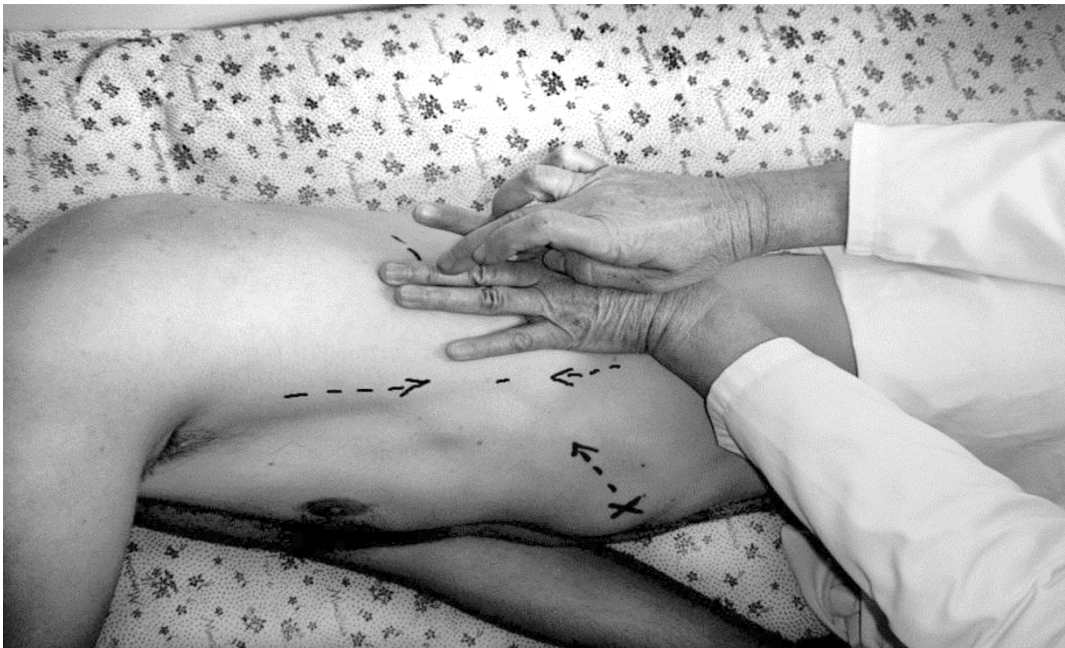

Fig. 7.10. Percussion of the spleen from the posterior axillary line and along X rib toward the abdomen (step 9)

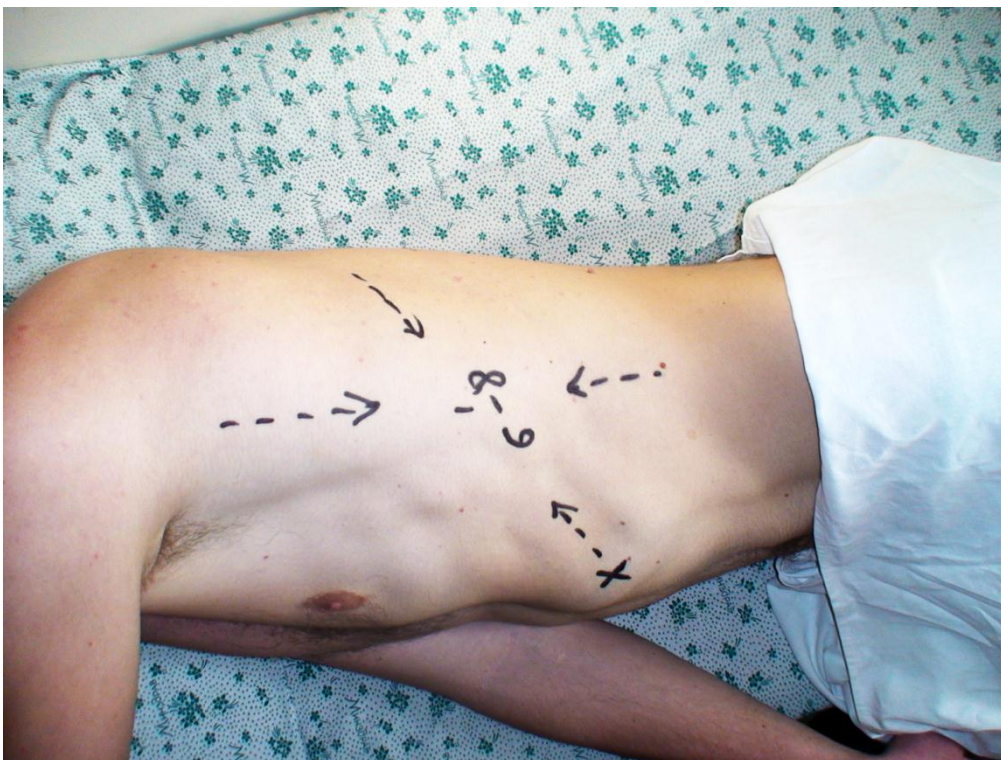


Fig. 7.11. Identification of the spleen length

Step 9. Make a mark at the edge of the pleximeter-finger, facing the clear sound (Fig. 7.10).

Step 10. Measure the distance between the two marks. Normally the spleen length is 6-8 cm (Fig. 7.11).

7.6. PERCUSSION OF BONES

On tapping on tubular bones and the sternum tenderness is observed in acute and chronic leukemia (ossalgia and sternalgia which is) due to increase of the amount of bone marrow (Fig. 7.12).

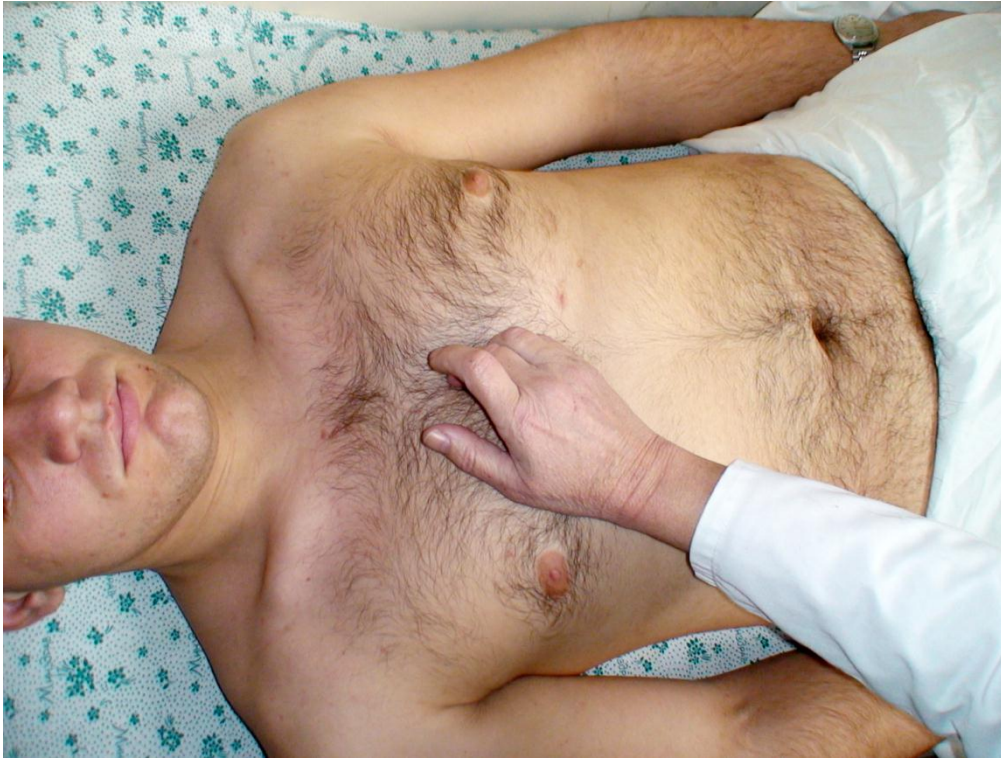

Fig. 7.12. Percussion of the sternum

Part 8

ORGANS OF THE ENDOCRINE SYSTEM AND METABOLISM

8.1. PLAN OF INVESTIGATION OF THE ORGANS OF THE ENDOCRINE SYSTEM AND METABOLISM

1. Examination:

- a) determine presence or absence of changes in the behavior of the patient;
- b) presence or absence of changes and the nature of speech of the patient.

2. Successive examination of the body parts:

- a) pay attention to the height (body length) of the patient;
- b) pay attention to the size and ratio of individual body parts;
- c) assess the shape of the chest;
- d) assess the nutritional status of the patient and peculiarities of distribution of the subcutaneous fat;
- e) assess the body hair;
- f) assess the condition of the skin and its appendages;
- g) examine the face;
- h) examine the neck.

3. Palpation of the neck:

- a) palpation of the thyroid gland;
- b) dynamic observation of the increased thyroid gland.

4. Examination and palpation of the external and internal genitals (genital study, diagnosis of diseases of the genitals).

5. Deep palpation of the abdomen.

6. Percussion.

7. Auscultation of the thyroid gland area.

8.2. EXAMINATION OF THE PATIENT WITH PATHOLOGY OF THE ENDOCRINE SYSTEM

Determine the presence or absence of changes in patient behavior

Changes in the behavior of the patient allow to detect symptoms of certain diseases. Thus, in constant anxiety hyperthyroidism is possible. Stolidity, stiffness, apathy, lack of facial expression can be observed in myxedema, melancholy and lethargy – in acromegaly. Depression, frequent mood swings are characteristic of the menopause in women.

The presence or absence of a change in the nature of the patient's speech

If the patient has experienced rapid speech, he interrupts the interlocutor all the time, inserts replica – these are possible signs of thyrotoxicosis.

Myxedema is characterized by slow speech, hoarse voice, slow answers to questions sometimes patients do not say phrases to the end. Excessively loud voice appears in acromegaly and high infant monotonic voice - in eunuchoidism.

Successive examination of the body parts

Pay attention to the height (body length) of the patient.

The height of the patient is measured with a height meter it is a device consisting of a square wooden platform and a vertical plank with centimeter divisions.

Along the plank there is a moving planchette with a horizontal bill.

The patient (without shoes) stands on a platform of the height meter, with his back to the plank, touching it with his heels, the interscapular region and neck area. The head is positioned so that the top edge of the external ear canal and the angle of the eye were on the same horizontal line. The planchette, raised above the patient's head in advance, is lowered down on the patient's head, then the patient is asked to get off the platform. At the dial at the lower edge of the planchette the patient's height in centimeters is subtracted.

If the patient's height is over 195 cm it is a giant growth, which may be the sign of acromegalic or eunuchoid gigantism.

If the patient's height is less than 135 cm it is dwarfism. There are proportional and disproportional dwarfisms distinguished, and also pituitary and thyrogenic forms.

Pay attention to the size and ratio of individual body parts.

Disproportionate increase in distal parts of the body (nose, lips, chin, hands, feet) is typical in acromegalia (Fig. 8.1). Shortening of the V finger can be a manifestation of hypothyroidism, hypofunction of the pituitary-hypothalamic system.

Assess the shape of the chest, using the data, given in Table 8.1.




Fig. 8.1. Acromegaly

Table 8.1 Assessment of the shape of the chest

Characteristics of the chest	Characteristic disease
Wide, short, barrel	Cushing disease (fig. 8.2).
Wide, high	Acromegaly
Flat, excessively big distance between nipples and underdeveloped breast	Turner syndrome
Absence of breast, their atrophy or hypoplasia	Hypoovarism, hypofunction of adenohipophysis
Enlargement of mammary glands in men - Gynaecomastia	Klinefelter's syndrome, tumours of testicles which feminize, hypothalamic pathology, pituitary pathology

Assess the nutritional status of the patient and peculiarities of distribution of the subcutaneous fat, using the data, given in table 8.2.

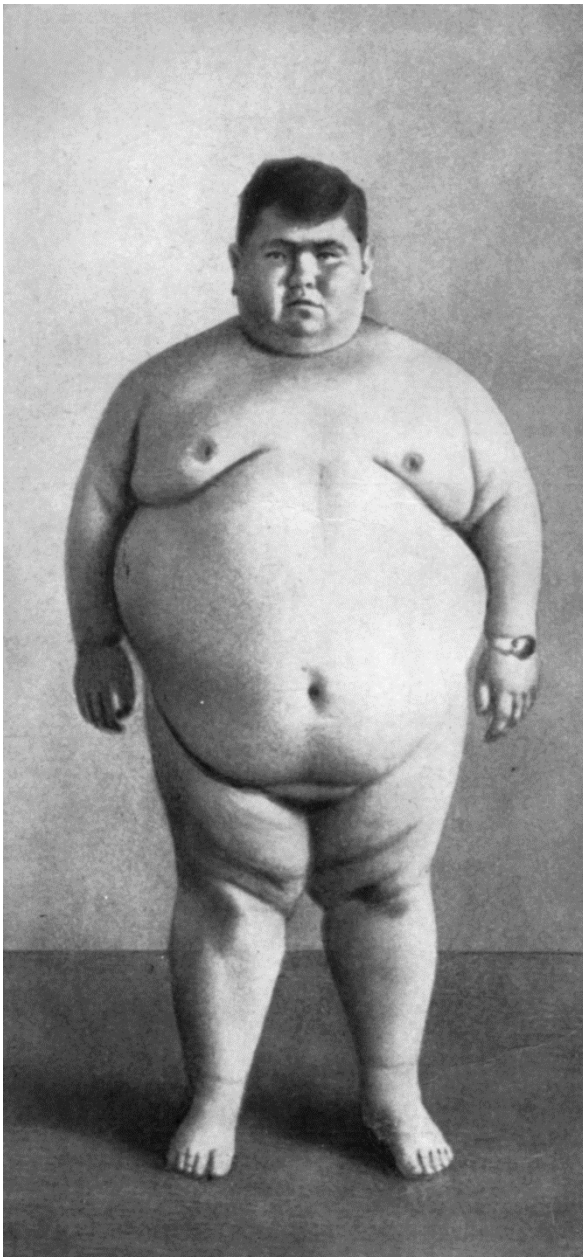


Fig. 8.2. Cushing disease

Table 8.2 Assessment of the nutritional status of the patient and peculiarities of distribution of the subcutaneous fat

Characteristics of the subcutaneous fat	Characteristic disease
Predominant adipopexia in the area of pelvic waist (lower part of the abdomen, buttocks, thighs) and on the chest	Adiposogenital degeneration
More or less equal distribution of fat	Thyrotoxic obesity

<p>all over the body</p> <p>Adipopexia in the area of shoulders, pelvis, head of the femur, pubis in men – feminization</p> <p>Lessening of adipopexia in the area of shoulders, pelvis, head of the femur, pubis and appearance of it in the area of the chest, lumbar area, neck, face, abdomen in women</p> <p>Equal, proportional adipopexia</p> <p>Significant obesity of the whole body, neck, face, adipopexia in the area of VII cervical vertebra, significant enlargement of the mammary glands due to fat, big hanging abdomen with less significant obesity of forearms, ankles, hands and feet</p>	<p>Underdevelopment of testes</p> <p>Masculinization</p> <p>Alimentary obesity</p> <p>Cerebral or hypothalamic obesity</p>
---	--

Assess the body hair, using the data, given in table 8.3.

Table 8.3 Assessment of the the body hair

Characteristics of the body hair	Characteristic disease
Dry brittle hair, loss of it on the head, in the external areas of the brows, in the armpits	Hypothyroidism
Darkening of hair, moderate loss of it in the armpits and on the pubis	Chronic adrenocortical insufficiency
Total hair loss on the head, in the armpits, on the pubis	Hypopituitarism
Growth of hair in men on the pubis in a female pattern (in the form of a triangle) – feminization	Underdevelopment of testes
	Cushing disease,

Growth of hair in women in a male pattern, in combination with coarseness and excessive growth (hypertrichosis) on the legs, trunk, face, loss of hair on the head

corticosteroma, androsteroma, virilizing tumor of the ovaries (Fig. 8.3).

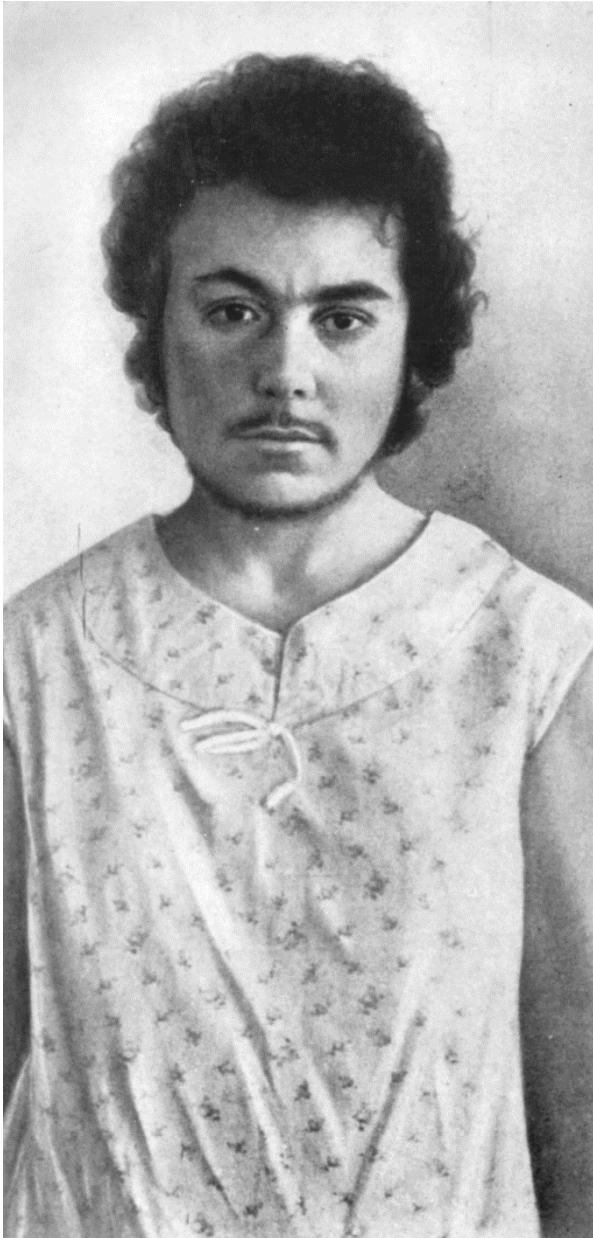

Fig. 8.3. Virilizing tumor of the ovaries

Assess the condition of the skin and its appendages in the following consequence.

Step 1. Pay attention to the colour of the skin:

- diffuse bronze skin on the open areas, in skin folds, in the areas of touch with clothes, often in combination with hyperpigmentation of mucous membranes is a characteristic sign of Addison disease (bronze disease, hypocorticism);
- moon face of vermilion red colour - Cushing disease;
- paleface with a yellowish tint – myxedema;
- pigmentation of the face around eyes (periorbital) - toxic goiter.

Step 2. Pay attention to the presence of the hair on the body, the temperature of the skin, wetness, elasticity:

- Hyperaemic, hot to the touch, thinned and moist skin - hyperthyroidism;
- Cold, dry, wrinkled, pale, scaled, senile looking skin - hypothyroidism;
- Pretibial myxedema (swelling of the supraclavicular areas, the outer surface of the hands, shins) - hyperthyroidism;
- Bronze skin tone - Addison's disease;
- Wrinkled, thin, dry, loose skin with a yellowish tint - hypopituitarism (pituitary dwarfism, Simond's disease).

Step 3. Pay attention to the presence of elements of rash:

- acne vulgaris - hypestrogenism;
- Cyanotic atrophy stripes (striae) - hypocorticism.

Examination of the face

On examination of the patient's face some characteristics can help to determine a possible disease:

- amimic, with narrowed eye slits - hypothyroidism;
- dry, with atrophy of facial muscles - hypopituitarism;
- presence of eye symptoms - hyperthyroidism (diffuse toxic goiter; Fig. 8.4);
- high eye brilliance, ophthalmoptosis - exophthalmos;
- eyelid skin hyperpigmentation – Ellinek's symptom;
- an expression of anger, surprise - Delrimpl's symptom;

- rare winking - Stellwag's symptom;
- disturbance of eyeball convergence (on the motion of an object in the direction of the tip of the nose eyeballs converge at first, then quickly return to the previous state) - Mobius symptom;
- small tremor of closed eyelids - Rosenbach's symptom;
- inability to corrugate the forehead when looking up - Doffrua's symptom;
- detachment of the upper eyelid from the iris on movement of the eyeball down - Kocher's symptom;
- when moving the eyeballs down strips of sclera may appear between the upper eyelids and the iris - Graefe's symptom.

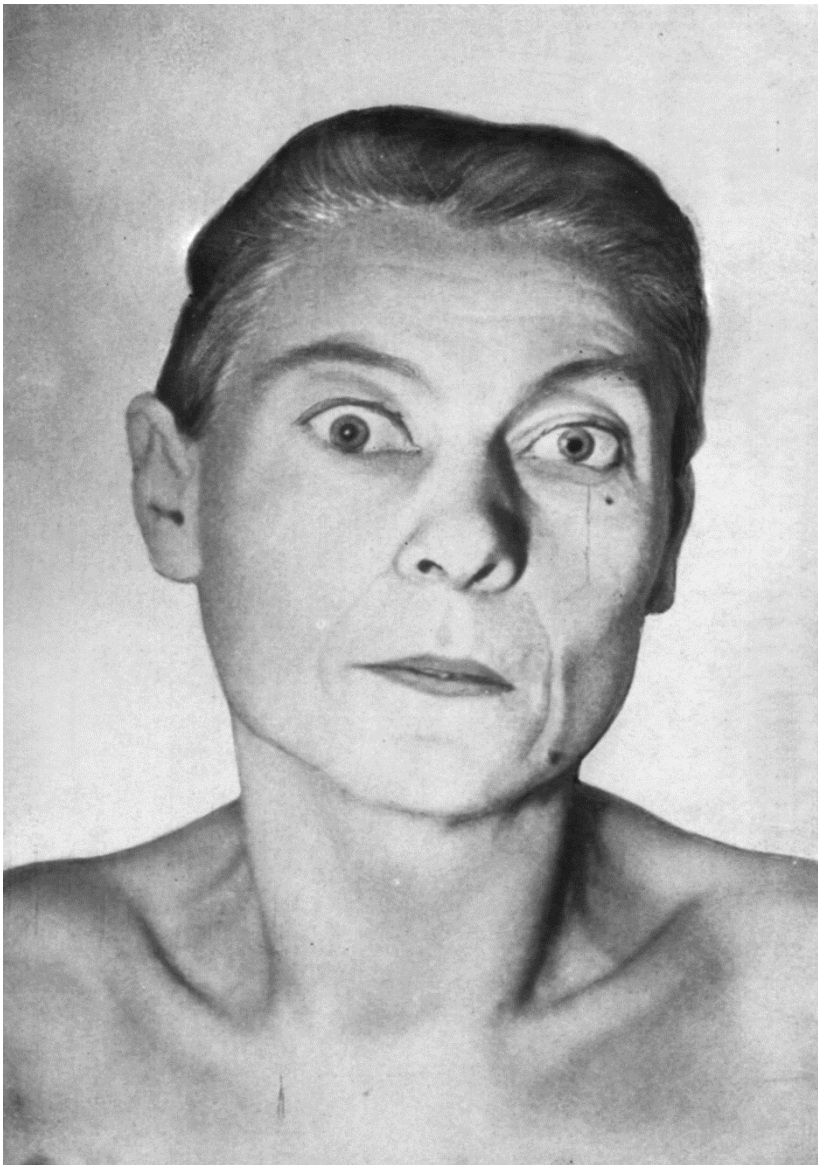

Fig. 8.4. Hyperthyroidism (diffuse toxic goiter)

Neck examination

The deformation of the neck is caused by increasing of the size of the thyroid gland and the asymmetry of its parts.

According to WHO, there are the following degrees of the thyroid gland enlargement:

0 - absent goiter (the thyroid gland is not palpable or palpable smaller than the end-point phalanx of the patient's finger);

1 a – the thyroid gland is clearly palpable, but is not identified visually; larger than normal (larger than the end-point phalanx of the patient's finger);

1 b – the thyroid gland is identified visually at the position with the upturned head, here belong all the cases of individual nodes;

2 – the thyroid gland is identified visually in the normal position of the head;

3 – goiter is seen from distance (Fig. 8.5).

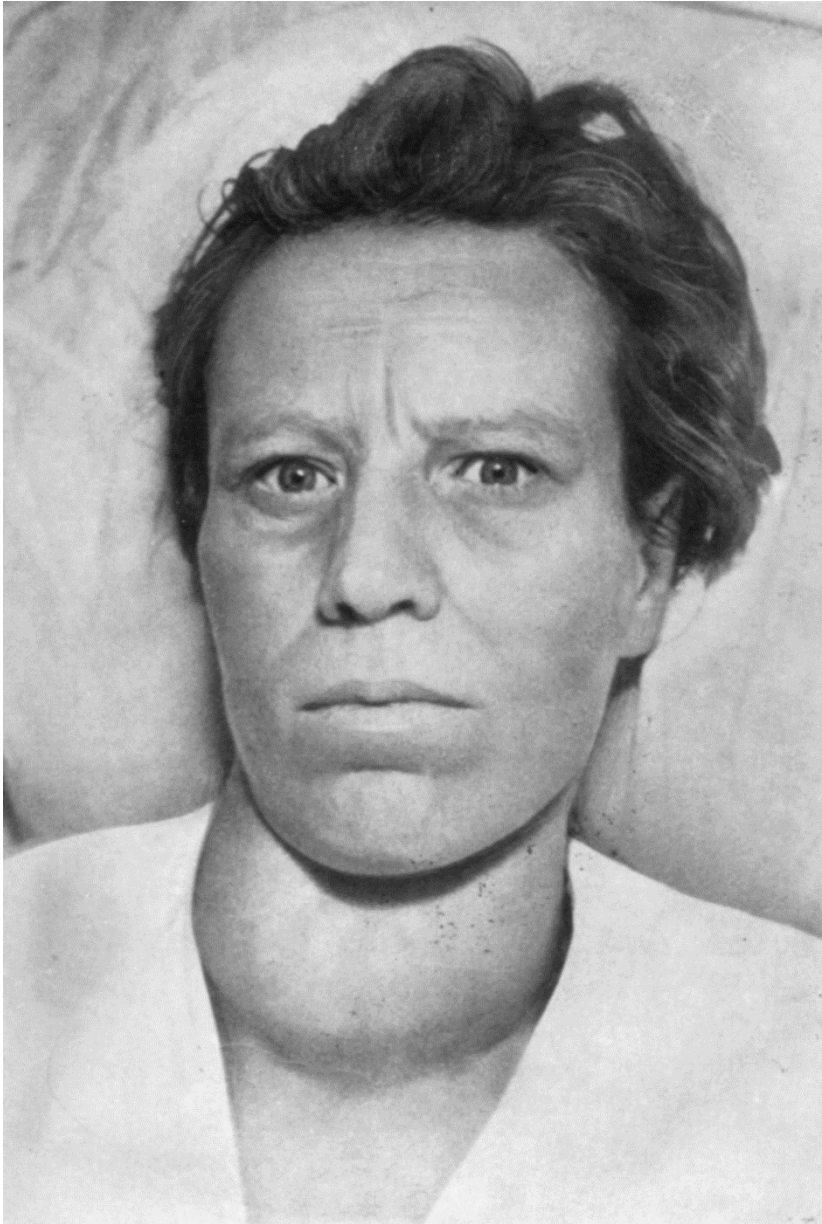

Fig. 8.5. The third degree of the thyroid gland enlargement

8.3. PALPATION OF THE NECK

Palpation of the thyroid gland

Palpation of the thyroid gland is carried out in three steps.

Step 1. Oriented palpation of the thyroid gland - superficial palpation in the projection of the thyroid gland. At this following features are identified:

- density of the organ;
- the character of the surface of the organ;

- presence of nodes;
- tenderness.

Step 2. Mono – and bimanual palpation of the thyroid gland:

There are three methods of palpation of the thyroid gland:

The first method. The doctor, standing face to the patient puts in bent II – V fingers of both hands on the posterior edges of the clavisternomastoid muscles, and the thumbs are placed in the area of the thyroid cartilages somewhat in the middle of the front edges of these muscles. At the time of palpation the patient is asked to swallow, as a result the thyroid gland moves along with pharynx and gets under the doctor's fingers (Fig. 8.6).

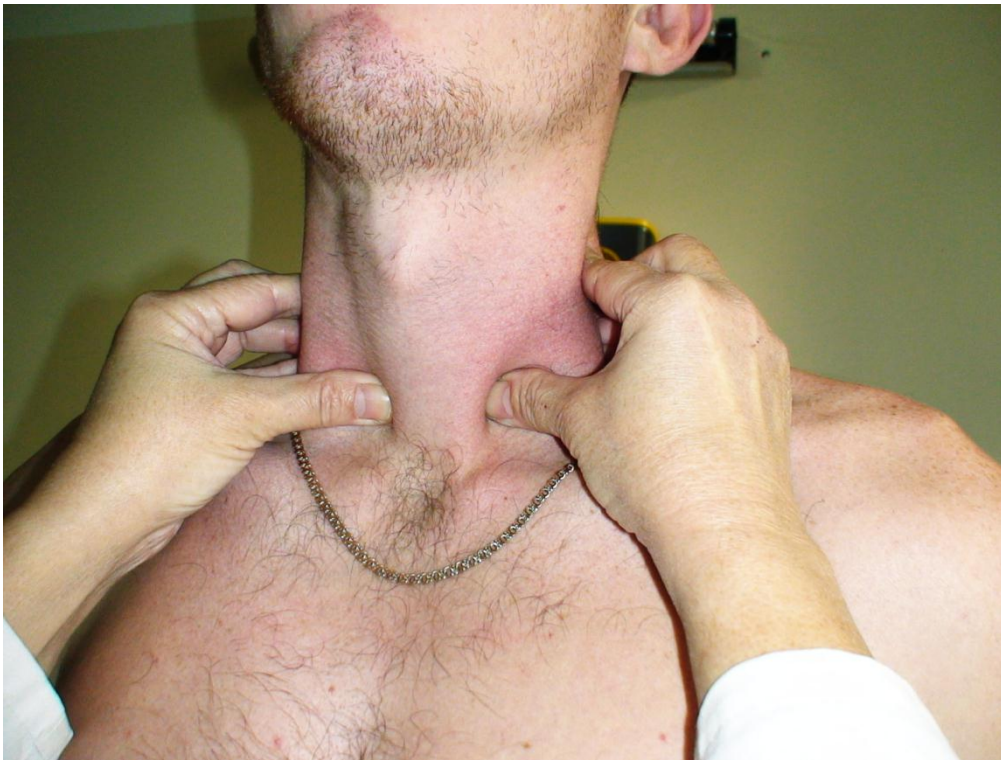

Fig. 8.6. The first method of the thyroid gland palpation

The second method. The doctor takes a position to the right and slightly in front of the patient. For better relaxation of the neck muscles the patient is asked to tilt his head slightly forward. The doctor fixes the palm of his left hand behind the patient's neck, and the fingers of his right hand carry out palpation of the thyroid gland. Palpation of the right part is conducted with the thumb, and palpation of the left part – with the other fingers put together (Fig. 8.7).

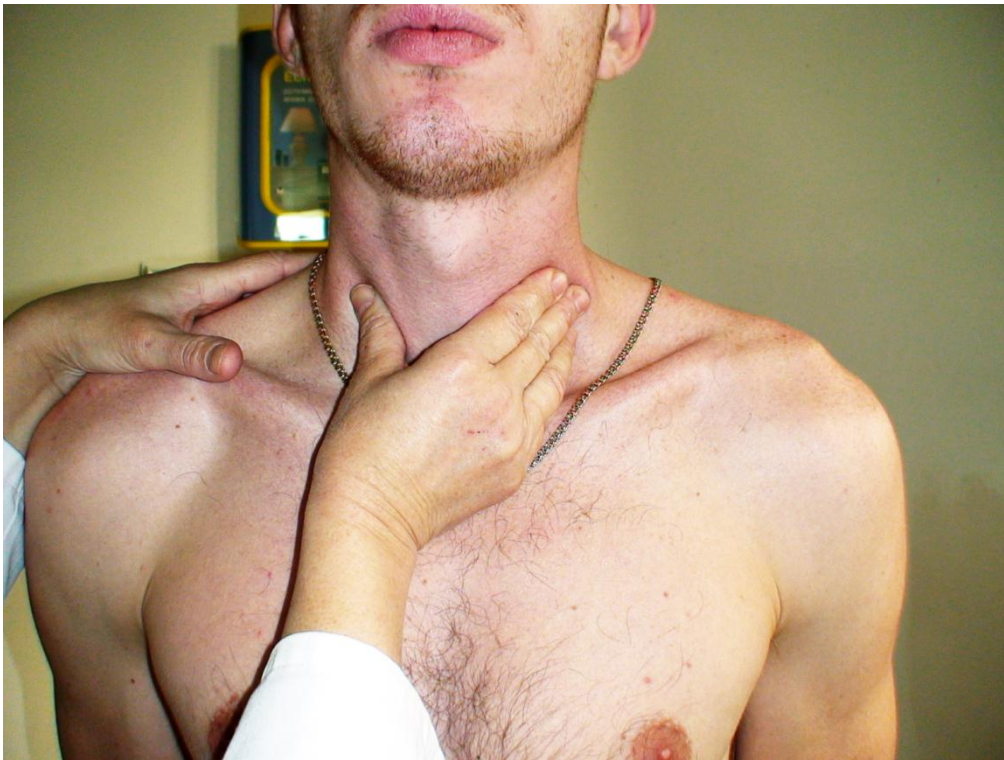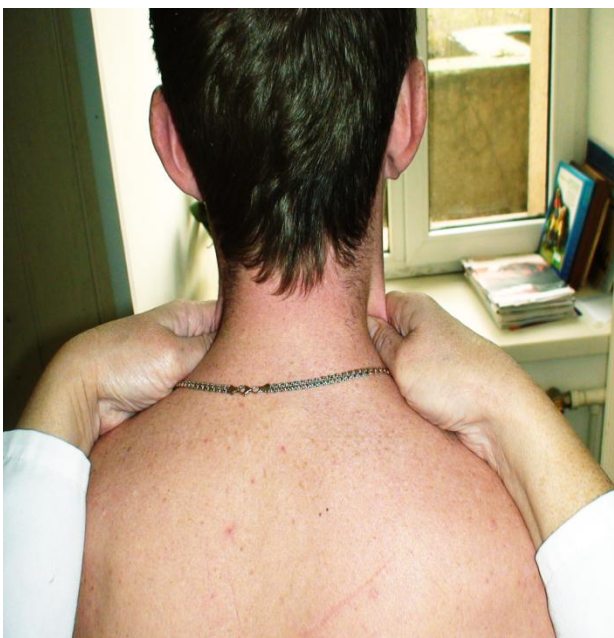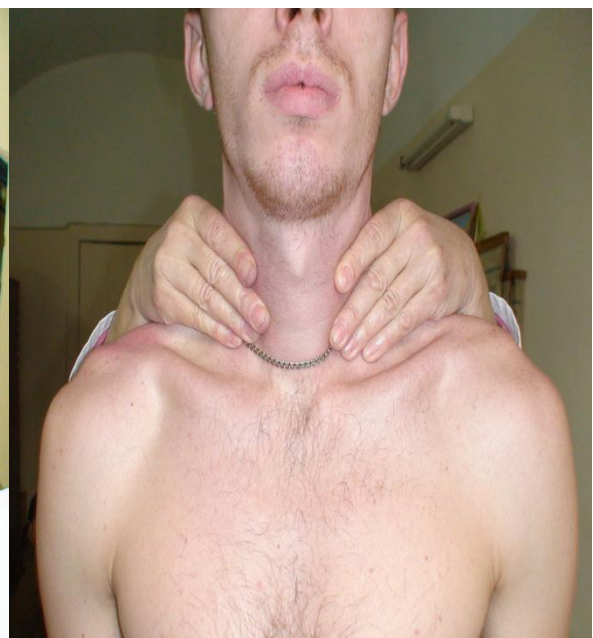


Fig. 8.7. The second method of the thyroid gland palpation

The third method. The doctor is behind the patient. Thumbs are positioned on the back of the neck, and the other fingers – over the area of the thyroid cartilage in the middle of the front edges of the clavisternomastoid muscles (Fig. 8.8,a, b).



a



b

Fig. 8.8. The third method of the thyroid gland palpation (a, b)

Step 3. Palpation of the thyroid isthmus: sliding finger movements across its surface from top to bottom in the direction of the manubrium of sternum.

Dynamic observation of the increased thyroid gland

Step 1. Determine the circumference of the neck. One end of the measuring tape is fixed on the spinous process of the VII cervical vertebra, and in the front the tape is fixed to the most bulging part of the thyroid gland.

Step 2: Measure the transverse size of the anteroexternal surface of the thyroid gland. The measuring tape is fixed behind the external posterior edges of the clavisternomastoid muscles and placed over the front surface of the thyroid gland.

Step 3. Determine the diameter of individual nodes of the thyroid gland by a measuring compass with rounded ends.

Examination and palpation of the external and internal genitals

Examination of genitals, diagnostics of sexual glands diseases is conducted according to the following plan:

Step 1. Determination of degree of development of the external genitals.

In men:

- underdevelopment of the external genitals – hypogonadism;
- enlargement of the external genitals in prepubertal period - premature puberty - pathology of the thyroid gland;
- enlargement of the external genitals in adults – tumours of the adrenal glands - congenital forms of adrenogenital syndrome.

In women:

- hypoplastic external genitalia - ovarian insufficiency;
- small, hypoplastic uterus and ovaries - hipoovaryzm, virilizing syndromes (excessive formation of androgens);
- enlargement of one or two ovaries - Stein-Leventhal syndrome, their invasion by a tumour.

Step 2. Palpation (testicular size, structure, tenderness, surface, condition of appendages and spermducts, presence of varicose veins):

- absence of testicles in the scrotum - cryptorchidism (one or double-sided);

- dense, larger than a pea testicles - eunuchoidism;
- significant reduction of the testicles, atony, lack of sensitivity to palpation – hypoplasia of testicles.

Deep abdominal palpation

It is important in revealing tumors of the adrenal glands, kidneys displaced downwards.

Percussion

Step 1. Identification of retrosternally located goiter – percussion of the sternum. In such cases, shortening of the percussion sound is revealed over the manubrium of sternum.

Step 2. Tapping with a hammer below the area of facial nerve: contraction of the muscles of the angle of the mouth, nose wings is a Chvostek's sign-hypoparathyroidism.

Auscultation of the thyroid gland area

Tones and noises of the thyroid gland - accelerated blood flow and blood supply of the thyroid gland – enlargement of the thyroid cancer.

Part 9

MUSCULOSKELETAL SYSTEM

9.1. PLAN OF EXAMINATION OF THE MUSCULOSKELETAL SYSTEM

1. Examination:

- a) assessment of the symmetry of the body;
- b) determination of the length of a limb and its parts related to the other one;
- c) assessment of changes of the shape and contours of the joints, shape of the bones of extremities;

- d) determining the condition of the muscles of the limbs;
- e) assessment of the condition of the skin in area of the joints.

2. Palpation:

- a) identification of increase in local body temperature;
- b) identification of joint tenderness;
- c) clarifying the nature of the change of the joint shape, presence of exudate in the joint, joint noises, pain points, etc;
- d) lateral compression test;
- d) determination of tone and tenderness of muscles.

3. Measurement:

- a) determination of the length of limbs;
- b) determination of the circumference of limbs and joints.

4. Investigation of the scope and range of motion in joints:

- a) investigation of the amount of active movements;
- b) investigation of the amount of passive movements;
- c) determining the ratio of active and passive movements in the joint.

5. Measurement of muscle strength.

9.2. EXAMINATION OF JOINTS

Examination of joints is conducted to determine the symmetry of the body; length of limbs and parts of limbs related to one another; change in the shape and contours of the joints, shape of the bones of extremities; change of boundaries in the placements of tendons and synovial bags; the condition of the skin in the joint areas.

The examination is usually started with the joints of the upper extremities, and after that it is proceeded with the joints of the lower limbs, the head and the trunk. The joints of the upper extremities are examined in standing or sitting position of the patient, the joints of the lower extremities – in the sitting or lying position.

Step 1. Evaluation of symmetry of the body:

- examining the patient in the standing position attention is paid to symmetry of limbs position related to the shoulder girdle or the pelvis, forearm to the shoulder, hand to the forearm, shin to the thigh, thigh to the shin;
- the position of shoulder girdle, angles of scapula, iliac crests, popliteal and gluteal folds is determined;
- the presence of physiological bends of the spine (2 - in the thoracic and 2 - in the lumbar regions), the presence of pathological distortions (kyphosis, scoliosis) are determined;
- postural disorders are revealed: if there are changes in the lumbar division of the spine, abdomen is bulging, if in the thoracic - inclined posture is observed, flat back is identified if there is no physiological kyphosis in the thoracic and lordosis in the lumbar divisions of the spine; in combination of hyperlordosis of the cervical and kyphosis of the thoracic divisions of the spine a characteristic posture appears - "beggar posture," which is a sign of ankylosing spondylitis.

Step 2. Determination of the length of a limb and parts of the limb related to the other one:

- attention is paid to the length of the limb and its parts related to the other limb, norm is stated, as well as shortenings or lengthenings.

It should be kept in mind that in some cases, more often in acute arthritis, with a significant pain syndrome the patient takes a forced position (position of unloading), with the affected joint is in the state of moderate bending, thus reducing the intraarticular pressure and reducing the severity of pain.

Step 3. Assessment of changes of the shape and contours of the joints, shape of the bones of extremities; changes in contours in the locations of tendons and synovial bags:

- a thorough study of all joints - hands, radiocarpal joint, elbow, shoulder, acromioclavicular joint, sternoclavicular joint, sternocostal articulations, temporomandibular, foot, ankle, knee, hip, cervical, thoracic, lumbar region of the spine, sacroiliac (Be sure to compare damaged joints with symmetric healthy ones);
- study of joint **configuration** changes: increase in joint volume - **swelling** is one of the main features of its damage.

Limited and **diffuse** swellings are distinguished.

A **limited swelling** is characterized by the following symptoms:

- infra-articular exudate;
- thickening and other changes in the soft extraarticular tissues (bursitis, tendonitis);
- change in the shape of bone;
- extraarticular fat thickening (cushions).

Diffuse swelling is characterized by the following symptoms:

- smoothing the contours of the joint, including the disappearance of bony prominence that is often caused by acute arthritis;
- a significant swelling of the synovial membrane or extraarticular soft tissues;
- presence of exudate in the joint cavity.

To characterize changes of the joint shape such terms as joint **defiguration** and **deformation** are used.

Defiguration is smoothing of joint boundaries with increase of its volume, which is associated with an exudative process in the joint or swelling of periarticular tissues, which is manifested with either a uniform joint swelling or irregular changes in its shape due to exudate in the joint bag.

The main causes of defiguration include:

- synovitis with the presence of fluid in the joint;
- swelling of periarticular tissues;
- thickened synovium.

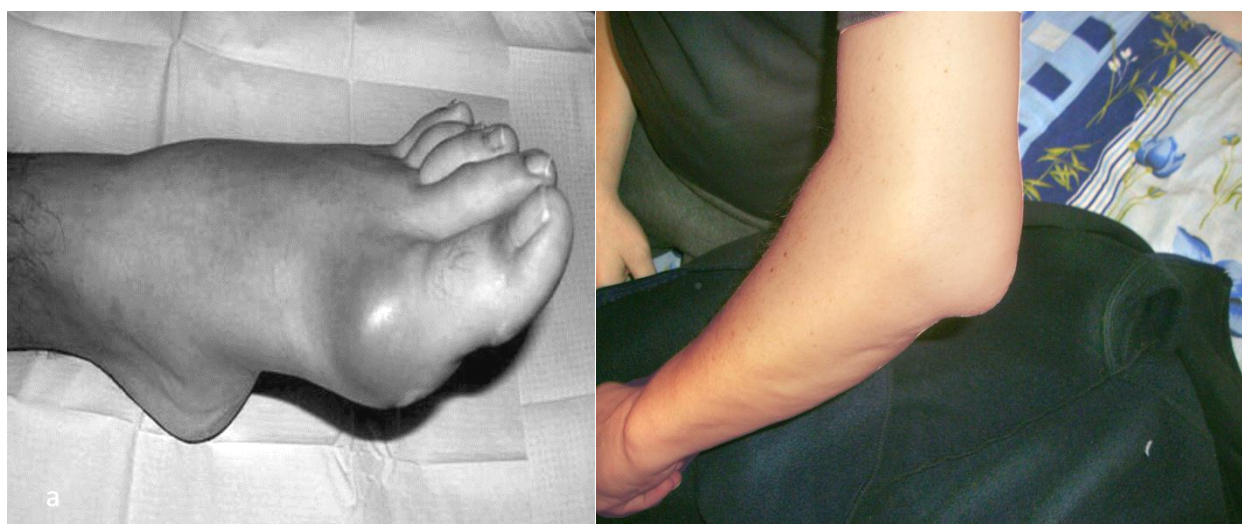Deformation - is uneven enlargement of the joint, which is characterized by severe, persistent changes in the shape. The main causes of deformation of the joint include:

- changes in bone tissue;
- fibrous layers;
- induration of periarticular tissues involving the nearby tendons and development of flexor and extensive contracture and ankyloses.

A pathological process may involve different number of joints with different combinations of features (Fig. 9.1).

Fig. 9.1. The scheme of classification of pathological processes in joints

Number of joints involved into a pathologic process
Monoarthritis – inflammation of a single joint - Acute gouty arthritis (Fig.9.2, a,b), Infectious arthritis, hemarthrosis in hemophilias, traumatic synovitis and others
Oligoarthritis – inflammation of several joints – symmetric, asymmetric - ankylosing spondylitis, Reiter's disease and others
Polyarthritis – inflammation of most joints - symmetric, asymmetric- rheumatoid arthritis (Fig. 9.3) and others



a

b

Fig. 9.2. Gouty arthritis (a, b)

Step 4. Identification of the condition of the muscles of extremities:

- the degree of muscle development is identified.

The early and constant sign of extraarticular rheumatoid arthritis is a progressive muscle atrophy, which spreads not only to paraarticular muscles, but also leads to general depletion. In case of hand damage in rheumatoid arthritis atrophy of interosseal muscles is observed, with the rise of I and V fingers. Most often atrophy of the extensor muscles of the forearm is identified in damage of wrist joints, the front group of thigh muscles (in the case of the knee joint damage).

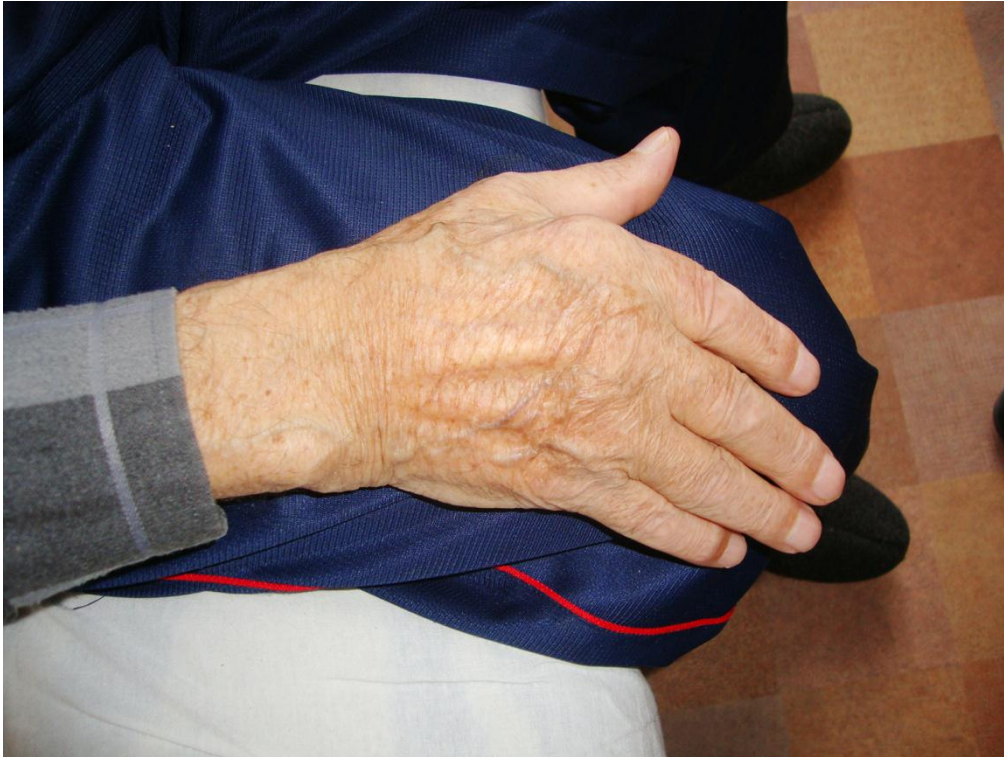

Fig. 9.3. Rheumatoid arthritis

Step 5. Assessment of the skin in the joint areas:

- pay attention to the color of the skin; the presence of nodes, rashes, ulcers, telangiectasias, scars; the condition of subcutaneous veins etc., which allows to predict the development of psoriasis, Reiter's disease, systemic sclerosis, nodular erythema etc. in the patient.
- in joint inflammation discoloration of the skin in the joint area is observed, rheumatoid nodules, tophi can also be detected.

9.3. PALPATION OF JOINTS

The purpose of joint palpation is to identify an increase of local body temperature, to identify the character of changes in the shape of the joint, the presence of joint exudate, joint noises, pain points, tenderness , muscle tone and more.

Palpation is usually carried out in a comfortable position of joints when the muscles are relaxed.

Step 1. Identification of increasing local body temperature:

- the back part of palm is used to determine the temperature of the skin in the joints (increase of local temperature indicates inflammation in the joints).

Step 2. Identification of joint tenderness:

- tenderness is revealed, mainly in the area of joint surface bones, which can be superficial and deep. In acute arthritis the pain is revealed by palpation in all parts of the joint and there is dermahemia over it. Polyarthralgia is a pain in multiple joints with no signs of inflammation in full motion.

Severity of pain on palpation is characterized by Ritchie index according to the scale:

0 - no pain;

1 - the patient notes tenderness on palpation;

2 - the patient responds with a grimace;

3 – the patient takes the hand away or doesn't allow to palpate the joint. In addition, there is myofascial pain distinguished, which is manifested not only with spasms, but also with the presence of strained muscles painful indurations, hardenings and trigger points.

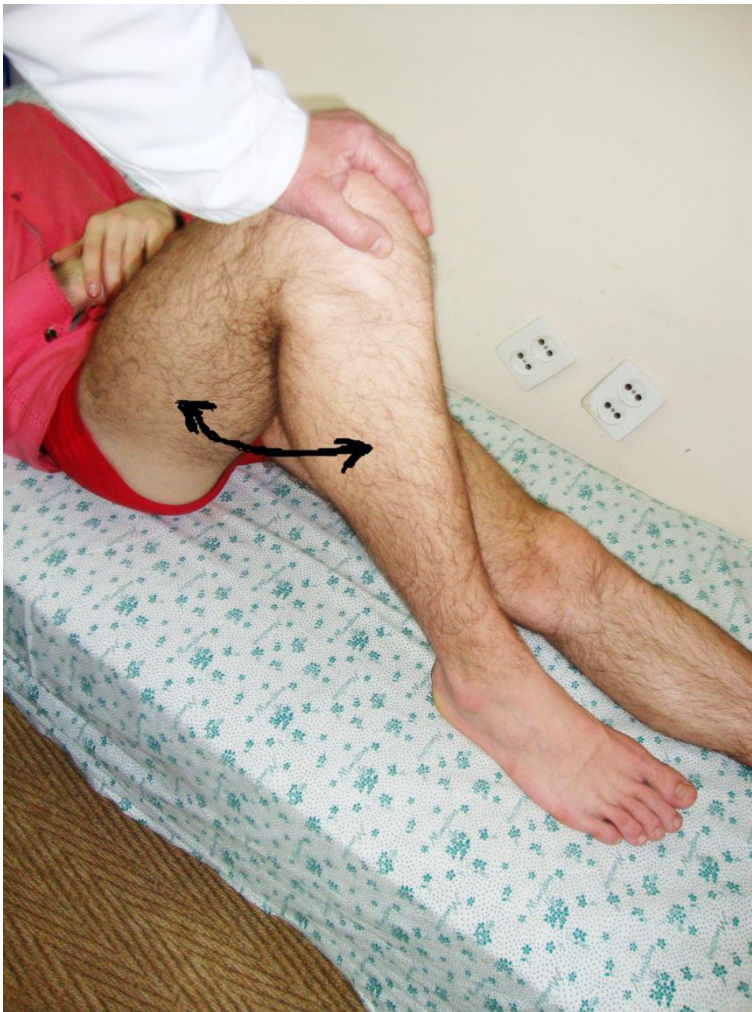

Fig. 9.4. Identification of the character of changes in the shape of the joint, presence of exudate in the joint, joint noises, pain points

Step 3. Identification of the character of changes in the shape of the joint, presence of exudate in the joint, joint noises, pain points:

- the character of the change of the joint shape is identified (it is determined what caused swelling of the joint - effusion in the joint cavity or bony growths; Fig. 9.4);
- palpation reveals fluctuations caused by accumulation of fluid in the cavity, it is often identified in the knee joint, more seldom - in the shoulder, even less - in the wrist and almost never - in the hip;
- articular crepitus is revealed by palpation during movements (full bending and extension of the joints).

Slight crepitus is the evidence of synovial inflammation (synovitis) and severe of the destruction of the articular cartilage.

Step 4. In case of suspected rheumatoid arthritis it is needed to use the test of lateral compression of small hand joints (proximal interphalangeal, carpal phalangeal), feet (metatarsus-phalangeal) and wrist joint (Fig. 9.5).

Step 5. Determination of tone and muscle pain:

- on palpation, muscle tone, the presence of indurations, tenderness are determined (Fig. 9.6 a, b).

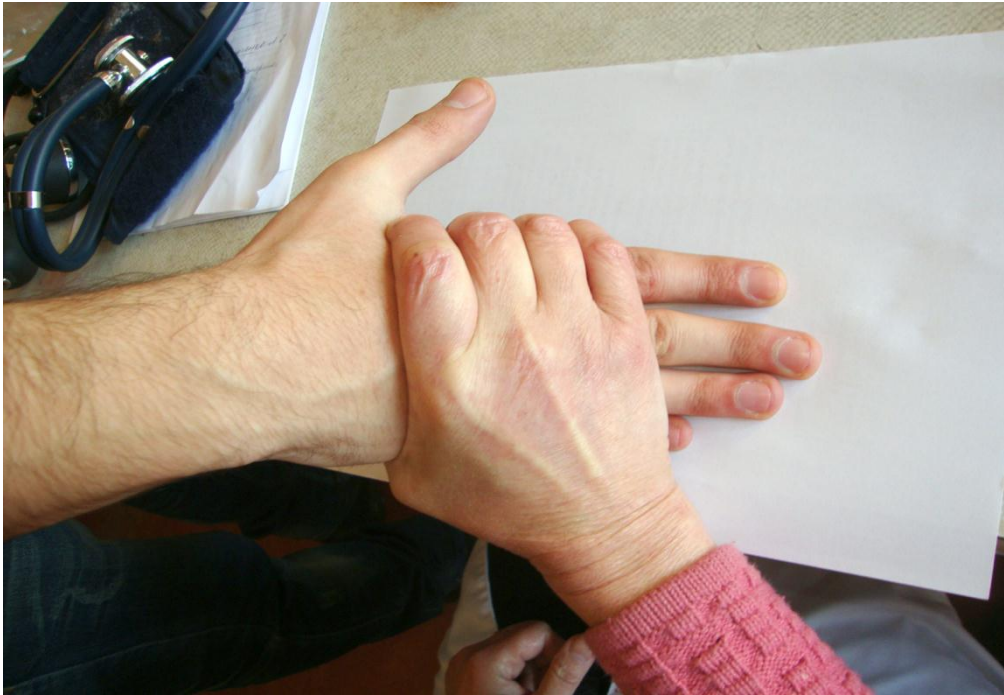
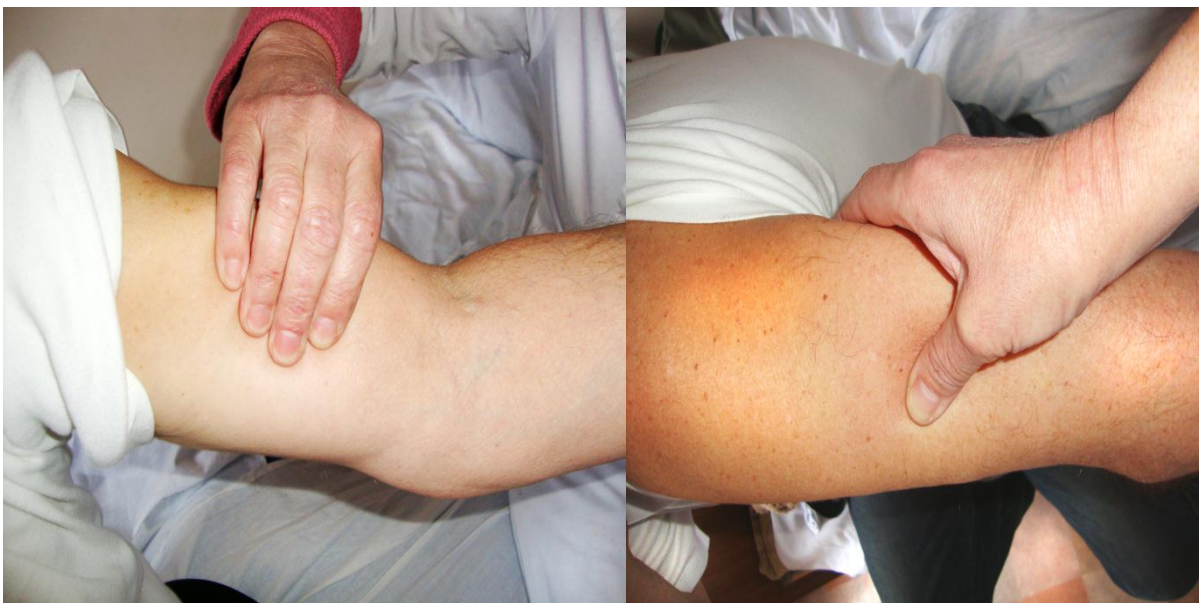
Fig. 9.5. The use of the test of lateral compression



a

b

Fig. 9.6. Identification of the tone and tenderness of muscles (a, b)

Measuring the length of the limbs, joint and limb circumference

Step 1. Determining the length of limbs:

- using a measuring tape the distance between the upper anterior iliac spine and the lateral ankle and also from the navel to the bone lateralis is measured.

It is necessary to distinguish the **functional** and the **real** shortening of a limb. The real shortening of the lower limb is determined on measuring the distance between the upper anterior spine of the iliac bone and the lateral ankle. The functional shortening is more commonly observed in scoliosis, contracture of the thigh joint. This difference is clear when comparing the distance from the navel to the lateral bones.

Step 2. Determining the circumference of limbs and joints, which allows to identify abnormalities, to assess the dynamics of the disease:

- measurement of the circumference is more commonly made at the level of the joint and if necessary at the top, middle and lower thirds of the limb;
- measurement of the hip circumference is conduct at the distance of 10, 15 or 20 cm from the top edge of the kneecap and the shin - 15-20 cm below the kneecap.

Investigation of the volume and range of motion in joints

This investigation determines the extreme limits of active and passive movements in all possible for this joint directions, pathological forms of movements are revealed and also muscle strength is measured.

Step 1. Revealing the volume of active movements:

- active movements in the joints are performed by the patient himself, the measurements are conducted using a goniometer.

Step 2. Revealing the volume of passive movements:

- passive movements of the joints are made by the physician on condition of complete muscle relaxation of the patient (Fig. 9.7).

Step 3. Determining the ratio of active and passive movements in the joint:

- in most cases, in inflammation of the synovial membrane, equal reduction of passive and active movements in the joints can be identified;
- in cases where the amount of passive movements exceeds the amount active movements, an accompanying destruction of periarticular tissues is revealed.

Limitation of joint motion can be **reversible** and **irreversible**.

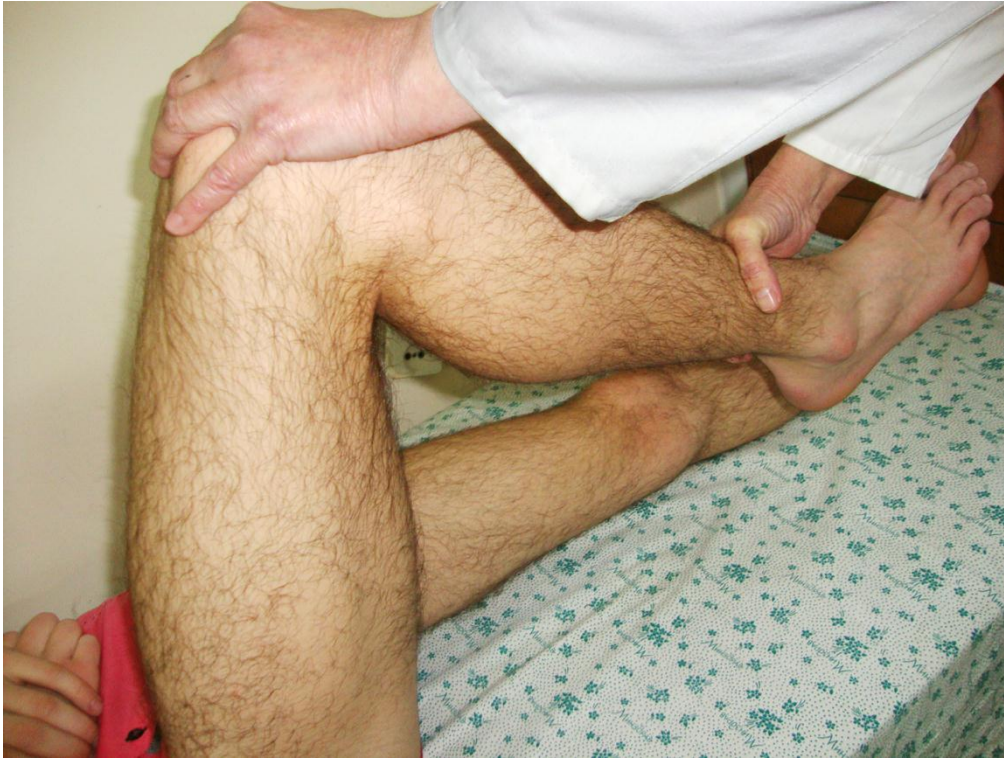

Fig. 9.7. Identification of the volume of passive movements

Reversible limitation is characterized by these symptoms:

- muscle tension;
- intraarticular effusion;
- joint blockade because of the free bodies in the joint.

The development of **irreversible limitation** is influenced by intra-articular reasons (bone ankylosis, the destruction of the articular surfaces) and extra-articular (induration of joint capsule, muscle contracture).

Contracture is a stable fixation of a joint in a certain position.

There are flexor and extensor contractures distinguished. They can be caused by a primary lesion of the musculoskeletal system (in rheumatoid arthritis - flexor contracture), diseases of the nervous system and muscles.

Ankylosis is lack of movement in the joint. There is fibrous ankylosis when the joint space is filled with fibrous tissue (psoriatic arthritis), and bone - at which the joint ends are connected by trabeculae of bone (rheumatoid arthritis).

Stiffness in the joints - functional disorder due to limitation of the amplitude and speed of movement.

Subluxation - shift within the joint capsule of bone heads surfaces that form the joint, due to destruction of the cartilage.

Step 4. Measurements of muscle strength:

- the patient is asked to do a particular movement with maximum muscle tension and the doctor offers resistance and thus can estimate the muscle strength;
- muscle strength can be determined also with the help of dynamometer.

Examination of joints allows to evaluate their functional ability and degree of its damage: 1 - vital manipulations are performed without difficulty; 2 - with difficulty; 3 – assistance is required.

Example of recording of the results of joint examination in medical history of a patient with rheumatoid arthritis:

Deformation and defiguration of the wrist, II-III metacarpal phalangeal and proximal interphalangeal joints of both hands, interosseous muscle atrophy, skin redness over these joints.

Example of recording of the results of joint palpation in medical history of a patient with rheumatoid arthritis:

The local skin temperature over the wrist, II-III metacarpal phalangeal and proximal interphalangeal joints of both hands is elevated, active and passive movements are accompanied with pain, light crepitation; the test of lateral compression of small joints of hands (proximal interphalangeal, metacarpal phalangeal) is positive.

LITERATURE

1. V.H. Vasilenko Propaedeutics of Internal Diseases: Textbook / V.H. Vasilenko, A.L.Ghrebnev. - 5th ed., Rev. and add. -M. : Medicine, 2001. – 592pp.
2. A.L. Ghrebnev Propaedeutics of Internal Diseases: Textbook / A.L.Ghrebnev.. - 5th ed., Rev. and add. - Moscow: Medicine, 2001. - 592 pp.
3. Propaedeutics of internal Diseases: a textbook for students / Y.I. Detsyk, E.M. Neiko, L.A. Pyrig [et al.]. - K.: Health, 2000. - 504 pp.
4. Practical Skills in Rheumatology: training aid / V.M. Kovalenko, N.M .Shuba, V.K. Kazymirko [et al.]. - C.: MORION, 2008. - 256 pp.
5. N.A. Mukhin . Propaedeutics of Internal Diseases: Textbook for Universities / N.A. Mukhin, V.S. Moiseev. - Moscow: HZOTAR-Media, 2005. - 768 pp.
6. V.Z. Netyazhenko Classification of Internal Medicine. Diagnostic methods and treatment algorithms / V.Z. Netyazhenko. - 2nd ed., Ext. - K: ALIU, 2005. - Part 1. Cardiology. Rheumatology. -404 pp.
7. V.G.Perederiy Principles of Internal Medicine: a textbook for students of medical universities / V.G .Perederiy, S.M. Tkach. - K., 2009. - Vol. 1. - 604 pp.
8. V.G.Perederiy Principles of Internal Medicine: a textbook for students of medical universities / V.G. Perederiy, S.M. Tkach. - K., 2009. - Vol. 2. - 784 pp.
9. V.G. Perederiy Principles of Internal Medicine: a textbook for students of medical universities / V.G. Perederiy, S.M. Tkach. - K., 2010. - Vol. 3. - 1006 pp.
10. Principles of Semiotics of Internal Diseases. Atlas / A.V. Strutshskyy, A.P. Baranov, G.E. Roitberg, Y.P.Haponenkov. - Moscow: MEDpress-inform, 2011. - 224 pp.

CONTENTS

Foreword

Part 1. GENERAL EXAMINATION OF THE PATIENT

Part 2. RESPIRATORY ORGANS

2.2 . Plan of objective examination of the respiratory organs

2.3. Chest examination

2.3. Chest palpation

2.4. Percussion of the lungs

2.5. Auscultation of the lungs

Part 3. THE CARDIOVASCULAR SYSTEM

3.1. Plan of objective examination of the cardiovascular system

3.2. Examination of the pericardiac area and the neck

3.3. Palpation of the pericardiac area and the neck

3.4. Percussion of the borders of the heart and vascular bundle

3.5. Auscultation of the heart and blood vessels

3.6. Palpation of the pulse

3.7. Measurement of the arterial pressure

Part 4. DIGESTIVE ORGANS

4.1. Plan of objective study of the digestive organs

4.2. Examination of the abdomen

4.3. Palpation of the abdomen

4.4. Percussion of the abdomen

4.5. Auscultation of the abdomen

4.6. Identification of free fluid in the abdominal cavity

Part 5. EXAMINATION OF THE LIVER

5.1. Plan of liver examination

5.2. Examination of the patient with diseases of the liver and bile ducts

5.3. Percussion of the liver borders after M.G. Kruglov

5.4. Palpation of the liver

Part 6. URINARY SYSTEM

6.1. Plan of examination of the urinary system

6.2. Examination of a patient with pathology of the urinary system

6.3. Palpation of the kidneys and the urinary bladder

6.4. Percussion of the kidneys and the urinary bladder

Part 7. CIRCULATORY SYSTEM

7.1. Plan of the circulatory system investigation

7.2. Examination of the circulatory system organs

7.3. Palpation of lymph nodes

7.4. Palpation of the spleen

7.5. Percussion of the spleen according to V.P. Obraztsov and M.D. Strazhesko method

7.6. Percussion of bones

Part 8. ORGANS OF THE ENDOCRINE SYSTEM AND METABOLISM

8.1. Plan of investigation of the organs of the endocrine system and metabolism

8.2. Examination of a patient with pathology of the endocrine system

8.3. Palpation of the neck

Part 9. MUSCULOSKELETAL SYSTEM

9.1. Plan of examination of the musculoskeletal system

9.2. Examination of joints

9.3. Palpation of joints

LITERATURE

Methods of objective examination of a patient in the clinic of internal diseases: teaching aid/A.A. Yakymenko, O.E. Kravchuk, V.V. Klochko [and others]; edited by A.A. Yakymenko. – Odessa; ONMedU, 2014. – (Library of a medical student).

ISBN 978-966-443-070-5

The teaching aid consists of nine parts, each dedicated to investigation of a separate organ system. It contains the main methods of objective examination of a patient (examination, palpation, percussion and auscultation).

For students of the medical and dental faculties of medical universities, interns and general practitioners.

