

Jean-Louis Dulucq

# Tips and Techniques in Laparoscopic Surgery



---

Jean-Louis Dulucq  
Tips and Techniques in Laparoscopic Surgery

---

Jean-Louis Dulucq

# **Tips and Techniques in Laparoscopic Surgery**

In Collaboration with Pascal Wintringer

Foreword by Jacques Périssat

With 281 Colored Figures

 Springer

---

Dr. Jean-Louis Dulucq  
Institut de Chirurgie Laparoscopique  
Hôpital Bagatelle MSPB  
203 Route de Toulouse  
33401 Bordeaux Talence, France

*Collaborator:*

Dr. Pascal Wintringer  
Institut de Chirurgie Laparoscopique  
Hôpital Bagatelle MSPB  
203 Route de Toulouse  
33401 Bordeaux Talence, France

---

*Title of the original French edition:*

Techniques et astuces en chirurgie laparoscopique  
© Springer-Verlag France, Paris, 2003  
ISBN 2-287-59749

---

Library of Congress Control Number: 2004104705

ISBN 3-540-20902-6 Springer Berlin Heidelberg New York

This work is subject to copyright. All rights are reserved, whether the whole or part of the material is concerned, specifically the rights of translation, reprinting, reuse of illustrations, recitation, broadcasting, reproduction on microfilm or in any other way, and storage in data banks. Duplication of this publication or parts thereof is permitted only under the provision of the German Copyright Law of September 9, 1965, in its current version, and permission for use must always be obtained from Springer-Verlag. Violations are liable for prosecution under the German Copyright Law.

Springer is a part of Springer Science+Business Media  
springeronline.com

© Springer-Verlag Berlin Heidelberg 2005  
Printed in Germany

The use of designations, trademarks, etc. in this publication does not imply, even in the absence of a specific statement, that such names are exempt from the relevant protective laws and regulations and therefore free for general use.

Product liability: The publisher can not guarantee the accuracy of any information about dosage and application contained in this book. In every individual case the user must check such information by consulting the relevant literature.

Editor: Gabriele Schröder, Heidelberg, Germany  
Desk editor: Stephanie Benko, Heidelberg, Germany  
Production editor: Ingrid Haas, Heidelberg, Germany

Cover-Design: Frido Steinen-Broo, Pau, Spain  
Typesetting: Fotosatz-Service Köhler GmbH, Würzburg, Germany  
Printing: Druckhaus Mitte, Berlin, Germany  
Bookbinding: Stein & Lehmann, Berlin, Germany

Printed on acid-free paper. 24/3150 ih - 5 4 3 2 1 0



---

## Foreword

Performing a surgical operation could be compared to navigating inside the human body. Two essential requirements are necessary for a successful apprenticeship:

- A perfect understanding of the roadmap, the anatomy
- Regular training with expert surgeon teachers showing strategies, tactics, manoeuvres, and gestures to make the journey safe, efficient and fast

For decades this was the way taken by apprentice-surgeons and also by surgeons already in practice concerned about updating their knowledge. For years their only travelling companions were books, drawings, and pictures. However, printed medium cannot satisfactorily and properly reproduce the movements of a manoeuvring surgeon. In open surgery, only the two first assistants can precisely capture by direct vision what is happening in the depth of the operating field. Therefore, the duration of apprenticeship is long and restricted to a small number of people per teacher. The introduction of movie cameras into the operating rooms improved the quality of surgical education. But filming in open surgery is not so easy. The cameraperson has to be well trained to catch good takes in the depth of a pit between the heads, shoulders, and fingers of the surgeon and assistants. Most of the time, those constraints disturb the operator's manoeuvres, altering their pedagogical value.

With the introduction of laparoscopic surgery (LS), using a video camera providing images in real time on a television screen, everything changed. Now, the surgeon can use the image to perform his operation. With images being the operating field, there are no longer any constraints due to movie taking. LS is a real revolution in the concept of surgical education; however, the two fundamental, above-mentioned requirements are persisting:

- A perfect knowledge of anatomy must be reinforced. The magnification due to the laparoscope permits a better determination of the planes of soft tissue between the organs.

It is mandatory to follow those planes precisely to avoid the opening of dozens of micro bleeders which alter the light and could oblige to convert in open surgery.

- Regular training with experts becomes of much easier access and involves a larger number of participants. They share the same vision of the operating fields with the surgeon and his assistants. The teacher can demonstrate perfectly his progression, having permanent audiovisual contact with the audience to provide additional explanations on demand. Such live, interactive demonstrations can be broadcast all around the world. The recording is easy, allowing the storage of plenty of documents that can be used to set up libraries of video tapes, CD-R, etc. This audiovisual aid is now the principal companion of the surgeon travelling the path of LS learning.

Dr. J.L. Dulucq understood that issue very quickly. He is among the ten surgeons in the world who opened the gates of LS in 1988–1989. He was immediately a terrific operator and he is still riding on the front wave of the developers of that surgery. He created as far back as 1993 an institute for the teaching and development of LS concerning the treatment of digestive, endocrine, and vascular disorders. This institute, named I.L.S., is now known worldwide and recognized as a centre of excellence in LS teaching. In addition to regular courses held at the institute, I.L.S. is connected by a satellite transmission system to similar centres in Europe and abroad. The I.L.S. library is easily accessible via Internet and maintains permanent contact with both current and former trainees. Having been part of the development of the centre, I thought that combining all those modern media could replace the traditional printed material. But with the course of time, I have changed my mind and encouraged J.L. Dulucq to write a book summarizing the best of his teaching.

And here is that book: seventeen different procedures concerning the cure of digestive, adrenal gland, groin hernia disorders presented in 280 pages in an original way. The style is sober and precise, as surgical manoeuvres have to be. The writing outlines only the main points. Opposite the text, excellent designs and intraoperative pictures are displayed as immediate illustrations. The whole presentation is as close as possible to recreating the atmosphere of a surgeon in action.

This book gathers the best-of innovations and tricks of J.L. Dulucq. Because of the large range of described procedures,

from appendectomy to colorectal surgery, the book will be useful to beginners as well as more expert surgeons. Although the book does not strive to be sufficient to train a complete laparoscopic surgeon, it is the best key to open the door of a training centre and to guide the steps of the learner.

Have a look at the book by visiting the show-case of I.L.S. on the Internet at [www.e-laparoscopy.com](http://www.e-laparoscopy.com). And be prepared to welcome a brother book on other advanced techniques on oesophageal, gastric, liver, and pancreas LS.

This book honours “l’Ecole Bordelaise” of laparoscopic surgery, which was so instrumental in the launching of LS during the former decade.

Jacques Périssat, M.D., F.A.C.S.

Professor of Surgery, Victor Segalen University, Bordeaux, France

President, IFSES

(International Federation of Societies of Endoscopic Surgery)

---

## Preface

The purpose of this work is a descriptive demonstration of laparoscopic techniques approached in a very practical way. Every intervention, summarized in six stages, is carefully illustrated with an operating cliché and a plan that shows the progress of the phases of the intervention.

The 17 operating chapters presented in this work represent the basic knowledge of every laparoscopic surgeon. This work is intended to be a handbook companion for every surgeon interested in this surgical domain. A special chapter is dedicated to the analysis of knowledge of the last 6 years in laparoscopic surgery. Overall, the book offers an account of more than 10 years of experience in laparoscopic surgery. I hope this book of surgical techniques will be a useful handbook for the novice surgeon and a reference for the confirmed surgeon.

I would really like to thank the team of the Institute of Laparoscopic Surgery of Bordeaux, Pascal Wintringer and Jacques Pérrisat, who enabled me during these many years to develop a practical education in the service of our fellow surgeons. I also would like to thank the surgeons who have participated in the training program at the Institute of Laparoscopic Surgery of Bordeaux. These surgeons, who come from all corners of the world, have contributed to the dynamics of our education and to the realization of this book of surgical techniques.

An identical work in advanced laparoscopic surgery will be published soon.

I hope this book is able to meet the expectations of laparoscopic surgeons. Good reading.

Jean Louis Dulucq, M.D.

---

# Contents

<b>Part 1 • Upper Gastrointestinal Tract Procedures . . . .</b>	<b>1</b>
1 Laparoscopic Cholecystectomy . . . . .	3
2 Laparoscopic Common Bile Duct Surgery. . . . .	23
3 Laparoscopic Fundoplication for GERD: Laparoscopic Nissen and Toupet Fundoplication . .	41
4 Laparoscopic Gastric Banding for Morbid Obesity . .	57
5 Laparoscopic Heller Esophagomyotomy for Achalasia . . . . .	77
6 Laparoscopic Splenectomy . . . . .	91
<b>Part 2 • Colorectal Procedures . . . . .</b>	<b>101</b>
7 Laparoscopic Appendectomy . . . . .	103
8 Laparoscopic Left Colectomy . . . . .	119
9 Laparoscopic Right Colectomy . . . . .	137
10 Laparoscopic Total Colectomy . . . . .	149
11 Laparoscopic Rectopexy for Rectal Prolapse . . . . .	153
<b>Part 3 • Inguinal Hernia and Retroperitoneal Procedures . . . . .</b>	<b>169</b>
12 Totally Extraperitoneal Approach (TEPA) for Laparoscopic Hernia Repair. . . . .	171
13 Laparoscopic Right Adrenalectomy . . . . .	189
14 Laparoscopic Left Adrenalectomy . . . . .	203
<b>Part 4 • Procedures for Pelvic Floor Disorders . . . . .</b>	<b>207</b>
15 Laparoscopic Posterior Colpopexy . . . . .	209
16 Laparoscopic Anterior Colpopexy . . . . .	221
17 Laparoscopic Burch Colposuspension . . . . .	233
Subject Index . . . . .	243

---

## Abbreviations

CBD Common bile duct

ERCP Endoscopic retrograde cholangiopancreatography

GERD Gastro-esophageal reflux disease

LAGB Laparoscopic adjustable gastric banding

OR Operating room

TEPA Totally extra-peritoneal approach

**PART 1**

**Upper Gastrointestinal Tract Procedures**

- 1 Laparoscopic Cholecystectomy 3
- 2 Laparoscopic Common Bile Duct Surgery 23
- 3 Laparoscopic Fundoplication for GERD:  
Laparoscopic Nissen and Toupet Fundoplication 41
- 4 Laparoscopic Gastric Banding for Morbid Obesity 57
- 5 Laparoscopic Heller Esophagomyotomy  
for Achalasia 77
- 6 Laparoscopic Splenectomy 91

---

# 1 Laparoscopic Cholecystectomy

## 1.1 Operating Room Setup: Position of the Patient

The patient is placed supine in the reverse Trendelenburg position. Lateral rotation to the left can be useful.

The surgeon stands between the patient's legs, his first assistant is on the patient's right side, the second assistant can be placed on the patient's left side (► Fig. 1.1).

Non-woven, self adhesive drapes are used. Instrument bags are very useful. The monitor is placed at the patient's head, slightly on the left side.

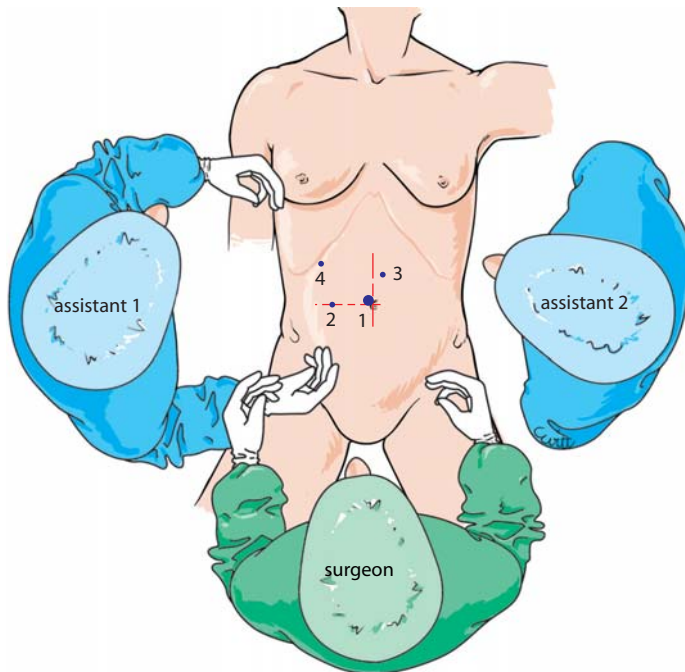


Fig. 1.1. OR setup – trocar position



## 1.2 Recommended Instruments

- Two 10-mm trocars
- Three 5-mm trocars
- A 0° endoscope
- Two non-traumatic grasping forceps
- A pair of coagulating 5-mm shears, straight or curved
- A strong 5-mm grasping forceps
- A 5-mm suction and irrigation cannula
- A 5-mm clip applicator
- A specimen retrieval bag
- A 5-mm needle holder

## 1.3 Pneumoperitoneum and Insertion of the Trocars: Exposure and Exploration of the Abdominal Cavity

Pneumoperitoneum is created with a Veress needle. The first 10-mm port is inserted at the superior margin of the umbilicus with a slightly oblique route to prevent subsequent incisional hernias.

Five-millimeter trocars are introduced under direct vision. One trocar is placed between the umbilicus and the xiphoid process slightly to the left, one right subcostal, and one in the right upper quadrant, slightly above the umbilicus (➤ Fig. 1.1). At this stage, the peritoneal cavity is thoroughly explored with the endoscope. The small bowel is mobilized. The left lobe of the liver is lifted to expose the gallbladder. The importance of inflammatory adhesions is assessed (⊙ Fig. 1.2). The gallbladder is grasped with a non-traumatic forceps. The coagulating scissors are introduced in the midline port to start the dissection. All dissection is made in close contact to the gallbladder wall. In a very inflammatory situation, dissection is performed with the suction cannula and with the coagulating scissors alternatively.

## 1.4 Exposure of Calot's Triangle and Dissection of the Cystic Duct

A lateral traction is exerted on the gallbladder exposing Calot's triangle. Peritoneum is incised close to the gallbladder neck by gentle dissection of peritoneal elements. The cystic duct is identified, freed with a dissector for 1 cm and closed proximally with a clip (➤ Figs. 1.3–1.5).

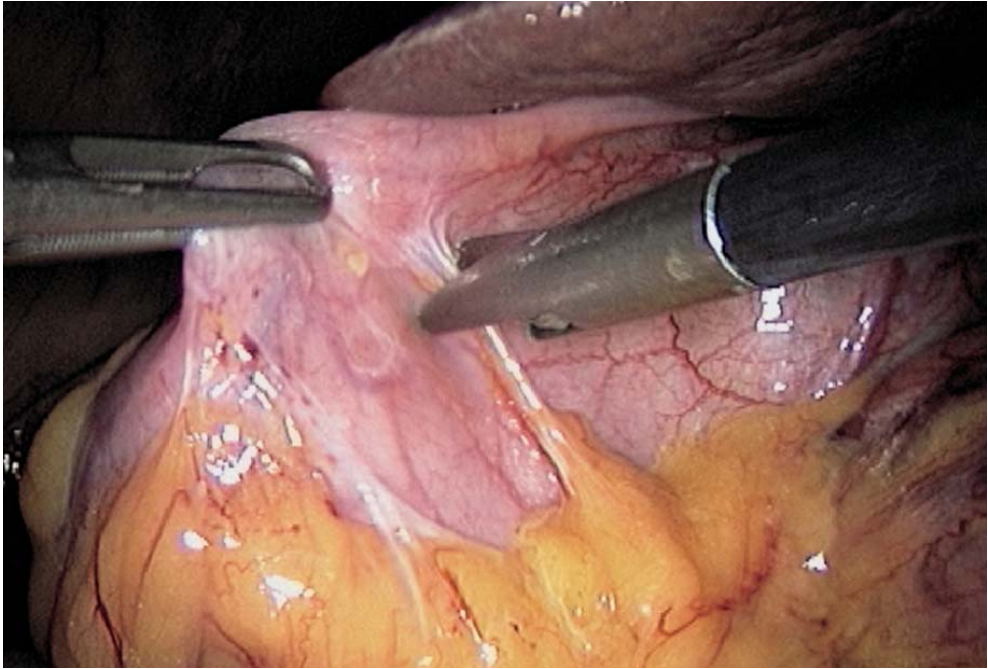


Fig. 1.2. Freeing omental adhesions

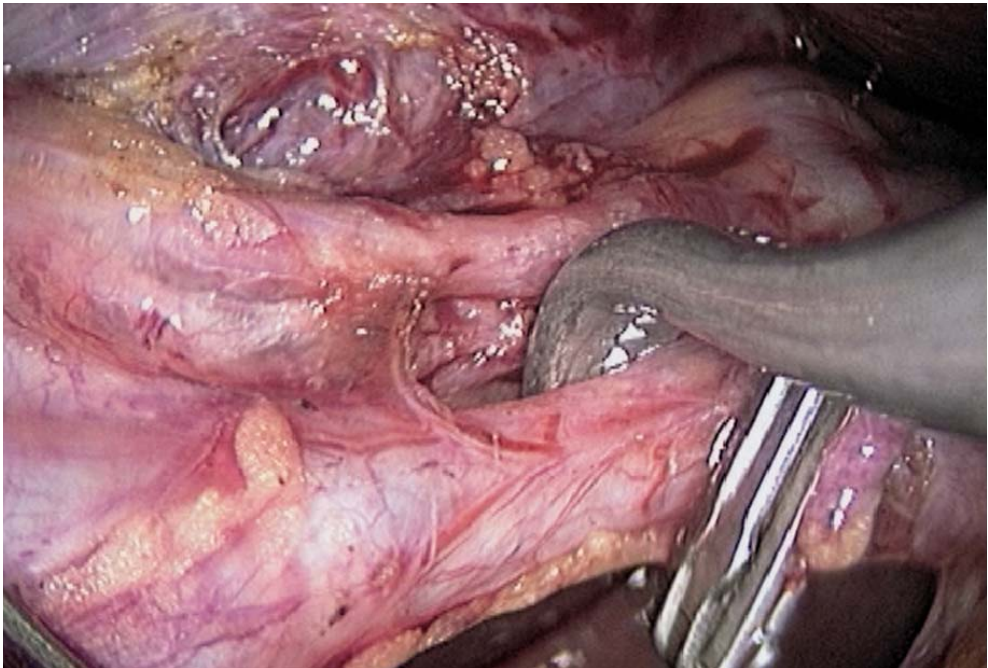


Fig. 1.3. Dissection of cystic duct

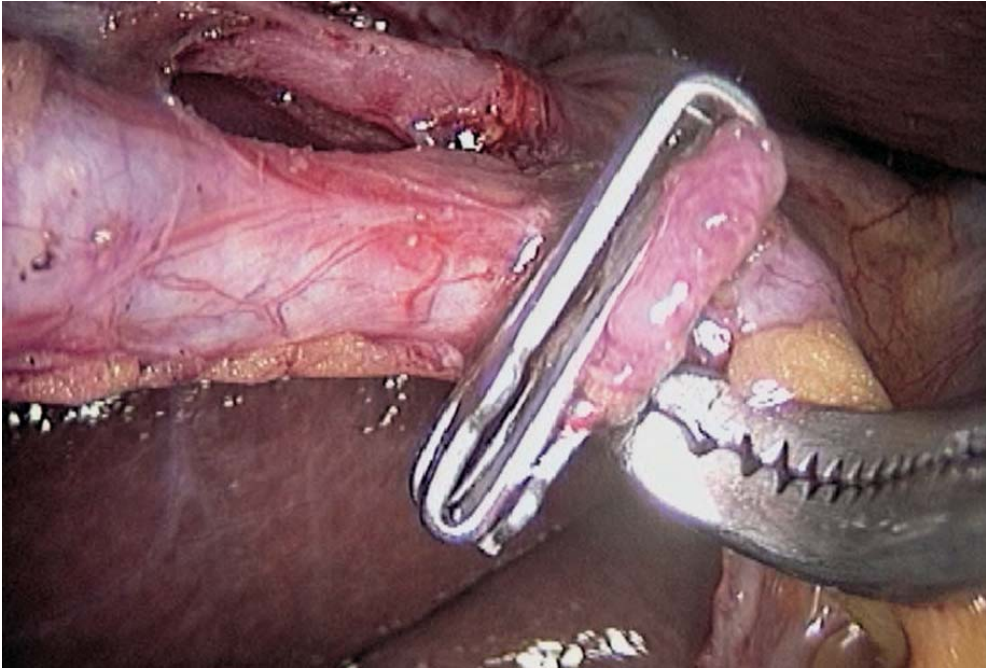


Fig. 1.4. Dissection of cystic duct completed

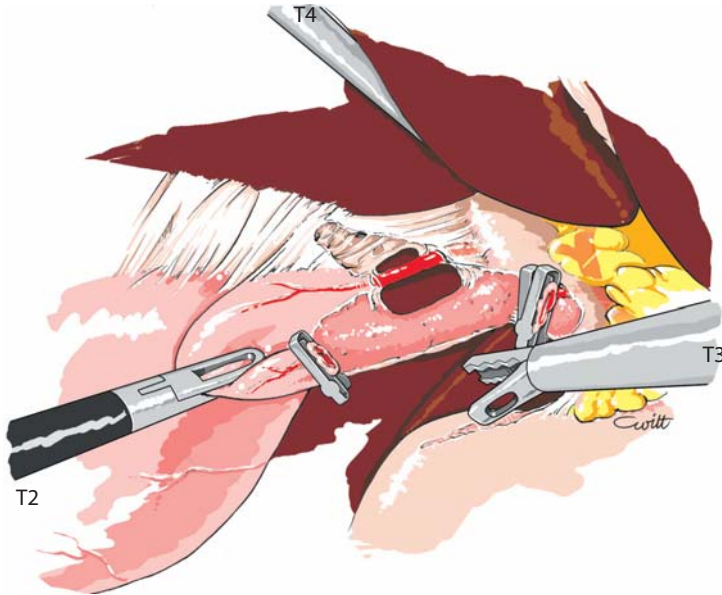


Fig. 1.5. Dissection of cystic duct completed

## 1.5 Intra-operative Cholangiography

The cystic duct is incised with scissors close to the clip (▶ Fig. 1.6). A cholangiography catheter is inserted into the cystic duct and held in place with a grasping forceps (▶ Fig. 1.7).

A radioscopic contrast cholangiography is performed. If the cholangiography is considered normal, the cholangiography catheter is removed and the cystic duct is closed with a clip. The cystic duct is transected, leaving a long enough stomp (▶ Fig. 1.8).

Alternatively, cholangiography can be replaced by laparoscopic ultrasound, but is more difficult and less sensible in this indication (▶ Figs. 1.9, 1.10).

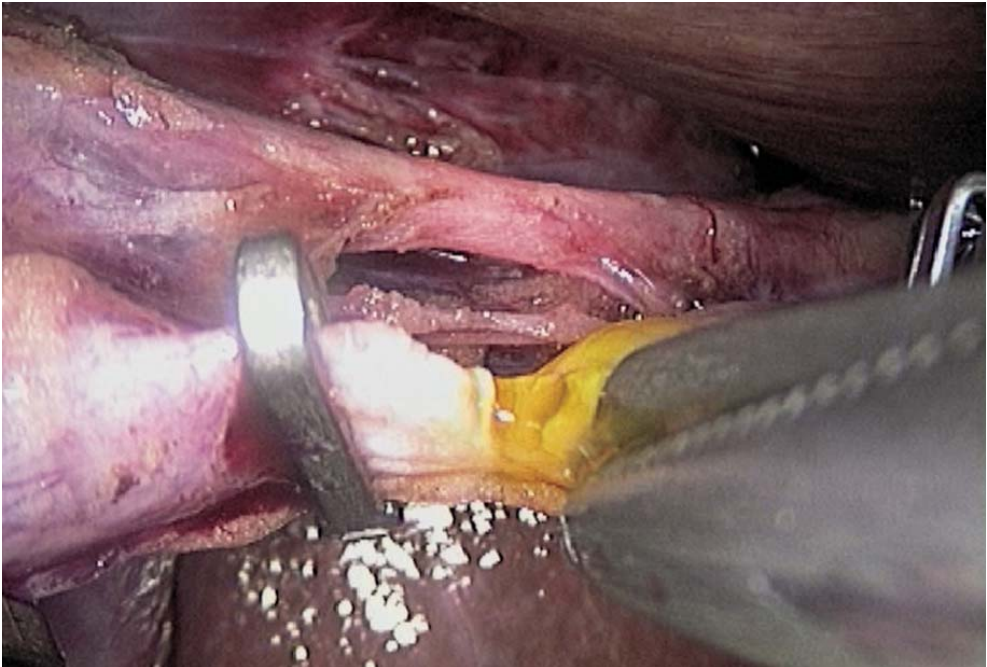


Fig. 1.6. Incision of cystic duct



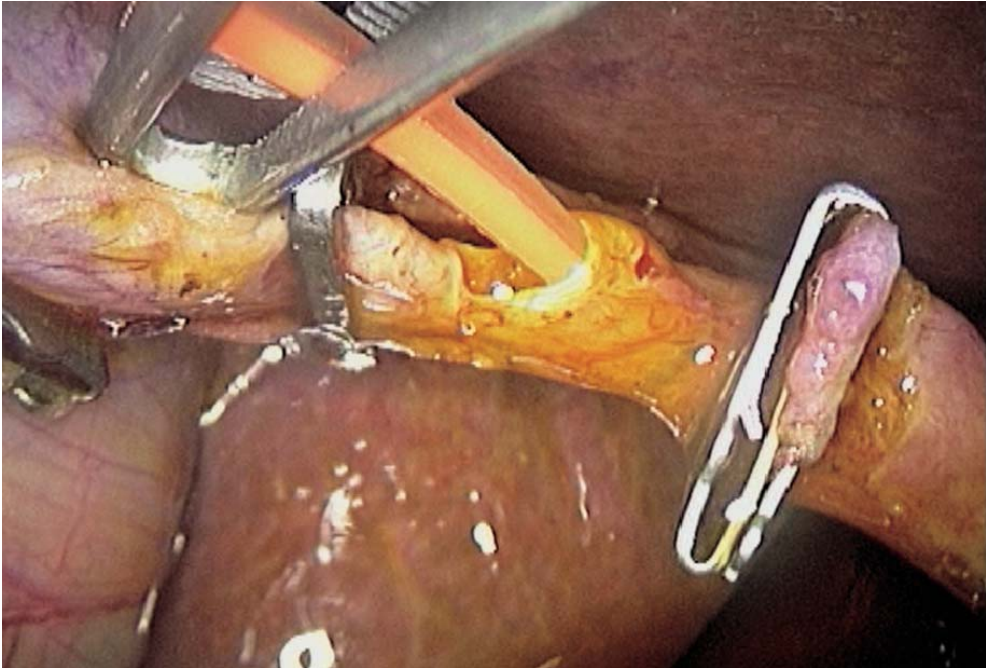


Fig. 1.7. Cholangiography

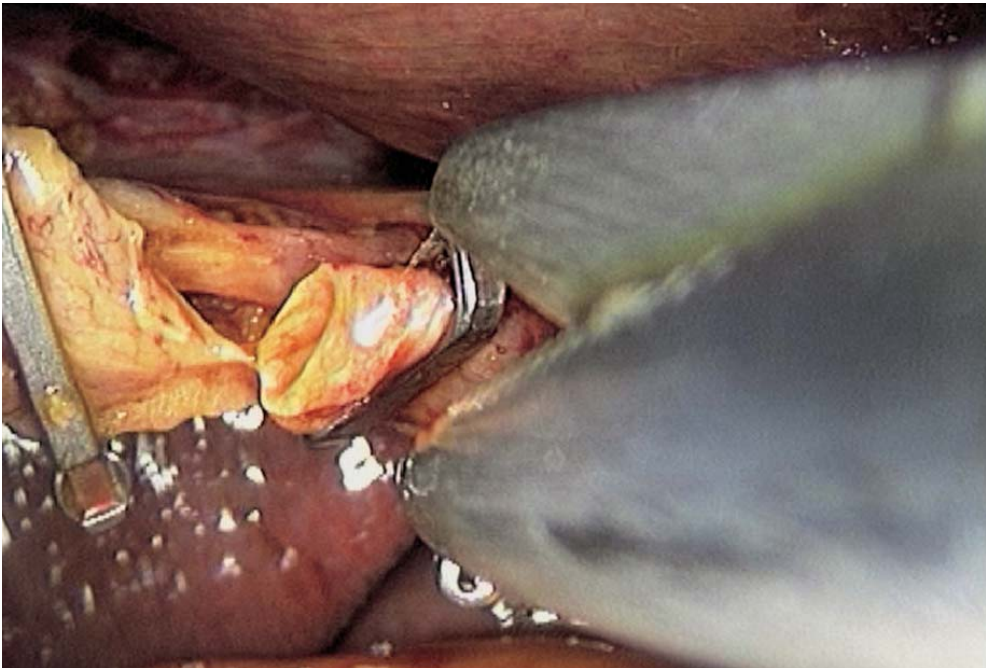


Fig. 1.8. Transection of cystic duct

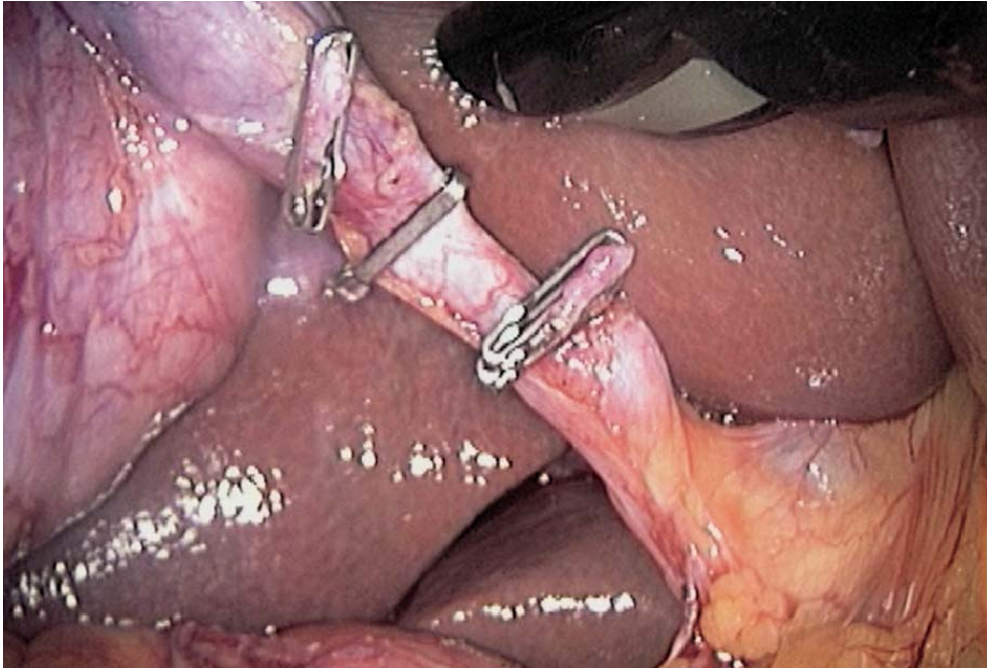


Fig. 1.9. Laparoscopic ultrasound probe

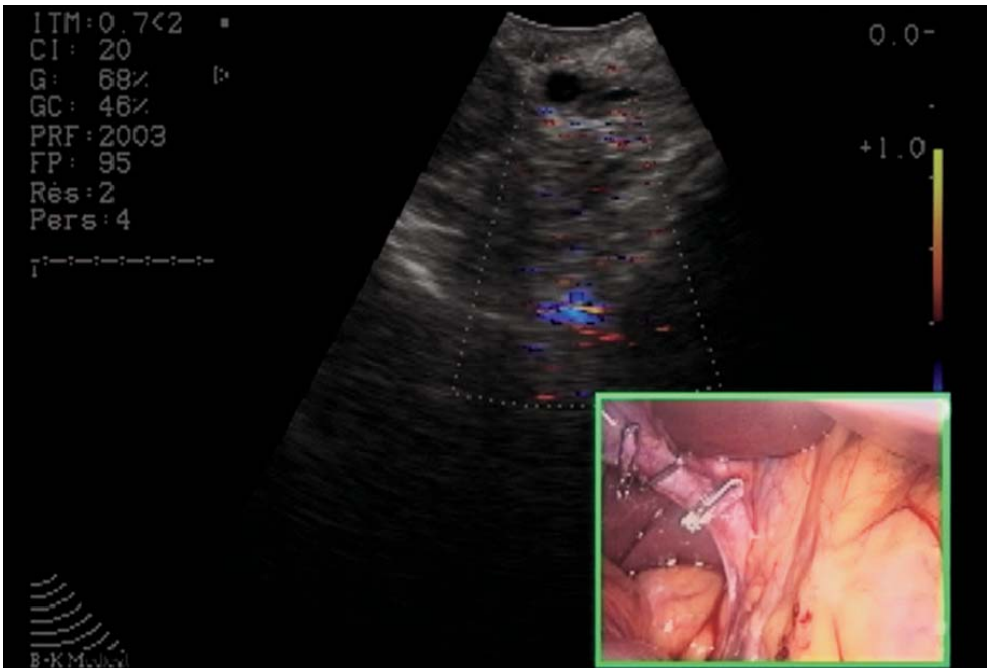


Fig. 1.10. Laparoscopic ultrasound

## 1.6 Vascular Control

Dissection of Calot's triangle is carried on, and the cystic artery is usually found easily. The liver retractor is repositioned. The cystic artery or several branches are individualized, far enough from the right hepatic artery. One or two clips are used to control the artery and one clip is placed distally. The artery is then sectioned between the clips and retrograde cholecystectomy is the further step (▶ Figs. 1.11–1.13).

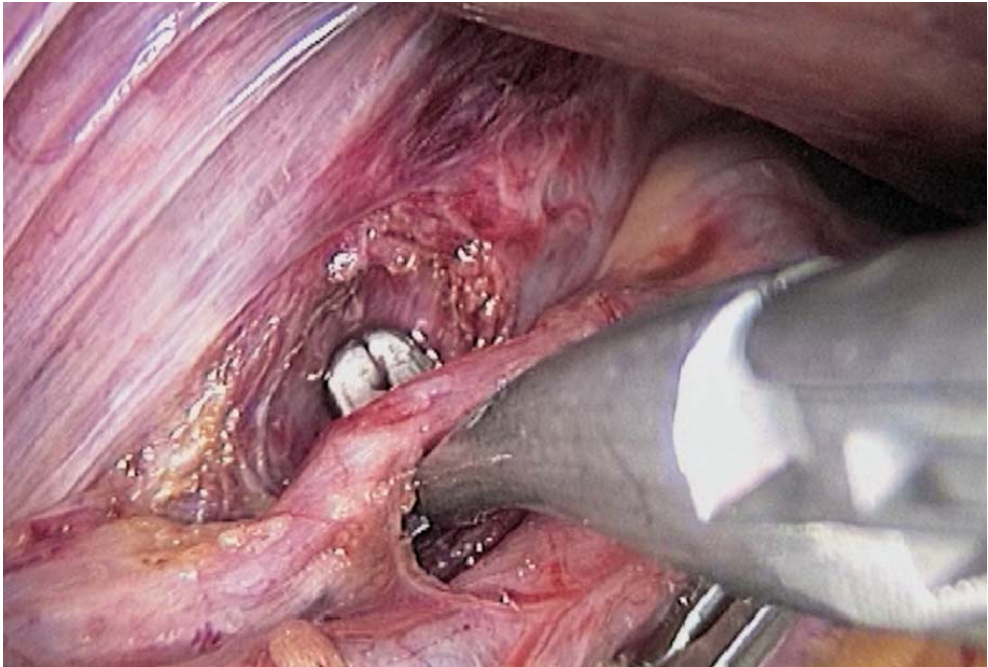


Fig. 1.11. Dissection of cystic artery



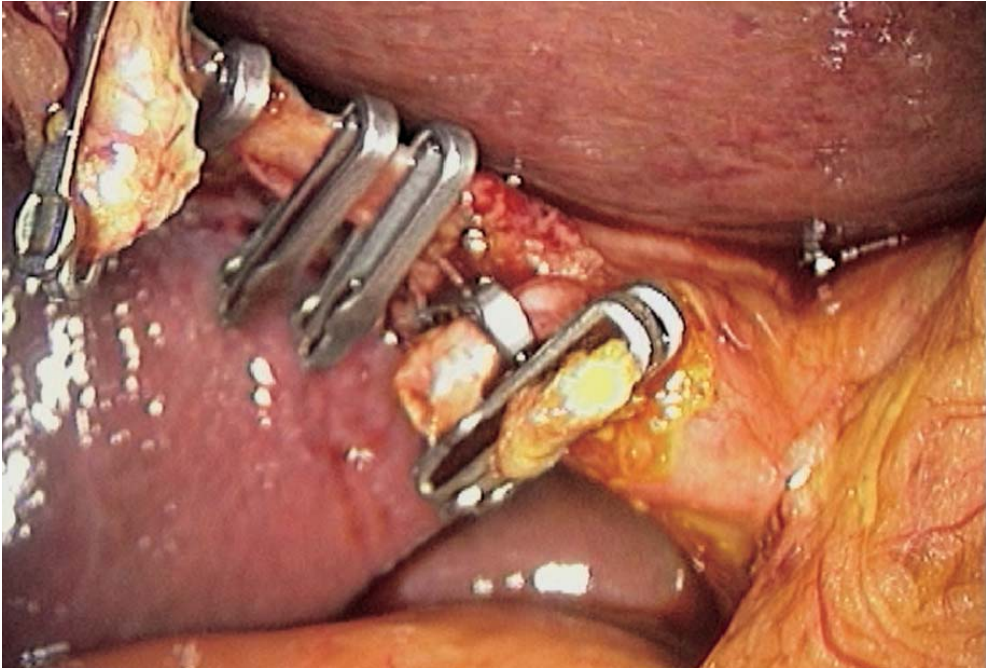


Fig. 1.12. Cystic artery clipped prior to transection

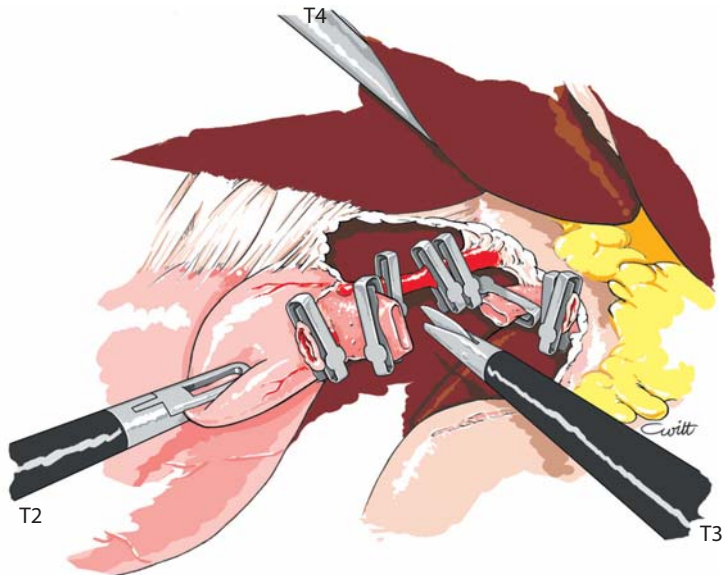


Fig. 1.13. Final dissection of Calot's triangle



### 1.7 Freeing the Gallbladder

The peritoneum is progressively incised anteriorly and posteriorly, and the gallbladder is freed from its hepatic attachments with the coagulating scissors. Usually, only small vessels are encountered, and they are easily coagulated. If necessary, a large vessel can be clipped. Dissection is carried on step by step pulling on the gallbladder with a grasping forceps. Hemostasis is achieved with the coagulating shears (◉ Figs. 1.14, 1.15).

### 1.8 Specimen Retrieval

The gallbladder, totally freed from the liver, is temporarily left aside. The operative field is checked for bleeding and a thorough lavage is performed. (◉ Fig. 1.16). The gallbladder is retrieved, either directly or with a protective bag, depending on the degree of inflammation. The gallbladder can be retrieved through the umbilical port after placing the endoscope in the left paramedian port. A 5-mm grasping forceps is introduced through the umbilical port. In case of large stones, the gallbladder has to be emptied prior to its retrieval. The gallbladder is opened and the stones are crushed inside with a strong grasping forceps. In case of a large widening of the umbilical port, the aponeurosis has to be sutured with absorbable sutures. At this step, the pneumoperitoneum is released. A suction drain can be placed subhepatically through the right lateral port. Skin incisions are sutured using absorbable sutures.

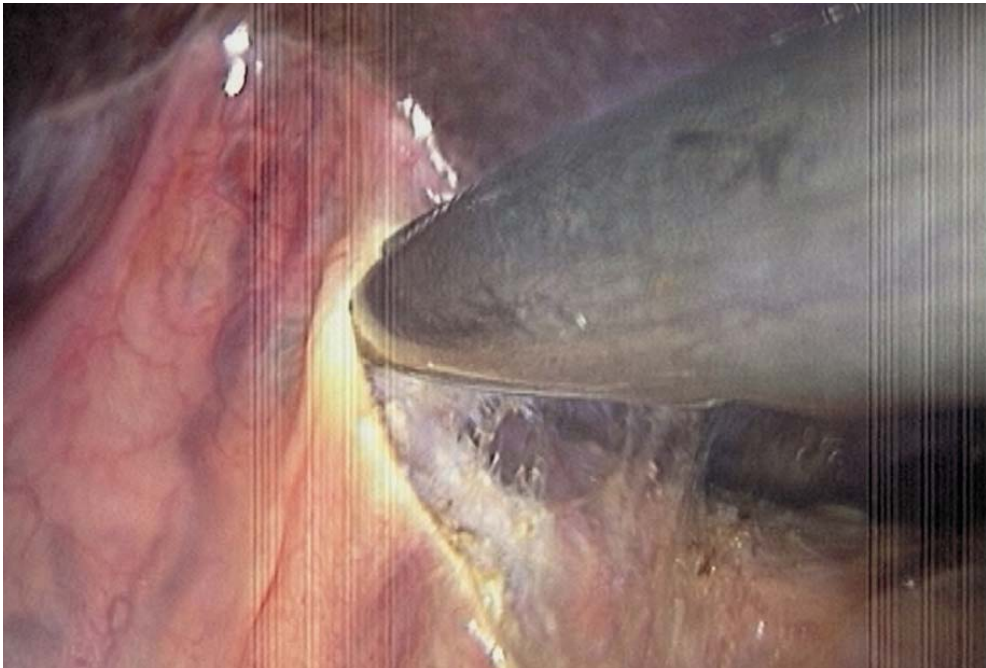
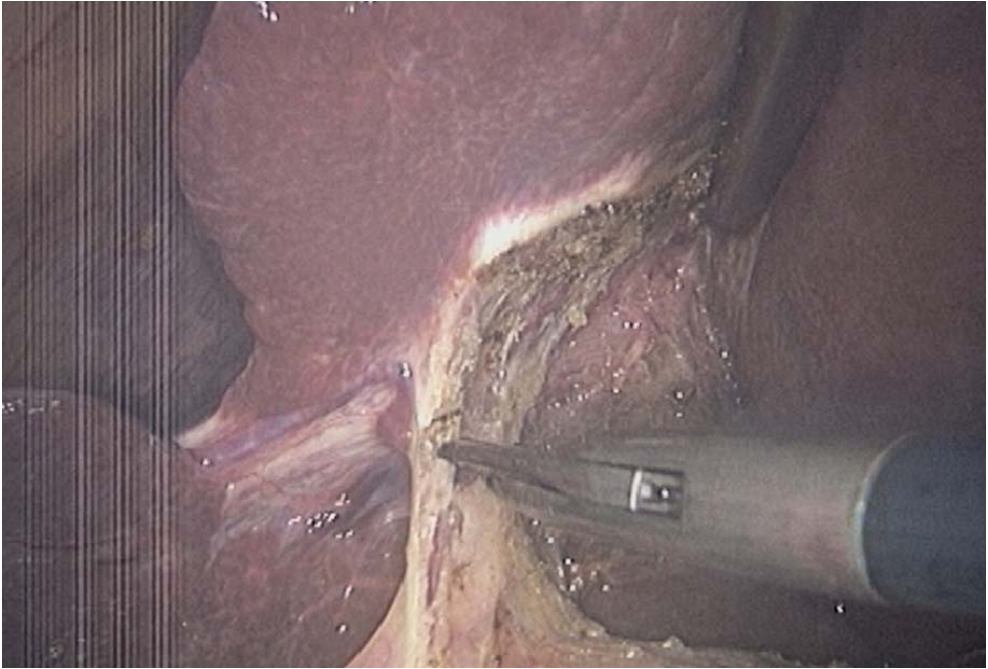
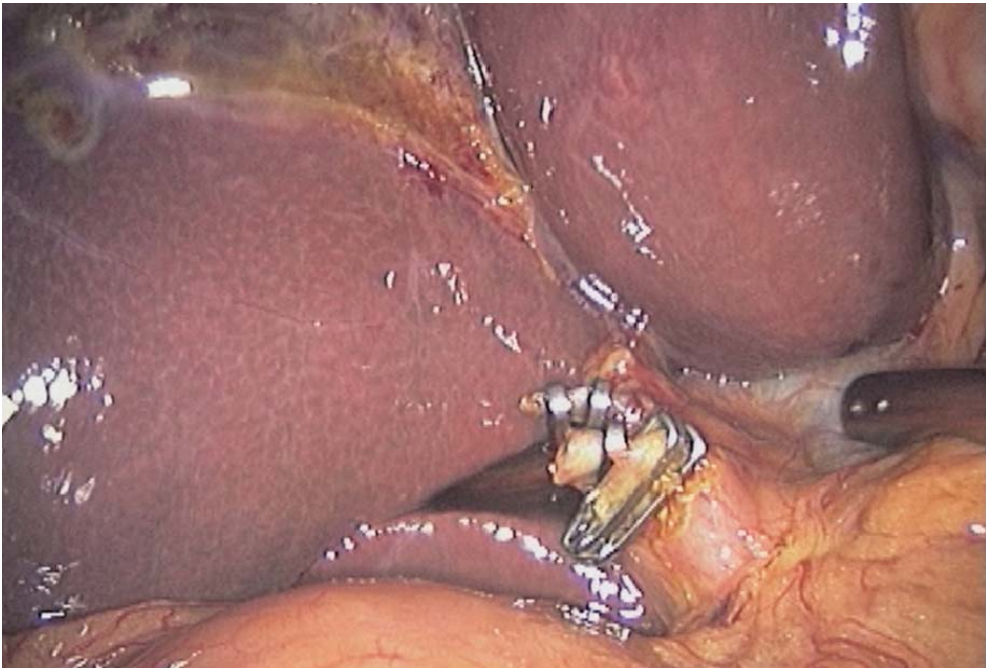


Fig. 1.14. Cholecystectomy



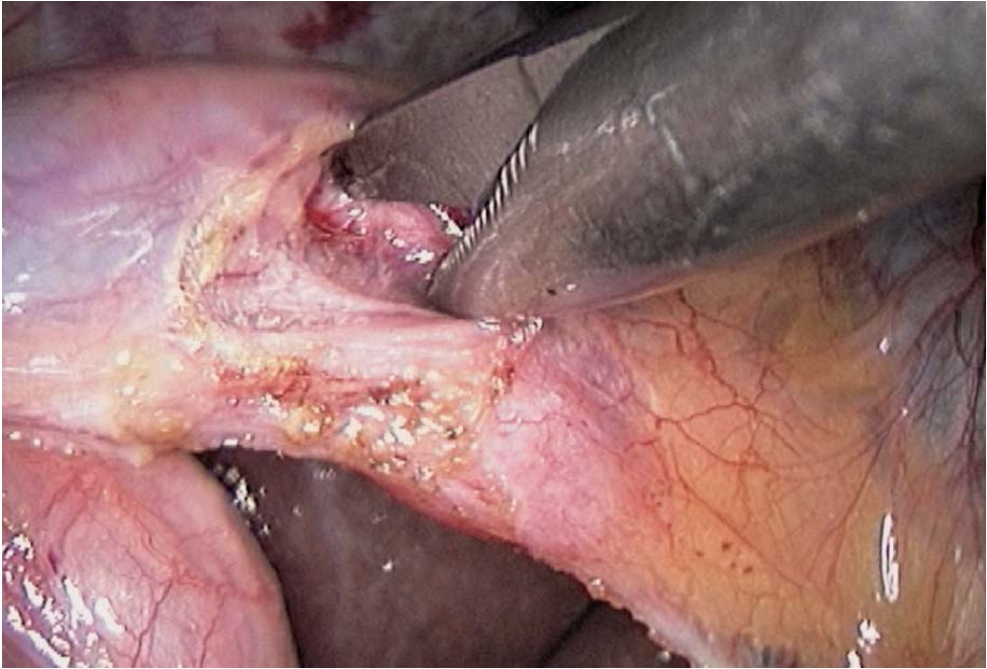
**Fig. 1.15. Cholecystectomy near completion**



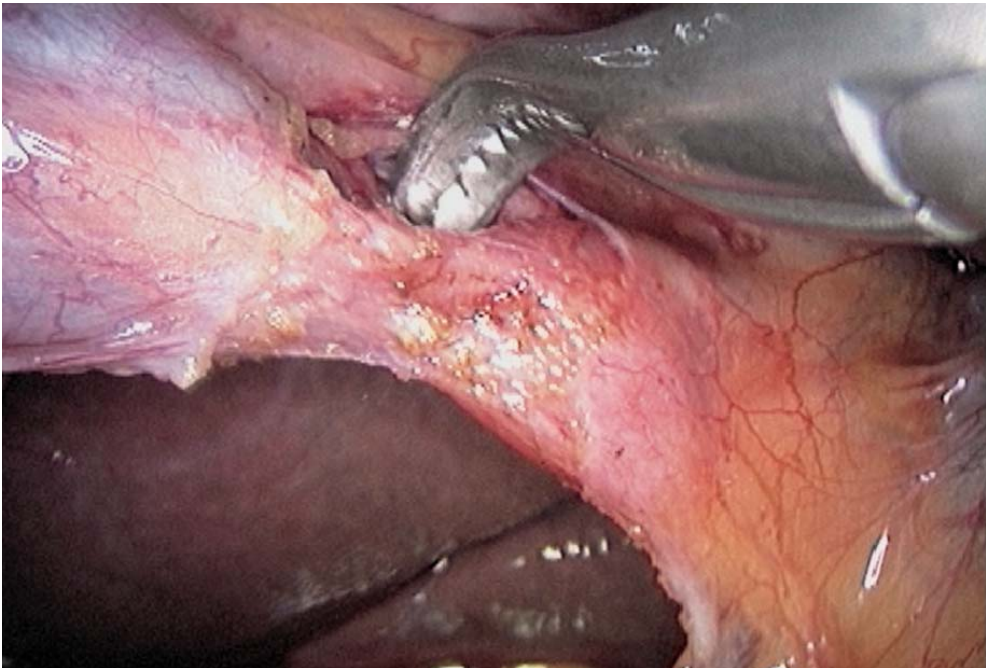
**Fig. 1.16. Peritoneal lavage**

## 1.9 Tips and Comments

- Clips on the artery should always be double for extra safety.
- The dissection should always start at the infundibulum of the gallbladder, enabling an easy location of the cystic duct.
- The use of a specific dissector helps in freeing the cystic duct for a long-enough length to easily perform the cholangiography and to close the cystic duct with clips thereafter.
- We recommend that the dissection of the cystic artery should be performed after dissection and control of the cystic duct. Doing this, the origin of the artery or arteries is more clearly visible. In the case of an anterior cystic artery, of course, arterial control is done first (▶ Figs. 1.17–1.20).
- In severe acute inflammation, it can be helpful to empty the gallbladder by needle puncture, the gallbladder being otherwise too thick to be grasped properly.
- In case of severe acute inflammation, dissection is best carried out by blunt dissection with a metallic suction cannula.
- A large cystic duct may exceed the size of usual clips. In that case, the cystic duct should be closed with a ligature using intracorporeal knots.
- In obese patients, omentum and the small bowel can be kept out of the way by using an extra trocar in a left subcostal position.
- Hepatic steatosis is best controlled with an auto static retractor introduced through the right subcostal port.
- The scars from laparoscopic cholecystectomy can even be reduced to 3 or 2 mm, and the right or left lateral ports can be placed on both axillary lines for less visible scars. This technique, without seriously hindering the handling of the instruments, has the advantage of shifting laterally the two 5-mm incisions. This reduces the scars to a minimum. In this case, it should be noted that the cholangiography is performed through the left port.



**Fig. 1.17. Dissection of anterior cystic artery**



**Fig. 1.18. Dissection of anterior cystic artery with curved dissector**



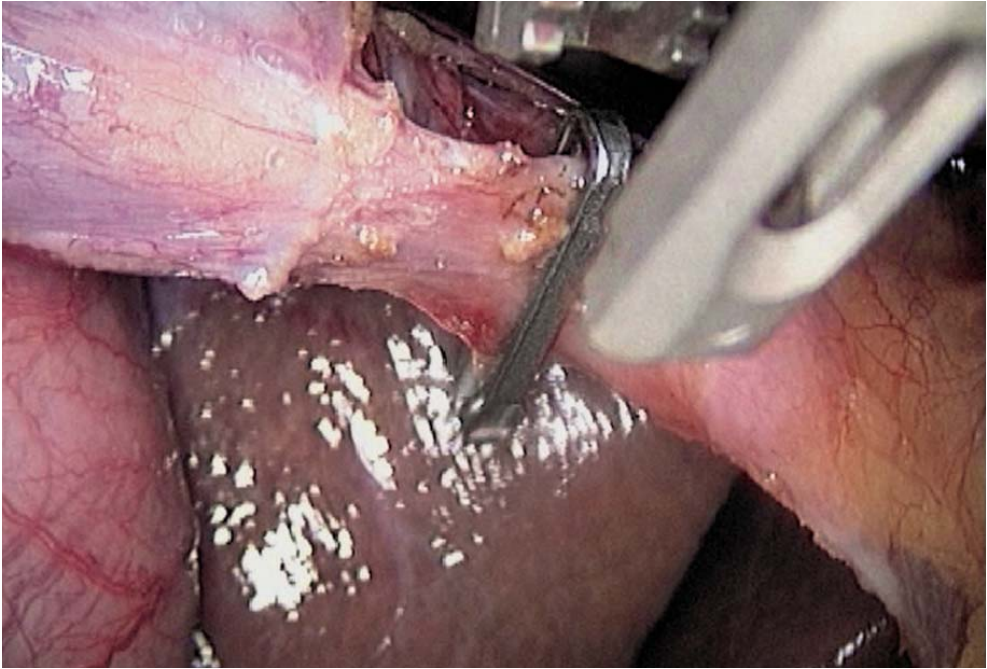

Fig. 1.19. Clipping anterior cystic artery

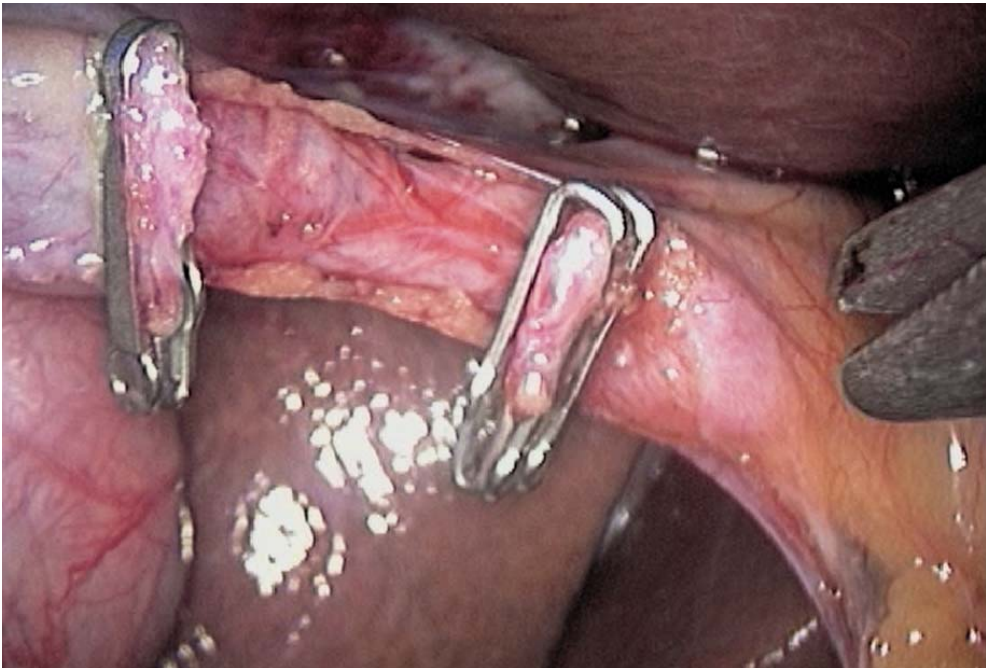


Fig. 1.20. Anterior cystic artery transected

---

## Literature

- Aliperti G, Edmundowicz SA, Soper NJ (1991) Combined endoscopic sphincterotomy and laparoscopic cholecystectomy in patients with choledocholithiasis and cholecystolithiasis. *Ann Intern Med* 115:783–785
- Anderson RE, Hunter JG (1991) Laparoscopic cholecystectomy is less expensive than open cholecystectomy. *Surg Laparosc Endosc* 1:82–83
- Andren-Sandberg A, Alinder G, Bengmark S (1985) Accidental lesions of the common bile duct at cholecystectomy: pre and perioperative factors of importance. *Ann Surg* 201:328–332
- Ardidsson D, Gerdin D (1991) Laparoscopic cholecystectomy during pregnancy. *Surgical Laparosc Endosc* 1:193–194
- Asbun HJ, Reddick EJ (1991) Cholecystectomy in the ambulatory setting. *Problems in general surgery. Laparosc Surg* 8:432–441
- Arregui ME, Davis CJ, Arkush A et al (1991) In selected patients outpatient laparoscopic cholecystectomy is safe and significantly reduces hospitalization charges. *Surg Laparosc Endosc* 1:240–245
- Bagnato VJ, Mc Gee GE, Hatten LE et al (1991) Justification for routine cholangiography during laparoscopic cholecystectomy. *Surg Laparosc Endosc* 1:89–93
- Bailey RW, Zucker KA, Flowers JL (1991) Laparoscopic cholecystectomy: experience with 375 consecutive patients. *Annals Surg* 214:531–541
- Baumel H, Domergue J (1991) Cholécystectomie coelioscopique. *Press Med* 20:678
- Becker CD, Burhenne HJ (1991) Percutaneous ablation of the cystic duct and the gallbladder: experimental and early clinical results. *Sem Roentgenol* 26:259–266
- Belghiti J, Sauvanet A (1990) La cholangiographie per opératoire a-t-elle vécue? *Act Digest* 3:115–117
- Berci G (1991) Cholangiography and choledochoscopy during laparoscopic cholecystectomy, its place and value. *Digest Surg* 8:92–96
- Berci G, Sackier JM (1991) Laparoscopic cholecystectomy. *Problems in general surgery. Laparosc Surg* 8:284–319
- Berci G, Sackier JM (1991) The Los Angeles experience with laparoscopic cholecystectomy. *Am J Surg* 161:382–384
- Berci G, Sackier JM, Paz-Partlow M (1991) Routine or selected intraoperative cholangiography during laparoscopic cholecystectomy? *Am J Surg* 161:355–360
- Berthelin JL, Fournier L, Galateau C (1984) L'agénésie de la vésicule biliaire: piège échographique. *Med Chir Dig* 13:619–621
- Blatner ME, Wittgen AM, Andrus CH et al (1991) Cystic duct cholangiography during laparoscopic cholecystectomy. *Arch Surg* 126:646–649
- Boulez J, Espalieu P, Voiglio E (1991) Premiers résultats de la cholécystectomie laparoscopique laparoscopique: à propos de 200 cas. *Lyon Chir* 87:452–454
- Brandon JC, Velez MA, Teplik SK (1991) Laparoscopic cholecystectomy: evolution, early results, and impact on nonsurgical gallstone therapies. *Am JR Ray Society* 157:235–239
- Brooks DC, Becker JM, Carr-Locke DL (1991) Laparoscopic cholecystectomy. *Bailliere's Clin Gastroenterol* 5:225–238
- Cameron JL, Gadacz TR (1991) Laparoscopic cholecystectomy. *Ann Surg* 214:1–2
- Champault G, Vazzana G (1991) La laparoscopie en chirurgie digestive. *J Pathol Dig* 1:40–43
- Cheslyn-Curtis S, Russell RCG (1991) New trends in gallstone management. *Br J Surg* 78:143–149
- Coburg A, Wolharn R, Weinelt N (1991) Technical and clinical complications of laparoscopic cholecystectomy. *Dig Surg* 8:84–85
- Collet D, Belliard C, Dost J et al (1991) La cholécystectomie par laparoscopie: 200 observations. *Med Chir Dig* 20:43–44
- Cooperman AM (1991) Laparoscopic cholecystectomy: result of an early experience. *Am J Gastro* 86:694–696

- Cope C (1991) Percutaneous cholecystectomy with operative cholangiogram. *Surg Laparosc Endosc* 1:229–232
- Cuilleret J, Bou B, Burgard G et al (1991) A propos de 225 cas de lithiases biliaires opérés sous coelioscopie. *Lyon Chirurgical* 87:455–457
- Cuschieri A (1991) Laparoscopic cholecystectomy: indications, technique and results, pros and cons. *Digestive Surg* 8:104–107
- Cuschieri A, Berci G (1990) Laparoscopic cholecystectomy and extracorporeal shock wave lithotripsy in the management of gallstones disease. *Br J Surg* 78:753
- Dent TL, Ponsky JL, Berci G (1991) Minimal access general surgery: the dawn of a new era. *Am J Surg* 161:323
- Drouard F, Delamarre J, Capron JP (1991) Cutaneous seeding of gallbladder cancer after laparoscopic cholecystectomy. *N Engl J Med* 31:1316
- Dubois F (1991) Laparoscopic cholecystectomy – personal experience. *Digest Surg* 8:97–100
- Dubois F (1991) Les indications en 1991 de la cholecystectomie coelioscopique. *Gastroenterol Clin Biol* 15:421–423
- Dubois F, Berthelot G (1982) Cholécystectomie par minilaparotomie. *Nouv Press Med* 11:1139–1141
- Dubois F, Icard P, Berthelot G, Levard H (1990) Coelioscopic cholecystectomy. *Ann Surg* 211:60–63
- Dubois F, Berthelot G, Levard H (1991) Laparoscopic cholecystectomy: history perspective and personal experience. *Surg Laparosc Endosc* 1:52–57
- Easter DW (1991) A surgeon's perspective on laparoscopic cholecystectomy. *Am J R Ray Society* 157:241–242
- Easter DW, Moossa AR (1991) Laser and laparoscopic cholecystectomy. *Arch Surg* 126:423
- Fabre JM, Przemyslaw P, de Seguin de Hons C (1992) Evaluation of the laparoscopic cholecystectomy on patients with simple and complicated cholecystolithiasis. *Word J Surg* 16:113–117
- Ferzli G, Kloss DA (1991) Laparoscopic cholecystectomy: 11 consecutive cases. *Am J Gastr* 86:1176–1178
- Fisher KS, Reddick EJ, Olsen DO (1991) Laparoscopic cholecystectomy: cost analysis. *Surgical Laparosc Endosc* 1:77–81
- Fitzgerald SD, Bailey PV, Liebscher GJ et al (1991) Laparoscopic cholecystectomy in anticoagulated patients. *Surg Endosc* 5:166
- Fitzgibbons RJ, Schmid S, Santoscoy R et al (1991) Open laparoscopy for cholecystectomy. *Surg Lap Endosc* 1:216–222
- Flowers JL, Bailey RW, Scowill WA (1991) The Baltimore experience with laparoscopic management of acute cholecystitis. *Am J Surg* 161:388–392
- Fontes-Dislaire I, Hammer-Besse T, Suc B (1991) 2820 cholécystectomies par coelioscopie: registre de la Société Française de Chirurgie Digestive; 6è réunion de la Société Française de Chirurgie Digestive, Strasbourg
- Fourtanier G, Fontes-Dislaire I, Aramouny H (1991) Cholécystectomie sous coelioscopie ou par laparotomie sous costale? Résultats d'une étude prospective. 6è réunion de la SFCD, Strasbourg
- François Y, Braillon G, Cuilleret J (1991) Morbidité de la cholécystectomie per coelioscopique: étude de la Société de Chirurgie de Lyon: 1060 observations. *Lyon Chir* 87:459–462
- Furuta K, Yoshimoto H, Watanabe R et al (1991) Laparoscopic cholecystectomy for a suspected case of gallbladder carcinoma. *Am J Gastro* 86:1851
- Gadacz TR, Talamini AA (1991) Traditional versus laparoscopic cholecystectomy. *Am J Surg* 161:336–338
- Gadacz TR, Talamini MA, Lillemoe KD et al (1990) Laparoscopic cholecystectomy. *Surg Clinics North America* 70:1249–1262
- Gigot JF (1991) Laparoscopic cholecystectomy: a multicenter Belgian experience. *Digest Surg* 8:126–127

- Gigot JF, Navez B. Techniques et résultats du traitement coelioscopique de la lithiase cholédocienne en cours de cholécystectomie laparoscopique. The Belgian group for endoscopic surgery [personal communication]
- Glaser K, Schwab G, Tschmelitsch J (1991) Combined extracorporeal shock wave lithotripsy and laparoscopic cholecystectomy. *Surg Laparosc Endosc* 1:233-235
- Goodman GR, Hunter JC (1991) Results of laparoscopic cholecystectomy in a university hospital. *Am J Surg* 162:576-579
- Grace Pa, Quereshi A, Coleman J et al (1991) Reduced postoperative hospitalization after laparoscopic cholecystectomy. *Br J Surg* 78:160-162
- Graves HA, Ballinger JF, Anderson WJ (1991) Appraisal of laparoscopic cholecystectomy. *Ann Surg* 213:655-664
- Hauer-Jensen M, Karesen R, Nygaard K et al (1986) Consequences of routine preoperative cholangiography during cholecystectomy for gallstone disease: a prospective, randomized study. *World J Surg* 10:996-1002
- Holohan T (1991) V. Laparoscopic cholecystectomy. *Lancet* 338:801-803
- Houdart R, Brisset D, Perniceni T et al (1990) La cholangiographie intra-veineuse est inutile avant cholécystectomie pour lithiase non compliquée: étude prospective de 100 cas. *Gastroenterol Clin Biol* 14:652-654
- Huguier M, Rostoucher P, Houry S (1991) Cholécystectomie: le coût de l'acte opératoire. *Ann Chir* 45:17-21
- Hunter JG (1991) Avoidance of bile duct injury during laparoscopic cholecystectomy; *Am J Surg* 167:71-76
- Hunter JG (1991) Laparoscopic cholecystectomy: laser or electrocautery? Problems in general surgery. *Laparosc Surg* 8:409-415
- Hunter JG (1992) Laparoscopic transcystic common bile duct exploration. *Am J Surg* 163:53-58
- Jakimowicz J (1991) Cholecystectomy - the »golden standard« treatment for cholecystolithiasis: the evolution of surgical technique. *Digest Surg* 8:71-75
- Jakimowicz J (1991) Intraoperative vs. postoperative biliary endoscopy: intraoperative ultrasonography vs. sonography during laparoscopic cholecystectomy; Problems in general surgery. *Laparoscopic Surg* 8:442-457
- Jakimowicz J, Ruers TJM (1991) Ultrasound-assisted laparoscopic cholecystectomy: preliminary experience. *Digestif Surg* 8:114-117
- Joyce WP, Keane R, Burke GJ (1991) Identification of bile duct stones in patients undergoing laparoscopic cholecystectomy. *Br J Surg* 78:1174-1176
- Kawahara H, Tsumura O, Kubouchi K (1991) Laparoscopic cholecystectomy and the »soft trocar«. *Surg Laparosc Endosc* 1:265-267
- Kempeneers I (1991) Risks and complications of laparoscopic cholecystectomy: critical evaluation of the method. *Digestive Surg* 8:114-117
- Kestens PJ, Gigot JF (1992) Accidents de la cholécystectomie laparoscopique. XIV<sup>e</sup> Journées de Pathologie Digestive, Nice
- Larson GM, Vitale GC, Casey J et al (1992) Multipractice analysis of laparoscopic cholecystectomy in 1983 patients. *Am J Surg* 163:221-226
- Ledet WP (1990) Ambulatory cholecystectomy without disability. *Arch Surg* 125:1434-1435
- Lennon F (1991) Laparoscopic cholecystectomy: a cautionary note. *Br J Surg* 78:1400
- Liguory CL, Lefebvre JF, Gossot D (1991) Complications biliaires de la cholécystectomie laparoscopique: diagnostic et traitement endoscopique à propos de 22 cas: 6<sup>e</sup> réunion de la société française de chirurgie digestive, Strasbourg
- Liguory C, Vitale GC, Lefebvre JF (1991) Endoscopic treatment of postoperative biliary fistulae. *Surgery* 11:779-784
- MacMahon A, Baxter J, Russel I et al (1991) Laparoscopic cholecystectomy. *The Lancet* 338:1333



- Mc Entee G, Grace PA, Bouchier-Hayes D (1991) Laparoscopic cholecystectomy and the common bile duct. *Br J Surg* 78:385–386
- Moos G (1986) Discharge within 24 hours of elective cholecystectomy: the first 100 patients. *Arch Surg* 121:1159–1161
- Moosa AR, Mayer AD, Stabile B (1991) Iatrogenic injury to the bile duct: who, how, where? *Arch Surg* 125:1026–1031
- Motson RW, Wetterl A (1990) Operative choledochoscopy: common bile duct exploration is incomplete without it. *Br J Surg* 77:975–982
- Mouret P (1991) From the first laparoscopic cholecystectomy to the frontiers of laparoscopic surgery: the future prospectives. *Digest Surg* 8:124–125
- Nagy AG, James D (1989) Diagnostic laparoscopy. *Am J Surg* 157:490–493
- Natanson LK, Easter DW, Cushieri A (1991) Laparoscopic cholecystectomy: the Dundee technique. *Br J Surg* 78:155–159
- Neugebauer E, Troidl H, Spangenberger W, Dietrich A et al (1991) Cholecystectomy study group. Conventional versus laparoscopic cholecystectomy and the randomized controlled trial. *Br J Surg* 78:150–154
- Nouaille JM (1990) À propos de la cholécystectomie sous coelioscopie. *La presse médicale* 19:337
- Nowzaradan Y, Westmorelad JC (1991) Laparoscopic cholecystectomy: new indications. *Surg Laparosc Endosc* 1:71–76
- O’Kelly TJ, Barr H, Malley WR (1991) Cholecystectomy through a 5 cm subcostal incision. *Br J Surg* 78:762
- Olsen DO (1991) Laparoscopic cholecystectomy. *Am J Surg* 161:339–344
- Olsen DO, Asbun HJ (1991) Laparoscopic cholecystectomy for acute cholecystitis. Problems in general surgery. *Laparosc Surg* 8:426–431
- Paterson-Brown S, Garden OJ, Carter DC (1991) Laparoscopic cholecystectomy. *Br J Surg* 78:131–132
- Périssat J (1990) La cholécystectomie par coelioscopie, une technique d’avenir. *Press Mé* 19:337
- Périssat J, Vitale GC (1991) Laparoscopic cholecystectomy: gateway to the future. *Am J Surg* 161:408
- Périssat J, Collet D, Belliard R et al (1990) Lithiase vésiculaire: traitement laparoscopique. Lithotritie intra corporelle (LIC) suivie de cholécystostomie ou cholécystectomie technique personnelle. *Actualités Digestives* 12:64–67
- Petelin JB (1991) Laparoscopic approach to common duct pathology. *Surg Laparosc Endosc* 1:33–41
- Peters JH, Ellison EC, Innes JT et al (1991) Safety and efficacy of laparoscopic cholecystectomy: a prospective analysis of 100 initial patients. *Ann Surg* 213:3–12
- Peters JH, Gibbons GD, Innes JT (1991) Complications of laparoscopic cholecystectomy. *Surgery* 11:769–778
- Phillips EH, Carroll B (1991) New techniques for the treatment of common bile duct calculi encountered during laparoscopic cholecystectomy. Problems in general surgery. *Laparosc Surg* 8:387–394
- Ponsky JL (1991) Complications of laparoscopic cholecystectomy. *Am J Surg* 161:393–395
- Quattalbaum JK, Dorsey H, Flanders HD (1991) Laparoscopic treatment of common bile duct stones. *Surg Laparosc Endosc* 1:26–32
- Raleigh BK (1991) Subcutaneous emphysema and hypercarbia following laparoscopic cholecystectomy. *Arch Surg* 126:1154–1156
- Reddick EJ (1991) Laparoscopic laser cholecystectomy: technique and results. *Digestive Surg* 8:79–83
- Reddick EJ, Olsen DO (1990) Out patient laparoscopic laser cholecystectomy. *Am J Surg* 160:485–498
- Reddick EJ, Olsen D, Spaw A et al (1991) Safe performance of difficult laparoscopic cholecystectomy. *Am J Surg* 161:377–381

- Reiner DS, Reiner MA (1991) A simple method for drain placement in coelioscopic cholecystectomy. *Surgery Gynecol Obstet* 173:57–58
- Rey JF, Greff M (1992) Traitement endoscopique de la lithiase cholédocienne. XIV<sup>e</sup> Journées de Pathologie Digestive, Nice
- Roseau E (1991) Cholécystectomie par coelioscopie, son coût et son avenir. *Press Méd* 20:6243
- Roseau E (1991) Cholécystectomie par coelioscopie: un enseignement indispensable. *Press Méd* 18:100–101
- Roseau E (1991) La cholécystectomie par coelioscopie, une technique d'exception. *Press Méd* 18:1528
- Rubio PA, Rowe G, Feste JR (1989) Endoscopic laser cholecystectomy. *Houston Medicine* 5:124–126
- Sackier JM, Berci G, Phillips E et al (1991) The role of cholangiography in laparoscopic cholecystectomy. *Arch Surg* 126:1021–1026
- Saltzstein EC, Mercer LC, Peacock JB et al (1991) Twenty-four hour hospitalization after cholecystectomy. *Gynecol Obst Surg* 173:367–370
- Schirmer BD, Edge SB, Dix J (1991) Laparoscopic cholecystectomy. *Ann Surg* 213:665–677
- Soper NJ, Dunneagan DL (1991) Laparoscopic cholecystectomy. *Surg Laparosc Endosc* 1:156–161
- Spaw AT, Reddick EJ, Olsen DO (1991) Laparoscopic laser cholecystectomy: analysis of 500 procedures. *Surg Laparosc Endosc* 1:2–7
- Spiro HM (1992) Diagnostic laparoscopic cholecystectomy. *Lancet* 339:167–168
- Stiegmann GV, Goff JS, Mansour A et al (1992) Precholecystectomy endoscopic cholangiography and stone removal is not superior to cholecystectomy, cholangiography, and common duct exploration. *Am J Surg* 163:227–230
- Stoker ME (1991) Laparoscopic common duct exploration, 3rd intern meeting of SMIT Boston, November
- Strasberg SM, Clavien PA, Sanabria J (1991) Laparoscopic cholecystectomy. *Sem Roentgenol* 26:232–238
- Talamini MA, Gadacz TR (1991) Traditional versus laparoscopic cholecystectomy. *Problems in general surgery. Laparosc Surg* 8:279–283
- Terblanche J (1991) Laparoscopic cholecystectomy: a new milestone or a dangerous innovation? *Surgery* 3:177–180
- Testas P, Chollet JM, De Watteville JC (1990) Essai d'évaluation de la cholécystectomie par abord coelioscopique: à propos de 2.266 malades. *Chirurgie* 116:844–847
- The Southern Surgeons Club (1991) A prospective analysis of 1518 laparoscopic cholecystectomies. *N Engl J Med* 324:1073–1078
- Troidl H (1991) Laparoscopic cholecystectomy in view of medical technology assessment. *Problems in general surgery. Laparosc Surg* 8:495–501
- Unger SW, Edelman DS, Scott JS et al (1991) Laparoscopic treatment of acute cholecystitis. *Surg Laparosc Endosc* 1:14–16
- Velez M, Mule J, Brandon J et al (1991) Laparoscopic repair of a cholecystoduodenal fistulae. *Surg Endosc* 5:224
- Vitale GC, Collet D, Larson GM et al (1991) Interruption of professional and home activity after laparoscopic cholecystectomy among French and American patients. *Am J Surg* 161:396–398
- Voyles RC, Petro AB, Meena AL et al (1991) A practical approach to laparoscopic cholecystectomy. *Am J Surg* 161:365–370
- Walsh TN, Russel RCG (1992) Cholecystectomy and gallbladder conservation. *Br J Surg* 1:4–5
- Walter P, Ledet J (1990) Ambulatory cholecystectomy without disability. *Arch Surg* 125:1434–1435
- Whiston RJ, Eggers KA, Morris RW (1991) Tension pneumothorax during laparoscopic cholecystectomy. *Br J Surg* 78:1325
- Wilkinson LH (1991) Laparoscopic cholecystectomy for a suspected case of gallbladder carcinoma. *Am J Gastro* 86:1851

- Wilson P, Leese T, Morgan WP et al (1991) Elective laparoscopic cholecystectomy for »all-comers«. Lancet 338:795–797
- Wolfe BM, Gardiner BN, Leary BF (1991) Laparoscopic cholecystectomy: a remarkable development. JAMA 265:1573–1574
- Wolharn R, Coburg AG, Wienelt N (1991) Borderline indications for laparoscopic cholecystectomy. Digest Surg 8:101–103
- Zucker KA, Bailey RW, Gadacz TR (1991) Laparoscopic guided cholecystectomy. Am J Surg 161: 36–44

---

## 2 Laparoscopic Common Bile Duct Surgery

### 2.1 Operating Room Setup: Position of the Patient

The patient is placed supine. The surgeon stands between the patient's legs. The first assistant is on the patient's right side while the second assistant is on the left (➤ Fig. 2.1). Two video monitor sets are required for this procedure; one for the actual laparoscopic part and the second for cholangioscopy. The laparoscopic monitor is placed left of the patient's head, while the cholangioscopy monitor is on the right. Some reverse Trendelenburg position is required, and slight left rotation at times.

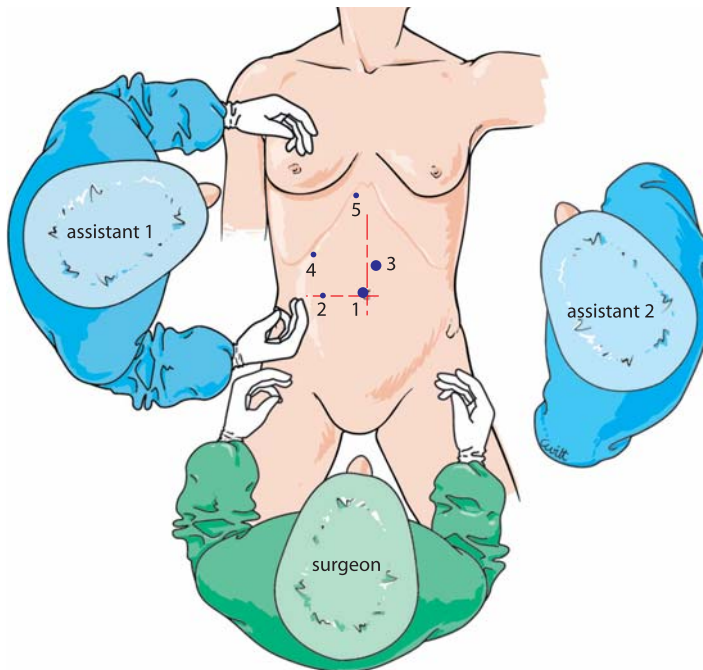


Fig. 2.1. OR setup – trocar position

## 2.2 Recommended Instruments

- Two 10-mm trocars
- Two 5-mm trocars
- A 0° endoscope
- Three Johan 5-mm fenestrated forceps
- A 5-mm straight grasping forceps
- Five-millimetre shears
- A 5-mm retractable knife
- A 5-mm needle holder
- A 5-mm dissector
- Two cholangioscopes: size 2.8 mm for a transcystic approach and size 4.8 mm for a choledochotomy approach
- A specific 10-mm cholangioscope grasping forceps
- A specific protective trocar for the flexible cholangioscope
- A plastic retrieval bag
- A titanium clip applicator, 5 or 10 mm
- Fogarty balloon catheters
- Various Dormia baskets, 3 and 4 stranded, 10 and 20 mm
- A flexible fiber lithotripter

## 2.3 Trocar Placement and Exposure

Pneumoperitoneum is created with a Veress needle, and the first trocar is introduced obliquely at the right lateral margin of the umbilicus. The abdominal cavity is explored and the operation site is exposed. A 5-mm right para-umbilical trocar is introduced about 8 cm lateral from the first port. A 5-mm fenestrated forceps goes in there. A second 10-mm port is inserted 5 cm above the umbilicus, slightly to the left of the midline. This allows insertion of the operating instruments, for instance coagulating shears. Two subcostal trocars are inserted, one on the axillary line allowing the insertion of a second fenestrated forceps or retractor. The trocar for the cholangioscope is positioned subcostally slightly to the right of the midline (➤ Fig. 2.1). The peritoneal cavity is visually explored (➤ Fig. 2.2). The right lateral fenestrated forceps grasps the gallbladder after positioning a smooth retractor in the right subcostal space.

## 2.4 Dissection of Calot's Triangle and CBD (➤ Fig. 2.3)

Lateral traction on the infundibulum straightens the anterior and posterior peritoneal layers (➤ Fig. 2.4). They are incised with coagulating shears and the cystic duct is exposed.

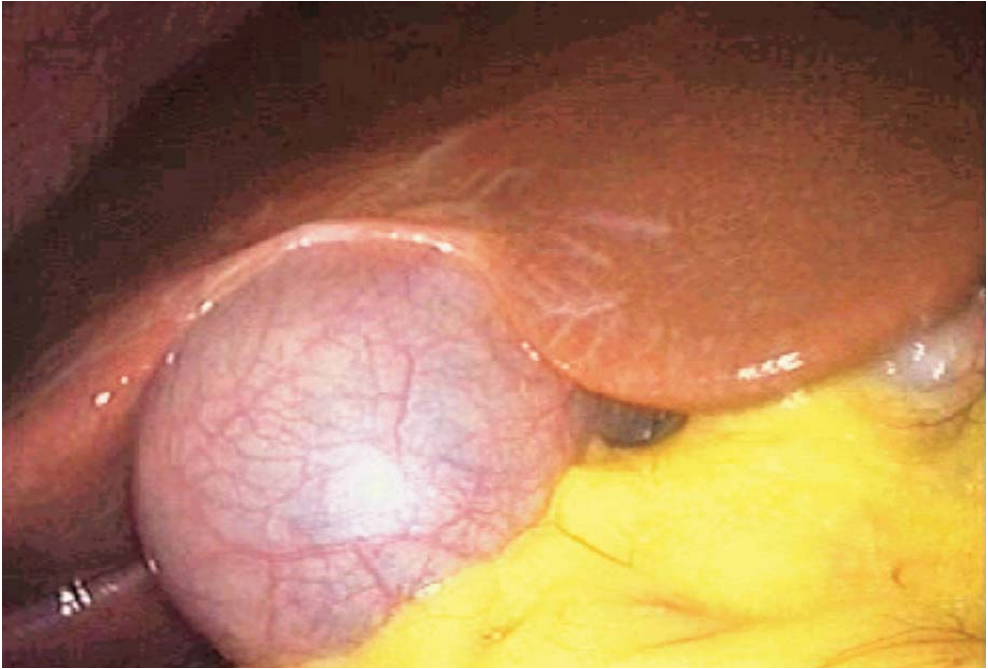


Fig. 2.2. Exposure of gallbladder

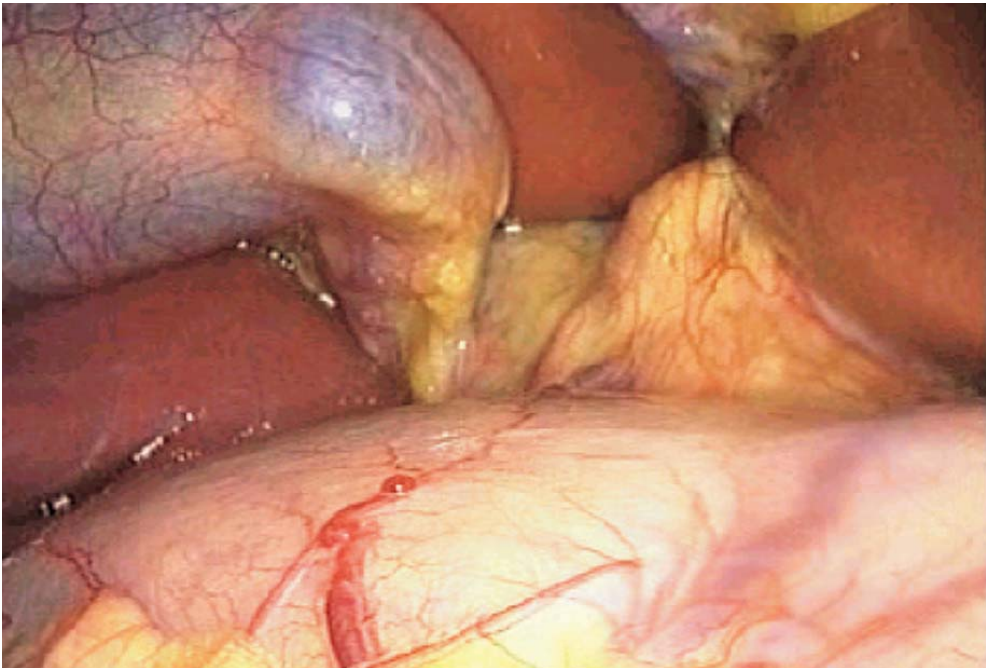


Fig. 2.3. Exposure Calot's triangle



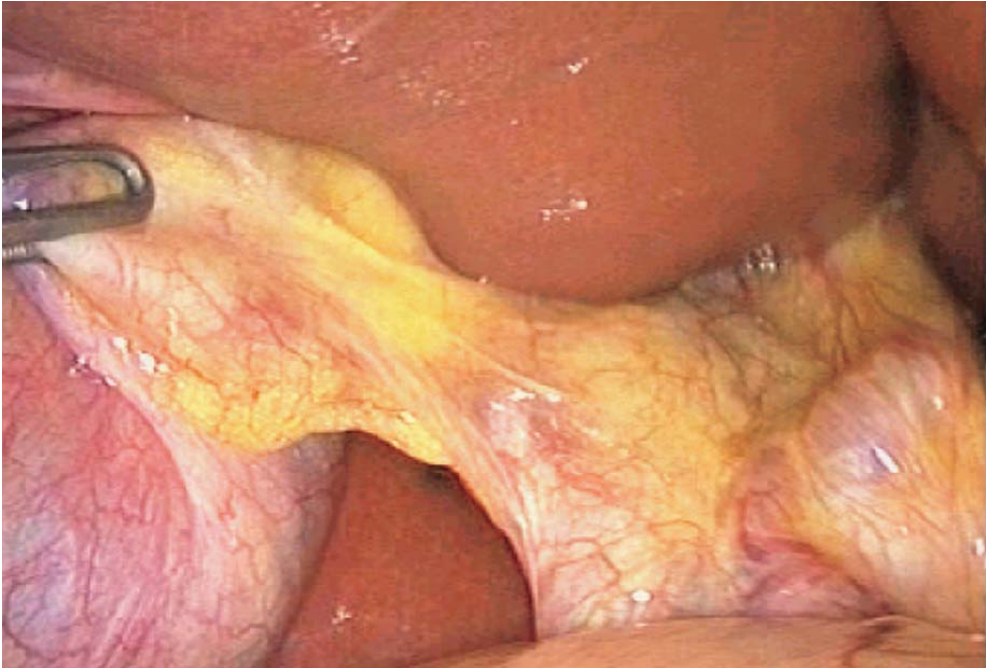

Fig. 2.4. Exposure of CBD

The distal cystic duct is dissected free down to the common bile duct (CBD). The anterior part of the CBD is prepared over a distance of 2–3 cm (▶ Fig. 2.7). The distal part of the cystic duct is thus clearly identified. The cystic duct is controlled proximally with a clip.

## 2.5 Intraoperative Cholangiography

Intraoperative cholangiography is then performed with a silicon catheter introduced with a fenestrated forceps (▶ Figs. 2.5, 2.6). The cystic duct is incised close to the clip. The catheter is introduced after careful filling and removing of air bubbles. Fluoroscopy of the CBD is performed.

## 2.6 Removal of CBD Stones

Cholangiography clearly identifies CBD stones, and the number of stones and their size can be assessed. Basically two situations are encountered. If stones are smaller than the cystic duct and are located in the distal CBD, transcystic extraction is possible. A single stone is the best indication. Otherwise, a choledochotomy is preferred, especially in case of multiple stones.

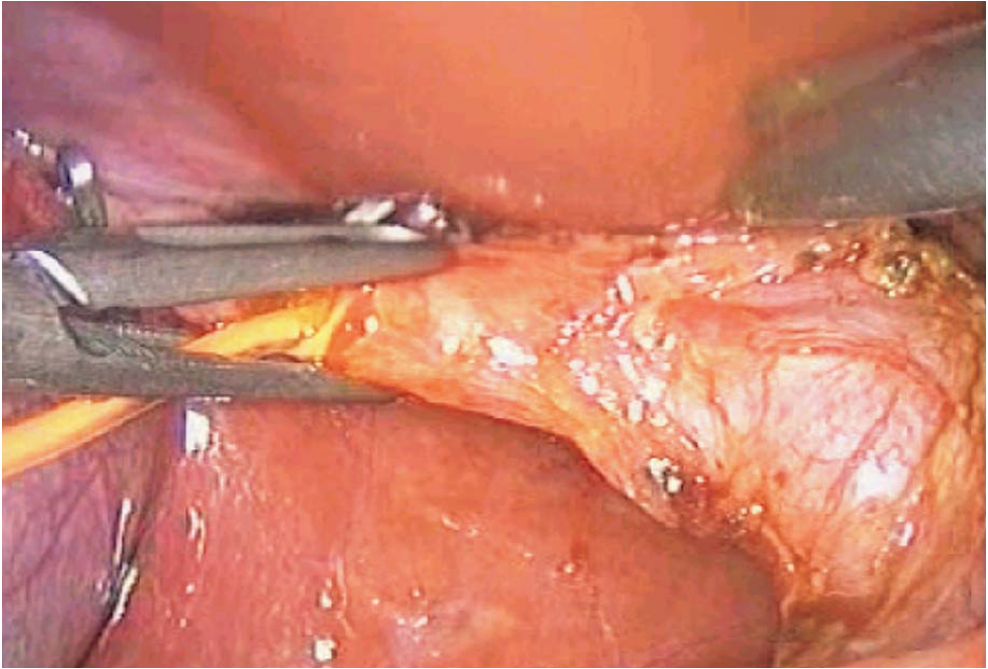


Fig. 2.5. Cholangiography

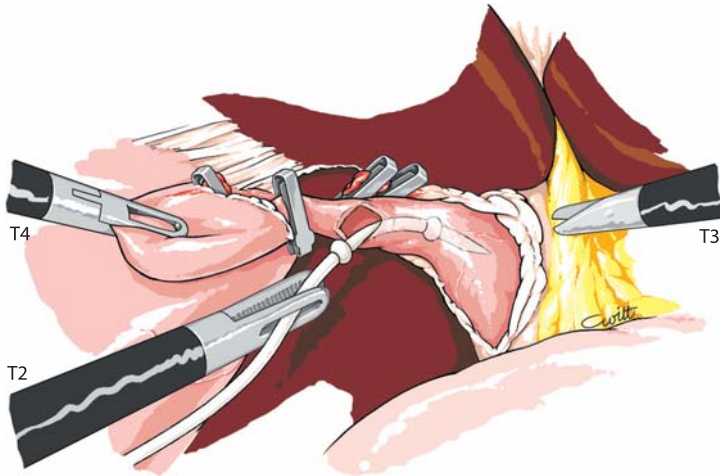


Fig. 2.6. Cholangiography



## 2.7 Transcystic Extraction

### 2.7.1 *Step 1: Preparation of Cystic Duct*

The opening of the cystic can be slightly dilated. This is done more easily by inserting a flexible wire guide. Ureteral dilatation bougies may be necessary. Care must be taken here not to exert excess traction on the instruments. The entire cystic duct must be dissected. This transcystic approach can be done only if the cystic duct enters the CBD laterally, and not in case of a posterior implantation.

### 2.7.2 *Step 2: Transcystic Extraction*

Cholangiography is performed; a Dormia basket is introduced through a flexible catheter. The stone may be extracted after catching it with the basket under fluoroscopic guidance. It is sometimes necessary to use the small flexible cholangioscope and to introduce the Dormia basket through the operating channel. The stone is caught and removed under direct vision. Once the lower part of the CBD seems empty, a control cholangioscopy of the CBD is performed to ensure it is actually empty. Cholangioscopic inspection of the intrahepatic ducts is usually impossible by this route. A final control cholangiography checks complete clearance of stones.

### 2.7.3 *Step 3: Closure of Cystic Duct*

Once the CBD is cleared of stones, the cystic duct is closed with two clips. In case of major inflammation, or any doubt, bile drainage is performed with a transcystic drain. The drain is tightened to the cystic duct with an absorbable ligature. This very ligature is especially important in preventing either postoperative leakage or catheter displacement. If these transcystic manoeuvres fail, a choledochotomy is always possible.

## 2.8 Choledocholithotomy: CBD Stone Extraction Through Choledochotomy

### 2.8.1 *Step 1: Exposure of CBD*

Exposure is done by traction with a right subcostal forceps on the infundibulum. The cystic duct is closed with two clips. The left lobe of the liver is suspended by a transcutaneous suture on the anterior ligament. An extra 5-mm trocar is inserted left subcostally to lower the duodenum and the small bowel. It is handled by the

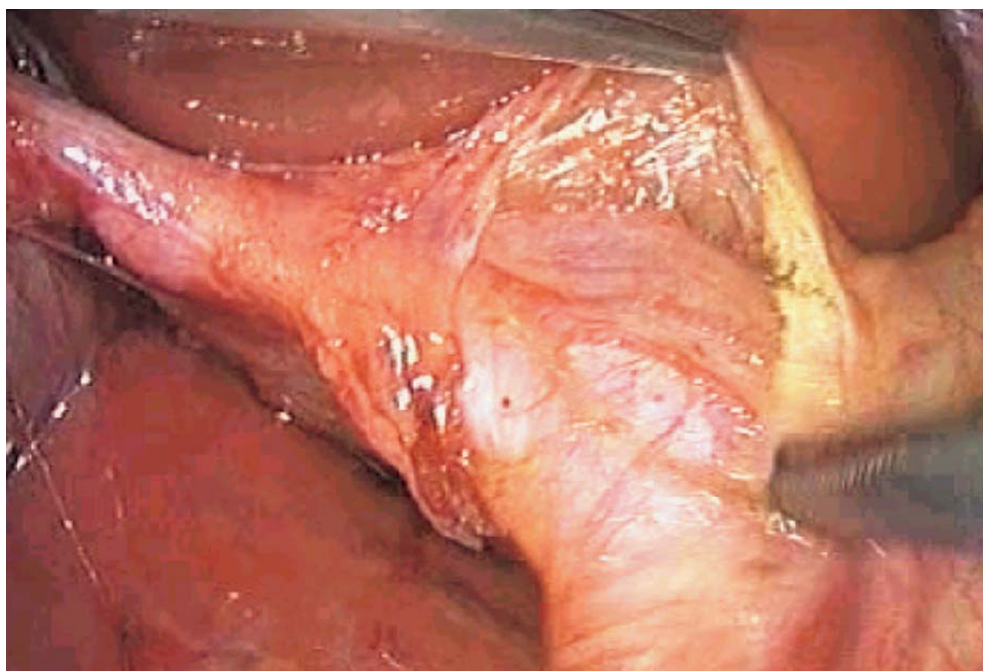

Fig. 2.7. Exposure of anterior CBD

second assistant. Coagulation of small vessels on the anterior part of the CBD is performed with coagulating shears (➤ Fig. 2.7). Choledochotomy is done with a retractable blade, either longitudinally or transversally (in case of a small CBD or small stones) (➤ Fig. 2.8). Dormia baskets and balloon catheters are introduced through a right lateral route.

### 2.8.2 Step 2: Stone Extraction and Checking for Residual Stones

Once the CBD has been opened, a retrieval bag is placed in the right subhepatic position in order to recover all CBD stones. The first manoeuvre consists of gentle pressure with a forceps on the CBD from distally to present stones at the choledochotomy site. Stones are removed and counted (➤ Figs. 2.9–2.11). Otherwise, Fogarty balloon catheter and Dormia baskets can be used. They are inserted directly into the choledochotomy, or under direct vision through the operating channel of the cholangioscope. An impacted stone may be destroyed by a contact lithotripsy catheter (Lithoclast) inserted through the operating channel of the cholangioscope. The fragments are then extracted with the above-mentioned techniques (➤ Fig. 2.14). The flexible cholangioscope is introduced through a protective cannula to check that the CBD is empty in both its extra- and intrahepatic portions (➤ Figs. 2.15–2.17). The lower CBD is fully explored.

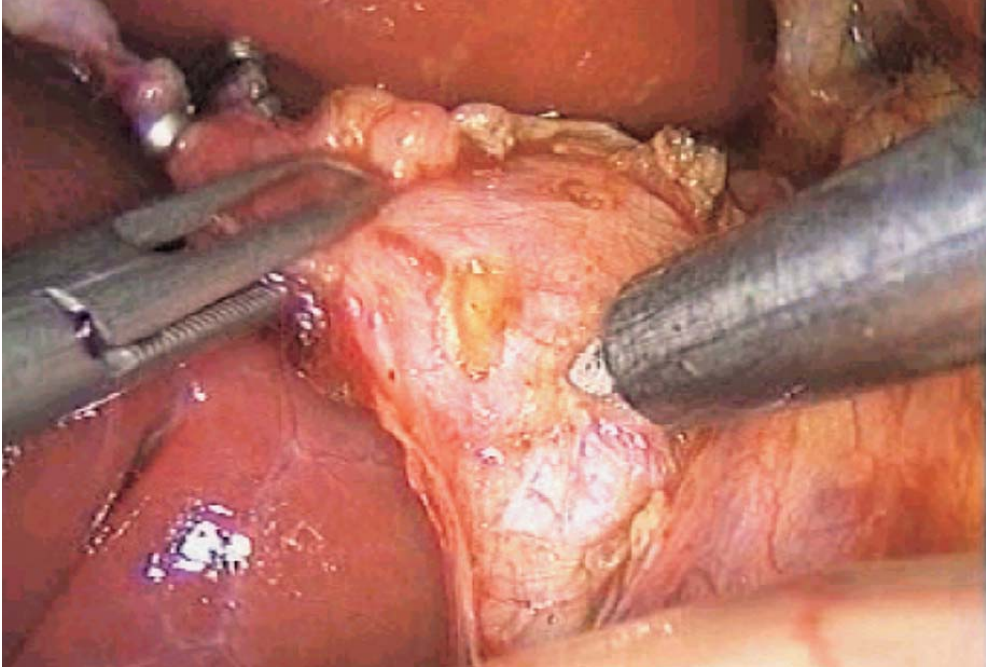


Fig. 2.8. Choledochotomy with retractable blade

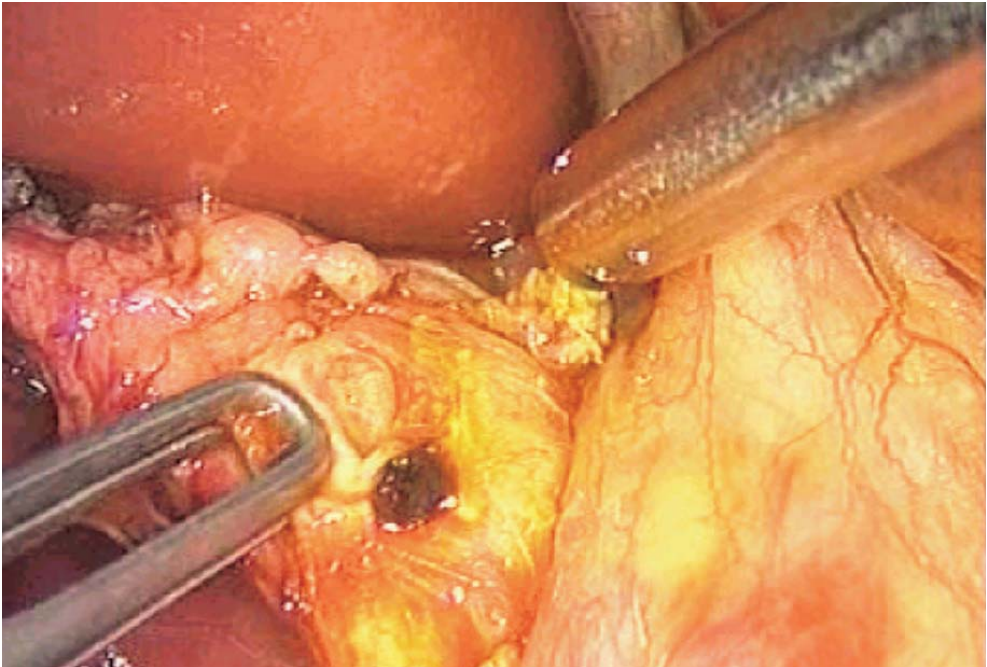


Fig. 2.9. Choledochotomy completed



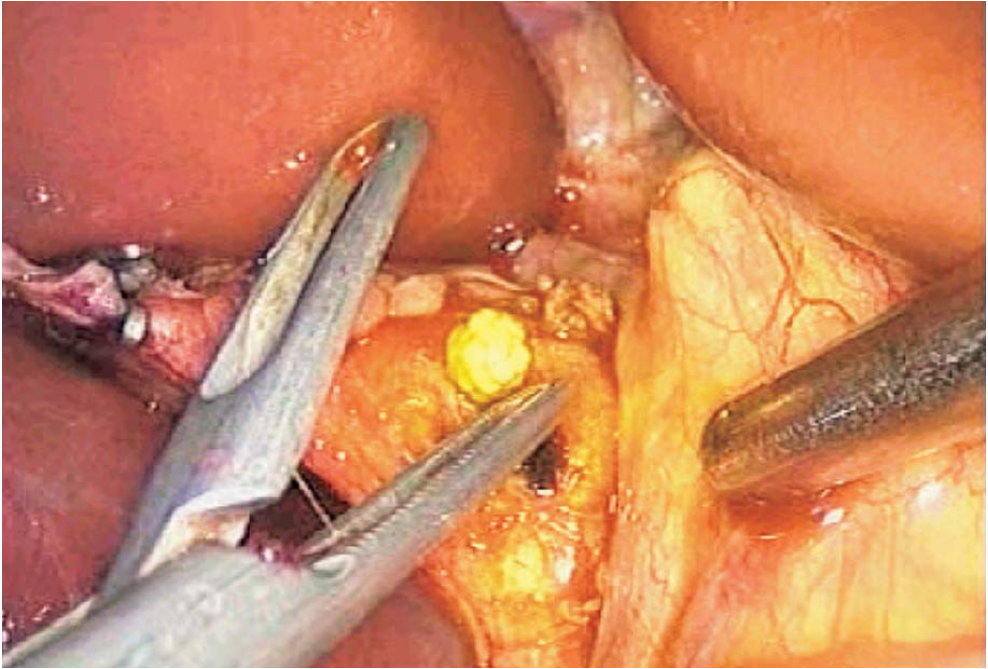


Fig. 2.10. Spontaneous stone discharge

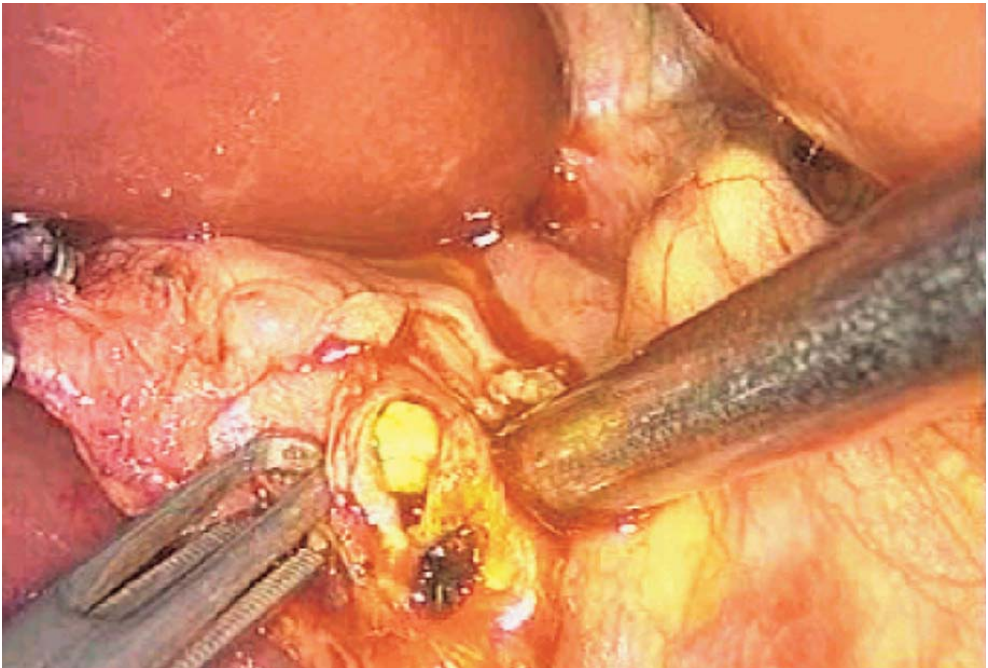


Fig. 2.11. Gentle stone expression

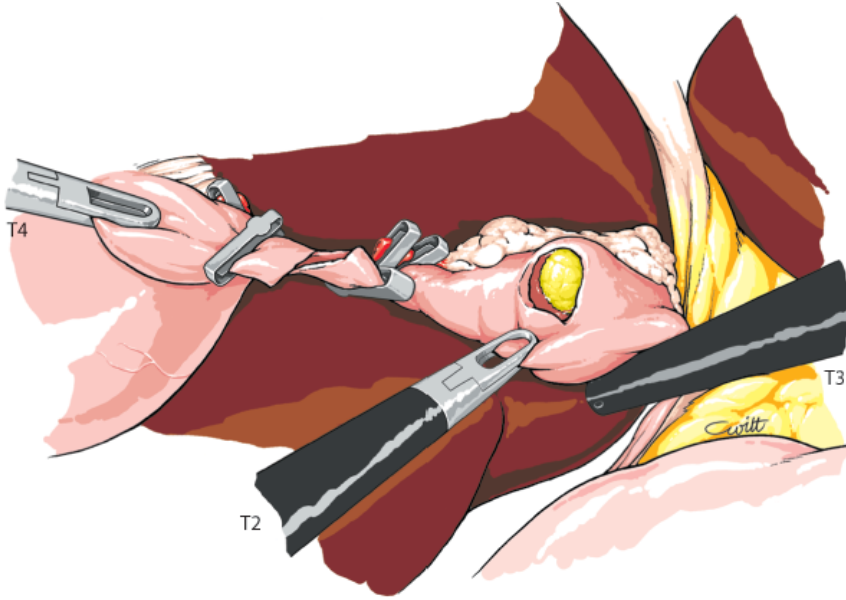


Fig. 2.12. Stone presenting at choledochotomy site

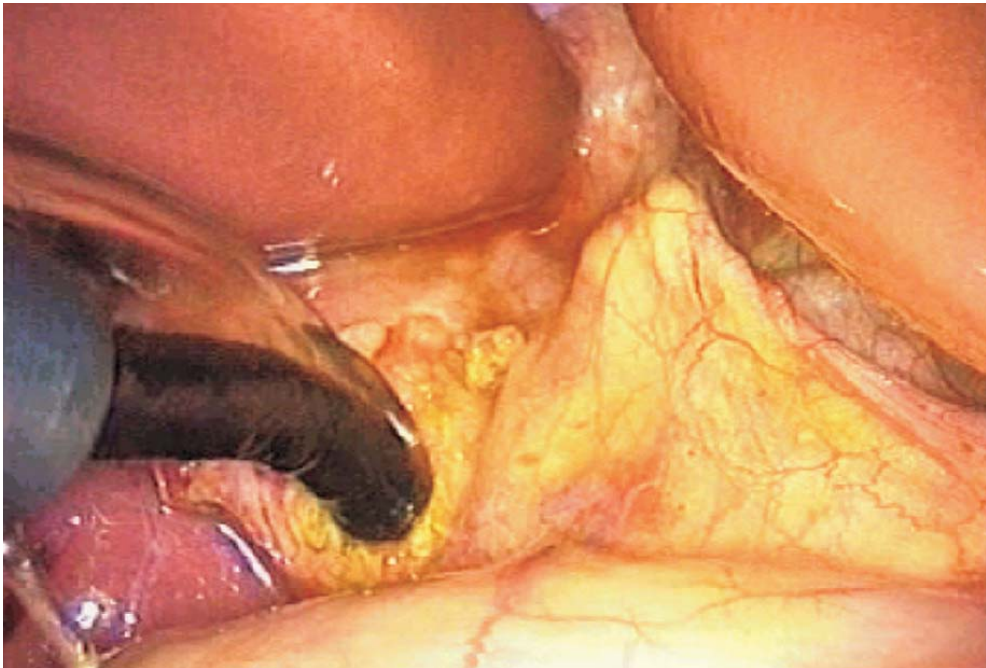


Fig. 2.13. Cholangioscopy

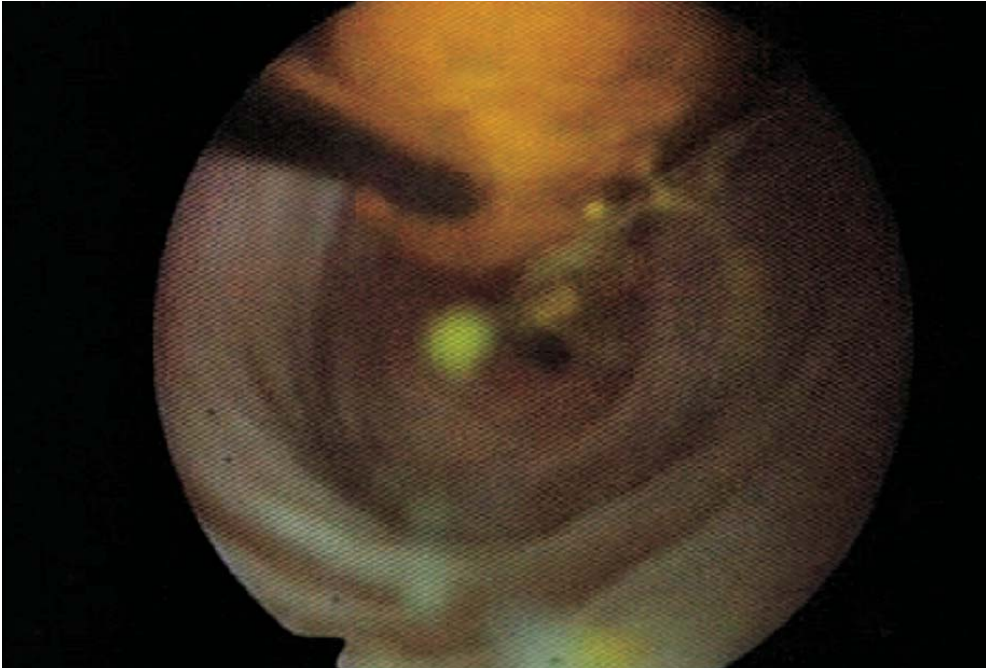


Fig. 2.14. Cholangioscopy: lithotripsy of a large stone

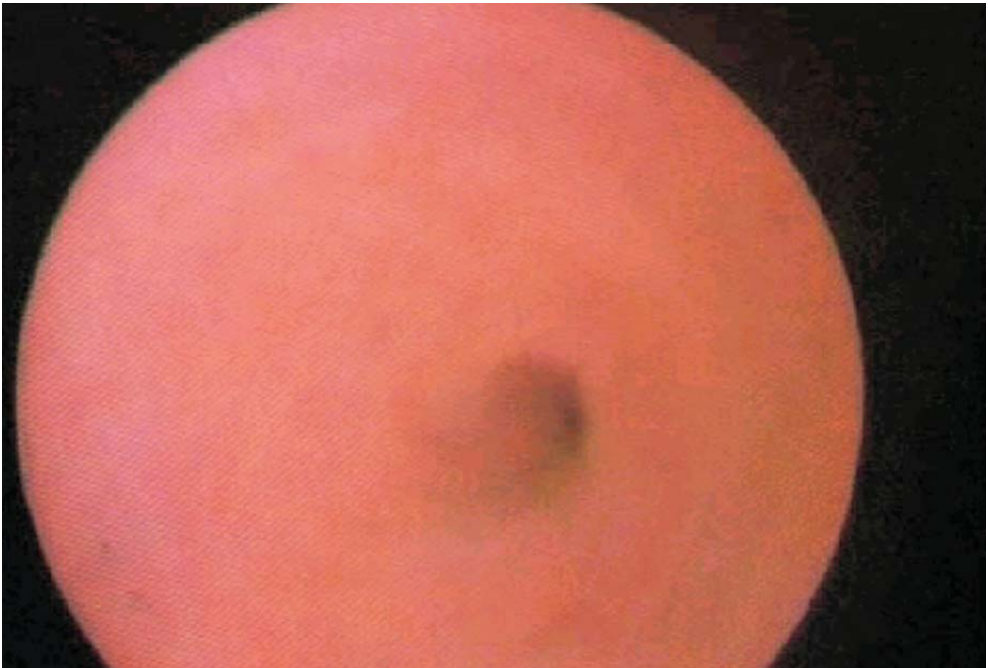


Fig. 2.15. Cholangioscopy: papilla



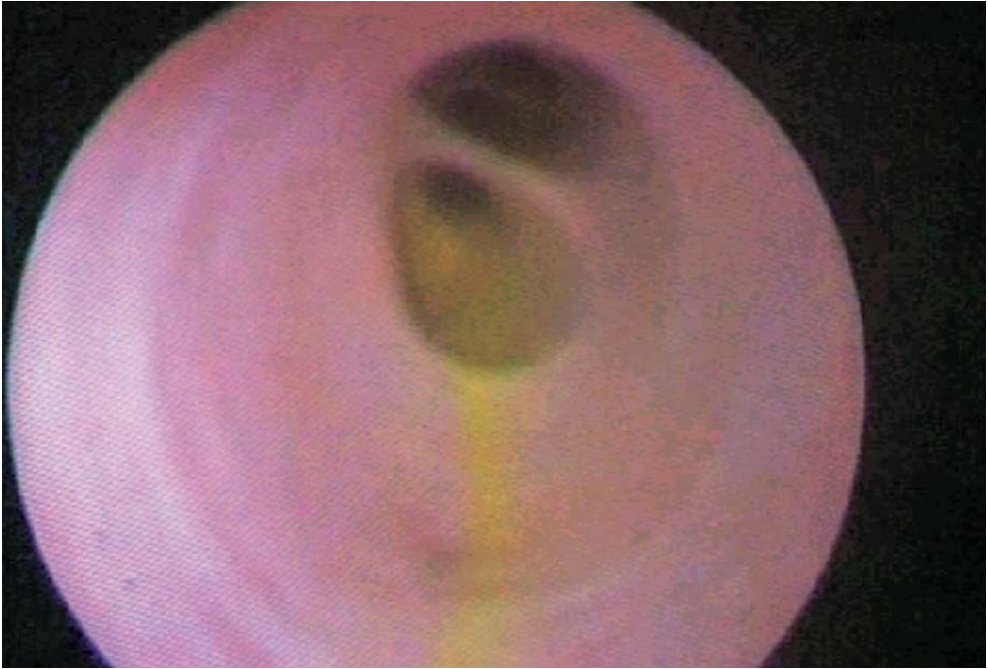


Fig. 2.16. Cholangioscopy: intrahepatic bile ducts

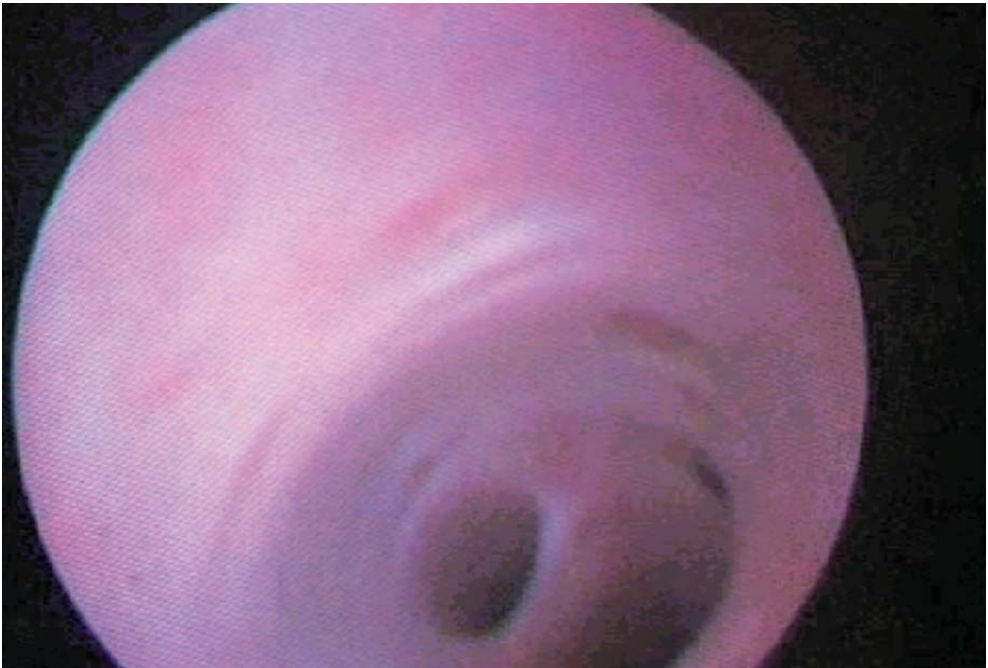

Fig. 2.17. Cholangioscopy: intrahepatic bile ducts

### 2.8.3 Step 3: Closure and Drainage of CBD (► Fig. 2.18)

The choledochotomy is closed with a 5/0 absorbable continuous suture. A T-tube or a transcystic drain may be left if there is major inflammation. In less inflammatory cases, primary closure of the CBD without drainage is possible (► Figs. 2.19–2.21).

## 2.9 Cholecystectomy (► Fig. 2.22)

Cholecystectomy is performed last. The cystic duct is divided. The cystic artery is dissected, clipped and divided (► Fig. 2.23). The gallbladder is freed from its hepatic attachments with coagulating shears.

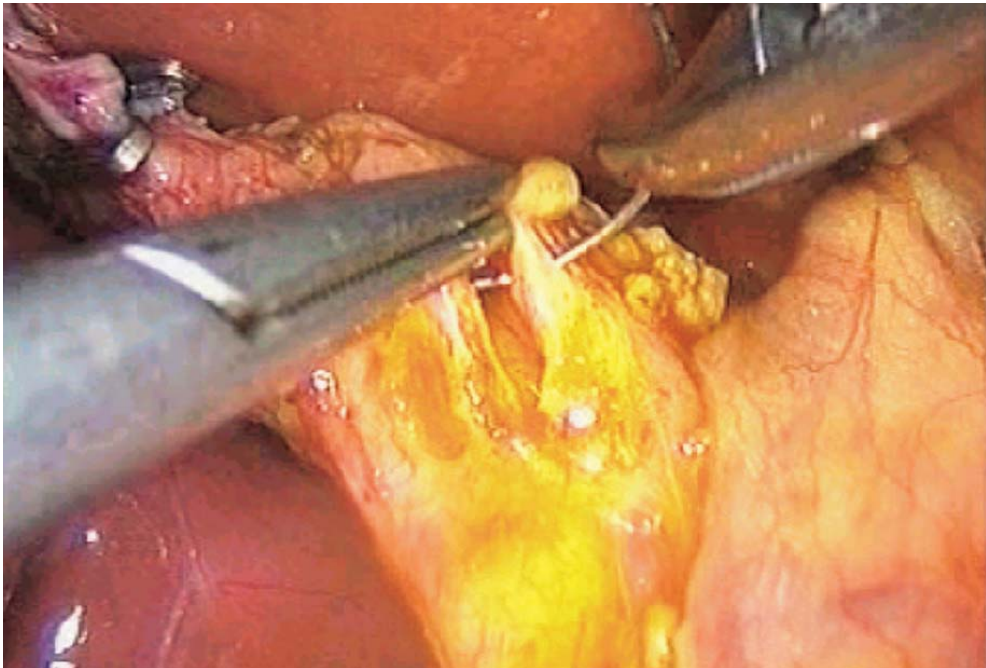


Fig. 2.18. Closure of CBD: beginning of suture



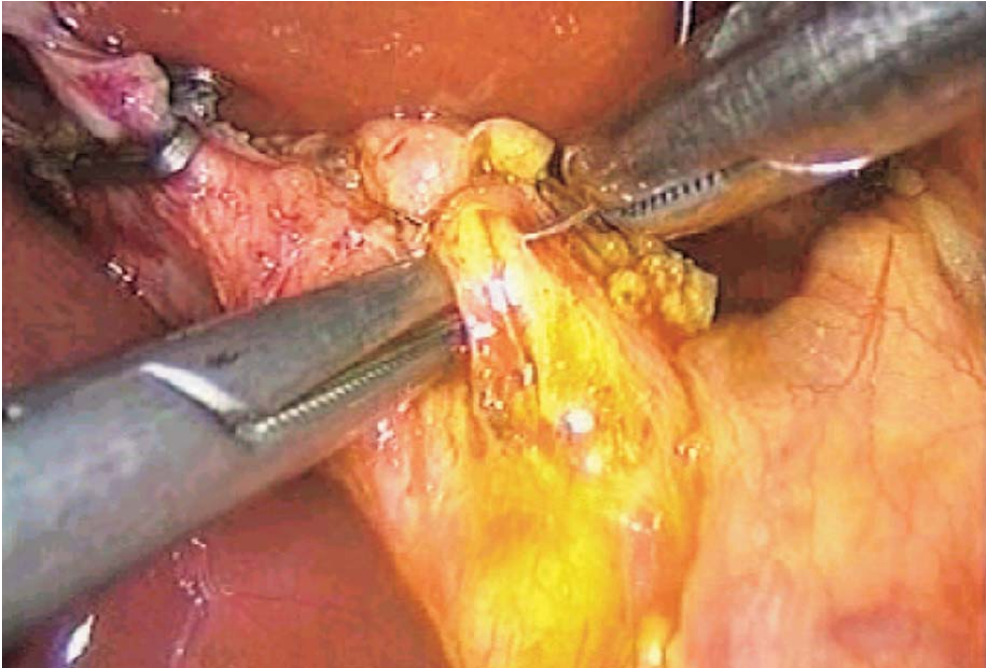


Fig. 2.19. Continuous suture on CBD

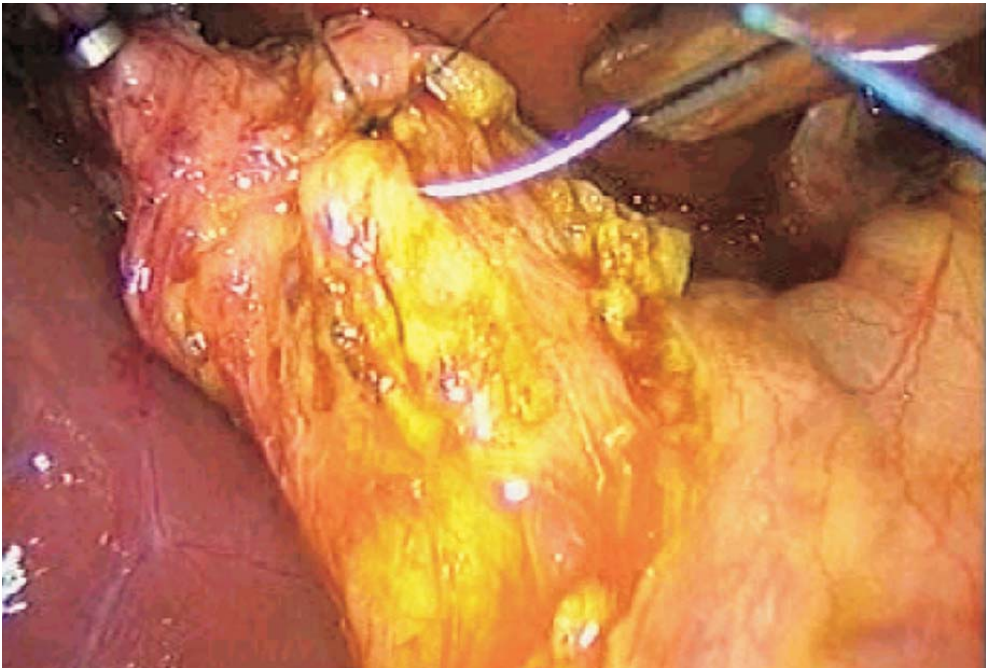


Fig. 2.20. Precise stitching

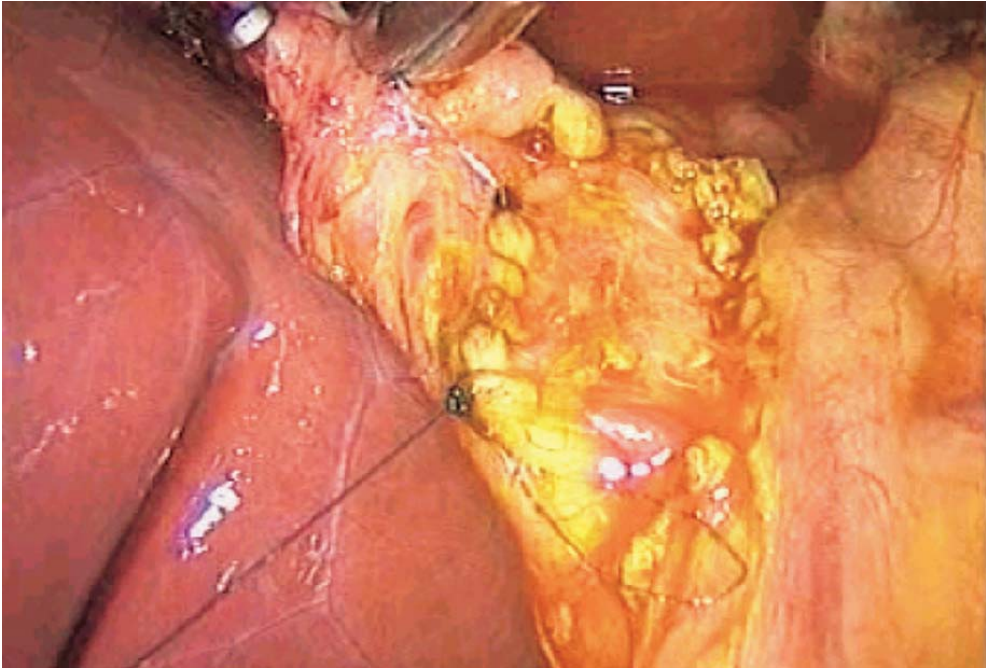


Fig. 2.21. End of suture on CBD

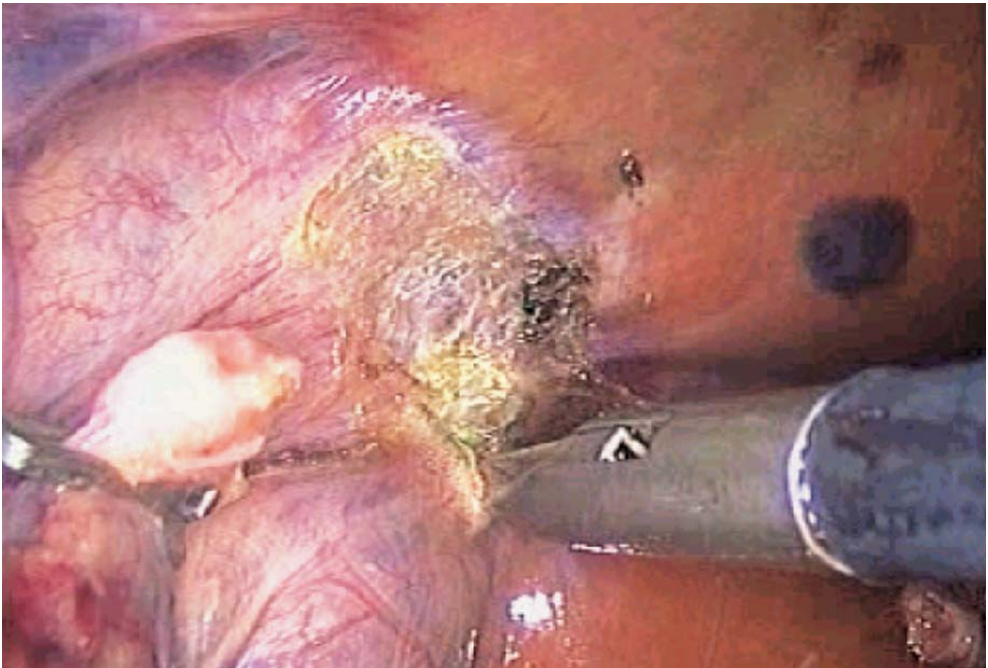

Fig. 2.22. Cholecystectomy

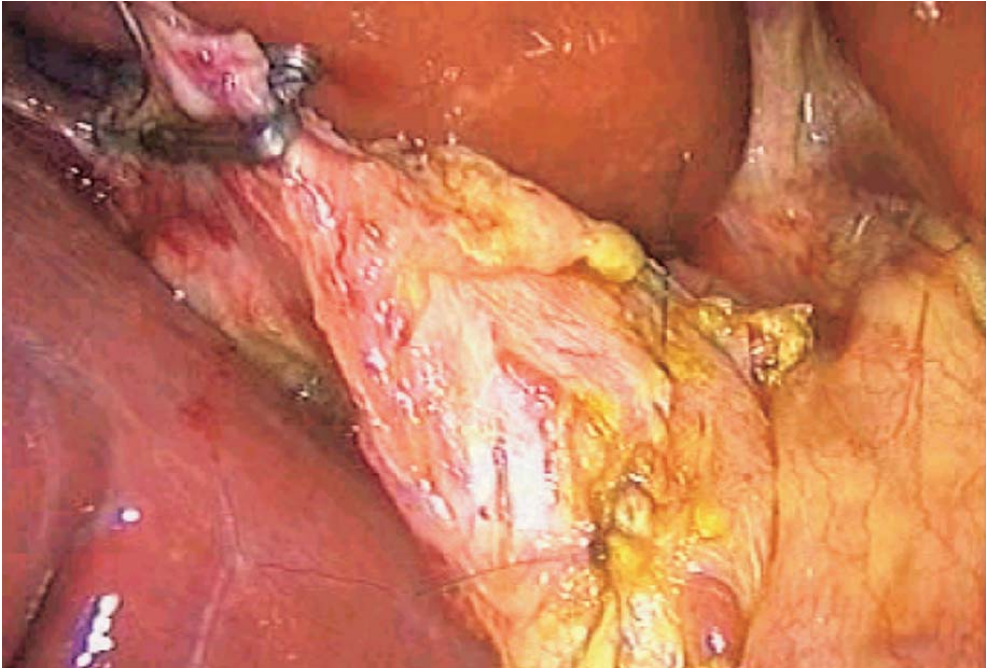


Fig. 2.23. Final check of CBD suture

## 2.10 Removal of Gallbladder and CBD Stones

The gallbladder and the CBD stones are removed with a retrieval bag. The peritoneal cavity is cleaned with saline. Subhepatic drainage is mandatory. The biliary drain, if present, is extracted through one of the lateral ports. Pneumoperitoneum is released. The port wounds are cleaned with saline and closed with everting absorbable sutures.

## 2.11 Tips and Comments

- Keeping cholecystectomy for the end allows better exposure of CBD by lateral traction during choledocholithotomy.
- Complete dissection of the distal cystic duct makes transcystic manoeuvres easier.
- Dissection of the CBD at the site of choledochotomy must be complete.
- Haemostasis of the CBD incision should be done with low-set coagulating shears during choledochotomy.
- The length of the choledochotomy must be adapted to the diameter of the cholangioscope in order to avoid excessive leakage. The incision can be widened according to the size of the stones.



- Gentle pressure on the CBD should be the first attempt at stone extraction.
- Failure to extract stones may lead to conversion to open surgery. In case of known residual stones, a biliary drain is left to help subsequent postoperative ERCP.
- The cholangioscope should be handled through its protective Teflon cannula. Even specifically manufactured forceps remain traumatic and may damage the endoscope.
- An extra dedicated instrument table should be used for the cholangioscopy material.
- The continuous suture of the choledochotomy terminates on three leads.

## Literature

- Aliperti G, Edmundowicz SA, Soper NJ (1991) Combined endoscopic sphincterotomy and laparoscopic cholecystectomy in patients with choledocholithiasis and cholecystolithiasis. *Ann International Med* 115:783–785
- Bagnato VJ, Mcgee GE, Hatten LE et al (1991) Justification for routine cholangiography during laparoscopic cholecystectomy. *Surg Laparosc Endosc* 1:89–93
- Baumel H, Domergue J (1991) Cholécystectomie coelioscopique. *Press Med* 20:678
- Belghiti J, Sauvanet A (1990) La cholangiographie per opératoire a t-elle vécue? *Actualités digestives* 3:115–117
- Corbitt JD, Cantwelle D (1991) Laparoscopic cholecystectomy with operative cholangiogram. *Surg Laparosc Endosc* 1:229–232
- Dubois F, Icard P, Berthelot G et al (1990) Approche chirurgicale simplifiée de la lithiase cholédocienne, réduisant la complexité et la gravité de cette chirurgie; 153 cas. *Ann Chir* 44:19–23
- Gigot JF, Navez B (Personal communication) Techniques et résultats du traitement coelioscopique de la lithiase cholédocienne en cours de cholécystectomie laparoscopique. The Belgian group for endoscopic surgery
- Handy JE, Rose SC, Nieves AS et al (1991) Intraoperative cholangiography: use of portable fluoroscopy and transmitted images. *Radiology* 181:205–207
- Hauer-Jensen M, Karesen R, Nygaard K et al (1986) Consequences of routine peroperative cholangiography during cholecystectomy for gallstone disease: a prospective, randomized study. *World J Surg* 10:996–1002
- Houdart R, Brisset D, Perniceni T et al (1990) La cholangiographie intra-veineuse est inutile avant cholécystectomie pour lithiase non compliquée: étude prospective de 100 cas. *Gastroenterol Clin Biol* 14:652–654
- Huguier M, Bornet P, Charpak Y (1991) Prédiction d'une lithiase de la voie biliaire principale (VBP). *Ann Chirurgie* 45:938
- Hunter JG (1992) Laparoscopic transcystic common bile duct exploration. *Am J Surg* 163:53–58
- Jakimowicz J (1991) Intraoperative vs. postoperative biliary endoscopy: intraoperative ultrasonography vs. sonography during laparoscopic cholecystectomy. *Problems in general surgery. Laparosc Surg* 8:442–457
- Joyce WP, Keane R, Burke GJ (1991) Identification of bile duct stones in patients undergoing laparoscopic cholecystectomy. *Br J Surg* 78:1174–1176
- Mallet G (1976) La cholangiographie opératoire dans la presse chirurgicale anglo-saxonne. *Lyon Chirurgical* 72:369–374
- Mills JL, Beck DE, Harford FJ et al (1985) Routine operative cholangiography. *Surg Gynecol Obstetric* 161:343–345

- Moreaux J, Horiot A (1982) La désobstruction de la voie biliaire principale par voie transcystique. *J Chir (Paris)* 119:193–194
- Motson RW, Wetter A (1990) Operative choledoscopy: common bile duct exploration is incomplete without it. *Br J Surg* 77:975–982
- Petelin JB (1991) Laparoscopic approach to common duct pathology. *Surg Laparosc Endosc* 1: 33–41
- Phillips EH, Carroll B (1991) New techniques for the treatment of common bile duct calculi encountered during laparoscopic cholecystectomy. *Problems in general surgery. Laparosc Surg* 8:387–394
- Ponchon T, Valette PJ, Henry L et al (1992) Cholédoscopie percutanée. XIV<sup>e</sup> Journées de pathologie digestive, Nice
- Sackier JM, Berci G, Phillips E et al (1991) The role of cholangiography in laparoscopic cholecystectomy. *Arc Surg* 126:1021–1026
- Schively EH, Wieman TJ, Adams AL (1990) Operative cholangiography. *Am J Surg* 159:380–385
- Spaw AT, Reddick EJ, Olsen DO (1991) Laparoscopic laser cholecystectomy: analysis of 500 procedures. *Surg Laparosc Endosc* 1:2–7
- Stoker ME (1991) Laparoscopic common duct exploration; 3rd Intern meeting of Summit, Boston
- Thompson JE, Bennion RS (1988) Intraoperative endoscopy of the biliary tract. *Surg Endosc* 2:172–175
- Unger SW, Edelman DS, Scott JS et al (1991) Laparoscopic treatment of acute cholecystitis. *Surg Laparosc Endosc* 1:14–16

---

### 3 Laparoscopic Fundoplication for GERD: Laparoscopic Nissen and Toupet Fundoplication

#### 3.1 Operating Room Setup: Position of the Patient

The patient under general anaesthesia is placed supine with a slight 10° reverse Trendelenburg position. The surgeon stands between the patient's legs. The first assistant is on the patient's right side and the second assistant on the surgeon's right side (➤ Fig. 3.1). The monitor and laparoscopy rack are placed left of the patient's head.

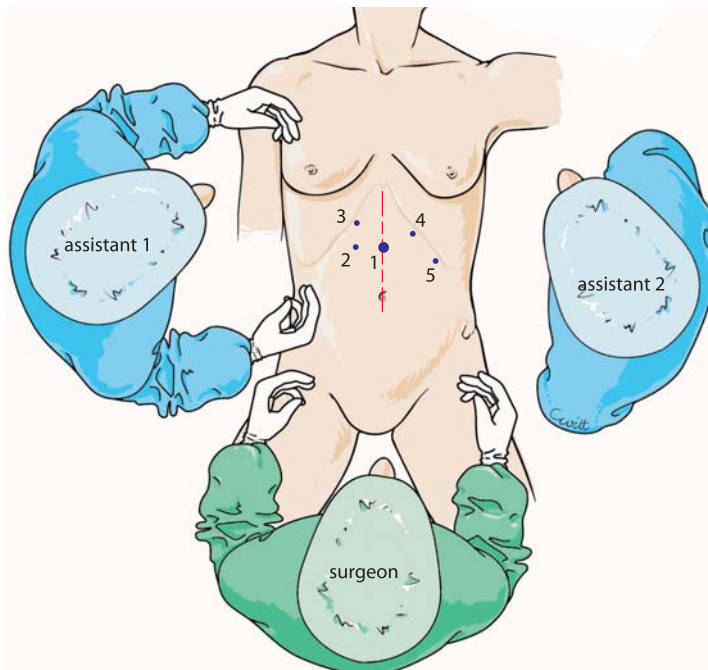


Fig. 3.1. OR setup – trocar position

### 3.2 Recommended Instruments

- A 0° straight endoscope
- One 10-mm trocar
- Four 5-mm trocars
- Two 5-mm Johan fenestrated grasping forceps
- Straight or curved 5-mm coagulating shears
- A straight 5-mm grasping forceps
- A 5-mm needle holder
- A 5-mm suction cannula
- Hooked 5-mm grasping forceps
- A 36F Faucher tube
- Harmonic scalpel, if available

### 3.3 Trocar Placement and Exposure: Dissection of Hiatus

The 10-mm trocar is placed in the middle of the xipho-umbilical line. The left operating trocar is placed 5 cm lateral to the right of the first trocar. The right operating trocar is placed in the left subcostal region. A third 5-mm left lateral subcostal trocar is placed for purposes of exposure. A final 5-mm right median subcostal trocar allows retraction of the liver. In obese patients, the latter trocar is placed closer to the xiphoid process.

The hiatus is defined by the two pillars of the diaphragm. Operative strategy consists of opening the visceral peritoneum medially around the pillars, irrespective of the size of the hiatal enlargement.

The first step is to reduce the stomach by gentle traction with the left lateral forceps placed on the anterior part of the stomach. The left lobe of the liver is then reclined by the right subcostal forceps (▶ Fig. 3.2). It is kept in place by attaching it to the diaphragm at the top of the right pillar. A 5-mm adjustable retractor may be used for this.

The pars flaccida of the lesser omentum is opened with coagulating shears. The right pillar is thus exposed. A left hepatic artery, if present, must be preserved (▶ Fig. 3.3).

The right crus is freed from its peritoneal adhesions from bottom to top. Mediastinal dissection is begun and the oesophagus is lowered (▶ Fig. 3.4). The V shape of the hiatus is reached, and the start of the left crus is identified (▶ Figs. 3.5–3.7) and then freed whilst pulling the stomach to the right. This exposes the gastrophrenic ligament, which is gradually resected.

The exposure is again modified by leftwards traction on the stomach. The dissection of the inferior part of the left crus is continued until the V-shaped origin of both crura is dissected (▶ Fig. 3.8). Lateral dissection of the left crus creates a retro-oesophageal window (▶ Figs. 3.9, 3.10).



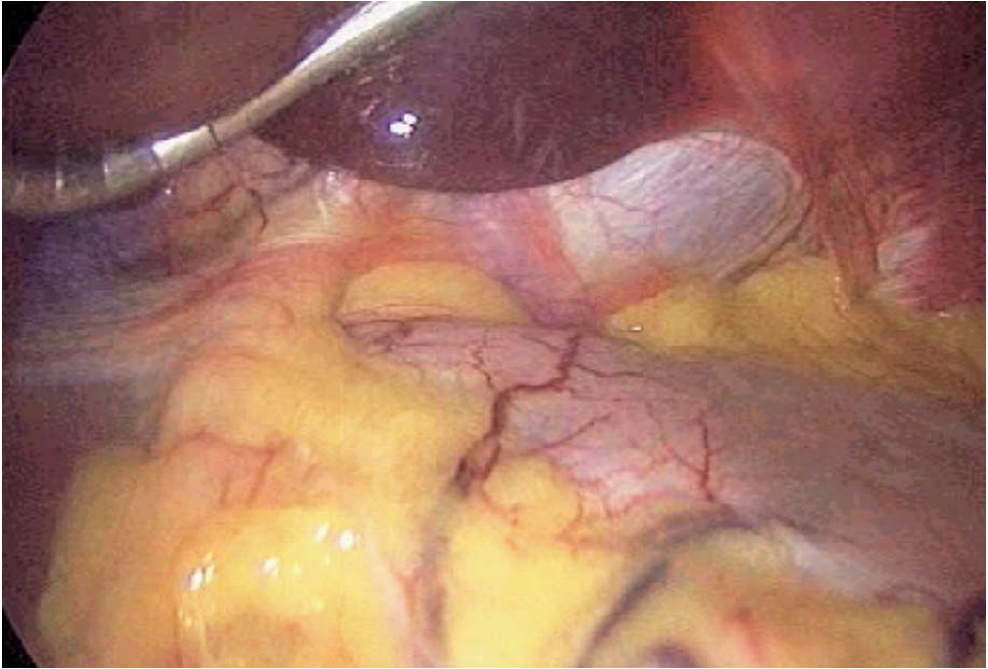


Fig. 3.2. Exposure with liver retractor

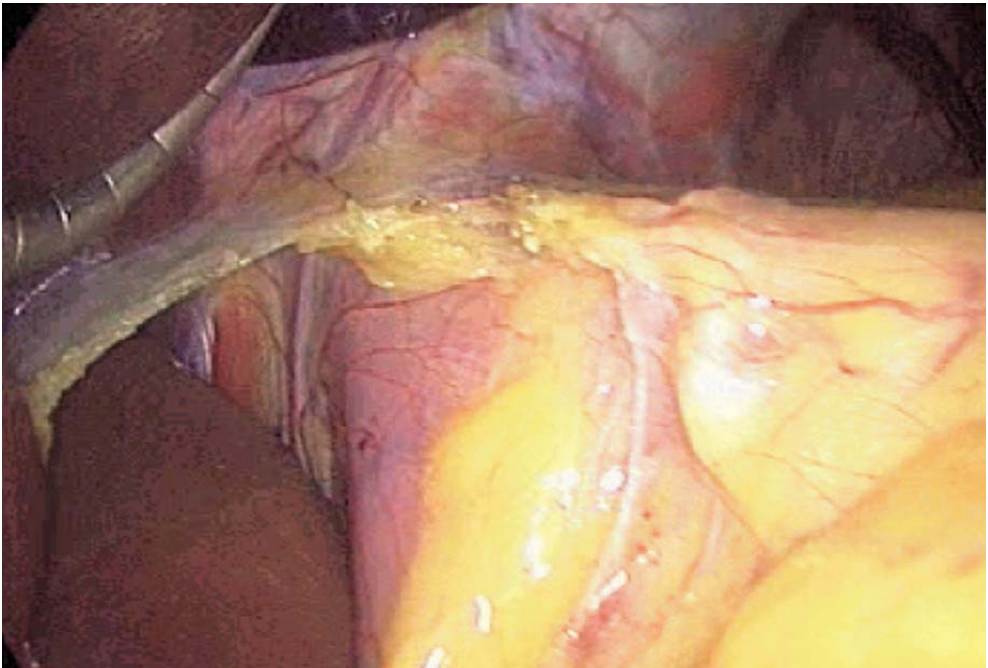


Fig. 3.3. Opening of lesser omentum

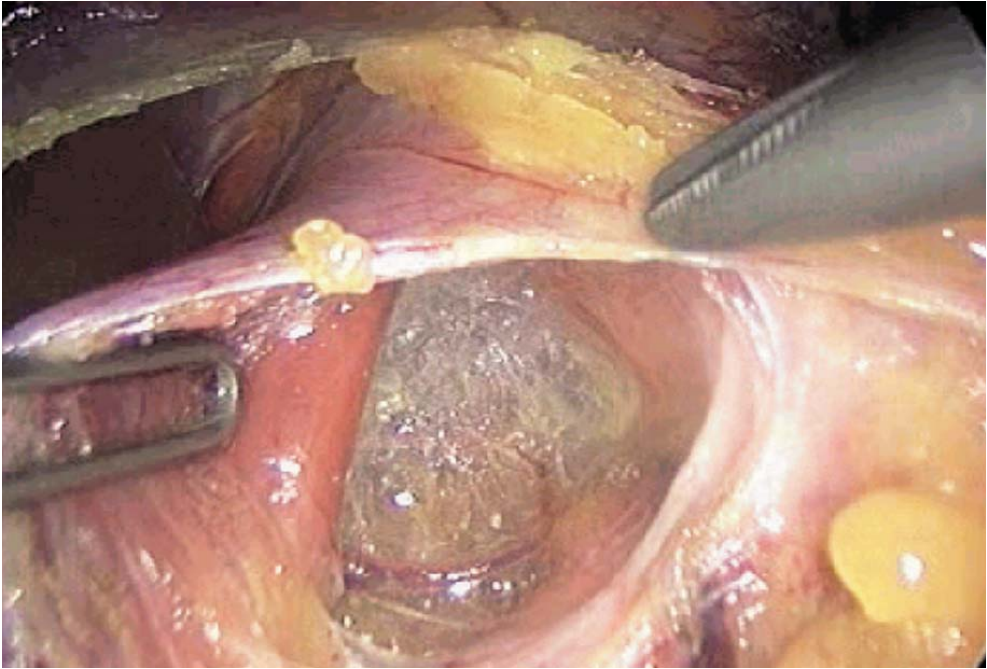


Fig. 3.4. Exposure of right crus

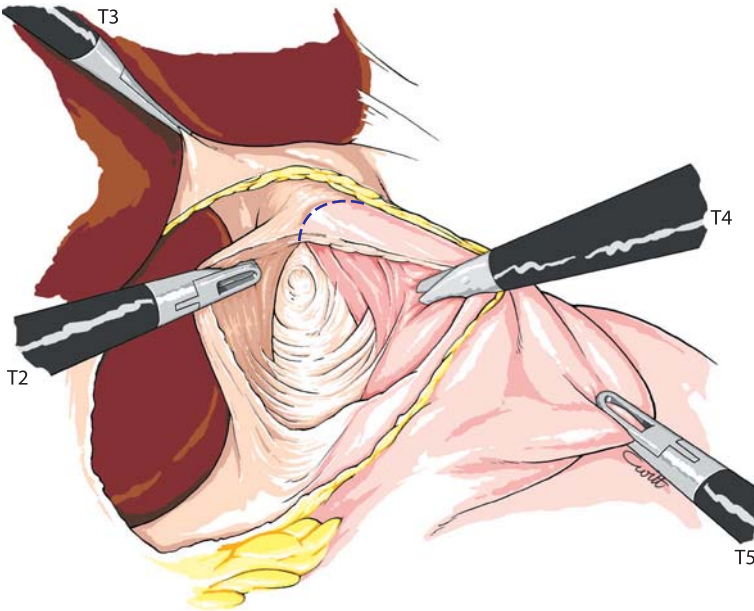
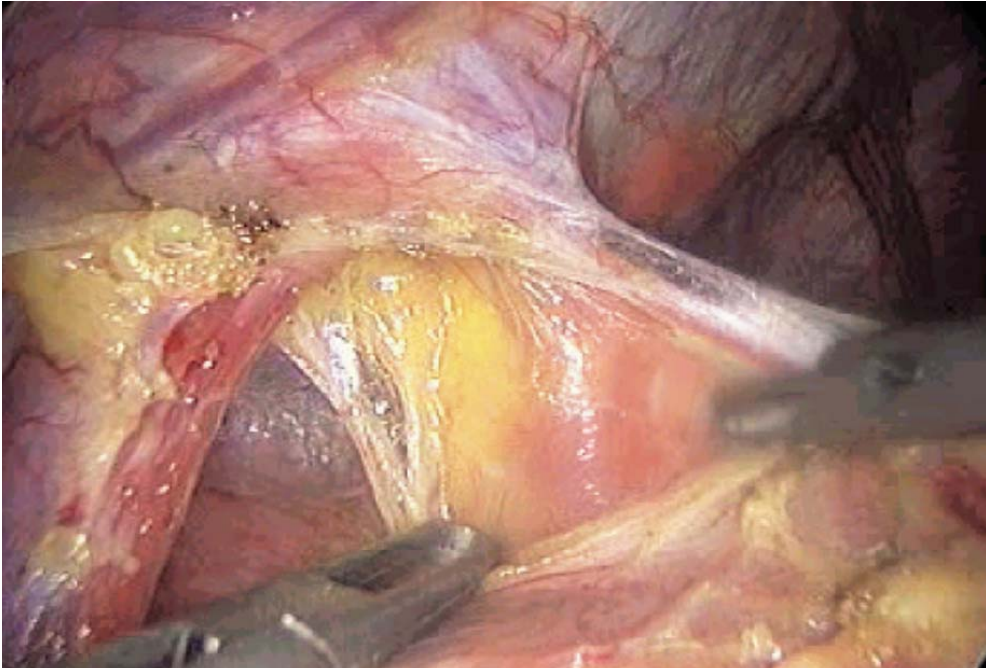
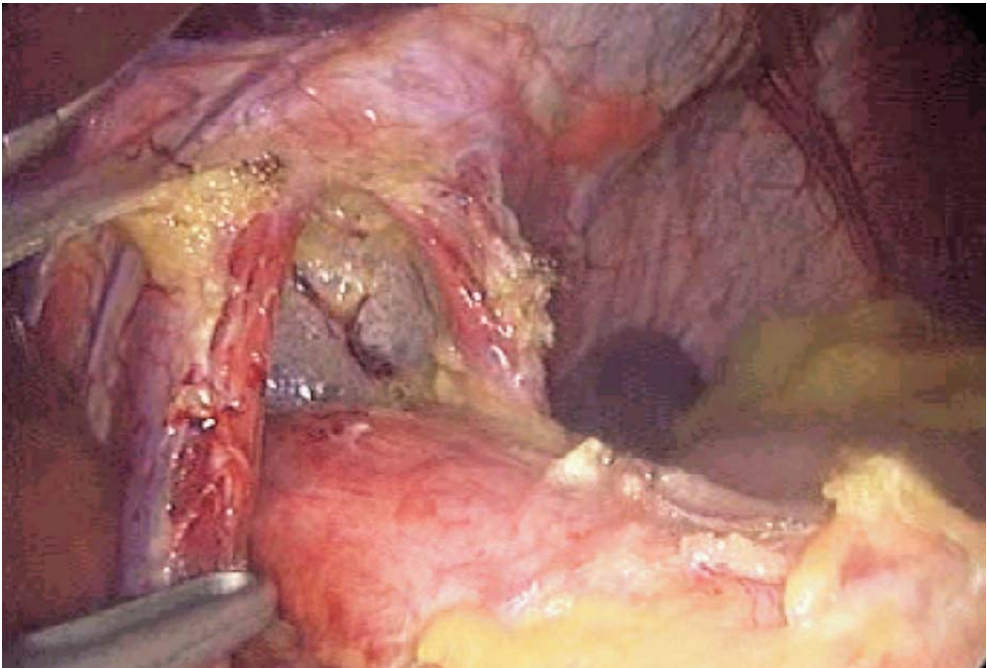


Fig. 3.5. Dissection of right crus

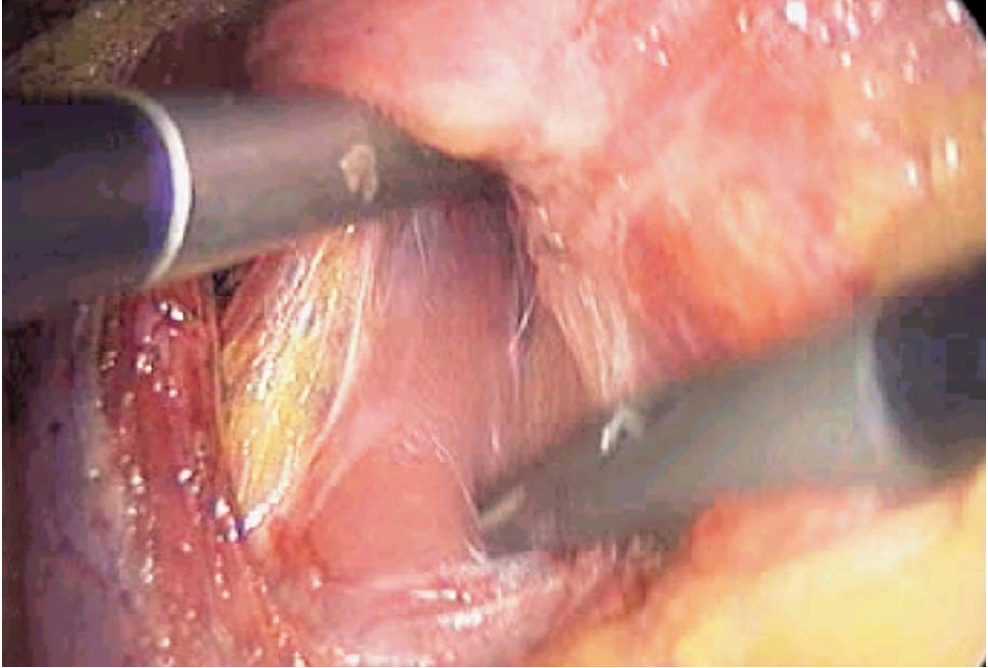


**Fig. 3.6. Exposure of left crus**

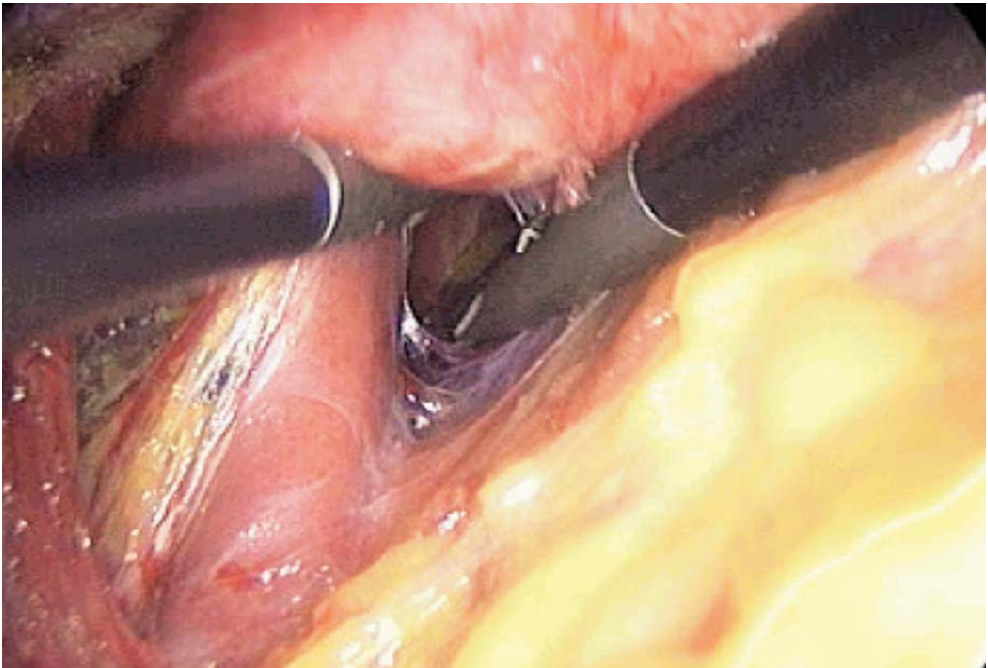


**Fig. 3.7. Completed anterior dissection**





**Fig. 3.8. Dissection of lower part of left crus behind the oesophagus**



**Fig. 3.9. Creating a retro-oesophageal window**

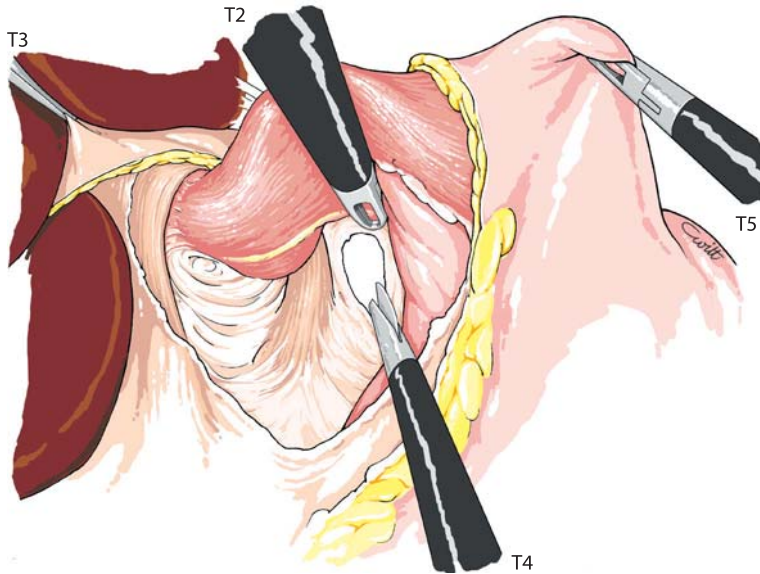
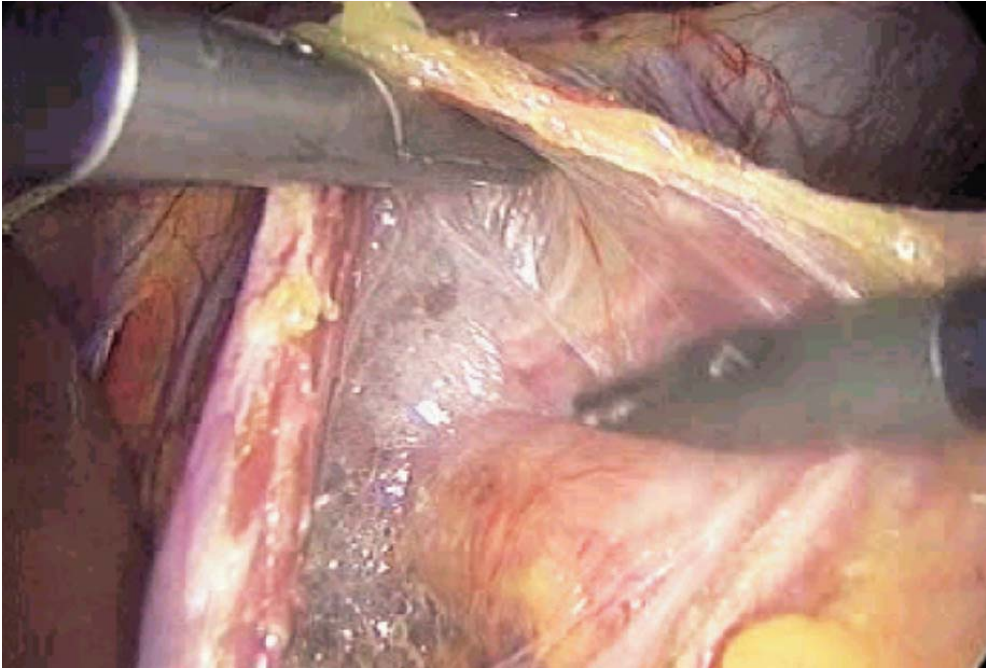


Fig. 3.10. Retro-oesophageal window

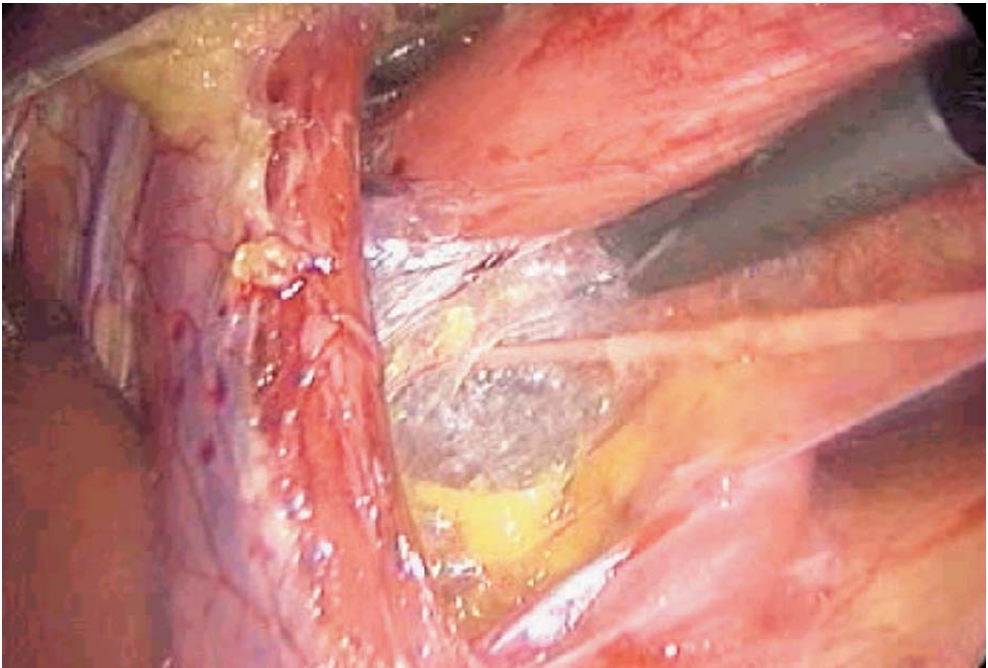
Dissection of the hiatus is then complete. This dissection can be performed with the coagulating shears or the harmonic scalpel. The oesophagus is centred on the hiatus. If there were a large hiatal defect, a visceral peritoneal collar would be seen on the oesophagus.

### 3.4 Oesophageal Dissection (► Fig. 3.11)

Dissection is continued inside the mediastinum by bluntly opening the web-like tissue. The pleura are pushed back. The vagus nerves are left in close contact with the oesophagus (► Fig. 3.12). The oesophagus is freed for 5–10 cm to gain intra-peritoneal length.



**Fig. 3.11. Dissection of oesophagus inside the mediastinum**



**Fig. 3.12. Exposure of right vagus nerve**



### 3.5 Mobilization of the Fundus

The fundus is gradually freed from its diaphragmatic attachments, especially by complete sectioning of the gastrophrenic ligament (▶ Fig. 3.13). If the fundus cannot be mobilized, control of short gastric vessels is carried out with clips or, better, with the harmonic scalpel. Exposure is ensured by traction on the stomach and gastrophrenic ligament. The stomach is thus sufficiently mobilized and the fundus is grasped behind the oesophagus through the retro-oesophageal window with a fenestrated forceps introduced from the right side (▶ Figs. 3.14–3.16). A retro-oesophageal wrap is created.

### 3.6 Closure of the Hiatal Defect

The hiatus should always be closed by suturing both crura. Exposure is obtained by traction on the gastric wrap with a left-sided forceps. Two or three interrupted sutures of nonabsorbable multifilament are placed on the inferior part of the crura (▶ Fig. 3.17). Intracorporeal knotting is best.

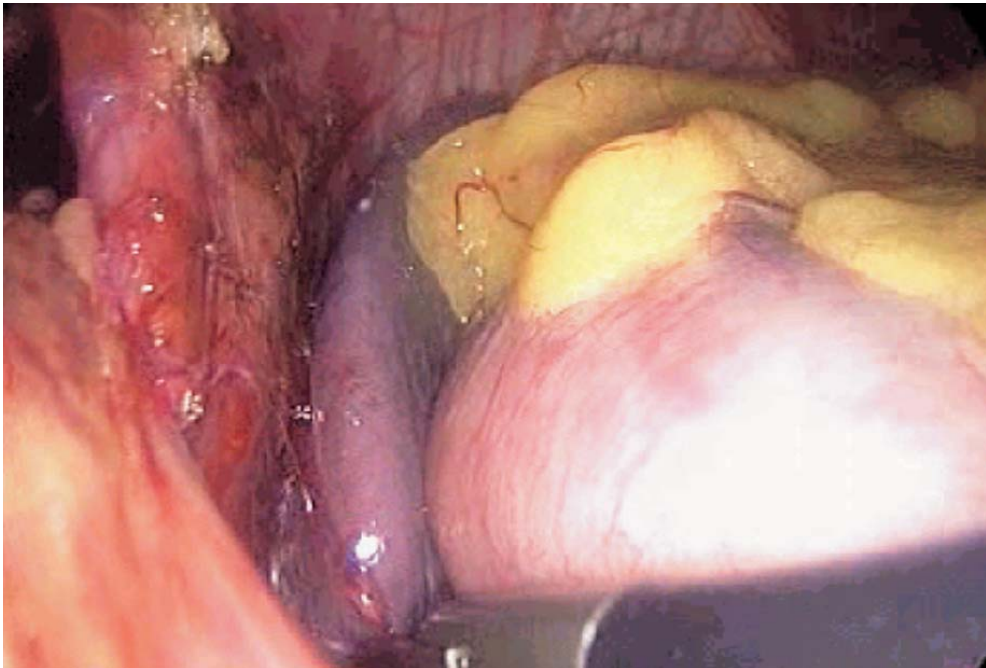


Fig. 3.13. Freeing gastro phrenic attachments



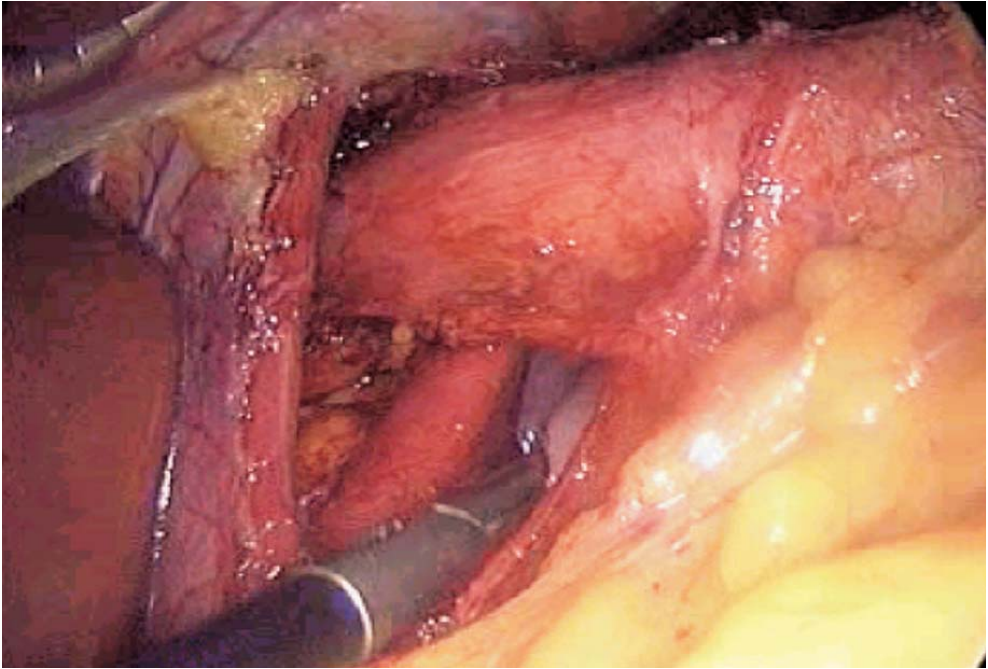


Fig. 3.14. Selecting the wrap

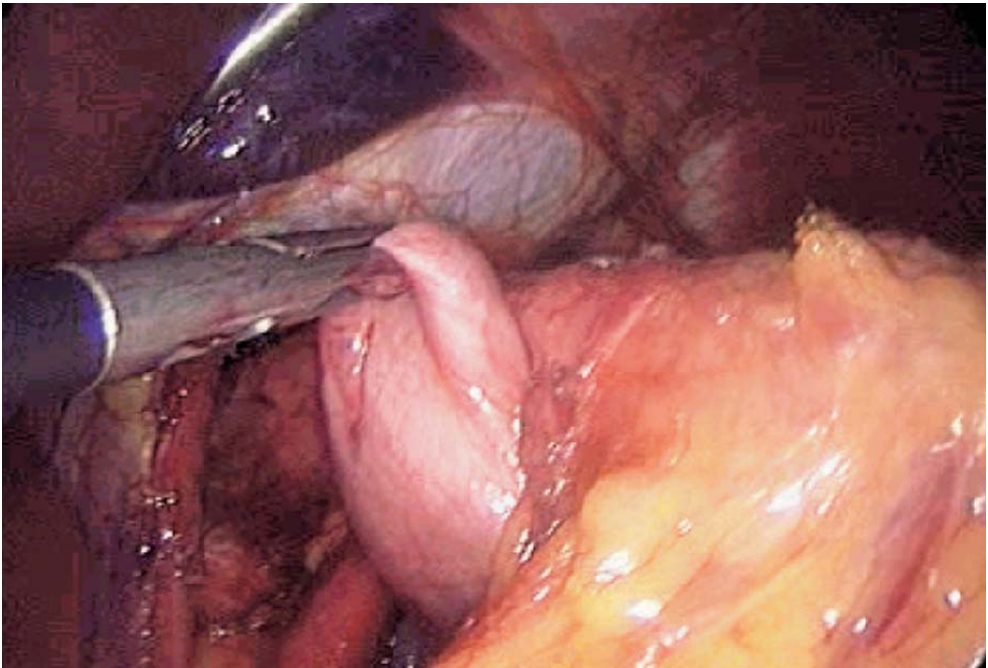


Fig. 3.15. Pulling the wrap behind the oesophagus

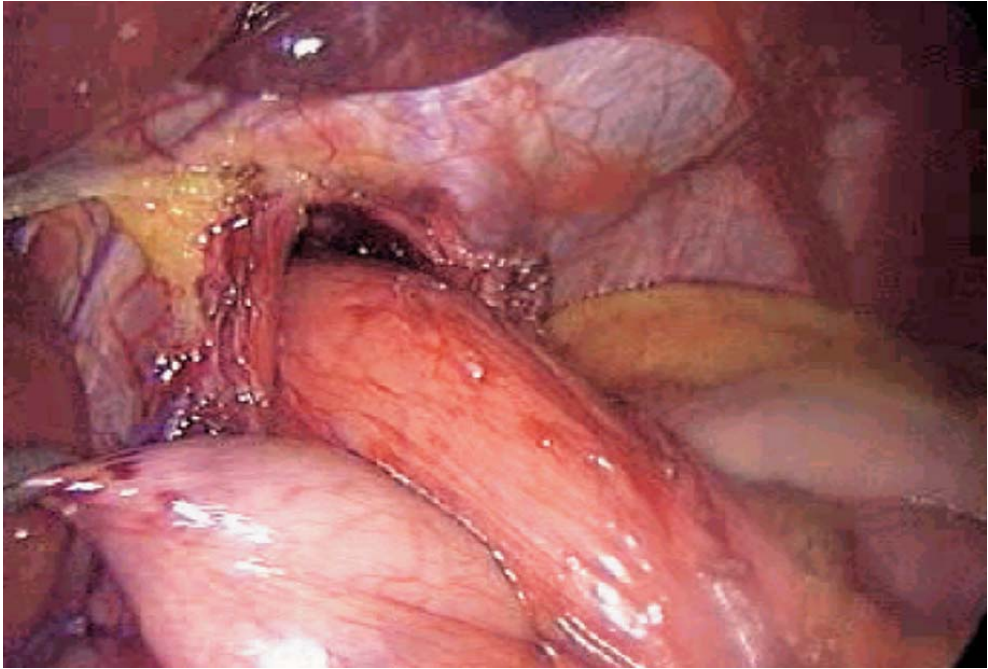


Fig. 3.16. Placing the wrap

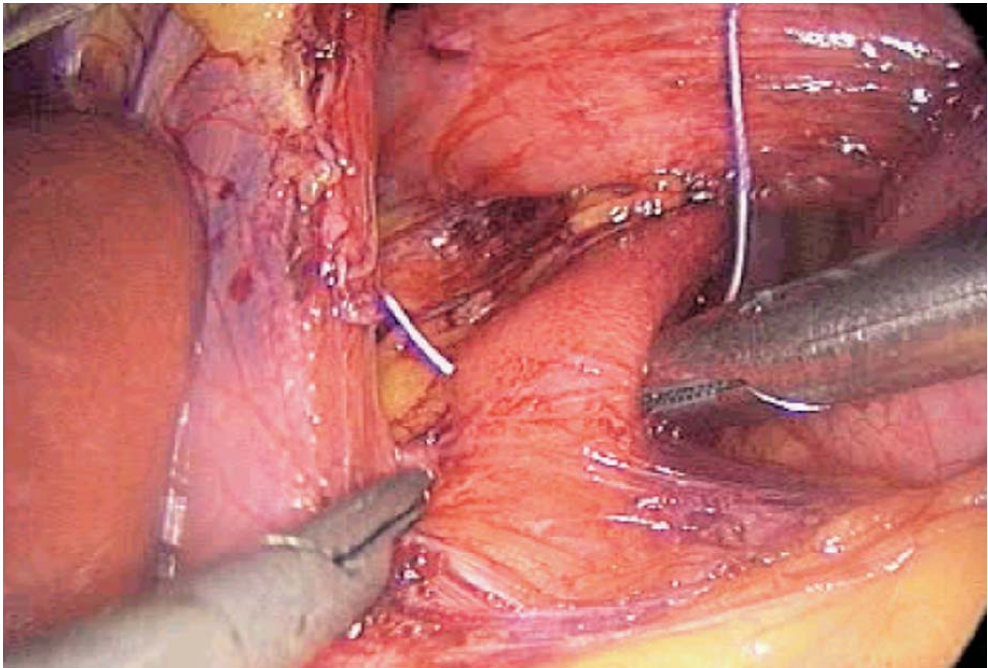


Fig. 3.17. Suturing the crura

### 3.7 Creating an Anti-reflux Wrap

Two types of gastric valve may be created. Most cases require a 270° partial posterior valve according to Toupet. In case of a large or modified hiatus, however, we prefer a complete 360° Nissen-type valve.

### 3.8 Toupet 270° Fundoplication

The left lateral grasping forceps exposes the esogastric junction. Usually the last suture may fix the gastric valve posteriorly on the crura (▶ Fig. 3.18). The right part of the gastric valve is sutured to the oesophagus with three or four interrupted sutures of nonabsorbable 2/0 multifilament, after locating the vagus nerve on the oesophageal wall (▶ Fig. 3.19).

The left part of the gastric valve is sutured in an identical and symmetrical manner, while respecting the anterior vagus nerve. The anterior part of the oesophagus is left free for 2 cm (▶ Figs. 3.20, 3.21).

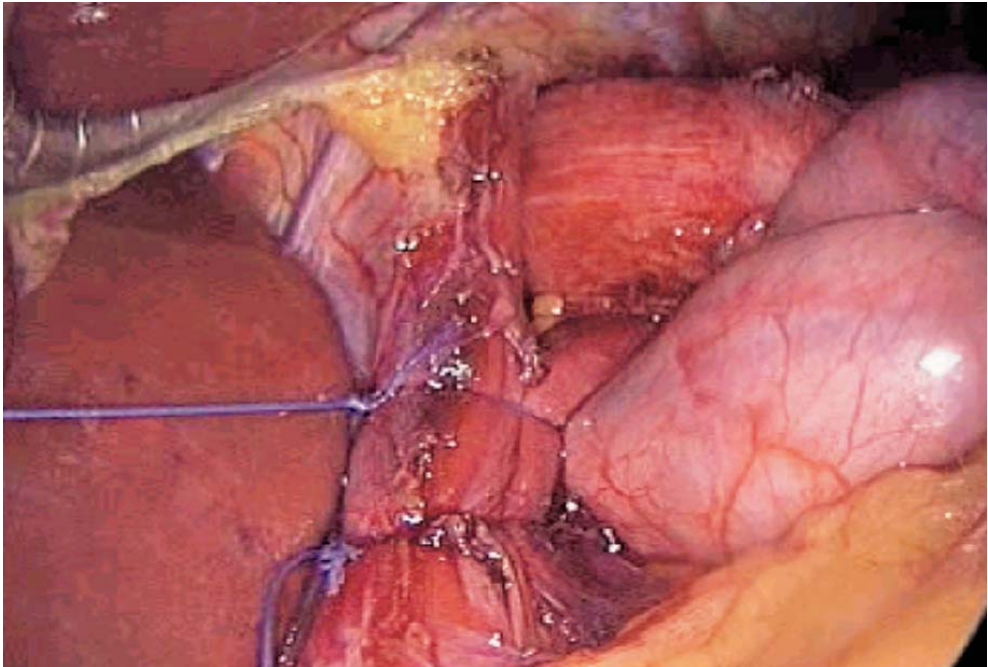


Fig. 3.18. The wrap is sutured posteriorly to the closed crura



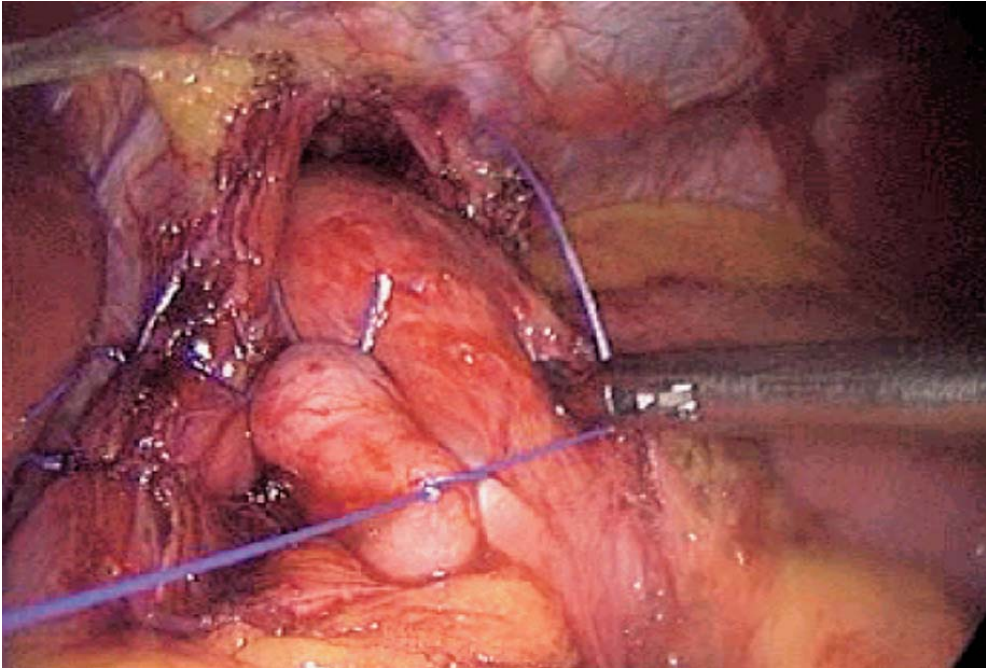


Fig. 3.19. Toupet: creating the right part of the wrap

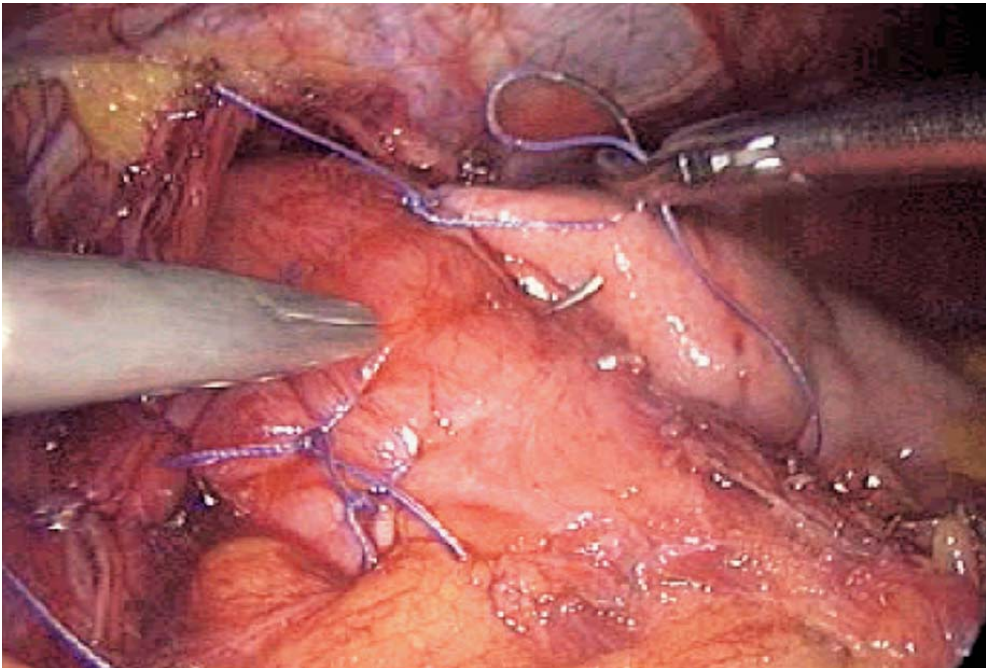


Fig. 3.20. Toupet: creating the left part of the wrap

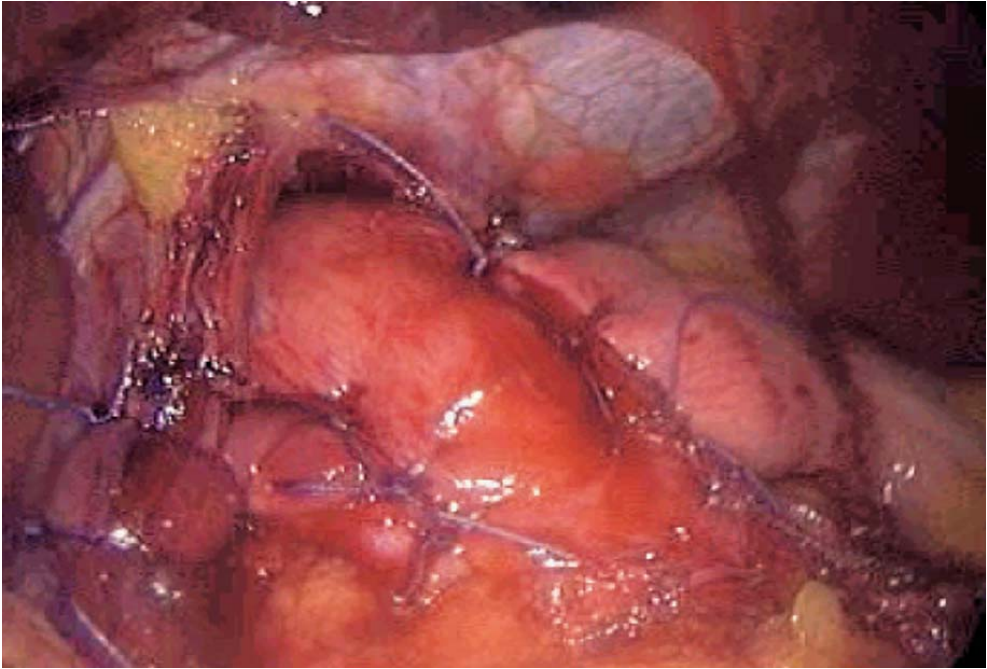


Fig. 3.21. Toupet completed

### 3.9 Nissen 360° Valve (▶ Fig. 3.22)

The gastric valve is completely wrapped around the abdominal oesophagus. The posterior part is sutured to the crura. Both valves of the wrapped fundus and the anterior part of the oesophagus are sutured together with four or five nonabsorbable multifilament sutures. The posterior vagus nerve is left close to the oesophagus inside the valve. The anterior vagus nerve should be avoided while suturing the wrap to the oesophagus. A 36F Faucher tube calibrates the oesophagus.

### 3.10 Fixing the Valve: Drainage

It is important to fix the valve correctly both in Nissen or Toupet procedure. The valve is always sutured to the crura posteriorly (▶ Fig. 3.18). The right part of the valve can also be sutured to the right crus. Subhepatic suction drainage is optional.



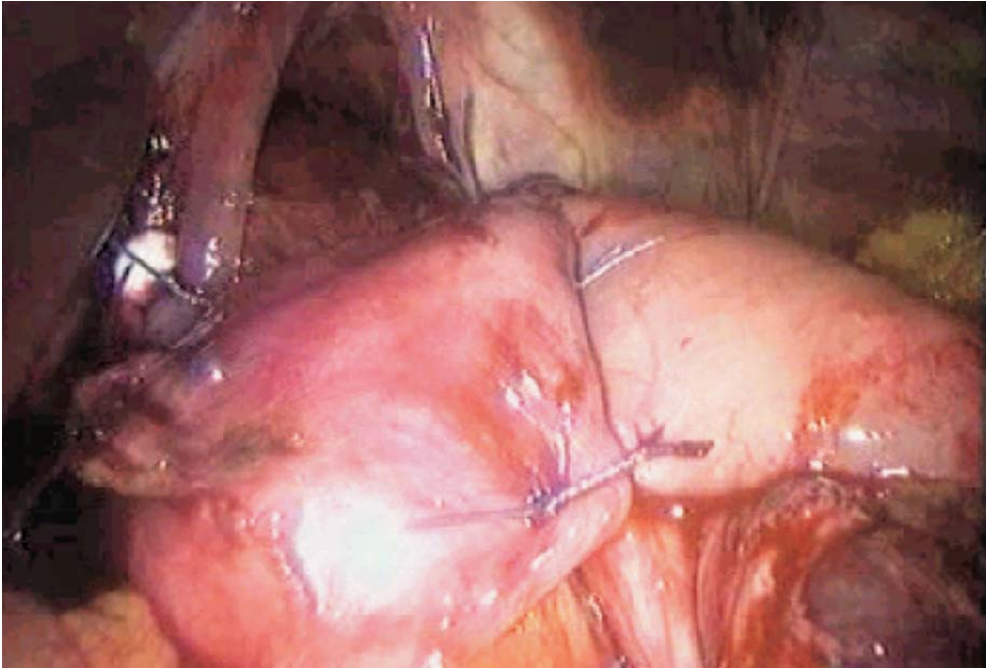


Fig. 3.22. Completed Nissen

### 3.11 Tips and Comments

- Always insert the trocars after complete inflation; orientate them in the direction of the hiatus.
- The liver may be reclinied by an auto static retractor and a specific instrument, especially in presence of steatosis or hypertrophy of the left lobe.
- A left hepatic artery is frequently encountered. The decision to keep it or not depends on its size.
- Giant hiatal hernias are treated the same way. Complete removal of the peritoneal sac is achieved by circular incision. The resected peritoneum is left collar-like around the oesophagus.
- Traction on the stomach through the left lateral trocar may be ensured by the auto static device. In this case, no second assistant is needed.
- Suturing of the crura may be reinforced with Teflon pledgets. U-shaped sutures are then performed, taking in these supports.
- In case of a large hiatal opening, one or two final sutures should be done anteriorly to avoid stricture on the oesophagus.
- The best gastric valve is the upper part of the fundus, at the junction between the anterior and posterior walls of the stomach. Looking through the retro-oesophageal window, if properly dissected, makes the best choice visible.
- A 36F Faucher tube upon termination of the procedure calibrates the oesophagus and outlines the quality of the repair.

## Literature

- Anvari M, Allen C, Borm A (1995) Laparoscopic Nissen fundoplication is a satisfactory alternative to long term omeprazole therapy. *Br J Surg* 82:938–942
- Cadiere GB, Houben JJ, Bruyns J, Himpens J, Panzer JM, Gelin M (1994) Laparoscopic Nissen fundoplication: technique and preliminary results. *Br J Surg* 81:400–403
- Cathey RP, Henry LG, Bielefield MR (1996) Laparoscopic Nissen fundoplication for gastroesophageal reflux disease: clinical experience and outcome in the first 100 patients. *Surg Laparosc Endosc* 6:430–433
- Coster DD, Bower WH, Wilson VT, Brebrick RT, Richardson GL (1997) Laparoscopic partial fundoplication vs. laparoscopic Nissen-Rossetti fundoplication: short-term results of 231 cases. *Surg Endosc* 11:625–631
- Cuschieri A, Hunter J, Wolfe B, Swanstrom LL, Hutson W (1993) Multicenter prospective evaluation of laparoscopic antireflux surgery: preliminary report. *Surg Endosc* 7:505–510
- Dallemagne B, Weerts JM, Jehacs C, Markiewid S, Lombard R (1991) Laparoscopic Nissen fundoplication: preliminary report. *Surg Laparosc Endosc* 1:138–143
- Fontaumarad E, Espalieu P, Boulez J (1995) Laparoscopic Nissen-Rossetti fundoplication. *Surg Endosc* 9:869–873
- Geagea T (1994) Laparoscopic Nissen-Rossetti fundoplication. *Surg Endosc* 8:1080–1084
- Gotley DC, Smithers BM, Menzies B, Branicki FJ, Rhodes M, Nathanson L (1996) Laparoscopic Nissen fundoplication and postoperative dysphagia: can it be predicted? *Ann Acad Med Singapore* 25:646–649
- Gotley DC, Smithers BM, Rhodes M, Menzies B, Branicki FJ, Nathanson L (1996) Laparoscopic Nissen fundoplication: 200 consecutive cases. *Gut* 38:487–491
- Hallerback B, Glise H, Johansson B, Radmark T (1994) Laparoscopic Rossetti fundoplication. *Surg Endosc* 8:1417–1422
- Hunter JG, Swanstrom L, Waring JP (1996) Dysphagia after laparoscopic antireflux surgery: the impact of operative technique. *Ann Surg* 224:51–57
- Jamieson GG, Watson DI, Britten-Jones R, Mitchell PC, Anvari M (1994) Laparoscopic Nissen fundoplication. *Ann Surg* 220:137–145
- Laycock WS, Trus TL, Hunter JG (1996) New technology for the division of short gastric vessels during laparoscopic Nissen fundoplication: a prospective randomized trial. *Surg Endosc* 10:71–73
- Leggett PL, Churchman-Winn R, Ahn C (1998) Resolving gastro oesophageal reflux with laparoscopic fundoplication: findings in 138 cases. *Surg Endosc* 12:142–147
- Nissen R (1956) Eine einfache Operation zur Beeinflussung der Refluxoesophagitis. *Schwed Med Wochenschr* 86:590–592
- Patti MG, Arcerito M, Feo CV, De Pinto M, Tong J, Gantert W, Tyrrell D, Way LW (1998) An analysis of operations for gastroesophageal reflux disease. *Arch Surg* 133:600–607
- Peters JH, DeMeester TR, Crookes P, Oberg S, de Vos Shoop M, Hagen JA, Bremner CG (1998) The treatment of gastroesophageal reflux disease with laparoscopic Nissen fundoplication: prospective evaluation of 100 patients with „typical“ symptoms. *Ann Surg* 228:40–50
- Rattner DW, Brooks DC (1995) Patient satisfaction following laparoscopic and open antireflux surgery. *Arch Surg* 130:289–294
- Rossetti M, Hell K (1977) Fundoplication for the treatment of gastroesophageal reflux in hiatal hernia. *World J Surg* 1:439–444
- Swanstrom LL, Pennings JL (1995) Laparoscopic control of short gastric vessels. *J Am Coll Surg* 181:347–351
- Watson DI, Jamieson GG (1998) Antireflux surgery in the laparoscopic era. *Br J Surg* 85:1173–1184
- Watson DI, Gourlay R, Globe J, Reed MWR, Johnson AG, Stoddard CJ (1995) Prospective randomized trial of laparoscopic (LNF) versus open (ONF) Nissen fundoplication [Abstract]. *Surgery* 118:58
- Watson DI, Pike GK, Baigrie RJ, Mathew G, Devitt PG, Britten-Jones R, Jamieson GG (1997) Prospective double-blind randomized trial of laparoscopic Nissen fundoplication with division and without division of short gastric vessels. *Ann Surg* 226:642–652

## 4 Laparoscopic Gastric Banding for Morbid Obesity

### 4.1 Operating Room Setup: Position of the Patient

The patient is placed supine with legs apart. Both legs are flexed and extra support is given on the thighs. Reverse Trendelenburg position must be generous, with the patient in a near-sitting position.

The surgeon stands between the patient's legs. The first assistant is at the right of the patient, and the monitor is on the left side of the patient. A second assistant stands on the left of the patient (► Fig. 4.1).

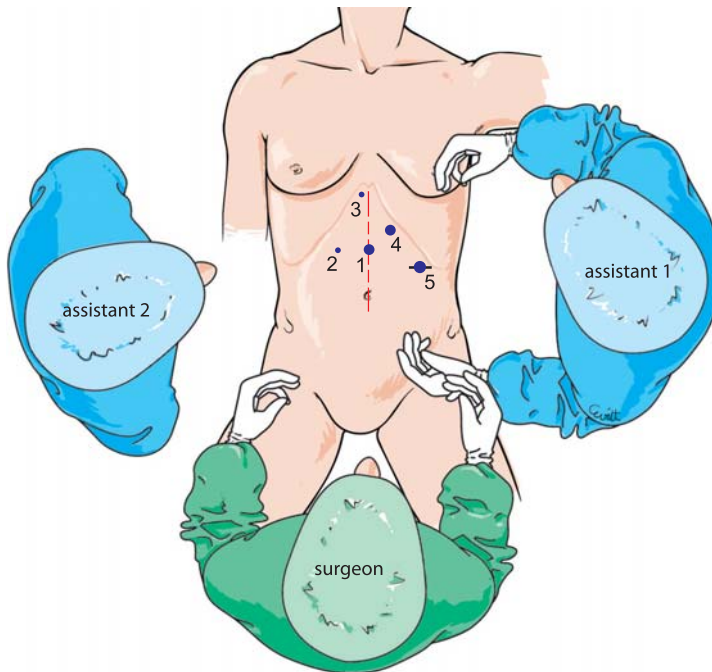


Fig. 4.1. OR setup – trocar position

#### 4.2 Recommended Instruments (▶ Fig. 4.2)

- Five-millimetre instruments
- Coagulating shears
- Three Johann fenestrated forceps
- A specific 10-mm dissection instrument, with angulation mechanism
- Auto-static endoscope holders
- Five-millimetre hepatic retractors
- Silicon banding device and access port, of various sizes depending on tissue thickness and models
- Two 10-mm trocars
- Three 5-mm trocars
- A 15-mm trocar
- A 30° endoscope
- A 5-mm needle holder
- A 2/0 nonabsorbable suture, with 26-mm needle

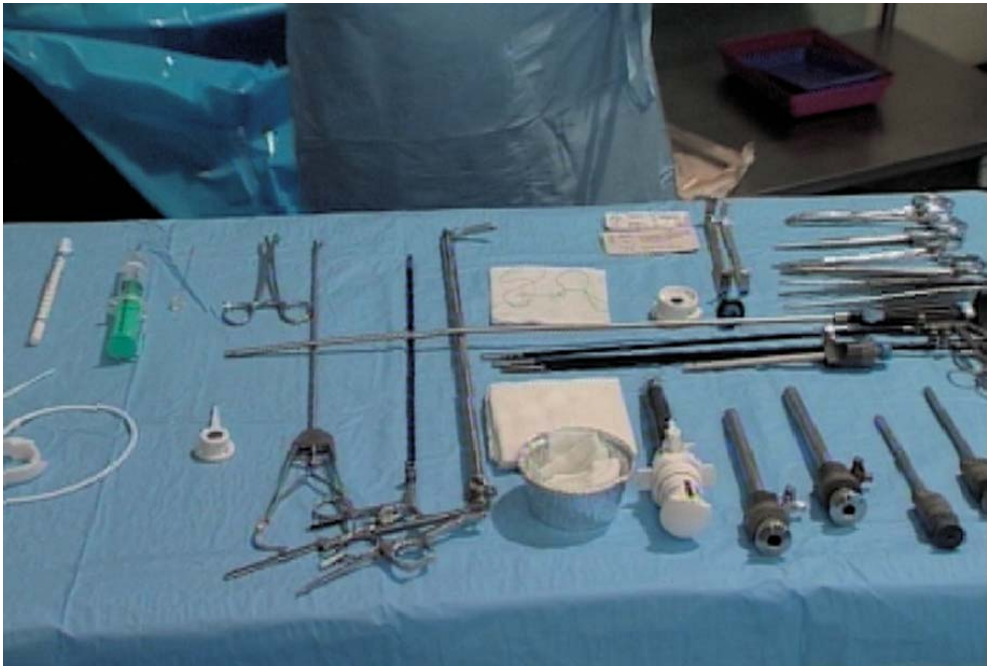

Fig. 4.2. Instruments

### 4.3 Position of the Trocars and Exposure (🔗 Fig. 4.3)

Pneumoperitoneum is created with a Veress needle. The first 10-mm trocar is inserted in the middle of the xipho-umbilical line. The general direction of the trocar should be oblique towards the hiatus. The left lobe of the liver is reclined through a right subcostal trocar, slightly right of the xiphoid process. A 5-mm trocar is placed 5 cm from the first on the right. A 10-mm trocar, placed in the left paramedian position at two finger widths from the costal rim, enables the insertion of the right-hand operating instrument. A more lateral 4-cm subcostal incision enables the future positioning of the access port and the insertion of the last 15-mm operating trocar.

Exposure is performed using the Johann forceps inserted through the left lateral trocar to seize the anterior part of the fundus. A liver retractor is inserted (🔗 Fig. 4.4). A specific inflatable gastric tube with a 25-ml balloon is introduced by the anesthesiologist. The balloon is inflated to 25 ml and placed by traction below the oesophageal gastric junction (🔗 Fig. 4.5). Incision of the lesser omentum is started and marked by electrocautery, close to the gastric wall, at the equator of the balloon. The balloon is deflated and the gastric tube removed. The gastrophrenic ligament is identified.

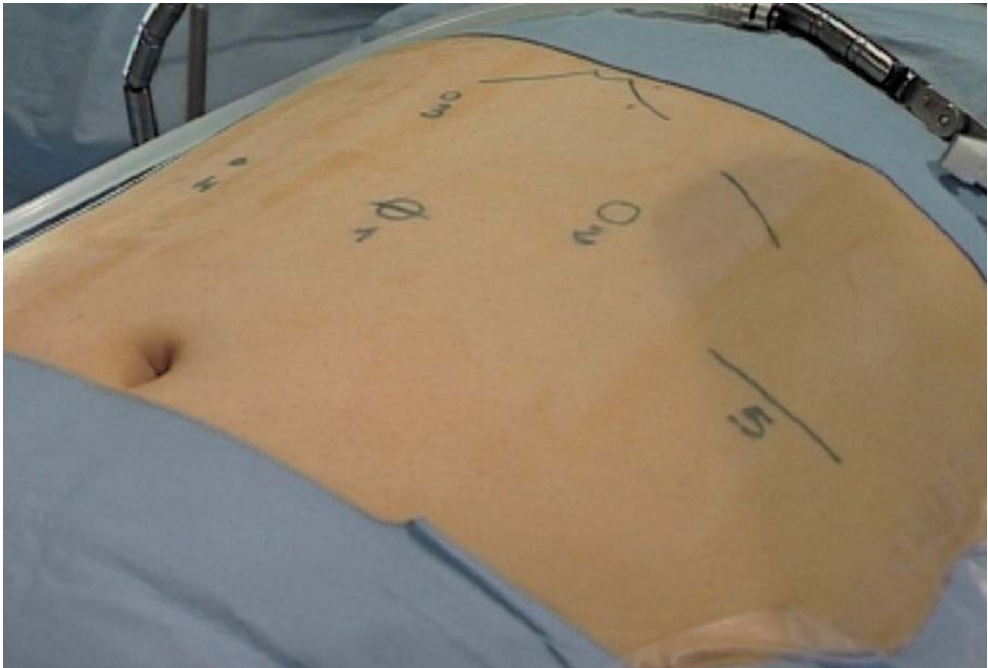


Fig. 4.3. Position of trocars



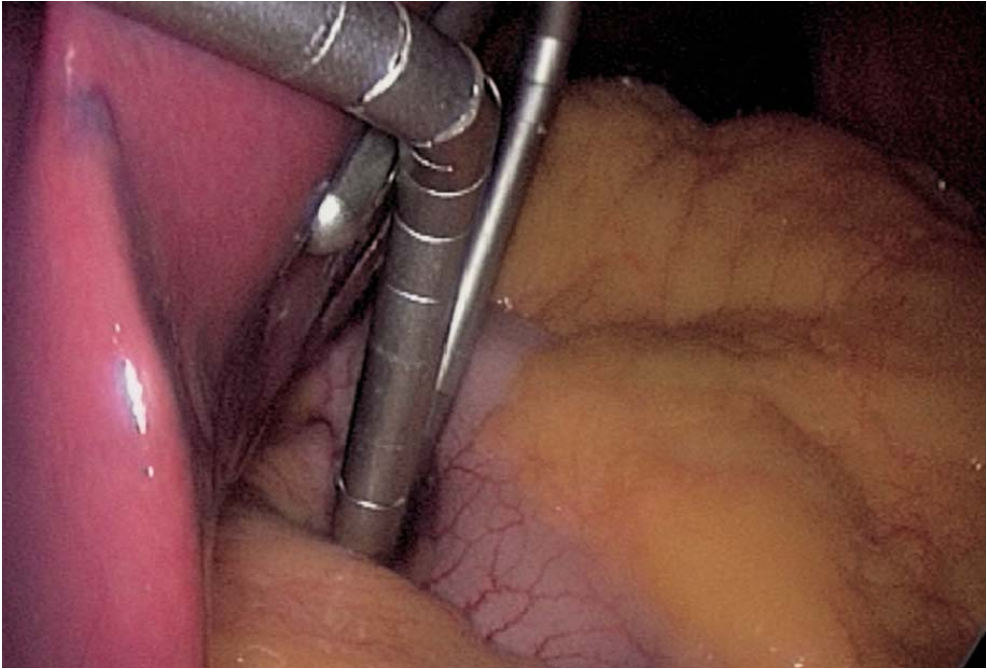


Fig. 4.4. Liver retractor

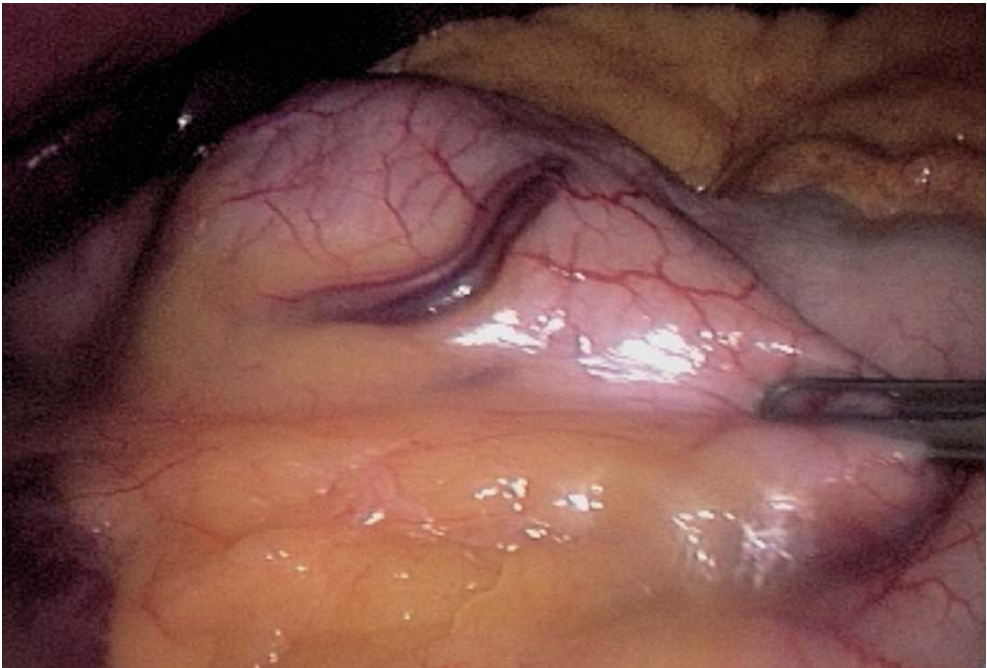

Fig. 4.5. Balloon measuring gastric pouch

#### 4.4 Retrogastric Channel (► Fig. 4.6)

The dissection and coagulation of the lesser omentum is started. This continues in contact with the gastric wall over a distance of 1 cm. A Johann forceps introduced from the left dissects this retrogastric plane as far as possible.

The fundus is grasped by the left lateral instrument. The gastrophrenic ligament is grasped by the left lateral instrument and by the coagulating scissors inserted through the left paramedian trocar. The esogastric angle and its diaphragmatic attachments are dissected by successive coagulation.

The retrogastric tunneling can be performed using the specific instrument inserted through the 10-mm left paramedian trocar. This instrument is placed in the retrogastric position and gently pushed forward. Exposure is progressively resumed, pushing back the fundus and revealing the esogastric angle. Once the dissector is seen, it is angulated and pushed forward, completing the retrogastric tunnel.

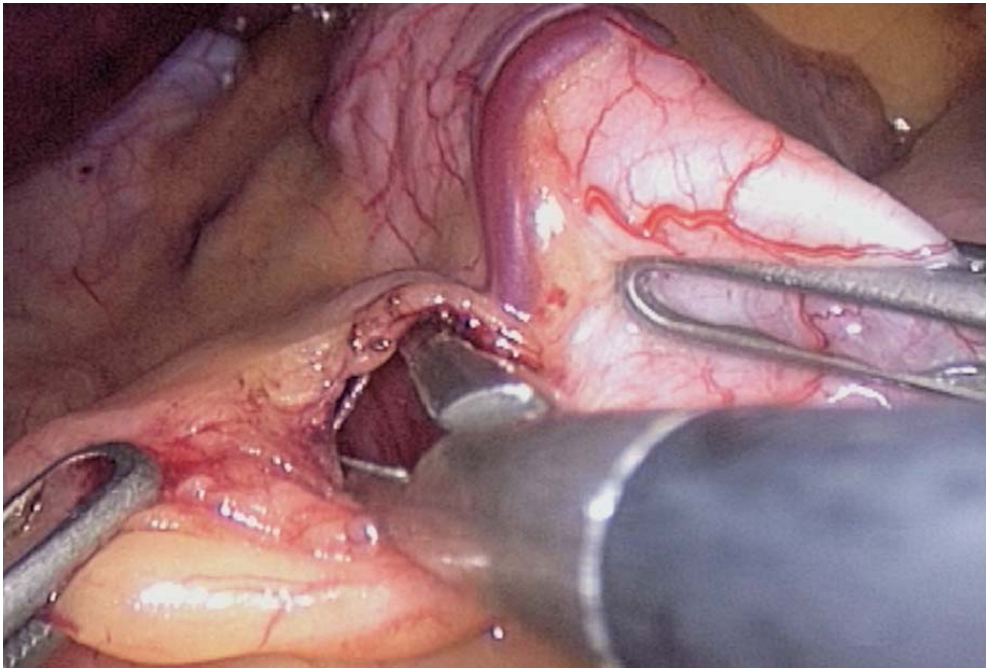


Fig. 4.6. Para-gastric dissection

#### 4.4.1 Preferred Option

The specific angulated instrument for making the retrogastric tunnel is introduced after opening the pars flaccida (◉ Fig. 4.7), and dissecting the right crus of the diaphragm. The instrument thus creates a high retrogastric channel at the level of the "V" of the two diaphragmatic crura and the esogastric junction (◉ Figs. 4.8, 4.9).

A second positioning of the instrument starts at the previously marked retrogastric channel, towards the esogastric junction. This two-step procedure places the banding higher, and leaves vagus nerve and lesser omentum outside the banding.

#### 4.5 Placement of the Gastric Banding (◉ Fig. 4.10)

The gastric banding is rinsed with saline and introduced into the abdomen through the 15-mm left lateral trocar. The catheter of the gastric banding is fitted with its Teflon tab (◉ Fig. 4.11). This end is either grasped with a forceps or with the specific angulating instrument. The catheter is then pulled through the retrogastric channel (◉ Figs. 4.12–4.14). Using a left paramedian Johann forceps, the band is passed into the retrogastric position; this occasionally requires additional coagulation due to the narrowness of the channel (◉ Figs. 4.15–4.19).

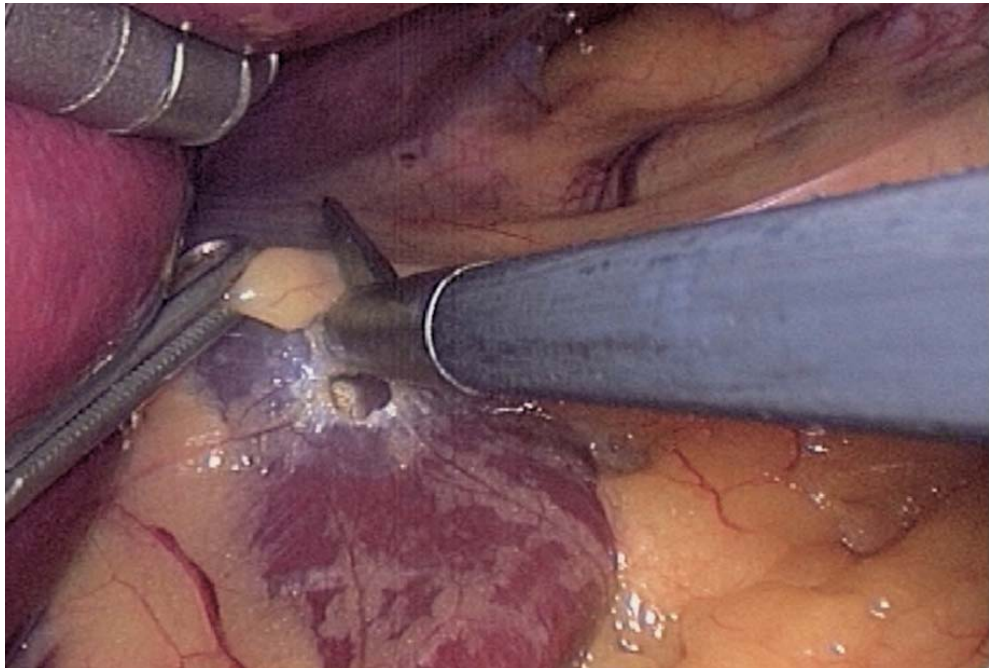


Fig. 4.7. Incision of the lesser omentum



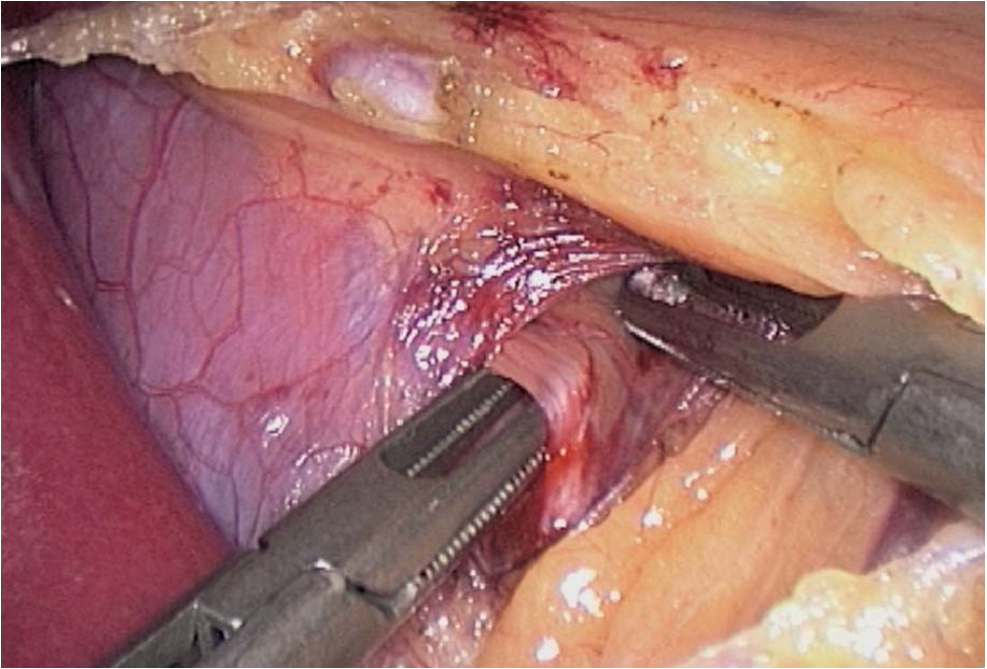


Fig. 4.8. Retro-oesophageal dissection

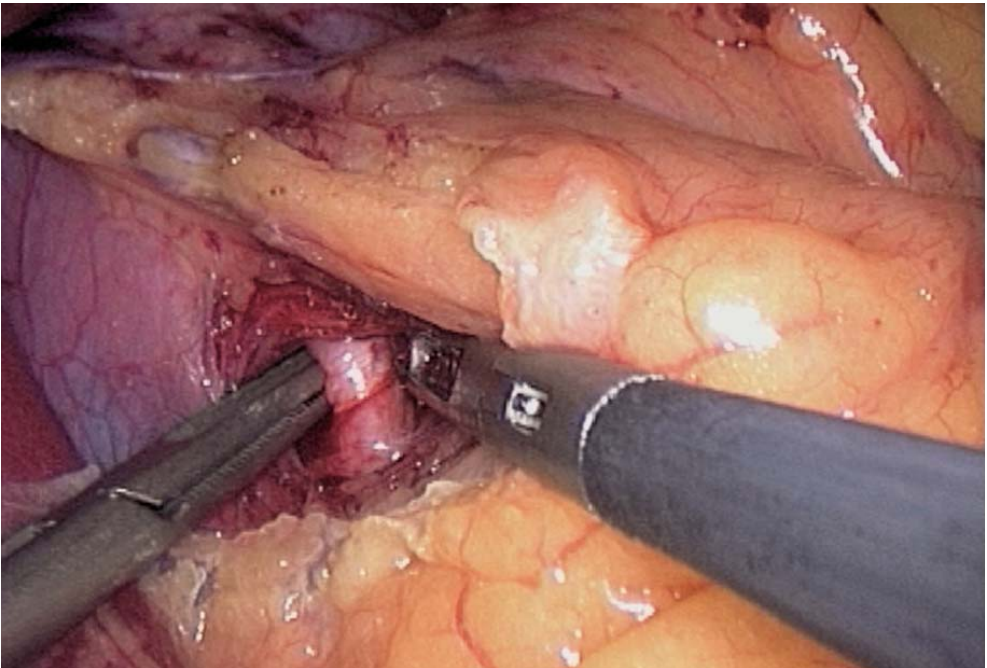


Fig. 4.9. Retro-oesophageal tunnelling

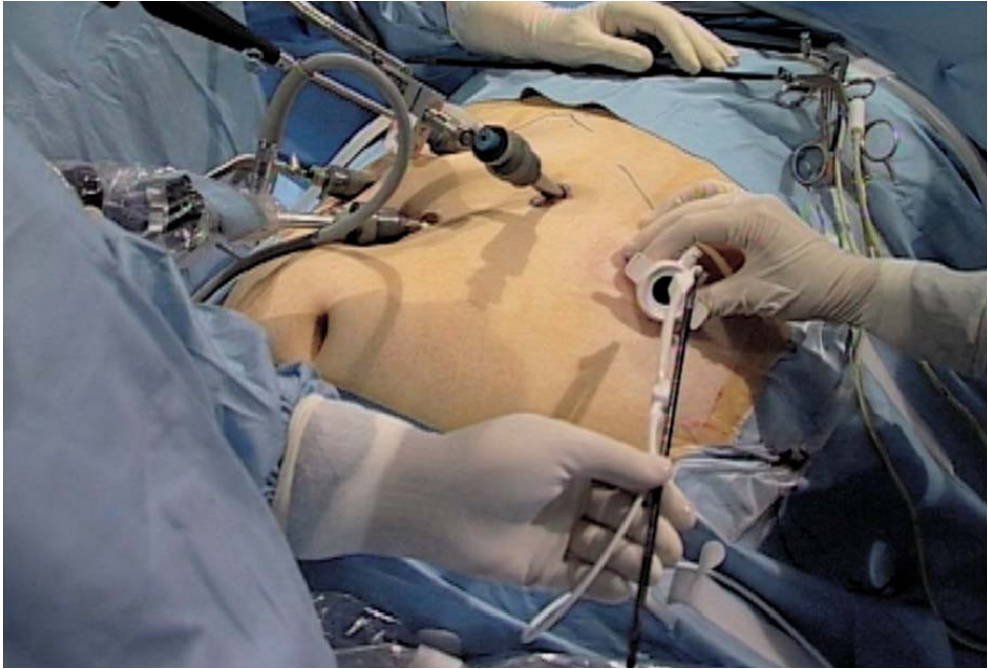


Fig. 4.10. Introducing the banding device

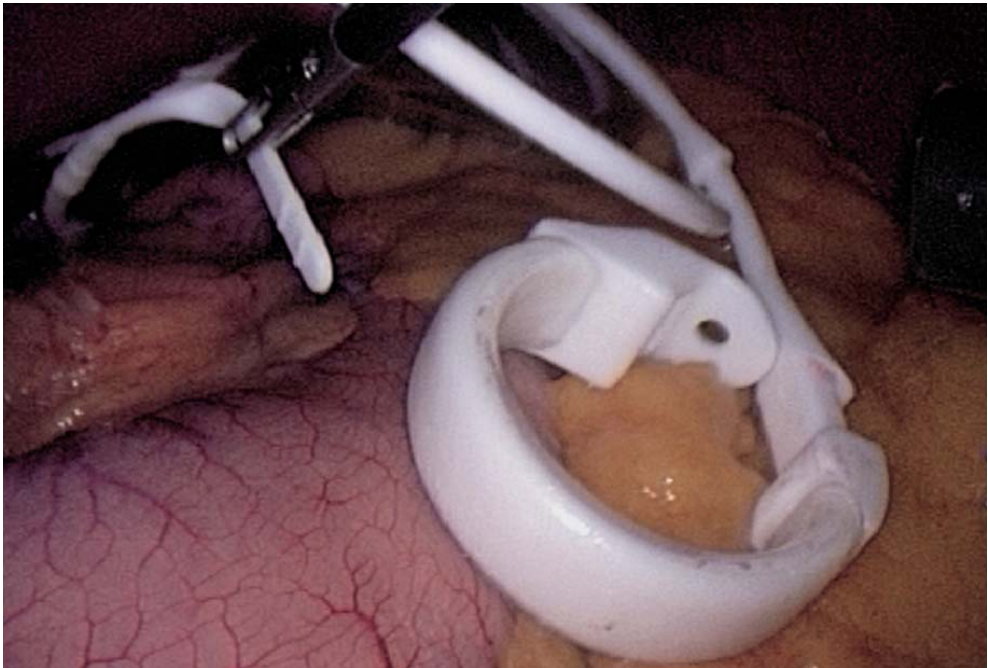


Fig. 4.11. Band inside the abdomen



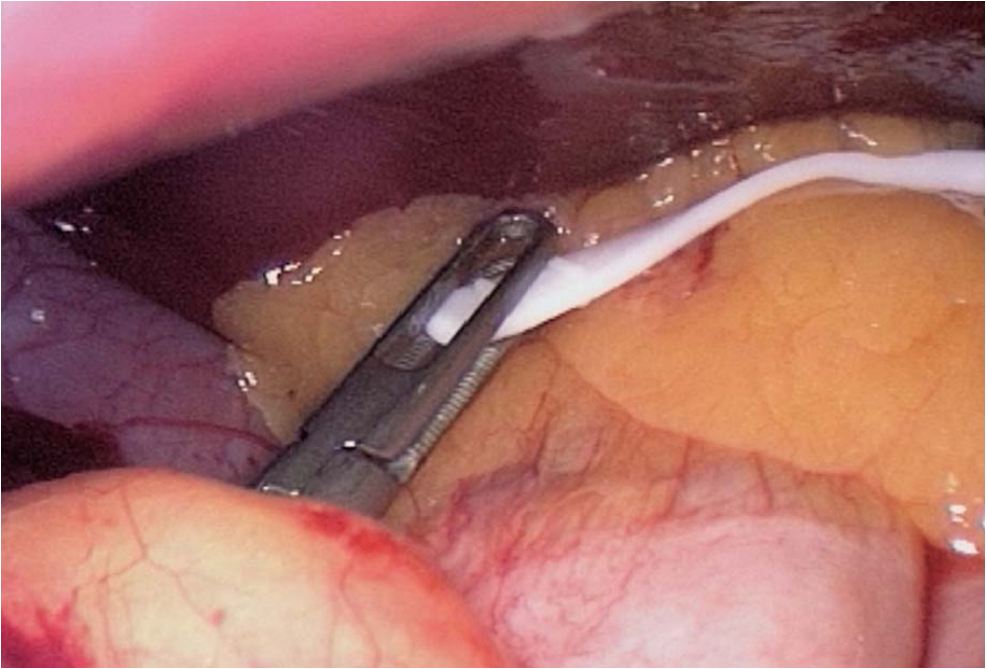


Fig. 4.12. Grasping the band catheter behind the oesophagus

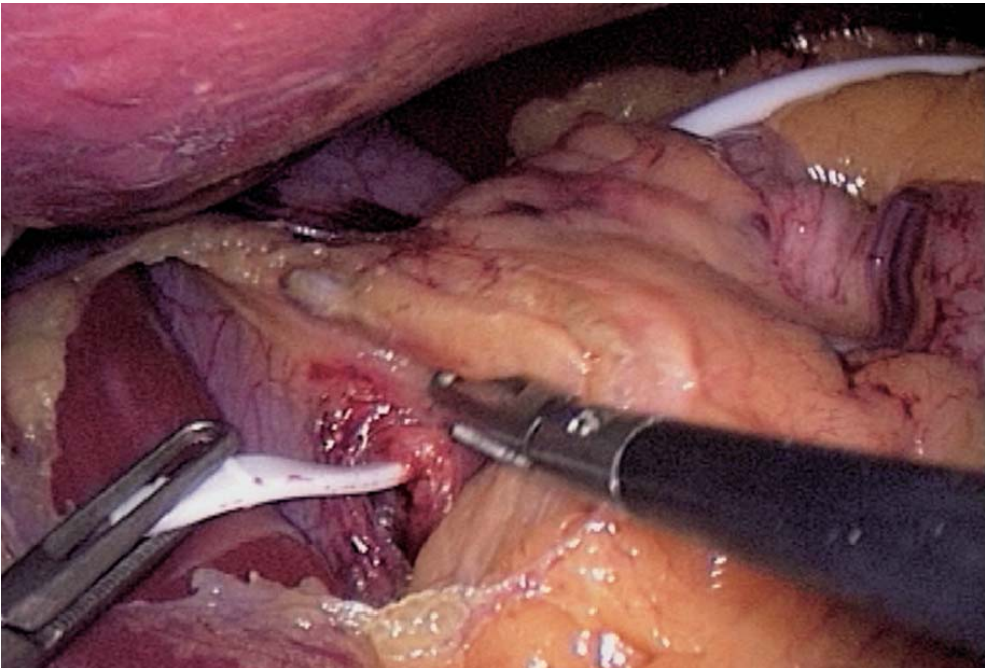


Fig. 4.13. Passing the catheter behind the oesophagus

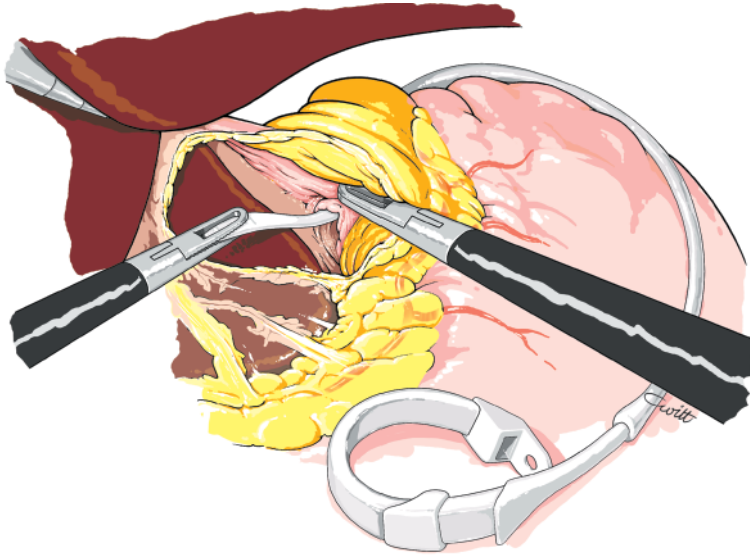


Fig. 4.14. Band catheter passed behind the oesophagus

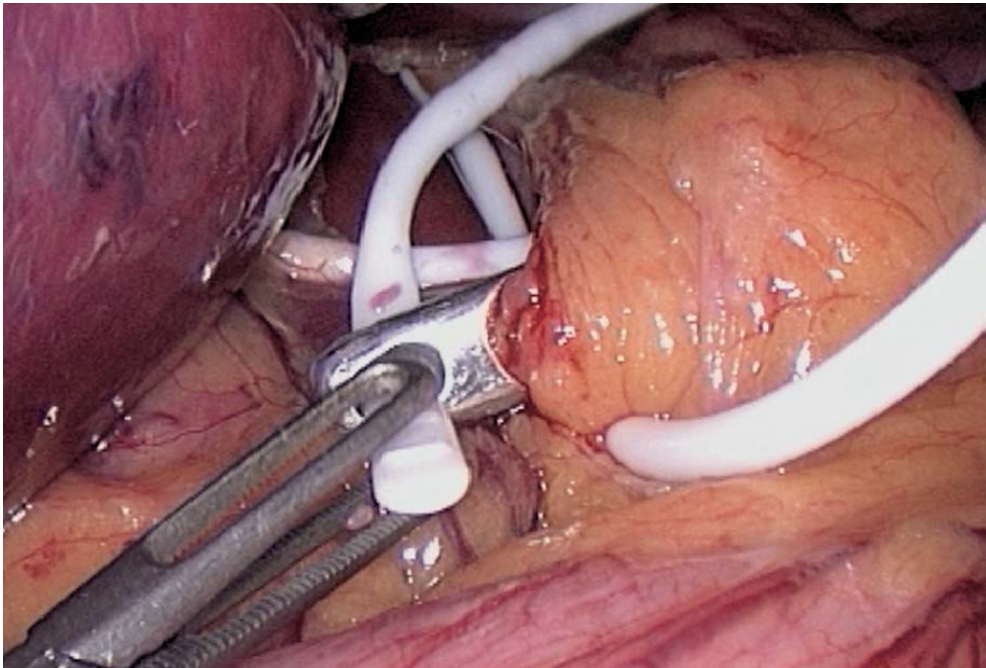


Fig. 4.15. Tunnelling through the lesser omentum

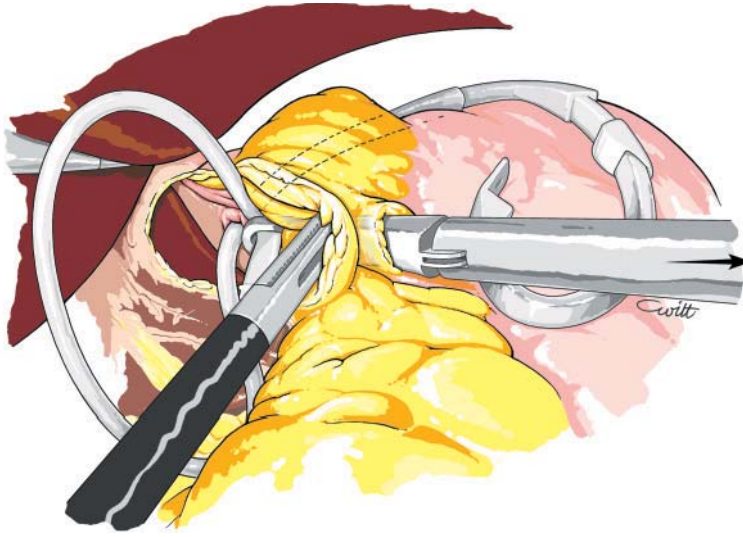


Fig. 4.16. Catheter passed through the lesser omentum

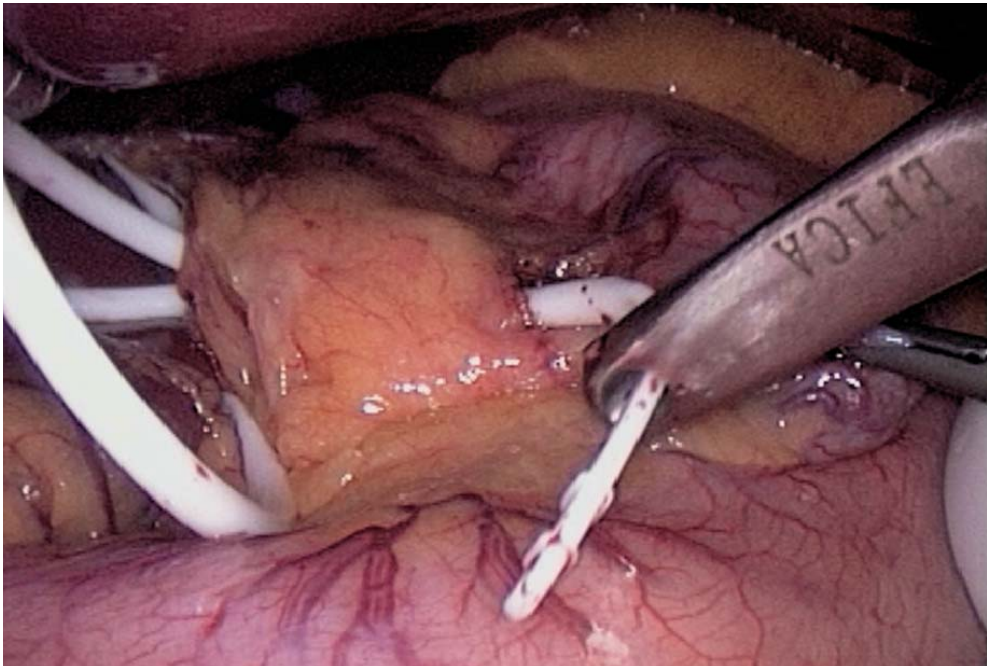


Fig. 4.17. Catheter securely passed through the lesser omentum



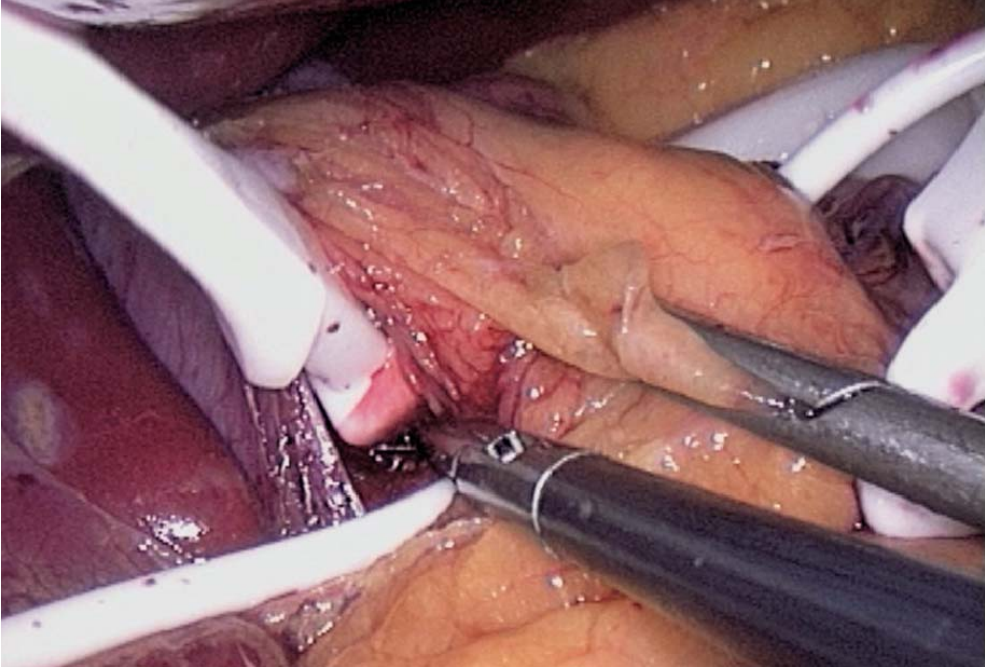


Fig. 4.18. Band placement behind the oesophagus

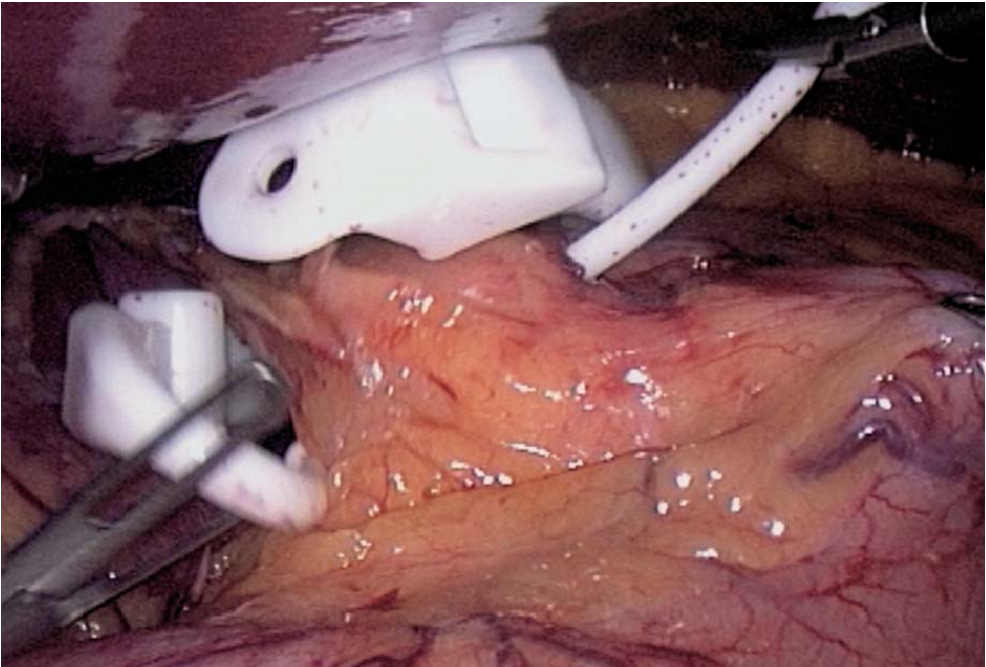


Fig. 4.19. Band passed through the lesser omentum



#### 4.6 Fitting of the Band (► Figs. 4.20–4.22)

Before closing the band, the gastric tube is introduced again and the balloon is inflated to 20 ml. The band is closed around the stomach, creating a 20-ml pouch.

#### 4.7 Suturing the Stomach to Fix the Band

The anterior wall of the fundus is used to create a gastric valve around the exposed part of the band. This is essential to prevent postoperative slippage of the band. Interrupted nonabsorbable 2/0 multifilament sutures are required. The band catheter is maintained on the side of the lesser curvature with the left fenestrated forceps. The first sutures are placed with the balloon still inflated. Continuous sutures are optional. In case of interrupted sutures, four stitches are usually needed (► Figs. 4.23–4.26).

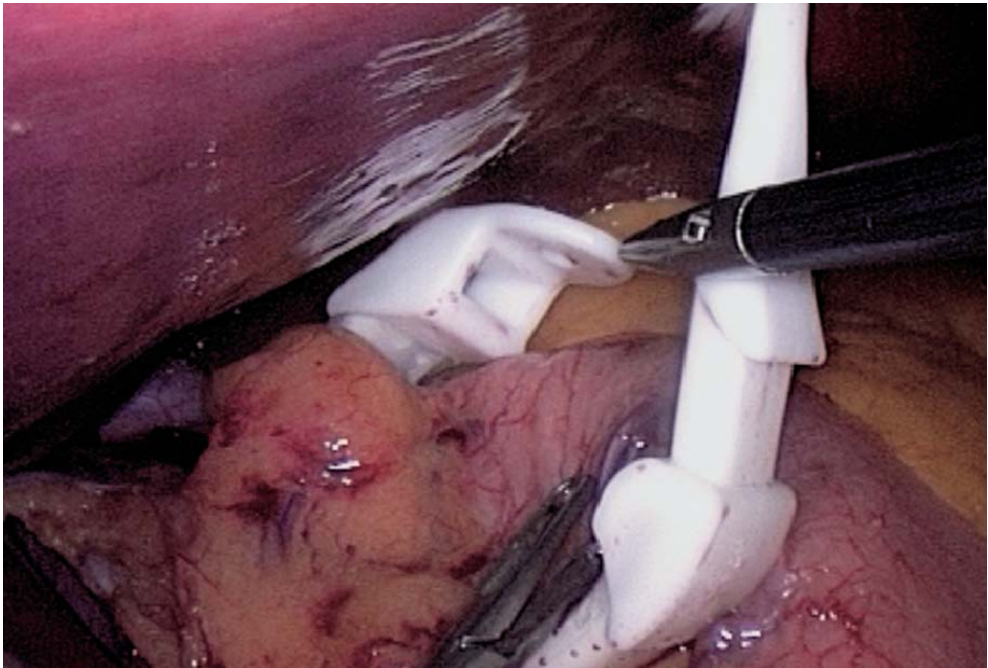


Fig. 4.20. Band in place around stomach

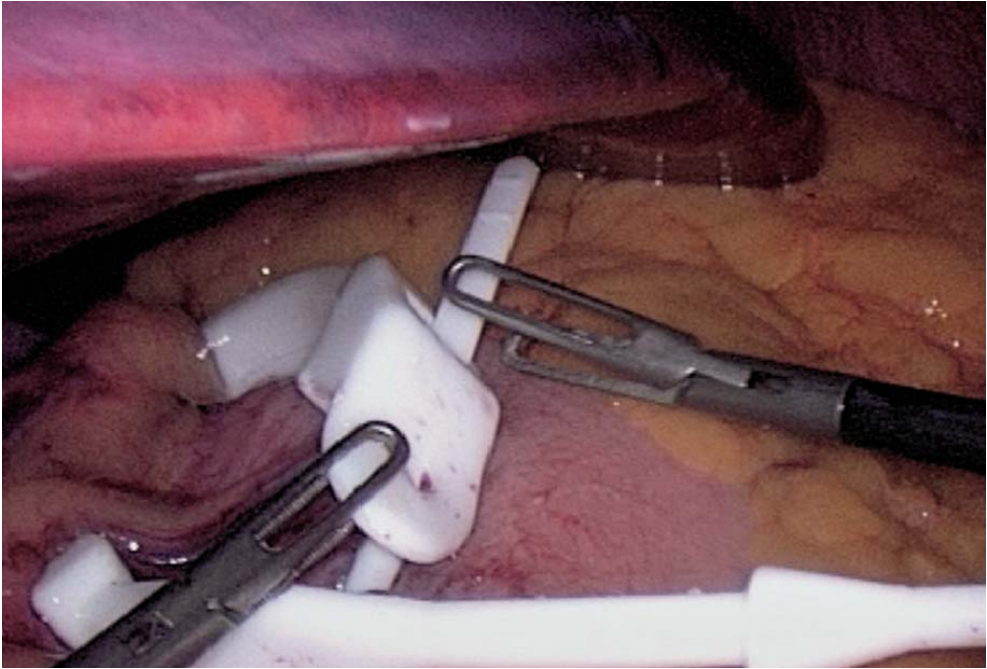


Fig. 4.21. Closure of band

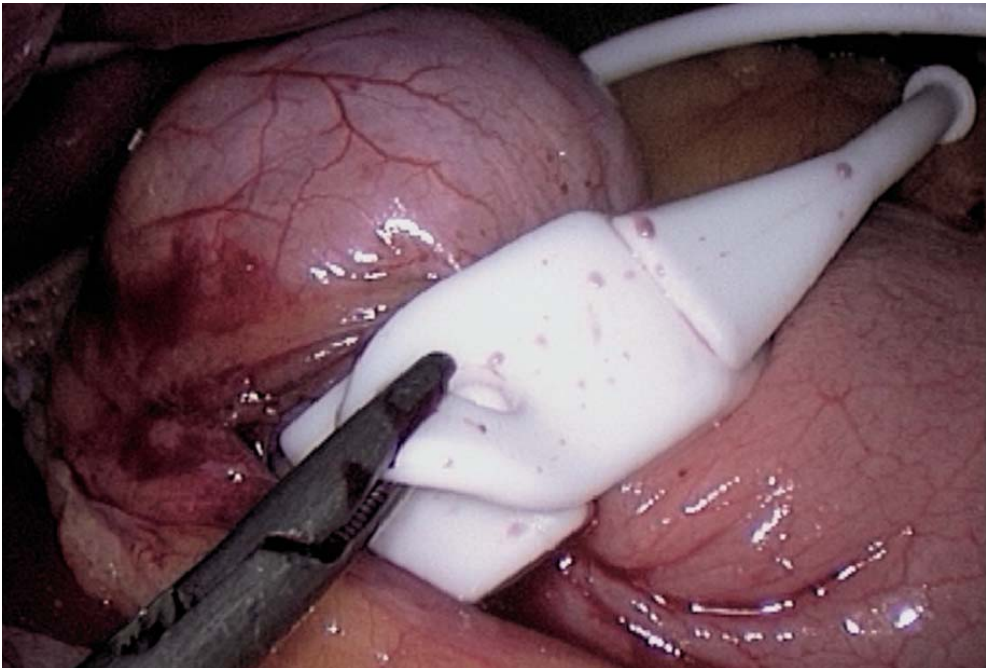


Fig. 4.22. Band closed after pouch measurement

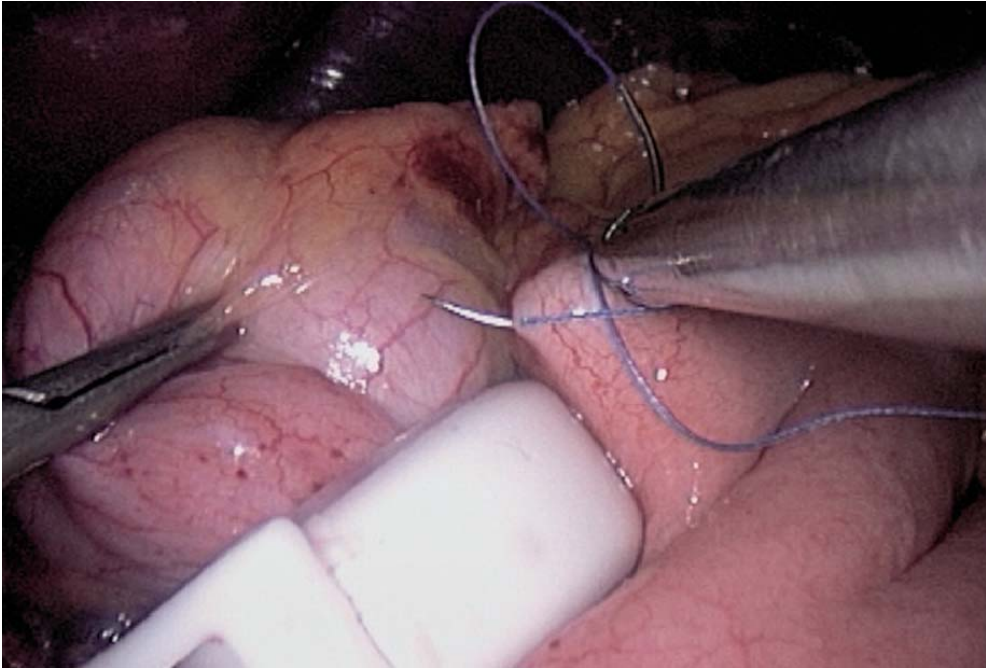


Fig. 4.23. Band wrapped with the gastric wall starting on the left

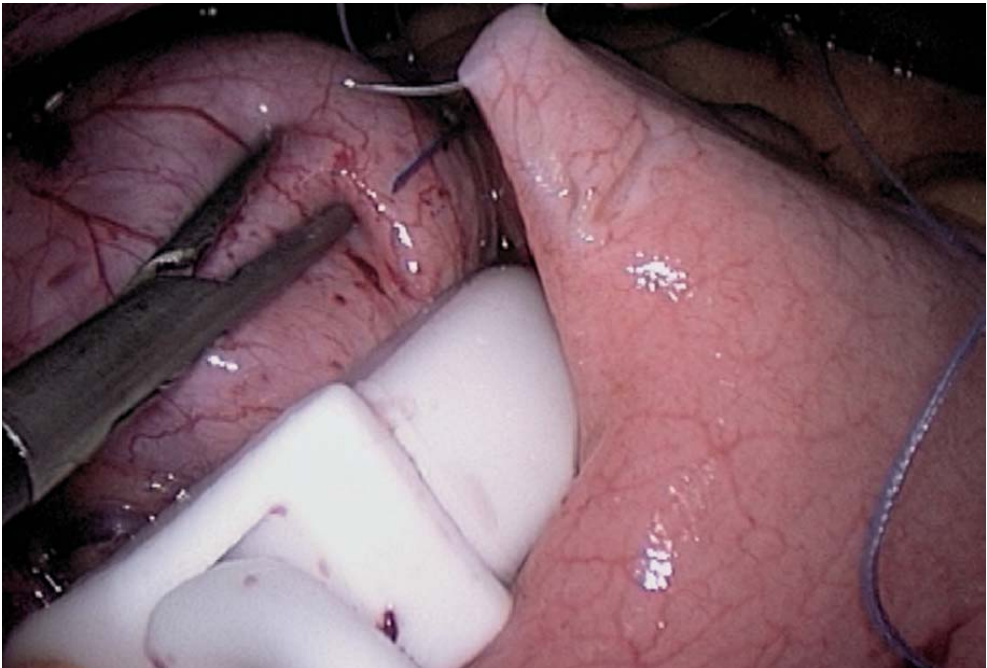


Fig. 4.24. Wrapping the band continued



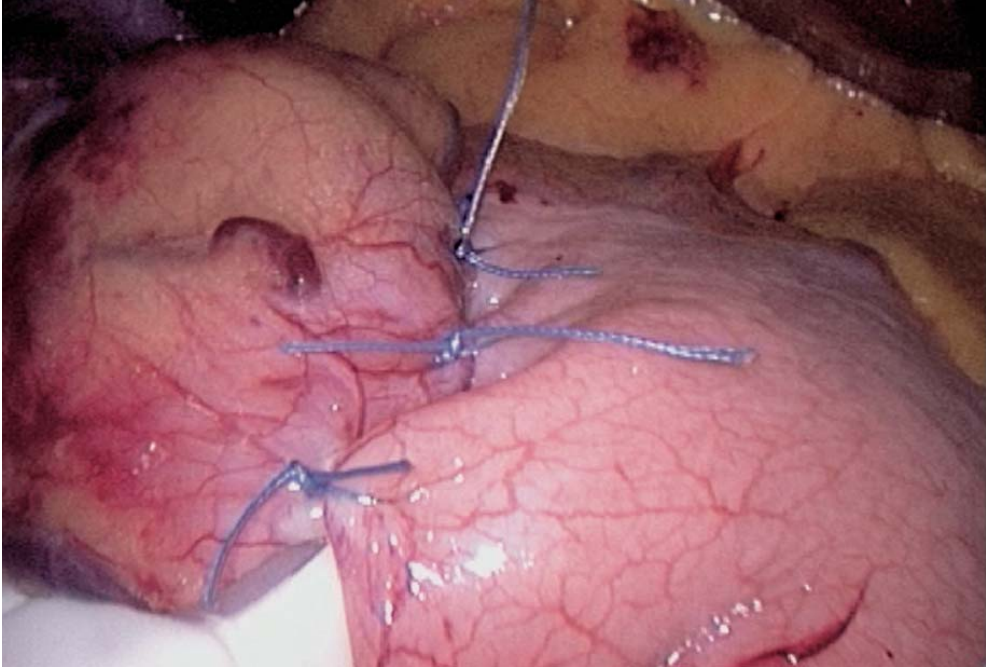


Fig. 4.25. Wrapping completed

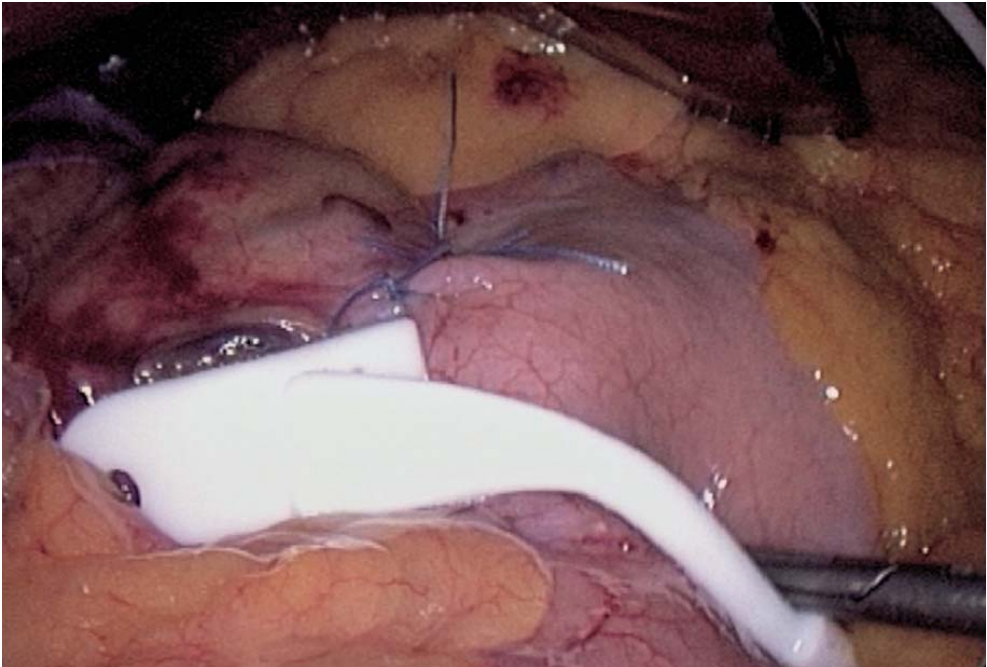


Fig. 4.26. Final laparoscopic view



#### 4.8 Placement of the Access Port (▶ Fig. 4.27)

The gastric band is in place. The hepatic retractor is removed. The distal end of the catheter of the gastric band is grasped with a Johann forceps inserted through the 15-mm trocar. The pneumoperitoneum is released. The catheter is connected to the access port that has been previously filled with saline. A subcutaneous space is created (▶ Fig. 4.28). The access port is placed subcutaneously and port wounds are closed.

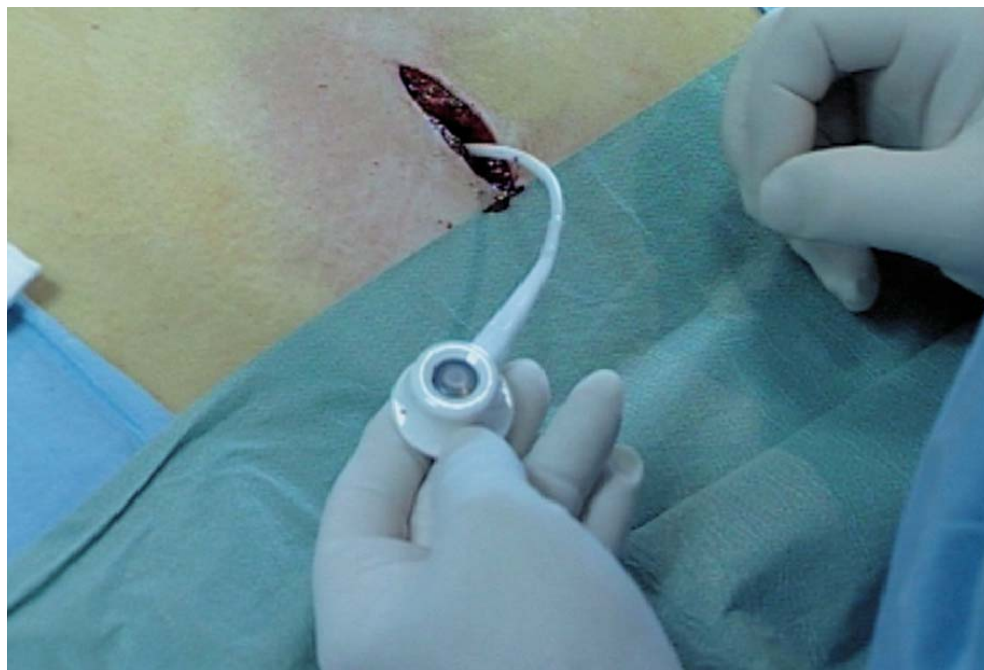

Fig. 4.27. Access port attached

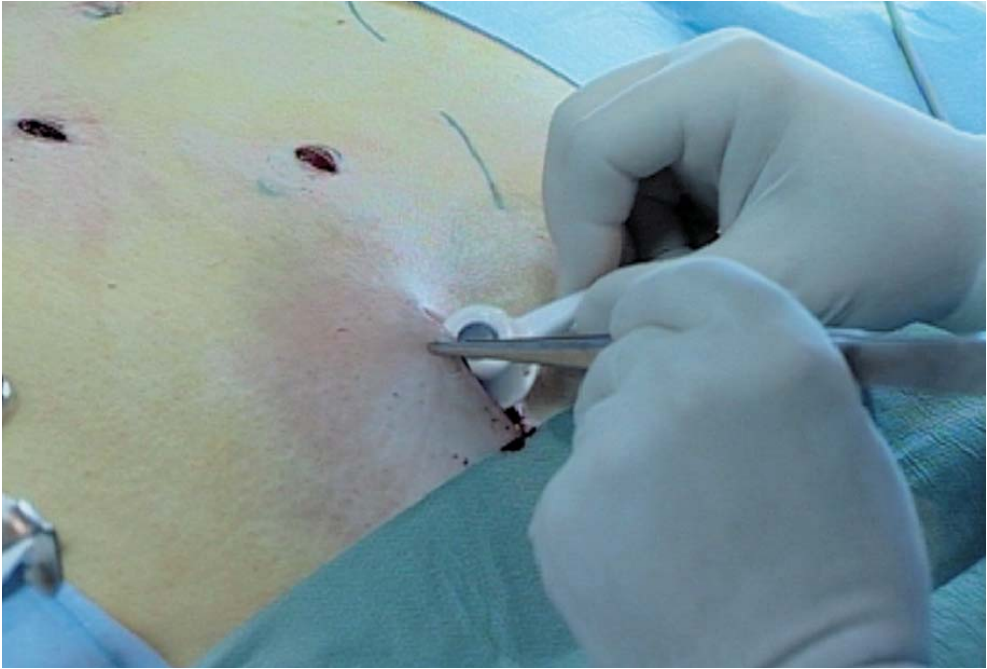

Fig. 4.28. Access port is placed subcutaneously

#### 4.9 Tips and Comments

- Given the parietal thickness, the trocars may be extra long.
- Trocars must be inserted after complete inflation of the abdomen, towards the hiatus in the general working direction because of the thickness of the obese abdominal wall.
- The retrogastric channel must be made with the left paramedian instrument for a correct direction of the retrogastric tunnel.
- The proposed option of a retrogastric channel near the foot of the crura must be performed with the right paramedian fenestrated forceps.
- The second tunnel excluding the lesser omentum must be performed with the specific angulated instrument inserted in the left paramedian position.
- The locking mechanism of the gastric band is positioned in contact with the lesser omentum, enabling a larger anterior gastric valve and making future band removal easier.
- The use of the 30° endoscope, while not 100% useful, is nonetheless strongly recommended for BMI's over 50 kg/m<sup>2</sup>.
- The band is never inflated immediately, but usually 6 weeks postoperatively.

## Literature

- Alvarez-Cordero R, Castillo-Gonzales A, Ramirez-Wiela G (1999) The »Mexican technique« for the laparoscopic placement of adjustable gastric band. Abstract of the 16th Annual Meeting of the American Society for Bariatric Surgery, San Diego. *Obes Surg* 9:135–143
- Ashley D, Bird DL, Sudgen G et al (1993) Vertical banded gastroplasty for the treatment of morbid obesity. *Br J Surg* 80:1421–1423
- Bado A, Levasseur S, Attoub S et al (1998) The stomach is a source of leptine. *Nature* 394:790–793
- Balsiger B M, Luque-de-Leon E, Sarr MG (1997) Surgical treatment of obesity: who is an appropriate candidate? *Mayo Clin Proc* 72:551–558
- Belachew M, Jacquet P, Lardinois F et al (1993) Vertical banded gastroplasty vs. ASGB in the treatment of morbid obesity: a preliminary report. *Obes Surg* 3:275–278
- Belachew M, Legrand M, Vincent N et al (1997) L'approche coelioscopique dans le traitement de la chirurgie de l'obésité morbide. *Annales de chirurgie* 51:165–172
- Belachew M, Legrand M, Vincent V, Lismonde M, Le Doche N, Deschamps V (1999) Laparoscopic adjustable gastric banding. *World J Surg* 22:955–960 DOI 10.1007/s002689900499
- Belva P, Takiédine M, Lefebvre JC, Vaneikem P (1997) How to reduce complication rate in laparoscopic gastric banding. *Obes Surg* 7:303–309
- Benotti PN, Forse RA (1995) The role of gastric surgery in the multidisciplinary management of severe obesity. *Am J Surg* 169:361–367
- Buyse M, Bado A (1999) Régulation de la prise alimentaire: données récentes. *Med Hyg* 57:1704–1706
- Cadière GB, Bruyns J, Himpens J, Favretti F (1994) Laparoscopic gastroplasty for morbid obesity. *Br J Surg* 81:1524
- Chelala E, Cadière GB, Favretti F, Segato G, Lise M, Bath O, Bruyns J, Vertruyen M, Himpens J (1996) Laparoscopic gastroplasty (LASGB). *Obes Surg* 6:316–317
- Chelala E, Cadière GB, Favretti F, Himpens J, Vertruyen M, Bruyns J, Maroquin L, Lise M (1997) Conversions and complications in 185 laparoscopic adjustable silicone gastric banding cases. *Surg Endosc* 11:268–271
- Consensus Development Conference Panel (1991) Gastrointestinal surgery for severe obesity: consensus development conference statement. *Ann Intern Med* 115:956–961
- Cusin I, Rohner-Jeanrenaud F (1998) Boucle régulatrice entre le neuro-peptide Y et la leptine et son altération chez le rongeur obèse. *Médecine/Science* 14:907–913
- Dadoun F (2000) De la neuro-biologie à la pharmacologie du comportement alimentaire. *Revue du Patricien* 50:512–520
- Desaive C (1996) A critical review of a personal series of 1000 gastroplasties. *Inter J Obesity* 19:256–360
- Dolbi SB (1996) La chirurgie de l'obésité morbide: des courts-circuits intestinaux à l'anneau gastrique ajustable. *Annales de chirurgie* 52:125–131
- Favretti F, Cadière GB, Segato G, Bruyns G, De Marchi F, Himpens J, Foletto M, Lise M (1995) Laparoscopic adjustable silicone gastric banding: technique and results. *Obes Surg* 5:364–371
- Favretti F, Cadière GB, Segato G, Himpens J, Busetto L, De Marchi F, Vertruyen M, Enzi G, De Luca M, Lise M (1997) Laparoscopic adjustable silicone gastric banding (Lap-Band®): how to avoid complications. *Obes Surg* 7:352–358
- Forsell P, Hallerback B, Glise H, Hellers G (1999) Complications following Swedish adjustable gastric banding: a long-term follow-up. *Obes Surg* 9:11–16
- Fricke J (1995) Obésité. *Abrégés Masson* 33–38
- Guerre-Millo M (1998) La leptine et l'obésité. *Biofutur* 192:829–841
- Jeanrenaud B, Cusin I, Rohner-Jeanrenaud F (1998) De Claude Bernard à la boucle régulatrice reliant l'hypothalamus à la périphérie: implication dans l'homéostasie du poids corporel et dans l'obésité. *CR Soc Biol* 192:829–841

- Kolanowski J (1997) Surgical treatment for morbid obesity. *Br Med Bull* 53:443–444
- Kunath U, Memari B (1995) Laparoskopisches »Gastric Banding« zur Behandlung der pathologischen Adipositas. *Chirurg* 66:1263–1267
- Kunath U, Susewind M, Klein S, Hofmann T (1998) Erfolg und Misserfolg beim laparoskopischen »Gastric Banding«. Ein 3-Jahres-Erfahrungsbericht. *Chirurg* 69:180–185
- Kuzmak L (1992) Stoma adjustable gastric banding. *Prob Gentle Surgery* 9:298–317
- Lecomte P, Marmuse JP (1996) Traitement de l'obésité morbide par cerclage gastrique ajustable en silicone J. *Chir Pairs* 133:226–228
- Morino M, Toppino M, Garrone C (1997) Disappointing long-term results of laparoscopic adjustable gastric banding. *Br J Surg* 84:868–869
- Morino M, Toppino M, Garrone C, Morino F (1994) Laparoscopic adjustable silicone gastric banding for the treatment of morbid obesity. *Br J Surg* 81:1169–1170
- NIH Conference (1991) Gastro-intestinal surgery for severe obesity. Consensus development conference panel. *Ann Intern Med* 115:956–961
- Niville E, Vankeirsblick J, Dams A, Anne T (1998) Laparoscopic adjustable esophagogastric banding: a preliminary experience. *Obes Surg* 8:39–43
- O'Brien PE, WA, Brown Smith, McMurrick PJ (1999) Prospective study of a laparoscopically placed, adjustable gastric band in the treatment of morbid obesity. *Br J Surg* 86:113–118
- Paganini AM, Guerrieri M, Feliciotti F, Lezoche E (1997) Laparoscopic adjustable silicone gastric banding (LASGB) for the treatment of morbid obesity. *Surg Technol Intern* 5:147–150
- Reinhold RB (1982) Critical analysis of long-term weight loss following gastric bypass. *Surg Gynecol Obstet* 155:385–394
- Sagar PM (1995) Surgical treatment of morbid obesity. *Br J Surg* 82:732–739
- Stieger R, Thurnheer M, Lange J (1997) Chirurgische Therapie der morbiden Obesitas: Indikation, Technik des Laparoscopic Gastric Banding und erste Resultate. *Ther Umschau* 54:521–528
- Suter M, Giusti V, Heraief E, Jayet C, Jayet A (1999) Early results of laparoscopic gastric banding compared to open vertical banded gastroplasty. *Obes Surg* 9:374–380
- Terra JL (1997) Le point de vue du psychiatre sur le traitement de l'obésité morbide par gastroplastie. *Annales de chirurgie* 51:177–182
- Weiner R (1999) Manual Laparoskopisches Gastric Banding. Barth Verlag, Heidelberg, Leipzig
- Weiner R, Datz M, Wagner D, Bockhorn H (1999) Quality of life outcome after laparoscopic adjustable gastric banding for morbid obesity. *Obes Surg* 9:539–545
- Weiner R, Wagner D, Bockhorn H (1999) Laparoscopic gastric banding for morbid obesity. *J Laparoendosc Adv Surg Technol* 9:23–30
- Weiner R, Bockhorn H., Rosenthal R, Wagner D (2001) A prospective randomized trial of different laparoscopic gastric banding techniques for morbid obesity. *Surg Endosc* 15:63–68
- Zhang Y, Proenca R, Maffei M (1994) Positional cloning of the mouse obese gene and its human homologue. *Nature* 372:425–482



---

## 5 Laparoscopic Heller Esophagomyotomy for Achalasia

### 5.1 Operating Room Setup: Position of the Patient

The patient is placed supine with a slight 10° reverse Trendelenburg position. The surgeon stands between the patient's legs. The first assistant is on the right of the patient and a second assistant is on the left of the patient. The monitor is placed behind and to the left side of the patient's head (● Figs. 5.1, 5.2).

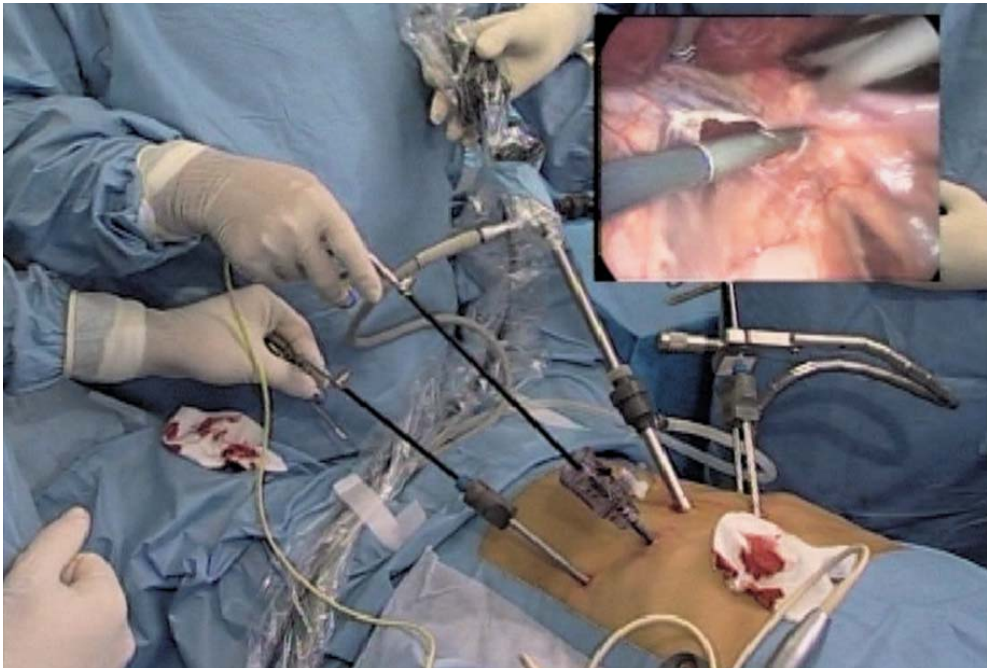


Fig. 5.1. OR setup

## 5.2 Recommended Instruments

- A 0° endoscope (a 30° endoscope can be useful)
- A 10-mm trocar
- Four 5-mm trocars
- Two Johan fenestrated grasping forceps
- Five-millimetre straight or curved coagulating shears
- A straight 5-mm grasping forceps
- A 5-mm needle holder
- A 5-mm suction cannula
- A 5-mm hooked grasping forceps
- A 10-mm oesophageal dilatation balloon
- Harmonic scalpel if available

## 5.3 Trocar Placement and Exposure (► Fig. 5.2)

The 10-mm trocar is positioned in the middle of the xipho-umbilical line. The left operating trocar is positioned 5 cm to the right of this first trocar. The right-hand operating trocar is positioned in the left median subcostal position. A third 5-mm trocar in the left lateral subcostal position is essentially used for exposure. A final

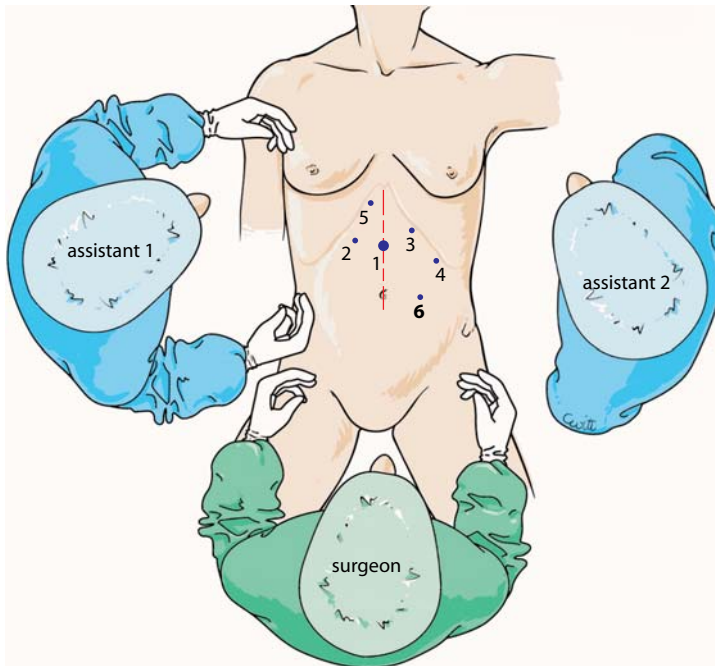


Fig. 5.2. Position of trocars

right median subcostal 5-mm trocar enables retraction of the liver. Depending on the degree of obesity of the patient, this latter port will be positioned closer to the xiphoid.

Dissection starts with opening the pars flaccida while pulling from the left on the stomach. Hepatic nerves in the pars flaccida can be sectioned. A left hepatic artery should best be preserved.

#### 5.4 Dissection of the Hiatus

The right crus of the diaphragm is exposed (◀ Fig. 5.3).

The peritoneum is opened medially to the right crus, starting from the middle, and top to bottom, to respect the posterior part of the hiatus. After opening the peritoneum, the mediastinal dissection is started.

The top of the hiatus at the level of the upper V of the crura is reached. The left crus is rapidly recognized (▶ Fig. 5.4).

The peritoneum medial to the left crus is opened to the middle part. The hiatus is thus dissected in its anterior half, as is exposed the anterior wall of the mediastinal oesophagus (▶ Fig. 5.5)

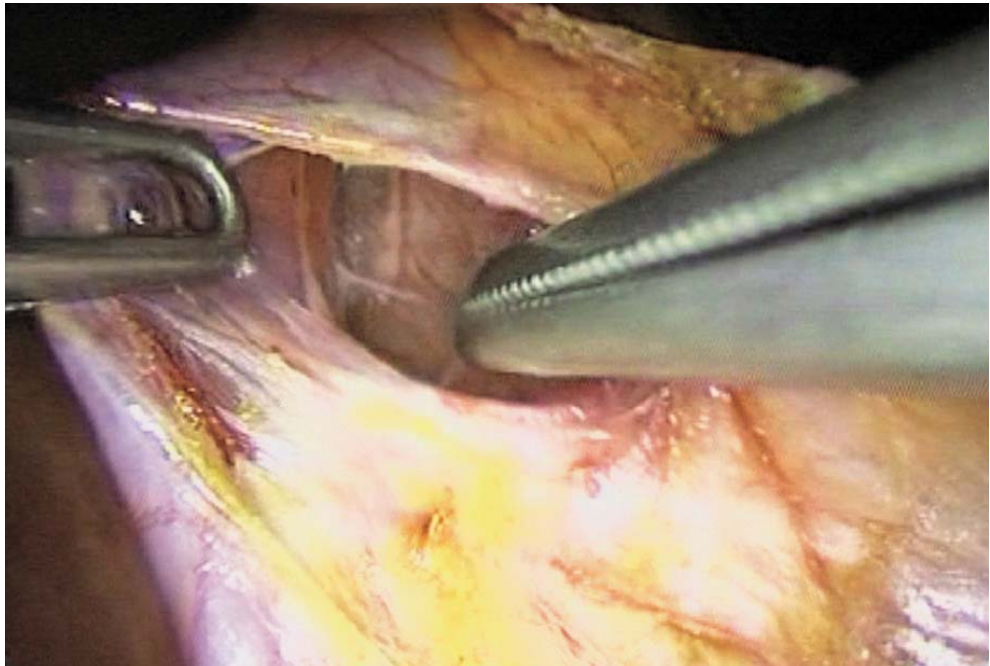


Fig. 5.3. Exposure of right crus

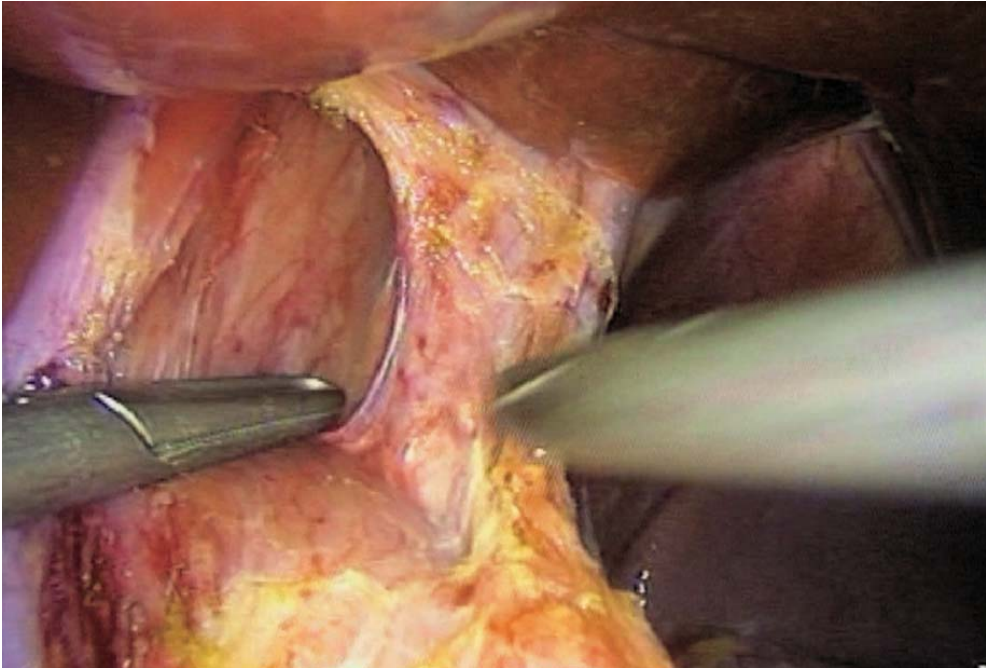


Fig. 5.4. Exposure of left crus and lower mediastinum

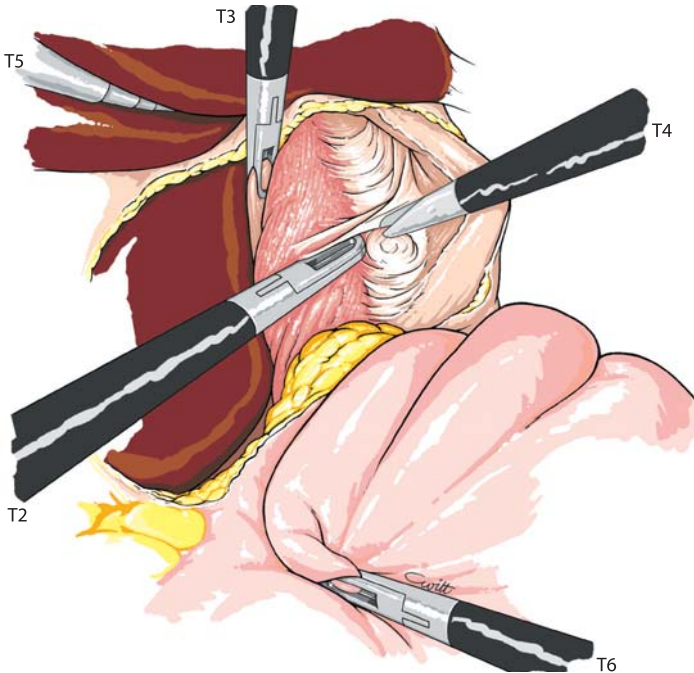


Fig. 5.5. Exposure of mediastinal oesophagus



## 5.5 Dissection of the Oesophagus

The anterior wall of the oesophagus is gently dissected, using a blunt instrument and proceeding with the greatest care. Exposure of at least 10 cm of mediastinal oesophagus is necessary. The right and left pleura are reclinced. During this stage of the operation, exposure is optimized by a grasping forceps lifting the upper V of the hiatus (▶ Fig. 5.6).

## 5.6 Esophageal Myotomy

The myotomy starts 1 cm above the gastro-oesophageal junction, using the coagulating shears (▶ Fig. 5.7). The longitudinal muscular fibres are incised in the middle of the anterior wall of the oesophagus. The endoscope should zoom in as close as possible to the operative field. The circular fibres appear. They are delicately transected. The submucosal plane is exposed (▶ Fig. 5.8).

The myotomy is carried on. A fenestrated forceps delicately explores the dissection plane between the mucosa and the muscular layers (▶ Fig. 5.9). The muscular fibers are resected with the coagulating scissors over a distance of 6–7 cm along the mediastinal oesophagus (▶ Figs. 5.10, 5.11).

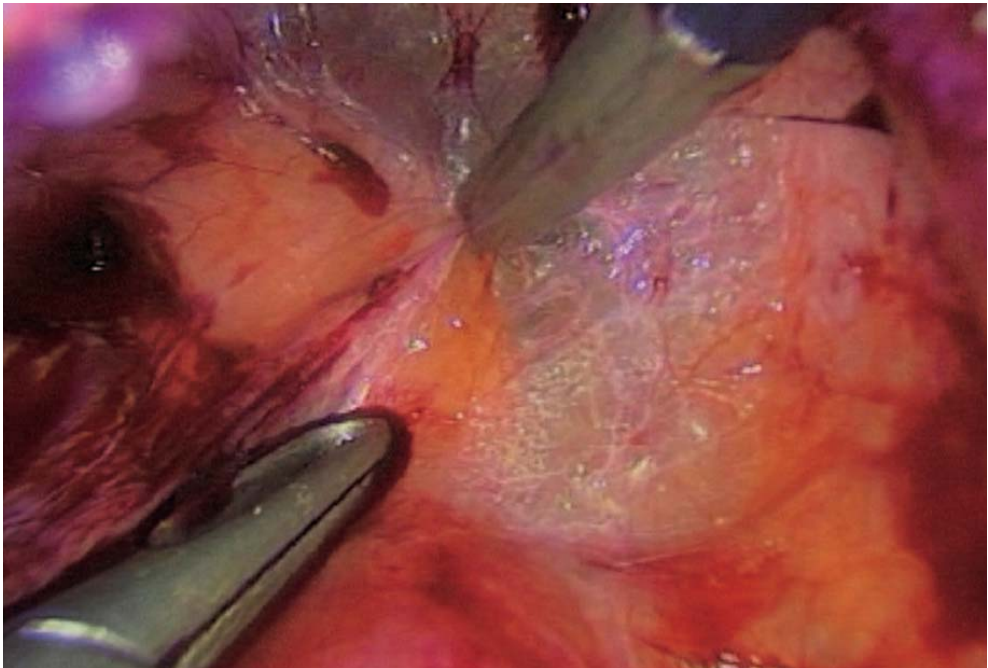


Fig. 5.6. Mediastinal dissection

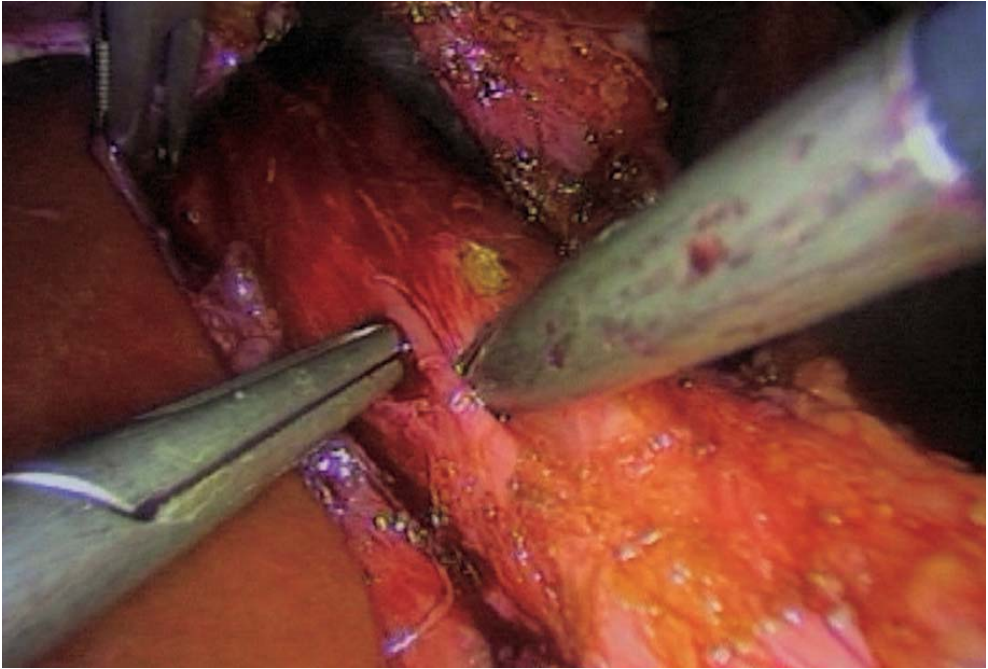


Fig. 5.7. Anterior vagus

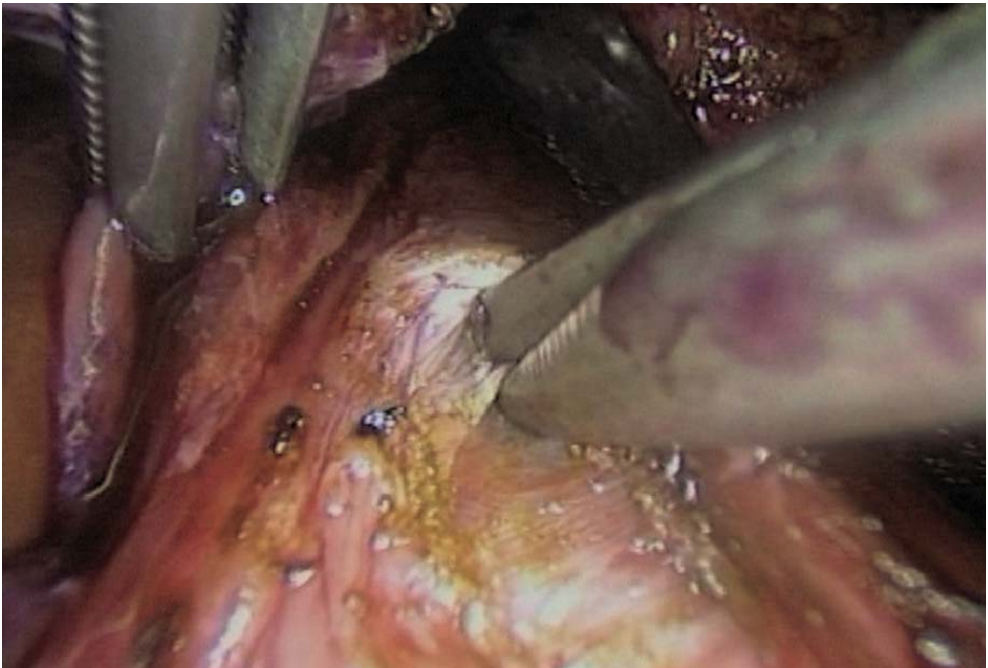


Fig. 5.8. Start of myotomy

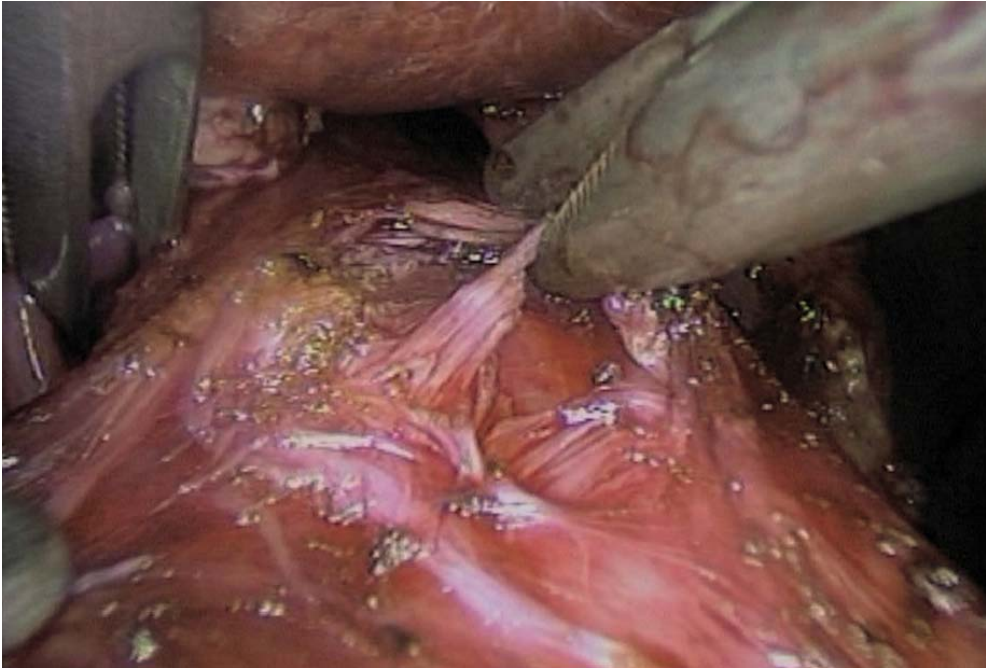

Fig. 5.9. Resection of circular muscle

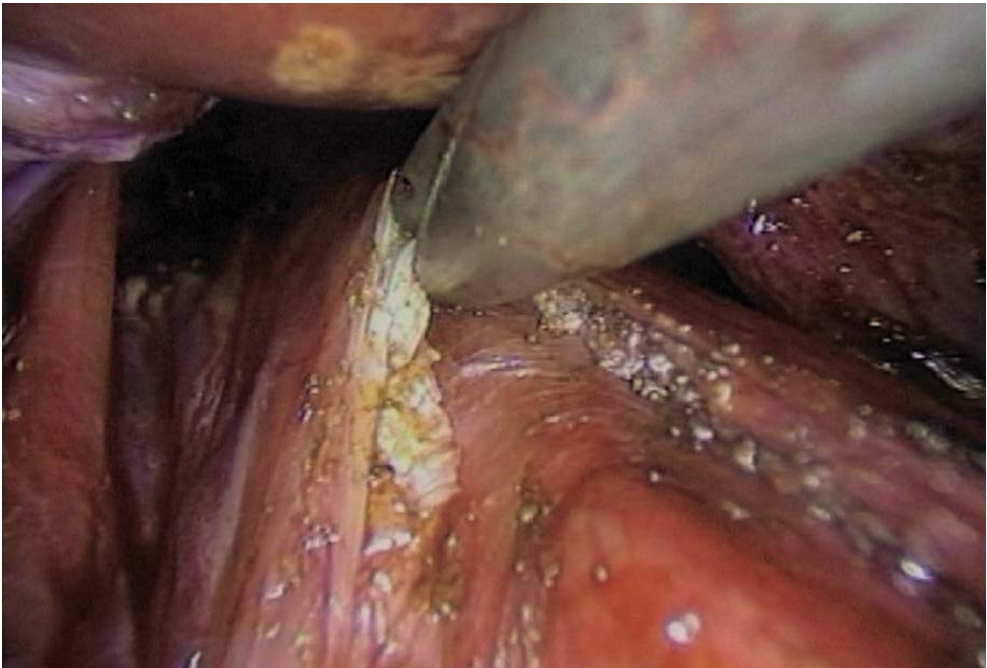
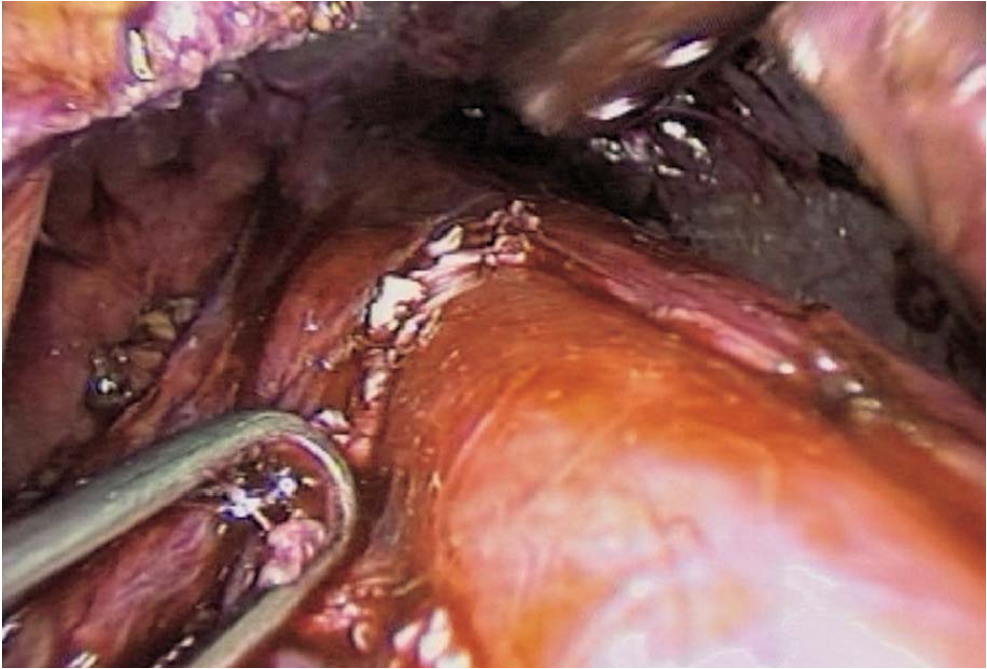
Fig. 5.10. Upper limit





**Fig. 5.11. Submucosal layer of oesophagus exposed**

The myotomy is continued towards the esogastric junction. The dissection becomes increasingly delicate and the muscular fibres are dissected progressively (► Figs. 5.12, 5.13). Resection is performed with the coagulating scissors. This is continued a further 2 cm downwards from the gastro-oesophageal mucosal junction, and must always be monitored by an intraoperative gastroscopy (● Fig. 5.14). The myotomy is checked for leakage by instillation of methylene blue.

### **5.7 Refection of the Angle of His: Anti-reflux Valve**

An anterior anti-reflux valve is made with the fundus. If the hiatus is not enlarged, the gastric valve is sutured to left side of the myotomy, just recreating the normal anatomy of the angle of His (► Fig. 5.15).

The anterior valve, however, may be total, covering the myotomy, performed by suturing the gastric tissue to the right edge of the myotomy with four to five intracorporeal sutures using 2/0 nonabsorbable ligatures (► Fig. 5.16). The right part of the anterior valve can be sutured to the right crus with two or three stitches (► Fig. 5.17).



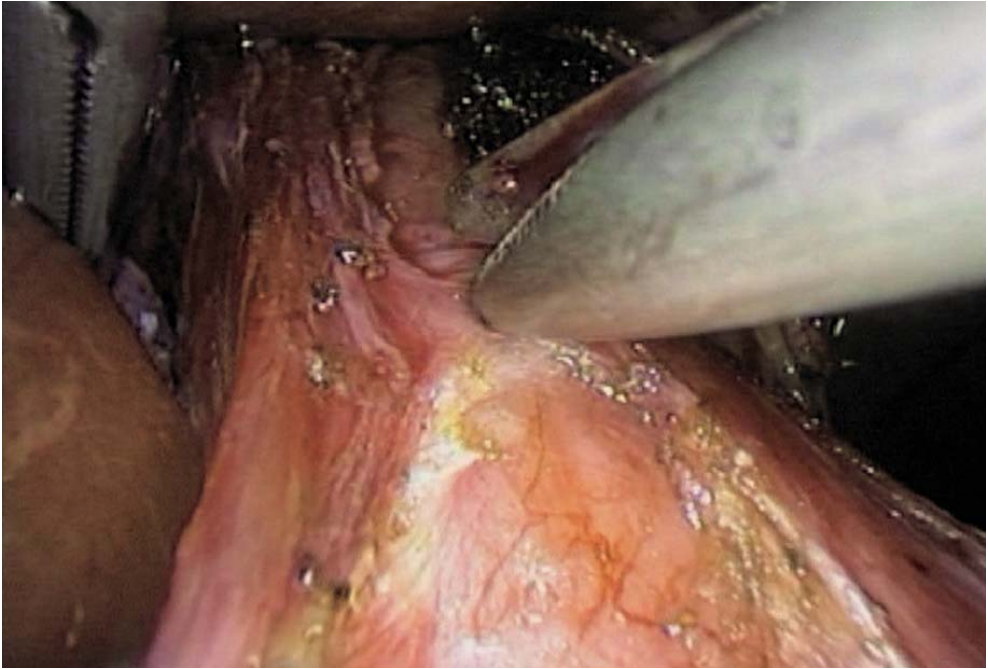

Fig. 5.12. Inferior part of myotomy



Fig. 5.13. Myotomy near completion

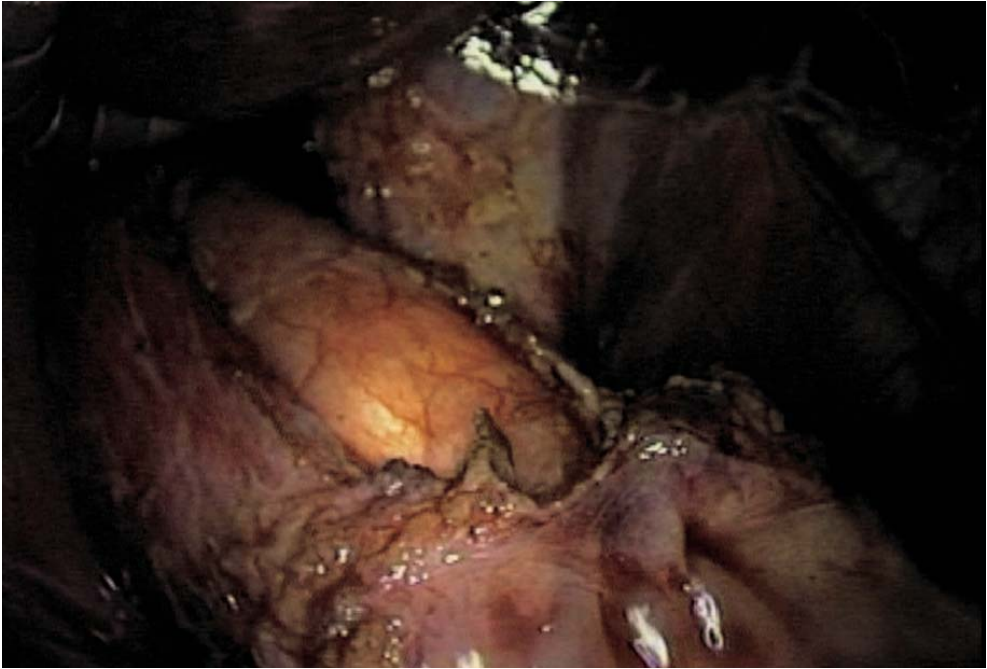


Fig. 5.14. Endoscopic control of esogastric junction

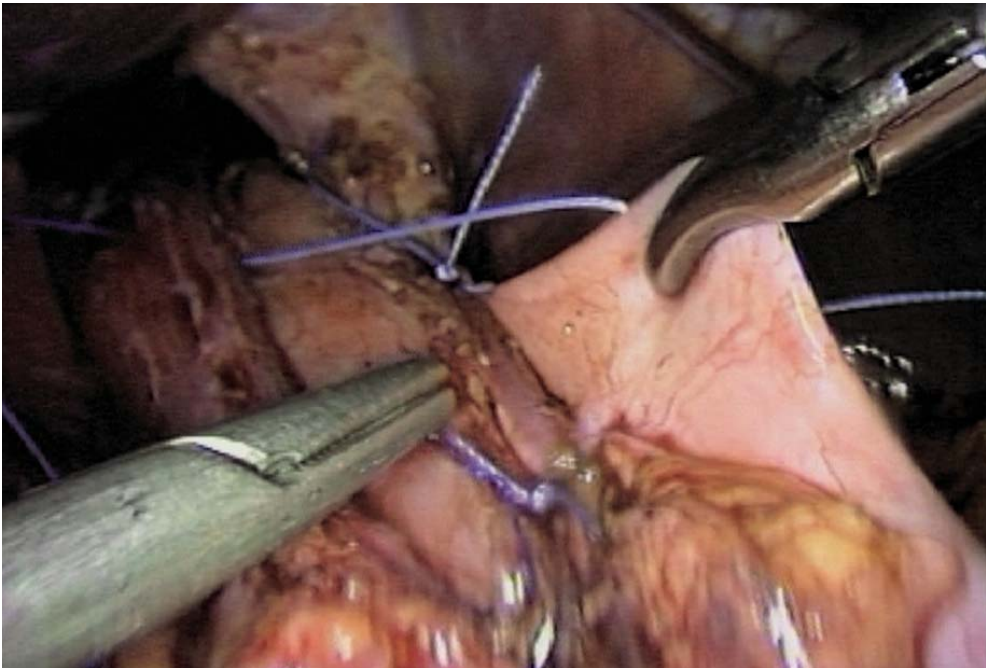


Fig. 5.15. Gastric wrap on left edge of the myotomy

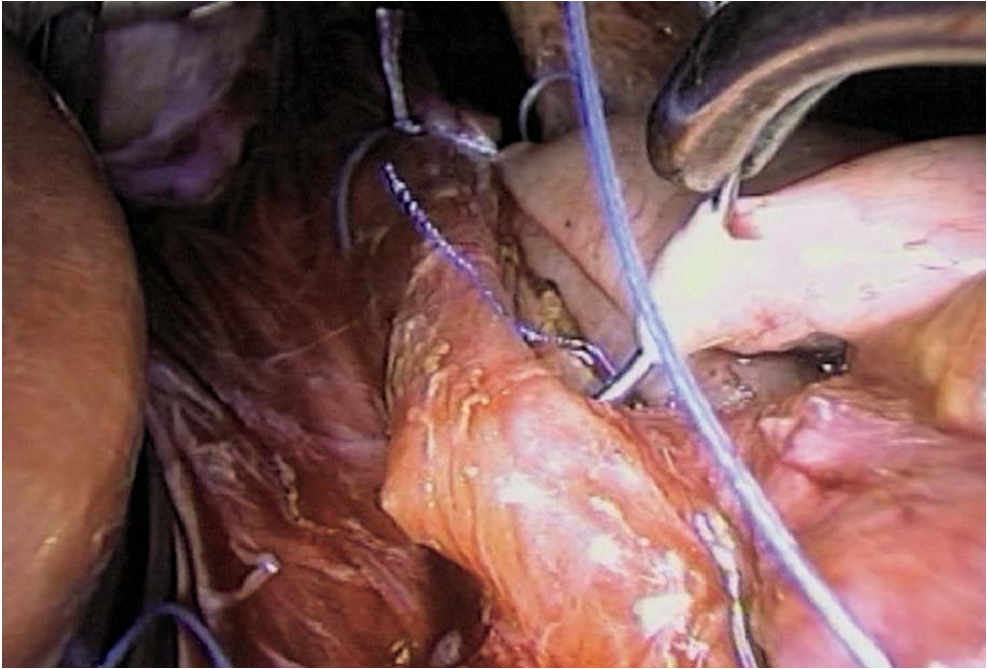


Fig. 5.16. Gastric wrap on the right edge of the myotomy

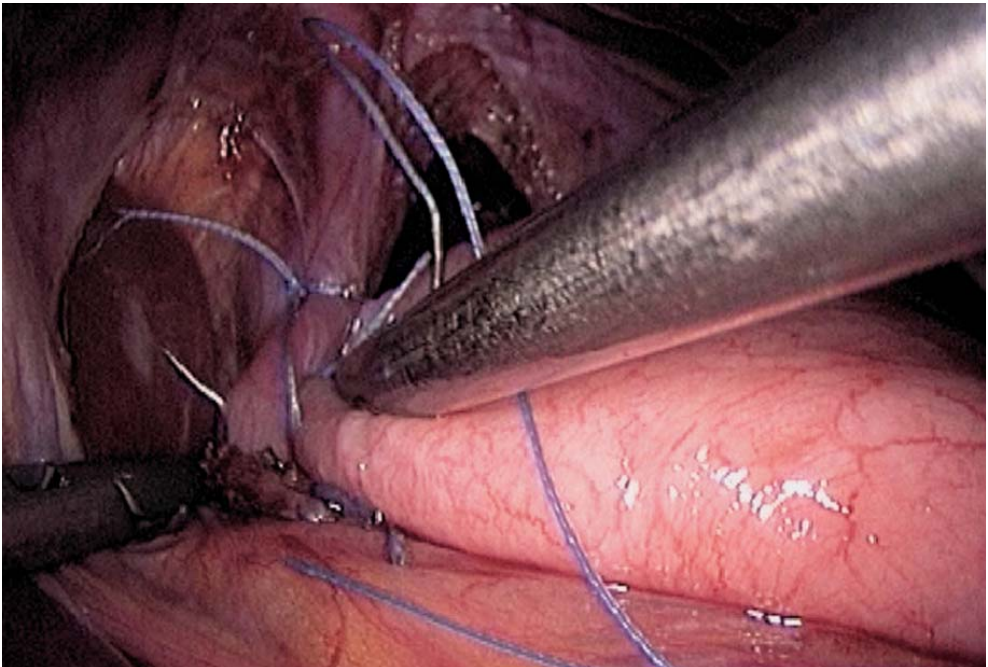


Fig. 5.17. Suturing the gastric wrap to the crura



### 5.8 Additional Surgery on the Hiatus: Peritoneal Lavage -Drainage

In the absence of a large hiatal defect, and as it has not been totally dissected, no extra closure is required. However, a large widening of the hiatus requires suturing the pillars of the diaphragm. This is usually performed in the upper part of the crura, by interrupted intracorporeal 2/0 nonabsorbable stitches (▶ Fig. 5.18).

The operative field is checked for bleeding. A suction drainage may be left.

### 5.9 Tips and Comments

- Always position the trocars after completion of the pneumoperitoneum and direct them in the direction of the hiatus.
- Myotomy can be facilitated by an oesophageal dilatation catheter inflated to a moderate pressure of 18 French.
- Harmonic scalpel can prove helpful in the transection of the muscular fibres. The mucosal plane, however, must not be exposed to the active blade of the instrument.
- A retro-oesophageal presentation lace can be positioned to better outline the oesophageal gastric junction and to tract on the abdominal oesophagus.

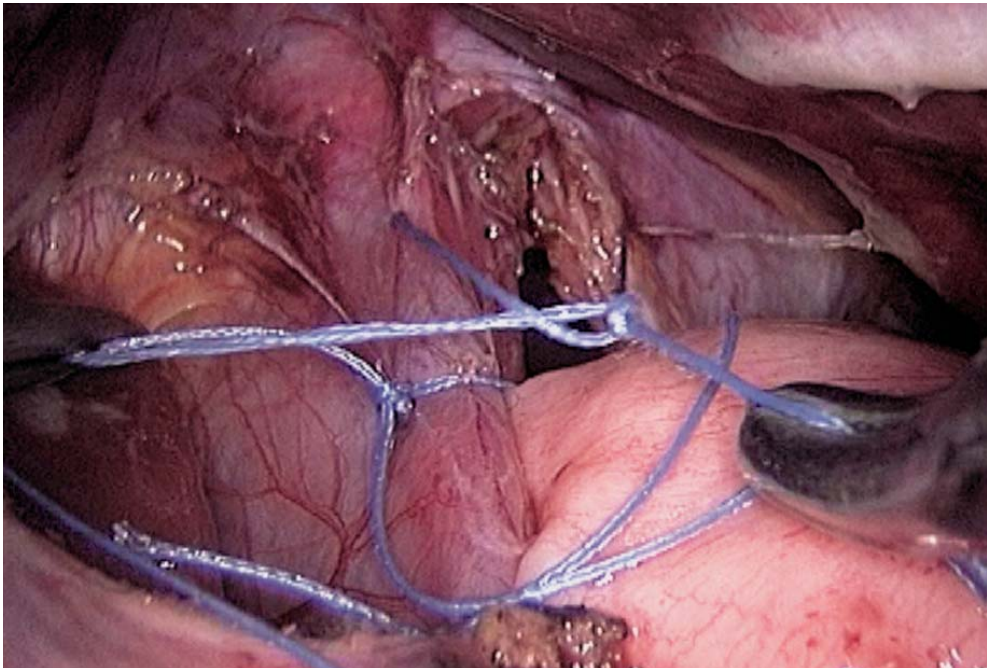


Fig. 5.18. Closure of the crura



- The liver may be reclined by an auto-static retractor and a specific instrument, especially in the presence of steatosis or hypertrophy of the left lobe.
- A left hepatic artery is frequently encountered. It should be preserved, depending on its size.
- An additional 5-mm trocar can be positioned to expose the two edges of the myotomy, thus achieving a symmetrical exposure, either by traction on the instruments or by the placement of two presentation sutures.

## Literature

- Abid S, Champion G, Richter JE et al (1994) Treatment of achalasia: the best of both worlds. *Am J Gastroenterol* 89:979–985
- Amarel JF (1994) Laparoscopic myotomies using an ultrasonically activated scalpel. *Surg Endosc* 8:463
- Ancona E, Peracchia A, Zaninotto G et al (1993) Heller laparoscopic cardiomyotomy with antireflux anterior fundoplication (Dor) in the treatment of esophageal achalasia. *Surg Endosc* 7:459
- Andreollo NA, Earlam RJ (1987) Heller's myotomy for achalasia: is an added anti-reflux procedure necessary? *Br J Surg* 74:765–769
- Anselmino M, Hinder RA, Filipi CJ, Wilson P (1993) Laparoscopic Heller cardiomyotomy and thoracoscopic oesophageal long myotomy for the treatment of primary oesophageal motor disorders. *Surgical Laparoscopy and Endoscopy* 3:437–441
- Bonavina L, Nosadini A, Bardini R, Baessato M, Peracchia A (1992) Primary treatment of oesophageal achalasia. *Arch Surg* 127:222–227
- Buess G, Cuschieri A, Manneke K, Schneider HJ, Becker HD (1993) Technique and preliminary results of laparoscopic cardiomyotomy. *Endoscopic Surgery* 1:76–81
- Crookes PF, Wilkinson AJ, Johnston GW (1989) Heller's myotomy with partial fundoplication. *Br J Surg* 76:98–99
- Csendes A, Braghetto I, Henriquez A, Cortes C (1989) Late results of a prospective randomised study comparing forceful dilatation and oesophagomyotomy in patients with achalasia. *Gut* 30:299–304
- Cuschieri A (1993) Endoscopic oesophageal myotomy for specific motility disorders and non-cardiac chest pain. *Endoscopic Surgery* 1:280–285
- Cuschieri A, Nathanson LK, Shimi SM (1992) Thoracoscopic oesophageal myotomy for motility disorders. In: Cuschieri A, Buess G, Perissat J (eds) *Operative manual of endoscopic surgery*. Springer, Berlin Heidelberg New York, pp 141–148
- Cuschieri A, Shimi SM, Nathanson LK (1992) Laparoscopic cardiomyotomy for achalasia. In: Cuschieri A, Buess G, Perissat J (eds) *Operative manual of endoscopic surgery*. Springer, Berlin Heidelberg New York, pp 298–302
- Dallemagne B (1993) Endoscopic approaches to oesophageal disease. *Baillière's Clinical Gastroenterology* 7:795–822
- DePaula AI, Hashiba K, Bafutto M (1995) Laparoscopic approach to esophageal achalasia. *Surg Endosc* 9:220
- Dor J, Humbert P, Figarella J (1962) L'intérêt de la technique de Nissen modifiée dans la prévention du reflux après cardiomyotomie extra-muqueuse de Heller. *Mémoires de l'Académie de Chirurgie* 88:877–883
- Ellis FH (1991) Functional disorders of the esophagus. In: Zuidema GD, Orringer MB (eds) *Shackelford's surgery of the alimentary tract*, 3rd edn. WB Saunders, Philadelphia, pp 146–163
- Ellis FH (1993) Oesophagomyotomy for achalasia: a 22-year experience. *Br J Surg* 80:882–885
- Ellis FH, Crozier RE, Gibbs SP (1986) Reoperative achalasia surgery. *J Thorac Cardiovasc Surg* 92:859–865

- Jaakkola A, Ovaska J, Isolauri J (1991) Esophagocardiomyotomy for achalasia. *Eur J Surg* 157:407–410
- Katz P (1994) Achalasia: two effective treatment options—let the patient decide. *Am J Gastroenterol* 89:969–970
- Mercer CD, Hill L (1986) Reoperation after failed esophagomyotomy for achalasia. *Can J Surg* 29:177–180
- Monson JRT, Darzi A, Carey PD, Guillou PJ (1994) Thoracoscopic Hellers's cardiomyotomy: a new approach for achalasia. *Surgical Laparoscopy and Endoscopy* 4:6–8
- Mucio M (1994) Achalasia: laparoscopic treatment. *Surg Endosc* 8:463
- Pai GP, Ellison RG, Rubin JW, Moor HV (1984) Two decades of experience with modified Heller's myotomy for achalasia. *Ann Thorac Surg* 38:201
- Paricio PP, Martinez de Haro L, Ortiz A, Aguayo JL (1990) Achalasia of the cardia: results of oesophagomyotomy and posterior partial fundoplication. *Br J Surg* 77:1371–1374
- Parkman HP, Reynolds JC, Ouyang A et al (1993) Pneumatic dilatation or esophagomyotomy treatment for idiopathic achalasia: clinical outcomes and cost analysis. *Dig Dis Sci* 38:75–85
- Pellegrini C, Wetter LA, Patti M et al (1992) Thoracoscopic Esophagomyotomy. *Ann Surg* 216:291–299
- Pellegrini CA, Leichter R, Patti M et al (1993) Thoracoscopy esophageal myotomy in the treatment of achalasia. *Ann Thorac Surg* 56:680–682
- Rosati R, Fumigalli U, Bonavina A et al (1994) Laparoscopic Heller-Dor procedure with intraoperative balloon dilatation of the cardia. *Surg Endosc* 8:463
- Sauer L, Pellegrini CA, Way LW (1989) The treatment of achalasia. *Arch Surg* 124:929–932
- Schwartz HM, Cahow CE, Traube M (1993) Outcome after perforation sustained during pneumatic dilatation for achalasia. *Dig Dis Sci* 38:1409–1413
- Shimi S, Nathanson LK, Cuschieri A (1991) Laparoscopic cardiomyotomy for achalasia. *J R Coll Surg Edinb* 36:152–154
- Spencer J (1994) Cardiomyotomy. In: Ballantyne GH, Leahy PF, Modlin IM (eds) *Laparoscopic surgery*. WB Saunders, Philadelphia pp 400–416
- Swanstrom LL, Pennings J (1995) Laparoscopic esophagomyotomy for achalasia. *Surg Endosc* 9:286–292
- Toupet A (1936) Technique d'oesophago-gastroplastie avec phrénogastropexie appliquée dans la cure radicale des hernies hiatales et comme complément de l'opération de Heller dans les cardiospasmés. *Mémoires de l'Académie de Chirurgie* 89:394–401
- Yang HK, Del Guercio Louis RM, Steichen FM (1995) Thoracoscopic Belsey-Mark IV fundoplication. *Surg Endosc* 9:622

## 6 Laparoscopic Splenectomy

### 6.1 Operating Room Setup: Position of the Patient

The patient is placed supine, with slight reverse Trendelenburg position, and with a right rotation of 30°. The surgeon stands to the right of the patient, and the first assistant to the surgeon's left. A second assistant may be placed to the left of the patient (➤ Fig. 6.1). The video monitor is positioned to the left of the patient's head.

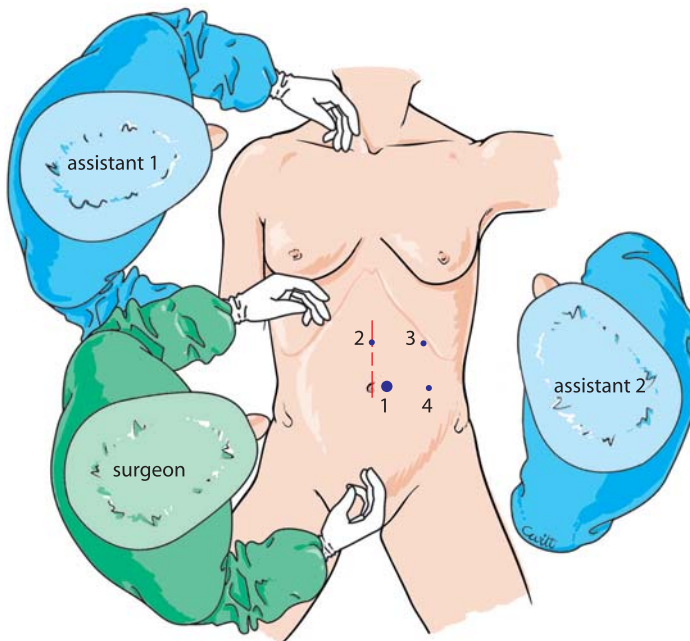


Fig. 6.1. OR setup – position of trocars

## 6.2 Recommended Instruments

- One or two 10-mm trocars
- Three 5-mm trocars
- A 0° endoscope
- Two Johan fenestrated grasping forceps
- Five-millimetre straight or curved coagulating shears
- A blunt paddle
- A straight 5-mm grasping forceps
- A 5-mm dissector
- A 5-mm needle holder
- A 5-mm clip applicator
- A 5-mm suction cannula
- Vascular linear staplers
- Harmonic scalpel if available, or LigaSure
- A strong specimen retrieval bag

## 6.3 Trocar Placement and Exposure

The pneumoperitoneum is created with a Veress needle. The first 10-mm trocar is inserted at the left margin of the umbilicus. The skin incision must match the size of the trocar. Insertion is oblique, through the muscle, in the direction of the spleen to avoid subsequent incisional hernias.

The other three 5-mm operating trocars are positioned as follows: the first trocar is on the median line, 8 cm above the umbilicus; a second operating trocar in a left subcostal position on the axillary line enables gastroepiploic mobilization; a left 5-mm operating trocar is positioned in the left lateral position, 10 cm from the umbilicus. The peritoneal cavity is explored, especially looking for accessory spleens (▶ Fig. 6.1).

## 6.4 Approach of the Spleen

The left colic omentum is opened using the harmonic scalpel (▶ Fig. 6.2). With the 5-mm subcostal instrument, blunt paddle or fenestrated forceps, the stomach and omentum are reclined rightwards (▶ Fig. 6.3). The body and tail of the pancreas are easily visualized at this stage. The splenic artery is easily found. It is dissected downwards. The 5-mm dissector enables a precise dissection and elective control of the splenic artery using clips, ligature or stapling. Control of the splenic vein is performed in the same way distal to the caudal part of the pancreas (▶ Figs. 6.4–6.6).



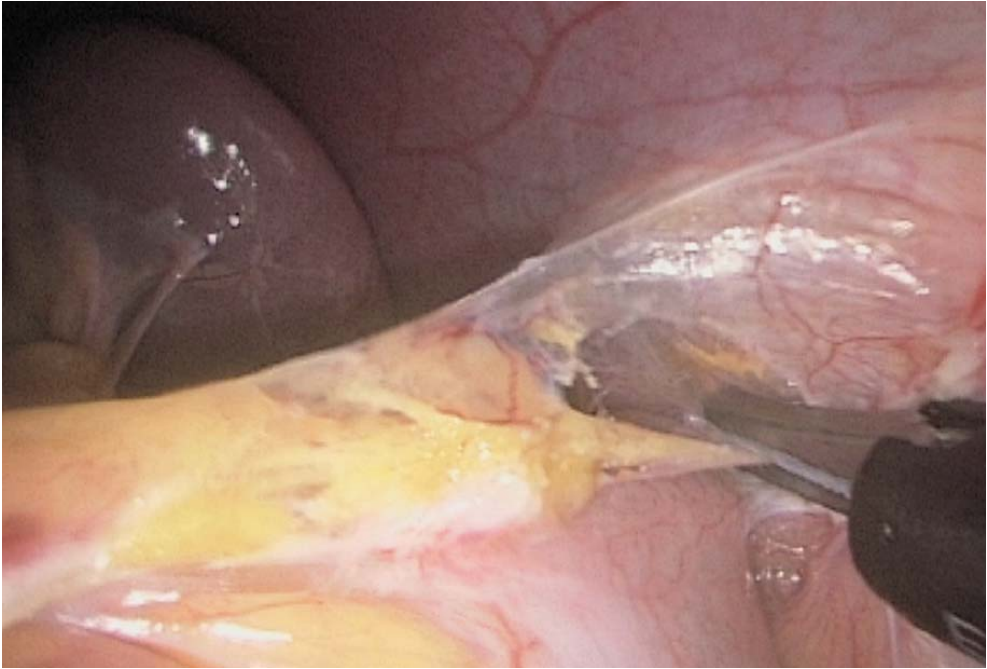

Fig. 6.2. Taking down the splenic flexure

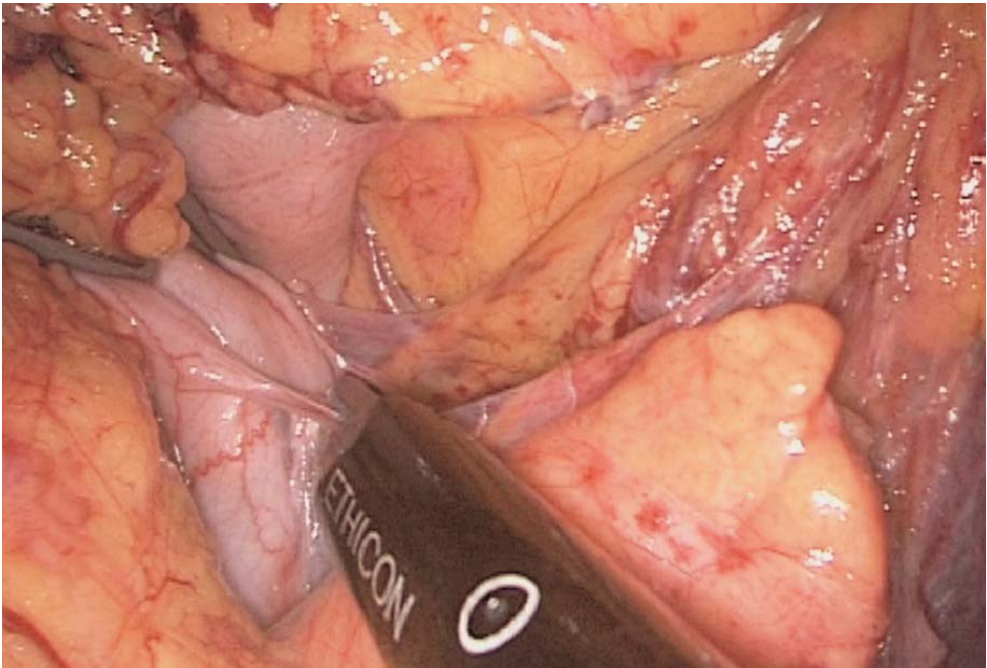


Fig. 6.3. Freeing the short gastric vessels

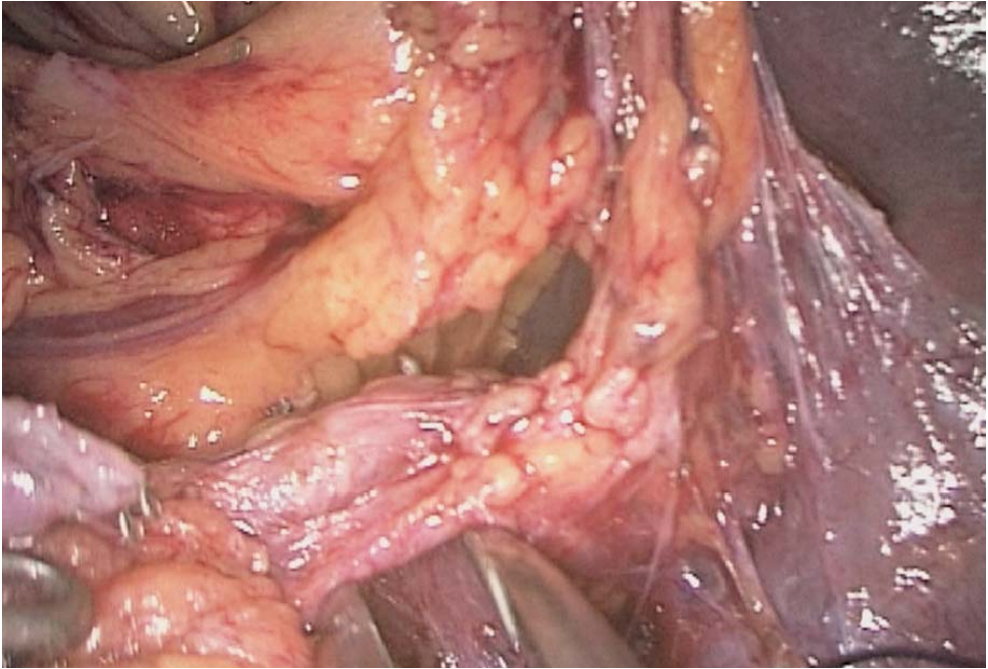


Fig. 6.4. Exposure of the splenic vessels

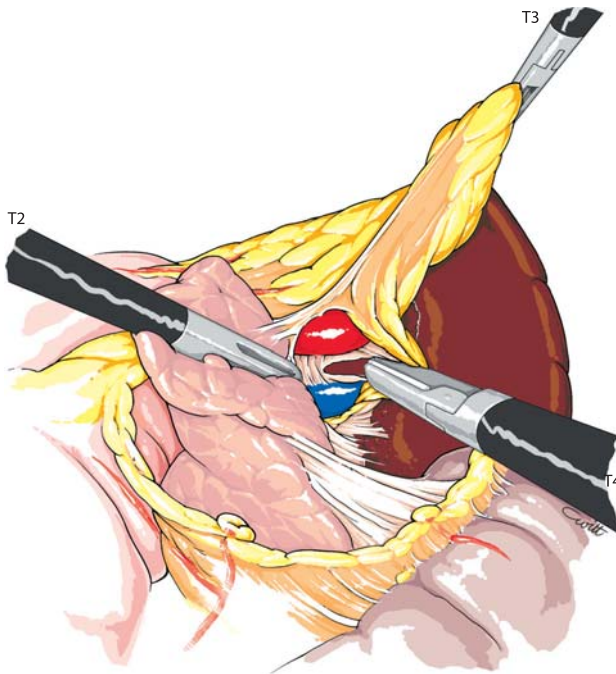


Fig. 6.5. Dissection of the splenic vessels

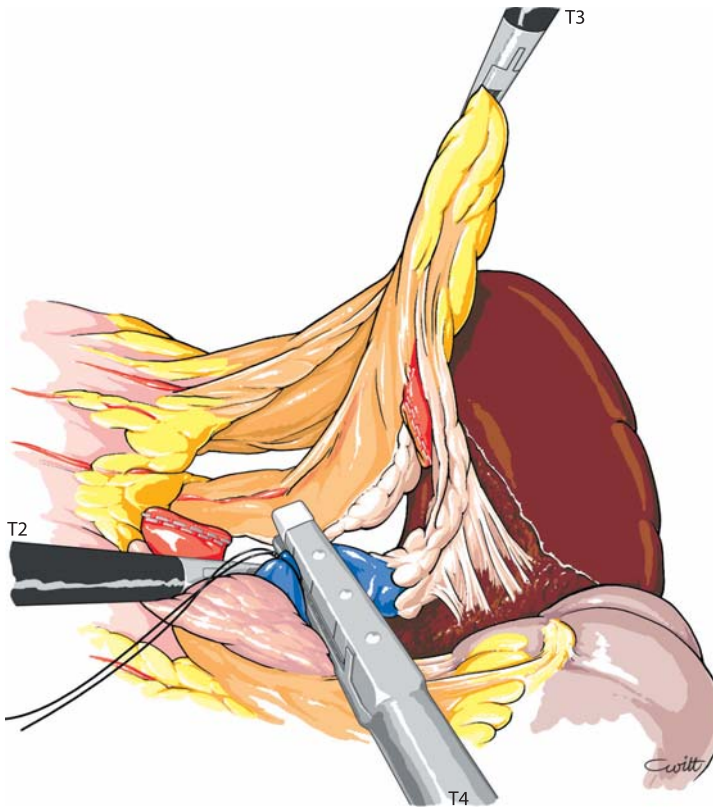


Fig. 6.6. Control of the splenic vein

### 6.5 Freeing the Splenic Capsule

The parietal attachments of the lower pole of the spleen are freed using the coagulating shears or harmonic scalpel (► Fig. 6.7). An extra arterial branch is frequently found in this area and is controlled by clips.

### 6.6 Control of Short Gastric Vessels (► Fig. 6.8)

Dissection continues medially. Short gastric vessels are controlled either by harmonic scalpel or clips or by linear stapling. The last diaphragmatic attachments on the upper pole of the spleen are transected by coagulation or with clips.



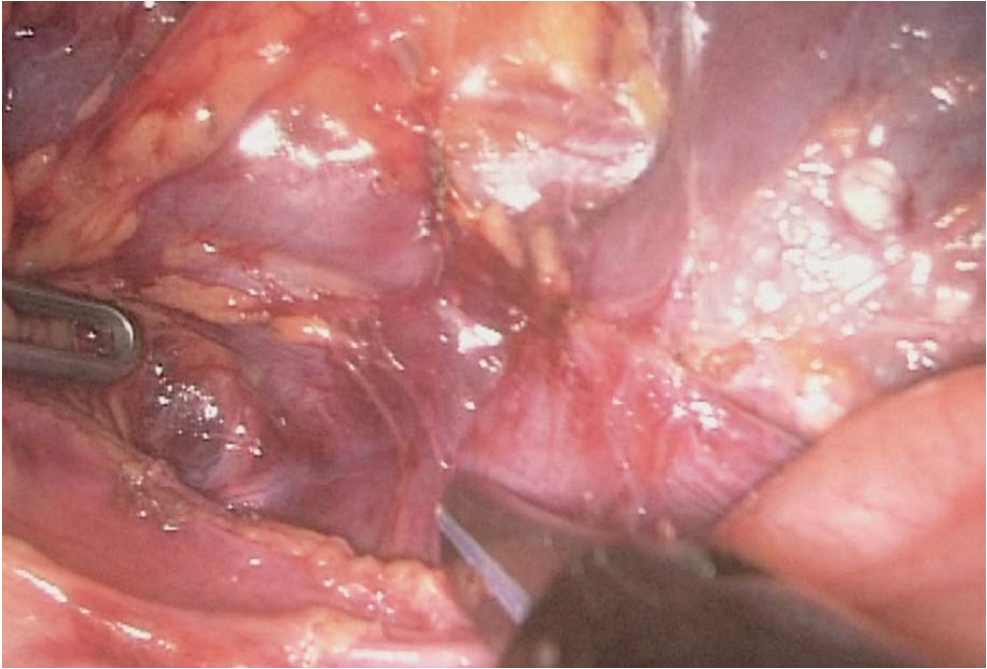


Fig. 6.7. Release of the lower capsular attachments

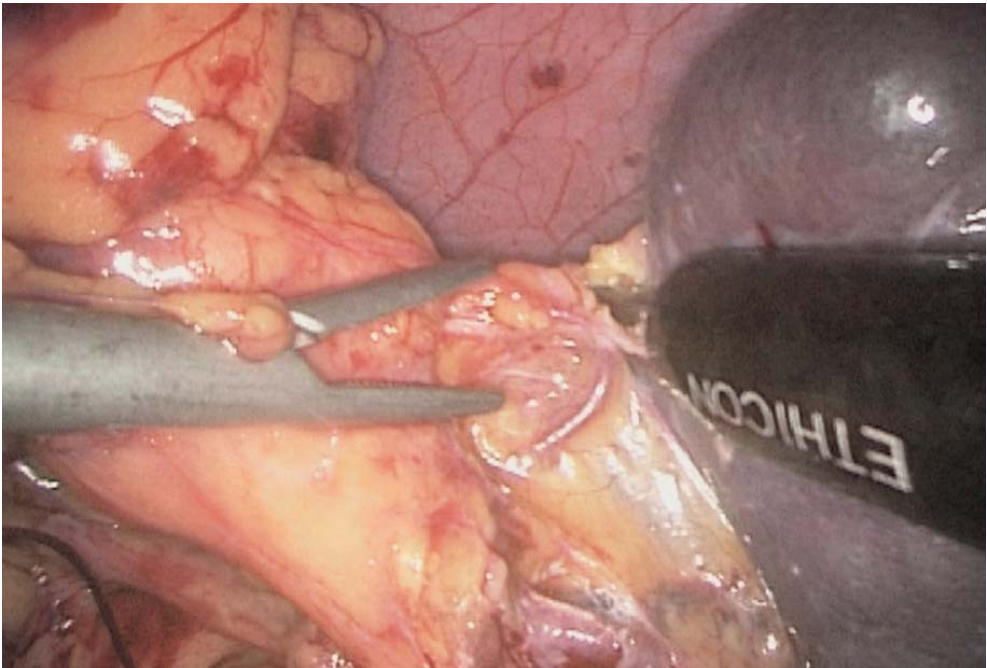


Fig. 6.8. Ligation of the short gastric vessels with harmonic scalpel



### 6.7 Dissection of Final Splenic Capsular Attachments (▶ Fig. 6.9)

The spleen can be mobilized, allowing exposure of the lateral and upper attachments. These are transected with the harmonic scalpel or with the coagulating shears.

### 6.8 Specimen Retrieval: Drainage

A lateral 5-mm port is enlarged to 2 cm and a strong retrieval bag is introduced. The spleen is caught and the bag extracted (▶ Fig. 6.10). The splenic parenchyma can be fragmented inside the bag using Kelly forceps. The peritoneal cavity is cleaned with saline. The operative field is checked for bleeding (▶ Fig. 6.11). A suction drain is installed.

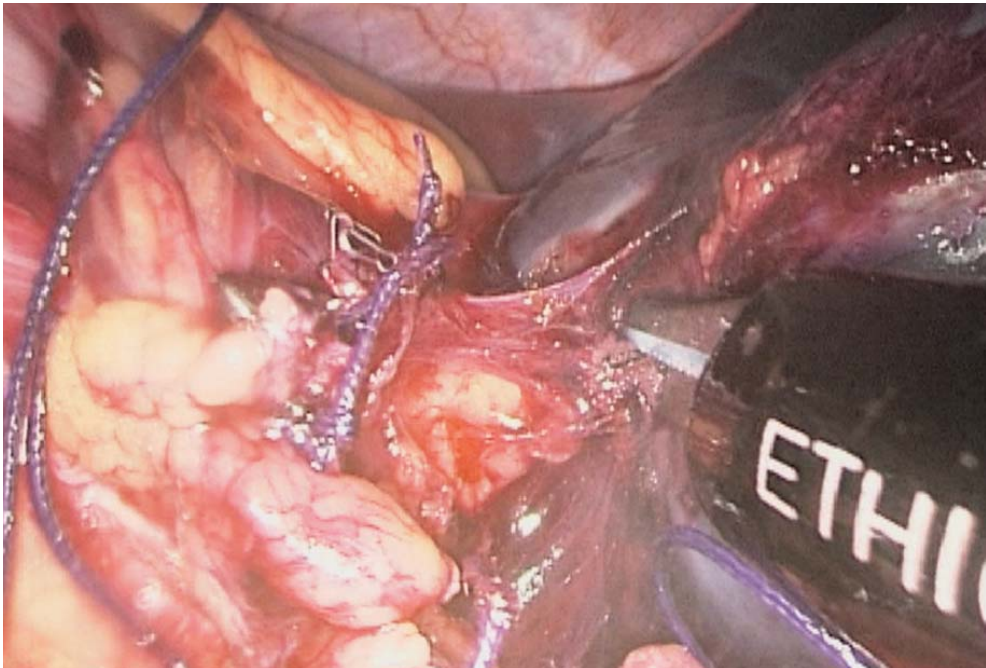


Fig. 6.9. Dissection of the final splenic capsular attachments

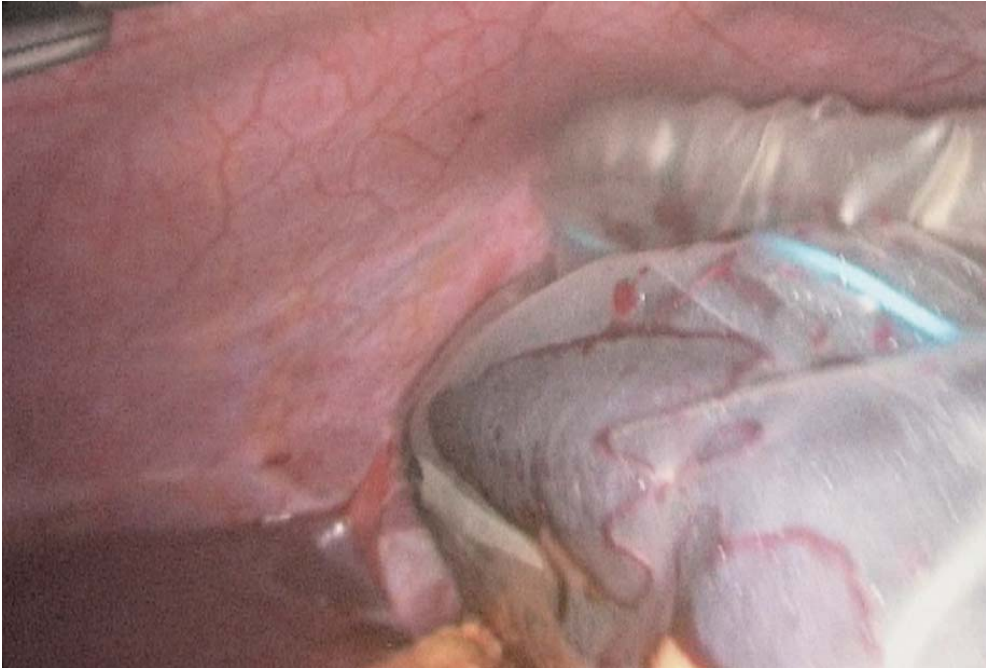

Fig. 6.10. Spleen in retrieval bag

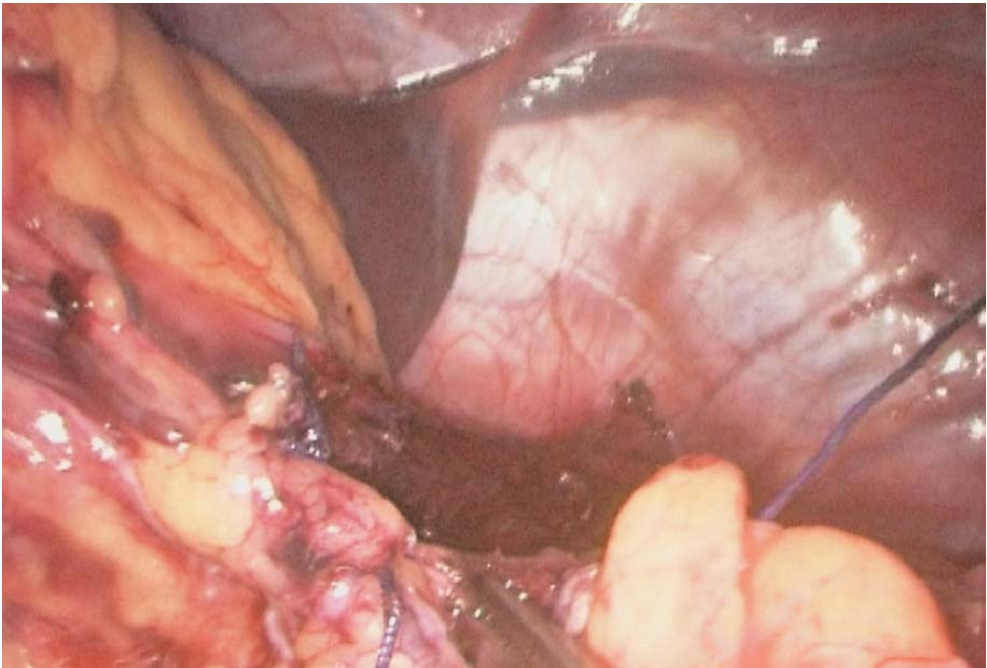


Fig. 6.11. Checking for bleeding

## 6.9 Tips and Comments

- Positioning of the patient in the posterolateral lumbar position results in changing the place of the surgeon for a left lateral position. This is a matter of choice. We prefer positioning the patient as indicated, with a maximum 30° left rotation.
- The use of a metallic suction cannula as a blunt dissector in the perisplenic fat is strongly recommended.
- Hand-assisted techniques may prove useful in case of a very large spleen at the stage of vascular dissection or extraction.
- The specimen retrieval incision can be a Pfannenstiel incision.
- Laparoscopic vascular clamps must be ready in case of need.

## Literature

- Baccarani U, Carroll BJ, Hiatt JR, Donini A, Terrosu G, Decker R, Chandra M, Bresadola F, Phillips EH (1998) Comparison of laparoscopic and open staging in Hodgkin disease. *Arch Surg* 133:517–522
- Brunt LM, Langer JC, Quasebarth MA, Whitman ED (1996) Comparative analysis of laparoscopic splenectomy versus open splenectomy. *Am J Surg* 172:596–601
- Carroll BJ, Phillips EH, Semel CJ, Fallas M, Morgenstern L (1992) Laparoscopic splenectomy. *Surg Endosc* 6:183–185
- Decker G, Millat B, Guillon F, Atger J, Linon M (1998) Laparoscopic splenectomy for benign and malignant hematologic diseases: 35 consecutive cases. *World J Surg* 22:62–68
- Delaitre B, Maignien B (1992) Laparoscopic splenectomy: technical aspects. *Surg Endosc* 6:305–308
- Duke BJ, Modin GW, Schecter WP, Horn JK (1993) Transfusion significantly increases the risk for infection after splenic injury. *Arch Surg* 128:1125–1132
- Flowers JL, Lefor AT, Steers J, Heyman M, Graham SM, Imbembo AL (1996) Laparoscopic splenectomy in patients with hematologic diseases. *Ann Surg* 224:19–28
- Friedman RL, Hiatt JR, Korman JL, Facklis K, Cymerman J, Phillips EH (1997) Laparoscopic or open splenectomy for hematologic disease: which approach is superior? *J Am Coll Surg* 185:49–54
- Glasgow RE, Yee LF, Mulvihill SJ (1997) Laparoscopic splenectomy: the emerging standard. *Surg Endosc* 11:108–112
- Glastein E, Guernsey JM, Rosenberg SA (1969) The value of staging laparotomy and splenectomy in the staging of Hodgkin's disease. *Cancer* 24:709–718
- Park A, Gagner M, Pomp A (1997) The lateral approach to laparoscopic splenectomy. *Am J Surg* 173:126–130
- Rege RV, Merriam LT, Joehl RJ (1996) Laparoscopic splenectomy. *Surg Clin North Am* 3:459–468
- Rhodes M, Rudd M, O'Rourke N, Nathanson L, Fielding G (1995) Laparoscopic splenectomy and lymph node biopsy for hematologic disorders. *Ann Surg* 222:43–46
- Schlinkert RT, Mann D (1995) Laparoscopic splenectomy offers advantages in selected patients with immune thrombocytopenic purpura. *Am J Surg* 170:624–627
- Smith CD, Meyer TA, Goretsky MJ, Hyams D, Luchette FA, Fegelman EJ, Nussbaum MS (1996) Laparoscopic splenectomy by the lateral approach: a safe and effective alternative to open splenectomy for hematologic diseases. *Surgery* 120:789–794
- Taragona EM, Espert JJ, Balague C, Piulachs J, Artigas V, Trias M (1998) Splenomegaly should not be considered a contraindication for laparoscopic splenectomy. *Ann Surg* 228:35–39

- Taragona EM, Espert JJ, Balangué C, Sugranes G, Ayuso C, Lomena F, Bosch F, Trias M (1998) Residual splenic function after laparoscopic splenectomy. *Arch Surg* 133:56–60
- Terrosu G, Donini A, Silvestri F, Petri R, Anania G, Barillari G, Bacarani U, Risaliti A, Bresadola F (1996) Laparoscopic splenectomy in the management of hematological diseases: surgical technique and outcome of 17 patients. *Surg Endosc* 10:441–444
- Terrosu G, Donini A, Bacarani U, Vianello V, Anania G, Zaja F, Pasqualucci A, Bresadola F (1998) Laparoscopic versus open splenectomy in the management of splenomegaly: our preliminary experience. *Surgery* 124:839–843
- Watson DI, Coventry BJ, Chin T, Gill G, Malycha P (1997) Laparoscopic versus open splenectomy for immune thrombocytopenic purpura. *Surgery* 121:18–22



**PART 2**

**Colorectal Procedures**

- 7 Laparoscopic Appendectomy 103**
- 8 Laparoscopic Left Colectomy 119**
- 9 Laparoscopic Right Colectomy 137**
- 10 Laparoscopic Total Colectomy 149**
- 11 Laparoscopic Rectopexy for Rectal Prolapse 153**

---

## 7 Laparoscopic Appendectomy

### 7.1 Operating Room Setup: Position of the Patient

The patient is placed supine in a 15° Trendelenburg position. Rotation to the left can be useful. The surgeon stands on the patient's left side. The first assistant stands on the surgeon's left. A second assistant may stand between the patient's legs. The monitor is on the patient's right side (► Fig. 7.1).

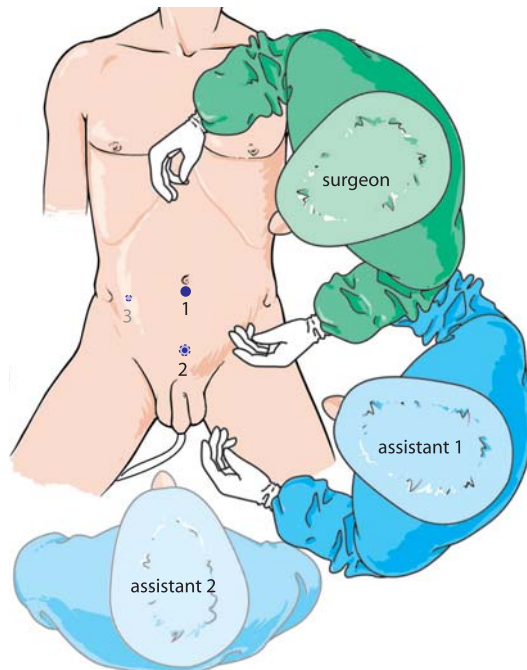


Fig. 7.1. OR setup – position of trocars

## 7.2 Recommended Instruments

- A 10-mm trocar with a 5-mm reducer
- Two 5-mm trocars
- Two Johan 5-mm fenestrated forceps
- Five-millimetre coagulating shears
- A 5-mm, straight 0° endoscope
- A linear stapler on occasion
- Specimen retrieval bag
- Three-millimetre instruments and 3-mm trocars in paediatric cases

## 7.3 Trocar Placement and Exposure (▶ Fig. 7.1)

The first trocar is introduced at the lower margin of the umbilicus after creating the pneumoperitoneum using a Veress needle. Insertion should be in a slightly oblique manner to prevent incisional hernias. The intraperitoneal pressure is set to 12, with a maximum of 14 mmHg in adults. In children, maximum pressure equals age. The abdomen is visually explored. A second 5- or 3-mm suprapubic trocar is inserted for the working instruments.

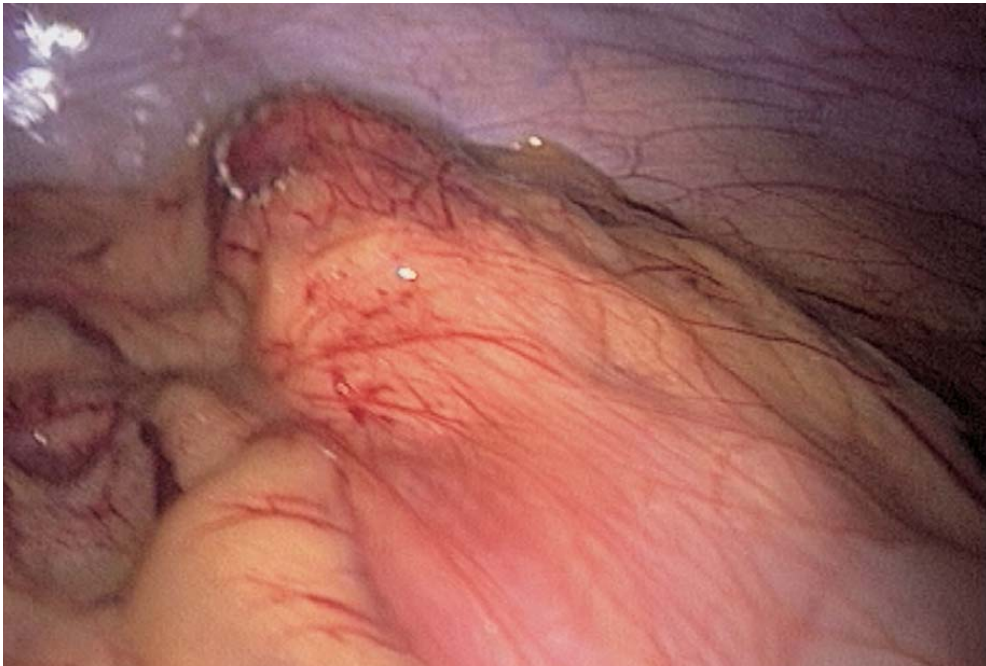


Fig. 7.2. Exploration of peritoneal cavity

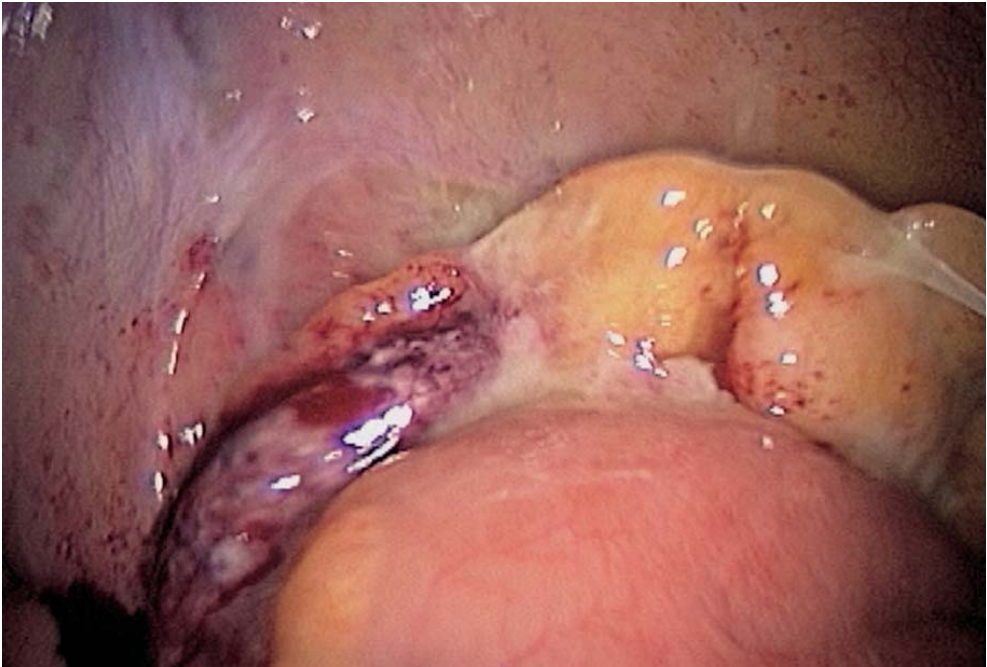


Fig. 7.3. Exposure

The patient is placed in the Trendelenburg position, to better mobilize the small bowel, gently with a non-traumatic forceps. The ileocaecal region is visualized. The appendix is identified and the degree of illness is assessed (◉ Figs. 7.2, 7.3).

#### 7.4 Three Situations Can Be Defined, Leading to Different Ways to Mobilize and Resect the Appendix

##### 7.4.1 *The Appendix Is Inflammatory, but Narrow and Entirely Free, and Without Thickening of the Mesoappendix*

The appendix can usually be grasped with a forceps without any additional trocar (◉ Figs. 7.4–7.9). Complete mobilization can be achieved by gentle pulling. The tip of the appendix is extracted through the umbilical port using a 5-mm forceps. Pneumoperitoneum is then released. Ligature is done extracorporeally, with absorbable sutures as in conventional appendectomy. The appendiceal stump is reintroduced, and pneumoperitoneum is resumed (◉ Fig. 7.10).



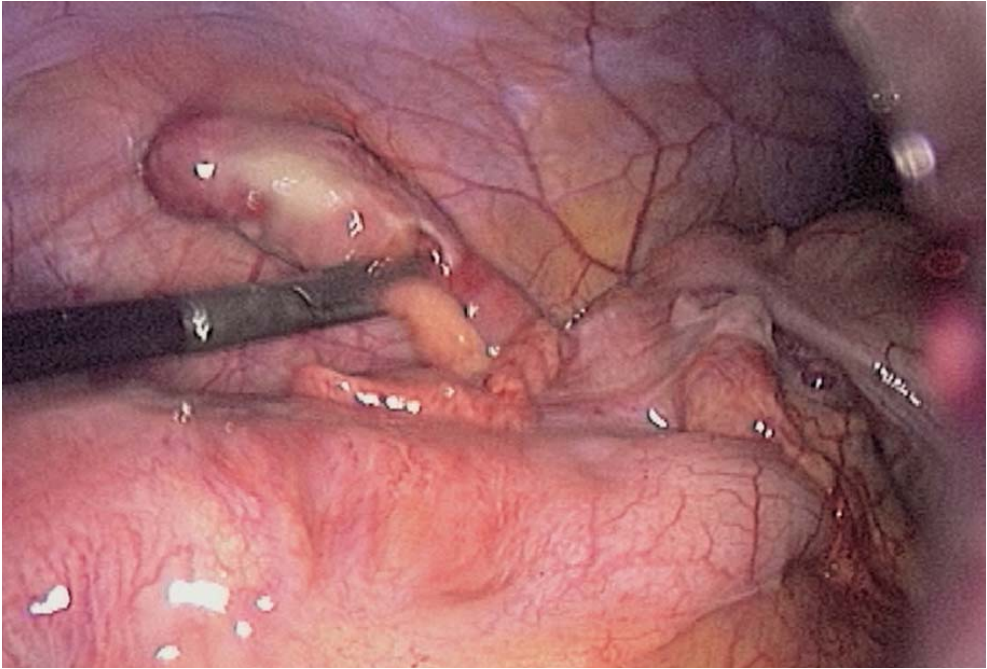


Fig. 7.4. Appendiceal dissection

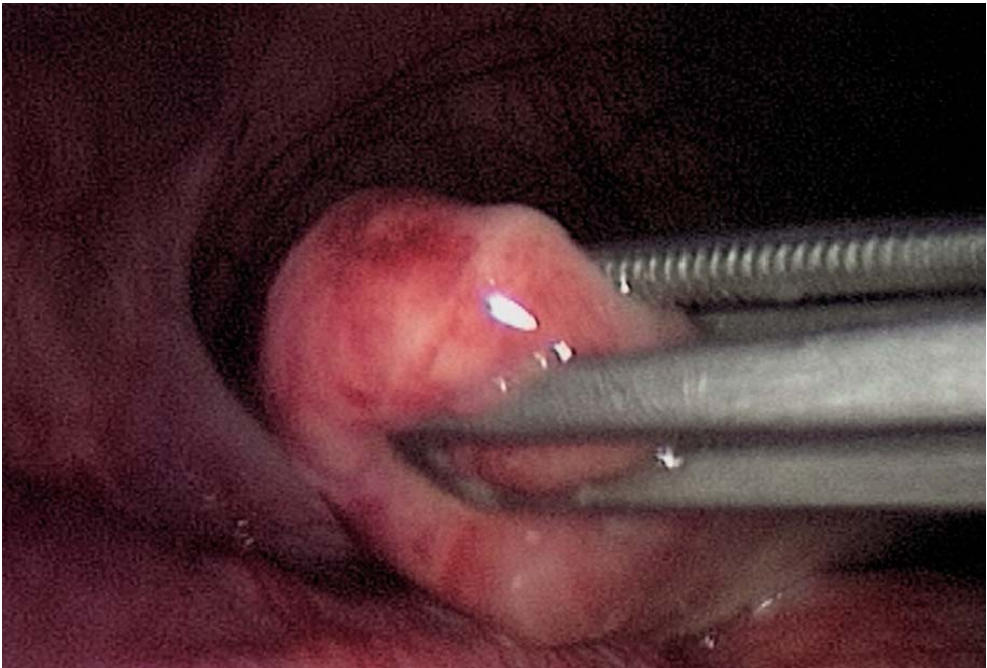


Fig. 7.5. Appendix grasped with umbilical forceps

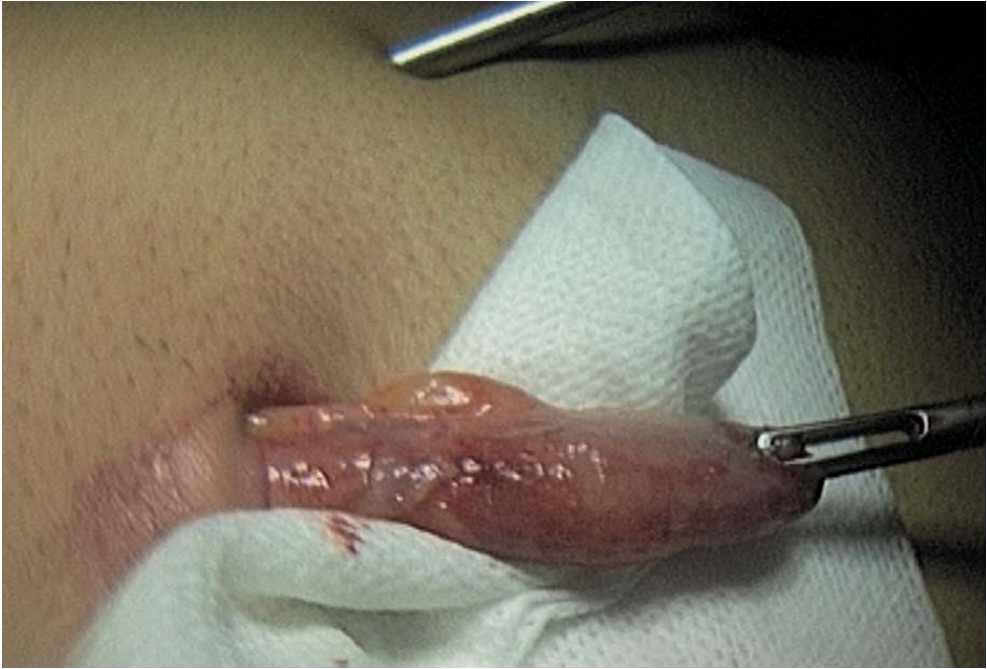

Fig. 7.6. Extraction through umbilicus after mobilization

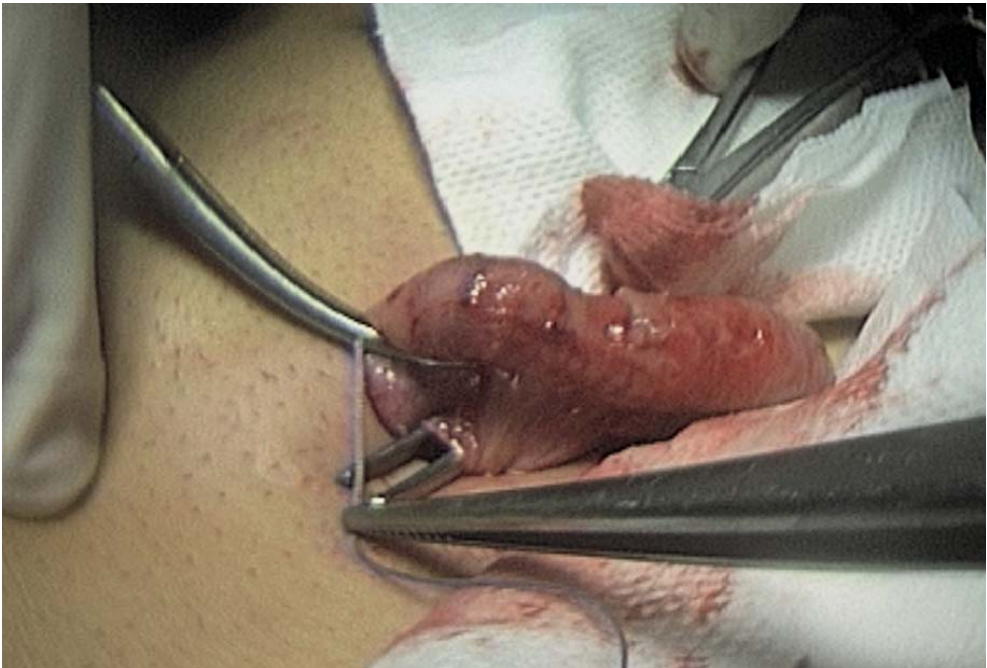

Fig. 7.7. Ligation of mesentery

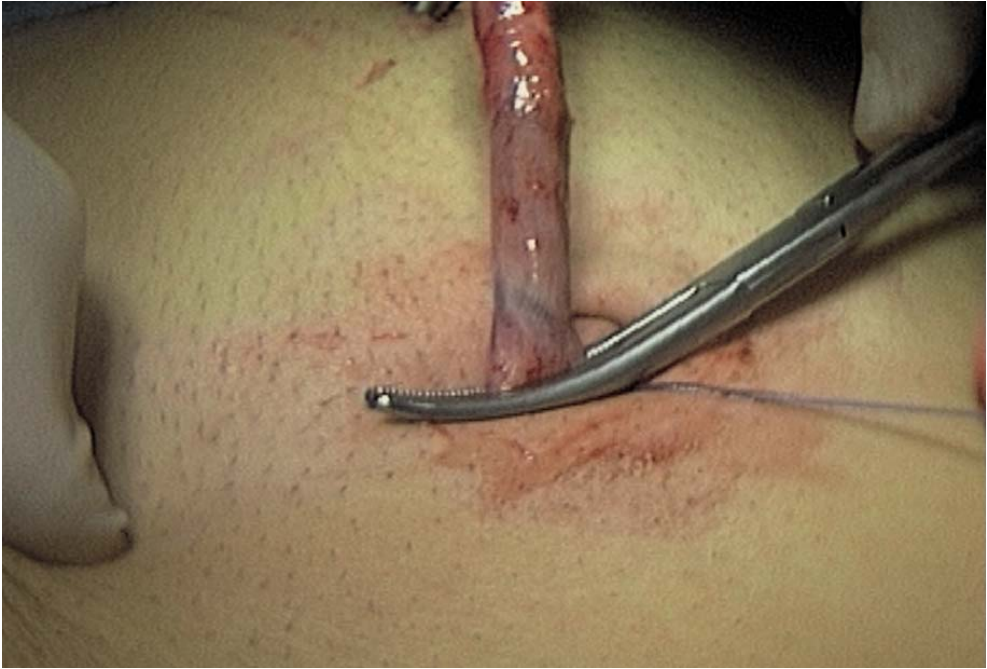

Fig. 7.8. Clamping of appendix

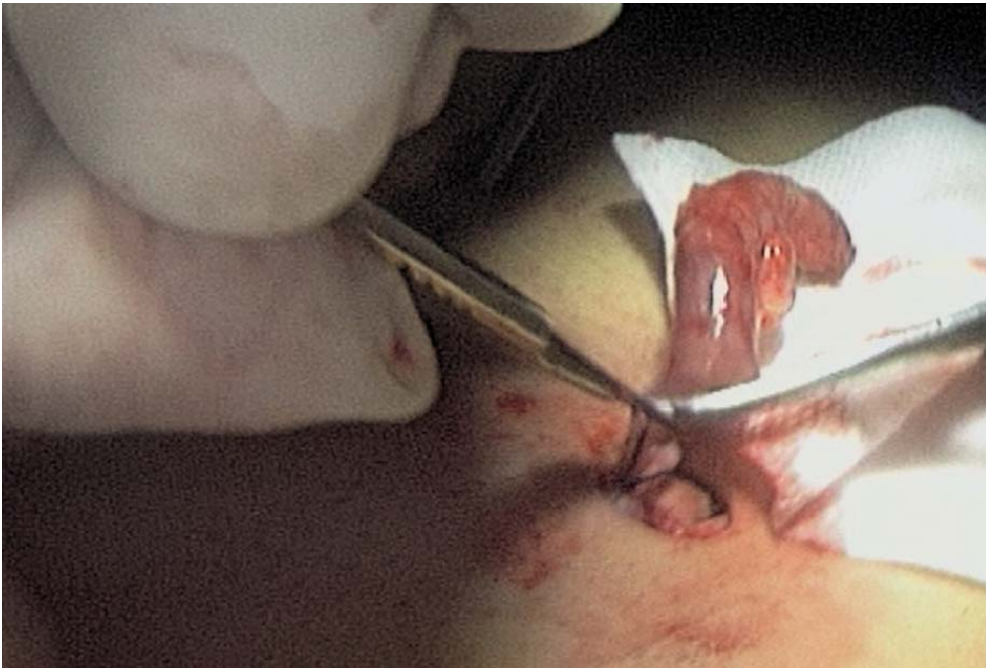

Fig. 7.9. Resection of appendix



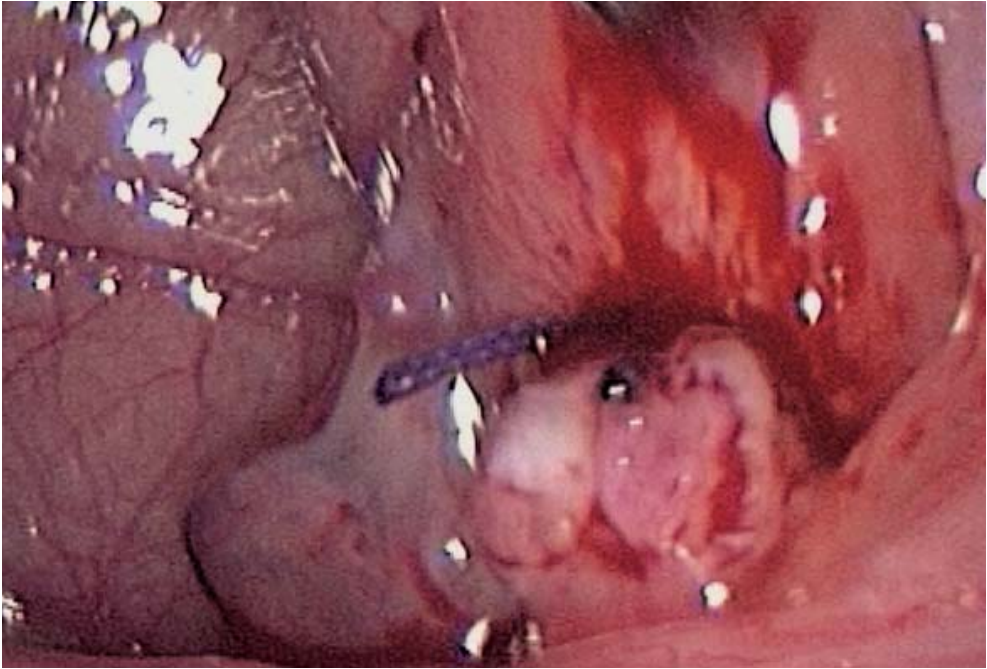


Fig. 7.10. Laparoscopic control of appendiceal stump

#### 7.4.2 *The Appendix Is Highly Inflammatory, with Thickening of the Mesoappendix, and Adherent to the Adjacent Structures*

A third operating trocar is essential and can be introduced either in the right iliac fossa or in the left iliac fossa. However, we even prefer placement in the right upper quadrant for better instrument handling (► Figs. 7.11, 7.12). As *the appendix is impossible to mobilize*, prior dissection with coagulating shears and a fenestrated forceps is carried out. The mesoappendix is opened at the base of the appendix, and two sutures are tied intracorporeally on both meso and appendix. The appendix is then extracted through the umbilical port after positioning the endoscope in the suprapubic region. Optionally, intracorporeal sectioning of the appendix enables specimen retrieval with a protective plastic bag.



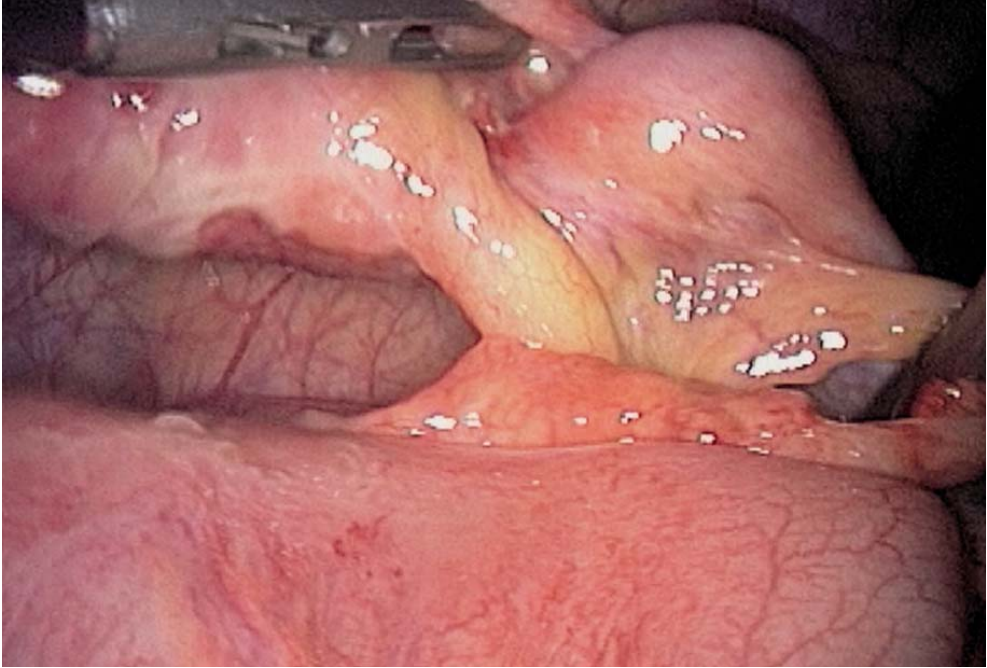


Fig. 7.11. Mobilization of appendix

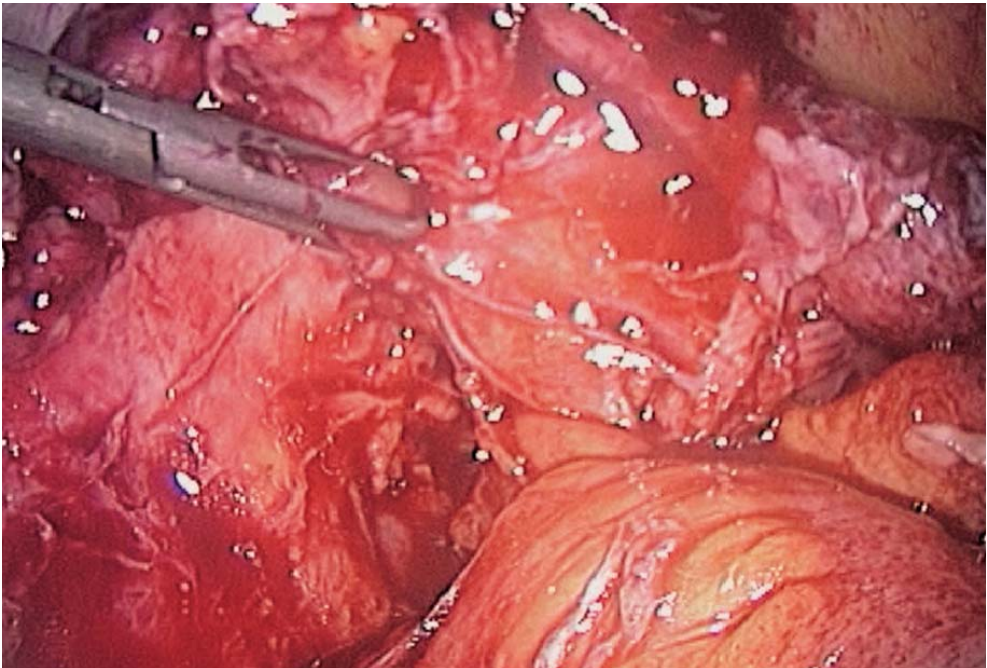


Fig. 7.12. Dissection: appendiceal abscess

### 7.4.3 The Appendix Has a Tumour-like Appearance or Is Totally Abscessed

Insertion of a third operating trocar can't be missed. One trocar site is enlarged to a 12-mm port to allow the use of endostaplers. As the *appendix is either abscessed or tumour-like with important caecal inflammation*, dissection is done with two operating trocars using a 5-mm fenestrated forceps and 5-mm coagulating shears. A 5-mm irrigation and suction cannula is often useful, working as a blunt dissector while aspirating. Pus is collected for bacteriological work-out. The caecum is carefully freed from all inflammatory adhesions, and the origin of the appendix can be identified. Resection is done with endo-staplers (► Figs. 7.13–7.17). The resected specimen is removed with a retrieval bag (► Fig. 7.18).

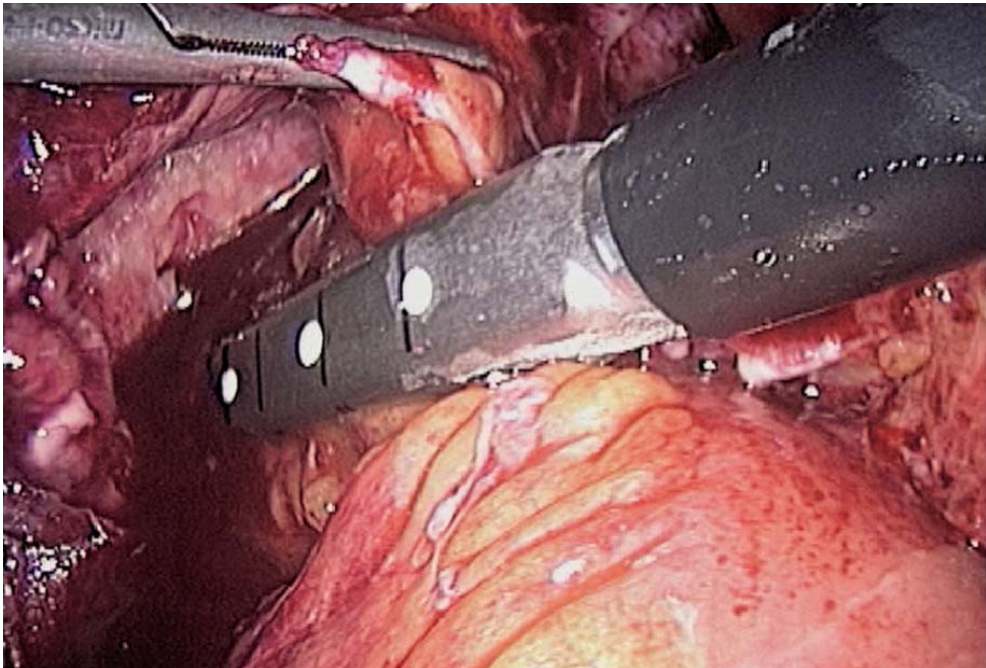


Fig. 7.13. Stapling in case of abscess

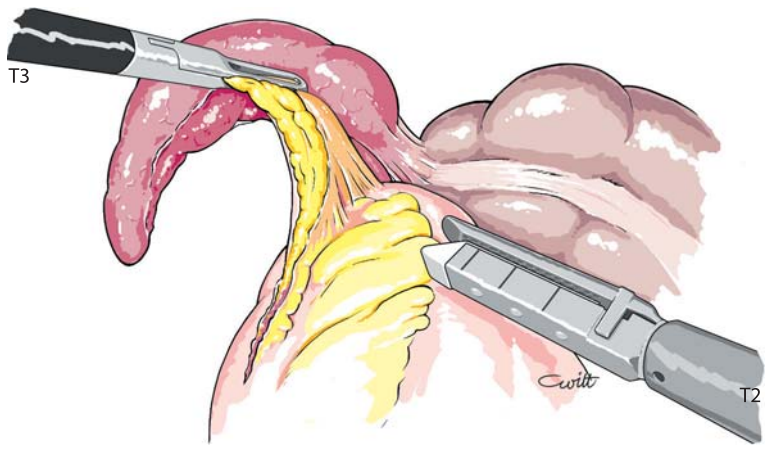


Fig. 7.14. Stapling the meso appendix

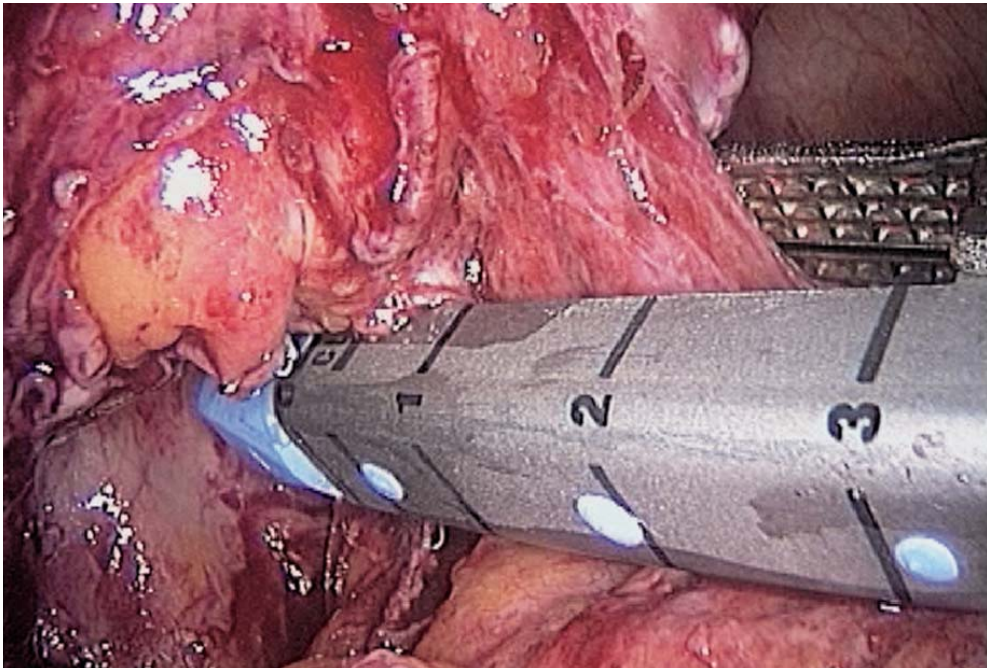


Fig. 7.15. Stapling a gangrenous appendix



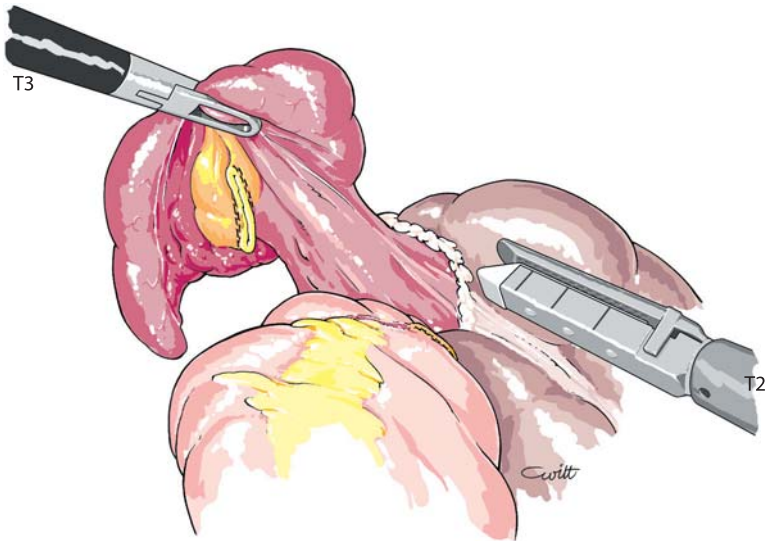


Fig. 7.16. Stapling the appendix

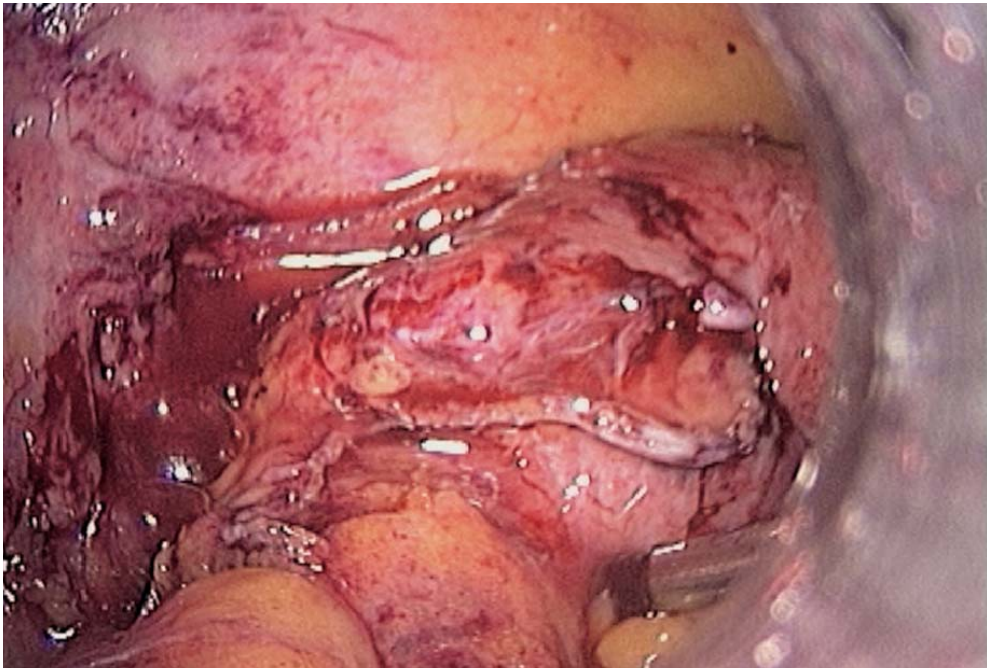


Fig. 7.17. Control of staple lines after completed resection



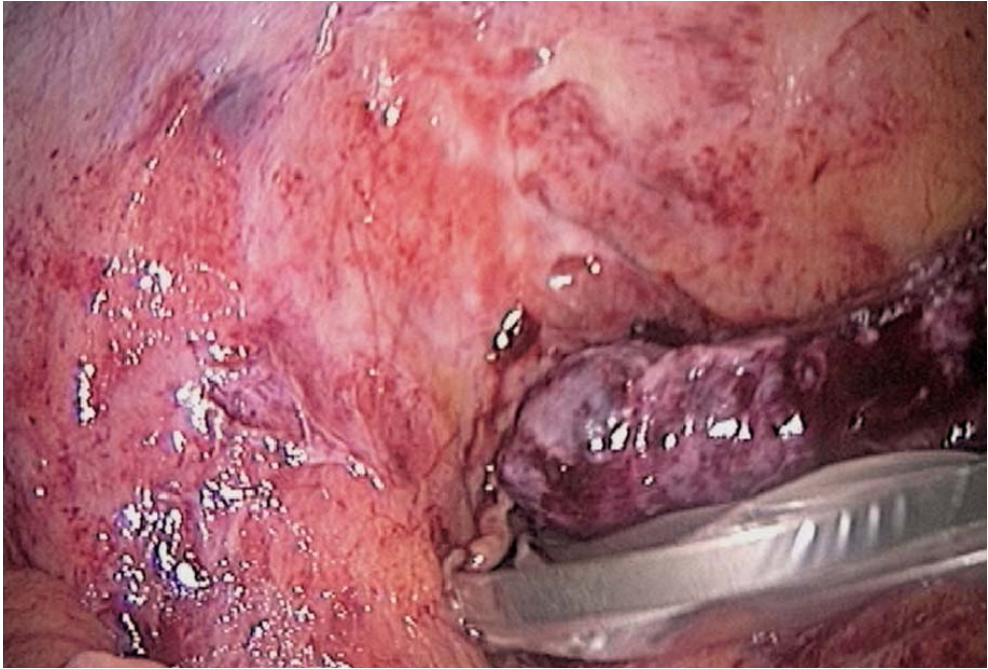


Fig. 7.18. Retrieval of gangrenous appendix with a bag

### 7.5 Peritoneal Cleaning and Checking for Bleeding: Inspection of the Peritoneal Cavity

In all cases, after resuming the pneumoperitoneum, the abdomen is checked for bleeding. Additional haemostasis is achieved with electrocautery or sutures. The peritoneal cavity is cleaned with saline. The pelvic cavity is thoroughly explored, as are the right and left diaphragmatic areas. In case of general peritonitis, an additional trocar may be inserted in the left upper quadrant for better subphrenic lavage. The terminal ileum is checked for Meckel's diverticulum or any mesentery or bowel inflammation.

### 7.6 Drainage and Closure of Ports

A suction drain may be left in the suprapubic position. A multitubular drain is usually placed through a lateral port (➤ Fig. 7.19). CO<sup>2</sup> is released and trocars are removed. The port wounds are cleaned with iodine and closed with everting absorbable sutures.

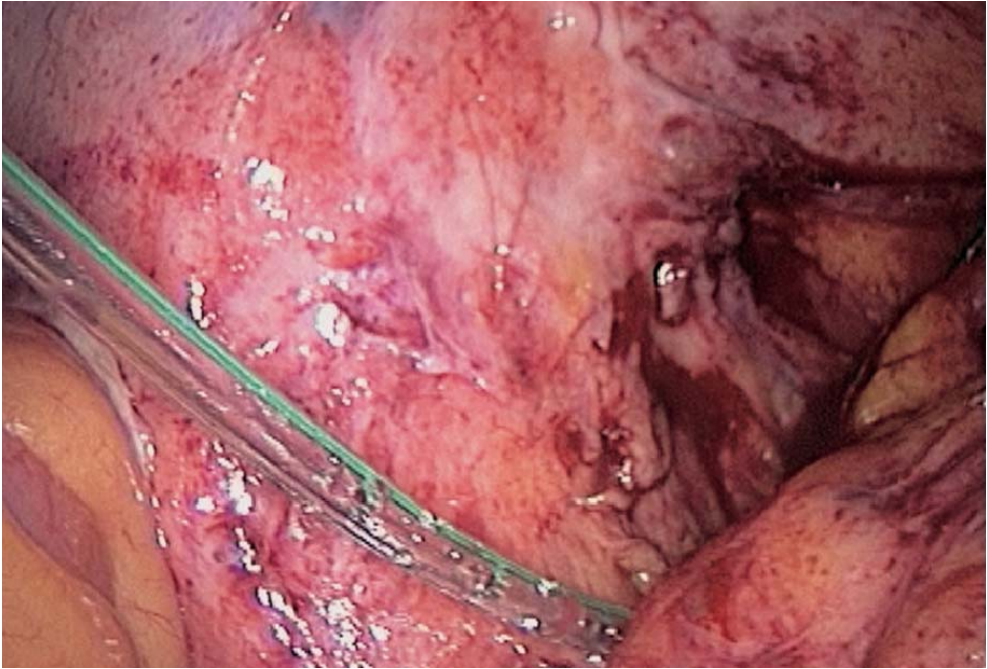


Fig. 7.19. Suction drain

## 7.7 Tips and Comments

- Minimal adhesions can be released by gentle traction on the appendix using a 5- or 3-mm suprapubic forceps.
- In the presence of severe inflammation, use of a metallic suction cannula enables quick dissection of inflammatory tissue, especially in the case of abscess.
- Peritoneal lavage may be helped with the insertion of a sponge, enabling reaspiration of fluids more easily.
- While removing the appendix through the umbilicus, pressure on the abdominal wall may help in extracting the caecum for better control and ligature.
- Surgeon's placement between the patient's legs facilitates intraperitoneal lavage of both upper quadrants.
- If no 5-mm endoscope is available, a 10-mm suprapubic port is needed at the time of umbilical extraction.
- The use of an endoscope with an operating channel can be an option.

## Literature

- Adamek HE, Maier M, Benz C, Huber T, Schilling D, Riemann JF (1966) Schwerwiegende komplikationen der diagnostischen laparoskopie. *Med Klein* 91:694–697
- Addiss GD, Shaffer N, Fowler S, Tauxe RV (1990) The epidemiology of appendicitis and appendectomy in the United States. *Am J Epidemiol* 132:910–925
- Andersson RE, Hugander A, Thulin AJG (1992) Diagnostic accuracy and perforation rate in appendicitis: association with age and sex of patient and with appendectomy rate. *Eur J Surg* 158:37–41
- Arnbjörnsson E (1984) Small intestinal obstruction after appendectomy: an avoidable complication? *Curr Surg* 354–355
- Arnbjörnsson E, Andrén-Sandberg A, Bengmark S (1983) Appendectomy in the elderly, incidence and operative findings. *Ann Chir Gyn* 72:223–228
- Attwood SEA, Hill ADK, Murphy PG, Thornton J, Stephens RB (1992) A prospective randomized trial of laparoscopic vs. open appendicectomy. *Surgery* 112:497–501
- Birkenfeld A, Brzezinski A, Schenker JG (1982) Post mechanical sterility. *Acta Eur Fertil* 13:173–176
- Blind PJ, Dahlgren ST (1986) The continuing challenge of the negative appendix. *Acta Chir Scand* 152:623–627
- Bonjer HJ, Hazebroek EJ, Kazemier G, Giuffrida MC, Meijer WS, Lange JF (1997) Open vs. closed establishment of pneumoperitoneum in laparoscopic surgery. *Br J Surg* 84:599–602
- Borgstein PJ, Gordijn RV, Eijsbouts QAJ, Cuesta MA (1997) Acute appendicitis: a clear-cut case in men, a guessing game in women. *Surg Endosc* 11:923–927
- Cang FC, Hogle HH, Welling DR (1973) The fate of the negative appendix. *Am J Surg* 126:752–754
- Champault G, Cazacu F, Taffinder N (1996) Serious trocar accidents in laparoscopic surgery: a French survey of 103,852 operations. *Surg Laprosc Endosc* 6:367–370
- Cox MR, McCall JL, Padbury RTA, Wilson TG, Wattchow DA, Toouli J (1995) Laparoscopic surgery in women with a clinical diagnosis of acute appendicitis. *Med J Aust* 162:130–132
- Deutsch AA, Zelikovsky A, Reiss R (1982) Laparoscopy in the prevention of unnecessary appendectomies: a prospective study. *Br J Surg* 69:336–337
- De Wilde RL (1991) Goodbye bowel obstruction after appendicectomy. *Lancet* 338:1012
- Frazee RC, Roberts JW, Symmonds RE, Snyder SK, Hendricks JC, Smith RW, Custer MD, Harrison JB (1994) A prospective randomized study comparing open vs. laparoscopy appendectomy. *Ann Surg* 219:725–731
- Fritts LL, Orlando R (1993) Laparoscopic appendectomy: a safety and cost analysis. *Arch Surg* 128:521–525
- Graham A, Henley C, Mobley J (1991) Laparoscopic evaluation of acute abdominal pain. *J Laparosc Surg* 1:165–168
- Hansen JB, Smithers BM, Schache D, Wall DR, Miller BJ, Menzies BL (1996) *World J Surg* 20:17–21
- Heinzelmann M, Simmen HP, Cummins AS, Largiader F (1995) Is laparoscopic appendectomy the new »gold standard«? *Arch Surg* 130:782–784
- Hellberg A (1999) Prospective randomized multicenter study of laparoscopy vs. open appendicectomy. *Br J Surg* 86:48–53
- Henle K, Beller S, Rechner J, Zerz A (1996) Laparoskopische vs. konventionelle appendektomie: eine prospektive, randomisierte studie. *Chirurg* 67:526
- Jansen FW, Kapiteyn K, Trimbos-Kemper T, Hermans J, Trimbor JB (1997) *Br J Obstet Gynecol* 104:595–600
- Kok HJM (1992) Laparoscopic appendectomy: a new opportunity for curing appendicopathy. *Surg Lap end* 2:297–302
- Krähenbühl L, Frei E, Klaiber Ch, Büchler MW (1998) Acute appendicitis standard treatment or laparoscopic surgery. In: Büchler MW, Farthmann EH (eds) *Progress in surgery*. Karger, Basel, pp 1–191

- Kum CK, Ngoi SS, Goh PMY, Tekant Y, Isaac JR (1993) Randomized controlled trial comparing laparoscopic and open appendectomy. *Br J Surg* 80:1599–1600
- Laine S, Rantala A, Gullichsen R, Ovaska J (1997) Laparoscopic appendectomy: is it worthwhile? *Surg Endosc* 11:95–720
- Lau WY, Fan ST, Ylu TF, Chu KW, Wong SH (1984) Negative findings at appendectomy. *Am J Surg* 148:375–378
- Leape LL, Ramenofsky ML (1980) Laparoscopy for questionable appendicitis: can it reduce the negative appendectomy rate? *Ann Surg* 191:410–413
- Lehmann-Willenbrock E, Mecke H, Reidel HH (1990) Sequellae of appendectomy, with special reference to intra-abdominal adhesions, chronic abdominal pain, and infertility. *Gyn Obst* 29:241–245
- Macarulla E, Vallet J, Abad JM, Hussein H, Fernandez E, Nieto B (1997) Laparoscopic vs. open appendectomy: a prospective randomized trial. *Surg Lap Endosc* 7:335–339
- Martin LC, Puente I, Sosa JL, Bassin A, Breslaw R, McKenney MG, Ginzburg E, Sleeman D (1995) Open vs. laparoscopic appendectomy. *Ann Surg* 22:256–262
- McAnena OJ, Austin O, O'Connell PR, Hederman WP, Gorey TF, Fitzpatrick J (1992) Laparoscopic vs. open appendectomy: a prospective evaluation. *Br J Surg* 79:818–820
- Moberg AC, Montgomery A (1997) Appendicitis: laparoscopic vs. conventional operation: a study and review of the literature. *Surg Laparosc Endosc* 7:459–463
- Moberg A, Ahlberg G, Leijonmarck CE, Montgomery A, Reiertsen O, Rosseland AR (1988) Diagnostic laparoscopy in 1,043 patients with suspected acute appendicitis. *Eur J Surg* 164:833–840
- Mutter D (1996) Laparoscopy not recommended for routine appendectomy in men: results of a prospective randomized study. *Surgery* 10:71–74
- Nagy AG, James D (1989) Diagnostic laparoscopy. *Am J Surg* 157:3
- Olsen JB, Myren CJ, Haahr PE (1993) Randomized study of the value of laparoscopy before appendectomy. *Br J Surg* 80:922–923
- Ortega AE, Hunter JG, Peters JH, Swanstrom LL, Schirmer B (1995) A prospective, randomized comparison of laparoscopic appendectomy with open appendectomy. 169:208–212
- Pedersen AG, Petersen OBB, Wara P, Qvist N, Laurberg S (1996) laparoskopii ved formodet appendicitis acuta. *Ugeskr Laeger* 158:2377–2380
- Pieper R, Kager L, Näsman P (1982) Acute appendicitis: a clinical study 1,018 cases of emergency appendectomy. *Acta Chit Scand* 148:51–62
- Pier A, Götz F, Bacher C, Ibaldo R (1993) Laparoscopic appendectomy. *World J Surg* 17:29–33
- Reiertsen O, Larsen S, Edwin B, Faerden AE, Rosseland AR (1997) A randomized controlled trial with sequential design of laparoscopic vs. conventional appendectomy. *Br J Surg* 84:482–486
- Riber C, Soe K, Jorgensen T, Tonnesen H (1997) Intestinal after appendectomy. *Scand J Gast* 32:1125–1128
- Richards W, Watson D, Lynch G, Reed GW, Olsen D, Spaw A, Holcomb W, Frexes-Steed M, Goldstein R, Sharp K (1993) A review of the results of laparoscopic vs. open appendectomy. *Gynecol Obstet* 177:473–480
- Scott-Conner CEH, Hall TJ, Anglin BL, Muakkassa FF (1992) Laparoscopic appendectomy. *Ann Surg* 215:660–668
- Semm K, Mettler L (1980) Progress in pelvic surgery via operative laparoscopy. *Am J Obstet Gynecol* 138:121–127
- Silberman VA (1981) Appendectomy in a large metropolitan hospital. *Am J Surg* 142:615–618
- Slim K, Pezet D, Chipponi J (1998) Laparoscopic or open appendectomy? *Dis Colon Rectum* 41:398–405
- Spirtos NM, Eisenkop SM, Spirtos TW, Poliakin RI, Hibbard LT (1987) Laparoscopy, a diagnostic aid in cases of suspected appendicitis: its use in women of reproductive age. *Am J Obstet Gynecol* 156:90



- Tanphiphat C, Chittmittrapap S, Prasopsunti K (1987) Adhesive small bowel obstruction: a review of 321 cases in a Thai Hospital. *Am J Surg* 154:283–287
- Tate JJT, Dawson JW, Chung SCS, Lau WY, Li AKC (1993) Laparoscopic vs. open appendicectomy: a prospective randomized trial. *Lancet* 342:633–637
- Taylor EW, Kennedy CA, Dunham RH, Bloch JH (1995) Diagnostic laparoscopy in women with acute abdominal pain. *Surg Laparosc Endosc* 5:125–128
- Tronin RJ, Burova VA, Grinberg AA (1996) Laparoscopic diagnosis of acute appendicitis in women. *J Am Assoc Gynecol Laparosc* 3:257–261
- Walker SJ, West CR, Colmer MR (1995) Acute appendicitis: does removal of a normal appendix matter, what is the value of diagnostic accuracy, and is surgical delay important? *Ann R Coll Surg Engl* 77:358–363
- Zbar RIS, Crede WB, Mckhann CF, Jekel JF (1993) The post operative incidence of small bowel obstruction following standard, open appendectomy and cholecystectomy. *Conn Med* 57:123–127

---

## 8 Laparoscopic Left Colectomy

### 8.1 Operating Room Setup: Position of the Patient

The patient is placed supine, with a 20° Trendelenburg position. The surgeon and the first assistant stand to the right of the patient. The second assistant is positioned between the legs of the patient. The video monitor is on the patient's left side (● Figs. 8.1, 8.2).

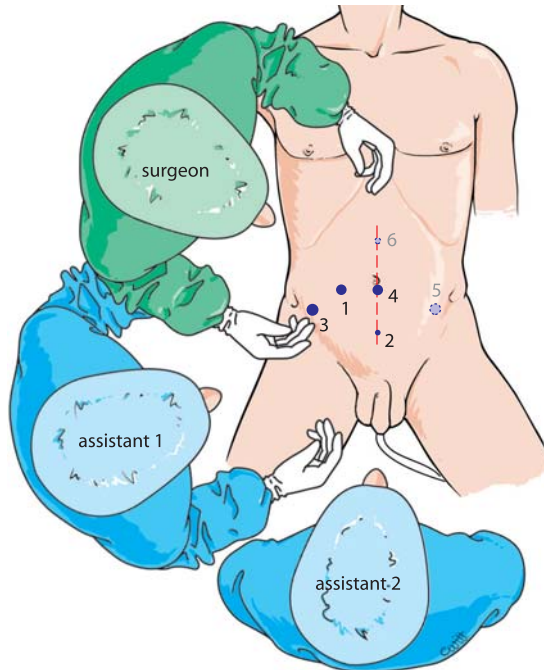


Fig. 8.1. OR setup – trocar position

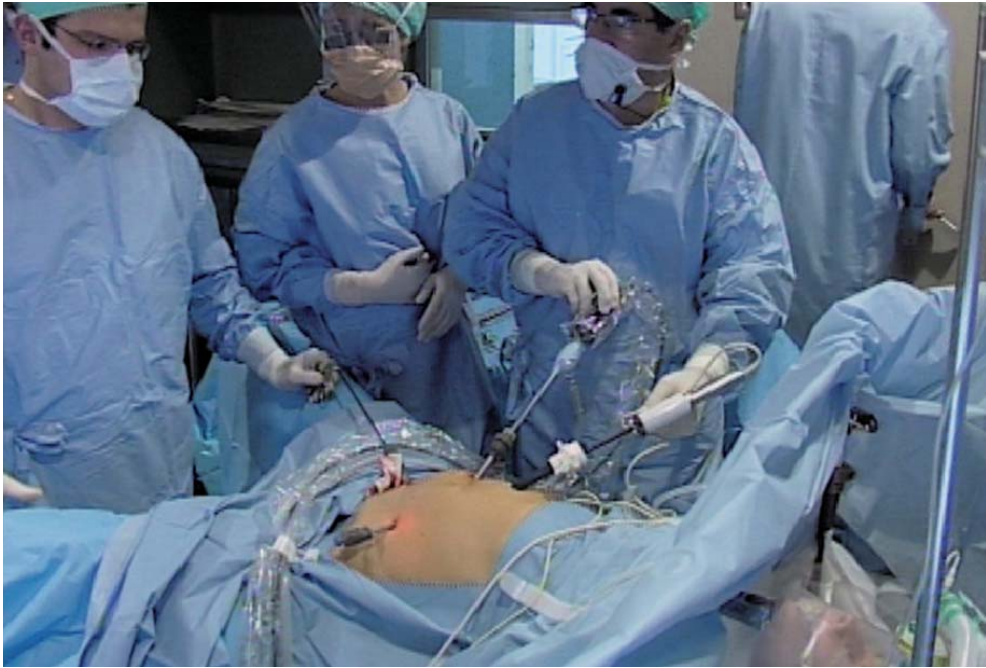

Fig. 8.2. Surgeon and team

## 8.2 Recommended Instruments

- Two 10-mm trocars
- Three 5-mm trocars
- A 12-mm trocar with reducers
- Three 5-mm fenestrated grasping forceps
- Five-millimetre coagulating shears
- A 5-mm straight grasping forceps
- Harmonic scalpel, 5 or 10 mm
- A 10-mm fenestrated forceps
- A 10-mm dissector
- A 5-mm needle holder
- Twelve-millimetre linear staplers
- A circular stapler for the anastomosis
- A 0° endoscope
- A parietal protective drape with an opening of 7 cm

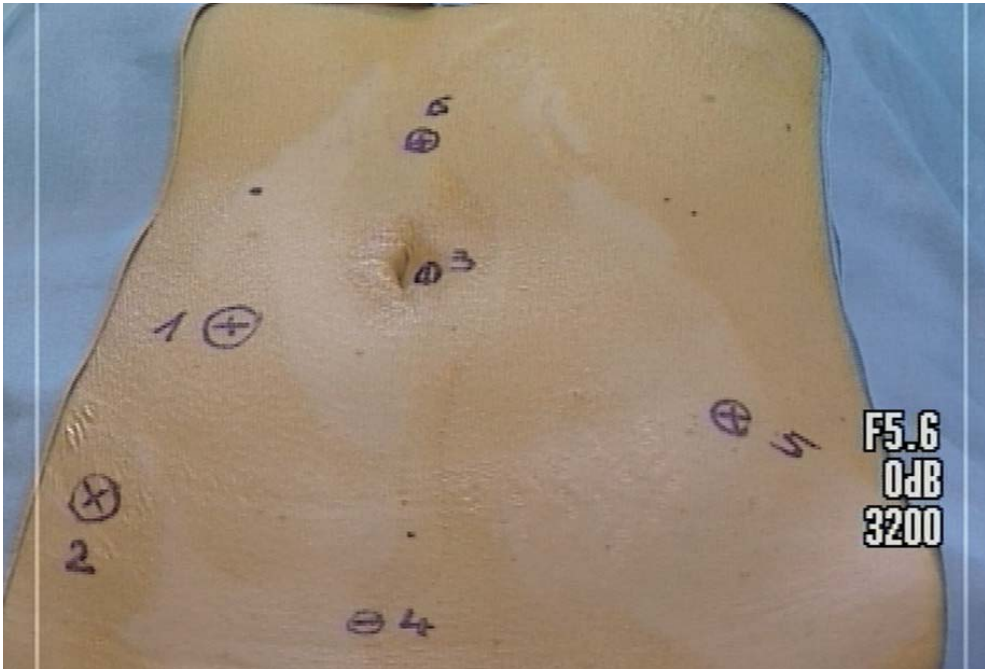


Fig. 8.3. Trocar sites

### 8.3 Trocar Placement and Exposure

The pneumoperitoneum is created with a Veress needle. The first trocar for the endoscope is inserted laterally, about 5 cm to the right of the umbilicus. The other trocars are then introduced under direct vision. A 5-mm trocar is placed suprapubic, a 12-mm trocar in the right iliac fossa, and a 10-mm trocar with reducer at the lower margin of the umbilicus (► Fig. 8.3). Two extra trocars will be needed at the time of splenic flexure mobilization.

The abdominal cavity is visually explored as a 20° Trendelenburg position is installed. The grasping forceps inserted through the suprapubic port mobilizes the omentum, the transverse colon and the small bowel. The rectosigmoid junction is then exposed using the suprapubic instrument.



#### 8.4 Rectosigmoid Mobilization and Control of Inferior Mesenteric Vessels

The secondary attachments of the sigmoid mesocolon are transected using the coagulating shears or the harmonic scalpel. The left ureter is identified (▶ Figs. 8.4, 8.5).

The suprapubic forceps mobilizes the rectosigmoid junction to the left side of the patient. The promontorium is easily identified (▶ Fig. 8.6). The right ureter is outlined and the posterior parietal peritoneum is opened with the harmonic scalpel or the coagulating shears. Dissection is continued in the pre-sacral region in contact with the mesorectal fat. The suprapubic fenestrated instrument applies vertical traction on the inferior mesenteric vessels. The dissection is continued along the inferior edge of the inferior mesenteric pedicle to its origin. A retromesenteric window is made (▶ Fig. 8.7). The left ureter is recognized once again in this freed space (▶ Fig. 8.8). The inferior mesenteric vessels can be controlled with a linear stapler or with intracorporeal ligature or clipping (▶ Figs. 8.9, 8.10).

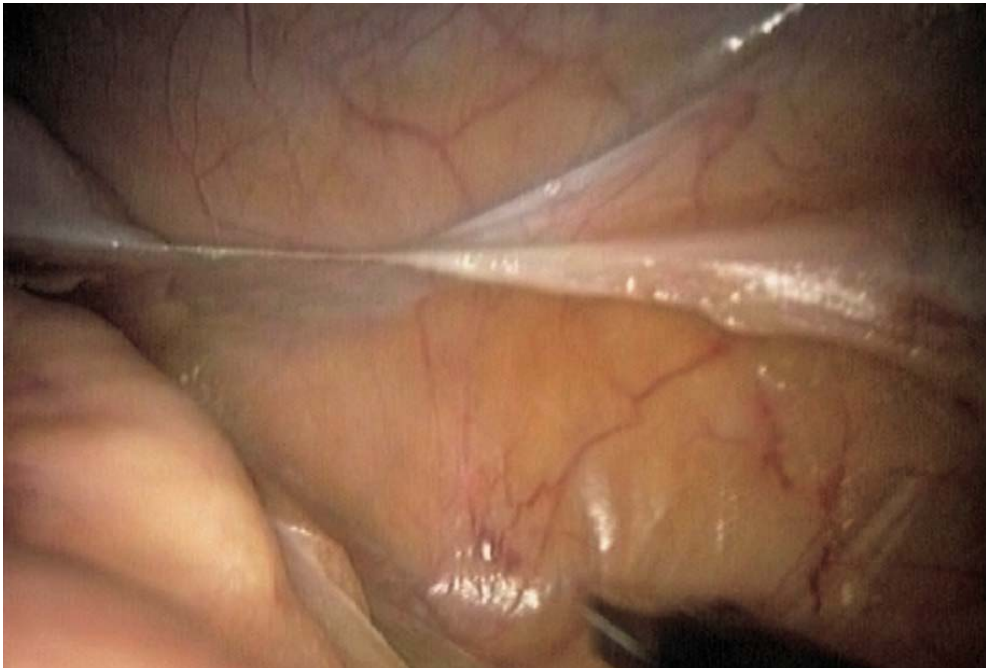

Fig. 8.4. Freeing the sigmoid colon

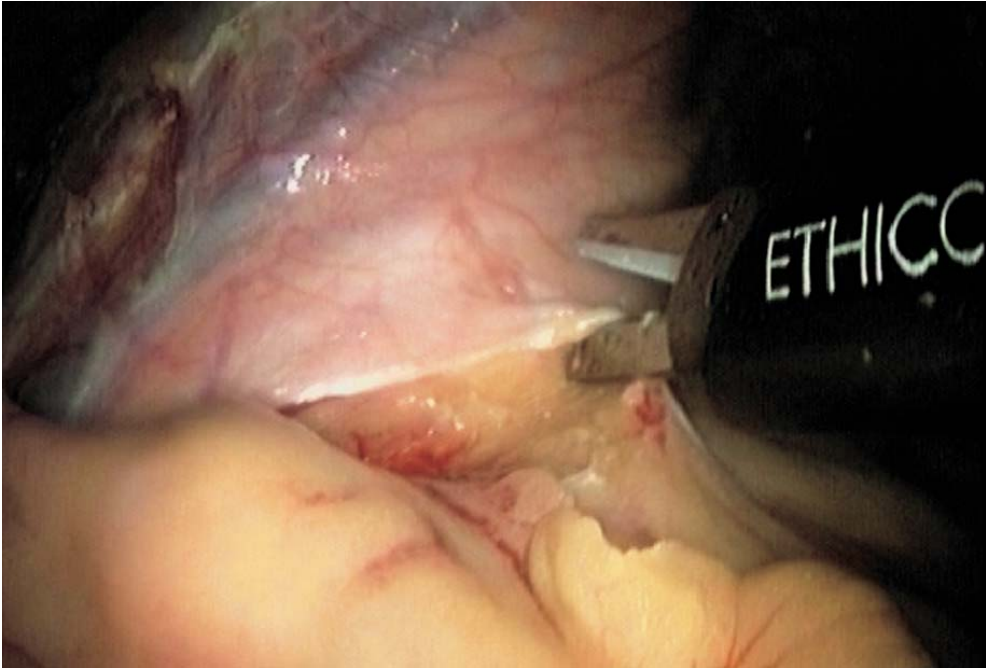


Fig. 8.5. Opening left lateral peritoneum

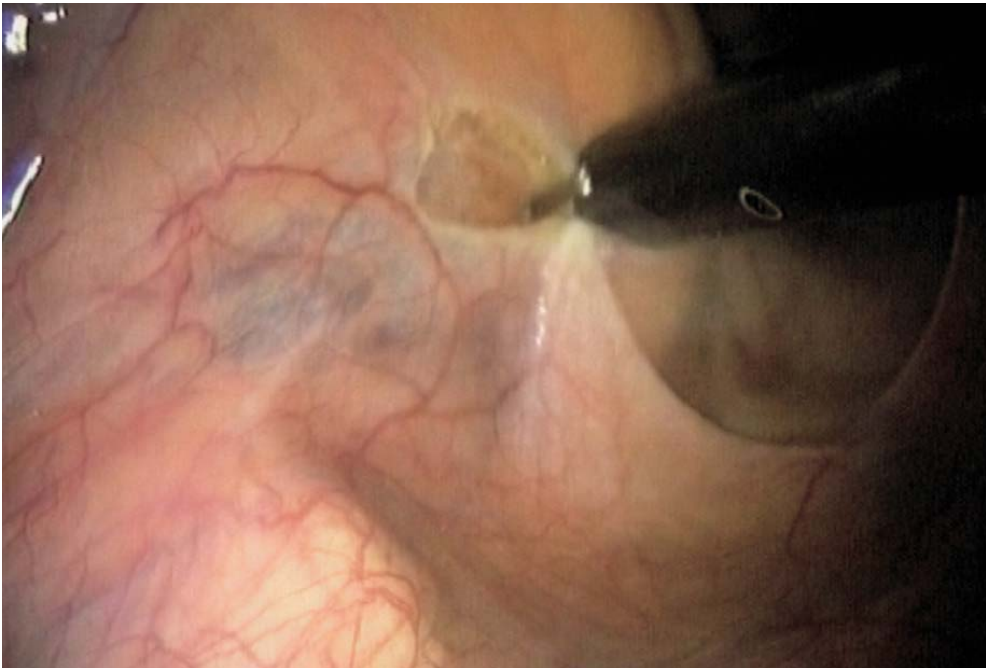

Fig. 8.6. Opening peritoneum on the right above the promontorium

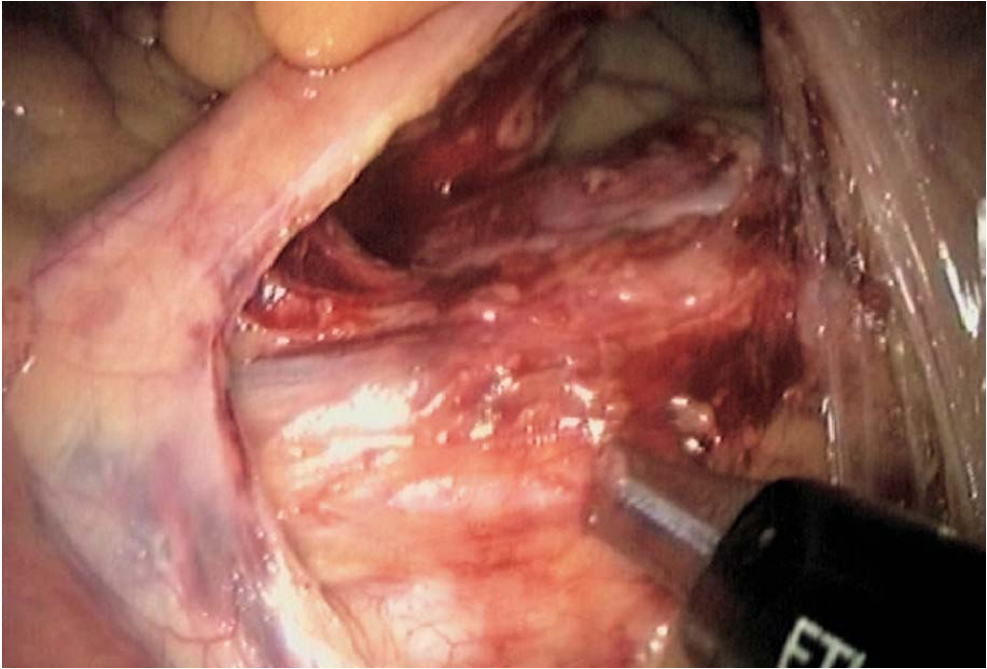


Fig. 8.7. Creating a retromesenteric window

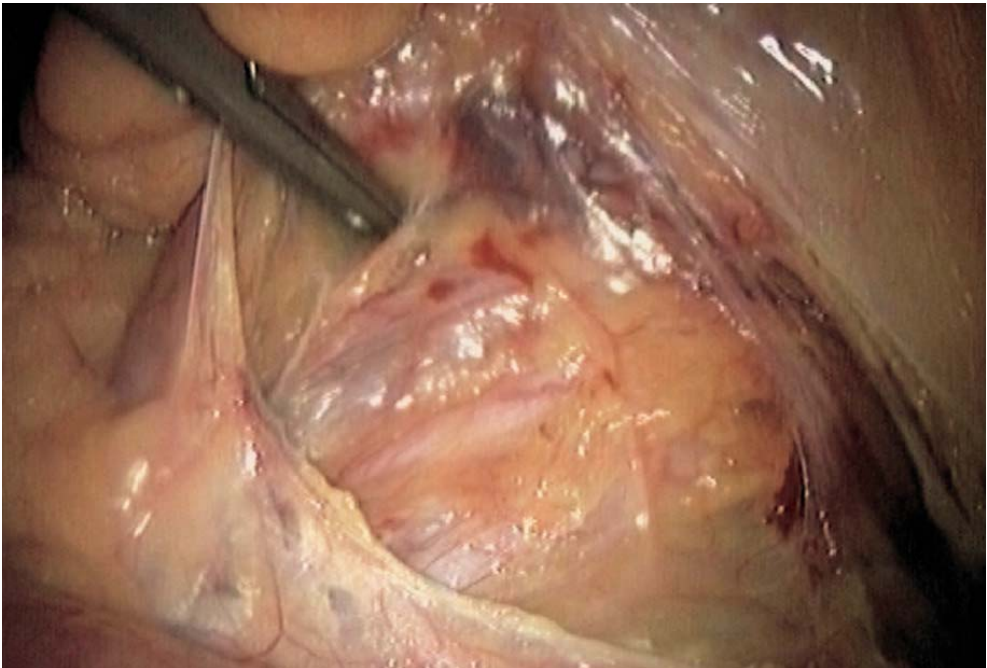


Fig. 8.8. Mesocolic dissection and identifying the left ureter

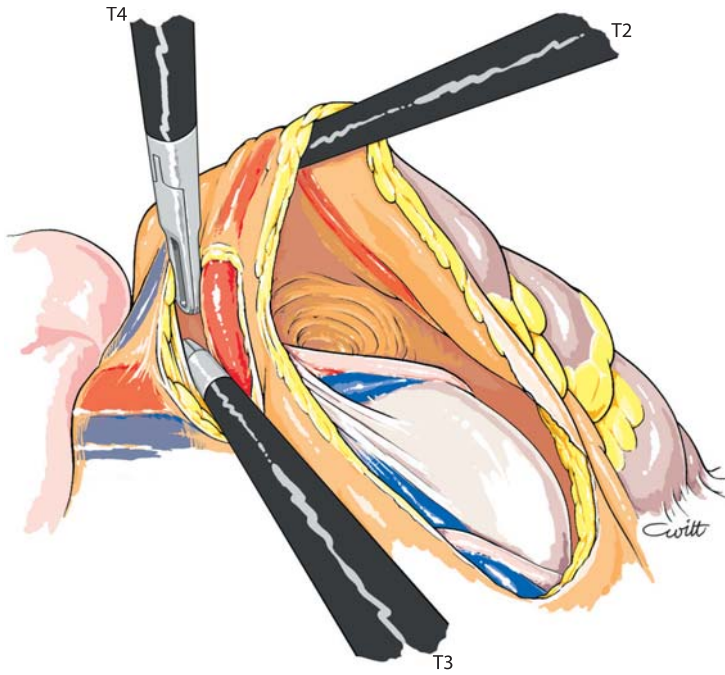


Fig. 8.9. Dissection of inferior mesenteric vessels

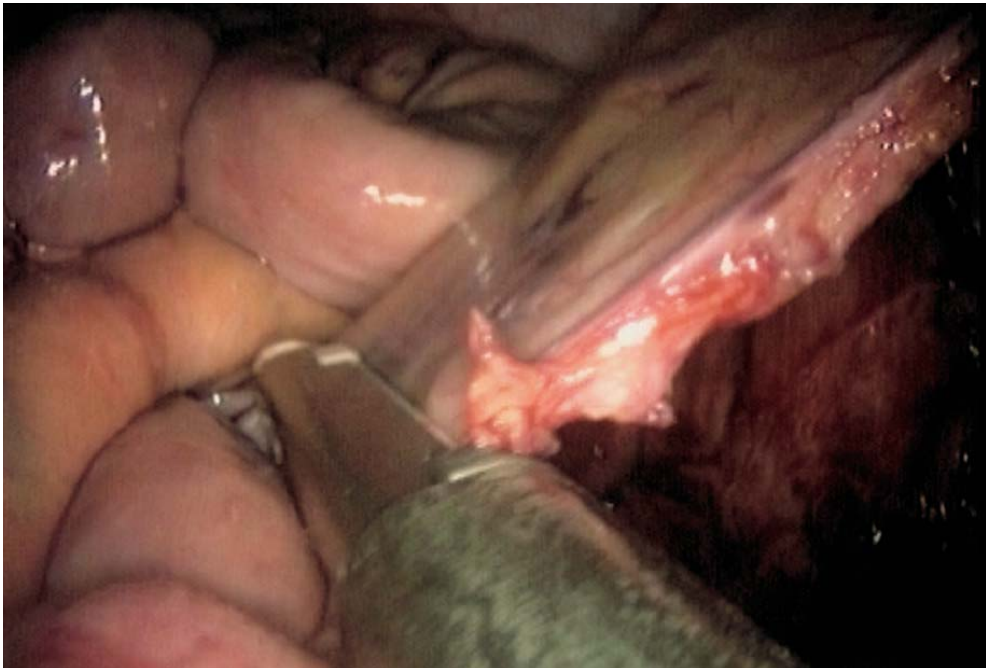

Fig. 8.10. Stapling of inferior mesenteric vessels



### 8.5 Taking Down the Splenic Flexure

The position of the trocars is changed. The endoscope is positioned in the umbilical region in the 10-mm trocar. A new 5- or 10-mm trocar is positioned in the left iliac fossa, and a final 5-mm trocar is positioned on the median supraumbilical line. The patient is placed in a reverse Trendelenburg position. The small bowel is re-positioned in the pelvic cavity. The coloparietal attachments are kept at this stage. A left retromesocolic dissection is carried out. The left mesocolon is lifted by the suprapubic instrument. The harmonic scalpel or the coagulating scissors inserted through the left iliac fossa port enable opening of the left retrocolic sub-peritoneal space up to the splenic flexure, and reaching the lower edge of the pancreas (◉ Figs. 8.11, 8.12). The lesser sac is opened anteriorly to the pancreas. Thus, the resection of the retroperitoneal attachments of the splenic flexure of the colon is easily carried out. The inferior mesenteric vein is transected at its termination in an enlarged left colectomy, or somewhat lower depending on the level of the left colic resection. The freeing of the left parietocolic peritoneal attachments is continued using the harmonic scalpel (◉ Fig. 8.13). The whole splenic flexure is thus lowered. The gastrocolic ligament can now be released. The omentum and the transverse colon are exposed using the suprapubic forceps and the supraumbilical instrument. The colo-omental attachments are released with the harmonic scalpel or the coagulating shears. The left colon is then totally released from its parietal attachments (◉ Fig. 8.14).

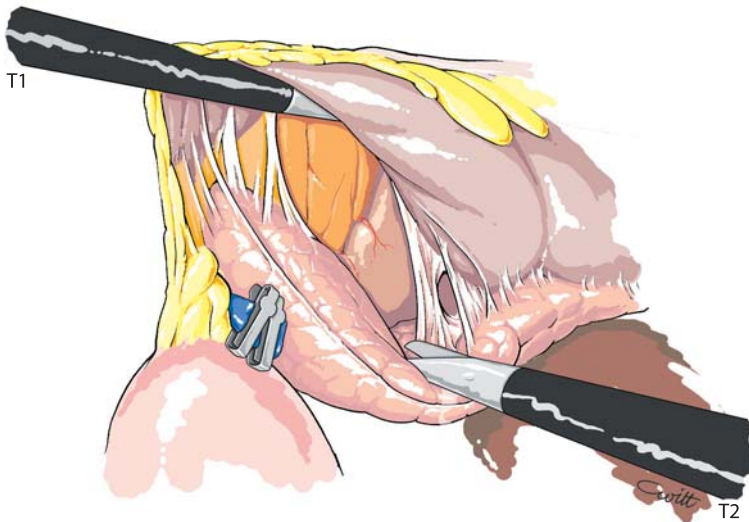


Fig. 8.11. Opening the lesser sac in front of the pancreas

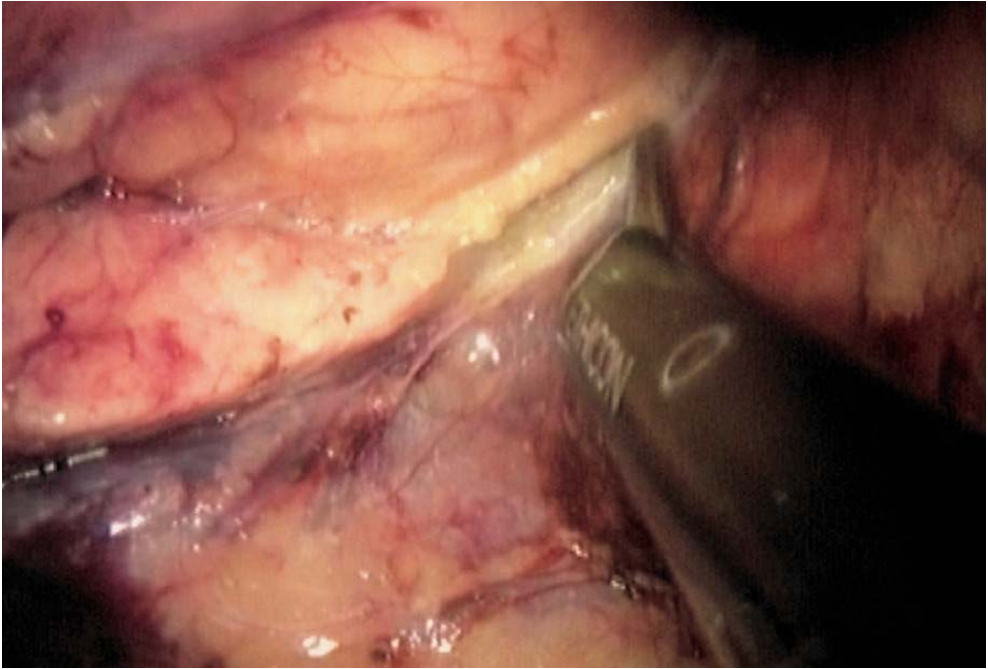


Fig. 8.12. Retroperitoneal dissection, identifying the pancreas

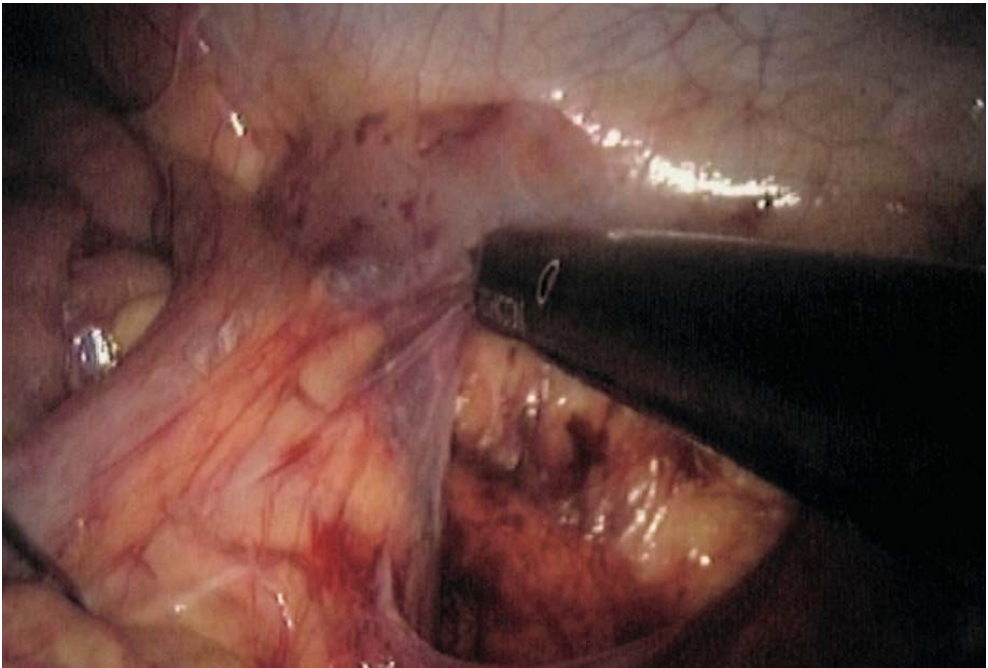


Fig. 8.13. Dissection of lateral peritoneal attachments

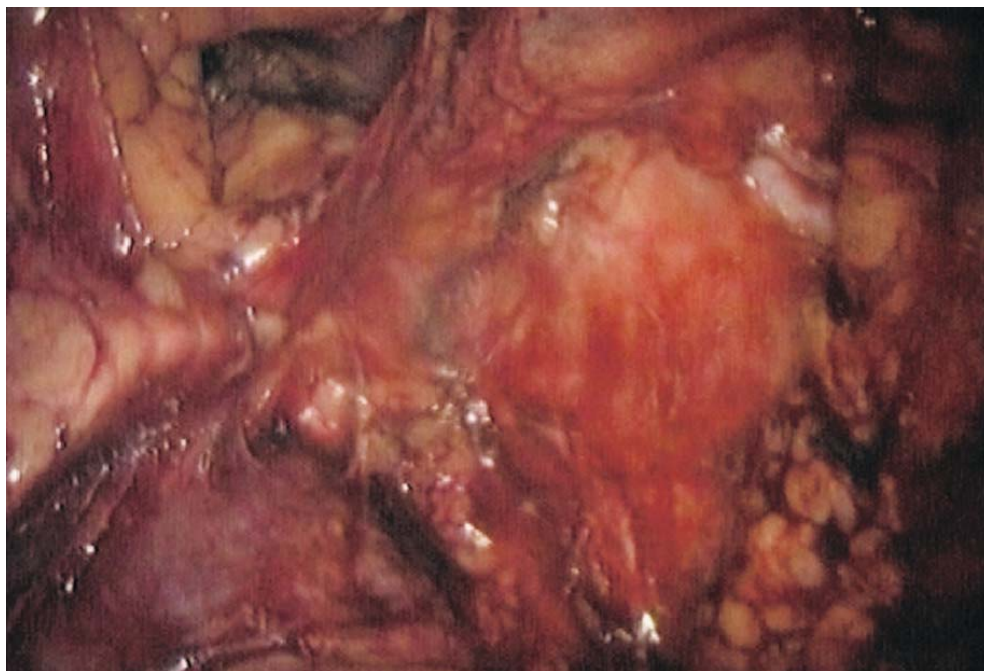

Fig. 8.14. Taking down the splenic flexure

## 8.6 Rectal Dissection

The patient is placed back as in the beginning of the procedure, and the endoscope goes back into the right lateral trocar. Opening of the left and right posterior parietal peritoneum is continued with the harmonic scalpel and the coagulating shears (▶ Fig. 8.15). Resection of the perirectal peritoneum is continued. The upper rectal wall is outlined (▶ Figs. 8.16–8.21). Wide opening of the presacral space is continued posteriorly, respecting the posterior presacral layer. As no complete mesorectal excision is needed in a left colectomy, the level of resection is located in the upper rectum. But the dissection may include total mesorectal excision in case of coloproctectomy. The posterior mesorectum is freed from the rectal tube with a 10-mm fenestrated forceps at the level chosen for rectal transection. The posterior mesorectum is transected either with the harmonic scalpel or the linear stapler (▶ Fig. 8.22). The rectum itself is then transected with a linear stapler introduced in the 12-mm right iliac fossa port (▶ Fig. 8.23). Several firings are required. An angulating stapler is preferred, especially in lower resections.

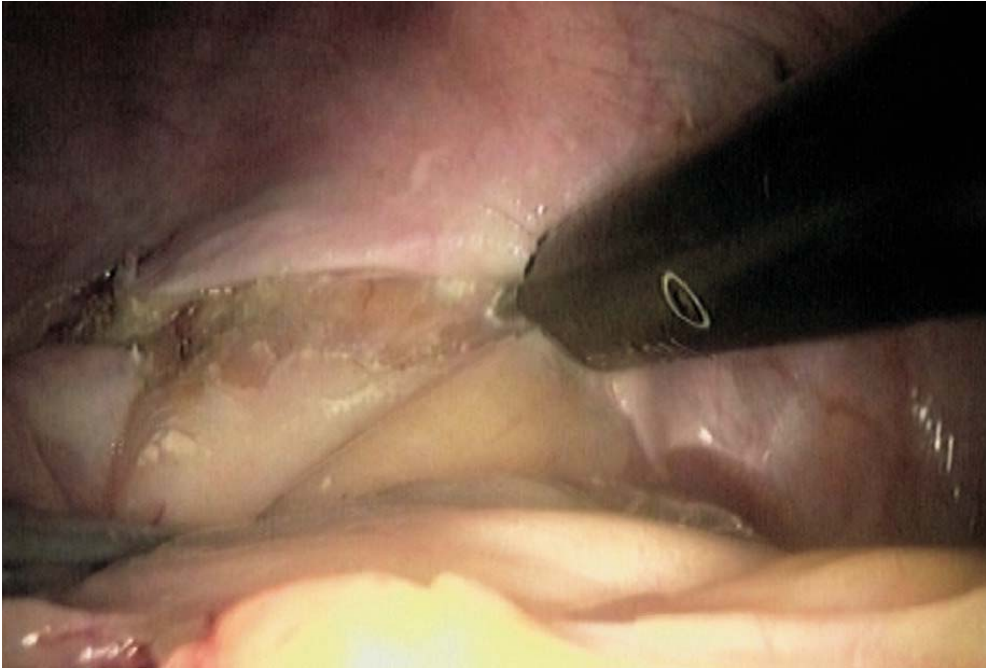


Fig. 8.15. Anterior perirectal peritoneum

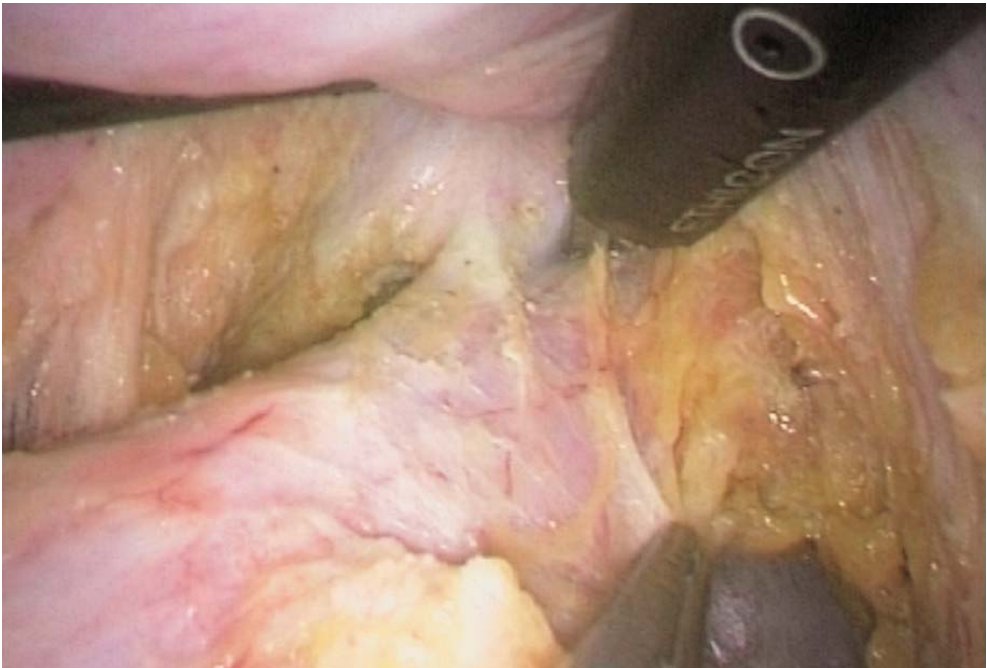
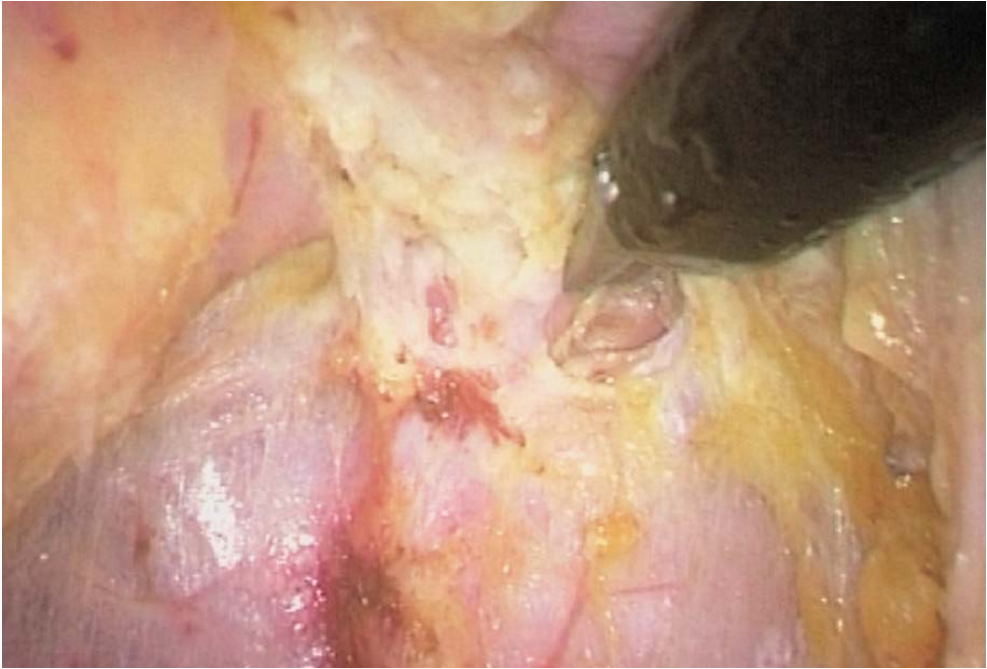
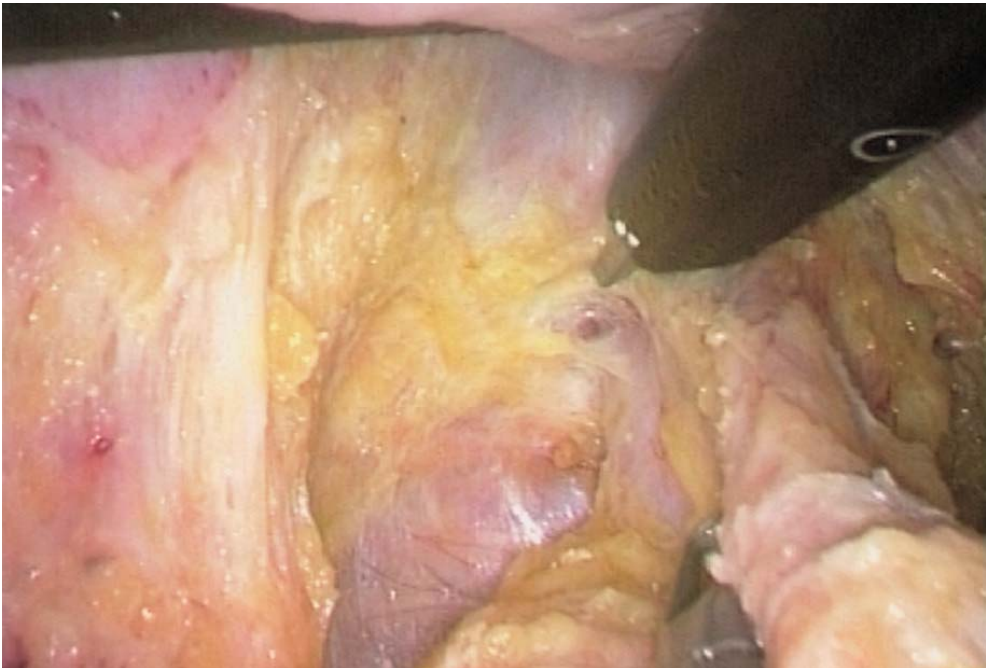
Fig. 8.16. Rectal dissection





**Fig. 8.17. Posterior rectal dissection**



**Fig. 8.18. Left lateral rectal dissection and transection of lateral ligaments**

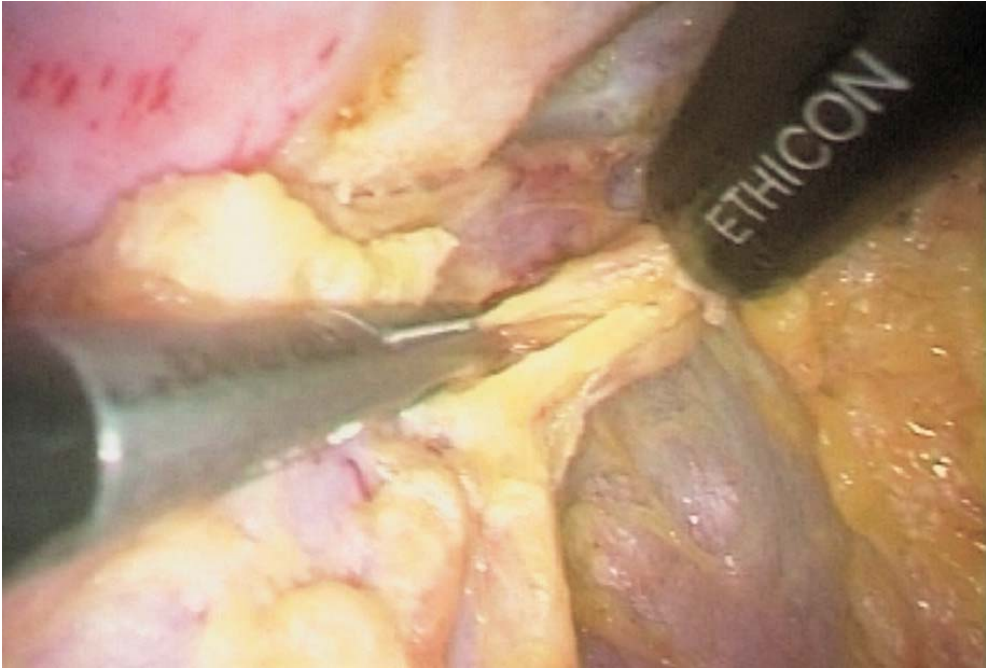


Fig. 8.19. Right lateral rectal dissection and transection of lateral ligaments

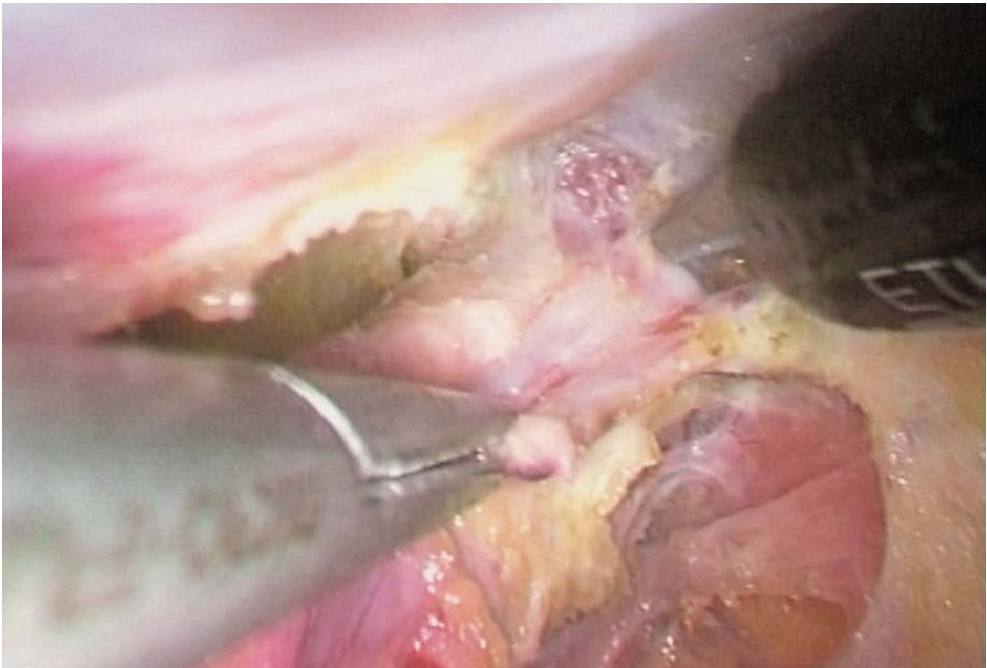


Fig. 8.20. Low rectal dissection

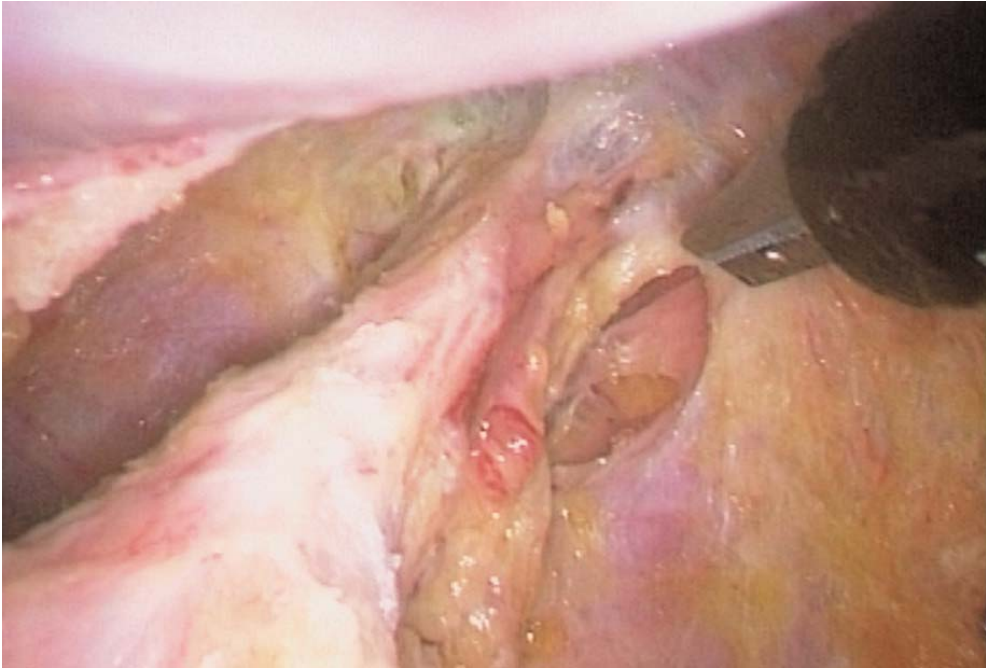


Fig. 8.21. Total mesorectal excision completed

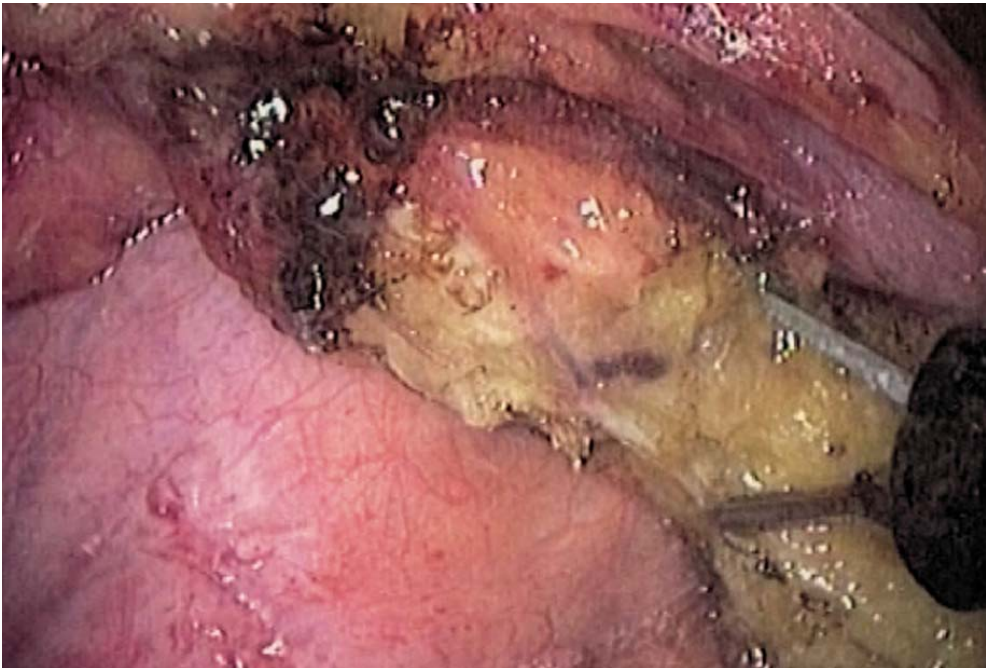


Fig. 8.22. Transection of mesorectum



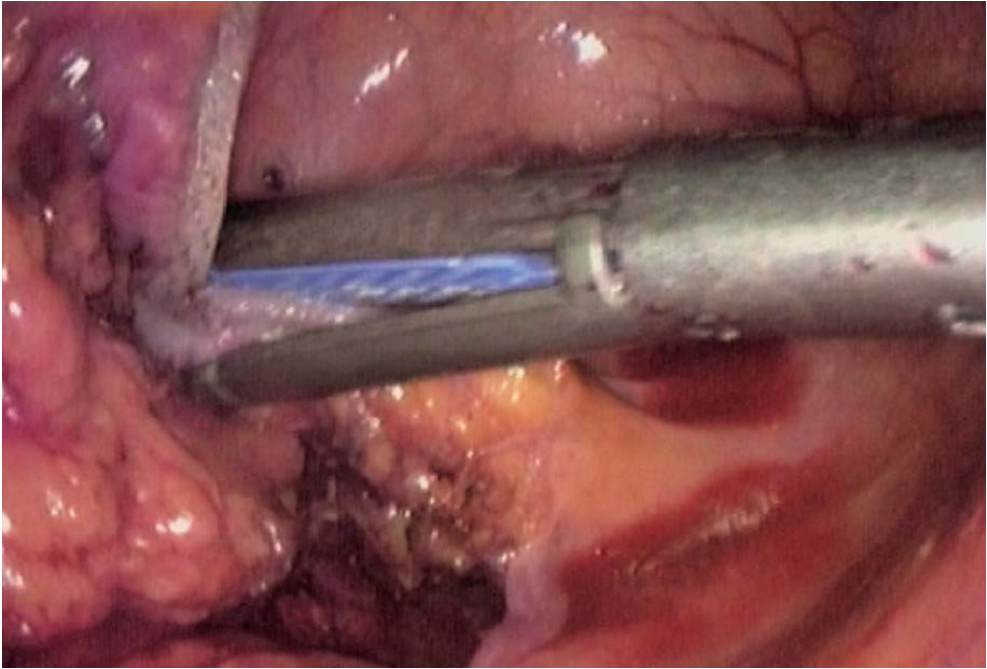


Fig. 8.23. Stapling the rectum

## 8.7 Specimen Retrieval and Colonic Resection

The proximal transected colon is grasped with the suprapubic forceps. A McBurney type left retrieval incision is made. A protective drape is installed. The proximal colon extraction is helped by the suprapubic instrument. The colon is checked for the level of disease. Mesocolic resection is done at the level of proximal colon resection. Vessels are ligated. The site of colonic resection is prepared. A tension-free anastomosis requires 15 cm of colon length outside the abdomen. The colon is transected and the specimen retrieved. An automatic or hand-sewn purse string is performed with 3/0 nylon suture. The colon is cleaned with iodine. The anvil of a circular stapler is introduced and the purse string tightened. The colon is replaced in the peritoneal cavity, and the retrieval wound is closed.



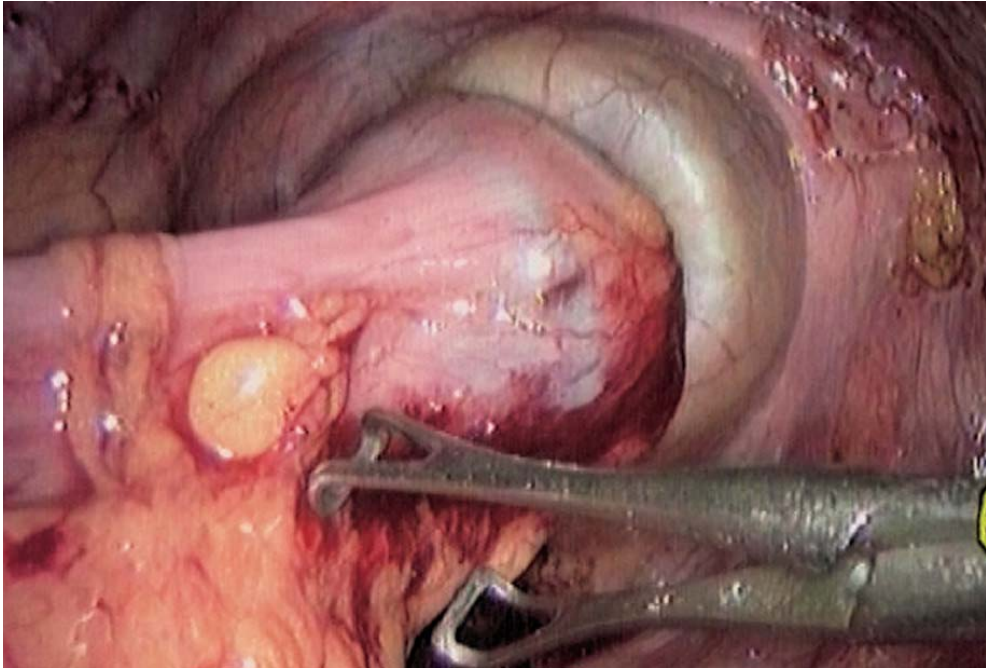


Fig. 8.24. Colorectal anastomosis

### 8.8 Colorectal Anastomosis

The pneumoperitoneum is resumed and the small bowel is re-positioned. The peritoneal cavity is rinsed with saline.

After anal dilatation, the circular stapler is carefully inserted transanally. The rectal stump is perforated, and the anvil is connected. The circular stapler is closed and fired (● Fig. 8.24). The stapler is removed, and the tissue doughnuts are inspected. There should be no tension on the anastomosis. A suction drain is inserted through the suprapubic port.

### 8.9 Tips and Comments

- Trendelenburg position must be sufficient for adequate exposure. The actual degree has to be measured, not guessed, by the anaesthesiologist.
- The left ureter is more easily found in the left parietal colic position in the learning stage and occasionally in difficult anatomical conditions.
- With experience, however, it is easy to perform a primary control of the inferior mesenteric vessels with visualization of the left ureter from the right side.
- Complex inflammatory conditions (abscess, fistula) occasionally make the latter solution mandatory.

- The first landmark for the dissection of the inferior mesenteric vessels is the promontorium. Opening of the peritoneum at this level makes it possible to see the vascular elements correctly.
- Dissection of the mesorectum must be performed in close contact to leave the pelvic innervations and the posterior presacral fascia untouched.
- To free the splenic flexure, one can choose to start at the level of the gastrocolic ligament. The retroperitoneal detachment of the mesocolic space may be made difficult by excess tissue.
- One must know how to continue laterally at the parietal colic attachments or at the upper part of the splenic flexure to complete the dissection and lowering of the left angle.
- Apart from any prior operative strategy, resection of the inferior mesenteric artery at its origin may sacrifice a left colic artery. The level of the colonic resection must be adapted to this anatomical circumstance and the quality of vascularization of the colon.
- The resection of the inferior mesenteric vein can be made at its termination near the pancreas in a true left colectomy (transverse colon – rectal anastomosis) or preferably lower of the left colic venous branches in the case of a resection of the descending colon.

## Literature

- Bemelman WA, Ringers J et al (1996) Laparoscopic assisted colectomy with the dexterity pneumo sleeve. *Dis Colon Rectum* 39[Suppl]: S59–S61
- Bergamaschi R (1997) Uncomplicated diverticulitis of the sigmoid: old challenges. *Scand J Gastroenterol* 32:1187–1189
- Berthou JC, Charbonneau P (1997) Results of laparoscopic treatment of diverticular sigmoiditis: apropos of 85 cases. *Chirurgie* 122:424–429
- Bruce CJ, Collier JA et al (1992) Laparoscopic resection of diverticular disease. *Dis Colon Rectum* 35:64–68
- Bruce CJ, Collier JA et al (1996) Laparoscopic resection of diverticular disease. *Dis Colon Rectum* 39[Suppl]: S1–S6
- Cady J, Godfroy J, Sibaud O (1995) Laparoscopic resection anastomosis in diverticular sigmoiditis and its complications: apropos of 65 cases. *Chirurgie* 10:605–610
- Cuesta MA, Borgstein PJ, Paul MA, de Jong D (1992) Surgery of the distal colon assisted by laparoscopy. *Video Rev Surg* 9:10–21
- Eijsbouts QAJ, Cuesta MA, de Brauw LM, Sietses C (1997) Elective laparoscopic-assisted sigmoid resection for diverticular disease? *Surg Endosc* 1:750–753. DOI 10.1007/s004649900442
- Franklin ME Jr, Dorman JP et al (1997) Is laparoscopic surgery applicable to complicated colonic diverticular disease? *Surg Endosc* 11:1021–1025. DOI 10.1007/s004649900516
- Hewett PJ, Stitz R (1995) The treatment of internal fistulae that complicate diverticulaire disease of the sigmoid colon by laparoscopically assisted colectomy. *Surg Endosc* 9:411–413
- Hinchey EJ, Schaal PG, Richards GK (1978) Treatment of perforated diverticular disease of the colon. *Adv Surg* 12:85–109
- Jacobs M, Verdeja JC, Goldstein HS (1991) Minimally invasive colon resection (laparoscopic colectomy). *Surg Laparosc Endosc* 1:144–150

- Junghans TB, Bohm (1997) Progress in laparoscopic sigmoid resection in elective surgical therapy of sigmoid diverticulitis. *Langenbecks in elective surgical therapy of sigmoid diverticulitis*. *Langenbecks Arch Chir* 382:266–270. DOI 10.1007/s004230050064
- Kohler L, Rixen D et al (1998) Laparoscopic colorectal resection for diverticulitis. *Int J Colorectal Dis* 13:43–47. DOI 10.1007/s003840050130
- Liberman MA, Phillips EH et al (1996) Laparoscopic colectomy vs. traditional colectomy for diverticulitis: outcome and costs. *Surg Endosc* 10:15–18. DOI 10.1007/s004649910002
- Mooney MJ, Elliot L et al (1998) Hand assisted laparoscopic sigmoidectomy for diverticulitis. *Dis Colon Rectum* 41:630–635
- Phillips EH, Rosenthal RJ (19xx) Nomenclature in laparoscopic colon surgery. In: Phillips EH, Rosenthal RJ (eds) *Operative strategies in laparoscopic surgery*. Springer, Berlin Heidelberg New York, pp 215–218
- Puente I, Sosa JL, Utpal Desai BS, Sleeman D, Hartmann R (1994) Laparoscopic treatment of colovesical fistulas: technique and reports of two cases. *Surg Laparosc Endosc* 4:157–160
- Schiedeck TH, Schwandner O et al (1998) Laparoscopic sigmoid resection in diverticulitis. *Chirurg* 69:846–853. DOI 10.1007/s001040050499
- Senagore AJ, Luchtfeld M (1994) Initial experience with lighted uretral catheters during laparoscopic colectomy. *Surg Laparosc Endosc* 4:399–403
- Sher ME, Agachan F et al (1997) Laparoscopic surgery for diverticulitis. *Surg Endosc* 11:264–267. DOI 10.1007/s004649900340
- Stabile BE, Puccio E, van Sonneneberg E, Neff CC (1990) Percutaneous drainage of diverticular abscesses. *Am J Surg* 159:99–105
- Standard Task Force of the American Society of Colon and Rectal Surgeons (1995) Practice parameters for sigmoid diverticulitis – supporting documentation. *Dis Colon Rectum* 38:126–132
- Stevenson AR, Stitz RW (1998) Laparoscopic assisted anterior resection for diverticular disease: follow-up of 100 consecutive patients. *Ann Surg* 27:335–342

---

## 9 Laparoscopic Right Colectomy

### 9.1 Operating Room Setup: Position of the Patient

The patient is placed supine. A Trendelenburg position is required at the initial stage of the operation with some left rotation. The surgeon stands to the left of the patient, and the first assistant to the surgeon's left. The second assistant is positioned between the patient's legs (➤ Fig. 9.1).

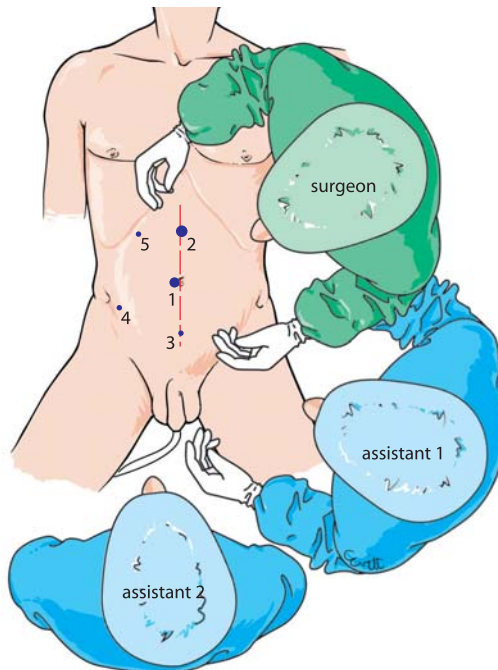


Fig. 9.1. OR setup – trocar position



## 9.2 Recommended Instruments

- Two 10-mm trocars
- Three 5-mm trocars
- A 12-mm trocar with reducer
- Three 5-mm fenestrated grasping forceps
- Five-millimetre coagulating shears
- A 5-mm straight grasping forceps
- A 5- or 10-mm harmonic scalpel
- A 10-mm fenestrated forceps
- A 10-mm curved dissector
- A 5-mm needle holder
- A 12-mm linear stapler
- A 0° endoscope

## 9.3 Trocars: Peritoneal Exploration – Cecal and Mesenteric Mobilization

A pneumoperitoneum is performed using the Veress needle. A 10-mm para-umbilical trocar for the 0° scope is inserted. Two trocars, one 5-mm suprapubic and the other 12-mm supra-umbilical, will enable the positioning of working instruments for both hands.

Two 5-mm right iliac fossa and right subcostal trocars will be used for the exposure instruments. The caecum is grasped with a Johann fenestrated forceps. The patient is placed in a 20° Trendelenburg position with left lateral rotation.

The small bowel is placed in the upper part of the peritoneal cavity. Dissection starts with the coagulating scissors or harmonic scalpel. The posterior parietal peritoneum is opened, after checking for the right ureter (◀ Fig. 9.2). The right mesocolon is detached from the right renal fascia to the duodenal genus inferius (▶ Figs. 9.3, 9.4). Right parietal colonic detachment is continued with complete release of the parietal attachments.

## 9.4 Mobilization of the Hepatic Flexure

The patient is now placed in a slightly prone position. The transverse colon and the greater omentum are exposed. The omental attachments of the transverse colon are released using the coagulating shears or harmonic scalpel (▶ Fig. 9.5). Proper dissection frees the genus superius. The ligaments of the hepatic flexure are dissected. The two lower and upper dissection planes then communicate. The right colon and mesocolon are completely freed (▶ Figs. 9.6, 9.7).

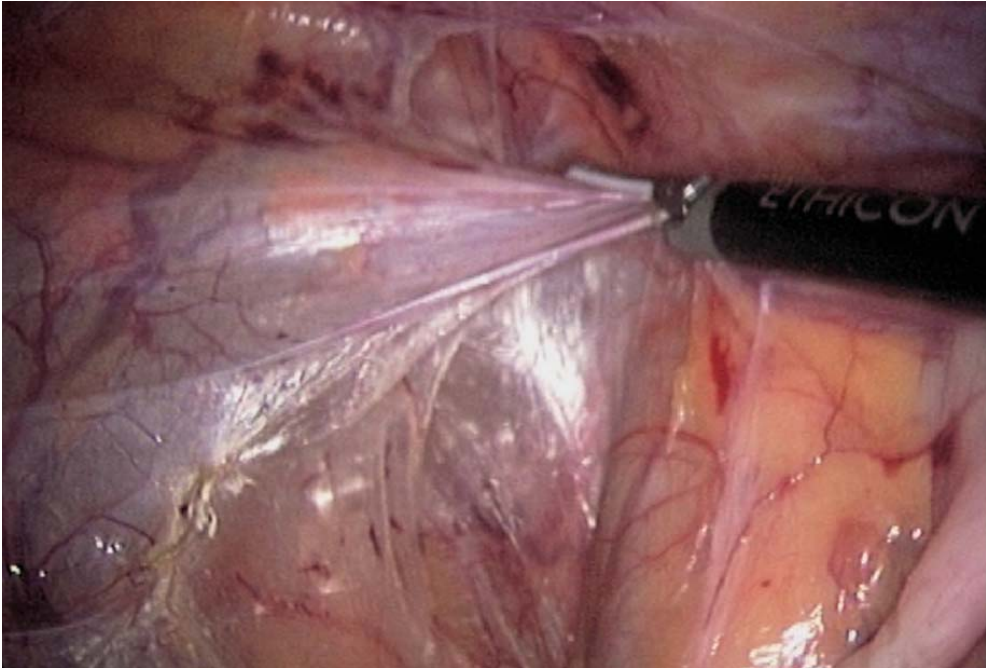


Fig. 9.2. Right parietal colonic detachment

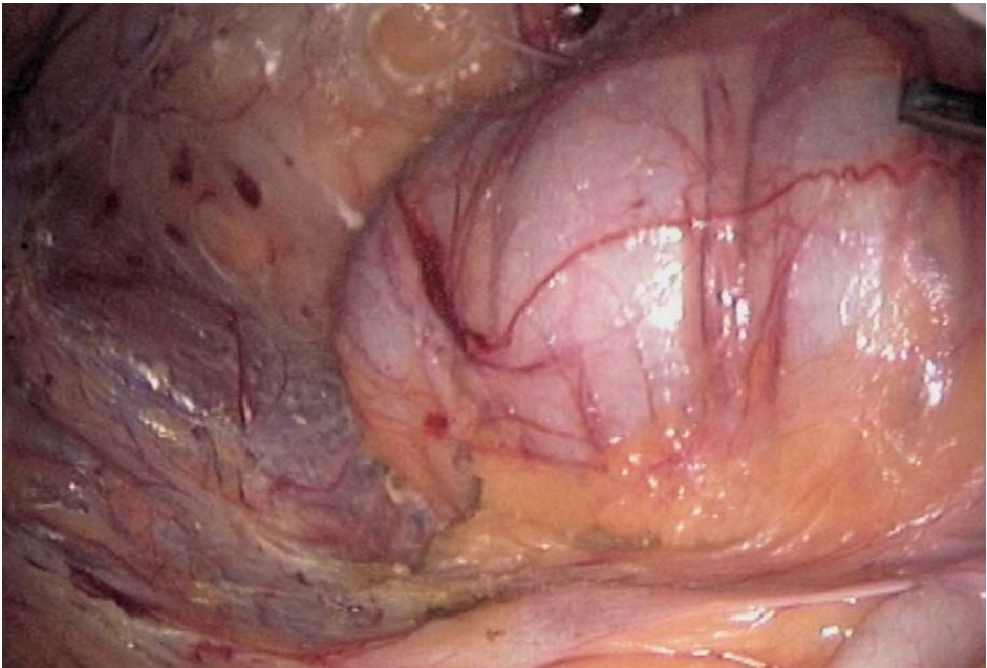


Fig. 9.3. Caecal dissection

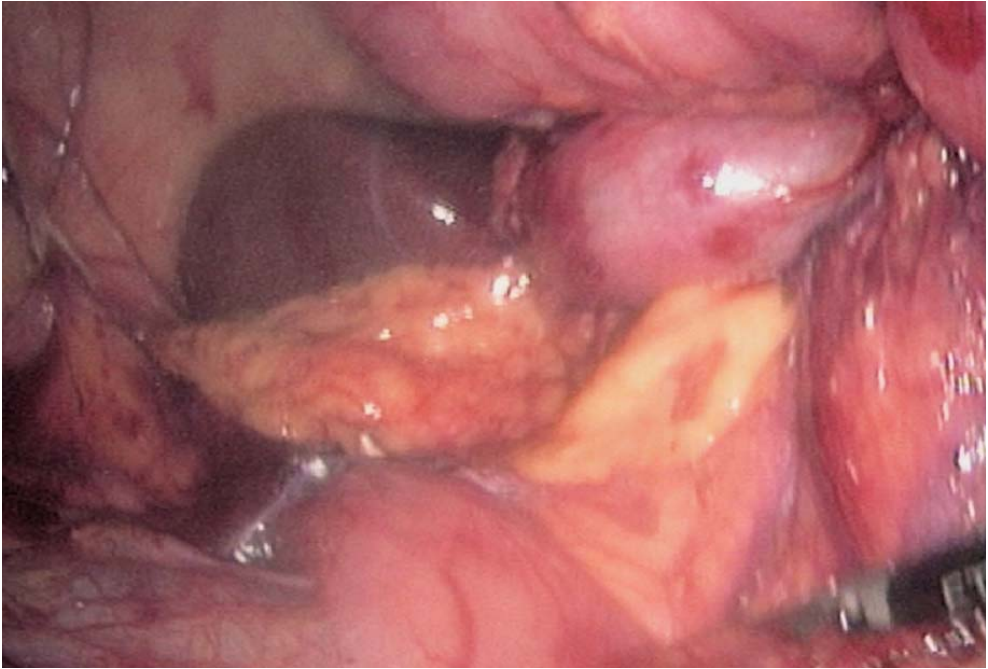


Fig. 9.4. Duodenal and pancreatic dissection

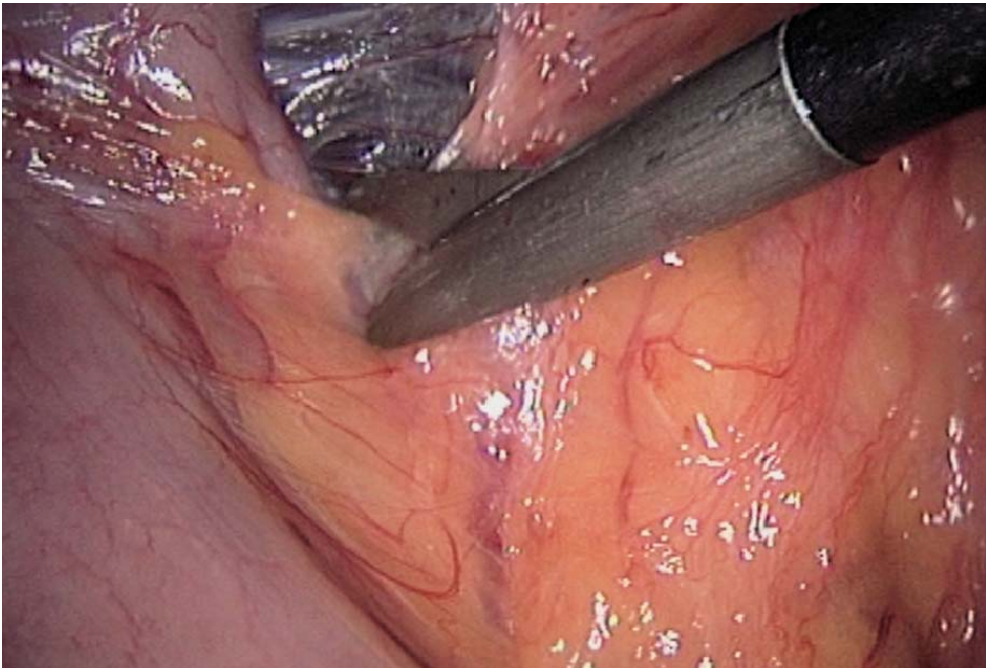


Fig. 9.5. Dissection of omental attachments of the transverse colon



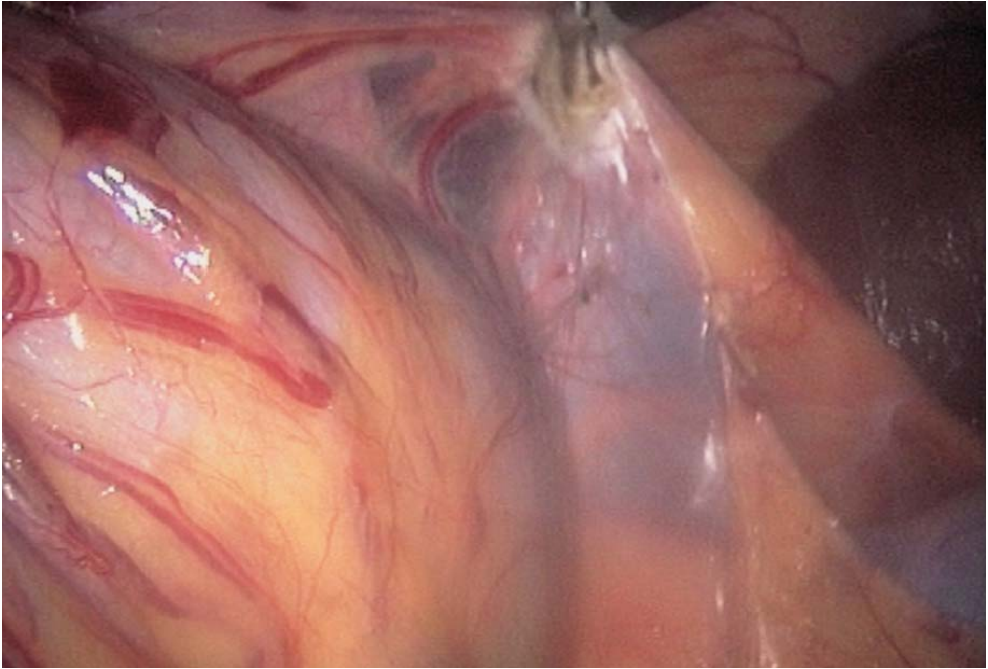


Fig. 9.6. Mobilization of the hepatic flexure

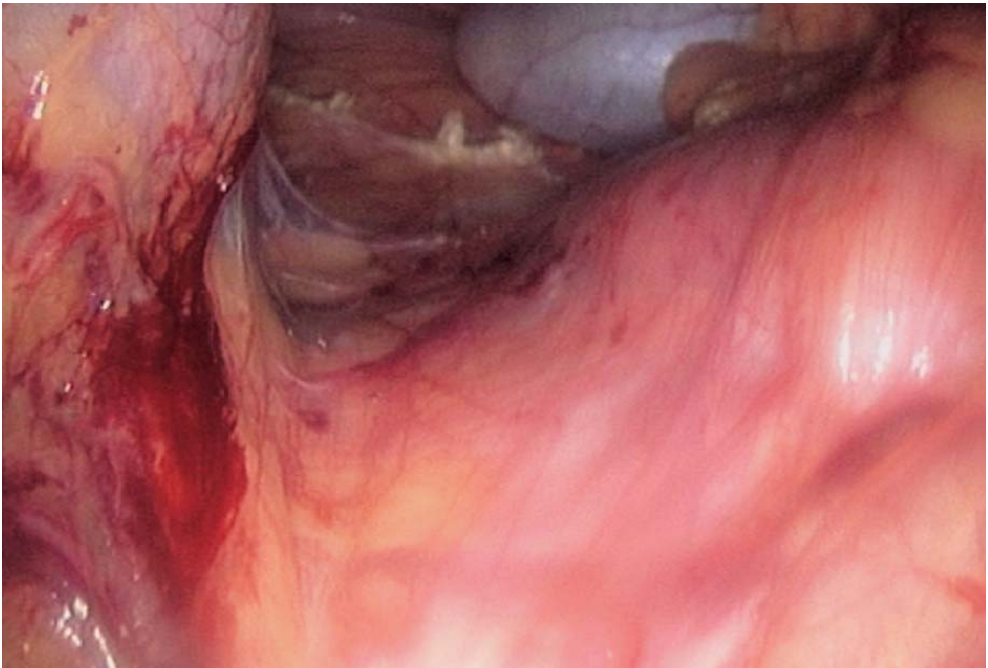


Fig. 9.7. Duodenal dissection (genus inferius)



## 9.5 Vessel Control

The patient is left in the same position. Exposure of the ileocecal junction is initially performed through the suprapubic and subcostal trocars. The colon is now under traction by the two exposure instruments. Mesenteric fenestration on both sides of the ileocaecal vessels is performed. The vessels are controlled either by an intracorporeal ligature or by vascular linear stapling (▶ Figs. 9.8–9.10). Second, the right colic vessels are exposed at the anterior part of the head of the pancreas, respecting Henlé's gastrocolic venous trunk (▶ Figs. 9.11, 9.12). Transverse mesocolic fenestration makes it possible to isolate precisely the vascular pedicle before ligature or stapling. An additional omental resection is done.

## 9.6 Specimen Retrieval and Colonic Resection

The surgeon moves to the patient's right side at this step. A small, up-to-5-cm lateral incision is made in the right lower quadrant. The wound is protected with a plastic sheet. The prepared colon is extracted. The paracolic vessels are controlled with conventional ligature. Ileal and colic resection is carried out.

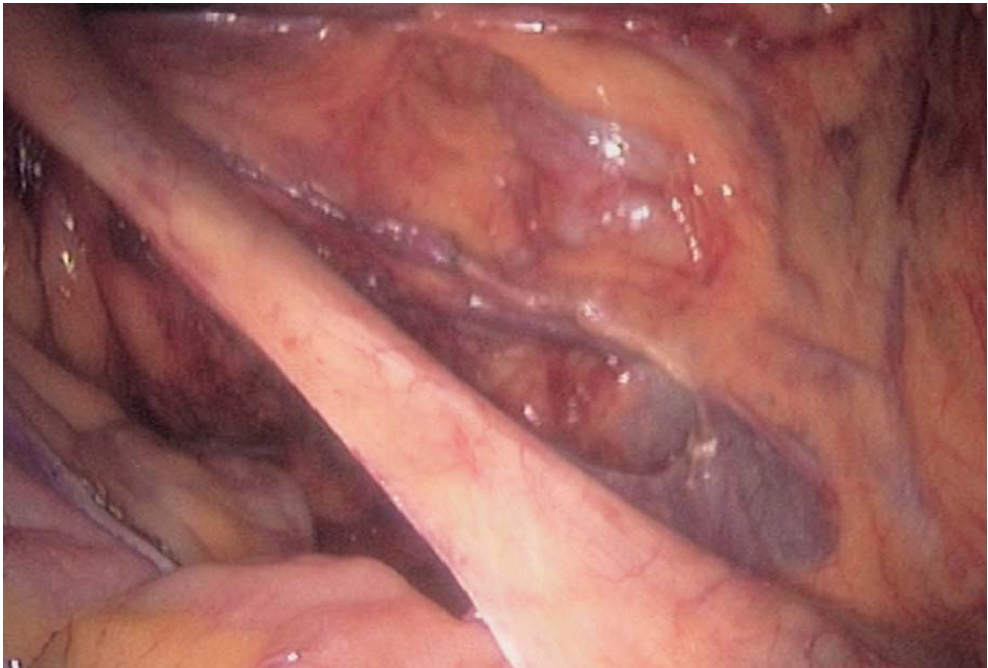

Fig. 9.8. Dissection of the ileocaecal vessels

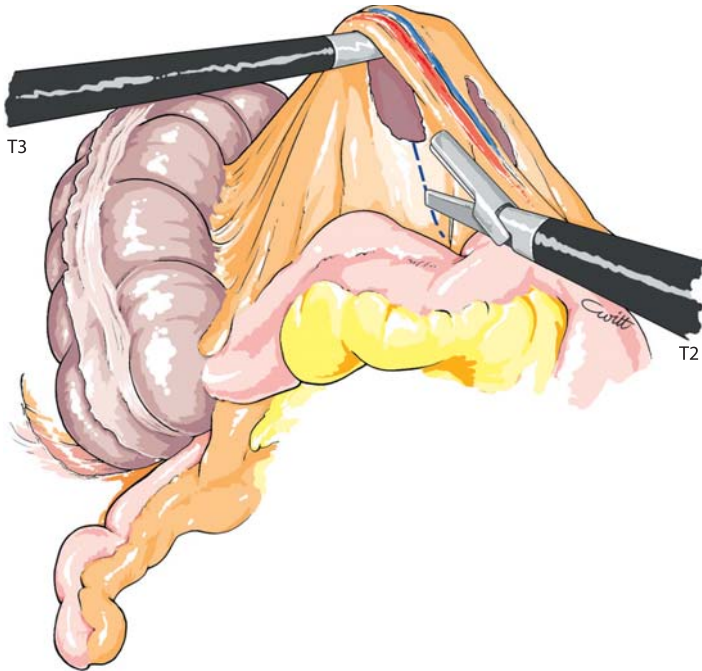


Fig. 9.9. Dissection of ileocolic vessels

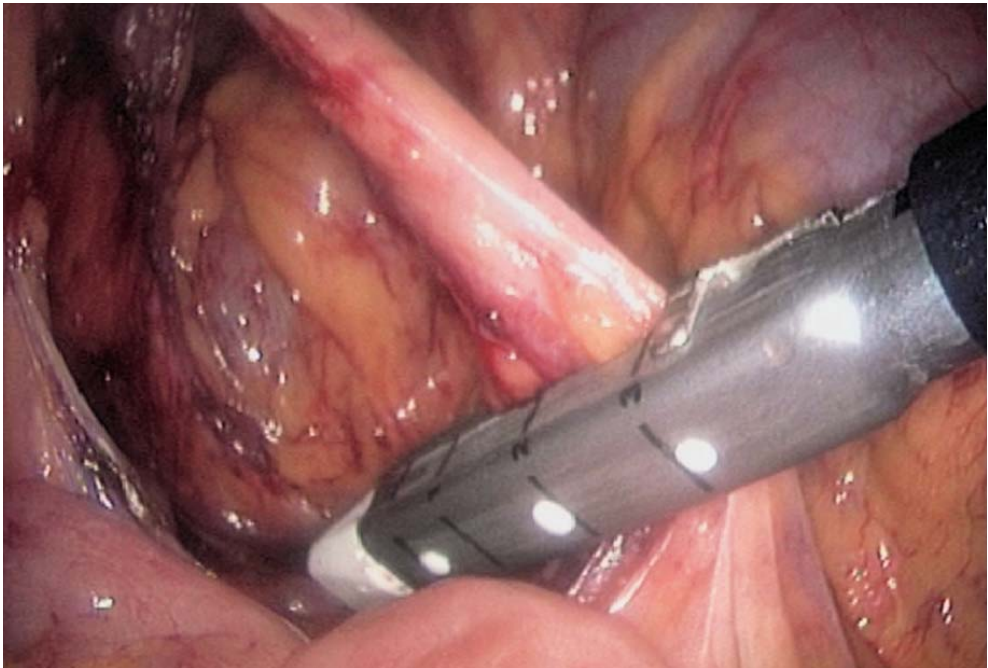


Fig. 9.10. Stapling of the ileocaecal vessels

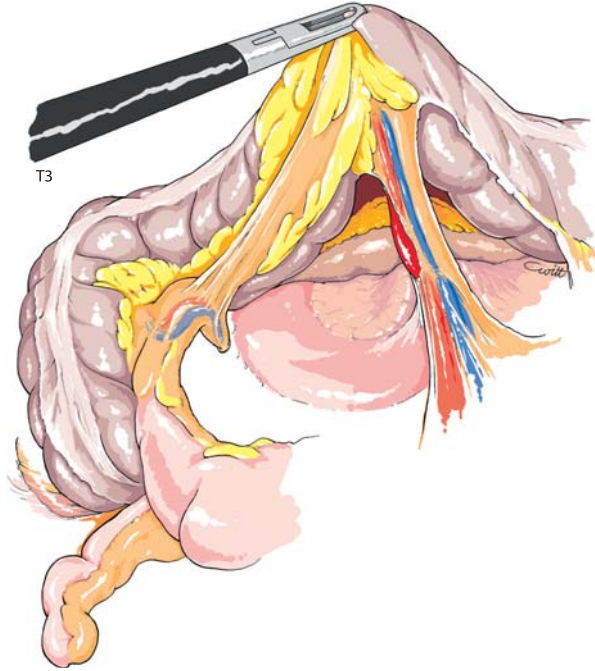


Fig. 9.11. Exposure of right colic vessels

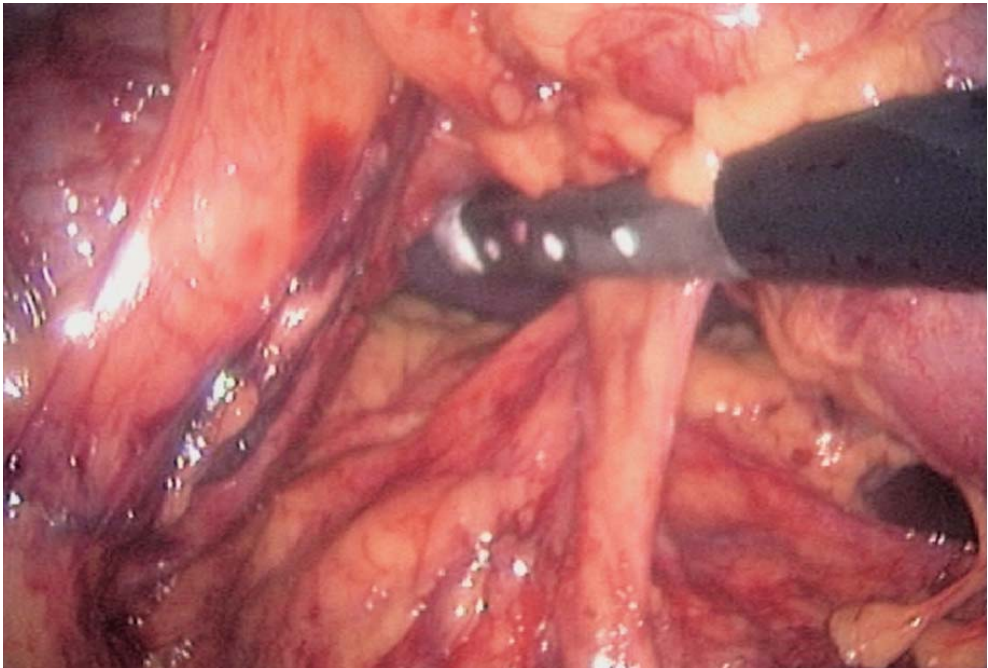


Fig. 9.12. Control of the right colonic vessels

## 9.7 Ileotransverse Anastomosis

A hand-sewn, or stapled latero-lateral anastomosis with two firings is done (◉ Fig. 9.13). The bowel is put back into the peritoneal cavity. The incision is closed with care.

## 9.8 Checking for Bleeding, Lavage, Suturing of the Mesenteric Defect

The abdominal cavity is re-inflated. The ileocolic anastomosis is inspected and the proper positioning of the small bowel is checked (◉ Fig. 9.14). The peritoneal cavity is cleaned with saline and checked for bleeding. The mesenteric opening can be sutured at this stage (◉ Fig. 9.15), but can also be missed. A suction drain is left in the right parietal fossa.

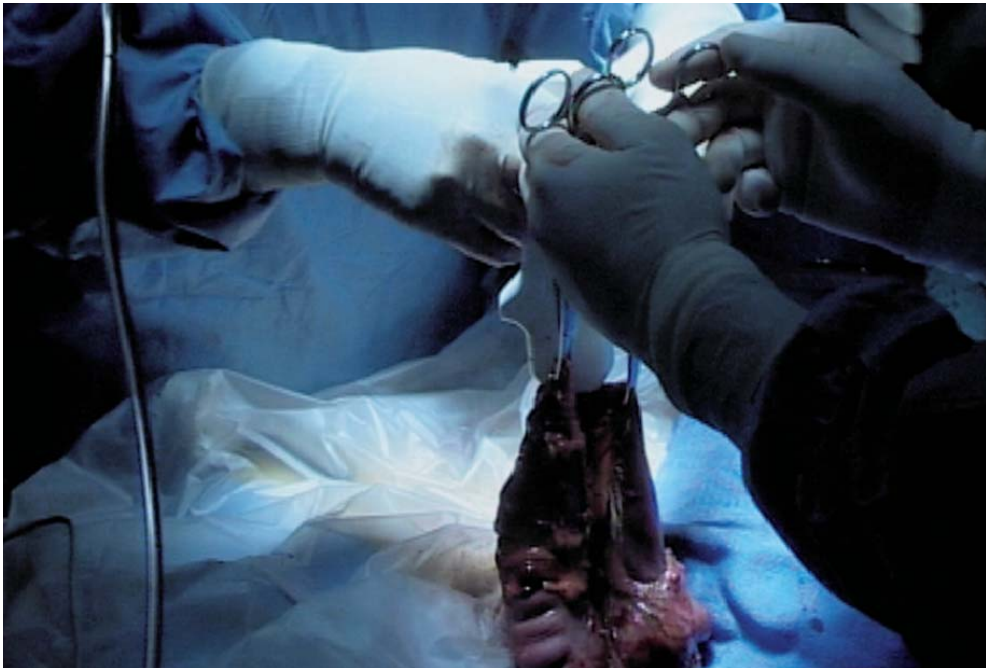

Fig. 9.13. Ileotransverse anastomosis (external view)



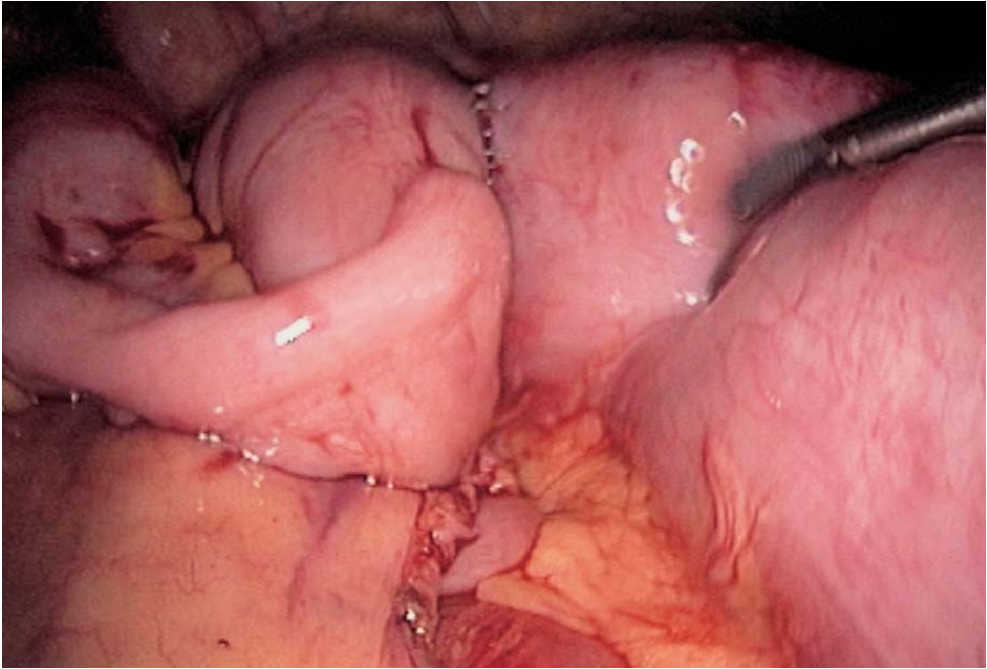


Fig. 9.14. Ileotransverse anastomosis (internal view)

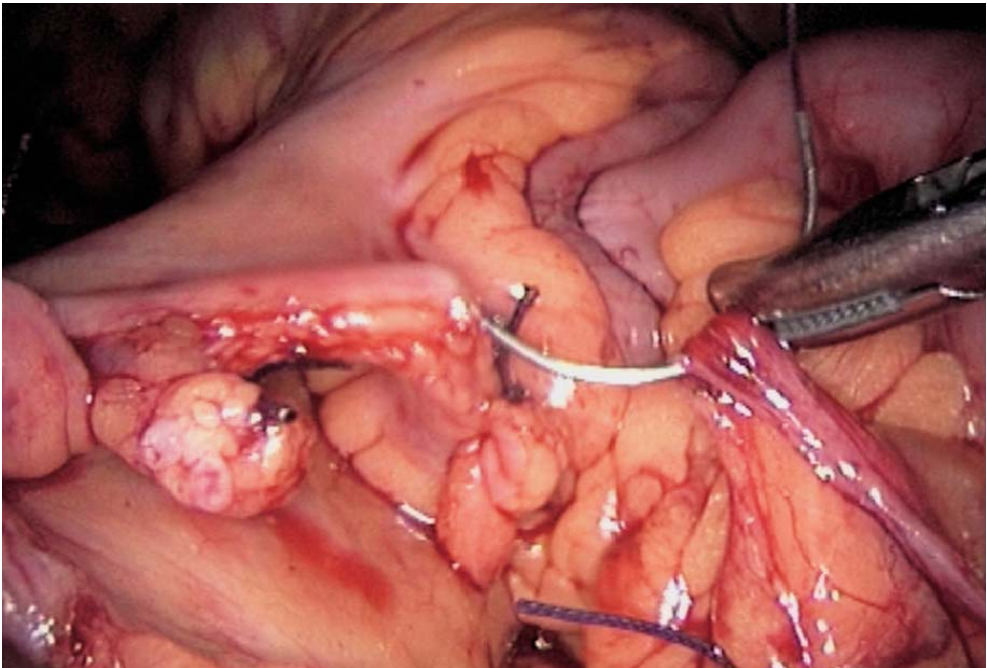


Fig. 9.15. Suturing of the mesenteric defect

## 9.9 Tips and Comments

- In obese patients, the first trocar can be inserted left to the umbilicus for a better view of the right colon.
- The omental detachment must be started in the medial part of the transverse colon to facilitate the dissection.
- The vessels should only be ligated after mobilization of the entire right colon. A primary control of the vessels may be extremely difficult due to excess tissue.
- The colon cannot be properly extracted without prior vessel control. Therefore, the vessels should always be controlled at the time of laparoscopic dissection.
- Complete mobilization can be done from downwards without changing position.
- Omental resection should be done in all cancer cases, but is even advisable at all times for easier dissection.

## Literature

- Bemelman WA, Ringers J et al (1996) Laparoscopic assisted colectomy with the dexterity pneumo sleeve. *Dis Colon Rectum* 39[Suppl]: S59–S61
- Bergamaschi R (1997) Uncomplicated diverticulitis of the sigmoid: old challenges. *Scand J Gastroenterol* 32:1187–1189
- Berthou JC, Charbonneau P (1997) Results of laparoscopic treatment of diverticular sigmoiditis: apropos of 85 cases. *Chirurgie* 122:424–429
- Bruce CJ, Collier JA et al (1992) Laparoscopic resection of diverticular disease. *Dis Colon Rectum* 35:64–68
- Bruce CJ, Collier JA et al (1996) Laparoscopic resection of diverticular disease. *Dis Colon Rectum* 39(Suppl):s1–S6
- Cady J, Godfroy J, Sibaud O (1995) Laparoscopic resection anastomosis in diverticular sigmoiditis and its complications: apropos of 65 cases. *Chirurgie* 10:605–610
- Cuesta MA, Borgstein PJ, Paul MA, de Jong D (1992) Surgery of the distal colon assisted by laparoscopy. *Video Rev Surg* 9:10–21
- Eijsbouts QAJ, Cuesta MA, de Brauw LM, Sietses C (1997) Elective laparoscopic-assisted sigmoid resection for diverticular disease? *Surg Endosc* 1:750–753. DOI 10.1007/s004649900442
- Franklin ME Jr, Dorman JP et al (1997) Is laparoscopic surgery applicable to complicated colonic diverticular disease? *Surg Endosc* 11:1021–1025. DOI 10.1007/s004649900516
- Hewett PJ, Stitz R (1995) The treatment of internal fistulae that complicate diverticular disease of the sigmoid colon by laparoscopically assisted colectomy. *Surg Endosc* 9:411–413
- Hinchey EJ, Schaaf PG, Richards GK (1978) Treatment of perforated diverticular disease of the colon. *Adv Surg* 12:85–109
- Jacobs M, Verdeja JC, Goldstein HS (1991) Minimally invasive colon resection (laparoscopic colectomy). *Surg Laparosc Endosc* 1:144–150
- Junghans TB, Bohm (1997) Progress in laparoscopic sigmoid resection in elective surgical therapy of sigmoid diverticulitis. *Langenbecks in elective surgical therapy of sigmoid diverticulitis. Langenbecks Arch Chir* 382:266–2. DOI 10.1007/s004230050064
- Kohler L, Rixen D et al (1998) Laparoscopic colorectal resection for diverticulitis. *Int J Colorectal Dis* 13:43–47. DOI 10.1007/s003840050130

- Lieberman MA, Phillips EH et al (1996) Laparoscopic colectomy vs. traditional colectomy for diverticulitis: outcome and costs. *Surg Endosc* 10:15–18 DOI:10.1007/s004649910002
- Mooney MJ, Elliot L et al (1998) Hand assisted laparoscopic sigmoidectomy for diverticulitis. *Dis Colon Rectum* 41:630–635
- Phillips EH, Rosenthal RJ (19xx) Nomenclature in laparoscopic colon surgery. In: Phillips EH, Rosenthal RJ (eds) *Operative strategies in laparoscopic surgery*. Springer, Berlin Heidelberg New York, pp 215–218
- Puente I, Sosa JL, Utpal Desai BS, Sleeman D, Hartmann R (1994) Laparoscopic treatment of colovesical fistulas: technique and reports of two cases. *Surg Laparosc Endosc* 4:157–160
- Schiedeck TH, Schwandner O et al (1998) Laparoscopic sigmoid resection in diverticulitis. *Chirurg* 69:846–853. DOI 10.1007/s001040050499
- Senagore AJ, Luchtfeld M (1994) Initial experience with lighted uretral catheters during laparoscopic colectomy. *Surg Laparosc Endosc* 4:399–403
- Sher ME, Agachan F et al (1997) Laparoscopic surgery for diverticulitis. *Surg Endosc* 11:264–267. DOI 10.1007/s004649900340
- Stabile BE, Puccio E, van Sonneneberg E, Neff CC (1990) Percutaneous drainage of diverticular abscesses. *Am J Surg* 159:99–105
- Standard Task Force of the American Society of Colon and Rectal Surgeons (1995) Practice parameters for sigmoid diverticulitis – supporting documentation. *Dis Colon Rectum* 38:126–132
- Stevenson AR, Stitz RW (1998) Laparoscopic assisted anterior resection for diverticular disease: follow-up of 100 consecutive patients. *Ann Surg* 27:335–342

---

## 10 Laparoscopic Total Colectomy

### 10.1 Operating Room Setup: Position of the Patient

The patient is placed supine in a 20° Trendelenburg position. The surgeon and first assistant are on the right side of the patient. The second assistant stands between the legs of the patient. The video monitor is placed to the left of the patient.

### 10.2 Recommended Instruments

- A 0° endoscope
- Two 10-mm trocars
- Three 5-mm trocars
- A 12-mm trocar with reducer
- Three 5-mm fenestrated grasping forceps
- Five-millimeter coagulating shears
- Three 5-mm straight grasping forceps
- A 5- or 10-mm harmonic scalpel
- A 10-mm fenestrated forceps
- A 10-mm curved dissector
- A 5-mm needle holder
- One 12-mm linear stapler
- One circular stapler
- A plastic protective surgical drape with a 7-cm opening

### 10.3 Total Colectomy with Rectal Resection Is the Addition of a Left Colectomy Followed by a Right Colectomy

- Two video monitors on both sides of the patient simplify the subsequent positions of the surgeon, who starts with the left colon resection and ends with the right colon resection.
- The specimen is delivered through a right Mac Burney-type incision. The stapled ileal J-pouch is created at that time in open surgery. A protective ileostomy can also be done.



- The bowel is placed back in the peritoneal cavity, taking extreme care to avoid rotating the distal mesentery.
- The lateral ligaments are controlled using the harmonic scalpel, linear stapling or coagulating systems. Total excision of the mesorectum is performed in case of total colectomy.
- The low transection of the rectum is preferably performed using an articulated linear stapler.
- In all cases, 1 cm to 5 mm of rectal tissue remains after stapling, allowing circular stapling.
- Omentoplasty is always possible by freeing the greater omentum and keeping its left vessels. Omental vessels are controlled by the harmonic scalpel or with clips.

## Literature

- Bemelman WA, Ringers J et al (1996) Laparoscopic assisted colectomy with the dexterity pneumo sleeve. *Dis Colon Rectum* 39[Suppl]: S59–S61
- Bergamaschi R (1997) Uncomplicated diverticulitis of the sigmoid: old challenges. *Scand J Gastroenterol* 32:1187–1189
- Berthou JC, Charbonneau P (1997) Results of laparoscopic treatment of diverticular sigmoiditis: apropos of 85 cases. *Chirurgie* 122:424–429
- Bruce CJ, Collier JA et al (1992) Laparoscopic resection of diverticular disease. *Dis Colon Rectum* 35:64–68
- Bruce CJ, Collier JA et al (1996) Laparoscopic resection of diverticular disease. *Dis Colon Rectum* 39(Suppl):s1–S6
- Cady J, Godfroy J, Sibaud O (1995) Laparoscopic resection anastomosis in diverticular sigmoiditis and its complications: apropos of 65 cases. *Chirurgie* 10:605–610
- Cuesta MA, Borgstein PJ, Paul MA, de Jong D (1992) Surgery of the distal colon assisted by laparoscopy. *Video Rev Surg* 9:10–21
- Eijsbouts QAJ, Cuesta MA, de Brauw LM, Sietses C (1997) Elective laparoscopic-assisted sigmoid resection for diverticular disease? *Surg Endosc* 1:750–753. DOI 10.1007/s004649900442
- Franklin ME Jr, Dorman JP et al (1997) Is laparoscopic surgery applicable to complicated colonic diverticular disease? *Surg Endosc* 11:1021–1025. DOI 10.1007/s004649900516
- Hewett PJ, Stitz R (1995) The treatment of internal fistulae that complicate diverticular disease of the sigmoid colon by laparoscopically assisted colectomy. *Surg Endosc* 9:411–413
- Hinchey EJ, Schaal PG, Richards GK (1978) Treatment of perforated diverticular disease of the colon. *Adv Surg* 12:85–109
- Jacobs M, Verdeja JC, Goldstein HS (1991) Minimally invasive colon resection (laparoscopic colectomy). *Surg Laparosc Endosc* 1:144–150
- Junghans TB, Bohm (1997) Progress in laparoscopic sigmoid resection in elective surgical therapy of sigmoid diverticulitis. *Langenbecks in elective surgical therapy of sigmoid diverticulitis. Langenbecks Arch Chir* 382:266–270. DOI 10.1007/s004230050064
- Kohler L, Rixen D et al (1998) Laparoscopic colorectal resection for diverticulitis. *Int J Colorectal Dis* 13:43–47. DOI 10.1007/s003840050130
- Liberman MA, Phillips EH et al (1996) Laparoscopic colectomy vs. traditional colectomy for diverticulitis: outcome and costs. *Surg Endosc* 10:15–18. DOI 10.1007/s004649910002
- Mooney MJ, Elliot L et al (1998) Hand assisted laparoscopic sigmoidectomy for diverticulitis. *Dis Colon Rectum* 41:630–635

- 
- Phillips EH, Rosenthal RJ (19xx) Nomenclature in laparoscopic colon surgery. In: Phillips EH, Rosenthal RJ (eds) *Operative strategies in laparoscopic surgery*. Springer, Berlin Heidelberg New York, pp 215–218
- Puente I, Sosa JL, Utpal Desai BS, Sleeman D, Hartmann R (1994) Laparoscopic treatment of colovesical fistulas: technique and reports of two cases. *Surg Laparosc Endosc* 4:157–160
- Schiedeck TH, Schwandner O et al (1998) Laparoscopic sigmoid resection in diverticulitis. *Chirurg* 69:846–853. DOI 10.1007/s001040050499
- Senagore AJ, Luchtfeld M (1994) Initial experience with lighted urethral catheters during laparoscopic colectomy. *Surg Laparosc Endosc* 4:399–403
- Sher ME, Agachan F et al (1997) Laparoscopic surgery for diverticulitis. *Surg Endosc* 11:264–267. DOI 10.1007/s004649900340
- Stabile BE, Puccio E, van Sonneneberg E, Neff CC (1990) Percutaneous drainage of diverticular abscesses. *Am J Surg* 159:99–105
- Standard Task Force of the American Society of Colon and Rectal Surgeons (1995) Practice parameters for sigmoid diverticulitis – supporting documentation. *Dis Colon Rectum* 38:126–132
- Stevenson AR, Stitz RW (1998) Laparoscopic assisted anterior resection for diverticular disease: follow-up of 100 consecutive patients. *Ann Surg* 27:335–342

# 11 Laparoscopic Rectopexy for Rectal Prolapse

Two laparoscopic mesh techniques address rectal prolapse: the **Orr Loygue** procedure and the **Wells** technique. Both techniques only differ in the shape of the mesh and the way it is sutured to the rectum.

## 11.1 Operating Room Setup: Position of the Patient

The patient is placed supine, with legs apart. The patient has been made to empty his bowel before surgery. A bladder catheter is inserted. A 25° Trendelenburg position is useful. The surgeon stands on the patient's left side. The first assistant is on the surgeon's left. A second assistant stands between the patient's legs. The video monitor is placed on the patient's right side, at the level of his right foot (▶ Fig. 11.1).

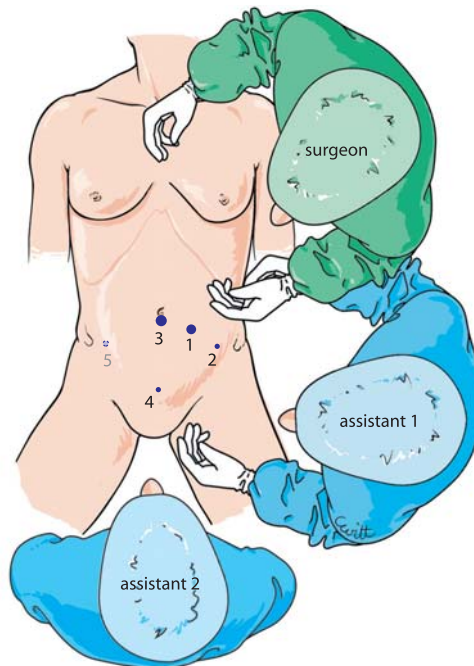


Fig. 11.1. OR setup – trocar position

## 11.2 Recommended Instruments

- One 10-mm trocar
- A 0° or 30° endoscope
- Two 5-mm trocars
- A 10-mm trocar
- A 5-mm fenestrated grasping forceps
- A 5-mm grasping forceps
- A pair of dissecting and coagulating scissors
- A 5-mm stapler (ProTak, Tyco HealthCare or EndoAnchor, Ethicon)
- A 5-mm needle holder
- A curved 10-mm dissector
- A vaginal retractor
- Heggar bougies
- Polyester or polypropylene mesh cut into two 3×20-cm strips
- Harmonic scalpel (useful but not mandatory)

## 11.3 Position of Trocars

The pneumoperitoneum is created with a Veress needle. A pressure of 14 mmHg is achieved at a flow rate of 6 l/min. The first trocar is inserted in the left para-umbilical region, 5 cm left of the umbilicus. The endoscope is inserted through this trocar. A 5-mm trocar is placed medial to the left antero-superior iliac spine for the left-hand grasping forceps. Another 5-mm trocar is placed at the inferior margin of the umbilicus in order to receive the right-hand operating instruments. A final 5-mm trocar is inserted suprapubic. If needed, a fifth trocar can be placed in the right iliac fossa for better exposure (➤ Fig. 11.1). The lateral position of the endoscope provides improved operating comfort but also requires permanent control of any median axial deviation.



## 11.4 Exposure of the Rectosigmoid Junction

The peritoneal cavity is explored after the OR table has been placed in the 25° Trendelenburg position. The small bowel is pushed back into the superior part of the abdominal cavity. In women, it helps to suspend the uterus anteriorly with a transfixing suture through the abdominal wall. The depth of the Douglas pouch is then assessed. There is always some degree of peritoneal thickness around the rectum.

The suprapubic grasping forceps, handled by the second assistant, mobilizes the sigmoid loop, then the superior part of the rectum. Rectal dissection is begun by opening the right pararectal posterior parietal peritoneum in contact with the mesorectum and the rectum. This pararectal peritoneal opening is continued from right to left (► Figs. 11.2, 11.3). In women, a vaginal retractor in the posterior vaginal cul-de-sac shows the rectovaginal junction more easily and facilitates complete excision of excess peritoneum (Douglassectomy) with the coagulating scissors or harmonic scalpel.

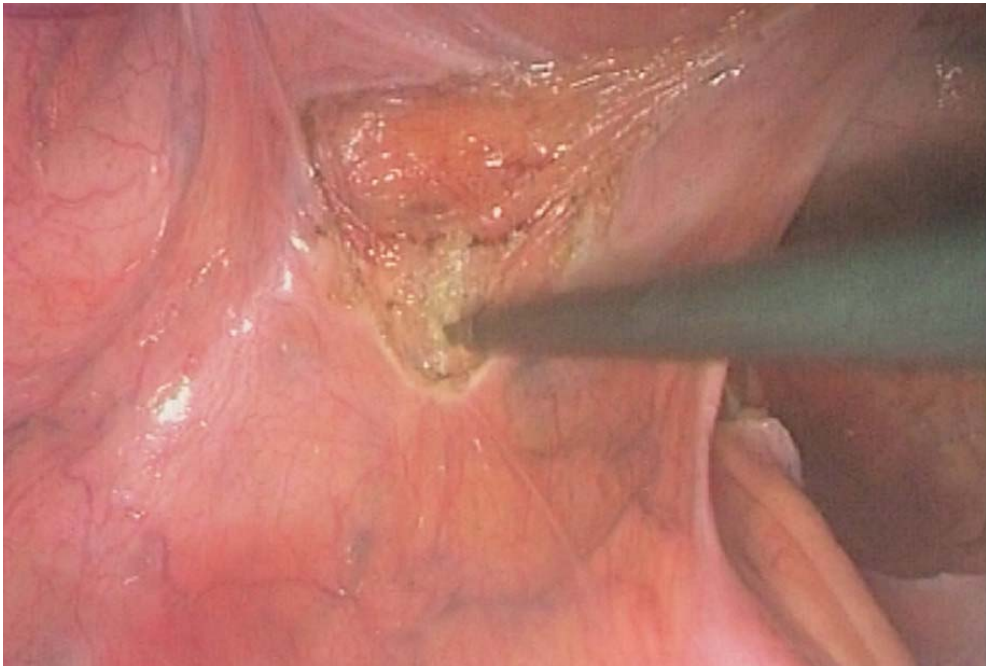


Fig. 11.2. Peritoneal excision

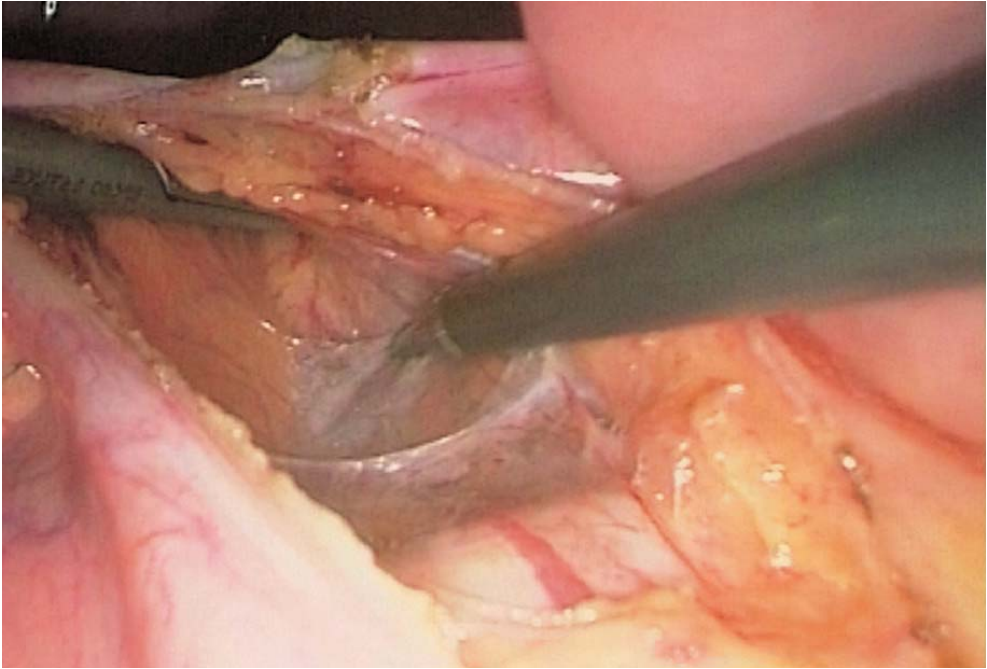


Fig. 11.3. Exposure of sacral ligament

### 11.5 Rectal Dissection

Posterior dissection continues with coagulating shears on the right in front of the sacral promontorium (● Fig. 11.4) and goes down to the Douglas pouch after identifying both ureters, from right to left. The suprapubic grasping forceps pushes and pulls the rectosigmoid to the patient's left. In this way, it is possible with a soft forceps or a soft-tipped fenestrated forceps to perform pre-sacral dissection by quickly mobilizing the posterior mesorectum as far as the levators. The intraperitoneal pressure helps at this stage.

Anteriorly, dissection of the rectovaginal or rectoprostate spaces is performed cautiously with the coagulating scissors in contact with the anterior wall of the rectum (◉ Fig. 11.5). A Heggar bougie may be used to better demonstrate the anterior wall of the rectum. The lateral ligaments are respected but not their superior fibrous elements, which are coagulated. Like Speakman et al. (1991) at St. Mark's Hospital, we find it useful to leave the lateral ligaments of the rectum in order to prevent constipation after rectopexy.

In males, it is essential to respect the hypogastric nerve plexus. The CO<sub>2</sub> pressure helps in locating the correct plane of the dissection of the presacral space. Digital control of the distal dissection of the rectum is then performed (5–6 cm from the anal verge).

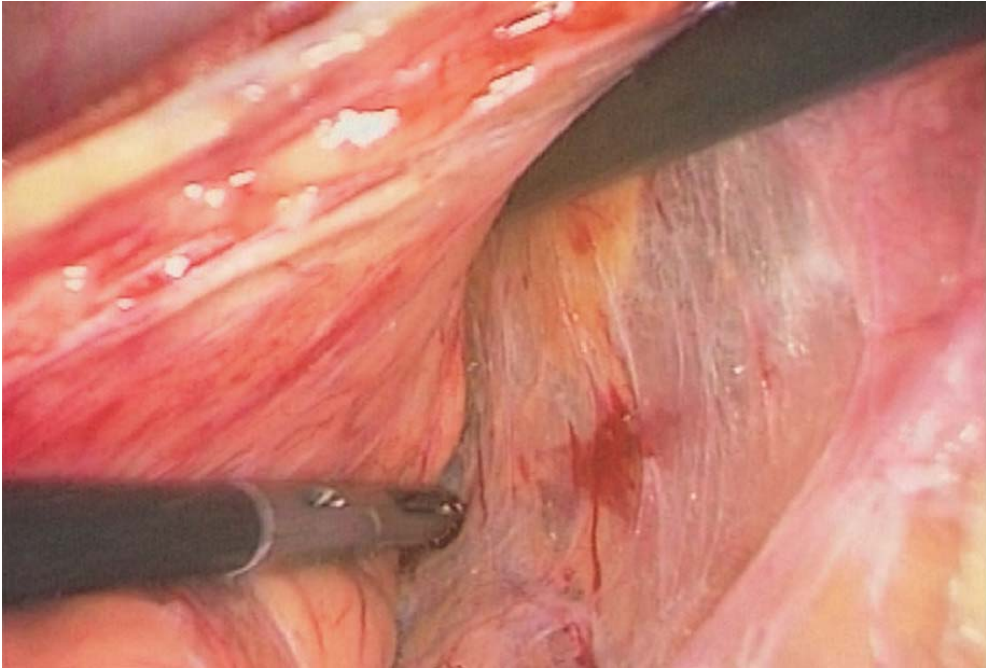


Fig. 11.4. Sacral dissection

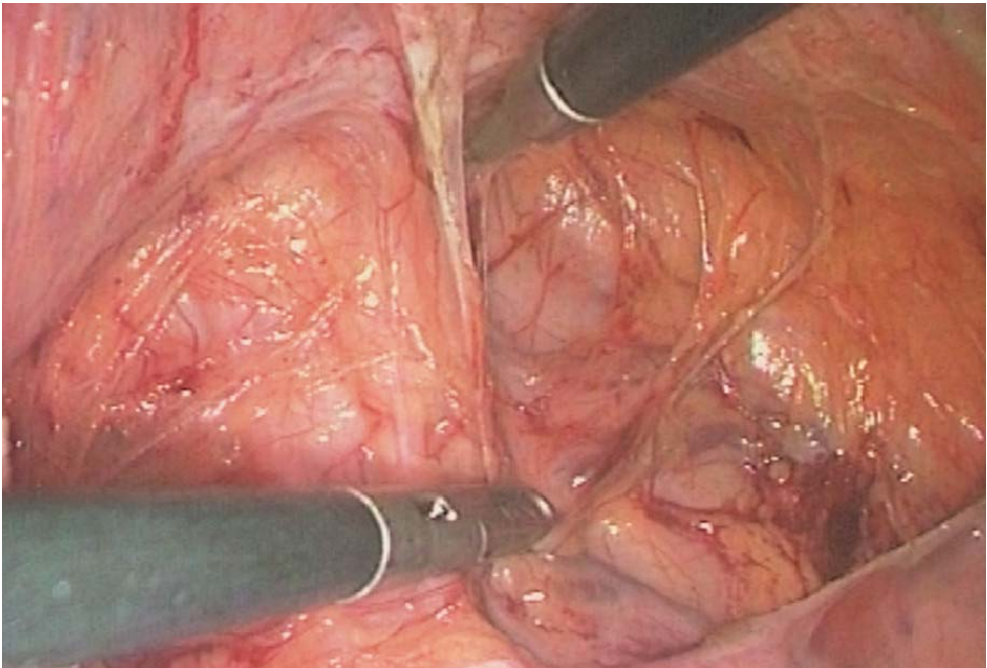


Fig. 11.5. Rectal dissection

### 11.6 Orr Loygue Procedure: Rectal Fixation of the Meshes

Two polyester, polypropylene or pTFE 3×20-cm meshes are inserted through the umbilical trocar. They are sutured to the right and left antero-lateral faces of the rectum (◉ Fig. 11.6) with nonabsorbable 2/0 stitches. Four to six stitches are placed on the rectum for each mesh. Stitches need to enter deep in the muscular layers of the rectum and knotting is done intracorporeally (◉ Figs. 11.7, 11.8).

### 11.7 Orr Loygue Procedure: Mesh Placement

In the classical French open technique described by Loygue and Cerbonnet in 1957, both meshes were placed on either side of the rectosigmoid colon and were then sutured to the promontorium. This can also be performed laparoscopically. The left mesh must be passed under the mesorectum with the umbilical grasping forceps, and the rectosigmoid colon is then placed on the left with the suprapubic grasping forceps. We noted, however, that the rectosigmoid colon may undergo stricture from the two meshes and this may lead to postoperative constipation in some patients.

Since 1983, we developed an original technique of placing the two meshes first in open, then in laparoscopic, surgery. The right mesh sutured to the right antero-

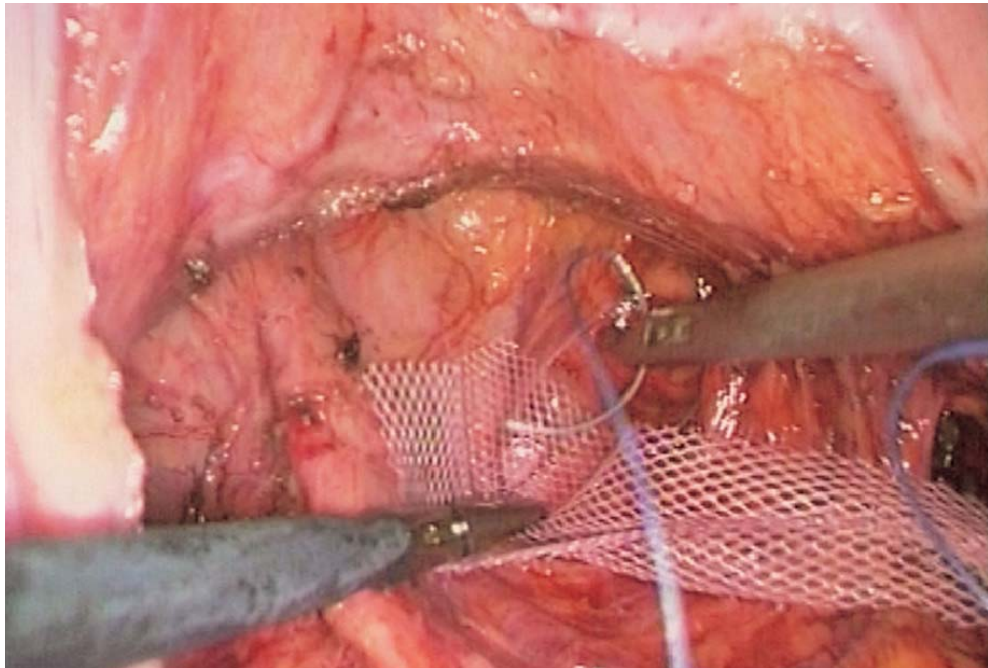
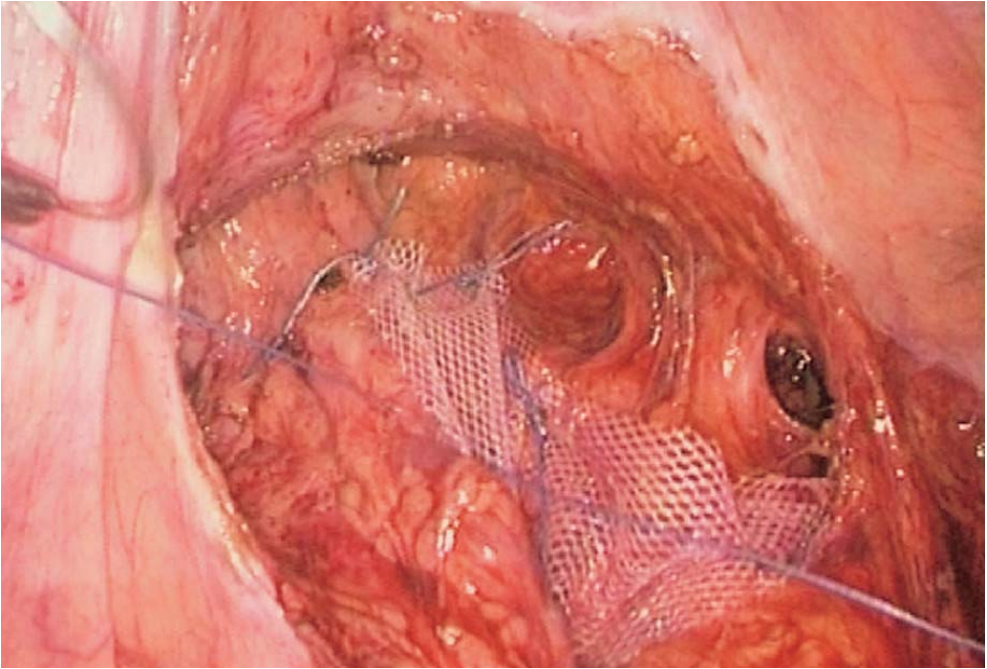
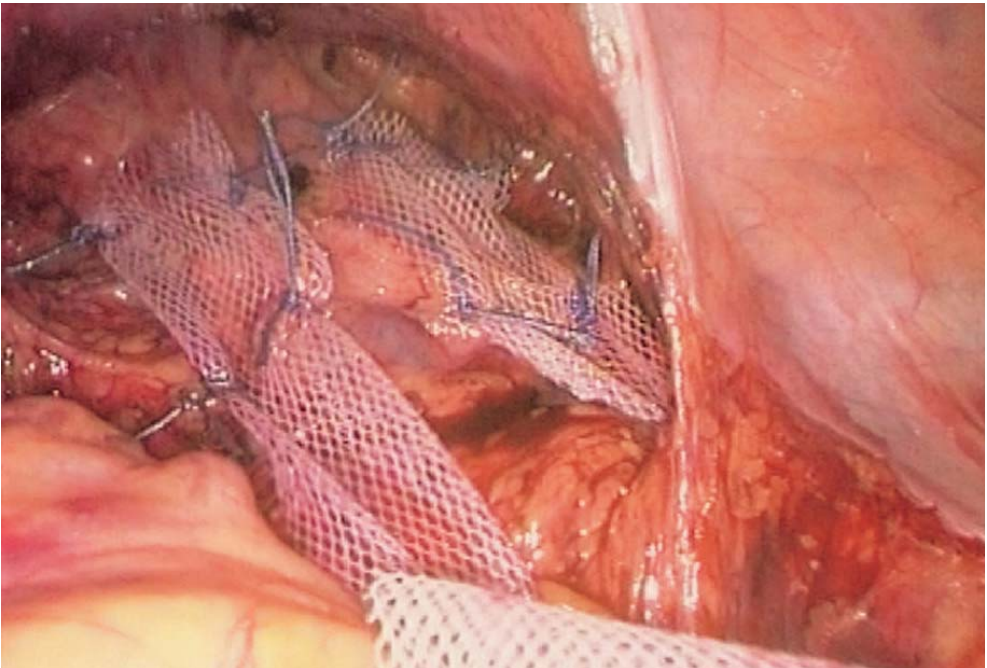


Fig. 11.6. Orr-Loygue: suturing right mesh





**Fig. 11.7. Orr-Loygue: right mesh suturing completed**



**Fig. 11.8. Orr-Loygue: final mesh placement**

lateral face of the rectum is placed behind the right lateral ligament of the rectum and passes through the lower mesorectum, and is then stapled to the promontorium (► Figs. 11.9, 11.10). This manoeuvre is performed with the angulated 10-mm dissector inserted through the umbilical trocar. An opening is made through the lower mesorectum with the dissector introduced behind the lateral ligament before grasping the right mesh. The left mesh sutured to the left antero-lateral face of the rectum passes anterior to the rectosigmoid colon and is stapled to the left part of the promontorium. The rectum usually undergoes a slight 20° right rotation. There is no stricture and the posterior or left lateral movement of the superior part of the rectum is controlled.

### 11.8 Orr Loygue Procedure: Fixing the Mesh to the Promontorium

The vertebral ligament on the promontorium is located. Only limited opening of the peritoneum is needed. The right ureter is identified and the peritoneum is opened with coagulating shears. The small vessels on the promontorium are identified. The two meshes are stapled to the promontorium and their tension is adjusted. The fixation to the promontorium can be secured with one or two extra sutures with intracorporeal knotting. The tension must be just enough to ensure good support. Any excess mesh is resected (► Figs. 11.11, 11.12).

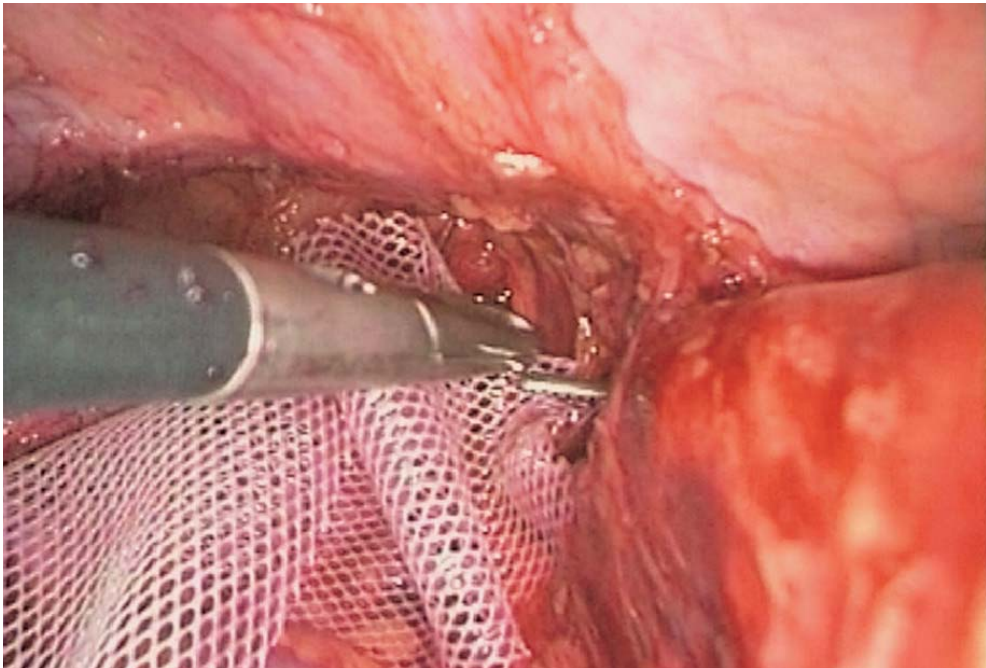


Fig. 11.9. Orr-Loygue: tunnelling of right mesh

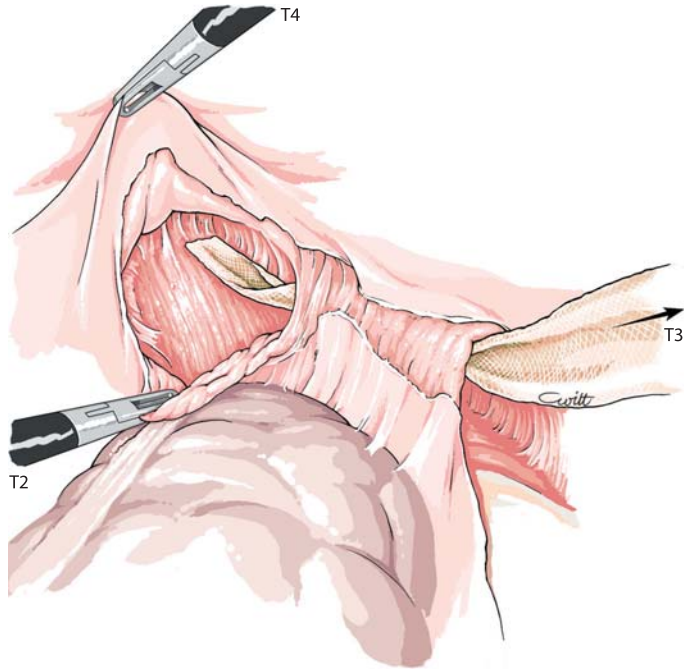


Fig. 11.10. Orr-Loygue: the right mesh is tunneled behind the lateral ligament

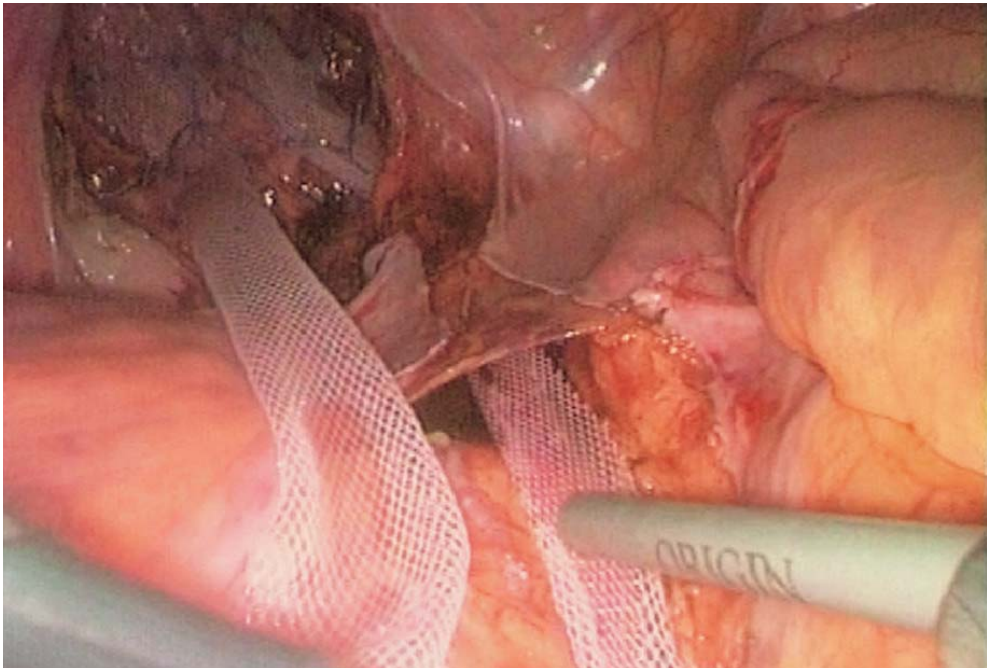


Fig. 11.11. Orr-Loygue: stapling the mesh to the vertebral ligament



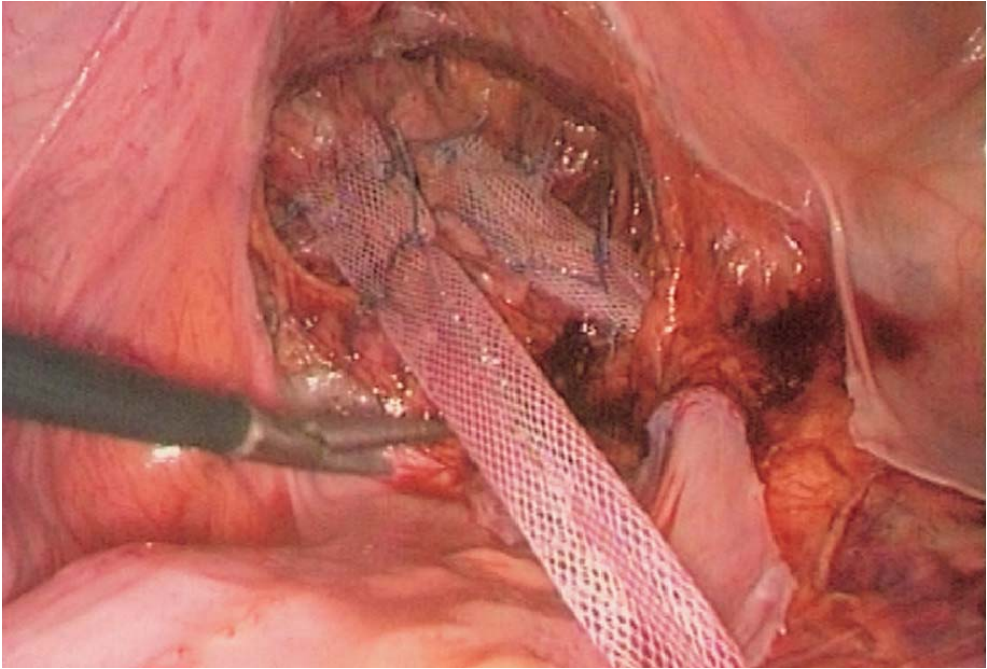


Fig. 11.12. Orr-Loygue: final result

### 11.9 Laparoscopic Wells Procedure

Rectal dissection is identical to that in the previous technique, but the superior parts of the lateral ligaments of the rectum are transected. The difference is in the shape of the mesh and the way it is sutured to the rectum and stapled to the sacrum.

After the rectum is fully dissected, a 7×7-cm mesh (polyvinyl, polypropylene, polyester or PTFE) is stapled to the sacral concavity and the promontorium by an extra portion 4 cm long and 2 cm wide. Fixation is performed with helical staples like Taks or with nonabsorbable running sutures. (◉ Fig. 11.13). Four to six median sutures are needed for good fixation of the extra part of the mesh on to the promontorium. The stapling instrument is being introduced through the suprapubic port.

The mesh is wrapped laterally around the extra peritoneal rectum without tension (◉ Figs. 11.14–11.16). The edges of the mesh are sutured to the antero-lateral faces of the rectum by interrupted or running 2/0 nonabsorbable sutures.



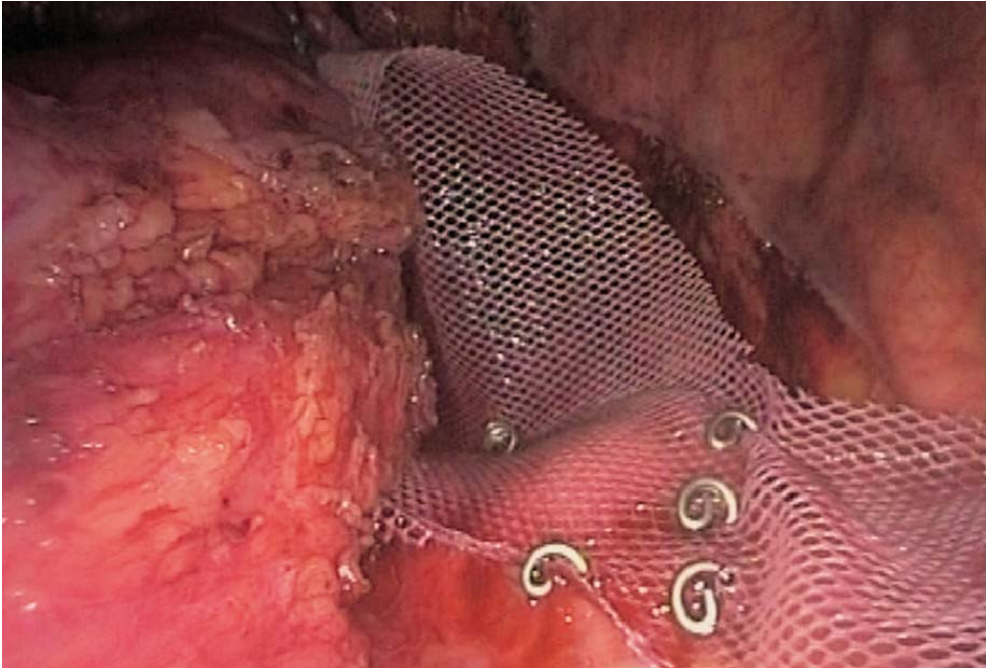


Fig. 11.13. Wells: sacral stapling

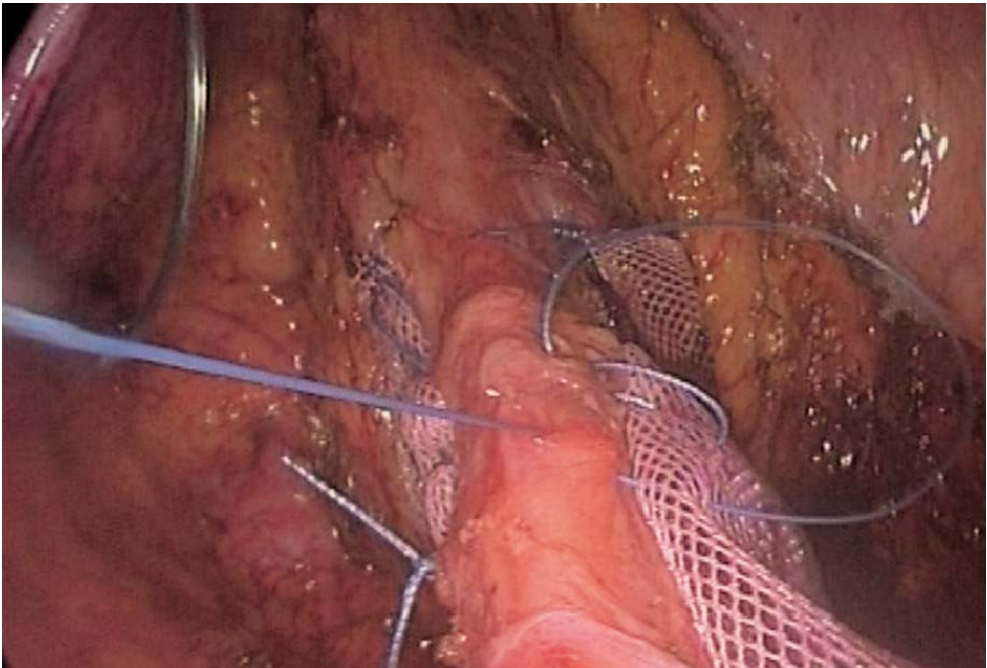


Fig. 11.14. Wells: mesh wrapped and sutured to the rectum

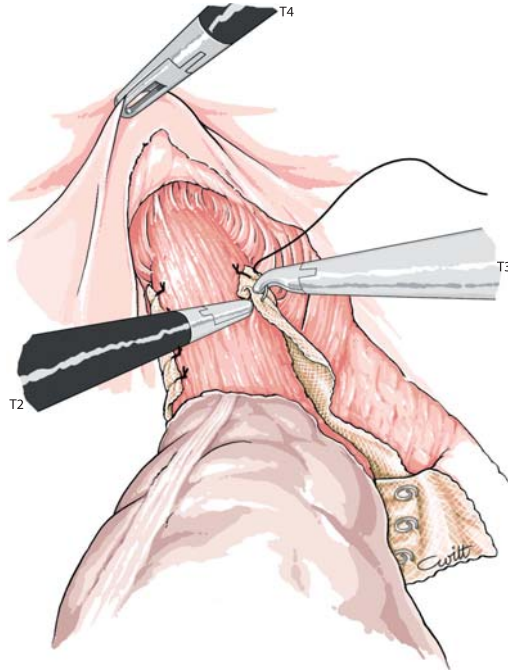


Fig. 11.15. Wells: suturing mesh to the right side of the rectum

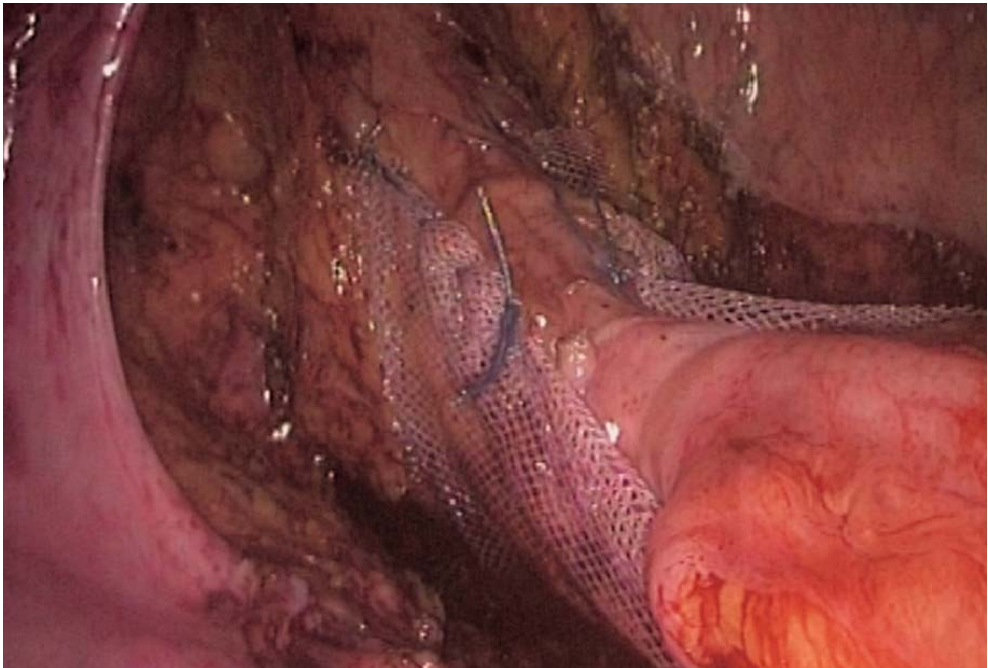

Fig. 11.16. Wells: final result

## 11.10 Douglassectomy and Peritonization

Closure of the peritoneum is performed with continuous 2/0 absorbable sutures. Excess peritoneal tissue of the Douglas pouch is resected or plicated after locating ureters and nerve plexus (➤ Figs. 11.17–11.19).

## 11.11 Tips and Comments

- Douglassectomy can be performed at the start with the coagulating shears or harmonic scalpel.
- For the modified Wells procedure, the upper part of the lateral ligaments must be transected in order to properly place the mesh and to have satisfactory peritonization in the end.
- Running sutures can be used to fix the mesh to the rectum.
- An articulated instrument is required for the trans-ligament passage of the mesh.
- Stapling of the mesh to the promontorium is mostly performed with helical Taks.

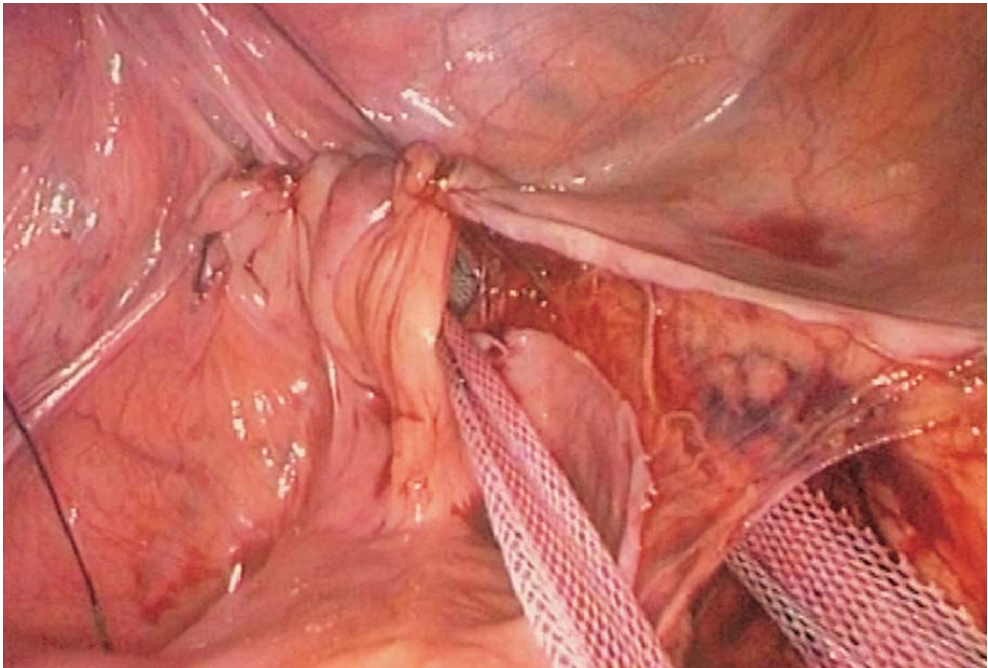


Fig. 11.17. Orr-Loygue: peritoneal closure



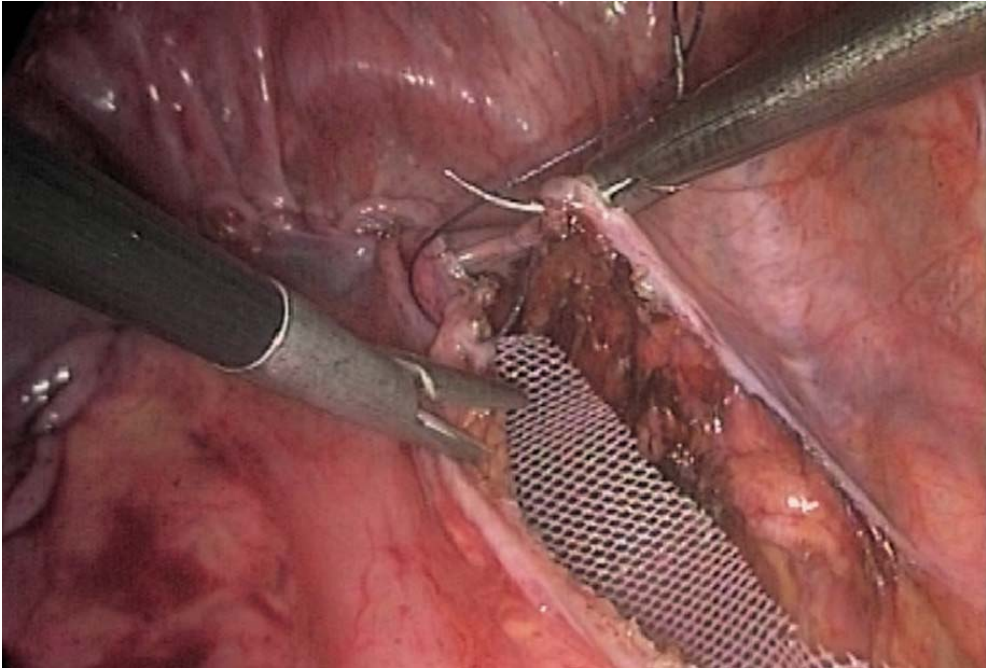


Fig. 11.18. Wells: peritoneal closure

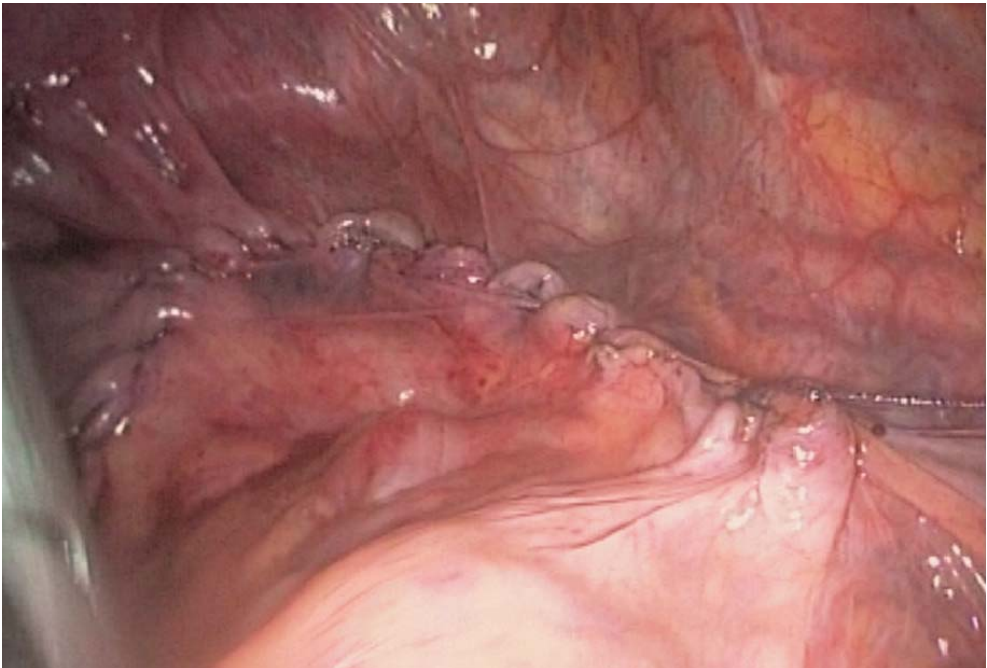


Fig. 11.19. Final result after peritoneal closure



- We prefer polyester meshes which are easily handled laparoscopically and are non-traumatic for the rectal wall.
- Lateral mesh fixation to the rectum is limited by the lateral ligaments.
- Fixation is usually antero-lateral.
- Exceptionally in women, a genital prolapse may be concurrent with complete rectal prolapse. Dual fixation will control hysterocele associated with either cystocele or rectocele.

## Literature

- Cuschieri A, Shimi SM, Vandervelpen G, Banting S, Wood AB (1994) Laparoscopic prosthesis fixation rectopexy for complete rectal prolapse. *Brit J Surg* 81:138–139
- Delorme R (1900) Sur le traitement des prolapsus du rectum totaux par l'excision de la muqueuse rectale et recto colique. *Bulletin Mémoires Soc Chirurgie, Paris* 26:498–499
- Dulucq JL (1993) Prolapsus rectal, rectopexie par laparoscopie, Technique de Orr Loygue modifiée. *Journal de coelio chirurgie*, 6
- Dulucq JL, Wintringer P (1997) XIX journées niçoises pathologie et chirurgie digestives, Actualités Médico Chirurgicales, Ed. Masson
- Lechaux JP, Lechaux D, Perez M (1995) Results of Delorme's procedure for rectal prolapse. Advantages of a modified technique. *Dis Colon Rectum* 38:301–307
- Loygue J, Carbonnet G (1957) Traitement chirurgical du prolapsus total du rectum par la rectopexie selon le procédé d'Orr. *Mem Ac Chir* 83:325–329
- Loygue J, Nordlinger B, Cunci O, Malafosse M, Huguet C, Parc R (1984) Rectopexy to the promontory for the treatment of rectal prolapse. Report of 257 cases. *Dis Colon Rectum* 27:356–359
- Oliver GC, Vachon D, Eisensat TE, Rubin RJ, Salvati EP (1994) Delorme's procedure for complete rectal prolapse in severely debilitated patients. *Dis Colon Rectum* 37:461–467
- Ratelle R, Volland S, Peloquin AB, Gravel, D (1994) La rectopexie au promontoire (OrrLoygue) dans le prolapsus rectal: approche coelioscopique ou chirurgie conventionnelle. *Ann Chir* 48:679–684
- Ripstein CB (1952) Treatment of massive rectal prolapse. *Am J Surg* 83:68–71
- Senapati A, Nicholls RJ, Thomson JPS, Philipps RKS (1994) Results of Delorme's procedure for rectal prolapse. *Dis Colon Rectum* 37:456–460
- Speakman CTM, Madden MS, Nicholls RJ, Kamm MA (1991) Lateral ligament division during rectopexy causes constipation but prevents recurrence: results of a prospective randomised study. *Brit J Surg* 78:1431–1433
- Wedell J, ZuEissen PM, Fiedler R (1980) A new concept for the management of rectal prolapse. *Am J Surg* 139:723–725
- Wells C (1959) New operation for prolapse of rectum. *Proc R Soc Med* 52:602–603
- Williams JG, Wong WD, Jensen L, Rothenberger DA, Goldberg S (1991) Incontinence and rectal prolapse. A prospective manometry study. *Dis Colon Rectum* 34:209–216

**PART 3**

**Inguinal Hernia and Retroperitoneal  
Procedures**

- 12**    **Totally Extraperitoneal Approach (TEPA)  
for Laparoscopic Hernia Repair**    **171**
- 13**    **Laparoscopic Right Adrenalectomy**    **189**
- 14**    **Laparoscopic Left Adrenalectomy**    **203**

---

## 12 Totally Extraperitoneal Approach (TEPA) for Laparoscopic Hernia Repair

### 12.1 Operating Room Setup: Position of the Patient

The patient is placed supine in a 10° Trendelenburg position. A bladder catheter is needed unless the patient has emptied his bladder before the operation. The surgeon stands opposite the hernia to be cured. The assistant is on the surgeon's left or right according to the side (▶ Fig. 12.1).

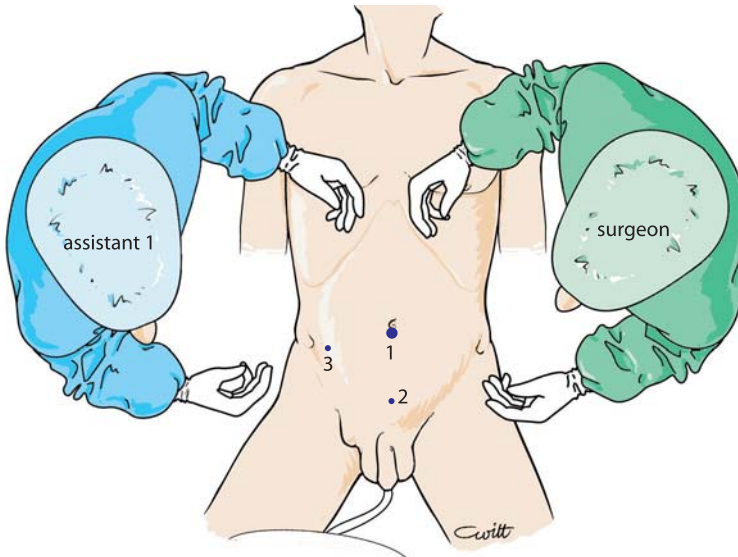


Fig. 12.1. OR setup – position of trocars

## 12.2 Recommended Instruments

- A 10-mm trocar for the endoscope
- A 0° or 30° endoscope
- Two 5-mm trocars (3-mm trocars and instruments possible)
- Two 5-mm fenestrated grasping forceps
- A 5-mm strong grasping forceps
- A pair of dissecting and coagulating shears
- Optionally, a stapler or Takker
- A 5-mm endoscopic needle holder
- A powerful Xenon light fountain
- An electronic inflator
- An endoscopic camera system
- An anatomically pre-shaped 14×10-cm or 16×12-cm polypropylene mesh
- A suction cannula

## 12.3 Position of Trocars and Exposure

Creating the pneumoperitoneum is done before inserting the first trocar. The Veress needle is inserted on the midline, straight through the aponeurosis into Retzius' space, 1 cm above the pubic bone. One litre of CO<sup>2</sup> is inflated at a pressure of 15 mmHg. This prior creation of a preperitoneal space allows subsequent easy insertion of the first trocar without any risk of peritoneal or bladder perforation.

The first trocar is introduced at the inferior margin of the umbilicus (◉ Fig. 12.2). A 4-cm subcutaneous route is followed before entering obliquely through the aponeurosis into the preperitoneal space previously created by the Veress needle. At this stage, CO<sub>2</sub> pressure is lowered to a maximum of 12 mmHg.

In easy cases a single second 5- or 3-mm trocar is introduced on the midline approximately three finger widths above the pubic bone. When needed, a third 5-mm trocar is placed medial to the antero-superior iliac spine on the side of the hernia for dissection.

The endoscope goes into the 10-mm trocar at the umbilicus, and the grasping forceps for blunt dissection into the 5-mm ports.

The endoscope in the preperitoneal space can easily identify the pubic bone and Cooper's ligament on both sides (◉ Fig. 12.3), which are the first landmarks in the extraperitoneal dissection of Retzius' space. The second landmarks are the epigastric vessels in the superior part of the field of dissection. The anatomical type of hernia, direct, indirect or femoral is defined by the position of the hernia sac to the epigastric vessels (◉ Fig. 12.4).



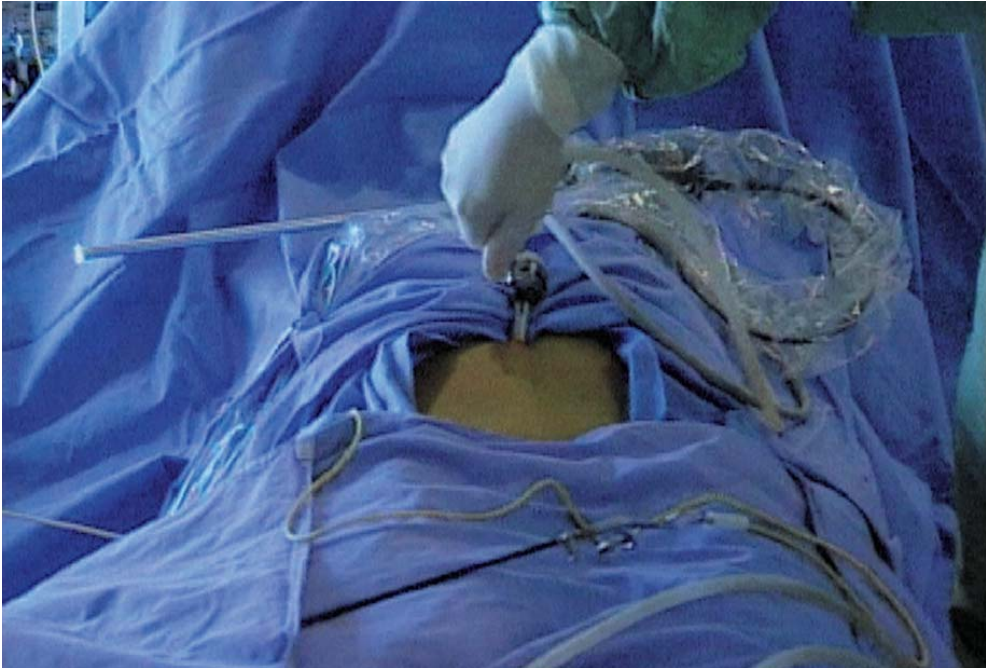

Fig. 12.2. Insertion of first trocar

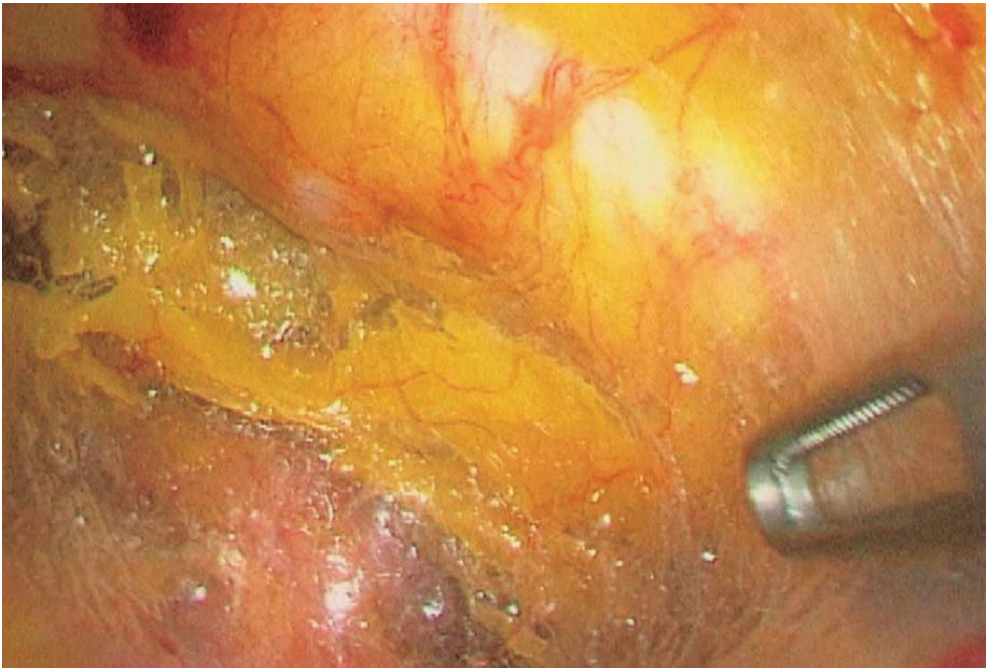

Fig. 12.3. Exposure of Cooper's ligament

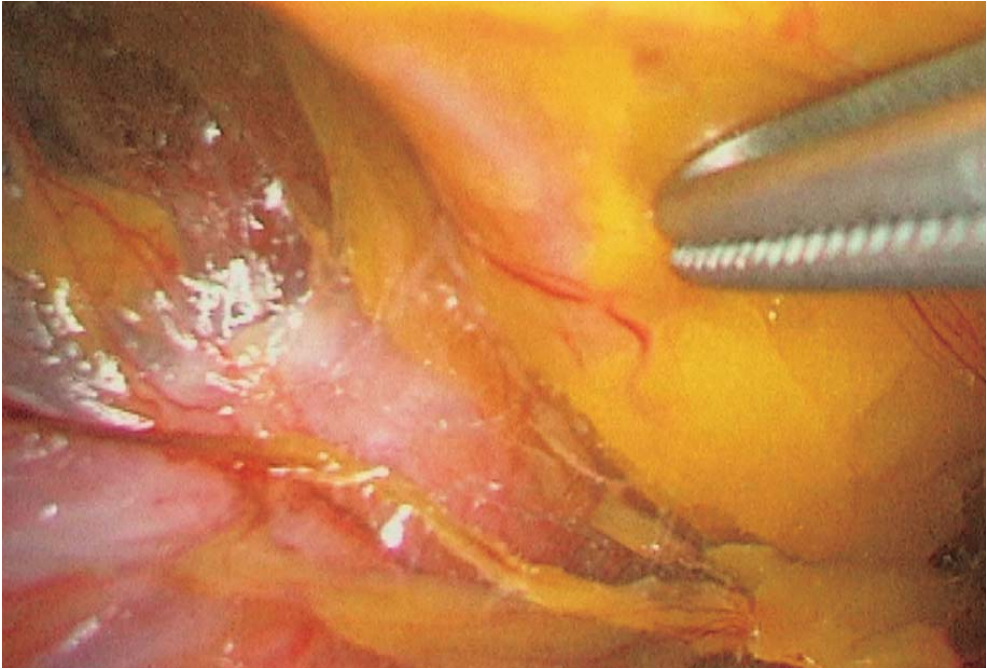


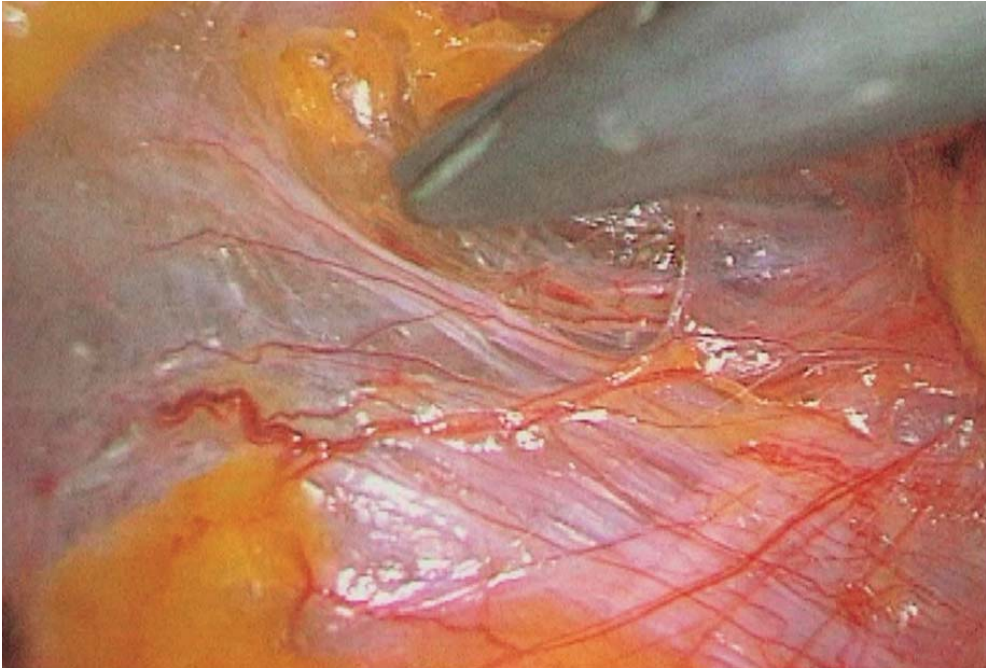
Fig. 12.4. Exposure of epigastric vessels

#### 12.4 Dissection of the Peritoneum

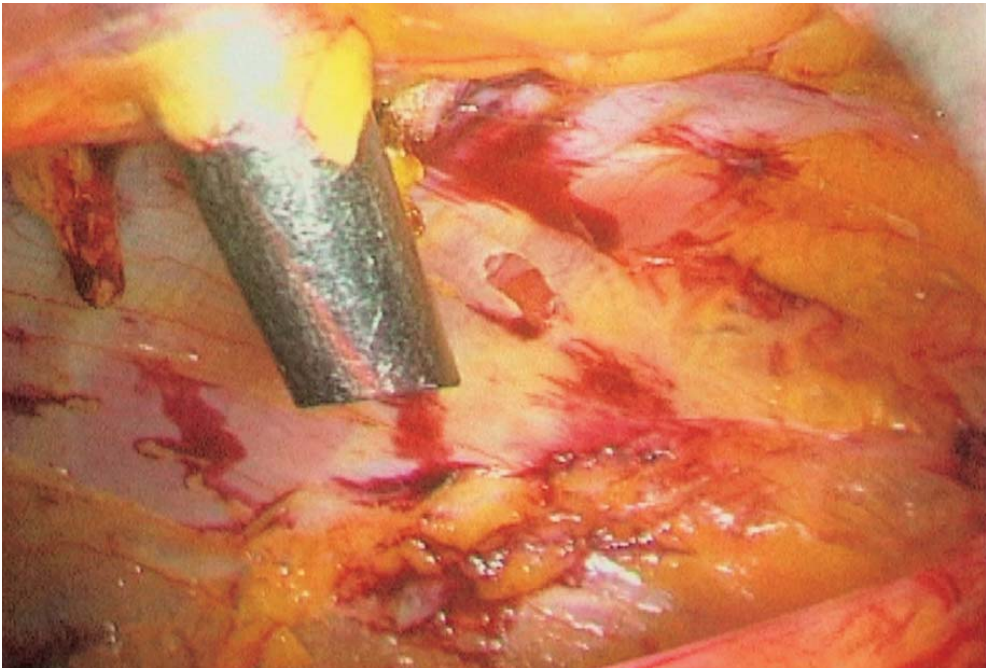
Leaving the epigastric vessels on the abdominal wall reveals the superior edge of the hernia sac. The dissector placed in the suprapubic trocar gradually dissects free the superior part of the peritoneal sac from the extraperitoneal space (◉ Fig. 12.5). Laterally, peritoneal attachments are loose, and dissection is performed easily and quickly. The hernia sac becomes pediculated. If necessary, a third 5-mm trocar for a second dissecting instrument is inserted at the level of the iliac fossa (◉ Fig. 12.6).

Lateral dissection is continued by superior dissection behind the muscle wall and inferior dissection on the psoas muscle. These two lateral extraperitoneal spaces are separated by a fascia which has to be transected with the coagulating scissors (◉ Fig. 12.7). The hernia sac is thus fully pediculated.





**Fig. 12.5. Dissection of the upper edge of the peritoneal sac**



**Fig. 12.6. Introduction of third trocar**

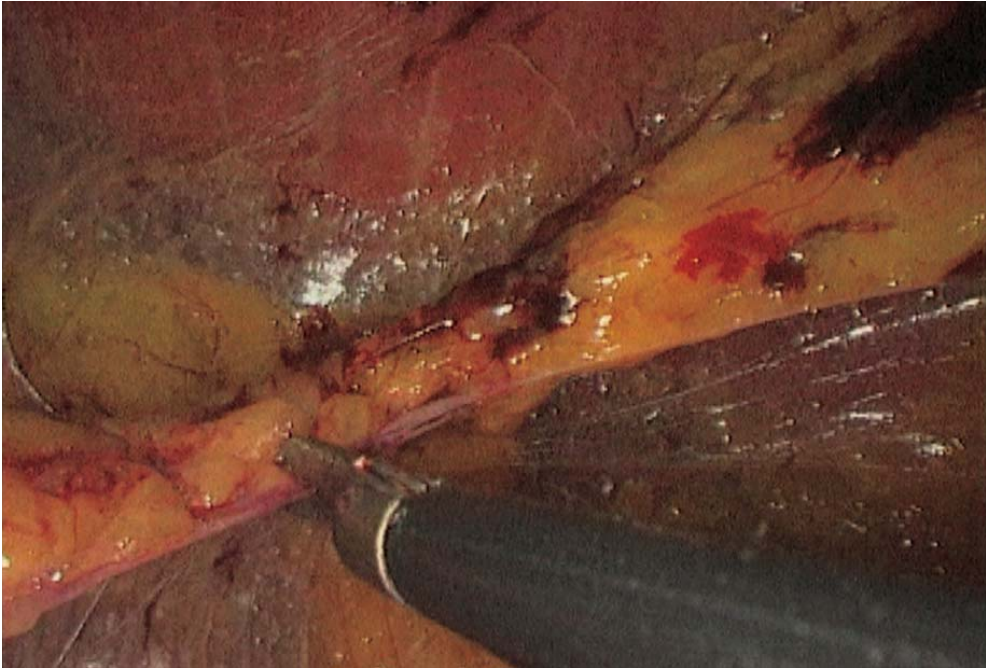


Fig. 12.7. Dissection of the left lateral fascia

### 12.5 Dissection of the Hernia Sac

A direct hernia is easily reduced by simple traction. An indirect oblique hernia requires the use of coagulating shears and a fenestrated dissecting forceps. The hernia sac is gradually dissected and freed from the internal inguinal ring. Dissection continues by gentle traction (▶ Figs. 12.8–12.10) on the cord elements in order to identify the spermatic vessels and the vas deferens. The remaining peritoneal attachments are then transected with the coagulating shears. The sac in femoral hernias is reduced by gentle traction with a fenestrated forceps.

### 12.6 Skeletonization of Spermatic Cord

The peritoneal sac is gradually freed from the spermatic cord, vas deferens and spermatic vessels (▶ Fig. 12.11). Lipomas are to be removed. The peritoneum is pushed back as far as possible into the abdominal cavity. The anterior part of the psoas muscle, as well as the crossing of the iliac vein by the vas deferens must be fully exposed (▶ Fig. 12.12).



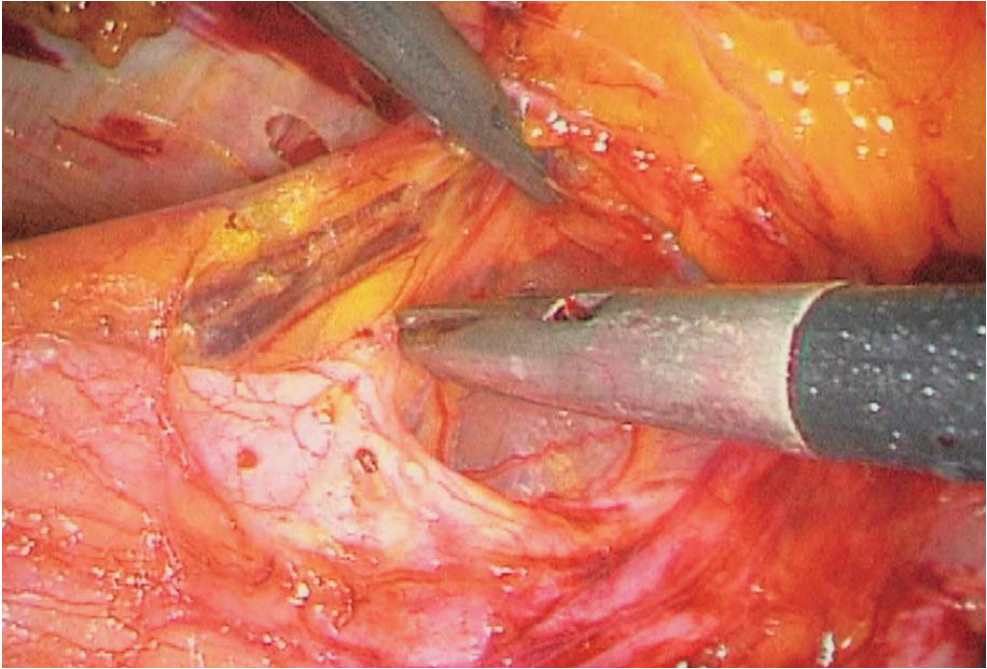


Fig. 12.8. Dissection of the upper part of the hernia sac

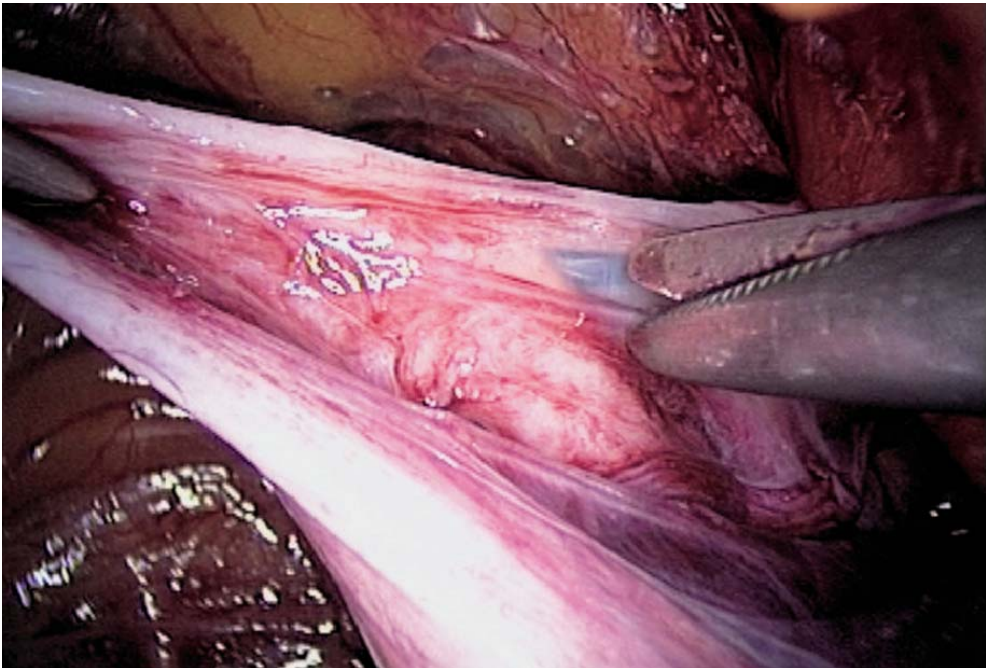


Fig. 12.9. Dissection of the hernia sac

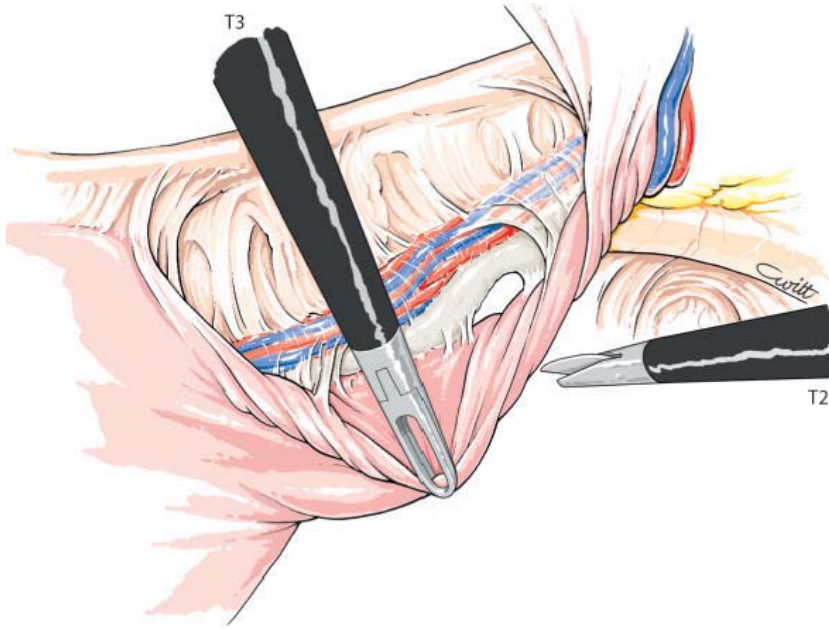


Fig. 12.10. Dissection of hernia sac

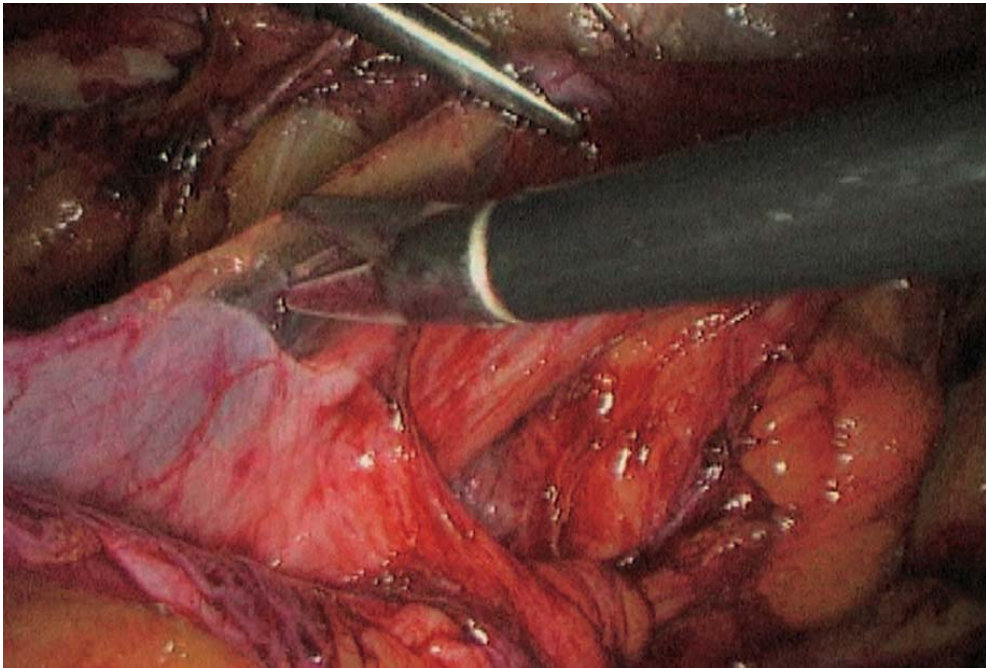


Fig. 12.11. Pulling back the peritoneum

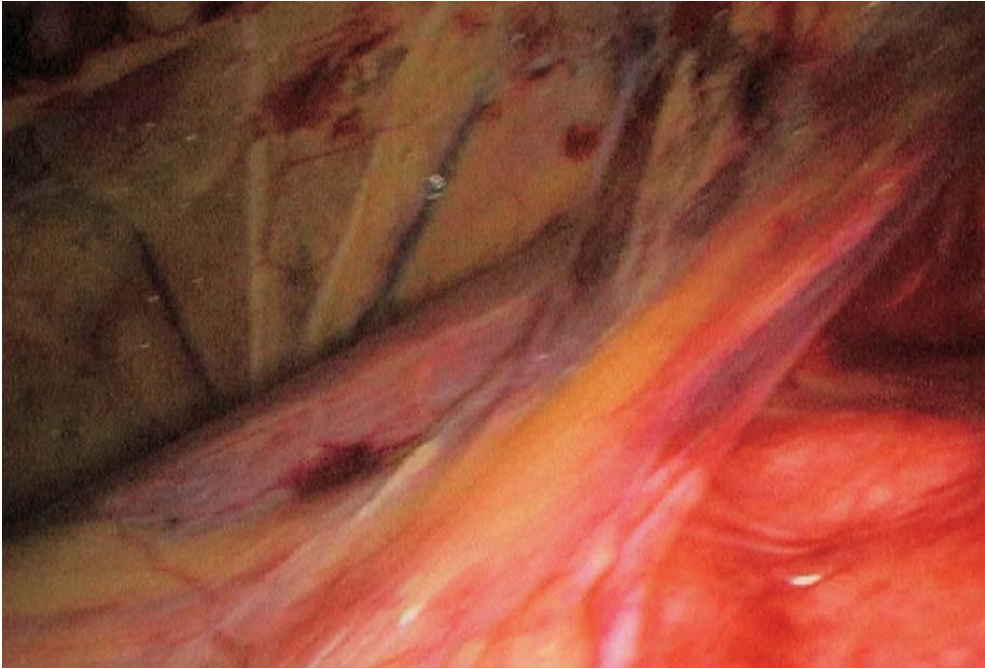


Fig. 12.12. Finished lateral dissection with psoas muscle and nerves

## 12.7 Full Exposure of the Inguinal Region

The final anatomical details of the region are dissected. Cooper's ligament is fully exposed and the iliac vessels are identified. The obturator ring is freed of its usual lipoma content. Dissection continues superiorly by sectioning the Douglas arch. The anatomical type of hernia can be assessed, either indirect (➤ Fig. 12.13) or direct (➤ Fig. 12.14).

## 12.8 Mesh Insertion

The 3-D mesh is rolled and introduced through the 10-mm trocar. It is placed across the inguinal ring and fits the anatomy of the inguinal region (➤ Figs. 12.15–12.18). Its inferior and lateral edge is placed on the anterior aspect of the psoas muscle (➤ Fig. 12.19) and the inferior and internal edge is placed under Cooper's ligament (➤ Fig. 12.20). The inferior edge of the mesh covers the iliac vessels and the spermatic cord which were skeletonized previously. The mesh is then applied against the internal inguinal ring and (➤ Fig. 12.21) its superior edge follows the contours of the abdominal wall during release of the pneumoperitoneum (➤ Fig. 12.22). Desufflation must be performed with care, under permanent visual control of the correct position of the mesh (➤ Fig. 12.23). Port wounds are closed by intradermal everting sutures.



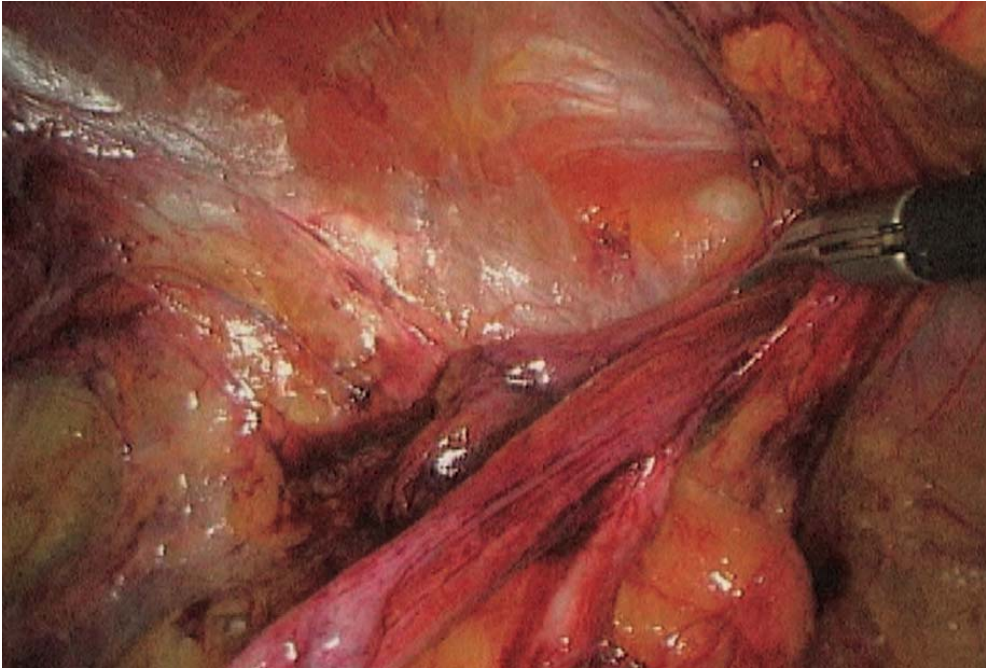


Fig. 12.13. Enlarged internal inguinal ring

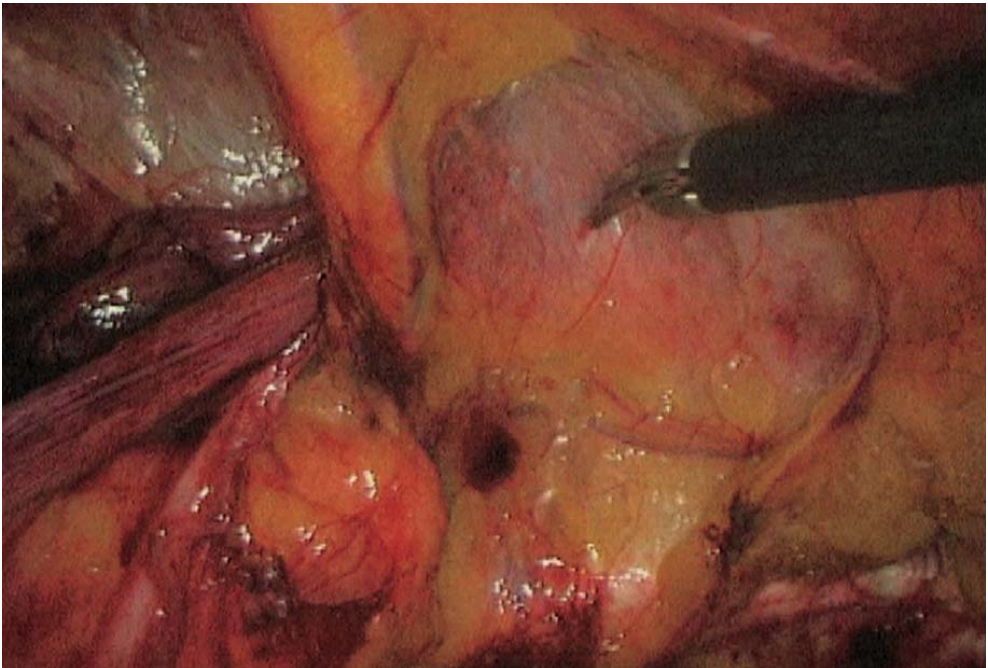


Fig. 12.14. Direct weakness



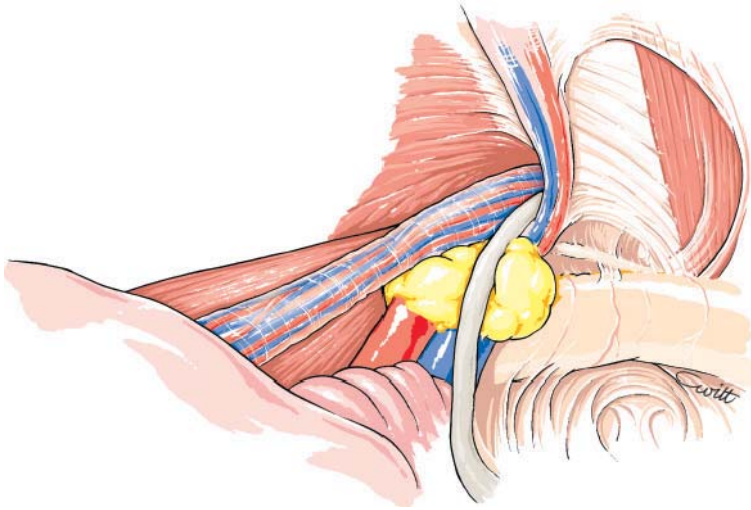


Fig. 12.15. Dissection completed

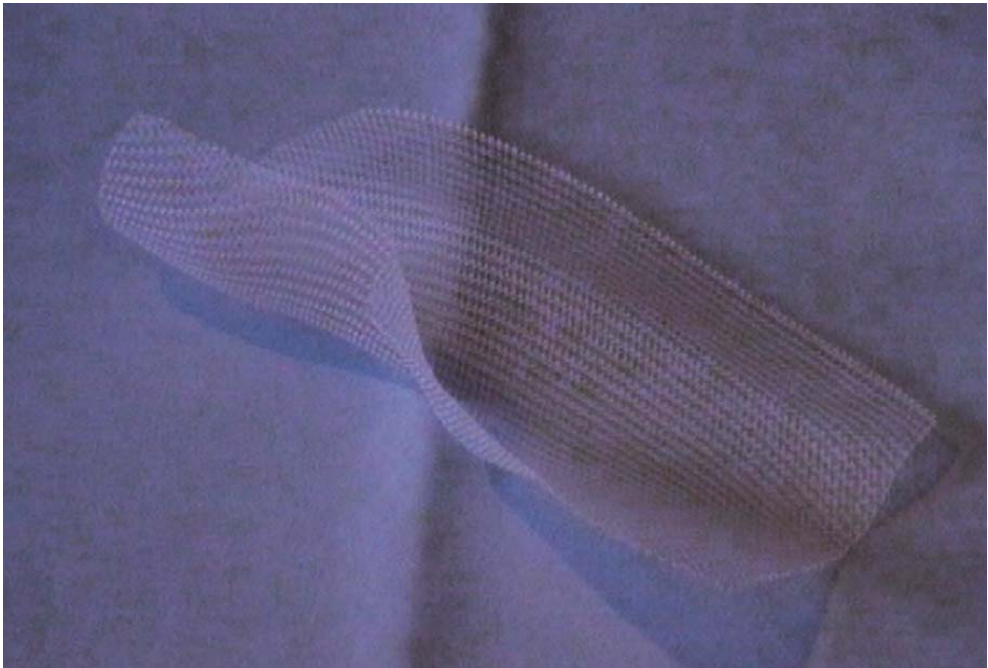


Fig. 12.16. 3-D mesh




Fig. 12.17. 3-D mesh rolled up

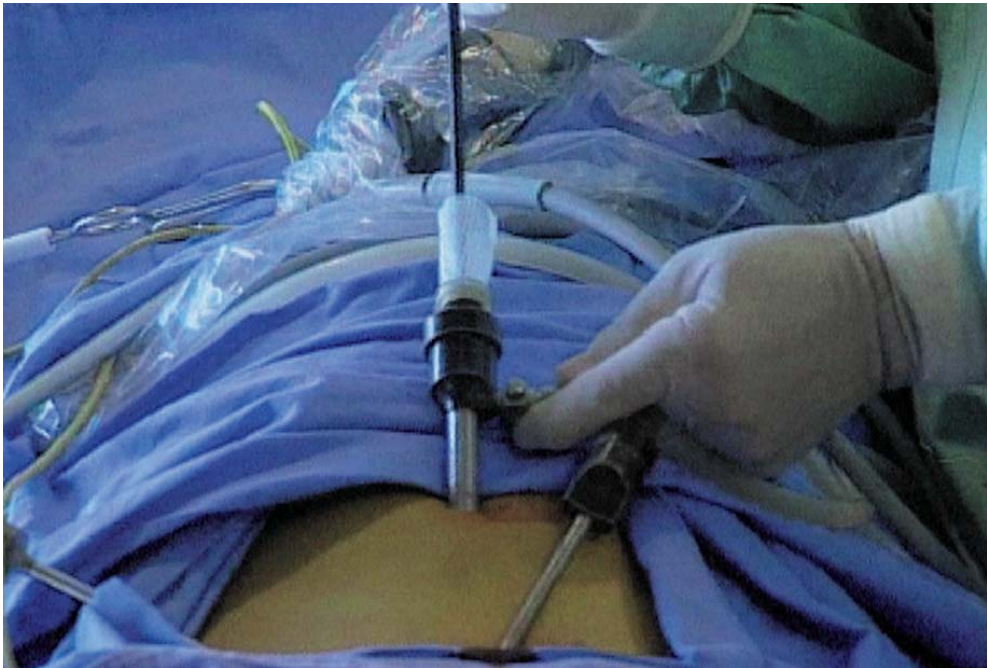

Fig. 12.18. Insertion of the 3-D mesh through umbilical port



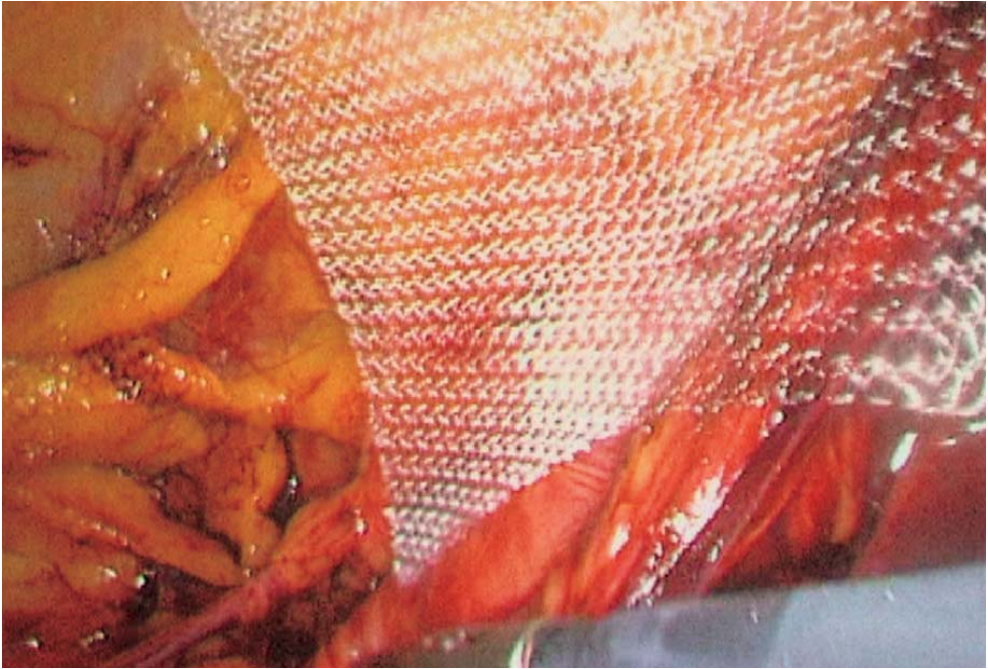


Fig. 12.19. Positioning the 3-D mesh on the psoas muscle

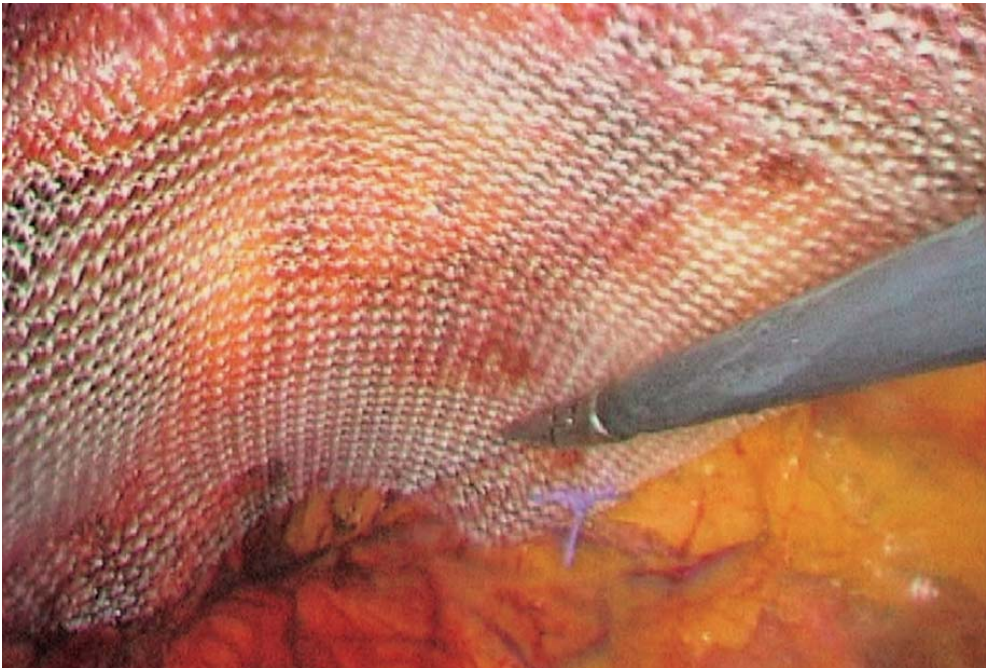


Fig. 12.20. Inferior part of 3-D mesh below Cooper's ligament

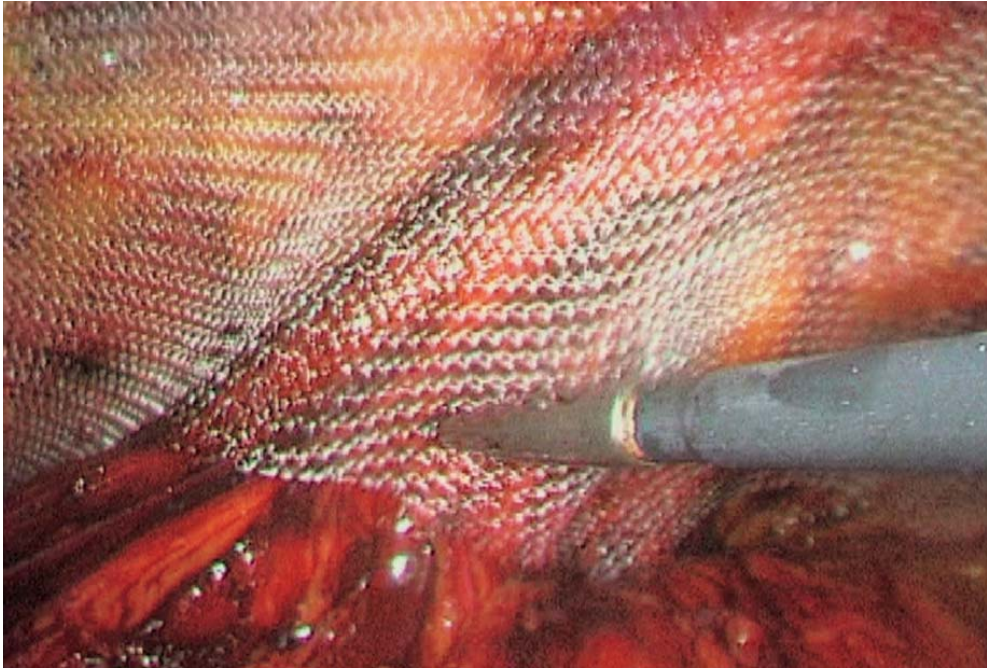


Fig. 12.21. Medial positioning of the 3-D mesh

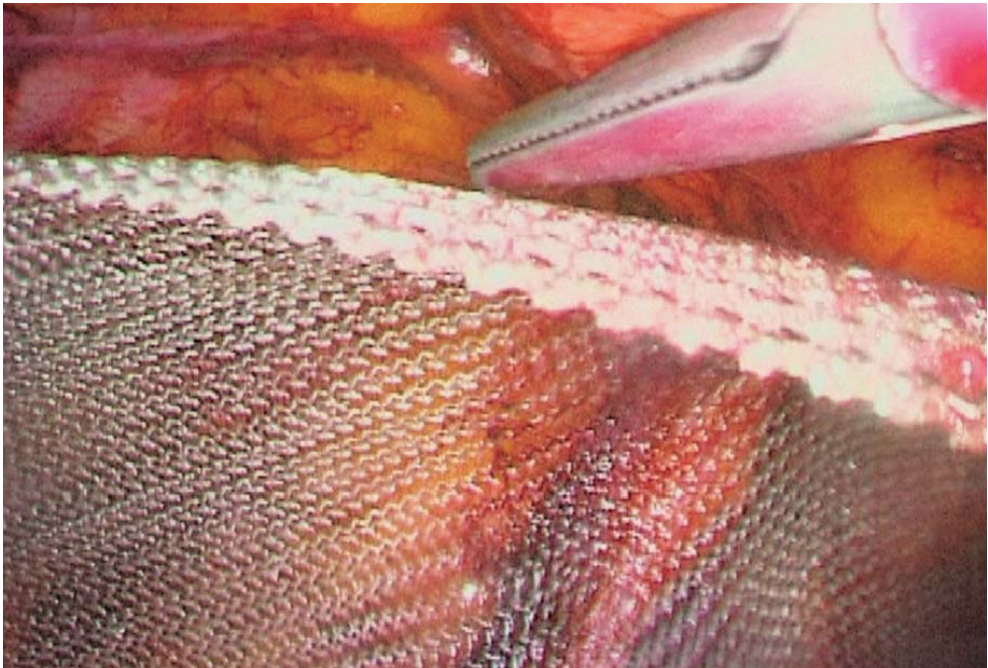


Fig. 12.22. Upper part of the 3-D mesh



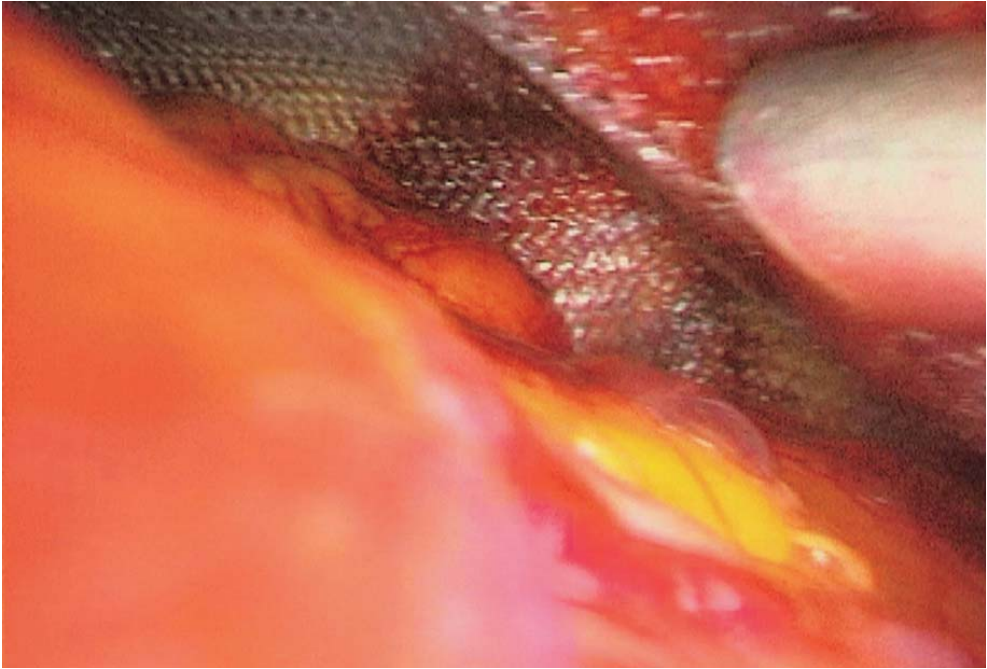


Fig. 12.23. Release of gas pressure under vision

## 12.9 Tips and Comments

- While creating the pneumoperitoneum with the Veress needle, pressure should be maintained at 15 mmHg, then lowered during the operation to 12 mmHg.
- In case the pressure drops due to inadvertent opening of the peritoneum, the operation usually can go on. However, there must be a balance between the intra- and extraperitoneal pressures. If the peritoneal tear is small, an intraperitoneal trocar fitted with a valve is required to balance the pressure. If a balance cannot be obtained, the peritoneal opening must be closed with a suture.
- The peritoneal repair must be performed either during or at the end of surgery.
- The lateral or anterior parietal perforating vessels may be controlled by coagulation.
- The presence of a very large external oblique hernia sac may require the insertion of an additional 5-mm trocar to allow a second dissector to be inserted.
- Dissection with only one instrument is often possible in cases of direct or femoral hernias, where reduction can be performed by simple traction.
- Such dissection with only one instrument for external oblique hernias may be achieved with partial reduction by traction, the use of fine coagulating scissors and by proceeding very cautiously.
- Lipomas must always be removed.

- In very large scrotal hernias, a preliminary scrotal incision enables easier resection of the hernia sac. In this way, the subsequent extraperitoneal laparoscopic repair is simplified.
- Correct positioning of the 3-D mesh is easily obtained by applying it to the infero-external edge opposite the anterior aspect of the psoas muscle. It may then be unfolded onto the infero-internal edge below Cooper's ligament.
- Spiegel hernias can be treated in the same way by reducing the hernia sac by simple traction. The superior part of the inguinal mesh is made to cover the hernia defect once wider anterior parietal dissection has been performed.
- The presence of a large hernia defect may lead to the following: (a) everting the fascia transversalis and fixing it to Cooper's ligament to prevent postoperative seromas; (b) fixing the superior edge of the mesh to the anterior parietal muscles; and (c) installing a suction drainage.
- Incision of the hernia ring is sometimes required to reduce a large femoral hernia.
- A bilateral approach means one mesh on each side, a more harmonious solution than using only a large one.
- A large hernia sac may be left reverted inside the peritoneal cavity without resection.
- A final intra-abdominal inspection at the end of the procedure makes it possible to stuck the mesh into place, to check its position, to ensure peritoneal closure in a satisfactory manner, to look for a hernia on the other side and to revert a large hernia sac.

## Literature

- Arregui ME, Davis CJ, Yucel O, Nagan RF (1992) Laparoscopic mesh repair of inguinal hernia using a preperitoneal approach: a preliminary report. *Surg Laparosc Endosc* 2:53–58
- Begin G (1992) Traitement laparoscopique des hernies de l'aine de l'adulte: à propos de 200 cas. *La lettre chirurgicale européenne* 113
- Begin G (1993) Création du pneumopéritoine sous contrôle visuel. *J Coeliochir* 18–19
- Begin G (1993) Cure coelioscopique des hernies de l'aine par voie prépéritonéale. *J Coeliochir* 7: 23–29
- Begin G (1994) Traitement laparoscopique des hernies de l'aine par voie extra-péritonéale – résultat à propos de 520 hernies. *J Coeliochir* 9:33–35
- Corbitt JD (1991) Laparoscopic herniorrhapy. *Surg Laparosc Endos* 23–25
- Dulucq JL (1991) Traitement des hernies de l'aine par la mise en place d'un patch prothétique par laparoscopie. Voie totalement extrapéritonéale. *Cah Chir* 79:15–16
- Dulucq JL (1992) Traitement des hernies de l'aine par mise en place d'un patch prothétique sous péritonéal en rétropéritonéoscopie. *Chir Endoscop* 1:6–8
- Dulucq JL (1992) Treatment of inguinal hernias by insertion of mesh through retroperitoneoscopy. *Post Graduate General Surgery* 4:173–174
- Ferzli G, Raboy A, Kleinerman D, Albert P (1992) Extraperitoneal endoscopic pelvic lymph node dissection vs. laparoscopic lymph node dissection in the staging of prostatic and bladder carcinoma. *J Laparoendosc Surg* 2:219–222

- Fitzgibbons RJ (1991) Laparoscopic hernia repair. In: Proceedings of symposium on new frontiers in endosurgery. Ethicon, New Brunswick, NJ
- Fitzgibbons RJ, Annibali R, Litke BS (1993) Gall-bladder and gallstone removal, open versus closed laparoscopy, and pneumoperitoneum. *Am J Surg* 165:497–504
- Himpens JM (1992) Laparoscopic hernioplasty using a self expandable (umbrella like) prosthetic patch. *Surg Laparosc Endosc* 2:312–316
- Himpens JM (1993) Laparoscopic inguinal hernioplasty: repair with a conventional vs. a new self expandable mesh. *Surg Endos* 7:315–319
- Liechtenstein IL, Shulman AJ, Amid PK et al (1989) The tension-free hernioplasty. *Am J Surg* 157:188–193
- McKernan JB, Laws HL (1993) Laparoscopic repair of inguinal hernias using a totally prosthetic approach. *Surg Endos* 7:26–28
- Phillips EH, Franklin M, Carroll BJ et al (1992) Laparoscopic colectomy. *Ann Surg* 216:703–770
- Phillips EH, Carroll BJ, Pearlstein AR, Daykhovsky L, Fallas MJ (1993) Laparoscopic choledochoscopy and extraction of common bile duct stones. *World J Surg* 17:22–28
- Stoppa RE, Wharlamont CR (1989) The preperitoneal approach and prosthetic repair of groin hernia. In: Nyphus LM, Condom RE (eds) *Hernia*. JP Lippincott, Philadelphia, pp 199–255
- Stoppa RE, Rives JL, Warlaumont CR et al (1984) The use of Dacron in the repair of hernias of the groin. *Surg Clin North Am* 64:269–285
- Toy FK, Smoot RT (1991) Toy Smoot hernioplasty. *Surg Laparosc Endos* 1:151–155
- Vernay A (1980) *La rétro-péritonéoscopie: justification anatomique. Expérimentation technique. Expérience clinique* [thèse]. Grenoble
- Webb DR, Redgrave N, Chan Y, Harewood LM (1993) Extraperitoneal laparoscopy: early experience and evaluation. *Aust NZJ Surg* 63:557–557
- Wurtz A (1989) L'endoscopie de l'espace rétro-péritonéal: techniques, résultats et indications actuelles. *Ann Chir* 43:475–480

# 13 Laparoscopic Right Adrenalectomy

## 13.1 Operating Room Setup: Position of the Patient

The patient is placed supine, with legs apart. Slight reverse Trendelenburg position and 20° left rotation is useful. The surgeon stands between the patient's legs. The first assistant is on the patient's right side, a second assistant is on the left (Fig. 13.1).

Self-adhesive non-woven drapes are arranged with sterile pockets to hold the instruments. The video monitor is placed at the patient's head, slightly to the left.

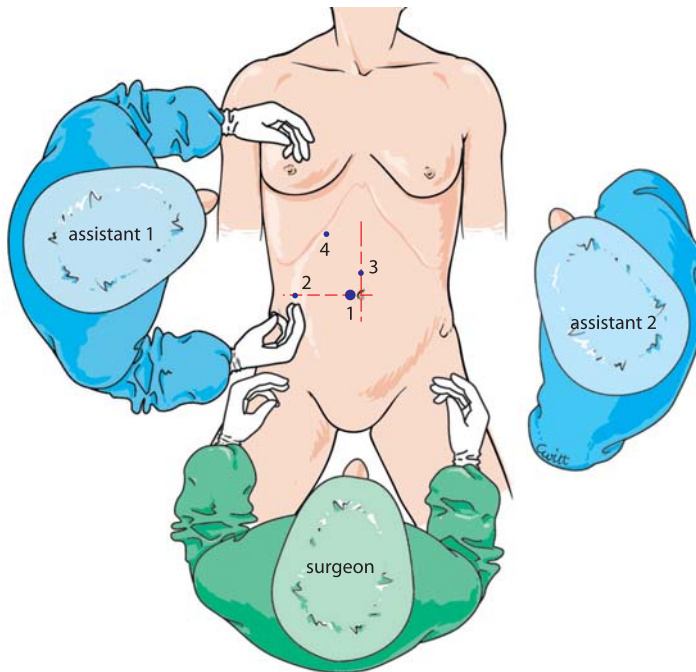


Fig. 13.1. OR setup – position of trocars



### 13.2 Recommended Instruments

- Two 10-mm trocars
- Three 5-mm trocars
- A 0° endoscope
- Two Johan fenestrated grasping forceps
- Five-millimetre straight or curved coagulating shears
- A blunt paddle
- A straight 5-mm grasping forceps
- A 5-mm dissector
- A 5-mm needle holder
- A 5-mm clip applicator
- A 5-mm suction cannula
- A vascular linear stapler
- Harmonic scalpel, if available
- Specimen retrieval bag

### 13.3 Position of the Trocars and Exposure

The pneumoperitoneum is created with a Veress needle. The first 10-mm trocar is inserted to the right of the umbilicus. The skin incision must match the size of the trocar. Insertion is oblique, in the direction of the supposed position of the adrenal. This enables a transmuscular route avoiding future incisional hernias.

The other three 5-mm operating trocars are positioned as follows: one is approximately 12 cm lateral to the umbilicus, on the right side; a second operating trocar in the right subcostal position enables mobilization of the liver; and the left 5-mm operating trocar is positioned on the median line, 4 cm above the umbilicus (▶ Fig. 13.1).

The right lobe of the liver is lifted by a liver retractor, in subcostal position. The peritoneal cavity is explored.

### 13.4 Approach of the Right Adrenal

The hepatic flexure of the colon is detached with coagulating scissors or harmonic scalpel. The duodenum is progressively exposed, and then the vena cava (▶ Fig. 13.2).

The right renal vein must next be identified (▶ Fig. 13.3). This evidences the adrenal parenchyma at the upper pole of the right kidney. Its orange colour distinguishes it from the periadrenal fatty tissue (▶ Fig. 13.4).

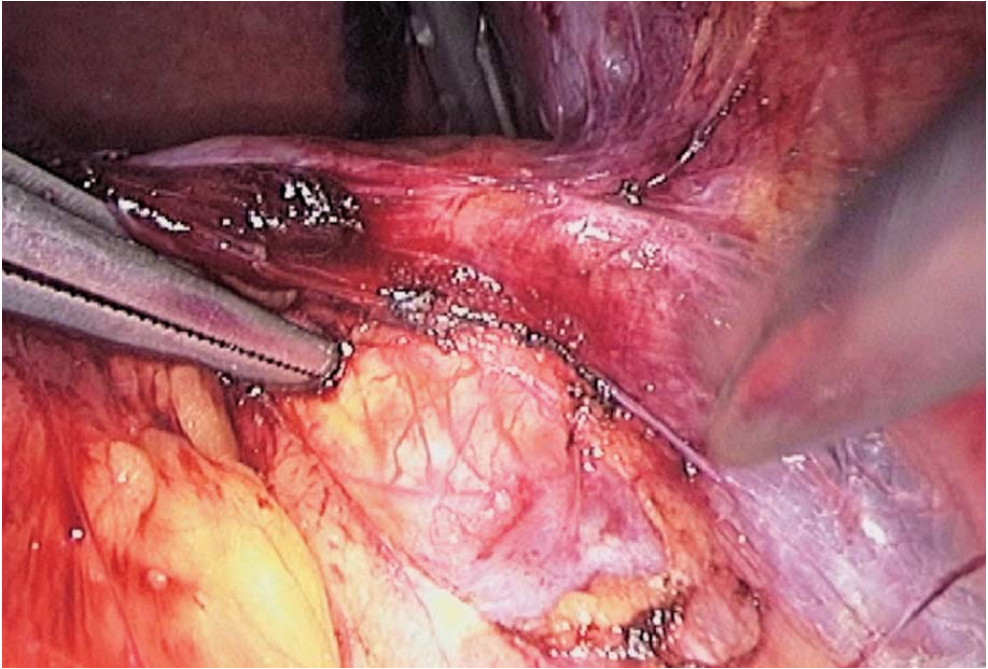


Fig. 13.2. Inferior vena cava

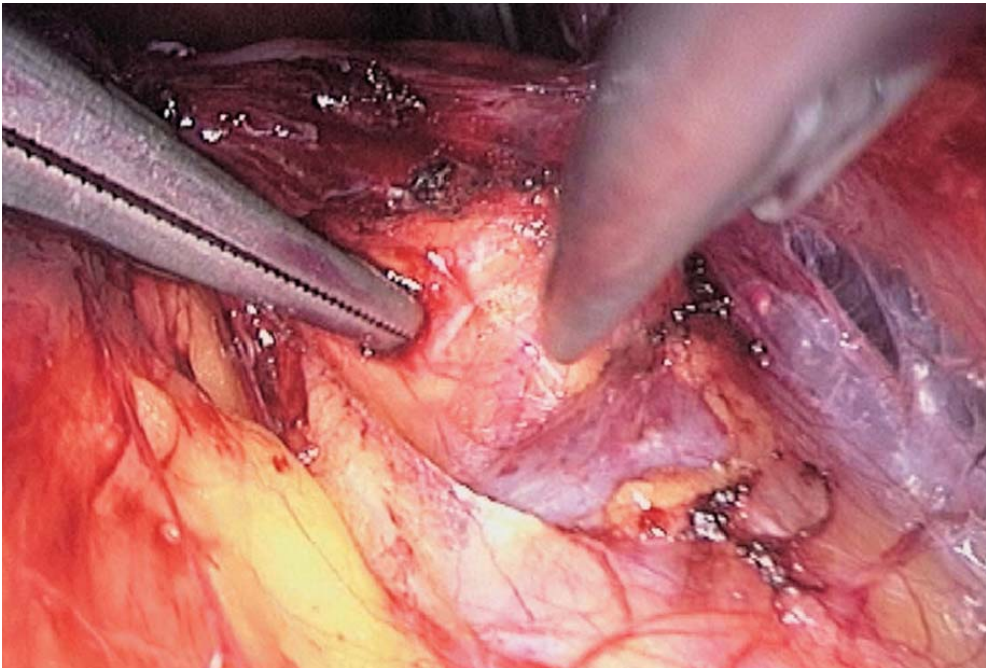


Fig. 13.3. Dissection of the renal vein

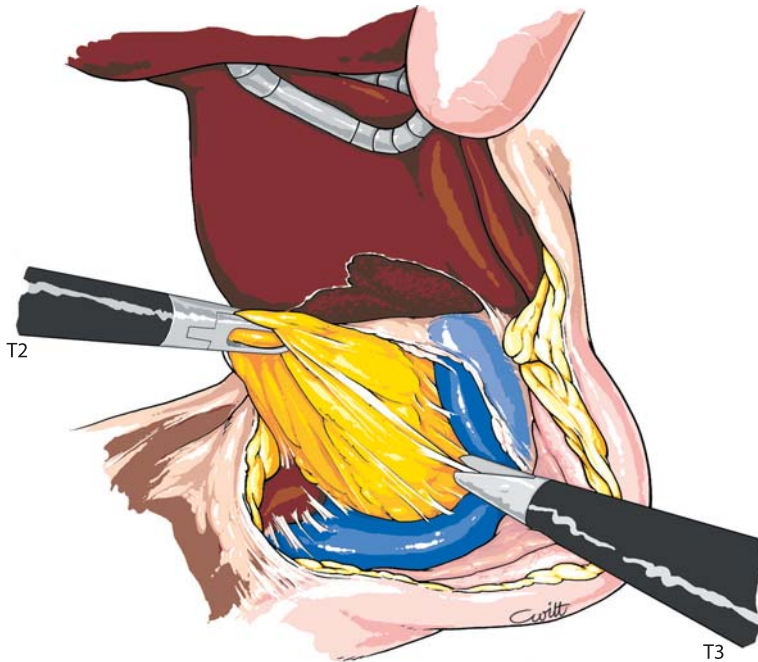


Fig. 13.4. Dissection of renal vein

### 13.5 Control of the Main Adrenal Vein

Dissection of the lower vena cava is continued caudally to the right renal vein (▶ Fig. 13.5). The vena cava is progressively dissected from the adrenal parenchyma, using either coagulating shears or a metallic suction cannula (▶ Figs. 13.6, 13.7). The adrenal vein is thus identified and must be skeletonized with a 5-mm dissector, enough to safely place two clips (▶ Fig. 13.8).

### 13.6 Dissection of the Adrenal

Once control of the vein has been completed, dissection of the posterior aspect of the adrenal gland is continued. Upward traction on the parenchyma with the grasping forceps enables exposure of the arterial branches and accessory veins, which are controlled with 5-mm clips or with the coagulating shears (▶ Figs. 13.9, 13.10).

The lower portion of the adrenal is then dissociated from its attachments. Any residual vessels are controlled in the same way (▶ Figs. 13.11, 13.12).



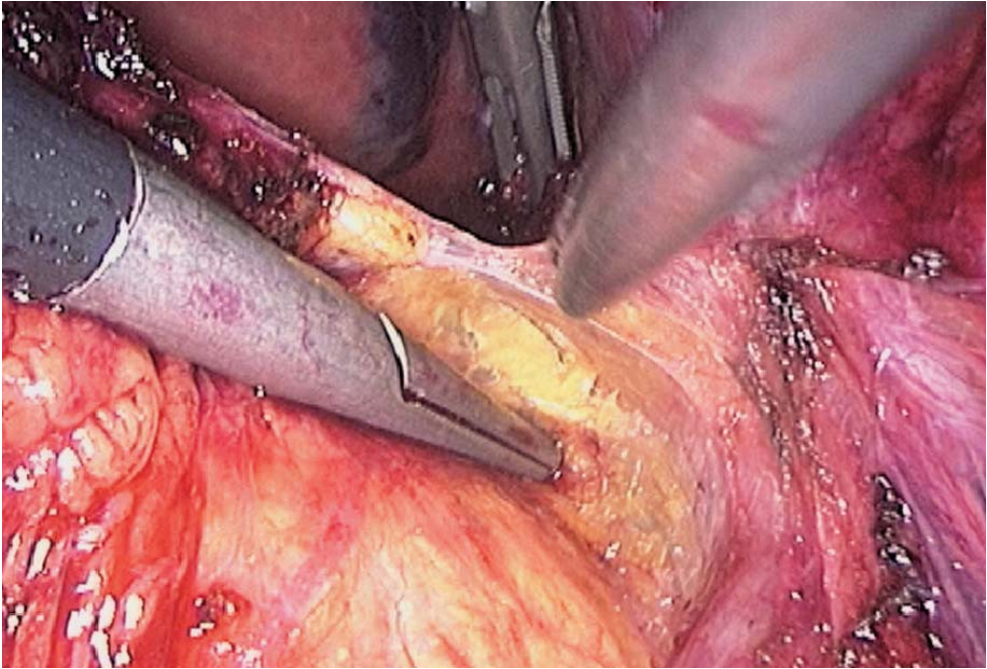


Fig. 13.5. Dissection of the inner part of the adrenal

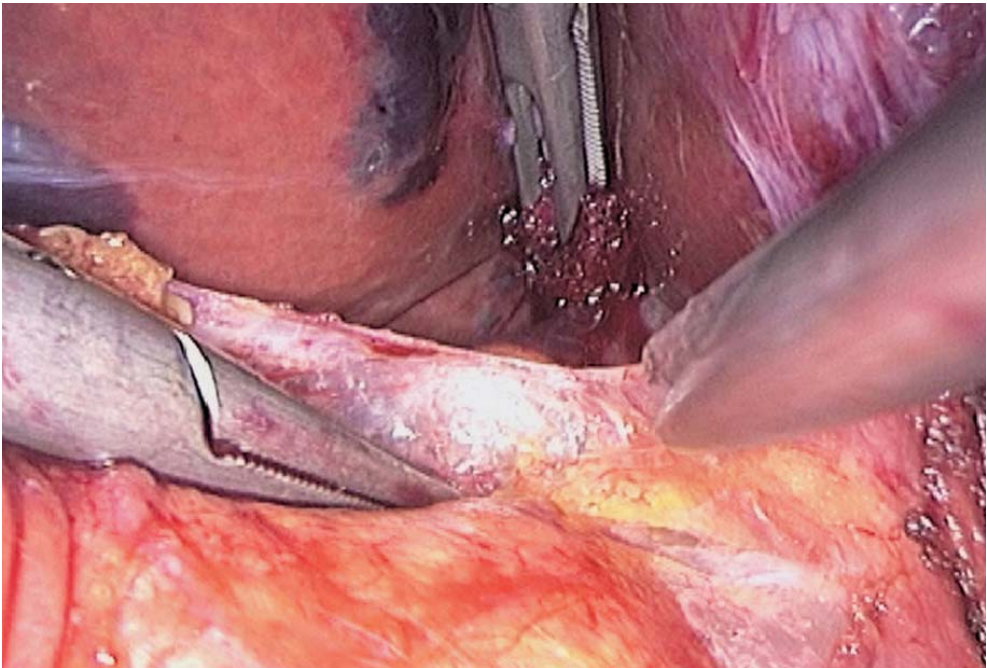


Fig. 13.6. Anterior aspect of adrenal



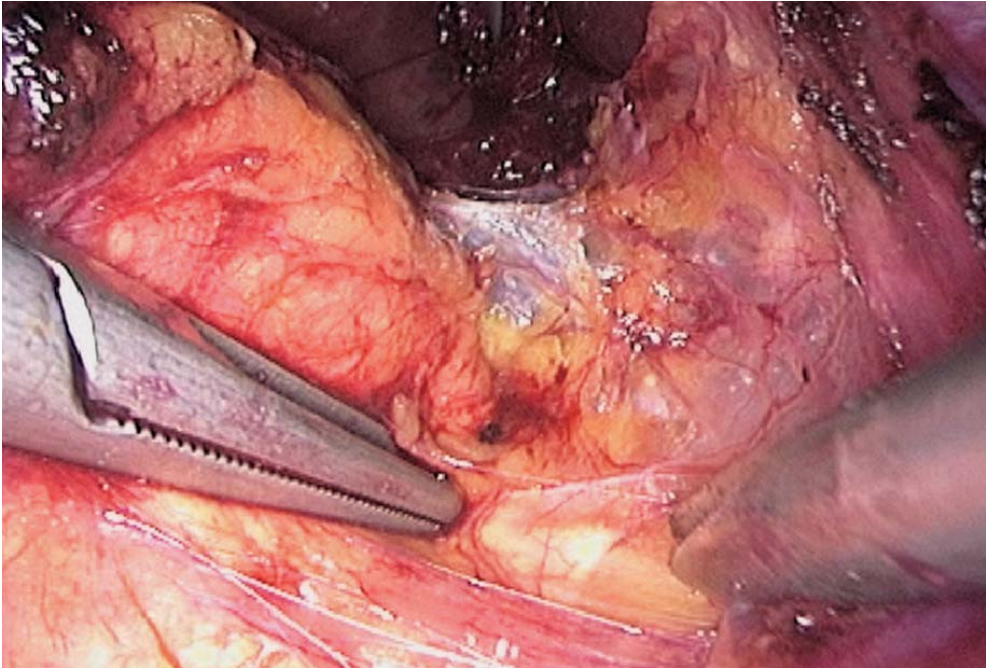


Fig. 13.7. Dissection between vena cava and renal vein

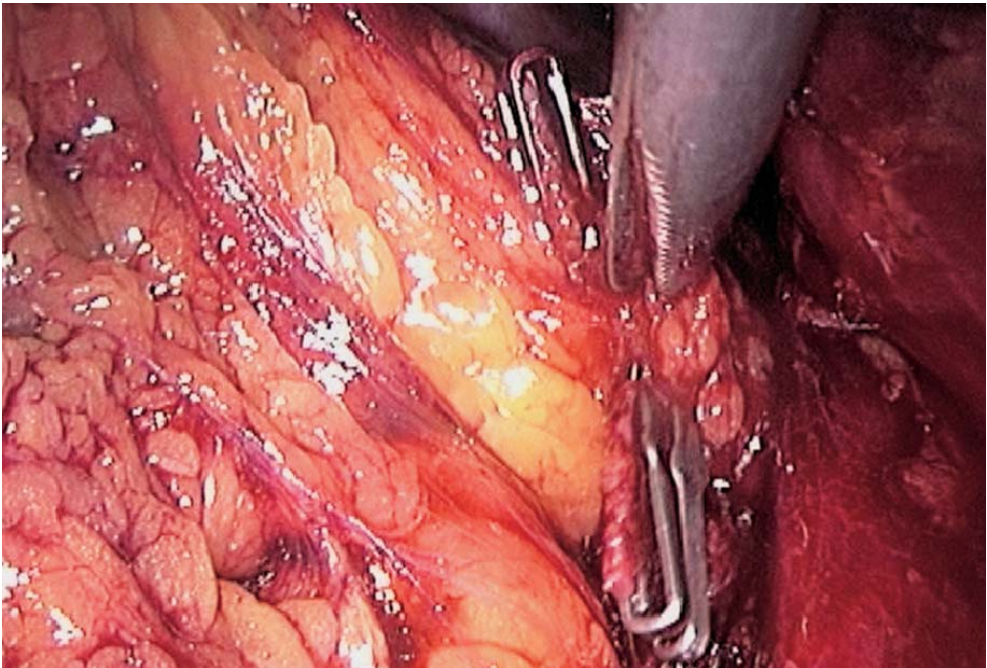


Fig. 13.8. Ligature of adrenal vein

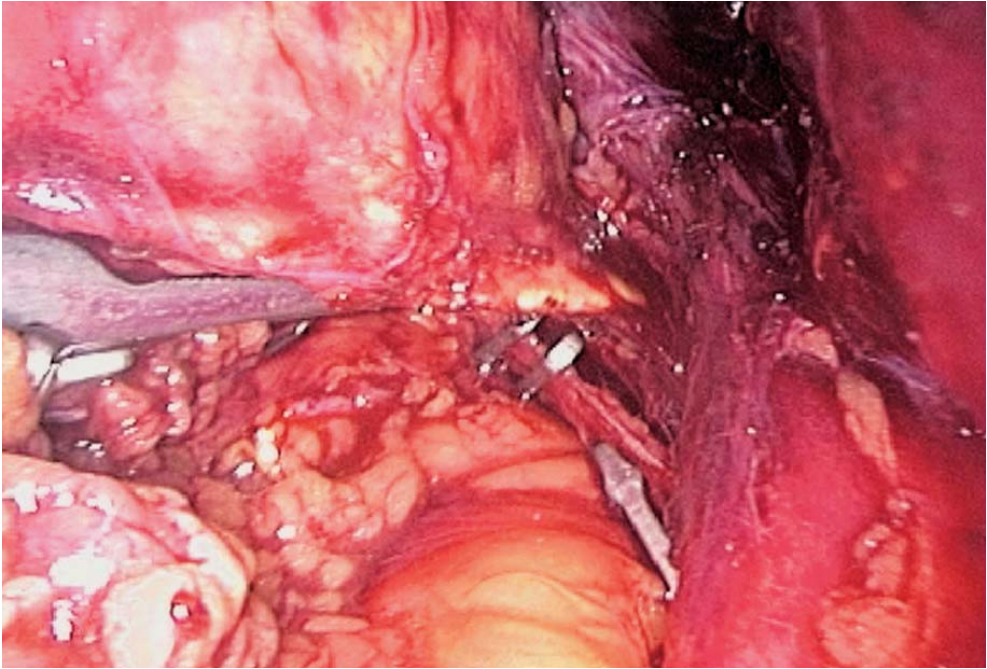


Fig. 13.9. Arterial ligature

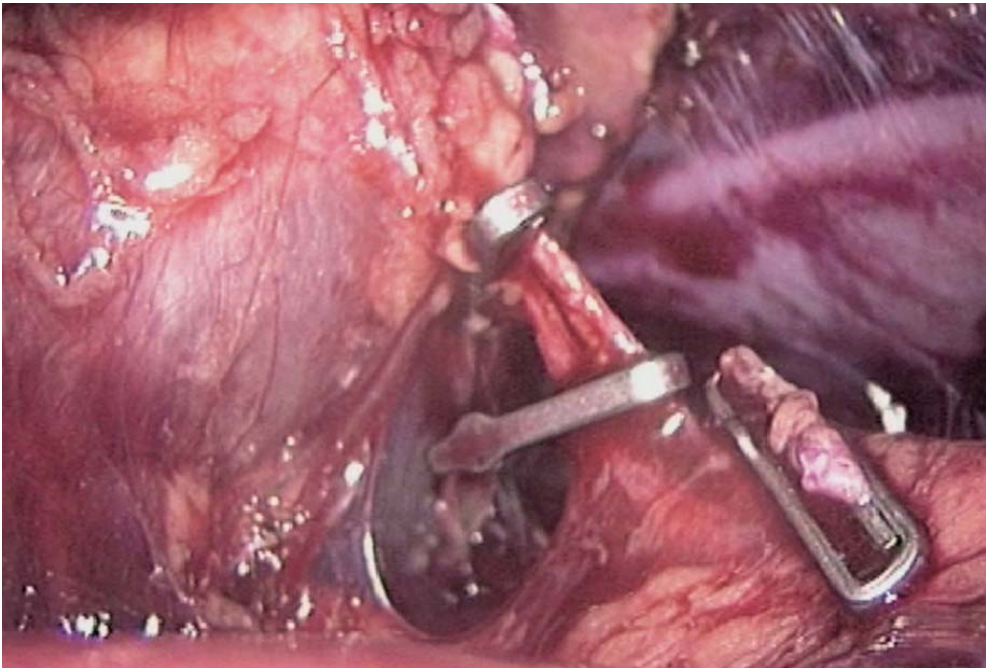


Fig. 13.10. Arterial control with clips



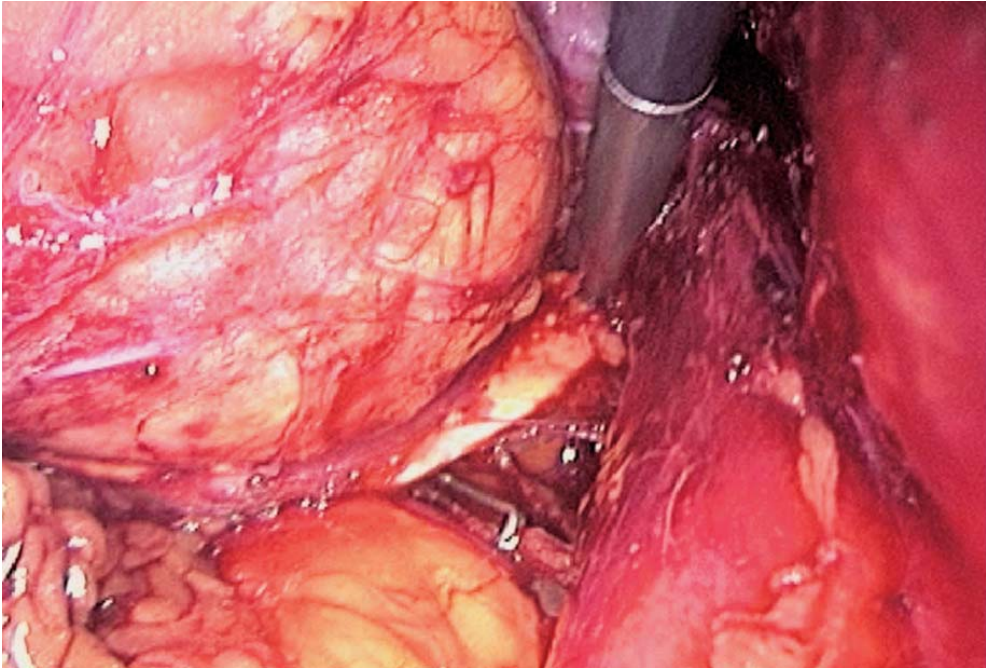


Fig. 13.11. Dissection continued along vena cava

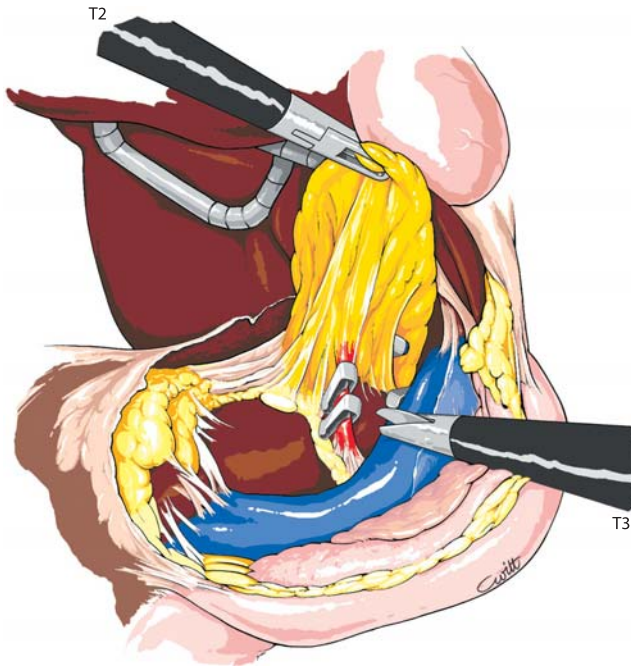


Fig. 13.12. Arterial control

### 13.7 Control of the Upper Adrenal Pedicles

Dissection of the inner part of the adrenal gland is continued in contact with the vena cava. Mobilization of the parenchyma is simplified by the prior dissection of its posterior part. An upper adrenal vein is controlled by clips after dissection with the 5-mm dissector (▶ Fig. 13.13). The residual arterial branches are controlled at the level of the upper part of the adrenal parenchyma. The last capsular elements can be controlled by coagulation (▶ Figs. 13.14–13.18). The adrenal is resected.

### 13.8 Specimen Retrieval: Haemostasis – Drainage

A specimen retrieval bag is introduced and the adrenal is extracted through the lateral port (▶ Fig. 13.19). The skin incision is enlarged to 2 cm after removal of the trocar. The bag is pulled out, and the adrenal is grasped inside the bag with an appropriate forceps.

The operative field is checked for bleeding and cleaned with saline. No peritoneal closure is needed. A suction drainage is left.

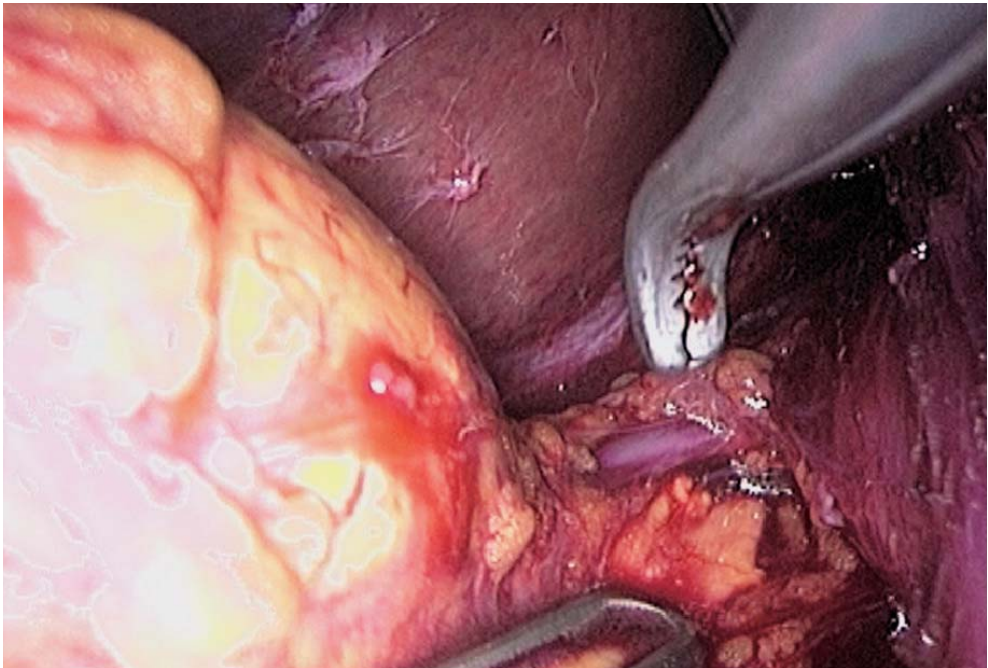


Fig. 13.13. Superior adrenal vein



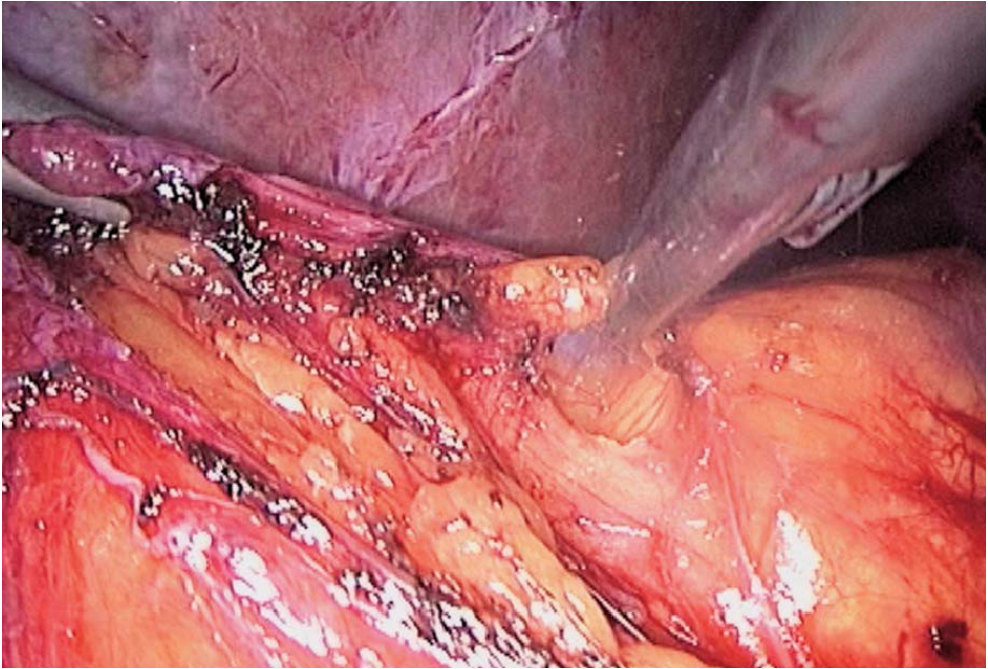


Fig. 13.14. Dissection at upper edge

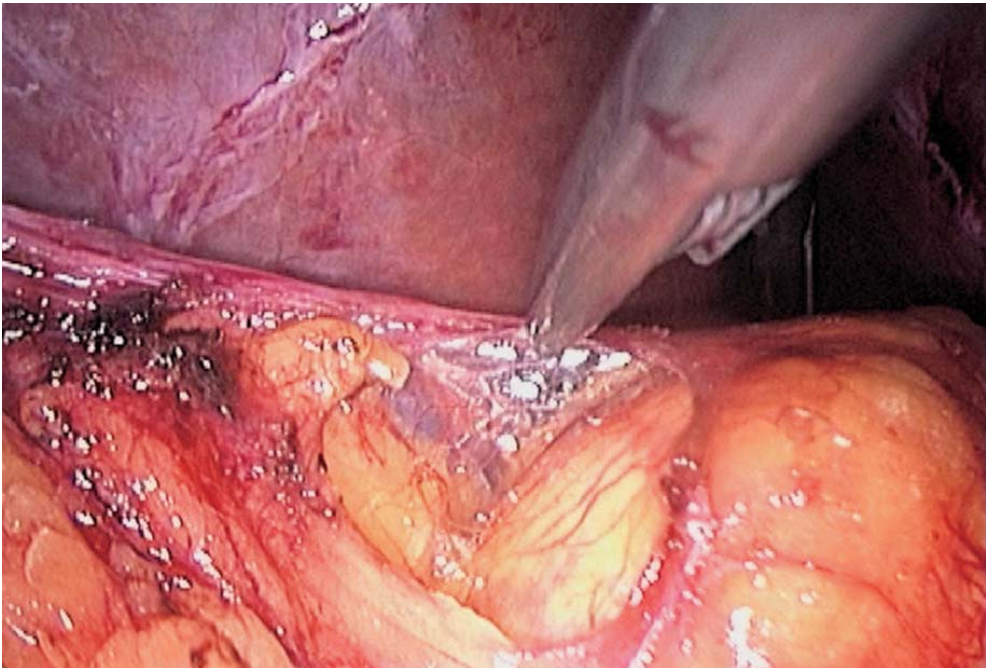


Fig. 13.15. Dissection of the upper part of the adrenal

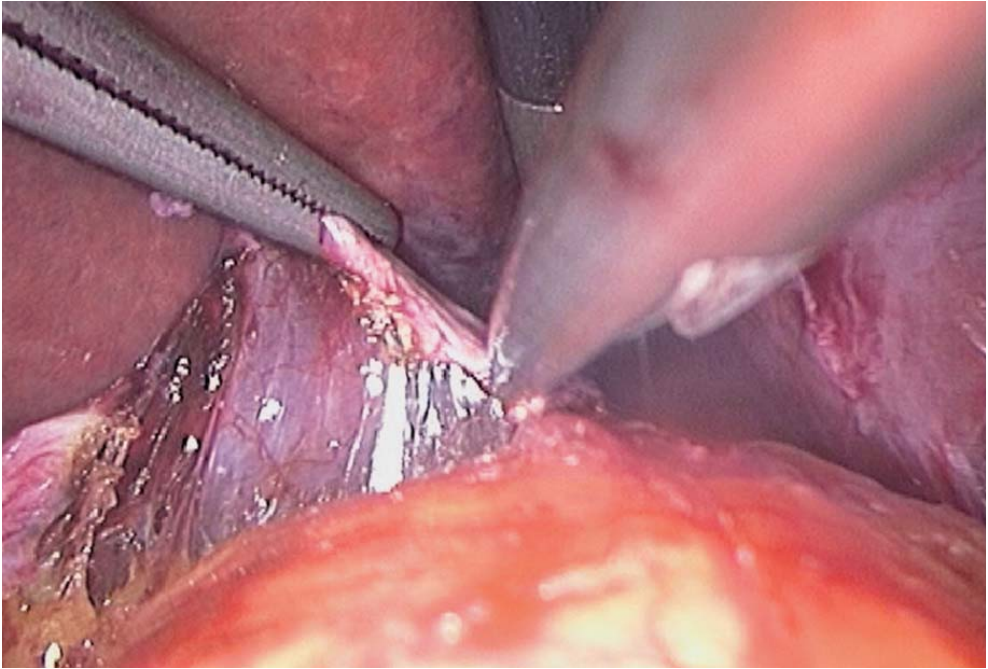


Fig. 13.16. Upper polar attachments

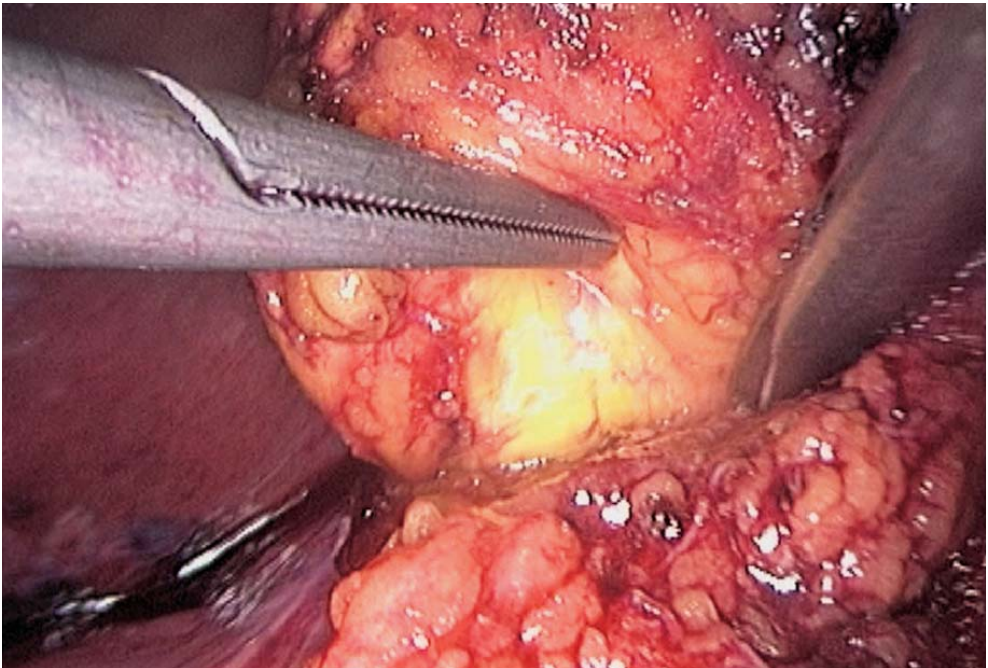


Fig. 13.17. Dissection of the posterior aspect of the adrenal



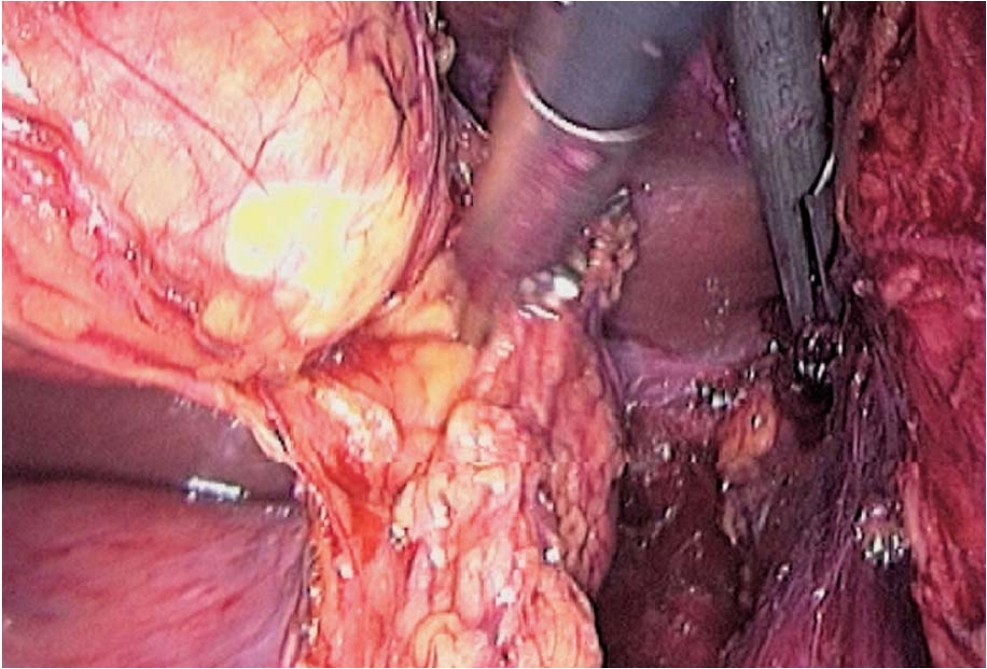


Fig. 13.18. Final dissection

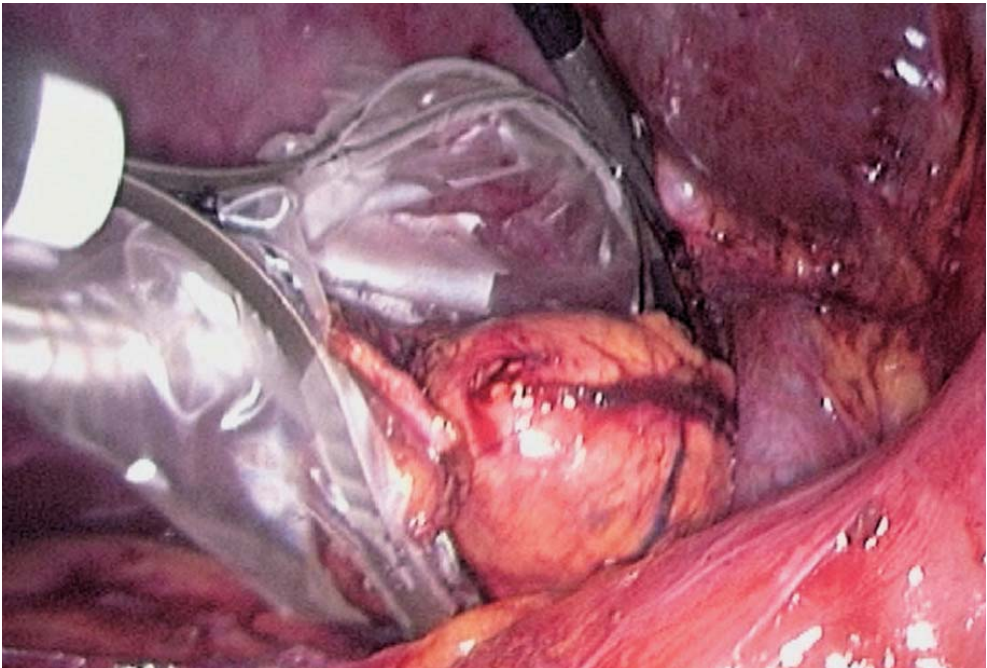


Fig. 13.19. Retrieval with a bag

### 13.9 Tips and Comments

- The harmonic scalpel minimizes the need for clips. However, clips remain necessary for control of the main adrenal vein and artery.
- The inferior adrenal vein is very short and must be dissected with extreme care. This justifies the use of the 5-mm dissector. Ligature of the vein is often necessary.
- A laparoscopic vascular clamp must be ready for emergency lateral clamping of the vena cava.
- The right renal vein is the main anatomical landmark to discover the adrenal, combined with the dissection of the vena cava.
- The size of the superior adrenal vein is often identical to that of the inferior adrenal vein. The choice of its early control is often warranted.
- Use of a metallic suction cannula as a dissector in the periadrenal fat is strongly recommended.
- The adrenal parenchyma must be mobilized very carefully using a Johan forceps without actual grasping.
- Installing the patient in the right posterior lumbar position results in placing the surgeon on the right side. It is a matter of choice. We prefer positioning the patient as indicated above, supine, with a maximum of 30° right rotation. This patient position does not change the anatomy.

### Literature

- Ambrosi B, Passini E, Re T, Barbetta L (1997) The clinical evaluation of silent adrenal masses. *J Endocrinol Invest* 20:90–107
- Bendinelli C, Materazzi G, Puccini M, Lacconi P, Buccianti P, Miccoli P (1988) Laparoscopic adrenalectomy: a retrospective comparison with traditional methods. *Minerva Chir* 53:871–875
- Bonjer HJ, Van der Hast E, Steyberg EW, de Herder WW, Kazeimier G, Mohammedamin RS, Bruining HA (1998) Retroperitoneal adrenalectomy: open or endoscopic? *World J Surg* 22:1246–1249
- Buel JF, Alexander HR, Norton JA, Yu KC, Fraker DL (1997) Bilateral adrenalectomy for Cushing's syndrome: anterior versus posterior surgical approach. *Ann Surg* 225:63–68
- Clayman RV, Kavoussi LR, Soper NJ, Dierks SM, Meretyk S, Darcy MD, Roemer FD, Pingleton ED, Thomson PG, Long SR (1991) Laparoscopic nephrectomy: initial care report. *J Urol* 146:278–281
- De Canniere L, Michel L, Hamoir E, Hubens G, Meurisse M, Squifflet JP, Urbain P, Vereecken L (1997) Multicentric experience of the Belgian Group for Endoscopic Surgery (BGES) with endoscopic adrenalectomy. *Surg Endosc* 11:1065–1067
- Demeure MJ, Jordan M, Zeiher M, Wilson SD (1997) Endoscopic retroperitoneal right adrenalectomy with the patient in the lateral decubitus position. *Surg Laparosc Endosc* 7:307–309
- Fernandez-Cruz L, Saenz A, Taura P, Benarroch G, Astudillo E, Sabater L (1999) Retroperitoneal approach in laparoscopic adrenalectomy: is it advantageous? *Surg Endosc* 13:86–90
- Filippini S, Guerrieri M, Arnaldi G, Giovagnetti M, Masini AM, Lezoche E, Mantero F (1998) Laparoscopic adrenalectomy: a report of 50 operations. *Eur J Endocrinol* 138:548–553
- Gagner M, Lacroix A, Prinz RA (1993) Early experience with laparoscopic approach for adrenalectomy. *Surgery* 114:1120–1125



- Imai T, Funahashi H, Tanaka Y, Tobinaga J, Wada M, Morita-Matsuyama T, Ohiso Y, Takagi H (1996) Adrenalectomy for treatment of Cushing syndrome: results in 122 patients and long-term follow-up studies. *World J Surg* 20:781–786
- Ishikawa T, Sowa M, Nagayama M, Nishiguchi Y, Yoshikawa K (1997) Laparoscopic adrenalectomy: comparison with the conventional approach. *Surg Laparosc Endosc* 7:275–280
- Janetschek G, Finkenstedt G, Gasser R, Waibel UG, Peschel R, Bartsch G, Neumann HP (1998) Laparoscopic surgery for pheochromocytoma: adrenalectomy, partial resection, excision of paragangliomas. *J Urol* 160:330–334
- Korman JE, Ho T, Hiatt JR, Phillips EH (1997) Comparison of laparoscopic and open adrenalectomy. *Am Surg* 63:908–912
- MacGillivray DC, Shichman SJ, Ferrer FA, Malchoff CD (1996) A comparison of open vs. laparoscopic adrenalectomy. *Surg Endosc* 10:987–990
- Mantero F, Masini AM, Opocher G, Giovagnetti M, Arnaldi G (1997) Adrenal incidentaloma: an overview of hormonal data from the National Italian Study Group. *Horm Res* 47:284–289
- Mobius E, Nies C, Rothmund M (1999) Surgical treatment of pheocromocytomas: laparoscopic or conventional? *Surg Endosc* 13:35–39
- Prinz RA (1995) A comparison of laparoscopic and open adrenalectomies. *Arch Surg* 130:489–492
- Sugarbacker PH (1995) Patient selection and treatment of peritoneal carcinomatosis from colorectal and appendiceal cancer. *World J Surg* 19:235–290
- Thompson W (1990) Conn's syndrome: primary aldosteronism. In: Friesen SR, Thompson NW (eds) *Surgical endocrinology: clinical syndromes*. JB Lippincott, Philadelphia, pp 433–449
- Ting AC, Lo CY, Lo CM (1998) Posterior or laparoscopic approach for adrenalectomy. *Am J Surg* 175:488–490

---

## 14 Laparoscopic Left Adrenalectomy

### 14.1 Operating Room Setup: Position of the Patient

The patient is installed supine, with a 30° right rotation, and with legs apart. The surgeon stands between the patient's legs. The first assistant stands on the right side of the patient. A second assistant stands to the patient's left. Self-adhesive non-woven drapes are used with sterile pockets to hold the instruments. The video monitor is placed behind and to the left side of the patient's head.

### 14.2 Recommended Instruments

- One or two 10-mm trocars
- Three 5-mm trocars
- A 0° endoscope
- Two Johan fenestrated grasping forceps
- A pair of 5-mm straight or curved coagulating shears
- A straight 5-mm grasping forceps
- A 5-mm dissector
- A 5-mm needle holder
- A 5-mm clip dispenser
- A 5-mm suction cannula
- A vascular linear stapler
- An ultrasound dissector, if available
- A plastic specimen retrieval bag

### 14.3 Position of the Trocars and Exposure: Exploration of the Peritoneal Cavity

The pneumoperitoneum is created with a Veress needle. The first 10-mm trocar is inserted slightly left of the umbilicus. The skin incision must match the precise size of the trocar. Insertion is oblique, in the direction of the supposed position of the adrenal. This enables a transmuscular route avoiding future incisional hernias.

The other three operating trocars are positioned as follows: the first right operating trocar is on the median, supra-umbilical line roughly 5 cm above the umbili-

cus; a second operating left subcostal trocar on the axillary line enables gastro epiploic and pancreatic mobilization; and the left 5-mm operating trocar is inserted in the left para-median position roughly 10 cm to the left of the umbilicus. The abdominal cavity is visually explored.

#### 14.4 Approach of the Adrenal

The left colic omentum is detached with the harmonic scalpel or by coagulation. Sometimes lowering of the splenic flexure of the colon is needed.

The lower edge of the pancreas and the anterior part of the left kidney are visible in the lesser sac. The lower edge of the pancreas is dissected with opening of the posterior parietal layer. The left renal vein and the splenic vein can easily be landmarked.

The left renal vein and the upper pole of the left kidney enable situating the adrenal. Dissection is performed with the Johan fenestrated forceps and the coagulating shears. The orange-coloured adrenal parenchyma appears at the inner edge of the upper pole of the left kidney and the upper edge of the origin of the left renal vein.

#### 14.5 Control and Dissection of the Main Adrenal Vein

The left adrenal vein is found caudal to the left renal vein. Clearly identifying the renal vein is absolutely necessary. The adrenal vein is dissected over a distance of 1–2 cm, enabling its control with titanium clips.

#### 14.6 Dissection of the Adrenal

In contact with the aorta, the adrenal is then dissected with the 5-mm suction cannula. The peri-adrenal fat can easily be dissociated from the adrenal parenchyma. Caudally to the operative field it is possible to distinguish the adrenal arteries that are clipped separately with titanium clips.

A superior adrenal pedicle is often encountered, both arterial and venous. Every vessel is clipped in turn. Dissection resumes at the posterior aspect of the adrenal, either with the harmonic scalpel or coagulating shears.

## 14.7 Final Dissection

Dissection of the gland parenchyma is completed by the control of a few upper tracts in contact with the diaphragm. Numerous small collateral vessels are coagulated or clipped. The entire adrenal is freed. A coagulating forceps can be used to perfect the haemostasis of the entire adrenal bed.

## 14.8 Specimen Retrieval: Drainage

The left trocar port is widened to retrieve the specimen through a protective bag. The field is cleaned with saline. A suction drainage is left. The reclined organs, caudal part of pancreas, splenic flexure, and omentum are repositioned.

## 14.9 Tips and Comments

- Use of the harmonic scalpel makes it possible to minimize the use of clips, needed only for the control of the main adrenal vein and of the main adrenal artery.
- The adrenal vein is usually very short. Dissection should be done especially carefully, and the use of a 5-mm dissector is recommended. A ligature may be necessary.
- A laparoscopic vascular clamp must be ready in case of injury to the large vessels.
- The right renal vein is the main anatomical landmark to finding the adrenal gland.
- The size of the superior adrenal vein is often identical to that of the inferior adrenal vein. The choice of its early control is often warranted.
- Use of a metallic suction cannula as a dissector in the peri-adrenal fat is strongly recommended.
- The adrenal parenchyma must be mobilized very carefully using a Johan forceps without actual grasping.
- Installing the patient in the right posterior lumbar position results in placing the surgeon on the left side. It is a matter of choice. We prefer positioning the patient as indicated above, supine, with a maximum of 30° left rotation. This position does not change the anatomy.
- There may be only one left adrenal vein. A large branch is, however, frequently found nearby that must be controlled in the same way.
- Finding the adrenal parenchyma is always ensured by a proper dissection of the anterior aspect of the upper pole of the left kidney and by the dissection of the left renal vein.



## Literature

- Ambrosi B, Passini E, Re T, Barbetta L (1997) The clinical evaluation of silent adrenal masses. *J Endocrinol Invest* 20:90–107
- Bendinelli C, Materazzi G, Puccini M, Lacconi P, Buccianti P, Miccoli P (1988) Laparoscopic adrenalectomy: a retrospective comparison with traditional methods. *Minerva Chir* 53:871–875
- Bonjer HJ, Van der Hast E, Steyberg EW, de Herder WW, Kazeimier G, Mohammedamin RS, Bruining HA (1998) Retroperitoneal adrenalectomy: open or endoscopic? *World J Surg* 22:1246–1249
- Buel JF, Alexander HR, Norton JA, Yu KC, Fraker DL (1997) Bilateral adrenalectomy for Cushing's syndrome: anterior versus posterior surgical approach. *Ann Surg* 225:63–68
- Clayman RV, Kavoussi LR, Soper NJ, Dierks SM, Meretyk S, Darcy MD, Roemer FD, Pingleton ED, Thomson PG, Long SR (1991) Laparoscopic nephrectomy: initial care report. *J Urol* 146:278–281
- De Canniere L, Michel L, Hamoir E, Hubens G, Meurisse M, Squifflet JP, Urbain P, Vereecken L (1997) Multicentric experience of the Belgian Group for Endoscopic Surgery (BGES) with endoscopic adrenalectomy. *Surg Endosc* 11:1065–1067
- Demeure MJ, Jordan M, Zeihem M, Wilson SD (1997) Endoscopic retroperitoneal right adrenalectomy with the patient in the lateral decubitus position. *Surg Laparosc Endosc* 7:307–309
- Fernandez-Cruz L, Saenz A, Taura P, Benarroch G, Astudillo E, Sabater L (1999) Retroperitoneal approach in laparoscopic adrenalectomy: is it advantageous? *Surg Endosc* 13:86–90
- Filippini S, Guerrieri M, Arnaldi G, Giovagnetti M, Masini AM, Lezoche E, Mantero F (1998) Laparoscopic adrenalectomy: a report of 50 operations. *Eur J Endocrinol* 138:548–553
- Gagner M, Lacroix A, Prinz RA (1993) Early experience with laparoscopic approach for adrenalectomy. *Surgery* 114:1120–1125
- Imai T, Funahashi H, Tanaka Y, Tobinaga J, Wada M, Morita-Matsuyama T, Ohiso Y, Takagi H (1996) Adrenalectomy for treatment of Cushing syndrome: results in 122 patients and long-term follow-up studies. *World J Surg* 20:781–786
- Ishikawa T, Sowa M, Nagayama M, Nishiguchi Y, Yoshikawa K (1997) Laparoscopic adrenalectomy: comparison with the conventional approach. *Surg Laparosc Endosc* 7:275–280
- Janetschek G, Finkenstedt G, Gasser R, Waibel UG, Peschel R, Bartsch G, Neumann HP (1998) Laparoscopic surgery for pheochromocytoma: adrenalectomy, partial resection, excision of paragangliomas. *J Urol* 160:330–334
- Korman JE, Ho T, Hiatt JR, Phillips EH (1997) Comparison of laparoscopic and open adrenalectomy. *Am Surg* 63:908–912
- MacGillivray DC, Shichman SJ, Ferrer FA, Malchoff CD (1996) A comparison of open vs. laparoscopic adrenalectomy. *Surg Endosc* 10:987–990
- Mantero F, Masini AM, Opocher G, Giovagnetti M, Arnaldi G (1997) Adrenal incidentaloma: an overview of hormonal data from the National Italian Study Group. *Horm Res* 47:284–289
- Mobius E, Nies C, Rothmund M (1999) Surgical treatment of pheochromocytomas: laparoscopic or conventional? *Surg Endosc* 13:35–39
- Prinz RA (1995) A comparison of laparoscopic and open adrenalectomies. *Arch Surg* 130:489–492
- Sugarbaker PH (1995) Patient selection and treatment of peritoneal carcinomatosis from colorectal and appendiceal cancer. *World J Surg* 19:235–290
- Thompson W (1990) Conn's syndrome: primary aldosteronism. In: Friesen SR, Thompson NW (eds) *Surgical endocrinology: clinical syndromes*. JB Lippincott, Philadelphia, pp 433–449
- Ting AC, Lo CY, Lo CM (1998) Posterior or laparoscopic approach for adrenalectomy. *Am J Surg* 175:488–490

**PART 4**

**Procedures for Pelvic Floor Disorders**

- 15 Laparoscopic Posterior Colpopexy 209
- 16 Laparoscopic Anterior Colpopexy 221
- 17 Laparoscopic Burch Colposuspension 233

---

# 15 Laparoscopic Posterior Colpopexy

## 15.1 Operating Room Setup: Position of the Patient

The patient is placed supine in a 20° Trendelenburg position. The surgeon and the scrub nurse stand on the left side of the patient. The second assistant stands between the patient's legs. The video monitor is positioned to the right of the patient, laterally to the right leg.

The patient is under general anaesthesia with an endotracheal tube. Self-adhesive non-woven drapes are used, with bags to hold the instruments.

## 15.2 Recommended Instruments

- Two 10-mm trocars
- Two 5-mm trocars
- Three 5-mm Johann fenestrated grasping forceps
- A 5-mm coagulating shears
- A straight 5-mm grasping forceps
- A 5- or 10-mm harmonic scalpel
- A 10-mm curved dissector
- A 5-mm needle holder
- A 0° endoscope

## 15.3 Position of the Trocars and Exposure

The pneumoperitoneum is created with a Veress needle at the lower margin of the umbilicus. A left transrectal trocar is inserted 5 cm outside of the umbilicus for the endoscope. The other operating trocars are inserted after inflation of the abdominal cavity, a 5-mm median suprapubic trocar, a 5-mm left iliac fossa trocar, and a 10-mm trocar at the lower margin of the umbilicus with a 5-mm reducer.

The abdominal cavity is then explored (◉ Fig. 15.1). A 20° Trendelenburg position enables positioning of the small bowel in the upper quadrants of the abdomen. A fenestrated grasping forceps inserted through the suprapubic port progressively exposes the rectosigmoid junction.

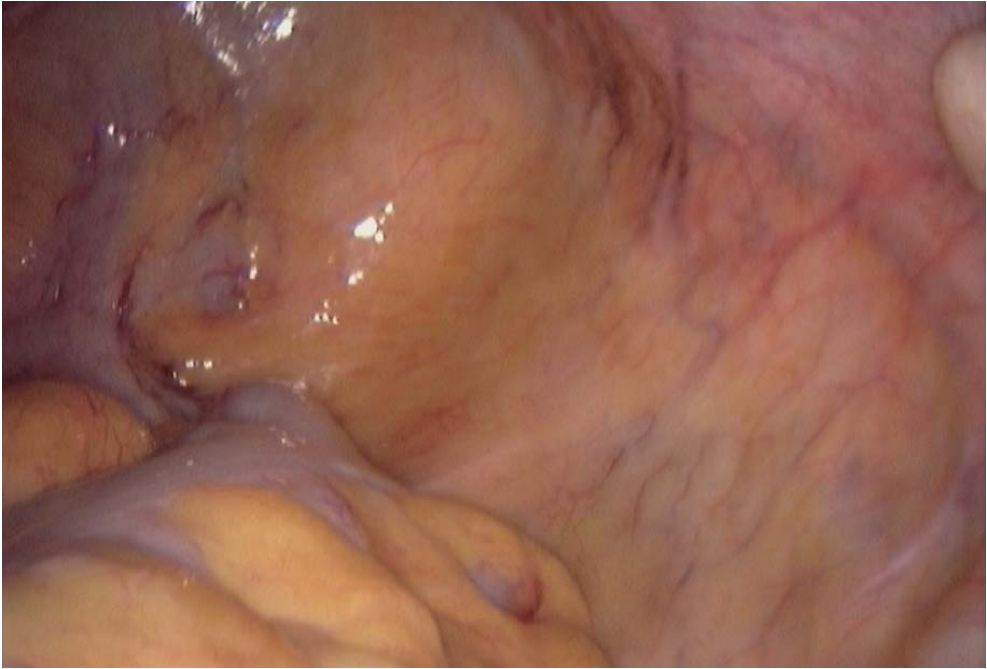

Fig. 15.1. Pelvic floor exposure

#### 15.4 Dissection of the Promontorium

The posterior parietal peritoneum is opened with the coagulating shears longitudinally in line with the promontorium, which is easily identified (● Fig. 15.2). A second pre-promontorium layer is opened enabling the exposure of the vertebral ligament of the promontorium and of its vessels. The dissection is continued laterally.

#### 15.5 Peritoneal Opening and Excision

An incision opposite the promontorium of the parietal peritoneum is continued to the back of the Douglas pouch, with the two uterosacral ligaments at the upper limit of the peritoneal incision, after location of the right and then the left ureter (● Figs. 15.3, 15.4). The uterus can be suspended through the abdominal wall by a transfixing stitch. The peritoneum thus delineated is then resected to its rectal insertion. The resection is performed in contact with the peritoneal layer using the coagulating shears or the harmonic scalpel. A perirectal collar is left to enable proper peritonization.



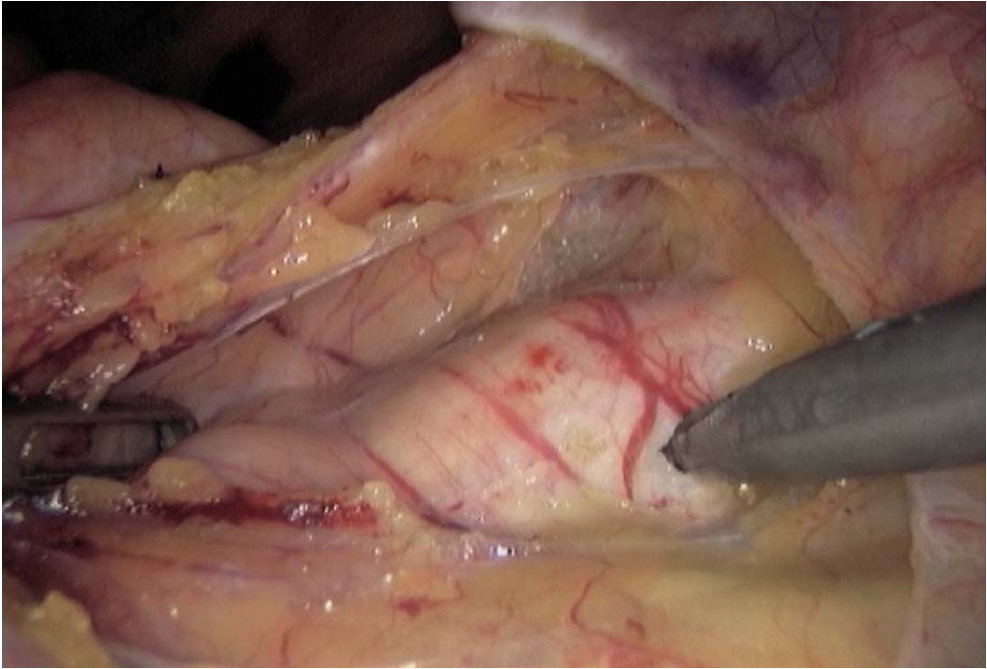


Fig. 15.2. Dissection of vertebral ligament

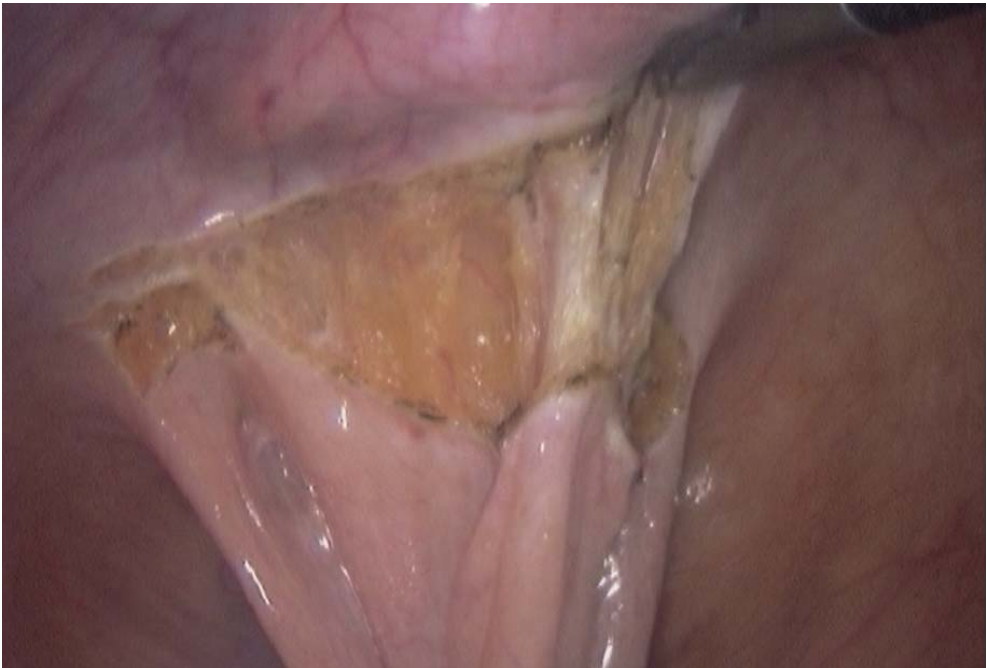

Fig. 15.3. Peritoneal incision

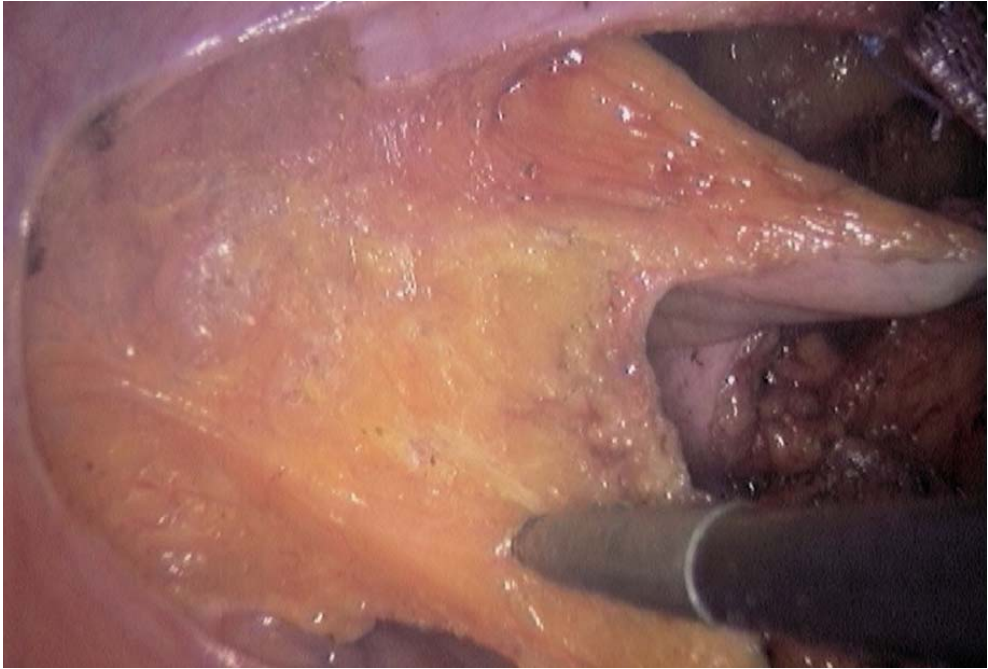


Fig. 15.4. Peritoneal incision leftwards

### 15.6 Rectovaginal Dissection

The positioning of a vaginal retractor in the posterior vaginal pouch makes it possible to expose and then open the rectovaginal septum (◀ Fig. 15.5). Traction is applied at the level of the rectosigmoid junction by the suprapubic grasping forceps. The rectovaginal septum can be progressively dissected using the coagulating shears, the harmonic scalpel or a blunt instrument (◀ Fig. 15.6). Haemostasis must be carefully performed. The posterior vaginal wall now appears, presented by the vaginal retractor, and is dissected as low as possible.

### 15.7 Mesh Placement

A mersilene mesh and two nonabsorbable 2/0 sutures with a 26-mm needle are inserted through the umbilical trocar. The mesh size is 3×20 cm. The mesh is sutured to the posterior vaginal wall by six stitches (◀ Figs. 15.7, 15.8). A final stitch is applied to the cervix or isthmus part of the uterus, transfixing the posterior wall of the cervix or the uterine isthmus (◀ Fig. 15.9). The mesh is tunneled under the peritoneum towards the promontorium (◀ Fig. 15.10).

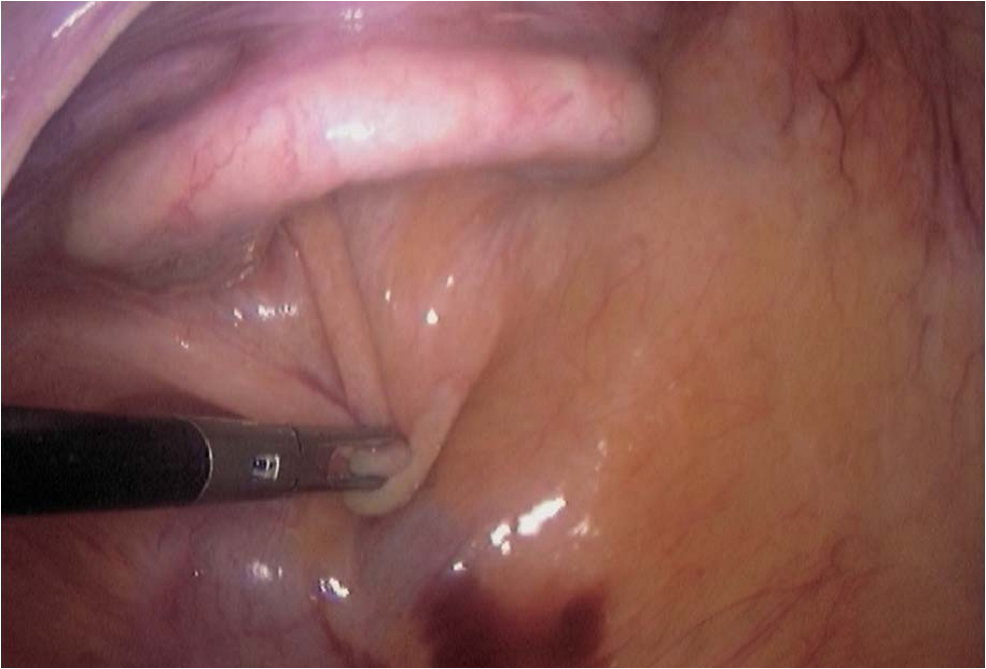


Fig. 15.5. Vaginal retractor presenting Douglas pouch

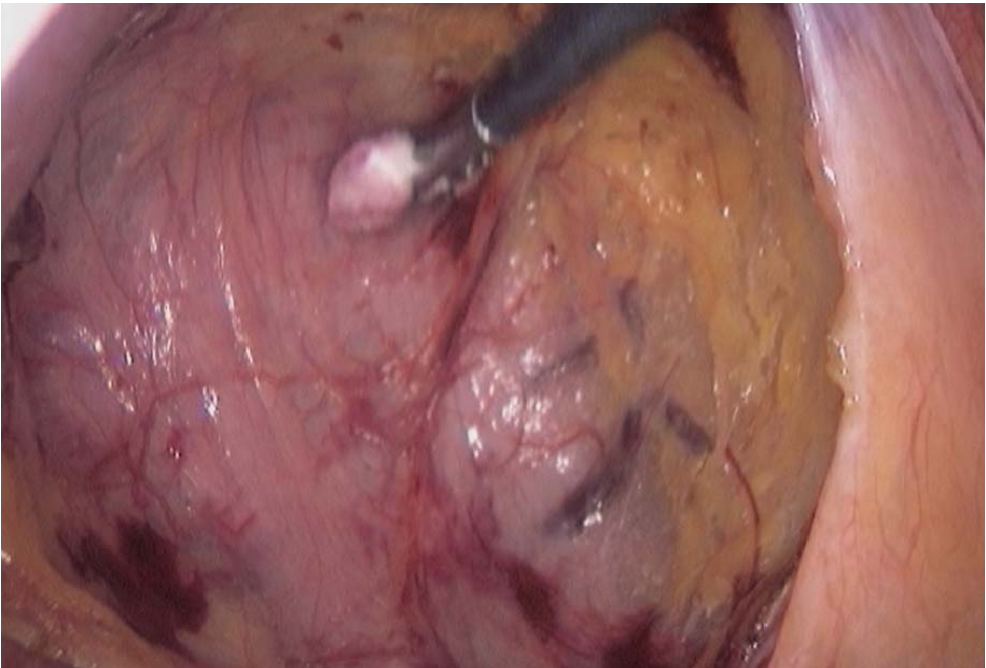
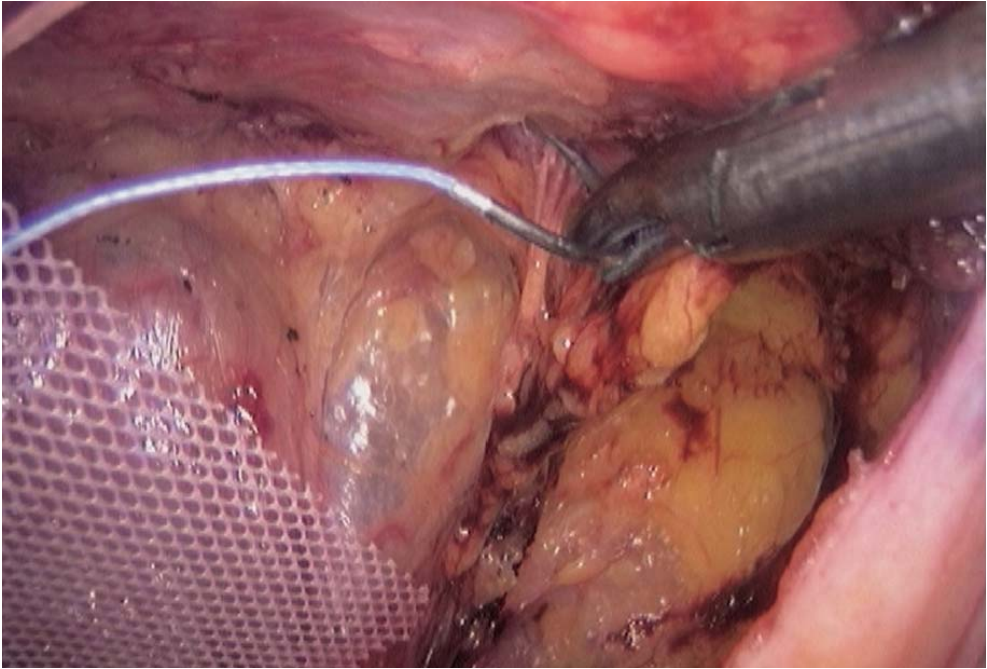
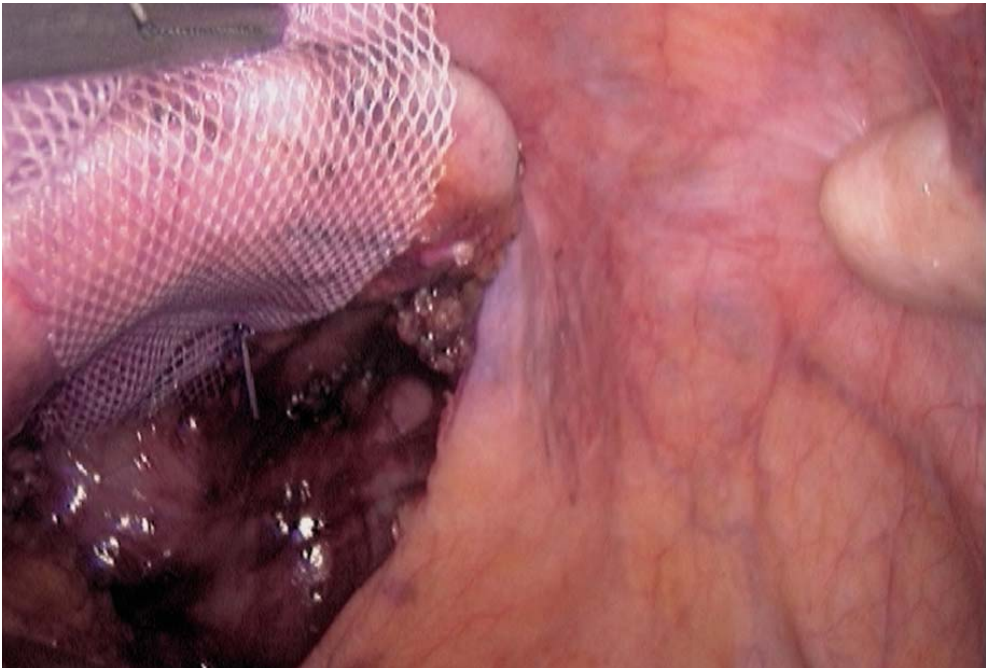


Fig. 15.6. Dissecting the rectum free from posterior vaginal wall





**Fig. 15.7. Low suture of mesh to posterior vaginal wall**



**Fig. 15.8. Suture of mesh to upper part of posterior vaginal wall**



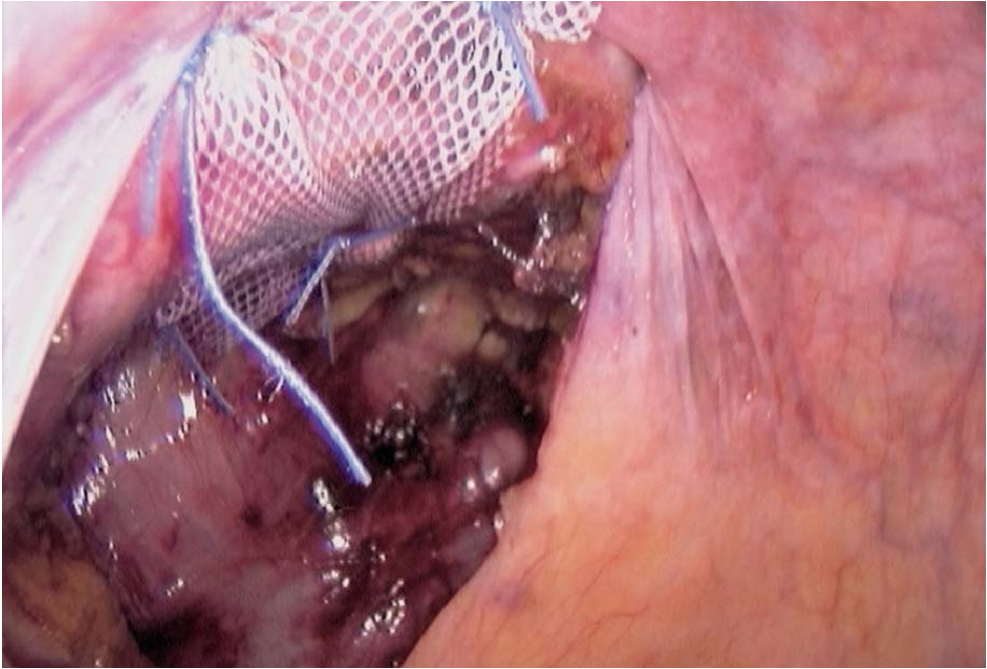


Fig. 15.9. Suture of mesh to vaginal wall completed

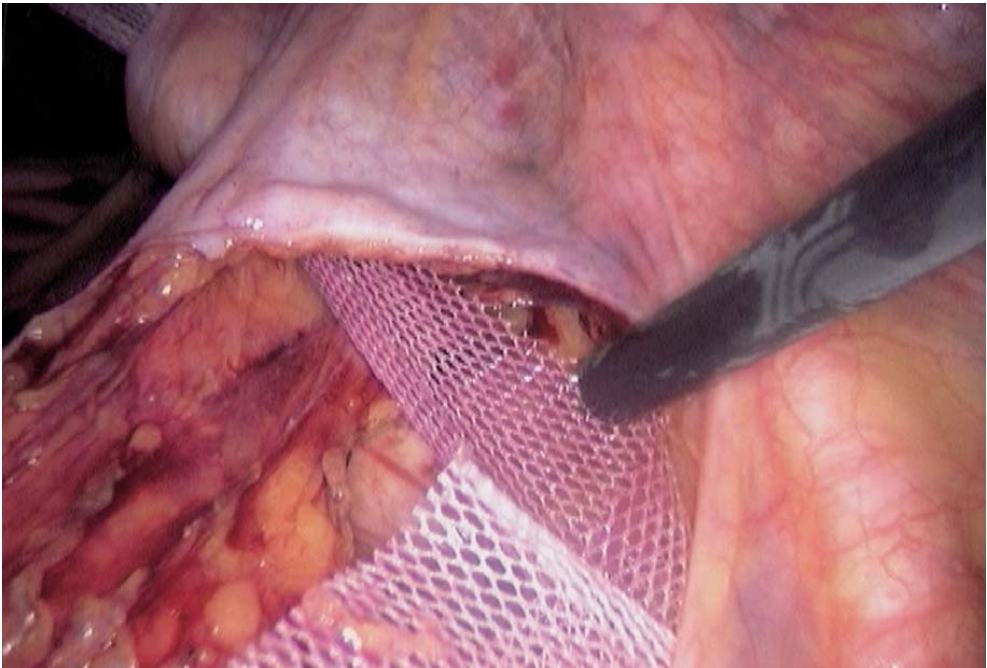


Fig. 15.10. Retroperitoneal tunneling of the mesh

### 15.8 Stapling to the Promontorium and Peritoneal Closure

The mesh is applied at the right tension to the vertebral ligament (◉ Fig. 15.11), and fixed with Taks or separate stitches of nonabsorbable 0 sutures (◉ Fig. 15.12).

Peritoneal closure is performed using absorbable sutures. A suction drainage may be left (◉ Fig. 15.13).

### 15.9 Tips and Comments

- It is sometimes necessary to mobilize the sigmoid colon to obtain proper exposure of the promontorium.
- A very large and fibromatous uterus may render hysterectomy necessary. However, in most cases it is best to keep the uterus.
- An anterior colpopexy may be combined with a posterior colpopexy. A second mesh is then needed.
- Traction on the peritoneum to perform the excision of the Douglas pouch may require an additional, right iliac fossa trocar, for an additional fenestrated forceps.

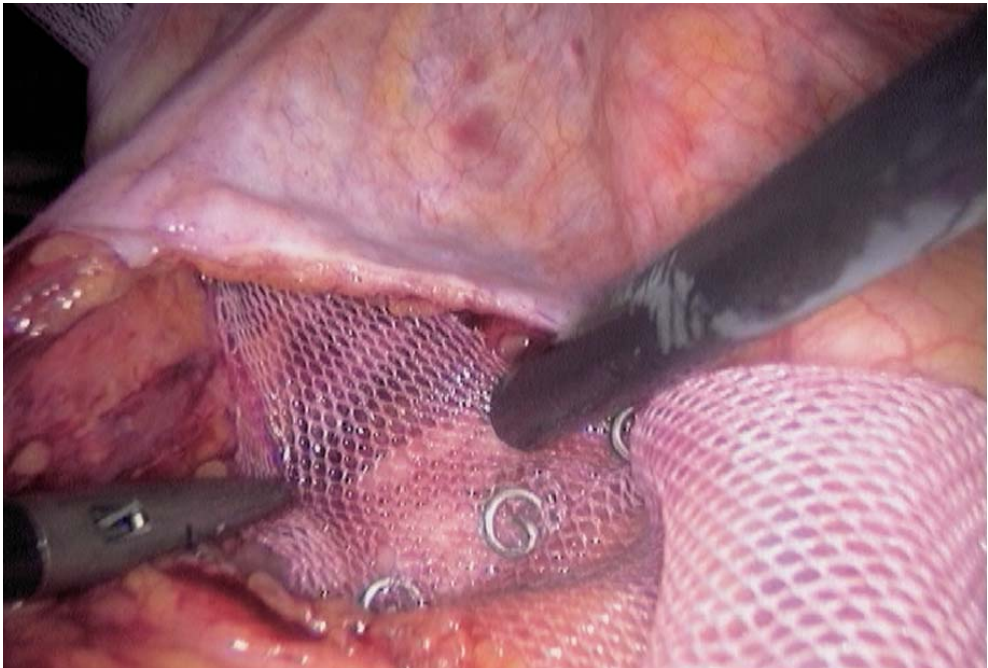


Fig. 15.11. Stapling mesh to promontorium

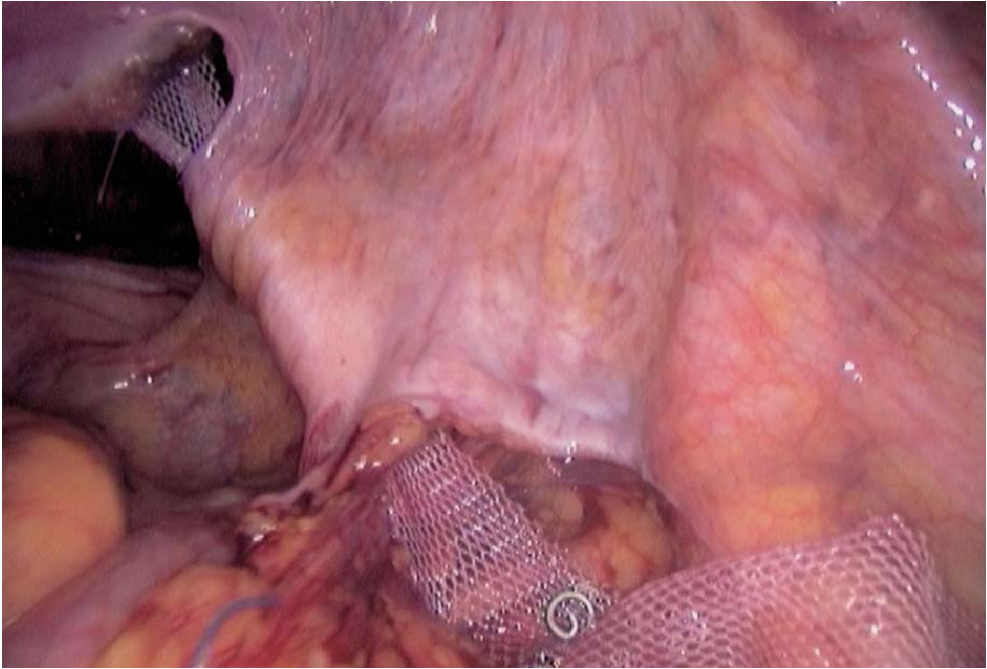


Fig. 15.12. Posterior colpopexy completed

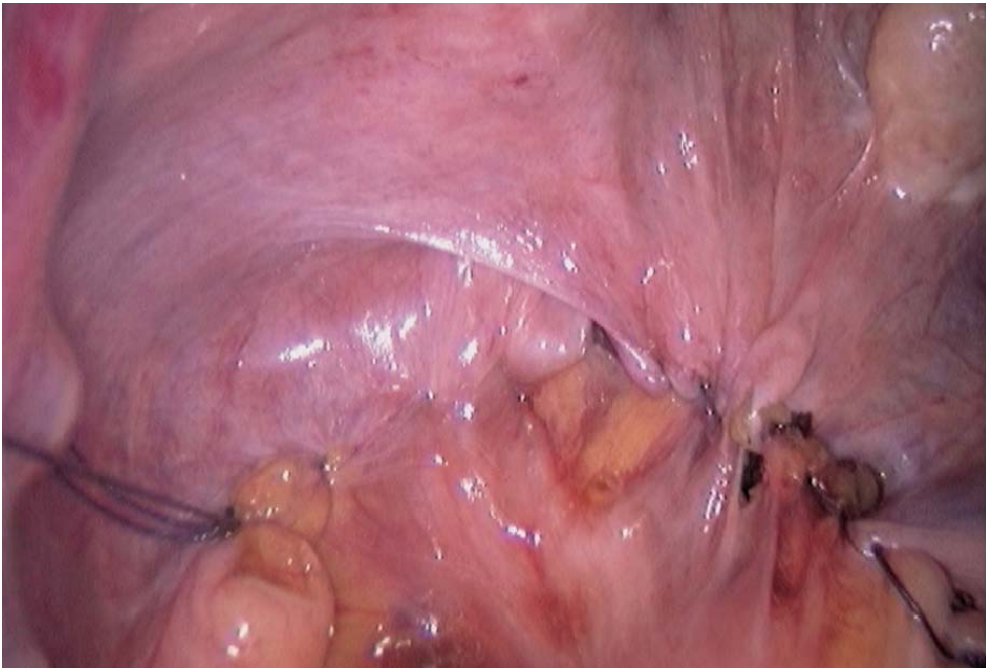

Fig. 15.13. Peritoneal closure completed



- The absence of rectal symptoms requires a posterior colpopexy with an isolated excision of the Douglas pouch. An associated rectal problem, however, may lead to a concurrent rectopexy.
- The proper tension on the mesh can be checked by vaginal examination.
- The extent of the excision of the Douglas pouch may vary. The maintenance of a perirectal collar appears to be essential for the quality of the subsequent peritoneal closure.

## Literature

- Addison WA, Livengood CH, Sutton GP, Parker RT (1985) Abdominal sacral colpopexy with Mer-silene mesh in the retroperitoneal position in the management of posthysterectomy vault pro-lapse and enterocele. *Am J Obstet Gynecol* 153:140–146
- Albala DM, Schluessler WW, Vancaillie T (1992) Laparoscopic bladder suspension for the treatment of stress incontinence. *Semin Urol* 10:22–26
- Blanc B, Luneau F, Boubli L, Bernard Y (1990) L'élytrocèle. A propos de 45 observations. *Mémoire original. Gynécologie, Masson, Paris* 41:171–176
- Brown WE, Hoffman MS, Bouis PL, Ingram JM, Hopes SL (1989) Management of vaginal vault pro-lapse: retrospective comparison of abdominal versus vaginal approach. *J Fla Med Assoc* 76:249–252
- Burch JC (1961) Urethrovaginal fixation to Cooper's ligament for correction of stress incontinence, cystocele and prolapse. *Am J Obstet Gynecol* 81:281–290
- Chapron C, Laforest L, Ansquer Y, Fauconnier A, Fernandez B, Breart G, Dubuisson JB (1999) Hys-terectomy techniques used for benign pathologies: results of a French multicentre study. *Hum Reprod* 14:2464–2470
- Cornier E, Madelenat P (1994) Hystéropexie selon M. Kapandji: technique per coelioscopique et résultats préliminaires. *J Gynecol Obstet Biol Reprod* 23:378–385
- Cravello L, de Montgolfier R, D'Ercole C, Roger V, Blanc B (1997) Endoscopic surgery. The end of classic surgery? [Review] *Eur J Obstet Gynecol Reprod Biol* 75:103–106
- Cuschieri A (1991) Minimal access surgery and the future of interventional laparoscopy. *Obstet Gynecol* 161:404–407
- Cuschieri A, Shimi S, Vander-Velpen G (1994) Laparoscopic prosthesis fixation rectopexy for com-plete rectal prolapse. *Brit J Surg* 81:138–139
- Denoit V, Bigotte A, Miannay E, Cosson M, Querleu D, Crepin G (2000) Burch laparoscopic colposus-pension. Results of 30-month follow-up. *Ann Chir* 125:757–763
- Dorsey JH, Cundiff G (1994) Laparoscopic procedures for incontinence and prolapse. *Curr Opin Obstet Gynecol* 6:223–230
- Drancourt E, Youinou Y, Brandt B, Herard A, Lardennois B (2000) Treatment of female stress urinary incontinence with cystocele by Gore Tex colpofixation and Burch operation. *Prog Urol* 10:211–218
- Glavind K, Mouritsen AL, Pedersen LM, Bek KM (2000) Genital prolapse [Review]. *Ugeskr Laeger* 162:1542–1546
- Harewood LM (1993) Laparoscopic needle colposuspension for genuine stress incontinence. *J Endo Urol* 7:319–322
- Hill D, Maher P, Careh M (1994) Laparoscopic retroperitoneal Burch colposuspension. *Gynaecologic Endoscopists* 1:339–349
- Kriplani A, Banerjee N, Kriplani AK, Roy KK, Takkar D (1998) Uterovaginal prolapse associated with rectal prolapse. *Aust N Z J Obstet Gynaecol* 38:325–326



- Liapis A, Bakas P, Pafiti A, Hassiakos D, Frangos-Plemenos M, Creatsas G (2000) Changes in the quantity of collagen type I in women with genuine stress incontinence. *Urol Res* 28:323–326
- Lim C, Pack W (1993) Laparoscopic retropubic colposuspension (Burch procedure). *J Am Assoc Gynecol Laparosc* 1:31–35
- Liu CY (1994) Laparoscopic treatment for genuine urinary stress incontinence. *Baillere's Clin Obstet Gynecol* 8:789–798
- Liu CY, Reich H (1996) Correction of genital prolapse [Review]. *J Endourol* 10:259–265
- Matysek P (1999) Present views on treatment of genital prolapse. *Ceska Gynekol* 64:390–393
- Moschowitz AV (1912) The pathogenesis, anatomy and cure of prolapse of the rectum. *Sax Gynaecol Obstet* 15:7–21
- Nezhat CH, Nezhat F, Nezhat C (1994) Laparoscopic sacral colpopexy for vaginal vault prolapse. *Obstet Gynecol* 84:885–888
- Nichols DH (1991) Surgery for pelvic floor disorder. *Surg Clin North Am* 71:927–946
- Powell JL, Joseph DB (1998) Abdominal sacral colpopexy for massive genital prolapse. *Prim Care Update Ob Gyns* 5:201
- Querleu D (1994) Cure de prolapsus par voie coelioscopique: chirurgie-fiction. Le pelvis féminin statique et dynamique. *Soc Fr Gynecol* 254–258
- Richardson D, Scotti R, Ostergard D (1989) Surgical management of uterine prolapse in young women. *J Reprod Med* 34:388–392
- Richter K (1967) Die operative behandlung des prolabiertern Scheidengrunders nach uterus-ex-tirpation. Ein bietrage zur vaginaefixation sacrotuberalis nach Amreich. *Geburstsh Frauenheilk* 27:941–954
- Rose CH, Rowe TF, Cox SM, Malinak LR (2000) Uterine prolapse associate with bladder exstrophy: surgical management and subsequent pregnancy. *J Mater Fetal Med* 9:150–152
- Stanton SL, Cardozo LD (1979) A comparison of vaginal and suprapubic surgery in the correction of incontinence due to urethral sphincter incontinence. *Br J Urol* 5:497–499
- Timmons MC, Addison WA, Addison WA, Addison SB, Cavenar MG (1992) Abdominal sacral colpopexy in 163 women with posthysterectomy vaginal vault prolapse and enterocele. Evolution of operative techniques. *J Reprod Med* 37:323–327
- Valaitis SR, Stanton SL (1994) Sacrocolpopexy: a retrospective study of a clinician's experience. *Brit J Obstet Gynecol* 101:518–522
- Van Caillie TG (1994) Laparoscopy in urogynaecology. *Proceedings PGV AAGL* 111–141
- Van Caillie TG, Schuessler W (1991) Laparoscopic bladder neck suspension. *Journal of Laparoendoscopic Surgery* 1:169–173

---

## 16 Laparoscopic Anterior Colpopexy

### 16.1 Operating Room Setup: Position of the Patient

The patient is placed in a 20° Trendelenburg position. The surgeon and the scrub nurse stand on the left side of the patient. The second assistant stands between the patient's legs. The video monitor is positioned at the right of the patient, laterally to the right leg.

The patient is under general anaesthesia with endotracheal intubation. Self-adhesive non-woven drapes are used, with attached bags to hold the instruments.

### 16.2 Recommended Instruments

- Two 10-mm trocars
- Two 5-mm trocars
- Three 5-mm Johann fenestrated grasping forceps
- A 5-mm coagulating scissors
- A straight 5-mm grasping forceps
- A 5- or 10-mm harmonic scalpel
- A 10-mm dissector
- A 5-mm needle holder
- A 0° endoscope

### 16.3 Position of the Trocars and Exposure

The pneumoperitoneum is created with a Veress needle at the lower margin of the umbilicus. A left transrectal trocar is inserted 5 cm outside of the umbilicus for the endoscope. The other operating trocars are inserted after inflation of the abdominal cavity: a 5-mm median suprapubic trocar, a 5-mm left iliac fossa trocar, and a 10-mm trocar at the lower margin of the umbilicus with a 5-mm reducer.

The abdominal cavity is then explored. A 20° Trendelenburg position enables positioning of the small bowel in the upper quadrants of the abdomen. A fenestrated grasping forceps inserted through the suprapubic port progressively exposes the rectosigmoid junction.

#### 16.4 Dissection of the Promontorium

The posterior parietal peritoneum is opened with the coagulating shears longitudinally in line with the promontorium, which is easily identified (▶ Fig. 16.1). A second pre-promontorium layer is opened, enabling the exposure of the vertebral ligament of the promontorium and of its vessels. The dissection is continued laterally (▶ Fig. 16.2).

#### 16.5 Anterior Vaginal Dissection

A vaginal retractor positioned under traction by the second assistant enables the exposure of the anterior vaginal wall (▶ Fig. 16.3). The peritoneum between bladder and vagina is opened medially and transversally with the coagulating shears.

The dissection plane between vagina and bladder is easily identified. The anterior wall of the vagina is freed from its bladder attachments with the coagulating scissors or by blunt dissection (▶ Fig. 16.4). The dissection is continued for 4–5 cm, sometimes even more in case of a large cystocele.

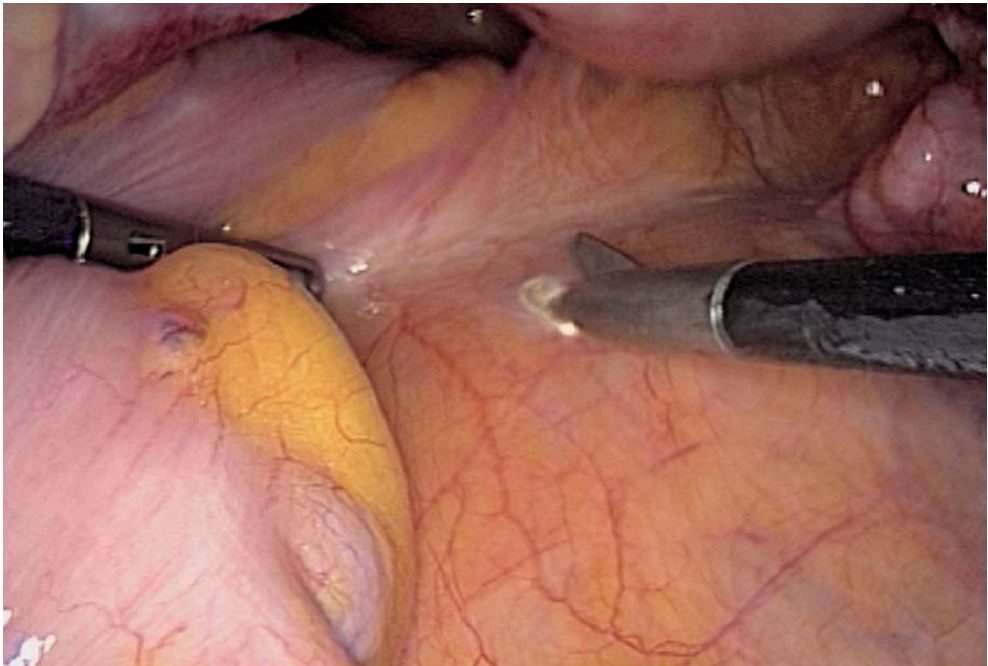


Fig. 16.1. Peritoneal incision on promontorium

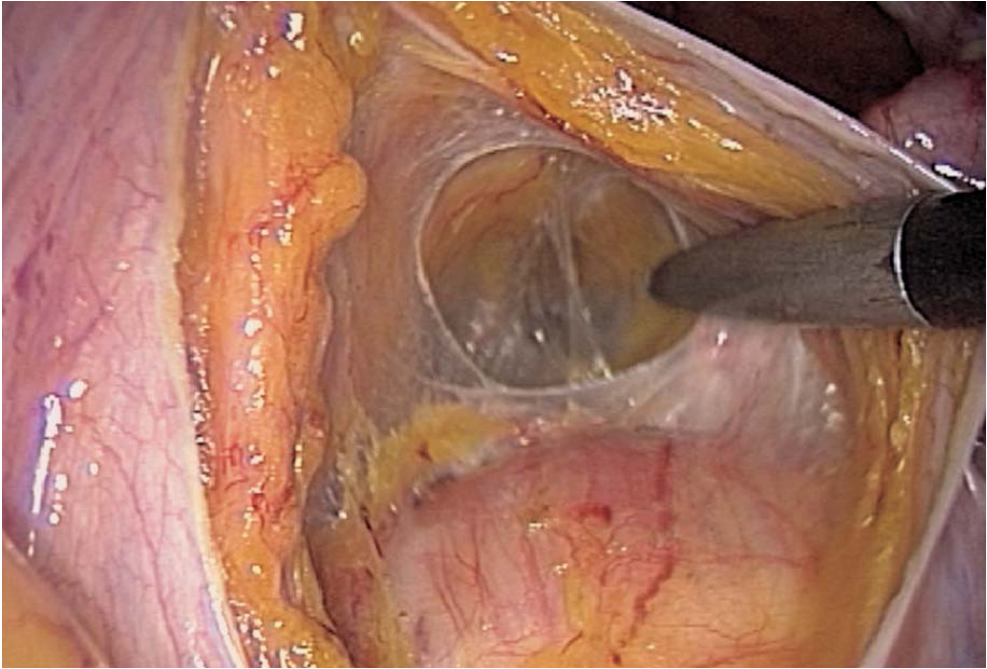


Fig. 16.2. Mesorectal dissection

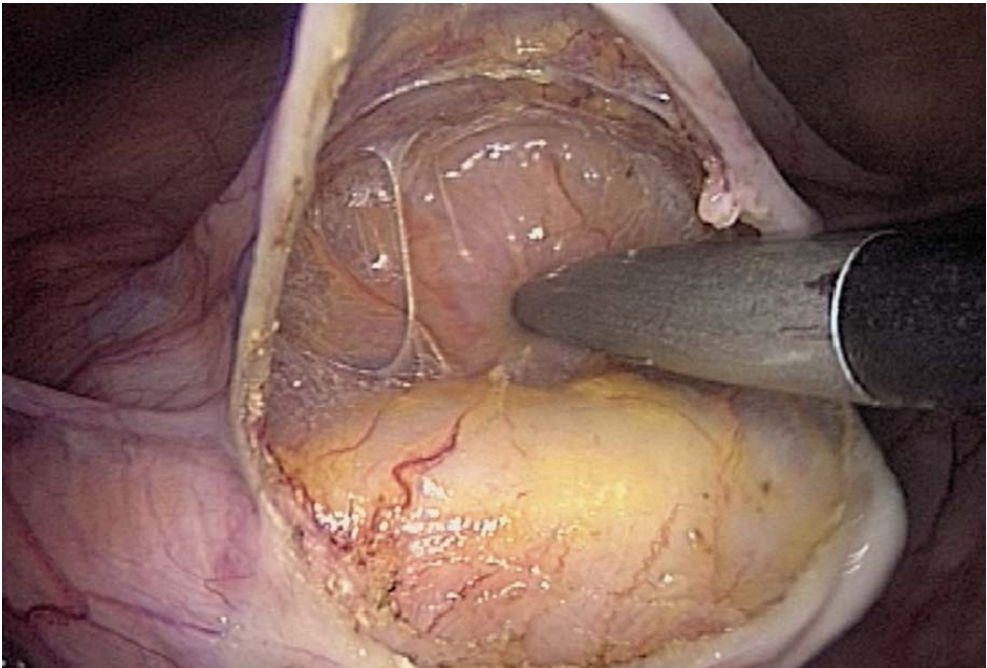


Fig. 16.3. Vaginal retractor lifting anterior vaginal wall



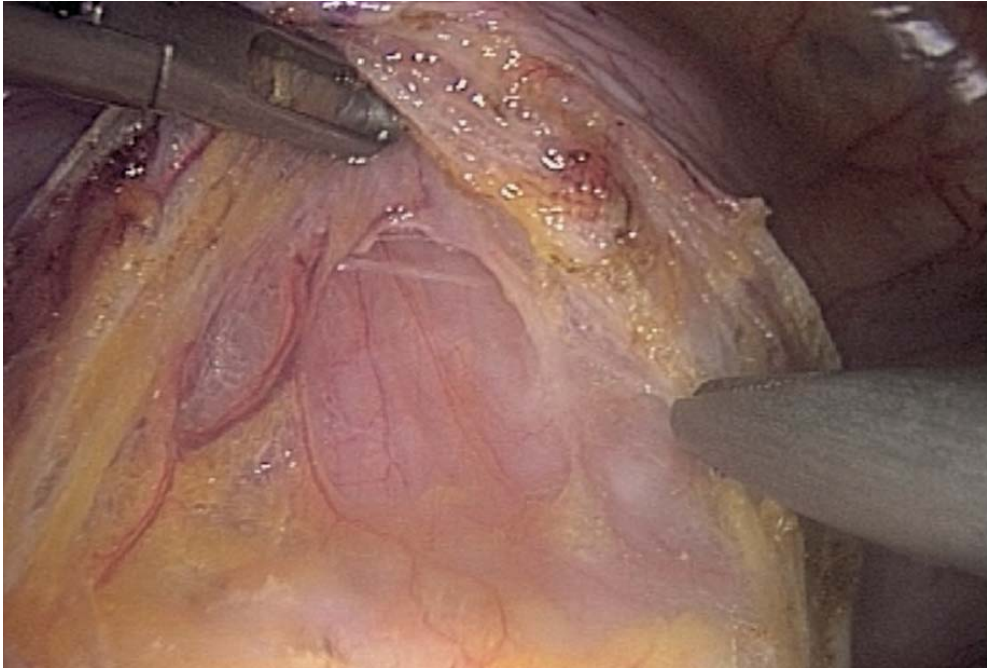


Fig. 16.4. Dissection of anterior vaginal wall

### 16.6 Fixation of the Mesh

A mersilene mesh is fixed to the anterior wall of the vagina and on the cervix and isthmus portion of the uterus, in the presence of a uterus, or, after total hysterectomy, on the remaining cervix.

The mesh and two nonabsorbable sutures with a 16-mm needle are inserted through the 10-mm trocar. A straight grasping forceps is inserted at the level of the left iliac fossa and a 5-mm needle holder is inserted through the umbilical trocar. The mesh is sutured to the anterior vaginal wall with six stitches (▶ Figs. 16.5–16.7). A final deep stitch sutures the mesh to the uterine cervix (◀ Fig. 16.8).

### 16.7 Tunnelling of the Mesh

A 10-mm dissector inserted through the umbilical port is tunnelled under the peritoneum parallel to the right ureter (▶ Figs. 16.9–16.11). The dissector is then passed through the uterine ligament from underneath into the previously dissected plane between bladder and vagina. The mesh is grasped with the dissector and passed through this route back to the promontorium. This step is usually easier after previous hysterectomy. Otherwise, the uterus can be mobilized with vaginal instruments (◀ Fig. 16.12).

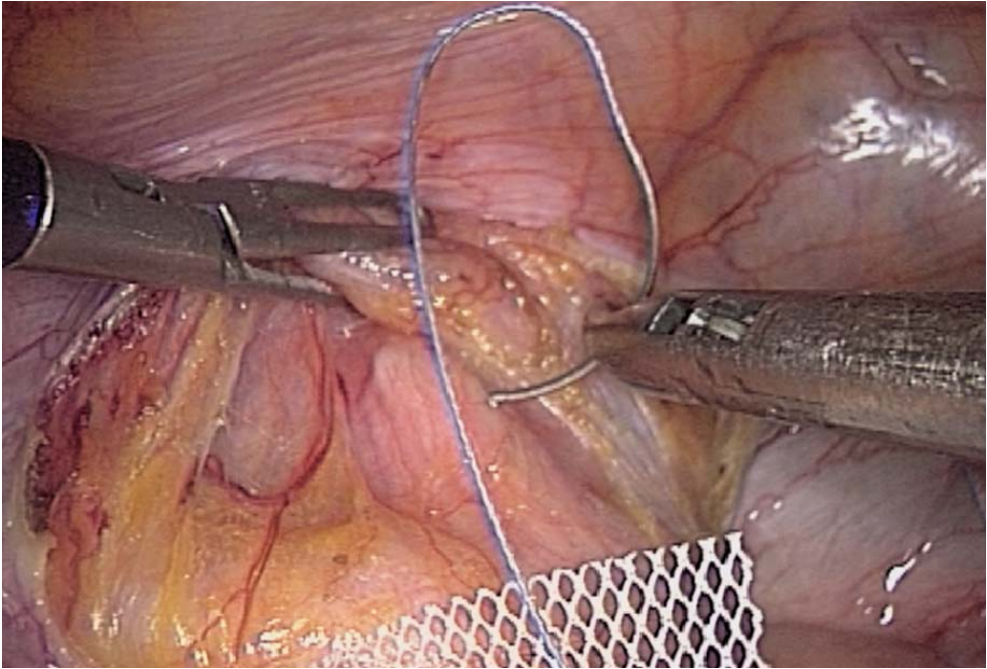


Fig. 16.5. Stitching the anterior vaginal wall

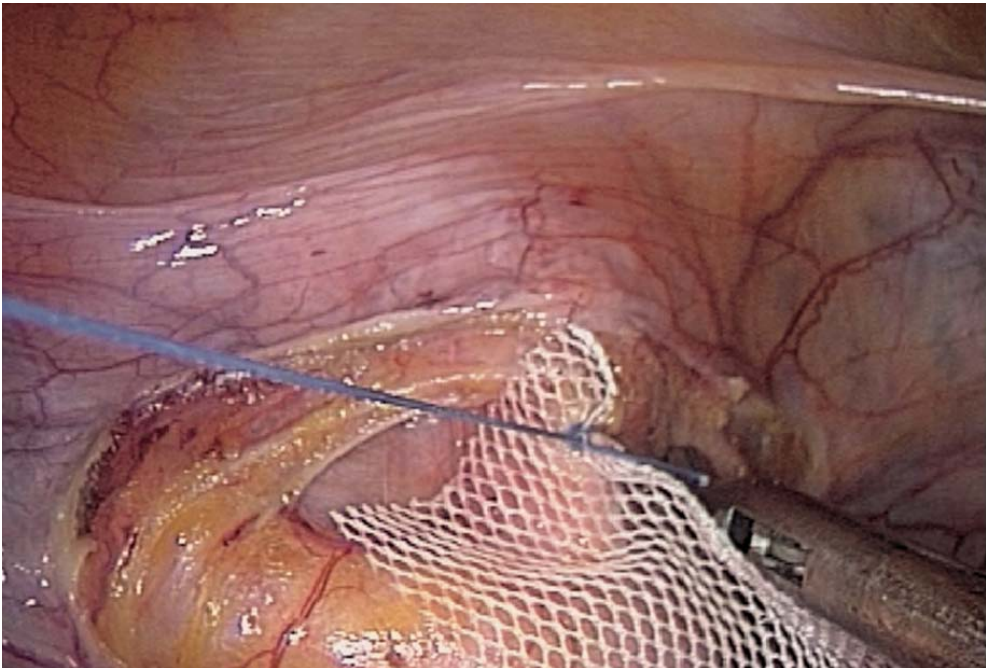


Fig. 16.6. Mesh sutured to the vaginal wall



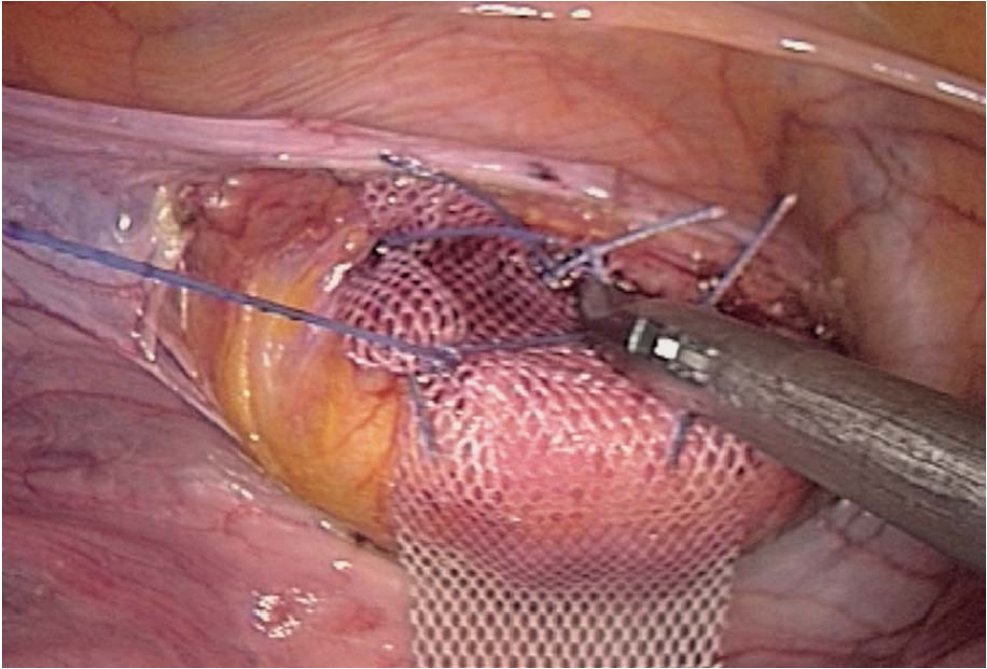


Fig. 16.7. Final suture on anterior vaginal wall

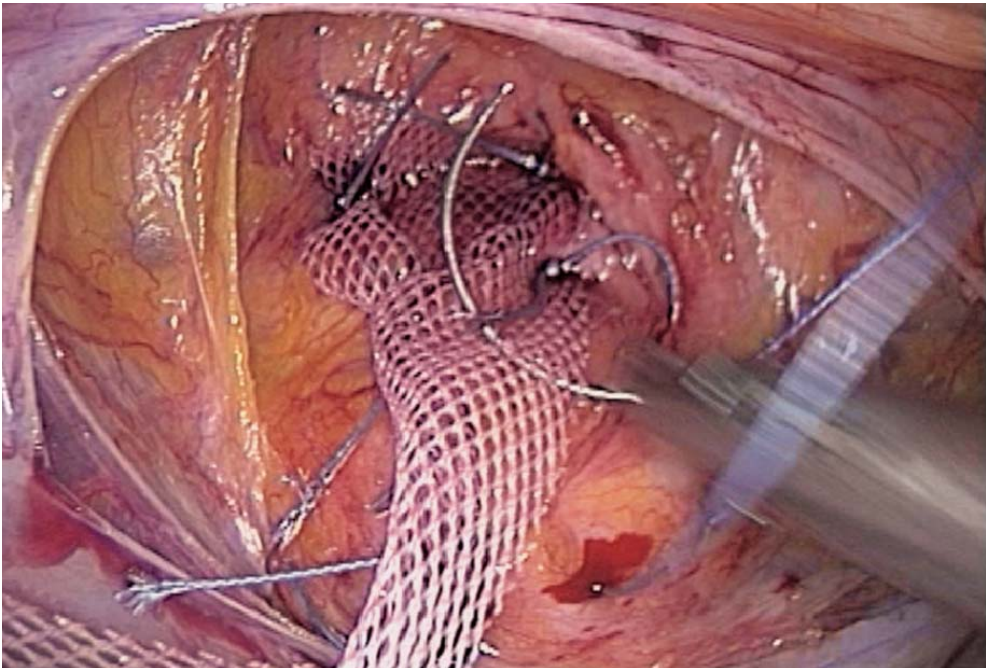


Fig. 16.8. Additional suture on uterine cervix

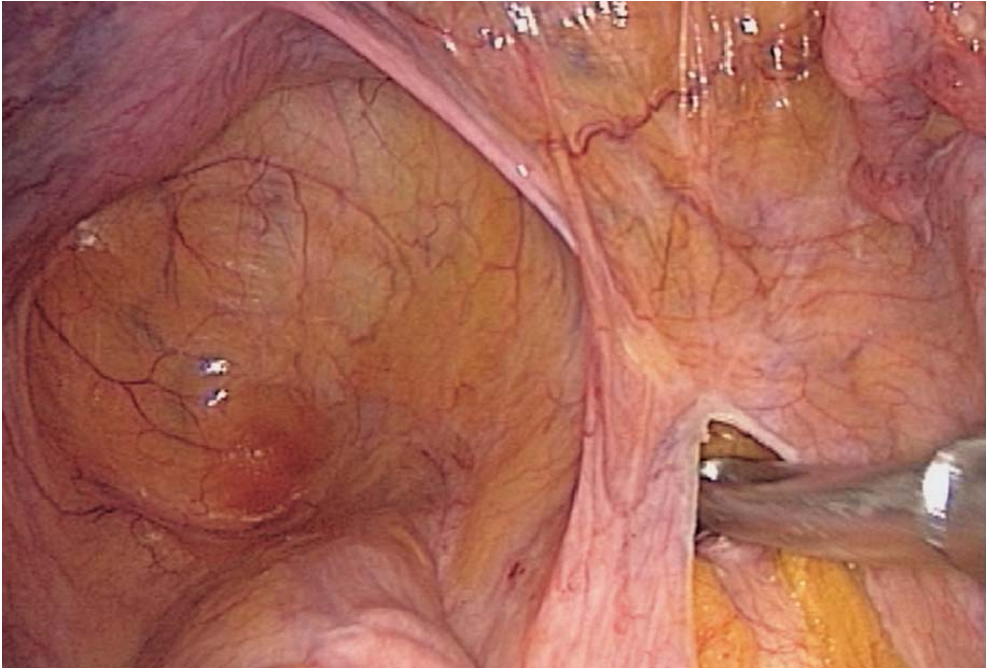


Fig. 16.9. Posterior extraperitoneal tunnelling

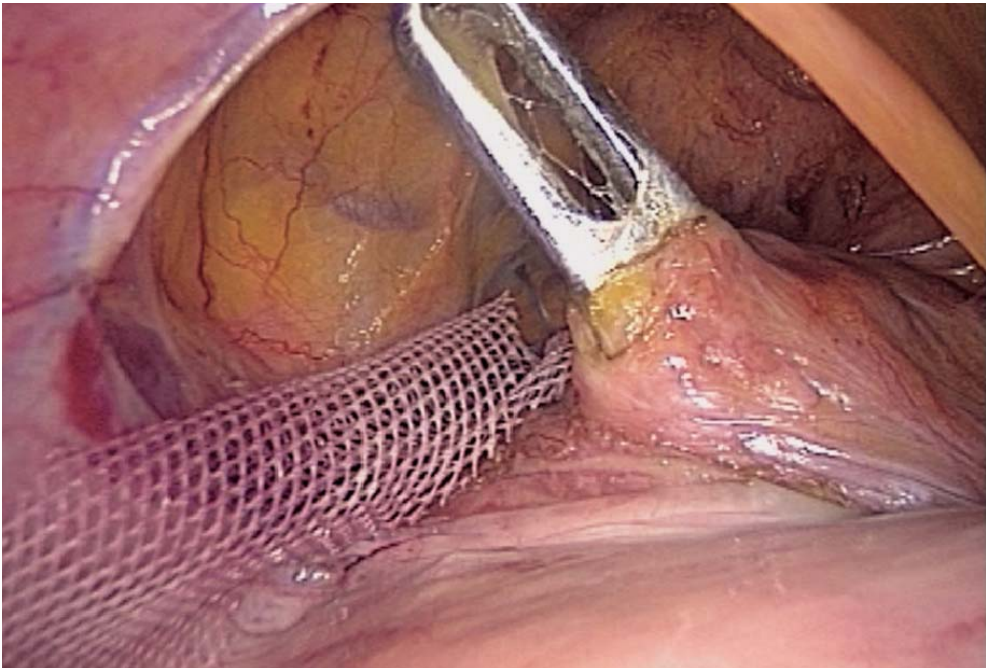


Fig. 16.10. Tunnelling performed with angulating instrument



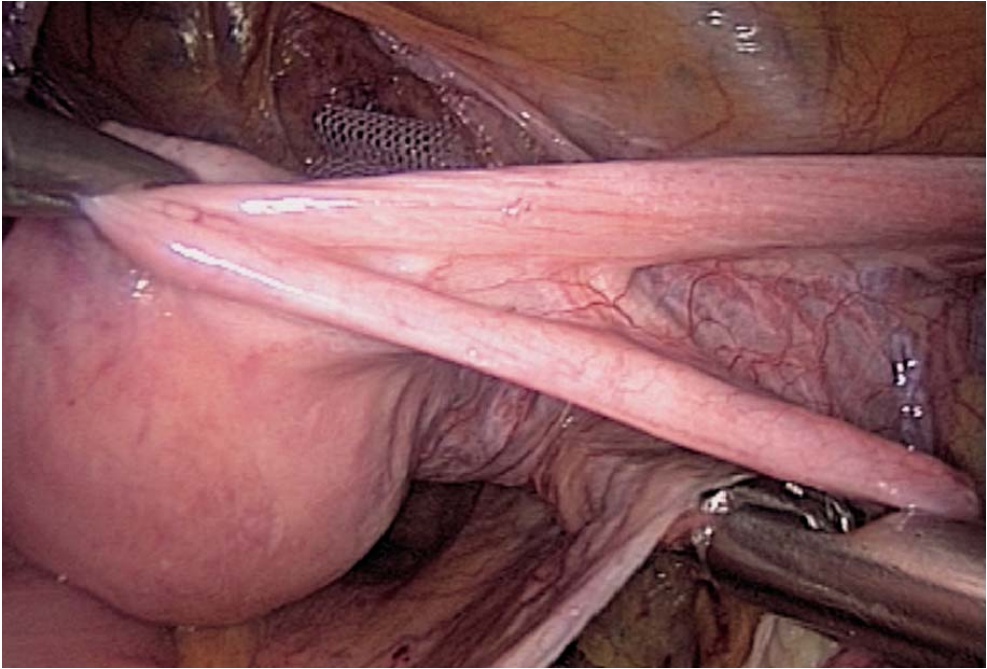


Fig. 16.11. Tunnelling of the mesh

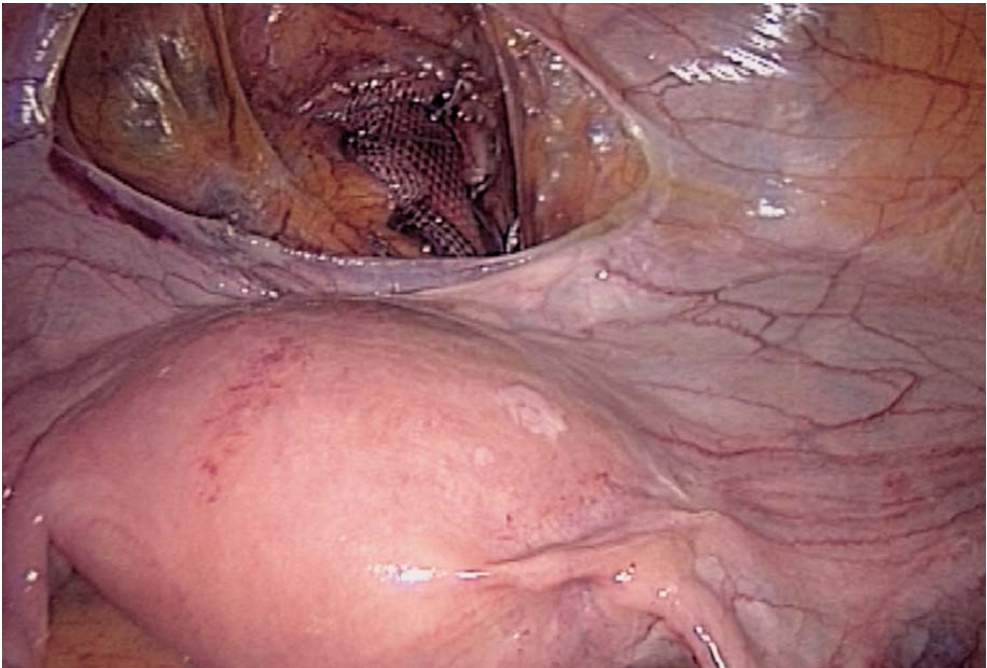


Fig. 16.12. Anterior colpopexy

## 16.8 Stapling to the Promontorium and Peritoneal Closure

The mesh is applied at the right tension to the vertebral ligament, and fixed with helical Taks or with separate stitches of nonabsorbable 0 sutures (◉ Fig. 16.13). Peritoneal closure is performed using absorbable sutures. A suction drainage may be left (◉ Figs. 16.14, 16.15).

## 16.9 Tips and Comments

- It is sometimes necessary to mobilize the sigmoid colon to obtain proper exposure of the promontorium.
- A very large and fibromatous uterus may render hysterectomy necessary. However, in most cases it is best to keep the uterus.
- The mesh should never be stapled to the anterior vaginal wall!
- An anterior colpopexy may be combined with a posterior colpopexy. A second mesh is then needed.
- There tends to be a leftward rotation of the uterus; this can be corrected by plication of the uterine ligament on the right side.

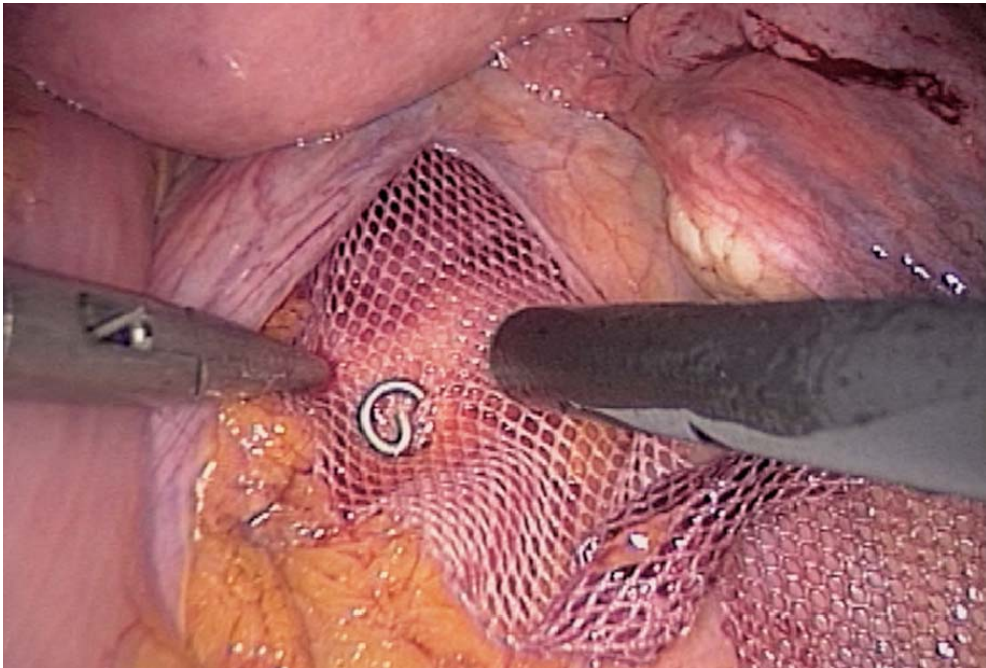


Fig. 16.13. Stapling mesh to vertebral ligament

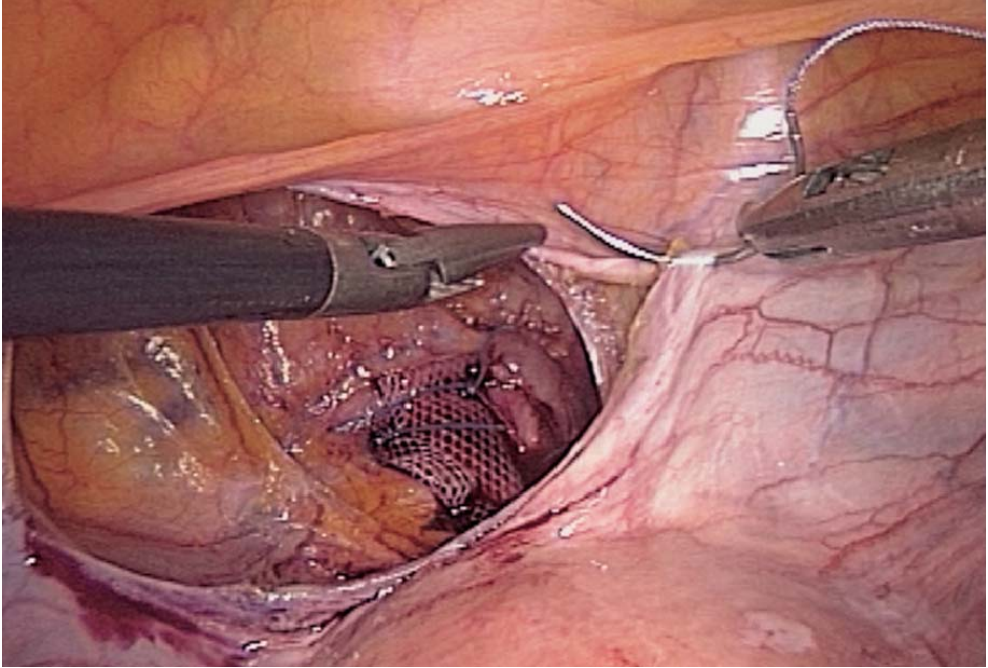


Fig. 16.14. Peritoneal closure

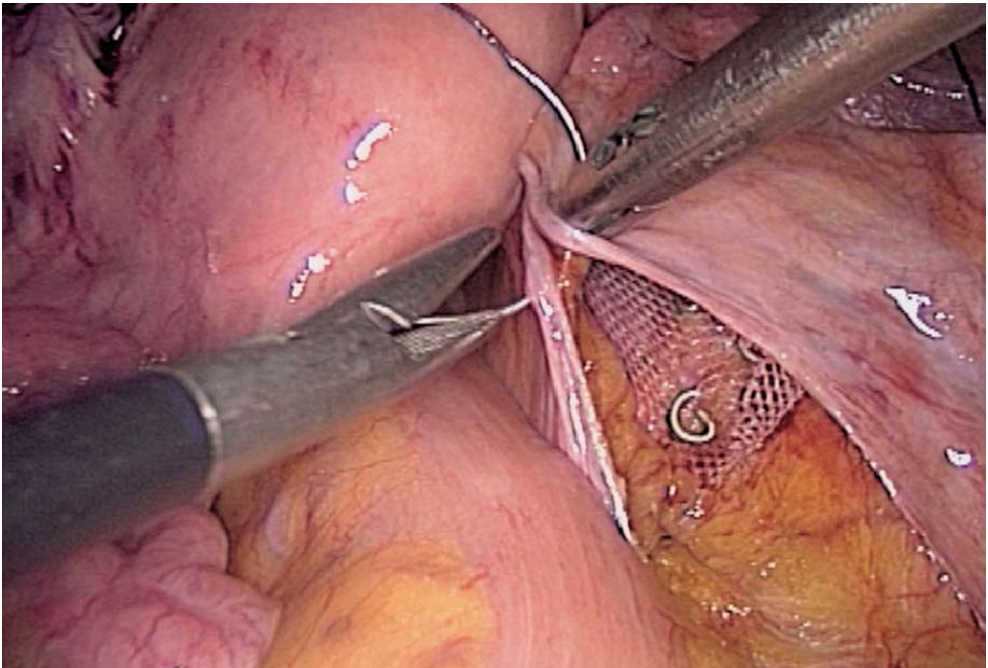


Fig. 16.15. Peritoneal closure on promontorium



- A cervix fixation reduces the posterior rotation of the uterus.
- The right tension to be exerted on the anterior vaginal wall can be assessed by vaginal examination.
- Median sacral arteries and veins should be avoided at the time of stapling or suturing the mesh to the vertebral ligament on the promontorium.

## Literature

- Addison WA, Livengood CH, Sutton GP, Parker RT (1985) Abdominal sacral colpopexy with Mer-silene mesh in the retroperitoneal position in the management of posthysterectomy vault pro-lapse and enterocele. *Am J Obstet Gynecol* 153:140–146
- Albala DM, Schluessler WW, Vancaillie T (1992) Laparoscopic bladder suspension for the treatment of stress incontinence. *Semin Urol* 10:22–26
- Blanc B, Luneau F, Boubli L, Bernard Y (1990) L'élytrocèle. A propos de 45 observations. *Mémoire original. Gynécologie, Masson, Paris* 41:171–176
- Brown WE, Hoffman MS, Bouis PL, Ingram JM, Hopes SL (1989) Management of vaginal vault pro-lapse: retrospective comparison of abdominal versus vaginal approach. *J Fla Med Assoc* 76:249–252
- Burch JC (1961) Urethrovaginal fixation to Cooper's ligament for correction of stress incontinence, cystocele and prolapse. *Am J Obstet Gynecol* 81:281–290
- Chapron C, Laforest L, Ansquer Y, Fauconnier A, Fernandez B, Breart G, Dubuisson JB (1999) Hys-terectomy techniques used for benign pathologies: results of a French multicentre study. *Hum Reprod* 14:2464–2470
- Cornier E, Madelenat P (1994) Hystéropexie selon M. Kapandji: technique per coelioscopique et résultats préliminaires. *J Gynecol Obstet Biol Reprod* 23:378–385
- Cravello L, de Montgolfier R, D'Ercole C, Roger V, Blanc B (1997) Endoscopic surgery. The end of classic surgery? [Review] *Eur J Obstet Gynecol Reprod Biol* 75:103–106
- Cuschieri A (1991) Minimal access surgery and the future of interventional laparoscopy. *Obstet Gynecol* 161:404–407
- Cuschieri A, Shimi S, Vander-Velpen G (1994) Laparoscopic prosthesis fixation rectopexy for com-plete rectal prolapse. *Brit J Surg* 81:138–139
- Denoit V, Bigotte A, Miannay E, Cosson M, Querleu D, Crepin G (2000) Burch laparoscopic colposus-pension. Results of 30-month follow-up. *Ann Chir* 125:757–763
- Dorsey JH, Cundiff G (1994) Laparoscopic procedures for incontinence and prolapse. *Curr Opin Obstet Gynecol* 6:223–230
- Drancourt E, Youinou Y, Brandt B, Herard A, Lardinois B (2000) Treatment of female stress urinary incontinence with cystocele by Gore Tex colpopexy and Burch operation. *Prog Urol* 10:211–218
- Glavind K, Mouritsen AL, Pedersen LM, Bek KM (2000) Genital prolapse [Review]. *Ugeskr Laeger* 162:1542–1546
- Harewood LM (1993) Laparoscopic needle colposuspension for genuine stress incontinence. *J Endo Urol* 7:319–322
- Hill D, Maher P, Careh M (1994) Laparoscopic retroperitoneal Burch colposuspension. *Gynaecologic Endoscopists* 1:339–349
- Kriplani A, Banerjee N, Kriplani AK, Roy KK, Takkar D (1998) Uterovaginal prolapse associated with rectal prolapse. *Aust N Z J Obstet Gynaecol* 38:325–326
- Liapis A, Bakas P, Pafiti A, Hassiakos D, Frangos-Plemenos M, Creatsas G (2000) Changes in the quantity of collagen type I in women with genuine stress incontinence. *Urol Res* 28:323–326



- Lim C, Pack W (1993) Laparoscopic retropubic colposuspension (Burch procedure). *J Am Assoc Gynecol Laparosc* 1:31–35
- Liu CY (1994) Laparoscopic treatment for genuine urinary stress incontinence. *Baillere's Clin Obstet Gynecol* 8:789–798
- Liu CY, Reich H (1996) Correction of genital prolapse [Review]. *J Endourol* 10:259–265
- Matysek P (1999) Present views on treatment of genital prolapse. *Ceska Gynekol* 64:390–393
- Moschowitz AV (1912) The pathogenesis, anatomy and cure of prolapse of the rectum. *Sax Gynaecol Obstet* 15:7–21
- Nezhat CH, Nezhat F, Nezhat C (1994) Laparoscopic sacral colpopexy for vaginal vault prolapse. *Obstet Gynecol* 84:885–888
- Nichols DH (1991) Surgery for pelvic floor disorder. *Surg Clin North Am* 71:927–946
- Powell JL, Joseph DB (1998) Abdominal sacral colpopexy for massive genital prolapse. *Prim Care Update Ob Gyns* 5:201
- Querleu D (1994) Cure de prolapsus par voie coelioscopique: chirurgie-fiction. *Le pelvis féminin statique et dynamique. Soc Fr Gynecol* 254–258
- Richardson D, Scotti R, Ostergard D (1989) Surgical management of uterine prolapse in young women. *J Reprod Med* 34:388–392
- Richter K (1967) Die operative behandlung des prolabiertern Scheidengrunders nach uterus-ex-tirpation. Ein bietrage zur vaginaefixation sacrotuberalis nach Amreich. *Geburstsh Frauenheilk* 27:941–954
- Rose CH, Rowe TF, Cox SM, Malinak LR (2000) Uterine prolapse associate with bladder exstrophy: surgical management and subsequent pregnancy. *J Mater Fetal Med* 9:150–152
- Stanton SL, Cardozo LD (1979) A comparison of vaginal and suprapubic surgery in the correction of incontinence due to urethral sphincter incontinence. *Br J Urol* 5:497–499
- Timmons MC, Addison WA, Addison WA, Addison SB, Cavenar MG (1992) Abdominal sacral colpopexy in 163 women with posthysterectomy vaginal vault prolapse and enterocele. Evolution of operative techniques. *J Reprod Med* 37:323–327
- Valaitis SR, Stanton SL (1994) Sacrocolpopexy: a retrospective study of a clinician's experience. *Brit J Obstet Gynecol* 101:518–522
- Van Caillie TG (1994) Laparoscopy in urogynaecology. *Proceedings PGV AAGL* 111–141
- Van Caillie TG, Schuessler W (1991) Laparoscopic bladder neck suspension. *Journal of Laparoendoscopic Surgery* 1:169–173

---

# 17 Laparoscopic Burch Colposuspension

## 17.1 Operating Room Setup: Position of the Patient

The patient is placed supine in a 20° Trendelenburg position. The surgeon stands to the left of the patient with the scrub nurse to the surgeon's left. The assistant stands between the patient's legs. The abdominal wall and perineal region are prepared. The video monitor is positioned on the patient's right side.

## 17.2 Recommended Instruments

- A 0° endoscope
- Two 10-mm trocars
- Two 5-mm trocars
- Three 5-mm fenestrated grasping forceps
- A 5-mm straight grasping forceps
- A 5-mm needle holder
- A 10-mm dissector
- A 5-mm coagulating shears
- A 5- or 10-mm harmonic scalpel
- Five-millimetre helical staples
- Mersilene mesh
- Nonabsorbable sutures

## 17.3 Position of the Trocars and Exposure

The pneumoperitoneum is created with a Veress needle at the lower margin of the umbilicus. A left transrectal trocar is inserted 5 cm outside of the umbilicus for the endoscope. The other operating trocars are inserted after inflation of the abdominal cavity: a 5-mm median suprapubic trocar, a 5-mm left iliac fossa trocar, and a 10-mm trocar at the lower margin of the umbilicus with a 5-mm reducer.

The abdominal cavity is then explored. A 20° Trendelenburg position enables positioning of the small bowel in the upper quadrants of the abdomen. The remnant of the left umbilical artery is easily identified. The peritoneum is incised lateral to the umbilical artery (▶ Fig. 17.1).

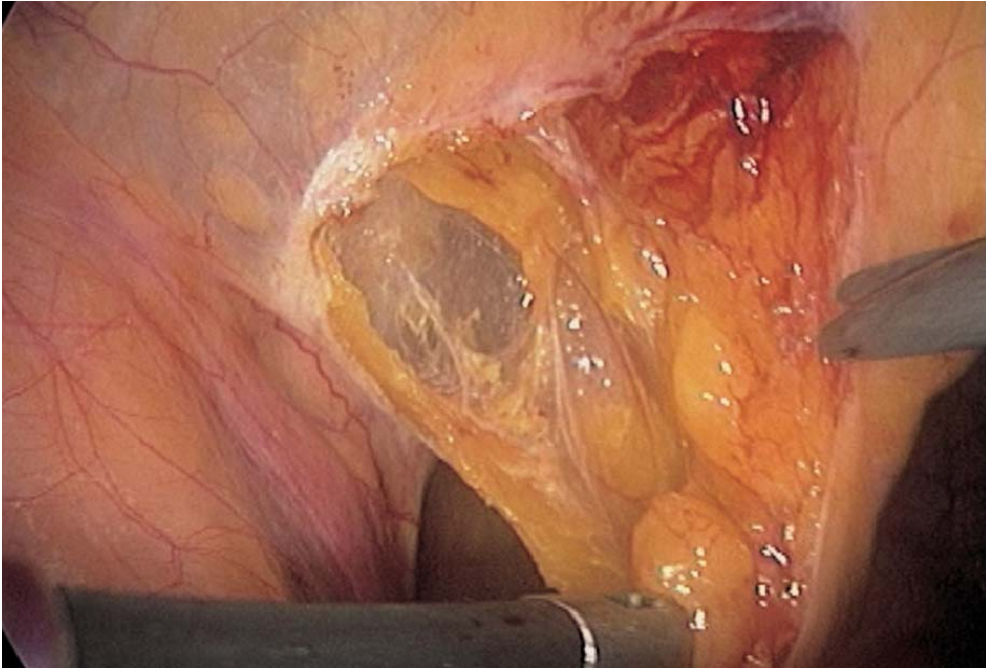


Fig. 17.1. Peritoneal incision left of bladder

#### 17.4 Extraperitoneal Dissection of the Bladder

The peritoneum is incised with the coagulating shears and Retzius' space is opened easily. Cooper's ligament is the first landmark. The pubic bone is exposed. Both Cooper's ligaments are dissected to the base of the femoral canal (➤ Fig. 17.2).

#### 17.5 Lateral Bladder Dissection

A bladder catheter is in place and helps to identify the urethra. The anterior walls of the vagina are carefully dissected laterally, with coagulating shears. The vagina has a whitish appearance (➤ Fig. 17.3).

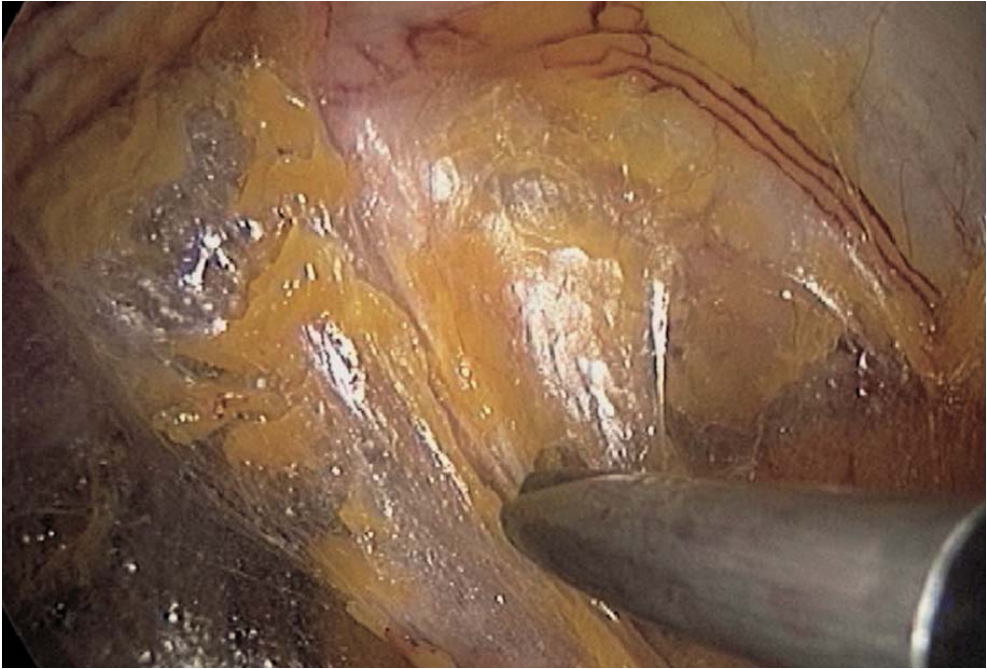

Fig. 17.2. Extraperitoneal dissection of Retzius' space

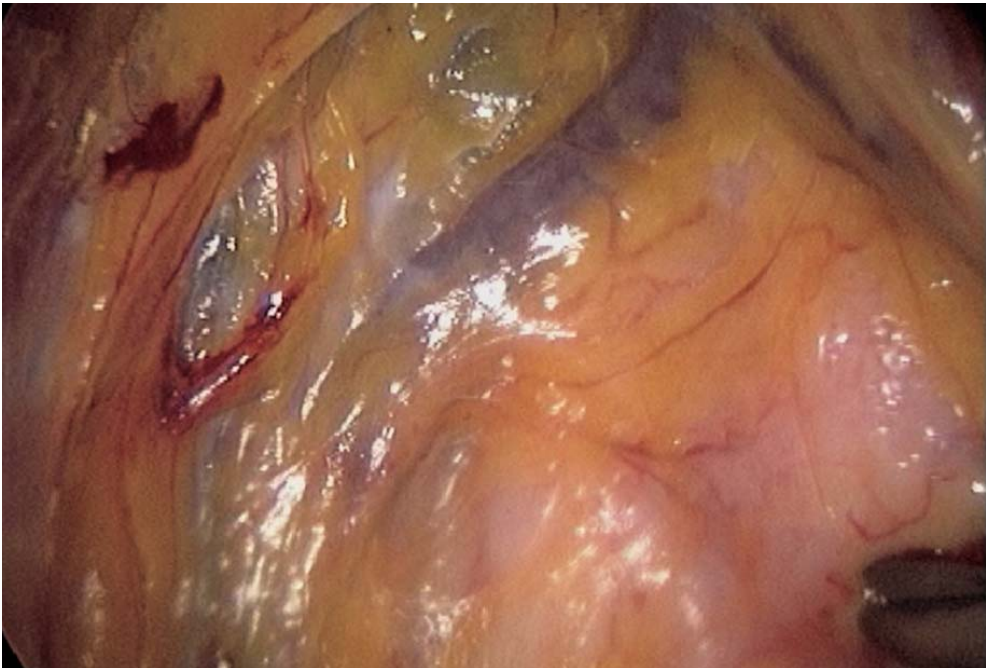


Fig. 17.3. Vaginal wall dissection left of urethra



### 17.6 Mesh Fixation

Two nonabsorbable 2/0 sutures with a 26-mm needle and two mersilene meshes 3×1 cm are introduced. The needle holder is inserted through the umbilical port. Two stitches are placed on both sides laterally to the urethra into the full thickness of the vaginal wall (▶ Figs. 17.4, 17.5). A finger inside the vagina may check the right passing of these stitches. One end of the mesh is sutured to the vaginal wall, on both sides (▶ Figs. 17.6, 17.7). Both meshes should be placed symmetrically.

### 17.7 Mesh Fixation to Cooper's Ligament

Both meshes are then stapled to either Cooper's ligament in turn. The mesh is straightened with a grasping forceps and three helical Taks are applied to Cooper's ligament (▶ Figs. 17.8, 17.9). Proper tension should be given to the mesh, symmetrically on both sides (▶ Figs. 17.10, 17.11).

### 17.8 Peritoneal Closure

The operative field is checked for bleeding and the peritoneum is closed with a running suture (▶ Fig. 17.12).

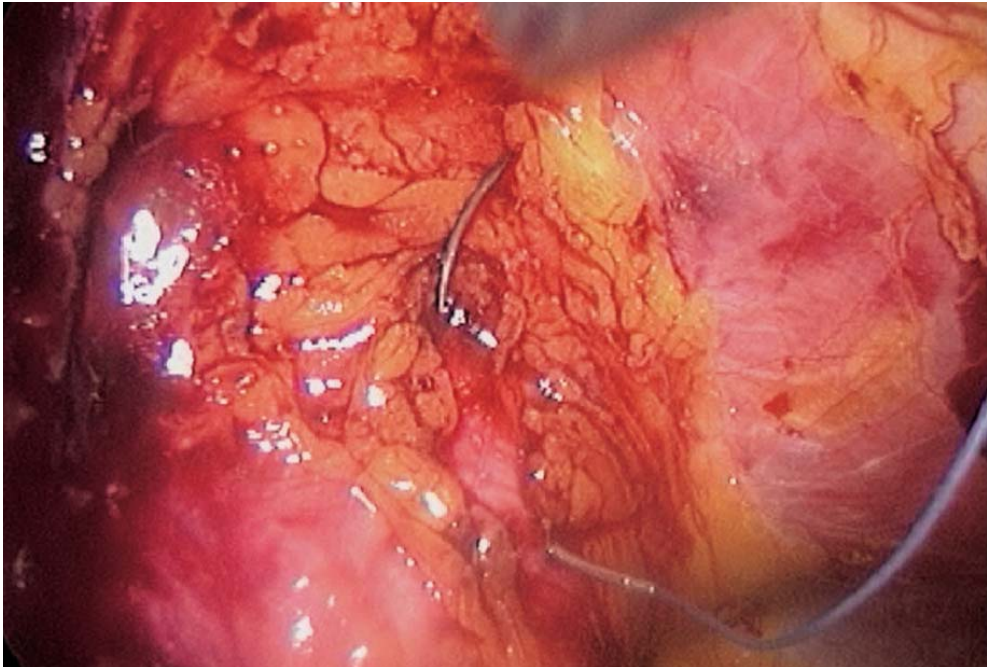


Fig. 17.4. First stitch right to the urethra

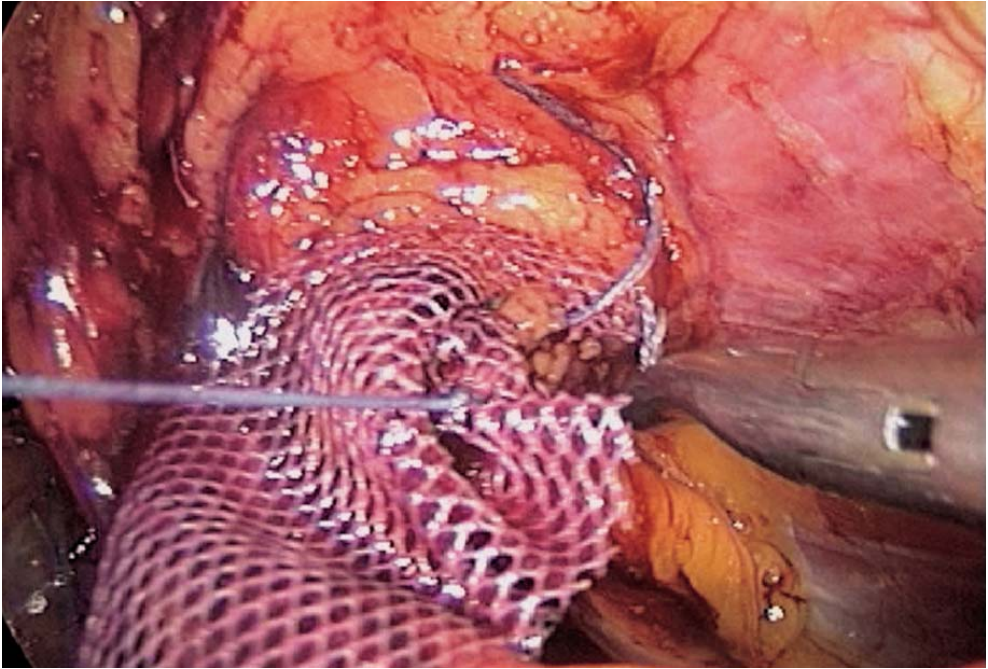


Fig. 17.5. Suturing right-sided mesh

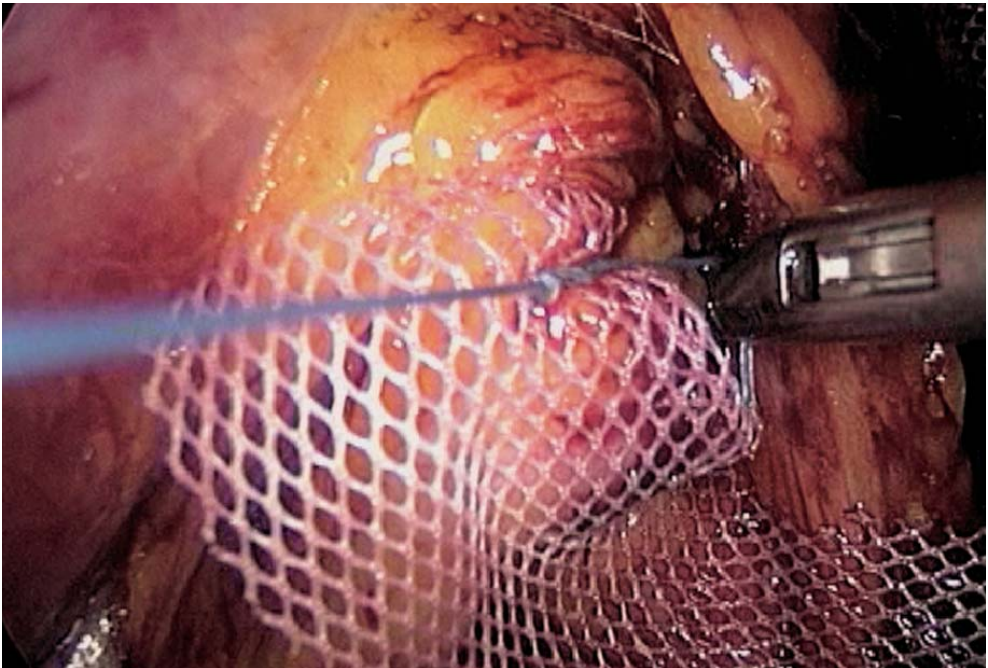


Fig. 17.6. Suturing left-sided mesh



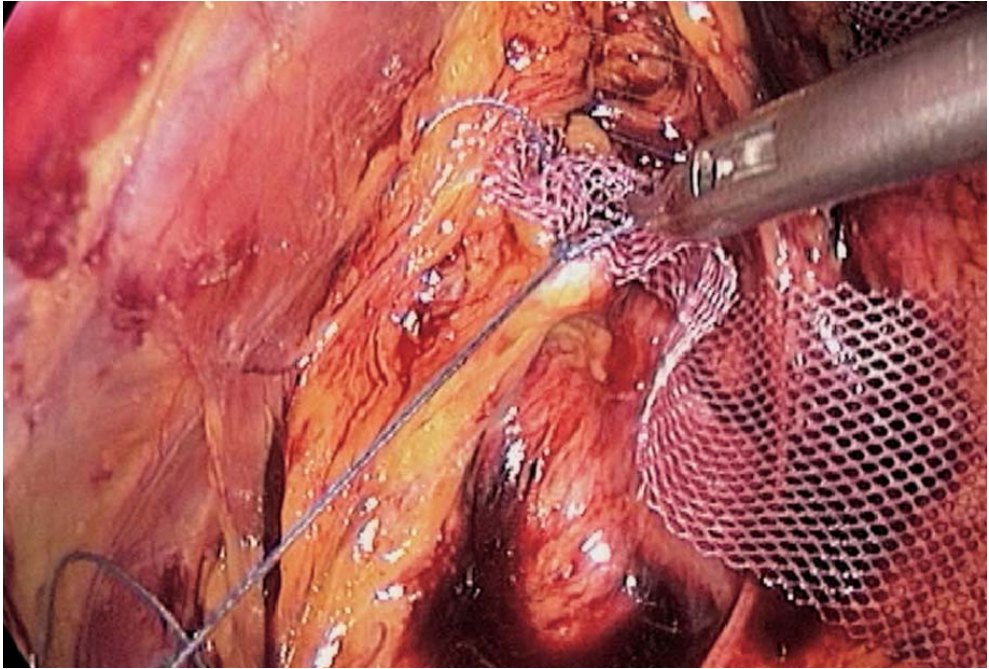


Fig. 17.7. Second stitch on left-sided mesh

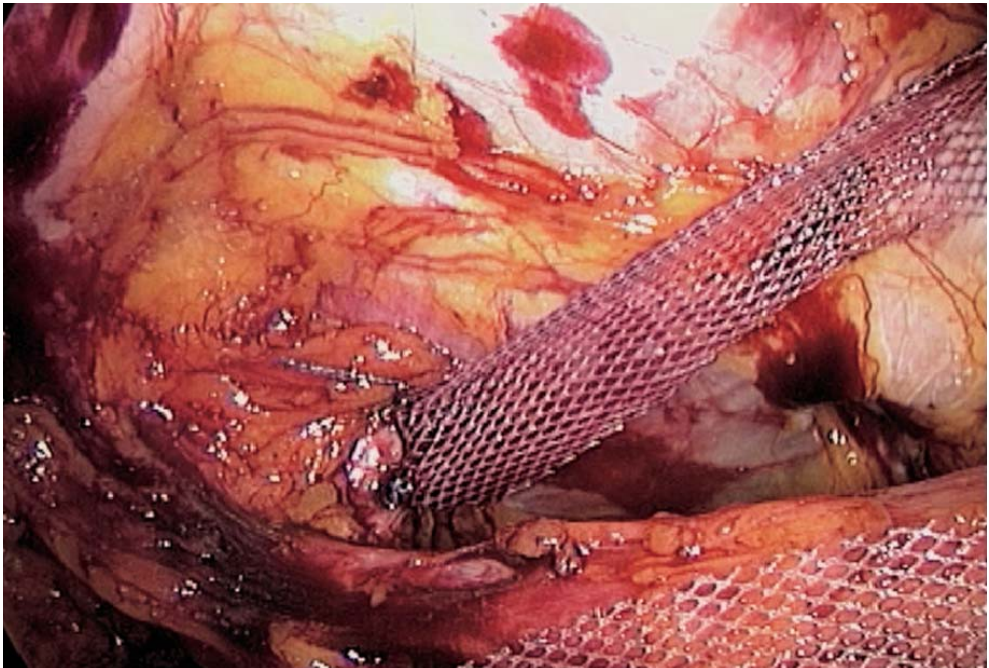


Fig. 17.8. Traction on right-sided mesh

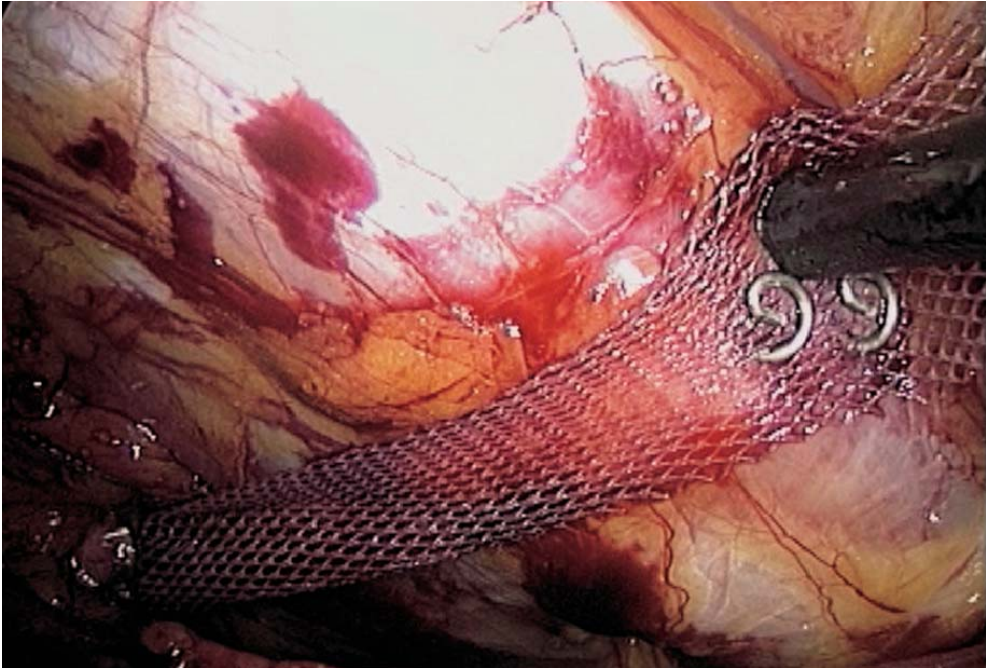


Fig. 17.9. Right mesh stapled to Cooper's ligament

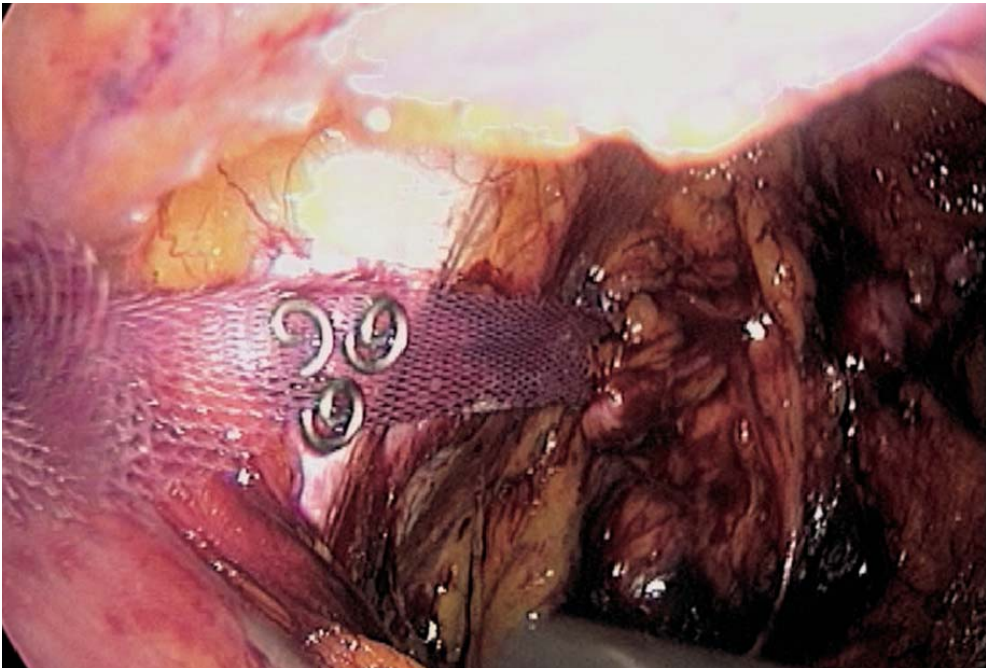


Fig. 17.10. Left-sided mesh stapled to Cooper's ligament



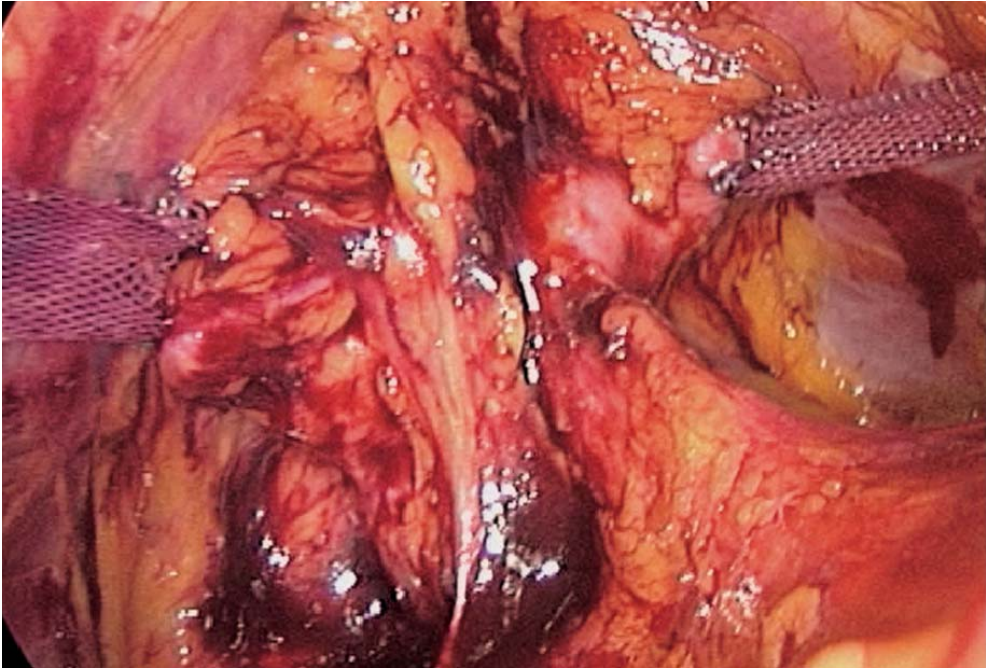


Fig. 17.11. Final result

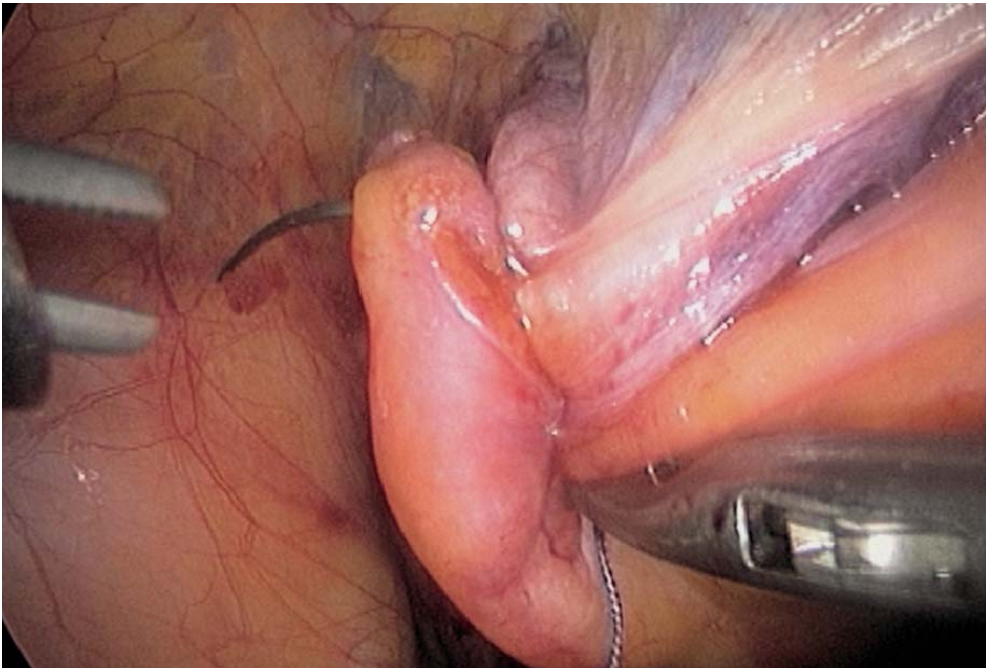


Fig. 17.12. Peritoneal closure

## 17.9 Tips and Comments

- The endoscope in a left lateral position leaves the umbilical port for dissecting and easier suturing, but this peculiar disposure has to be remembered at every step of the procedure.
- An additional stitch can be made higher up on the vaginal surfaces to control any slight cystocele.
- A suction drainage can be left in the extraperitoneal space.
- The bladder catheter is left in place for 24 h.
- The vertical opening peritoneum leaves the bladder in place and facilitates closing.
- The tension on the meshes must be perfectly symmetrical.

## Literature

- Addison WA, Livengood CH, Sutton GP, Parker RT (1985) Abdominal sacral colpopexy with Mersilene mesh in the retroperitoneal position in the management of posthysterectomy vault prolapse and enterocele. *Am J Obstet Gynecol* 153:140–146
- Albala DM, Schluessler WW, Vancaillie T (1992) Laparoscopic bladder suspension for the treatment of stress incontinence. *Semin Urol* 10:22–26
- Blanc B, Luneau F, Boubli L, Bernard Y (1990) L'élytrocèle. A propos de 45 observations. *Mémoire original. Gynécologie, Masson, Paris* 41:171–176
- Brown WE, Hoffman MS, Bouis PL, Ingram JM, Hopes SL (1989) Management of vaginal vault prolapse: retrospective comparison of abdominal versus vaginal approach. *J Fla Med Assoc* 76:249–252
- Burch JC (1961) Urethrovaginal fixation to Cooper's ligament for correction of stress incontinence, cystocele and prolapse. *Am J Obstet Gynecol* 81:281–290
- Chapron C, Laforest L, Ansquer Y, Fauconnier A, Fernandez B, Breart G, Dubuisson JB (1999) Hysterectomy techniques used for benign pathologies: results of a French multicentre study. *Hum Reprod* 14:2464–2470
- Cornier E, Madelenat P (1994) Hystéropexie selon M. Kapandji: technique per coelioscopique et résultats préliminaires. *J Gynecol Obstet Biol Reprod* 23:378–385
- Cravello L, de Montgolfier R, D'Ercole C, Roger V, Blanc B (1997) Endoscopic surgery. The end of classic surgery? [Review] *Eur J Obstet Gynecol Reprod Biol* 75:103–106
- Cuschieri A (1991) Minimal access surgery and the future of interventional laparoscopy. *Obstet Gynecol* 161:404–407
- Cuschieri A, Shimi S, Vander-Velpen G (1994) Laparoscopic prosthesis fixation rectopexy for complete rectal prolapse. *Brit J Surg* 81:138–139
- Denoit V, Bigotte A, Miannay E, Cosson M, Querleu D, Crepin G (2000) Burch laparoscopic colposuspension. Results of 30-month follow-up. *Ann Chir* 125:757–763
- Dorsey JH, Cundiff G (1994) Laparoscopic procedures for incontinence and prolapse. *Curr Opin Obstet Gynecol* 6:223–230
- Drancourt E, Youinou Y, Brandt B, Herard A, Lardennois B (2000) Treatment of female stress urinary incontinence with cystocele by Gore Tex colpopexy and Burch operation. *Prog Urol* 10:211–218
- Glavind K, Mouritsen AL, Pedersen LM, Bek KM (2000) Genital prolapse [Review]. *Ugeskr Laeger* 162:1542–1546

- Harewood LM (1993) Laparoscopic needle colposuspension for genuine stress incontinence. *J Endourol* 7:319–322
- Hill D, Maher P, Careh M (1994) Laparoscopic retroperitoneal Burch colposuspension. *Gynaecologic Endoscopists* 1:339–349
- Kriplani A, Banerjee N, Kriplani AK, Roy KK, Takkar D (1998) Uterovaginal prolapse associated with rectal prolapse. *Aust N Z J Obstet Gynaecol* 38:325–326
- Liapis A, Bakas P, Pafiti A, Hassiakos D, Frangos-Plemenos M, Creatsas G (2000) Changes in the quantity of collagen type I in women with genuine stress incontinence. *Urol Res* 28:323–326
- Lim C, Pack W (1993) Laparoscopic retropubic colposuspension (Burch procedure). *J Am Assoc Gynecol Laparosc* 1:31–35
- Liu CY (1994) Laparoscopic treatment for genuine urinary stress incontinence. *Baillere's Clin Obstet Gynecol* 8:789–798
- Liu CY, Reich H (1996) Correction of genital prolapse [Review]. *J Endourol* 10:259–265
- Matysek P (1999) Present views on treatment of genital prolapse. *Ceska Gynecol* 64:390–393
- Moschowitz AV (1912) The pathogenesis, anatomy and cure of prolapse of the rectum. *Sax Gynaecol Obstet* 15:7–21
- Nezhat CH, Nezhat F, Nezhat C (1994) Laparoscopic sacral colpopexy for vaginal vault prolapse. *Obstet Gynecol* 84:885–888
- Nichols DH (1991) Surgery for pelvic floor disorder. *Surg Clin North Am* 71:927–946
- Powell JL, Joseph DB (1998) Abdominal sacral colpopexy for massive genital prolapse. *Prim Care Update Ob Gyns* 5:201
- Querleu D (1994) Cure de prolapsus par voie coelioscopique: chirurgie-fiction. Le pelvis féminin statique et dynamique. *Soc Fr Gynecol* 254–258
- Richardson D, Scotti R, Ostergard D (1989) Surgical management of uterine prolapse in young women. *J Reprod Med* 34:388–392
- Richter K (1967) Die operative Behandlung des prolabierten Scheidengrundes nach Uterusextirpation. Ein Beitrag zur Vaginalfixation sacrotuberalis nach Amreich. *Geburstsh Frauenheilk* 27:941–954
- Rose CH, Rowe TF, Cox SM, Malinak LR (2000) Uterine prolapse associated with bladder exstrophy: surgical management and subsequent pregnancy. *J Mater Fetal Med* 9:150–152
- Stanton SL, Cardozo LD (1979) A comparison of vaginal and suprapubic surgery in the correction of incontinence due to urethral sphincter incontinence. *Br J Urol* 5:497–499
- Timmons MC, Addison WA, Addison WA, Addison SB, Cavenar MG (1992) Abdominal sacral colpopexy in 163 women with posthysterectomy vaginal vault prolapse and enterocele. Evolution of operative techniques. *J Reprod Med* 37:323–327
- Valaitis SR, Stanton SL (1994) Sacrocolpopexy: a retrospective study of a clinician's experience. *Brit J Obstet Gynecol* 101:518–522
- Van Caillie TG (1994) Laparoscopy in urogynaecology. *Proceedings PGV AAGL* 111–141
- Van Caillie TG, Schuessler W (1991) Laparoscopic bladder neck suspension. *J Laparoendosc Surg* 1:169–173

---

# Subject Index

## A

access port 73  
achalasia 77  
adrenal vein 192, 194, 204  
adrenalectomy 189, 203  
appendectomy 103

## B

band 62, 64–66, 68–71  
bladder 234  
burch 233

## C

Calot's triangle 4, 10, 11, 24, 25  
cholangiography 7, 8, 26–28  
cholangioscopy 29, 32–34  
cholecystectomy 10, 12, 13, 35, 37  
choledocholithotomy 28  
choledochotomy 28–30, 35  
colorectal anastomosis 134  
colpopexy 209, 217, 221, 228  
Cooper's ligament 172, 173, 179, 236, 239  
cystic duct 4–8

## D

Douglas pouch 155, 156, 165, 213  
Douglassectomy 155, 165

## E

epigastric vessel 174

## F

fundoplication 41  
fundus 49

## G

gallbladder 4, 12, 25, 35, 38

## H

heller 77  
hepatic flexure 138, 141, 190  
hernia  
– repair 171  
– sac 174, 176–178

## I

ileal J-pouch 149  
ileocaecal vessel 142, 143  
ileostomy 149  
ileotransverse anastomosis 145, 146  
inferior mesenteric vessel 122, 125

## L

lateral ligament 156  
left colectomy 119, 126, 149  
lithotripsy 29

## M

mesh 158, 160, 162, 179, 214, 215, 224, 228, 236  
– 3-D mesh 179, 181–184  
mesorectal excision 128, 132  
mesorectum 128, 132, 156  
morbid obesity 57  
myotomy 81, 84, 85



**N**

Nissen 41, 54, 55

**O**

orr loygue 153, 158

**P**

pancreas 126, 142

promontorium 160, 165, 210, 216,  
222, 229

psoas muscle 174, 179

**R**

rectal

– prolapse 153

– resection 149

rectopexy 153

rectum 153

renal vein 191, 192, 194, 204

Retzius' space 172, 235

right colectomy 137, 149

right colic vessel 142, 144

**S**

short gastric vessel 49, 93, 95, 96

spermatic vessel 176

splenectomy 91

splenic

– artery 92

– flexure 93, 126, 128

– vein 92, 95

stapling 111–113

**T**

TEPA 171

total volectomy 149

Toupet 41, 52–54

**U**

ultrasound 7, 9

ureter 122, 156, 160

**V**

vagus 82

– nerve 47, 48, 54

vas deferens 176

vena cava 190, 191, 194, 196

**W**

Wells 153, 162