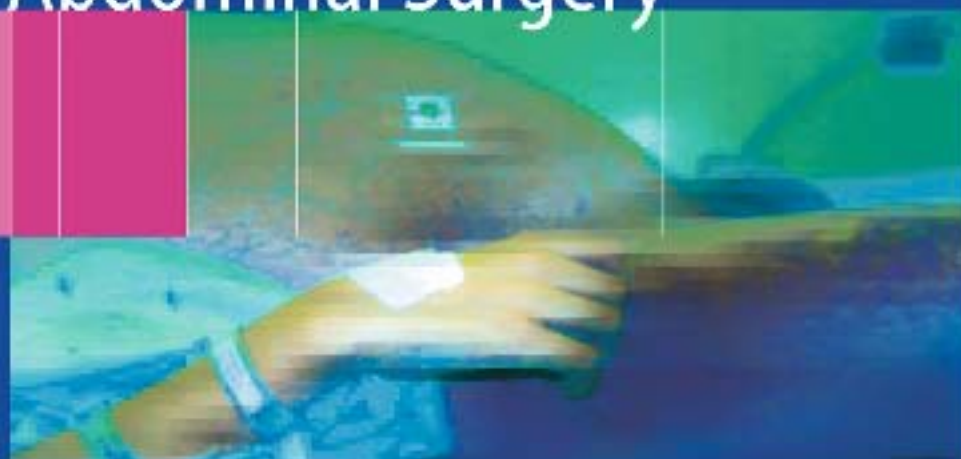

Moshe Schein
Paul N. Rogers *Editors*

Schein's Common Sense Emergency Abdominal Surgery



Second Edition

 Springer

Moshe Schein · Paul N. Rogers (Editors)
Schein's Common Sense Emergency Abdominal Surgery

Moshe Schein • Paul N. Rogers (Editors)

Schein's Common Sense Emergency Abdominal Surgery

Second Edition

With 97 Figures and 21 Tables

 Springer

Moshe Schein, MD, FACS, FCS(SA)
Surgical Specialists of Keokuk, Keokuk, IA 52632, USA
Formerly: Professor of Surgery, Weill College of Medicine
Cornell University, New York, NY, USA

Paul N. Rogers, MB ChB, MBA, MD, FRCS (Glasgow)
Consultant General and Vascular Surgeon, Department of Surgery
Gartnavel General Hospital, Glasgow, Scotland, UK

Editorial Adviser: Robert Lane, MD, FRCSA, FACS

Graphics: Evgeny E. (Perya) Perelygin, MD and Alexander N. Oparin, MD

Library of Congress Control Number: 2004104706

ISBN 3-540-21536-0 Springer Berlin Heidelberg New York

ISBN 3-540-66654-0 1st ed. Springer-Verlag Berlin Heidelberg New York

This work is subject to copyright. All rights are reserved, whether the whole or part of the material is concerned, specifically the rights of translation, reprinting, reuse of illustrations, recitation, broadcasting, reproduction on microfilm or in any other way, and storage in data banks. Duplication of this publication or parts thereof is permitted only under the provision of the German Copyright Law of September 9, 1965, in its current version, and permission for use must always be obtained from Springer-Verlag. Violations are liable to prosecution under the German Copyright Law.

Springer is a part of Springer Science+Business Media
springeronline.com
© Springer-Verlag Berlin Heidelberg 2000, 2005
Printed in Germany

The use of designations, trademarks, etc. in this publication does not imply, even in the absence of a specific statement, that such names are exempt from the relevant protective laws and regulations and therefore free for general use.

Product liability: The publisher can not guarantee the accuracy of any information about dosage and application contained in this book. In every individual case the user must check such information by consulting the relevant literature.

Editor: Gabriele Schröder, Heidelberg, Germany
Desk editor: Stephanie Benko, Heidelberg, Germany
Production editor: Ingrid Haas, Heidelberg, Germany

Cover-Design: Frido Steinen-Broo, Pau, Spain
Typesetting: Fotosatz-Service Köhler GmbH, Würzburg, Germany
Printing and bookbinding: Strauss-Offsetdruck GmbH, Mörlenbach, Germany

Printed on acid-free paper. 24/3150 ih - 5 4 3 2 1 0

Dedication

MS dedicates this book to his late father Karl Schein (1911–1974), a surgeon on the Eastern Front during World War II, and later in Haifa, Israel.



Editors' Note

This book has been assembled – in pieces – during 20 years of intensive personal involvement, clinical and academic, with emergency abdominal surgery in South Africa, Israel, USA, UK and Australia.

A long line of good old friends from all around the world were helpful in generating this book and its first edition. For the foundations in this noble surgical field MS is indebted to George G. Decker of Johannesburg. Drs. Roger Saadia, Asher Hirshberg and Adam Klipfel contributed to the first edition. Dr. Alfredo Sepulveda of Santiago, Chile, provided aphorisms and edited the Spanish translation. Professor Boris Savhucuk of Moscow who edited the Russian translation passed away recently. We will remember him with affection.

Special thanks to Frau Gabriele Schroeder and Frau Stephanie Benko of Springer-Verlag, Heidelberg, for their immense support. Most of the aphorisms and quotations used to decorate this book were retrieved from *Aphorisms & Quotations for the Surgeon*, edited by MS and published by Nikki Bramhill's tfm Publishing Ltd, Harley, UK.

The reader will find that there are not a few duplications scattered along the book. We did this on purpose, as repetition of important points is crucial in adult education. Any reader who has a question or a comment about anything mentioned in this book is invited to e-mail us directly – mschein1@mindspring.com or pnrogers@msn.com. We will respond.

Finally, we are indebted to our loving wives, **Heidi** and **Jackie** and our children **Omri**, **Yariv**, **Dan**, **Lucy** and **Michael** for their patience and sacrifice.

July 2004

Moshe Schein, New York
Paul N. Rogers, Glasgow

Preface to the Second Edition

“In literature, as in love, we are astonished at what is chosen by others.”
(Andre Maurois, 1885–1967).

In the harsh environment of the competitive publishing market only a tiny fraction of medical texts ever gets to see the light of a *second edition*. Thus, we were proud to hear from our publishers that the *first edition* of this book has been sold out. “Do you want us to simply *re-print* the book”, they asked, “or do you think that it deserves to be *updated* and *re-written*?” We opted for the latter.

Is there anything new in emergency abdominal surgery that merits the revision of a 4-year-old book? Yes. **Our practice has been gradually changing for the better and worse.** Where we practice – in the “developed world” – the volume and spectrum of emergency surgery are declining and becoming narrower. Where any abdominal grumble is followed by a CT scan or any fart by a colonoscopy, ruptured aortic aneurysm and acute malignant colonic obstruction are becoming rarities. When most asymptomatic inguinal hernias undergo elective repair, one does not see many strangulated or obstructed groin hernias. When the entire population is being fed – or buys at the counter – anti-ulcer medications, operations for bleeding or perforated ulcer are hardly ever performed. This, however, may not be true in other parts of the world where you have the fortune (or misfortune) to practice.

The way we practice emergency surgery has also been rapidly evolving. With almost unlimited access to abdominal imaging, we can rapidly pinpoint the diagnosis and avoid an unnecessary operation, or perform an indicated operation instead of engaging in a prolonged period of uncertainty. We are gradually becoming more selective and cautious – understanding that everything we do involves wielding a double-edged sword, and that in emergency surgery usually doing less is better but occasionally doing more may be life saving. Meanwhile fancy diagnostic modalities are used chaotically by our non-surgical colleagues (and some of our surgical ones) – producing *red herrings* or new “image diseases”, “incidentalomas” and adding to the general confusion.

This brave new world of changes needed to be incorporated into this book. We have to learn how to deal with the old s**t – which is perhaps becoming rarer – even when its odor is masked by the perfume of modern practice. And this is what we have attempted in this new edition – to recite the old basics but also show how to apply them in the evolving modern world.

What is new in the *Second Edition*? We have a new co-editor. We added new chapters (viz., historical perspectives, imaging, esophageal and diaphragmatic emergencies, complications of endoscopy, pediatric emergencies, HIV patients, before the flight, before landing, and postoperative bleeding) by new contributors. All existing chapters have been revised or re-written by the old or new contributors and/or the Editors.

We knew that a book like this – written in colloquial and “direct” style will be either loved or hated. And indeed, a few reviewers – appalled by dogmas that clash with their own – almost killed it. But many loved it; for example:

- From **Germany**: “Despite the “Wild West style” the book is far from being anachronistic. Instead, it is throughout updated and modern. To the experienced surgeons this book could provide joy with its wisdom and humor... What makes this book really very readable for the surgeons are the “pregnant” citations, aphorisms and “smart sayings”, which are often heard at the bedside and operating rooms but almost never reach the pages of a book”. (P. Klein, Heidelberg, *Chirurg*, 2000).
- From **Scotland**: “A surgeon of considerable experience may feel that they have little to learn from such a book, but this is written with short punchy chapters making it a very difficult book to put down...the wealth of common sense in the book still makes it a worthwhile read and stimulates one’s own bias and views and challenges one’s own practice of surgery”. (R.A.B. Wood, *Journal Royal College of Surgeons of Edinburgh*, 2000)
- From **Sweden**: “Through its direct language, the book becomes not only an entertaining lecture but also a valuable aid of handling patients with the acute abdomen.” (Svante Nordgren, *Östra Sjukhuset*, 2000).
- From **Russia**: “Since Henry Mondor’s times in the forties of the last century there was no other book in clinical surgery to be written so easy and witty about most important things in the emergency abdominal surgery”. (Boris D. Savchuk, *World Journal of Surgery*, 2002).

And from the many letters we received:

- A terrifically refreshing book, full of wisdom as well as wit. (Mr. George Youngson, Consultant Surgeon Aberdeen, Scotland)
- This is a very fantastic book and I have found a lot of new and useful advices in it (Dr. Csaba Csonka, Head Surgeon, Ajka, Hungary)

- Absolutely wonderful. I am going to make it compulsory reading for all of my registrars. Otherwise – fantastic!! (Eddie Chaloner, UK)
- I can't remember a surgical book which I was able to digest with so much interest and without becoming tired even late at night. (Dr.med. Achim Schröder, Germany)
- This is one of the most useful and interesting surgical books in my library. You will read it in two hours with pleasure and interest and remember forever. (Dr. Andrea Favara, Milan, Italy)
- A book like this is long overdue. (Mr. R.D. Quill. Dublin, Ireland)
- A gold mine for the trainee surgical doctor. (Mr. Saboor Kahn, Wales, UK)

By popular demand the *First Edition* of this book has been translated into Spanish and Russian.

Motivated by the enthusiasm with which the book has been received across the world – particularly among those practicing “real surgery” in the “real world” – we set about enhancing it to produce a text that should be palatable to all of you – wherever you try to save lives – be it in Bogota, Dundee, Teheran, Calcutta, Naples, Dusseldorf, Krakov, Moscow or Boston. **If you are a surgeon who practices the way he was trained 20 or 30 years ago you will hate this book; if you are being trained by such a surgeon then you desperately need to read this book.**

Anton Chekhov said: “Doctors are just the same as lawyers; the only difference is that lawyers merely rob you, whereas doctors rob you and kill you, too.” Our chief aim in writing this book was to help you not to kill your patients. We hope that this modest book will be of some value to you.

New York/Glasgow, July 2004

The Editors (♥ see figure)



The Editors: Rogers is the one in the *kilt*...

Contents

I	Background	1
1	General Philosophy	3
	Moshe Schein · Paul N. Rogers	
2	A Brief History of Emergency Abdominal Surgery	9
	Harold Ellis	
II	Before the Operation	15
3	The Acute Abdomen	17
	Moshe Schein	
4	Rational Diagnostic Procedures	27
	Moshe Schein	
5	Abdominal Imaging	33
	Moshe Schein · Sai Sajja · Hans Ulrich Elben	
6	Optimizing the Patient	55
	James C. Rucinski	
7	Pre-operative Antibiotics	67
	Moshe Schein	
8	Family, Ethics, Informed Consent and Medicolegal Issues	71
	James C. Rucinski	
9	Before the Flight: Pre-op Checklist	77
	Moshe Schein	

III	The Operation	81
10	The Incision	83
	Moshe Schein	
11	Abdominal Exploration: Finding What is Wrong	87
	Moshe Schein	
12	Peritonitis: Contamination and Infection, Principles of Treatment	95
	Moshe Schein · Roger Saadia	
13	The Intestinal Anastomosis	103
	Moshe Schein	
14	Esophageal Emergencies	109
	Tom Anthony Horan	
15	Diaphragmatic Emergencies	119
	Ulrich Schoeffel · Moshe Schein	
16	Upper Gastrointestinal Hemorrhage (and Portal Hypertension)	125
	Moshe Schein	
17	Perforated Peptic Ulcer	143
	Moshe Schein	
18	Acute Pancreatitis	151
	Moshe Schein	
19	Acute Cholecystitis	163
	Moshe Schein	
20	Acute Cholangitis	173
	Gary Gecelter	
21	Small Bowel Obstruction	179
	Moshe Schein	
22	Acute Abdominal Wall Hernias	191
	Paul N. Rogers	
23	Acute Mesenteric Ischemia	197
	Moshe Schein · Paul N. Rogers	
24	Inflammatory Bowel Disease and Other Types of Colitis	205
	Per-Olof Nyström	

25	Colonic Obstruction	217
	Per-Olof Nyström	
26	Acute Diverticulitis	229
	Per-Olof Nyström	
27	Massive Lower Gastrointestinal Bleeding	239
	Per-Olof Nyström	
28	Acute Appendicitis	245
	Moshe Schein	
29	Anorectal Emergencies	255
	Luis A. Carriquiry	
30	Surgical Complications of Endoscopy	265
	Ahmad Assalia · Anat Ilivitzki	
31	Gynecological Emergencies	275
	Bashar Fahoum · Moshe Schein	
32	Abdominal Emergencies in Infancy and Childhood	283
	Wojtek J. Górecki	
33	The AIDS Patient	291
	Sai Sajja	
34	Penetrating Abdominal Trauma	297
	Avery B. Nathens	
35	Blunt Abdominal Trauma	305
	Avery B. Nathens	
36	The Abdominal Compartment Syndrome	321
	Moshe Schein	
37	Abdominal Aortic Emergencies	329
	Paul N. Rogers	
38	Abdominal Closure	337
	Moshe Schein	
39	Before Landing	343
	Moshe Schein	

IV	After the Operation	345
40	Postoperative Care	347
	Moshe Schein	
41	Nutrition	355
	James C. Rucinski	
42	Postoperative Antibiotics	363
	Moshe Schein	
43	Postoperative Ileus vs Intestinal Obstruction	369
	Moshe Schein · Sai Sajja	
44	Intra-abdominal Abscesses	377
	Moshe Schein	
45	Anastomotic Leaks and Fistulas	387
	Moshe Schein	
46	Re-laparotomies and Laparostomy for Infection	395
	Moshe Schein · Roger Saadia · Danny Rosin	
47	Abdominal Wall Dehiscence	411
	Moshe Schein	
48	LIRS, SIRS, Sepsis, MODS and Tertiary Peritonitis	415
	Moshe Schein · John Marshall	
49	Wound Management	425
	Moshe Schein	
50	Postoperative Bleeding	431
	Barry Armstrong	
51	The Role of Laparoscopy	439
	Pieter Gorecki	
52	In the Aftermath and the M & M Meeting	449
	Moshe Schein	
	Subject Index	457

Contributors

Dr. Barry D. Armstrong, MD, FRCSC

General Surgeon, Thunder Bay Regional Health Centre
Downtown North RPO Box 24002, Thunder Bay, Ontario, P71 8A9, Canada
docbear@sympatico.ca

Ahmad Assalia, MD

Fellow, Division of Laparoscopy and the Minimally Invasive Surgery Center
Mount Sinai Medical Center, New York, NY, USA
Lecturer in Surgery, Faculty of Medicine, Technion
Israel Institute of Technology
Department of Surgery B, Rambam Medical Center
Bat Galim, Haifa, Israel
assaliaa@aol.com

Luis A. Carriquiry, MD

Professor and Head, Second Surgical Clinic
Maciel Hospital School of Medicine University of the Republic
Rafael Postoriza 1451, Apt. 502, Montevideo 11600, Montevideo, Uruguay
Icarriq@dedicado.net.uy

Hans Ulrich Elben, MD

Leitender Arzt der Radiologischen Abteilung
Kreisklinikum Schwarzwald-Baar GmbH
Sonhaldenstrasse 2, 78166 Donaueschingen, Germany
HansUlrichElben@swol.net

Harold Ellis, CBE, MCh, FRCS

Professor, Applied Biomedical Research Group
5th Floor, Hodgkin Building, Guy's Campus
London SE1 1UL, Great Britain

Bashar Fahoum, MD, FACS

Attending Surgeon, Director of SICU
Department of Surgery, New York Methodist Hospital
516 Sixth Street, Brooklyn, 11215 NY, USA

Gary Gecelter, MD, FACS

Associate Professor of Clinical Surgery, Albert Einstein College of Medicine
Department of Surgery, Long Island Jewish Medical Center
New Hyde Park, NY, USA
GGecelter@lij.edu

Pioter Gorecki, MD, FACS

Director of Laparoscopic Surgery, New York Methodist Hospital
516 Sixth Street, Brooklyn, 11215 NY, USA
pgorecki@pol.net

Wojtek J. Górecki, MD, PhD

Assistant Professor, Department of Pediatric Surgery Jagiellonian
University, University Children's Hospital
265 Wielicka Street, 30-663 Kraków, Poland
wigoreck@cyf-kr.edu.pl

Anat Ilivitzki, MD

Department of Surgery B, Rambam Medical Center
Bat Galim, Haifa, Israel

Thomas Anthony Horan, MD, FACS, FRCSC

Thoracic Surgeon, Sarah Network of Hospitals
Brasilia-DF, Brazil
thoran@sarah.br

Alexander N. Oparin, MD

Attending Surgeon, Department of Surgery
Mediko-Sanitarnaya Chast No. 4, 178 Novo-Sadovaya,
443011 Samara, Russia
anoparin@mailsnare.net

Robert Lane, MD, FRCSC, FACS

General Surgeon, Morristown, TN 37813, USA
roblane@charter.net

John Marshall, MD, FRCSC, FACS

Professor of Surgery, Eaton North 9-234
Toronto General Hospital, University Health Network
200 Elizabeth Street, Toronto, Ontario, Canada
John.Marshall@uhn.on.ca

Avery B. Nathens, MD, FACS

Associate Professor of Surgery, University of Washington
Division of General Surgery and Trauma, Harborview Medical Center
Box 359796, Seattle, WAS 98104, USA
anathens@u.washington.edu

Per-Olof Nyström, MD, PhD

Associate Professor of Surgery, Consultant Colorectal Surgeon
Department of Surgery, Linköping University Hospital
SE-581 85 Linköping, Sweden
p-o.nystrom@lio.se

Evgeny E. Perelygin, MD

Attending Surgeon, Department of Surgery
Krasnovishersk Regional Hospital
3 Pobedy, 618550 Krasnovishersk, Permskaya Oblast, Russia
perya-32@yandex.ru

Danny Rosin, MD

Department of General Surgery & Transplantation
Sackler School of Medicine, Tel Aviv University
Sheba Medical Center, Tel Hashomer, Israel
drosin@netvision.net.il

James C. Rucinski, MD, FACS

Director of Surgical Education, New York Methodist Hospital
516 Sixth Street, Brooklyn, 11215 NY, USA
jrucinski@pol.net

Roger Saadia, MD, FRCS (Ed)

Professor of Surgery, University of Manitoba and Health Sciences Centre
820 Sherbrook Street, Winnipeg, R3A 1R9, Canada
rsaadia@shaw.ca

Sai Sajja, MD

Chief Resident, Department of Surgery, Bronx Lebanon Hospital
1650 Selwyn Avenue, Bronx, NY 10457, USA
saisajja@hotmail.com

Ulrich Schoffel, MD

Professor für Chirurgie, Universität Freiburg
Leitender Arzt der Allgemein- und Viszeralchirurgie
Rotes Kreuz-Krankenhaus Lindenberg
Jägerstrasse 41, 88161 Lindenberg, Germany
Ulrich.Schoeffel@swmbrk.de

General Philosophy

MOSHE SCHEIN · PAUL N. ROGERS

Surgeons are internists who operate...
“Wisdom comes alone through suffering.”
(Aeschylus, Agamemnon)

At this moment – just as you pick up this book and begin to browse through its pages – there are many thousands of surgeons around the world facing a patient with an abdominal catastrophe. The platform on which such an encounter occurs differs from place to place – be it a modern emergency department in London, a shabby casualty room in the Bronx, or a doctor’s tent in the African bush – but the scene itself is amazingly uniform. It is always the same: you confronting a patient, he – in pain, suffering and anxious. And you are anxious as well – anxious about the diagnosis, concerned about which is the best management, troubled about your own abilities to do what is correct. We are in the twenty-first century – but this universal scenario is not original. It is as old as surgery itself. You are perhaps too young to note how little things have changed over the years. Yes, your hospital may be in the forefront of modern medicine; its emergency room has standby, state-of-the-art spiral computed tomography and magnetic resonance imaging machines, but, practically, nothing has changed; it is the patient and you (often with the entire “system” against you) – you who are bound to provide a correct management plan and execute it.

The “Best” Management of an Abdominal Emergency

It is useful to compare the emergency abdominal surgeon to an infantry officer (● Fig. 1.1). Away from the limelight and glory that surrounds cardiac or neurological surgeons, emergency abdominal surgery resembles the infantry more than the airforce. A war can be won by not remote control with cruise missiles, but with infantry on the ground. To achieve the final victory someone has to agonize, sweat, bleed, and wet his hands in human secretions and excreta. Likewise, technological gimmicks have a limited place in emergency abdominal surgery, which is the domain of the surgeon’s brain and hands. Some readers may object to this military metaphor but the truth of the matter is that, with the infantry, emergency abdominal surgery shares a few simple rules – accumulated in the trenches and during



Fig. 1.1. “Think as an infantry soldier...”

offensives – rules that are the key to victory and survival. Such a code of battle echoes the “best” management of abdominal emergencies.

	Infantry	Emergency abdominal surgery
Rule 1.	Destroy your enemy before he destroys you	Save lives
Rule 2.	Spare your own men	Reduce morbidity
Rule 3.	Save ammunition	Use resources rationally
Rule 4.	Know you enemy	Estimate severity of disease
Rule 5.	Know your men	Understand the risk-benefit ratio of your therapy
Rule 6.	Attack at “soft” points	Tailor your management to the disease and the patient
Rule 7.	Do not call for airforce support in a hand-to-hand battle	Do not adopt useless gimmicks – use your mind and hands
Rule 8.	Conduct the battle from the front line – not from the rear	Do not take and accept decisions over the phone
Rule 9.	Take advice from the generals but the decision is yours	Procure and use consultation from “other specialties” selectively
Rule 10.	Avoid friendly fire	Reduce iatrogenesis
Rule 11.	Maintain high morale among your troops	Be proud in providing the “best” management

From your previous or current surgical mentors you know that there are many ways to skin a cat and different clinical pathways to arrive at a similar outcome. However, only one of the diverse pathways is the “correct one” – thus, the “best”! **To be considered as such the “preferred pathway” has to save life and decrease morbidity in the most efficient way.** Look at this example: you can manage perforated acute appendicitis using two different pathways – both leading to an eventual recovery and both considered absolutely appropriate.

Pathway 1	Pathway 2
Young male – right lower quadrant peritonitis *** ***	Young male – right lower quadrant peritonitis CT scan Attempted laparoscopic appendectomy Conversion to open appendectomy
Appendectomy for gangrenous appendicitis – 3 hours after admission Primary closure of the wound 24 hours of postoperative antibiotics ***	Appendectomy for gangrenous appendicitis – 24 hours after admission Wound left open 5 days of postoperative antibiotics Secondary closure of wound
Discharge home on the 3rd postoperative day	Discharge home on the 7th postoperative day

Both above pathways are OK, right? Yes, but pathway 1 clearly is the “best” one: safer, faster and cheaper.

Today many options exist to do almost anything. Just by clicking open MEDLINE you are overwhelmed with papers that can prove and justify almost anything you elect to do, with people practicing *surgical acrobatics* for the mere sake of doing so. Data and theory are everywhere – the sources are numerous but what you really need is *wisdom* to enable you to apply correctly the knowledge you already have and constantly gather.

General Philosophy (🔗 Fig. 1.2)

“There is nothing new in the story...” Winston Churchill said, “want of foresight, unwillingness to act when action would be simple and effective, lack of clear thinking, confusion of counsel until the emergency comes, until self preservation strikes its jarring gong...”. How true is this Churchillian wisdom when applied to emergency surgery. How often do we forget old – written in stone – principles while re-inventing the wheel?



Fig. 1.2. “General philosophy...”

The “best” management in each section of this book is based on the following elements:

- Old-established principles (don’t re-invent the wheel)
- Modern-scientific understanding of inflammation and infection
- Evidence-based surgery (see below)
- Personal experience

The inflamed patient (▶ Fig. 1.3)

Think about your patient as being INFLAMED by myriad inflammatory mediators, generated by the primary disease process, be it inflammatory, infectious or traumatic. Those local (e.g., peritonitis) and *systemic inflammatory response syndromes* (SIRS) are the ones that lead to organ dysfunction or failure, and the eventual demise of your patient. The greater the inflammation, the sicker the patient, and the higher will be the expected mortality and morbidity. Think also that anything you do to halt your patient’s inflammation may in fact contribute to it – adding wood to the inflammatory fire. Excessive surgery, inappropriately performed, and too late, just adds nails to your patient’s coffin. And SIRS is antagonized by CARS (compensatory anti-inflammatory syndrome), mediated by anti-inflammatory cytokines, which in turn promotes the immune suppression and infections, which

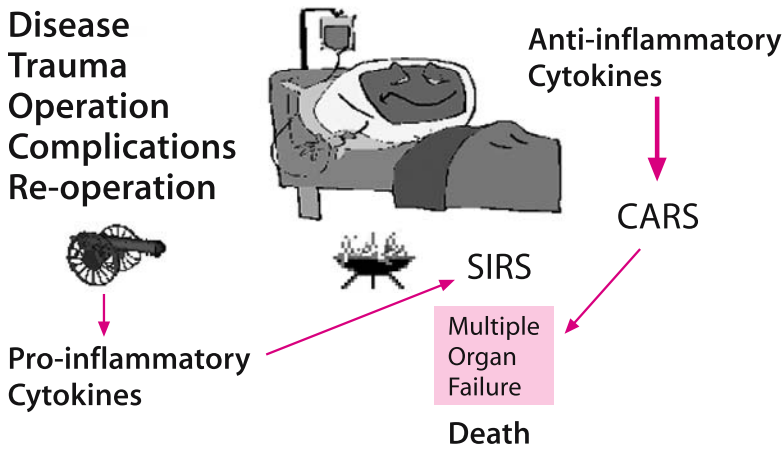


Fig. 1.3. The inflamed surgical patient. SIRS systemic inflammatory response syndrome, CARS compensatory anti-inflammatory syndrome. [Read the classic by the late Roger Bone: Bone RC (1996) Sir Isaac Newton, sepsis, SIRS, and CARS. Crit Care Med 24:1125–1128]

are so common after major operations and severe trauma. The philosophy of treatment that we propose maintains that in order to cure or minimize the inflammatory processes, and the anti-inflammatory response, management should be accurately tailored to the individual patient's disease. **The punishment should fit the crime – it is useless to fire indiscriminately in all directions!**

Evidence

A few words about what we mean when we talk about “evidence”.

Evidence level	Description
I	A scientifically sound randomized controlled trial
II	Randomized controlled trial with methodological “problems”
III	Non-randomized concurrent cohort comparison
IV	Non-randomized historical cohort comparison
V	A case series without controls
To the above “official” classification we wish to add another three categories frequently used by surgeons around the world	
VI	“In my personal series of <i>X</i> patients (never published) there were no complications”
VII	“I remember that case...”
VIII	“This is the way I do it and it is the best”

Note that level V studies form the main bulk of surgical literature dealing with abdominal emergencies, whereas level VI–VII evidence is the main form of evidence used by surgeons in general (think about your departmental meetings...), and level VIII may remind you of your chairman! You should educate yourself to think in terms of levels of evidence and resist local dogmas. We believe that support for much of what we write here is available in the published literature, but we choose not to cite it here because it is not that kind of book. When high-level evidence is not available, we have to use an individual approach and common sense, and that is much of what this book is about.

You can get away with a lot...but not always. Most patients treated according to the above-mentioned pathway 2 will do well, but a few will not. The following pages will help you to develop your own judgment – pointing to the correct pathway in any situation. This is obviously not a Bible but it is based on a thorough knowledge of the literature and vast personal experience. So wherever you are – in India, Norway, Chile, Canada or Palestine, and whatever your resources – the approach to emergency abdominal surgery is the same. So come and join us – to save lives, decrease morbidity, do it “correctly” – and attain glory!

“The glory of surgeons is like that of actors, which lasts only for their own lifetime and can no longer be appreciated once they have passed away. Actors and surgeons ... are all heroes of the moment.” (Honore de Balzac, 1799–1850)

“The operation is a silent confession to the surgeon’s inadequacy.” (John Hunter, 1728–1793)

A Brief History of Emergency Abdominal Surgery

HAROLD ELLIS

“In the study of some apparently new problems we often make progress by reading the work of the great men of the past.” (Charles H. Mayo, 1865–1939)

From the earliest days until comparatively modern times, surgeons were ignorant about the causes of the vast majority of acute abdominal emergencies and equally ineffectual in their treatment. They were, of course, well familiar with abdominal trauma and the dire consequences of perforating injuries of the belly, the great majority of which would be fatal. Thus, in the Bible we read in the Book of Judges:

But Ehud made him a dagger, which had two edges of a cubit length, and he did gird it under the raiment of his right thigh. And he brought the present unto Eglon, King of Moab. And Eglon was a very fat man...And Ehud put forth his left hand and took the dagger from his right thigh, and thrust it into his belly. And the haft went in after the blade and the fat closed over the blade, so that he could not draw the blade out of his belly; and the dirt came out...And behold their Lord was fallen down dead on the earth.

Occasionally a fecal fistula would form and the patient survive. That great sixteenth century French military surgeon, Ambroise Paré, records in his Case Reports and Autopsy Records:

In time I have treated several who recovered after having had wounds by sword or pistol pass through their bodies. One of these, in the town of Melun, was the steward of the Ambassador of the King of Portugal. He was thrust through with a sword, by which his intestines were wounded, so when he was dressed a great deal of fecal matter drained from the wound, yet the steward was cured.

Occasionally a prolapsed loop of bowel, projecting through a lacerated abdominal wound, might be successfully reduced. Still less often, an enterprising surgeon might suture a laceration in such a loop and thus save his patient's life. In 1676 Timothy Clark recorded the case of a butcher who attempted suicide with his butcher's knife in the village of Wayford in the country of Somerset, located in

the south west corner of England. Three days later, a surgeon who Clark does not name replaced the prolapsed gut, removed extruded omentum and prolapsed spleen and the patient recovered. Clark, himself, in 1633 had removed the spleen of a dog with survival, thus showing that the organ was not essential to life, and confirming an observation made by Vesalius a century beforehand.

Strangulated hernias were also well known to ancients. Treatment usually consisted of forcible manipulative reduction, which was aided by hot baths, poultices, and the use of the head-down, feet-up position. Sometimes their efforts succeeded, but there was, of course, a dire risk of rupture of the gut, especially in advanced cases. William Cheselden in 1723 reported the case of a woman in her 73rd year with a strangulated umbilical hernia. At operation, he resected 26 inches of gangrenous intestine. She recovered with, of course, a persistent fecal fistula. The extreme danger of strangulated hernia is well demonstrated by the fact that Queen Caroline, wife of George II of England, died of a strangulated umbilical hernia at the age of 55 in 1736.

Acute abdominal emergencies have no doubt affected mankind from its earliest existence, yet it has only been in comparatively recent times – the past couple of hundred years – that the pathology and then the treatment of these conditions were elucidated. This is because over many centuries postmortem examinations were either forbidden or frowned upon in most societies. Operations on the abdomen were performed rarely, if at all, until the beginning of the nineteenth century. So, what Berkeley Moynihan called “the pathology of the living”, the pathology of the abdominal cavity as revealed in the operating theatre, awaited to a large extent the development of anesthesia in the 1840s and antiseptic surgery in the 1870s.

Knowledge of the causes of the acute abdomen advanced little in the 2000 years following the days of Hippocrates in the fifth century b.c. The Greek and Roman doctors were keen clinical observers. They recognized that, from time to time, a deep abdominal abscess might discharge spontaneously or be amenable to surgical drainage with recovery of the patient. Every other serious abdominal emergency was given the name of “ileus” or “iliac passion” and was considered to be due to obstruction of the bowels. Of course, the fatal abdominal emergencies they were seeing were indeed due either to mechanical obstruction or to the paralytic ileus of general peritonitis. Thus in Hippocrates we read:

In ileus the belly becomes hard, there are no motions, the whole abdomen is painful, there are fever and thirst and sometimes the patient is so tormented that he vomits bile... Medicines are not retained and enemas do not penetrate. It is an acute and dangerous disease.

Over the centuries there was little to offer the patient beyond poultices to the abdomen, cupping, bleeding, purgation and enemas, all of which probably did more

harm than good. It was not until 1776 that William Cullen, of Edinburgh, coined the term “peritonitis” for inflammation of the lining membrane of the abdominal cavity and its extensions to the viscera. However, he did not think exact diagnosis of great importance, since “when known, they do not require any remedies besides those of inflammation in general.”

Appendicitis

Lorenz Heister, of Helmstadt in Brunswick, must be given credit for the first description of the appendix as the site of acute inflammation, reporting this at an autopsy in 1755. For more than a century after this there were occasional autopsy reports, but most cases were unrecognized or labeled “typhlitis”, “peri-typhilitis” or “iliac passion”.

In 1848 Henry Hancock, of Charing Cross Hospital, London, reported the drainage of an appendix abscess in a young woman who was 8-months pregnant. She recovered, but in spite of Hancock’s plea, so fixed was the idea that it was useless to operate once peritonitis was established that his advice was ignored for some 40 years. Indeed, it was a physician, not a surgeon, who advised appendectomy and early diagnosis. This was Reginald Fitz, Professor of Medicine at Harvard, who, in 1886, published a review of 257 cases, which clearly described the pathology and clinical features, and advised removal of the acutely inflamed organ or, in the presence of an abscess, surgical drainage. Fitz’s advice was taken up rapidly in the United States. Thomas Morton of Philadelphia was the first to report, in 1887, the correct diagnosis and successful removal of a perforated appendix (although Robert Lawson Tait as early as 1880 had had a similar case, he did not report this until 1890). The surge in early diagnosis and operative treatment was particularly pioneered by Charles McBurney of the Roosevelt Hospital, New York, who described “McBurney’s point” and devised the muscle split incision, and J.B. Murphy of Chicago, who emphasized the shift in pain in “Murphy’s sequence”. Fredrick Treves, of the London Hospital, drained the appendix abscess of King Edward VII in 1902, 2 days before the coronation, and did much to raise the general public’s awareness of the disease.

The Ruptured Spleen

The spleen is the most commonly injured viscus in closed abdominal trauma, yet there was surprising diffidence among the pioneer abdominal surgeons to perform a splenectomy on these exsanguinating patients – in spite of the fact that Jules Péan of Paris had performed a successful splenectomy on a girl with a massive

splenic cyst in 1867. Two unsuccessful attempts to save life in splenic rupture were reported in 1892 by Sir Arbuthnot Lane of Guy's Hospital, London, and three more fatal cases recorded by Freidrich Trendelenburgh in Leipzig the following year. The wording of these case reports strongly suggests that had blood transfusion been available, the patients might well have survived.

It fell to Oskar Riegner in Breslau to perform the first splenectomy for a pulped spleen with survival in 1893. The patient, a lad of 14, was found to have the spleen completely severed and there were 1.5 liters of blood in the abdomen. Normal saline was given subcutaneously into all four limbs. His recovery was complicated by gangrene of the left foot, which required amputation, but he left hospital, complete with artificial limb, 5 months after his splenectomy.

Intestinal Obstruction

Not surprisingly, early attempts to deal with large bowel obstruction, (usually due to a left-sided colonic cancer), comprised performance of a colostomy. The first attempt to do this was made by Pillore of Rouen in 1776. He actually carried out a cecostomy on a wine merchant with gross abdominal distension due to a recto-sigmoid growth. The operation produced great relief, but the patient died on the 28th day because of necrosis of a loop of jejunum, brought about by the large amounts of mercury given in the pre-operative attempts to overcome the obstruction. It remained for Pierre Fine of Geneva, in 1797, to perform a successful transverse colostomy. The patient, a lady of 63 with an obstructing sigmoid growth, died 14 weeks later with ascites.

Not until the introduction of anesthesia and antisepsis could routine resection of bowel cancers be performed, the first success in this era being reported by Vincent Czerny in Heidelberg in 1879. It was soon realized that resection of the obstructed colon was very likely to result in a fatal anastomotic leak. Exteriorization of the growth, with formation of a double-barreled colostomy and its subsequent closure was introduced by Frank Thomas Paul of Liverpool in 1895, and by Johannes von Mikulicz-Radecki of Breslau a little later. This procedure, the Paul-Mikulicz operation, was shown by the latter to reduce mortality in his own cases from 43% with primary resection to 12.5% with the exteriorization method.

With its vivid clinical features of intestinal obstruction in a baby, passage of red current jelly stools, a palpable abdominal mass and sometimes a prolapsing mass to be felt per rectum or even seen to protrude through the anal verge, it is not surprising that intussusception in children was one of the earliest specific pathologies of the acute abdomen to be recognized. Treatment was expectant, with the use of enemas or rectal bougies, in attempts to reduce the mass. Surgeons were encouraged to do this by very occasional reports of success and still rarer accounts

of recovery following the passage of the sloughed gangrenous bowel per rectum. The first operative success was reported by Sir Jonathan Hutchinson, of the London Hospital, in 1871. His patient, a girl aged 2, had her intussusception reduced through a short mid-line incision, the operation requiring just a few minutes. Hutchinson's meticulous report tabulates 131 previously recorded cases, which make sad reading indeed.

There was a downside to this new abdominal surgery. It was not long after this new era commenced that the first reports appeared of small bowel obstruction due to post-operative adhesions. Thomas Bryant of Guy's Hospital recorded the first example in 1872 – a fatal case following an ovariectomy. A second fatality, 4 years after removal of an ovarian mass, was reported in 1883 by William Battle of London. Today, post-operative adhesions and bands account for some three-quarters of all cases of small bowel obstructions in the Western World.

Perforated Peptic Ulcer

Untreated, a perforated peptic ulcer nearly always results in fatal peritonitis. Unsuccessful attempts at repair were made by Mikulicz-Radecki in 1884 and by Czerny in 1885 and subsequently by a number of other surgeons. This depressing series came to an end under most difficult circumstances. In 1892, Ludwig Heusner of Wuppertal, Germany, repaired a perforated gastric ulcer high up on the lesser curve in a 41-year-old businessman with a 16-hour history; the operation was performed in the middle of the night by candlelight! The convalescence was complicated by a left-sided empyema, which required drainage. Two years later, Thomas Morse, in Norwich, published the successful repair of a perforation near the cardia in a girl of 20. With these two successes, operation for this condition became routine. Interestingly, gastric ulcer at the turn of the twentieth century was far commoner than duodenal ulcer, and was especially found in young women.

Ruptured Ectopic Pregnancy

Until 1883 a ruptured ectopic pregnancy was a death sentence. This is surprising, because the early pioneers of abdominal surgery, going back to pre-anesthetic era, were, in the main, concerned with removal of ovarian masses. Indeed, the first elective abdominal operation for a known pathology was the removal of a massive ovarian cyst by Ephraim McDowell in Danville, Kentucky, in 1809. Yet, for some inexplicable reason, the surgeon would stand helplessly by the bedside and watch a young woman, in the most useful time of her existence, exsanguinate from her ruptured tube.

The first surgeon to perform successful surgery in this condition was Robert Lawson Tait, of Birmingham, whom we have already mentioned performing a successful appendectomy in 1880. Tait was asked to see a girl with a ruptured ectopic pregnancy by Dr. Hallwright, a general practitioner. Hallwright suggested that Tait should remove the ruptured tube. Tait records:

The suggestion staggered me and I am afraid I did not receive it favourably. I declined to act and a further haemorrhage killed the patient. A post-mortem examination revealed the perfect accuracy of the diagnosis. I carefully inspected the specimen that was removed and found that if I had tied the broad ligament and removed the tube I should have completely arrested the haemorrhage, and I now believe that had I done this the patient's life would have been saved.

Eighteen months later, Tait operated on a clearly dying patient, the first occasion in which such an operation was performed. The patient, in those pre-transfusion days, died of exsanguination. Finally, in March 1888, Tait performed a successful salpingectomy on such a case, who survived even though, at operation, the abdomen was full of clot. Years later, he was able to report 39 cases, with but two deaths, including the first.

Envoi

Even today, the acute abdomen presents a diagnostic and therapeutic challenge to the surgeon. This is in spite of the fact that we have the ancillary aids of radiology, imaging, biochemical and hematological studies to help the diagnosis, and blood transfusion, fluid replacement, nasogastric suction, antibiotics and skilled anesthetists to assist with therapy.

"Let us therefore look back with a mélange of amazement, pride, and humility at the efforts of our surgical forefathers as they paved the way for us in the management of this fascinating group of diseases." (Harold Ellis)

Editorial Comment

We are proud to offer this chapter by Professor Ellis of London: a renowned surgeon, educator, writer, editor, anatomist, and surgical historian. Among his many books we would particularly recommend *Operations That Made History* and *A Brief History of Surgery*.

Before the Operation



The Acute Abdomen*

MOSHE SCHEIN

“For the abdominal surgeon it is a familiar experience to sit, ready scrubbed and gowned, in a corner of the quiet theatre, with the clock pointing midnight. ...In a few minutes the patient will be wheeled in and another emergency laparotomy will commence. This is the culmination of a process which began a few hours previously with the surgeon meeting with and examining the patient, reaching a diagnosis, and making a plan of action.” (Peter F. Jones)

*“The general rule can be laid down that the majority of severe abdominal pains which ensue in patients who have been previously fairly well, and which last as long as six hours, are caused by conditions of surgical import.”
(Zachary Cope, 1881–1974)*

Simply stated, the term acute abdomen refers to abdominal pain of short duration that requires a decision regarding whether an urgent intervention is necessary. This clinical problem is the most common cause for you to be called to provide a surgical consultation in the emergency room, and serves as a convenient gateway for a discussion of the approach to abdominal surgical emergencies.

The Problem

Most major textbooks contain a long list of possible causes for acute abdominal pain, often enumerating 20–30 “most common” etiologies. These “big lists” usually go from perforated peptic ulcer down to such esoteric causes as porphyria and black widow spider bites. The lists are popular with medical students, but totally useless for practical guys like you.

The experienced surgeon called upon to consult a patient with acute abdominal pain in the emergency room (ER) in the middle of the night simply does not work this way. He or she does not consider the 50 or so “most likely” causes of acute abdominal pain from the list and does not attempt to rule them out one by one. **Instead, the smart surgical resident tries to identify a clinical pattern, and to decide upon a course of action from a limited menu of management options.** Below we will demonstrate how the multiple etiologies for acute abdominal pain actually converge into a small number of easily recognizable clinical patterns. Once recognized, each of these patterns dictates a specific course of action.

* Asher Hirshberg, MD contributed to this chapter in the 1st edition of the book.

The Acute Abdomen: Clinical Patterns and Management Menus

The Management Options

Seeing a patient with an acute abdomen in the ER you have only the four possible management options listed in Table 3.1. The last option (discharge) deserves some consideration. Many patients with acute abdominal pain undergo a clinical examination and a limited workup – which today in some centers may include even a CT scan – only to be labeled as “non-specific abdominal pain” (NSAP), and then discharged. NSAP is a clinical entity, albeit an ill-defined one. It is a type of acute abdominal pain that is severe enough to bring a patient to seek medical attention (● Fig 3.1). The patient’s physical examination and diagnostic workup are negative, and the pain is self-limiting and usually does not recur. It is important to keep in mind that in an ER setting, more than half the patients presenting with acute abdominal pain have NSAP, with acute appendicitis, acute

Table 3.1. Management options

Immediate operation (“surgery now”)
 Pre-operative preparation and operation (“surgery tomorrow morning”)
 Conservative treatment (active observation, intravenous fluids, antibiotics, etc.)
 Discharge home




Fig. 3.1. “Which of them has an ‘acute abdomen?’”

Table 3.2. Clinical patterns

Abdominal pain and shock
Generalized peritonitis
Localized peritonitis (confined to one quadrant of the abdomen)
Intestinal obstruction
“Medical” illness

cholecystitis and “gynecological causes”, the commonest “specific” conditions. But the exact pathology you see depends of course on your geographical location and pattern of practice. Just remember that patients discharged home labeled with the diagnosis of NSAP have an increased probability of a subsequent diagnosis of abdominal cancer. Therefore, referral for elective investigations may be indicated.

The Clinical Patterns

The acute abdomen usually presents as one of five distinct and well-defined clinical patterns stated in Table 3.2. Two additional patterns (trauma and gynecological) are addressed elsewhere in this volume. Occasionally a mixed picture of obstruction/inflammation may present. Each of these clinical patterns dictates a specific management option from the menu. Your task is to identify the specific pattern in order to know how to proceed.

Abdominal Pain and Shock

This is the most dramatic and least common clinical pattern of the acute abdomen. The patient typically presents pale and diaphoretic, in severe abdominal pain and with hypotension, the so-called abdominal apoplexy. The two most common etiologies of this clinical pattern are a **ruptured abdominal aortic aneurysm** and a **ruptured ectopic pregnancy** (☛ Chaps. 37 and 31). Here the only management option is immediate surgery-now. No time should be wasted on “preparations” and on ancillary investigations. Losing a patient with abdominal apoplexy in the CT scanner is a cardinal, and unfortunately not too rare, sin. Note that other abdominal emergencies may also present with abdominal pain and shock due to fluid loss into the “third space”. This is not uncommon in patients with **intestinal obstruction** (☛ Chap 21), **acute mesenteric ischemia** (☛ Chap. 23), or **severe acute pancreatitis** (☛ Chap. 18) – particularly if neglected or superimposed on a marginal or pre-morbid cardiovascular system.

Generalized Peritonitis

The clinical picture of generalized peritonitis consists of diffuse severe abdominal pain in a patient who looks sick and toxic. The patient typically lies motionless, and has an extremely tender abdomen with “peritoneal signs” consisting of board-like rigidity, rebound-tenderness, and voluntary defense-guarding. Surprisingly enough, less experienced clinicians occasionally miss the diagnosis entirely. This is especially common in the geriatric patient who may have weak abdominal musculature or may not exhibit the classical peritoneal signs. The most common error in the physical examination of a patient with acute abdominal pain is rough and “deep” palpation of the abdomen, which may elicit severe tenderness even in a patient without any abdominal pathology. Palpation of the abdomen should be very gentle, and should not hurt the patient. The umbilicus is the shallowest part of the abdominal wall where the peritoneum almost touches the skin. Thus one of the most effective maneuvers in the physical examination of a patient suspected of having peritonitis is gentle palpation in the umbilical groove, where tenderness is very obvious. We appreciate that at this stage of your surgical career you do not need a detailed lecture on the examination of the acute abdomen. Forgive us, however, for emphasizing that the absence of rebound tenderness means nothing and that a good way to elicit peritoneal irritation is by asking the patient to cough, shaking (gently) his bed, or by very gentle percussion of the abdomen.

The three most common causes of generalized peritonitis in adults are a **perforated ulcer** (◉ Chap. 17), **colonic perforation** (◉ Chap. 26), and **perforated appendicitis** (◉ Chap. 28). The management of a patient with diffuse peritonitis is pre-operative preparation and operation (*surgery tonight*). The patient should be taken to the operating room only after adequate pre-operative preparation as outlined in ◉ Chap. 6.

The only important exception to this management option is the patient with acute pancreatitis. While most patients with acute pancreatitis present with mild epigastric tenderness, the occasional patient may present with a clinical picture mimicking diffuse peritonitis (◉ Chap. 18). As a precaution against misdiagnosing these patients, it is good practice always to measure the serum amylase in any patient presenting with significant abdominal symptoms (◉ Chap. 4). An (unnecessary) exploratory laparotomy in a patient suffering from acute severe pancreatitis may lead to disaster. **Remember: God put the pancreas in the back because he did not want surgeons messing with it.**

Localized Peritonitis

In the patient with localized peritonitis, the clinical signs are confined to one quadrant of the abdomen. In the right lower quadrant (RLQ) the most common cause of localized peritonitis is **acute appendicitis** (⦿ Chap. 28). In the right upper quadrant (RUQ) it is **acute cholecystitis** (⦿ Chap. 19), and in the left lower quadrant (LLQ) it is **acute diverticulitis** (⦿ Chap. 26). Peritonitis confined to the left upper quadrant (LUQ) is uncommon, making this quadrant the “silent one”.

As a general rule, localized peritonitis is often not an indication for a surgery-tonight policy. Instead, when the diagnosis is uncertain, it may initially be treated conservatively. The patient is admitted to the surgical floor, given intravenous antibiotics (e.g., if the diagnosis of acute cholecystitis or diverticulitis is entertained) and hydration, and is actively observed by means of serial physical exams. **Time is a superb diagnostician; when you return to the patient’s bedside after a few hours you may find all the previously missing clues.**

The exception to this rule is, of course, a tender RLQ, for which the working diagnosis is acute appendicitis, and appendectomy may therefore be indicated. However, if there is a palpable mass in the RLQ, the working diagnosis is an “appendiceal phlegmon” for which an appropriate initial management would be conservative (⦿ Chap. 28). In young women RLQ signs may be gynecological in origin, and continued conservative management may also be appropriate in this situation (⦿ Chap. 31).

The management of **acute cholecystitis** varies among surgeons. While past experience taught us that most of these patients would respond to antibiotics, “modern” surgeons prefer to operate early on a “hot” gallbladder – usually the next morning or whenever operating room schedule permits (⦿ Chap. 19).

Intestinal Obstruction

The clinical pattern of intestinal obstruction consists of central, colicky abdominal pain, distension, constipation and vomiting.

As a general rule the earlier and more pronounced the vomiting, the more proximal the site of obstruction is likely to be; the more marked the distension, the more distal the site of obstruction. Thus, vomiting and colicky pain are more characteristic of small bowel obstruction, whereas constipation and gross distension are typical of colonic obstruction. However, the distinction between these two kinds of obstruction usually hinges on the plain abdominal X-ray. There are two management options for these patients: conservative treatment, or operative treatment after adequate preparation. The major problem with intestinal obstruction is not in making the diagnosis but in deciding on the appropriate course of action.

If the patient has a history of previous abdominal surgery and presents with small bowel obstruction but without signs of peritonitis, the working diagnosis is “simple” adhesive small bowel obstruction. The initial management of these patients is conservative, with intravenous fluids and nasogastric tube decompression. If the obstruction is complete (e.g., no gas in the colon above the peritoneal reflection of the rectum), the chances of spontaneous resolution are small and some surgeons would opt for an operative intervention. In the presence of clinical peritonitis, fever, and elevated white blood cell count, the indication for laparotomy is clear-cut (see Chap. 21).

There are three classical pitfalls with small bowel obstruction:

- The obese elderly lady with no previous surgical history who presents with small bowel obstruction, where an incarcerated femoral hernia can easily be missed if not specifically sought
- The elderly patient with a “simple” adhesive small bowel obstruction who improves on conservative treatment and is discharged only to come back later with a large tumor mass in the right colon
- The elderly lady whose “partial” small bowel obstruction “resolves and recurs” intermittently and is finally diagnosed as gallstone ileus
- The patient with a history of previous gastric surgery who presents with intermittent episodes of obstruction originating from a bezoar in the terminal ileum

Unlike small bowel obstruction, colon obstruction is always an indication for surgery – “tonight or tomorrow” but usually “tomorrow”. A plain abdominal X-ray cannot make the diagnosis where functional **colonic pseudo-obstruction** (Ogilvie’s syndrome) or chronic megacolon cannot reliably be distinguished from a mechanical obstruction. Thus, these patients usually undergo either fiberoptic colonoscopy or a contrast enema to clinch the diagnosis. The management option for these patients is operation after adequate preparation (see Chap. 25).

Important Medical Causes

While there is a large number of non-surgical causes that may result in acute abdominal pain, two must be kept constantly in your mind: inferior wall myocardial infarction and diabetic ketoacidosis. A negative laparotomy for porphyria or even basal pneumonia is an unfortunate surgical (and medicolegal) occurrence, but inadvertently operating on a patient with an undiagnosed inferior wall MI or diabetic ketoacidosis may well be a lethal mistake that should be avoided at all costs.

Wherever you practice you may be exposed to a growing number of HIV-positive patients suffering from AIDS, who are susceptible to a large number of abdominal conditions, which can produce or mimic an “acute abdomen”. In

◉ Chap. 33 we will tell you how to deal with these patients, most of them being best treated without an operation.

Conclusion

The multiple etiologies of the acute abdomen converge to five distinct and well-defined clinical patterns, each of which is associated with a specific management option. You should be familiar with these patterns and with the various management options. You should also keep in mind the classical pitfalls inherent in this common surgical condition in order to avoid gross errors in the surgical care of such patients. After all, you already have enough cases to present at the morbidity and mortality (M & M) meeting, don't you? (◉ Chap. 52).

“It is as much an intellectual exercise to tackle the problems of belly ache as to work on the human genome.” (Hugh Dudley)

Who Should Look After the “Acute Abdomen” and Where?

Everybody's business is nobody's business

The majority of patients suspected of having an acute abdomen or other abdominal emergency do not require an operation. Nevertheless, it is you – the surgeon – who should take, or be granted, the leadership in assessing, excluding or treating this condition, or at least, play a major role in leading the managing team. To emphasize how crucial this issue is, we dedicate an entire section of this chapter to it – although its scope would fit into a paragraph.

Unfortunately, in “real life”, surgeons are often denied the primary responsibility. Too often we see patients with **mesenteric ischemia** (◉ Chap. 23) rotting away in medical wards, the surgeon being consulted “to evaluate the abdomen”, only when the bowel – and, subsequently, the patient – has died. A characteristic scenario is a patient with an abdominal surgical emergency, admitted under the care of non-surgeons who undertake a series of unnecessary, potentially harmful and expensive diagnostic and therapeutic procedures. Typically, internists, gastroenterologists, infectious-disease specialists and radiologists are involved, each prescribing his own wisdom in isolation (◉ Fig. 3.2). When, finally, the surgeon is called in, he finds the condition difficult to diagnose, partially treated or maltreated. Eventually, the indicated operation is performed, but too late and thus carries a higher morbidity and mortality. The etiology of such chaos is not entirely clear. Motives of power, ego and financial considerations are surely involved.



Fig. 3.2. “Who is responsible?”

The team approach to the acutely ill surgical patient should not be discarded. The team, however, should be led and co-ordinated by a general surgeon. He is the one who knows the abdomen from within and without. He is the one qualified to call in consultants from other specialties, to order valuable tests, to veto those that are superfluous and wasteful. And, above all, he is the one who will eventually decide that enough is enough and the patient needs to be taken to the operating room.

When you decided to become a general surgeon you became the captain of the ship, navigating the deep ocean of the abdomen. Do not abandon your ship while the storm rages on!

Continuity of care is a *sine qua non* in the optimal care of the acute abdomen as the clinical picture, which may change rapidly, is a major determinant in the choice of therapy and its timing. Such patients need to be frequently re-assessed by the same clinician who should be a surgeon. Any deviation from this may be hazardous to the patient; this is our personal experience and that which is repeated *ad nauseum* in the literature. But why should we be re-inventing the wheel? Why don't we learn? The place for the patient with an acute abdominal condition is on the surgical floor, surgical intensive-care unit (ICU), or in the operating room and under the care of a surgeon – yourself! Don't duck your responsibilities!

Only 10 or 20 years ago, when we were residents, an “acute abdomen” and clinical evidence of peritonitis mandated an operation. Today we are smarter. Judicious usage of diagnostic modalities (see Chap. 4) and better understanding of the natural history of various disease processes allow us to decrease mortality and

morbidity by being less invasive and more selective and, in general, to achieve more by doing less harm.

The key for the “best” outcome of the acute abdomen is:

- Operate only when necessary, and do the minimum possible
- Do not delay a necessary operation, and do the maximum when indicated

Advice: When you finish this book go and buy yourself Cope’s Early Diagnosis of the Acute Abdomen. Zachary Cope, who died in 1974, published the first edition of his book in 1921. The current edition is the twentieth! You cannot be a real general surgeon without reading this book. Or can you?

MOSHE SCHEIN

Believe nobody – question everything

“To open an abdomen and search for a lesion as lightly as one would open a bureau drawer to look for the laundry, may mean lack of mental overwork to the surgeon, but it means horror to the patient.” (J. Chalmers Da Costa, 1863–1933)

When treating a patient with acute abdominal pain it is tempting to make extensive use of ancillary investigations. This leads to the emergence of “routines” in the emergency room (ER) whereby every patient with acute abdominal pain undergoes a plain X-ray of the abdomen (AXR) and a series of blood tests, which typically include a complete blood count, routine blood chemistry and serum amylase. These “routine” tests have a very low diagnostic yield and are not cost-effective. However, they are also an unavoidable part of life in the ER and are often obtained before the surgical consultation.

For the vast majority of patients who on examination have a clear-cut *diffuse peritonitis* no imaging is necessary because a laparotomy is indicated. But what appears clear cut to the experienced surgeon may be less so for you. Bear in mind the following caveats:

- **Intestinal distension**, associated with obstruction or inflammation (e.g., enteritis or colitis) may produce diffuse abdominal tenderness – mimicking “peritonitis”. The “whole” clinical picture as well as the AXR will guide you toward the proper diagnosis (🔗 Chaps. 21 and 25).
- **Acute pancreatitis** may present with clinical acute peritonitis. You should obtain, therefore, a serum *amylase* level in order to avoid falling into the not so uncommon trap of unnecessarily operating on acute pancreatitis. (🔗 Chap. 18)
- In any patient who receives or has recently received any quantity of antibiotics think about ***C. difficile enterocolitis***, which may present – from the beginning – as an acute abdomen without diarrhea. Here, the optimal initial management is medical and not a laparotomy; bedside sigmoidoscopy and/or computed tomography (CT) may be diagnostic (🔗 Chap. 24).

* Asher Hirshberg, MD contributed to this chapter in the 1st edition of the book.

Chest X-ray (CXR)

A CXR is routinely obtained to search for free air under the diaphragms, which is demonstrated in the majority of patients with perforated peptic ulcer (↪ Chap. 17) but less frequently when colonic perforation is the underlying problem (↪ Chap. 26). Remember that free air is better seen on an erect CXR than AXR. Free intra-peritoneal air is not always caused by a perforated viscus and it is not always an indication for a laparotomy. There is a long list of “non-operative” conditions that may produce free intra-peritoneal air, such as a tension pneumothorax or even vigorous *cunnilingus* (oral sex). So, rather than being dogmatic, look at the whole clinical picture.

Any textbook tells you that lower lobe pneumonia may mimic an acute abdomen, so think about it. Obviously, findings such as lung metastases or pleural effusion may hint at the cause of the abdominal condition and influence treatment and prognosis. Pneumothorax, pneumomediastinum or pleural effusion may be associated with spontaneous esophageal perforation – Boerhaave’s syndrome (↪ Chap. 14), which can present as an acute abdomen. The value of a CXR in blunt or penetrating abdominal injury is obvious. A pre-operative CXR may also be requested by the anesthesiologists, especially after you have inserted a central venous line, or for no reason at all.

Plain Abdominal X-ray (AXR)

This is the classical surgeon’s X-ray, as only surgeons know how to rely on those simple and cheap radiographs. Radiologists can look and talk about AXRs forever, searching for findings that could justify “additional” imaging studies. We surgeons need only a few seconds to decide whether the AXR is “non-specific”, namely, does not show any obvious abnormality, or shows an *abnormal gas pattern* or *abnormal “opacities”*. Unfortunately, in many of today’s “modern ERs” the humble AXR is bypassed in favor of the high-tech CT. In fact now, for many (but hopefully not for you), the CT supplants AXR as well as proper history taking and physical examination. Do not forget that we operate on patients and not on CT abnormalities. Go to ↪ Chap. 5 to read about AXR in detail.

Abdominal Ultrasound (US)

Abdominal US is a readily available diagnostic modality in most places. Its reliability is operator dependent; the ideal situation is when the US is performed and interpreted by an experienced clinician – a surgeon. US is very accurate in the

diagnosis of acute cholecystitis (➤ Chap. 19); it is also used by the gynecologists to rule out acute pelvic pathology in female patients (➤ Chap. 31), and to demonstrate an acutely obstructed kidney caused by a ureteric stone. A non-compressible tubular structure (a “small sausage”) in the right lower quadrant may be diagnostic of acute appendicitis, but as will be discussed in ➤ Chap. 28 you rarely need abdominal imaging to reach this diagnosis. US is useful in demonstrating intra-abdominal fluid – be it ascites, pus, or blood, localized or diffuse. In blunt abdominal trauma, FAST (focused abdominal sonography for trauma) has emerged as a serious rival to diagnostic peritoneal lavage (➤ Chap. 35).

Abdominal Computed Tomography

The use of the CT scan in the acute abdomen is not well defined, and remains a subject of some controversy. While it is true that a CT scan should *not* be part of the management algorithm in most patients with acute abdominal pain, the new spiral CT technology is nevertheless immediately available, very powerful and thus extremely tempting to use, especially by less experienced clinicians.

A case in point is acute diverticulitis (➤ Chap. 26). Once the clinical pattern of localized peritonitis in the lower left quadrant has been identified, initial management is conservative. A CT may show the inflammatory process and even a paracolic abscess, but will not distinguish between diverticulitis and a localized perforation of a colonic tumor. In any case, this will not alter the approach because most surgeons would still opt for a trial of intravenous antibiotics as the initial treatment modality for this clinical pattern (➤ Chap. 26).

The true role of the CT, where it can really make a critical difference, is with “clinical puzzles”. Not infrequently, the surgeon encounters a patient with acute abdominal pain that does not fit any of the clinical patterns described in the previous ➤ Chap. 3. The patient is obviously sick, but the diagnosis remains elusive. Occasionally, there may be a suspicion of acute intra-abdominal pathology in an unconscious patient. Under these unusual circumstances, the CT scan may be very helpful in identifying an intra-abdominal problem. It is even better in *excluding* the latter by an absolutely normal CT. CT is frequently indicated in patients with blunt abdominal trauma as discussed below (➤ Chap. 35).

Judicious and selective use of CT may help in avoiding surgery altogether – where previously “negative” or “exploratory” or “non-therapeutic” operations would have been performed. It may suggest that alternative percutaneous treatment is possible and, even if operation is still indicated, CT may dictate the optimal incision and approach (➤ Chap. 10). CT has a definite role in the post-laparotomy patient as discussed in ➤ Chap. 46. For detailed discussion on the interpretation of abdominal CT go to ➤ Chap. 5.

A Word of Caution

For most patients with acute abdominal pain, unnecessary ancillary investigations are merely a resource problem and a waste of time. But for two types of surgical problems, unnecessary imaging is often lethal:

- **Acute mesenteric ischemia** is the only life-threatening abdominal condition that cannot be easily classified into one of the five clinical patterns described in ◉ Chap. 3. Because of this, and because the window of opportunity to salvage viable bowel is so narrow, you must have this diagnosis constantly embedded in the back of your mind. The best chance to salvage these patients is to identify the clinical picture of very severe abdominal pain with few objective findings in the appropriate clinical context (◉ Chap. 23) and to proceed directly to mesenteric *angiography*. Needless to say, if the patient has diffuse peritonitis, no imaging is necessary and the next step is an urgent laparotomy. The tragedy in these patients is the inability of even an experienced clinician to make his or her mind up regarding the need for urgent angiography. As a result the patient is sent for a long series of non-relevant imaging studies and the opportunity to salvage viable bowel is lost.

- The second condition where the abuse of imaging is often lethal is with a **ruptured abdominal aortic aneurysm (AAA)** (◉ Chap. 37). A ruptured AAA may not present as abdominal pain and shock but merely as severe abdominal or back pain, and it may not be easily palpable in an obese patient. When the possibility of a contained rupture is raised in a hemodynamically stable patient, the one and only ancillary investigation that is required is an urgent CT scan of the abdomen. Unfortunately, too many times these patients spend several hours in the ER, waiting for the results of non-relevant blood tests and progressing slowly along the imaging path from AXRs, which are usually non-diagnostic, to US, which shows the aneurysm but usually cannot diagnose a rupture, to a long wait for unnecessary contrast material to fill the bowel in preparation for a “technically perfect” CT scan. The tragic consequence of these delays is a dramatic hemodynamic collapse either before or during an abdominal CT scan.

Contrast Studies: Barium vs. Water-soluble Contrast

A caveat: in emergency situations do not use barium! Radiologists prefer barium because of its superior imaging qualities, but for us – surgeons – barium is an enemy. Bacteria love barium, for it protects them from the peritoneal macrophages; a mixture of barium with feces is the best experimental recipe for the production of intractable peritonitis and multiple intra-abdominal abscesses. Once barium leaks into the peritoneal cavity it is very difficult to get rid of. Barium administered to the gastrointestinal tract from above or below tends to stay there for many days – distorting any subsequent CT or arteriography.

A contrast study in the emergency situation has only two queries to answer:

- Is there a **leak** and, if so, where?
- Is there an **obstruction** and, if so, where?

For these purposes Gastrografin is adequate. Use Gastrografin in upper gastrointestinal studies to document or exclude gastric outlet obstruction or a Gastrografin enema to diagnose colonic obstruction or perforation. Unlike barium, Gastrografin is harmless should it leak into the peritoneal cavity. Try to operate on a colon full of barium: a clamp slides off, a stapler misfires and you – not the radiologist – are the one left to clean the mess. Take some advice from our bitter experience: *ordering* a Gastrografin study is not enough; you must personally ensure that barium is not used.

Blood Tests

As stated above, “routine labs” are of minimal value. In addition to amylase level the only “routines” that can be supported are white cell count and hematocrit. *Elevated white cell count* denotes an inflammatory response. Be aware, however, that you can diagnose acute cholecystitis or acute appendicitis even when the white cell count is within a normal range. Its elevation, however, supports the diagnosis. Low *hematocrit* in the emergency situation signifies a chronic or subacute anemia; it does not reflect on the magnitude of any acute hemorrhage. *Liver function tests* are of some value in patients with right upper quadrant pain, diagnosed to have acute cholecystitis (▶ Chap. 19) or cholangitis (● Chap. 20). Serum *albumin* on admission is a useful marker of the severity of the acute, or acute-on-chronic disease, and is also of prognostic value. When operating, for example, on someone with albumin levels of 1.5 g%, you know that you have to do the minimum and to expect troubles after the operation.

Whichever tests are ordered, either by you or by someone else on your behalf (usually the ER doctor), be aware that the significance of the results should never be judged in isolation but considered as part of the whole clinical picture.

Unnecessary Tests

Unnecessary testing is plaguing modern medical practice. Look around you and notice that the majority of investigations being ordered do not add much to the quality of care. Unnecessary tests, on the other hand, are expensive and potentially harmful. In addition to the therapeutic delay they may cause, be familiar with the following paradigm: **the more non-indicated tests you order, the more false positive results are obtained, which in turn compel you to order more tests and lead**

to additional, potentially harmful, diagnostic and therapeutic interventions. Eventually, you lose control...

What are the reasons for unnecessary tests? The etiology is a combination of ignorance, lack of confidence, and laziness. When abdominal emergencies are initially assessed by non-surgeons who do not “understand” the abdomen, unnecessary imaging is requested to compensate for ignorance. Junior clinicians who lack confidence tend to order tests “just to be sure – not to miss” a rare disorder. And experienced clinicians occasionally ask for an abdominal CT over the phone in order to procrastinate. Isn’t it easier to ask for a CT rather than to drive to the hospital in the middle of the night and examine the patient? (“Let’s do the CT and decide in the morning...”).

An occasional surgical trainee finds it difficult to understand “what’s wrong with excessive testing?” “Well” we tell him or her, “Why do we need you at all? Let us all go home instead, and instruct our ER nurses to drive all patients with abdominal pain through a predetermined line of tests and imaging modalities”. Patients are not cars on a production line in Detroit. They are individuals who need your continuous judgment and selective use of tests.

Be careful before adopting an investigation claimed to be “effective” by others. You read, for example, that, in a Boston ivory tower, routine CT of the abdomen has been proven cost-effective in the diagnosis of acute appendicitis. Before succumbing to the temptation to order a CT for any suspected acute appendicitis check out whether the methods used in the original study can be duplicated in your own environment. Do you have senior radiologists to read the CT at 3 a.m. – or would the CT be reported only in the morning – after the appendix is, or should be, in the formalin jar?

Perhaps the day is near, when all patients on their way from the ambulance to the ER will be passed through a total body CT scanner – read by a computer. But then luckily we will not be practicing surgery and this book will be out of print. We do not believe, however, that patients will fare better under such a system.

Diagnostic Laparoscopy

This is an invasive diagnostic tool (some call it “controlled penetrating abdominal trauma”) to be used in the operating room, after the decision to intervene has been already taken. It has a selective role as discussed in ◀ Chap. 51.

The more the noise – the less the fact

“God gave you ears, eyes, and hands; use them on the patient in that order.”
(William Kelsey Fry, 1889–1963)

Abdominal Imaging

MOSHE SCHEIN · SAI SAJJA · HANS ULRICH ELBEN

*“The diagnostic problem of to-day
Has greatly changed – the changes have come to stay;
We all have come to confess, though with a sigh
On complicated tests we much rely
And use too little hand and ear and eye.”
(The Acute Abdomen in Rhyme, Zachary Cope, 1881–1974)*

There are fundamental differences in how physicians belonging to the different specialties involved in decision-making concerning the “acute abdomen” look at abdominal imaging. The radiologists’ sharp eyes see “everything” but they tend to see “too much” – not always understanding the clinical significance of what they see. ER physicians do not see much and do not understand the meaning of the little they do see; all they care about is where to dump the patient. This leaves us with ourselves, the surgeons. Armed with a better understanding of the natural history of the disease processes, and able to correlate radiological imaging with previous operative observations, we should be the finest interpreters of abdominal imaging. We already discussed above (Chap. 4) the role of abdominal imaging in the evaluation of the patient with an “acute abdomen”. In this chapter we will try to provide you with practical tips on **how to look at the images and what to too look for**.

Plain Abdominal X-ray (AXR)

MOSHE SCHEIN

Tragically, this simple, cheap and safe X-ray is increasingly bypassed in favor of an immediate computed tomography (CT) scan – which delivers a much greater radiation dose. This is a pity because there is so much that you can learn from a quick glance at the AXR.

Abnormal Gas Pattern

Gas Outside the Bowel

- Free gas (pneumoperitoneum) is best seen on an erect chest X-ray (CXR; Chap. 4) but may also be seen on an AXR (Fig. 5.1). If the CXR is “normal” and

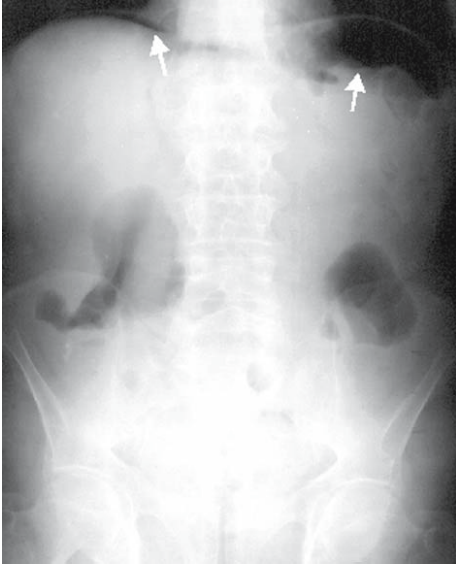


Fig. 5.1. Abdominal X-ray, upright position. Pneumoperitoneum. Air under both diaphragms (*arrows*)

you suspect perforation of a viscus, a left lateral decubitus abdominal film may show free gas in the peritoneal cavity.

- Make a habit always to look for **atypical free gas** patterns – occasionally you may be rewarded with an eye-popping diagnosis: **Gas in the biliary tree** (pneumobilia) implies either a cholecysto-enteric fistula (gallstone ileus; ◉ Chap. 21) or a previous entero-biliary bypass or, more commonly, a sphincterotomy of the sphincter of Oddi (via ERCP, endoscopic retrograde pancreatography) (◉ Fig. 5.2). Note that gas in the intra-hepatic biliary ducts appears *centrally*, while gas in the *periphery* of the liver suggests **portal vein gas**. The gas finds its way into the portal venous system through a breach in the bowel wall – usually associated with *mesenteric ischemia* or *severe colitis* – and rarely with *pyelophlebitis* (◉ Fig. 5.3). Commonly, gas in the portal vein as a result of ischemic small or large bowel is associated with **pneumatosis intestinalis**, i.e., the presence of intramural gas (◉ Fig. 5.4).
- Gas within the wall of gallbladder signifies a necrotizing infection (◉ Chap. 19). **Soap-bubble appearance** signifies free gas in the *retroperitoneum*, in the epigastrium it is associated with *infected pancreatic necrosis* (◉ Chap. 18), in the right upper quadrant with a retroperitoneal *perforation of the duodenum*, and in either gutter it is associated with retroperitoneal perforation of the *colon* (◉ Fig. 5.5).

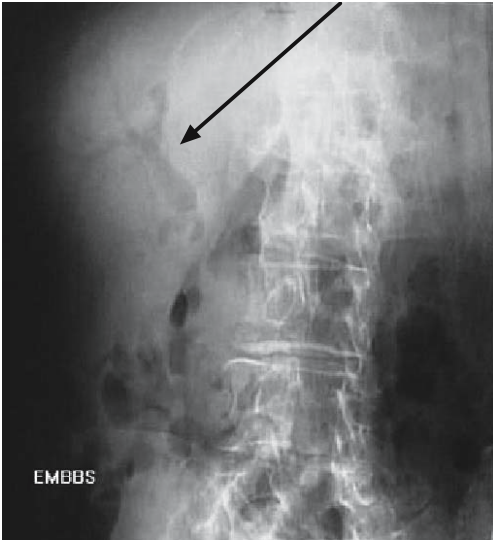


Fig. 5.2. Abdominal X-ray. Air in biliary tract (*arrow*)

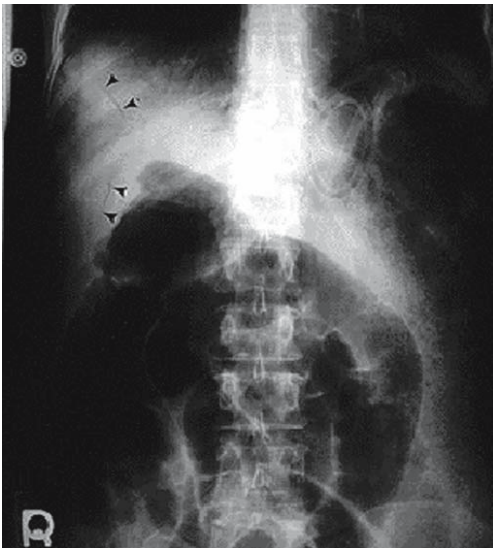


Fig. 5.3. Abdominal X-ray. Air in portal veins (*arrowheads*)

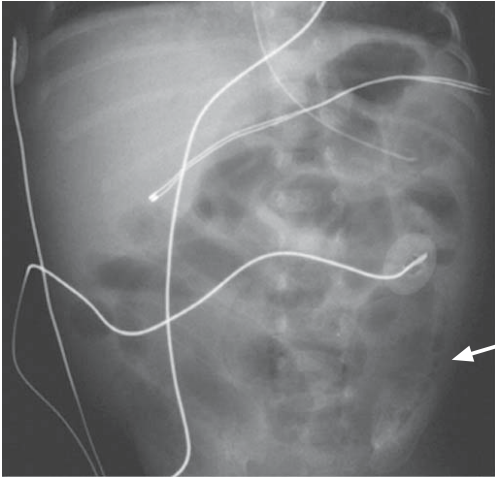


Fig. 5.4. Abdominal X-ray: Pneumatosis intestinalis (*arrow*)

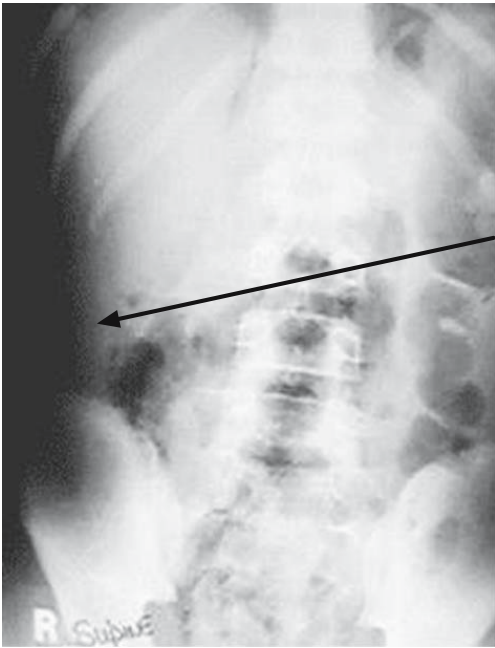


Fig. 5.5. Abdominal X-ray. Free retroperitoneal air (*arrow*)

Gas Within the Bowel

- Abnormal gaseous distension/dilatation of **small bowel loops**, with or without fluid levels, implies a small bowel process – be it *obstructive* (small bowel obstruction, ⦿ Chap. 21), *paralytic* (ileus, ⦿ Chap. 43) or *inflammatory* (Crohn’s disease, ⦿ Chap. 24). Remember – *acute gastroenteritis* may produce small bowel fluid levels; the diarrhea hints at the diagnosis.
- Abnormal gaseous distention/dilatation of the *colon* denotes colonic *obstruction* or *volvulus* (⦿ Chap. 25), colonic *inflammation* (inflammatory bowel disease, ⦿ Chap. 24) or *colonic ileus* (pseudo-obstruction, ⦿ Chap. 25).

Distinguishing small bowel from colon on an AXR is easy: the “transverse lines” go all the way across the diameter of the small bowel (the valvulae conniventes) and only partly across the colon (the haustra). In general, loops of small bowel are situated centrally while large bowel occupies the periphery (⦿ Fig. 5.6).

Useful rules of thumb:

- Gaseous distension of small bowel + no gas in the colon = complete small bowel obstruction
- Significant gaseous distension of small bowel + minimal quantity of colonic gas = partial small bowel obstruction
- Significant gaseous distension of both the small bowel and the colon = paralytic ileus
- Significant gaseous distension of the colon + minimal distention of the small bowel = colonic obstruction or pseudo-obstruction

Abnormal opacities

The opacities which you are able to spot on the AXR are the calcified ones, *gallstones* in the gallbladder (visible in about one-third of patients with cholelithiasis), *ureteric stones* (visible in some patients with ureteric colic), pancreatic calcifications (seen in some patients with chronic pancreatitis), and *appendicular fecaliths* (occasionally seen in patients with a perforated appendicitis) (⦿ Fig. 5.7). Fecal matter may opacify the rectum and colon to a variable degree – achieving extreme proportions in patients with fecal impaction. Note that a moderate amount fecal material in the right colon is normal, while a column of feces on the left implies some abnormality, ranging in severity from simple constipation to early malignant obstruction. Another opacity, which may surprise you, is a forgotten surgical instrument or gauze swab (⦿ Fig. 5.8).

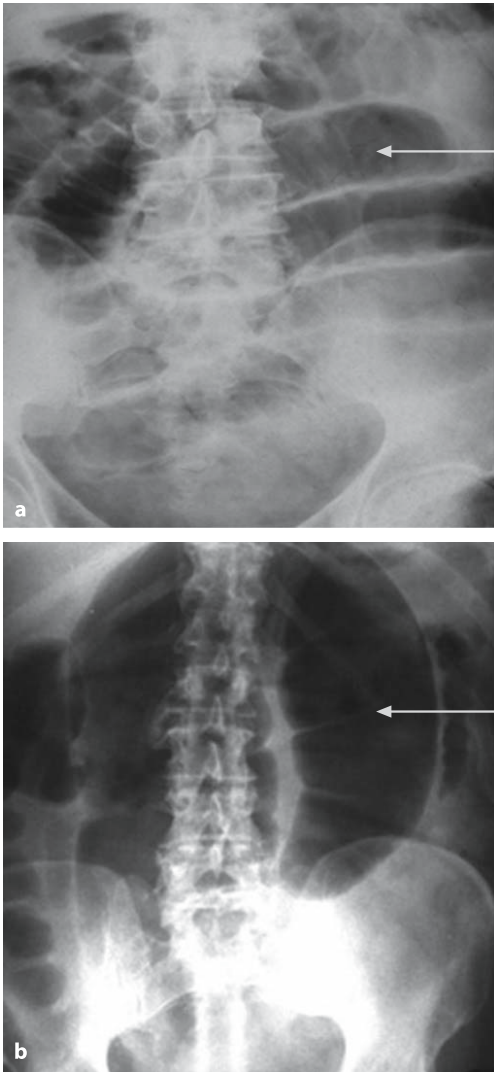


Fig. 5.6 a,b. Abdominal X-ray: small bowel vs. large bowel. **a** Small bowel obstruction. Note the valvulae conniventes (*arrow*) crossing the whole width of bowel. **b** Volvulus of the sigmoid colon. Note the haustra crossing a portion of bowel width (*arrow*)

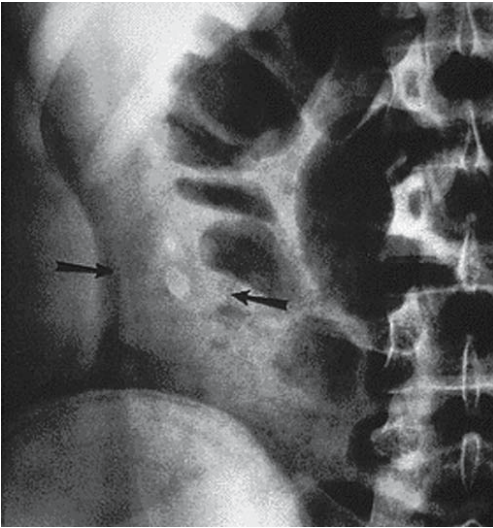


Fig. 5.7. Abdominal X-ray. Appendicular fecalith (*arrows*; when visualized in a patient with symptoms and signs of acute appendicitis it is highly diagnostic)

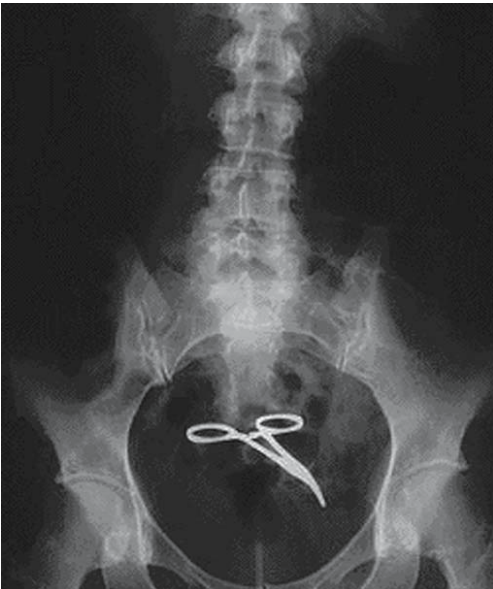


Fig. 5.8. Abdominal X-ray. Retained surgical clamp

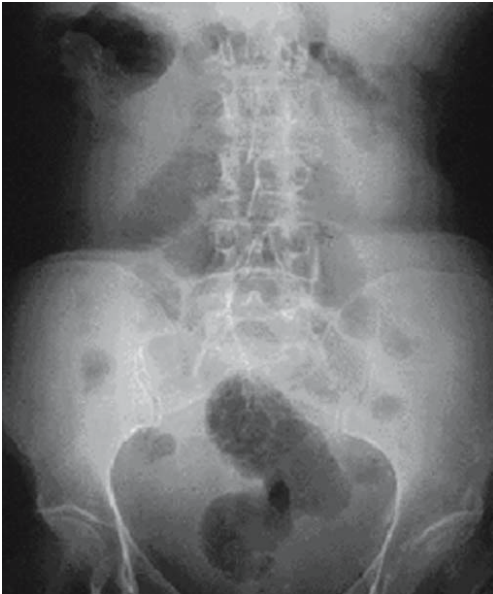

Fig. 5.9. Abdominal X-ray. Massive ascites. In the supine position the bowel gas lies centrally and there is nothing peripherally. The lighter bowel loops are practically floating on a lake of ascites in the abdominal cavity

Also, **massive ascites** has a typical picture on AXR (➤ Fig. 5.9).

The simple abdominal X-ray is an extension of your clinical evaluation, which is not complete without it.

Computed Tomography in Abdominal Emergencies

SAI SAJJA · MOSHE SCHEIN

The road to the operating room does not have always to pass through the CT scanner but an indicated CT may obviate the need for an operation

The supremacy of CT in the imaging of the abdomen is not in dispute. CT shows details that no other diagnostic method does: free gas, fluid, masses, tissue planes, inflammatory changes, opacities, blood vessels and organ perfusion. So why should we object to the indiscriminate use of CT as practiced today in many countries across the world?

We object for the simple reason that in most patients the diagnosis can be established without CT – the obtaining of which often only delays treatment and

confuses the picture by showing non-significant findings (see ◉ Chap. 4). Typically, whenever radiologists publish papers on the use of CT in various abdominal emergencies they always declare sensitivity and specificity rates approaching 100%. When surgeons, however, look objectively at the overall impact of CT on the diagnosis and treatment of specific conditions, the real impact of CT is usually marginal (e.g., in acute diverticulitis, acute appendicitis).

In addition, remember that the radiation exposure of one abdominal CT examination can be several hundred times that of a chest X-ray. According to the US Food and Drug Administration this amount of radiation exposure may be associated with a small increase in radiation-associated cancer in an individual. This would be detrimental if people were to receive this examination *repeatedly*, starting at a young age.

The key word in the effective use of abdominal CT is “selectivity”. Rather than indicating a need for exploration, CT is more useful in deciding when NOT to operate – avoiding unnecessary “exploratory” laparotomies or “diagnostic” laparoscopies. Also, a “normal CT” can exclude surgical abdominal conditions – allowing the early discharge of patients without the need for admission for observation.

The recent introduction of fast scanners that image the abdomen from the diaphragm to the pubis in a single breath-hold has greatly improved the image quality and reduced the time required to obtain the images. However, it does require that patients be transported to the CT suite and exposes them to the risks of aspiration of oral contrast media and adverse reactions to intravenous (IV) contrast media such as anaphylaxis and nephrotoxicity. Unenhanced (no IV contrast) helical or spiral CT scans are being increasingly used in suspected appendicitis, while CTs without oral contrast have been reported as accurate in patients suffering from blunt abdominal trauma. **Whatever the CT methodology in your hospital, you – who knows the abdomen inside out and understands the natural history of abdominal diseases – have to be able to analyze the CT images better than the radiologist.**

As is the case with all imaging studies, interpretation of CT scan images requires a systematic approach, and it takes plenty of practice to become confident in one’s own ability. One also needs to spend time, and the more time you spend the more findings – both negative and positive – you pick up. We are going to describe the way we look at a CT scan of the abdomen; it is not “ideal” or “perfect” but it works for us, especially in the middle of the night when all the radiologists are snoring in bed. [In the morning they will, with latte in hand, dictate detailed reports...]

It is important to pay attention to a few technical aspects of the study before beginning to interpret it. While there is a lot of literature to support the notion that there is no need for oral or intravenous contrast material, the use of the latter improves *your* own diagnostic yield. One exception to this is when *ureteric calculi*

are at the top of the differential diagnosis list and a non-contrast study gives almost all the information required.

Contra-indications to Intravenous Contrast Medium

- Impaired renal function
- History of prior allergic reaction to iodinated contrast medium
- Severe asthma or congestive heart failure
- Diabetic patient on metformin
- Multiple myeloma or sickle-cell anemia

Reviewing the Abdominal CT

It is important to note the distance between two CT “slices”. Usually the technologists use 7-mm intervals between the slices but it is sometimes helpful to request 5-mm or even 3-mm cuts of the appendiceal area in a clinically challenging case. Also, it is essential to ensure that you have all the images by looking at the image numbers. Some hospitals have done away with hard copies and introduced instead Picture Archiving and Communication Systems (PACS), which make access to images easier.

We always begin with a good look at the scout film; it provides similar information as a flat plate of the abdomen and provides a “global view”. The visualized portions of the lower lung fields should also be looked at in both *mediastinal* and *lung windows*. Pulmonary infiltrates and pleural effusions can be easily identified and at times are a reflection of an acute sub-diaphragmatic process. An unsuspected pneumothorax in a trauma patient will also be obvious in the lung windows.

Whilst it is easier to concentrate on the area of interest (e.g., the right lower quadrant in a patient with suspected appendicitis) and look for findings to support or exclude the diagnosis, it is essential to look at the rest of the abdomen. One needs to look specifically for the presence of free gas and free fluid, and to see all the solid organs (liver, spleen, kidneys), stomach, small and large bowel, the pancreas and blood vessels. **One key point is to follow the structure in question in serial images – stacking – to obtain as much information as possible.**

Pneumoperitoneum

While an erect chest film can identify a straightforward case of pneumoperitoneum, CT scan is the most sensitive means available for its detection. On a CT

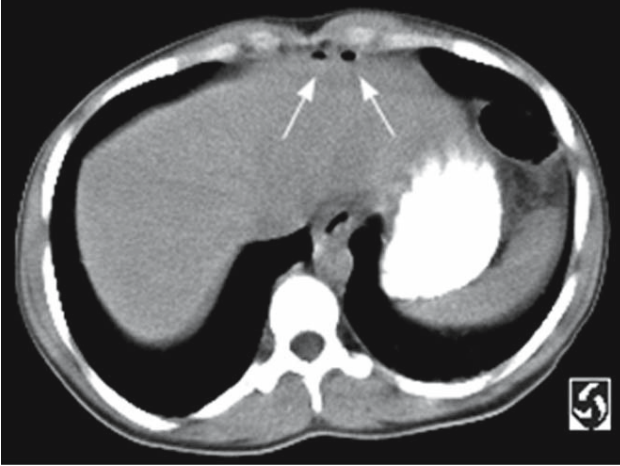


Fig. 5.10. CT: two pockets of extraluminal gas in the epigastric region (*arrows*)

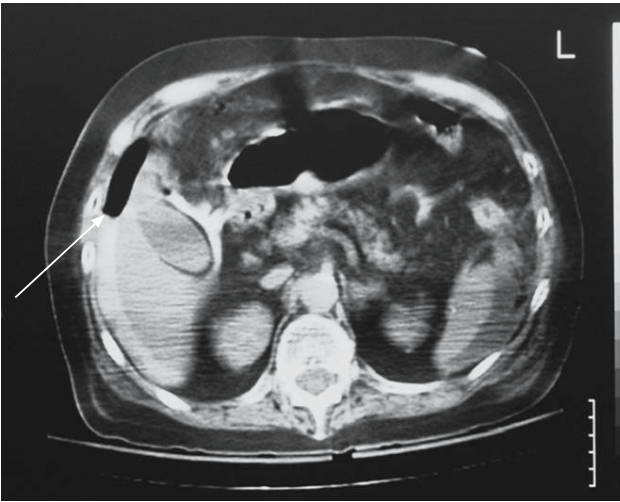


Fig. 5.11. CT in a patient with perforated duodenal ulcer: free gas between the liver and anterior abdominal wall (*arrow*). Gas is also seen around the gallbladder and leakage of orally administered contrast is seen around the liver

scan gas collects beneath the two rectus muscles around the falciform ligament (◉ Fig. 5.10). It also collects between the liver and anterior abdominal wall and within the “leaves” of the mesentery (◉ Fig. 5.11). The findings are at times very subtle and only few bubbles of extra luminal gas are all that is required to make the diagnosis of pneumoperitonem. The key to the identification of extraluminal gas is inspection of all the scans of the abdomen in *lung windows*. It is easier with PACS as

we can manipulate the window settings. Even if your hospital does not have PACS, the CT scan station will have the ability to do that.

Free Fluid

Free fluid from any source tends to accumulate in the most dependent parts of the peritoneal cavity: Morrison's hepatorenal pouch and the pelvis. When there is a large amount of fluid the bowel loops float to the midline. In addition to identifying the presence of fluid, measurement of the fluid density offers some clues regarding its nature: less than 15 Hounsfield Units (HU) for transudative ascites, and more than 30 HU for exudative ascites or blood.

Solid Organs

While solid organ pathology is a rare cause of non-traumatic acute abdominal conditions, CT is the modality of choice in the investigation of the hemodynamically stable victim of blunt abdominal trauma. Lacerations of the solid organs appear as linear or branching low-attenuation areas. Sub-capsular hematomas appear as crescentic low-attenuation areas at the periphery. Intra-parenchymal hematomas appear as round or oval collections of blood within the parenchyma.

Hollow organs

The entire gastrointestinal tract from the stomach to rectum can be traced in serial sections and abnormalities should be sought. In case of small bowel obstruction, the cause (e.g., tumor or inflammatory mass) and the site of obstruction (the transition point) can be identified (◉ Fig. 5.12). The presence of *pneumatosis* can be identified more readily with CT and, if present, suggests intestinal ischemia. CT is also sensitive for identifying inflammation, which is suggested by the appearance of tissue infiltration or *stranding* (◉ Figs. 5.13 and 5.14).

The various CT scan findings that are associated with acute appendicitis are as follows:

Appendiceal signs

- Appendix >6 mm in antero–posterior diameter
- Failure of the appendix to fill with oral contrast or gas to its tip
- Enhancement of the appendix with IV contrast
- Appendicolith

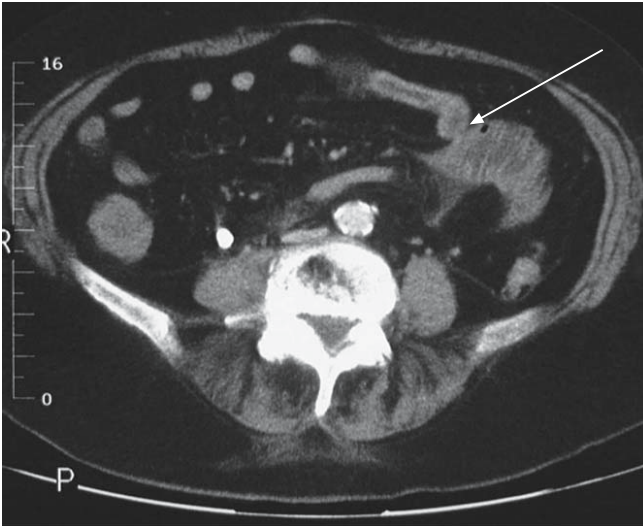


Fig. 5.12. CT in a patient with small bowel obstruction showing the transition point between the distended proximal and collapsed distal bowel (*arrow*)

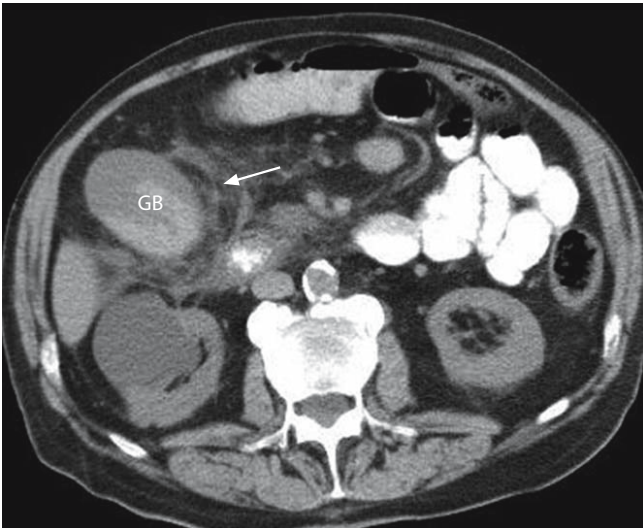


Fig. 5.13. CT scan through the upper abdomen shows a distended thick walled gallbladder (GB) with marked pericholecystic stranding (*arrow*) suggestive of acute cholecystitis

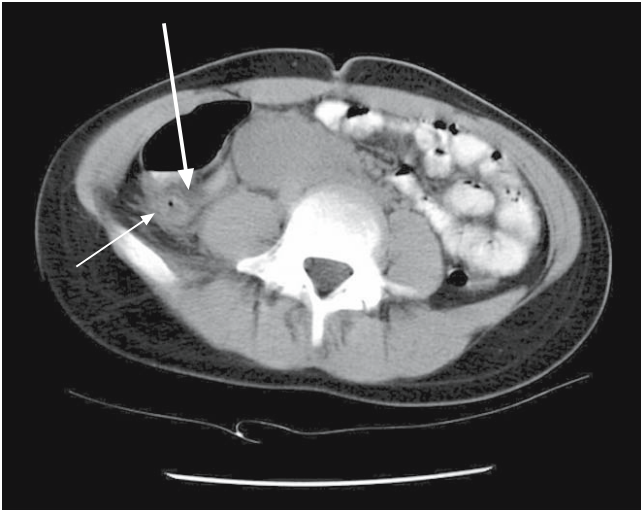


Fig. 5.14. CT scan through the right lower quadrant showing thickened appendix (*thin arrow*) with peri-appendiceal fat infiltration (*thick arrow*) confirming the diagnosis of acute appendicitis

Periappendiceal signs

- Increased fat attenuation (stranding) in the right lower quadrant
- Cecal wall thickening
- Phlegmon in the right lower quadrant
- Abscess or extra-luminal gas
- Fluid in the right lower quadrant or pelvis

Similarly, stranding in the left lower quadrant, or thickening of the sigmoid colon suggests diverticulitis (◊ Fig. 5.15). Diffuse thickening of the colon suggests an inflammatory process like colitis whether infective or ischemic. (◊ Fig. 5.16).

The retroperitoneum including the pancreas should then be looked at; the presence of stranding and fluid collections around the pancreas suggests pancreatitis. Retroperitoneal hematoma next to an abdominal aortic aneurysm suggests a leak.

It is also important to look at the pelvic organs in female patients. Particular attention should be paid to any large cystic masses in the adnexa, which may suggest a complicated cyst, ovarian torsion or a tubo-ovarian abscess.

You can admit your patient to the operating room without showing his CT like a ticket (◊ Fig. 5.17) – but occasionally such a ticket will change your operative plans or even cancel the need for the operation.

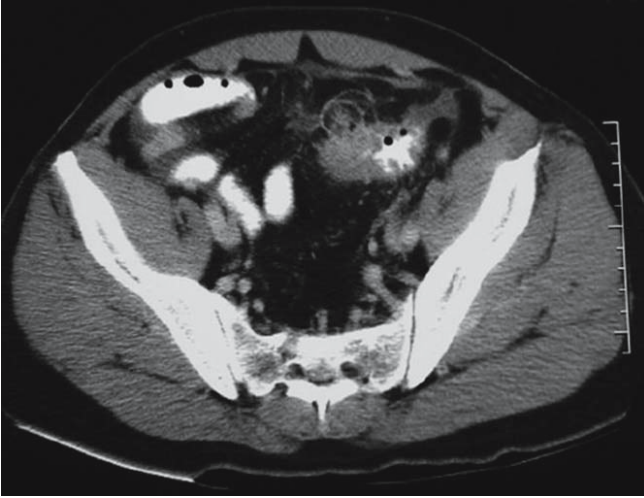

Fig. 5.15. Contrast enhanced CT scan of the lower abdomen showing thickening of the sigmoid colon with diverticula and surrounding inflammation (acute diverticulitis)

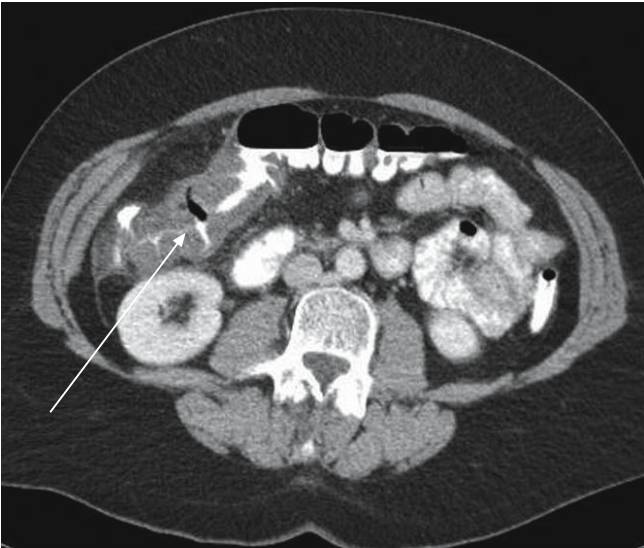

Fig. 5.16. Contrast enhanced CT scan showing thickening of the hepatic flexure of the transverse colon (*arrow*) suggestive of colitis



Fig. 5.17. “Where is the CT!”

Invited Commentary: How to Read and Interpret the Abdominal CT for an Acute Abdomen

HANS ULRICH ELBEN

How to order a CT examination

Contrary to what you may think, a few of us radiologists understand something about medicine and surgery. And a few of us know something about CT scans. We therefore respectfully request that you please provide us with an accurate clinical picture and your tentative diagnosis when requesting a scan. You should tell us also about any relevant previous operations or injuries (like cholecystectomy, appendectomy, hysterectomy).

Technically State-of-the-Art CT Examination

A good CT examination is performed with a spiral CT after IV administration of a contrast medium. If possible, we also like to use an oral diluted Gastrografin medium. The latter can also be given rectally especially when suspecting acute diverticulitis, an obstructing colonic lesion or colonic trauma. In women with suspected gynecological pathology, you should mark the position of the vagina with a normal vaginal tampon. An important exception: in case of suspected ureteric colic the use of contrast media is not necessary.

Interpretation

Start with a scout view, similar to a plain abdomen X-ray in a supine patient.

Look at the distribution of gas in the stomach and the small and large intestine. Are there signs of free gas outside the intestinal lumen? It is absolutely necessary to look at the CT images in a special window for chest-examination (center -700 HU, window width 2000 HU) as well as in a normal window (center 40 HU, window width 400 HU). Thus, you will recognize free gas outside the intestinal lumen much better.

Step-by-Step Interpretation of Images According to the Organs

Try to examine every organ from cranial to caudal direction completely. Especially note the limits and the structures of the tissues.

Liver

Look at edges of the organ, homogeneous enhancement, and luminal contrast within the portal vein and its branches. **Important diagnoses:** blunt trauma with rupture of the liver, abscesses, portal vein thrombosis (▶ Fig. 5.18).

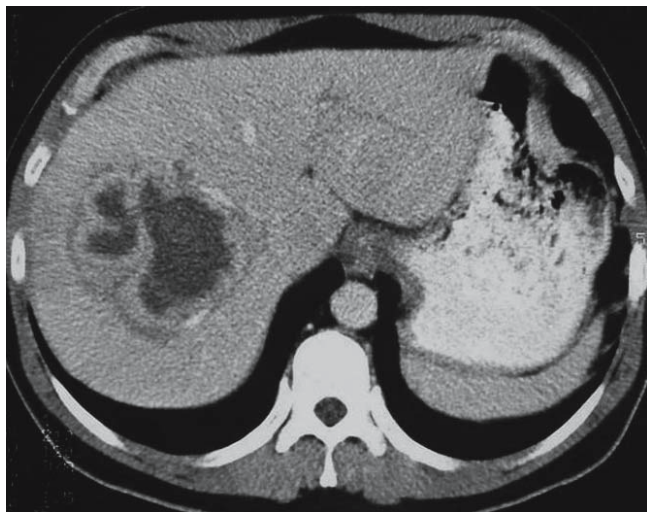


Fig. 5.18. Abdominal CT: intra-hepatic abscess. Note the enhancement of the wall

Gallbladder and Bile Ducts

The intrahepatic bile ducts accompany the branches of the portal vein. Normally they are hardly recognized unless dilated. If there is cholangiectasis follow the common bile duct down to the duodenal papilla. Do you see any signs of tumor-associated obstruction or choledocholithiasis?

Normally, the wall of the gallbladder is thin (about 2–3 mm). A distended gallbladder, thickened wall, a peri-cholecystic layer of fluid, a “halo” sign and intramural air are strong indications of cholecystitis (● Fig. 5.19).

Spleen

Notice the size and form of the organ. Is there homogeneous enhancement? Important diagnoses include traumatic or spontaneous rupture with lack of contrast and fluid around the spleen, and infarct of the spleen with a hypoperfused wedge-like area.

Pancreas

The position of this organ is from the hilum of the spleen (cauda pancreatici), in front of the contrast-enhanced splenic artery and vein and superior mesenteric

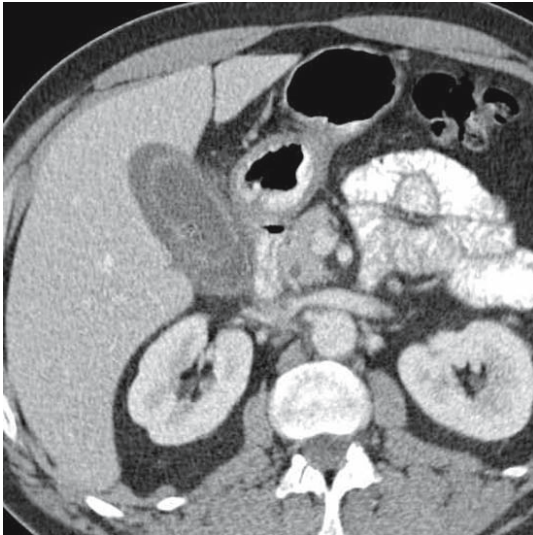


Fig. 5.19. Abdominal CT: acute cholecystitis

artery and vein to the duodenal loop (caput pancreatici). Normally, the pancreas shows a uniform homogeneous enhancement. In pancreatitis, the organ is enlarged diffusely. In pancreatic necrosis, parts of the gland do not light up with contrast. The surrounding fatty tissue is not dark and inconspicuous by comparison but shows bright streaks. Fluid around the pancreas signifies inflammatory exudate.

Kidneys, Ureters, Urinary Bladder and Urethra

Stones you will see best in a native (i.e. not contrasted) scan within the renal pelvis or one of the ureters. The ureters have to be examined along their entire course from the renal pelvis to the bladder. Any dilatation? Any tissue reaction surrounding calcification (rim sign)? Irregular spotty contrast of the renal tissue refers to nephritis, and wedge-shaped absence of contrast implies a renal infarct. In renal vein thrombosis, the renal vein does not enhance with contrast. Streaky changes in the perirenal fatty tissue suggest inflammation.

Organs of the Pelvis

Women ▶ Examine the uterus and the adnexa positioned laterally to it. Do you see cystic structures (ovarian cysts)? Do you recognize inflammatory signs in the surrounding fatty tissue or is there a fluid concentration with enhancement of its wall (tubo-ovarian abscess)? Are there signs of bleeding?

Men ▶ Identify bladder, prostate gland, seminal vesicles.

Stomach, Gut and Peritoneal Cavity

Examine the whole intestinal tract starting with the stomach and following the small bowel from duodenum to jejunum, ileum down to the ileocecal valve, the cecum and the ascending, transverse, descending and pelvic colon to the rectum. CT features of obstruction and inflammation and other specific conditions are discussed elsewhere in this book. An inflamed Meckel's diverticulum can be identified by a diverticulation of the intestinal lumen with streaky reactions of the surrounding tissue (◉ Fig. 5.20). In the right lower quadrant look for the cecum and the vermiform appendix; signs of acute appendicitis are well described in the previous section. In active Crohn's disease, you'll often recognize a considerably thickened wall of the terminal ileum.

In the descending and pelvic colon you should look for diverticula and signs of inflammation – thickened wall and streaky thickened structures in the pericolic

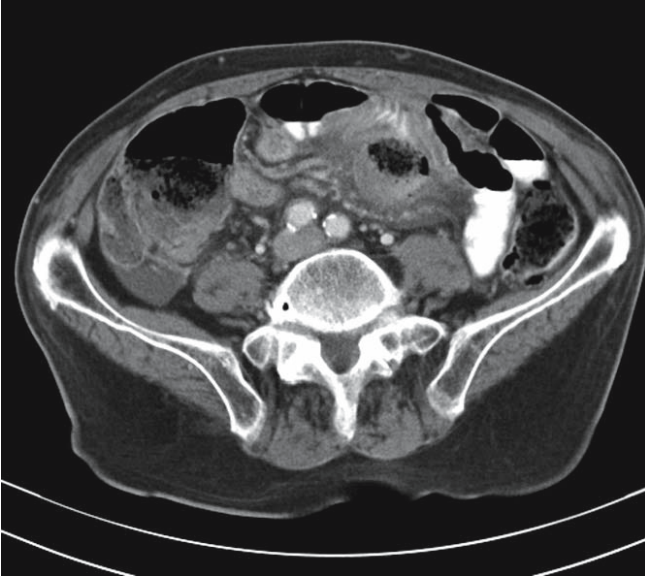


Fig. 5.20. Abdominal CT: perforation of a Meckel's diverticulum. Note the central structure which lacks luminal contrast and is surrounded by tissue reaction

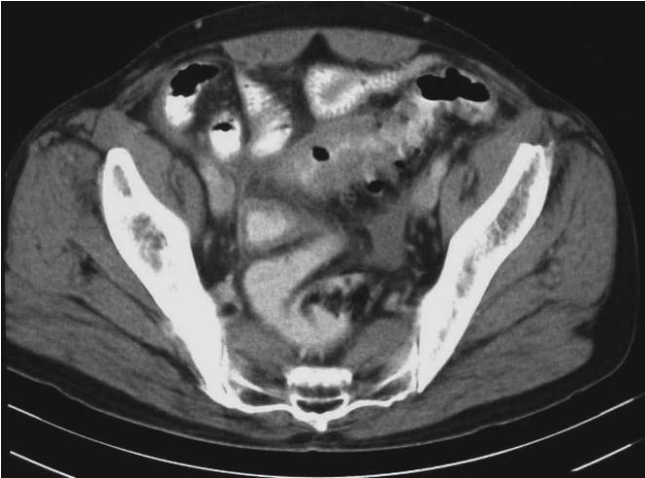


Fig. 5.21. Abdominal CT: acute sigmoid diverticulitis. Note the thickened loop of sigmoid with almost absent lumen and the tissue stranding around it – denoting inflammation

fat. Complicated diverticulitis is suggested by extraluminal gas, leakage of contrast and an abscess (● Fig. 5.21). Colonic diverticula tend to perforate in the high pressure zone above an obstructing carcinoma. CT is not a good tool for distinguishing a colonic inflammatory mass from a malignant one.

Free fluid

Watch for free fluid between the intestinal loops and elsewhere. The fluid density gives a clue to its nature: for ascites it is like water, 0–20 HU, for pus between 15 and 30 HU, and for blood about 50 HU, but be aware that these specifications don't always allow an exact differentiation.

An **abscess** shows an annular enhancement, and gas inclusions inside will prove it. Diffuse peritonitis is not easy to diagnose, but helpful signs include fluid collections between intestinal loops and in the pouch of Douglas, and a thickened base of the small bowel mesentery.

Retroperitoneum, Big Vessels and Abdominal Wall

Watch the lumen of aorta and the pelvic vessels in order to find a ruptured aneurysm (● Fig. 5.22). Look for free gas or a collection suggesting an abscess due to retroperitoneal perforation of a viscus such as the colon or duodenum.

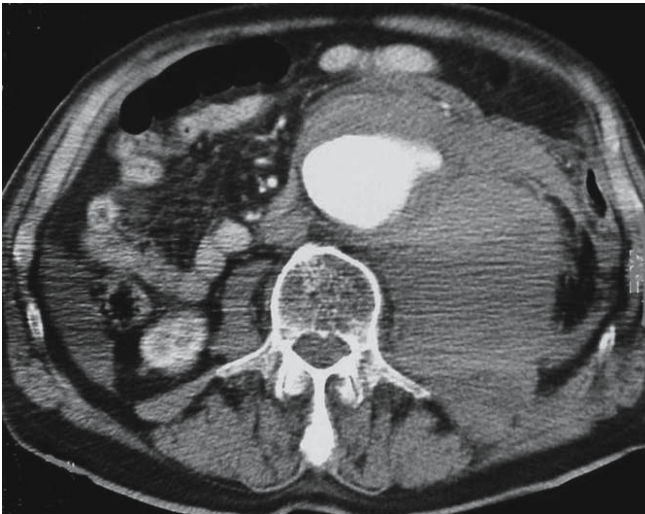


Fig. 5.22. Abdominal CT: leaking abdominal aortic aneurysm. See the aortic aneurysm and large retroperitoneal hematoma on the left

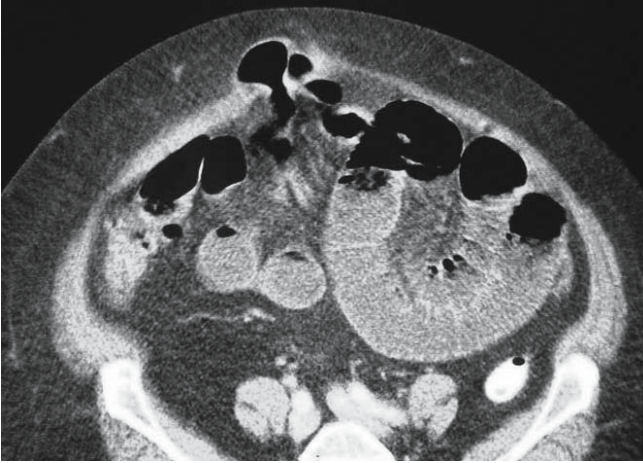

Fig. 5.23. Abdominal CT: incisional hernia. Note a loop of small bowel incarcerated within an incisional abdominal wall defect

Abdominal wall ▶ Looking at the abdominal wall, try to find pathological changes like subcutaneous abscesses, rectus sheath hematomas or abdominal wall hernias (◊ Fig. 5.23).

And please be nice to your radiologist – you may need him or her...

Optimizing the Patient*

6

JAMES C. RUCINSKI

When physiology is disrupted attempts at restoring anatomy are futile.

The preparation of the patient for surgery may be as crucial as the operation itself.

It's 4 a.m. and you assess your patient as having an “acute abdomen” – probably due to a perforated viscus. Clearly your patient needs an emergency laparotomy; what is left to decide is what efforts, and how much time, should be invested in his optimization before the operation.

Optimization is a double-edged sword: wasting time trying to “stabilize” an exsanguinating patient is an exercise in futility, for he will die. Conversely, rushing to surgery with a hypovolemic patient suffering from intestinal obstruction is a recipe for disaster.

The issues to be discussed here are:

- Why pre-operative optimization at all?
- What are the goals of optimization?
- Who needs optimization?
- How to do it?

Why is Pre-operative Optimization Necessary?

Simply, because volume-depleted patients do not tolerate anesthesia and operation. The induction of general anesthesia and muscle relaxation causes systemic vasodilatation, depressing the compensatory anti-shock physiologic mechanisms. On opening the abdomen, intraperitoneal pressure suddenly declines, allowing pooling of blood in the venous system that, in turn, decreases venous return and thus depresses cardiac output. An emergency laparotomy in an under-resuscitated patient may result in cardiac arrest even before the operation is started. In addition, the intraoperative fluid requirements are unpredictable: do you want to start with a volume-depleted patient, having to chase your tail?

* A comment by the Editors is found at the end of the chapter.

What Are the Goals of Optimization?

Patients awaiting an emergency laparotomy need optimization for two main reasons: *hypovolemia* or “*sepsis*”. Both conditions cause under-perfusion of the tissues and both are treated initially with volume expansion. **The chief goal of pre-operative optimization is to improve the delivery of oxygen to the cells.** There is a direct relationship between cellular hypoxia and subsequent cellular dysfunction, systemic inflammatory response syndrome (SIRS), organ failure and adverse outcome (● Chap. 48).

In sick surgical patients, unlike the medical ones, optimization means VOLUME and more volume – a lot of fluids. (This is, however, not true in actively bleeding patients; here optimization means immediate control of the hemorrhage – and until this is achieved you should restrict fluids and keep the patient moderately hypotensive.)

Who Needs Optimization?

Surgical patients often “look” sick. The appearance of the patient usually gives an important first impression even before factoring in tachycardia, tachypnea, hypotension, mental confusion, and poor peripheral perfusion.

Only basic laboratory studies are necessary. *Hemoconcentration*, reflected in an abnormally high hemoglobin and hematocrit, implies either severe dehydration or extracellular “third space” fluid sequestration. *Urine analysis* with a high specific gravity (>1.039) provides similar information. *Electrolyte imbalance* and associated *prerenal azotemia* (with a BUN-to-creatinine ratio of >20:1) again imply volume depletion. *Arterial blood gas* measurement gives critical information regarding respiratory function and tissue perfusion. **Note that in the emergency surgical patient metabolic acidosis almost always means lactic acidosis** – associated with inadequate tissue oxygenation and anaerobic metabolism at the cellular level. Other causes of metabolic acidosis such as renal failure, diabetic ketoacidosis or toxic poisoning are possible but extremely unlikely. *Base excess* (BE) is a useful parameter. A base deficit of more than 6 (BE less than –6) is a marker of significant metabolic acidosis and adverse prognosis and indicates a need for aggressive resuscitation.

All patients with any degree of the above physiological abnormalities need optimization. Naturally, the magnitude of your efforts should correlate with the severity of the disturbances.

PHYSIOLOGIC VARIABLE	HIGH ABNORMAL RANGE					LOW ABNORMAL RANGE				
	+4	+3	+2	+1	0	+1	+2	+3	+4	
1. Temperature rectal (°C)	≥ 41°	39°-40.9°		38.5°-38.9°	36°-38.4°	34°-35.9°	32°-33.9°	30°-31.9°	≤ 29.9°	
2. Mean arterial pressure	≥ 160	130-159	110-129		70-109		50-69		≤ 49	
3. Heart rate (ventricular response)	≥ 180	140-179	110-139		70-109		55-69	40-54	≤ 39	
4. Respiratory rate (non-ventilated or ventilated)	≥ 50	35-49		2.5-3.4	12-24	10-11	6-9		≤ 5	
5. Oxygenation: A-aDO ₂ or PaO ₂ (mmHg) a) FIO ₂ > 0.5; record A-aDO ₂ b) FIO ₂ < 0.5; record only PaO ₂	≥ 500	350-499	200-349		< 200					
6. Arterial pH	≥ 7.7	7.6-7.69		7.5-7.59	7.33-7.49		7.25-7.32	7.15-7.24	< 7.15	
7. Serum Sodium	≥ 180	160-179	155-159	150-154	130-149		120-129	111-119	≤ 110	
8. Serum Potassium	≥ 7	6-6.9		5.5-5.9	3.5-5.4	3-3.4	2.5-2.9		> 2.5	
9. Serum creatinine (mg/dl)	≥ 3.5	2-3.4	1.5-1.9		0.6-1.4		< 0.6			
10. Hematocrit (%)	≥ 60		50-59.9	46-49.9	30-45.9		20-29.9		< 20	
11. White Blood Count	≥ 40		20-39.9	15-19.9	3-14.9		1-2.9		< 1	
12. Glasgow coma score	15 - GCS =									
[A] Total acute physiology score (APS)	Sum of the 12 individual variable points =									
● Serum HCO ₃ (venous - mmol/l)	≥ 52	41-51.9		32-40.9	22-31.9		18-21.9	15-17.9	< 15	

Glasgow Coma Scale	(Circle appropriate response)	[B] Age Points	[C] Chronic Health Points	Apache-II Score (Sum of [A]+[B]+[C])
Eyes open: 4-spontaneously 3-to verbal 2-to painful stimuli 1-no response Motor response: 6-to verbal command 5-withdrawing to pain 4-withdraws to pain 3-decoricate 2-debarrate 1-no response	verbal-intubated 4-responds 3-to verbal 2-to painful stimuli 1-no response Motor response: 6-to verbal command 5-withdrawing to pain 4-withdraws to pain 3-decoricate 2-debarrate 1-no response	Age Points Age ≤ 44 0 45-54 2 55-64 3 65-74 5 ≥ 75 6 Age Points =	If any of the 5 CHE categories is answered with yes give +5 points for non-operative or emergency postoperative patients. Liver Cardiovascular Pulmonary Kidney Immune Chronic Health Points =	APS points + Age points + Chronic Health points = Total Apache-II

Fig. 6.1. APACHE II (Acute Physiological And Chronic Health Evaluation)

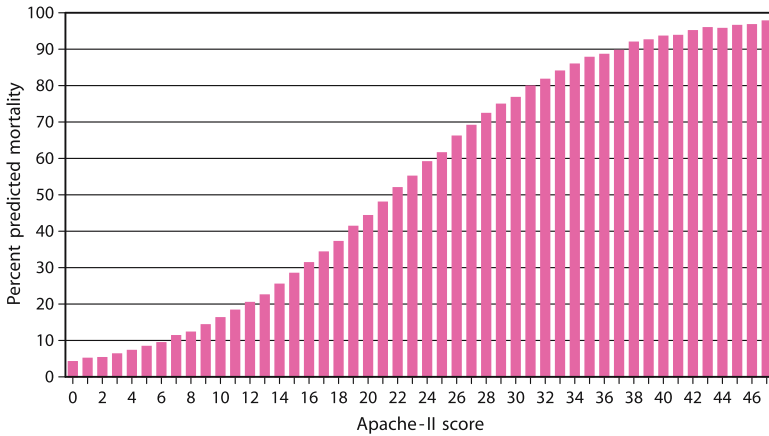


Fig. 6.2. Eventual morbidity and mortality in emergency abdominal surgery

Measurement of the Severity of Illness

An experienced surgeon can “eye-ball” his or her patient and estimate how sick they are by assessing “the glare in his eye and the strength of the grip...”. But terms such “very sick”, “critically ill” or “moribund” mean different things to different people. We recommend therefore that you become familiar with a universal physiological scoring system which gives an objective measure of “sickness”. One scoring system, which has been validated in most emergency surgical situations, is the APACHE II (Acute Physiological And Chronic Health Evaluation) (◉ Fig. 6.1). It measures the physiological consequences of acute disease while taking into consideration the patient’s pre-morbid state and age. The scores are easily measured from readily available basic clinical and laboratory variables and correlate with a prediction of morbidity and mortality (◉ Fig. 6.2). A score of 10 or below represents a relatively mild disease, a score above 20 signals a critical illness. Instead of telling your chief resident that this patient is “really sick” you’ll say “his APACHE II is 29”. Now it is clear to everyone involved that the patient is moribund.

How to Do It? (◉ Fig. 6.3)

Despite the high-tech intensive care unit (ICU) environment, which may or may not be available to you, the optimization of the surgical patient is simple. It can be accomplished anywhere and requires minimal facilities. **All you want is better oxygen delivery, i.e., increased oxygenation of arterial blood and enhanced tissue perfusion.** You do not need a five-star ICU but you do have to stick around with the



Fig. 6.3. “Let me optimize you...”

patient! Writing orders and going to bed (until the operation) will unnecessarily prolong the optimization and delay the operation. So stay with the patients, monitor their progress and be there to decide when enough is enough.

Oxygenation

— Hypoxia not only stops the motor, it wrecks the engine

Any patient who requires optimization should at least receive oxygen by mask. Look at the patient and his pulse oximetry or arterial blood gases; evidence of severe hypoventilation or poor oxygenation may be an indication for endotracheal intubation and mechanical ventilation. Do not temporize, the patient will need intubation anyway, so why not now? Remember, pain and distention associated with the abdominal catastrophe impede ventilation. Effective analgesia would impair ventilation further. If a nasogastric tube is not already in situ this may be the time to insert one. The advantage of NG insertion before intubation is to decompress the distended stomach and prevent aspiration during the procedure. The disadvantage is that the presence of a tube through the cricopharyngeus may allow regurgitation during rapid sequence induction of anesthesia.

Restoration of Volume

The major cause of shock is decreased circulatory volume. Replace body fluids by the best means at hand. (Alfred Blalock, 1899–1964)

Now after your patient is well oxygenated you must see to it that the oxygen arrives where it is needed, by restoring blood volume. This is accomplished by intravenous infusion of crystalloids such as normal saline or Ringer's lactate. Forget about the much more expensive colloids such as fresh frozen plasma, albumin or solutions containing synthetic organic macromolecules such as Hemastarch or low molecular weight dextran; their theoretical advantages have never been translated to better results. Hypertonic saline resuscitation may theoretically be advantageous but it remains an investigational therapy at present. [It has been experimental since we finished Medical School! Eds.]. Blood and blood products are given if necessary as discussed below.

How much crystalloid to infuse? **A good rule of thumb is that the hypovolemic surgical patient needs more volume than you think they need and much more than the nursing staff think they need.** We assume that your patient already has a large bore IV catheter in situ – so just hook it up to the solution and open the valve and let it run! You run in a liter and hang up another; how much is enough? At this stage you need to assess the *effectiveness of what you do*.

Measurement of Effectiveness of Treatment

The only goal of non-operative treatment in the emergency surgical patient is the restoration of *adequate tissue oxygenation*! This endpoint is recognized by *physical examination* and measurement of *urinary output*, in conjunction with the information provided by *selective invasive monitoring* and laboratory studies.

With fluid resuscitation one hopes to see improvement of tissue oxygenation by normalization of vital signs and improvement in the visible peripheral circulation. Resolution of hypotension, mental confusion, tachypnea and tachycardia may be seen either partially or fully. *Postural hypotension* reflects a significant deficit in the circulating blood volume. Remember that the usual response to a change in position from supine to upright is an increase in the systolic blood pressure – a widening of the pulse pressure. Consequently, if a narrowing of the pulse pressure is seen when the patient sits up then postural hypotension is present. With fluid resuscitation, mottling of the skin and the palpable temperature of the fingers and toes may improve. *Capillary refill* is a clinical test, which observes the peripheral circulation in the nail bed. The nail bed blanches when pressed and should return

to its normal pink color in less than 2 seconds. Fluid resuscitation aims to correct this subtle abnormality of the peripheral circulation as well.

Urine Output

Ventilate, perfuse, and piss is all that it is about! (Matt Oliver)

A Foley urinary bladder catheter is essential in any patient requiring optimization. It allows an accurate, if indirect, measurement of tissue perfusion and *adequacy of fluid resuscitation*, as reflected in the urine output.

Your aim is at least $\frac{1}{2}$ to 1 ml urine/kg patient's weight in each hour. This is the single best sign of adequate tissue perfusion associated with successful fluid resuscitation.

Invasive Monitoring

The central venous catheter and the Swan-Ganz pulmonary arterial catheter are tools which permit "special studies" to be carried out rapidly and repeatedly. The downside of such devices is that they are invasive, expensive, often inaccurate, and associated with potentially life-threatening complications. Invasive hemodynamic monitoring provides endpoint measurements that, in conjunction with urinary output, indicate the adequacy of fluid resuscitation.

The Central Venous Catheter

The **central venous catheter** measures central venous pressure (CVP) which is a product of the venous return (i.e., blood volume) and right ventricular function. **Low CVP always means hypovolemia, but a high CVP can signify either over-expansion of blood volume or cardiac failure.** So aim for an adequate urinary output with a CVP in the normal range, up to 12 cmH₂O. When the CVP rises above the normal range and the urinary output is still not adequate then either the cardiac or renal function is impaired or the measurement is in error. False elevations in CVP are caused by abnormally high intra-thoracic or intra-abdominal pressure, which is directly transmitted to the great thoracic veins. The message is clear – **as long as the urine output is not adequate and the CVP is low – pour in the fluids.** But remember: your patient may be far behind on fluid in the presence of a high or normal CVP. And another hint – **the absolute CVP reading means less than its trend;** it is when a low or normal CVP suddenly jumps up that you have to slow the fluids.

The Swan-Ganz Pulmonary Artery Flotation Catheter

The Swan-Ganz measures pulmonary capillary wedge pressure, which reflects the volume status and left cardiac function. Like the CVP catheter, the “Swan” is used in conjunction with the urinary output. We aim for a normal “wedge” pressure (around 14 mmHg) in conjunction with an adequate urinary output. As with the CVP – a low wedge always means hypovolemia, a high wedge on the other hand, may indicate either a volume overload, or dysfunction of the left heart. With the Swan-Ganz in situ, you can calculate and derive information about cardiac function (cardiac output and cardiac index), adrenergic response to injury or illness (peripheral vascular resistance) or tissue perfusion (oxygen consumption and oxygen delivery). A normal cardiac index is a good confirmatory endpoint for resuscitation and, if pre-existing renal failure is present, is a good independent endpoint. When the wedge pressure is normal or high and the urinary output and cardiac index are still low then pharmacological intervention with inotropic agents may be indicated.

We know that intensivists and junior doctors like to insert central lines and especially Swan-Ganz catheters. Being invasive and able to measure sophisticated data is fun and clinically attractive. But invasive monitoring is far from being a panacea. Wedge pressures are notoriously inaccurate in emergency surgical patients – prone to false high reading similar to the CVP. **Swan-Ganz catheters are expensive, predisposed to complications and – above all – they very rarely add something to the management of your patients.** Consider this: when was the last time that your anesthesiologist *really* effectively used, intraoperatively, the Swan-Ganz you placed pre-operatively? We cannot remember such a case.

Laboratory

The information provided by laboratory studies is easy to interpret. Aim for resolution of hemoconcentration, normalization of electrolyte, BUN and creatinine levels, and resolution of metabolic acidosis. As mentioned previously, look at the BE – if persistently negative the oxygen deficit at the tissue level has not resolved.

Blood and Blood Products

Blood products, such as whole blood, packed red blood cells, fresh frozen plasma, cryoprecipitate or platelet concentrate, are indicated selectively to restore oxygen-carrying capacity in actively bleeding or chronically anemic patients, and to correct clotting abnormalities if present. Do not forget, however, the blood bank blood is a double-edged sword. Beyond the usual and well-known complications of

transfusion, blood is immunosuppressive and may be associated with an increased probability of postoperative infections. In addition, **the more blood you give the higher the risk of postoperative organ system dysfunction and mortality.**

Do not forget that re-hydration with crystalloids may unmask chronic anemia as the hematocrit falls with volume expansion.

Suggested Steps in Volume Optimization

- Institute intravenous fluid therapy and if signs of intestinal dysfunction such as nausea, vomiting or abdominal distension are present then designate nil per mouth (NPO) and, in more severe cases, nasogastric suction. Intravenous crystalloid may be started at a basic rate of 100 to 200 ml per hour with the addition of boluses of 250 to 500 ml given over intervals of 15 to 30 minutes. We advise you, however, to sit by your patient and completely open the valve of the transfusion set, despite the “nurses desire” to keep it on a pump.
- Institute procedures for monitoring the effectiveness of treatment including serial physical exam, Foley catheter placement and, in more severe cases, central venous catheter placement. Swan Ganz? Please, be very selective with this “gimmick”.
- If the main underlying problem is hemorrhage, institute transfusion of packed red blood cells – typed and cross-matched if there is time, type-specific only if there is not.
- Titrate the rate of fluid administration in light of the results of monitoring. Increase or decrease the basic rate of fluid flow and give additional bolus infusions as necessary.
- *After* the restoration of intravascular fluid volume address any residual signs of physiologic dysfunction with inotropic agents to improve cardiac output and, possibly, an afterload reducing agent to improve myocardial oxygen supply and ease the workload of the heart. There is no shame in looking up the dosage and administration recommendations while the fluid is going in.
- Wheel the patient directly to the operating room yourself. Do not wait for the porter – aren’t they usually late?
- If the basic problem is continuing hemorrhage then forget this list and go directly to the operating room. The best resuscitation in actively bleeding patients is surgical control of the source. In addition, **pre-operative over-resuscitation and transfusion increase the blood loss.**

When enough is enough?

The above steps in optimization are done with the aim of correcting physiologic derangement as much as possible but without unnecessarily delaying operative intervention. There is no magic formula for achieving this balance. The disease process itself will determine the duration of pre-operative optimization. At one end of the spectrum, uncontrolled hemorrhage will require immediate operative intervention after only partial fluid resuscitation or none at all. At the other end of the spectrum, intestinal obstruction that has been developing over several days will require a more complete resuscitation prior to operation. As in life in general, most cases will fall somewhere in between – which means around 3 hours. Stubborn attempts to “improve” a “non-responder” beyond 6 hours are usually counter-productive. That you, or your boss, do not feel like leaving your warm beds at 3 a.m. is not an excuse to “continue aggressive resuscitation” until sunrise.

But stop: perhaps your patient does not need an operation? One of the cleverest aphorisms in surgery was coined by the late Francis D. Moore (1913–2001):

Never operate on a patient who is getting rapidly better or rapidly worse

Conclusions

The key to pre-operative optimization in emergency surgery is oxygenation of the blood and intravenous fluid resuscitation with crystalloid solutions. The only goal of resuscitation is the restoration of adequate tissue perfusion to supply oxygen to the suffocating mitochondria. Accomplish it aggressively to reduce intra- and post-operative complications.

These old folks maintain a fragile system quite well...until it gets disturbed – like a card house

“Every operation is an experiment in physiology.” (Tid Kommer)

Editorial Comment

We agree that restoring blood volume is a crucial step before any emergency operation but at the same time we have to warn you – as we’ll do again and again – not to drown your patients in too much fluid. Preop, intraop, or postop fluid administration is a double-edged sword. Equipped with huge bore IV lines and fancy monitoring devices, enthusiastic surgeons and anesthesiologists commonly flood their

patients with too much water and salt. We tend to ignore the “obligatory” post-operative weight gain caused by too aggressive resuscitation with a shrug: “Well”, we say,” the patient is perfusing well and his urine output is excellent – he’ll diurese the excess fluids once he’s well.” But we are wrong!

Recent evidence shows that the deleterious effect of excess fluid is not limited to patients who are actively bleeding (by increasing the rate of hemorrhage and the risk of re-bleeding) but can, in fact, be demonstrated in each and every one of our patients. Swollen, edematous cells are bad news in each and every system. Edema contributes to respiratory failure and cardiac dysfunction. It prevents tissue healing – adversely affecting intestinal anastomoses and fascial wounds. It swells abdominal contents producing intra-abdominal hypertension.

So do not go over board. Give only as much fluid as is necessary and, above all, monitor what the anesthetist is doing on his side of the screen. The old-fashioned formulas used to calculate how much fluid to administer during the operation are exaggerated and outdated. One has to replace blood loss and maintain urine output at 0.5 ml/kg per hour – nothing more. **The more unnecessary fluid given before and during the operation – the more problems you’ll have with the patient in the ICU and on the floor.**

Pre-operative Antibiotics

MOSHE SCHEIN

“Most men die of their remedies, not of their diseases.”
(Molière, 1622–1673)

It is common practice to administer broad-spectrum antibiotics before a laparotomy for an acute surgical condition or trauma. In this situation, antibiotics are either **therapeutic** or **prophylactic**.

Therapeutic antibiotics: given for an already established, tissue invasive, infection (e.g. perforated appendicitis).

Prophylactic antibiotics: administered in the absence of infection, with the objective of reducing the anticipated incidence of infections, which result from existing (e.g. penetrating injury of the colon) or potential (e.g. gastrotomy to suture a bleeding ulcer) contamination during the operative procedure.

It is very important to distinguish between *contamination* and *infection* (↻ Chap. 12) as only the latter requires postoperative antibiotic administration, a topic to be discussed in the postoperative section (↻ Chap. 42). *Therapeutic* antibiotics assist the surgeon and the natural peritoneal defenses to eradicate an established infection. *Prophylactic* antibiotics prevent postoperative infections of the laparotomy wound; they do not prevent pulmonary or urinary infections nor the occurrence of intra-abdominal abscesses, and should not be administered in an attempt to do any of these things. Finally, *even dummies know that antibiotics are only an adjunct to the proper surgical management of contamination and infection* (↻ Chap. 12).

When Should You Start Antibiotics?

There are two schools of thought here. One says that if intra-abdominal contamination or infection is evident or strongly suspected pre-operatively, administer antibiotics immediately – “the sooner the better”. In cases where there is delay in proceeding with the laparotomy, give a second dose of pre-incisional antibiotics in the operating room. Pre-incisional administration is best in cases where contamina-

tion is expected to occur intra-operatively. Some surgeons believe differently, however, and prefer to await the operative findings before giving antibiotics. Should, for example, the acute appendicitis prove to be “simple phlegmonous” (● Chap. 28), or the blunt trauma not breach the lumen of a hollow viscus (● Chap. 35), they would avoid antibiotics altogether. Alternatively, if contamination or infection were encountered, they would start antibiotic therapy a few minutes after abdominal entry, apparently with no disadvantage. Support for this second philosophy comes from the suggestion that antibiotics liberate endotoxin from the killed bacteria; this leads some surgeons to believe that evacuation of pus (containing the source of endotoxin) should be a prerequisite for commencing antimicrobial therapy.

We, among many others, believe however, that antibiotics should permeate the tissues at the time of the abdominal incision, because immediate vasoconstriction at the incision site would prevent antibiotics – if given later – from reaching the operative wound. Thus, our position is to administer a dose of antibiotics *prior to all* emergency abdominal operations. When infection or contamination is present, or when contamination is expected to occur, the prophylactic or therapeutic value of antibiotics is obvious. In view of the beneficial effects of prophylactic antibiotics in certain elective, clean procedures, we assume that the same may be true in the acutely ill patient who is subjected to laparotomy, even in the absence of contamination or infection. The clinical significance of any antibiotic-generated endotoxemia is presently unknown.

Not uncommonly, we observe surgeons who, in the peri-operative chaos, forget to administer antibiotics. To compensate for their failure, they order antibiotics after the operation. This is utterly futile! Are dirty hands washed before or after the meal? The fate of the operative wound is sealed by intra-operative events, including timely administration of antibiotics. Nothing done after the operation can change the outcome of the wound (● Chap. 49).

Which antibiotics to use?

Contrary to what is preached by drug companies and their various beneficiaries or representatives, the choice of drugs is straightforward. Many single drug or combination regimens are available and equally effective; the most recent and expensive not necessarily being better. The bacterial flora of abdominal contamination or infection derives from the gastrointestinal tract and is predictable. When a drop of feces leaks into the peritoneal cavity, it contains more than 400 different species of bacteria; only a handful of these are involved in any ensuing infection. Thus, from the initial plethora of contaminating bacteria, the inoculum is spontaneously reduced and **simplified** to include only a few organisms that survive outside their natural environment. These are the endotoxin-generating facultative

anaerobes such as *Escherichia coli* and obligate anaerobes, such as *Bacteroides fragilis* – which act in synergy. Any agent or combination of agents that effectively kills these target bacteria can be used.

The once-popular “triple regimen” of the 1970s (ampicillin, an aminoglycoside, and metronidazole or clindamycin) has become obsolete. *Enterococcus*, frequently isolated in experimental and clinical peritonitis, is clinically almost non-significant as a pathogen in the peritoneal cavity and is not required to be “covered” with ampicillin. Aminoglycosides are markedly nephrotoxic (especially in critically ill patients), are inefficient in the low pH of the infected peritoneal environment, and are no longer the first choice of antibiotics in the initial treatment of intra-abdominal infection. Surgeons tend to be creatures of habit, desperately clinging to dogmas passed on by their mentors; the “triple regimen” is one such dogma that has been carried into the twenty-first century through ignorance.

There are numerous agents on the market you can choose from. You may use whichever agent, as “monotherapy” or in combination – as long as *E. coli* and *B. fragilis* are covered. In abdominal emergencies, the same agent should be used for prophylaxis and treatment. An initial dose of the appropriate drug is given pre-operatively and, if indicated by the intra-operative findings, can be continued following the operation. The common (mal)practice of starting with a “weak” agent (e.g., cephazolin) before the operation and converting to the “strong” regimen is baseless.

In the course of the fluid-resuscitation of hypovolemic patients, antimicrobials may be “diluted”, reducing the availability of antimicrobial drugs at sites of contamination or infection. In these cases, especially in the trauma patient, higher initial doses should be used: “sooner and more is better than less and longer”.

In Conclusion

Start antibiotics prior to any emergency laparotomy; whether you continue administration after the operation depends on the operative findings (see ● Chap. 42). Know the target flora and use the cheapest and simplest regimen. **The bacteria cannot be confused, nor should you be!**

PS: Try to get yourself a copy of Mazuski JE, Sawyer RG, Nathens AB et al. (2002) The Surgical Infection Society Guidelines on antimicrobial therapy for intra-abdominal infections. *Surg Infect* 3:161–173.

“Patients can get well without antibiotics.” (Mark M. Ravitch, 1910–1989)

Family, Ethics, Informed Consent and Medicolegal Issues

JAMES C. RUCINSKI

*“Doctor, my doctor, what do you say...?”
(Philip Roth)*

The wind whistles through the cracks in your call room window when the emergency room (ER) calls and suddenly you find yourself in the maelstrom of that environment, speaking to a small group of extremely anxious strangers – having to explain that an immediate operation will be required to save their beloved one. The operating room is ready.

Obtaining informed consent is a practical combination of salesmanship, ethical problem solving and psychological nurturing. It involves the rapid marketing of one’s own skills and plan for treatment. It requires the recruitment of the patient and the family as allies in the decision-making process. Rather than a legal requirement, however, informed consent requires an ethical commitment to the patient, your peers and to yourself.

Salesmanship

Begin by explaining your proposed treatment using the same words and language that you might use in speaking to one of your non-medical relatives. **Describe the expected benefits of operation and what the consequences of alternative treatment approaches might be.** Offer several scenarios; take a case of obstructing carcinoma of the sigmoid colon, for example. At one end of the spectrum is non-operative management, which almost certainly will result in a slow and difficult death. At the other end of the spectrum is rapid recovery from operation with long term cure of the disease. In between lie the potential difficulties of peri-operative complication or death, recovery with disability or recurrent disease. It is crucial that you believe in the plan of treatment that you propose. If this is not the case, and the plan is not acceptable to you but dictated to you from above, then let the responsible surgeon conduct his own pre-operative “negotiations” with the patient and/or his family.

“Sell” yourself to the patient and family as a scientific expert who recognizes the needs of another person, and is participating with them in solving a difficult

problem. Include a description, with approximate probabilities, of the most common “problems” (complications) for the proposed procedure in your particular patient. You will need to make an estimate based on general and specific information. For example, the risk of mortality for elective colon resection may be negligible but in an elderly patient with acute colonic obstruction and hypoalbuminemia the odds of dying may be one in four (➤ Chap. 6). Discuss general potential postoperative complications such as infection, hemorrhage (and risk of transfusion), poor healing and death. Then mention the unique complications specific to the procedure you are proposing to undertake, such as common bile duct injury in laparoscopic cholecystectomy.

It is crucial that before any major emergency abdominal operation you emphasize that a re-operation may be necessary based on your operative finding or if a problem subsequently develops. This would drastically facilitate the “confrontation” with the family when a re-operation is indeed indicated (➤ Chap. 46); they would understand that the re-operation represents a “continued management effort” rather than a “complication”. Minor complications, such as phlebitis arising from perioperative intravenous therapy, may contribute to information overload and probably should be omitted. Try to conduct the above “script” in a relatively quiet setting – away from the usual chaos of the ER, SICU or the OR. Use simple language and repeat yourself ad libitum; stressed members of family may have difficulty in grasping what you say. Offer the opportunity to ask questions and assess whether there is understanding of your discussion. The more they understand initially, the fewer “problems” you’ll have if complications subsequently develop. Be “human”, friendly, empathetic but professional. **A good trick is to remind yourself from time to time that the family you are talking to could be yours.**

Illustrate the Problem

When discussing the prospects of an operation with a patient or a family we find that illustrating the problem and the planned procedure on a blank piece of paper greatly enhances the communication. Draw, schematically, the obstructed colon: “here is the colon, this is the obstructing lesion and here is the segment we want to remove; we hope to be able to join this piece of bowel to that one, a colostomy may, however, be needed; this is the place it will be brought out.” Below the drawing write the diagnosis and the name of the operation plan. At the end of the consultation you’ll be surprised to see how carefully members of the family re-study the piece of paper you left with them, explaining to each other the diagnosis and planned operation.

The Family

When it comes to operation, you *advise* and the patient, and his family *decides*

The patient's family is your greatest ally in promoting your plan of action. By involving them at an early point in the decision-making process you may be able to make them partners in the relationship that you share with the patient. By avoiding the family you may alienate potential allies or worsen an already "difficult" group. The *difficult family* is common. Long submerged conflicts and feelings of guilt tend to surface when a member of the group becomes ill. Recruit them as allies by offering them a chance to participate, by "reading" the nuances of their relationships and by confidently and continuously selling yourself as a knowledgeable and compassionate advisor. Use your first meeting with the family to make a good impression and gain their trust so that you will continue to be trusted when a complication arises or when further therapy becomes necessary.

Ethical Problem Solving

In order to sell a particular product or idea one must believe in it. In other words, based on your knowledge and experience, the operation you offer should appear ethical to you. **It is ethical if it is expected to save or prolong the patient's life or palliate his symptoms, and can achieve this goal with a reasonable risk-benefit ratio. At the same time you must be also convinced that there are no non-operative treatment modalities that are safer or as effective as your proposed operation. The burden of proof is on you!**

Medicolegal Considerations

"Surgery is the most dangerous activity of legal society." (P.-O. Nystrom)

The medicolegal dangers associated with emergency abdominal surgery greatly depend on where you practice. In some countries surgeons can get away with almost anything, in other countries emergency surgery is a legal minefield. There are a few simple but well-proven tactics to prevent lawsuits against you:

- Have the patient and family "on your side" (as mentioned above) by being empathetic, caring, honest, open, informative, and at the same time professional. Young surgeons tend to be over-optimistic, trying to cheer-up the family. A common scenario finds the surgeon emerging from the operating room, assuming a "tired hero" pose and announcing: "It was smooth and easy, I removed the cancer from



Fig. 8.1. “Is he going to sign?”

the colon, relieving the obstruction. I was able to join the ends of the bowel together – avoiding a colostomy. Yes, your father is stable, he took the operation very well, let’s hope he’ll be home next week for Easter... (or Passover or Ramadan).” Such a script is somewhat misguided in that it may raise high hopes and expectations, with subsequent anger and resentment if complications should develop. The better script might be: “The operation was difficult, but we managed to achieve our goals. The cancer is out and we avoided a colostomy. Considering your father’s age and other illnesses he took it well. Let us hope for the best but you must understand that the road to recovery is long and, as I mentioned before the operation, there are still many potential problems ahead.”

- Detailed informed consent (◊ Fig. 8.1).

- Documentation. This is crucial, as “what has not been documented in writing did not actually take place”. Your notes can be brief but must encompass the essentials. Prior to an emergency laparotomy for colonic obstruction we would write: “78 YO male patient with hypertension, diabetes and COPD. Three days of abdominal pain plus distension. Abdominal X-ray – suggesting a distal large bowel obstruction – confirmed on gastrografin study. APACHE II score on admission 17 – making him a high risk. Therapeutic options, risks and potential complications explained to the patient and family who accept the need for an emergency laparotomy. They understand that a colostomy may be needed and that further operations may be necessary.” **A few years later – in court – this short note will prove invaluable to you!**

Avoid selling Autopsies under Anesthesia (AUAs)

We compared you above to an astute salesman, interacting with the patient and his family. In this capacity, you, a respected clinician, can easily sell anything to the trusting clients. Be honest with yourself and consider as objectively as possible the risk–benefit ratio of the procedure you are trying to “sell”. It may be easy to convince a worried family that a (futile) operation is indeed necessary and then at the inevitable M & M (morbidity and mortality) meeting (● Chap. 52) explain that the family forced the AUA on you. Easy and ethical don’t always coexist!

“One should advise surgery only if there is a reasonable chance of success. To operate without having a chance means to prostitute the beautiful art and science of surgery.” (Theodor Billroth, 1829–1894)

Concluding Remarks

Not only is what you say important but also how it is said. Introduce yourself and all members of your team who are present. Shake hands with all members of the family. Conduct the “session” in a sitting position – you sitting at eye level with the patient and his family. Maintain constant eye contact with each of them – do not ignore the ugly daughter hiding in the corner of the room – for she may be the one who becomes your enemy. Be “nice” but not “too nice” – this is not the time to smile or joke around. Just play the serious surgeon committed to the well-being of the patient. This surgeon is you, so play yourself!

Nothing is truer than the cliché that should be constantly replayed in your mind – would you recommend the same treatment to your father, mother, wife or son? Studies show that surgeons are much less likely to recommend operations on themselves or their loved ones. **Do unto others as you would have them do unto you – the golden rule.**

“The patient’s family will never forgive a guarantee of cure that failed and the patient will not let the physician forget a pronouncement of incurability if he is so fortunate as to survive.” (George T. Pack, 1898–1969)

Before the Flight: Pre-op Checklist

MOSHE SCHEIN

“The pilot is by circumstances allowed only one serious mistake, while the surgeon may commit many and not even recognize his own errors as such.”
(John S. Lockwood)

Like any military or commercial pilot, prior to any flight, you have to go over a “check list”. In fact, the need to check everything obsessively is more crucial to you than to the pilot. For while a team of dedicated and well-trained maintenance professionals surround the pilot – you are not uncommonly surrounded only by jerks. We do not want to be abusive or rude but let us be realistic: at 2 a.m. your intern or junior resident is much more interested in his lost sleep than your prospective operation. And the anesthetist? Your emergency case is just a pain in his ass. The sooner he or she can administer the gases, the sooner they can dump your “case” in the recovery room or intensive care unit and the sooner they can crawl under the warm duvet – the place they yearn to be. And the nursing staff? Forget them! Not in vain today are they called OR *technicians* (● Fig. 9.1).



Fig. 9.1. “Doctor, show me your pilot’s license...”

So face it – you are alone; it is always a solo flight and you can count only on yourself. Regardless of how many people are buzzing around the patient – this is your patient, and you are responsible for the success, failure, morbidity, mortality, and potential lawsuit. The fate of your patient is in your hands. So wake up and go over the checklist.

The Checklist

- **Does he *really* need the operation?** The cliché that it is more difficult to decide when not to operate than when to operate is mentioned elsewhere in this book. Variations of this aphorism are circulating around the world in many languages. But it is much more difficult to decide against the operation *after* the operation has been scheduled. So you decided to book the patient for appendectomy based on what the chief resident told you over the phone – that “the CT is compatible with acute appendicitis” – and now, when you arrive in the OR, you find the patient smiling and sitting in bed with a soft and non-tender abdomen. Do you want to operate on the CT or the patient? You do not need big balls (or ovaries) to book a patient for operation but you need large balls to *cancel* the operation and order the patient back to the floor (ward). You need huge balls to *remove* the patient from the operating table and giant balls to tell the anesthetist to *wake* him up... but if you palpate a large appendiceal mass after the induction of anesthesia and abdominal wall relaxation – what is the point of continuing?
- **Examine the patient before he is put to sleep.** Never ever – we repeat – never ever operate on a patient without having examined him yourself; if you do then you are a butcher. That the endoscopist visualized a “bleeding ulcer” and the patient continues to vomit blood may be an indication for operation, but this is your chance to diagnose the large spleen and ascites, which were hitherto overlooked by the others. You do not want to operate on a Child’s C portal hypertension patient, or do you? (See ◉ Chap. 16).
- **Look at the X-rays and imaging studies.** Review all X-rays and imaging studies by yourself. Do not rely only on what the radiologist said or wrote. You may pick up findings, which may move you to cancel the operation or to decide on a different incision.
- **Position the patient.** Already before you start you have to have a general idea what you are going to do or what you may have to do. This has an impact on your patient’s position. For example – does he need a Lloyd-Davies position, offering access to the anus and rectum? This may be needed during colorectal procedures – to insert a scope, to decompress the colon or to insert a stapler. You do not want to have to stop the operation and place the patient in the correct position or to send the intern crawling under soggy drapes looking for the anus. In whatever position

your patient is to be, check that all limbs are protected and well padded at potential pressure sites. Poor positioning on the OR table may result in damage to nerves, skin ulceration and compartment syndrome of the extremities – and a lawsuit.

- **Warm your patient.** See that the patient is well covered and warmed. Hypothermia increases the likelihood of postoperative infections and contributes to intra-operative coagulopathy.

- **Think about preventing deep vein thrombosis (DVT):** Prevention of DVT should be initiated before the patient is put to sleep – not after the operation. Any abdominal procedure lasting longer than 30 minutes is associated with a moderate risk of DVT; you can add to this specific risk factors such as smoking, use of oral contraceptives, previous history of DVT, age, obesity, a cancer and so forth. But instead of pondering too much – why don't you provide all your patients undergoing an emergency abdominal operation with DVT prophylaxis? Whether it is in the form of subcutaneous heparin or calf compression depends on what your OR can offer. Bear in mind that anticoagulation is not good for an exsanguinating patient! We have seen young patients dropping dead from pulmonary embolism a few days after appendectomy and young women developing intractable post-phlebotic syndromes following appendectomy performed for pelvic inflammatory disease. Always think about this.

- **Is the bladder empty?** Most patients undergoing emergency operations arrive at the OR with a urinary catheter in place; in the rest you will insert the catheter on the table. But if contemplating a lower abdominal procedure on a non-catheterized patient you have to check that the bladder is empty. When the bladder is full it may look to you like the peritoneum. Bladder distension may also mimic a surgical abdominal condition.

- **Think antibiotic prophylaxis** (see ◀ Chap. 7).

- **Document everything** (see ◀ Chap. 8).

Now you can go and scrub! You are the captain of the ship – behave like one; the sight of a surgeon dramatically entering the room with his scrubbed hands held high in the air is pitiful.

— “Poor judgment is responsible for much bad surgery, including the withholding of operations that are necessary or advisable, the performance of unnecessary and superfluous operations, and the performance of inefficient, imperfect, and wrongly chosen ones.” (Charles F.M. Saint, 1886–1973)

— “The surgeon, like the captain of the ship or a pilot of an aircraft, is responsible for everything that happened. His word is the only one that cannot be gainsaid.” (Francis D. Moore, 1913–2001)

The Incision*

MOSHE SCHEIN

Incisions heal from side to side, not from end to end, but length does matter.

When entering the abdomen, your finger is the best and safest instrument.

The patient now lies on the table, anesthetized and ready for your knife. Before you scrub, carefully examine the relaxed abdomen. Now you can feel things which were impossible to feel in the tense and tender belly. You may feel a distended gallbladder in a patient diagnosed as an acute appendicitis, or an appendiceal mass in a patient booked for a cholecystectomy. Yes, this may also occur in the era of ultrasound and CT.

Traditionally, abdominal entry in an emergency situation or for exploratory purposes has been through a generous and easily extensible vertical incision, especially the midline one. Generally speaking, the trans *linea alba* midline incision is swiftly effected and relatively bloodless. On the other hand, transverse incisions are a little more time- and blood-consuming but are associated with a lower incidence of wound dehiscence and incisional hernia formation. In addition, transverse incisions are known to be “easier” on the patient and his lung function in the post-operative period. (It seems that vertical paramedian incisions belong to history).

Keeping this in mind, we should be **pragmatic rather than dogmatic** and tailor the incision to the individual patient and his or her disease process. **We should take into consideration the urgency of the situation, the site and nature of the condition, the confidence in (or uncertainty about) the preoperative diagnosis, and the build of the patient.**

Common sense dictates that the most direct access to the specific intra-abdominal pathology is preferable. Thus, the biliary system is often best approached through a transverse, right subcostal incision. Transverse incisions are easily lengthened, to offer additional exposure; a right subcostal incision can be extended into the left side (as a “chevron”), offering an excellent view of the entire abdomen. When a normal appendix is uncovered through a limited, transverse, muscle-splitting, right lower quadrant incision, one can extend it by cutting the muscles across the midline to deal with any intestinal or pelvic condition. Alternatively, when an upper abdominal process is found, it is perfectly reasonable to close the small right iliac fossa incision and place a new, more appropriate, one. **Two good incisions are better than one, poorly placed.**

* Asher Hirshberg, MD contributed to this chapter in the 1st edition of the book.

The midline incision – bloodless, rapid, and easily extended – affords superior exposure and versatility; it remains the classic “incision of indecision” when the site of the abdominal catastrophe is unknown and is the safest approach in trauma.

This is an occasion to mention that an emergency laparotomy without a diagnosis is not a sin! Do not surrender to the prevailing dogma that the patient cannot enter the operating theater without a ticket from the CT scanner. A clinical acute abdomen – when “other diagnoses” have been ruled out (see ♦ Chaps. 3 and 4) – remains an indication for laparotomy and on many occasions the abdominal wall is the only structure separating the surgeon from an accurate diagnosis.

At What Level Must the Midline Incision Start and How Long Should It Be? (♦ Fig. 10.1)

The macho surgeons of previous generations often screamed: “Make it long. It heals from side to side, not from end to end”. Today, in the era of minimal access surgery, we are familiar with the advantages of shorter incisions. In the absence of any obvious urgency, enter the abdomen through a short incision and then extend as necessary; but never accept less than adequate exposure or strive for keyhole surgery. Begin with an upper or lower midline incision, directed by your clinical assessment; when in doubt, start near the level of the umbilicus and “sniff” around from there, then extend towards the pathology. Just remember what the famous




Fig. 10.1. “Which incision?”

Swiss surgeon Theodor Kocher said more than 100 years ago: **“The incision must be as long as necessary and as short as possible”.**

Should You Extend Your Incision into the Thorax?

Very rarely! In the vast majority of cases, infra-diaphragmatic pathology is approachable through abdominal incisions. The combination of a subcostal and upper midline incision offers an excellent exposure for almost all emergency hepatic procedures, with the exception of retrohepatic venous injuries where insertion of a trans-atrial vena cava shunt necessitates a median sternotomy – usually a futile exercise, anyway. Thoracoabdominal incisions are mainly reserved for combined thoracoabdominal trauma.

Knife or Diathermy?

A few studies suggest that the latter is a few minutes slower while the former sheds a few more drops of blood; otherwise results are comparable. We use either. In extreme urgency, gain immediate entry with a few swift strokes of the knife; otherwise, diathermy is convenient, especially when performing transverse muscle-cutting incisions. Adequate hemostasis is a crucial surgical principle but do not go overboard chasing individual erythrocytes and avoid reducing the subcutaneous fat or skin to charcoal. The hypothesis that “You can tell how bad the surgeon is by the stink of the Bovie in his OR” has not been proven by a double-blind randomized trial but makes sense nonetheless.

Subcutaneous hemostatic ligatures behave like a foreign body and are almost never necessary. In fact, most incisional “oozers” stop spontaneously, after a few minutes, under the pressure of a moist lap pad. It is also unnecessary to “clean” the fascia by sweeping the fat laterally: **the more you dissect and “burn”, the more inflammation and infection-generating dead tissue you create!**

Keep in Mind Special Circumstances

If a stoma is anticipated then place the incision away from its planned location. Abdominal re-entry into the “hostile abdomen” of a previously operated patient can be problematic; you may spend more time, sweat and blood, but the real danger is creating inadvertent enterotomies in intestine adherent to the previous incisional scar. This is a common cause of postoperative external bowel fistula! (🔗 Chap. 45). The prevailing opinion is to use the previous incision for re-entry, *if possible*. When

doing so, however, start a few centimeters below or above the old incision and gain entry into the abdomen through virgin territory. Then insert your finger into the peritoneal cavity and navigate your way safely in, taking down adhesions to the abdominal wall, which hamper the insertion of a self-retaining retractor. Essentially, you are finished “getting in” when you are able to place a self-retaining retractor to open the abdomen wide. In a dire emergency or when you expect the abdomen to be exceptionally scarred, it may be prudent to stay away from trouble and create an entirely fresh incision. In this situation beware of parallel incisions in close proximity to one another because the intervening skin may be at risk of necrosis, particularly if the first incision is relatively recent.

Pitfalls

- When in haste, do not forget that the *liver* lies in the upper extremity of the long midline incision, and the *urinary bladder* at its lowermost. Be careful not to damage either.
- When approaching the upper abdomen divide and ligate the *round* hepatic ligament. Leave it long: it could be used to elevate and retract on the liver. Take the opportunity to divide the bloodless *falciform* ligament, which runs from the anterior abdominal wall and the diaphragm to the liver. If left intact it may “tear” off the liver causing irritating bleeding.
- When performing any transverse incision across the midline, do not forget to ligate or transfix the *epigastric vessels* just behind the rectus abdominis muscles. They may retract and cause a delayed abdominal wall hematoma.
- **In the very obese patient**, in the upright position, the umbilicus commonly reaches the level of the pubis. After elevating the fat paniculus you can place a lower midline incision between the pubis and umbilicus but after the operation it will be macerated by the sweaty paniculus. Thus, in the super-fat, a supra-umbilical midline incision would provide a better access into the lower abdomen.

— “Pray before surgery, but remember God will not alter a faulty incision.”
(Arthur H. Keeney)

Abdominal Exploration: Finding What is Wrong*

MOSHE SCHEIN

Never let the skin stand between you and the diagnosis.

*“In surgery, eyes first and most; fingers next and little; tongue last and least.”
(Humphrey George Murray, 1820–1896)*

Not uncommonly, when opening the abdomen, the surgeon knows what to expect inside; the clinical picture and/or ancillary tests direct him to the disease process. In many instances, however, he explores the unknown, led on only by the signs of peritoneal irritation, and assuming that the peritoneal cavity is flooded by blood or pus. Usually, the surgeon speculates about the predicted diagnosis but always remains ready for the unexpected. This is what makes emergency abdominal surgery so exciting and demanding: the ever looming catastrophe and the anxiety about whether or not you are able to tackle it competently.

Abdominal exploration (● Fig. 11.1)

While the specific sequence and extent of abdominal exploration are to be tailored to the clinical circumstances, the two principal stages of any exploration are:

- Identification of the specific pathology which prompted the laparotomy
- Routine exploration of the peritoneal cavity

Essentially, there is a sharp distinction between a laparotomy for non-traumatic conditions such as bowel obstruction, inflammation or peritonitis, and laparotomy for trauma with intra-abdominal hemorrhage, the later being rarely due to spontaneous, non-traumatic intra-abdominal causes.

So you incise the peritoneum, what now? Your action depends on the urgency of situation (condition of the patient), mechanisms of abdominal pathology (spontaneous versus trauma), and the initial findings (blood, contamination or pus). Whatever you find, follow the main **priorities**:

- Identify and arrest active bleeding
- Identify and control continuing contamination

* Asher Hirshberg, MD contributed to this chapter in the 1st edition of the book.




Fig. 11.1. “Hey Doc, did you find anything?”

At the same time: **do not be distracted by trivia.** Do not chase isolated red blood cells or bacteria in a patient who is bleeding to death. For example do not repair minor mesenteric tears in a patient who is busy exsanguinating from a torn inferior vena cava. This is not a joke – surgeons are easily distracted.

Intraperitoneal Blood

The patient may have suffered a blunt or penetrating injury or no injury at all; in the latter case he is suffering from spontaneous intra-abdominal hemorrhage (**abdominal apoplexy**), an uncommon entity caused by the etiologies summarized in Table 11.1.

You may have been expecting the presence of free intra-peritoneal blood from the clinical findings of hypovolemic shock, or the results of the CT, the ultrasound or peritoneal lavage. Your action depends on the magnitude of hemorrhage and the degree of resulting hemodynamic compromise. When the abdomen is full of blood, and the patient unstable, you should act swiftly.

Control the situation:

- Enlarge your initial incision generously (avoid liver and bladder)
- Lift out the small bowel completely
- Suck out blood as fast as possible (always have 2 large suckers ready)
- Pack the four quadrants tightly with laparotomy pads

Table 11.1. Causes of spontaneous intra-abdominal hemorrhage (“abdominal apoplexy”)**Vascular**

- Ruptured abdominal aortic aneurysm
- Ruptured arterial visceral aneurysm (hepatic, gastroduodenal, splenic, pancreaticoduodenal, renal, gastroepiploic, middle colic, inferior mesenteric, left gastric, ileocolic (may be associated with Ehlers-Danlos syndrome))
- Intraperitoneal rupture of varices associated with portal hypertension
- Spontaneous rupture of the iliac vein

Gynecological

- Ruptured ectopic pregnancy
- Spontaneous rupture of the pregnant uterus with placenta percreta
- Postpartum ovarian artery rupture
- Spontaneous ovarian hemorrhage (idiopathic, ruptured follicular cyst or corpus luteum, ovarian cancer)

Pancreatitis

- Erosion of adjacent vessels involved in the process of severe acute pancreatitis, chronic pancreatitis or pancreatic pseudocyst

Liver

- Rupture of benign (typically adenomas) or malignant hepatic tumors

Spleen

- Spontaneous rupture

Adrenal

- Spontaneous hemorrhage: normal gland or secondary to tumor

Kidney

- Spontaneous rupture: normal kidney or secondary to tumor

Anti-coagulation

- Patients on anticoagulation are prone to spontaneous retroperitoneal or intra-peritoneal bleeding – often prompted by unrecognized minor trauma

Unrecognized or denied trauma

- Patient “forgot” the kick to the LUQ, which broke his spleen

Miscellaneous

- Acute ruptured cholecystitis
- Mediolytic arteritis of an omental artery
- Periarteritis nodosa

Evacuation of massive hemoperitoneum temporarily aggravates hypovolemia. It releases the tamponade effect and relieves intra-abdominal hypertension (🔗 Chap. 36), resulting in sudden pooling of blood in the venous circulation. At this stage, compress the aorta at its diaphragmatic hiatus and let the anesthetist catch up with fluid and blood requirements.

Be patient, do not rush forward; with your fist on the aorta, the abdomen tightly packed, and the patient's vital organ perfusion improving, you have almost all the time in the world. Do not be tempted to continue with the operation, which can result in successful hemostasis in a dead patient. Relax and plan the next move, remembering that from now on you can afford to lose only a limited amount of blood before the vicious cycle of hypothermia, acidosis, and coagulopathy ("the triangle of death") will further frustrate efforts to achieve hemostasis.

Primary Survey

Now you are ready to identify and treat the life-threatening injuries. The initial direction of your search will be guided by the causative mechanisms. In penetrating injury the bleeding source should be in the vicinity of the missile or knife tract; in blunt trauma, bleeding will probably originate from a ruptured solid organ – the liver or spleen – or the pelvic retroperitoneum.

Unpack, suck and re-pack each quadrant consecutively noting where there is blood re-accumulation (active bleeding) or hematoma. Having accurately identified the source (or sources) of bleeding, start definitive hemostasis, the rest of the abdomen being packed away. Simultaneously, if the situation permits, control contamination from injured bowel using clamps, staplers or tapes, or re-packing in desperate situations.

Stay tuned constantly to events behind the blood-brain barrier (BBB) – which is the screen between you and the anesthetists. Wake them up from time to time and ask how the patient is doing. Take this opportunity also to explain how and what you are doing. Communication among members of the medical team in this situation is vital. While you are repairing the iliac vein the patient may be developing a pericardial tamponade.

Secondary Survey


Now the exsanguinating lesion is permanently or temporarily controlled and the patient's hemodynamics have been stabilized. With less adrenaline floating around you can divert your attention to all the rest, and look more precisely around. With growing experience your abdominal exploration will become more efficient

but never less thorough, as “missed” abdominal injuries continue to be a common source of preventable morbidity. The practicalities of systematic abdominal exploration are described below.

Intraperitoneal Contamination or Infection

First you register the offensive fecal smell or fecal-looking fluid that denotes abundance of anaerobic bacteria and usually an infective source in the bowel. Note, however, that neglected infections from any source can be *pseudofeculant* due to the predominance of anaerobes. When, on opening the peritoneum gas escapes with a hiss, be aware that a viscus has perforated. In the non-trauma situation this usually implies perforated peptic ulcer or sigmoid diverticulitis. Bile-staining of the exudate points to pathology in the biliary tract, gastroduodenum or proximal small bowel. Dark stout-beer fluid and fat necrosis hints at pancreatic necrosis or infection in the lesser sac. **Whatever the nature of contamination or pus, suck and mop it away as soon as possible.**

Generally, bile directs you proximally and feces distally, but “simple” pus can come from anywhere. When its source remains elusive, start a systematic search keeping in mind all potential intra and retroperitoneal sources “from the esophagus to the rectum”. Be persistent with your search. We recall a case of spontaneous perforation of the rectum in a young male, twice explored by experienced surgeons who failed to appreciate the minute hole deep in the recto-vesical pouch. It was found during a third operation.

Occasionally, however, the root of contamination or secondary peritonitis is not found. A Gram-stain disclosing a *solitary* bacterium – as opposed to a few – would support the diagnosis of **primary peritonitis**, since *secondary peritonitis* (e.g. secondary to a visceral pathology) is always polymicrobial. More about this in  Chap. 12.

The Direction and Practicalities of Exploration

This depends on the reason for the laparotomy; here we bring a general plan.

The peritoneal cavity *comprises two compartments: the supracolic and the infracolic compartment*. The dividing line is the transverse (meso)colon, which in a xipho-pubic midline incision is located approximately in the center of the incision. It is important to develop and adhere to a fixed routine of abdominal exploration, which will include both compartments. Our preference is to begin with the infracolic compartment; the transverse colon is retracted upwards, the small bowel eviscerated, and the rectosigmoid identified. Exploration begins with the pelvic

reproductive organs in the female, and then attention is turned to a systematic inspection and palpation of the rectosigmoid, progressing in a retrograde fashion to the left, transverse and then right colon and cecum, including inspection of the mesocolon. The assistant follows the exploration with successive movements of a hand-held retractor to retract the edge of the surgical incision and enable good visualization of whichever abdominal structure is the focus of attention. Exploration then proceeds in a retrograde fashion from the ileo-cecal valve to the ligament of Treitz, with special care being taken to inspect both “anterior” and “posterior” aspects of each loop of bowel as well as its mesentery.

Attention is then turned to the **supracolic compartment**. The transverse colon is pulled down, and the surgeon inspects and palpates the liver, gallbladder, stomach (including the proper placement of a nasogastric tube), and spleen. Special care should be taken to avoid iatrogenic damage to the spleen caused by pulling hard on the body of the stomach or the greater omentum. A complete abdominal exploration also includes entry into the lesser peritoneal sac, which is best undertaken through the gastrocolic omentum. This omentum is usually only a thin avascular membrane on the left side, and this should therefore be the preferred entry route into the lesser sac. Take care to avoid injury to the transverse mesocolon which may be adherent to the gastrocolic omentum. A misdirected surgeon can be convinced that he is entering the lesser sac when in fact he or she is cutting a hole in the transverse mesocolon. The gastrocolic omentum is divided between ligatures bringing the body and tail of the pancreas into full view.

Exploration of retroperitoneal structures involves two key mobilization maneuvers, which should be employed whenever access to the retroperitoneum is deemed necessary:

- **“Kocher’s maneuver”** is mobilization of the duodenal loop and the head of the pancreas by incising the thin peritoneal membrane (posterior peritoneum) overlying the lateral aspect of the duodenum and gradually lifting the duodenum and pancreatic head medially. This maneuver is also the key to surgical exposure of the right kidney and the right adrenal gland. Kocher’s maneuver may be extended further caudad along the “white line” on the lateral aspect of the right colon all the way down to the cecum. This extension allows medial rotation of the right colon and affords good exposure of the right-sided retroperitoneal structures such as the inferior vena cava, iliac vessels and the right ureter. Further extension of this incision angles around the caecum and continues in a supero-medial direction along the line of fusion of the small bowel mesentery to the posterior abdominal wall. Thus it is possible to mobilize and reflect the small bowel upwards, the so-called *Catell-Braasch maneuver*. This affords optimal exposure of the entire infra-mesocolic retroperitoneum, including the aorta and its infra-renal branches.

- The second key mobilization maneuver is called “*left-sided Kocher*” or “*medial visceral rotation*” (also called by some the *Mattox maneuver* although he was not the

first to perform it) and is used especially to gain access to the entire length of the abdominal aorta and to the left-sided retroperitoneal viscera. Depending on the structures to be exposed this maneuver begins either lateral to the spleen (spleno-phrenic and spleno-renal ligament) working caudally or in the “white line” of Toldt lateral to the junction of the descending and sigmoid colon, working upwards. The peritoneum is incised and the viscera, including the left colon, spleen and tail of pancreas are gradually mobilized medially. The left kidney can either be mobilized or left in situ, depending on the surgical target of the exploration.

In cases of **spontaneous hemoperitoneum**, you’ll have to look for a ruptured aortic, iliac or visceral arterial aneurysm, ectopic pregnancy, bleeding hepatic tumor, spontaneous rupture of an enlarged spleen, or any of the other causes listed in Table 11.1. In penetrating trauma you’ll follow the entry-exit tract, taking into consideration the missile’s energy, velocity and potential to fragment. **Wherever there is an entry wound in a viscus or blood vessel look for the exit one!** The latter may lie concealed on the lesser sac wall of the stomach, the retroperitoneal surface of the duodenum, or the mesenteric edge of the small bowel. It is the blunt abdominal injury, however, that requires the most extensive and less directed search, from the surface of both hemi-diaphragms to the pelvis, from gutter to gutter, on all solid organs, along the whole length of the GI tract, and on the retroperitoneum. (The retroperitoneum selectively, as discussed in Chap. 35). The exact sequence of exploration is less important than its thoroughness.

Additional Points: Grading the Severity of Injury

Abdominal exploration for trauma ends with a strategic decision about the subsequent steps. Forget at this stage the many available organ injury scales, which are of only academic value; from the operating surgeon’s point of view there are essentially two patterns of visceral damage: “minor trouble” and “major trouble”.

- “**Minor trouble**” involves easily fixable injuries, either because the injured organ is accessible or the surgical solution is straightforward (e.g., splenectomy, suture of mesenteric bleeders, or a colon perforation). There is no immediate danger of exsanguination or loss of surgical control. Under these circumstances you can immediately proceed with definitive repair.

- “**Major trouble**” is when the spontaneous condition or injury is not easily rectified because of complexity or inaccessibility (e.g., a high-grade liver injury, a major retroperitoneal vascular injury in the supracolic compartment, or destruction of the pancreatoduodenal complex). Here the secret of success is to **STOP** the operation when temporary (usually digital or manual) control of bleeding is achieved. Take time to optimize the surgical attack on the injured organ. Update all members of the operating and anesthesia teams on the operative plan. Allow your anestheti-

ologist to use the time to stabilize the patient hemodynamically and to obtain more blood products. (Often you have to think for your anesthetist – don't assume that he is awake. However, bear in mind that just as you are a “modern” surgeon there are now “modern” anesthetists, and they are an invaluable resource in the management of such patients. Take care not to alienate these excellent practitioners!). Order an autotransfusion device and a full range of vascular and thoracotomy instruments to be brought in. This is also the appropriate time to seek more competent help, and to plan the operative attack, including additional exposure and mobilization. Such preparations are crucial for the survival of your patient.

Remember: very often the initial exploration of the abdomen in the trauma patient is incomplete, because the patient's critical condition creates a situation where every minute counts and injuries are simply repaired as they are encountered. **Under these circumstances you must complete the exploration before terminating the procedure.**

Finally, **first do not harm.** This applies everywhere in medicine but is of paramount importance during abdominal exploration. The injured or infected contents of the peritoneal cavity may be inflamed, swollen, adherent, friable and brittle. Careless and sloppy manipulation and separation of viscera during exploration commonly induce additional bleeding and may produce additional bowel defects, or enlarge the existing ones. And as usual, new problems translate into additional therapies and morbidity.

This is what makes emergency abdominal surgery so exciting and demanding: the ever looming catastrophe and the anxiety about whether you are able, or not, to tackle it competently.

Peritonitis: Contamination and Infection, Principles of Treatment

MOSHE SCHEIN · ROGER SAADIA

In peritonitis – source control is above all.

“The mechanical control of the source of infection, while itself nonbiologic, determines the extent of the host biologic response to the disease.” (Ronald V. Maier)

The finding of inflammation, bowel contents or pus, localized or dispersed throughout the peritoneal cavity is common at emergency laparotomy. How is this scenario best handled? This chapter will discuss general aspects of the surgical treatment.

Nomenclature

Peritonitis and **intra-abdominal infection** are not synonymous. The former may result from sterile inflammation of the peritoneum, like the chemical peritonitis seen following a very recent perforation of a peptic ulcer or acute pancreatitis. Intra-abdominal infection implies inflammation of the peritoneum caused by micro-organisms. Because, in clinical practice, the vast majority of cases of peritonitis are bacterial, these two terms are used interchangeably.

As a reminder:

— **Primary peritonitis** is caused by micro-organisms which originate from a source outside the abdomen. In young girls, it is usually a *Streptococcus* gaining access via the genital tract; in cirrhotics, *E. coli* is thought to be a blood-borne agent infecting the ascites; and in patients receiving peritoneal dialysis, *Staphylococcus* migrates from the skin along the dialysis catheter. Primary peritonitis in patients without a predisposing factor, such as ascites or dialysis catheter, is extremely rare. It is usually diagnosed during a laparotomy for an “acute abdomen” when odorless pus is found without an apparent source. The diagnosis is reached by exclusion (after a thorough abdominal exploration), and is confirmed by a Gram-stain and culture, which document a solitary organism. In patients with a known predisposing factor (e.g. ascites associated with chronic liver disease), primary peritonitis should be suspected and diagnosed by paracentesis, thus avoiding an operation – as an exploratory laparotomy in an advanced cirrhotic patient often represents an *autopsy in vivo*. Initial antibiotic treatment is empiric, until results of bacteriological sensitivities become available.

— **Secondary peritonitis** implies that the source of infection is a disrupted or inflamed abdominal viscus. This entity is “bread and butter” for you, the general surgeon.

— **Tertiary peritonitis** (🔗 Chap. 48).

— **Intra-abdominal infection (IAI)** is defined as an inflammatory response of the peritoneum to micro-organisms and their toxins that results in a purulent exudate in the abdominal cavity.

— **Abdominal contamination** represents conditions without a significant peritoneal inflammatory response: soiling has occurred but infection is not established yet (e.g. early traumatic bowel perforation).

— **Resectable IAI** represents infectious processes that are contained within a diseased but resectable organ (e.g. gangrenous appendicitis). These conditions are easily eradicated by an operation and consequently do not require prolonged post-operative antibiotic therapy.

— **Non-resectable IAI** are infections that have spread beyond the confines of the source organ. In perforated appendicitis, for instance, you may resect the appendix but residual peritoneal infection persists, requiring extended antibiotic coverage.

— **Abdominal sepsis** is still a term used very commonly, yet it is confusing. According to modern consensus usage “sepsis” means systemic inflammatory response syndrome (SIRS) plus a source of infection (🔗 Chap. 48). The use of “sepsis”, in the abdominal context, would not take into account the important initial *local* inflammation within the peritoneal cavity. This peritoneal response is analogous, at a local level, with SIRS at the systemic level, because it represents, likewise, a non-specific inflammatory response of the host to a variety of noxious stimuli, not necessarily infectious. Strictly speaking, therefore, *local contamination, infection and sepsis refer to different processes*. Yet, they may co-exist in the same patient, developing simultaneously or consecutively. The soiling of the peritoneal cavity with feces may result in one or another pathological entity, belonging to a continuum of local and systemic conditions ranging from local contamination to septic shock. Untreated or neglected abdominal contamination progresses to intra-abdominal infection, which is invariably associated with a systemic inflammatory response. **More significantly, abdominal inflammation or indeed the systemic response (fever, leukocytosis) may even persist after the intra-peritoneal infection has been eradicated.**

This is not just a matter of semantics or hair-splitting. It has clinical relevance in determining management.

Abdominal contamination is controlled by the local peritoneal defense mechanisms, assisted by operative peritoneal toilet and *prophylactic* antibiotics.

Resectable infection is managed by the resection of the contained focus of infection, supplemented with a short *peri-operative* course of antibiotics.

Infection, which is not entirely “*resectable*”, requires surgical control of its source and, in this situation, *therapeutic* antibiotics are continued postoperatively (♣ Chaps. 7 and 42).

Management

The outcome of intra-abdominal infection (IAI) depends on the virulence of infection, the patient’s pre-morbid reserves, and his current physiological compromise. Your goal here is to assist the patient’s own local and systemic defenses.

The philosophy of management is simple – comprising two steps: **source** control, followed by **damage** control.

Source control

The key to success is timely surgical intervention to stop delivery of bacteria and adjuvants of inflammation (bile, blood, fecal fiber, barium) into the peritoneal cavity. All other measures are of little use if the operation does not successfully eradicate the infective source and reduce the inoculum to an amount that can be handled effectively by the patient’s defenses, supported by antibiotic therapy. This is not controversial – all the rest may be.

Source control frequently involves a simple procedure such as appendectomy (♣ Chap. 28) or closure of a perforated ulcer (♣ Chap. 17). Occasionally, a major resection to remove the infective focus is indicated, such as gastrectomy or colectomy for perforated gastric carcinoma (♣ Chap. 17) or colonic diverticulitis (♣ Chap. 26), respectively. Generally, the choice of the procedure, and whether the ends of resected bowel are anastomosed or exteriorized (creation of a stoma), depends on the anatomical source of infection, the degree of peritoneal inflammation and SIRS, and the patient’s pre-morbid reserves, as will be discussed in the individual chapters.

Damage control

This comprises maneuvers aimed at cleaning the peritoneal cavity, so-called *peritoneal toilet*. What should this entail?

Contaminants and infectious fluids should be aspirated and particulate matter removed by swabbing or mopping the peritoneal surfaces with moist laparotomy pads. Although cosmetically appealing and popular with surgeons, there is no scientific evidence that *intra-operative peritoneal lavage* reduces mortality or infective complications in patients receiving adequate systemic antibiotics. Also *peritoneal irrigation with antibiotics* is not advantageous, and the local addition of antiseptics may produce toxic effects. You may want to “irrigate copiously” (a term popular among American surgeons) as much as you wish, but know that beyond wetting your own underwear and shoes, you do not accomplish much. Should you choose to remain a dedicated irrigator, remember to suck out all the lavage fluid before you close; there is evidence that leaving saline or Ringer’s solution behind interferes with peritoneal defenses by “diluting the macrophages”.

Bacteria swim perhaps better than macrophages!

The concept of *radical debridement of the peritoneal cavity*, by removing every bit of fibrin, which covers the peritoneal surfaces and viscera, did not withstand the test of a prospective randomized study, since aggressive debridement causes excessive bleeding from the denuded peritoneum and endangers the integrity of the friable intestine.

Despite the dictum that **it is impossible to effectively drain the free peritoneal cavity**, drains are still commonly used and misused. Their use should be *limited* to the evacuation of an “established” abscess (when the ensuing cavity would not collapse or cannot be filled with omentum or adjacent structures), to allow escape of potential visceral secretions (e.g., biliary, pancreatic) and, rarely, to establish a controlled intestinal fistula when the latter cannot be exteriorized. To prevent erosion of intestine use soft drains, for the shortest duration possible, keeping them away from bowel. In general, *active-suction* drainage may be better than the *passive*, and infective complications can be reduced using “closed” systems. **Drains provide a false sense of security and reassurance**; we have all seen the moribund post-operative patient with an abdomen “crying” to be re-explored while his surgeon is strongly denying any possibility of intra-peritoneal catastrophe because the tiny drains he inserted, in each abdominal quadrant, are “dry” and non-productive. This is particularly true of drains inserted to deal with post-op hemorrhage (● Chap. 50); it is perfectly possible to have a drain producing no more than a few milliliters of blood yet sitting in an abdomen full of clot. Drains inserted close to an anastomosis “just in case it leaks” are more likely to cause anastomotic problems than to deal with them.

The role of *postoperative peritoneal lavage*, through tube drains left in place for this purpose, is at best questionable. Is it really possible to irrigate the whole abdominal cavity? In our experience tubes or drains are rapidly “walled-off” by adhesions and adjacent tissues. You’ll be irrigating nothing more than the drains’ tracks (● Fig. 12.1).




Fig. 12.1. “Which of the drains is draining?”

Aggressive Modalities of Management

— “In doubtful cases do not wait too long
Before exploring, for it is quite wrong
To act upon the slogan Wait and See,
When looking may provide the remedy” (Zachary Cope, 1881–1974)

Most of your IAI patients will respond to the combination of adequate source control with competent supportive management and appropriate antibiotic administration. Most but not all – a few will need more. During the 1980s it became clear that if the initial standard operation fails, persisting or recurrent IAI sometimes is overlooked or the diagnosis is delayed. Waiting for signs of persisting infection or organ failure as the indication for re-exploration (“on demand”) of the abdomen often proves futile. To improve results, two new concepts of *aggressive management* had to be addressed: to *repeat or ascertain source control* and to *extend damage control*:

- **Planned re-laparotomy** continues the process of source control – repeated operative interventions are planned before the first “index” procedure for peritonitis is completed. The commitment is made to return to the abdominal cavity to re-explore, evacuate, debride or resect as needed, until the disease processes are resolved (● Chap. 46).
- **Open management (laparostomy)** is an addition to damage control, it facilitates frequent re-explorations. It also serves to decompress the high intra-abdomi-

Table 12.1. Indications for laparostomy/planned re-laparotomy

- Critical patient condition (hemodynamic instability) precluding appropriate source control at the first operation, thus calling for “abbreviated laparotomy” or “damage control” strategy
- Excessive peritoneal (visceral) swelling preventing tension free abdominal closure (Abdominal Compartment Syndrome; ⦿ Chap. 36)
- Massive abdominal wall loss
- Inability to eliminate or to control the source of infection
- Incomplete debridement of necrotic tissue
- Uncertain viability of remaining bowel (⦿ Chap. 23)
- Uncontrolled bleeding (the need for “packing”)

nal pressure caused by peritoneal edema associated with inflammation, infection and fluid resuscitation, thus obviating the deleterious local and systemic consequences of the **abdominal compartment syndrome** (⦿ Chaps. 36 and 46).

Early results of these methods were promising, particularly in the management of infected pancreatic necrosis but were less favorable in cases of post-operative peritonitis, perhaps because the sickest patients were included. Intestinal fistulas plagued simple open management – problems that were significantly reduced by introduction of *temporary abdominal closure* (TAC) techniques as explained in ⦿ Chap. 46. Our indications to utilize these modalities are shown in ⦿ Table 12.1.

In our experience, less than a fifth (remember, we promised not to use percentages) of all patients operated upon for IAI will qualify for such management modalities. Note, however that such aggressive treatment methods carry their own list of complications (in surgery you pay for anything you do...). The possibility has been raised that re-laparotomies constitute a “second hit” in patients in whom the inflammatory response is already “switched-on” – thus escalating the systemic inflammatory response syndrome (SIRS) (⦿ Chap. 48). To solve this controversy, prospective randomized studies are necessary but extremely difficult, if not impossible, to organize. We believe, however, that these techniques are beneficial if initiated early, in well-selected patients, for specific indications, and performed by a team of dedicated surgeons. Conversely, indiscriminate use, at “the end of the operative list”, often by ever changing members of the junior staff, is a recipe for disaster (⦿ Chap. 46).

Intra-abdominal Abscess

Many surgical texts still, erroneously, use the term intra-abdominal abscess as a synonym with peritonitis. This is not true as abscesses develop due to effective host defenses and represent a relatively successful outcome of peritonitis. *The mainstay of treatment is drainage, but by which route?* This is discussed in detail in ● Chap. 44.

Need for Peritoneal Cultures

The expensive ritual of obtaining routine intra-operative peritoneal cultures has become questionable. Think, how many times did you act, changing antibiotics, based on peritoneal culture results? Probably never! As you saw above, the microbiology of IAI is predictable, the pathogens being “covered” by the broad-spectrum empiric agents started by you prior to the operation (● Chap. 7). Furthermore, usually after a few days, when culture and sensitivity results are available, the antibiotics are no longer necessary. Being a modern surgeon you stopped them at the appropriate time (● Chap. 42). Recently we conducted an audit among infection disease (ID) specialists and a group of surgeons interested in surgical infections. We asked them the following question: a patient undergoes a laparotomy 3 hours after receiving a gunshot injury to his abdomen. At operation you find a hole in the left colon and fecal peritoneal contamination. Would you send the peritoneal fluid for culture and sensitivity?

Guess what was the response? Almost all (95%) of ID specialists would send the pure s**t for culture – as if they do not know what kind bacteria it contains! But now you know better than they: you know that this patient had peritoneal contamination – necessitating source control, peritoneal toilet and prophylactic peri-operative antibiotics. Nothing more!

[If you want to read much more about this topic, then find a copy of the recently published book *Source Control* (edited by M. Schein and J. Marshall), Springer, Berlin Heidelberg New York, 2002]

“Shakiness of the hand may be some bar to the successful performance of an operation, but he of a shaky mind is hopeless.” (Sir William MacEwen, 1848–1924)

MOSHE SCHEIN

The enemy of good is better: the first layer is the best – why spoil it?

The Ideal Anastomosis

The ideal intestinal anastomosis is the one which does not leak, for leaks, although relatively rare, represent a dreaded and potentially deadly disaster (♦ Chap. 45). In addition, the anastomosis should not obstruct, allowing normal function of the gastrointestinal tract within a few days of construction.

Any experienced surgeon thinks that his anastomotic technique, adopted from his mentors and with a touch of personal virtuosity, is the “best”. Many methods are practiced: end-to-end, end-to-side or side-to-side; single- versus double-layered, interrupted versus continuous, using absorbable versus non-absorbable and braided versus monofilament suture materials. We even know some obsessive-compulsive



Fig. 13.1. “Give it to me, nurse...this will be a perfect anastomosis!”

surgeons (do you know any?) who carefully construct a three-layered anastomosis in an interrupted fashion. Now add staplers to the mix. So where do we stand; what is preferable? (👉 Fig. 13.1).

Pros and Cons

Numerous experimental and clinical studies support the following:

- **Leakage:** the incidence of anastomotic dehiscence is identical – irrespective of the method used, provided the anastomosis is technically sound; constructed with well-perfused bowel without tension, and being water and airtight.
- **Stricture:** the single-layer anastomosis is associated with a lower incidence of stricture formation than the multi-layered one. Strictures are also commoner following end-to-end anastomosis performed with the circular stapler.
- **Misadventure:** intra-operative technical failures with staplers are more frequent due to “misfires”.
- **Speed:** stapled anastomoses, on the average, are slightly faster than those sutured by hand. The fewer the layers, the faster the anastomosis and the continuous method is swifter than the interrupted one. In practice, the time consumed in placing two “purse-string” sutures for a stapled circular anastomosis is identical to that required to complete a hand-sutured, single-layered, continuous anastomosis.
- **Suture material:** braided sutures (e.g., silk or vicryl) “saw” through tissues and, experimentally at least, are associated with greater inflammation and activation of collagenases than monofilament material (e.g., PDS, prolene). “Chromic catgut” is too rapidly absorbed to support (alone) an anastomosis. Monofilament slides better through the tissues and, when used in a continuous fashion, is self-adjustable allowing equal distribution of the tension around the entire circumference of the anastomosis.
- **Cost:** staplers are much more expensive than sutures and, thus, generally not cost-effective. The single-layer continuous technique requires less suture material, and is therefore more economical than the interrupted method.

The Choice of Anastomotic Technique

Since all methods, if correctly performed, are safe, nobody can fault you for using the anastomotic method with which you are most familiar and comfortable. We maintain, however, and we may be biased, that the one-layer, continuous method, using a monofilament suture material, is the one that a “modern surgeon” should adopt, because it is fast, cheap and safe. What is good for the high-pressure vascular

anastomosis should be as good for the low-pressure intestinal one. If the first layer suffices why narrow and injure it with inverted and strangulated tissue? Would you replace a well-done hamburger on the grill?

We acknowledge that staplers are elegant, admired by the nursing operating room staff, “fun” to use and of great financial benefit to the manufacturers. Certainly, staples may be advantageous in selected “problematic”, rectal or esophageal anastomoses, deep in the pelvis or high under the diaphragm. But those types of anastomoses are seldom performed in emergency situations. Furthermore, as a surgical trainee you should start using the staplers only after achieving maximal proficiency in manual techniques, and in difficult circumstances. Even the stapler aficionado has to use his hands when the instrument misfires, or cannot be used because of specific anatomic constraints such as the retroperitoneal duodenum. The modern surgeon, and the trainee too, need to be equally proficient in hand-sewn and stapled anastomotic techniques; we suggest, however, that before driving a car you should be able to ride a bicycle.

The Edematous Bowel

There is some evidence (not level I) that, in trauma patients, stapled intestinal anastomoses are more prone to leak than the hand-sewn ones. This has been attributed to the post-resuscitation bowel edema which develops after severe injury. (The staplers cannot “adjust” to the swelling of the bowel – the surgeon’s hands can). It is also our experience that a continuous, monolayer anastomosis occasionally fails when performed in edematous bowel (e.g., after massive fluid resuscitation or severe peritonitis). From findings at re-operation we have learned that subsequently, as the bowel edema subsides, the suture becomes loose, leading to anastomotic dehiscence. Therefore, when anastomosing swollen, edematous bowel we prefer not to use staplers or the continuous hand sutured method. Instead, we use a closely placed single layer of interrupted sutures – individually tied “not too tight, not too loose” – in order to avoid cutting through the bowel edges, but also to obviate the risk of loosening after the edema subsides. A similar interrupted technique may be preferred in colo-colo anastomoses where the avoidance of the hemostatic effects of continuous sutures may have theoretical advantages. Furthermore, in this situation the ability of the colon to change dramatically in diameter under normal physiological conditions may be impaired if a continuous suture with its fixed length is utilized. We admit, however, that scientific data to back these hypotheses are lacking.

Technique

Our preferred continuous, monolayered anastomosis uses one double-armed, or two regular, 3-0 or 4-0 monofilament sutures (PDS or maxon). No bowel clamps are used, as we like to assess the adequacy of blood supply to the bowel edges. It is not necessary to devascularize the bowel edges by “cleaning off” the fat at the mesenteric side or removing appendices epiploica. The suture line begins at the posterior/mesenteric wall, running “over and over” towards both sides to meet, and be tied, anteriorly (at the anti-mesenteric border). The secret is to take generous bites through the submucosa, muscularis and serosa and avoid the mucosa (“big bites outside, small bites inside”). This suturing technique is known variously as extra-mucosal or sero-submucosal. The needle exit or entry site on the serosal side is 5–7 mm from the bowel edge, while the distance between the bites should be such as not to allow access to the tips of a Debaquey forceps (3–4 mm). The assistant who “follows” the suture should use just enough tension to maintain approximation and avoid strangulation of the tissue. This technique suits both the end-to-side and side-to-side versions and, in essence, it is the intestinal version of a routine vascular anastomosis. We use the above technique throughout the entire gastrointestinal tract, from the esophagus above down to the rectum. Essentially, you create an inverted and safe anastomosis, with a wide lumen, using only a suture or two, in less than 15 minutes.

In “difficult” situations – when the anastomotic site is relatively inaccessible – we prefer a one-layer interrupted technique, which allow more accurate placement of sutures. “How to do” the latter and how to use staplers correctly you will learn from your mentors.

Testing the Anastomosis

A correctly performed anastomosis should not leak. There is little point in routinely testing your simple intra-abdominal intestinal anastomosis; the common practice of pinching-masturbating the anastomosis to confirm an adequate lumen is laughable if you used a one-layer technique as described above. “Problematic” anastomoses, such as those performed in the lower rectum, should be tested: simply clamp the bowel above the anastomosis, fill the pelvis with saline and inject air into the rectum. Instead of air you may wish to use dye. If air bubbles or dye are observed leaking, an attempt to identify and correct the defect is indicated; if unsuccessful, a proximal diverting stoma is necessary.

When Not to Perform an Anastomosis?

We wish we had an exact answer! In broad terms, whenever the probability of a leak is high avoid an anastomosis since any anastomotic leak portends disastrous consequences (➤ Chap. 45). But how do you accurately predict anastomotic failure?

Traditionally, the avoidance of colonic suture lines during emergency operations for trauma, obstruction, or perforation was the standard practice. But times are changing; during World War II a colostomy was mandatory for any colonic injury, but nowadays we successfully repair most of these wounds (➤ Chap. 35). Furthermore, three- or two-stage procedures for colonic obstruction are being replaced by the one-stage resection with anastomosis (➤ Chap. 25). And, as you will read in ➤ Chaps. 25 and ➤ Chap. 26, the issue of whether the large bowel is “prepared” or not has become a “non-issue” – multiple prospective randomized trials show that safe colorectal suture lines can be effected in unprepared bowel.

It is difficult to lay down precise guidelines as to when an intestinal anastomosis is not to be made. You should make a careful decision after considering the condition of the patient, the intestine, and the peritoneal cavity. Generally, we would avoid a colonic anastomosis in the presence of established and diffuse intra-abdominal infection (as opposed to contamination) (➤ Chap. 26) and under the conditions listed in ➤ Table 13.1. Regarding the *small bowel*, anastomosis is indicated in most instances; however, when more than one of the factors listed in the table are present we would tend to err on the conservative side and exteriorize or divert, depending on technical circumstances.

No formula or algorithm is available, so use your judgment and try not to be too obsessive in always attempting an anastomosis. Yes, we know that you wish the patient well by wanting to spare him a stoma, but few will be impressed if he is dead! You should not be fearful of creating a high small bowel stoma. The latter was previously considered unmanageable. Today, however, with total parenteral nutrition, techniques of distal enteric feeding and re-infusion, somatostatin, and stoma care, these temporary proximal intestinal “vents” can be life saving (see also

Table 13.1. Factors that may influence us not to anastomose

- Diffuse established peritonitis
- Postoperative peritonitis (➤ Chap. 46)
- Leaking anastomosis (➤ Chap. 45)
- Mesenteric ischemia (➤ Chap. 23)
- Extreme bowel edema/distension (➤ Chap. 45)
- Extreme malnutrition (➤ Chap. 41)
- Chronic steroid intake
- Unstable patient (damage control situation) (➤ Chap. 35)

► Chaps. 41 and 45). On the other hand, do not be a chicken by avoiding an anastomosis when it is indicated and possible.

Whatever you do, some people will be unhappy. **If you do a colostomy there will be always someone to ask you why not primary anastomosis? If you do a primary anastomosis there will be always someone to say why not colostomy?**

Conclusions

The intestinal anastomosis is the “elective” part of the emergency operation you are going to perform. Remember – your aim is to save life and minimize morbidity; create an anastomosis when its chances of success are at least reasonable. There are many ways to skin a cat and to fashion an anastomosis. Master a few methods and use them selectively.

THOMAS ANTHONY HORAN

“If thou examinest a man having a gaping wound piercing through to his gullet; if he drinks water he chokes (and) it come out of the mouth of his wound; it is greatly inflamed, so that he develops fever from it; thou shouldst draw together that wound with stitching. Thou shouldst bind it with fresh meat the first day. Thou shouldst treat it afterward with grease, honey, (and) lint every day, until he recovers. If, however, thou findst him continuing to have fever from that wound thou shouldst apply for him dry lint in the mouth of his wound, (and) moor (him) at his mooring stakes until he recovers.” (From the Edwin Smith Papyrus, written in Egypt roughly 3000 years ago)

The esophagus gives no pleasure, but senses all forms of pain. Its job is simple: relax and let the bolus in, push it with gravity assistance, relax again to let it into the stomach. Despite this simplicity it is prone to obstructive problems. As there is no serosa, the submucosa is its one layer of strength – thus it is relatively weak. The stomach can generate 2–3 times the force necessary to rupture it during vomiting. Almost all neoplastic or inflammatory lesions of the esophagus rapidly affect this one layer of strength, as may vigorous endoscopic manipulation. When something disrupts its integrity, the esophagus delivers a cocktail of mouth anaerobes directly into the mediastinum, which is one of the body’s least resistant areas.

As a general surgeon, the two esophageal emergencies you are most likely to be called to solve are obstruction and perforation.

Foreign Body Ingestion – Obstruction

The night nursing matron ate her tuna sandwich as always at 2 a.m., but felt something sharp in her throat. The X-rays in the a.m. were normal. Discomfort persisted for the next 3 weeks; barium swallow suggested cervical esophageal cancer. September 10th, I slipped out her dentures and passed the flexible scope for biopsy. The bread bag clip, deeply imbedded in the esophageal wall, read “best before August 13”. How true.

Swallowed foreign bodies (FBs) are the most frequent cause of acute dysphagia. Food with bones and other imbedded sharp objects take the unaware – children, patients with dentures, the intoxicated – and their doctors by surprise. Children will swallow just about anything that fits in the mouth, coins and safety

* A comment by the Editors is found at the end of the chapter.

pins predominating. Psychiatric patients swallow the most interesting things. Most of the rest of FB-related esophageal obstruction is superimposed on underlying esophageal diseases such as motility disorder, hiatus hernia, stricture, diverticula and cancer. Even the notorious *steak house syndrome* is more common in patients with underlying esophageal pathology. Therefore, after the FB is evacuated all patients deserve evaluation of their esophagus. Delay in treatment vies with ill-conceived efforts at retrieval as the cause for most perforations from FBs.

How to Manage Esophageal Foreign Bodies?

The average transit time from cricopharyngeus to stomach is between 3 and 5 seconds. Thus, if the FB is still in the esophagus when the patient gets to the hospital, it is by definition **STUCK**. Stuck FBs cause people to gag, cough, drool, hurt, bleed, and aspirate while it tries to move down, up or through the esophagus. So you have to assist it out through an anatomical passage before it describes a non-anatomical one by itself.

— **First, find it.** Frequently, the patient knows right where it is, what it is, and why and how it got there. So ask him. Insistence on antero-posterior and lateral neck, chest and abdomen X-rays seems a bit old-fashioned but it is cheap and efficient and may quickly define the problem. If it doesn't, there is always contrast and/or CT to help. Sometimes a wisp of contrast-soaked cotton baton will hang up on it. The X-rays help you plan, choose your equipment and warn you about possible risks of perforation. Because of false negative radiology and associated conditions *every symptomatic patient should get endoscopy.*

— **Methods of FB removal** are based on visualization for safe removal (see near disaster below). No matter how sophisticated your snares and flexible equipment, you must know how to use the good-old rigid scope for the removal of sharp objects. Blind methods or pushing impacted boluses into the stomach are risky and can lead to iatrogenic perforation. **Judging when the risk of endoscopic removal outweighs risk of open surgery is aided by a history of bleeding, pus and buried sharp objects next to the aortic indentation.** A large number of exculpatory reports testify to the role for operative removal in selected high-risk cases. For example, a recent report of poor planning, which led to pneumomediastinum and bilateral pneumothorax while attempting to remove a knitting needle incarcerated in a hiatus hernia.

— There is controversy about asymptomatic patients with *smooth small* FBs, like coins, since left alone most pass into the stomach and then go down the whole distance without further trouble. Some caution needs to be exercised, but if you are sure it isn't chemically active (button batteries and zinc-containing coins), how long should you wait? Many suggest "up to 3 days", but this sounds suspiciously like it

is based on the length of the weekend. In the absence of a fail-safe rule, any symptom or failure to reach the stomach by the time of the X-ray in the morning should urge you do the endoscopic removal.

Summary

- Investigate all symptomatic patients
- Remove all FBs not in the stomach within 24 hours
- Get help from someone who can use a rigid scope
- Consider surgery in very selected cases

Esophageal Perforation

The admiral had eaten a heavy meal. During the next few hours he had taken small cups of a mild emetic, as was usual when he was feeling heavy. Four times he had about 28 g of olive oil and later drank about 180 g of beer. When this did not have the desired effect, he took another four cups. He tried to throw up, but suddenly screamed because of an excruciating pain in the chest. He immediately declared himself dying and started praying. It was a very sick patient, though free of fever, who met Boerhaave. The house physician, Dr. de Bye, had tried bleeding. There were no symptoms of any known disease or poisoning, and the two physicians ordered another bleeding, something non-alcoholic to drink and warm compresses. But, in vain, the baron succumbed the next day. Herman Boerhaave conducted an autopsy that revealed the rent in the oesophagus and the contents of a previous meal, gas, and fluid in the chest.

Esophageal perforations continue to increase in number with the “traditional” foreign body and vomiting etiologies remaining constant but instrumental or iatrogenic perforations having a four-fold increase. It is likely to increase even further with the current enthusiasm for laparoscopic Nissen fundoplication. Prior to the Second World War the mortality of esophageal perforations was horrendous. Today, the emphasis on early diagnosis and treatment, and perhaps the effective antibiotic treatment of the associated mediastinitis, have greatly improved results. The survival improvement seems correlated with the large number of endoscopic instrumental perforations, which make early diagnosis correspondingly easier.

In general there are four major groups of esophageal perforations, each one with differing therapy.

The Kind You Think You Can Get Away With

The catheter slipped beyond the impacted 4 cm beach rock. The 30-ml balloon got a good hold. Increasing withdrawal tension released with a “thwack”. NADA! Re-inspection

revealed blood and esophageal muscle but no rock. Gastrografin swallow suggested a contained rupture and a rock packed in the posterior nose. Nasal disimpaction, NPO (nothing by mouth), nasogastric suction, antibiotics, parenteral nutrition and discharge to his mental hospital followed over the next 2 weeks.

The non-operative treatment of a small, contained, intramuscular, incomplete tears of the esophagus is employed when it is recognized right away and only if there is no adverse systemic response, tachycardia, fever or pain. The trick is being sure there is no residual material retained outside the esophageal wall and no dependent pockets (by which I mean what goes in comes right back out). The mucosal defect closes on the follow up esophagram. If anything is not right, treat like all ruptures (see below). Optimistic over-diagnosis of this entity leads to delay and possible disaster.

The Kind a Surgeon Likes to Treat (If Someone Else Caused It)

This is the classic early-diagnosed perforation treated in the first 24 hours scenario. But it is surprising how frequently patients get sent home despite the obvious – “*Worst case of esophagitis I ever saw.*” (🔴 Fig. 14.1). Reticence to accept the obvious costs lives and reputations. Pain after endoscopy means a high risk of perforation, subcutaneous emphysema ditto, and fever means mediastinitis. History almost always gives the cause and the diagnosis and frequently the level of injury. Positive physical findings of emphysema, pericardial crunch, pneumothorax or hydrothorax used to be indicators of late diagnosis. Now, with the air being pumped in by endoscopes, they may be the first noted abnormality. The level of emphysema on X-ray corresponds to the level of injury: low perforations typically give left hydropneumothorax, midesophageal perforations are suspected in right hydrothorax. Diagnosis is confirmed with contrast studies, with or without CT. Don't waste time, treat with NPO, resuscitation, antibiotics and surgery.

Perforations in the neck and upper mediastinum are repaired and drained through the neck. Use the anterior border of the sternomastoid approach because it is so easy to extend and lends itself to the rotation of buttressing strap muscles. See the whole defect and close the mucosa/submucosa. Close the muscle over it, buttress with local muscles and use a big floppy soft drain. Make a two-finger hole for the drain. If they leak they get better anyway as long as there is good drainage.

Perforations in the chest, follow exactly the same principles. Go to the left side for low leaks, right side for higher leaks, and get wide mediastinal exposure for good visualization and drainage. See and close the whole mucosal defect. Then close the esophageal muscle over it. Cover them all with good tissue, like pleural flaps or intercostal muscle flap wrapped around the esophagus and sewn on the esophageal closure, not just laid on it. Every book written in the last 40 years shows this tech-



Fig. 14.1. “Gee, this is severe esophagitis!”

nique; use it even if you don’t think it is necessary, because you only get one good chance. Finish with big dependent chest drains, provisions for nutrition and antibiotics.

Spontaneous perforation results from vomiting against a conscious attempt to prevent it (Boerhaave Syndrome). The pressure generated in the esophagus blows out the weakest point, usually located just above the lower esophageal sphincter. It is treated just as all the other perforations, with surgery at the earliest opportunity. However, the risk of spontaneous rupture is higher in patients with an already sick esophagus due to hiatus hernia, congenital or acquired connective tissue disorders, use of steroids, malnutrition and old-age. Because of a particularly high mortality and morbidity, these special cases need to be considered in the same category as late diagnosed perforations (see below).

— **Associated lesions.** Closing a perforation above an obstructing lesion doesn’t work. In *achalasia*, epiphrenic diverticula and diffuse esophageal spasm, do the myotomy on the opposite side of the esophagus from the perforation. Make the myotomy as always from the gastroesophageal junction to 8 cm above the level of the perforation. Then close the perforation just like above. Strictures distal to a perforation have to be dealt with one way or another. Perforation at or just above a stricture associated with gastroesophageal reflux may pose a special problem with full thickness fibrosis and shortening of the esophagus. The antireflux wrap will greatly assist the closure in these cases provided that the fundus is able to be sutured to the perforation. Don’t simply wrap like usual but be sure to secure in place over the perforation. You may need to add a *Collis gastroplasty* to lengthen the esophagus

or to close the perforation using the gastric fundus as a serosal patch – combined with a floppy non-constricting antireflux procedure. This is the one time I don't insist on the wrap being in the abdomen; it is most important not to put any tension on the repair of the perforation. If it doesn't easily go back into the abdomen leave it in the chest.

— **Isolated external penetrating and blunt injuries** to the esophagus are rare. Thoracic gun-shot injury will hit the esophagus about 1 in 20 cases. Associated injuries to heart, lung, blood vessels, spine and airway always take precedence. Signs of esophageal injury such as hemothorax or mediastinal emphysema are similarly attributable to concomitant injuries. Therefore, always examine the esophagus prior to closure after all the other more dramatic injuries to lung, heart and blood vessels have been controlled. Complete exploration of the hematoma and tracts of penetrating objects usually prevents missing the esophageal defect. There is nothing worse than operating for trauma and 2 days later finding the patient moribund from mediastinitis from overlooked esophageal perforation. *Blunt disruption* of the esophagus implies violent deceleration, difficult diagnosis and a terrible prognosis. However, blunt trauma may occasionally cause rupture of the esophagus from intrusion of osteophytes at a lower degree of violence.

The Kind Nobody Wants

This is the killer. The patient presents late, is septic, has mediastinitis and empyema, whether from spontaneous vomiting-induced rupture, foreign body, neglect, or missed iatrogenic perforation – it doesn't matter; he is in big trouble and you know it. Perforations occurring in cancer, manipulation of extensive caustic strictures, third degree caustic burns, congenital connective tissue disorders, and congenital epidermolysis bullosa, are all in the same category. Rapid concerted effort from a dedicated group is critical. You have to stabilize and then operate. You have to control the source of the infection, thus he will need esophagectomy AND provide wide drainage. You can restore continuity at a time of your choice; after all you can always re-operate on an alive patient.

The toughest decision to make in perforation of the esophagus is what to do when the diagnosis has been *delayed* in a previously well esophagus. The inclination is to preserve the esophagus if possible. The mediastinal tissues and the state of the esophagus will tell you. If the patient is lucky, the perforation has passed directly into the pleural cavity and the mediastinum and esophagus are relatively intact. The basis of surgical treatment is surgical closure as described above, but you must debride any necrotic tissue prior to any attempt at closure. Even so, the sutures you place will be at a high risk of leakage. Thus along with wide mediastinal drainage, large bore chest tubes, antibiotics and nutrition you must consider proximal

diversion, and gastrostomy to protect the closure, especially if the mucosa is edematous, stiff and friable.

When the perforation is mostly contained within the mediastinum severe mediastinitis is invariable. None of the choices is good, but don't give up; remember, the patient survived with no treatment up until now. With good treatment he can still pull through. The inflamed esophagus will not hold sutures so it is useless to think of primary closure. Wide drainage alone will lead to a long, debilitating and perilous course, and therefore isolation of the esophagus via cervical diversion with gastrostomy is a safer option. Emergency resection is my preferred option especially when the esophagus is partially necrotic and wide debridement will make stricture a near certainty. The benefits of this approach are rapid effective control of the contamination of the mediastinum and better avoidance of complications such as vascular fistula.

Perforations from dilation of strictures secondary to accidental caustic ingestion outnumber acute perforations from liquefaction of the esophagus secondary to suicide attempts. Both need emergency resection. I have never understood the reticence in resection of severe caustic injuries. Should they survive without resection they are condemned to a life of stricture dilatation with one in five suffering instrumental perforations. Anyway, if not resected at the acute stage many of these patients will come to resection and replacement at later date because of difficulties with nutrition and the high risk of malignancy developing in the burned esophagus – perhaps as high as 1000 times the general risk.

Perforations in Patients that Can't be Fixed

“Doctor, the lymphoma you ‘mediastinoscoped’ yesterday wants to go home.”

“Sure, but how is he?”

“Just fine, but he feels a little cold coming on and would feel better at home. Oh! by the way, his neck is kind of sore and crinkly. Do you think he needs a prescription for antibiotics before he goes?”

Inaudible response.

Never underestimate the risk in this type of patient. They need a little operation for diagnostic biopsy or palliative therapy, but their disease can't be cured surgically. Don't give up too easily. Thoracostomy drainage, antibiotics, nutrition and proximal diversion and gastrostomy may salvage the inoperable or unfixable patient. This is worth the effort especially so if there is other effective ancillary therapy for the underlying disease, like my lymphoma disaster above.

Palliative attempts to dilate, stent or laser ablate inoperable or non-resectable carcinomas should have been discussed with the patient and family prior to the procedure. The instrumental perforation rate is in the region of 10%, and it won't be

long before the surgeon is confronted with this problem. If you have already dilated it and gotten into the distal esophagus put in a stent, and count yourself lucky. The patient still has a chance for palliation if the antibiotics, nasogastric suction and nothing-by-mouth are successful. Otherwise morphine may be your only choice.

Summary

- Have a high index of suspicion for perforation, especially following instrumentation
- Investigate and manage aggressively
- Be aware of esophageal co-morbidity
- Preserve the normal esophagus
- Close and patch perforations
- Drain widely
- Resect, if the gullet is very diseased (cancer, long strictures, burns)

“When it [occurs] it can be recognized but it cannot be remedied by the medical profession.” (Herman Boerhaave, 1668–1738)

Editorial Comment

Some authorities believe that the time factor is unimportant. This is not necessarily to disagree with Dr Horan since he observes that the important issue is to tailor the procedure to the state of the gullet at the time of surgery. The time interval may obviously have some indirect bearing on this. We wish to quote another expert in this field: Dr. J. David Richardson of Louisville as recently published in the book *Source Control*¹.

- I really do not think that the *time of perforation* should enter into treatment decisions to any significant extent. Generally, we try to treat the patients in a similar fashion regardless of the time that they are seen after esophageal perforation.
- If the *esophagus is presumably normal* prior to the insult (such as with Boerhaave’s syndrome), preservation of the esophagus should be the primary goal with attempted closure of the esophagus.

¹ Richardson JD (2002) In: Schein M, Marshall J (eds) *Source control: a guide to the management of surgical infections*. Springer, Berlin Heidelberg New York, Chap 20, p 197.

- If the *underlying disease* is cancer and an iatrogenic perforation has occurred during its diagnosis or treatment, then the patient is best treated by esophagectomy and immediate reconstruction in my experience
- I believe *non-operative treatment* must be reserved for relatively few patients and should only be done in a very narrow set of circumstances. If contrast goes beyond the wall of the esophagus, it is my opinion that the patient should have operation and treatment of that problem – even if the contrast drains back into the esophagus from a cavity. Granted, some patients may be able to heal such a perforation non-operatively, but I am aware of several disasters with patient deaths where this strategy was tried and subsequently failed. I have also observed significant scarring at the area of the healed perforation. Therefore, I reserve non-operative treatment only for “micro-perforations” in which there may be some small tear observed in the muscle itself, but the contrast does not actually escape the confines of the esophagus.
- I believe that an attempt should be made to close *every perforation*.
- In my opinion, esophageal diversion should be reserved only for those patients who are almost certainly going to die unless diversion is done.

The only diaphragmatic pathology of interest to the emergency abdominal surgeon is the diaphragmatic hernia through which a single or multiple abdominal structures may migrate into the thorax and become incarcerated or strangulated. These may occur in three different settings, each of which however shares most of the same clinical features.

Diaphragmatic Hernia

Rupture of the Diaphragm due to Blunt or Penetrating Trauma

Here the hernia may become symptomatic acutely, immediately after the injury, or may present many years later – in a patient who has almost forgotten the trivial car accident 14 years ago. Read about the diagnosis and treatment of acute traumatic hernia in ◉ Chaps. 34 and 35. Late complications are diagnosed and managed along the lines described below for the non-traumatic diaphragmatic hernia.

Congenital Diaphragmatic Hernia

These very rare entities are either the *Bochdalek* hernia (posterolateral defect in the trigonum lumbocostale) or *Morgagni* hernia (just posterior to the xyphoid at the foramen Morgagni or the trigonum sternocostale), or a defect of the tendinous center of the left diaphragm, or the paraesophageal hernia. Left-sided defects more commonly become symptomatic because the liver seals those of the right side. Most congenital hernias are symptomatic and require operative treatment during the first hours of life due to compression of lungs and mediastinal structures. This can easily be accomplished from an abdominal incision by manual reposition (there are no adhesions between thoracic structures and abdominal viscera in these cases) and direct closure of the defect. If several organs are transposed intra-thoracically, the

reposition should follow the order stomach first, small bowel next, then large bowel, and finally parenchymal organs such as the spleen.

If there is no overt herniation during the fetus's development, the newborn may appear normal but may develop an acute herniation anytime later during his life. It then would present like any acquired diaphragmatic hernia, with the final diagnosis established at operation when the exact localization of the defect is revealed.

Acquired Diaphragmatic Hernia

In clinical practice, only two different entities have to be considered in this context: the herniation through a traumatic or preformed defect of the tendinous part of the left diaphragm and the paraesophageal hernia.

— **Left diaphragmatic hernia.** It has been stated commonly that older post-traumatic hernia should be approached via a thoracotomy and non-traumatic hernia by laparotomy. Indeed, the presence of a peritoneal envelope generally simplifies reposition by gentle traction from below, whereas perforation or rupture of the diaphragm often includes a tear in the peritoneal lining, thus leading to dense adhesions between thoracic and herniated abdominal structures. However, in the individual case, the etiology is often not clear and the presence or absence of a peritoneal hernia sac is difficult to predict preoperatively. Therefore the operative strategy often is influenced by probability and personal experience. It has to be stressed, however, that a posterolateral thoracotomy in the seventh intracostal space always allows for careful dissection of herniated organs and exploration of the sub-diaphragmatic space whereas the abdominal approach may prove more difficult and hazardous. If, irrespective of the approach, a small hernia ring has to be enlarged, the radial ramifications of the phrenic nerve have to be respected.

— **Paraesophageal hernia.** Here the gastroesophageal junction lies inside the abdomen anchored by the phrenoesophageal membrane (non-sliding hernia!) and the herniation – most commonly of the stomach – develops through the enlarged esophageal hiatus and a defect in the phrenoesophageal membrane alongside the esophagus. The fundus of the stomach may roll up and down intermittently, producing no or only “subacute” symptoms but occasionally a larger portion or even the whole of the stomach may herniate into the chest producing the so-called intrathoracic gastric volvulus (the “upside-down stomach”, or giant type II hiatal hernia). Common complications include gastric strangulation with infarction, necrosis and perforation, mucosal bleeding, or acute intrathoracic dilatation causing compression of other intrathoracic structures.

Gastric Volvulus

Gastric volvulus is defined as an abnormal rotation of the stomach of at least 180 degrees, creating a closed loop obstruction. According to the axis around which the stomach rotates, volvulus of the stomach may be **organoaxial** or **mesenteroaxial**, or a combination of both.

In **organoaxial volvulus** – which is the more common variant – the stomach rotates around an axis that connects the gastroesophageal junction and the pylorus. In this situation the stomach flips up into the chest with the greater curvature – dragging with it the omentum – coming to lie at the top; this kinks the esophagogastric junction as well as the distal stomach – producing in between a “closed loop gastric obstruction”. A **mesenteroaxial volvulus** (the less common variant) occurs around the axis that runs from the center of the greater curvature of the stomach to the gastric angulus. Gastric volvulus can occur at any age and with equal frequency in both men and women and has been reported in neonates and infants.

Clinical features

Acute gastric volvulus may develop against a background of intermittent non-specific dyspepsia attributed to the known presence of a paraesophageal hernia but usually it presents acutely “out of the blue.” Precipitating events may be a heavy meal or any event that increases intra-abdominal pressure, such as postoperative ileus, pregnancy or parturition.

The abdomen is relatively innocent with little epigastric pain and no abdominal findings on examination. There is more pain substernally or in the chest and the compression of the left lung by the herniated stomach (or other viscera) may result in acute respiratory distress. The shift of mediastinal structures to the right may result in cardiovascular instability while kinking of the gastroesophageal junction may produce retching. **The diagnostic triad described by Moritz Borchardt (1868–1948) includes epigastric/substernal pain, retching without vomiting, and the inability to pass a nasogastric tube.**

Traditionally acute gastric volvulus was diagnosed on a chest X-ray showing a retrocardiac air bubble or a large fluid level in the chest (◉ Fig. 15.1). A contrast study, showing obstruction of the stomach at the site of the volvulus, would have then confirmed the diagnosis. Currently, however, a CT scan can offer an immediate diagnosis with all anatomical details (see ◉ Figs. 15.2 and 15.3).




Fig. 15.1. "What is your stomach doing in the chest?"

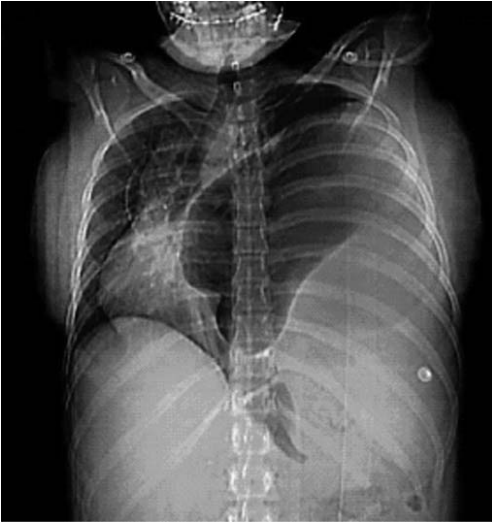

Fig. 15.2. Scout film of the CT scan showing a distended stomach occupying the left hemithorax with gross shift of mediastinum to the right

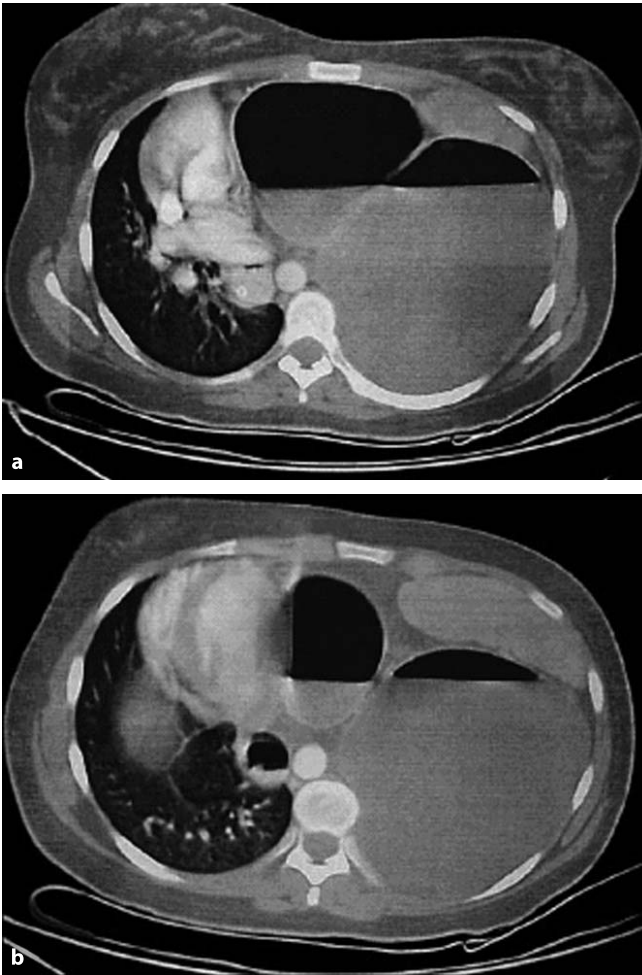


Fig. 15.3 a, b. Axial CT scan through the lower thorax. **a** Air fluid level in a distended stomach with shift of the heart to the right. The “bubble” on the *right* represents the gastric antrum. Note the nasogastric tube in the distal esophagus to the right of aorta. **b** A lower cut with the spleen visible on the *left*. The *left bubble* represents the gastric fundus. Note the “transition line” between the two “bubbles” representing the site of the volvulus

Management

Although emergency room staff tend initially to eyeball these patients and label them as suffering from “respiratory failure” or myocardial infarction, a prompt chest X-ray will suggest the diagnosis and promote further aggressive imaging studies. **The presence of the stomach (and/or other viscera) in the chest is a dire surgical emergency because of the unpredictability of the situation, the patient may appear well but the stomach may be rapidly becoming necrotic!** On the other hand, of course, an asymptomatic upside-down stomach may coincide with other intra-thoracic emergencies.

The treatment of acute gastric volvulus is surgical, consisting of a laparotomy, reduction of the volvulus, and assessment of gastric viability. The vast majority of acute diaphragmatic hernias can be reduced through the abdomen and very rarely is there a need to add a thoracotomy. **Reduction of the herniated viscera may be aided by two maneuvers.** Inserting a wide tube through the diaphragmatic defect abolishes the negative, “sucking” thoracic pressure and the nasogastric tube may be manipulated into the distended stomach to reduce its size. When the latter is not successful a decompressive gastrotomy is necessary before the stomach can be reduced into the abdomen. This should be performed carefully in order not to contaminate the thoracic cavity – an event that often leads to postoperative empyema.

After the hernia is reduced the hernial sac is excised and the diaphragmatic defect is closed with interrupted sutures. A very large defect may need to be patched with a synthetic prosthesis although this is not advised in the presence of contamination. Finally, some experts would recommend a tube gastrostomy – well-sutured to the anterior abdominal wall – to decompress the stomach and prevent recurrence of the volvulus. Others have recommended gastropexy – suturing of the stomach to the abdominal wall. The addition of an anti-reflux procedure such as fundoplication is controversial – and most probably inadvisable – in such emergency situations when it is unknown whether the patient has also a sliding hernia and gastroesophageal reflux.

When the stomach is found to be non-viable, gangrenous portions are resected by partial or total gastrectomy as required. In the moribund patient who needs total gastrectomy it may be safer to postpone the reconstruction, insert a tube into the distal esophagus, close the duodenal stump and place a tube jejunostomy distal to the level of the eventual planned entero-entero component of the Roux-en-Y loop jejunoesophagostomy which will be performed once the patient is stabilized and ready for such an intervention.

In selected hemodynamically stable patients, laparoscopic reduction and detorsion of the stomach, followed by endoscopic gastropexy or fundoplication have been reported possible. The finding of gastric necrosis would call for immediate conversion to an open approach.

Upper Gastrointestinal Hemorrhage (and Portal Hypertension)

MOSHE SCHEIN

“If anyone should consider removing half of my good stomach to cure a small ulcer in my duodenum, I would run faster than he.” (Charles H. Mayo, 1861–1939)

*“About gastrectomy for duodenal ulcer: in this operation... a segment of an essentially normal stomach is removed to treat the disease next door in the duodenum. It is like taking out the engine to decrease noise in the gear box.”
(Francis D. Moore, 1913–2001)*

During our residencies in the 1980s not a week passed without a few operations for bleeding duodenal or gastric ulcers. Emergency gastrectomies, antrectomies, truncal vagotomies, and highly selective vagotomies were our daily bread and butter. But gradually things started to change: first appeared the H₂ antagonists, followed by the proton pump inhibitors, and then the anti-*Helicobacter* therapy. In addition, novel methods of achieving trans-endoscopic hemostasis of bleeding ulcers emerged. As a result, at least where we practice, operations for upper gastrointestinal hemorrhage (UGI-H) have become a rarity and our approach to them has been modified. However, if you work somewhere in the so-called developing world, where modern anti-ulcer medications are not freely available, you may be exposed still to the old pattern of peptic ulcer disease and the traditional methods of dealing with it.

In all likelihood you are becoming less and less familiar and de-skilled in the operative management of UGI-H. Therefore, you need to listen to us – ☺...

The Problem

UGI-H implies a source of bleeding **proximal to the ligament of Treitz**. Although textbooks list multiple causes, the vast majority of patients bleed from a chronic *duodenal* (DU) or *gastric* ulcer (GU), complications of portal hypertension (*esophageal varices* or *hypertensive gastropathy*; acute complications of portal hypertension are discussed at the end of this chapter), or *acute gastric mucosal lesions* (e.g., stress ulcers, erosive gastritis and other terms that mean more or less the same). The latter are usually due to ingestion of analgesics and/or alcohol (“aspirin for the hangover”). With the routine use of anti-ulcer prophylaxis in hospitalized “stressed” patients, significant UGI-H from mucosal lesions is now rare. In fact, hemorrhage in stressed patients often originates from re-activated chronic

peptic ulcers. The mixture of etiologies in your hospital depends on local social habits and the sort of population you work with.

Presentation

Patients present either with **hematemesis** (vomiting fresh blood), **melanemesis** (vomiting altered “coffee-ground”) or **melena** (passage of black stool per rectum). **Hematochezia** (passage of fresh or altered non-black blood per rectum) usually originates from a source below the ligament of Treitz. Nevertheless, with massive UGI-H and rapid intestinal transit, unaltered blood may appear in the rectum.

Remember:

- Melena is black, sticky and very smelly
- Maroon feces are not melena
- Red feces are not UGI bleeding
- Black blood per rectum always means UGI bleeding
- Fresh, red blood per rectum in a hemodynamically stable patient means that the source is NOT in the UGI tract
- Any type of blood – fresh or old, vomited or retrieved through the nasogastric tube – means that the source is in the UGI tract

You do not need pan-endoscopy to diagnose UGI-H – contrary to the gastroenterologists’ credo. A finger, a nasogastric tube and set of eyes are as good.

Key Issue: Is the Hemorrhage “Serious”?

This is a key issue because the “seriousness” of hemorrhage determines your diagnostic-therapeutic steps and the patient’s outcome. In general, the larger the bleeding vessel, the more “serious” the hemorrhage. The more “serious” the hemorrhage, the less likely it is to stop without an intervention, and the more likely to recur after it has stopped. As with almost any acute medical or surgical condition, the affected patients can be classified into three groups. The obviously “serious” and obviously “not serious” at both extremes, and the “potentially serious” group in the middle. The “intermediate” group is always the most problematic in terms of diagnosis and selection of therapy but, at the same time, includes those patients in whom your correct management can improve outcome. Whatever the condition, the mildly ill patient should do well and the very sick one may die in spite your efforts. Your management has most to offer in the moderately ill.

Stratification

Massive bleeding from a large vessel requires your immediate attention and intervention. A small ooze from a tiny vessel is usually self-limiting and of minor significance at least for the moment; you can investigate it electively. For most patients however, seeing any quantity of blood emerging from any bodily orifice is alarming!

When Should You Be Alarmed?

The literature contains various formulas, usually based on hemodynamic parameters and the volume of blood transfusions required, to distinguish between “massive” versus “non-massive” UGI-H. We suggest, however, that you use your common sense and consider the clinical paradigm consisting of the following:

- Was the vomited blood (or the aspirate in the nasogastric tube) fresh or “coffee ground”?
- Were the rectal contents, fresh, juicy melena, or old dry melena?
- Was, or is, the patient hemodynamically compromised?
- Is there laboratory evidence of severe bleeding (hemoglobin/hematocrit)?
- Is the patient over 60 years of age? *Bleeding in elderly patients should be considered “more serious”* because they are less likely to withstand a prolonged hemorrhage. [We find the APACHE II scoring system (p. 57) useful in this situation as it takes account of the severity of the bleeding, any acute physiological compromise, age and comorbidity.]

These considerations should place your patients somewhere on the large spectrum of UGI-H “seriousness”. At one extreme, the patient presenting in shock, with fresh blood pouring from his stomach, belongs to the “**serious**” group (group I); at the other, the stable patient, with a little coffee ground and old, hard melena is definitively “**not serious**” (group III). Many patients, however, belong to the “**potentially serious**” (group II); the problem here is to distinguish between those who continue to ooze, or will re-bleed, and those who have stopped bleeding and whose chance of re-bleeding is low. This distinction requires active observation and endoscopy.

Approach

Check vital signs. Aggressive management of hypovolemic shock is the first priority. Do not over transfuse, as there is evidence that excessive blood product administration exacerbates bleeding and results in a higher incidence of re-bleeding.



Fig. 16.1. “This is a ‘serious’ UGI hemorrhage”

- **With resuscitation underway, take a history.** Previous peptic ulceration? Dyspepsia? Anti-ulcer medications? (Remember, bleeding patients do not have pain because blood is alkaline and serves as an anti-acid). Recent consumption of analgesics or alcohol? Severe vomiting or retching (Mallory-Weiss)? Chronic liver disease and/or varices? Nose bleed (swallowed blood)? Coagulopathy? Amount of blood vomited or passed per rectum (extremely inaccurate)? Full medical history (operative risk factors)?
- **Pass a large bore nasogastric tube,** flush the stomach with 50 ml of water, and aspirate: fresh blood indicates active or a very recent hemorrhage; coffee ground – recent bleeding which has stopped; clean aspirate or bile – no recent hemorrhage. **Note:** very rarely, a bleeding DU is associated with pyloric spasm with no blood refluxing into the stomach; bile-stained aspirate excludes such a possibility.
- **Perform a rectal examination:** fresh blood or juicy soft melena indicates active or very recent bleeding while dry and solid melena signifies a non-recent UGI-H. (🔗 Fig. 16.1).

How to proceed?

Now, with all the above information in mind you can classify the patients into one of the three groups (🔗 Table 16.1).

Table 16.1. Stratification and management of patients with upper gastrointestinal hemorrhage

	Group I Serious	Group II Potentially serious	Group III Not serious
Vomiting	Fresh blood	Coffee ground or fresh	Nothing/coffee ground
Per rectum	Fresh melena/ blood	Fresh melena	Old melena
Hemodynamically	Compromised	Stable	Stable
Hemoglobin/ hematocrit	<9/27		>9/27
Approach	Endoscopy now	Endoscopy soon	Endoscopy tomorrow
Prognosis	Requires hemostasis	Variable	Self limiting

The “non-serious bleeder” (group III). These patients have suffered a minor hemorrhage, which has stopped. Do not rush to endoscopy in the middle of the night. Semi-elective investigation suffices, and is more accurate and safer. Note that a very low hematocrit/hemoglobin in patients belonging to this group results from a chronic or intermittent ooze. The very anemic patient will tolerate endoscopy better after his general condition is improved. These patients do not require an emergency operation and therefore they won't be discussed further.

The “serious” bleeders (group I). In a minority of patients belonging to this group fresh blood is pouring torrentially from the stomach; they are virtually exsanguinating. You have to move fast. Esophageal or gastric varices often bleed this way – like an open tap. In such cases a previous history of portal hypertension or clinical stigmata of chronic liver disease often coexist, suggesting the diagnosis. Remember: **you do not want to operate on varices** (see the end of this chapter).

In any event, you should transfer the exsanguinating patient to a critical care facility or the operating room. **Intubate and sedate him/her to facilitate gastric lavage and subsequent endoscopy, and, most importantly, to reduce the risk of aspiration of the gastric contents in the shocked, obtunded, bleeding patient.** You should attempt endoscopy because, even if gastroduodenal visualization is totally obscured by blood, fresh bleeding from esophageal varices, (usually at 40 cm from the teeth – the gastroesophageal junction) can be always detected, indicating a subsequent non-operative approach. In the absence of varices proceed to surgery.

The “serious” patients who are not exsanguinating should undergo an emergency endoscopy (as discussed below for group II).

The “potentially serious” bleeder (group II). Perform an emergency endoscopy.

Emergency endoscopy for UGI-H

This should be done only after you have resuscitated the patient and are in a controlled environment. Endoscopy induces hypoxemia and vagal stimulation; we have seen it cause cardiac arrest in unstable and poorly oxygenated patients. (In addition, closed cardiac massage on a patient with a stomach ballooned with blood may lead to gastric rupture). *Ideally, you – the surgeon – should be the one who performs the procedure.* Unfortunately, because of political and fiscal considerations, in many hospitals you are denied this access to endoscopy. If this is the case – at least be present at the endoscopy to visualize the findings at first hand. Do not entirely trust the gastroenterologist; he’ll be going home soon, leaving you with the patient and any problems resulting from a poorly identified bleeding site.

To improve the diagnostic yield the stomach should be prepared for endoscopy. Pass the largest nasogastric tube you can find and flush the stomach rapidly and repeatedly, aspirating as many clots as possible. A common ritual is to use ice-cold saline (with or without a vasoconstricting agent) for this purpose. None of these methods has been proven to be *therapeutic*. Tap water, is just as good, much cheaper, and does not aggravate hypothermia.

At endoscopy you attempt to visualize the source of bleeding, which may be **esophageal (varices, Mallory-Weiss), gastric (chronic GU or superficial lesions), duodenal (DU), solitary (chronic ulcer) or multiple (erosive gastritis)**. Look also for the following prognostic “stigmata”:

- Active bleeding from lesion/s
- A “visible vessel” standing up in the ulcer’s base, indicating that the bleeding originated from a large vessel and that there is a high chance of further hemorrhage
- A clot adherent to the ulcer’s base, signifying a recent hemorrhage

You may like to classify the findings as presented in [Table 16.2](#).

Endoscopic Management

Having visualized the lesion you should now treat it endoscopically in order to achieve hemostasis and to prevent further hemorrhage. In broad terms, endo-

Table 16.2. Suggested classification of upper gastrointestinal hemorrhage

No evidence of recent bleeding	Evidence of recent bleeding	Active bleeding
Clean base	Flat spot Adherent clot Visible vessel	Oozing Spurting

scopic therapy has a better chance of success in shallow lesions, which contain small vessels. You should also attempt, however, endoscopic hemostasis in deeper, large vessel-containing lesions, with the aim of achieving at least temporary cessation of bleeding. This will permit a safer, elective, definitive operation to be performed in a better-prepared patient. The specific method of endoscopic hemostasis, be it a “hot” probe or injection with adrenaline or a sclerosant, depends on local skills and facilities, and is outside the scope of these pages.

Post-endoscopy Decision Making

- At the end of endoscopy you are left with the following categories of patients:
- **Actively bleeding:** failed endoscopic hemostasis. The source is usually a chronic ulcer and emergency operation is indicated.
 - **Bleeding (apparently) stopped:** chronic ulcer with a “visible vessel” or adherent clot visualized. The chances of further hemorrhage, usually within 48–72 hours, are substantial. Treat conservatively but *observe closely!*
 - **Bleeding stopped:** acute shallow lesion or chronic ulcer without the aforementioned “stigmata”. In these patients further hemorrhage is unlikely; treat conservatively and *relax*.

Conservative Treatment

The mainstay of conservative treatment comprises completion and maintenance of resuscitative measures and observation for further hemorrhage. Neither gastric lavage nor medications will change the acute course in the individual patient. The acid-reducing medications you administer may not reduce the incidence of early re-bleeding, and are prescribed for the healing of the ulcer in the long term. Obviously, correct coagulopathies if present. All you need to do is to sustain the patient’s organ systems, and watch for re-bleeding, which usually occurs within 48–72 hours and can be massive and lethal. Careful monitoring of vital signs,

observation of the number and character of melena stools and serial hematocrit measurements will detect episodes of further hemorrhage. A nasogastric tube on suction is often advocated to provide early warning. In our experience, however, it is often blocked by clots, is of great discomfort to the patient and therefore worse than useless. If, nonetheless, you choose to use it, flush it frequently.

Indications for Operation

We do not suggest that you use cookbook recipes or formulas, as they are of little help in the individual patient. Instead, use clinical judgment. That the exsanguinating patient, and the one who continues to bleed after endoscopic hemostasis fails, needs an emergency operation is clear and has been discussed above. Regarding those in whom the hemorrhage stopped, with or without endoscopic hemostasis, the main indication for operation is *recurrent hemorrhage*. Factors, which may or may not modify your decision to operate include the magnitude of recurrent hemorrhage, its source, and the age and general condition of the patient.

In general terms, **recurrent hemorrhage is an ominous sign**, meaning that bleeding will continue or, if stopped again, may well recur!

- If hemodynamically significant or originating from a chronic ulcer *you have to operate!*
- If re-bleeding seems of mild or moderate magnitude and stems from a superficial lesion you may elect to continue conservative treatment or re-treat endoscopically.

But, whatever you do remember that old and chronically ill patients poorly tolerate repeated episodes of bleeding; do not mess around with them.

Operative Management

Repeat Endoscopy

It is crucial that you know from where in the UGI the patient is bleeding. If the initial endoscopy was not done by you, or in your presence, *do it again*. In an anesthetized patient it will not take you more than 5 minutes to insert and remove the endoscope. Do not trust the scribbled, 2-day-old endoscopy report that the “source of hemorrhage appeared to be in the duodenum”. This could lead you to start with an unnecessary duodenotomy while the source lies high in the stomach.

Exploration

An upper midline incision, supplemented with a para-xyphoid extension and forceful upward sternal retraction, lets you deal with anything in the foregut. In obese patients with a wide costal angle, however, a transverse-chevron-type incision make take a few more minutes but affords a more comfortable exposure. In addition, *a generous reverse-Trendelenburg tilt of the patient will bring the upper stomach almost into your nose.*

Start by searching for external visual or palpable features of chronic ulceration. The latter are invariably associated with serosal inflammatory changes. Look for evidence of chronic ulcers from the duodenum to the gastric cardia. Duodenal “Kocherization” [Theodor Kocher is perhaps the only surgeon in history to have his name used as a verb] will be necessary to reveal the sporadic postbulbar ulcer in the second portion of the duodenum. Occasionally, a posterior or lesser curvature GU will become palpable only through the lesser sac. Acute superficial mucosal lesions are unfortunately not identifiable from the outside although a Mallory-Weiss lesion may be tattooed by bluish serosal staining at the gastroesophageal junction.

The finding of a chronic ulcer in accordance with the pre-operative endoscopic finding tells you where the trouble is; but what to do in the absence of any external evidence of pathology. You have a few options:

- Proceed according to the endoscopist’s findings – if you trust them ... but they will not always be correct
- Surgical exploration
- Intra-operative endoscopy

Intra-operative Endoscopy

Having endoscopically visualized, with your own eyes, an actively bleeding DU, you should not have any doubts. A doubtful endoscopic report, however, may promote a negative duodenotomy, extending it – piecemeal – proximally, until the acute high gastric lesion is found. All that was needed was a small high gastrotomy and suture ligation of the lesion; instead you are left with a very long, messy and unnecessary duodenogastrotomy to repair. To obviate such a mini-disaster we would unscrub for a moment and shove in an endoscope. Sometimes, when the stomach is distended with huge clots, we would place a purse-string suture at the anterior wall of the antrum, perform a small gastrotomy, and with a large sucker remove and irrigate all clots. An endoscope is then inserted through the gastrotomy with the purse-string tightened to allow gastric insufflation; this offers an excellent and controlled view of the stomach and duodenum. We call it “intra-operative retrograde gastroscopy”.

Philosophy of Surgical Management

A friend of ours, Asher Hirshberg, aptly stated that “*In the era of Helicobacter pylori, doing a gastrectomy for peptic ulcer is like doing a lobectomy for pneumonia*”. Clearly, where potent anti-ulcer drugs are available elective ulcer surgery has disappeared and definitive anti-ulcer procedures during emergency surgery for complications of ulcer are disappearing as well. Why do a *surgical vagotomy* when proton pump inhibitors offer a “*medical vagotomy*”?

The general philosophy is that saving lives, i.e. stopping the bleeding, comes first. This is the main consideration in the severely ill patients. In the less compromised subjects, *the secondary issue of long-term cure of disease may be considered.* But now, when such a goal can be achieved by medical means, the role of definitive anti-ulcer procedures is limited and should be considered only in well-selected patients: those expected to be not compliant with medications and in situations where such medications are not readily available.

Our current operative approach in the vast majority of cases is thus limited to *hemostasis only*. In a few selected and good risk (e.g. APACHE II <10) patients we may consider a definitive anti-ulcer procedure *tailored* to the patient and the type of ulcer.

Specific Sources of Bleeding

Duodenal Ulcer (DU)

The source of bleeding is always at the base of a posterior ulcer. Hemostasis is accomplished through an anterior duodenotomy, underrunning the base (and bleeding vessel) with two or three (2-0 monofilament) deeply placed sutures – each placed on a different axis. When bleeding is active successful ligation of the vessel will be evident; in its absence you may want to abrade the ulcer’s base, dislodging the clot and inducing bleeding. Otherwise, just underrun the base, deeply, and in a few directions. *The theoretical danger of underrunning a nearby common bile duct has been mentioned but we are unaware of even a single report of such a case.*

After achieving hemostasis you are left with a few options. In the “compromised” patient – and most such patients are compromised – all you want is to stop the bleeding, close the duodenotomy without constricting the lumen, and get out. The eventual cure of the ulcer is left to acid- and/or Helicobacter-reducing drugs.

If the patient is in good shape and requires a definitive procedure you may choose to prolong the operation by 30 minutes, adding a truncal vagotomy (TV), extending the duodenotomy across the pylorus, and closing it to form a Heineke-

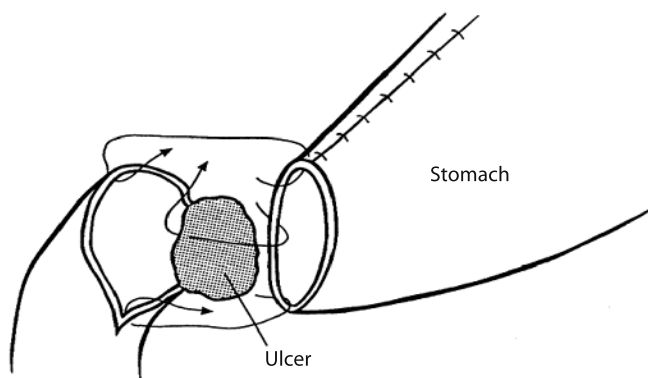


Fig. 16.2. Gastroduodenostomy: note that the posterior aspect of the anastomosis is performed with interrupted sutures, taking “big bites” of the duodenum (which is adherent to the pancreas) – well into the scar tissue at the base of the (now excluded) ulcer

Mikulicz pyloroplasty. In a fit and stable patient, only 10 years ago, we would close the duodenotomy and perform a highly selective vagotomy (HSV), adding an hour or so to the procedure. But today we do not find suitable candidates for this procedure.

Local hemostasis can be achieved even in the base of giant ulcers or when the duodenum is extremely inflamed or scarred. When simple closure of the duodenotomy appears to compromise the lumen or pyloroplasty is deemed otherwise unsatisfactory, just close the duodenum and do a posterior gastroenterostomy (GE) – alone or added to the TV or HSV. The proponents of antrectomy plus vagotomy for bleeding DUs claim an increased incidence of re-hemorrhage when gastric resection is avoided. In over 100 emergency operations for bleeding DUs this has not been our experience and we believe that there is no sense in removing a healthy stomach, producing gastric cripples, for a benign duodenal disease – which in any case can be subsequently cured with medications.

When, however, the duodenum is virtually replaced by a huge, giant ulcer involving the anterior and posterior wall of the duodenal cap (“kissing ulcer”) one essentially is forced to perform an **antrectomy** (with a truncal vagotomy). In this situation, to avoid creating a “difficult-to-close” duodenal stump we prefer a Billroth I gastroduodenostomy (◊ Fig. 16.2).

Postbulbar DU

For unknown reasons this kind of ulcer has almost disappeared from the Western World. Although extensive resective procedures (including emergency Whipple’s) are mentioned in the old literature, all you need to do is to mobilize the

duodenum, underrun the ulcer through a duodenotomy, and – perhaps – add a TV and GE, or HSV.

Gastric Ulcer (GU)

Traditionally, for most surgeons, a bleeding GU mandated a partial gastrectomy. Gastric resection is indeed effective in controlling the hemorrhage, but in most instances represents a superfluous ritual. For acute-superficial ulcers all that is required is simple underrunning of the lesion through a small gastrotomy. In fact, in most patients who bleed from a chronic GU, simple underrunning of the ulcer from within, through a gastrotomy, suffices. In large chronic ulcers we first underrun the bleeding point with an absorbable suture; with a heavy absorbable suture we then obliterate the ulcer's base. UGI-H from a malignant ulcer very rarely requires an emergency operation. We would, however, take tissue from the ulcer's edges for histology. Partial gastrectomy becomes necessary only in cases of a giant GU on the lesser curvature with direct involvement of the left gastric or splenic arteries.

Definitive Procedure?

After hemostasis, in selected patients, as discussed above, a definitive ulcer procedure may be considered. Chronic GU is not “one disease” to be managed by a ritual gastrectomy; instead it comprises different types, which should be managed selectively. But frankly, in our part of the world this has become useless information; perhaps it is still valuable in yours?

- **Type I** is the classical lesser curvature GU. Billroth I partial gastrectomy is the textbook recommendation. An HSV (from the ulcer proximally) plus the excision of the ulcer (from inside the stomach) is the alternative that we would recommend instead.
- **Type II** is a pre-pyloric ulcer. Though antrectomy plus vagotomy are popular for this “hybrid” – between DU and GU – ulcer, excellent results are achieved with HSV plus pyloroplasty. This is what we would do.
- **Type III** is a combination of a GU and a DU; it should be treated as type II.
- **Type IV** implies a high, juxta-cardial lesser curvature GU. Prior to the days of effective anti-ulcer medication, partial gastrectomy – distal to the ulcer – was the procedure of choice. Since the entire lesser curvature may be obliterated, HSV is usually impossible – making TV plus a drainage procedure a reasonable alternative.
- **“Riding” GU** is a variant of a high GU associated with sliding hiatal hernia, produced by injury to the herniated stomach, “riding” against the diaphragm.

Surgical therapy involves reduction of the stomach by pinching the ulcer away from the adherent diaphragm, local hemostasis, and crural repair. This may be easier said than done since occasionally the huge riding ulcer adheres to mediastinal structures and may require major resective surgery.

Stomal Ulcer

This ulcer develops on the jejunal side of the gastrojejunal anastomosis, following a previous vagotomy and GE or Billroth II gastrectomy. Because stomal ulcers almost never involve a large blood vessel, hemorrhage is usually self-limited or amenable to endoscopic therapy. Remember also that all stomal ulcers will heal on modern acid-suppressing medications. Persisting or recurrent hemorrhage, however, will force you, rarely, to operate. In the high risk patient do the minimum: through a small gastrotomy, perpendicular to the anastomosis, examine the stoma and ulcer; underrun the latter with a few deeply placed absorbable sutures; close the gastrotomy and put the patient on H₂ antagonists or proton pump inhibitors for life. In selected patients you can opt for a more definitive procedure. If the previous operation was a vagotomy plus GE, look for a missed vagal nerve or add an antrectomy. In the case of a previous Billroth II gastrectomy, add TV or consider a higher gastrectomy (do not forget to rule out Zollinger-Ellison syndrome later on). Remember: **hemorrhage from a stomal ulcer can be arrested with a simple surgical maneuver (underrunning); try to stay out of trouble by not escalating the emergency procedure into complicated reconstructive gastric surgery, which may kill your bleeding patient.**

Dieulafoy's Lesion

This small, solitary and difficult to diagnose gastric vascular malformation typically causes a recurrent "obscure" massive UGI-H. It is best managed by trans-gastric excision or underrunning.

Acute Superficial Mucosal Lesions

Due to effective anti-ulcer prophylaxis in critically ill patients you will be called to operate on such lesions only a few times in your surgical life. When massive hemorrhage necessitating an operation occurs, however, the involved stomach may look and behave like a blood-soaked and dripping sponge. Surgical options mentioned by the standard textbooks include TV and drainage or total gastrectomy.

The former is associated with a very high rate of re-bleeding and the latter with a prohibitive mortality rate. In this situation we advocate **gastric devascularization by ligating the two gastroepiploic, and left and right gastric arteries near the stomach's wall**. This relatively simple and well-tolerated procedure results in an immediate drying of the "gastric" sponge.

UGI-H from an Unknown Source

You won't encounter many of these having followed the above management plan, including – if necessary – the resort to intra-operative endoscopy. Angiography is an option, and an excuse exercised by those looking for a pretext to delay surgery. It is useless if performed when bleeding is not active.

Conclusions

Admit patients with UGI-H to your surgical service. Do not leave them to the internists who will call you just before the patient is almost dead. After resuscitation diagnose the source of hemorrhage and stage it. Give endoscopic treatment a chance but do not delay an indicated operation. **At surgery the goal is to stop the bleeding – remembering that most ulcers can be cured later on by medication. Life comes first**. Perhaps this rhyme will help you to remember:

When the blood is fresh and pink and the patient is old
It is time to be active and bold.
When the patient is young and the blood is dark and old
You can relax and put your knife on hold.

Esophageal Varices, Portal Hypertension and Cirrhosis

Luckily, abdominal surgery plays almost no role in the modern management of bleeding from esophageal or gastric varices. Luckily – because some of us still remember the old days when these patients were subjected to all sorts of emergency portocaval shunts or devascularization procedures – which were effective in arresting the hemorrhage but led to tremendous mortality from postoperative liver failure and its complications. (The operation was successful but the patient died). In this section we will briefly touch on the non-surgical approach to variceal bleeding and the cirrhotic patient in general.

Table 16.3. The Child-Pugh classification^a

	Score ^b		
	1	2	3
Bilirubin (mg%)	<2	2–3	>3
Albumin (g%)	>3.5	2.8–3.5	<2.8
Prothrombin time (s prolonged)	<4	4–6	>6
Encephalopathy	None	Mild	Marked
Ascites	None	Mild	Marked

^a Charles Gardner Child III (1908–1991) was a professor of Surgery at the University of Michigan. RNH Pugh published his classification in 1973 [Pugh et al. (1973) Transection of the oesophagus for bleeding oesophageal varices. *Br J Surg* 60:649–690].

^b The individual scores are summed and then grouped as:

— <7 = Child A

— 7–9 = Child B

— >9 = Child C

(A Child C classification forecasts a survival of less than 12 months)

Stratification

Remember that *anything* you plan to do in a cirrhotic patient, with or without varices, depends on his or her hepatic reserves, which are best assessed by the modified Child-Pugh classification presented in [Table 16.3](#).

Child A patients have good hepatic reserves. They will tolerate variceal bleeding and its management fairly well. They are also reasonable candidates for any indicated emergency abdominal procedures. Essentially, you can treat them as you treat non-cirrhotic patients. But bear in mind that the chronically diseased liver may decompensate when burdened with the metabolic consequences of severe surgical complications.

Child C patients (some call them “yellow balloons”) have no hepatic reserves whatsoever and in the absence of successful hepatic transplantation they are doomed to die within a year or so. Child C patients tolerate surgical procedures and their complications poorly. Consequently, operate on them only for life saving indications, in the absence of non-operative alternatives and expect very high mortality and morbidity – depending of course on the specific problem and the magnitude of the operation.

Child B patients fall in between groups A and C; do the minimum necessary and be very careful.

Bleeding Varices

Patients presenting with UGI-H from varices will usually provide a history of chronic liver disease or cirrhosis (alcoholic, viral) and/or previous episodes of bleeding. On examination, most of them will have features of portal hypertension and liver dysfunction listed in ◈ Fig. 16.3. The variceal source of the hemorrhage will be diagnosed or confirmed during the emergency endoscopy – not forgetting the cliché that one-third of UGI-H's in portal hypertension patients are not variceal but from other sources such as peptic ulcers. While *portal hypertensive gastropathy* can be a source for minor and chronic blood loss, it is probably not a cause for severe UGI-H. **It is a classic and unforgivable error to attribute bleeding in a cirrhotic patient to varices while overlooking the responsible DU.**

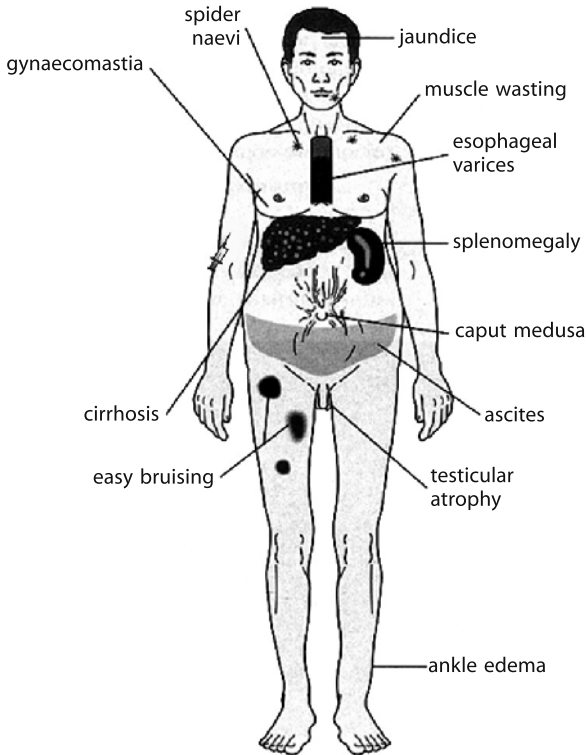


Fig. 16.3. Clinical features of cirrhosis

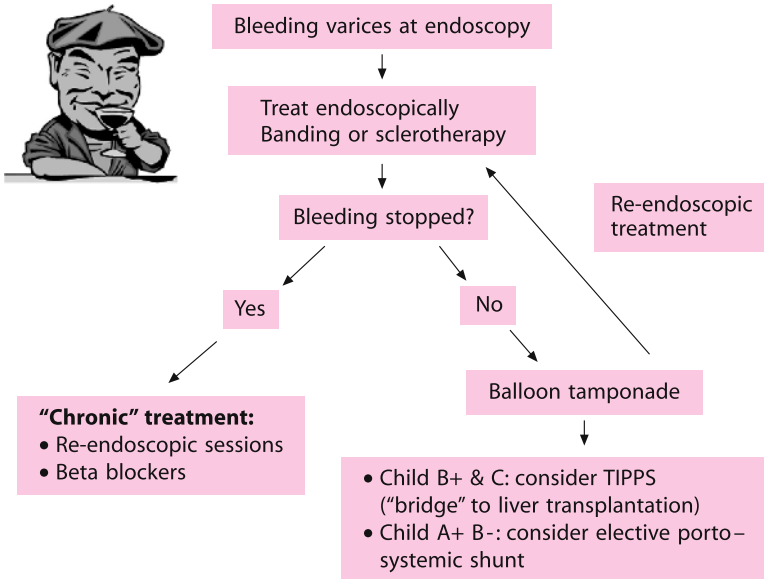


Fig. 16.4. Variceal bleeding: options in management. *TIPPS* Transjugular intrahepatic portal systemic shunt

How best to manage an episode of esophageal variceal hemorrhage depends on the local facilities and expertise in your hospital and the tertiary care available in your environment. The essential options of management are outlined in Fig. 16.4).

Summary

The surgeon's role in variceal hemorrhage is limited. Resuscitate, exclude non-variceal causes of hemorrhage, tamponade bleeding with a balloon tube and then send for help from the GI specialists!

Perforated Peptic Ulcer

MOSHE SCHEIN

- *There's a hole in my bucket...How should I mend it?*
- *Just patch it! (a folk song)*

“Every doctor, faced with a perforated ulcer of the stomach or intestine, must consider opening the abdomen, sewing up the hole, and averting a possible or actual inflammation by careful cleansing of the abdominal cavity.”
(Johan Mikulicz-Radecki, 1850–1905)

Thanks to effective, modern anti-ulcer drug management the incidence of perforated peptic ulcers has decreased drastically, but not everywhere. Perforated ulcers are still common in the socio-economically disadvantaged or stressed populations worldwide. Usually perforations develop against the background of chronic symptomatic ulceration but de novo presentation without previous history is not uncommon. In the Western World perforated duodenal ulcers (DU) are much more common than perforated gastric ulcers (GU), which are seen more in lower socio-economic groups.

Natural History

Classically, the abdominal pain caused by a peptic perforation develops very suddenly in the upper abdomen. Most patients can accurately time the dramatic onset of symptoms. The natural history of such an episode can be divided into three phases:

- **Chemical peritonitis/contamination.** Initially, the perforation leads to chemical peritonitis, with or without contamination with micro-organisms. (Note that the presence of acid sterilizes gastroduodenal contents; it is when gastric acid is reduced by treatment or disease (e.g. gastric cancer) that bacteria and fungi are present in the stomach and duodenum). Spillage of gastroduodenal contents is usually diffuse but may be localized in the upper abdomen by adhesions or the omentum. Spillage along the right gutter into the right lower quadrant, mimicking acute appendicitis, is mentioned in every textbook but almost never seen in clinical practice.
- **Intermediate stage.** After 6 to 12 hours many patients obtain some spontaneous relief of the pain. This is probably due to the dilution of the irritating gastroduodenal contents by the ensuing peritoneal exudate.
- **Intra-abdominal infection.** Should the patient escape the scalpel initially, after 12 to 24 hours intra-abdominal infection supervenes. The exact point in time in the individual patient when contaminating micro-organisms become invasive-infective,

is unknown. Therefore, you should consider any perforation operated upon with a delay of more than 12 hours as infection rather than contamination. This bears on your postoperative antibiotic therapy as discussed below. Neglected patients may present a few days after the perforation in septic shock. Shock in the earlier stages is very rare although quoted commonly by medical students, but when confronted with a combination of shock and abdominal pain think about ruptured aortic aneurysm, mesenteric ischemia or severe acute pancreatitis. Untreated perforation can lead eventually to an early “septic” death from peritonitis or the development of an intra-abdominal abscess.

Diagnosis

The vast majority of patients present with signs of diffuse or localized peritoneal irritation; most lie still, groaning, and have a board-like abdomen as in the textbook. Spontaneous “sealing off” of the perforation or localization of the spill or leakage into the lesser sac causes atypical and delayed presentation. We had a patient who re-perforated his duodenal ulcer a few years after receiving an omental patch. The second perforation was thus diverted backwards into the retroperitoneum – behind the pancreas, the left colon and into the scrotum – while the abdomen remained soft.

In a patient with an abrupt onset of upper abdominal pain and diffuse peritonitis the diagnosis is simple. It can be summarized in the following formulas:

Sudden onset peritonitis + free gas = perforated viscus

Sudden onset peritonitis + no free gas + normal amylase = perforated viscus

There is free gas under the diaphragm in about two-thirds of perforated patients. Remember, free gas is visualized better on upright chest X-ray than on plain abdominal radiographs (☛ Chaps. 4 and 5). If your patient can’t stand, or sit up, order a left lateral decubitus abdominal film. Free gas is diagnostic, although it is not always due to a perforated peptic ulcer. But so what? It signifies a perforated viscus, and a laparotomy is almost always indicated. But “almost always” means not “always”: **free gas without clinical peritonitis is NOT an absolute indication for an emergency laparotomy**. As mentioned in ☛ Chap. 4 there is a long list of “non-operative” conditions that may produce free intra-peritoneal gas. Free gas in a “soft” abdomen may also mean that the perforation has been spontaneously sealed and is amenable to non-operative therapy as discussed below.

In the absence of free air, acute pancreatitis – the “great simulator” – should be considered and excluded (☛ Chap. 18). Normal serum amylase levels support

a diagnosis of a perforation, while very elevated amylase levels in a “susceptible” patient (e.g., alcohol, gallstones) suggest acute pancreatitis. The “border line” patient with atypical presentation and marginal elevation of amylase remains a problem because perforated ulcer may cause hyperamylasemia. In the good old days, before imaging techniques replaced clinical skills, our decision to operate or observe would have depended on the whole clinical picture. Rarely, a gastrografen contrast study was performed to demonstrate or exclude leakage. Faced with such a patient today we would advise you to obtain a CT scan of the abdomen, looking for free gas, extraluminal gastrografen and free peritoneal fluid. CT is excellent at picking up minute amounts of free intraperitoneal gas and is thus a valuable tool in clarifying the diagnosis in patients with an ambiguous clinical picture.

Philosophy of Treatment

The **primary goal of treatment is to save the patient’s life by eliminating the source of infection and cleaning the abdominal cavity. The secondary goal is to cure, if possible, the ulcer diathesis.** The former goal may be achieved by simple closure of the ulcer; the latter requires a definitive ulcer operation. *When to do what?* Before telling you what to do we must answer a few other questions.

Who Are the Patients who Require a Definitive Procedure?

Twenty years ago the reply was simpler. The “law of thirds” maintained that after a simple closure of perforation one-third of the patients are cured permanently, another third would require long-term medical anti-ulcer therapy, and the last third would require definitive ulcer surgery because of intractability or further complications. This provided us with a rationale to add a definitive procedure in order to cure the ulcer in two-thirds of the patients. With the emergence of modern anti-ulcer agents we were told that definitive ulcer procedures are not necessary as all perforated patients could be maintained indefinitely and effectively on proper anti-ulcer drugs. Our counter-argument was then that an ulcer operation is more cost-effective than a life-long commitment to drugs; that patients often are not compliant with the latter, and, in fact perforate while taking anti-ulcer drugs. Now, with the availability of anti-*Helicobacter pylori* treatment of peptic ulcers we are told: “why do you want to add an anti-ulcer procedure? Close the perforation and give a course of anti-*Helicobacter* antibiotics – the ulcer will be cured and never recur”. This may be true, but in patients acutely operated for a perforated ulcer we do not know whether *Helicobacter* is or is not involved. Furthermore, the very patients who are susceptible to perforation also suffer from substandard access to medical care and

reduced compliance, both adversely affecting successful medical anti-ulcer therapies. Consequently, if the operation for a perforated ulcer can kill two birds using one bullet (especially if the environment around you cannot ensure optimal medical management and follow up of your patient) why not do it?

This appears initially to be a reasonable argument, but after a few moments' thought one realizes that it is obviously just the ravings of a committed peptic ulcer surgeon who laments the passing of interesting anti-ulcer surgery. Modern surgeons know that duodenal ulcers are due to acid hypersecretion and *H. pylori* infection and that elimination of this infection will cure the disease. Thus, definitive anti-ulcer surgery is nowadays indicated in only the most unusual of situations and should not even be considered in the routine perforation. [Paul Rogers, Co-editor].

Rebuttal: I agree with this comment in the Western World settings but there are places where follow-up and effective anti-ulcer therapy are not available. And there are patients who perforate while allegedly on such "effective" therapy and those whose ulcers are associated with non-steroidal anti-inflammatory drug intake. Thus, while I agree that the role of definitive surgery for perforated and bleeding (see ◊ Chap. 16) ulcers has drastically declined, surgeons still need to know how to do these procedures and when. [Moshe Schein]

In What Patients is a Definitive Procedure Safe?

Surely you do not want to embark on a lengthy definitive procedure in a critically ill and "septic" patient. Over the years we encountered surgeons who omitted a definitive procedure because of "severe contamination", often quoting a myth that vagotomy in a perforated patient may "spread the infection into the mediastinum". The Hong Kong group showed that when the following three factors are present an anti-ulcer procedure can be safely performed: blood pressure >90 mmHg, operation within 48 hours of perforation, and lack of associated medical illnesses. We found the APACHE II scoring system (p. 57) useful in this situation as patients with perforated ulcers with scores less than 11 can tolerate a definitive procedure of any magnitude. Conversely, in patients with higher APACHE II scores the simplest operation should be performed.

Operative Treatment: Simple Closure (◊ Fig. 17.1)

Classically, simple closure of the ulcer is best achieved by an omental Graham's patch also called *omentopexy*. A few "through-all-layers" interrupted sutures are placed through both edges of the perforation (transversely – not vertically – in order not to narrow the lumen), and are left untied; a pedicle of the greater omentum is created and flipped over the perforation; the sutures are then *gently* tied over the omentum in order *not to strangulate* it (◊ Fig. 17.2). At this stage the anesthetist may



Fig. 17.1. “How should we mend it?”

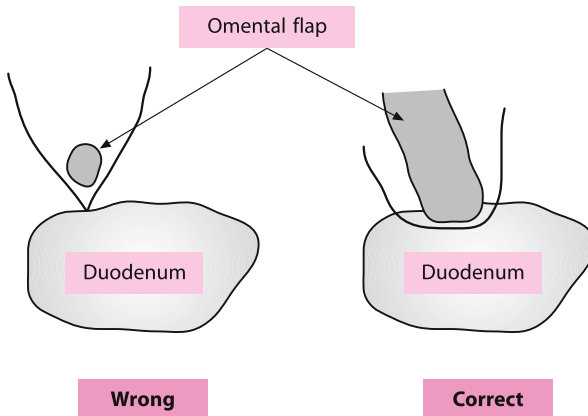


Fig. 17.2. Simple closure. Note the omental patch should “plug” the hole with the sutures tied over it. First suturing the hole and then sticking omentum over the repair is wrong

be asked to inject water through the nasogastric tube to ascertain that the patch is waterproof.

Not a few surgeons misunderstand this operation; they initially suture-close the perforation and only then *cover* the suture line with the omentum. However, the approximation of the edematous, friable edges of perforation can be troublesome. In all cases of postoperative duodenal fistula witnessed by us the simple suture-closure of perforated DU was the causative mechanism. **Remember, you do not stitch the perforation but plug it with viable omentum.**

Omentopexy can be easily performed for most perforated DUs. Rarely, a giant perforated DU creates a huge anterior bulbar-pyloric defect, which is not amenable to safe closure and thus mandates partial gastrectomy. Perforated GUs are usually larger than the duodenal ones. For those positioned on the greater curvature of the stomach, a wedge resection of the ulcer, hand sutured or stapled, may be easier and safer than omentopexy. For chronic and large lesser curvature ulcers, omentopexy is notoriously difficult and unsafe; partial gastrectomy may serve the patient better.

Operative Treatment: Definitive Procedure

Ideally, in emergency you should choose the anti-ulcer procedure with which you are most familiar in the elective situation. The problem is that today you and other young surgeons are deprived of experience with elective anti-ulcer operations. Based on our philosophy to avoid, if possible, a gastric resection for a benign

Table 17.1. Selection of procedures in perforated ulcers

Ulcer type	Textbook options		We recommend	
	Good risk	Poor risk	Good risk	Poor risk
Duodenal	Omentopexy ±TV+D or HSV or TV+A	Omentopexy	Omentopexy plus HSV	Omentopexy
Prepyloric	Omentopexy ±TV+D or TV+A	Omentopexy	Omentopexy plus HSV+D	Omentopexy
Gastric	Omentopexy or wedge excision or partial gastrectomy	Omentopexy or partial gastrectomy	Omentopexy plus HSV+D or partial gastrectomy	Omentopexy or partial gastrectomy

TV+D truncal vagotomy and drainage procedure; *TV+A* truncal vagotomy and antrectomy; *HSV* highly selective vagotomy; *HSV+D* highly selective vagotomy and drainage.

process, and on results of elective ulcer operations, we recommend an operative policy which tailors the definitive procedure to the specific ulcer (● Table 17.1). Whatever you do please remember that if your patient is “sick” and you are not a skilled gastroduodenal surgeon – forget about the definitive procedure. Just patch the hole and get out!

Special Problems

“Kissing” ulcers: any evidence of a preceding or co-existing UGI hemorrhage (e.g. finding of “coffee ground” or fresh blood in the nasogastric tube or at the perforation site or peritoneal cavity) suggests the presence of “kissing” ulcers – the anterior perforated, the posterior bleeding. Simple closure of the former, without hemostasis for the latter, could lead to a severe postoperative hemorrhage. In such circumstances enlarge the duodenal perforation into a duodenotomy and explore the inside of the duodenum. If posterior ulcer is found suture-transfix its base as described in ● Chap. 16.

Laparoscopic Management of Perforated Ulcers

Omentopexy and peritoneal toilet can be executed laparoscopically (● Chap. 49). A large experience has been accumulated in the treatment of perforated DUs with conflicting results. We suggest that laparoscopic procedure is a reasonable option in stable and well-resuscitated patients and when the perforation can be promptly and securely closed. Conversely, a prolonged pneumoperitoneum will be poorly tolerated in the high risk or severely “septic” patients. The addition of a laparoscopic anti-ulcer procedure could lengthen the operation beyond what is reasonable in an emergency situation.

Non-operative Management of Perforated Ulcers

A non-operative approach consisting of nil per mouth, nasogastric suction, systemic antibiotics, and acid secretion inhibitors, has been proven effective by a few enthusiastic groups. The *sine qua non* for success is the spontaneous sealing of the perforation by the omentum or other adjacent structures; if this occurs, a non-operative approach would be successful in the majority of cases.

Non-operative treatment may be of particular value for two types of patients: the “late presenter” and the “extremely sick”. The “late presenter” presents to you a day or more after the perforation occurred, with an already improving clinical-

picture and minimal abdominal findings. This, together with radiographic evidence of free air, hints at a localized and spontaneously sealed perforation. Non-operative treatment, following a gastrografin UGI study, or contrast CT, to document that the perforation is sealed, should be successful in most instances. The “**extremely sick**” are the other candidates for conservative therapy: those in whom the risk of any operation could be prohibitive, such as the early post-massive myocardial infarct patient, the COPD (chronic obstructive pulmonary disease) grade IV, or the patient with an APACHE II score over 25. Also in this group, however, conservative treatment may be successful only if the perforation is sealed and radiographically proven to be so. When sealing did not occur, in desperate situations we have successfully carried out omentopexy under local anesthesia.

Antibiotics

As soon as the diagnosis of perforation is made, and the patient is “booked” for a laparotomy, administer a dose of wide spectrum antibiotics. The vast majority of patients presents for treatment within 12 hours of perforation and suffer, therefore, from peritoneal **contamination** rather than **infection**. In many of them, in fact, the peritonitis is chemical and does not contain any microorganisms. Antibiotics in this group will serve for prophylaxis. Postoperative therapeutic antibiotics are not needed in these patients. Those who present later than 12 hours may suffer from intra-abdominal infection; here antibiotics should be continued in the postoperative phase (🔗 Chap. 42). The antibiotics given, either in the form of monotherapy or combination therapy, should “cover”, empirically, Gram-negatives and anaerobes. Routine culturing of the peritoneal fluid in perforated patients is not indicated (🔗 Chap. 12). Those who practice it (unnecessarily, we believe) often grow *Candida*, which represents a contaminant and does not need specific therapy.

Conclusions

Patch a perforated ulcer if you can, if you cannot, then you must resect. Consider adding a definitive anti-ulcer procedure on a *very* selective basis, and do not forget that a non-operative approach is possible, beneficial and indicated in selected patients.

“We have no responsibility to such patients but to save their lives. Any procedure, which aims to do more than this, can quite significantly be considered meddling surgery. We have no responsibility during the surgery to carry out any procedure to cure the patient of his original duodenal ulcer.” (Roscoe. R Graham, 1890–1948)

Acute Pancreatitis

MOSHE SCHEIN

“Acute pancreatitis is the most terrible of all the calamities that occur in connection with the abdominal viscera.” (Berkeley Moynihan, 1865–1936)

God put the pancreas in the back because He did not want surgeons messing with it.

Most attacks of acute pancreatitis (AP) are mild to moderate and resolve spontaneously. This chapter concentrates on the complications of AP, which may require more than conservative-supportive care.

Classification

Emergency surgery is seldom required in cases of uncomplicated AP, but a severe episode of AP of any etiology may lead to a plethora of complications, both infective and necrotic, including:

- Pancreatic and peri-pancreatic necrosis
- Infected pancreatic necrosis and peri-pancreatic necrosis (IPN)
- Pancreatic abscess
- Pseudocyst
- Infected pseudocyst

Natural History

Uncomplicated AP is “a 1-week disease”. Failure to recover or the persistence of local and systemic signs of pancreatic inflammation beyond the seventh day are signs that a complication may be brewing. You’ll best understand this complicated disease, and develop a rational clinical approach to its treatment, when you consider its evolution week by week (● Fig. 18.1).

First Week: Inflammation

This is the phase of acute inflammation resulting in an inflammatory mass, which consists of the pancreas and adjacent structures – the so-called pancreatic

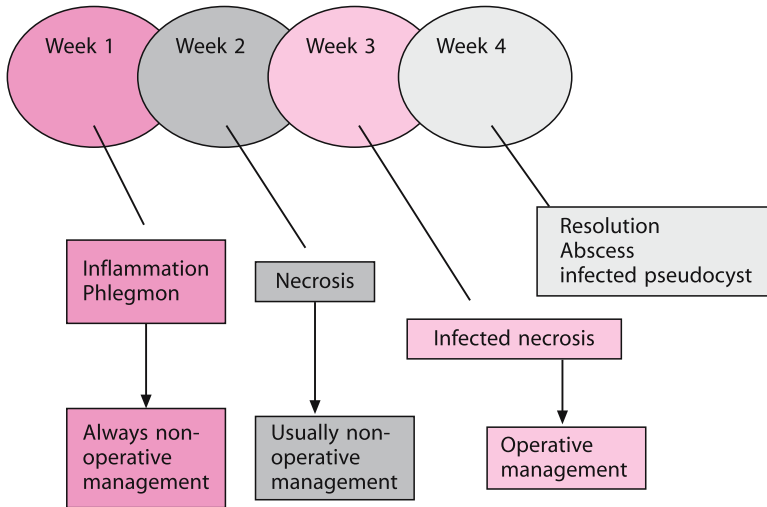


Fig. 18.1. Natural history of complicated acute pancreatitis and its management

phlegmon. Pro-inflammatory mediators (e.g. cytokines) are present in the beer-like hemorrhagic exudate of severe AP, and are responsible for producing the characteristic local and systemic clinical inflammation (SIRS, systemic inflammatory response syndrome). The systemic repercussions of AP (e.g., respiratory or renal failure) depend on the intensity of the process and the quantity of mediators entering the retroperitoneum, the peritoneal cavity and the circulation. In most patients the inflammation is mild and will resolve in a few days. Patients with a severe inflammatory process tend to progress into the second week.

Second Week: Necrosis

This is the phase of necrosis, which starts towards the end of the first week. The necrotizing process may involve the pancreas and its surroundings; retroperitoneal spread is hastened by activated proteolytic pancreatic enzymes. The severity of disease, and therefore the prognosis, depend on the quantity and extent of necrotic tissue (sometimes involving the entire retroperitoneum) and whether secondary infection supervenes. Pooling of the exudate in the lesser sac and beyond forms the so-called acute peri-pancreatic fluid collections, which may resolve spontaneously or gradually develop an *inflammatory wall* to become a pancreatic pseudocyst. The necrotic process may resolve spontaneously over a period of weeks. It may however become secondarily infected – a process that may occur as early as the second week but usually later.

Third Week: Infection

This is the phase of infection. The diagnostic modalities described below may point to infection of the necrotic tissue by the middle of the second week, but its peak incidence is the third week. The causative organisms probably originate from the nearby colon by translocation, but superinfection with *Candida* species is not uncommon. The resulting infection of necrotic tissue produces infected pancreatic and/or peri-pancreatic necrosis, whereas secondary infection of a pseudocyst results in an *infected pseudocyst* (a late, rarer and more benign process). The combined effects of necrosis and infection give rise to the clinical manifestations of local and systemic inflammatory syndromes.

Sterile necrosis and IPN are clinically indistinguishable! IPN may occasionally produce a relatively mild systemic illness, while widespread sterile necrosis may cause the patient's demise, the outcome probably depending on the intensity of the inflammatory response in the individual patient.

Fourth Week and Beyond

Patients with non-infected pancreatic and/or peri-pancreatic necrosis, whose hitherto relatively benign clinical course did not mandate an operation, enter this "late" phase. We do not know what quantity of necrotic pancreatic parenchyma is capable of spontaneous resolution. We know, however, that large necrotic zones may be reabsorbed and thus resolve or, alternatively, undergo secondary infection, to present weeks later as a **pancreatic abscess**. This is an infective localized process developing after the resolution of the acute pancreatic inflammatory process. Therefore, its presentation, management and prognosis differ drastically from those of IPN. Pseudocysts may also develop at this stage.

Estimation of the Severity of Illness


Severe AP will eventually declare itself either by failing to resolve or by its dramatic systemic effects. It is important for you to recognize early that the attack is severe in order to optimize patient care, prevent infective complications, and estimate the prognosis.

Early attempts to estimate severity of disease revolved around measurement of levels of specific pancreatic enzymes or acute phase reactants but it became obvious that one or two biochemical tests would not suffice. Beer-like, murky peritoneal fluid is diagnostic of necrotizing-hemorrhagic pancreatitis (i.e. severe AP) but this observation requires peritoneal aspiration, which is an invasive procedure and is unacceptable as a routine in the early phase of AP.

A number of scoring systems have been developed to estimate the severity of AP. Most are based on the estimation of clinical and laboratory variables that reflect the intensity of the inflammatory process. Imrie's (Clement Imrie, contemporary, Glasgow) method is popular in the UK, whereas elsewhere most medical students and enthusiastic medical residents can recite the lengthy list of early and late Ranson's criteria (John C. Ranson, 1938–1995). The APACHE II scoring system is useful in measuring the severity of *any acute disease*, and has been shown to prognosticate the outcome of AP better than any other system. We advise you to use this uniform and user-friendly scoring system (p. 57). **A patient with an APACHE II score of more than 8 has severe AP.**

Contrast-enhanced dynamic computed tomography has been reported to be useful in diagnosing AP and grading its severity. The clinical diagnosis of AP is, however, straightforward and scoring can assess the severity of disease better. Not uncommonly we see patients with CT images of “horrendous pancreatitis” who feel well and go home after a few days without any complications. Moreover, contrast-enhanced CT examination has been implicated in the aggravation of microvascular damage in the pancreatic parenchyma. In addition, CT findings during the first week of AP will very rarely influence management decisions. **We suggest that you avoid CT scanning the AP patient in the early phase of the disease and reserve this examination for patients in whom the diagnosis of AP is uncertain.** Please do not treat severe acute pancreatitis with daily CT scans. Ultrasound should, however, be performed early to confirm or exclude cholelithiasis as a possible cause of AP.

Diagnostic and Therapeutic Approach

Each issue will be discussed in the order of its clinical occurrence, again, week by week (see  Fig. 18.1).

Inflammation – First Week

Generally, the approach to early severe AP is *conservative* and the treatment *supportive*. Historically, many different approaches have been tried in attempts to limit the effects of this disease. For example, since pro-inflammatory mediators cause the clinical manifestations there were attempts to prevent or diminish such responses with *early pancreatectomy* or *peritoneal lavage*, respectively. Pancreatic resection in early severe AP is associated with a horrendous mortality rate and, anyway, does not prevent the development of intra-abdominal infection. Although continuous peritoneal lavage, if started within a day or two, may improve systemic manifestations, it is clear that it does not prevent the late major complications

(and mortality) we are talking about. “Hemo-filtration” of the blood of the noxious mediators liberated by AP has been tried but remains experimental.

It appears, therefore, that you should offer these patients nothing more (and nothing less) than supportive care, preferably in the Surgical Intensive Care Unit. You should remember that **severe AP represents a major abdominal “chemical burn”** with many liters of fluid sequestered in the retroperitoneum and peritoneal cavity. Optimal fluid balance and replacement are mandatory to protect the kidneys and provide an adequate venous return to the heart, which may be adversely affected by the pancreatitis-related myocardial depressing factor. Overhydration, on the other hand, should be prevented especially in the presence of an associated ARDS (acute respiratory distress syndrome). The swollen pancreas, together with the edematous SIRS-affected viscera, may easily produce intra-abdominal hypertension. You won’t know about it unless you measure the intra-abdominal pressure. When **abdominal compartment syndrome** complicates severe AP, the abdomen should be decompressed (➤ Chap. 36). To us, this is the only indication for early laparotomy in AP.

We have always been told that “resting the pancreas”, by gastric decompression and a regimen of nil-per-mouth is beneficial. This remains unproven. Gastric decompression with a nasogastric tube should be employed only in the presence of gastric ileus or outlet obstruction due to the swollen pancreas. Classically, the parenteral route was used for nutritional support but recent evidence suggests that enteral nutrition via a transduodenal tube is well tolerated and results in fewer local and systemic complications and better outcome (➤ Chap. 41). **Early enteral feeding may indeed be beneficial.**

Some evidence suggests that intravenous antibiotics are to be started in any AP patient assessed as “severe”. This serves to prevent superinfection of the necrotic tissue, thus reducing the incidence of IPN. *Imipenem*, a wide spectrum agent which achieves high levels within the pancreatic parenchyma appears to be the drug of choice. Some authorities recommend the addition of an anti-fungal agent (e.g., fluconazole) to prevent fungal superinfection of the necrotic pancreas. Others would administer antibiotics in all cases of *biliary pancreatitis*; this of course would be the logical thing to do when there are associated features of *ascending cholangitis*.

As already mentioned, there is no indication at this stage to obtain a CT scan unless you are insecure about your diagnosis. Laparotomy is almost contra-indicated during early AP and should be allowed only in cases where a life-threatening surgical catastrophe cannot be otherwise excluded or – as mentioned above – to decompress an *abdominal compartment syndrome*. Indeed, *exploratory laparotomy in AP is not innocuous*; it adversely affects the natural history of the disease by increasing the incidence of infective complications. For this reason no laparotomy for unexplained peritonitis should be undertaken unless the diagnosis of AP has been excluded.

Endoscopic sphincterotomy is the only invasive therapeutic modality that should be considered early, during the first week, in the course of severe biliary AP, especially if features of ascending cholangitis are present and the presence of common bile duct (CBD) stones is suspected.

Your dedicated supportive care will result in the survival of most of these patients until their disease process enters the second week.

Necrosis – Second Week

Pancreatic necrosis develops in one-fifth of AP patients who have more than three Ranson's criteria or an APACHE II score higher than 8. Dynamic, contrast-enhanced CT is the best way to diagnose necrosis and should be obtained in patients who are not improving towards the end of the first week. CT examination at this stage serves also as a "base-line" for subsequent imaging. Pancreatic parenchyma that does not pick up contrast is considered necrotic; the volume of necrosis is then estimated relative to the well-perfused area.

Once pancreatic necrosis is diagnosed, you must answer two questions:

- **Is the process infected (i.e., IPN)?**
- **Is an operation indicated, and if so, which?**

The probability of infection is very low at the beginning of the second week but it gradually increases, reaching its peak in the third week. Because it is impossible to distinguish clinically between sterile and infected necrosis, additional diagnostic modalities are necessary. *Gas bubbles* in the region of the pancreas are observed on plain radiographs or CT in a third of infected cases, and were considered pathognomonic. However, there are a few reports of gas detected in the *non-infected* necrotic pancreas as well. Thus, fine needle CT-guided aspiration of necrotic

Table 18.1. Indication for pancreatic necrosetomy^a

1. Presence of infected pancreatic necrosis (IPN) on CT (extra-intestinal air) or fine needle aspiration biopsy culture
2. Irreversible clinical deterioration despite maximum supportive care for at least 2 weeks from onset of symptoms
3. Suspicion of IPN in the absence of above features (item 1) in patients with >50% of their pancreas assessed as necrotic on CT
4. Extensive (>50%) necrosis and a prolonged ileus or continuing symptoms (pain, vomiting, inability to eat) despite resolution of distant organ dysfunction

^a Uhl W, Warsaw A, Imrie C et al. (2002) International Association of Pancreatology Guidelines for the surgical management of acute pancreatitis. *Pancreatology* 2:565–573.

tissue for Gram-stain and culture is necessary in all patients suspected of harboring IPN. **Bacterial infection of pancreatic or peri-pancreatic necrosis is considered lethal if left untreated and therefore represents an absolute indication to do “something”.**

The indications for surgery according to the International Association of Pancreatology Guidelines are depicted in  Table 18.1.

Recent Controversy

For most surgeons the presence of proven IPN is an indication for operation. This dogma has been recently challenged with sporadic reports documenting resolution of IPN on antibiotic therapy alone. **We believe that the diagnosis of IPN is not an indication for *immediate* operation in a patient who is systemically well and not deteriorating.** Continuation of supportive care and antibiotics even if not “curative” would delay the operation and make it easier and less traumatic as the necrotic-infected process “matures”.

How to Treat Non-infected Necrosis?

On one hand, massive sterile necrosis is responsible for severe morbidity and even death; furthermore, necrosis may lead to IPN. On the other hand, we know that sterile necrosis may resolve spontaneously. It is not clear, however, whether or not very large segments (more than a half) of the pancreatic parenchyma may respond to conservative therapy. These uncertainties led to different approaches. Partial pancreatic resections to eradicate the involved areas have been performed, at the price of excessive morbidity and mortality. Often, normal parenchyma is excised as both radiologists and surgeons tend to overestimate the extent of necrosis. At the other end of the spectrum, there are those – today most experts in the field – who persist with conservative treatment for as long as possible, waiting for demarcation of the necrotic tissue that facilitates the eventual operation – if it ever becomes necessary. A stable patient with sterile necrosis should be subjected to serial CT examinations and fine needle aspiration. Operation may become necessary in the third or fourth week if infection is uncovered or the patient fails to recover.

Infection (or Resolution), Pseudocyst – Third Week

During this phase most patients with IPN undergo an operation, while those with sterile necrosis begin to recover. The resolution of necrosis may result in the formation of a pseudocyst diagnosed on CT or ultrasonography. If signs of infec-

tion are present, a diagnostic needle aspiration should be carried out. **The treatment of choice of an infected pseudocyst is percutaneous drainage.**

Pancreatic Abscess – Fourth Week and Beyond

In some cases of pancreatic necrosis treated non-operatively, resolution does not occur. Instead, a collection of pus – **pancreatic abscess** – forms in the retroperitoneum. Generally, these patients are less severely sick than those with IPN. Nevertheless, drainage by one or other means is indicated.

Operative Approach

Percutaneous Drainage

Successful CT or ultrasound-guided percutaneous (PC) drainage of isolated intra-abdominal abscesses (● Chap. 44) has prompted attempts at a similar approach in AP-related collections. Clearly, PC drains are able to remove exudate and thin pus but inadequate to evacuate the thick “porridge” typical of IPN. Thus, PC drainage may be successful in the treatment of isolated early peri-pancreatic fluid collections, infected and non-infected pseudocysts or the late-occurring isolated pancreatic abscess. When your patient fails to improve within 24–48 hours of PC drainage consider surgery. PC drainage is doomed to fail whenever a *significant* amount of infected pancreatic necrosis is present; this always requires an operation.

The Operation

The surgical approach to infected or non-infected pancreatic necrosis is essentially the same, revolving around the removal of necrotic tissue. (It is hoped that you won’t have too many opportunities to operate on sterile necrosis). The key issues are:

- **Timing** (early versus late), as discussed above
- **Approach** (trans-peritoneal versus retroperitoneal)
- **Technique** (pancreatic resection versus removal of necrotic tissue – necrosectomy)
- **Management of wound** (closure of the abdomen versus open management – laparostomy)
- **Postoperative management** (with or without continuous irrigation of the pancreatic bed)
- **Re-operations** (“planned” versus “on-demand”)

You can approach the site of necrosis from the front, trans-peritoneally, or extra-peritoneally, via a flank incision. The latter prevents contamination of the peritoneal cavity and could decrease the incidence of wound complications. This “blind” technique is associated however with a higher risk of injury to the transverse colon and retroperitoneal hemorrhage. In addition, it makes proper exploration and necrosectomy difficult. We prefer therefore a trans-peritoneal approach through a long transverse incision (chevron), which offers generous exposure of the entire abdomen. A midline incision offers adequate exposure but interferes with the small bowel in cases where planned re-operation or laparostomy are subsequently necessary (● Chap. 46). The extra-peritoneal routes are valuable in rare instances when the process is localized at the pancreatic tail, on the left side, or its head, on the right. It is more often used to evacuate localized sequestra of necrotic fat during subsequent re-operations.

Your main objectives at operation are:

- To evacuate the necrotic and infected material
- To drain the toxic products of the process
- To prevent re-accumulation of these products
- To avoid injury to adjacent visceral and vascular structures

We should emphasize that pancreatic necrosis/infection is drastically different from other surgical infections you are called to treat, as the pancreatic process tends to progress despite an apparently adequate initial debridement and drainage.

The three main operative approaches practiced today are:

1. Debridement, wide drainage and abdominal closure. Further procedures are carried out on “on demand”.
2. As above plus continuous, local irrigation of the lesser sac (for a few weeks!) with re-operations performed “on demand”.
3. The “aggressive” method, which includes leaving the abdomen open (laparostomy) and planned re-laparotomies to repeatedly debride the necrotizing process until it is completely eradicated (● Chap. 46). Another theoretical advantage of this method is that it prevents the development of the **abdominal compartment syndrome** due to increased intra-abdominal pressure, which results from swelling of the pancreas, accumulation of necrotic material and fluid, and visceral edema.

What is the “best” approach? It appears that significantly lower mortality rates are achieved with methods 2 and 3. Method 3 is associated with higher rate of mechanical re-operative complications including hemorrhage, fistulization of the transverse colon, and abdominal wall defects. **It is clear that the mainstay of therapy is complete evacuation of IPN and that an overly conservative approach in the face of a diffuse process is the chief cause of mortality.**

Each of the three methods may succeed in a certain patient and should be used selectively depending on the extent of IPN and severity of the illness in the individual patient. The first approach may suffice in a patient with a localized process and small quantity of necrosis. The second technique may be advantageous when a more extensive process is limited to the lesser sac. Extensive IPN, however, requires the most aggressive treatment as represented by method 3, which is life saving when the process extends diffusely in the retroperitoneum and down into the pelvis.

Practical Operative Points

When operating on pancreatic necrosis or IPN you must understand that it is often impossible to be performing a *definitive* debridement. Leave the rest for tomorrow (i.e. re-operation). Over-enthusiastic debridement will debride the bowel (which will leak) or adjacent vessels (which will bleed). Follow the necrotizing process down the retroperitoneum; it may extend behind the left and right colon into the pelvis. Only the soft necrotic black/gray Camembert cheese-like material should be removed. Using your fingers or blunt sponge forceps to pick up the material will avoid the hard, non-necrotic pancreas and other structures.

Enter the lesser sac from whatever direction is easiest, but expose it completely. *Try not to add insult to injury.* This is easier said than done while burrowing within inflamed and friable tissues. Safeguard the vessels in the transverse mesocolon; these are commonly injured during trans-mesocolon entry into the lesser sac or by drains placed through this route. It is tempting to remove the spleen, which may take part in an inflammatory mass in the pancreatic tail. This is not necessary; try not to injure the spleen during re-operations. The adherent duodenum and loops of small bowel are frequently injured during re-operations; this, together with the corrosive action of activated pancreatic enzymes, causes intestinal leaks. Be extremely gentle with the bowel and avoid rigid drains near the duodenum for they will erode. Often after *necrosectomy* there is diffuse ooze from the resulting cavity. Pack it! Try not to place packs directly on exposed veins – they will be eroded and bleed! Safeguard the omentum and place it between the packs and exposed vessels. For more on the conduct of laparostomy see ● Chap. 46.

Laparoscopic Necrosectomy in Infected Pancreatic Necrosis?

Recently laparoscopic management has been reported to be successful in these patients, performed either through the anterior trans-abdominal approach or, more commonly, from the loins through the retroperitoneum. The sites of debridement

are guided by CT findings with multiple ports of entry used simultaneously or in a staged manner. Recent series report favorable results but it is often unclear how many patients were subjected to unnecessary procedures on non-infected necrosis, which would have resolved spontaneously. It is of course possible to write success stories with any method but we hope that if and when embarking on laparoscopic surgery for IPN you know exactly what you are doing.

Conclusions

The proper management of severe acute pancreatitis requires that you understand its natural history and be armed with lots of patience. During the early phases of the disease **“our patience will achieve more than our force”** (Edmund Burke); later on, when called to operate on necrotic and infected complications, remember that **“patience and diligence, like faith, remove mountains”** (William Penn).

“Everything in surgery is complicated until one learns to do it well, then it is easy.” (Robert E. Condon)

Acute Cholecystitis

MOSHE SCHEIN

“In dropsy of the gallbladder... and in gallstones we should not wait ‘til the patient’s strength is exhausted, or ‘til the blood becomes poisoned with bile, producing hemorrhage; we should make an early abdominal incision, ascertain the true nature of the disease, and then carry out the surgical treatment that necessities of the case demand.” (James Marion Sims, 1813–1883)

Acute cholecystitis (AC) is either *calculous* or, less commonly, *acalculous*. Since the clinical picture of these two entities differs they are discussed separately.

Calculous Acute Cholecystitis

Acute cholecystitis is initiated by a gallstone, which obstructs the gallbladder’s outlet. Its spontaneous dislodgment results in so-called *biliary colic* while persisting impaction of the stone produces gallbladder distention and inflammation, namely *AC*. The latter is initially chemical but gradually, as gut bacteria invade the inflamed organ, infection supervenes. The combination of distention, ischemia, and infection may result in a gallbladder empyema, necrosis, perforation, peri-cholecystic abscess or bile-peritonitis. You must have heard or read numerous times about the classical symptoms and signs of *AC*. Let us concentrate therefore only on problem areas.

How to Differentiate Between Biliary Colic and AC

Time is the best discriminator as the pain and right upper quadrant (RUQ) symptoms of biliary colic are self-limiting, disappearing within a few hours. Conversely, in *AC*, the symptoms and signs persist. Furthermore, *AC* is accompanied by local (e.g., local peritonitis or tender mass) and systemic (e.g., fever, leukocytosis) evidence of inflammation, while biliary colic is not.

The clinical picture, which you know so well (we do not need to mention Murphy’s sign again), is very suggestive. Laboratory findings of leukocytosis and elevation of bilirubin and/or liver enzymes may back it up. But note that a lack of some or all features of inflammation/infection does not rule out *AC* – as is true also for acute appendicitis.

Luckily, you can (and should) confirm your diagnosis of *AC* with ultrasound or a *radionuclide HIDA (hepatic iminodiacetic acid) scan*, which are readily available.

Which of the two you should ask for first depends on its availability, and the expertise in your hospital. We prefer ultrasound as it may also provide incidental information concerning the liver, bile ducts, pancreas, kidneys and peritoneal fluid, possibly suggesting alternative diagnoses. The *ultrasonographic findings in AC* include a distended, stone or sludge-containing gallbladder, thickened wall, mucosal separation, peri-cholecystic fluid collection or intramural air. Not all of these findings are necessary to make a diagnosis. Positive *radionuclide scan* in AC means **non-filling** of the gallbladder by the isotope. The specificity of the test is increased (e.g., fewer false-positives) if morphine is administered, causing spasm of the sphincter of Oddi and reflux of isotope into the cystic duct. There are other (chronic) causes of non-filling of the gallbladder (e.g., mucocele) **but a negative scan with the isotope entering the gallbladder excludes AC.**

Associated Jaundice ▶ Mild to moderate elevation of bilirubin and hepatic enzymes is a relatively common feature of AC, caused by reactive inflammation of the hepatic pedicle and the surrounding liver parenchyma. Thus, you need not attribute the jaundice to choledocholithiasis, unless there are also clinical and ultrasonographic features of ascending cholangitis and/or bile duct stones (◀ Chap. 20).

Associated Hyperamylasemia ▶ Similarly, mild elevation of the serum amylase does not mean that the patient is suffering from biliary pancreatitis. Commonly, hyperamylasemia is produced by AC with no signs of acute pancreatitis detected at operation.

Management

Non-operative Management

The natural history of AC is such that in more than two-thirds of patients treated non-operatively the increased intra-gallbladder pressure will be relieved by dislodgment of the obstructing stone and resolution of the process. Conservative therapy, which should be started in all AC patients after the diagnosis is established, includes: nil per mouth (nasogastric tube only if the patient is vomiting), analgesia (use a non-opioid if you believe in the hypothetical importance of avoiding constriction of the sphincter of Oddi), and antibiotics (active against enteric Gram-negative bacteria).

In the “old days” patients were discharged home after responding to a few days of conservative treatment to return for a *delayed, “interval”, cholecystectomy* a few weeks later. This approach has been discontinued because of unpredictable failure to respond and recurrences of AC prior to the planned operation. Today, we reserve

delayed cholecystectomy for patients who are medically unfit to undergo an operation in the acute stage, provided they respond to conservative management. There is abundant evidence showing **that the earlier the operation – the easier it is**. The acute inflammatory edema provides tissue planes, which facilitate cholecystectomy. Conversely, the more one delays the operation – the more fibrosis and scar tissue forms – and the more traumatic the operation.

Surgical Management

Cholecystectomy is the optimal procedure; it eradicates the inflammation/infection and prevents its recurrence. Based on your clinical impression it will be performed either as an “emergency” (rarely needed) or, usually, “early”.

Emergency Cholecystectomy

An immediate, emergency procedure should be performed following resuscitation in patients with clinical evidence of *diffuse peritonitis and systemic toxicity, or presence of gas within the gallbladder wall* – features suggesting perforation, necrosis or empyema of the gallbladder. Most surgeons today would attempt a trial laparoscopic cholecystectomy (LC) in this situation, converting to “open” in the presence of technical difficulties. We would warn, however, against prolonged peritoneal insufflation in the critically ill patient and would avoid prolonged attempts with laparoscopic dissection of the necrotic, perforated and difficult-to-grasp gallbladder. Emergency cholecystectomy for complicated AC in the critically ill or compromised patient could be “open” as described below. **Obviously, a brief open cholecystectomy is easier on your patient than an open cholecystectomy following 2 hours of futile laparoscopic attempts!** (● Fig. 19.1).

Early Cholecystectomy

Patients in whom emergency cholecystectomy is not clinically indicated should undergo an early cholecystectomy. But what is “early”? For some it means that you do not need to rush to the operating room in the middle of the night but operate during day-hours, under favorable “elective” conditions. For others it means to operate on the “first elective list”. Depending on the surgeon’s schedule and the availability of the OR, patients are often left “to cool down” for days awaiting their “semi-elective” cholecystectomy, which is often performed at the end of the elective lists. Occasionally, a waiting period as short as 48 hours results in deterioration



Fig. 19.1. “I never convert...”

of the patient, but as we have observed already the majority of AC will settle down without an early operation.

Clinical appraisal of the severity of AC is notoriously unreliable; patients with gallbladder empyema or necrosis may be initially clinically silent only to deteriorate suddenly while those with impressive RUQ signs may harbor just a simple AC. A mandatory operation within 24 hours will prevent any problems arising from a delay in operation. Furthermore, we wish to point out again that the operative dissection (laparoscopic or open) is easier and less bloody during the early phase of inflammation, with tissue planes becoming progressively more difficult as the process progresses. **Thus, our definition of early cholecystectomy is an operation within 24 hours of admission.**

Note: there is a subgroup of patients who will benefit from a delayed approach, in order to prepare them better for surgery. For example, decompensated cardiac failure should be treated and coagulation disturbances corrected. Do not brandish your knife at unprepared patients.

The High-risk Patient who Needs an Emergency Procedure

With today's advanced anesthetic techniques and ICU support it is rare to encounter a patient who cannot be subjected to an emergency procedure under general anesthesia. But what are we to do with the occasional extremely sick patient who is “not even fit for a hair cut under local” as they used to say? The best option

is a *tube cholecystostomy* under local anesthesia. This can be done by you in the operating room, or – even better and less traumatic – by the radiologist, inserting the tube into the gallbladder percutaneously, and transhepatic, under CT guidance. Failure of the patient to improve within 24–48 hours, particularly after the percutaneous procedure, should suggest the presence of undrained pus or necrotic gallbladder wall, and the need to operate.

Acute Cholecystitis in Cirrhotic Patients

An emergency cholecystectomy in cirrhotic patients with portal hypertension not uncommonly culminates in a *bloody disaster* due to an intra- or post-operative hemorrhage from the congested gallbladder's hepatic bed or large venous collaterals at the duodenohepatic ligament. Although conventional laparoscopic cholecystectomy has been judged safe in “Child's A” portal hypertension patients (see ● Chap. 16), we believe that the secret here is to stay away from trouble, by avoiding dissection near engorged and rigid hepatic parenchyma and the excessively vascular triangle of Callot. Subtotal or partial cholecystectomy is the procedure of choice in this situation (see below).

Technical Points

Cholecystectomy

As mentioned, “emergency” procedures may be “open” unless you like to play around with the laparoscope in desperately ill patients. In early cholecystectomy you may start laparoscopically, accepting a need to convert to “open” in up to one third of the patients. It is important not to be carried away, persisting with laparoscopic dissection in the face of hostile anatomy. A practical rule of thumb is to convert to laparotomy if after 45–60 minutes of laparoscopy you feel like you are “going nowhere”. In many patients a decision to convert can be made much earlier than this even, and you should not be afraid to abandon the laparoscopic approach at any stage if the circumstances are obviously unfavorable. Inappropriate persistence with the laparoscopic approach may well end in disaster with a bile duct injury. For an excellent list of rules of thumb to prevent this calamity look at the article by Lawrence W. Way¹.

¹ Way LW, Stewart L, Gantert W, Liu K, Lee CM Whang K, Hunter JG (2003) Causes and prevention of laparoscopic bile duct injuries: analysis of 252 cases from a human factors and cognitive psychology perspective. *Ann Surg* 237:460–469.

There is no need to educate you further on the topic of laparoscopic cholecystectomy. However you may need some advice on the open procedure, which is becoming rare in elective practice, and is increasingly being reserved for the “difficult” cases.

The *routine*, “maxi”, full-size gallbladder abdominal incision belongs to history. In the acute situation start with a “midi” – 5 to 10 cm – transverse RUQ incision, extending “piecemeal” as necessary. When converting from LC simply extend the epigastric trocar site laterally.

The wise-man’s rule is: “go fundus first (dome down) and stay near the gallbladder”. After needle-decompression (connect a wide-bore needle to the suction) of the distended gallbladder, hold the fundus up and away from the liver with an instrument and dissect down towards the cystic duct and artery, which are the last attachments to be secured and divided. By observing this rule it is virtually impossible to damage anything significant such as the bile duct.

Subtotal (Partial) Cholecystectomy

Asher Hirshberg, MD, summarized it aptly: **“It is better to remove 95% of the gallbladder (i.e., subtotal cholecystectomy) than 101% (i.e., to together with a piece of the bile duct).**

And yes, yes, yes – any weathered surgeon will tell you that this is the procedure to use, in order to avoid misery, in problematic situations such as fibrotic triangle of Calot, portal hypertension, or coagulopathy. Partial or subtotal cholecystectomy has been popularized in the United States by Max Thorek (1880–1960) and thus some call it the Thorek procedure. Thorek, by the way, was a keen aphorist and also said: **“...how old is our newest knowledge, how painfully and proudly we struggle to discoveries, which, instead of being new truth, are only rediscoveries of lost knowledge”.**

The gallbladder is resected starting at the fundus; the posterior wall (or what has remained of it when a necrotizing attack has occurred) is left attached to the hepatic bed and its rim is diathermized or oversewn for hemostasis with a running suture. At the level of Hartmann’s pouch, the cystic duct opening is identified from within. The accurate placement of a purse-string suture around this opening, as described by others, is not satisfactory, because the suture tends to tear out of the inflamed and friable tissues. A better option is to leave a 1-cm rim of Hartmann pouch tissue and suture-buttress it over the opening of the cystic duct. When no healthy gallbladder wall remains to close the cystic duct, it is absolutely safe just to leave a suction drain and bail out. In the absence of distal common bile duct obstruction you won’t see even a drop of bile in the drain because in such cases the cystic duct is obstructed due the inflammatory process. The exposed and often

necrotic mucosa of the posterior gallbladder wall is fried with diathermy (some say until you smell fried liver...) and the omentum is brought into the area. In this operation, the structures in the Calot's triangle are not dissected out and bleeding from the hepatic bed is avoided; it is a fast and safe procedure having the advantages of both cholecystectomy and cholecystostomy.

Cholecystostomy

In our hands, subtotal cholecystectomy has almost replaced "open" tube cholecystostomy for the "difficult" gallbladder. This latter procedure is indicated in the very rare patient who *must* be done under local anesthesia and then only when percutaneous cholecystostomy is not available or is not successful.

After the infiltration of local anesthesia place a "mini" incision over the point of maximum tenderness or the palpable gallbladder mass. You can mark the position of the fundus on the skin at the pre-operative ultrasound as it is rather unpleasant for both you and the patient to enter the abdomen, under local anesthesia, and find that the gallbladder is far away. Visualization of gallbladder wall necrosis at this stage mandates a subtotal cholecystectomy; otherwise open the fundus and remove all stones from the gallbladder and Hartmann's pouch. For improved inspection of the gallbladder lumen, and complete extraction of stones and sludge, a sterile(!) proctoscope may be useful. Thereafter, insert into the fundus a tube of your choice (we prefer a large Foley), securing it in place with a purse-string suture. Fix the fundus to the abdominal wall, as you would do with a gastrostomy. A tube cholangiogram performed a week after the operation will tell you whether the cystic duct and bile ducts are patent; if so the tube can be safely removed. Whether an interval cholecystectomy is subsequently indicated is controversial. Cystic duct obstruction on the other hand (according to the prevailing dogma) mandated interval cholecystectomy.

Choledocholithiasis Associated with Acute Cholecystitis

About a tenth of patients who suffer from AC also have stones in the bile ducts. Remember, however, that AC may produce jaundice and liver enzyme disturbances in the absence of any ductal pathology. AC is very rarely associated with active complications of choledocholithiasis. In other words, AC combined with acute pancreatitis, ascending cholangitis, or jaundice is unusual. The emphasis, therefore, should be on the treatment of AC, which represents the life-threatening condition; ductal stones, if present, are of secondary importance.

Our management of patients with diagnosed AC and suspected choledocholithiasis would be tailored to the severity of the AC, the ultrasound appearances of the bile ducts, and the condition of the patient. Add to the decision tree your local facilities. As you know, there are many ways to skin this particular cat:

- **Acute cholecystitis, mildly elevated bilirubin and enzymes, bile ducts not dilated on ultrasound:** we would start with LC combined with intra-operative cholangiography. Should the latter be positive we would proceed with an open common bile duct exploration or – if the stones are small – leave them to be dealt with by ERCP (endoscopic retrograde cholangiopancreatography) after the operation. Of course, if you are skilled at laparoscopic trans-cystic common bile duct exploration, have at it!
- **If the bile ducts are dilated on ultrasound,** there are liver function disturbances, and the AC is clinically not “severe” we would treat it conservatively and evaluate the duct with MRCP (magnetic resonance cholangiopancreatography) or ERCP. Any ductal stones would be dealt by endoscopic sphincterotomy prior to LC.
- In the critically ill patient with or without gallbladder empyema or perforation we would even “waive” the cholangiogram, leaving the symptomatic ductal stones to endoscopic retrieval after the life-saving cholecystectomy or cholecystostomy.

Acalculous Cholecystitis

This is a manifestation of the disturbed microcirculation in critically ill patients. Although of *multifactorial etiology* (e.g. prolonged fasting, administration of total parenteral nutrition etc.) the common pathogenic pathway is probably gallbladder ischemia, mucosal injury and secondary bacterial invasion. Acalculous cholecystitis is a *life-threatening condition* developing during a serious illness, e.g., following major surgery or after severe injury. Stones may occasionally be present in the acutely inflamed gallbladders in these circumstances but are probably etiologically irrelevant.

Clinical diagnosis is extremely difficult in the postoperative, critically ill or traumatized patient as abdominal complaints are masked. Fever, jaundice, leukocytosis and disturbed liver function tests are commonly present but are entirely nonspecific. Early diagnosis requires a high index of suspicion on your part: **suspect and exclude cholecystitis as the cause of an otherwise unexplained “septic state” or SIRS (systemic inflammatory response syndrome).**

Ultrasonography performed at the bedside is the diagnostic modality of choice. Gallbladder *wall thickness* (>3.0–3.5 mm), *intramural gas*, the “*halo*” sign and *pericholecystic fluid*, are very suggestive. Similar findings on CT examination would confirm the diagnosis. False-positive and negative studies have been reported with both imaging modalities. *Hepatobiliary radio-isotope* scanning is associated with

a high incidence of false-positive studies. However, *filling of the gallbladder with the radio-isotope (morphine assisted, if necessary) excludes cholecystitis*. A highly suggestive clinical scenario and diagnostic uncertainty together are an indication for abdominal exploration.

Management should be promptly instituted as acalculous cholecystitis progresses rapidly to necrosis and perforation. *Select* the best treatment modality based on the condition of your patient and the expertise available in your hospital. In patients stable enough to undergo general anesthesia *cholecystectomy* is indicated. When coagulopathy, portal hypertension or severe inflammatory obliteration of the triangle of Calot are present, *subtotal cholecystectomy* appears to be safer. *Laparoscopic cholecystectomy* may be performed in well-selected and stable patients. **Note:** Insufflation pressure during laparoscopy should be kept under 10 mmHg in order not to upset the flimsy cardio-respiratory balance and hemodynamics in such patients.

“Open” tube cholecystostomy under local anesthesia may be indicated in the moribund patient when expertise for *percutaneous, transhepatic cholecystostomy* is not locally available. The latter is the procedure of choice in the severely ill patient when diagnostic certainty is strong.

Remember: Many of these patients will have a totally necrotic or perforated gallbladder. In these, cholecystostomy may not suffice. *Percutaneous cholecystostomy* is a *blind* procedure; when rapid resolution of “sepsis” does not follow suspect residual pus or necrosis, or an alternative intra-abdominal or systemic diagnosis.

Antibiotics in Acute Cholecystitis

Although routinely administered the role of antibiotics is only adjunctive to the operative treatment as outlined above. In its early phase AC represents a sterile inflammation, while later on in most instances it represents a “resectable infection”, i.e. infection contained within the gallbladder that is to be removed (◉ Chap. 12). Therefore, cases with simple AC need only peri-operative antibiotic “coverage”, which is discontinued postoperatively. In gangrene or contained empyema of the gallbladder we recommend a day or two of post-cholecystectomy antibiotic administration. In cases of perforation with a per-cholecystic abscess or bile peritonitis we suggest that you administer the maximal postoperative course of 5 days (◉ Chap. 42).

When the gallbladder is “difficult” – go fundus first and stay near the wall.

GARY GECELTER

That an emergency operation is very rarely indicated in acute cholangitis does not mean that it is never indicated.

What is the Mechanism?

Acute ascending cholangitis is an infectious-inflammatory consequence of biliary obstruction. Increased intra-biliary pressure above 30 cm H₂O (normal 10–15) is associated with complete bile stasis and induces cholangiovenous reflux. This results in translocation of organisms and an inflammatory response that can result in death if not properly treated.

Cholangitis may “ascend” from an obstruction arising in the extra-hepatic biliary tree with the two common causes of extra-hepatic biliary obstruction being *common bile duct stones* and pancreatic (or periampullary) carcinoma. Choledocholithiasis is more common as a primary cause of cholangitis, whereas the endoscopic treatment of periampullary carcinomas is the commonest cause of iatrogenic cholangitis. During the first decade of laparoscopic gallbladder surgery the incidence of acquired biliary strictures increased tenfold and was frequently associated with cholangitis as the presenting manifestation. Typical of cholangitis arising from choledocholithiasis is the prior history of “fluctuant” jaundice – an awareness of having been jaundiced at various times in the past. This is in contrast to patients who present with progressive (or crescendo) jaundice typical of periampullary tumors. The patient may also admit to having had gallstones diagnosed in the past or may have had a prior cholecystectomy.

What Are the Risks?

It is always a good idea to know who is likely to die from a disease, and why, before you decide how to proceed from the emergency room (ER), through the hospital, and occasionally to the morgue! As with any acute illness, age, associated cardio-respiratory compromise caused by the current event, and the patient’s prior medical problems, all contribute to his or her risk of dying from acute cholangitis. It is always useful to run an APACHE II baseline in the ER and keep a mental note

of the changes as you monitor your patient to ensure that your interventions, or lack thereof, are not causing a rise in your patient's score (p. 57). As a rule in this condition, the direct bilirubin decreases as the treatment takes effect.

How to Make the Diagnosis? (◊ Fig. 20.1)

Charcot's Triad (Jean Martin Charcot of Paris, 1825–1893) characterizes acute ascending cholangitis:

- Right upper quadrant (RUQ) pain
- Fever
- Jaundice

The fever and jaundice are easy to determine. It is our experience that residents miss the objective distinction between the clinical finding of a tender liver, which is the cause of the RUQ pain in cholangitis, and Murphy's Sign, which is a sign of gallbladder obstruction. **Murphy's Sign** (John Benjamin Murphy of Chicago, 1857–1916) is elicited by the presence of point tenderness in the region of the distended gallbladder fundus as it descends, on deep inspiration, to the awaiting fingertips of the right hand. The RUQ tenderness seen in acute cholangitis is objective percussion tenderness elicited along the width of the liver, especially in the epigastrium where the left lobe is not shielded by the costal margin. In addition,




Fig. 20.1. “Oh, the urine is dark ... what do you call that, triad? – Charcoal triad?”

there is usually a varying degree of liver swelling, which makes this sign easier to elicit. If correctly identified in the ER “cot-side”, the treatment for cholangitis is begun before obtaining any investigations.

What are Signs of Complications?

In the elderly patient, or when medical intervention is delayed, the syndrome can progress to include two further clinical features:

- Confusion (do not assume that any elderly-confused patient has senile dementia, ask about the patient’s baseline mental status)
- “Septic” shock

These two, when added to the *Charcot’s Triad* become the *Reynold’s Pentad* (B. M. Reynolds, USA), which is associated with a 4-fold mortality risk increase; consequently, clinical decision intervals must be hourly rather than q4h!

Special Investigations

Ascending cholangitis is diagnosed on the aforementioned clinical grounds. With early presentation, the jaundice may only be biochemical and must be substantiated by a liver panel. A typical panel has mildly elevated transaminases, variably elevated total bilirubin with a direct preponderance, and a disproportionately elevated alkaline phosphatase and glutamyl transferase; white cells are usually elevated. Amylase may be mildly elevated (less than 5-fold elevation) but don’t be confused by acute pancreatitis (● Chap. 18). Note, however, that patients with gallstone pancreatitis may have an associated element of ascending cholangitis. Other laboratory data will be appropriate for the patient’s degree of hydration and respiratory status, which can deteriorate rapidly if the patient presents late or the diagnosis is delayed.

The right upper quadrant sonogram is the best test to confirm the diagnosis. Invariably gallstones are seen in the gallbladder (unless the patient has had a prior cholecystectomy). Mild intra-hepatic ductal dilatation will be demonstrated and the common hepatic duct /common bile duct axis will be variably dilated above a normal level of 7 mm. Rarely can the incriminating bile duct stone(s) be seen directly. Rather, their presence is inferred from the above associated findings. If gallstones are not seen in the gallbladder then the diagnosis of (malignant) periampullary biliary obstruction must be suspected justifying the performance of a thin slice pancreas protocol CT scan. This is usually requested after treatment is begun and during regular hours to prevent a substandard nocturnal study.

Treatment

Initial Management

- **Antibiotics.** Initial management comprises appropriate empiric antibiotics with bowel rest and rehydration. Although it has always been felt that antibiotic selection should be based upon the drug's ability to concentrate in the biliary system, recent re-evaluation of this concept has concluded that no antibiotics are able to reach obstructed bile and that the spectrum of suspected pathogens is a better target for antimicrobial selection. Coverage must be directed against Gram-negative, gut-derived organisms (typically *E. coli* and *Klebsiella* sp.). Up to a fifth of bile cultures will grow anaerobic organisms such as *Bacteroides* or *Clostridia* sp., so it is a good idea to include appropriate coverage empirically.
- **ERCP (endoscopic retrograde cholangiopancreatography).** It is important to recognize that most patients will defervesce within 24 hours on the above treatment, allowing interventional therapies to be scheduled electively and selectively. A minority of patients will have persistent fever and pain, and their bilirubin may rise, implying a persistent complete obstruction. It is at this time that urgent ERCP is indicated with sphincterotomy and stone extraction. It is the gastroenterologist's task to ensure biliary decompression at the first attempt. This does not mean complete duct clearance, as stones may be difficult to extract at one session, but it may mean that placement of a plastic biliary stent or nasobiliary tube is necessary. The latter's advantage is that it can be removed without re-endoscopy after cholecystectomy. If ERCP fails in the critically ill cholangitis patient there is another non-operative alternative – ultrasound-guided percutaneous drainage of the obstructed ductal system by the radiologist. Check it out.

Surgical Strategies

If the patient is one of the majority who settles with initial conservative measures, then one can elect to perform one of the following *semi-elective* procedures, based upon one's local expertise:

- Preoperative ERCP with common duct clearance, followed by laparoscopic cholecystectomy.
- ERCP with common duct clearance alone leaving the gallbladder *in situ*. This is indicated in the very high-risk patient; on follow-up most patients so treated never require a cholecystectomy.
- Laparoscopic cholecystectomy with laparoscopic common bile duct exploration.
- Open cholecystectomy with common bile duct exploration.

In most hospitals preoperative ERCP is selected because it is ubiquitously available. Further, it is diagnostic if periampullary carcinoma is suspected and delineates the biliary anatomy for the surgeon. If it is unsuccessful and the papilla cannot be cannulated then the surgeon knows preoperatively that clearance of the biliary tree at operation *must* be assured (or the duct bypassed).

Primary Emergency Surgical Treatment

We have encountered another subset of patients who present with rapid clinical deterioration and may even develop diffuse signs suggesting gallbladder perforation. It is this group which probably benefits from expeditious surgery following resuscitation. The case is made more compelling if they have had a prior gastrectomy that prevents rapid cannulation for ERCP. Staged surgery, comprising initial placement of a T-tube and subsequent elective cholecystectomy once the patient has settled, is a safe option to remember in this situation.

Conclusions

Acute cholangitis is best managed by a concordant multidisciplinary team that understands when appropriate interventions are needed. Since the introduction of endoscopic management of bile duct stones, surgery is seldom required as an emergency. Removal of the gallbladder and clearance of the bile duct of all stones are the two goals of treatment. In the absence of stones, suspect periampullary carcinoma. When the patient is toxic and ERCP fails, or is not immediately available, do not procrastinate, waiting for “re-ERCP tomorrow” – operate and drain the obstructed biliary system!

— In ascending cholangitis consider the common bile duct an abscess.

MOSHE SCHEIN

“It is less dangerous to leap from the Clifton Suspension Bridge than to suffer from acute intestinal obstruction and decline operation.” (Fredrick Treves, 1853–1923)

By far, the most common causes of small bowel obstruction (SBO) are post-operative adhesions and hernias. Other, uncommon mechanical etiologies are bolus obstruction (e.g. bezoar), malignant or inflammatory (e.g. Crohn’s disease) or intussusception. Hernias causing SBO are discussed in ◉ Chap. 22 while early post-operative small bowel obstruction (EPSBO) and paralytic ileus are discussed in ◉ Chap. 43. Mention will be made below of SBO in the virgin abdomen, intussusception, the cancer patient, radiation enteritis and gallstone ileus. The bulk of this chapter is, however, devoted to adhesive SBO.

The Dilemma

A significant number of SBO patients respond to conservative (non-operative) treatment. But persevering with conservative management in SBO may delay the recognition of compromised (strangulated) bowel, leading to excessive morbidity and mortality. Clearly, your challenge is to resolve the following issues:

- Which patients need an urgent laparotomy for impending or established bowel strangulation? And when is initial, conservative treatment appropriate and safe?
- Once instituted, how long should conservative treatment be continued before an operation is deemed necessary? In other words, how to omit an operation without risking intestinal compromise?

You will be provided with guidelines to answer these questions. But first we need to clarify some terminology.

Definitions

- **“Simple” obstruction:** the bowel is blocked, compressed or kinked, but its vascular supply is not threatened.
- **Strangulation-obstruction:** the vascular supply to the segment of obstructed bowel is compromised.
- **Closed-loop obstruction:** a segment of bowel is obstructed at a proximal and distal point. Commonly, the involved bowel is strangulated.

Understanding the terms “**partial**” versus “**complete**” obstruction is crucial to the planning of treatment. These terms are based on *plain abdomen radiographic* findings (see ◊ Chap. 5).

- **Partial obstruction:** there is gas seen in the colon, in addition to the small bowel distention with fluid levels.
- **Complete obstruction:** no gas seen in the colon.

Most episodes of partial SBO will resolve without an operation, while the majority of patients presenting with a complete obstruction will require one.

Clinical Features (◊ Fig. 21.1)

The three important clinical manifestations of SBO are colicky abdominal pain, vomiting and abdominal distension. Constipation and absence of flatus is a relatively late symptom of SBO. The pattern of these features depends on the site, cause and duration of the obstruction. For example, in high obstruction, vomiting is prominent while pain and distension are absent or mild; as the level of obstruction descends, the crampy pain becomes more marked. In distal SBO, distension is the outstanding symptom with vomiting appearing later. **Feculent vomiting** is the hallmark of long-standing, distal, complete SBO and is characteristic of massive bacterial overgrowth proximal to the obstruction (*Remember* – the main bulk of feces is made of bacteria). It is a poor prognostic sign – the more thick and smelly the nasogastric aspirate, the less chance there is that the obstruction will resolve spontaneously.

The essential radiographic features seen on supine and erect abdominal X-rays are: gaseous distension of the bowel proximal to the obstruction, presence of fluid levels and, in complete SBO, absence of gas distal to the obstruction. The presence of parallel striations (caused by the valvulae conniventes) running transversely, right across the lumen, are characteristic of distended small bowel. Colonic gas shadows lack this pattern. (See also ◊ Chaps. 4 and 5).



Fig. 21.1. “I suspect this is intestinal obstruction...”

Is There a Strangulation?

The answer to this question is crucial – if positive, not only is an operation compulsory, but it also needs to be performed promptly. **The most important feature of strangulation is continuous pain.** Signs of peritoneal irritation (guarding, rebound tenderness) may be present but remember that:

- Dead bowel can be present with a relatively “innocent” abdomen.
- Signs of peritoneal irritation are rarely useful in differentiating “simple” obstruction from strangulation because they may also be found in “simple” SBO when the distension is severe. Dilated loops of intestine are tender – you must surely have seen internists poking aggressively into distended abdomens and diagnosing “peritonitis”?

Remember: no isolated clinical feature or laboratory finding – present or absent – can exclude or confirm that the intestine is strangulating or dead. Only fools let themselves be guided by lactic acid levels. Do not wait for fever, leukocytosis or acidosis to diagnose ischemic bowel because when all these systemic signs are present the intestine is already dead!

Having diagnosed strangulation, you will be congratulated for having expeditiously resuscitated and wheeled your patient to the operating room. Save yourself the embarrassment of explaining, the next day, the presence of the long midline

incision to deal with a knuckle of ischemic gut trapped in the groin! Never forget that a common cause of strangulated bowel is an external hernia. The suspicion of strangulation must make you examine, or rather re-examine more carefully, the five external hernial orifices: two inguinal, two femoral and one umbilical (➤ Chap. 22).

You have to understand that nothing, nothing can accurately distinguish between “simple” and “strangulating” SBO. So how to play it safe?

Management

Fluid and Electrolytes

There is hardly a need to remind you that SBO results in significant losses (or sequestration) of extracellular fluid and electrolytes, which have to be replaced intravenously. The aggressiveness of fluid management and hemodynamic monitoring depend on the condition of the individual patient. The fluid of choice is Ringer’s lactate. The charting of urine output in a catheterized patient is the minimal monitoring necessary. Even patients scheduled for urgent laparotomy for strangulation require adequate pre-operative resuscitation (➤ Chap. 6). Patients with SBO sometimes have intra-abdominal hypertension, which may falsely raise their cardiac filling pressures (CVP, wedge). These patients require all the more aggressive fluid administration to maintain adequate cardiac output (➤ Chap. 36).

Nasogastric Aspiration

A large NG tube (at least 18F in diameter) is needed. The NG tube has both therapeutic and diagnostic functions. It controls vomiting, but its main aim is to decompress the dilated stomach and consequently the gut proximal to the obstruction, which overflows back into the stomach. In a “simple” obstruction, decompression of the obstructed bowel results rapidly in pain relief and alleviates the distension. Essentially, the segment of intestine *proximal* to the obstruction and *distal* to the gastroesophageal junction behaves like a closed loop – decompression of the stomach with a nasogastric tube converts it to a “simple” obstruction. **In strangulation or closed-loop obstruction, the pain persists despite nasogastric aspiration.**

Insertion of an NG tube is extremely unpleasant. Many patients remember it as the most horrendous experience of their hospital stay (and would certainly resist fiercely any attempt at re-insertion). The procedure can be made much “kinder”. Soften the rigid tube by immersion for a minute or two in very hot water, spray the nostril of the patient with a local anesthetic, and lubricate the tube. There is no

advantage in connecting the NG tube to a suction apparatus; drainage by gravity is as effective and more “physiological”. Long naso-intestinal tubes are a gimmick with unproven benefits – requiring cumbersome manipulations and causing delay when operation is necessary.

When to Operate?

An hour or two of fluid replenishment is compulsory in the management of every patient. Re-assess your resuscitated patient: what is the pattern of pain now? Is there improvement on abdominal re-examination?

Immediate operation is required in a minority of patients: those who did not improve, those who experience continuous pain, or those with significant abdominal tenderness. Here abdominal X-rays usually show a complete obstruction. The probability of strangulation is high. Book them for an emergency operation.

An initial non-operative approach is often possible because most patients improve at first on the “drip-and-suck” regimen. It would be safe to bet, at this stage, that patients with radiological partial obstruction will eventually escape surgery, whereas those with complete obstruction will eventually visit the operating room. But how long is it safe to continue with conservative management? Some surgeons would abort the conservative trial at 24 hours if the patient fails to “open up”, because of the nagging concern about strangulation even in a benign-looking abdomen. Others are prepared to persevere, up to 5 days, in a carefully monitored patient. In the absence of an immediate indication for operation, we favor the use of an oral water-soluble contrast medium (e.g. Gastrografin) as soon as the diagnosis of SBO is made. Gastrografin, a hyperosmolar agent that promotes intestinal “hurry”, plays two roles: *diagnostic-prognostic* and *therapeutic*.

The Gastrografin “Challenge”

After the initial gastric decompression, 100 ml Gastrografin are instilled via the NG tube, which is then clamped for 2 hours. After 4–6 hours, a simple plain abdominal X-ray is obtained. This is not a formal radiological study under fluoroscopy. Make sure that your patient does not get barium (⊙ Chap. 4).

- Presence of contrast in the large bowel proves that the obstruction is partial. In most of these instances, the Gastrografin is passed per rectum as well. In partial SBO, Gastrografin is often therapeutic as it expedites the resolution of the obstructing episode.
- On the other hand, failure of Gastrografin to reach the colon within 6 hours indicates a complete obstruction. The probability of spontaneous resolution after

a failed Gastrografin “challenge” is very low; most of these patients will require surgery anyway so why not operate on them now?

- Another sign of failed Gastrografin challenge is the failure of Gastrografin to leave the stomach and enter the small bowel. It signifies a significant backpressure in the obstructed bowel and the need for an immediate operation.

So if we admit a patient during evening hours with suspected adhesive SBO, and without features mandating an immediate operation, we perform the Gastrografin challenge, and if by the morning the contrast has not reached the colon we would operate. Of course the results of the Gastrografin challenge test should be correlated with the whole clinical picture. Note that Gastrografin may pass across a chronic small bowel narrowing. Thus, for the obstructive episode to be considered “resolved” the abdominal symptoms and signs should disappear as well.

Additional Investigations

Clinical examination and plain abdominal radiographs, complemented by a Gastrografin challenge are sufficient to allow us to reach the correct decision in the majority of patients. Is additional imaging necessary or useful? *Ultrasonography* has been reported by enthusiasts to define accurately the site of obstruction and establish whether strangulation is present. It requires access to an expert, which most institutions lack. *Oral and IV contrast-enhanced CT* has been shown to accurately define the level of obstruction and identify a strangulated bowel segment (see ◉ Chap. 5). This, however, does not mean that CT is usually necessary. CT should be resorted to selectively in the following scenarios:

- History of abdominal malignancy. A CT finding of diffuse carcinomatosis with or without ascites could imply that symptomatic management is the correct option.
- “Virgin” abdomen (see below).
- Clinical picture not consistent with the usual partial adhesive SBO. *Paralytic ileus* may be easily confused with a partial SBO (◉ Chap. 42). There is air in the large bowel, the Gastrografin goes through but the patient remains symptomatic; fever and/or leukocytosis may be present. CT will document the underlying responsible cause for the paralytic ileus (e.g. acute appendicitis or diverticulitis).

Antibiotics

In animal models of SBO, systemic antibiotics delay intestinal compromise and decrease mortality. In clinical practice, there is no need for antibiotics in patients treated conservatively, and we operate whenever the suspicion of intestinal com-

promise is entertained. A single pre-operative dose of antibiotics is administered prophylactically; no postoperative antibiotics are necessary even if bowel resection has been performed (➤ Chaps. 7 and 42). The only indication for postoperative therapeutic administration would be long-standing bowel gangrene with established intra-abdominal infection.

The Conduct of the Operation

- The incision for abdominal re-entry has been discussed in ➤ Chap. 10 but we need to remind you to carefully avoid iatrogenic enterotomies with their associated postoperative morbidity. Finding your way into the peritoneal cavity may take time, but be patient for this is the longest part of the procedure. The rest is usually simpler.
- Find a loop of collapsed small bowel and follow it proximally. It will lead you to the point of obstruction just distal to the dilated obstructed intestine. Now deal with the cause of obstruction, be it a simple band or a bowel kink. Mobilize the involved bowel segment using sharp and blunt dissection with traction applied on the two structures to be separated.
- Resect only non-viable bowel or when the obstructed segment is impossible to be freed. Frequently, an ischemic-looking loop of bowel is dusky after being released. Do not rush to resect; cover the bowel with a warm, wet laparotomy pad and wait patiently; it will usually pink up within 10 minutes. If not, it requires resection.
- Concentrate on the loop which is responsible for the obstruction; there is no need to free the whole intestine by dividing all the remaining innocent adhesions. This maneuver may be cosmetically appealing, but adhesions lysed today will re-form tomorrow. As aptly stated by Timothy Fabian: “Lysis of all small bowel adhesions is not required because I believe that the bowel is ‘locked in the open position’ by these chronic adhesions.”
- Occasionally, multiple points of obstruction appear to be present with no clear area of demarcation between dilated and collapsed bowel. This is more common in patients after multiple operations for SBO or those with early postoperative SBO. In this situation the whole length of the gut has to be unraveled.

How to Manage an Iatrogenic Intestinal Injury During Adhesiolysis?

Transmural enterotomies should be repaired. We recommend a running, one-layered, absorbable, monofilament technique (➤ Chap. 13). Superficial serosal tears should be left alone. Areas where the mucosa pouts through the defect should be repaired with a running monofilament seromuscular suture.

Decompress or Not?

Attempting decompression of the proximal distended bowel represents a double-edged sword. On the one hand, excessive bowel distension impedes abdominal closure and contributes to postoperative intra-abdominal hypertension with its well-known deleterious physiological consequences (⦿ Chap. 36). On the other hand, bowel decompression may contribute to postoperative ileus and even cause peritoneal contamination. Most would decompress the distended bowel by gently milking its contents towards the stomach, from where it is sucked by the anesthetist. Milk the bowel very gently with your index and middle fingers, as obstructed bowel is thin-walled and very easily injured. Do not pull too hard on the mesentery. Palpate the stomach from time to time; if full, gently squeeze and shake it to restore patency of the NG tube. For a distal SBO, you may also milk the small bowel contents towards the collapsed colon. Be that as it may, “open” decompression through an enterotomy is unwise, given the risk of gross contamination. Needle decompression is not effective, as enteric juices are abnormally viscous. Obviously, open decompression should be performed if bowel is being resected – insert a “pool” sucker or a large sump drain connected to the suction through the proximal line of bowel transection and “accordion” the bowel onto your suction device.

Before closing, run the bowel again for missed enterotomies. Check for hemostasis, as extensive adhesiolysis leaves large oozing raw areas; intra-peritoneal blood promotes ileus, infection and more adhesion formation. Close the abdomen safely (⦿ Chap. 38). SBO is a risk for wound dehiscence and a “classic” for the M & M conference (⦿ Chap. 52).

Laparoscopic Approach

Wouldn't it be nice to relieve the SBO laparoscopically? And indeed laparoscopic lysis of the obstructing adhesions seems attractive because in many cases the cause of SBO is a single fibrous band. Easier said than done! The collective published experience (and that which is not published, which is more realistic) points to a higher risk of injury to the distended and friable obstructed intestine during the laparoscopic operation. This, of course, translates to a higher rate of septic complications and postoperative morbidity.

Should you wish to attempt laparoscopic approach do it *selectively* on the easier cases:

- First episode of SBO
- Abdomen not excessively distended
- Patient “stable” and able to endure a prolonged pneumoperitoneum – superimposed on an already distended abdomen

The first port should be placed through an open approach and away from the old incision. **Most importantly: do not be obstinate and know when to abort – before you create too many holes.**

Special Circumstances

The “Virgin” Abdomen

The patient presents with clinical and radiological features of SBO but with no abdominal wall scar of previous surgery. What to do? Evidence of a complete obstruction is of course an indication for a laparotomy but what with partial SBO? As with the adhesive partial obstruction, we recommend a Gastrografin challenge. In an obstruction caused by an intraluminal bolus, be it parasites or dry fruits, Gastrografin may disimpact the bowel. In these cases, we would recommend elective abdominal imaging to exclude an underlying cause. Non-resolving partial obstruction despite the Gastrografin challenge suggests a mechanical cause, such as a congenital band, an internal hernia, malignancy, inflammation or even an impacted bezoar. Laparotomy usually uncovers a treatable cause of obstruction. A pre-operative CT scan “just to find out what we’re dealing with” is not mandatory and may only delay the operation without changing its indication. But when in doubt, if readily available, and in the absence of clinical strangulation, it may be helpful. *Cecal carcinoma* is a typical cause of distal SBO in the “virgin” (or “non-virgin”) abdomen. The clinical presentation is commonly gradual and “smoldering”. Gastrografin may pass through into the cecum. In this case a CT would be diagnostic. SBO due to previously undiagnosed but suspected *Crohn’s disease* is an exception; here a CT may be very suggestive – indicating continued conservative therapy (☛ Chap. 24).

Intussusception

Although common in pediatric patients (☛ Chap. 32) is a very rare cause of SBO in adults. In adults the “leading point” is usually organic (e.g. neoplasm, inflammatory lesions), and seldom *idiopathic* as in children. Patients with small bowel or ileo-colic intussusception present with non-specific features of SBO (in a “virgin” abdomen) necessitating operative treatment. A specific pre-operative diagnosis can be obtained with ultrasound or CT, showing the *multiple concentric ring sign* (bowel within bowel), but won’t change what you need to do – operate and resect the involved segment of bowel. Although controversial, some would attempt reduction of intussusception when there are no external signs of ischemia or malignan-

cy and if after reduction no leading point is found (i.e., idiopathic intussusception) one could leave the bowel alone.

The Known Cancer Patient

A patient is admitted with SBO a year or two following an operation for gastric or colonic cancer. You should first attempt to obtain information about the findings at previous laparotomy. The more advanced the cancer then, the higher the probability that the current obstruction is malignant. Clinically, cachexia, ascites or an abdominal mass suggests diffuse carcinomatosis. These cases present a medical and ethical dilemma. On the one hand, one wishes to relieve the obstruction and offer the patient a further spell of quality life. On the other hand, one tries to spare a terminal patient an unnecessary operation. Each case should be assessed on merit. In the absence of stigmata of advanced disease, surgery for complete obstruction is justifiable. In many instances adhesions may be found; in others, a bowel segment obstructed by local spread or metastases can be bypassed. When diffuse carcinomatosis is suspected clinically or on CT scan, a reasonable option would be to insert a palliative, venting percutaneous gastrostomy, allowing the patient to die peacefully at home or in a Hospice environment.

Radiation Enteritis

Radiation treatment of abdominal or pelvic malignancies is not an uncommon cause of SBO; this usually develops months or even years after irradiation. A relentless course of multiple episodes of partial SBO, initially responding to conservative treatment but eventually culminating in a complete obstruction, is characteristic. There is also the uncertainty about the obstruction being malignant or adhesive in nature. One always hopes that it is adhesive, because SBO due to radiation injury is “bad news” indeed. When forced to operate for complete obstruction, one finds irradiated loops of bowel glued or welded together and onto adjacent structures. The paper-thin bowel tears easily. Accidental enterotomies are frequent, difficult to repair, and commonly result in postoperative fistulas. Short involved segments of bowel are best resected, but when longer segments are encountered, usually stuck in the pelvis, it is safest to bail out with an entero-enteric or entero-colic bypass. Post-operative short-bowel syndrome is common whatever the procedure. Long-term prognosis is poor – radiation enteritis is almost as bad as the malignancy the radiation had attempted to control (see also ● Chap. 43).

Recurrent Multiple Episodes of SBO

The patient is typically re-admitted every second month for SBO and has undergone, in the past, multiple operations for this condition. How should he be managed? We would treat him as any other patient presenting with adhesive SBO. Fortunately, most such episodes are “partial”, and responsive to conservative treatment. When complete obstruction develops, operative management is obviously necessary. Attempts at preventing subsequent episodes with bowel or mesentery plication or long tube stenting are recommended by some. The evidence in favor of such maneuvers is anecdotal at best. We do not practice them. Occasionally a patient develops obstruction early in the aftermath of an operation for SBO: this is a case par excellence for prolonged non-operative management, with the patient maintained on TPN until adhesions mature and the obstruction resolves as also discussed in ● Chap. 43.

A Word About Patience

You will understand by now that in some circumstances a laparotomy for SBO will be a long and difficult operation due to multiple adhesions or radiation enteritis for example. If you begin an operation expecting a quick and easy procedure and are then confronted by a nightmare abdomen the first thing you must do is reset your mental clock. Failure to do this may mean that you will attempt to rush the procedure and this inevitably leads to disaster with multiple inadvertent enterotomies, peritoneal contamination and ultimately an even longer and more dangerous procedure. When you enter such a disastrous abdomen unexpectedly, tell everyone immediately that the procedure is now going to take a few hours while you unravel all the loops necessary to get at the problem and fix it. And then take your time and fix it carefully and slowly.

Gallstone Ileus

Gallstone ileus develops typically in elderly patients with longstanding cholelithiasis. It is caused by a large gallstone eroding into an adjacent segment of bowel – usually the duodenum – that then migrates distally, until stranded at the narrow ileum. Presentation is usually vague as initially the stone may disimpact spontaneously – causing intermittent episodes of partial obstruction. You will never miss the diagnosis once you habitually and obsessively search for *air in the bile ducts* on any plain abdominal X-ray you order (● Chap. 5). The air enters the bile duct via the entero-cholecystic fistula created by the eroding gallstone. Treatment is operative and should be tailored to the condition of the patient. In frail and sick patients

deal only with the SBO: place an enterotomy proximal to the stone and remove it and search for additional stones in the bowel above – you do not want to have to re-operate! In patients who are younger and reasonably fit and well you may want to also deal with the cause of the problem – the gallbladder. Perform a cholecystectomy and close the duodenal defect.

Prognosis

Overall, about half the patients presenting with an adhesive SBO can be managed without an operation. About half the patients will suffer subsequent episodes of SBO, irrespective of the treatment – surgical or conservative. **The aim is therefore to operate only when necessary, but not to delay a necessary operation.**

The only thing predictable about small bowel obstruction is its unpredictability.

PAUL N. ROGERS

*“You can judge the worth of a surgeon by the way he does a hernia.”
(Thomas Fairbank, 1876–1961)*

Acute Groin Hernia


In the Western World many more hernias are now repaired electively than was formerly the case. In spite of this, surgeons are frequently confronted by acute groin hernias and it is important to know how to deal with them.

A word about terminology: groin hernias, inguinal or femoral, may be described as reducible, irreducible, incarcerated, strangulated, obstructed. This terminology can be confusing and the words, which have come to mean different things to different people, are much less important than the concepts that underlie the recognition and management of acute hernia problems. **The important concept to be grasped is that any hernia that becomes painful, inflamed, tender and is not readily reducible should be regarded as a surgical emergency.**

Presentation

Patients may present acutely in one of two ways:

- Symptoms and signs related directly to the hernia itself
- Abdominal symptoms and signs, which at first may not seem to be related to a hernia

The **first mode** of presentation usually means pain and tenderness in the irreducible and tense hernia. A hernia, which was reducible, may suddenly become irreducible. The problem is obvious as shown in  Fig. 22.1.

The **second mode** of presentation will be much more insidious. **Beware the vomiting old lady!** Treated at home for several days by the primary care physician as a case of gastro-enteritis she eventually comes under the care of the surgeons due to intractable emesis. By this stage she is dehydrated and in need of much resuscitation. It is surprisingly easy in these circumstances to miss the small femoral hernia barely palpable in the groin, trapping just enough small bowel as is required to



Fig. 22.1. “This must be strangulated, eh?”

achieve obstruction. No abdominal symptoms or signs are present and the plain abdominal radiographs are non-diagnostic. None of these difficulties saves you from the embarrassment of the following morning’s round when the hernia is discovered.

Hernias are still one of the commonest causes of small bowel obstruction (🔗 Chap. 21). A careful search must be made for them in all cases of actual or suspected intestinal obstruction. This may mean meticulous, prolonged and disagreeable palpation of groins which have not seen the light of day, let alone soap and water, for a long time. In most cases, however, the diagnosis is obvious with a classical bowel obstruction and a hernia stuck in the scrotum.

Beware the **Richter’s** hernia – typical of femoral hernias, where only a portion of the circumference of the bowel is strangulated. Because the intestinal lumen is not completely blocked, presentation is delayed and non-specific.

Preparation

Surgery for acute groin hernia problems should be carried out without undue delay, but these patients must not be rushed to surgery without careful assessment and preparation (🔗 Chap. 6). As we suggested earlier, some patients may be in need of quite a bit of resuscitation on admission to hospital.

Analgesia is an important part of the management of these patients. Opiate analgesia and bed rest with the foot of the bed slightly elevated may successfully manage a painful obstructed hernia of short duration. Gentle attempts at reduction of such a hernia are justified once the analgesics have taken effect. A successful reduction of the hernia means that emergency surgery at unsociable hours may be traded for a semi-elective procedure on the next available routine list – a benefit for both patient and surgeon. Note that manual reduction of the incarcerated hernia should be attempted only in the absence of signs of intestinal strangulation; it should be gently performed, to avoid “*reduction en masse*” – when the herniated bowel with the constricting ring are reduced together, with persisting symptoms of strangulation.

The Operation

Inguinal Hernia

An inguinal incision is a satisfactory approach. Even if a bowel resection is required it is possible to deliver sufficient length of intestine through the inguinal canal to carry this out.

The main difference in dissection in an emergency hernia operation compared to an elective procedure is the moment at which the hernial sac is opened. In the emergency situation the hernia will often reduce spontaneously as soon as the constricting ring is divided. The site of constriction may be the superficial inguinal ring, in which case the hernia reduces when external oblique is opened. It is recommended, therefore, that the sac be opened and the contents grasped for later inspection *before* the constricting tissues are released. If the hernia reduces before the sac contents are inspected it is important that they are subsequently identified and retrieved so that a loop of non-viable gut is not inadvertently left in the abdomen. Retrieval of reduced sac contents can be an awkward business via the internal ring and occasionally a formal laparotomy may be required to inspect matters properly. It is for these reasons that great care should be taken to secure the sac contents for inspection as soon as possible during the procedure.

If the hernial sac contains omentum only, then any tissue which is necrotic or of doubtful viability should be excised, ensuring meticulous hemostasis in the process. If, on the other hand, bowel is involved, then any areas of questionable viability should be wrapped in a warm moist gauze pack and left for a few minutes to recover. Irretrievably ischemic gut should be resected. If there is a small patch of necrosis that does not involve the whole circumference of the bowel then this can sometimes be dealt with by invagination rather than by resorting to resection. In this situation the injured bowel wall is invaginated by a seromuscular suture, taking bites on the viable bowel on either side of the defective area of gut.

Occasionally, particularly if a bowel resection has been necessary, edema of the herniated gut makes its replacement in the abdomen difficult. Maneuvers such as putting the patient into a marked Trendelenburg position and gently compressing the eviscerated gut, covered by a large moist gauze swab, will almost invariably allow the bowel to be replaced in the abdomen. It is possible to minimize the chances of this difficulty arising if care is taken during any bowel resection not to have any more gut outside the abdomen than is absolutely necessary. Very rarely the herniated viscera won't return to the abdomen without pulling on it from **within**; in such instances **La Rocque's maneuver** may be useful: extend the skin incision up and laterally; then extend the split of the external oblique aponeurosis and follow this with a muscle splitting incision of internal oblique and transverse muscles above the internal ring. Though this incision you enter the peritoneal cavity and reduce the hernial content simply by pulling on it from within.

The question of the type of hernia repair to be employed is a matter for the individual surgeon, with one proviso. In these days of tension-free hernia repair, it seems imprudent to place large amounts of mesh in the groin if necrotic gut has had to be resected. In this situation some other type of repair seems advisable to obviate the misery of infected mesh.

Femoral Hernia

You can approach the acute femoral hernia from below the inguinal canal, from above, or through it.

- With the **low approach**, you place the incision below the inguinal ligament, directly over the bulge. You find the hernial sac and open it, making sure to grasp its contents for proper inspection. Strangulated omentum may be excised, viable bowel is reduced back into the peritoneal cavity through the femoral ring. When the ring is tight, and usually it is, you can stretch it with your small finger, inserted medially to the femoral vein. You can resect non-viable small bowel through this approach and even anastomose its ends, but pushing the sutured or stapled anastomosis back into the abdomen is like trying to squeeze a tomato into a cocktail glass. Therefore, when bowel has to be resected, it is advisable to do it through a small right lower quadrant muscle splitting laparotomy (as for appendectomy).

- Some authorities favor an approach **via the inguinal canal** but we can see little merit in this approach, which must disrupt the anatomy of the canal and presumably risk subsequent inguinal hernias.

- Yet another approach is McEvedy's. This involves an approach to the extra-peritoneal space along the lateral border of the lower part of rectus abdominis. The skin incision may be vertical, in line with the border of rectus, or oblique/horizontal. A vertical skin incision has the merit of allowing extension to a point below the

inguinal ligament and this may be helpful in reducing stubborn hernias, allowing traction from above and compression from below. Once the space behind the rectus muscle has been accessed the hernia can usually be freed from behind the inguinal ligament. The peritoneum can be opened as widely as necessary to permit inspection of the contents of the hernial sac and to carry out intestinal resection if necessary.

All above approaches are reasonable provided the contents of the hernial sac are examined and dealt with appropriately. As with inguinal hernias the implantation of large amounts of mesh should be avoided in patients who have contamination of the operative field with intestinal contents. With this caveat the choice of repair is not different from what you would do in the elective situation.

Incisional Hernias

Incisional hernias are common but most are asymptomatic except for the unsightly bulge and discomfort they sometimes produce. **It is the small incisional hernias with the tight neck, which become acutely symptomatic – incarcerating omentum or intestine.**

The presentation is well known to you: an old “silent” hernia or abdominal scar, which has now become painful. When bowel has been incarcerated there may be associated symptoms of small bowel obstruction (► Chap. 21). The hernia itself is tense, tender and non-reducible. It is important to distinguish between intestinal obstruction caused by the incisional hernia or simply associated with it. The latter situation, which is not uncommon, implies that the patient suffers SBO due to adhesions for example, and the obstructed and distended loops of bowel invade the long-standing incisional hernia. On examination, the bowel-filled tender hernia may mimic incarceration. **It is for this reason that the contents of any hernia associated with obstruction must be examined carefully at operation to ensure that the hernia truly is the cause of the obstruction.** (This applies to all kinds of hernias. We recall a case of obstruction that was addressed by reducing and repairing a tense femoral hernia, only for the obturator hernia, which was the true cause of the obstruction, to be discovered at laparotomy many days later when the patient failed to recover from the first operation.)

Any “acute” incisional hernia is a surgical emergency. This is also true with other types of abdominal wall hernias, such as paraumbilical or epigastric ones. (It should be noted that epigastric hernias rarely, if ever, cause trouble. They only contain extraperitoneal fat from the falciform ligament, and for this reason need not be repaired routinely in the absence of symptoms.) At operation the hernial sac has to be entered to evaluate the incarcerated contents that are to be reduced or resected depending on the findings. **The surgical findings should explain the clinical pre-**

sentation. For example, if you do not find strangulated omentum or bowel in the sac, you have to retrieve the whole length of the intestine in search for distal SBO. If you find pus within the sac you have to look for the source. We have seen patients operated upon for a “strangulated incisional hernia” when the underlying diagnosis was perforated appendicitis.

After the contents of the hernia have been dealt with identify the fascial margins of the defect. Use your conventional “best” repair but do not forget that placing a mesh in a contaminated field is potentially problematic. Bear in mind also that leaving non-absorbable mesh in contact with the gut leads to difficulties and disasters later. In a critically ill patient, when the repair is deemed complex or is judged to significantly increase the intra-abdominal pressure – we would simply close the skin – leaving the patient with a large incisional hernia. **Remember – patients do not die from the hernia but from its intestinal complications or a closure that is too tight** (🕒 Chaps. 36 and 38).

“Always explore in cases of persistent vomiting if a lump, however small, is found occupying one of the abdominal rings and its nature is uncertain.” (Augustus Charles Bernays, 1854–1907)

Acute Mesenteric Ischemia

MOSHE SCHEIN · PAUL N. ROGERS

*“Vascular surgery is peculiar because, above all, it is mainly surgery of ruins.”
(Cid dos Santos)*

“Occlusion of the mesenteric vessels is regarded as one of those conditions of which the diagnosis is impossible, the prognosis hopeless, and the treatment almost useless.” (A. Cokkins, 1921)

Acute mesenteric ischemia usually involves the region supplied by the superior mesenteric artery (SMA). Thus the small intestine is predominantly affected but the right colon, which is also supplied by the SMA, can be involved as well. Isolated ischemia of the colon, which is much less common, will be discussed separately under the heading of *ischemic colitis* in ● Chap. 24.

The Problem

The problem is a sudden reduction in arterial perfusion of the small bowel, which quickly leads to central abdominal pain. If left untreated, the process progressively involves the muscular layer of the intestines and it is only after some hours, when the serosa is affected, that peritoneal signs appear. In an attempt to simplify matters let us divide acute mesenteric ischemia (AMI) into three types, which are almost equally common:

- **Thrombotic:** due to an acute arterial thrombosis, which usually occludes the orifice of the SMA, resulting in massive ischemia of the entire small bowel plus the right colon – the area supplied by the SMA.
- **Embolic:** due to a shower of embolic material originating proximally – from the heart (atrial fibrillation, post myocardial infarction, diseased valve) or an aneurysmal or atherosclerotic aorta. Emboli usually lodge in the proximal SMA, but beyond the exit of the middle colic artery; therefore – as a rule – the most proximal segment of proximal small bowel is spared, along with the transverse and (probably) the right colon. Emboli tend to fragment and re-embolize distally, producing a patchy type of small bowel ischemia.
- **Non-occlusive:** due to a “low-flow state”, in the absence of documented arterial thrombosis or embolus. Note, however, that an underlying mesenteric atherosclerosis may be a precipitating/contributory factor. The low-flow state is a product of low cardiac output (e.g. cardiogenic shock), reduced mesenteric

flow (e.g. intra-abdominal hypertension) or mesenteric vasoconstriction (e.g. administration of vasopressors) – usually, however, it is due to a combination of these factors, developing in the setting of a pre-existent critical illness.

Mesenteric venous thrombosis can also produce small bowel ischemia. The features and management of this entity differ drastically from the other three. It will be discussed separately below.

The problem is that in clinical practice, outside the textbook, mesenteric ischemia is usually recognized when it has already led to intestinal gangrene. At that stage the Pandora's box of SIRS (systemic inflammatory response syndrome) has been opened and even removal of the entire gangrenous intestine will not always stop the progression to organ failure and death. Even if such physiologic consequences can be overcome the patient commonly becomes an “intestinal cripple”, suffering from the short bowel syndrome.

Assessing the Problem

Typically, the early clinical picture is **non-specific – the patient complains of severe abdominal pain – if he is able to complain at all – and the doctor finds little on physical examination.**

There may have been preceding symptoms of a similar sort of pain developing with meals and accompanied by weight loss, suggesting pre-existing *mesenteric angina*. History or evidence of systemic atherosclerotic vascular disease is almost the rule in patients with mesenteric thrombosis while a source for emboli, such as atrial fibrillation, is usually present in patients with mesenteric embolism. Low-flow state patients are commonly moribund due to underlying critical disease.

Nausea, vomiting, diarrhea and hematochezia come late, if ever. You must resist the natural temptation to ascribe patients' non-specific symptoms to some other benign condition such as gastroenteritis, unless the associated history and symptoms for the alternate explanation are fully present. **And by the way – in the elderly – the diagnosis of “acute gastroenteritis” is very rarely the final diagnosis.**

Physical examination in the early stages of the process is treacherously benign; peritoneal irritation appears too late, when the bowel is already dead.

Plain abdominal X-rays early in the course of the illness are normal. Later there may be a pattern of adynamic ileus, with visible loops of small bowel and fluid levels, but with gas and feces seen within the normal colon and rectum. Likewise, **laboratory studies** usually are normal until the intestine loses viability; only then do leukocytosis, hyperamylasemia, and lactic acidosis develop.

The bottom line is that initially in acute mesenteric ischemia the physical examination and all commonly available X-rays and blood tests may be *normal*. At this stage, entertaining the diagnosis of mesenteric ischemia, you have two options: the first is to enter in the chart “abdominal examination normal; mesenteric ischemia cannot be ruled out; will re-assess later”. The second option is to order a CT scan, which has replaced mesenteric angiography as the initial, “screening” imaging modality in AMI. Although angiography is more specific and accurate, surgeons have been reluctant to offer such an invasive procedure in patients with a non-specific clinical picture. Unfortunately, the first option is the still common in the community – leading to procrastination, late diagnosis and treatment, and a very high mortality rate.

Computed Tomography

To be diagnostic the examination should include oral contrast and intravenous contrast (“CT angio”), with the focus on two areas: the bowel wall and mesenteric vessels. The commonest finding is bowel wall thickening, which is, however, non-specific. The bowel wall may appear low in attenuation due to edema or, when sub-mucosal hemorrhage is present, it may appear of high attenuation due to the blood products. Visualization of the dynamic enhancement pattern of the affected bowel loops may improve diagnosis. Affected bowel loops may demonstrate absence of enhancement, delay in enhancement, or persistent enhancement when compared to unaffected loops. Pneumatosis is an uncommon but specific sign. It is due to intraluminal gas dissecting into the friable bowel wall. “CT angio” can also visualize emboli within the SMA or thrombosis of the latter at its origin. From this description one can easily appreciate that even the CT findings in this condition are subtle and easy to miss.

Mesenteric Angiography

To be beneficial the angiogram should be performed before the bowel has become gangrenous. The clock is ticking; every minute passing reduces the chances of the bowel and the patient surviving. Note that an “acute abdomen” with peritoneal signs is a contra-indication to angiography. The radiologist should start with biplanar angiography (i.e. including a lateral view to show the origins of the SMA and the celiac axis). An *occluded ostium of the SMA denotes thrombosis* and calls for an immediate operation – unless there is evidence of a good collateral inflow – the angiography providing the road map for vascular reconstruction. When the ostium is patent the radiologist advances the catheter into the SMA. *Emboli* lodge distal to

the takeoff of the middle colic artery, produce a smooth filling defect on the background of a normal SMA, and can be multiple.

Non-operative Treatment

In the absence of peritoneal signs attempts at non-operative treatment are justified – tailored to the clinical/CT/angiographic findings. The selective diagnostic angiography can now become therapeutic – infusing a thrombolytic agent to lyse the thrombus or embolus with or without adding *papaverine*¹ to relieve the associated mesenteric vasospasm. Cessation of abdominal symptoms together with angiographic resolution means that the emergency is over; pre-existing mesenteric artery stenoses can be addressed electively – if indicated.

In the event of **non-occlusive mesenteric ischemia** the approach involves attempts at restoring compromised hemodynamics. To relieve associated arterio-spasm, a selective intra-arterial infusion of a vasodilator, such as *papaverine*², has been advocated. The few champions of this method have reported “favorable responses”. When **emboli** are the cause, after successful trans-catheter therapy, long-term anticoagulation is indicated. A final point – while rushing to the arteriography suite remember to ensure adequate hydration of your patient to oppose the nephrotoxic effect of the contrast media, which may be used in large quantities.

Operative Treatment

As we told you above – peritoneal signs are an indication *not* to do arteriography but to operate; the same applies to the failure of the non-operative regimen discussed above. Through a midline incision assess the viability of the intestine. In general there are two main possible scenarios: one is the bowel *being frankly gangrenous* (“dead”), the second when the bowel *appears ischemic* (“dusky”) and of questionable viability.

— **Frank gangrene.** Frank gangrene of the *entire small bowel* is usually combined with the same problem of the right colon and signifies *SMA thrombosis*. Theoretically, a sporadic patient could survive resection of his entire small bowel and right colon. He may even tolerate a duodenocolic anastomosis while being nutritionally supported at home with total parenteral nutrition (TPN). But the eventual mortal-

¹ That intra-arterial *papaverine* infusion is beneficial is a myth – originating in a retrospective study from one New York hospital more than 20 years ago, and since perpetuated in reviews and texts, but never further corroborated by a meaningful clinical experience.

² See previous footnote.

ity of such an exercise in the average elderly vasculopath approaches 100% and the cost is immense. Our recommendation to you when involved in a similar situation is to walk out to talk to the family, explain that anything done will only increase the suffering of their beloved, return and close the abdomen over the dead bowel. Provide a lot of morphine and comfort. Frank gangrene of a *shorter segment of small bowel* or multiple segments-usually denotes *embolism*. After excising all dead segments carefully examine the remaining bowel. Measure it: how long it is? **Only about half of patients left with less than 1 meter (3 feet) of small bowel will live without TPN (saving the ileocecal valve improves the prognosis)**. Now, observe the remaining bowel. Is it truly non-compromised? Are the mesenteric arcades pulsating well? Feel the SMA at its root – is it vigorously pulsating?

— **Dusky bowel.** When you are not happy with the remaining bowel, or when the bowel is not dead but appears ischemic and of questionable viability from the start, proceed as follows. Wrap the bowel in warm, saline-moistened sponges and wait 15 minutes. Unscrub and have a coffee; surgeons cannot stare at an inactive field for that long without starting to fiddle. Failure of the bowel to pink-up mandates its resection. When the length of remaining normal-looking bowel reduces towards 1.5 meters (5 feet) it may be advisable to leave the doubtful bowel in situ, to be re-examined during a re-look operation (see below). Saving even a short segment of small bowel may improve the chances of a reasonable life quality. Some authors recommend the use of hand-held Doppler to examine the perfusion of the anti-mesenteric side of the bowel; others use intra-operative fluorescein angiography.



Fig. 23.1. How much should I resect?"

You may choose to use such modalities if available to you but your clinical judgment should be just as good as any gimmick (● Fig. 23.1).

Adjunctive Vascular Procedures

The ideal setting surgically to improve the perfusion of ischemic small bowel is when the operation follows emergency arteriography (plus failed angiographic therapy) and the bowel is viable or doubtful. Obviously, when the bowel is dead it cannot be revived! Arteriography serves as a road map; when the SMA is occluded – thrombosed at its origin – a vein or graft bypass, antegrade or retrograde, is indicated to re-perfuse the SMA. Such a scenario is, however, extremely rare; more commonly you'll encounter a picture of SMA embolism. Palpate for the SMA just at the base of the mesocolon; if non-pulsatile you'll find it, after incising the peritoneum, to the right of the large/blue superior mesenteric vein. After obtaining control, open the artery transversely and pass up and down a small Fogarty embolectomy balloon catheter. You may conclude the procedure with a shot of urokinase injected distally to lyse the clots in the distal branches, which are inaccessible to your embolectomy balloon catheter.

To Anastomose or Not?

You should be very **selective** in attempting an anastomosis following any resection of devitalized intestine. The patient has to be hemodynamically stable and his nutritional status at least fair. To be hooked-up the remaining bowel has to be unquestionably viable and the peritoneal cavity free of established infection. Most crucially, the cause of ischemia has to be solved. Another factor strongly bearing on your decision is the length of the remaining bowel and its predicted postoperative function. When more than half of the small bowel is resected, the resection is considered “massive”. Restoring intestinal continuity in such cases would lead to poorly tolerated and intractable diarrhea. And finally, the chief reason not to anastomose the bowel is the possibility that further ischemia may develop.

We recommend, therefore, that whenever the above-mentioned favorable factors are absent, or when resection is “massive”, the two ends of the resected bowel should be exteriorized as an end-enterostomy and mucus fistula – if possible via one abdominal wall site (this would allow a subsequent re-anastomosis without a major laparotomy). The postoperative appearance of the stomas will accurately reflect the status of the remaining bowel.

Second-Look Operations?

A routine planned “second-look” re-operation allows direct re-assessment of intestinal viability at the earliest possible stage, before additional mediators of SIRS have been released, and in a way that aims to preserve the greatest possible length of viable intestine. This concept, which in theory at least is attractive, motivates many surgeons to re-explore their patients routinely after 24 to 48 hours. The finding of completely normal bowel at re-operation is of course reassuring but the anastomosis may still leak 5 days after it has been observed to be intact. If you plan a “second look” operation there is no need to close the abdomen at the end of the first procedure; instead, treat the abdomen as a laparostomy (◆ Chap. 38) until re-exploration; relieving any intra-abdominal hypertension to further improve mesenteric blood flow.

An alternative option is to close the abdomen, leaving a few laparoscopic ports adjacent to the bowel, through which a laparoscope may subsequently be inserted to assess the status of the bowel.

To sum up – it appears that in most patients who at the end of the operation do not have stomas, a second-look procedure is indicated. Those with viable stomas, who are otherwise well, can be observed.

Mesenteric Venous Thrombosis

This is a rare condition, which occludes the venous outflow of the bowel. The clinical presentation is entirely non-specific, with abdominal pain and varying gastrointestinal symptoms that may last a few days until eventually the intestines are compromised and peritoneal signs develop. Mesenteric venous thrombosis may be idiopathic (i.e. the doctor is an idiot – ignorant of the underlying reason) but commonly an underlying hypercoagulable state (such as polycythemia rubra vera) or sluggish portal flow due to hepatic cirrhosis, are present.

Typically, many of these patients are admitted to “medicine” with a surgeon consulted much later – to operate for non-viable bowel. However, an early trip to a contrast-enhanced CT scan may achieve an earlier diagnosis, helping to avoid an operation altogether and improve survival.

Characteristic findings on CT represent a **triad** of:

- A hypodensity in the trunk of the superior mesenteric vein
- Associated intra-peritoneal fluid
- Thickened segment of small bowel

With the above findings, and in the absence of peritoneal signs, full systemic anticoagulation with heparin may result in a spontaneous resolution of the process.

The role of systemic thrombolysis is not clear. Failure to improve or the development of peritoneal signs mandate an operation.

At surgery, you'll find some free serosanguinous peritoneal fluid; the small bowel will be thick, edematous, dark-blue but not frankly "dead", with the involved intestinal segment poorly demarcated. Arterial pulsations will be present and thrombosed veins seen. You'll need to resect the affected bowel. As to whether to anastomose or not and considerations about the need for a "second look" – apply the same judgement as discussed above for arterial ischemia. Postoperative anti-coagulation is mandatory to prevent progression of the thrombotic process. Adding a venous thrombectomy is advocated by some, so is intra-operative thrombolysis; the real benefits of these controversial approaches are unknown.

Conclusion

In most places the mortality rate of acute mesenteric ischemia is still prohibitive. Why? Because surgeons **fail** to do the following:

- Suspect ischemia before intestinal gangrene develops
- Proceed with diagnostic/therapeutic angiography
- Improve intestinal perfusion during laparotomy
- Exteriorize the bowel or execute a second-look operation

If you wish to see survivors of this horrendous condition – be aggressive.

On the other hand, the presentation of these patients is so non-specific and the CT findings so subtle that if an aggressive approach is taken, many patients with self-limiting minor abdominal complaints will have unnecessary investigations and operations, and yet cases will still be missed. Furthermore these patients rarely have simple pathology. They commonly suffer from multisystem disease and even in receipt of optimal care they will have a high mortality. Regrettably, in the majority of patients this condition seems likely to remain an agonal complaint.

It is almost impossible to increase the current M & M associated with acute mesenteric ischemia.

"The man is as old as his arteries." (Thomas Sydenham, 1662–1689)

Inflammatory Bowel Disease and Other Types of Colitis*

PER-OLOF NYSTRÖM

When an internist wants you to operate urgently on his IBD patient assume that the operation was indicated at least a week ago...

Ulcerative colitis (UC) is a disease of the colonic mucosa only. **Crohn's disease (CD)** involves all layers of the bowel and can appear anywhere along the intestinal tract. Because of this difference UC is curable with proctocolectomy whereas CD is not amenable to surgical cure. For CD, surgical excision of the affected bowel segment serves only to reduce symptoms, as nearly all patients will suffer recurrence. The need for emergency surgery in inflammatory bowel disease (IBD) patients has drastically diminished in recent years because patients are diagnosed earlier and are better controlled by gastroenterologists. In places where specialized care of IBD is lagging behind, emergency surgery is more common.

About a third of UC patients will eventually require an operation whereas nearly all with CD will have one or more operations during their lifetime. Most general surgeons will not attend more than a few cases per year and patients may be referred too late – unless gastroenterologists and surgeons co-operate and share a common philosophy of what medical and surgical treatments can and should provide. Gastroenterologists should know and appreciate that skilled surgery has a high rate of success when medical treatment fails. But surgeons must appreciate that an operation may cripple the patient and turn some into intestinal invalids.

Acute Attack of UC

There was a time when mortality was high for acute attacks of UC – both with medical and surgical treatment. It was British gastroenterologists and surgeons who led the way to almost abolish mortality by establishing criteria to measure the severity of the attack and timing for operation. **The simple wisdom is that failure of medical treatment should be recognized early – being an indication for surgical treatment.** Another development has almost abolished emergency colectomy for

* A comment by the Editors on neutropenic enterocolitis and ischemic colitis is found at the end of the chapter.

UC as we now are able to schedule the colectomy semi-electively for nearly every patient. The skilled gastroenterologist is able to decide early when medical treatment is failing and the colectomy can then be discussed with the patient without haste. This is the standard of care the surgeon should opt for. Thus, the need for an emergency colectomy for UC in your practice implies a failure on the part of the treating team.

Assessment of the Acute UC Patient

When asked to review a case of acute UC for colectomy you should consider the following:

- **How extensive is the colitis and how badly is the mucosa affected?** The acute attack has usually been progressing for several weeks. The patient has had ambulatory with oral steroids, then admitted to hospital and given parenteral steroids because of deterioration. Some gastroenterologists are unwilling to do a full colonoscopy for an acute attack, fearing perforation. However, a sigmoidoscopy suffices to demonstrate ulcerations. From plain abdominal films it is often possible to tell how extensive the colitis is by demonstrating no bowel contents in the affected colon. A little air injected through a rectal catheter will function as a contrast medium – giving a good demonstration of the extent of the colitis and often disclosing the presence of ulcerations (◉ Fig. 24.1). The so-called **toxic megacolon**,



Fig. 24.1. “Pancolitis, eh? Shouldn't we increase the steroids and add Imuran?”

Table 24.1. Grading of ulcerative colitis

	Mild/moderate colitis	Severe colitis
Temperature	<38°C	>38°C
Pulse	<90/min	>90/min
Diarrhea	5 per day or less	6 per day or more
Blood in stool	None or little	Large amounts
Anemia	None or mild	Severe (75% or less)
Albumin	>3 g/l	<3 g/l
Abdominal pain	None or some	Severe

an extreme dilatation and impending perforation of the colon with systemic toxicity, is a problem of the past. It should never be allowed to happen in a patient under proper care, where an operation will have been scheduled long before such destruction of the colon has happened.

— **How has the colonic pathology affected the patient's physiology?** Colitis restricted to the left colon usually produces minor signs of systemic inflammation and wasting. Most such patients are not candidates for surgery unless it is obvious that the colitis cannot be controlled after extensive medical treatment has failed. We have seen, however, acute attacks limited to the left colon causing perforation of the sigmoid colon. In general, the extent and severity of colitis correlate with the physiological derangement of the patient. There will be fever, leukocytosis, and increased levels of C-reactive protein. The hemoglobin and albumin may drop significantly, often over just a few days. The patient has deteriorated while on high parenteral dose of steroids and now his physiology is breaking down. It is time to decide on the operation. 📍 Table 24.1 will allow you to better distinguish between mild/moderate colitis and a severe one – which should be taken seriously. The APACHE II score is also useful to estimate the severity of illness in this situation (📍 Chap. 6).

— **Are there complications of colitis?** We pay little attention to the number of bowel movements because the actual counts are so dependent on tenesmus and urgency. There are patients who have 20 or more bowel movements per day because of the urgency but the more common figure is around 10. Blood in the stools is common, but try to get some objective information about how often and how much, and compare with the hemoglobin concentration. Is the patient able to compensate for the blood loss? If not, it strengthens the indication to operate. Bleeding that requires several blood transfusions is an indication for urgent colectomy; fortunately, this has become very rare today. Considering that there may be extensive ulcerations of the mucosa it is remarkable that systemic sepsis with positive blood cultures is relatively rare. Associated pneumonia is occasionally present. With secondary infections there is no haste as it is better to treat the infection with antibiotics and do the colectomy

a few days later. We have seen several cases manifesting venous thromboembolic phenomena. One should probably view such complications as indications of that the host defenses and homeostasis are breaking down and that colectomy is necessary. Thrombosis and especially thromboembolism is a troublesome complication as its treatment with heparin may increase the bleeding from the bowel and the colectomy in itself is a distinct risk factor for further thromboembolism.

— **What is the general status of the patient?** One must evaluate how the colitis and its treatment have affected the patient over an extended period of time. It should be unusual to find obvious stigmata of cortisone treatment apart from some edema and acne. If there is a moon face, muscle atrophy, hip adiposity and cutaneous striae, the patient has either been treated too long or is too sensitive to cortisone. Any such patient, in our mind, should have a colectomy to get him off steroids. How alert is the patient? Is he out of bed, reading or watching TV? At the first consultation the patient may deny the operation as an alternative but as soon as the malaise associated with the disease activity appears, the patient is usually happy to consent to the operation. Both the short-term and the long-term consequences of the colitis should be considered: **the worse the previous course has been – the stronger the indication for a colectomy during the current attack.**

— **What is the nutritional status of the patient?** Withholding food and drink does not improve the acute attack but eating increases the diarrhea and most patients are unable to eat properly in the later stages of an acute attack. In general, in IBD patients, enteral nutrition is preferred over the parenteral route but total parenteral nutrition may be indicated in the setting of a severe attack prior to the operation.

The Operation for Acute Colitis

Schedule the operation for the next day if the patient is in reasonably good condition but do not delay it further. No pre-operative bowel preparation is necessary. Antithrombotic prophylaxis with low molecular weight heparin should be given as for elective operations. Single dose antibiotic prophylaxis is adequate. Do not forget to “cover” the peri-operative phase with hydrocortisone.

The operation for acute colitis is **total abdominal colectomy**. In younger or leaner patients the colectomy is easy and should take about 2 hours; in a middle-aged male it can be substantially more difficult. There are often only minor signs of inflammation on the exterior of the colon; there may be some thickening of the wall and tortuous inflammatory capillaries on its surface. The segmental blood vessels may be enlarged due to the rich blood flow. You can begin the dissection on the right or left side as is convenient. Incise the peritoneal reflections laterally and identify the plane between the mesocolon and the retroperitoneal fascia. Divide the gastrocolic ligament so the omentum is removed with the colon but the gastroepiploic

artery is preserved for the stomach. Once the colon has been freed laterally it is time to divide the segmental arteries. Divide the ileum about 5 cm from the ileocolic junction and the rectosigmoid junction just above the promontory with the linear stapler. It is unnecessary to oversee the staple line. There is no role for drains. The closed terminal ileum is brought out through an ostomy hole through the rectus abdominis muscle on the right side. The site should have been marked before the operation. Avoid suturing the ostomy or the ileal mesentery to the abdominal wall which only creates more adhesions. Close the abdomen and then fashion the stoma. Cut the bowel 5 cm above the skin, evert and suture to the skin – which results in a 2.5-cm long protrusion.

A **proctocolectomy** for an acute attack of ulcerative colitis belongs to history, as does the proctostomy with a long rectal remnant brought out through the wound or a separate incision. The remaining in situ inflamed rectum is too small to keep the patient sick. After the operation the diverted rectum becomes silent but it is a good idea to finish the operation by turning the patient on the side and evacuate the rectum transanally because the retained blood may suppurate and cause problems in the postoperative course.

Your patient may be young and relatively well and the operation may appear a “piece of cake” to you. But resist the temptation to do anything more than a total abdominal colectomy by adding an ileo-rectal anastomosis or even a restorative pouch ileoproctostomy. Those patients are catabolic and on steroids – the punishment for anastomotic complications is extremely severe!

The colectomy for acute colitis is a delicate operation in a sick patient who, because of the systemic inflammatory response syndrome, is more likely to sustain postoperative complications. Watch carefully over these patients. The colectomy will be followed by a second **restorative procedure** within the next few months. The surgeon who does the colectomy can greatly ameliorate the second procedure. Most importantly, avoid the adhesions that can be extensive when all four quadrants of the abdomen have been touched. Precise surgery in embryonic planes with minimal blood loss is important. Avoid suturing of peritoneum or stoma. A sheet of Seprafilm in the pelvis covering the closed rectal stump will do wonders to avoid the adhesions of the pelvis, particularly important in females who plan to have children.

Emergency Surgery for Crohn's Disease

The need for an emergency operation in CD should be rare indeed. There are a few patients with acute colitis, which is clinically indistinguishable from acute UC. They are handled as acute colitis. Most of the time, however, the course and anatomical appearance of the colitis suggest that it is CD rather than UC. When the small bowel is involved a diagnosis of CD is obvious.

Surgery for CD demands a lot more consideration because the patient will not be cured, and choosing the operation and its timing makes a difference to the future course. There is a growing understanding that repeated surgery contributes, and perhaps is the major factor behind the phenomenon of “CD cripples” and, even, the premature death of patients with this disease. It seems, however, that patients with recurrent or chronic symptomatic CD, like patients with chronic arthritis, slowly waste over the years, a wasting to which steroids and repeated “amputations” of bowel contribute. For those of us who believe that any operation marks the patient permanently, biologically and socially, it is a cause of concern that some patients with CD will have many operations during their life. It must be stressed, however, that for the vast majority of the cohort, timely surgery is part of the optimal treatment. **There are a few other instances, excluding acute colitis, when emergency surgery is considered in CD patients: suspected appendicitis, small bowel obstruction and intra-abdominal abscess.**

Acute Appendicitis

If you operate for suspected acute appendicitis (◉ Chap. 28) and encounter changes that are compatible with CD of the terminal ileum and cecum (e.g. serosal inflammation, thickened mesentery), what then? If the cecum is involved but the appendix appears normal, the best option is probably to leave it alone as appendectomy may result in an enterocutaneous fistula. The patient is then treated with steroids. An ileocecal resection at that situation may provide you with the histological diagnosis but is unnecessary or could at least have been postponed for several years. Almost every patient with an ileocolic resection will develop recurrent Crohn’s inflammation of the anastomosis, usually within a year, yet another reason not to be blasé about the resection. Let’s not forget that CD patients may develop acute appendicitis, which is treated with an appendectomy.

Small Bowel Obstruction (SBO)

SBO is common in patients with CD. Usually it is due to a narrow segment of diseased terminal ileum but it may be caused by a more proximal stricture of a skip lesion. **When the diagnosis of CD is known you should treat the obstructive episode conservatively;** SBO in CD is usually “simple obturation” of the narrow segment and resolves spontaneously – at least until the next exacerbation. In the absence of a previous diagnosis of CD a careful history may reveal the typical previous abdominal symptoms, including episodes of transient obstruction, and systemic signs of inflammation that are compatible with a diagnosis of CD. A *CT*

scan (showing typical segmental bowel wall and mesenteric thickening) rather than a small bowel follow-through can give the diagnosis. Conservative management of SBO is discussed in ◉ Chap. 21; steroids will be required.

If you operate for SBO and find an inflamed and thickened terminal ileum, findings compatible with CD, what then? It is much better and simpler to operate on CD in the elective situation, when the bowel is empty and its inside can be inspected for strictures with intraoperative endoscopy through the wound. But now the bowel is obstructed and distended. “Run” the bowel to identify any skip lesion that is more proximal and make sure there is a “passage” through it, i.e., it is non-obstructing. Record any proximal skip lesions in your notes but leave them untouched. Your task is to deal with the acute SBO. Obstruction in CD is very rarely complete or strangulating (◉ Chap. 21); therefore, your best option is to close up the abdomen and start the patient on steroids – thus sparing his bowel.

Rarely you’ll be called to operate upon an acutely obstructed patient who failed conservative treatment. Here the operative options are: resection of the ileocecal region, stricturoplasty or a temporary proximal loop ileostomy. When the last option is adopted the inflammation is medically treated until the acute phase resolves and an elective operation can deal permanently with the affected bowel.

Intra-abdominal Abscess

This represents a more serious pathology. There is rarely a need for emergency surgery and it is better to convert the acute situation to a semi-elective case. Most abdominal abscesses in CD patients can be drained percutaneously (◉ Chap. 44). The patient is then treated with antibiotics, steroids and nutritional support to allow the resolution of the acute phase before undergoing elective resection of the involved bowel – the source of the infection. Complex abscesses, which fail percutaneous drainage, should be operated upon; the involved segment of bowel has to be resected. Whether to restore bowel continuity with an anastomosis, or exteriorize the bowel ends as a double-barrel stoma, depends on the condition of the patient, his abdomen and the bowel (◉ Chap. 13). Re-operation on CD patients with one or more previous operations can be very difficult; there is also a higher risk of anastomotic failure and postoperative enteric fistula. The complex abscess marks a patient with such increased risk.

Clostridium difficile Colitis

This is not considered an IBD but is an acute colitis. With the prevalent overuse and misuse of antimicrobial agents by physicians and surgeons, *Clostridium*

difficile colitis (CDC) is a common problem in hospitalized patients. CDC classically presents with diarrhea and abdominal pain following a history of antibiotic intake, with independent risk factors including age over 65, cephalosporin use, use of multiple antibiotics, prolonged hospital stay, and use of antibiotics for more than a week. In fact, the more antibiotics you give, the higher is the chance of a patient developing CDC, but it can develop even after one dose. **The tragedy is that, commonly, patients die from CDC after having received antibiotics for dubious indications.**

The clinical spectrum of CDC is broad, ranging from mild diarrhea on one side, to colonic perforation of the other. The gold standard for diagnosis is the stool cytotoxin assay for toxin B; however, the test results may take 1–3 days. Therefore, many institutions use the latex agglutination test, which has a faster return time but is less sensitive. Beside this, fiberoptic sigmoidoscopy, demonstrating the typical pseudo-membranes and ulceration, is an excellent test. **The preferred medical therapy for CDC includes oral metronidazole or oral vancomycin and, if the patient is unable to take oral medications, intravenous metronidazole. These therapies are highly effective in most patients, with only a minority eventually requiring surgical therapy.** Established indications for laparotomy in CDC patients include systemic deterioration and peritonitis despite optimal medical therapy.

Another subgroup of CDC patients present from the beginning with an “acute abdomen”, exposing them to a highly morbid and unnecessary exploratory laparotomy, which discloses viable and not perforated CDC. Therefore, **remember** that in any patient who presents with an “acute abdomen”, with a history of recent or current antibiotic intake, and without findings that mandate an immediate exploration (e.g., free air), CDC should be urgently excluded. Timely diagnosis of CDC through the use of sigmoidoscopy and/or CT scan – showing diffuse colonic wall thickening and colonic dilation – will allow adequate medical treatment and could spare the critically ill patient an unnecessary and risky operation.

At operation for fulminant CDC that failed conservative treatment, the bowel appears gray and paper-thin; “sealed” mini-perforations may be present. There is no doubt that subtotal colectomy is the procedure of choice when the colon is non-viable or perforated. It is also a reasonable option, albeit unproven, when operating on a fulminant CDC that failed to improve on medical treatment. But whether a subtotal colectomy is advisable during an exploratory laparotomy in a critically ill patient for an acute abdomen, with a surprise operative finding of an undiagnosed CDC, is unknown. It appears that the construction of any bowel anastomosis is contra-indicated when operating on CDC; the ileum should therefore be exteriorized as an ileostomy and the rectum closed (Hartmann’s).

Summary

In acute UC:

- Liaise closely with physician gastroenterologists
- Assess extent and severity of colitis
- Assess effects of colitis on the overall status of the patient
- Operate semi-electively and do a total abdominal colectomy

In CD:

- Avoid surgery if at all possible
- Indications for emergency surgery include Crohn's colitis, suspected appendicitis, SBO and abscess
- In surgery for suspected appendicitis avoid resection of CD unless appendicitis is present
- In SBO operate only if the gut is truly completely obstructed
- Drain abscesses percutaneously and operate later in a planned, elective fashion

In CDC:

- Treat medically with metronidazole or vancomycin
- If operating, resect without anastomosis

Editorial Comment

We feel that this chapter is where **neutropenic enterocolitis** and **ischemic colitis** should be mentioned.

Neutropenic Enterocolitis

This is a transmural inflammation of the large bowel in myelosuppressed and immunosuppressed patients – usually suffering from myeloproliferative disorders, receiving chemotherapy or following solid organ or bone marrow transplantation. Profound neutropenia appears to be the common denominator; the process involves mucosal damage and alteration in bacterial flora, which then invades the bowel wall. The cecum is primary affected but the process may extend to the ascending colon and even the ileum. The presentation may mimic acute appendicitis; watery or bloody diarrhea is present in only half of the patients. Right lower quadrant tenderness, palpable cecum, peritoneal signs and features of ileus may be present. Neutropenia is a pathognomonic laboratory finding. Plain abdominal X-rays are usually non-specific, revealing an associated ileus but may show *thumbprinting*

of the right colon and intramural air (pneumatosis) – denoting severe involvement of the cecal wall. **CT scan of the abdomen is the diagnostic procedure of choice, showing thickening of the cecum and free air if an underlying perforation exists.**

Management should be initially supportive, including broad spectrum antibiotics effective against colonic Gram-negative bacteria and anaerobes; granulocyte colony stimulating factor (GCSF) may be considered. Clinical deterioration, evidence of free perforation and, rarely, severe lower gastrointestinal hemorrhage may necessitate operation. At laparotomy, normal-looking serosal surfaces may hide mucosal breakdown and necrosis. Therefore, the whole involved segment of colon should be resected; anastomosis should be avoided in these debilitated patients. Mortality is obviously high. The key is to recognize the condition and avoid an operation in the majority of patients.

Ischemic Colitis

Ischemic colitis is a poorly defined entity, which encompasses a wide variety of conditions. Paradoxically, occlusion of the named arteries supplying the colon is not associated with ischemic colitis but local vascular changes in the wall of the colon may play a role. Thus, a patient with sigmoid colon gangrene following repair of an abdominal aortic aneurysm and *ligation* of the inferior mesenteric artery has *colonic ischemia* – not *ischemic colitis*. But a patient that undergoes treatment of a ruptured abdominal aortic aneurysm with preoperative hypotension that develops gangrene of the right colon postoperatively has ischemic colitis.

Ischemic colitis develops in two different clinical settings:

- **Spontaneous:** in patients with underlying cardiac failure, chronic lung disease, renal failure, diabetes, and collagen disease – probably related to diseased intra-mural vessels.
- **Shock-associated:** in patients who have experienced sustained shock regardless of etiology (e.g. ruptured aortic aneurysms)

Typically the colonic process involves a varying depth of penetration. **Transient mucosal involvement may or may not progress to partial thickness necrosis, which may recover with or without a stricture, or progress to full-thickness gangrene.** Although most common in the “watershed” area of the splenic flexure and the left colon, the disease can involve any part of the colon and the rectum and rarely the entire colon; although usually focal it may be patchy or diffuse.

Patients with **spontaneous ischemic colitis** present typically with non-specific abdominal pain and lower gastrointestinal bleeding (hematochezia). Those with **shock-associated ischemic colitis** develop these features on top of their underlying critical disease.

As with mesenteric ischemia (🔗 Chap. 23), the clinical picture – as well as laboratory findings – is entirely non-specific as is the commonly associated ileus. Abdominal X-rays may demonstrate an ileus and colonic dilation proximal to the area of ischemia or a dilated ischemic colon. In the rare, advanced transmural cases, pneumatosis coli or free gas may be seen. Findings on CT include colonic wall thickening, free fluid and pneumatosis coli. Lower GI **endoscopy (often bedside) is the best diagnostic test**, visualizing a spectrum of hemorrhagic and ischemic changes which, although non-specific and that may be confused with CD colitis (see above), are highly suggestive in the specific clinical setting.

Treatment ▶ Clinical and radiographic evidence of colonic perforation or an endoscopic picture of dead bowel (black, paralyzed) necessitates a laparotomy and resection of the involved segment, but this is infrequently needed. Non-transmural ischemia is managed non-operatively with supportive measures and wide spectrum antibiotics, as long as the patient is not deteriorating. Increasing or persisting abdominal pain, fever, ileus, leukocytosis, acidosis and progressive changes on abdominal imaging may call for a laparotomy and colonic resection.

Although most patients recover from the acute insult, some may progress to develop a chronic ischemic stricture – but this is beyond the scope of our story.

PER-OLOF NYSTRÖM

The only time human beings wish they could defecate and fart is when they are not able to do so.

In this chapter we consider the most common cause of acute obstruction of the colon – **cancer** – but also mention a much less common cause, which is **diverticulitis**. We'll also discuss the condition that mimics obstruction: **pseudo-obstruction or Ogilvie's syndrome**. Finally, we'll deal with **volvulus of the colon** affecting the sigmoid and cecum.

Malignant and Diverticular Colonic Obstruction

The four “steps” you should consider in the approach to patients with mechanical colonic obstruction are:

- Establish the exact diagnosis
Then, at operation...
- Decompress the colon
- Resect the obstructing lesion
- Decide whether there should be a primary anastomosis or a colostomy

Preoperative Diagnosis and Management

The clinical hallmark of colonic obstruction is significant abdominal distention associated with recent onset of constipation and lack of flatus. The obstruction usually develops gradually over a few days, sometimes on a background of a change in bowel habit. The usual site of the obstructing carcinoma is in the sigmoid or left colon. The sigmoid is also the locus of any obstructing diverticular mass. Right colonic lesions become obstructing only at the ileocecal region. Because of the wide caliber of the rectum, rectal cancer very rarely presents with a complete obstruction.

Most of these patients are elderly and, because the obstruction may have affected them for several days, they have not been eating and drinking properly, and

so they are dehydrated. Make a thorough examination of the abdomen. It is usually, but not invariably, grossly distended. Be especially observant of signs of peritonitis, which may indicate a manifest or pending perforation of the colon – usually proximal to the obstructing lesion. The site of perforation may be a pre-existing sigmoid or left colonic diverticulum, but more commonly it is in the right colon. The right colon and cecum is the widest part of the bowel. It will also be the most distended part with the highest tension of the bowel wall (Laplace's law), thus the most likely to perforate. When the ileocecal valve is competent the small bowel will be only mildly distended while massive distension and pressure affects the right colon. This pressure can tear the circular muscle layer or cause ischemic necrosis with subsequent perforation. Tenderness of the abdomen on the right side may be a sign of this development. If such tenderness is present and the abdominal X-ray shows a grossly distended right colon (in excess of 10 cm) then operation must not be delayed beyond the requirements of resuscitation.

Plain abdominal X-rays (Chaps. 4 and 5) usually show a distended colon because the obstructing lesion is most often in the left colon. When the obstruction is in the right colon, at the cecal area, it can sometimes be difficult to differentiate between small bowel and large bowel obstruction. In long-standing left colonic obstruction when the ileocecal valve is incompetent, the small bowel becomes dilated as well. Severely dilated loops of fluid-filled small bowel may then obscure the distended colon – a picture that may be misinterpreted as partial small bowel obstruction. **Regardless of the appearances on plain X-rays you must positively confirm the diagnosis by additional investigation and exclude pseudo-obstruction** (see below). What you have to do is document the site of the obstruction: this can be done either with **colonoscopy or a contrast enema**. For reasons explained in Chap. 4 our bias is against the use of barium in this situation and in favor of a water-soluble contrast such as Gastrografin. The site of the obstruction, but not the cause, will usually be evident. At this stage “obstruction is obstruction” – the management is the same whether a carcinoma (common) or a diverticular mass (rare) causes it. A pre-operative **CT scan** is not mandatory but will usually give the diagnosis. When clinical and laboratory features are suggestive of carcinomatosis, or extensive hepatic metastatic involvement, CT documentation of the advanced disease allows better planning of treatment together with the patient and family. You do not want to operate on a jaundiced patient whose liver is almost replaced with metastases for he'll surely succumb to hepatic failure after the operation.

Planning and Timing the Operation

In general, in the absence of signs of actual or impending compromise of the bowel wall there is no reason for you to hurry with the operation. Daytime surgery,

with all that it means in terms of the surgical team and supportive personnel, is the better option for the patient and yourself. There is plenty of time to prepare the patient for a definitive operation to relieve the obstruction. On the other hand, should the patient have peritonitis, systemic inflammatory response syndrome (SIRS), or free abdominal gas on abdominal imaging, an emergency operation is necessary. Antibiotic treatment should be started and the time of the operation decided according to the progress of the resuscitation-optimization (⦿ Chap. 6).

Obviously, in patients with colonic obstruction bowel preparation is contraindicated. Any cleansing solutions administered from above will accumulate proximal to the obstruction – further dilating the obstructed colon and making your life more miserable during the operation. Some surgeons like to administer enemas to clear the rectum and colon distal to the obstruction but these sections of the bowel are usually empty. Do not forget to administer the usual dose of systemic antibiotic prophylaxis just before the operation (⦿ Chap. 7).

In general, the operation for acute colonic obstruction is a major procedure, often in a patient who is old and fragile. Consequently the mortality and morbidity of these operations are significant (sorry – no percentages were allowed by the editors). To avoid complications and mortality you have to exercise your best judgment along the lines presented below.

The Operation

A long midline incision is nearly always preferable. The findings of ascites, peritoneal seedlings, “omental cake”, and hepatic metastases will immediately tell you that the battle has been lost and the operation is merely palliative. **If the obstruction is in the right colon there is usually not a lot of bowel distension. Then, the operation is a rather straightforward right hemicolectomy with primary anastomosis.**

The **left colon or the sigmoid**, however, is the usual site of the obstruction. Here the proximal colon is distended making the operation more difficult. **First inspect the ascending colon to find out if there are tears or necrosis due to the distension.** If there are they can be of any stage from minor to large with micro-perforation. The significance of the tears is that if they are extensive or necrotic it may suggest that a **subtotal colectomy** is indicated. Otherwise proceed as follows:

— **Decompression.** Because of the distended bowel it may be difficult to expose the lesion on the left side and to manipulate the bowel. Sometimes it is better to make an enterotomy into the terminal ileum and insert the suction device (“pool” suction or a large sump drain) through the hole to decompress the small bowel and also pass the device through the ileocaecal valve to decompress the right colon. Close the hole transversely with a suture. It should now be possible to expose the lesion that

causes the obstruction. Often, in cases diagnosed and treated early, the colonic distention is caused by gas and not fecal matter; it can be relieved simply by inserting a large needle or angiocath connected to the suction tube, and tunneled through the tenia coli.

— **Resection.** Whether it is cancer or diverticulitis-sigmoiditis (♦ Chap. 26) the principles of treatment are the same. Mobilize the lesion the same way you would at an elective operation and resect it. If you are accustomed to linear cutting staplers (TLC or GIA) this is one of the best instances to use staplers. Transect the bowel on each side of the lesion and divide also the mesentery and the segmental vessels with the linear stapler. You have resected the cause of the obstruction with complete control of the bowel ends and no leakage. Now is the time to decide whether the bowel ends should be joined or the proximal end should be brought out as a colostomy.

Do notice that it is considerably more difficult to operate on colonic obstruction than on a similar elective case. You will need the extra hands of an assistant to achieve exposure and the decisions are much more complex during the operation. It is advisable to do the operation together with a colleague who can assist with the decisions. If it is a cancer operation it should be the correct cancer resection not just an operation that relieves the obstruction. A “simple” bowel resection is permissible only if the cancer is disseminated so the type of resection has no influence on the prognosis of the cancer. In that situation a colostomy is usually the better option because it is safer for the patient and has less risk of a new obstruction due to local recurrence of the tumor.

To Anastomose or Not?

The judgment process here is not much different from that considered after sigmoidectomy for acute diverticulitis as is discussed in ♦ Chap. 26. What is different, however, is that here there is no associated peritonitis and suppuration. In essence after you have resected the lesion you are left with a few options:

- End left (iliac) colostomy – Hartmann’s procedure
- Primary colocolic or colorectal anastomosis
- Subtotal colectomy with ileosigmoid anastomosis

If the cancer is situated in the *transverse or descending colon* it is often better to do a *subtotal colectomy and an ileosigmoid anastomosis*. This usually means that empty or mildly distended and well-perfused small bowel is joined to normal colon below the obstruction. Most patients will manage an ileosigmoid anastomosis without incapacitating diarrhea and incontinence, while an ileorectal anastomosis requires that the patient has had normal continence before the current illness. For

cancers of the **sigmoid colon or rectosigmoid junction**, a **sigmoid colectomy** is adequate and a subtotal colectomy should be considered only if the ascending colon is ischemic or perforated as mentioned above.

Some Controversies

The main dispute is the question of primary anastomosis and the means of obtaining that goal. It is only a problem for left-sided obstructions. **On-table bowel irrigation** has been proposed as a means of primary anastomosis between clean proximal colon and the rectum. Its value is discussed in Chap. 26 on diverticulitis (in the section on “Fecology”). The irrigation prolongs the operation substantially and therefore represents “negative damage control”. An alternative is the **subtotal or total abdominal colectomy with anastomosis of the terminal ileum to the sigmoid colon or rectum**. This also is a bigger operation that takes longer. In a large Scottish randomized trial comparing the two means (subtotal vs. segmental resection) of obtaining a primary anastomosis there was no difference in survival or anastomotic healing with either method¹. There are now several randomized trials of elective colonic resection with or without mechanical bowel preparation. Again there was no difference in anastomotic healing. It may not be entirely valid to extrapolate the results with residual feces of the “elective” colon to the massive fecal load of the acute colon. It appears, however, that a primary anastomosis can be made safely on the obstructed colon after decompression and removal of feces with suction and milking the colonic end before joining it to the rectum. We, among others, make an anastomosis in an “unprepared bowel” in selective cases.

Why bother with a primary anastomosis at all when it increases the operation time and complexity of the operation? A Hartmann resection and colostomy is quicker and simpler. It is not an all-or-nothing situation but the concerned surgeon will know that the Hartmann resection is often the better choice if the patient is in bad general condition or if the cancer cannot be radically removed. **About half of the Hartman resections will never be reversed, often for very good reasons.** For the less experienced surgeon we suggest that the Hartmann resection is always a valid option.

Is there any role for a decompressive colostomy without resection of the obstructing lesion? This staged management was commonly used only a few decades ago, usually consisting of a transverse colostomy which represented the first stage. Nowadays we would reserve this option in two circumstances:

¹ SCOTIA Study Group (1995) Single-stage treatment for malignant left-sided colonic obstruction: a prospective randomized clinical trial comparing subtotal colectomy with segmental resection following intraoperative irrigation. *Br J Surg* 82:1622–1627.

- The critically ill patient who won't tolerate a major procedure; for example, a patient developing an obstruction a week after a myocardial infarction. Here, a transverse colostomy or even cecostomy under local anesthesia will alleviate the obstruction.
- When there is pre-operative evidence of wide-spread malignant disease, as discussed above.

The Colostomy

It should be understood that the creation of an emergency colostomy is potentially problematic. A common problem is *retraction* due to inadequate mobilization of the bowel. It frequently causes disruption of the mucocutaneous suture line in the early postoperative course, followed by retraction of the bowel end to a subcutaneous position and progressive stenosis of the skin orifice. Even retraction into the peritoneal cavity resulting in peritoneal soiling with feces occasionally occurs. To be safe, make sure that the left colon has been mobilized up to and sometimes including the splenic flexure. The closed proximal end should easily reach out several centimeters beyond skin level and rest in that position without support. Do not settle for anything less or you may make the patient's remaining life an ordeal. The colostomy hole through the rectus abdominis muscle will have to be larger than normal because of the bowel distension. It is sometimes necessary to evacuate some of the gas and feces before the bowel can be brought out. A simple rule of thumb is that when the colostomy hole is kept open with retractors the bowel end should pass "easily" between them, and it will not pass if the retractors are removed. There is no need to close the lateral gutter, or even to fix the bowel to the anterior abdominal wall if it has been sufficiently mobilized. The mucocutaneous suture of the colon to the skin with an absorbable suture is all that is needed.

You should choose either an anastomosis or a colostomy. The proximal "protective" ostomy for an anastomosis is a hybrid of disputable value. Should the anastomosis break, the "protective" colostomy is of little help because the colon was not clean and will leak all the residual feces distal to the protective stoma. A reoperation becomes necessary anyway. There is no study that proves that the ostomy prevents anastomotic failure.

Our Own Preferences

We believe that nowadays in most patients resection of the obstructing lesion and a primary anastomosis can and should be achieved safely. For sigmoid lesions we opt for a sigmoidectomy followed with a colorectal anastomosis; if the proximal colon is excessively "loaded" or appears "compromised" we proceed with a subtotal

colectomy and an ileorectal anastomosis. The latter is also our preference for lesions in the proximal descending colon and the transverse colon. We reserve the Hartmann procedure for high risk patients and those who appear poorly nourished.

Acute Colonic Pseudo-obstruction (Ogilvie's Syndrome)

William Heneage Ogilvie (1887–1971) was not only a great British surgeon but also a keen surgical aphorist. For example, “Personal statistics are at the bottom of all unsound teaching; they are either too good to be true or too true to be good.”

This is an important differential diagnosis of mechanical colonic obstruction. Pseudo-obstruction has the same symptoms, signs, and radiographic appearances of acute large bowel obstruction but there is no mechanical blockage. The X-ray films suggest a left colon obstruction but a contrast study or colonoscopy finds no obstruction. This pseudo-obstruction can be so intense that the right colon becomes ischemic and perforates due to the high intra-mural pressure.

The mechanisms behind pseudo-obstruction are not known. It has been proposed that the condition may be due to sympathetic over-activity, parasympathetic suppression, or both. Most patients are already in hospital for other reasons when the pseudo-obstruction develops. It is a rare but well-recognized sequel to giving birth, but more commonly is seen after major non-intestinal surgery or trauma, or on the background of serious medical illnesses.

This entity is the reason why you should not operate on a suspected colonic obstruction without a pre-operative colonoscopy, contrast enema or CT. **Taking an elderly patient with multiple pre-morbid conditions for a laparotomy to find “only” a distended colon, without an obstructing lesion, is a cardinal error.** Avoid it! Instead, these patients should not have surgery but be treated medically or decompressed with colonoscopy.

— For *medical treatment* it is suggested that **neostigmine** (2 mg) will effectively induce bowel movements and colonic emptying within a few minutes. There are side effects to the neostigmine, including bradycardia, salivation, nausea and abdominal cramps. The patient should therefore be under close surveillance during the treatment.

— If medical treatment is ineffective, a *colonoscopy* may decompress the bowel. The target is decompression of the grossly distended cecum; occasionally, repeated colonoscopic decompressions may be needed. A large and long rectal tube can be left in situ after the colonoscopy for a few days. The diagnostic Gastrografin enema may occasionally also be therapeutic with the hyperosmolar contrast medium promoting colonic peristalsis.

Surgical treatment is required if the cecum perforates or, very rarely, if medical treatment fails and the cecum reaches gigantic size. If the cecum becomes *necrotic* or perforates a right hemicolectomy is necessary. Because the functional obstruction must be in the left colon a primary anastomosis is inappropriate. It is better to fashion an end ileostomy and bring out the distal end of the colon through the same colostomy hole, fashioning a “double-barrel” stoma. This arrangement makes it easy to restore bowel continuity later at the site of the colostomy without the need to re-open the abdomen.

When at laparotomy the cecum is distended but *viable* most surgeons would opt for a **cecostomy**. Tube cecostomy is “messy”; it is associated with a high incidence of local complications such as a fecal leak around it or even into the abdomen. To minimize these risks use a soft large-bore tube and surround its insertion site in the cecum with a double purse-string suture; the cecostomy site should then be carefully attached to the abdominal wall (as you do with a gastrostomy). Cecostomy tubes tend to obstruct with fecal matter and need regular flushing. A viable alternative to tube cecostomy is the formal – “matured” – cecostomy: simply exteriorize a portion of the cecum above the skin level and suture it to the surrounding skin. This, in medically ill patients with pseudo-obstruction, can be easily performed under local anesthesia.

Editorial Comment – Another Option

We wish to mention *another option* in the management of distal colonic obstruction, namely, **endoscopic stenting**. This could be palliative – obviating a proximal colostomy in the patient with disseminated cancer in whom only few months life are expected. Alternatively, it could serve as a temporizing measure during which the bowel is decompressed and the patient’s general condition optimized – allowing safer definitive surgery under ideal conditions. Finally, **beware the cecal lesion obstructing at the ileocecal region, for it is treacherous**. It commonly presents with features of intermittent partial small bowel obstruction and non-specific findings on plain abdominal X-ray. Colonoscopists often miss it if the ileocecal region is not visualized. Iron deficiency anemia should raise your suspicion and CT should be diagnostic.

Volvulus of the Colon

“Though sometimes in a person who is fat
The diagnosis is not clear as that
’Tis then you get help from plain X-ray
Which gas within the gut should well display
So that the coil you see in the radiogram
Reaching from pelvis to the diaphragm.”
(*The Acute Abdomen in Rhyme*. Zachary Cope, 1881–1974)

While volvulus accounts for only one-tenth of all instances of colonic obstruction we tend to remember those patients. It is probably because of the spectacular appearance on abdominal X-rays and the equally spectacular way it is treated. Volvulus of the sigmoid colon is by far the most common, followed by that of the cecum. There is also volvulus of the transverse colon but it is so rare that you will probably not see even a single case during your surgical life.

Sigmoid Volvulus

In affected patients the sigmoid is long, with a redundant mesentery that allows the sigmoid to rotate around its mesenteric axis, usually counter-clockwise. We do not know why it usually occurs after patients have reached seniority. It does happen in younger ages but then typically in an institutionalized patient. The rotation must be at least 180 degrees to be symptomatic for obstruction, but if the rotation is 360 degrees there is also a risk of strangulation. These circumstances account for two types of volvulus: a “slow” form where obstruction is progressively developing and a “rapid” form where strangulation dominates. As the obstructing point is distally at the recto-sigmoid junction, the propulsion of the proximal colon will blow up the obstructed sigmoid loop to impressive dimensions.

The typical patient presents with a history of recent onset constipation and lack of flatus and a grossly distended belly. **Because half of the patients have recurrent episodes of volvulus the diagnosis may already be known.** A **plain abdominal film** will suggest the diagnosis: a tremendously large loop of colon fills the abdomen from the pelvis to the upper abdomen. A contrast enema with Gastrografin will show the obstruction at the recto-sigmoid junction. Typically, the contrast ends in a “beak-of-a-bird” sign that is very characteristic. It is the lower twist that causes this image.




Fig. 25.1. Non-operative management of sigmoid volvulus

Treatment of Sigmoid Volvulus

Non-operative Approach

Until around 1950 the treatment of sigmoid volvulus was essentially surgical and associated with a significant mortality. Then it was demonstrated that the volvulus could be decompressed with much lower morbidity and mortality by passing a tube through the rectum. There are three ways of doing the procedure. If you are lucky to work in a hospital where the radiologist treats the patient this is what they do. A large-bore, flexible but rather stiff tube, size 30–36 and 50 cm long, is passed through the anus and rectum to the site of obstruction. A bag of barium is connected to the tube and by letting in a little contrast the hydrostatic pressure will open the twisted bowel sufficiently to pass the tube into the obstructed sigmoid. A flush of gas and feces signifies successful decompression. The whole procedure is done under X-ray imaging. Whether the tube should be left in place for a day or withdrawn immediately is a matter of debate (◉ Fig. 25.1).

You might have to do the procedure yourself without the assistance of imaging. Then, use a rigid rectoscope and pass it to the twist, which should be seen. The lubricated tube is introduced through the rectoscope and carefully manipulated into the sigmoid. A third method is by means of a flexible colonoscopy and maneuvering the scope itself into the sigmoid. The eventual success of your manipulations is usually announced with a sudden rush of flatus and liquid feces at your face (watch out!).

Operative Treatment

These non-operative methods are successful in the vast majority of cases because strangulation is uncommon. If strangulation and necrosis of the sigmoid are suspected on clinical grounds (evidence of peritonitis) or if attempts at non-operative decompression fail, then an emergency laparotomy is required. At operation (lithotomy position) you will encounter a hugely distended sigmoid colon that has to be decompressed. This is best achieved by gently untwisting the sigmoid and advancing a pre-positioned rectal tube into the dilated segment. **Today, in most patients who undergo an emergency operation for sigmoid volvulus the bowel will be non-viable or compromised. Thus, the procedure of choice is sigmoid resection – either with a colorectal anastomosis or as a Hartmann’s procedure.** The selection of what to do is essentially the same as discussed above with regard to malignant colonic obstruction. Finally, we have to mention the option of **sigmoidopexy** – the fixation of the sigmoid to the lateral abdominal wall. This is a theoretical option when the sigmoid is viable, and well decompressed, and you think that sigmoid resection with anastomosis is “too much” for the individual patient.

After Successful Non-operative Decompression

Elective sigmoidectomy to prevent recurrence, on the other hand, is very simple. It is done with a small transverse incision through which the hypertrophied mobile sigmoid loop is delivered and resected. There is no general agreement when patients should be offered a sigmoidectomy to prevent a recurrence. About half of the patients will have only one episode but those with two episodes will frequently have a third. **Most surgeons therefore offer resection after the second episode.** Anecdotally, a fragile lady in her mid 80s suffered one episode after another but each time she was thought unfit for an elective operation on a benign condition. After her 12th volvulus she had proved her case and was subjected to sigmoidectomy from which she recovered uneventfully and was discharged after 5 days.

Volvulus of the Cecum

This is much less common – you probably won’t see more than four cases during your career – but will usually require an operation. The diagnosis is not as straightforward as that of the sigmoid volvulus. **These patients have clinical and radiographic signs of small bowel obstruction. In addition, typically, the cecal “shadow” is absent from the right lower quadrant. Instead, the poorly attached and redundant cecum – which has flipped to the left and upwards – is visualized in the**

epigastrium or the left hypochondrium, with its concavity pointing to the right lower quadrant. A single fluid level may be seen, representing the dislocated cecum and often confused with the gastric shadow. If in doubt, and in the absence of peritoneal signs, order a Gastrografin enema, which will demonstrate the characteristic “beak” in the right colon.

There are isolated reports of **colonoscopic decompression** of cecal volvulus but the complexity of such a procedure and its doubtful results suggest that operation is the treatment of choice. What to do? There is an eternal controversy – probably never to be solved – between the proponents of cecal fixation-cecoplexy, and the advocates of mandatory resection. This is our selective approach: first de-tort the cecum; the torsion is clockwise so de-rotate the mobile cecum. If after de-torsion the bowel appears gangrenous or of doubtful viability then proceed with a **right hemicolectomy**. A primary anastomosis should usually be permissible but occasionally circumstances suggest that an ‘ostomy is preferable. If so, bring out the small bowel as an end ileostomy and a corner of the closed colon end through the same ‘ostomy hole. This combined “double-barrel” ‘ostomy allows simple closure and restoration of bowel continuity through the site of the ‘ostomy.

If the cecum is viable we see no point in resecting it. Why remove a healthy organ that can be “fixed”? To prevent recurrence of the volvulus fix the mobile cecum to the lateral abdominal wall: i.e. **cecopexy**. Start with decompression of the cecum by “milking” its contents towards a rectal tube, for sutures hold poorly in a distended bowel wall. Cecoplexy is accomplished by suturing the entire length of the cecum to the lateral abdominal wall. Use non-absorbable material and take big seromuscular bites on the bowel and big-deep bites on the abdominal side. Some surgeons elevate a flap of parietal peritoneum that is sutured to the anterior wall of the cecum.

Cecostomy, either a tube or “matured” to the skin, is an option that is mentioned in the literature as an alternative to cecoplexy. We, however, think that it is a bad idea: why convert a simple and clean procedure (i.e. cecoplexy) to a contaminated and potentially complicated one (i.e. cecostomy)?

“Sometimes a bowel-coil gets out of place
By twisting round a narrow base
With gradual strangulating of the blood supply
And danger that th’ affected coil will die.
This is a VOLVULUS which you should learn
Is from the Latin – volvere – to turn”
(*The Acute Abdomen in Rhyme*. Zachary Cope, 1881–1974)

PER-OLOF NYSTRÖM

Think about acute diverticulitis as a left-sided acute appendicitis which is, however, usually treated without an operation.

Diverticula of the colon are not “true” diverticula but herniations of the mucosa through a weak spot of the muscular bowel wall. They can occur in all parts of the colon but are most abundant in the sigmoid colon. The mucosa bulges out through the points of entry for the blood vessels, which transgress the bowel wall on each side, where the mesentery joins the bowel. It is thought that the pressure inside the sigmoid colon, which can be very high, causes expulsion of the mucosa. The smooth muscle of the affected sigmoid colon, unlike that of the rest of the colon and rectum, is often hypertrophied. This thickening is always located at the summit of the sigmoid loop and rarely extends for more than 15 cm. The diverticula mainly appear within this thickened segment of the sigmoid but are not restricted to it. The thickening may reach the rectosigmoid junction but never extends into the rectum proper (15 cm from anal verge). However, it is common to find diverticula extending into the descending colon. Be aware that **diverticulosis** – the mere presence of sigmoid diverticula – is extremely prevalent in persons consuming a Western-type diet, while **acute diverticulitis**, inflammation of the diverticula-bearing segment of the colon, is relatively much rarer.

Surgical Pathology

A wide spectrum of pathological conditions is covered by the term “acute diverticulitis” – each correlating with a specific clinical scenario, which in turn necessitates selective management.

At operation for acute diverticulitis the sigmoid usually feels like a thick fusiform tumor, with only a few diverticula. There are also cases of minor thickening with many diverticula, one of which has perforated and is the cause of the acute inflammation. Such observations make one think about the basic pathology of acute diverticulitis. B.C. Morson, the famous pathologist at St Mark’s, London, highlighted

* A comment by the Editors is found at the end of the chapter.

the hypertrophy of the bowel wall as the primary pathology and we are inclined to accept this, with the addition that the mesenteric fat tissue also plays a role. It is this fat that creeps up the bowel wall, becomes inflamed, produces the phlegmon or abscess, and heals with fibrosis. In our experience, many cases of acute diverticulitis might better be termed acute sigmoiditis – recognizing that it is an acute inflammation of the thickened bowel wall and mesentery. When it is a diverticulum that has been eroded by a fecalith, one finds a localized inflammation, which identifies the site of the perforation. In cases of free fecal peritonitis a perforated diverticulum is the cause although more often it has been walled off by the mesentery or epiploic appendices to produce a peri-colic abscess. Sometimes, the perforation occurs entirely within the mesentery, forming a mesenteric phlegmon or abscess. The latter may secondarily perforate into the free peritoneal cavity but usually this variety only gives rise to minor abdominal and systemic signs but can occasionally produce septicemia in a patient who is unable to contain and isolate the perforation.

There is a strong tendency for diverticulitis and sigmoiditis to adhere locally and fistulize. The formation of fistulas has an obscure mechanism as most patients with such a fistula present as non-emergency cases and often do not even give a history of previous attacks of acute diverticulitis. Most often the fistulas are into the bladder. The patient seeks attention for pneumaturia or persistent urinary tract infection. Fistulas can also communicate with the fallopian tubes, the uterus, small bowel or the skin. It is usually thought that the fistula is the sequel of an abscess but commonly there is no sign of an associated abscess; if there had been one it must have been silent or drained spontaneously via the fistulous tract.

Clinical Features, Diagnosis and Approach

It is clinically pragmatic to think about acute diverticulitis or sigmoiditis as a “left-sided acute appendicitis”. Unlike appendicitis, however, most episodes of acute diverticulitis are successfully managed without an operation. [As most episodes of acute appendicitis might be. See ↗ Chap. 28 – The Editors].

Practically, we find it convenient to think about the clinical scenarios of acute diverticulitis in order of increasing severity:

- Simple-phlegmonous diverticulitis

and COMPLICATED FORMS:

- Peri-colic abscess
- Free perforation with purulent peritonitis
- Free perforation with fecal peritonitis

Phlegmonous Diverticulitis

Most patients admitted to the hospital with acute diverticulitis harbor a phlegmon; they are still capable of mounting an anti-inflammatory response that quenches the inflammation. Such patients are in good condition but suffer from acute pain and tenderness in the left lower quadrant and above the symphysis pubis. A mass may be felt on abdominal or rectal examination. There are signs of systemic inflammation with fever, increased CRP (C-reactive protein) and leukocytosis with left shift. For this stage the diagnosis is clinical. The patient is treated conservatively and usually responds.

Conservative Treatment of Acute Diverticulitis

Traditionally patients with “mild” phlegmonous diverticulitis are admitted to the hospital; they are kept nil-per-mouth and on intravenous fluids. Wide spectrum antibiotics are given and continued until local and systemic inflammatory manifestation subsides. The colon, however, contains feces and will contain feces even after a few days of starvation. So what is the rationale of the “traditional” regimen? We contend that in the absence of an associated intestinal ileus you may feed your patient or at least provide him with oral fluids instead of the intravenous. The same is also true concerning antibiotics: a perfectly adequate “coverage” of anaerobic and aerobic colonic bacteria can be achieved using oral agents such as metronidazole and ciprofloxacin. So if intravenous therapy is not necessary – why admit the patient at all? And in fact mild acute diverticulitis can be managed with oral antibiotics on an outpatient basis.

Complicated Diverticulitis

In the minority of diverticulitis patients local and systemic signs of inflammation will persist or increase over the next couple of days. This is when you should start considering the presence of complicated forms of diverticulitis. Now it is time to order an abdominal CT (➤ Chap. 5) to better define the pathological anatomy. P. Ambrosetti in Geneva has devised criteria to grade acute diverticulitis on CT in a clinically meaningful way¹:

- **Simple attack:** bowel wall thickness of more than 5 mm with signs of inflammation of the pericolic fat
- **Severe attack:** In addition, abscess, extra-luminal gas or leakage of contrast

¹ Ambrosetti P, Grossholz M, Becker C, Terrier F, Morel P (1997) Computed tomography in acute left colonic diverticulitis. *Br J Surg* 84:532–534.

About half of the patients found on CT to have a “severe attack” required an operation during the current admission or subsequent to it. Significantly, however, half of such patients did *not* require an operation, suggesting that CT findings are to be used **together** with the clinical picture in tailoring the proper management.

Should you order a routine CT in all patients suspected of suffering from acute diverticulitis? This is surely unnecessary “overkill” as most patients respond to conservative treatment. In addition, in many instances of clinically mild diverticulitis the CT is negative.

Approach to Complicated Diverticulitis

A small number of patients present from the start with diffuse peritonitis, with or without free intra-peritoneal gas on abdominal X-ray (🔗 Chaps. 3, 4 and 5). Here of course a CT scan may be a waste of time, which would be better used in the intensive care unit for preoperative preparation (🔗 Chap. 6). The final diagnosis will then be established at the operation. The same applies for patients who show signs of spreading peritonitis and increasing systemic inflammation accompanied by tachycardia, tachypnea, hypovolemia with oliguria, hypoxia or acidosis.

CT manifestations of a “**severe attack**” (e.g., extraluminal gas, leakage of contrast or abscess) in a patient who failed to resolve after a few days of antibiotics are not necessarily an immediate indication for an operation. Instead, in the absence of spreading abdominal signs, or systemic deterioration, even small (<5 cm) pericolic abscesses usually resolve without an operation (probably spontaneously draining back into the bowel). In such cases we would therefore advise the continuation of conservative treatment.

Larger pericolic **abscesses** (>5 cm) should be drained; this is best done percutaneously under CT guidance. After successful drainage a “semi-elective” resection of the sigmoid is usually recommended. We do not know, however, whether this is absolutely necessary since an unknown percentage of such patients would probably never develop another attack of acute diverticulitis.

The Operation for Acute Diverticulitis

When you are “forced” to operate for acute diverticulitis the procedure of choice is **sigmoidectomy**. It is usually best to open the abdomen with a lower midline incision, which should extend above the umbilicus to allow access to the descending colon, and be extended further to reach the left flexure should it be necessary to mobilize it. The inflamed sigmoid has frequently folded itself into the pelvis – adherent to the left pelvic brim, and may rest against the bladder or uterus. At times

it will descend further into the pelvis between the rectum and bladder in the man, and behind the uterus and upper vagina in the woman, depending upon how deep the fossa is. The differential diagnosis of a perforated cancer easily comes to mind. A clue is to remember that the inflammation is always at the summit of the sigmoid loop. The rectum and the rectosigmoid junction anterior to the promontory are always unaffected. It is usually possible to reach the anterior rectum from the right side of the pelvis to identify the folding of the sigmoid. Try not to use sharp dissection in this inflammatory and adherent situation; using finger dissection is your best bet; gentle finger-pinching of the planes will separate the inflamed sigmoid from its attachments to the surrounding viscera.

This is not a cancer operation and your aim is simply to remove the sigmoid colon, which is the source of the problem. Staying near the bowel wall helps you to stay out of danger, away from the left ureter and ovarian and spermatic vessels, which may be part of the inflammatory mass. It is best to start dividing the mesentery away from the inflammatory process below and above the sigmoid. After dividing and clamping (or using a linear stapler) the sigmoid at both ends, the rest of the sigmoid mesentery is dealt with. It is prudent to suture-ligate vessels within the thick-edematous mesentery rather than use simple ligatures that may slip. Using a vascular cartridge in a linear stapler to control the mesentery is another, albeit more expensive, alternative. Remove any residual blood, pus or intestinal contents (↻ Chap. 12) and consider the next step. [The present author believes that the inflamed mesentery of the sigmoid should be removed as well.]

To Anastomose or Not?

Should the two bowel ends be joined together or is a Hartmann procedure with an end sigmoid colostomy to be preferred? **An anastomosis is justified in the majority of patients but there are a number of factors to consider.** Localized peritonitis or an abscess is certainly not a contraindication to an anastomosis. Generalized peritonitis is also not a contraindication in itself but the surgeon needs to give it special consideration. Whether purulent or feculent the generalized peritonitis signifies a greater insult to the patient as reflected by the corresponding APACHE II score and the higher risk of dying (↻ Chap. 6). Operative trauma adds to the post-operative SIRS (systemic inflammatory response syndrome) and MODS (multi-organ dysfunction syndrome) (↻ Chap. 48). Most patients with generalized peritonitis due to perforated diverticulitis have an immunological defect that prevents localization of the process. Typically, they suffer from chronic obstructive lung disease or chronic arthritis with anti-inflammatory drugs or steroid dependence for years. Occasionally they have received chemotherapy or are just recovering from major surgery such as a coronary bypass. On the other hand it seems that patients

without such immunologic defects are capable of containing the inflammation and rarely have free peritonitis. Patients with free peritonitis will certainly not tolerate an anastomotic failure and it is therefore all the better if there is no need to worry about the integrity of an anastomosis during the postoperative course. Therefore, in such patients we choose a **Hartmann's procedure**-sigmoidectomy, end-colostomy and closure of the rectal stump.

It is our impression that surgeons pay little attention to the consequences of the operative trauma added to the acute inflammation. We find surgeons blaming the unfavorable course of some of these patients on the diverticulitis and peritonitis, believing that residual infection is the problem. They should instead think about the operative trauma and postoperative SIRS. Consider this. If a sick patient is thrown out of the window (inadvertently of course) and the surgeon then blames the subsequent course on the original illness, we would all say it is a misconception of the situation. The height the patient falls is the operative trauma. The longer the operation takes, the more dissection that is necessary and the more bleeding it causes, the greater the operative trauma. This metaphor encapsulates the modern concept of damage control (● Chaps. 12 and 35) and surgeons need to have a firm understanding of when enough is enough.

Fecology

Reasonable amounts of feces in the colon are not a contraindication for an anastomosis. You can evacuate most of the fecal material from the left colon by milking it into a dish. Occasionally, however, the colon may contain large amounts of fecal material because the sigmoiditis has caused a relative obstruction in the days preceding the acute attack. Massive fecal loading is a factor against an anastomosis. To overcome this it has been proposed that on-table antegrade bowel irrigation (through the cecum or appendiceal stump) be added to clean the colon before the anastomosis. Unless such irrigation is common practice in your hospital, with all the equipment available, the irrigation will take at least half an hour and often much more to accomplish. The subsequent anastomosis will add another 20–30 minutes to the operation. If this is the case a stoma is quicker and gives better damage control.

In summary: consider an anastomosis in patients who are in reasonable health and without diffuse peritonitis. There should be no technical problems in making the anastomosis if the bowel ends are healthy and without tension. [How to do it? Consult ● Chap. 13].

A Few Controversies

- Some surgeons believe that the inflamed mesentery should be anatomically resected together with the sigmoid, claiming that it usually provides for a better source control and anastomosis, when there is no intervening mesentery left. Although the sigmoiditis affects the apex of the sigmoid colon the mesentery is often shortened by the inflammation. The distal transection of the bowel should always be at the rectosigmoid junction because leaving a part of the distal sigmoid is the cause of recurrent diverticulitis. For these several reasons some think that it is often better to resect the sigmoid in much the same way as one does a resection for cancer.
- Should the left flexure always be mobilized? No. This is indicated only in the minority of patients in whom the proximal colon fails to reach the rectum for a good anastomosis without tension, or in patients in whom the blood flow in the marginal artery is uncertain. Diverticula of the descending colon are common but we do not hesitate to anastomose diverticula-containing descending colon to the rectum. Recurrent diverticulitis proximal to the sigmoid is extremely rare.
- What should you do with phlegmonous diverticulitis, which is accidentally discovered during operation with no frank perforation or suppuration present? Probably do nothing at all; just close-up and treat with antibiotics. Most such patients will never return.

Newer Concepts

There are reports of successful **laparoscopic** management with peritoneal lavage of perforated diverticulitis and generalized peritonitis, without resection of the involved bowel. All patients recovered uneventfully and were well during 12–24 months of follow-up. The concept that emerges is that the disease process can be reversed without a bowel resection, which can be postponed or not be performed at all. Larger experience is necessary to validate such an approach.

After the Attack

Most patients with acute diverticulitis respond to conservative therapy; it is estimated that around one-fourth will experience a recurrence. Somewhat confusingly this is variably interpreted as either confirming the need for elective surgery or indicating that the majority of patients do not require an operation. A second attack is probably an indication for an elective sigmoidectomy – this being particularly true in the younger patient.

Looking at the “whole picture” it appears that we operate too early in acute diverticulitis, perform too many CTs, carry out too many percutaneous drainage procedures, remove too many colons, raise too many colostomies, re-operate electively on too many patients, and perform too few randomized controlled trials in order to know what is right and what is wrong.

Editorial Comment – Other Forms

Though sigmoid diverticulitis is so common in our daily practice other forms of diverticulitis should be kept in mind.

— With the horrendous amount of junk food consumed by “western societies” we see a growing number of younger patients with colonic **pandiverticulosis** extending from the rectosigmoid junction to the ileocecal valve. Not a few of these present with **acute diverticulitis in the right or transverse colon**, which may mimic acute cholecystitis or acute appendicitis. The key to diagnosis here is an abdominal CT scan finding a localized colonic phlegmon. This avoids unnecessary laparotomy and the temptation to proceed with colonic resection when the vast majority would respond to conservative treatment with antibiotics.

— **“Solitary” cecal diverticulitis.** This is a different entity: young, mostly male, patients with one or two diverticula in the cecum – in the absence of diverticula distally. Once or twice a year you will see a patient presenting with what you think to be “classical” acute appendicitis but at operation you’ll find a cecal inflammatory mass or phlegmon of variable size. Free perforation and localized peritonitis are uncommon. On CT scan a good radiologist should be able to distinguish cecal diverticulitis from acute appendicitis; if this is the case, you can treat conservatively as these patients would respond to antibiotics – exactly like those with sigmoid diverticulitis. And, of course, recurrent cecal diverticulitis has been reported in conservatively treated patients. Most patients, however, come to operation, either because CT is not done or its findings are mistaken as acute appendicitis. What to do at operation depends on the size of the process, ranging from diverticulectomy (place a liner stapler across the base of the diverticulum – including healthy cecal wall – and fire) to partial cecotomy (again, fire a stapler across and be careful not to narrow the ileo-cecal junction). Surgeons who are not aware of this condition or cannot recognize it are often carried away and perform right hemi-colectomy. But now you know that this is unnecessary. Surgeons who discover the process at laparoscopic appendectomy usually do not know what they see (one has to palpate it) and have to convert.

— For the sake of “completeness” let us mention here that acute diverticulitis *very rarely* affects patients with **jejunal diverticulosis**. These patients present with systemic signs of inflammation as well as with local peritoneal signs in the center of



Fig. 26.1. “Which of these do we have to remove?”

the abdomen. The key to diagnosis and to a trial of non operative management and treatment with antibiotics (usually successful) is a CT scan – showing an inflammatory mass affecting a segment of the jejunum and its mesentery. If forced to operate, all you have to do is a segmental small bowel resection and anastomosis.

◆ Figure 26.1 will remind you that intestinal diverticula affect all of us, they may produce complications but most can be treated without an operation. In the heart of Africa you will rarely see a case of acute diverticulitis: people there do not yet eat the junk that we do.

Massive Lower Gastrointestinal Bleeding

PER-OLOF NYSTRÖM

*“It’s not bleeding until you can hear it bleeding.”
(Gail Waldby)*

“Massive bleeding” is defined as “exsanguinating” or hemodynamically significant bleeding, which persists and requires at least 4 units of blood over a period of 24 hours. Fortunately, truly massive bleeding from the colon and rectum is unusual. The vast majority of episodes of lower gastrointestinal bleeding (LGIB) are self-limiting and not hemodynamically significant. As with all types of gastrointestinal bleeding, never neglect it or think it is trivial until a period of vigilant observation tells you whether the bleeding is minor or major, whether it is likely to have ceased or is protracted.

Sources of Bleeding

Probably, many episodes of overt colonic bleeding never have the precise site and cause established. Often the bleeding is assumed to originate from an already known pathology. Later, when the bleeding episode is over, a diagnostic workup may reveal a previously unknown pathology as the cause or suggest, in retrospect, a lesion that may have been the source. ▶ Table 27.1 shows the most common causes (without ranking their relative frequency).

Table 27.1. Causes of colorectal bleeding

- Neoplasm
- Inflammatory bowel disease
- Diverticulosis – diverticulitis
- Ischemic colitis
- Vascular malformation – angiodysplasia
- Hemorrhoids
- Postoperative – anastomotic
- Meckel’s diverticulum
- Infectious

A short comment about the causes mentioned in the table may help you to choose the most likely cause in your next patient with colonic bleeding. **Neoplasms**, whether cancer or benign polyp, rarely bleed massively but often have occult bleeding that can produce significant anemia. Rectal cancer commonly bleeds overtly and if associated with anemia it can at first suggest a massive bleed until rectoscopy is performed. The patient with rectal cancer will give a history of tenesmus and usually there will have been episodic minor bleeding with the stools for some time. Bleeding in **inflammatory bowel disease** (IBD) is almost never the first symptom of the disease and is rarely massive (🔗 Chap. 24). The diagnosis will be known in most such patients and the bleeding is associated with an exacerbation, where diarrhea precedes the bleeding by several days. The exception is proctitis, which may present with bleeding, again easily identified at rectoscopy. The differential diagnosis of proctitis includes **infections** such as *Campylobacter* or amebiasis. The onset is then more sudden, with diarrhea and bleeding beginning together just a few days previously. **Radiation proctitis** may bleed significantly but here the history is obvious.

Diverticula of the sigmoid colon are assumed to be the commonest cause of acute major LGIB. By nature it occurs more often in elderly patients, and particularly in those taking non-steroidal anti-inflammatory drugs (NSAIDs) or anti-coagulants. In middle-aged patients and also elderly patients, with an unknown reason for hemorrhage you must consider mucosal **angiodysplasia** as the possible explanation. The bleeding can be massive and recurrent. In elderly patients **ischemic colitis** can rarely present with massive bleeding. **Postoperative** bleeding from colonic anastomoses, polypectomy site, or after anal surgery, should be easily identified. And finally, do not forget that internal hemorrhoids may bleed copiously: you do not want to diagnose an anal source at laparotomy.

Diagnosis

We find it very annoying to consult on bleeding patients where the referral note simply states: “Patient has melena”. Anything can hide behind such a note. It tells us that not a lot of thought was invested in this request. There are two very powerful tools to help you: the patient’s history and the rectoscope. First, find out whether the blood is pink-fresh blood, or maroon-almost-fresh blood. These two represent **hematochezia** (bloody stools) and signify a colonic (common) or small bowel (rare) source. We must not remind you that tarry black stools of **melena** signify an upper gastrointestinal (UGI) source above the ligament of Treitz (🔗 Chap. 16). Remember that with massive UGI hemorrhage, and rapid intestinal transit, unaltered fresh blood may appear in the rectum. Insertion of a nasogastric tube with gastric irrigation may quickly direct you to a gastric bleed but remember that bleeding duodenal ulcers may not show blood in the stomach (🔗 Chap. 16).

Rectoscopy

For all cases of hematochezia rectoscopy is the first step. It is amazing how often this step is omitted in “modern” practice – how often we see patients immediately referred instead for a “panendoscopy”. Use a rigid rectoscope because the flexible instrument will be coated rapidly with blood and you will see nothing. Have a good suction device available. It is not unusual to discover that there is simply too much blood to really see anything (● Fig. 27.1). If blood can be aspirated and you do get to see the rectum, simple things like a rectal cancer or proctitis should be obvious. Do not decide on a diagnosis of proctitis too lightly because the mucosa may look all red from the fresh blood. The mucosa should be swollen and there should be no visible mucosal blood vessels. The proctitis is often so distal that the margin between inflamed and normal mucosa can be seen. The redder the blood is, the closer to the anus is the source. **Bleeding from the upper anal canal and lower rectum will reflux at least to the recto-sigmoid junction, so do not be fooled by finding fresh blood at that level.** If you have a good view, when there is not too much bleeding, fresh blood may be seen flowing on the wall or dripping from above – in which case bleeding from a more proximal source is likely. Quite frankly, in patients with active bleeding you won’t be able to see much at rectoscopy. But at least you have the opportunity to exclude an anal source and to observe personally the character and magnitude of the bleeding.

Let us forget, at this stage, the majority of patients in whom the bleeding stops spontaneously. They will be further investigated with a colonoscopy performed in



Fig. 27.1. “Hey, are you sure that all of this is coming from above?”

a well-prepared bowel. Let us concentrate instead on that problematic minority of patients – those bleeding massively or continuing to bleed. In such patients more aggressive means will be needed to establish and treat the source of the bleeding.

The “Sophisticated” Means of Diagnosis

There are two means of diagnosis in this situation: **technetium-labeled erythrocyte scan** and **mesenteric angiography**. Which of the two should be chosen roughly depends on the intensity of the bleeding. The more profuse the bleeding, the better it is to start with angiography. Not only will it define the site of the bleeding but also the bleeding vessel may be treated by embolization through the angiographic catheter. Both investigations require that the patient is bleeding actively; do not waste the radiologist’s time with a non-bleeding patient.

The Operation

This is how to proceed if you elect to perform a laparotomy on a patient who fails to settle. Make a quick examination of the colon to exclude obvious pathology. Then inspect the small bowel, which may contain blood even if the bleeding comes from the right colon, although it would be unusual for the blood to regurgitate throughout the entire small bowel. If you find blood in the upper small bowel, direct your investigation to the UGI tract. Blood in the right colon, but not small bowel, does not definitely identify the bleeding as being in the right colon because blood will regurgitate long distances in the colon. Make your guess based on what you find because now comes the really difficult part. Are you going to take a chance on a right or left colectomy? Do you trust the pre-operative localizing studies-if performed? Or can you identify the bleeding spot with certainty? Not even if you open and clean the colon can you be sure to see the bleeding site. It is messy and takes time, which is a reason why traditional teaching proposed the “blind” right hemicolectomy (assuming angiodysplasia as the cause). There are instances when the colon is so full of blood that a total or subtotal colectomy is advisable. Temporary clamping of the three main vessels to the colon will reduce the bleeding while you mobilize the colon.

A Pathway to Reason

The experience with, and perception of, LGIB differs slightly from one surgeon to another. This is understandable if one realizes that all published data on this topic represent retrospective studies on poorly stratified patients. So this is what we think:

- Let's face it – in nine-tenths of patients with LGIB, the bleeding stops spontaneously. Emergency localizing tests are unnecessary in this group; elective colonoscopy is indicated. Hysterical MDs tend, however, to over-investigate this group – jumping on them with isotope scans and angiograms – all useless when the hemorrhage is not active.
- Each of us operates perhaps once or twice a year on “massive” lower LGIB (>4–6 units bleed over 24 hours, which continues). Therefore, the collective experience of each hospital is small – not allowing any meaningful prospective studies. All that is published on this subject is therefore retrospective and biased by local dogma and facilities.
- Reports by radiologists boasting about high accuracy rates of isotope scans and angiography are often meaningless, because such reports do not discuss the clinical benefit of such accuracy; i.e. did it change the management and how?
- Most “massive” LGIB in elderly patients is either from colonic diverticula (in the left or, less commonly, the right colon) and angiodysplasia (usually of the right colon). True, angiodysplasia lesions are common but we do not know how often they bleed. It is our impression that colonoscopists often over-diagnose these lesions as the source after the hemorrhage has ceased, whereas the true source of bleeding was elsewhere (e.g. diverticular).

Based on the above considerations this is how we would approach a LGIB:

- Start with supportive care. Exclude UGI bleeding. There is no need for a routine UGI endoscopy, as fresh blood per rectum in a stable patient means that the source is not in the UGI tract. Do a rectoscopy to rule out an anorectal source.
- When the patient requires the second and third unit of blood it is time to get a little excited. Angiography at this stage is indicated – if it localizes the source of bleeding in the left or right colon so much the better. If it fails – not a big deal. Isotope scan requires time and is clinically almost useless in actively bleeding patients. Blood migrates within the lumen of the colon and so does the extravasated isotope. We do not value this investigation. (Nuclear medicine = unclear medicine).
- When the patient is on his fifth or sixth unit and blood is still dripping from his rectum – it is time to take him to the operating room. If angiography has localized the source in either the left or right colon we do a segmental colectomy – either right or left hemicolectomy. If angiography is not available or is non-localizing, we do a subtotal colectomy with ileo-rectal anastomosis. **“Blind” segmental colectomy may produce a re-bleeder who won't tolerate a major re-operation.**
- A few authors have described intra-operative colonoscopy after “on-table” colonic lavage. Theoretically it appears attractive but practically it is messy and time consuming. If the hemorrhage has stopped it won't show us much; try and see what an angiodysplasia is and what just some old clotted blood is.

— There is no doubt that in practice we are over-investigating these patients and often waiting too long prior to operation. The bleeding either stops or continues; when it continues you must operate – on a well-resuscitated patient who has not been allowed to deteriorate in a medical ward. A fast subtotal colectomy is a safe, definitive, and life-saving procedure.

Whether we are right or wrong depends on which papers you read, on what you believe, your local facilities and your own philosophy. We hope you'll adopt ours.

— Beware: in lower gastrointestinal bleeding, removing the wrong side of the colon is embarrassing. Removing any segment of the colon while the bleeding source is in the anorectum is shameful.

MOSHE SCHEIN

We all know: “Whatever the clinical presentation, whatever the abdominal findings, always keep acute appendicitis at the back of your mind”.

Acute appendicitis (AA) is discussed in any surgical text dating from the turn of the nineteenth century. Looking at the lengthy chapters devoted to this subject we often wonder what there is to chat so much about. Knowing that you have been fed on AA *ad nauseum* since the early days of medical school we do not intend to repeat here the whole “spiel” again. Instead, we promise to be brief and not to bore, and perhaps teach a few things, which have escaped you until now.

Diagnosis

AA is an inflammation – turning into infection – of the appendix. This rudimentary structure varies in length and position, making matters complicated. Even a dentist (but not a gynecologist) can diagnose a case of “classical” AA (◊ Fig. 28.1); the history of mid-abdominal visceral discomfort, shifting to the right lower quadrant (RLQ) and becoming a somatic, localized pain speaks for itself. Add to it the clinical and laboratory evidence of systemic inflammation/infection and, most important, the localized physical findings of peritoneal irritation. Unfortunately (or fortunately, otherwise dentists would be treating AA), for each classical case you will see two atypical cases. Sure, you know by now that AA is missed at the extremes of age, that in menstruating females it is often confused with gynecological conditions (◉ Chap. 31), that retrocecal and pelvic appendices are more problematic, and that it should be “always on your mind” – at least number two on your list of differential diagnosis. So what can we add that you do not know? Perhaps nothing – but let us emphasize a few points:

- Never confirm or exclude the diagnosis of AA on the presence or absence of one or other symptom, sign or finding “that must be there” because such an obligatory variable does not exist. Instead, suspect AA from a synthesis of the whole clinical picture and the various laboratory tests.
- Every budding surgeon feels compelled to design his own screening test for AA. The “cough test”, the “jump sign” the “please bring your tummy to my finger



Fig. 28.1. Even a dentist can diagnose classic appendicitis

test” and many others. They are all fun, but none approaches a sensitivity or specificity of 90% (oops, sorry, we promised not to use percentages). The truth is that it is impossible to be completely accurate in the clinical diagnosis of AA. Should your policy to operate be based only on clinical assessment and basic laboratory values then one or two out of ten extracted organs will be a normal, “white” appendix (in fertile females this proportion will be much higher...). More than that implies that you are a “cowboy”; less suggests that you are dangerously prudent.

So you seriously suspect AA after having excluded, or at least you believe so, a gynecological complaint, urological pathology, gastroenteritis, the nebulous “mesenteric lymphadenitis”, or the trash bin called “non-specific abdominal pain”. Should you now proceed directly to the operating theatre or order fancy imaging?

Caveat

The management of patients with suspected appendicitis has traditionally focused on the prevention of perforation by early operation, but at the expense of a high proportion of unnecessary operations. But despite an increase in use of modern diagnostic modalities the rate of perforation has not declined. In addition, population-based studies document that diagnostic accuracy decreases as the rate of appendectomy increases, *but the rate of perforation does not change*. This teaches

us that **perforation is a different disease**: patients come to hospital with perforation – they do not perforate while we investigate them or observe them. Sure, sometimes we miss a “masked” perforation but that’s another story.

Abdominal Imaging in Acute Appendicitis

While it is clear that we cannot modify the rate of perforated appendicitis (one in four will be perforated) we can decrease the number of unnecessary, negative appendectomies. It has been said, “a fool with a tool is still a fool”. Indiscriminate and non-selective usage of modern diagnostic technology is not going to change this observation. What is needed is common sense and rational deployment of available investigations. Frankly, managing at least one case of adult (i.e. >13 years old) acute appendicitis per week, I do not recall when last I removed a normal one (during a non-therapeutic laparotomy) or missed an abnormal one (but then again, don’t ALL my patients do well??).

And this is how I do it:

1. Male patients with “typical” presentation. Operate immediately or the next morning.
2. Male patients with “atypical” presentation. Serial re-examinations – if not “better” or still “atypical” I do a CT (see ◉ Chap. 5).
3. Females in the reproductive age with “typical” presentation. I always start with a trans-vaginal ultrasound (US), which frequently detects ovarian pathology and fluid in the pouch of Douglas to explain the clinical picture. If US is not helpful they are sent for a CT.
4. Females with “atypical” presentation – see items 2 and 3 above.
5. As the above approach differentiates between those who need an operation and those who do not **I see no sense in using laparoscopy as a purely diagnostic tool**. Diagnostic laparoscopy per se is a costly and invasive operation (some call it “controlled penetrating abdominal trauma”) and, despite assertions that normal appendices discovered during laparoscopy should be left alone, many surgeons still feel uncomfortable with this approach. Thus, commonly, “negative laparoscopy” means “negative appendectomy”. And in fact, studies of laparoscopic appendectomy report a much higher rate of these negative appendectomies.

Ultrasound in “good hands” has been reported to be accurate in the diagnosis of AA and is useful in excluding other diagnoses, which may require a different therapy (e.g., hydronephrosis), or incision (e.g., acute cholecystitis), or indeed no therapy at all (e.g., ovarian cyst). Most of us do not work in an institution where we

can be so confident of the radiologist's diagnosis of appendicitis on the basis of ultrasound.

Periodic Re-evaluation

Many of you, however – in Russia or in the “bush” for example – don't have a CT scanner readily available, and thus can't follow the advice given above. But this does not mean that you should have a high rate of negative appendectomies. *Periodic re-evaluation* is a time-honored and proven diagnostic modality in the doubtful case. Unfortunately, the art of periodic re-examination and the virtue of patience are disappearing from the scene of modern practice where the emphasis is on obsessive activity, when in order to prove oneself one has always to “do something”. In the absence of clear peritonitis and toxicity, very rarely are attacks of AA a true emergency requiring an immediate operation. If undecided, admit the patient and periodically re-examine him or her over the day or night. In most instances, AA will declare itself and, if it is not AA, the “attack” will resolve. **Patients do not perforate under surgical observation – they lie with neglected perforations in the emergency room or pediatric wards.**

[Note: if you decide to observe the patient, do not administer antibiotics as they may mask the findings, “partially treat”, or even cure the AA.]

So we order imaging selectively. Unfortunately on our side of the Atlantic the diagnostic algorithm is increasingly driven by dogmatic emergency room personnel who perform CT scans in lieu of clinical evaluation. Such indiscriminate use of CT scanning leads to a new syndrome we call “CT appendicitis”: you admit for observation a patient with right lower quadrant pain and ambiguous clinical findings. Meanwhile the emergency room doctor orders a CT, which is reported by the radiologist the following morning. At this stage, the patient feels much better, his abdomen is benign, and he wants to go home but the radiologist claims that the appendix is grossly inflamed. *Should we treat the CT digital image or the patient?*

Classification

Let us bring here a simple classification of AA to facilitate the discussion of management. In essence, AA is either “**simple**” or “**complicated**”. “Simple” AA implies inflammation of the appendix of any extent in **the absence of appendiceal gangrene, perforation or peri-appendicular pus formation**. Define AA as “complicated” whenever any of these changes is present.

Another entity you should be familiar with is the **appendiceal mass**, developing late in the natural history of AA. The “mass” is an inflammatory phlegmon made

of omentum or/and adjacent viscera, walling off a “complicated” appendix. A “mass” containing a variable amount of pus is an **appendiceal abscess**.

Management

Antibiotics

Judicious administration of antibiotics, to cover **Gram-negative and anaerobic** bacteria, will minimize the incidence of postoperative wound (common) and intra-abdominal (rare) infective complications. In “simple” AA the antibiotics are considered **prophylactic**, while in “complicated” AA they are **therapeutic**. We encourage you to administer the first dose of antibiotics pre-operatively just before you scrub. If at surgery the AA proves to be “simple”, no postoperative administration is necessary. Should you, on the other hand, discover “complicated” AA, additional postoperative doses are indicated. We suggest that you tailor the duration of administration to the operative findings. Gangrenous AA, without any pus formation, represents a “resectable infection”, which does not require more than 24 hours of postoperative administration. Perforated AA with or without intra-peritoneal pus should be treated longer – but **for no more than 5 days** (☛ Chaps. 7, 12 and 42).

Perhaps you are not aware that most attacks of simple AA would respond to non-operative management with antibiotics. Also complicated AA may respond to antibiotics or at least could mature into an abscess. So why don't we treat most cases of AA initially conservatively, along the same lines as acute diverticulitis (☛ Chap. 6) of the sigmoid colon? Because the surgical management of AA is simpler and less morbid than that of diverticulitis. However, when faced with AA away from surgical facilities (e.g., in mid ocean) you should treat the patient with antibiotics (which should be available on any ship). Also the preferred management of an appendiceal mass is conservative as discussed below.

The Operation

— “The appendix is generally attached to the cecum.” (Mark M. Ravitch, 1910–1989)

— “The point of greatest tenderness is, in the average adult, almost exactly 2 inches from the anterior iliac spine, on a line drawn from this process through the umbilicus.” (Charles McBurney, 1845–1913)

When to Operate?

You don't have to rush to the operating room as soon as possible with each patient diagnosed as AA! Obviously, if your patient is systemically "sick" and his abdominal findings are impressive (denoting a perforation), operate immediately. Otherwise, a few hours of delay while the patient receives antibiotics are acceptable. You do not rush to the operating room with acute diverticulitis (◉ Chap. 26), so what's the difference?

Open versus Laparoscopic Approach?

As pointed out above, liberal use of diagnostic laparoscopy for suspected AA leads to a high incidence of unnecessary removal of normal appendices – procedures that are not free of complications. But what about laparoscopic appendectomy (LA) if the diagnosis has been established? Evidence suggests that, compared to the open procedure, LA is associated with some reduction in postoperative pain, earlier discharge (a day) and lower incidence of wound infection. However, it is associated with a higher risk of intra-abdominal infective complications when performed for complicated AA. Concerning costs, the money saved by an earlier discharge after LA is spent on a more expensive and longer procedure. It appears, thus, that surgeons who prefer open appendectomy – we are among them – have the support of the literature but it does not mean that they should avoid LA altogether; it surely has a place in very obese patients (avoiding a large incision) or in those with non-perforated appendicitis who specifically demand the laparoscopic approach.

Technical Points

Only the open procedure will be discussed here. Should you like, however, to play with gas, sticks and staplers help yourself!

We presume that you have done your share of appendectomies already as an intern. However, having seen many surgeons transform a customary appendectomy to an elaborate operation resembling a Whipple's procedure, we remind you of the KISS principle (keep it simple, stupid! – ☺):

- **Incision:** you do not need the long unsightly oblique incision. Use the transverse one. A common error is to place it too medially over the rectus sheath; stay lateral to it. Start with a mini-incision; it can be always enlarged.
- **Appendectomy:** you can remove the appendix in an antegrade or retrograde fashion but there is no need to invert the stump- unless you are hooked on useless

rituals. So just ligate or suture-transfix the appendix at its base and chop the rest off. The commonly performed rituals of painting the stump with Betadine or burning it with diathermy are simply ridiculous.

- **Peritoneal toilet:** just suck out the fluid and mop up whatever pus is present with a dry gauze-stick (do not forget the pelvis). Peritoneal lavage through this keyhole incision is useless. Don't do it.
- **Drains:** almost never necessary but may perhaps be indicated after the drainage of a large appendicular abscess.
- **Closure:** separate closure of the peritoneum is not necessary. Instillation of an antibiotic in the fat protects against wound infection (in addition to systemic administration). Do not insert subcutaneous sutures (foreign bodies). Our bias is for primary closure of the skin in all cases. A few will develop wound infection managed by removal of (a few) stitches. Isn't this better than secondary closure, which condemns all patients to further manipulations and an ugly scar? (● Chaps. 38 and 49).

The "White" Appendix

What should you do when the appendix proves to be normal-white? Well, you can rub it to allow the pathologist to diagnose mild acute inflammation (just kidding). The classical dictum is that whenever an abdominal appendectomy incision exists the appendix should be removed in order not to confuse matters in the future. What about a normal appendix visualized at laparoscopy? Should it be also removed? The emerging consensus is to leave it alone, informing the patient or his parents that the appendix has been left in situ. However, most laparoscopists do not feel comfortable with this recommendation, always worrying that what appears normal through the video camera may prove diseased at histology. Thus, for most surgeons, diagnostic laparoscopy for suspected appendicitis leads to appendectomy regardless of whether the appendix is normal or diseased.

Obviously, when the appendix appears normal you should search for alternative diagnoses such as Meckel's diverticulitis, adnexal pathology, perforated cecal diverticulitis (● Chap. 26), or mesenteric lymphadenitis (whatever that is). In most instances, however, you'll find nothing. What should you do if foul smelling, murky, or bile-stained peritoneal fluid is encountered, suggesting serious alternate pathology elsewhere? Bile should guide you into the upper abdomen. Close the incision and place a new one where "the action is". Feces or its odor direct you towards the sigmoid; just extend the incision across the midline and you are there.

The “Valentino” Appendix

Intra-peritoneal inflammation from any cause can inflame-inject the appendix from the outside, mimicking AA. This was the case with the famous movie actor and womanizer Rudolph Valentino who underwent an appendectomy for suspected acute appendicitis in New York (1926). He became gravely ill after the operation and died; autopsy revealed a perforated peptic ulcer. The findings of peritoneal fluid and suppuration, together with a mildly inflamed and non-gangrenous and non-perforated appendix should raise your suspicions that the pathology is elsewhere-look for it!

The Post-appendectomy Appendiceal Stump Phlegmon

Your patient had an uneventful appendectomy for acute appendicitis following which he happily went home. Seven days later he presents with right lower quadrant pain, a temperature and high white cell count. The wound looks OK. This is a typical presentation of an appendix stump phlegmon. Nowadays the diagnosis is simple: a CT will demonstrate a phlegmon, which involves the cecum – as opposed to a drainable abscess. A few days of antibiotic therapy will cure this relatively rare complication, which for some reason is not mentioned by standard texts.

Stump appendicitis: be aware that patients can develop classical acute appendicitis at any time *after appendectomy*. This is becoming more common in the era of *laparoscopic appendectomy*, where during the procedure surgeons may misidentify the cecal base of the appendix and consequently leave a long appendiceal stump – prone to stump appendicitis and requiring a re-appendectomy.

Appendiceal Mass

Typically, patients with an appendiceal mass present late in the course of the disease, with abdominal symptoms lasting a week or more. Occasionally, they report a spontaneous improvement in their symptoms, reflecting the localization of the inflammatory process. On clinical examination you will find a right iliac fossa mass. Overlying tenderness or obesity may obscure the presence of the mass. Therefore, suspect an appendiceal mass in the “late presenters” or those with an atypical smoldering picture. When palpation is not rewarding, obtain a CT scan, which is the best way to document an appendiceal mass. Another indication for CT is associated evidence of undrained pus such a spiking fever and toxicity, signifying an **appendiceal abscess**.

Why should you distinguish between AA and appendiceal mass (or abscess) if the management of these conditions is the same (e.g. operation and antibiotics)? **Because the appendiceal mass (and abscess) can be managed non-operatively.** You could operate on both, as you operate on AA, but removal of the appendix involved in an inflammatory mass may be more hazardous than usual, occasionally necessitating a right hemicolectomy. On the other hand, conservative treatment with antibiotics leads to the resolution of the mass in the vast majority of cases. As no more than one out of five patients will suffer a recurrence of AA (usually within 1 year and not a severe attack) the dogma of routine “interval appendectomy” within 6 weeks has become obsolete. Interestingly, in many of these patients at interval appendectomy the appendix is found to be rudimentary and scarred. In patients over the age of 40 years we suggest an elective colonoscopy and CT scan (after 3 months) to exclude the rare situation in which cecal carcinoma was the cause of the mass.

Failure of the mass to respond to antibiotics signifies an abscess. CT or ultrasound guided percutaneous drainage is the most rational approach (🔗 Chap. 44). Failure to improve clinically within 48 hours means that an operation is needed. At operation, drain the pus and remove the appendix if it is not too difficult.

With a high index of suspicion you can obviate an operation in the majority of patients with an appendiceal mass. *And remember – appendiceal mass represents an unfavorable situation for your laparoscopic skills.*

Appendicitis Epiploica

We mention this condition here because of its name, because you probably have not heard much about it, and because it is not so rare and often imitates AA. Appendicitis epiploica follows a spontaneous torsion of the appendix epiploica – the peritoneum-covered tabs of fat attached along the tenia coli. It is more common in obese individuals and in the cecum and sigmoid. Since the sigmoid colon often crosses the midline the most common manifestation is localized tenderness and peritoneal signs in the right iliac fossa. Typically, patients do not feel or appear sick despite these findings. Thus, “AA on examination” in an afebrile and healthy looking patient should raise your suspicions. The natural history is spontaneous remission as the appendix epiploica sloughs off, transforming into that loose calcified peritoneal body that you occasionally find during unrelated abdominal procedures. CT scan may identify the localized area of peri-colonic inflammation. If you are misled into an operation just remove the necrotic piece of fat.

Conclusions

Acute appendicitis, like any other surgical condition, has a *spectrum*. To reach the diagnosis, consider historical, physical and laboratory variables together. No isolated variable can confirm or exclude AA, while the more typical variables are present, the higher the chance that you are dealing with AA. Whether you operate immediately or tomorrow, whether you observe or obtain additional tests is determined *selectively* based on your individual patient.

Never become blasé about AA; it can kill even today, and may humble even the most experienced surgeon.

There are two things in life that I will never understand: women and acute appendicitis.

“The surgeon who can describe the extent of an appendiceal peritonitis has convicted himself of performing an improper operation.” (Mark M. Ravitch, 1910–1989)

LUIS A. CARRIQUIRY

“We suffer and die through the defects that arise in our sewerage and drainage systems.” (William A. Lane, 1856–1943)

Why have a chapter about anorectal emergencies in a book about emergency abdominal surgery? The easiest answer would be one based on anatomy – the rectum is an abdominal viscus and the anus, although not strictly abdominal, belongs to the perineum, which *latu sensu* is the floor of the abdominal cavity. But the best reason for inclusion is mostly pragmatic – anorectal emergencies are usually managed by the general surgeon on duty. And he must have the proper knowledge to manage adequately these frequent emergencies without doing further harm to the patient.

What can be defined as an anorectal emergency? Broadly speaking, any condition related to the anus and/or the rectum, which, either because of the risk of death or injury, or simply because of intense pain and suffering, deserves immediate treatment. Consider the following:

- Trauma to the rectum and anus
- Rectal foreign bodies
- Perianal abscess
- Necrotizing infections of the perineum
- Acute strangulated internal hemorrhoids
- Acute incarcerated full-thickness rectal prolapse

Trauma to the Rectum and Anus

I have never seen any anal or rectal injury associated with blunt abdominal trauma; injury occurs as a consequence of penetrating injuries (almost exclusively from missile wounds), from severe perineal lacerations due to falls on irregular and pointed surfaces, or as a consequence of impalement or sexual abuse.

* A comment by the Editors is found at the end of the chapter.

The exact assessment of damage following such injuries is best performed in the operating room, under general anesthesia with the patient in lithotomy position – using your fingers and proctosigmoidoscope. There is no need to remind you of the usual priorities of trauma care; oxygenation, hemostasis and vital organs come before the torn ass. Do not forget to “prepare” the abdomen should laparotomy or colostomy prove to be necessary.

— **Injuries to the intraperitoneal rectum** are usually caused by gunshot wounds (⊙ Chap. 34). They must be carefully looked for in the course of exploratory laparotomy, especially when the bullet trajectory is within the pelvis. Such injuries occur also after impalement with long poles, where perforation of the high rectum or even the sigmoid is not exceptional and other abdominal organs can be equally injured (I even know of a myocardial injury caused by impalement with a billiard cue). Intraperitoneal injuries can be treated almost always with simple suture, as with any colonic injury. Exceptionally, facing severe damage to the rectum that is not safely repairable, a proximal colostomy or a Hartmann operation may be necessary. Be that as it may, do not be afraid to suture the rectum with unprepared bowel... the rectum should be no more intimidating than, say, the cecum.

— **Injuries to the extraperitoneal rectum** are more challenging. Any suspicion of extraperitoneal rectal injury according to the bullet trajectory must be confirmed or refuted by clinical examination. Discharge of blood and palpation of a hole in the rectal wall are confirmatory. Until recently, management was based on three basic principles developed for war injuries and demonstrated to be very effective in reducing mortality and morbidity: *diverting sigmoidostomy*, *presacral drainage* and *rectal washout*. (Repair of the actual rectal wound was added when technically possible.) However, the routine use of these dogmas in civil injuries has been challenged in recent years. *Suture repair* of the rectum is a nice concept, but has little to recommend it. Doing so through a transanal approach is not easy and everybody agrees that opening the pelvic peritoneum during abdominal exploration is indicated only to arrest hemorrhage from major vessels or for debridement in the face of extensive bony and soft-tissue damage. In most civilian rectal injuries, suture repair can be omitted without affecting morbidity and mortality (a similar situation exists in the case of full-thickness local excision of rectal tumors without suturing the rectal defect). *Rectal washout* has become the second victim of iconoclasts. Most recent series have omitted it with no change in results. The value of *presacral drainage* has also been questioned. Only *proximal fecal diversion* seems to remain a firm principle, but recent debates about its protective role in very low rectal anastomosis and the necessity of mechanical preparation in colon and rectal surgery are challenging even this status. I look at these developments with an open mind; probably colostomy may be omitted in low-velocity missile wounds but I am still inclined to use it in the management of most injuries. The colostomy should be created as distally as possible; a properly constructed loop colostomy, with an

adequate spur, has been demonstrated to be completely diverting, with no need for a terminal or loop-end colostomy. The only recent development to be considered is the laparoscopic approach to look for associated intraperitoneal injuries and to exteriorize the sigmoid, without a formal laparotomy. Although not an unconditional fan of laparoscopic approaches, I think it may be a good idea and probably one of the better indications for laparoscopic colon surgery.

— **Injuries to the anal canal.** Hemostasis is achieved and lacerations are debrided while taking care to spare as much of the sphincter muscle as possible. The wounds are then left open. A sigmoid colostomy is recommended only for very extensive anal and perineal laceration; in minor cases it is not necessary. I would not recommend attempts at sphincter reconstruction in the emergency setting – sutures do not hold well in the traumatized muscle, nerve lesions can result from difficult dissection in a bloody field and all this can lead to failure, which risks compromising the success of further reconstruction. It is better to leave the job of anal canal reconstruction to the specialized surgeon, who can in due course perform a sphincteroplasty or even think about more complex techniques such as implantation of an artificial sphincter or creation of a stimulated gracilis neosphincter.

Rectal Foreign Bodies

These are not uncommon. In the rarest case, they may result from accidental ingestion, with the foreign body making its way through the whole digestive tract and impacting on the rectal or anal walls (I have seen a toothpick transversely impacted in the anal canal, giving origin to bilateral anal abscesses). Most of them are inserted per anum and almost always by the patient attempting sexual gratification. By the way, do not assume this occurs only with flamboyantly gay people – in most cases you will find middle-aged or even senior married men, who give the most incredible explanations for the unfortunate location of the foreign body. Self-inserted foreign bodies, whatever their shape and size, do not ordinarily cause rectal lesions that go deeper than the mucosa, but the same cannot be said when insertion is due to sexual assault, where perforation at the level of peritoneal reflection or even at the rectosigmoid junction are not exceptional.

When the patient gives a history of impalement injury (fact or fiction), you must carry out a careful abdominal examination and consider abdominal imaging in order to confirm or rule out a visceral perforation, which may necessitate a laparotomy. In all other cases, an initial attempt to remove the foreign body through the anal canal is recommended, under local, regional or general anesthesia, which allows relaxation of the anal sphincters and prevents muscular disruptions due to forceful stretching. Many instruments and maneuvers for grasping the foreign body have been described, but if extraction is not easy, the risk of laceration of the rectal

wall or the anal canal increases with time and effort and laparotomy should be considered, always with the patient in the lithotomy position. In that case, you should try first to deliver the foreign body through the anus to the hands of the perineal operator by manipulating it through the rectal wall, but sometimes opening the rectum and removing the object from the top is paradoxically the least aggressive way of solving the problem. A post-extraction rectoscopy is mandatory to ensure the integrity of the rectal wall.

Perianal Abscesses

These are extremely common in the emergency department. Their incidence, for unknown reasons, is higher in younger men. Any patient with acute, continuous and increasing pain in the anus should be considered to have a perianal abscess until proven otherwise. Ask the patient to lie in the Sims lateral position – preferably with the affected side down, and examine the perianal region. Sometimes the abscess is evident: a localized, very tender red swelling at the anal margin. At other times, you have to carefully palpate the anal margin to elicit a localized pain. Be careful to make this maneuver as brief and delicate as possible; repeating it many times or pressing your finger against the painful zone can be considered an act of torture. If you elicit localized tenderness, you do not need any other imaging technique to confirm the diagnosis; go and treat it.

Where? North American surgeons, always cost-conscious or pressed to be cost-conscious by managed care organizations, prefer to drain the abscess through an incision under local anesthesia in the emergency department. [Laziness is another factor. In the USA the attending surgeon is required to be present at all operative procedures performed in the operating room. Ordering the resident to “lance” the abscess in the ER under local anesthesia, with or without intravenous morphine, saves the attending a night trip to the hospital and OR. – The Editors]. Like many European surgeons, I prefer to complete my examination and perform the drainage under general anesthesia in the operative theatre. A properly done exploration and drainage is too painful to be done in the awake patient and local anesthesia does not work well in these circumstances. Most patients subjected to drainage in the emergency ward have bad memories of their ordeal. Perhaps, adopting a more eclectic posture, you can drain a small, well-defined, bulging perianal abscess, which is on the verge of spontaneous drainage in the ward, but in the case of bigger abscesses – especially those in the ischiorectal fossa – a trip to the operating room is mandatory.

How? I prefer to make a radial incision in the zone of the swelling. When localization is not evident apart from the pain, tap it with a needle in search of pus. There is no need for the “classical” cruciate incisions or skin resections. But the

incision must be long enough to permit introduction of your finger to gently debride the cavity and look for unexpected extensions. Irrigation with normal saline is useful to remove residual pus or blood from the cavity. Many surgeons prefer general anesthesia to be able to look for the associated anorectal fistula – which is present in more than half of the patients – and perform a primary fistulotomy or placement of a *seton*, depending on the type of fistula. The collected evidence shows that this line of management leads to fewer recurrences. I personally share this view but I think it is not wise for the general surgeon occasionally dealing with abscesses, and in particular for the surgeon in training, to indulge in this practice, which can result in new fistula tracts and even in development of incontinence. Just drain, debride and do not pack or leave a drainage tube, except in big cavities. The patient will experience almost immediate disappearance of pain and will be most thankful, although in subsequent months, approximately half will develop a fistula – to be dealt with electively. **And hey – please – these patients do not require any antibiotics!**

Necrotizing Perineal Infections

Necrotizing perineal infections may be the consequence of neglected anorectal infections but they also arise from trauma, skin infections and urethral instrumentation. A urethral source implies *Fournier's gangrene* – an eponym that has been incorrectly extended to the whole spectrum of this entity. But more important than etiology is prompt diagnosis and treatment.

These patients are commonly diabetic or immunosuppressed. The synergistic action of Gram-negative bacteria, anaerobes and *Streptococcus* causes rapid dissemination of the infection along *superficial* fascial and subcutaneous planes with secondary ischemic involvement of the skin. Pain may be the first symptom but it may be vague. Swelling of the perineum, crepitus, local tenderness and erythema of the skin – followed by its necrosis – are the typical elements found on examination.

There is no need for X-rays or CTs, unless one suspects extension to fascial abdominal or retroperitoneal tissues. Only prompt treatment can prevent a fatal evolution; it should include supportive care, high dose intravenous antibiotics to cover aerobic and anaerobic bacteria and prompt surgical debridement – which is the mainstay of treatment. Necrotic skin must be resected but as fascial and fat necrosis extends much further, extensive skin incisions are usually necessary to allow radical excision of fascia and fatty tissue until well-perfused and viable fat is found. If the infection extends to the perineal muscles, they must be sacrificed following the same criteria. Careful surgical revisions in the subsequent days must not be spared. Concerns about future reconstruction should be left to the plastic surgeon, but if it is necessary to excise scrotal skin, it is convenient to wrap

the testicles, which are rarely compromised, in healthy tissues in the abdominal wall or the thigh.

Chop out everything that stinks, is dark, gray or dead – irrespective of how large and horrendous the wound you create. And do it again and again – as many times as it is necessary. Eventually it will all pink-up, granulate, contract and heal.

Two controversial issues remain: the necessity of a colostomy and the use of hyperbaric oxygen. Most authors think a diverting stoma is generally not necessary even in the case of a free-floating anus. Nevertheless, when ongoing fecal contamination is not easily manageable (e.g. incontinent patient, poor nursing facilities) I would consider proximal fecal diversion. The use of hyperbaric oxygen has been strongly recommended on the basis of the action of oxygen free radicals against anaerobic bacteria, but it remains controversial, cumbersome and expensive and so cannot be considered a necessary component of the standard of treatment. Your knife should be the instrument to provide oxygen to the wound.

Acute Strangulated Internal Hemorrhoids

This is a relatively common occurrence in patients with grade III or IV hemorrhoids. The prolapsed hemorrhoids become irreducible because of swelling and thrombosis frequently develops. The patient experiences intense pain and has serious difficulties sitting and walking. On examination you see the prolapsed *piles* (this is how the Brits term hemorrhoids) – blue with areas of mucosal necrosis.

Emergency treatment must be considered. **Three options are available: medical treatment, anal dilatation and emergency hemorrhoidectomy.** Most colorectal specialists prefer the latter, which is the quickest solution to the problem although they admit that the swelling may lead to an excessive excision of anal mucosa and to the subsequent development of anal stenosis. So, if you feel confident about your training in anal surgery, proceed to hemorrhoidectomy but always consider that a few residual skin tags resulting from insufficient removal of perianal and mucosal folds is a better result than stenosis as a consequence of an over-enthusiastic excision. Some surgeons would remove only the prolapsed piles with or without the addition of internal sphincterotomy to relieve the secondary anal spasm. If you are not so confident in dealing properly with this condition, you may safely resort to anal dilatation under general anesthesia – reducing the prolapsed piles upwards, where they belong – or even to medical treatment with bed rest (with the buttocks elevated) and analgesia until spontaneous resolution occurs. You can try the use of sugar for accelerating this resolution. [See *Editorial Comment* at the end of this chapter]

Acute Incarcerated Full-Thickness Rectal Prolapse

This is a rare condition but most painful and distressing for the patient. It is more common in middle age than in older patients with weaker sphincters. The first option is to try to reduce the prolapse with local or general anesthesia. The use of sugar has been recommended also for this condition; it works by osmotically reducing the edema of the mucosa and thus allows an easier reduction. In cases of failures or where there is extensive mucosal necrosis, I think operative treatment is a better option, and doing a perineal rectosigmoidectomy with a coloanal manual suture (Altmeier operation) is the best choice. This is obviously major, specialized surgery and therefore outside the scope of this small book.

Editorial Comment

In this chapter Dr. Luis A. Carriquiry eloquently discusses all “serious” anorectal emergencies but omitted some “banal” ones – which, however, are an everyday cause of severe “pain in the ass” – such as acute *anal fissure* and acute *perianal hematoma* (◊ Fig. 29.1). These two, together with *perianal abscess*, are the usual causes of acute anal pain. So here is a practical approach to dealing with these



Fig. 29.1. “I know I’m a pain in the ass, but please help me!”

“minor” but distressing conditions. Note that you can usually and easily come to an accurate diagnosis without resorting to painful rectal examination!

What is the Pattern of the Pain?

◊ Figure 29.2 shows you that each of the three conditions has a typical pattern of pain. In anal fissure the pain is *sharp* and *intermittent* – aggravated by defecation, relieved thereafter. In perianal abscess (as already mentioned above) the pain is *constant, dull* and *gradually increasing* – until surgical or spontaneous drainage of the pus. In acute perianal hematoma, the pain is more often than not already *abating* when the patient presents to you.

Examination

Place the patient in the lateral decubitus position or let him or her stand flexed forwards with you sitting behind his or her buttocks. Gently spread the buttocks and look at the perianal region – now you can easily visualize any perianal hematoma and often any fissure. If not – then assume that you are dealing with a perianal abscess and continue as discussed above.

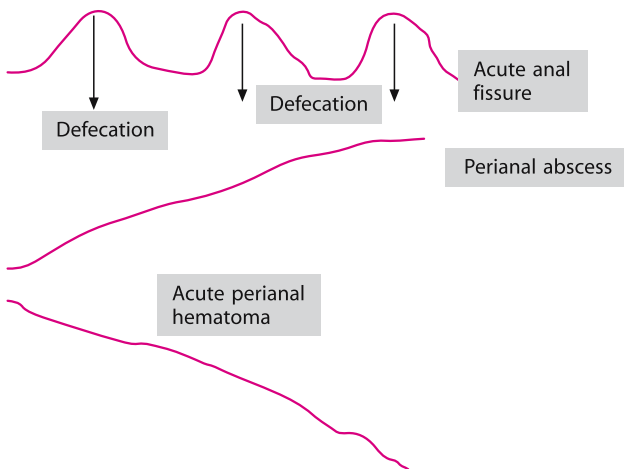


Fig. 29.2. Pattern of acute anal pain

Acute Anal Fissure

This is a linear superficial tear extending from the anoderm to the dentate line – most commonly at the 6-o’clock position but in females an anterior midline location (12 o’clock) is not uncommon. The sentinel skin tag and hypertrophied papilla typical of *chronic* fissure will be absent. Acute fissure almost never requires operative treatment. Your task is to interrupt the pain-spasm-pain cycle, the pain caused by the fissure – resulting in spasm of the internal sphincter – which in turn increases the pain. We would inject, using a 23-gauge needle, a few milliliters of local anesthetic solution (e.g. marcaine) just under the fissure. The pain will disappear quickly and with it the anal spasm. Now the patient will allow you to insert a gloved finger into the anus. Gently introduce your finger coated with a generous dose of local anesthetic cream (lignocaine) – dilating the anal canal gently. Send the patient home with stool softeners and instructions to massage his or her own anus with local anesthetic cream. However, willing spouses or partners would perform this task much better. Management of recurrent, persisting or chronic fissures – whether with topical application of glyceryl trinitrate or diltiazem cream, injection of botulinum toxin or lateral internal sphincterotomy – is beyond the scope of emergency treatment.

Acute Perianal Hematoma

You will recognize it immediately after the buttocks are separated – a swelling the size and shape of a grape, bluish, tense and situated at the anal verge. It is also known erroneously as a “thrombosed external hemorrhoid” although it is believed to represent a clotted perineal vein of indefinite etiology. If left untreated the pain will subside gradually within a day or two and the swelling will disappear within a week or so. From our own very personal experience we know that stool softeners and local anesthetic cream alleviate symptoms rapidly. But if the patient is hysterical and you are one of those who always like to “do something” you may want to inject the lesion with lignocaine, or numb it with ethyl chloride spray, and evacuate the clot through a tiny radial incision through the overlying mucoderm. This relieves the symptoms, although you should be warned that we have seen patients return with an abscess or bleeding at the incision site. We therefore strongly favor non-operative management of this condition.

“Tell Me About the Sugar”

Dr. Carriquiry recommends applying sugar on prolapsed strangulated hemorrhoids or/and prolapsed rectum. This is not a joke but an excellent idea. The hygro-

scopic sugar rapidly reduces the tissue edema – shrinking the prolapsed tissues and allowing manual reduction. Simply place the patient prone and pour a generous quantity of sugar on the strangulated parts until the tortured anus looks like a cake covered with icing sugar. Repeat as necessary following any sitz bath – you won't believe how fast the swelling will subside.

“An abscess near the anus should not be left to burst by itself, but...be boldly opened with a very sharp lancette, so that pus and the corrupt blood may go out. Or else...the gut which is called rectum...will burst...for then may it...be called fistula. And I have seen some who have seven or nine holes on one side of the buttocks...none of which except one pierce the rectum.” (John of Arderne, 1306–1390)

AHMAD ASSALIA · ANAT ILIVITZKI

“If you are too fond of new remedies, first you will not cure your patients; secondly, you will have no patients to cure.” (Astley Paston Cooper, 1768–1841)

Complications of endoscopy may be defined as *immediate*, occurring during the procedure or before the patient leaves the endoscopic suite, or *delayed*, occurring up to 30 days after the procedure.

Some Basic Points

Complications

- In the real world, complications are much more frequent than the “beautiful” figures quoted in the books you read would suggest!
- Complication rates vary with expertise and case volume; expect more in smaller hospitals and with less experienced endoscopists.
- The risks associated with endoscopy are higher when the pathology is more complex and in *therapeutic* as opposed to *diagnostic* procedures.
- With complications of endoscopy, **it’s often more important to know when not to operate than when to operate**; many episodes of post-endoscopy bleeding and perforation are best treated conservatively. It is unhelpful to carry out a laparotomy for post-endoscopy complications and then be unable to identify the perforation or bleeding source.

When called to see a “sick” patient after an endoscopic procedure:

- Suspect catastrophe! And until proven otherwise, assume the patient has the most dreadful surgical complications: **bleeding or perforation**. **Severe pancreatitis** is another possibility after ERCP (endoscopic retrograde cholangiopancreatography).
- What’s common is common! Adverse events following immediately after endoscopy are likely to be due to the procedure itself.
- Always transfer these “sick” patients to the surgical service regardless of the immediate need for surgical intervention. In the interests of everyone,

especially the patient, the best environment is the surgical floor where he/she can be monitored and treated appropriately.

- Recognition and early management of complications is the key for a successful outcome. So... if you don't think about it, you won't diagnose it.
- Regardless of the etiology, always treat shock immediately and prepare the patient with obvious peritonitis for urgent laparotomy.
- Always: **READ** carefully any admission and progress notes and the endoscopic report; **TALK** to patient, his doctor and *directly contact the GI specialist who performed the "uneventful" procedure* (many clues for the possible complication, often unmentioned in the report, are there) and **VIEW**, yourself, all images taken at the endoscopy and thereafter.

Complications of Upper Gastrointestinal Endoscopy

Flexible esophagogastroduodenoscopy (EGD) is a relatively safe procedure with few complications. Almost half of serious complications are cardiopulmonary, related to aspiration, hypoxemia, vasovagal reflexes, and endocarditis. The surgical complications include:

- **Esophageal Perforation.** The cervical esophagus is the area most likely to be at risk. Risk factors include anterior cervical osteophytes, Zenker's diverticulum, esophageal stricture or web and a cervical rib. Most cervical esophageal perforations occur during rigid endoscopy or with blind passage of a flexible endoscope. Retching with an over-inflated stomach and the endoscope occluding the gastro-esophageal junction can result in Mallory-Weiss tears or transmural perforation. Cervical pain, crepitus and cellulitis are all signs of high esophageal perforation. Distal perforations cause chest pain. A cervical soft tissue X-ray and chest radiogram may be helpful in the initial stages for the detection of cervical air, pneumomediastinum and pneumothorax or pleural effusion. The diagnosis is confirmed with water-soluble esophagography or CT scan. With a high index of suspicion, don't waste time. An emergency CT scan with oral contrast medium will detect minimal perforations and provide other valuable information as to the location and other important findings. The management of esophageal perforation is outlined in ◉ Chap. 14.
- **Post-EGD upper gastrointestinal bleeding** (variceal and non-variceal) is approached and treated according to the principles presented in ◉ Chap. 16.
- **Other complications.** Following sclerotherapy, and less frequently ligation for esophageal varices, up to half of the patients will have one or more of the following: chest pain, pleural effusions, pulmonary infiltrates and bacteremia (without perforation). Bacteremia is especially common after esophageal dilatation. Therefore, antibiotic prophylaxis should be considered in an effort to prevent bacterial endo-

carditis in susceptible individuals. Esophageal placement of stents for malignant strictures may cause erosions, bleeding, migration, tumor ingrowth with recurrent obstruction, food impaction or esophagitis with aspiration if they are inserted across the gastro-esophageal junction. Remember: these patients have a short life expectancy and do no more than the minimum required for palliation. This may include repeated endoscopies for ablation of the tumor ingrowth or placement of a second stent.

Complications of ERCP

ERCP carries a relatively high incidence of complications. Were we not constrained by the Editors, who forbade mention of percentages in this book, we would have told you that in decreasing order of frequency, the complications include: pancreatitis (2%–5%), bleeding (2%), cholangitis (1%–2%) and perforation (0.5%–1.2%). The mortality rate may be as high as 1.5%. Therefore, ERCP – especially therapeutic ERCP – should be viewed as a potentially risky endoscopic procedure!

Pancreatitis

While hyperamylasemia may be seen in up to two-thirds of patients, clinical pancreatitis occurs rarely. The incidence is the same for both diagnostic and therapeutic procedures. The severity in the majority of cases is usually mild to moderate and self-limiting. Unfortunately, however, severe post-ERCP pancreatitis, and even fatalities do occur. Interestingly, pancreatitis is more common in younger patients and has its highest incidence in patients having ERCP for suspected “sphincter of Oddi dysfunction”.

Diagnosis ▶ Any significant upper abdominal pain coupled with hyperamylasemia after ERCP should raise the suspicion of pancreatitis. Sometimes the diagnosis is difficult to make, since perforation (see below) may give a similar clinical presentation. If cannulation of the duct was easy and no “precut” or therapeutic interventions were attempted, the likelihood of duodenal perforation is low. Even so, whenever you suspect a perforation order a Gastrografin UGI, or preferably a CT scan, to exclude the perforation and confirm pancreatitis.

Management ▶ Intravenous fluids and NPO (nil-by-mouth) until the symptoms abate is usually all that is required. In a minority of patients, a more severe protracted course may follow. The management strategy in such cases is discussed in Chap. 18. Obviously, impacted common bile duct stones may precipitate pancreatitis and protract its course; if so – repeated ERCP or operative common bile duct exploration may be indicated.

Hemorrhage

Clinically significant hemorrhage may occur after endoscopic sphincterotomy (ES). In patients with obstructive jaundice, it's important that the prothrombin time (PT) be checked and corrected, if necessary, prior to ES. If ES must be done urgently, then fresh frozen plasma is given. Anti-platelet medications should be withheld 7–10 days before ES. Similarly, if ES is urgent, bleeding time should be measured, and if abnormal, corrected with a platelet transfusion.

Diagnosis ▶ Bleeding may present as upper GI bleeding or mimic lower GI bleeding; the patient may develop hemodynamic compromise before hematemesis or melena appears. Admit the patient to the ICU or the surgical floor for close monitoring and apply all the principles of management of GI bleeding.

Management ▶ Repeated endoscopy is indicated for accurate diagnosis and to confirm if the bleeding is in the form of oozing or brisk arterial “pumping”, and also to achieve hemostasis. In case of failure or unavailability of EGD, if the patient's condition is stable and an experienced interventional radiologist is available, celiac angiography with selective embolization of the gastroduodenal artery bleeding branch may avoid operative intervention. However, if this in turn fails or is unavailable, and the bleeding continues or the patient is unstable, then operative intervention must be undertaken. After full Kocherization of the duodenum, a longitudinal duodenotomy in the second part will allow access to the papilla of Vater. The bleeding can be controlled by suture ligation, being careful not to stenose the opening of the papilla or the sphincterotomy site (often converting the latter to surgical sphincteroplasty). If the patient is stable and in case of failure of the ERCP and ES, attention can then be turned to the definitive surgical correction of the problem for which the ES was being done. Otherwise, the minimum should be done that allows drainage of the obstructed biliary system (e.g., cholecystostomy or a T-tube).

Perforation

This is by far the most serious complication of ERCP and endoscopy in general, with up to one-fifth of the patients dying. The vast majority of perforations are into the retroperitoneum in the peri-ampullary area. They are caused by “precut” or ES. Less frequently, guide-wire perforations of the common bile duct and the pancreatic duct may occur. Only a tenth of perforations are intra-peritoneal and are caused by the endoscope itself (usually in the anterior wall of the second part of the duodenum). Risk factors for this include limited experience of the endoscopist, too generous precut or ES, therapeutic procedure, intramural injection of contrast material, repeated ERCP, and patients with a Billroth-II gastrectomy.

Diagnosis ▶ This is often apparent during the procedure or at the conclusion of it when the endoscopist suspects that something went awry. Abdominal and back pain during or immediately after ERCP, together with the presence of retroperitoneal air on plain X-ray of the abdomen will confirm the diagnosis. Alternatively, injection of contrast medium by the endoscopist with demonstration of a leak is possible. The best single modality for the diagnosis is an abdominal CT scan – detecting retro- or intra-peritoneal air and contrast leakage. This prevents a mistaken diagnosis of pancreatitis, which could result in a delay in appropriate management.

Management ▶ In highly specialized centers, a repeat ERCP with insertion of a stent, to “seal” the perforation, may be attempted, but most endoscopists are reluctant to re-approach these patients after endoscopy has caused the problem in the first place. Although there is lack of consensus as to the best management strategy for this problem, it seems that if the following conditions are met, the majority of these patients can be successfully treated non-operatively:

- **Absence of free leakage of contrast**
- **Absence of clinical peritonitis and/or systemic inflammation** (hemodynamic compromise, high fever and leukocytosis)
- **Absence of large pneumoperitoneum**

All other patients with a free leak, intra-peritoneal air (denoting intra-peritoneal perforation), peritonitis and/or sepsis, should be treated surgically.

If conditions for non-operative management are met, a nasogastric tube should be inserted and broad-spectrum antibiotics with adequate Gram-negative coverage administered. Patients should be followed closely and improvement should be expected within 12–24 hours. Normally, these patients recover within 7–10 days and repeated procedures, if still indicated, can be done at that time. Lack of improvement with the appearance of peritoneal irritation or signs of ongoing sepsis mandate immediate operative intervention. After fully “Kocherizing” the duo-

denum, the site of perforation is usually revealed at the posterior aspect of the duodenum. Depending on the degree of induration and inflammation of the tissues, either primary closure or an omental patch repair (see Chap. 17) are performed and a drain left in situ. The next step depends on the patient's condition, underlying pathology, failure or success of the "index" ERCP and the adequacy of the duodenal closure. The principles are: If the patient's condition is stable and the repair looks adequate (this occurs with early perforations), there is no need for a pyloric exclusion procedure. An obstructed biliary system should be decompressed preferably by a T-tube (after cholecystectomy and common bile duct exploration and clearance). **If you are already there, please do not leave the patient at the mercy of the endoscopist again!** If you are worried about the duodenal repair, or its lumen, do add a pyloric exclusion procedure. This is accomplished by gastrostomy – closing the pylorus from the inside with an absorbable suture – and forming a gastrojejunostomy (see ● Chap. 35). Finally, feed a narrow bore nasogastric tube deep into the efferent loop of the gastrojejunostomy to feed your patient distal to the stoma and the duodenal repair.

Severe complications and deaths after ERCP are heartbreaking. But what is tragic is that in many such cases – in retrospect – it is clear that the original procedure was not really indicated.

Complications of Colonoscopy

Colonoscopy is relatively a safe procedure, with the main complications being perforation and hemorrhage. The complication rate is very low for diagnostic procedures (up to 0.3% for perforations and 0.2% for hemorrhage), and rises when the procedure is therapeutic – especially after polypectomy (up to 0.4% for perforation and 2.3% for hemorrhage).

Bleeding

Bleeding might occur immediately after the procedure or may be "secondary" or delayed, from an ulcer developing at the site of the polypectomy or biopsy. The risk is higher with resection of polyps larger than 15 mm, recurrent or difficult procedures, or a bleeding tendency. Rarely, bleeding may occur due to mucosal injury caused by traumatic insertion and manipulation of the scope. Very rarely, vigorous manipulations in the region of the splenic flexure of the colon result in splenic injury and intra-abdominal hemorrhage.

Management ▶ This includes resuscitation and correction of any coagulopathy followed by an endoscopic attempt to treat the bleeding. If, after replacing fluids and correcting coagulation deficits, the patient has clearly stopped bleeding one may elect not to repeat the colonoscopy so as to minimize the risk of perforation at the biopsy site. Persistence of bleeding after unsuccessful colonoscopic management mandates an immediate abdominal exploration. **Always have the endoscopist ready in the operating room to perform an intra-operative colonoscopy** (or even better – master the technique yourself). **Remember:** finding the bleeding spot could be a difficult task: an intra-operative colonoscopy will minimize blood loss and prevent unnecessary bowel resections. In most instances, after localizing the bleeding source, all you have to do is to perform a colotomy and achieve hemostasis by oversewing the site of bleeding; then close the colotomy. If bleeding originates from a source that requires resection (e.g., a large polyp or carcinoma) then an appropriate colectomy should be performed.

Perforation

The mechanism of perforation determines the size of the hole, which can then be managed selectively by the smart surgeon – not the “blind” gastroenterologist.

Difficult, traumatic, and therapeutic colonoscopies are associated with an increased risk of perforation of the colon. Barotrauma from excessive insufflation of air, excessive use of cautery, or overzealous dilatation of strictures are common causative factors. In addition, prior surgery, diverticulitis, or pre-existing intra-abdominal adhesions and a poorly prepared bowel may increase the difficulty of the procedure and the possibility of perforation.

When a colonic perforation occurs, the spectrum of consequences is wide and unpredictable. The *mechanism* of perforation matters: perforations that follow therapeutic colonoscopy (at a biopsy or polypectomy site) are usually small and more amenable to non-operative treatment. On the other hand, perforations following diagnostic colonoscopy often result in sizeable rents in the colonic wall – and thus require prompt surgical treatment

Diagnosis ▶ **The key to diagnosis is a high index of suspicion. Think about the possibility of perforation in any patient who develops abdominal discomfort or pain at any time after colonoscopy.** Presentation is varied: abdominal complaints and signs may develop immediately after the colonoscopy when there is a large colonic tear. On the other hand, patients may present a few days later with gradually increasing local and systemic manifestations of infection. Such delayed presentation is typical of perforations that are initially “contained” within the

retroperitoneum or the mesenteric leaves, and gradually leak or rupture into the free peritoneal cavity.

The abdominal-peritoneal signs, and systemic repercussions, of colonic perforation are well known to you. But remember that loops of bowel – pumped up with air during colonoscopy – may still be tender many hours after the procedure.

Start with a plain upright chest X-ray and left lateral decubitus films of the abdomen and look for free air. The findings of free intra-abdominal air together with a clinical picture of local or systemic peritonitis are diagnostic of perforation. Pneumoperitoneum may be seen after colonoscopy with minimal or no clinical evidence suggesting perforation (“benign” post-colonoscopy pneumoperitoneum). Conversely, free air may be missing when the perforation is initially contained or retroperitoneal. Basing decision-making on the absence or presence of free air reflects naivety common to non-surgeons (e.g., gastroenterologists) attempting to treat abdominal surgical emergencies.

Obviously, clinical signs of perforation and free air on abdominal X-ray are diagnostic of perforation. In the absence of free air insist on obtaining a CT scan (or a Gastrografin enema if CT is not available). Not only is CT able to show free air not visualized by plain X-rays but it may also show other details suggestive of injury such as colonic wall hematoma or air in the colonic wall, the mesentery or the retroperitoneum. When combined with Gastrografin enema, CT usually demonstrates the site and size of the leak and whether it is contained or not. Free fluid may reflect spillage of bowel contents or developing peritonitis.

Remember: the chief cause of death following colonoscopic perforation is delay in diagnosis and consequent delay in treatment. This holdup usually results from the failure of the responsible clinician (it is usually the colonoscopist himself to whom the patient presents with the complication) to consider such a diagnosis. Remember the “surgical ostrich” (👉 Fig. 30.1) who can’t diagnose his own complications? Well, gastroenterologists are not different. We have to help them.

Non-operative Management ▶ Not all patients with colonoscopic bowel injury need a laparotomy. Patients who are minimally symptomatic, without fever or tachycardia, and in whom the abdominal exam is benign (i.e. no features of peritonitis), can be managed non-operatively with nil-per-mouth and broad-spectrum antibiotics (as you would manage acute diverticulitis 👉 Chap. 26). Patients who respond to conservative treatment typically have no, or minimal, pneumoperitoneum and no, or minimal, leak of contrast on CT.

As stated above, perforation at the site of a polypectomy is more amenable to a trial of non-operative management. Such an approach is often successful because these patients have had bowel preparation prior to colonoscopy and therefore the



Fig. 30.1. “Nurse, is that the omentum?”

potential for abdominal contamination is reduced. All such patients should be closely monitored for local and systemic progression of the process or failure to improve. Deterioration should prompt an urgent surgical intervention. Perforation at the site of pathology which mandates colectomy (e.g. malignant tumor) is an indication for immediate, definitive surgery.

Surgical Management ▶ Patients who look sick, complain of localized or spreading pain, with systemic sepsis and localized or generalized peritonitis should receive antibiotics and undergo an emergency laparotomy. In most patients undergoing early exploration the findings are those of peritoneal *contamination* rather than established *infection*; all that is required is “peritoneal toilet” (◊ Chap. 12) and primary suture of the perforation as you would do with any traumatic colonic injury (◊ Chap. 35). The absence of feces in the colon helps to minimize the severity of contamination/infection. A diverting or exteriorizing colostomy may be indicated in selected patients; e.g. with neglected established peritonitis or severe debilitating co-morbidities such as malnutrition or steroid dependence. The role of laparoscopy in the diagnosis and treatment of colonic perforations is not defined yet. However, an experienced laparoscopist, with the help of intra-operative colonoscopy, may accurately diagnose and treat colonic perforations.

Conclusions

The management of endoscopic injury to any hollow gastrointestinal viscus, from the esophagus down to the rectum, can be summed up thus:

- Always suspect disaster
- Image for diagnosis
- Those who are missed and neglected tend to die
- Some can be managed conservatively
- Some need an immediate operation
- Some who are managed conservatively may eventually need an operation
- **To achieve optimal results: be selective, alert and always ready to change your mind**

— A fool with a tool is still a fool.

BASHAR FAHOUM · MOSHE SCHEIN

Have you ever seen a gynecologist who is convinced that the “acute abdomen” is gynecological in origin, and not due to acute appendicitis?

The famous English writer and physician W. Somerset Maugham (1874–1965) wrote: “...woman is an animal that micturates once a day, defecates once a week, menstruates once a month, parturates once a year and copulates whenever she has the opportunity...”. One could not have written such a “sexist” and politically incorrect statement today, but if one could one might have added to it some comment about “lower abdominal pain”...

As a practicing general surgeon you are unlikely ever to deliver a baby but you are likely to face a gynecological problem that you should know how to handle. Acute abdominal pain is very common in women during their reproductive years. Such pain is commonly “gynecological” in origin but is equally likely to be “surgical”. Your gynecological colleagues are generally “nice,” but typically possess a vision limited by the boundaries of the bony pelvis (◉ Fig. 31.1). **Consequently, they are**

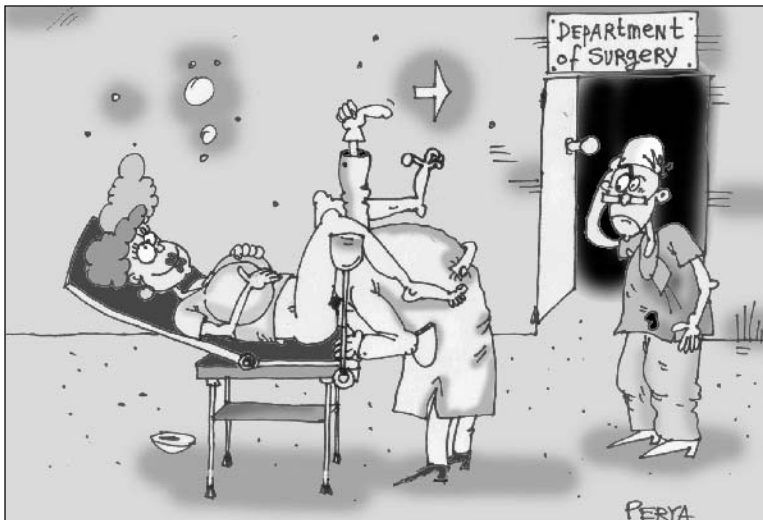

Fig. 31.1. “Call the general surgeon!”

often reluctant to diagnose any acute condition as “gynecological” unless you have ruled out acute appendicitis. Occasionally you operate for what you think is acute appendicitis and the findings are “gynecological”. You should know how to deal with this. Another situation, which provides you with the pleasure of interacting with gynecologists-obstetricians, is the pregnant patient. As you know, pregnancy itself may be the cause of abdominal pain while at the same time it may modify the presentation of common surgical disorders, making diagnosis difficult. It may also pose considerable challenges in the injured patient.

Acute Abdominal Pain in the Fertile Woman

Assessment and Approach

We do not have to remind you to take a history concerning *menstruation*, *sexual activity* and *contraception*. Pregnancy, whether uterine or *ectopic*, should always be ruled out; this is done in most hospitals with a rapid pregnancy test. Any history of pain that occurs during the first days of the menstrual period, hints at underlying *endometriosis* or *endometrioma* (“chocolate cyst”). Acute pain developing mid-cycle (*mittelschmerz*) may be due to rupture of the Graafian follicle at ovulation. Pain referred to the shoulder raises the possibility of *free intra-peritoneal blood* – irritating the diaphragm – with a likely source of bleeding being a *ruptured ovarian cyst* or an *ectopic pregnancy*.

There is no need to talk to you about physical examination. You surely know that the conditions to be discussed below can produce signs of peritoneal irritation, often indistinguishable from those of acute appendicitis. However, the *site of pain and local findings on examination* are helpful in narrowing the differential diagnosis. When bilateral, consider pelvic inflammatory disease (*PID*); when on the right think about acute appendicitis; when on the left, in an older lady, consider acute diverticulitis (⦿ Chap. 3).

Bimanual vaginal examination performed by your gynecological friend, (or by you), is an essential part of the assessment of these patients. You are palpating for masses or fullness at the cul-de-sac (pouch of Douglas) and looking for *excitation tenderness* – when moving the cervix produces a lot of pain (*PID*, *ectopic pregnancy*). Your friend hopefully is also armed with a trans-vaginal ultrasound, allowing him (more commonly her) to visualize any free fluid, the uterus and adnexae. When fluid is present in the cul-de-sac, it can be aspirated with a needle through the vagina (*culdocentesis*); **when pus is present think about PID or perforated appendicitis, while blood hints at a ruptured cyst or ectopic pregnancy.**

Generally speaking, most acutely painful gynecological conditions are treated non-operatively. With all the above information to hand, your job now, together with the gynecologist, is to classify the patient into one of the following groups:

- “Benign” abdominal examination. Most probably a gynecological condition – treat conservatively.
- “Impressive” abdominal examination, no apparent gynecological pathology. This is perhaps the best indication to start with a diagnostic/therapeutic laparoscopy.
- “Not sure”. Admit and observe with or without a CT scan (➤ Chaps. 3 and 28).

The most common acute gynecological problems are complicated ovarian cysts, ectopic pregnancy, and PID. You should know how to diagnose each of these conditions, how to treat them conservatively and what to do – if encountered during laparoscopy or laparotomy – when your old gynecological buddy is not around or takes hours to arrive.

Ovarian Cysts

“*Functional*” cysts (follicular or corpus luteum) are common and usually asymptomatic. Typical features on trans-vaginal ultrasound include: solitary, no solid components, and size <5 cm. *Acute pain develops when the cyst ruptures or undergoes torsion.* Rupture with minimal local and systemic findings should be treated conservatively. If, however, the rupture results in significant intra-peritoneal hemorrhage and when another pathology cannot be ruled out, laparoscopy or laparotomy is indicated. If there is active bleeding from the cyst, obtain local hemostasis by whichever means. There is no need to aspirate or resect the cyst and please, do not even think of removing the ovary. *Torsion* is usually associated with more severe pain, abdominal findings and systemic manifestations, calling for a laparoscopy or laparotomy. If viable, the tube and ovary can be de-torted and conserved; if non-viable – resect.

Ectopic Pregnancy

The great French surgeon Henri Mondor (1885–1962) said:

“When in front of an acute abdomen, consider ectopic pregnancy, think always about it, thinking about it again is not enough, and still go on thinking about it.”

“Ectopic” means that the fertilized ovum has implanted somewhere outside the usual location (i.e. the body of the uterus). The most common site for ectopic is the tubes but implantation may occur in the ovary, cervix and abdominal cavity. The presentation of these patients varies tremendously, the most common being with abdominal pain and vaginal bleeding. Many women do not even know about the pregnancy, ignoring associated symptoms of pregnancy such as a missed menstrual period. The spectrum of clinical manifestations is similarly wide, ranging from local lower abdominal pain to diffuse peritonitis with hypovolemic shock. The combination of a relevant clinical picture together with a positive pregnancy test, and an empty uterus on ultrasound, confirms the diagnosis.

As a general surgeon you are more likely to be involved with the more dramatic scenario of a ruptured tubal ectopic, which may occur as early as the fourth week of gestation. The sudden development of acute peritonitis and hypovolemic shock will force you to rush to the operating room without the gynecologist. Evacuate the gestational sac, control the bleeding sites with suture-ligatures and preserve the ovary. Less dramatic presentations are usually managed by or in partnership with the gynecologist, often laparoscopically. Note that in most ectopics at operation the bleeding has already stopped; when it is active it may necessitate a simple salpingectomy. When the ovaries are left intact the patient can still undergo *in vitro* fertilization even after bilateral salpingectomies.

Pelvic Inflammatory Disease

PID is an infective syndrome which involves, to a greater or lesser extent, the endometrium, tubes and ovaries. The clinical spectrum of infection is wide, ranging from minimal pain, dyspareunia, fever, and vaginal discharge, associated with mild endometritis/salpingitis, to severe peritonitis and septic shock due to ruptured tubo-ovarian abscess. Likewise, physical findings depend on the disease process and vary from localized abdominal tenderness to generalized tenderness and rebound. Note that the pain and tenderness are commonly *bilateral*. Pelvic examination reveals purulent discharge with cervical motion tenderness. Ovarian or pelvic abscess may be palpated or seen on ultrasound or CT. The majority of “mild cases” should be treated with antibiotics. Outpatient treatment is appropriate for patients who can tolerate oral diet. Patients with severe abdominal and systemic manifestation should be admitted for intravenous antibiotic therapy. Antibiotic treatment is empiric, targeting the common causative organisms, which are, in isolation or combination, *C. trachomatis*, *N. gonorrhoea*, *E. coli*, and *H. influenza*. Many oral and intravenous agents are available for you to choose from.

Patients who do not respond to the above regimen or in whom the diagnosis is uncertain are subjected to laparoscopy. This should be left to the gynecologist. The

typical case you will be involved with is the ruptured tubo-ovarian abscess, causing severe pelvic or diffuse peritonitis. During laparotomy or laparoscopy you'll find pus; you read how to deal with peritonitis in • Chap. 12. The abscess should be drained; whether to remove the uterus and ovaries depends on the age of the patient, the operative findings and your gynecologist.

When talking about PID, formal textbooks usually mention the *Curtis-Fitz-Hugh syndrome* or “perihepatitis” as a late sequel – ascending from the pelvis. Although originally associated with *gonococcal* infection, nearly all present-day cases are associated with *C. trachomatis* infection. It may produce non-specific abdominal complaints and has been reported to mimic acute cholecystitis, but in our experience it has never represented a specific entity warranting operative measures. We have seen it, however, as an incidental finding of peri-hepatic “piano-string” adhesions at laparoscopy or laparotomy for other conditions.

Acute Abdominal Pain in the Pregnant Women

“In men nine out of ten abdominal tumors are malignant; in women nine out of ten abdominal swellings are the pregnant uterus.” (Rutherford Morrison, 1853–1939)

General Considerations

A consultation about abdominal pain in a pregnant or immediately post-partum woman is frequently an anxiety-provoking experience for the general surgeon. We think that the following few paragraphs will help you to approach these difficult problems with a new understanding and confidence based on some simple concepts. Abdominal emergencies in pregnant women pose a great challenge for the following reasons:

- The ascending uterus gradually distorts the normal abdominal anatomy, displacing organs and thus changing the typical clinical scenario.
- Physiologically, the pregnant woman is different; nausea and vomiting are not uncommon during the first trimester, thereafter, tachycardia, mild elevation of temperature and leukocytosis are considered “normal”.
- To a certain degree, abdominal “aches and pains” are common during pregnancy
- When dealing with a sick pregnant woman you automatically have two patients; the life and well-being of the fetus have also to be considered.

Generally speaking, acute abdominal conditions during pregnancy are either:

- Specific to pregnancy
- Incidentally developing during pregnancy

Abdominal emergencies specific to pregnancy are either:

- **“Obstetric”** – such as ectopic pregnancy (see above), abortion and septic abortion (a septic uterus may present with an impressive acute abdomen), “red degeneration” of a fibroid, abruptio placenta, rupture of uterus, and pre-eclampsia. These conditions won’t be further discussed. Hey, we did not promise you a manual of obstetrics.
- **“General”** – such as acute pyelonephritis, which is more common in pregnant women, or rupture of visceral aneurysm (e.g. splenic artery), which is rare but “typically” occurs during pregnancy. Another condition which may be associated with pregnancy, is *spontaneous hematoma of the rectus abdominis muscle*. (This condition may also develop in non-pregnant men and women, particularly in anticoagulated patients). The hematoma originates from a ruptured branch of the inferior epigastric artery and develops deep to the muscle. On examination a tender abdominal wall mass is often felt; it won’t disappear when the patient tenses his or her abdominal wall (Fothergill’s sign). Ultrasound or a CT can confirm the diagnosis. Treatment is conservative.

Abdominal Emergencies Randomly Developing During Pregnancy

Any abdominal emergency may occur during pregnancy. Here are a few basic considerations:

- **“Think in trimesters”**. During the *first trimester* the fetus is most susceptible to the potential damaging effects of drugs and X-rays. Abdominal operations at this stage may precipitate an abortion. Operations during the *third trimester* are more likely to induce a premature labor, posing additional risk to the mother and fetus. Thus, **surgery is best tolerated during the second trimester** – if you have the luxury of choice.
- **The well-being of the mother overrides that of the fetus**. If a maternal and fetal distress is present simultaneously on presentation, all therapeutic efforts should be for the benefit of the mother. A Caesarian section is considered only if the fetus is more than 24 weeks old and in persistent distress in spite of maximal therapy to the mother.
- **Pregnant women suffer from a chronic abdominal compartment syndrome** (🕒 Chap. 36). The abdominal emergency (e.g., perforated appendicitis or intestinal obstruction) will further increase the intra-abdominal pressure, reducing venous return and cardiac output. Place such patients in a *left lateral decubitus*

position in order to shift the gravid uterus away from the compressed inferior vena cava.

You should be aware of:

- **Acute appendicitis.** You are commonly called to “exclude acute appendicitis” in a pregnant woman. Address the problem as discussed in ◉ Chap. 28, but be aware that as the pregnancy advances, the cecum, with the attached appendix, is displaced higher and laterally – towards the gallbladder. In addition, the appendix shifts progressively beyond the protective, “walling-off” reaches of the omentum – making free perforation more likely. An ultrasound may help in excluding acute cholecystitis. Diagnostic laparoscopy and/or laparoscopic appendectomy during pregnancy have been reported safe to the mother and fetus but still remain somewhat controversial. If you chose to operate, tilt the table to left and places a muscle-splitting incision *directly over the point of maximal tenderness* – wherever it is.
- **Acute cholecystitis.** This is easily recognized clinically and ultrasonographically (◉ Chap. 19) during pregnancy. During the first trimester try conservative management, delaying the operation to the second trimester. If it occurs during the third trimester try to postpone the operation, if possible, until after the delivery. Laparoscopic cholecystectomy appears safe during pregnancy. Inflate the abdomen with the lowest pressure possible and rotate the table well to the left to decrease compression of the IVC (inferior vena cava) by the uterus. When cholecystectomy is required late in pregnancy (when the uterus fills the entire abdominal cavity) we prefer an open approach through a small subcostal incision. This is perhaps the place to mention the *HELLP syndrome* (hemolysis, elevated liver enzymes, and low platelet count). It is a relatively rare syndrome, which may develop in a pre-eclamptic, pre-term, patient and be confused with acute biliary disease (even a “mild” HELLP may stretch the liver capsule producing severe right upper quadrant pain). Liver hemorrhage and hematoma and even liver rupture are serious complications of the HELLP syndrome and represent a surgical emergency; the child should be promptly delivered and the liver managed based on trauma principles. In the unstable, coagulopathic patient the liver should be packed (◉ Chap. 35). Think about HELLP: a misguided cholecystectomy may kill the mother and her offspring.
- **Intestinal obstruction:** *sigmoid* or *cecal volvulus* is more common during late pregnancy. The displacement of abdominal structures during pregnancy may also shift longstanding adhesions, producing small bowel obstruction or volvulus. Pregnancy tends to cloud presenting features and impedes early diagnosis. Notice that a few plain abdominal X-rays, with or without Gastrografin (◉ Chaps. 4 and 21), are entirely safe even in early pregnancy. So if you suspect a large or small bowel obstruction, do not hesitate. Remember that intestinal strangulation threatens the life of the mother and her child.

Trauma in Pregnancy

The management of abdominal trauma in pregnancy is identical to the management in the non-pregnant woman (📍 Chaps. 34 and 35), except that in pregnancy there is concern for two patients – the mother and the fetus. Therefore, assessment of the fetal status either by Doppler or by continuous cardiotocodynamometry is mandatory when the clinical circumstances permit. The major clinical concerns in the injured pregnant female are uterine rupture and abruptio placentae. The former condition is suggested by abdominal tenderness and signs of peritoneal irritation, sometimes in conjunction with palpable fetal parts or inability to palpate the fundus. The latter is suggested by vaginal bleeding and uterine contractions. When the fetus is in jeopardy, a rapid caesarian section is usually in the best interests of both the mother and fetus.

The “Post-partum” Period

Abdominal emergencies are notoriously difficult to diagnose during the early post-partum or post-Caesarian section period. Abdominal pain and gastrointestinal symptoms are commonly attributed to “after pain”, and fever or systemic malaise to “residual endometritis”. In addition, at this stage the abdominal wall is maximally stretched out and redundant, such that guarding and other peritoneal signs may be missing. “Things move around” the abdomen during delivery and a loop of bowel may be twisted or caught. We have treated perforated acute appendicitis, perforated peptic ulcer and acute cholecystitis during the early post-partum days. Diagnosis is usually delayed and so is the treatment. Be aware!

“Six men give a doctor less to do than one woman.” (A Spanish proverb)

Abdominal Emergencies in Infancy and Childhood

WOJTEK J. GÓRECKI

Children are not small adults.

The well-known phrase that children are not small adults is eminently applicable to pediatric abdominal emergencies, not only because of differences in physiology and metabolism, but also because of a different clinical spectrum of abdominal emergencies, their presentation and management. This chapter focuses on abdominal surgical emergencies in infants and small children. Neonatal emergencies are omitted, as you are unlikely to encounter them unless you are a specialist pediatric surgeon.

The **first principle** to remember is that you are less likely to commit an error if you consider an atypical presentation of a common condition than a typical presentation of a rare condition. Translating this principle into clinical reality, a pediatric acute abdomen is intussusception in infancy or appendicitis in childhood – until proven otherwise. **Another principle** is that, much like with adults, watchful waiting is a prudent strategy in children.

General Approach to Pediatric Abdominal Pain

The philosophy of classifying the multiple etiologies of the acute abdomen into several well-defined clinical patterns, presented in ◉ Chap. 3, works for children as well. The major pitfalls in assessing the pediatric acute abdomen are *timing, history and abdominal palpation*.

— *Children with abdominal pain* present to the emergency room at varying stages of disease because the timing of presentation depends on the parents. Some parents delay, while others are over-sensitive and rush for a surgical consultation. As a general rule – as originally stated by Sir Zachary Cope – consider any abdominal pain lasting more than 6 hours as a potential surgical problem.

— *Younger children do not give you a history*, but listen to the parents because they know their kids so well. A classical example is intussusception, where a descrip-

tion of the child's behavior and a glance at the stool can point you to the diagnosis even before the physical examination.


- *The importance of gentleness* during abdominal palpation cannot be overemphasized. The majority of children with a sore tummy object to abdominal palpation. Sometimes a toy provides a temporary distraction that will allow you to examine the abdomen, but it is pointless to persist if the child is antagonized. Instead of the usual “head-to-toe” sequence of the physical exam in adults, take advantage of a spell of sleep to sneak a warm gentle hand underneath the blanket to palpate the abdomen.
- *An infant* who will not allow a gentle attempt even when held in his mother's lap should be sedated, because sedation does not affect muscle guarding. Our preference is intranasal midazolam 0.1–0.2 mg/kg.
- *Examination of the scrotum* is essential for two reasons. First, an acute condition in the right testicle, such as torsion, can present with pain in the right groin and iliac fossa. Secondly, perforated appendicitis occasionally presents with a painful scrotal swelling, because pus enters the *patent processus vaginalis*, causing acute *funiculitis*.
- *Rectal examination* is best left to the end of physical examination, after looking at the throat and ears, and is not needed if there is a clear indication for laparotomy.

Clinical Patterns of Acute Abdomen in Kids (see also ◊ Chap. 3)

- The combination of **acute abdominal pain and shock** is rare in children, and should make you think of occult abdominal trauma with rupture of an enlarged solid organ or a tumor (e.g. ruptured Wilms' tumor). Contrary to adults, urgent laparotomy is not always indicated.
- **Generalized peritonitis** in children is most commonly due to appendicitis. Do not try to elicit rebound tenderness, as you will lose the confidence and cooperation of your patient. (This applies to adults too!)
- **Localized peritonitis** in the left lower quadrant can be due to acute constipation, whereas right or left upper quadrant tenderness is commonly due to acute distension of the liver or spleen, respectively.
- **Intestinal obstruction** in a virgin abdomen is caused by intussusception or appendicitis. One of ten children with complicated rotational anomalies of the midgut presents after the neonatal period. The critical concern with malrotation is *midgut volvulus* with acute bowel ischemia. This life-threatening condition carries the risk of rapid transmural intestinal necrosis. Your surgical intervention should be prompt because simple counter-clockwise detorsion of the bowel may save it. The two *major pitfalls* in pediatric small bowel obstruction are missing an incarcerated inguinal hernia and waiting too long with conservative management before surgery.

— A wide spectrum of **non-surgical conditions** mimic abdominal emergencies. Particularly in infants, any acute systemic disease may present with apathy, vomiting and stool abnormalities. Gastroenteritis is common in children and typically presents with acute abdominal complaints. The converse is also true. A child with an acute abdomen may present with a wide array of seemingly unrelated symptoms suggesting early meningitis, a neurological disorder or poisoning.

Specific Pediatric Emergencies

The relative incidence of the conditions in the different age groups is depicted in  Fig. 32.1.

Acute Appendicitis (AA) (see also)

AA is rare during the first year of life and is uncommon during the second. Thereafter the incidence rises and peaks between ages 12 and 20. AA in infancy typically presents as generalized peritonitis due to perforation. The infant looks unwell, with fever, tachycardia and tachypnea. The abdomen is distended and generally tender with guarding. Diarrhea is more common than constipation. **Pay attention to the useful “hunger sign”; we have not seen a hungry child who turned out to have AA.** Consider AA in the second place on your list of differential diagnoses for an infant with an acute abdomen, and in the first three places in a child. The white cell count is normal in many cases of pediatric AA, but neutrophilia is more specific. Admitting children with equivocal signs for observation is a safe option, as the chance of rupture under observation in a pediatric surgical ward is less than 1% (oops – the Editors asked for no percentages...).

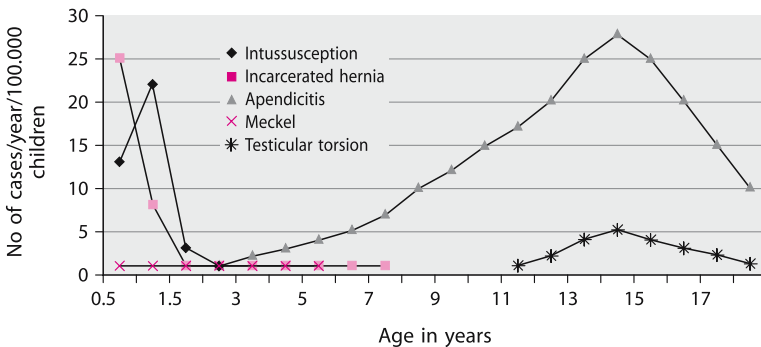


Fig. 32.1. Pediatric abdominal emergencies

A *limited helical CT* with rectal contrast has high accuracy in diagnosing AA in children, but clinical examination by an experienced pediatric surgeon is just as good. Even if the CT scan is positive, appendectomy is not indicated if the child improves clinically.

What is the role of laparoscopy in the doubtful case? While it offers the advantage of a diagnostic modality that can be immediately followed by appendectomy, it will subject some children to an unnecessary operation. If you can get the child into a CT scanner without general anesthesia, this should be your preferred choice instead of diagnostic laparoscopy.

The value of *laparoscopic pediatric appendectomy* remains controversial because there are no good data to suggest that it confers an advantage in postoperative recovery. However, it is a valid alternative to the open technique. The short distances and thin abdominal wall of children allow a port-exteriorization appendectomy, performed via *two ports*, where the appendix is exteriorized by pulling it out of the right iliac fossa port and then the entire appendectomy is performed *outside* the abdomen. Or the appendix can be pulled out of the umbilical port, and if you have a laparoscope with a working channel, you can perform a *single port* appendectomy using the same technique. [Which would be equivalent to a conventional – *no port* – appendectomy through a 2-cm incision. – the Editors]

There is no point in culturing the peritoneal fluid in case of obvious AA because the results are predictable and antibiotics have usually been stopped by the time the culture results become available. Decide on the duration of postoperative antibiotics according to the degree of contamination/infection found in the peritoneal cavity (see ◉ Chap. 12).

Intussusception

Telescoping of one portion of the intestine into another can turn a healthy baby into a critically ill patient within a few hours. It typically occurs between the ages of 5 and 7 months, and the etiology is idiopathic. In children older than 2 years, look for an underlying pathology, the most common being a *Meckel's diverticulum*. Early intussusception is generally a benign condition, although it is a strangulating obstruction eventually leading to vascular compromise. Most cases start in the ileum as ileo-ileal intussusception and then progresses through the ileo-cecal valve to become ileo-colic intussusception.

The diagnosis is straightforward if the infant exhibits the classical clinical syndrome. A previously healthy infant suddenly starts to scream, pulls up its legs and perhaps clutches the abdomen. The pain is then relieved and the child may relax for a while only to have a similar bout 15–30 minutes later. This leaves the infant pale and ill. Vomiting and passing of “red currant jelly” stools is also characteristic,

although salmonellosis may show a similar clinical picture. Atypical presentations are common and lead to diagnostic errors. The infant may be fretful and restless without either pain or vomiting. Pallor and peripheral coolness due to vasoconstriction, lethargy and seizures may also confuse the picture. **The crucial physical sign is palpation of an abdominal mass.** The ultrasonographic findings of a “target sign” on cross section and “pseudo-kidney sign” in a longitudinal view are important adjuncts to the clinical diagnosis.

Children with diffuse peritonitis, perforation, progressive sepsis and possible gangrenous bowel should undergo an urgent laparotomy. Early intussusception without peritonitis is reduced non-operatively with pneumatic or hydrostatic pressure under radiographic or ultrasonic guidance. Water-soluble contrast is safer than barium in case of perforation. Reduction is successful in the majority of cases but requires close collaboration between surgeon and radiologist.

Operative reduction of an early intussusception: squeeze on the apex of the intussusception while the bowel is still within the abdomen so that the intussuscepted segment begins to slide out. When the reduction reaches the region of the hepatic flexure it may become more difficult but after you eviscerate the proximal colon the reduction can be completed under direct vision. After achieving complete reduction remember to examine the entire bowel for a pathology serving as a lead point. If the intussusception is truly irreducible, or if the bowel has suffered a serious vascular compromise – resect it.

Meckel's Diverticulum

Two-thirds of Meckel's diverticula encountered by surgeons are incidental findings while the remaining one-third will present with a complication. The incidence of these complications is maximal during the first year of life and decreases thereafter so that more than two-thirds of all complications occur in the pediatric population. These complications include bowel obstruction (adhesive obstruction, volvulus or intussusception), complications of peptic ulceration in ectopic gastric mucosa (stricture, hemorrhage, or perforation), or acute inflammation (“second appendicitis”). There is also a distinct tendency for foreign bodies to penetrate and perforate a diverticulum. *Littre's* inguinal hernia contains a strangulated Meckel's diverticulum and, like *Richter's* hernia, does not produce signs of intestinal obstruction.

The treatment of a symptomatic diverticulum is resection. Diverticulectomy is possible if the base is wide and non-inflamed, but remember to check the base of the diverticulum and the adjacent ileal mucosa because the bleeding source may lie within it. If in doubt, or if there is any technical difficulty, resect the segment of ileum carrying the diverticulum.

What should you do with an *incidentally* found Meckel's diverticulum? Consider the degree of peritoneal infection, the patient's age and the shape of the diverticulum. On balance, the arguments *against* removing an asymptomatic Meckel's diverticulum are a little stronger than those in favor, and the strength of the argument increases with the age of the patient. Thin-walled, wide-mouthed diverticula should be left alone.

Irreducible Inguinal Hernia

This emergency occurs primarily in boys during their first year of life. The fundamental difference between an irreducible inguinal hernia in an infant and an adult is that the former presents a **danger to the viability of the testis**, whereas with the latter the major concern is the potential for bowel ischemia. Neonates with symptoms lasting for more than 24 hours and with intestinal obstruction are at the greatest risk of testicular infarction. Necrosis of incarcerated bowel is extremely rare in pediatric hernias.

The diagnosis is straightforward because the baby cries and vomits and the parents have usually noticed a tender lump in the groin. The major differential diagnosis is with torsion of a maldescended testicle, acute inguinal lymphadenitis and a hydrocele of the cord. After making the diagnosis, sedate the infant and position him in a head-down position. In the majority of babies, this will result in spontaneous reduction within 1–2 hours. Let the tissue swelling subside for a day or two and book the child for an elective herniotomy on the next available operative list.

The operation for irreducible inguinal hernia in an infant is fraught with danger and should be undertaken only by a surgeon with previous experience in pediatric surgery. The hernia sac is edematous and extremely fragile, and the ductus deferens is almost invisible. Simple herniotomy at the level of the neck of the sac is all that is required. Always make sure that the testicle is safely replaced into the lower part of the scrotum. In a *female infant*, a movable tender lump may be an irreducible ovary. The child may be almost asymptomatic yet require emergency herniotomy because of the risk of ovarian ischemia.

Testicular Torsion

The key to successful treatment of testicular torsion is speedy detorsion, within less than 6 hours of the onset of symptoms. The incidence of torsion rises sharply around age 12, with two of every three cases occurring between the ages of 12 and 18. Some boys with testicular torsion present with lower abdominal and

inguinal pain so you will miss the diagnosis if you fail to examine the scrotum. No clinical sign or test is foolproof, and because the price of delay is loss of the testis, the common wisdom is to have a low threshold for exploring an “acute scrotum”.

If prompt surgery is not available, manual detorsion in a lateral direction under sedation or local anesthetic infiltration of the cord may restore testicular blood flow. The operative procedure is bilateral orchidopexy to protect the ipsilateral testicle from recurrence and to secure the contralateral one, as inadequate anatomic suspension is a bilateral phenomenon. After induction of anesthesia, first examine the scrotum to rule out incarcerated hernia or testicular tumor, both requiring an inguinal incision. Then proceed with a scrotal exploration via a vertical incision in the median raphe of the scrotum or two transverse incisions to access both sides. Enter the serosal compartment of the scrotum to deliver and detort the testis. If it is necrotic, remove it. Orchidopexy of the viable testis is performed by suturing the surface of the testis (tunica albuginea) at four points to the wall of serosal compartment using non-absorbable sutures. If you find torsion of the testicular appendage, simply excise it.

Pediatric Abdominal Injuries

Trauma is the major cause of death among children older than 1 year of age, and is responsible for more deaths than all other causes combined. In about one injured child in seven, the most important injury is to the abdomen. The patterns of blunt abdominal trauma and the clinical picture are similar to those of adults, with injuries to the kidneys, spleen, liver and the intestines being the most common (☛ Chap. 35). Most cases can be treated conservatively and laparotomy is required only in one child in four. The major motivation for a non-operative approach to abdominal trauma in children is the risks of non-therapeutic laparotomy and overwhelming post-splenectomy infection.

Even children with hemodynamic instability on admission often quickly improve with crystalloid administration and remain hemodynamically stable thereafter. If the situation stabilizes after infusion of not more than 20 ml/kg of fluid then it is safe to observe the child in an intensive care unit. If the child continues to bleed and there is no other source of hemorrhage, a prompt laparotomy is indicated.

The Achilles heel of this conservative approach is the possibility of missed injuries to hollow organs. Thus if the child develops increasing abdominal tenderness or peritonitis, this too is an indication for laparotomy. **A useful clinical marker of blunt bowel trauma is the triad of a fastened lap belt, a seat belt sign on the abdominal wall, and fracture of a lumbar vertebra.**



Fig. 32.2. “But...but I’m a pediatric surgeon...”

No discussion of pediatric trauma can be complete without emphasizing the need for a high index of suspicion for child abuse. While isolated abdominal trauma is a rare presentation of child abuse, unusually shaped or multiple bruises, associated long bone fractures or inexplicable genital lesions should always raise the suspicion of this tragic and potentially life-threatening condition.

Children are not small adults but ... see  Fig. 32.2.

SAI SAJJA

Also the AIDS patient can suffer from acute appendicitis.

Human immunodeficiency virus (HIV) infection and its inevitable consequence of acquired immunodeficiency syndrome (AIDS) is a major public health problem worldwide that has affected the way surgery and medicine are practiced. With the advances in medical treatment, people infected with HIV are living longer so it is likely that most of you, wherever you practice, will encounter and treat patients with HIV/AIDS. While the general principles of emergency abdominal surgery described elsewhere in this book are relevant to the HIV patient, we will highlight below what is unique to this population.

Natural History

This disease presents a spectrum ranging from asymptomatic HIV infection to advanced AIDS, including its associated opportunistic infections.

Depending on the CD4+ count HIV disease is categorized as:

- Early stage (CD4+ count >500 cells/ μ l)
- Mid stage (CD4+ count 200–499 cells/ μ l)
- Advanced (CD4+ count 50–200 cells/ μ l)
- Terminal (CD4+ count <50 cells/ μ l).

A CD4+ count of <200cells/ μ l now is defined as AIDS irrespective of the presence of symptoms or other illnesses. A long list of opportunistic infections and cancers, when present, place the HIV-infected patient in the category of AIDS.

* Why a separate chapter on HIV/AIDS? We're sure we are not alone in deploring the current trend in making some diseases (AIDS and breast cancer being the most notable) more "fashionable", and their sufferers more worthy of support and sympathy than regular patients. This chapter is emphatically not an addition to this regrettable development, but an acknowledgement that these patients and their illness may be different in a surgically relevant way (The Editors).

Abdominal Pain

Abdominal pain and non-specific gastrointestinal complaints are very common in patients with HIV/AIDS (◉ Fig. 33.1). Clinical evaluation is difficult as many patients suffer from chronic abdominal symptoms and, for the physician encountering the patient for the first time, what may be the baseline status for the patient may appear very abnormal. Also the list of differential diagnoses is much larger in this population. White blood cell count, which is very valuable in the normal population, is not reliable because of pre-existing leukopenia. Patients often have coexisting infections of the central nervous system, which makes evaluation of the abdominal pain difficult. Anti-viral medications frequently cause chronic abdominal symptoms as well as acute pancreatitis. A thorough history, including the stage of the HIV disease, the presence of opportunistic infections and the anti-retroviral therapy, and a careful physical examination along with an erect chest X-ray and abdominal X-rays and routine laboratory tests, including serum amylase and lipase, form the basis on which further management is planned.

When the initial examination is inconclusive, serial examinations often yield valuable information. In the absence of clinical peritonitis, free intra-peritoneal air and exsanguinating hemorrhage, CT scan of the abdomen and pelvis is an indispensable investigation in AIDS patients. It often identifies non-surgical pathology and avoids a non-therapeutic laparotomy. ◉ Table 33.1 shows causes of abdominal pain in HIV/AIDS and ◉ Fig. 33.2 the suggested clinical approach. (Note that the algorithm in that figure differs from the management of a non-HIV/AIDS patient



Fig. 33.1. “Is it appendicitis or CMV colitis again?”

Table 33.1. HIV-related and HIV-unrelated causes of abdominal pain according to the need for source control

	HIV-related conditions conditions	Non-HIV-related
Surgical procedure usually indicated	CMV bowel perforation CMV-related toxic megacolon Acalculous cholecystitis Kaposi sarcoma Lymphoma with bowel perforation Splenic abscess	Appendicitis Cholecystitis Secondary peritonitis Intra-abdominal abscesses Intestinal ischemia Trauma
Usually conservative management	Uncomplicated CMV infection <i>Mycobacterium avium</i> complex <i>Mycobacterium tuberculosis</i> Pancreatitis: infectious (CMV, MAC), drug-induced (pentamidine, dideoxyinosine, trimethoprim-sulphamethaxazole)	Organomegaly Constipation Uncomplicated peptic ulcer disease Uncomplicated pelvic inflammatory disease

CMV cytomegalovirus; MAC *Mycobacterium avium* complex.

really only in the early and uniform use of CT scanning in patients not scheduled for early surgery).

Specific Conditions

— **Acute appendicitis.** That a patient suffers from AIDS does not mean that he cannot develop acute appendicitis and, in fact, the incidence of appendicitis in the HIV population appears to be higher than in the general population. While some patients present with typical symptoms and localizing signs in the right lower quadrant, often the presentation is atypical: diarrhea and vomiting are seen frequently while fever and leukocytosis are not very reliable. CT scan is the diagnostic imaging study of choice when the presentation is atypical. Interestingly, CMV (cytomegalovirus) infection and Kaposi sarcoma of the base of the appendix have been reported to cause appendicitis. The operative and post-operative management are similar to those in the non-HIV population (◉ Chap. 28).

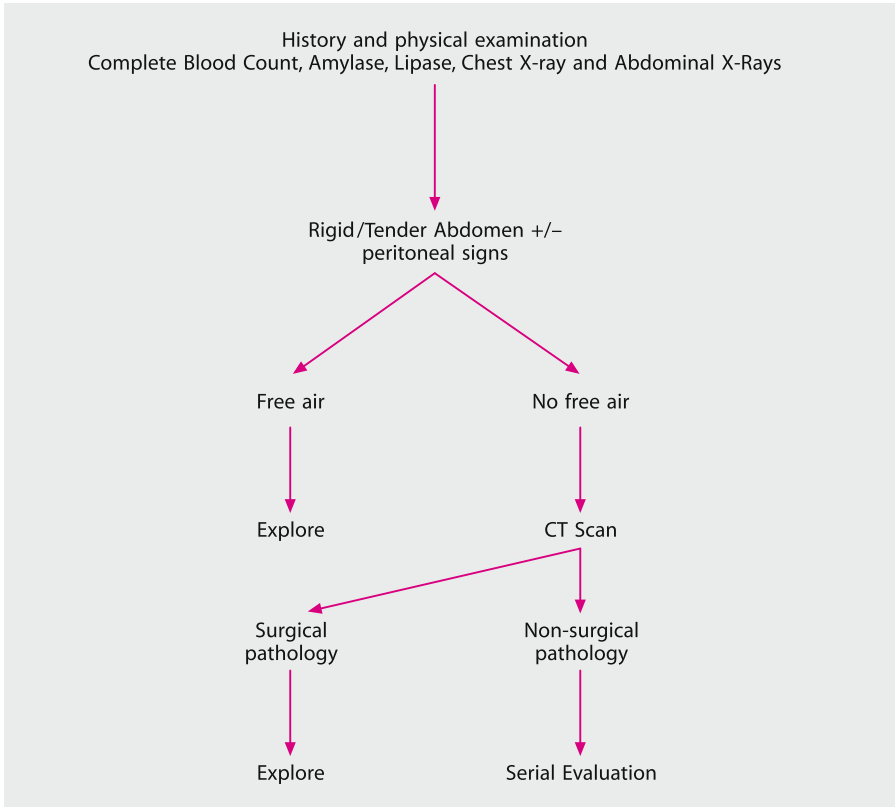


Fig. 33.2. An approach to abdominal pain in AIDS patients

— **Cytomegalovirus.** In the AIDS patient, CMV is found in every organ system in the body, is the most common opportunistic infection of the gastrointestinal tract, and often involves the colon – causing fever, diarrhea and abdominal pain. CMV infects endothelial cells, leading to thrombosis of the sub-mucosal blood vessels which results in mucosal ischemia, ulceration, hemorrhage, perforation and toxic megacolon. Diagnosis is established by colonoscopy and biopsy, which shows characteristic intra-nuclear inclusion bodies. CT scan findings of thickening of bowel wall and mural ulceration are non-specific. Once the diagnosis is established, treatment with ganciclovir or foscarnet is started. It is very important to keep these patients under close observation while they are on medical therapy, to identify early the development of complications. **Despite aggressive medical management some patients develop perforation, toxic megacolon and hemorrhage – complications that require urgent surgical intervention – following adequate fluid resuscitation and institution of broad-spectrum antibiotic therapy.** The perforations related to CMV appear punctate when viewed from the serosal surface. Resection of the

involved segment of bowel and formation of a colostomy or ileostomy – rather than primary anastomosis – is the treatment of choice. Toxic megacolon with impending perforation is best managed with a sub-total colectomy and ileostomy.

— **Acute cholecystitis.** Right upper quadrant abdominal pain associated with fever, nausea and vomiting is a common complaint in patients with HIV/AIDS. While the cause of this pain may be due to hepatomegaly associated with granulomatous infiltration or colitis, the possibility of biliary pathology needs to be investigated. Although gallstones are present in many HIV/AIDS patients undergoing cholecystectomy they are also believed to have a relatively high incidence of acalculous cholecystitis. CMV and *Cryptosporidium* are the commonest opportunistic micro-organisms isolated from the affected gallbladders: overwhelming growth of the pathogens seems to cause inflammation and functional obstruction, unlike the combination of hypotension, ischemia and sepsis that is believed to be the cause of acalculous cholecystitis in the non-HIV, critically ill patient. **Ultrasound** is the initial imaging study of choice: gallstones, size of the common bile duct, gallbladder wall thickness, pericholecystic fluid and intramural air can be demonstrated. **CT scan and HIDA scan** (radioisotope hepatic iminodiacetic acid) are useful when the sonogram is inconclusive. As the pathogenesis of acalculous cholecystitis may not involve cystic duct obstruction, the HIDA scan may demonstrate gallbladder filling. Once the diagnosis is established, depending on the overall condition of the patient, surgical intervention is recommended. Laparoscopic cholecystectomy can be safely performed, as experimental observations have not substantiated the concerns of aerosolization of HIV virus in the laparoscopy gas. To prevent blood spray during retrieval of the gallbladder, the pneumoperitoneum must be evacuated first. The routine use of specimen bags is recommended to prevent the accidental spillage of infected contents. The relatively high morbidity and mortality of cholecystectomy in these patients reflects the fact that acalculous cholecystitis occurs in the more advanced stages of AIDS.

— **Splenic abscess.** Splenic abscess is more common in patients with HIV/AIDS. Metastatic spread from other infections, secondary infection of a splenic infarct and contiguous spread from an adjacent organ, are the possible mechanisms of its development. CT scan or ultrasound establishes the diagnosis. In the absence of loculations, percutaneous CT-guided drainage of splenic abscess has a reasonable success rate. Splenectomy is the definitive treatment when radiological features do not favor percutaneous drainage or to salvage a failed radiological intervention.

— **Perianal sepsis.** Acute anorectal conditions are discussed in ◉ Chap. 29 but AIDS patients are different. Anorectal pathology is very prevalent in the HIV/AIDS population, especially in those who practice anal-receptive intercourse. While being susceptible to anorectal problems of the general population, HIV/AIDS patients are additionally prone to a variety of opportunistic infections like CMV, herpes, and benign and malignant neoplasms in the perianal area. Careful inspection of the

perianal area, gentle digital rectal examination and a proctoscopic visualization will identify the perianal condition. **Examination under anesthesia** is an essential part of evaluation before definitive surgical therapy. As in the non-HIV population, perianal sepsis in this population could result from cryptoglandular disease or, by contrast, be associated with HIV-related anorectal ulcers or result from secondary infection of anal proliferative lesions. The abscesses associated with HIV-related anorectal ulcers tend to be very deep – transgressing the sphincter planes – with variable destruction of the sphincter mechanism. Surgical intervention is usually necessary: abscesses should be liberally drained and specimens should be obtained for acid-fast staining and culture. Biopsy for histology is done if underlying malignancy is suspected. The principles of treatment are similar to the management of perianal sepsis in Crohn's disease – it has to be conservative. Damage to the sphincters is avoided and non-cutting setons and drains are utilized liberally. Delayed wound healing is a major concern with CD4+ cell count of less than 50/ μ l being a predictor of delayed wound healing.

Remember:

- The general principles of surgical care described in this book are applicable to the HIV/AIDS patients; however, a thorough understanding of the natural history and the spectrum of HIV disease is essential. The pathology may or may not be related to their HIV status
- Abdominal complaints are extremely common in the HIV population and clinical evaluation is often difficult. Serial clinical examination and frequent use of CT scan are essential to prevent non-therapeutic interventions
- Early diagnosis and prompt intervention are essential for non-HIV-related surgical pathology like acute appendicitis and cholecystitis. Surgical intervention is also essential for complications of opportunistic infections like CMV perforation. The morbidity and mortality for surgical procedures depends on the stage of the HIV disease and the nature of pathology.
- Surgical interventions should not be denied to this population because of the risk of occupational transmission and the fear of high complication rates. Relief of symptoms and improvement in quality of life are the chief considerations.

EVERY B. NATHENS

“It is absolutely necessary for a surgeon to search the wounds himself, which were not drest by him at first, in order to discover their nature and know their extent.”
(A. Belloste, 1701)

Among many trauma surgeons, decision-making in patients with penetrating trauma is considered much easier than that in blunt abdominal trauma. The principal reason for this difference is that the clinical exam is not clouded by an altered sensorium due to head injury and the source of blood loss in the unstable patient is usually localized to the abdomen. These factors make an expensive, time-consuming series of radiologic investigations unnecessary. In fact, with the exceptions described below, **there is no role for imaging studies in patients with penetrating abdominal injuries.**

Avoid Unnecessary Laparotomies

The goal is to operate on patients in a timely fashion without an excess rate of *unnecessary operations*. Many surgeons distinguish a negative laparotomy from a non-therapeutic one. A *negative laparotomy* refers to an operation where no injury is identified, whereas a *non-therapeutic laparotomy* refers to the situation where an injury is identified but requires no surgical intervention. For example, an operation where a non-bleeding stab wound to the liver is identified would be considered a non-therapeutic laparotomy. However, I contend that there is no need to discriminate between the two – in either case the patient experiences the cost and consequences of an unnecessary procedure without any benefit.

Stab versus Gunshot Wounds

The approach to patients with gunshot wounds to the abdomen differs significantly from that of stab wounds (or other impalements). The reason for a different approach is that almost every transabdominal gunshot wound requires an operation

* A comment by the Editors is found at the end of the chapter.

and in almost all cases this operation will identify injuries in need of surgical repair. The yield is far lower for stab wounds, so most (smart) surgeons use a *selective approach* to guide the need for operation. However, as surgeons become more comfortable with selective non-operative management of stab wounds, some have applied a similar approach to patients with gunshot wounds.

Stab Wounds to the Abdomen

All decision-making in patients with a stab wound to the abdomen begins with the assessment of vital signs. **A laparotomy is indicated in all patients with unstable vital signs – either hypotension or persistent tachycardia if the latter is presumed to be due to hemorrhage.**

In patients with upper abdominal or *thoracoabdominal stab* wounds (i.e., between the nipples and the costal margins), a chest X-ray is warranted to rule out a significant hemothorax or pneumothorax, which might represent an immediate threat to life and/or alter the surgical plan. It is also important to consider the potential for pericardial tamponade due to a ventricular laceration in patients with wounds to the epigastrium. There is usually neither time nor need for any imaging study to diagnose tamponade. It will become evident at laparotomy when the trajectory of the wound is cephalad to or through the diaphragm. In this setting, a rapid pericardial window and conversion to sternotomy is indicated.

If the patient is hemodynamically normal, the next important determinant is evidence of peritonitis, a clinical finding being suggestive of an injury to a hollow viscus (e.g., stomach, small bowel, or colon). The diagnosis of peritonitis is not straightforward, as many of these patients have local pain at the site of penetration. If generalized peritonitis is present, a laparotomy is clearly indicated.

Aside from generalized peritonitis and hemodynamic instability, the only other indication for laparotomy at initial presentation is a retained stabbing instrument. As the instrument might be tamponading a significant arterial or venous injury, these should be removed under direct vision in the operating room.

Occasionally, peritoneal penetration manifests as *omental or bowel evisceration* through the stab wound. These patients have a high likelihood of hollow viscus injury and should undergo operation to safely reduce the herniated contents, rule out other injuries and properly close the fascia.

The “Asymptomatic” Patient

Decision-making in the relatively asymptomatic patient without the indications for operation listed above is more complicated. The first question to be answer-

ed is whether or not there is penetration of the peritoneum. **Of all stab wounds to the abdomen one-third do not have peritoneal penetration and another third have peritoneal penetration without any significant abdominal injury.** Wound exploration using local anesthetic and appropriate lighting usually allows one to determine whether the peritoneum has been violated.

If it can be established **with certainty** that there is no peritoneal penetration, the patient can be safely discharged from the emergency department

Peritoneal penetration confirmed by wound exploration presents two options:

— The first approach, and one practiced safely by many experienced clinicians, is admission to an observation unit with serial examinations. This is an active process requiring serial hematocrits, hourly monitoring of vital signs, and repeat examination of the abdomen at intervals no greater than every 4 hours for 24 hours. Any clinical deterioration or change in the abdominal examination warrants a laparotomy.

— In the second approach, practiced in some institutions, clinicians employ diagnostic peritoneal lavage to provide an earlier diagnosis of intra-abdominal injury. The red blood cell threshold typically used as an indication for laparotomy is much lower than that for blunt trauma, usually in the range of 1,000 to 10,000 cells/dl. The lower the threshold, the higher the rate of negative or non-therapeutic laparotomy. The high rate of negative laparotomy represents the single major disadvantage to this approach. By contrast, the rate of negative laparotomy in those who fail serial examination is, as one would expect, much lower.

Adjunctive Imaging

In patients with *stab wounds to the back or flank*, the risk of abdominal injuries is quite low. However, the retroperitoneal colon, duodenum, kidneys, ureter and major vascular structures are all at risk. Injuries to the retroperitoneal colon or duodenum will typically manifest later than intraperitoneal injuries, and are associated with significant morbidity. On the other hand, stab wounds to the kidneys might not require operation at all. Given the potential morbidity of a significantly delayed diagnosis of a retroperitoneal injury, a CT scan of the abdomen with intravenous, oral, and rectal contrast to opacify the entire colon should be performed to allow earlier diagnosis of injuries requiring repair. This approach is indicated only if there is no other reason to operate.

The Diaphragm

There is a lot of controversy regarding the natural history of stab wounds to the diaphragm. It is likely that many of these remain silent with no adverse consequences over the patient's lifetime. Alternatively, there might be a risk of chronic diaphragmatic herniation with the potential for late complications such as strangulation requiring a more difficult repair. For this reason, diagnostic laparoscopy (or thoracoscopy) should be performed to evaluate fully the diaphragm in patients with thoracoabdominal stab wounds who lack other indications for operation. If there is an injury to the diaphragm, we convert to laparotomy to rule out a hollow viscus injury, as the sensitivity of laparoscopy in identifying such injuries is poor. At laparotomy, a thorough exploration is carried out and all injuries repaired. If at laparoscopy for a right thoracoabdominal stab wound, a non-bleeding liver laceration is identified, it is often possible to repair the diaphragmatic laceration laparoscopically and avoid a laparotomy entirely.

Gunshot Wounds to the Abdomen

Traditionally, the standard of care for a gunshot wound to the abdomen was a laparotomy. The rationale for this approach was two-fold. First, the incidence of injuries requiring repair was considered high enough that the rate of negative laparotomy was minimal. Secondly, the morbidity associated with a negative laparotomy was considered trivial.

Non-operative Management

With higher rates of negative laparotomy in the civilian population (with less destructive munitions) and a greater understanding that a negative laparotomy is associated with a real rate of complications and costs, some trauma surgeons are beginning to re-evaluate this. **There is an increasing trend toward selective non-operative management of stable patients without evidence of peritonitis.** These patients undergo active observation as that described above for stab wounds. If the patients are well selected, approximately one-third might get by without a laparotomy. Those who fail non-operative management do so early, typically in the first 4 hours.

Successful non-operative management requires experience, good clinical judgment and, not infrequently, a CT scan of the abdomen to help define the trajectory of the bullet.

Certain clinical settings are better suited to selective management. For example, a gunshot wound to the *right thoracoabdominal region* (between the right

nipple and right costal margin) typically injures the liver and diaphragm. As the liver will prevent diaphragmatic herniation, there might be very little to be gained by operation in the stable patient. However, as for stab wounds, the natural history of these diaphragmatic injuries is unknown and might be associated with significant later morbidity. Another scenario appropriate for selective non-operative management is a *low transpelvic* gunshot wound. These gunshot wounds might injure the rectum, bladder and iliac vessels. If the trajectory of the bullet can be determined to be extraperitoneal and injury to these structures ruled out using a combination of sigmoidoscopy, CT scan and cystography, then non-operative management might be appropriate. A diagnostic peritoneal lavage might be necessary to rule out intraperitoneal penetration if this cannot be excluded with certainty based on CT scan.

As for stab wounds, successful non-operative management is an active process. If resources or manpower do not allow for serial re-evaluation and close monitoring, then a policy of routine laparotomy for gunshot wounds to the abdomen should be adhered to.

Conduct of the Laparotomy

The patient should be prepped from the neck to the knees so that the surgeon has access to all intrathoracic structures as well as vessels in the groin. A full-length midline incision provides access to the entire abdomen and should be the incision of choice if the patient is unstable. It is not appropriate to spend excessive amounts of time trying to get better exposure while trying to control bleeding. Smaller incisions might be appropriate for stab wounds or gunshot wounds in the stable patient. If there is a significant hemoperitoneum, all four quadrants should be packed off – both to tamponade ongoing bleeding and to allow the anesthesiologist time to catch up with restoration of intravascular volume. The packs are then removed sequentially, starting with the packs in the quadrants where there is least likely to be ongoing bleeding.

Once the source(s) of bleeding have been isolated and controlled, a more thorough evaluation of the abdomen should be done. It is critical to create a mental image of the trajectory of the bullet (or stabbing instrument) so that a thorough evaluation of all structures in the path can be carried out. While doing this bear in mind that the patient is likely to have been in a contorted position attempting to avoid injury and the result may be that individual intraperitoneal injuries may be anatomically widely separated. When evaluating injuries to hollow organs, there is almost always an even number of holes. Rarely, this rule is violated when an injury is tangential to the bowel or the missile fragment lodges within the bowel lumen. Diligence is required, particularly with stab wounds to the bowel as these might be

very subtle. There is no sense in subjecting the patient to an operation only to miss an injury.

To review exploration of the abdomen consult also • Chap. 11. Management of specific organ injuries is outlined in • Chap. 35.

Summary

- Stab wounds to the abdomen should be managed selectively, avoiding a large number of negative laparotomies (• Fig. 34.1).
- If local wound exploration demonstrates no peritoneal penetration, the patient can be discharged.
- If the patient is stable, without peritonitis, or bowel or omental evisceration, they should be observed with serial abdominal exams, hemoglobin, and white blood cell count. Any change in clinical status for the worse should mandate a laparotomy.
- Diaphragmatic injuries should be ruled out using laparoscopy in patients with thoracoabdominal stab wounds without other indications for laparotomy.

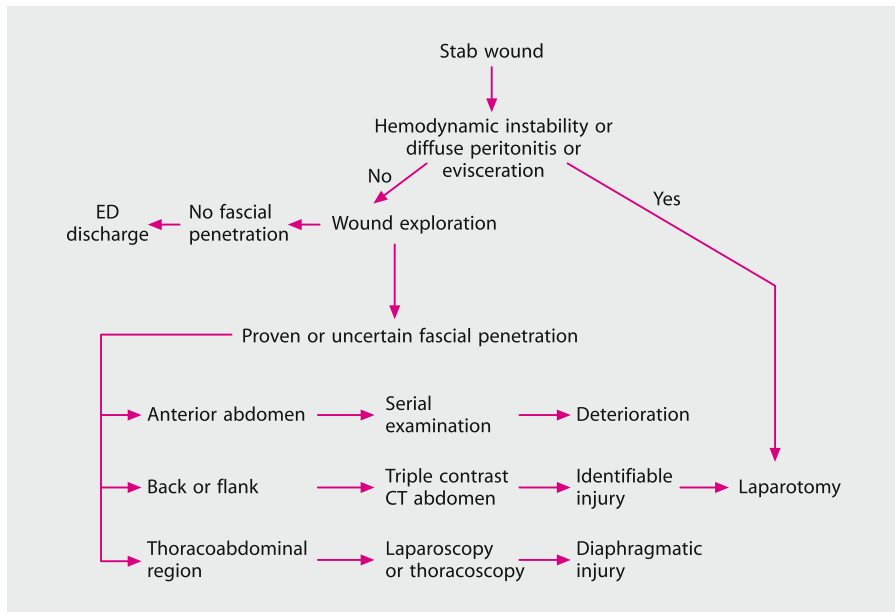


Fig. 34.1. Algorithm for the management of stab wounds to the abdomen (see text for details)

- Imaging studies have no role, except for patients with stab wounds to the back or flank, where CT scan using intravenous, oral and rectal contrast to opacify the entire colon will help identify the relatively few patients who will require operation.
- The selective approach is not well accepted for gunshot wounds, so it is my preference to subject these patients to laparotomy given the high likelihood of intra-abdominal injuries requiring operative repair.

“It is highly desirable that anyone engaged in war surgery should keep his idea fluid and so be ready to abandon methods which prove unsatisfactory in favor of others which, at first, may appear revolutionary and even not free from inherent danger.” (H. H. Sampson, 1940)

Editorial Comment

Dr. Nathens provides a balanced approach to the patient with penetrating abdominal injuries – not too aggressive, not too conservative and extremely safe. But wherever you practice and whatever your experience do understand that two-thirds of stab wounds to the abdomen do not need surgery. Shock and/or peritonitis indicate a laparotomy – when absent you may take Dr. Nathens’s advice and explore the wound to detect peritoneal penetration and discharge home those with proven superficial wounds.

All the others should be subjected to “selective conservatism” during which the abdomen is frequently re-evaluated at intervals of 1–3 hours, preferably by the *same surgeon*. The stab wound and its surroundings are usually tender. It is useful to mark with a pen the tender zone around the laceration to monitor any subsequent spread of the tenderness beyond the marked area. Even if you feel that the patient may object to being treated as a drawing table, the underlying principle is to look for evidence of tenderness *away from the stab wound*.

Please do us a favor and do not subject patients with stab wounds to the anterior abdominal wall to CT and diagnostic laparoscopy. People who perform these unnecessary investigations do it because they lack clinical skills and experience. In our hands, and those of others, the *clinical* approach has proven reliable and safe. Do you want to be known as a seasoned clinician? Practice as one.

Laparoscopy or thoracoscopy to identify diaphragmatic injuries seems sensible if the wound is left-sided. We remain skeptical of the benefits of active management of lesions over the right hepatic lobe; it seems unlikely that troublesome hernias will occur in this situation.




Fig. 34.2. “Let’s be conservative!”

Whether you want to explore all abdominal gunshot wounds, including those with an innocent looking abdomen – denoting absence of peritoneal penetration or a tangential abdominal wall trajectory of the bullet – is up to you. However, the vital signs and abdominal examination in most of these patients will declare that a prompt laparotomy should be performed. When the patient is hemodynamically stable and his abdomen is clinically “innocent” we see no reason to treat him other than with the selective conservatism outlined above (● Fig. 34.2).

“Failure to promptly recognize and treat simple life-threatening injuries is the tragedy of trauma, not the inability to handle the catastrophic or complicated injury.”
(F. William Blaisdell)

AVERY B. NATHENS

The approach to blunt abdominal trauma differs considerably from that taken with penetrating trauma for several reasons:

- The frequent coexistence of a head injury renders the physical exam unreliable if not actually impossible.
- Even with a communicative patient, multiple injuries to other body regions render the abdominal examination less reliable. Proximity of rib or pelvic fractures may produce pain and tenderness in the upper and lower abdomen, respectively. Significant extremity fractures and associated soft tissue injury may distract the patient from noticing abdominal pain or tenderness.
- Hemodynamic instability might represent bleeding into the thigh following a femur fracture; blood loss into the pelvic retroperitoneum following a severe pelvic fracture; hemothoraces; tension pneumothorax; neurogenic shock or, rarely, blunt cardiac injury.

In essence, the abdomen represents a “black box”, which might or might not be the source of the patient’s blood loss or subsequent deterioration in the case of a missed hollow viscus injury (▶ Fig. 35.1). In the remote past, the only diagnostic test available was a laparotomy. As the frequency of injuries requiring operation following blunt trauma is low, this approach resulted in a large number of either negative or non-therapeutic laparotomies with their attendant morbidity. As a result, laparotomy as a “diagnostic test” if you will, has been supplanted by a multi-modality approach tailored to the individual patient.

Laparotomy Without Prior Testing?

In blunt trauma, there are almost no clinical settings that mandate laparotomy without a prior abdominal test pointing to a “surgical problem” in the abdomen. One example would be a chest radiograph demonstrating a traumatic diaphragmatic hernia. In this situation no additional tests are required to lead the surgeon to operate.



Fig. 35.1. “So what’s wrong inside your black box?”

A distended abdomen in a hypotensive patient usually represents hemoperitoneum but might occasionally be a manifestation of a massive retroperitoneal hematoma following a pelvic fracture. An operation in this situation would likely increase pelvic bleeding, rather than offer benefit.

A “seat belt sign” refers to abdominal bruising over the lower abdomen and results from wearing a seat belt across the abdomen, rather than across the iliac crests. This sign indicates significant crushing of the mesentery and hollow viscera between the abdominal wall and the spine at the time of injury. It might be associated with a *Chance fracture of the second lumbar vertebrae*. The presence of a seat-belt sign, particularly in the context of a Chance fracture is associated with a small bowel or pancreatic injury in one-third of patients. Additionally, the abdominal wall bruising renders the abdominal exam inaccurate. To avoid missing a small bowel injury, some surgeons operate on all those with this constellation of injuries; however, this approach would result in unnecessary operations in over two-thirds of patients.

Adjunctive Diagnostic Tests in Blunt Abdominal Trauma

There are three diagnostic tests that guide the surgeon in the patient with blunt abdominal trauma: *ultrasonography* (referred to as FAST – focused abdominal sonography for trauma), *computed tomography* (CT), and *diagnostic peritoneal lavage* (DPL). **Only DPL and FAST are appropriate for the hemodynamically unstable patient.** The radiologists emphasize the speed of helical CT scanners with the ability to complete a scan in under a minute. However, the need to transport the patient from stretcher to CT scan, setting up the appropriate CT protocol, administering intravenous contrast (oral contrast is unnecessary) and taking the patient off

the scanner takes at least 20 minutes. By contrast, a FAST exam can be done in less than 3 minutes and a DPL in about 5 minutes without having to move the patient. There is considerable debate about whether a marginal patient (intermittent hypotension, tachycardia) can safely undergo a CT scan. Often, they can tolerate the time required for the scan, but there is a risk of sudden deterioration in a very uncontrolled environment. In view of the potential for a rapid change in clinical status, FAST or DPL should be used in this setting.

FAST: Focused Abdominal Sonography for Trauma

FAST might be performed by the surgeon, emergency room physician or radiologist. It is not a regular diagnostic abdominal ultrasound. Instead, its sole purpose is to identify fluid in one of four areas:

- Morrison's (hepatorenal) pouch in the right upper quadrant
- The splenorenal recess in the left upper quadrant
- The pelvis
- The pericardial sac

It is important to note that with the exception of the pericardial sac, at least 300 ml of fluid must be present before it can be reliably detected by FAST. Evaluation of the pericardium is routinely performed to rule out the possibility of pericardial tamponade. **The presence of abdominal free fluid in an unstable patient is an indication for urgent laparotomy.** With an understanding that no test is perfect, the FAST exam should be repeated or a DPL performed in the presence of unexplained hypotension and an initial negative FAST.

DPL: Diagnostic Peritoneal Lavage

DPL is performed less frequently with the ready availability of FAST in the unstable patient and CT in the stable. However, it is cheap and fast, although somewhat invasive.

- A *grossly positive* DPL means that gross blood is aspirated from the DPL catheter following its insertion.
- A *microscopically positive* DPL usually refers to a DPL with $>100,000$ red blood cells per mm^3 as measured following the collection of the DPL effluent.

In an unstable patient a grossly positive DPL is an indication for operation. If only microscopically positive (usually manifest as an inability to read newsprint through the blood-stained fluid), the source of blood loss is usually the abdomen, but other occult sources of blood loss (e.g. the pelvis) should also be considered.

As DPL is very sensitive to small amounts of blood loss, operating on stable patients with a microscopically positive DPL will result in a high rate of non-therapeutic laparotomies. If the DPL fluid is seen flowing out through the urinary catheter or the chest tube, the patient should undergo laparotomy for suspected bladder rupture or diaphragmatic rupture, respectively. This scenario is rare, but should be considered. Similarly, if gross enteric contents are seen upon aspiration of the peritoneal fluid, laparotomy for bowel injury is mandated. Bacteria present on Gram-stain might either represent a bowel injury, or more commonly, placement of the DPL catheter (or needle) into the bowel. With this limitation in mind, DPL is the most sensitive test for a bowel injury and because of this strength, it is the test of choice in patients where the possibility of such an injury is high – typically in a patient with a seatbelt sign.

CT: Computed Tomography

In the stable patient, a CT scan is the test of choice. Depending on institutional protocols, CT scan might be the initial diagnostic test, or alternatively, might follow a positive FAST or DPL if these were performed and the patient remains stable.

A CT scan will identify the source of blood loss both in the peritoneal cavity and in the retroperitoneum (a limitation of both FAST and DPL). If there is a liver or spleen laceration, the information can be integrated into the clinical picture and an assessment made as to whether the patient might be a candidate for a trial of non-operative management (see below). Improvements in CT technology have increased the sensitivity and specificity of this test for the identification of *injuries to the bowel* – often suggested by mesenteric stranding, mesenteric fluid, bowel thickening and/or extraluminal air.

Occasionally, *free fluid without a solid organ injury* is identified and the question arises as to whether there is an injury to bowel or mesentery that requires operation. If the patient has a reliable abdominal exam, he can be followed by serial examination. If not, a DPL is a reasonable test to ensure the fluid is not bowel contents, reflected by an elevated effluent amylase or bacteria on Gram-stain. If this cannot be reliably ascertained, a non-evaluable patient with free fluid and no solid organ injury should undergo a laparotomy.

It is critically important to use clinical judgment and never solely rely on one test if the clinical picture doesn't make sense. This is particularly true for FAST, where operator dependence and the timing of the test are important. For example, an exam done very early following injury might be negative if there is insufficient time for significant bleeding to occur. In settings where CT is not readily available, FAST (preferably, if local expertise allows) or DPL can be used to screen patients who will ultimately require a CT scan. DPL is our test of choice in hemodynamically

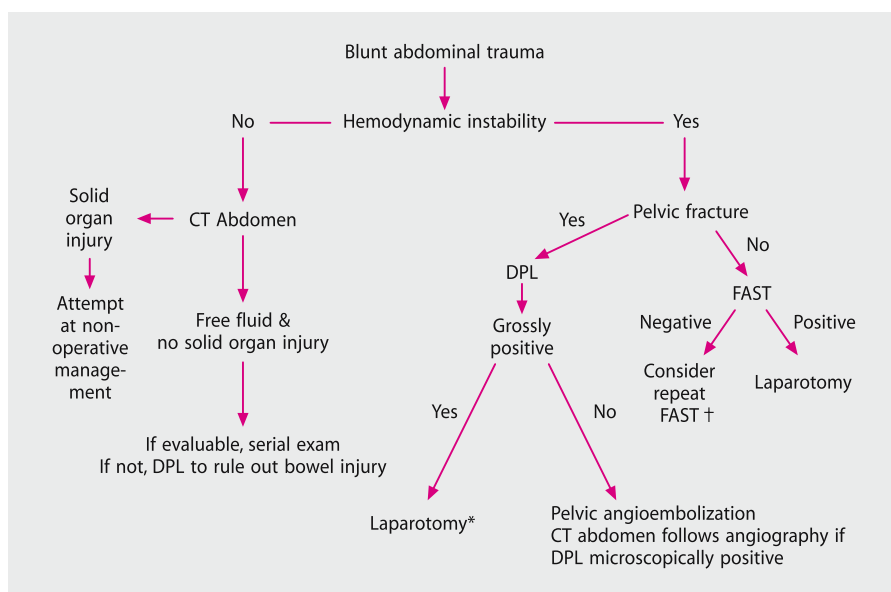


Fig. 35.2. Algorithm for the assessment of the patient with blunt abdominal trauma. *Patient might require pelvic angioembolization postoperatively. †If time interval from injury is very short, repeat FAST prior to discharge from the emergency department or within an hour of arrival

unstable patients with significant pelvic fractures (see below) (◉ Fig. 35.2). Additionally, in clinical settings where CT is not available, then DPL is the test of choice due to its higher sensitivity albeit, at the cost of lower specificity.

Non-operative Management of Solid Organ Injuries in Blunt Trauma

If a CT scan demonstrates an injury to the liver or spleen and the patient remains hemodynamically stable without evidence of peritonitis, then an initial attempt at non-operative management is warranted. This is the preferred approach and is easily accomplished in most patients.

Non-operative management:

The patient should be admitted to an intensive care unit or other closely monitored environment for at least 24 hours with careful serial abdominal examination and repeat hemoglobin evaluation. If stable, the patient can be transferred to a regular ward bed with less intensive monitoring for the 3–5 days, depending on the

severity of the injury. Serial imaging studies have been recommended by some, but it is our preference to limit repeat imaging studies to those who develop evidence of complications. Patients are told to avoid contact sports or any activity that might put the injured organ at risk for approximately 3 months.

The Spleen

If the patient has a splenic injury and a persistently dropping hemoglobin is noted during the course of observation, a splenectomy should be performed in preference to blood transfusion. The approach is different in children, where transfusion risks are balanced by the risk of post-splenectomy sepsis, leading to a greater tolerance for transfusion. Any patient who develops hemodynamic instability during a period of observation with a splenic injury should undergo splenectomy. Attempts at splenic salvage in adult patients belong to history.

The Liver

Severe liver injuries require a more complex decision making process. With an understanding that mobilization and/or manipulation of the injured liver will often lead to significant bleeding (and significant transfusion requirements), we are much more apt to transfuse in the hope of avoiding an operation. Even hepatic angio-embolization should be considered for the stable patient with a dropping hemoglobin. It is important to be aware of the potential for bilomas or abscesses in patients with severe liver injuries. Any evidence of increasing pain, jaundice or sepsis should provoke a repeat CT scan to re-evaluate the right upper quadrant. Hemodynamic instability in a patient with a liver laceration is an indication for operation.

Management of Individual Organ Injuries

“We will always start with the most dangerously injured without regard to rank and distinction.” (Jean Larrey, 1766–1842)

You have decided to perform a laparotomy. The incision and finding out what’s wrong are described in ◀ Chaps. 10 and 11, respectively. Here, we’ll run through the essentials in the management of specific abdominal injuries. In general, doing “less” in blunt trauma may be “better” – the less blood you lose the better is the outlook for the patient. Do not forget that your operation adds further tissue injury fueling the inflammatory response, and increasing the risk of later complications (▶ Chap. 48).

Diaphragm

A through-and-through diaphragmatic laceration requires closure with heavy, interrupted, sutures. Lacerations with substantial tissue loss are rare and need repair with a synthetic mesh-patch. If the tissue loss is at the periphery, it is possible to reimplant the diaphragm to the ribs more cephalad and avoid using prosthesis. This is very helpful in patients with extensive contamination where the risk of prosthetic infection is substantial.

Liver

An irreverent classification of liver injuries follows:

- **Nothing should be done (treat conservatively)**
- **Something should be done (local hemostasis)**
- **Too much should not be done (packing only)**
- **Only God can do something (heroic measures)**

The following are some practical considerations:

- Bleeding from small, superficial capsular tears can be controlled by diathermy or individual vessel ligation.
- More severe bleeding constitutes a surgical challenge requiring a stepwise approach. First, the liver should be packed with laparotomy pads. *Liver packing* implies restoring the normal anatomy of the liver by placing packs in the subphrenic region and below the liver, thus pushing the liver up tightly against the diaphragm. This tight packing effectively closes the laceration and tamponades bleeding. **If the liver is packed too tightly, however, the inferior vena cava (IVC) is compressed, which will further aggravate hypotension.** One option is to roll up packs and place these behind the liver, just to the right of the IVC, effectively buttressing the liver off of the IVC. The depths of the laceration should not be packed. If a decision is made to leave packs in place and return to the operating room another day, it is our practice to place absorbable mesh between the packs and the liver so that removal of the packs does not cause further bleeding.
- *If packing is ineffective*, or the decision is made to pursue hemostasis further, the next step is to perform a Pringle maneuver (occlusion of the undissected triad of portal vein, hepatic artery and common bile duct), which can be performed intermittently for periods of up to 60 minutes (you can use an atraumatic bowel clamp for this purpose). If inflow occlusion stops the bleeding, then the primary source is a branch of the hepatic artery or portal vein. If not, then the source is usually either a hepatic venous branch or the retrohepatic vena cava. Once inflow occlusion is performed, the liver should be rapidly mobilized by division of its

ligamentous attachments. Deep parenchymal bleeding is then controlled by finger fracture technique, individual vessel ligation or clipping, and conservative resectional debridement. Rarely is hepatic artery ligation (either the hepatic artery proper or its left or right branch) required for control, but should be considered when necessary. Residual parenchymal dead space can be plugged with viable omentum.

- Retrohepatic caval injuries are characterized by exsanguinating hemorrhage despite inflow occlusion; probably there are more techniques described for immediate hemostasis than there are survivors; it is perhaps best to resort to damage control with packing and come back to fight another day.

- Injuries to the porta hepatis require a wide Kocher maneuver for exposure. The injured portal vein should be repaired or, as a last resort, ligated. Hepatic artery ligation is better tolerated than portal vein ligation. Suture repair or Roux-en-Y biliary enteric anastomoses are the treatment options for an injured common bile duct; the latter can be performed either at the initial operation or at the reconstruction phase of a damage control strategy. Unilateral lobar bile duct injuries should be managed by ligation.

Spleen

The treatment at laparotomy of a significant splenic injury in the adult is splenectomy. The risk for post-splenectomy sepsis exists but it is negligible and can be further minimized by adequate prophylaxis and vigilance; it is, nevertheless, often overemphasized to justify what we regard as the potentially harmful acrobatic surgical maneuvers of splenic conservation. Additionally, most patients undergoing laparotomy for blunt trauma are doing so because of hemodynamic instability and/or failed attempt at conservative management. The excess time required for splenorrhaphy in this context is not justified.

Kidney and Ureter

The intra-operative discovery of a perinephric hematoma is usually indicative of renal injury, but a large proportion of these are self-limiting. Kidney exploration is indicated in the presence of an expanding or pulsatile hematoma, or when a hilar injury is suspected. Moderate severity injuries can be controlled usually by cortical renorrhaphy and drainage; occasionally, a polar nephrectomy may be indicated. A shattered kidney or a vascular hilar injury requires nephrectomy. Contrary to advice offered by some, preliminary control of the renal artery and vein is not necessary prior to exploration of the kidney. This is particularly true now that operations are being done primarily for hemodynamic instability. Attempts at saving a kidney

in the unstable patient are probably not warranted unless the patient has a single kidney. Lacerations of the renal pelvis are treated with fine absorbable sutures. An injured ureter should be carefully exposed, avoiding ischemic damage by over-enthusiastic skeletonization. Primary repair over a double-J stent with absorbable material is the rule. Either very proximal or very distal ureteric injuries require an expert urologic opinion.

Pancreas

The anterior aspect of the pancreas is exposed through the lesser sac by division of the gastrocolic omentum; the posterior aspect of the head is exposed by a Kocher maneuver, whereas access to the posterior aspect of the tail is achieved by splenic mobilization. **The state of the main pancreatic duct is a crucial determinant of the operative strategy in the injured pancreas.** Intraoperative pancreatography by means of a cholecystectomy and cholangiogram with filling of the pancreatic duct is occasionally informative. Pancreatograms performed through a duodenotomy with cannulation of the ampulla of Vater have been described, but creating an enterotomy in the presence of a significant pancreatic injury might cause more harm than good. In some settings, intraoperative endoscopic pancreatography (ERCP) might be available.

With an understanding that intraoperative pancreatograms are a luxury, we attempt to determine the integrity of the pancreatic duct by examining the pancreas. If the main duct appears intact (superficial parenchymal wounds) most pancreatic injuries require drainage alone. When deeper parenchymal wounds are observed in the body or tail, indicating the possibility of a distal ductal transection, a distal pancreatectomy (usually with splenectomy) is indicated. For deeper injuries of the head wide drainage is indicated; the management of the inevitable pancreatic fistula is simpler than that of a leaking enteric fistula in the aftermath of a fancy immediate reconstruction with Roux-en-Y pancreaticojejunostomy. Additionally, postoperative ERCP might demonstrate an injury to the proximal duct, which can often be stented, thus controlling the fistula. The Whipple procedure is reserved for massive injuries of the pancreatic head, with common bile duct and duodenal disruptions; the procedure is attended by a high mortality and might require a staged approach – with the reconstruction performed only after the patient has been stabilized. The following aphorism captures most of what you should know about pancreatic trauma:

“For pancreatic trauma: treat the pancreas like a crawfish, suck the head... eat the tail.” (Timothy Fabian)

Stomach

Most injuries are caused by penetrating trauma and are treated by simple suture repair. The posterior gastric wall should always be checked by opening the lesser sac. Blunt injuries are rare and gastric resection exceptionally required.

Duodenum

Intramural duodenal hematomas without full-thickness injury do not require evacuation; nasogastric suction, fluid replacement and nutrition (intravenous or via jejunostomy) need to be instituted for up to 3–4 weeks. Clean-cut, small lacerations can be safely repaired primarily. Extensive lacerations, the presence of significant tissue contusion (usually inflicted by blunt trauma), involvement of the common bile duct, or high velocity gunshot injuries should be treated by duodenal repair and pyloric exclusion. This procedure consists of closure of the pylorus through a gastrotomy and re-establishment of gastrointestinal continuity by a gastrojejunostomy; the addition of a truncal vagotomy is not necessary. A feeding jejunostomy is a useful adjunct for the provision of enteral nutrition. The Whipple operation is reserved for massive combined pancreaticoduodenal disruptions; in an unstable patient you should stage it – resect first and return another day for reconstruction.

Small Bowel

Most lacerations can be treated by simple suture repair; occasionally a segmental resection with end-to-end anastomosis is required for the treatment of multiple lacerations in close proximity. Significant mesenteric lacerations might compromise large segments of small bowel. If there is a large amount of bowel of questionable viability and a risk that an extensive resection will result in short gut syndrome, than a second-look laparotomy should be performed. A decision of what bowel is viable and what is not is best made in the well-resuscitated patient. As mentioned in ◉ Chap. 13, we feel that in the post-resuscitation, edematous intestine, hand sutured anastomoses are safer than the stapled ones.

Colon

Right or left-sided colonic lacerations can be safely treated by suture repair or resection with primary anastomosis (by necessity, in an unprepared colon). Long-standing peritonitis mandates the performance of a colostomy. We avoid a

primary anastomosis following destructive colon injuries in the presence of shock or extensive other intra-abdominal injuries. Lacerations to the colon following blunt trauma are rare. Usually extensive areas of deserosalization occur, typically in the cecum and sigmoid colon where the seat belt compresses the underlying viscera. Rather than resect, it is our approach to extensively imbricate (repair the serosa) the injury, even if circumferential.

Rectum

In the absence of gross fecal contamination, minor lacerations can be repaired by simple suture repair. In all other cases, a proximal diverting colostomy must be added; a loop sigmoid colostomy is usually adequate. Wash-out of the distal rectal stump and pre-sacral drainage seem unnecessary except in extensive injuries with wide dissection and soiling of the peri-rectal spaces.

Bladder

An intraperitoneal rupture requires repair with absorbable sutures and catheter drainage; in an extraperitoneal rupture, catheter drainage alone is sufficient. In both cases, the bladder drainage provided by a urethral Foley catheter is adequate, rendering suprapubic drainage unnecessary.

Intra-abdominal Vascular Injuries

— *The aorta:* the most important step in the management of aortic injuries is exposure in order to achieve proximal and distal control. The posterior parietal peritoneum must be incised lateral to the left colon, allowing the reflection of the colon to the right and the small bowel medially. If needed, other organs can also be reflected medially: left kidney, spleen and pancreas, stomach. The suprarenal aorta can be approached through the gastrocolic omentum – via the lesser sac – with retraction of the stomach and esophagus to the left. For injuries to the supraceliac aorta, a left thoracotomy may be required. Aortic injuries require repair with a 3-0 or 4-0 polypropylene monofilament.

— *Infrahepatic vena cava:* the exposure to the infrahepatic vena cava is achieved by incision of the peritoneum lateral to the right colon and medial reflection of the right colon, duodenum, right kidney and small bowel. The bleeding site must be occluded by direct finger pressure, the use of sponge-sticks or vascular clamps; no attempt should be made to encircle the vessel. Venorrhaphy can be achieved with a

4-0 or 5-0 monofilament vascular suture; also check for the presence of a posterior laceration that can be repaired by gently rotating the vena cava or from inside the vessel. In massive disruptions, a synthetic graft may be used, but more commonly the infrarenal vena cava is ligated. Ligation is not well tolerated above the renal veins.

- Injured *common or external iliac arteries* should be repaired; if a graft is necessary, synthetic material may be used even in the presence of peritoneal soiling. In the setting of gross contamination the artery should be ligated and circulation restored with a fem-fem extra-anatomic bypass. The internal iliac artery may be ligated with impunity.

- The exposure of the *iliac veins* is notoriously difficult and may require the division of the ipsilateral internal iliac artery or even a temporary division of the common iliac artery. Iliac veins may be ligated with little morbidity provided compression stockings and limb elevation are used postoperatively.

- The *celiac artery*, the retro-pancreatic portion of the *superior mesenteric artery* and the *inferior mesenteric artery* may be ligated; the infra-pancreatic superior mesenteric artery should be repaired. The *superior mesenteric vein* should be repaired if possible; its ligation causes bowel infarction in a small percentage of cases only but **it often results in severe postoperative intestinal congestion; small and large bowel varices are a well-described sequela.** The *inferior mesenteric artery* may be ligated without risk.

Heroic attempts to restore flow by repairing a vessel in a patient in extremis should not be tried. At times, ligation with later revascularization (if the extremity remains viable) might be necessary. A better approach is a temporary shunt across the injury with definitive revascularization over the subsequent 24 hours.

Retroperitoneal Hematoma

The main issue is whether to explore or observe such a hematoma discovered in the course of a trauma laparotomy.

As a general rule, in penetrating trauma, all retroperitoneal hematomas should be explored, irrespective of their location or size. In blunt trauma, a more selective policy can be applied, depending mainly on the location of the hematoma.

- A central abdominal location (Zone I) (including the main abdominal vessels and the duodeno-pancreatic complex) always warrants exploration.

- Lateral hematomas (Zone II) (including kidney and retroperitoneal portion of the colon) can be left alone, unless they are very large in size, pulsating or expanding.

Table 35.1. Approach to traumatic retroperitoneal hematoma

Type of hematoma	Penetrating injury	Blunt injury
Central (Zone I)	Explore	Explore
Lateral (Zone II)	Usually explore	Usually do not explore
Pelvic (Zone III)	Explore	Do not explore

— Blunt traumatic pelvic hematomas (Zone III) should not be explored. It is important to realize that these hematomas may extend cephalad – even so, exploration may result in the loss of the tamponade effect of the intact retroperitoneum (see Table 35.1).

The Management of Pelvic Hematoma

With the exception of isolated fractures of the iliac crest, fractures involving the pelvic or obturator rings and/or sacrum have the potential for significant bleeding leading to shock and death. The bleeding arises from disrupted pelvic veins, branches of the iliac (usually internal) arteries and cancellous bone. For this reason, all patients with a significant mechanism of injury undergo a simple anteroposterior radiograph of the pelvis as part of their initial evaluation. Additionally, simple lateral or anteroposterior compression of the pelvis might demonstrate instability of the pelvic ring.

With this degree of pelvic instability, particularly in the presence of a dropping hemoglobin and/or hemodynamic instability, we wrap a sheet around the iliac crests and tie it tightly, effectively reducing the volume of the pelvis, and increasing the potential for tamponade by the pelvic retroperitoneum.

With the pelvis wrapped as above, a rapid assessment must be made as to the site of bleeding. With the *chest* as a source of blood loss ruled out by a simple chest X-ray, the possibilities include *extremity fractures* (often obvious) or the *abdomen*. **The question of intra-abdominal bleeding is critical. An unnecessary laparotomy in a patient with a large pelvic hematoma from a pelvic fracture only decompresses the hematoma and leads to more bleeding. There is very little that one can do operatively. To avoid this scenario, we perform a very quick supra-umbilical DPL.** Ultrasonography is less accurate in the context of a severe pelvic fracture.

— If the *DPL is grossly positive*, the patient is first rapidly transported to the operating room to deal with a source of bleeding in the peritoneal cavity.

- If the DPL is not grossly positive, our preference is to accompany the patient to *angiography*, where the radiologist embolizes major arterial bleeding. These patients are critically ill and require the presence of nurses and physicians actively resuscitating them during this process. Angioembolization should be used selectively – bleeding arteries are found in approximately 60%–80% of patients that are unstable. If the patient is not unstable, the yield of angiography is much lower. In these cases, the bleeding is assumed to be coming from disrupted pelvic veins and/or bone.
- In clinical settings where angiography isn't readily available, the next option is placement of an *external fixator on the pelvis*. In effect, this replaces the sheet placed during the initial resuscitation. It functionally reduces the volume of the pelvis and re-approximates bony fragments. As a result, it might lessen bleeding coming from veins and cancellous bone, but the effect on arterial bleeding in our experience, is minimal.

A severe pelvic fracture is to be respected – there is little a surgeon can do to stop the bleeding, but much that can be done to make the bleeding worse. Do not explore these hematomas in the operating room, and if a laparotomy is necessary, do not extend the incision down to the pubic symphysis – this will allow the pelvic hematoma to decompress freely. Our approach is to limit the incision to just below the umbilicus and extend more caudally only if absolutely required.

The Abbreviated Trauma Laparotomy

When physiology is disrupted attempts at restoring anatomy are futile

In a small minority of patients, time-consuming organ repair cannot be undertaken safely in a patient with a critical physiological status. A bailout procedure consisting of temporary control of bleeding and contamination is then indicated. **These cases can be recognized either by physiological criteria or by a complex pattern of anatomical injuries.** In the first setting, the presence of coagulopathy, hypothermia and acidosis – the triad of death – singly or in combination, are pointers to impending physiological exhaustion. In the second setting, the combination of severe and complex injuries (for example, a major vessel injury associated with a severe duodeno-pancreatic disruption) is recognized early as a precursor of major blood loss and a prolonged reconstructive procedure, in an unstable patient. In these circumstances, the surgeon may opt for expeditious control of the hemorrhage (usually by packing) and the simplest means of preventing further peritoneal contamination. Abdominal closure would then consist of rapid cutaneous approxi-

mation or is avoided altogether – **thus avoiding the commonly associated abdominal compartment syndrome** (see ● Chap. 36). Our approach is to place an inexpensive bowel bag on the viscera and place drains on the bag. An impermeable occlusive dressing is placed over the drains to contain the viscera, bowel bag, and drains. The patient is then transported to the surgical intensive care unit where secondary stabilization is undertaken over the next 24–48 hours. Delayed definitive organ repair and abdominal closure are effected only when secondary resuscitation has been achieved.

Summary

- Patients experiencing blunt trauma require additional diagnostic tests to rule out intra-abdominal injuries.
- In the unstable patient, the goal of these investigations is not to precisely identify which organs are injured, but to identify which patients need a laparotomy. A FAST exam is a good screening test for this purpose, but in the case of unexplained hypotension and a dropping hemoglobin despite a negative FAST (and no other source of blood loss) or of a clinical picture that does not make sense, a DPL will be necessary to help decision making. We have seen a small number of patients with profound hypotension and significant hemoperitoneum in whom the FAST exam, even in retrospect, is negative.
- CT scan is the optimal test for patients that are stable. It provides information regarding the retroperitoneum and identifies injuries that might well be treated non-operatively (liver, spleen, kidneys). In centers with very high volume, or that have limited resources, ultrasound or DPL (depending on FAST expertise) are useful to identify patients that require a CT scan. A stable patient with a microscopically positive DPL or free fluid on FAST requires a CT scan.
- Surgery, when necessary, should be directed at accomplishing only what absolutely has to be done. Many of these patients have significant associated injuries and prolonged attempts at repair are unwarranted.
- The triad of hypothermia, acidosis and coagulopathy are harbingers of a bad outcome and are best avoided if at all possible. It is critical to maintain an appreciation for precisely where the patient is on the resuscitation continuum – their blood requirements, pH, temperature and coagulation panel are all critical in determining whether an extensive operation is appropriate and will guide when best to abbreviate the laparotomy.

The Abdominal Compartment Syndrome

MOSHE SCHEIN

In surgery, physiology is the king, anatomy the queen; you can be the prince, but only provided you have the judgment . . .

At Thanksgiving, a national holiday here in the United States, many millions of turkeys – also called “thanksgiving birds” – are tightly stuffed with various sorts of ingredients (mine would include chickpeas, garlic, wine-soaked bread, and thyme) and served to the assembled members of American families. Bear in mind, however, that these large birds are stuffed post-mortem but imagine what would happen to the poor bird if it were tightly stuffed alive? First, the bird would stop flying and then gradually it would hypoventilate, collapse and die. Surely, you could attribute the death of the stuffed avian to bad lungs, old heart, toxins produced by the ingredients used in the stuffing and as a last resort – you could blame the anesthetist. But frankly there is a huge body of first grade scientific evidence to prove beyond any doubt that the tragic outcome for your bird was the result of elevation of her **intra-abdominal pressure (IAP)**, causing **intra-abdominal hypertension (IAHT)**, which in turn led to the **abdominal compartment syndrome (ACS)**.

Does Abdominal Compartment Syndrome Exist?

Much good evidence now supports the concept that elevated IAP or IAHT may impair physiology and organ function by producing the *abdominal compartment syndrome (ACS)*. Complex, adverse physiological consequences of increased IAP develop as the pressure is transmitted to adjacent spaces and cavities, decreasing cardiac output, restricting pulmonary ventilation, diminishing renal function and visceral perfusion, and increasing cerebrospinal pressure (● Table 36.1, Fig. 36.1).

How Do You Measure IAP?

At the bedside, IAP is best measured through the urinary bladder catheter connected to a manometer or a pressure transducer. In fact, all you need to measure IAP is a Foley catheter: disconnect it from the urine bag; instill 100 ml saline into

Table 36.1. Physiological consequences of intra-abdominal hypertension

	Increased	Decreased	No change
Mean blood pressure	–	–	x
Heart rate	x	–	–
Peak airway pressure	x	–	–
Thoracic/pleural pressure	x	–	–
Central venous pressure	x	–	–
Pulmonary capillary wedge pressure	x	–	–
Inferior vena cava pressure	x	–	–
Renal vein pressure	x	–	–
Systemic vascular resistance	x	–	–
Cardiac output	–	x	–
Venous return	–	x	–
Visceral blood flow	–	x	–
Gastric mucosal pH	–	x	–
Renal blood flow	–	x	–
Glomerular filtration rate	–	x	–
Cerebro-spinal fluid pressure	x	–	–
Abdominal wall compliance	–	x	–

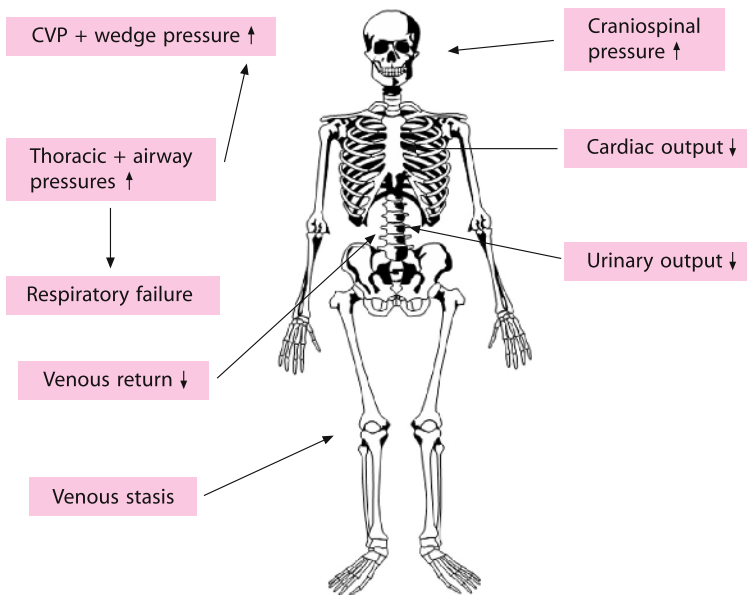


Fig. 36.1. The abdominal compartment syndrome

the bladder and elevate the disconnected catheter perpendicular to the supine patient and his bed. The height of the water-urine column in the catheter is the IAP in cmH₂O (1 cm H₂O=0.735 mmHg). The level will fluctuate with the patient's respiratory cycle – up during inspiration, down during expiration – following the movements of the diaphragm. A neurogenic or small contracted bladder may render the measurements invalid. Errors can also occur if the catheter is blocked or in the presence of a pelvic hematoma which may selectively compress the bladder. Because the Trendelenburg position (or its reverse) may affect intra-bladder pressure, accurate measurements are best achieved in the supine position.

Deleterious Consequences of Raised IAP Appear Gradually

At pressures less than 10 mmHg cardiac output and blood pressure are normal but hepatic arterial blood flow falls significantly; IAP of 15 mmHg produces adverse, but easily compensable, cardiovascular changes; IAP of 20 mmHg may cause renal dysfunction and oliguria, and an increase to 40 mmHg induces anuria. In an individual patient, the effects of increased IAP are not isolated but usually superimposed on multiple underlying and co-existent factors, the most notable being hypovolemia, which aggravates the effects of increased IAP.

Why Didn't You Notice IAHT and ACS Before?

Because you – or your mentors – did not know that this entity exists! (● Fig. 36.2) Any increase in the volume of any of the contents of the abdomen or the retroperitoneum elevates IAP. Clinically significant elevation of IAP has been observed in a variety of contexts (● Table 36.2), such as: postoperative intra-abdominal hemorrhage, after complicated abdominal vascular procedures or major operations like hepatic transplantation, in association with severe abdominal trauma accompanied by visceral swelling, hematoma or the use of abdominal packs, severe peritonitis, necrotizing pancreatitis, use of the pneumatic anti-shock garment, and tense ascites in cirrhotic patients. Peritoneal insufflation during laparoscopic procedures is currently the most common (iatrogenic) cause of IAHT. Note that severe intestinal edema causing IAHT has been described following massive fluid resuscitation for **extra-abdominal** trauma. The combination of severe abdominal wall burns – producing a tight-constricting eschar, and fluid resuscitation causing visceral edema – could lead to ACS in the burned patient.

Be aware that *morbid obesity* and *pregnancy* (● Chap. 31) are “chronic” forms of IAHT; various manifestations associated with such conditions (e.g. hypertension, pre-eclampsia) are attributed to IAHT. Note that *anything* can cause IAHT and



Fig. 36.2. “What? Abdominal compartment syndrome? Never heard of it!”

Table 36.2. Etiology of increased intra-abdominal pressure. The list cannot be considered “complete” as any increase, of any etiology, in the volume of the intra- or retro-peritoneal space will increase intra-abdominal pressure

Condition	Etiology
ACUTE	
I. Spontaneous	Peritonitis, intra-abdominal abscess, ileus, intestinal obstruction, ruptured abdominal aortic aneurysm, tension pneumoperitoneum, acute pancreatitis, mesenteric venous thrombosis
II. Postoperative	Postoperative peritonitis, paralytic ileus, acute gastric dilatation, intra-peritoneal hemorrhage
III. Posttraumatic	Intra/retro-peritoneal bleeding, post-resuscitation visceral edema
IV. Iatrogenic	Laparoscopic procedures, pneumatic anti-shock garment, abdominal packing, reduction of a massive parietal or diaphragmatic hernia, abdominal closure under excessive tension
CHRONIC	
	Ascites, large abdominal tumor, chronic ambulatory peritoneal dialysis, pregnancy, morbid obesity

ACS – irrespective of the ingredients used in the “stuffing” or its flavor. The “stuffing” can even be composed of feces:

An elderly lady presented with poor peripheral perfusion, blood pressure of 70/40, and respiratory rate of 36/min. Her abdomen was very distended, diffusely tender with guarding. Rectal examination revealed a large amount of soft impacted feces. Blood urea nitrogen (BUN) and creatinine levels were 30 mg% and 2 mg%, respectively. Arterial blood gases showed a metabolic acidosis with pH of 7.1. Her IAP was 25 cm H₂O. She survived following a decompressive laparotomy and resection of the partially ischemic rectosigmoid.

Only a few years ago we would have described this patient as suffering from “septic shock” due to “colonic ischemia”. We would have attributed the cardiovascular collapse and acidosis to the consequences of endotoxemic sepsis. But today it is clear to us that the mass effect created by the extreme dilatation of the rectum produced severe IAHT, causing cardiovascular and respiratory collapse and renal dysfunction – representing a typical ACS. This further decreased splanchnic perfusion, thus aggravating colorectal ischemia. Rectal disimpaction and abdominal decompression rapidly reversed the adverse physiological manifestations of the abdominal hypertension. Being more aware that IAHT is a “real problem” and liberally measuring IAP, we recognize it with an increasing frequency in our daily clinical practice.

The Mechanisms Culminating in an ACS Are Usually Multiple

The typical scenario occurs in a multiple trauma or post-emergency laparotomy patient who receives a large volume of fluid for resuscitation, causing an increase in interstitial fluid volume. The ensuing visceral and retroperitoneal edema is aggravated by shock-induced visceral ischemia and reperfusion edema, as well as by temporary mesenteric venous obstruction caused by surgical manipulation or the employment of hemostatic packs. The edematous abdominal wall is closed over the bulging abdominal contents under extreme tension.

The Clinical Syndrome

The clinical syndrome of ACS consists of:

- Need for increased ventilatory pressure
- Presence of decreased cardiac output
- Decreased urinary output
- Abdominal distension

These abnormalities are often present despite apparently normal cardiac filling pressures because transmission of increased IAP to the thorax elevates central venous pressure (CVP), right atrial pressure and pulmonary capillary wedge pressure. Cardiovascular, respiratory and renal dysfunction become progressively difficult to manage unless IAP is reduced. Rarer consequences of ACS have been described, such as intestinal ischemia following laparoscopic cholecystectomy or spinal cord infarction in the setting of IAHT following a perforation of a gastric ulcer.

When Should You Consider Abdominal Decompression?

The decision to decompress the abdomen should not be taken based on isolated measurements of IAP without taking into account the whole clinical picture. Early or mild physiological abnormalities caused by IAHT can be managed by fluid administration or afterload reduction. (Note, however, that increasing cardiac filling offers only a temporary solution and that fluid administration may in fact increase tissue edema and thus aggravate IAHT). In patients receiving mechanical ventilation *muscle paralysis* may decrease IAP by relaxing the abdominal wall.

Established ACS, however, mandates an emergency decompressive laparotomy, which, when performed in the well-resuscitated patient, promptly restores normal physiology. To prevent hemodynamic decompensation intravascular volume should be restored, oxygen delivery maximized, and hypothermia and coagulation defects corrected. Following decompression, the abdominal skin and fascial edges are left open using one of the temporary abdominal closure devices (TACD) described in ◉ Chap. 46.

Prevention

In order to avoid IAHT and ACS, forceful closure of the abdomen in patients having massive retroperitoneal hematoma, visceral edema, severe intra-abdominal infection, or a need for hemostatic packing, should be avoided (◉ Chap. 38). Leaving the fascia open, closing only the skin with sutures or towel clips to protect the bulging viscera, has been recommended. Occasionally, however, the skin closure alone may produce IAP of 50 mmHg or more. Certainly, leaving both fascia and skin unsutured offers maximal reduction in IAP but may result in fistula and evisceration. Bridging the fascial gap with a TACD circumvents these problems (◉ Chaps. 38, 46, and 47).

Would Decompression Benefit Patients with Only a Moderate IAHT?

That the “extreme” case of ACS as described above necessitates an urgent abdominal decompression is obvious. But what about a less extreme case? Would decompression benefit a postoperative patient in whom the moderately increased IAP of 20 mmHg is compensated by appropriate fluid and ventilatory therapy? We believe that the available evidence suggests that the detrimental effects of IAHT take place long before the manifestations of ACS become clinically evident – just as nerve and muscle ischemia begins long before neuromuscular signs of the extremity compartment syndrome are evident. IAHT may cause gut mucosal acidosis at relatively low pressures, long before the onset of clinical ACS. Uncorrected, it may lead to splanchnic hypoperfusion, distant organ failure and death. Prophylactic non-closure of the abdomen may facilitate the prevention, early recognition and treatment of IAHT and reduce these complications. It appears that “borderline” IAHT contributes to the overall morbidity but the risk/benefit ratio of abdominal decompression in such patients is not yet clear.

In Conclusion

IAHT is yet another factor to consider in the overall management of the emergency abdominal patient. It may be obvious – “crying” for abdominal decompression. More commonly, however, it is relatively silent but contributing to your patient’s SIRS (systemic inflammatory response syndrome), organ dysfunction and death. So now you know better, you know that your patient is not a dead turkey to be stuffed. Bon appetit!

Be as aware of intra-abdominal hypertension as you are of arterial hypertension. It is much more common and clinically relevant than you have suspected hitherto.

PAUL N. ROGERS

Abdominal/back pain and hypotension = a ruptured AAA, unless proven otherwise.

Urological and orthopedic wards are a cemetery for ruptured AAA cases.

Presentation

The diagnosis of a leaking abdominal aortic aneurysm (AAA) is usually not difficult to make. Typically the patient presents with a sudden onset of acute lumbar backache, abdominal pain and collapse associated with hypotension. On examination the presence of a pulsatile abdominal mass confirms the diagnosis. In this situation the patient proceeds directly to the operating room with a delay only to allow cross-matched blood to become available if the patient is stable.

Atypical Presentation

Not infrequently however, the diagnosis can be difficult to make. There may be no history of collapse and the patient may be normotensive on admission. The only clue may be non-specific back or abdominal pain. A pulsatile mass may not be palpable. Ruptured AAA patients are frequently obese; thinner patients tend to notice their AAA and present early for an elective repair. A leaking AAA may be mislabeled as “ureteric colic” but the absence of microscopic hematuria should alert one to the possibility that a leaking aneurysm is responsible for the symptoms. A high index of suspicion is important to prevent the diagnosis of a leaking AAA being overlooked. In appropriate individuals, particularly men in late-middle and old age, if significant and unexplained abdominal or back pain causes the patient to present acutely, abdominal aneurysms should be excluded by means of ultrasound or CT.

The Diagnostic Dilemma

A different diagnostic dilemma occurs in the patient who is known to have an aneurysm and who presents with abdominal or back pain, which may or may not be related to the aneurysm. The difficulty here is that a small, contained, “herald” leak from an aneurysm might produce pain without any hemodynamic instability. Examination in these patients may be unhelpful in that the aneurysm may not be tender. These patients are at high risk of a further bleed from the aneurysm and this could be sudden and catastrophic. For this reason it is important that they are identified appropriately and have an operation before a major, possibly fatal, hemorrhage occurs. The difficulty of course is that such a patient might easily have another cause for the symptoms, mechanical backache for example, which is unrelated to the aneurysm. Here, an operation is clearly not in the patient’s best interests, particularly if his or her general health is poor. **This dilemma, of operating without delay in patients who require it yet avoiding operation in those in whom it is not necessary, is a difficult one, sometimes even for experienced clinicians to resolve.** An emergency CT scan is indicated in this situation to delineate the AAA and presence of any associated leak – usually into the retroperitoneum. In general however, in this situation it is safer to err on the side of operating on too many rather than too few patients.

Who Should Have an Operation?

A useful rule of thumb is that the chances of survival in a patient with a ruptured AAA are directly proportional to the blood pressure on admission. Shocked patients rarely survive; sure, they may survive the operation but usually do not leave hospital through the front door. Consequently, it has been proposed that operating on shocked ruptured AAA patients is a futile waste of resources. Another view is that you should proceed with the operation unless the patient is clearly “agonal” or known to suffer from an incurable disease. You may be able to save the occasional patient and gain additional experience, which may help you to save the next rupture patient. These issues of philosophy of care are for the individual surgeon to resolve with his patients. A scoring system has been devised that aims to help with this decision-making. The so-called Hardman criteria relate the presence of several easily determined variables to the likelihood of survival from surgery from a ruptured aneurysm.

The Hardman¹ Criteria

- ✓ Age >76
- ✓ History of unconsciousness
- ✓ Hemoglobin <9.0 g/dl
- ✓ Creatinine >190 µmol/l
- ✓ ECG evidence of ischemia

If three or more criteria are present the mortality is 100%

If two are present mortality is 72%

If one, 37%

It is impossible to fill a bucket which has a hole.

The Operation

Once the diagnosis of aortic rupture has been established, or strongly suspected, the patient should be rushed to the operating theatre without delay. Do not even bother with additional lines and intravenous fluids as what you pour in will pour out, and increasing the blood pressure will increase the bleeding. **Aim for stable hypotension in resuscitation.**

Preparation ▶ “Prep and drape” for surgery while the anesthetic team establishes the appropriate monitoring lines. Do not allow them, however, to waste time by inserting unnecessary gimmicks such as the pulmonary arterial catheter. Anesthesia should not be induced until you are ready to make the skin incision; not infrequently the administration of muscle relaxants at induction, and the subsequent relaxation of the abdominal wall, is sufficient to permit a further bleed from the aneurysm with an immediate hemodynamic collapse. **Remember: your clamp on the aorta proximal to the aneurysm is more important than anything else.**

Incision ▶ Open the abdomen through a long mid-line incision extending from the xiphisternum to a point mid way between the umbilicus and the symphysis pubis. Occasionally, if the distal iliac arteries are to be approached, the incision must be extended. In most cases however, for the insertion of a simple aortic tube graft, an incision as described is adequate.

¹ Hardman DT, Fisher CM, Patel MI, Neale M, Chambers J, Lane R, Appleberg M (1996) Ruptured abdominal aortic aneurysms: who should be offered surgery? *J Vasc Surg* 23:123–129.

Proximal Control ▶ Upon entering the peritoneal cavity, the diagnosis is immediately confirmed by the presence of a large retroperitoneal hematoma. The first priority is to obtain control of the aorta proximal to the aneurysm. In the majority of patients who are stable at this stage (with a contained retroperitoneal leak), there is time to approach the aorta above the aneurysm just below the level of the renal arteries. In patients who are unstable, rapid control of aortic bleeding may be obtained by approaching the aorta just under the diaphragm and temporarily applying a clamp there until the infra-renal aorta can be dissected.

Subdiaphragmatic Aortic Control ▶ Remember how you do truncal vagotomy? Of course you don't! So pay attention. Incise the phrenoesophageal ligament overlying the esophagus (feel the nasogastric tube underneath). With your index finger bluntly mobilize the esophagus to the right; forget about hemostasis at this stage. Now feel the aorta pulsating to the left of the esophagus, dissect with your index on both sides of the aorta until you feel the spine. Apply a straight aortic clamp, pushing it "onto" the spine. Leave a few packs to provide hemostasis and proceed as below.

Infra-renal Aortic Control ▶ Returning to the matter of isolation of the aortic neck note that the main principle to be observed is to avoid disturbing the retroperitoneal hematoma while gaining control of the proximal aorta. Once you enter the retroperitoneum at the neck's level, dissect bluntly using your finger or the tip of the suction apparatus, to identify and isolate the neck of the aneurysm. Once the neck is identified carry on down both sides of the aorta until the vertebral bodies are reached. Do not attempt to encircle the aorta with a tape. Apply a straight aortic clamp in an antero-posterior direction with the tips of the jaws of the clamp resting against the vertebral bodies. Placement of this clamp is facilitated by placing the index and middle fingers of your non-dominant hand on either side of the aorta so that the vertebral bodies can be palpated. The jaws of the open clamp are then slid along the backs of the fingers until the clamp lies in the appropriate position. Now you can remove the subdiaphragmatic clamp.

Juxtarenal Neck ▶ Occasionally the aneurysm extends close to the origin of the renal arteries. If this is the case then the neck of the aneurysm will be obscured by the left renal vein, which may be stretched anteriorly. Care must be taken that the vein is not damaged. It may be divided to facilitate access to the aneurysm neck. This is done by very gently mobilizing the vein from the underlying aorta. It should be ligated securely as close to the vena cava as prudence permits. If this is done then the vein may be ligated with impunity and the kidney will not be endangered, because collateral venous drainage will take place via the adrenal and gonadal anastomoses. **How do you know that effective proximal control has been achieved?**

Simple – the retroperitoneal hematoma stops pulsating. If it pulsates your clamp is not properly placed. Re-apply it!

Distal Control ▶ The next part of the dissection to identify the common iliac arteries is often more difficult. Under normal circumstances the pelvis is the site of accumulation of much of the retroperitoneal hematoma and the iliac arteries are buried within this. The arteries are difficult to locate not only because they are buried in hematoma but because with the aorta clamped proximally, there is no pulsation to guide the operator. In most patients, however, the presence of atheroma in the vessels makes palpation in the depths of the hematoma possible. Again, the use of the suction apparatus facilitates isolation of the iliac vessels. Otherwise, dig with your fingers within the hematoma and “fish” the iliacs out. As with the aorta, no attempt should be made to encircle the iliac vessels with tapes. This invariably produces damage to the iliac veins, which is a disaster. It is sufficient to clear the anterior and lateral aspects of the iliac vessels and apply clamps in an anteroposterior manner as before.

An Alternative – Balloon Control ▶ After proximal control has been achieved and when the iliacs are immersed within a huge hematoma you may also rapidly open the aneurysm sac and shove a Foley or large Fogarty catheter into each iliac artery, inflating the balloons to produce temporary distal control.

Aortic Replacement ▶ Once the proximal and distal arterial tree is controlled, incise the aneurysm sac in a longitudinal fashion. Evacuate the clot and control back bleeding from any patent lumbar arteries and the inferior mesenteric artery with sutures within the aneurysm sac. A small self-retaining retractor placed within the aneurysm sac to retract its cut edges facilitates this and the next few stages of the procedure. The proportion of patients in whom aortic replacement with a simple tube graft can be achieved varies widely from surgeon to surgeon and center to center. **We believe that in the majority of patients insertion of a tube graft can be achieved quite satisfactorily.** The advantages of this are that limitation of dissection in the pelvis minimizes the risk of damage to the iliac veins and also damage to the autonomic nerves in the pelvis. Furthermore, there seems little point in extending the length of what is already a challenging operation by inserting a bifurcation graft unnecessarily. Obviously there are circumstances when a tube graft is not acceptable – namely when the patient has occlusive aorto-iliac disease, when the iliac arteries are also significantly aneurysmal, or in some situations when the bifurcation is widely splayed so that the orifices of the common iliac arteries are widely separated.

Take care when fashioning the aorta to receive the graft. The longitudinal incision in the aortic sac should be terminated at both ends by a transverse incision

so that the incision becomes T-shaped at each end. The limbs of the ‘T’ at either end should not extend more than 50% of the circumference of the normal aorta.

Suture the graft in place using monofilament material so that a parachute technique can be used. This allows you to visualize clearly the placement of the individual posterior sutures. Large bites of the posterior aortic wall should be taken because the tissues in this situation are often very poor. Furthermore, leaks that occur after completion of the anastomosis are notoriously difficult to repair if they are situated at the back wall. Once the upper anastomosis has been completed, a clamp is applied to the graft just below the anastomosis and the clamp on the aorta then released. Assuming there are no significant leaks at the upper end, attention is turned to the distal anastomosis. This is completed in a similar fashion to the proximal anastomosis. Back-bleeding from the iliac vessels should be checked before the distal anastomosis is completed. Likewise, the graft should be flushed with saline and one or two ‘strokes’ of the patient’s own cardiac output to clear it of thrombotic junk. If there is no back-bleeding it may be necessary to pass balloon embolectomy catheters into the iliac systems to check that there has been no intra-vascular thrombus formation. Once the distal anastomosis has been completed and found to be secure, the iliac clamps should be released individually allowing time for any hypotension to recover before the second clamp is removed. The anesthesia team will appreciate a warning from you that the time is approaching for removal of the clamps, allowing them to be well ahead with fluid replacement. Inadequate fluid replacement at this stage will result in significant hypotension when the iliac clamps are released.

A Word About Heparin ▶ It is clearly not sensible to administer systemic heparin prior to cross-clamping in patients who are bleeding to death from an aortic rupture. In patients in whom surgery has been carried out for suspected rupture, however, and in whom no rupture is found at operation, then systemic heparinization according to the surgeon’s normal practice should be carried out. It is permissible, however, to heparinize locally the iliac vessels once the aneurysm sac has been opened and back-bleeding from the small vessels has been controlled. Heparinized saline may be flushed down each of the iliac vessels in turn before reapplying the iliac cross-clamps. No consensus on the need for this practice has been reached and in the vast majority of patients it appears to be unnecessary.

Abdominal closure ▶ The large retroperitoneal hematoma and visceral swelling resulting from shock, resuscitation, re-perfusion and exposure, commonly produce severe intra-abdominal hypertension, which becomes manifest after closure of the abdomen. Rather than closing under excessive tension use temporary abdominal closure as discussed in ◉ Chap. 36, and come back to close the abdomen another day. **Avoidance of abdominal compartment syndrome is crucial for survival**



Fig. 37.1. AAA: common outcome...

in these physiologically compromised patients in whom any further derangement may be the straw that breaks the camel's back.

In emergency operations for AAA simplicity of the operation is a key for survival: rapid and atraumatic control, avoidance of injury to large veins, tube graft, minimal blood loss, and rapid surgery.

Many patients who reach the operating table will survive the operation only to die in its aftermath, usually due to associated medical illnesses such as myocardial infarction. A successful outcome therefore requires excellent postoperative ICU care as well as competent surgery. **The operation is only half the battle.**

In ruptured AAA the operation is commonly the beginning of the end—the end arriving postoperatively (● Fig. 37.1).

Aortic Occlusion

This emergency is characterized by acute ischaemia of the legs with mottling of the skin of the lower trunk. It occurs for three reasons:

- **Saddle embolus.** A large clot originating from the heart occludes the aortic bifurcation. The patient most likely will have signs of atrial fibrillation or a recent history of acute myocardial infarction.
- **Aortic thrombosis.** The patient probably has a history of pre-existing arterial disease suggestive of aorto-iliac involvement. Occasionally this disaster will occur

unannounced in a patient who is desperately ill for some other reason. Extreme dehydration, for example, may cause “sludging” of major vessels if there has been some pre-existing atheroma. Malignancy may produce intra-arterial thrombosis.

— **Aortic dissection.** Suspect this if there is a history of interscapular pain or chest pain associated with obvious hypertension. Look for evidence of other pulse deficits or signs of visceral ischemia suggesting involvement of other aortic branches.

Management

This depends on the etiology and the presence of any relevant underlying pathology. Embolism may often be dealt with easily by bilateral transfemoral embolectomy under local anesthetic. Thrombosis on pre-existing atheroma is a more difficult problem. Catheter thrombectomy is unlikely to be successful either in the short or long term. If the patient is very fit (unlikely) aorto-femoral bypass may be indicated. More likely an extra-anatomic bypass (axillo-femoral) may be feasible, always assuming that any underlying illness is not likely to cause the patient’s demise in the immediate future. Often these patients are not fit for any intervention and the aortic thrombosis is an indication that the end is near.

Aortic dissection is a complex illness and its management is variable. The mainstay is control of hypertension and relief of major vessel occlusion by endovascular “fenestration” of the dissection. The details of this therapy are beyond the scope of this little book.

MOSHE SCHEIN

Big continuous bites, with a monofilament and – above all – avoiding tension – this is how to avoid dehiscence and herniation.

Finally, it is time to “get the hell out of here”. You have been working all night and it is tempting to do so hastily. Impatience, however, is inadvisable since correct abdominal closure protects the patient from abdominal wound dehiscence and yourself from a great humiliation (“everybody knows”), and later on, from the development of a hernia. Yes, you are tired but, before closing, stop and think; ask your assistants: “Did we forget to do something?” See the checklist in ◊ Chap. 39.

Generally, an abdominal closure fails because of poor quality of the tissues, increased intra-abdominal pressure, faulty technique, or a combination of all of these. Occasionally, a suture knot comes undone, but more typically, the fault lies with the tissue and not the suture. In order to achieve secure closure keep in mind (and hands) the following.

Principles of Closure

Suture Material ▶ Use a non-absorbable (e.g. nylon or prolene) or “delayed” absorbable (e.g. PDS or Maxon) monofilament suture. Rapidly absorbed material such as Vicryl and Dexon are still widely used even though their use is illogical in view of wound-repair kinetics. Those who fancy such suture material produce the hernias for the rest of us to repair. Non-absorbed or slowly absorbable suture material, on the other hand, keeps the edges of wound together until its tensile strength takes over. Monofilament sutures are advantageous because they slide better, inflicting less “saw-injury” to the tissues and, when used in the preferred continuous fashion, better distribute the tension along the length of the wound. The use of braided non-absorbable material (e.g. silk) is associated with chronic infected sinus formation and belongs, we hope, to remote history.

"Mass Closure"

This is the preferred technique as documented in numerous studies. It has been popularized for the closure of midline incisions but is as effective for the closure of transverse-muscle cutting incisions. For the latter, however, many surgeons still prefer layered (posterior fascia–anterior fascia) closure. We do too. For example, to close a subcostal incision we would run a looped PDS 1 from the center laterally – taking the posterior sheath; at the lateral corner we would lock the suture and run it back medially – taking the anterior sheath, or vice versa.

"Mass closure" entails mono-layered suturing of **all** structures of the abdominal wall in a continuous manner to provide "one strong scar". The secret here is to take large bites of tissue, at least 1 cm away from the wound's edges; the bites should be closely spaced so not to create gaps greater than 1 cm. Avoid the common mistake of carefully excluding muscle in your fascial bites; this may look cosmetically appealing as the muscle is hidden away under the fascia, but does not produce the desired "mass scar". No less important is the issue of the **correct tension** to be set on the suture (◉ Fig. 38.1). If you pull too tight on the suture the tissue is strangulated and necrosed; if you keep the suture too loose the wound edges gape. Bear in mind that the muscles are relaxed as you close (or should be) and that postoperatively they will acquire their normal tone, the tissues in the wound will swell and abdominal girth will increase. All of these changes make the wound closure tighter; if it is tight when you put the sutures in then something must give way when these changes take



Fig. 38.1. "Jack, what are you doing?"... "The Boss told me to close it tight..."

place – the tissue tears. A suture-length to wound-length ratio of at least 3:1 will ensure a moderate but secure tension of closure. The corners of the incision are the Achilles heels of closure, especially the corner that is closed last. Do not compromise the complete closure of the corner because you are afraid of injuring the underlying bowel; there are good tricks to accomplish this endeavor – learn them from one of your mentors.

Do not harm the underlying bowel, which frequently bulges towards your large needle. At the end of the operation the anesthetist always swears to God that the patient is “maximally relaxed”; he lies. Make him relax the patient again – do not compromise. Protect the bowel by whichever instrument is available, the best, in our experience, being the commercially available rubber “fish” retractor. The assistant’s hand may be useful for this purpose but with all the hepatitis and HIV around we do not find many volunteers willing to offer a retracting hand.

We recommend the use of a “looped” number 1 PDS suture. It is a slowly absorbable monofilament, usually long enough to provide a suture-to-wound ratio of 3:1. Threading the needle through the loop after the first “bite” replaces the need for the initial knot.

The Subcutaneous Space

Now when the fascia is closed what to do with the subcutis? Nothing! There is no evidence that the so-called dead space reduction using subcutaneous fat approximation reduces wound complications. On the contrary, subcutaneous sutures serve as a foreign body and strangulate viable fat while not producing a more satisfactory wound. **Subcutaneous drains increase the rate of infection and are almost never indicated.** Plain *saline irrigation* has been shown to be useless, but use of topical antibiotics (solution or powder) has been demonstrated to further decrease wound infection rate in contaminated wounds in patients who have already received systemic antibiotic prophylaxis.

“Delayed Primary” or “Secondary Closure”

What about the well-entrenched ritual of “delayed primary” or “secondary closure” after contaminated or infected laparotomies?

We believe that these techniques are only rarely indicated. In spite of surgeons’ obsession with tradition, lessons learned years ago under certain circumstances are not necessarily true today. Thus, 20 years ago when antibiotic prophylaxis was given incorrectly, heavy silk sutures were buried in the fat, and rubber drains were

mushrooming through each wound, the infection rate in primarily closed wounds was intolerable. Today, on the other hand, with proper surgical technique and modern antibiotic prophylaxis, primary suture of the wound can be undertaken uneventfully in the majority of the emergency laparotomy cases. When a wound infection develops it usually responds to local measures. Thus, leaving all contaminated, potentially infected wounds gaping open – awaiting spontaneous or secondary closure – produces unnecessary physical and financial morbidity. On rare occasion we decide to leave a wound open, usually in patients with gross, established purulent or fecal peritonitis, in patients planned for further re-operations or in the re-laparotomized abdomen. In the vast majority of patients, we irrigate the subcutaneous tissues with antibiotics (after fascial closure) and close the skin with staples or interrupted sutures. Truly modern surgeons, however, are happy to close almost all wounds with a subcuticular stitch of absorbable material. This obviates the discomfort and expense of arranging staple or suture removal and gives a much neater scar. (You'd be surprised to discover how much this little thing matters to some patients!) An occasional wound infection is not a disaster and is simple to treat (🔗 Chap. 49).

The High-Risk Abdominal Closure

Classically, in patients with systemic (e.g. cancer) or local (e.g. abdominal distension) factors predisposing to wound dehiscence (🔗 Chap. 47), “retention” sutures were and are still used by surgeons. Those heavy “through-and-through”, interrupted sutures take bites of at least 2 cm through all abdominal-wall layers – including the skin – preventing evisceration but not the occurrence of late hernia formation.

We do not find any use for the *classical retention* sutures, which cut through the skin and produce parietal damage and ugly skin wounds and scars. Instead, we suggest that in selected high-risk closures, you place a few interrupted all-layers “mass” sutures (excluding the skin) to take the tension off the continuous “mass” closure. Should the latter fail at any point, the interrupted sutures would prevent separation of the fascial edges and evisceration¹.

The crucial consideration is, however, that use of retention sutures together with abdominal distension, results in intra-abdominal hypertension. Forceful closure under excessive tension may result in an abdominal compartment syndrome

¹ Co-editor comments: There is no evidence supporting this. Moreover, if the mechanically sound pulley mechanism of the mass suture fails, then these itty-bitty interrupted sutures cannot survive!

with its deleterious physiological consequences (☛ Chap. 36). Thus, when the fascia is destroyed as is often the case after multiple abdominal re-entries, or when closure may produce excessive intra-abdominal pressure **we suggest that you do not close the abdomen but cover it with a temporary abdominal closure device (TACD)** (☛ Chaps. 36, 46, and 47).

In conclusion – remember: “Big continuous bites, with a monofilament, not too tight – this is how to avoid dehiscence and herniation”.

“Abdominal closure: if it looks all right, it’s too tight – if it looks too loose, it’s all right.” (Matt Oliver)

MOSHE SCHEIN

Takeoffs are optional. Landings are mandatory.

Everyone knows that a “good landing” is one from which you can walk away. But very few know the definition of a “great landing.” It’s one after which you can use the airplane another time. Yes, we know that you are tired; you may have worked all night and this may be the last of many long cases. But any landing must be perfect and even this last operation has to succeed.

Before closing the abdomen you must be absolutely happy with what you did. Prevent “guilt-worry”. Always ask yourself “Am I totally satisfied with my procedure?” (♦ Fig. 39.1). Don’t silence the little voice within you that informs you that the anastomosis is somewhat dusky. You must be absolutely convinced, at this stage, that you have done the best that your patient deserves. If not, swallow your pride, do it again, or call for help. Hiding a potential problem will not solve it. And you will go back to sleep so much better.

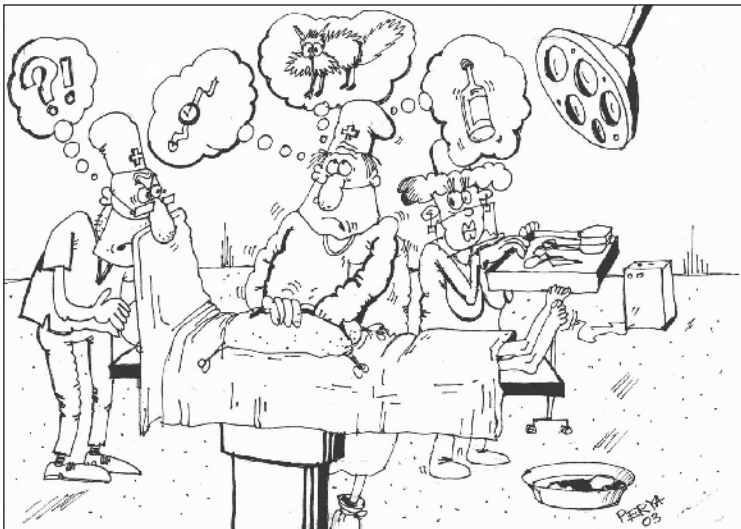

Fig. 39.1. “Am I satisfied?”

You may want to go over a pre-closure checklist:

Hemostasis perfect? This does not mean that you have to run after each red blood corpuscle...

Source control achieved?

Peritoneal “toilet” completed? All fluid sucked out?

Anastomosis: Viable? Not under tension, lying well?

Potential sites **for internal herniation** dealt with?

Small bowel comfortably arranged in place below the transverse colon?

Omentum placed between intestine and incision?

All additional **fascial defects** (e.g. trocar sites) closed?

Drains (only if indicated!) in place?

Need a **feeding jejunostomy**?

Should I close the abdomen at all? Or leave it open?

Do not compromise. Keep looking around; there’s always something you’ve missed. **Remember: when the abdomen is open you control it, when closed it controls you!**

There are old pilots, and there are bold pilots, but there are no old, bold, pilots!
There are however old, bold surgeons – but their patients do not live long...

MOSHE SCHEIN

We repeat: “As long as the abdomen is open you control it. Once closed it controls you.”

The long operation is finished, leaving you to savor the sweet postoperative “high” and elation. But soon, when your serum level of endorphins declines, you start worrying about the outcome. And worry you must, for the cocksure, macho attitude is a recipe for disasters. We do not intend to bring here a detailed discussion of postoperative care or to write a new surgical intensive care manual. We only wish to share with you some basic precepts, which may be forgotten, drowned in a sea of fancy technology and gimmicks. The following are a few practical “commandments” for postoperative care.

1. Know Your Patient

This is no joke! How often do we encounter a postoperative patient looked after by someone who has no clue about the patient’s pre- and intra-operative details? Mistakes in management are more commonly done by those who “temporarily adopt” the case. Once you operate on a patient he or she is yours! **Shared responsibility means that no one is responsible!**

2. Touch-Examine Your Patient

Not only from the foot of the bed. Examining the chart or the ICU monitor is not enough. Look at the patient, smell and palpate him at least once a day. Wouldn’t it be embarrassing to load your patient with intravenous antibiotics or CT scan his abdomen, while an unsuspected abscess is cooking under the wound dressing, begging to be simply drained at the bedside?

3. Treat the Pain

You know the different drugs, and their modes of administration. Sure, you always prescribe postoperative analgesia, but ordering is not nearly enough. Most randomly questioned postoperative patients complain that they are under-treated for pain. Nurses tend to be stingy with analgesia. You are the man on the spot; see that your patient does not suffer unnecessarily.

4. Do not “crucify” your patient in the horizontal position

Typically the “modern” patient is “crucified” horizontally, tethered by the **spaghetti** of monitoring cables, nasogastric tubes, venous lines, drains, leg pumps and urinary catheters. Free the patient from these paraphernalia as soon as possible; the nurses won’t do it without your order. The earlier your patient is out of bed, sitting or walking about, the faster he will be going home. Conversely, keeping the patient in the supine position increases the incidence of atelectasis/pneumonia, deep vein thrombosis, decubitus ulcers, and prolongs paralytic ileus, all adding fuel to the inflammatory fire of SIRS (systemic inflammatory response syndrome).

5. Decrease the Plastic and Rubber Load

Monitoring functions as an early warning system to detect physiological disturbances so that prompt corrective therapy could be instituted. The invasiveness of monitoring employed in the individual patient should be proportionate to the severity of disease: *“The sicker the patient, the greater number of monitoring tubes used, the less likely is survival”*.

Complete discussion of the continuously growing number of monitoring methods available today is beyond the scope of this chapter. However, please note:

- In order to be able to respond to monitoring-generated warning signs you must fully understand the technology being employed. You should be able to distinguish between real acute physiological changes and electrical or mechanical artifacts of observation.
- Understand that all methods of monitoring are liable to a myriad of potential errors, specific to the technique or caused by patient-related variables. Alertness and sound clinical judgment are paramount!
- Because of improving technology, monitoring is becoming more and more sophisticated (and expensive). Furthermore, monitoring techniques are responsible for a significant number of iatrogenic complications in the surgical intensive care unit. Use monitoring discriminately and do not succumb to the *Everest syndrome*:

“I climb it because it is there”. Before embarking on invasive monitoring ask yourself *“Does this patient really need it?”* Remember there are safer and cheaper alternatives to invasive monitoring: for example, in a stable patient, remove the arterial line, as the blood pressure can be measured with a conventional sphygmomanometer, PO₂ determined transcutaneously, and blood tests drawn by phlebotomy. Each time you see your patient ask yourself which of the following can be removed: nasogastric tube, Swan-Ganz catheter, central venous line, arterial line, peripheral venous line, Foley’s catheter?

Nasogastric (NG) Tubes ▶ Prolonged postoperative NG decompression to combat gastric and intestinal ileus is a common baseless ritual. The concept that the NG tube “protects” distally-placed bowel anastomosis is ridiculous as liters of juices are secreted each day below the decompressed stomach. Nasogastric tubes are extremely irritating to the patient, interfere with breathing, cause esophageal erosions and promote gastroesophageal reflux. Traditionally, surgeons keep the tube until the daily output drops below a certain volume (e.g., 400 ml); such a policy often results in unnecessary torture. It has been repeatedly demonstrated that most post-laparotomy patients do not need nasogastric decompression – not even following upper gastrointestinal procedures – or need it for a day or two at most. In fully conscious patients, who are able to protect their airway from aspiration, NG tubes can be safely omitted in most patients. Following an emergency abdominal operation, nasogastric decompression is compulsory though, in mechanically ventilated patients, in obtunded patients, and after operations for intestinal obstruction. In all other cases, consider removing the NG tube on the morning after surgery.

Drains ▶ Despite the widely publicized dictum that it is impossible to effectively drain the free peritoneal cavity, drains are still commonly used and misused (◉ Chap. 12). In addition to the false sense of security and reassurance they provide, drains can erode into intestine or blood vessels and promote infective complications. We suggest that you limit the use of drains to the evacuation of an established abscess, to allow escape of potential visceral secretions (e.g. biliary, pancreatic) and to establish a controlled intestinal fistula when the bowel cannot be exteriorized. Passive, open-system drainage offers a bi-directional route for microorganisms and should be avoided. Use only active, closed-system drainage systems, placed away from the viscera. Leaving a drain close to an anastomosis in the belief that a possible leak will result in a fistula rather than in peritonitis is a long-enduring dogma; drains have been shown to contribute to the dehiscence of a suture line. A policy like “I always drain my colonic anastomoses for 7 days” belongs to the dark ages of surgical practice. Remove drains as soon as they have fulfilled their purpose.

6. Obtain Postoperative Tests Selectively

Unnecessary diagnostic procedures or *interpretative* errors in *indicated* diagnostic procedures commonly result in *false-positive* findings, leading, in turn, to an increasingly invasive escalation of diagnostic or therapeutic measures. Added morbidity is the invariable price. If the results of a test are not going to affect your management, don't order the test!

7. Realize that the Problem Usually Lies at the Operative Site

The cause of fever or “septic state” in the surgical patient is usually at the **primary site of operation unless proven otherwise**. Do not become a “surgical ostrich” by treating your patient for “pneumonia” while he is slowly sinking in multiple organ failure from an intra-abdominal abscess (◀ Fig. 40.1).

Postoperative “problems”
usually develop at the site
of the operation...

Do not behave as a
“surgical ostrich”...



Fig. 40.1

8. Temperature is Not a Disease; Do Not Treat it as Such

Postoperative fever represents the patient's inflammatory response (SIRS) to different insults including infection as well as surgical trauma, atelectasis, transfusion and others. SIRS does not always mean sepsis (sepsis = SIRS + infection). Therefore, fever should not be treated automatically with antibiotics. It also should not be stifled with antipyretics as the febrile response may be beneficial to the host's defenses. The absolute level of temperature is of less importance than its trend and it's difficult to assess this important sign when you are artificially suppressing it.

“Fever is, in a measure, a beneficial process operating to protect the economy.”
(Augustus Charles Bernays, 1854–1907)

9. Avoid Poisoning Your Patient with Antibiotics: Tailor Antibiotic Administration to the Patient

Avoid the common practice of administering antibiotics for as long as the patient is in the hospital and beyond (🕒 Chap. 42).

10. Be Frugal with Blood-Product Transfusions

Generally, the amount of blood or derived products transfused inversely and independently correlates with the outcome of the acute surgical disease. Donated blood is immunosuppressive and is associated with an increased risk of infection, sepsis and organ failure, not to mention the other well-known hazards. Cancer patients in particular fare worse in the long term if they receive a transfusion. Transfuse your patient only if absolutely necessary. A patient requiring only 1 unit of blood does not require any at all. For the vast majority of patients, a hematocrit of 30% is more than satisfactory.

11. Do Not Drown Your Patient in Salty Water

The current, exaggerated “protocols” of postoperative fluid management provide too much water and salt, resulting in obligatory weight gain and swelling of tissues. And edematous tissues do not function well and do not heal well – causing a higher rate of medical and surgical complications. (See *Editorial Comment* in 🕒 Chap. 6). All your patient needs is enough water to replace insensible losses (500–1000 ml) and provide for urinary flow of 0.5 ml/kg per hour. Additional losses

(e.g. NG tube) should be replaced selectively on an ad hoc basis but writing an order for 150 ml/hour of saline and going to sleep will result in a swollen patient. You have to read the article by Brandstrup et al. (2003)¹ to see how postoperative fluid restriction may help your patient. And get rid of the intravenous line as soon as possible!

“Fluids given intravenously bypass all the defenses set up by the body to protect itself against excess of any constituent, against bacterial entry...they give the patient what the surgeon thinks his tissues need and what they are damned well going to get.” (William Heneage Ogilvie, 1887–1971)

12. Do Not Starve or Over-Feed Your Patient; Use the Enteral Route Whenever Possible (🔗 Chap. 41)

Please do not torture your patient with the useless and baseless ritual of slowly increasing the permitted consumption of oral fluids from 30 mls hourly to 60 then 90 and so on over several days.

13. Recognize and Treat Postoperative Intra-abdominal Hypertension (🔗 Chap. 36)

14. Prevent Deep Vein Thrombosis (DVT) and Pulmonary Embolism

It is easy to forget DVT prophylaxis in the pre-operative chaos of emergency surgery. As a pilot goes over a checklist prior to any flight – you should be the one to inject the subcutaneous heparin and/or to place the anti-DVT pneumatic device – **before** the operation. DVT prophylaxis should be continued postoperatively as long as the patient continues to be at high risk of thrombosis.

15. Be the Leader and Take Responsibility

Many people tend to dance around your postoperative patient, giving consults and advice. But remember, this is not their patient; he or she is yours. At the Mortality

¹ Brandstrup B, Tonnesen H, Beier-Holgersen R et al. (2003) Effects of intravenous fluid restriction on postoperative complications: comparison of two perioperative fluid regimens: a randomized assessor-blinded multicenter trial. *Ann Surg* 238:641–648.



Fig. 40.2. “Who is missing, guys? Where is the podiatrist?”

and Morbidity Meeting (or in court), the others will say “I just gave a consult” (◉ Chap. 52). The ultimate responsibility for all aspects of your patient’s management falls squarely in your hands. Know when you need help and request it, preferably from one of your mentors. As Francis D. Moore said: “**Seek consultation even if it is not sure to help; never be a lone wolf**”. But solicit advice judiciously and apply it selectively. Relinquishing blindly the care of your postoperative patient to anesthesiologists, medical intensivists, or other modern “experts” may be a recipe for disaster. It is much better in this modern surgical age to form close working relationships with colleagues who share your philosophy of care and who have expertise in areas beyond your own. We all need help with patients suffering multi-system failure; while we can take care of the abdominal problem we do need assistance and advice to manage cardiac, respiratory and renal failure appropriately. As Mark M. Ravitch said: “**The problem with calling in a consultant is that you may feel obliged to take his advice**” (◉ Fig. 40.2).

— Above all – avoid “consultorrhea,” which may adversely affect survival.

JAMES C. RUCINSKI

“In every disease it is a good sign when the patient’s intellect is sound, and he is disposed to take whatever food is offered to him; but the contrary is bad.”
(Hippocrates, 460?–377? BC)

God created man with a mouth, a stomach and gut – not a TPN line.

The relatively brief interval available to you to prepare an emergency abdominal patient for an operation does not allow for nutritional considerations. This issue, therefore, is addressed only during and after the operation. Towards the end of the laparotomy you should ponder whether there is a need to provide *enteral access* to facilitate postoperative feeding. After the operation the issues to think about are how early, and by which route, the patient should be fed.

Starvation

Starvation results in a state of adaptation. After hepatic glycogen stores are consumed in 24–48 hours, the liver synthesizes glucose, using amino acids derived from protein breakdown. This “auto-cannibalization” of functional protein stores is ameliorated, to some degree, by conversion to ketone metabolism of the two major “obligate” glucose users, the central nervous system and the kidney. Fat stores help by providing ketones and, through glycerol metabolism, adding a small amount of glucose. Injury, illness or operation, though, greatly increases the demand for glucose to answer the hyper-metabolic demands made by SIRS (systemic inflammatory response syndrome) and to provide energy for wound repair and for the bone marrow and its offspring, the leukocytes. The end result, then, is the breakdown of protein leading to general debility, impaired reparative processes, attenuated immune function and respiratory muscle weakness that in turn may cause atelectasis, pneumonia, ventilator-dependence and death.

The need for nutritional support then, is based on:

- Your physical and laboratory assessment of the patient’s *nutritional reserves*
- An estimate of the *associated stress of the underlying illness*
- An estimate of the *time interval* that will pass before the patient can resume a normal diet

Assessment of Need for Nutritional Support

You must ask the patients how long they have felt sick and how much weight they lost, if any, in the weeks prior to the operation. You must also ask when they last ate. By looking at the person you can estimate what their ideal weight might be and make a “guesstimate” regarding the percentage that has been lost. (Your rule of thumb standard is the fabled “70-kg man.”) *A loss of more than 10% is associated with a higher rate of complications and death after abdominal surgery.* This will give you the first two pieces of information necessary for decision-making:

- Percentage weight loss and available reserves
- Time since normal feeding was stopped

Serum albumin level reflects the balance of synthesis and degradation of one of the products of hepatic metabolism. In the emergency setting, the albumin level will be the only laboratory parameter available to you to estimate *available reserves*. *A level of <3 mg/dl is associated with a higher rate of complications and death in abdominal surgery.*

The associated stress of illness may be roughly estimated as minimal, moderate or maximal. It is better, though, to characterize stress by the use of a physiologic scoring system that measures the severity of the acute illness – such as the APACHE II system (● Chap. 6). *An increased level of stress is associated with a higher rate of protein breakdown, as well as complications and death, in abdominal surgery.*

The third piece of information necessary for decision-making is *the time interval that will pass before the patient can resume a normal diet*. This estimate is based on the nature of the primary illness and the type of operation that is required or has been performed. For example, a person with “simple” acute appendicitis will experience cessation of normal feeding for a period of 24–72 hours, whereas a person with perforated diverticulitis with generalized peritonitis may experience cessation of feeding for a period as long as 10–14 days.

With the above information, then, you can decide which patients will be most likely to benefit from nutritional support.

- At one end of the spectrum, the patient with *normal reserves* by history and examination, with *minimal to moderate associated stress*, and with *less than 7–10 days estimated before resumption of a normal diet*, is *unlikely* to benefit from nutritional support.
- At the other end of the spectrum, the patient with *depleted available reserves*, *moderate to severe stress*, and with *more than 7–10 days estimated before resumption of a normal diet*, is *likely* to benefit from nutritional support.

Enteral versus Parenteral Nutrition

Nutritional support may be provided by *enteral* (through the alimentary tract) or *parenteral* (intravenous) routes. The advantage of enteral nutrition is that it is easier to manage, less expensive, associated with fewer complications and, very likely, associated with improved immune function and decreased intestinal bacterial translocation. The advantage of parenteral nutrition is that it can be used when and if the gastrointestinal tract is not functional. **This is no longer controversial; when the gut functions, use it! Clearly, enteral feeding is safer, cheaper, and more physiologic than parenteral nutrition!**

Enteral Nutrition

Tasty food given by mouth is the ideal. Oral feeding requires the co-operation of the patient, a normal swallowing mechanism and normal gastric motility. Unconscious and intubated patients, however, cannot swallow but the main problem is that following abdominal operations the stomach is lazier than the intestine. In other words, after laparotomy the small bowel recovers motility before the stomach. The gut is ready to absorb nutrients in the first postoperative day whereas the stomach may have delayed emptying for a few days (● Chap. 43). It is clear then, that when early postoperative feeding is deemed necessary, or when oral intake is inadequate, the food should be installed distally – beyond the esophagus and the stomach.

Routes

In general when the mouth is not available the following feeding routes are options:

- *Nasogastric and nasoenteric.* The former is of course not usable when the stomach is not functioning. The latter delivers the nutrients directly into the duodenum and jejunum. *Transnasal intubation* in conscious patients is only tolerated with narrow-bore and soft tubes. Rare complications are nasal trauma, sinus infection and even (very rarely) misplacement into the bronchial tree with inadvertent instillation of the feeding solution into the lungs.
- *Gastrostomy and transgastric jejunal tube.* The feeding tube is operatively placed directly into the stomach, and/or through the pylorus into the jejunum. This is a surgical procedure, which violates the gastric wall. The chief complication is leakage at the insertion site: around the tube – which is not uncommon – or into the peritoneal cavity – which is rare but potentially fatal.

- *Jejunostomy tube.* The feeding tube (or a catheter) is inserted directly into the proximal jejunum as discussed below.

Clearly, feeding directly into the jejunum, as opposed to gastric feeding, is associated with less risk of aspiration.

Should I Place a Jejunal Feeding Tube?

This is the question you should ask yourself at the end of the emergency laparotomy. It is much more convenient to do it at this stage as opposed to doing it postoperatively. You should consider the three questions mentioned above: What is the likelihood that this patient will be eating in 7–10 days? Are they malnourished or not? What is the magnitude of this illness?

A malnourished alcoholic patient who requires a total gastrectomy with esophagojejunal anastomosis for massive upper gastrointestinal bleeding represents a classical indication for a jejunal (J) feeding tube. A case of multi-trauma involving the thorax, pelvis and long bones, who undergoes a laparotomy for hepatic injury, could also benefit from immediate J-tube feedings. After a partial gastrectomy in a previously well-nourished patient, J-tube placement is not indicated as the potential risks override the assumed benefits. Hey, you don't want to place a J-tube in a patient who won't need it.

There are three methods to place the J-tube during the operation:

- *Transnasally* – into the stomach from which you can manipulate it by palpation into the proximal jejunum. The advantage is that it does not require a gastrotomy or enterotomy; disadvantages are its nasal presence and risk of accidental dislodgment.
- *Transgastric* – combined gastrostomy/jejunostomy tubes are available to allow gastric aspiration and jejunal feeding at the same time. Obviously gastrostomy has its own complications – mainly leakage around the tube, leakage into the peritoneal cavity and abdominal wall cellulitis. A meticulous fixation of the stomach onto the abdominal wall is mandatory.
- *Jejunostomy* – a 16 or larger French tube may be placed through a purse-string-controlled enterotomy and then suture-tunneled with serosa over the site of entry extending 5–7 cm proximal (“Witzel technique”). Alternatively, a 12 or 14 gauge catheter may be “tunneled” into the jejunal lumen through a needle (“needle catheter technique”). Both techniques require suture fixation of the bowel to the site of catheter entry in the abdominal wall in order to prevent intra-abdominal leakage of small bowel contents and feedings if the tube is accidentally removed before an enterocutaneous tract is developed (in 7 to 10 days). Additional useful tricks are: fix the efferent and afferent portions of the loop to the abdominal wall to prevent

kinking and obstruction at the site of the jejunostomy. The needle and catheter should pierce the abdominal wall obliquely – in a direct line with the bowel-wall “tunnel”; this will prevent kinking – followed by breaking – of the fine tube at the bowel–skin junction.

Continuous J-feeding may be instituted immediately following operation in most cases. Diarrhea is a common problem requiring adjustment of the volume and concentration of the specific solution you prefer to use. Be aware that nasojejunal tubes can be inserted across suture lines and that feeding can be installed proximal to suture lines. Note also that cases of *massive intestinal infarction were reported in critically ill patients* receiving early postoperative jejunal feeding, possibly due to increased metabolic demands on an already poorly perfused gut. Therefore, hold J-feedings in unstable patients and those on vasopressors. Small bowel ileus can prevent adequate J-feeding; always consider that behind the non-resolving or re-appearing ileus there may be a treatable cause (▶ Chap. 43).

You may have been approached by the manufactures of the new “immuno-enhancing diets”. Those are tube feeding formulas that contain high concentrations of certain nutrients and are claimed to “increase immunity”, thus reducing the post-operative infection rate. The value of such expensive diets is questionable, as is the value of enteral supplementation with the amino acid glutamine.

Postoperative Placement of Transnasal J-Tube

You can place a transnasal J-tube also *after* the operation – if indicated. This however is not easy and requires prolonged manipulation under fluoroscopy. An alternative is to use a gastroscope, with a long tube (e.g., nasobiliary) placed into the distal duodenum through the biopsy channel of the scope and under vision. Clearly, intra-operative placement is much easier. Please do not forget this option before closing the abdomen.

Parenteral Nutrition

Patients who cannot eat and won't tolerate enteral feeding may need parenteral nutritional support, which comes in three “flavors”:

- *Protein sparing hydration* takes advantage of the fact that 100 g of glucose a day suppresses hepatic gluconeogenesis by supplying much of the obligate daily glucose need. Two liters of dextrose 5% provide this amount of sugar. For the average “not so stressed” patient this is more than enough for the first 7 postoperative days.

- *Peripheral parenteral nutrition* (PPN) contains amino acids in addition to a low concentration of glucose and may provide an additional protein-sparing effect when “stress” is added to starvation. It is useful in maintenance nutrition for an intermediate period of postoperative starvation, 7–14 days, or as long as the patient’s peripheral veins last. This is so because PPN is a “vein destroyer”, which often requires frequent change of the venous access. (The Editors asked me not to cite references but I can’t resist and wish to recommend an excellent recent review on this subject by A.D. Anderson and colleagues: Anderson AD, Palmer D, MacFie J (2003) Peripheral parenteral nutrition. Br J Surg 90:1048–1054).
- *Total parenteral nutrition* (TPN) contains amino acids and a concentrated dextrose solution, into which a lipid solution is usually added, which can provide for an indefinite duration the total amount of nutritional requirements even in the face of maximal stress. As usual, bypassing physiology has a price – TPN is associated with a long list of mechanical, catheter-related, infectious and metabolic complications and is rather expensive.

Measurement of Effectiveness of Nutritional Support

In the long term this can be calculated by observing the balance of protein synthesis and degradation reflected in serum protein levels such as albumin (half-life 17 days) or transferrin (half-life 8 days). In the short term, particularly in the critically ill, nitrogen balance can be assessed by comparing the amount of nitrogen that is produced in the urine (24-hour urine specimen analyzed in the laboratory) with the amount of nitrogen that is given by nutritional support (written on the package).

So What Should You Do?

- First decide if nutritional support will be helpful by estimating *nutritional reserve, degree of stress and time interval to normal diet*.
- Hold off starting nutritional supplements until peri-operative intravenous fluid resuscitation has attenuated the effect of third-space fluid sequestration and the initial hypermetabolic, hyperglycemic physiologic picture has abated somewhat (usually within 24 hours).
- Calculate the nutritional requirement by formula (there is no shame in looking this up) or indirect calorimetry.
- Institute nutritional support.
- Measure the effectiveness of treatment by analysis of urinary nitrogen loss compared with the amount of nitrogen provided by the treatment.

“Routine” Oral Feeding

Fortunately, most of your emergency abdominal patients recover from the ileus, induced by the underlying disease and its surgical treatment, within a few days. Traditionally, resumption of oral intake was completed in stages. First there was the nasogastric tube, which was kept in situ for variable periods (◉ Chap. 40); then the tube was removed (according to the rules established by the local dogmatic guru). After the patient professed the blessed sounds of flatus he was started on “sips”, thereafter, gradually, being advanced from “clear fluids” to “full fluids” to “soft diet”, until the great day when “regular diet” was allowed, usually indicating that discharge home was imminent. Is such a ritual or its variant still practiced in your environment? If yes, you should know that its value is based on no evidence at all. In fact, there is scientific evidence to prove that starting the patient on solid feeds is as “safe” and tolerable as the staged method still practiced by many.

On the other side of the coin, there are surgeons who maintain that a patient who devours a beefsteak a day after a colectomy is a testimony to their superb surgical skills. This attitude is probably wrong as well – what’s the point of force-feeding a patient who does not have an appetite? The physiological postoperative ileus is a response that must have some purpose; appetite and desire to eat return when intestinal motility recovers. Our approach is therefore to let the patient decide when to eat, what to eat and how much; they’ll tell you when their stomach is ready for a steak or the cornmeal. (◉ Fig. 41.1)



Fig. 41.1. Postoperative day 1: “Let him eat as much as he wants...”

Concluding Remarks

Before we finish let us share a few truths with you:

- We know that *prolonged* starvation may be harmful, but there is no proof that early re-feeding after surgery is beneficial.
- We know that when compared to postoperative TPN, enteral nutrition is associated with better results. However, in the absence of a non-fed control group in any of the studies, it is not clear whether enteral nutrition provides specific benefit or that TPN is associated with an increased rate of complications.
- There is some evidence that early postoperative enteral nutrition may adversely affect respiratory function

Abdominal catastrophes and their operative treatment are often complicated by compromised nutritional reserve, stress and a long interval before a normal diet is resumed. The result of these factors is the production of immunoparesis by “auto-cannibalization” of functional protein with associated morbidity and mortality. Nutritional support in selected patients may help to attenuate these effects. Driven by manufacturers, nutrition hospital services or “TPN teams”, the current trend is towards unnecessary overfeeding of the surgical patient – provoking additional morbidity and costs. Artificial feeding is a double-edged sword. Thus, be selective and cautious.

“Some people never seem able to allow their patients to use the channels designed by nature to receive nourishment... food and fluids given by the alimentary canal allow the tissues to select and keep what they want, and to reject what is harmful or surplus to requirements.” (William Heneage Ogilvie, 1887–1971)

“In most conditions, foods that agree with the patients may be eaten, those which do not, should not be eaten.” (Mark M. Ravitch, 1910–1989)

MOSHE SCHEIN

No amount of postoperative antibiotics can compensate for intra-operative mishaps and faulty technique, or can abort postoperative suppuration necessitating drainage.

The Issue

Perhaps an issue as apparently banal as postoperative antibiotics does not deserve a separate chapter. Already in ◉ Chap. 7 you read about pre-operative antibiotics, and in ◉ Chap. 12 you were introduced to the concepts of contamination and infection and their therapeutic implications. Why not just administer postoperative antibiotics routinely for any emergency abdominal operation until the “patient is well”? In fact, this is a common practice in the surgical community in this country and around the world – patients receive postoperative antibiotics for many days, many of them are even discharged home on oral agents “just in case”. What is wrong with this approach? Our aim is to convince you that indiscriminate postoperative antimicrobial administration is **wrong** and to provide guidelines in order to approach this issue in a more rational way.

For a long time the topic of **duration** of administration has been easily dismissed by the “official” literature, with the common laconic recommendation that antibiotics should be continued until all signs of infection, including fever, leukocytosis, and even ileus subside, and the patient is “clinically well”. No evidence existed, however, to prove that indeed the continuation of antibiotics along these lines could abort an infection-in-evolution, or cure an existing one (◉ Fig. 42.1).

During the last decade, we learned that fever and white cell response are part of the patient’s inflammatory response to a variety of infective and non-infective causes. We realized that sterile inflammation is common after any operation, manifesting itself as a local inflammatory response syndrome (LIRS), or a systemic one (SIRS) (◉ Chap. 48). Is there a need to administer antibiotics after the bacteria are already dead?

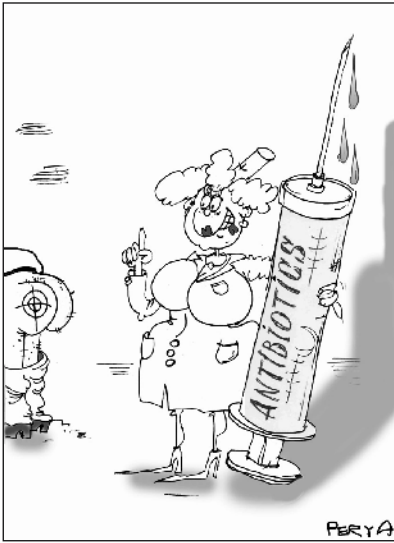

Fig. 42.1. “This will cure your fever...”

The evolving policy of **minimal antibiotic administration** (strongly supported by the Surgical Infection Society – see Mazuski et al. 2002)¹ represents a trend away from the use of postoperative therapeutic courses of “fixed” and often long duration; **rather, you should attempt to stratify the infective processes into grades of risks, and to tailor the duration of administration to the severity of infection.**

Duration of Postoperative Administration

We recommend the policy summarized in Table 42.1. It is based on the following arguments:

- Conditions representing **contamination** do not require postoperative administration since the infectious source has been dealt with at operation; bacteria and adjuvants of infection are effectively removed by the host’s defenses, supplemented by peritoneal toilet, and adequate tissue levels of pre- and intra-operative prophylactic antibiotics. **By definition, prophylaxis should not be continued beyond the immediate operative phase.**
- In processes limited to an organ amenable to excision (“**resectable infection**”), the residual bacterial inoculum is low. A postoperative antimicrobial course of

¹ Mazuski JE, Sawyer RG, Nathens AB et al. (2002) The Surgical Infection Society Guidelines on antimicrobial therapy for intra-abdominal infections. *Surg Infect* 3:161–173.

Table 42.1. Duration of postoperative antibiotic therapy**Contamination: no postoperative antibiotics**

Gastroduodenal peptic perforations operated within 12 hours
 Traumatic enteric perforations operated with 12 hours
 Peritoneal contamination with bowel contents during elective or emergency procedures
 Appendectomy for early or phlegmonous appendicitis
 Cholecystectomy for early or phlegmonous cholecystitis

Resectable Infection: 24-hour postoperative antibiotic course

Appendectomy for gangrenous appendicitis
 Cholecystectomy for gangrenous cholecystitis
 Bowel resection for ischemic or strangulated necrotic bowel without frank perforation

“Mild” Infection: 48-hour postoperative antibiotic course

Intra-abdominal infection from diverse sources with localized pus formation
 “Late” (more than 12 hours) traumatic bowel lacerations and gastroduodenal perforation with no established intra-abdominal infection

“Moderate” Infection: up to 5 days of postoperative antibiotics

Diffuse, established intra-abdominal infection from any source

“Severe” Infection: more than 5 days of postoperative antibiotics

Severe intra-abdominal infection with a source not easily controllable (e.g. infected pancreatic necrosis)
 Postoperative intra-abdominal infection

24 hours should suffice to sterilize the surrounding inflammatory reaction and deal with gut bacteria, which may have escaped across the necrotic bowel wall by translocation.

— “Non-resectable infections” with a significant spread beyond the confines of the involved organ should be stratified according to their severity. A therapeutic postoperative course of more than 5 days is usually not necessary. However, certain complex situations may need **extended** courses of postoperative antibiotics. A typical example is infected pancreatic necrosis where the nidus of infection is not readily eradicated in a once-and-for-all surgical procedure. Similarly, patients with postoperative peritonitis, where the control of the source of infection is questionable, should be considered for prolonged antibiotic therapy.

It should be quite clear that the commonplace, blind, extended antibiotic administration, for as long as fever or leukocytosis are present, should be abandoned. Pyrexia and white cell response represent usually a sterile, peritoneal (LIRS)

or systemic (SIRS), cytokine-mediated, inflammatory response; admittedly, less commonly, they may indicate the presence of a focus of persistent or recurrent infection. The former situation is self-limiting and resolves without antibiotics. The latter usually represents suppurative infection, which should be treated by drainage of the intra-abdominal abscess (◉ Chap. 43) or the infected wound (◉ Chap. 48). Antibiotic treatment can neither prevent nor treat suppurative infection; it may only succeed in masking it.

By now you should understand that the persistence of inflammation beyond the appropriate therapeutic course is not an indication to continue, re-start or change antibiotics. What should be avoided is complacent reliance on the advice of the average infectious disease (ID) specialist; this can only lead to an expensive and often unnecessary diagnostic work-up and, even more alarmingly, to the prescribing of the latest antibiotic agent on the market (e.g., dinnericillin, lunchicillin). What should instead be done is, first, to stop the antibiotics. The fever will subside spontaneously in most patients, within a day or two, with little more than chest physiotherapy. At the same time, a directed search is undertaken for a treatable source of intra- or extra-peritoneal infection. Surgeons are best placed to anticipate complications in their patients, and this is what is meant by a directed search: a search that is conducted with the full knowledge of the patient's initial disease process, the operative findings and the natural history of the surgical disease; in brief, a corpus of information that usually eludes the ID specialist.

We have nothing personal against the so-called medical ID specialists – who, at least on this side of the Atlantic, are considered the gurus on antibiotic therapy. But we have reasons to believe that many of them do not understand the concept of “surgical” infection and how it differs from “medical” infections (see ◉ Table 42.2).

Table 42.2. Differences between “medical” and “surgical” infections

Medical infection (e.g. pneumonia)	Surgical infection (e.g. appendicitis)
Not amenable to surgical source control	Amenable to surgical source control
Antibiotics mainstay of treatment	Antibiotics only adjunct to source control
A host of potential causative organisms	Predictable causative organisms
Prolonged formal course of antibiotics	Antibiotics tailored to operative findings

So when was the last time the ID “expert” asked you about your operative findings? And by the way, in a questionnaire study we asked ID specialists whether they would recommend obtaining peritoneal cultures during operation for a “fresh” penetrating wound of the colon; 100% said yes – as if we do not already know the bacterial composition of s***!

We hope that you realize that unnecessary antibiotics are wrong because anything unnecessary in medicine is bad medicine. In addition, the price to be paid is high, not only financially. Antibiotics are associated with patient-specific adverse effects (the list is long, think of the gravity of *C. difficile* colitis) and ecological repercussions such as drug-resistant nosocomial infections in your hospital.

Are you convinced?

Start antibiotics prior to any emergency laparotomy; whether to continue administration after the operation depends on your findings. Know the target flora and use the cheapest and simplest regimen. The bacteria cannot be confused, nor should you be.

Postoperative Ileus vs Intestinal Obstruction

MOSHE SCHEIN · SAI SAJJA

The postoperative fart is the best music to the surgeon's ears . . .

Five days ago you removed this patient's perforated appendix (● Chap. 28); you gave him antibiotics for 2–3 days (● Chap. 42), and by today you expected him to eat (● Chap. 41) and go home. Instead, your patient lies in bed with a long face and a distended abdomen, vomiting bile from time to time. And the family is asking you what you are asking yourself – what is the problem?

Definitions and Mechanisms

The term **ileus** as used in this book, and in daily practice, signifies a “paralytic ileus” – the opposite of mechanical ileus, which is a synonym for intestinal obstruction. In essence, the latter consists of a mechanical stoppage to the normal transit along the intestine whereas the former denotes hindered transit because the intestines are “lazy”.

In previous chapters you noted that ileus of the small bowel, colon or both, can be secondary to a variety of intra-abdominal (e.g. acute appendicitis), retroperitoneal (e.g. hematoma) or extra-abdominal (e.g. hypokalemia) causes, which adversely affect normal intestinal motility. Following abdominal operations, however, ileus is a “normal” phenomenon – its magnitude directly proportional to the magnitude of the operation. In general, the more you do within the abdomen, the more you manipulate, the more prolonged will be the postoperative ileus.

Ileus

Unlike mechanical intestinal obstruction, which involves a segment of the (small) bowel, postoperative ileus concerns the whole length of the gut, from the stomach to the rectum. As mentioned in ● Chap. 41, physiological postoperative ileus resolves gradually. The small bowel resumes activity almost immediately, followed, a day or so later, by the stomach, and then the colon, being the laziest, is the last to start moving.

The magnitude of the postoperative ileus correlates to some extent with that of the operation performed and the specific underlying condition. Major dissections, prolonged intestinal displacement and exposure, denuded and inflamed peritoneum, residual intra- or retro-peritoneal pus or clots, are associated with a prolonged ileus. Thus, for example, after simple appendectomy for non-perforated appendicitis, ileus should be almost non-existent, whereas after a laparotomy for a ruptured abdominal aortic aneurysm (● Chap. 37) expect the ileus to be prolonged. Common postoperative factors, which can aggravate ileus, are the administration of opiates and electrolyte imbalance. While the “physiological” postoperative ileus is diffuse, ileus due to complications may be local. A classical example of a local ileus is a postoperative abscess (● Chap. 44) that may “paralyze” an adjacent segment of bowel. For example, a localized leak from an ileo-transverse anastomosis after right hemicolectomy may paralyze the adjacent duodenum, mimicking a picture of gastric outlet obstruction.

Early Postoperative Mechanical Intestinal Obstruction

You became familiar with small bowel obstruction (SBO) in ● Chap. 21. Early postoperative SBO (EPSBO) is defined as one developing immediately after the operation or within 4 weeks. Two primary mechanisms are responsible: **adhesions** and **internal hernia**.

Early post-laparotomy **adhesions** are immature, inflammatory, poor in collagen – thus “soft” – and vascular. Such characteristics indicate that early adhesions may resolve spontaneously and that surgical lysis may be difficult, traumatic to involved viscera and bloody. Postoperative adhesions may be diffuse, involving the whole length of the small bowel in multiple sites, as is occasionally seen following extensive lysis of adhesions for SBO (● Chap. 21). Localized obstructing adhesions may also develop at the operative site with the bowel adherent, for instance, to exposed Marlex mesh or raw peritoneal surface. The operation also may create new potential spaces into which the bowel can herniate to be obstructed – forming **internal hernias**. Typical examples are the partially closed pelvic peritoneum after abdomino-perineal resection, or the space behind an emerging colostomy. The narrower the opening into the space, the more likely the bowel is to be trapped.

Diagnosis

Failure of your patient to eat, fart or evacuate his bowel within 5 days after a laparotomy signifies a persistent ileus. The abdomen is usually distended and silent to auscultation. Plain abdominal X-ray typically discloses significant gaseous

distension of both the small bowel and the colon (🔗 Chaps. 4 and 5). The diagnosis of EPSBO in the recently operated abdomen is much subtler. Textbooks teach you that on abdominal auscultation ileus is silent and SBO noisy – this may be theoretically true but almost impossible to assess in the recently operated upon belly. *If your patient has already passed flatus or defecated and then ceases to manifest these comforting features, SBO is the most likely diagnosis.* **The truth is that in most instances the patient will improve spontaneously without you ever knowing whether it was an EPSBO or “just” an ileus.**

The natural tendency of the operating surgeon is to attribute the “failure to progress” to an ileus rather than SBO and to procrastinate. Procrastination is not a good idea, however. A distended and non-eating patient is prone to the iatrogenic hazards of nasogastric tubes, intravenous lines, parenteral nutrition, and bed rest (🔗 Chap. 40). Be active and proceed with diagnostic steps in parallel to therapy.

Management

A management algorithm is presented in 🔗 Fig. 43.1. Pass an NG tube – if not already in situ – to decompress the stomach, prevent aerophagia, relieve nausea and vomiting, and measure gastric residue. Carefully search for and correct, if present, potential causes of prolonged ileus:

- Opiates are the most common promoters of ileus; pain should be controlled but not excessively and for too long.
- Measure and correct electrolyte imbalances.
- Consider and exclude the possibility that an intra-abdominal complication is the cause of the ileus or EPSBO. A hematoma, an abscess, an anastomotic leak, postoperative pancreatitis, postoperative acalculus cholecystitis – all can produce ileus or mimic EPSBO.
- Significant hypoalbuminemia leads to generalized edema, involving the bowel too. Edematous and swollen bowel does not move well; this is called *hypoalbuminemic enteropathy* and should be considered.
- Some claim that manual abdominal massage, positional changes and/or chewing gum hasten the resolution of ileus. We carry chewing gum in our pockets and distribute it generously to our postoperative patients. Even if it does not alleviate ileus it will surely promote salivary flow and oral hygiene in the fasting patient and improve his or her mood.

Practically speaking if on the fifth post-laparotomy day your patient still has features of ileus/EPSBO we recommend a plain abdominal X-ray to assess the gas pattern (🔗 Chaps. 4 and 5). If the latter suggests an ileus or EPSBO a **Gastrografin challenge** as described in 🔗 Chap. 21 may be useful in relieving both conditions.

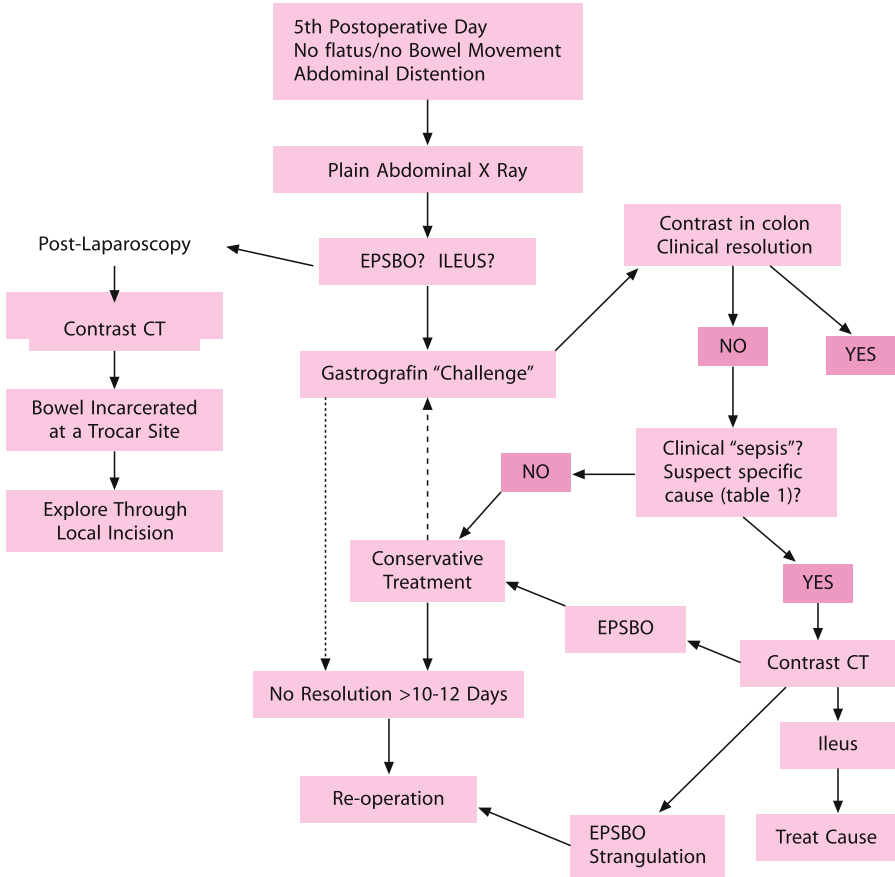


Fig. 43.1. Management algorithm

When the clinical picture suggests one of the above mentioned intra-abdominal causes of persistent ileus, an **abdominal CT** is indicated to pinpoint the problem and, at times, to guide treatment.

Failure of the Gastrografin to arrive at the colon denotes an EPSBO. In the early postoperative phase this is not an indication for a laparotomy. **Intestinal strangulation almost never occurs in this situation and spontaneous resolution is common. Resolution of SBO, however, rarely occurs beyond postoperative days 10–12.**

In the absence of intra- or extra-abdominal causes for ileus, and when the “ileus” does not respond to the Gastrografin challenge, the diagnosis is EPSBO. Do not rush to re-operate; treat conservatively while providing nutritional support (● Chap. 41). Lack of resolution beyond 10–14 days is an indication for re-laparotomy, which in itself may be difficult and hazardous because of the typical early dense and vascular adhesions cementing the bowel at many points.

Specific Considerations

The various primary operations may result in different and specific types of postoperative obstruction as summarized in ▶ Table 43.1.

Table 43.1. Early postoperative small bowel obstruction (EPSBO): special consideration

Primary operation	Question	Consideration
Laparotomy for SBO	Was the obstructing point dealt with?	If not – consider an earlier re-operation
Abdominal-perineal resection	Is the small bowel prolapsing into a pelvic space (CT)?	If yes – consider an earlier re-operation
Colostomy, ileostomy	Is the small bowel caught behind the stoma (contrast/CT)?	If yes – consider an earlier operation
Appendectomy	Is there a pelvic abscess or stump phlegmon?	If yes – consider percutaneous drainage and/or antibiotics
Laparoscopy	Is the bowel caught in a trocar site (CT)?	If yes – operate immediately
Radiation enteritis	How severe and extensive was the process? Is it “resectable”?	If no – consider prolonged non operative management
Carcinomatosis	How severe and extensive was the process? Is it “resectable”?	If no – continue prolonged palliative/symptomatic approach
“Frozen” abdomen	Was the abdomen “frozen” during index operation?	If yes – consider prolonged non-operative management
Intestinal anastomosis	Anastomotic obstruction: a bowel anastomosis at any level may cause early postoperative upper gastrointestinal, small bowel or colonic obstruction. A self-limiting “mini” anastomotic leak, associated with local phlegmon, is often responsible but under diagnosed. Diagnosis is reached with a contrast study or CT. Most such early postoperative anastomotic obstructions are “soft” and edematous – resolving spontaneously within a week or two	

EPSBO Following Laparoscopy

Cholecystectomy, trans-peritoneal hernia repair and appendectomy are the three most common procedures associated with postlaparoscopic EPSBO. The mechanism of obstruction is adhesive in half of the patients and small bowel incarceration at the port site in the other half. All port site herniations involve the usage of 10 or 12 mm trocars and the umbilical port is the commonest site. In the majority of port site herniations adequate fascial closure was achieved at the initial operation. However, adequate closure of the fascial defect does not preclude the possibility of trocar site incarceration of bowel: a strangulated Richter's hernia may develop, with the bowel caught in the preperitoneal space behind a well-repaired fascial defect. Another cause for EPSBO following laparoscopic surgery are spilled gallstones during cholecystectomy, which can lead to the development of an inflammatory mass to which the bowel adheres.

Therefore remember that when EPSBO follows laparoscopy the first question on your mind should be whether the bowel is caught partially, or fully, in one of the trocar sites. Because physical findings suggestive of this condition, such as a mass or exceptional tenderness at the trocar site, are rarely present, CT examination of the abdomen is recommended to provide an early diagnosis. CT detects the trocar site responsible for the EPSBO, allowing immediate operation to relieve the obstruction. Surgery can be carried out through the (extended) actual trocar site itself obviating the need for a formal laparotomy. **Unlike EPSBO following open procedures postlaparoscopy obstruction usually won't resolve without a re-operation. You have to understand that postlaparoscopy EPSBO is a specific entity, which calls for immediate action.**

The "Hostile" Abdomen (see also ◀ Chap. 21)

Any "mixed" series of patients with EPSBO includes a subgroup of patients in whom the index operation has disclosed a "hostile" peritoneal cavity suggesting that any further surgery to relieve the obstructive process would be hazardous and futile. To such group belong patients with extensive radiation enteritis in whom persisting obstruction can be defined as "intestinal failure" and who are best managed with long-term parenteral nutrition. Indiscriminate re-operation in such patients often leads to massive bowel resection, multiple fistulas and death, and should be avoided. Patients with evidence of peritoneal carcinomatosis at the index operation also belong to this group. In general, only one-third of patients with "malignant" bowel obstruction from peritoneal carcinomatosis will have prolonged postoperative palliation. Thus, EPSBO in such patients represents an ominous sign; abdominal re-operation should be avoided and future palliative treatment planned, based on

the individual patient's functional status and the burden of cancer. Finally, every surgeon has some personal experience with a little reported entity, the *frozen abdomen*, in which intractable SBO is caused by dense, vascular and inseparable adhesions – fixing the bowel at many points. The astute surgeon knows when to abort early from a futile dissection before multiple enterotomies – necessitating massive bowel resection – are created. He also knows not to re-operate on such patients even if persisting EPSBO develops after what appeared to be a successful adhesiolysis. Prolonged parenteral nutrition over a period of months, with complete gastrointestinal rest, may allow the adhesions to mature – with resolution of the SBO, or at least allowing a safer re-operation.

Anastomotic Obstruction

A bowel anastomosis at any level may cause early postoperative upper gastrointestinal, small bowel or colonic obstruction. Faulty technique (▶ Chap. 13) is usually the cause. A self-limiting “mini” anastomotic leak is often responsible but under-diagnosed (● Chap. 45). Diagnosis is reached with a contrast study (water soluble please!) or CT. Most such early postoperative anastomotic obstructions are “soft” and edematous, resolving spontaneously within a week or two. Do not rush to re-operate; gentle passage of an endoscope – if accessible – may confirm the diagnosis and “dilate” the lumen.

Delayed Gastric Emptying

Often the stomach fails to empty following a partial gastrectomy or a gastrojejunostomy for any indication. This is more common when a vagotomy has been performed or when a Roux-en-Y loop has been constructed. With Gastrografin study the contrast persistently sits in the stomach. The differential diagnosis is between a gastric ileus (gastroparesis) and mechanical obstruction at the gastrojejunostomy or below it. A complete discussion of the various post-gastrectomy syndromes is beyond the scope of this volume but remember this fundamental principle – **postoperative gastric paresis is self limiting** – it will always resolve spontaneously but may take as long as 6 weeks to do so. Exclude mechanical stomal obstruction with an endoscope or contrast study and then treat conservatively with nasogastric suction and nutritional support. Try to pass a feeding tube distal to the stomach (● Chap. 41). Parenteral *erythromycin* has been shown to enhance gastric motility and is always worth a trial in this situation. **Resist the devil within you – tempting you to re-operate for gastric paresis – for it will eventually resolve, while re-operation may only make things worse.**

Prevention

It is imperative to emphasize that you can, and ought to, prevent prolonged postoperative ileus or SBO by sound operative technique and attention to detail. Gentle dissection and handling of tissues, careful hemostasis to avoid hematoma formation, not using the cautery like a blowtorch, leaving as little foreign material as possible (e.g. large silk knots, spilled gallstones during laparoscopic cholecystectomy), not denuding the peritoneum unnecessarily, not creating orifices for internal hernias, carefully closing large port sites, and not catching loops of bowel during abdominal closure, are self explanatory essentials. We are not yet too impressed with the evidence supporting recently developed expensive commercial products that allegedly “prevent adhesions”.

Summary: exclude and treat causes of persistent ileus, treat EPSBO conservatively as long as indicated, think about specific causes of SBO (e.g., herniation at a laparoscopic trocar site) and re-operate when necessary. In most instances ileus/EPSBO will resolve spontaneously (◊ Fig. 43.2).

Better to leave a piece of peritoneum on the bowel than a piece of bowel on the peritoneum.

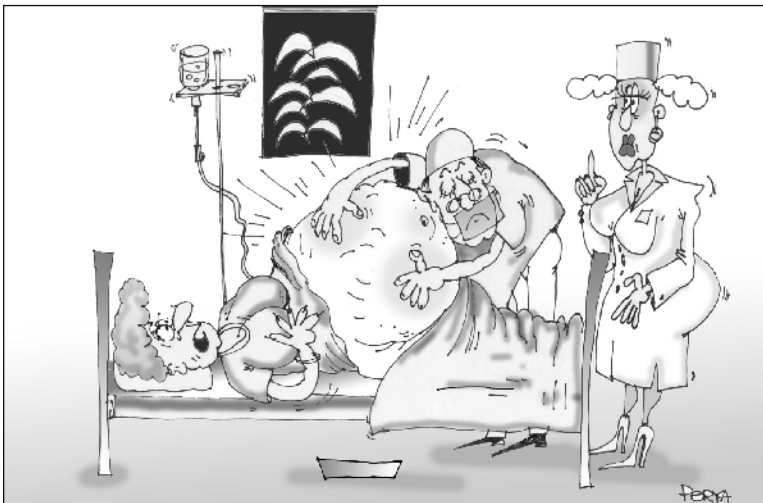


Fig. 43.2. “Doctor, is it mechanical obstruction or ileus?” ... “Sh...let me hear...”

MOSHE SCHEIN

“Signs of pus somewhere, signs of pus nowhere else, signs of pus there – under the diaphragm”. This was 100% true when I was a student, 50% true when I was a resident. Today it is irrelevant . . .

The contents of this chapter could have been summarized in a sentence: an abscess is a pus-containing, confined structure, which requires drainage by which ever means available. We believe, however, that you want us to elaborate.

Abscesses may develop anywhere within the abdomen, resulting from myriad conditions. Specific types such as diverticular or peri-appendicular abscesses (☛ Chaps. 26 and 28) are covered elsewhere in this book; this chapter will introduce you to general concepts – with emphasis on what is probably the commonest abscess in your practice – the **postoperative abscess**.

Definition and Significance

Erroneously, the term intra-abdominal abscess has been and still is used as a synonym for secondary peritonitis (☛ Chap. 12). This is not true as abscesses develop as a result of effective host defenses and represent a relatively successful outcome of peritonitis.

To be termed an abscess, the confined structure has to be walled off by an inflammatory wall and possess a viscous interior. In contrast, free flowing, contaminated or infected peritoneal fluid or loculated collections, which are deprived of a wall, represent a phase in the spectrum/continuum of peritoneal contamination/infection and not an abscess.

Classification and Pathogenesis

The myriad forms of intra-abdominal abscesses makes their classification complex (☛ Table 44.1), but practically, abscesses are **visceral** (e.g. hepatic or splenic) or **non-visceral** (e.g. subphrenic, pelvic), **intrapertitoneal** or **extraperitoneal**. **Non-visceral** abscesses arise following the resolution of diffuse peritonitis during which

Table 44.1. Classification of abdominal abscesses

Classification	Examples
Visceral vs non-visceral	Hepatic vs subphrenic
Primary vs secondary	Splenic vs appendiceal
Spontaneous vs postoperative	Diverticular vs peri-anastomotic
Intra-peritoneal vs retroperitoneal	Tubo-ovarian vs psoas
Simple vs complex	Complex: Multiple (liver) Multiloculated Communication with bowel (leaking anastomosis) Associated with necrotic tissue (pancreatic) Associated with cancer
Anatomical	Subphrenic, subhepatic, lesser sac, paracolic, pelvic, interloop, peri- nephric, psoas

loculated areas of infection and suppuration are “walled off” and persist; or arise after a perforation of a viscus, which is effectively localized by peritoneal defenses. **Visceral abscesses** are caused by hematogenous or lymphatic dissemination of bacteria to a parenchymatous viscus. **Retroperitoneal** abscesses may result from perforation of a hollow viscus into the retroperitoneum as well as by hematogenous or lymphatic spread. Another distinction is between the **postoperative abscess** – for the development of which we surgeons feel responsible – and **spontaneous abscesses**, unassociated with a previous operation. A further clinically significant separation is between **simple abscesses** and **complex abscesses**, (e.g. multiple, multiloculated ones, associated with tissue necrosis, enteric communication or tumor), which require a more aggressive therapy and carry a poorer prognosis. The **anatomical classification**, based on the specific anatomical location of an abscess – which typically develops in one of the few constant potential spaces – has diminished in significance since the advent of readily available modern imaging and percutaneous drainage techniques.

Note that abscesses signify an **intermediate** natural outcome of contamination/infection. At one end of the spectrum infection persists, spreads and kills; at the other, the process is entirely cleared by host defenses – assisted by your therapy. Abscesses lie in no-man’s land, where the peritoneal defenses are only partially effective – being disturbed by an overwhelming number of bacteria, micro-environmental hypoxemia or acidosis, and adjuvants of infection such as necrotic debris, hemoglobin, fibrin and barium sulfate. An abdominal abscess won’t kill your

patient immediately, but if neglected and undrained, it will become gradually lethal, unless spontaneous drainage occurs.

Microbiology

Generally speaking abdominal abscesses are polymicrobial. Abscesses that develop in the aftermath of secondary peritonitis (e.g., appendiceal or diverticular abscess) possess the mixed aerobic-anaerobic flora of secondary peritonitis (↻ Chaps. 7 and 12). It appears that while endotoxin-generating facultative anaerobes, such as *E. coli*, are responsible for the phase of acute peritonitis, the obligate anaerobes, such as *Bacteroides fragilis*, are responsible for late abscess formation. These bacteria act in **synergy**; both are necessary to produce an abscess, and the obligate anaerobe can increase the lethality of an otherwise non-lethal inoculum of the facultative microorganisms. The vast majority of visceral abscesses (e.g., hepatic and splenic) are polymicrobial – aerobic, anaerobic, Gram-negative and -positive. This is also true for retroperitoneal abscesses. Primary abscesses, such as the psoas one, are often monobacterial, with *Staphylococci* predominating. Post-operative abscesses are often characterized by the flora typical of tertiary peritonitis – representing superinfection with yeasts and other opportunists (↻ Chap. 48). The low virulence of these organisms, which probably represent a *marker* rather than a cause of tertiary peritonitis, reflects the global immunodepression of the affected patients.

Clinical features

The clinical presentation of abdominal abscesses is as heterogeneous and multifaceted as the abscesses themselves. The spectrum is vast; systemic repercussions of the infection vary from frank septic shock to nothing at all when suppressed by immunoparesis and antibiotics. Locally the abscess may be felt through the abdominal wall, the rectum or vagina; in most instances, however, it remains physically occult. In our modern times, when any fever is an alleged indication for antibiotics, most abscesses are initially partially treated or masked – presenting as a systemic inflammatory response syndrome (SIRS) with or without multi-organ dysfunction (↻ Chap. 48). Ileus is another not uncommon presentation of abdominal abscess; in the postoperative situation it is an “ileus that fails to resolve” (↻ Chap. 43).

Diagnosis

Life has become simple! Modern abdominal imaging has revolutionized the diagnosis of abdominal abscesses. Yes, you still need to suspect the abscess and carefully examine your patient but the definitive diagnosis (and usually the treatment) depends on imaging techniques. Computed tomography (CT), ultrasound (US) and various radioisotope-scanning techniques are available. Which is the best?

Radioisotope scanning, regardless of the isotope used, does not provide any anatomical data beyond vague localization of an inflammatory site; it is not accurate enough to permit percutaneous (PC) drainage. The usefulness of these methods is limited therefore to the continuous survival of nuclear medicine units and an excuse to publish papers (nuclear medicine = unclear medicine). Practically, these tests have no role at all. Both US and CT provide good anatomical definition including the abscess's site, size and structure; both can guide PC drainage. US is portable, cheaper, and more accurate at detecting abscesses in the right upper abdomen and pelvis. It is, however, extremely operator dependent. We surgeons are better trained to read CT scans rather than US; hence, we prefer CT, which allows us to visualize the entire abdomen, independently assess the anatomy of the abscess, and plan its optimal management. *CT, enhanced with intravenous and intraluminal contrast is also helpful in classifying the abscess either as simple or complex* (Table 44.1).

It appears that performing multiple tests – adding a CT to a US – is not productive. **Do understand that CT or US scanning during the first postoperative week is futile** because neither technique can distinguish between a sterile fluid collection (e.g. residual lavage fluid), an infected fluid collection or a frank abscess. The only way to document the infective nature of any visualized fluid is a **diagnostic aspiration** – subjecting the aspirate for a Gram stain and culture. CT features suggestive of a proper abscess are a contrast-enhancing, well-defined rim, and the presence of gas bubbles. Please bear in mind that not all fluid collections that are detected in the postoperative abdomen require active management; be guided by the patient's clinical condition at all times.

Treatment

Abdominal abscesses should be drained; when an “active” source exists it should be dealt with. Antibiotic treatment is of marginal importance.

Antibiotics

The truth is that no real evidence exists to prove that antimicrobial agents, which penetrate poorly into established abscesses anyway, are necessary as an adjunct to the complete evacuation of pus. Think about the good old days, not many years ago, when pelvic abscesses were observed until reaching “maturity” and then drained through the rectum or the vagina; no antibiotics were used and the recovery was immediate and complete. The prevalent “standard of care”, however, although lacking evidence, maintains that when an abscess is strongly suspected or diagnosed then antibiotic therapy should be initiated. The latter should initially be empirically targeted against the usual expected polymicrobial spectrum of bacteria; when the causative bacteria are identified the coverage can be changed or reduced as indicated.

How long to administer antibiotics? Again there are no scientific data to formulate logical guidelines. Common sense dictates that prolonged administration after effective drainage is unnecessary. Theoretically, antibiotics may combat bacteremia during drainage and eradicate locally spilled microorganisms; but after the pus has been evacuated, leading to a clinical response, antibiotics should be discontinued. The presence of a drain is not an indication to continue with administration.

Conservative Treatment

Traditionally, multiple hepatic abscesses, as a consequence of portal pyemia, which are not amenable to drainage, are treated with antibiotics, with a variable response rate. There are those who claim that non-operative treatment, with prolonged administration of antibiotics, is also effective in children who develop abdominal abscesses following appendectomy for acute appendicitis. The problem with such “successes” is that the alleged “abscesses”, which were imaged on US or CT, were never proven as such. Instead, they probably represented sterile collections – the majority requiring no therapy at all.

Drainage

Philosophy and timing. Presently, the prevailing paradigm, when an abscess is suspected on a CT or US, is to hit the patient with antibiotics and rush to drainage. In this hysterical hurry to treat, clinical lessons learned over centuries are often ignored. Only a generation ago, a patient who spiked a temperature after an appendectomy was patiently but carefully observed without antibiotics (which did not

exist); usually the temperature – signifying residual local inflammatory response syndrome (LIRS) (🔗 Chap. 48) – subsided spontaneously. In the minority of patients “septic” fever persisted reflecting maturing local suppuration. The latter was eventually drained through the rectum when assessed as “mature”. Today, on the other hand, antibiotics are immediately given to mask the clinical picture, and imaging techniques are instantly ordered to diagnose “red herrings”, which in turn promote unnecessary invasive procedures. Remember, in a stable patient fever is a *symptom* of effective host defenses – not an indication to be aggressively invasive (🔗 Chap. 40).

Practical Approach

When an abscess is suspected a few dilemmas arise and should be dealt with stepwise:

- Is it an abscess or a sterile collection? The aforementioned CT features may be helpful but the clinical scenario is as important – especially when postoperative abscesses are concerned. Abscesses rarely mature for drainage before a week has passed since the operation and, 3 weeks after the operation, the cause of “sepsis” is rarely within the abdomen. When in doubt image-guided diagnostic aspiration is indicated.
- Percutaneous (PC) versus open surgical drainage? During the 1980s multiple retrospective series suggested that the results of PC drainage are at least as good as those achieved by an operation. It was also said by some that, paradoxically, despite the attractiveness of a PC technique for abscess drainage in the most ill patients, a better chance of survival is achieved with surgical treatment, and that surgical treatment should not be avoided because the patient is considered to be too ill. Be that as it may, there is no clear evidence to attribute lesser mortality or morbidity to PC drainage versus surgical drainage. The former, however, is a minimal access procedure that can spare the patient the unpleasantness and obvious risks of yet another open abdominal operation.
- **The concept of a complex abscess is clinically useful.** Abscesses that are multiple, multiloculated, associated with tissue necrosis, enteric communication or tumor, are defined as **complex** and are less likely to respond to PC drainage, whereas most **simple** abscesses do. However, in gravely ill patients with **complex** abscesses, PC drainage may offer significant **temporizing** therapeutic benefits – allowing a definitive semi-elective laparotomy in better-stabilized patients.
- **It appears that PC drainage and surgical drainage techniques should not be considered competitive but rather complementary.** If an abscess is accessible by PC techniques, it is reasonable to consider a non-operative approach to the problem. You, the surgeon, should consider each abscess individually together with the radiologist, taking into the consideration the “pros and cons” presented in 🔗 Table 44.2.

Table 44.2. Intra-abdominal abscesses: percutaneous (PC) versus open surgical drainage. Considerations in selecting the approach

	PC drainage	Open drainage
Surgically accessibility	Hostile abdomen	Accessible
PC accessibility	Yes	No
Source controlled	Yes	No
Location	Visceral	Interloop
Number	Single	Multiple
Loculation	No	Yes
Communication with bowel	No	Yes
Associated necrosis	No	Yes
Associated malignancy	No	Yes
Viscosity	Thin	Thick debris
Invasive radiologist	Available	Not available
Severity of illness	“Stable”	Critically ill
Failed PC drainage	No	Yes

- **Percutaneous aspiration only versus catheter drainage?** A single PC needle aspiration may successfully eradicate an abscess – especially when it is small and contains low-viscosity fluid. There is good evidence, however, that PC catheter drainage is more effective.
- **Size of PC catheters-drains?** Some claim advantage for large-bore trocar catheters for PC drainage but the evidence indicates that size 7 French PC sump drains are as effective as size 14 French.
- **Management of PC drains.** There is not much science here; these are small tubes and should be regularly flushed with saline to remain patent. The drain site should be regularly cleaned and observed: there are single case reports of necrotizing fasciitis of the abdominal wall around a PC drain site. PC drains are removed when clinical SIRS has resolved and the daily output (minus the saline injected) is below 25 ml. On average, after PC drainage of a simple abdominal abscess, the drain is removed after 7 days.
- **Re-imaging.** Clinical improvement should be seen within 24 to 72 hours following PC drainage. Persistent fever and leukocytosis on the fourth day after PC drainage correlates with management failure. Non-responders should be re-imaged with CT, combined with water-soluble contrast injected through the drain. Depending on the findings a decision should be taken by you – the surgeon – in consultation with the radiologist, as to the next appropriate course of action – a re-PC drain or an operation. Persistence of high output drainage in a patient who is clinically well can be better investigated with a tube sinogram to delineate the size of the residual abscess cavity. Abscess cavities which do not collapse commonly tend to recur.

Failure of PC Drainage: When to “Switch Over” to Surgical Drainage?

Patients who deteriorate after the first attempt at PC drainage should be operated upon promptly; further procrastination may be disastrous.

In stable non-responders to the initial PC drainage a second attempt may be appropriate, according to the considerations mentioned in ◊ Table 44.2. Inability successfully to effect the second PC drainage, or its clinical failure, mandates an open procedure.

Surgical Management of Intra-abdominal Abscesses

About a third of intra-abdominal abscesses are not suitable for PC drainage and require an open operation. A few practical dilemmas exist:

- **Exploratory laparotomy vs direct surgical approach.** A “blind” exploratory laparotomy to search for an abscess “somewhere”, so common less than 20 years ago, is currently very rarely necessary. A direct approach is obviously more “benign”, sparing the previously uninvolved peritoneal spaces and avoiding bowel injury and wound complications. It is almost always possible in spontaneous abscesses, which are so well defined on CT. But those are also the kind of abscesses that usually respond to PC drainage. Nowadays, although postoperative abscesses are anatomically well localized on CT, those that fail PC drainage are usually “complex”, and therefore often not amenable to a direct approach (e.g., interloop abscess) or they require additional procedures to control the intestinal source. Criteria for choosing the correct approach are summarized in ◊ Table 44.3.

- **Direct approach:** extra-peritoneal versus trans-peritoneal? There are no significant differences in overall mortality and morbidity between the two approaches; however, the trans-peritoneal route is associated with a higher incidence of injury to the bowel. It is logical to suggest that the extraperitoneal approach should be used whenever anatomically possible. Subphrenic and subhepatic abscesses can be approached extraperitoneally through a subcostal incision or – if posterior – through the bed of the 12th rib. Old-timers are still familiar with these techniques, which are currently rarely utilized – having been replaced by PC drainage. Pericolic, appendicular and all sorts of retroperitoneal abscesses are best approached through a loin incision. Late-appearing pancreatic abscesses (◊ Chap. 18) too can be drained extraperitoneally – through the flank – but occasionally need a bilateral approach. Pelvic abscesses are best drained through the rectum or vagina.

- **Drains?** Classically, at the end of the open procedure a drain has been placed within the abscess cavity – brought to the skin away from the main incision. The type, size and number of drains used depended more on local traditions and preferences than on science. Similarly, the postoperative management of drains

Table 44.3. Exploratory laparotomy vs “direct” open drainage of abdominal abscesses

	Exploratory laparotomy	Direct open drainage
Abscess accurately localized on CT	No	Yes
Early postoperative phase	Yes	No
Late postoperative phase	No	Yes
Single abscess	No	Yes
Multiple abscesses	Yes	No
Lesser sac abscess	Yes	No
Interloop abscess	Yes	No
Source of infection uncontrolled	Yes	No
Subphrenic/subhepatic	No	Yes
Gutter abscess	No	Yes
Pelvic abscess	No	Yes

involved cumbersome rituals with the drains sequentially shortened, based on serial contrast sinograms, to ascertain the gradual collapse of the cavities and drain-tracts. House surgeons and nurses forever changed dressings and irrigated the drains – again according to the locally prevailing ritual. **Our experience is that this elaborate nonsense should belong to history.** With adequate surgical drainage, when the source of infection has been controlled, when the abscess cavity is “filled” with omentum or adjacent structures, and prophylactic peri-operative antibiotics are administered – no drains are necessary. Trust the peritoneal cavity to deal with the residual bacteria better in the absence of a foreign body – the drain. We do not recall the last time we had to “shorten” a drain or to obtain a drain-sinogram. Oh, the sweet memories of naïve youth.

Summary

Tailor your approach to the anatomy of the abscess, the physiology of the patient, and the local facilities available to you. Do not procrastinate, do not forget to deal with the source, do not over-rely on antibiotics, and get rid of the pus. Sepsis, the host-generated systemic inflammatory response to the abscess may persist, and progress to organ failure, even after the abscess has been adequately managed (Chap. 48). Try not to be too late.

“No drainage is better than the ignorant employment of it... A drain invariably produces some necrosis of the tissue with which it comes in contact, and enfeebles the power of resistance of the tissues toward organisms.” (William Stewart Halsted, 1852–1922)

Anastomotic Leaks and Fistulas

MOSHE SCHEIN

“If there is a possibility of several things going wrong, the one that will cause the most damage will be the one to go wrong.” (Murphy’s Law, Arthur Bloch)

Somebody’s leak is a curiosity – one’s own leak is a calamity.

There are two chief clinical patterns of postoperative intestinal leak:

- The leak is obvious – you see intestinal contents draining from the operative wound or from the drain site (if a drain was used).
- You suspect a leak but do not see one.

Scenario 1: The Obvious Leak

It is postoperative day 6 after a laparotomy for small bowel obstruction (☉ Chap. 21). The procedure was uneventful, except for two accidental enterotomies, which were closed with interrupted Vicryl 3-0 in one layer. During morning rounds the patient complains: “look, doctor, my bed is full of this green stuff”. You uncover the patient’s abdomen to see bile-stained intestinal juice pouring through the incision! Now you are very upset. True, the patient’s recovery was not smooth; he was running a fever and a high white cell count. And now this terrible disaster! It is a disaster indeed, for even today around one-third of patients with intestinal suture-line breakdown die.

Your first reaction is, “Let’s get him to the operating room immediately and fix this mess”. Is this advisable?

The Controversy

There is little controversy that established postoperative external enteocutaneous fistulas, which usually result from leaking anastomoses or incidental enterotomies, should initially be managed *conservatively*. As noted in previous chapters, there is also little controversy that acute gastrointestinal perforation, be it spontaneous or traumatic, is an indication for an emergency laparotomy to deal with the source of contamination/infection (☉ Chap. 12).

So what about the “early postoperative small bowel leakage”? Is it a “simple perforation” requiring an immediate operation, or a “fistula” to be managed conservatively? We contend that this scenario represents both conditions and should therefore be managed selectively in the individual patient.

The Role of Non-operative Management

With proper supportive management, and in the absence of distal obstruction or loss of bowel continuity, more than half of postoperative small bowel fistulas will close spontaneously within 6 weeks. Those which fail to close by this time will require elective re-operation. When performed on an anabolic, non-SIRS patient, in a less hostile peritoneal environment, a procedure will restore the integrity of the gastrointestinal tract with an acceptable risk of complications.

A crucial issue when deciding on a trial of conservative management is the presence or absence of peritonitis or sepsis; clinical peritonitis is an indication for an immediate operation. Even when clinical peritonitis is not present, any evidence of SIRS or sepsis should promote an aggressive search for drainable intra-abdominal pus. This is best done with a CT scan; associated abscesses should be drained, percutaneously (PC) or at laparotomy (▶ Chap. 44).

Remember: in unselected series of postoperative enteocutaneous fistulas a third of patients die – the vast majority from neglected intra-abdominal infection.

The Role of Operative Management

As stated above, peritonitis or a complex intra-abdominal abscess not suitable for, or responding to, PC drainage, are an indications for laparotomy. But why not operate on all such patients? Why not just surrender to the temptation buzzing in your brain: “I know where this leak is coming from; let me just return to that abdomen and fix the small problem with a few more sutures”? Why won’t resuturing the leak solve the problem?

Primary Closure of a Disrupted Intestinal Suture Line is Doomed to Fail

We can all remember an isolated success in closing an intestinal leak, but the collective experience points to an overwhelmingly high rate of failure. Attempts to close an intestinal leak, after a few days, in an infected peritoneal cavity are doomed to fail. Re-doing an intestinal anastomosis in the presence of postoperative peritonitis is an exercise in futility. Obviously, if successful the surgeon is a hero who saves his patient a prolonged hospitalization and morbidity. If, however, a leak re-develops, as it usually does, it produces a tremendous “second hit”, which strikes an already primed, susceptible and compromised host (▶ Chap. 48). Sepsis and death are then almost inevitable.

Suggested Approach to Early Postoperative Intestinal Fistula

Trial of conservative management is warranted when:

- There is no clinical peritonitis.
- There are no associated abscesses on CT and you know the leak is “controlled”.
- You know, or can accurately guess at, the underlying cause of the leak – you were the one to perform the first operation and know with reasonable certainty what the source of the leak is (an anastomosis or an enterotomy).

An immediate re-laparotomy is warranted when:

- There is evidence of clinical peritonitis.
- There is “SIRS/sepsis” with proven or suspected intraperitoneal abscesses (an attempt at PC drainage may be in order, however).
- Abdominal compartment syndrome exists.
- Somebody you do not trust performed the primary, “index”, operation. Bitter experience has taught us that in such cases “anything is possible” and it is better to re-operate – you never know what the findings will be.

What to Do During an Emergency Re-laparotomy?

There are three things to consider: (1) the condition of the bowel, (2) the condition of the peritoneal cavity, and (3) the condition of the patient.

Very rarely in a stable, minimally compromised patient, when peritonitis is macroscopically minimal, when the bowel appears of “good quality”, when the patient’s serum albumin levels are reasonable, we would resect the involved segment and re-anastomose. Such a sequence of events is possible only when the leak presents within a day or two after the operation (usually caused by a technical mishap). An immediate re-operation before local and systemic adverse repercussions develop may thus provide definitive cure. If conditions are not so propitious though, the less heroic but logical and life saving option of exteriorization of the leaking point as an enterostomy should be carried out, and at **any level**.

Conservative Management

The principles of management are few and simple.

- **Restore fluid and electrolyte balance.** All the fistula’s losses should be measured and replaced.
- **Protect the skin** around the fistula from the corrosive intestinal juice. A well-fitting colostomy bag around the fistula often does the trick. Otherwise place a tube

connected to a continuous suction source adjacent to the fistula, place stomadhesive sheaths around the defect, and cover the entire field with an adhesive transparent dressing (similar to the “sandwich” described in ◉ Chap. 46 but without the mesh). Make generous use of Karaya and/or zinc paste to protect the skin around difficult-to-manage, complex fistulas. Although such wounds require lots of effort and dedication they are almost always manageable – but only if you care. **The way the abdominal wall of your fistula patient looks is how you look!**

- **Provide nutrition.** Proximal gastrointestinal fistulas require TPN initially until a nasal feeding tube is inserted beyond the leak level. Distal small bowel and colonic fistulas will close spontaneously whether the patient is fed orally or not. As emphasized in ◉ Chap. 41, using the intestine for feeding – if possible – is better. In high fistulas it is often possible, and beneficial, to collect the fistula’s output and re-infuse it, together with the enteral diet, into the bowel below the fistula.
- **Delineate anatomy.** This is best done with a sinogram – injecting water-soluble contrast into the fistula tract. This will document the level of the bowel defect and the absence of distal obstruction and loss of continuity – prerequisites for successful conservative management.
- **Exclude and treat infection.** This has been mentioned above and is repeated here only to emphasize that when your fistula patient dies it is usually because you were not aggressive enough in pursuing our advice.

Gimmicks

The initial output of a fistula has few prognostic implications. A fistula which drains 1000 ml/day during the first week has the same chance of spontaneously sealing as one with an output of 500 ml/day. Artificially decreasing a fistula’s output with total starvation and administration of a somatostatin analogue is cosmetically appealing but not proven to be beneficial.

In patients with a well-established (and long) fistula tract (which takes a few weeks to develop) it is possible to hasten the resolution of the fistula by **blocking the tract**. Many “innovative” methods have been reported as successful (usually in small series of patients), ranging from the injection of fibrin glue (through a fiberscope) deep into the tract, to plugging the tract’s orifice with chewing gum (chewed by the patient not by you...).

Fistula Associated with a Large Abdominal Wall Defect

Not uncommonly the end result of intestinal leaks and re-operative surgery is an abdominal wall defect with multiple intestinal fistulas in its base. **This so-called complex or type IV fistula represents a catastrophe, which carries a very high**

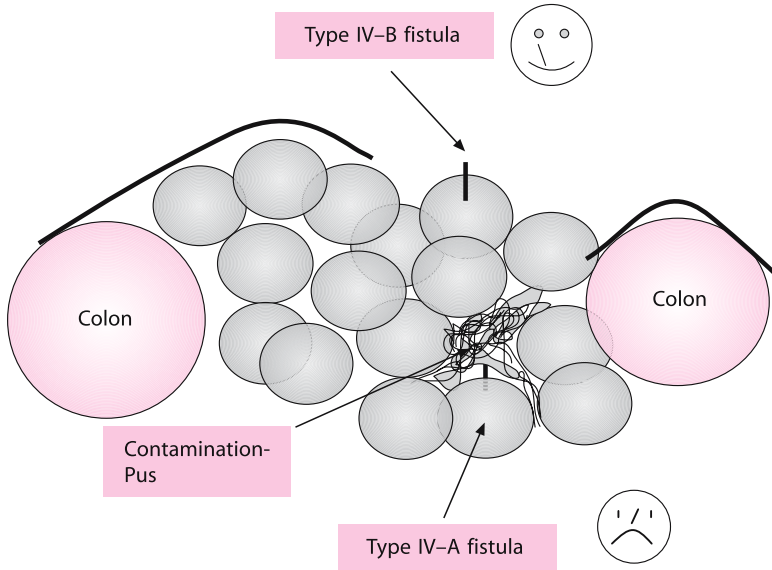


Fig. 45.1. Type IV-A fistulas vs. Type IV-B fistulas

mortality rate. (According to our classification (Schein M, Decker GAG. Postoperative external alimentary tract fistulas. *Am J Surg.* 1991; 161: 435–8) type A are foregut fistulas, type B, small bowel, and type C, colonic). The distance of the fistulous opening in the intestine from the surface of the defect and the condition of the peritoneal cavity have bearing on the treatment of this condition. It is practical to distinguish between two situations (☉ Fig. 45.1):

— **Type IV-A fistulas.** When the fistula is located in the depths of the infected abdominal defect, the prolonged contact of large peritoneal surfaces with gastrointestinal contents allows increased absorption of toxic products, perpetuating local and systemic inflammatory responses and organ dysfunction. In such instances re-operation is necessary to exteriorize or divert the intestinal leak away from the defect. Otherwise, the patient is doomed, as more than half of the patients with this type of postoperative fistula die!

— **Type IV-B fistulas.** Those are “exposed” fistulas near the surface of the defect. Also called “bud” fistulas they result from damage to intestine exposed at the base of the defect. Because the peritoneal cavity is usually clean and sealed away from intestinal contents, an expectant approach is indicated as early attempts at intestinal reconstruction are hazardous during the resolution of severe peritoneal inflammation. **A simple rule of thumb is that the condition of the abdominal wall defect reflects the condition of the peritoneal cavity.** A well-contracted abdominal wall defect, and fistulas that look like surgical stomas are indicators that an elective intervention is possible and safe (☉ Chap. 46).

- Note: an “exposed-bud” fistula may be dealt with temporarily (until definitive reconstruction) using the following technique: define the mucosal and submucosal layer of the protruding intestinal hole, close it with a fine monofilament suture. Immediately cover the repaired bowel and the surrounding abdominal wall defect with a split-thickness skin graft. This should be successful in half of your attempts.

Scenario 2: You Suspect a Leak but Do Not See One

Your patient is now a week after an uneventful right hemicolectomy for a carcinoma of the cecum. She is already at home, and eating, when a new pain develops on the right side of her abdomen, accompanied by vomiting. The patient returns to the emergency room. She is febrile, her right abdomen is tender with a questionable mass, the abdominal X-ray suggests an ileus or partial small bowel obstruction (🔗 Chap. 43), the white cell count is elevated. You suspect an anastomotic leak.

From a clinical standpoint there are three types of intestinal leaks that “you cannot see”:

- **Free leak.** The anastomosis is disrupted and the leak is **not** contained by adjacent structures. The patients usually appear “sick”, exhibiting signs of diffuse peritonitis. An immediate laparotomy is indicated as outlined above.
- **Contained leak.** The leak is partially contained by peri-anastomotic adhesions to the omentum and adjacent viscera. The clinical abdominal manifestations are **localized**. A peri-anastomotic abscess is a natural sequela.
- **A mini-leak.** This is a “minute” anastomotic leak – usually occurring late after the operation when the anastomosis is well sealed off. Abdominal manifestations are localized and the patient is not “toxic”. A mini-leak is actually a “peri-anastomosis” – an inflammatory phlegmon around the anastomosis. Usually it is **not** associated with a drainable pus-containing abscess.

In the absence of diffuse peritonitis you should document the leak and grade it. Colonic anastomoses are best visualized with a Gastrografin enema. For upper gastrointestinal and small bowel anastomoses give Gastrografin from above. We usually combine the contrast study with a CT – searching for free intraperitoneal contrast or abscesses. There are a few possibilities:

- Free leak of contrast into the peritoneal cavity (a lot of free contrast and fluid on CT). You have to re-operate. We previously discussed what to do: it’s best to take down the anastomosis.
- Contained localized leak (a local collection or abscess on CT). The rest of the peritoneal cavity is “dry”. This is initially treated with antibiotics and PC drainage (🔗 Chap. 44).

— No leak on contrast study (a peri-anastomotic phlegmon on CT). This represents mini-leak or “peri-anastomosis” and usually resolves after a few days of antibiotic therapy.

Note that a contained leak or a mini-leak may be associated with an obstruction at the anastomosis – a result of the local inflammation. Such obstruction usually resolves spontaneously (within a week or so) after the pus has been drained and the inflammation has subsided (🔗 Chap. 43).

Conclusion

We have tried to persuade you that an anastomotic leak is not one disease but a variety of conditions requiring customized approaches. To keep morbidity at bay, tailor your treatment to the specific leak, its severity and the condition of the affected patient. **Above all – remember that non-drained intra-peritoneal bowel contents and pus are killers – often silent ones.**

— We tend to remember best those patients we almost killed; we never forget those we actually managed to kill.

Good surgeons operate well; great surgeons know how to manage their own complications.

Re-laparotomies and Laparostomy for Infection

MOSHE SCHEIN · ROGER SAADIA · DANNY ROSIN

“When is a surgeon (not a new, but an experienced one) nervous? Not during operations. But basically a surgeon’s nervousness beings after the operations, when for some reason the patient’s temperature refuses to drop or a stomach remains bloated and one has to open it not with a knife, but in one’s mind, to see what had happened, to understand and put it right. When time is slipping away, you have to grab it by the tail.” (Alexander Solzhenitsyn)

Remember ● Chap. 12 where we discussed the principles of management of *intra-abdominal infection (IAI)*? We told you that in some patients, to improve survival, the performance of *source* and *damage* control must be repeated; certain patients need a **re-laparotomy**. In this chapter we’ll discuss re-laparotomies in greater detail. Leaving the abdomen open (**laparostomy**), is a frequently encountered alternative to repeated laparotomy, hence it is discussed here as well (in the second part). And at the end of the chapter we present an “invited commentary” about **laparoscopic abdominal re-exploration after open surgery**.

Re-laparotomy

MOSHE SCHEIN · ROGER SAADIA

Definitions

Before we continue you should be re-introduced to some definitions.

“On-demand” versus “planned” re-laparotomy

- “**On-demand**”: when, in the aftermath of an initial laparotomy, evidence of an intra-abdominal complication forces the surgeon to re-operate.
- “**Planned**” (or “electively staged”): when, at the initial laparotomy, the surgeon makes the decision to re-operate within 1–3 days, irrespective of the patient’s immediate postoperative course.

Both these types of re-laparotomy have a place in the postoperative management of the patient following a laparotomy, but they apply in different clinical contexts.

Re-laparotomy "On Demand"

The unexpected development of IAI after an initial, "index", laparotomy constitutes the indication for re-exploration. The two postoperative complications that may require a re-look are *generalized peritonitis* or *intra-abdominal abscess*. A postoperative suture line or anastomotic dehiscence may manifest itself either as an external fistula, with no peritoneal contamination, or as peritonitis – be it generalized or localized (e.g. abscesses). Leaks take place typically between the fifth and eighth postoperative days, but may occur earlier or later (see also ⦿ Chaps. 44 and 45).

Postoperative Peritonitis

Peritonitis complicating a laparotomy is termed "*postoperative peritonitis*". This is one of the most lethal types of peritonitis – killing between one-third and one-half of the patients – for the following two reasons:

- Its diagnosis is usually delayed, because the abdominal signs (tenderness, distension) are initially masked by the expected similar signs of the postoperative abdomen.
- It occurs in the postoperative phase, when the patient is catabolic, already "inflamed" by SIRS (systemic inflammatory response syndrome) and immunodepressed by CARS (compensatory anti-inflammatory response syndrome; ⦿ Chap. 48).

There are several possible clinical presentations developing within days of a laparotomy:

- *Generalized peritonitis*. The abdominal findings are out of proportion to the normal postoperative state (severe abdominal pain and tenderness, massive or prolonged ileus). There may be associated systemic repercussions (fever, leukocytosis) that are uncharacteristic of the expected postoperative recovery. Sometimes, the diagnosis is made easier by the additional presence of an entero-cutaneous fistula (⦿ Chap. 45), deep wound infection (⦿ Chap. 49) or abdominal wall dehiscence (⦿ Chap. 47).
- *Organ dysfunction (renal failure or incipient ARDS – acute respiratory distress syndrome – manifested as atelectasis or pneumonia)*. Not infrequently, the unsuspecting surgeon seeks expert advice from medical colleagues (nephrologist, chest physician, infection disease specialist or intensivist). Of course, renal failure or pneumonia may well occur in a postoperative patient for a variety of reasons that are unrelated to an intra-abdominal complication. But similarly, persistent or recurrent intra-abdominal infection may present itself initially as a single system dysfunction and progress, in time, to multiple organ failure. It is essential, firstly, to

be aware of the relationship between IAI and organ dysfunction (➤ Chap. 48) and secondly, to be humble enough to consider the possibility of such a complication in one's patient (➤ Chap. 40). The diagnosis is established by careful clinical evaluation of the abdomen, usually supplemented with abdominal imaging – mainly computed tomography (CT).

— *The intensive care setting.* The possibility of IAI is raised because of the need for prolonged ventilation or aggravation of multiple organ dysfunction in a critically ill postoperative patient, for example after massive trauma or major abdominal surgery. Intensivists are usually quick to point to the abdomen as the culprit and eager to spur the surgeon to re-explore. In a ventilated, paralyzed patient, the abdomen cannot be evaluated clinically. There is therefore a real dilemma in differentiating between the presence of an abdominal focus of infection and the SIRS without infection (➤ Chap. 48) or due to infection elsewhere. Abdominal CT is claimed by radiologists to be very useful but unfortunately it is not so *during the first 5–7 postoperative days*. After any laparotomy, tissue planes are distorted and potential spaces may contain fluid; even the best radiologist cannot tell you whether the fluid is blood, serous fluid, leaking bowel contents or pus. In addition, transporting a critically ill patient on maximal organ support to the CT suite is not an innocuous procedure. Thus, the decision to re-operate during the first postoperative week can be extremely vexing and requires good co-operation between surgeons, intensivists and radiologists.

— *Intra-abdominal abscess.* (See ➤ Chap. 44).

Remember: the diagnosis of postoperative intra-abdominal “septic” complications is extremely difficult. *Denial* is a major culprit! Surgeons hate to admit to their own failures and confront it. Look around you, and at your past experiences: how many times have you seen patients fading away while everything is blamed on the “bad pneumonia”? If all your dead postoperative patients were subjected to a routine autopsy you would find intra-abdominal complications (unknown to you) in around half of them. The following cliché should be deeply imprinted in your surgical soul:

“Look for pneumonia inside the abdomen.”

As said by Mark M. Ravitch: “The last man to see the necessity for re-operation is the man who performed the operation.”

“Planned” (“Electively Staged”) Re-laparotomy

A negative re-laparotomy is better than a positive autopsy but is not, nevertheless, a benign procedure.

The policy of *planned re-laparotomies* is decided upon during, or immediately after, the first *index* operation for peritonitis, when the surgeon decides to re-operate within 1–3 days, irrespective of the patient’s immediate postoperative course. The decision to re-explore the abdomen is part of the initial management plan. Historically, mesenteric ischemia (⦿ Chap. 23) was probably the first instance when a planned re-look laparotomy was advocated. In the context of intra-abdominal infection, the “excuse” for a re-look is better source control, to repeat the “peritoneal toilet”, anticipating the re-formation of infected collections. The inspiration behind all of this is to abort or diminish the magnitude of SIRS and associated multiple organ failure (⦿ Chap. 48).

Indications for Planned Re-laparotomies

The indications to embark on planned re-laparotomy remain poorly defined and empiric. We would undertake it during the **first postoperative week** – a period when abdominal CT findings are “non-specific” and thus CT-directed percutaneous, or open, procedures are not an option.

- In our own experience **the most appropriate indication is failure to obtain adequate source control during the initial operation**. A classic example is infected pancreatic necrosis after necrotizing pancreatitis (⦿ Chap. 18). Another example is an intestinal leak, which cannot be safely repaired or exteriorized – a scenario commonly associated with postoperative peritonitis.
- The necessity to **re-debride or re-drain poorly localized, “stubborn” infective processes**. For example, for diffuse retroperitoneal fasciitis due to retroperitoneal perforation of the duodenum or colon.
- **Diffuse fecal peritonitis** is a relative indication used by us, with the rationale that in the face of massive fecal contamination another laparotomy is necessary to achieve an adequate peritoneal toilet.
- “Instability” of the patient during the initial operation may occasionally lead to an abbreviated “**damage control**” type procedure, with an obligatory subsequent planned re-laparotomy to complete the source control and peritoneal toilet. Obviously, when hemostatic packs have to be left in situ a re-laparotomy is needed to remove them.
- Dr. Dietmar Wittmann – who combines an obsessive policy of planned re-laparotomies with laparostomy, calling it *STAR* (staged abdominal repair) – contends that re-operations allow him to “assess” high-risk anastomoses “where in the past a colostomy would have been done”. We are not convinced.

The Conduct of a Re-laparotomy

The key piece of advice for the surgeon who plans to re-enter a recently opened abdomen is to **be gentle!** The peritoneal surfaces are edematous, friable and vascular, and so is the bowel. Re-operative abdominal surgery is a situation where the dictum “first do not harm” has particular relevance. Do not produce holes in the bowel, do not cause bleeding – such mishaps could kill your already compromised patient.

Another important tip: **know your way around.** Ideally, the surgeon who has performed the original procedure should be the one to re-operate or at least be among the re-operating team. Think about the infected postoperative abdomen as a thick jungle; a previous journey through it renders a re-visit easier. You will remember, for example, that the colon was “sticking” to the lower end of the incision; your partner, on the other hand, who did not visit this jungle before, will immediately enter the lumen of the colon – with horrendous consequences.

The abdominal re-look itself aims at draining all infected collections and controlling, if necessary, persistent sources of contamination. How thorough the exploration depends on the individual case. Sometimes there are several inter-loop abscesses that need to be drained and the whole bowel must be carefully unraveled; in other cases, particularly in instances of frozen abdomen, it is sufficient to explore the spaces around the matted bowel (subphrenic spaces, paracolic gutters, pelvis). The decision about the extent of exploration is important because the more widespread it is, the more danger it poses to adjacent structures. And – as you have been told here again and again – the more you do, the more local and systemic inflammation you create. **The “extent” of exploration then depends on whether your operation is “directed” or “non-directed” and on its timing.**

“Directed” versus “Non-directed” Re-look

“Directed” re-operation means that you know exactly where you want to go and what for. The CT showed a right subhepatic collection, with the rest of the abdomen appearing “clean”. You can go directly to where the action is – sparing the rest of the abdomen the potentially damaging effects of your hands and instruments. Conversely, a “non-directed” re-look is a blind re-exploration when you are not sure where the problem exactly lies, for example, the CT showed free fluid everywhere – in this instance, a thorough search is required.

Timing of Re-look

When you re-explore the abdomen 24–72 hours after the initial operation the adhesions between the viscera and peritoneal surfaces are easily separable; you can enter any space with atraumatic dissection. At this stage “total” abdominal exploration is readily accomplishable. However, as time passes, the intra-abdominal structures become progressively cemented to each other with, dense, vascular, immature adhesions that are troublesome to divide. Clearly, abdominal re-entry within 7 days to 4 weeks of the “index” operation may be hazardous – until the eventual maturation of the adhesions, which takes many weeks to occur.

Consequently, during an “early” re-look operation you may separate all loops of bowels – getting rid of intra-loop collections. **At “late” re-operations, however, you will find a central mass of matted small bowel. Leave it alone!** Dissection of the individual loops at this stage is dangerous and non-productive because significant collections are to be found at the periphery – **above** (under the diaphragms, under the liver), **below** (in the pelvis), and on the **sides** (in the gutters).

During re-exploration sharp dissection is rarely needed. Your fingers are the best exploratory instruments – dissecting into the spaces. Remember – where tissue planes are normal – not readily admitting your dissecting, pinching fingers – nothing is to be found. **So follow your fingers, which lead you to where the pus lies.**

The Leaking Intestine

Dehisced suture lines and anastomoses must be de-functioned, ideally by the fashioning of appropriate stomas or, if this is not possible, by tube drainage. Re-suturing leaking bowel in an infected peritoneal cavity is doomed to failure and carries a high mortality. For more on this issue see ◉ Chap. 45.

Drains

The use of intraperitoneal drains is controversial in this setting. They are certainly not required as long as planned re-laparotomies continue. The placement of a drain at the final laparotomy is another matter; the advantages need to be weighed against the risk of damage to viscera that are extremely friable as a result of recent re-explorations (◉ Chap. 40).

When to Stop?

As in most vital aspects in life, too much of anything is hurtful, and too many planned re-laparotomies are harmful. When to stop? In a management program of planned re-looks the decision to discontinue must be based on the finding of a macroscopically clean peritoneal cavity and evidence that sources of contamination have been controlled definitively. Whether the source is controlled or not is obvious but estimation of whether the peritoneal cavity is “clean” or not requires experience and judgment. Thus, do not send your junior partner or senior resident to re-explore it alone.

“Frequent dilemma: take your wife for dinner or the patient back to the OR?”

When peritonitis persists despite apparently adequate source control and repeated re-operation – think about **tertiary peritonitis** (⦿ Chap. 48).

Are Planned Re-laparotomies Beneficial?

What is the verdict? Do planned re-laparotomies reverse, prevent or aggravate SIRS and multi-organ dysfunction? Is the benefit/risk ratio favorable? Here we repeat what has been already mentioned above, but you were warned that this book would be repetitive! You were warned this book would be repetitive!

Any surgical maneuver that successfully eliminates the source of contamination/infection and/or evacuates contaminants and pus, has to be beneficial; this is an axiom. The problem is that planned re-laparotomies are a double-edged sword – achieving the above goal while injuring the host. Indeed, strict adherence to the policy of planned re-laparotomies is overkill. If one operates until the abdomen is clean then – in retrospect – the last operation is unnecessary. In view of the high morbidity of multiple re-laparotomies we believe that in the long run we serve the patient better with an aggressive policy of postoperative *on-demand* percutaneous CT-guided drainage procedures or CT-directed *on-demand* laparotomies. In doing so one can go directly to where the action is – sparing the rest of the abdomen, and the patient, the trauma of blind exploration.

However, postoperative abdominal imaging does not become accurate before postoperative days 5 to 7; thus, during the first postoperative week – before the infective process has become localized – planned re-laparotomies may be necessary. That is when one or two planned re-laparotomies may help to better control the source, and eliminate heavy contamination. It is our opinion that at a later phase everything should be done “on demand” – based on the patient’s condition, findings on clinical examination (when the abdomen is left open [see below], one can easily place a hand in one of the gutters and feel gently around) and imaging. We do not

believe that we will ever have objective data to solve this controversy. Let us use rational and common sense instead.

Laparostomy

MOSHE SCHEIN · ROGER SAADIA

P. Fagniez of Paris has coined the term “laparostomy”, which implies leaving the abdomen open. Open management of the infected abdomen was instituted in the belief that the peritoneal cavity could be treated like an abscess cavity. It soon became clear, however, that there was sometimes still a need for thorough abdominal re-exploration in search of deep pockets of infection. Laparostomy has become an *adjunct* to the policy of repeated laparotomies; indeed, if the abdomen is to be re-looked 48 hours later, why close it at all?

The notion that peritonitis and its operative treatment often result in increased intra-abdominal pressure (IAP) has been raised sporadically throughout the twentieth century. However, only very recently have clinicians accepted the concept that the prevention or treatment of intra-abdominal hypertension with laparostomy is beneficial. The potential advantages of laparostomy are substantial. Necrosis of the macerated abdominal midline incision closed forcefully and repeatedly in the presence of an edematous and distended bowel is avoided, better diaphragmatic excursion may be expected, and the abdominal compartment syndrome with its renal, respiratory and hemodynamic repercussions is prevented (● Chap. 36).

Indications

For practical purposes think that **laparostomy may be indicated either when the abdomen cannot be closed or should not be closed** (● Fig. 46.1).

Abdomen that cannot be closed:

- After major loss of abdominal wall tissue following trauma or debridement for necrotizing fasciitis
- Extreme visceral or retroperitoneal swelling after major trauma, resuscitation, or major surgery (e.g. ruptured abdominal aortic aneurysm)
- Poor condition of fascia after multiple laparotomies

Abdomen that should not be closed:

- Planned re-operation within a day or two – why lock the gate through which you are to re-enter very soon?
- Closure possible only under extreme tension – compromising the fascia and creating intra-abdominal hypertension (IAHT)

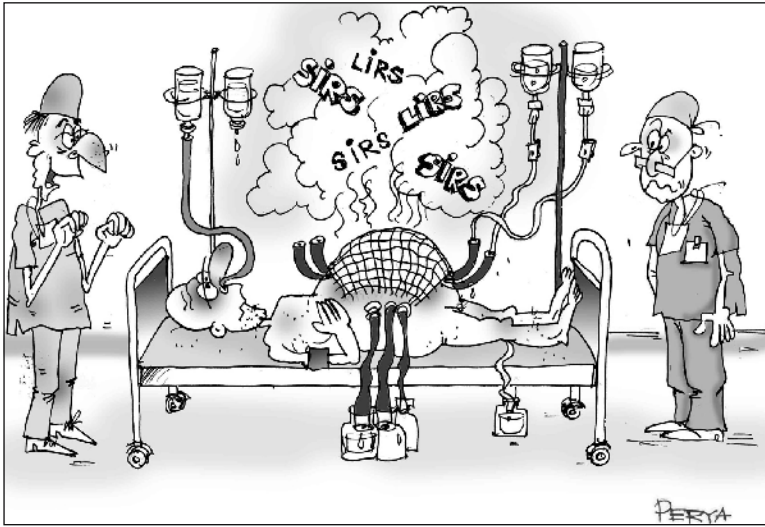


Fig. 46.1. “I told you that laparostomy would make him better: it lets the SIRS out...”

Technical Considerations of Laparostomy

OK, you have decided not to close the abdomen; now, how should you manage it? The option of simply covering the exposed viscera with moist gauze packs has been practiced for generations but is inadvisable: intestine – if not matted – can eviscerate; it is also messy – requiring intensive work to keep the patient and his bed clean and dry. More importantly, it carries a significant risk of creating spontaneous “exposed” intestinal fistulas (● Chap. 45). A friable, dilated bowel wall does not weather the trauma of exposure and repeated dressing change well, and is likely at some point to break down. Temporary abdominal closure (TAC) devices to cover the laparostomy wound are therefore highly recommended.

Your local guru/mentor has probably his own preferred method of TAC, be it a “Bogota bag” made of a large sterile intravenous-fluid bag, a ready to use transparent “bowel bag”, a synthetic mesh (absorbable or non-absorbable), or a Velcro-type material, which can be tightened like your tennis shoe (Wittmann patch). We even know a guy in South America who uses discarded nylon hose for this purpose. In fact, what you choose to use probably does not matter, but there are a few practical points worth remembering:

- Whichever TAC device you use, try to place it over the omentum – if available.
- Suture the TAC device to the fascial edges. Just placing it “on top” will result in huge abdominal wall defects because the midline-wound fascial edges tend to retract laterally (note that this is the reason why the abdominal defect resulting from

a **transverse** laparostomy is smaller). The larger the defect the more problematic its eventual reconstruction.

- Using a permeable TAC device (e.g., mesh) as opposed to a non-permeable (e.g. Bogota bag) has the advantage of allowing the egress of infected intraperitoneal fluids.
- Try to adjust the tension of the TAC device to the intra-abdominal pressure (🔗 Chap. 36).
- If you plan another re-operation within a day or two the type of TAC device you use is of little importance: you can always replace it at the end of the next laparotomy. The selection of TAC device when no more re-operations are deemed necessary is crucial; we recommend an **absorbable synthetic mesh** as discussed below.
- Abdominal re-entry through the TAC device is simple: divide it at its centre; with your finger gently separate the omentum and viscera from the overlying TAC device. At the end of the procedure re-suture the TAC device with a running suture. Zippers can be used instead – an attractive gimmick to nurses.

The “Sandwich Technique”

Our own TAC of choice is the “sandwich technique”. Absorbable permeable synthetic mesh is sutured to the fascial edges. Two tubes (sump drains) are placed at the sides of the abdominal defect – over the mesh, brought out through the skin, and connected to suction – to collect the abdominal effluent. Sheets of stoma adhesive are placed on the healthy skin surrounding the defect; a large adhesive transparent sheet (“Steridrape” or “Opsite”) is placed on top to cover the entire abdomen. The benefits of this arrangement are that the viscera are protected, the laparostomy’s output is measurable, the patient is clean and dry, and the demands on nursing are minimized (🔗 Fig. 46.2).

Terminating the Laparostomy

How should the ensuing abdominal-wall defect be managed when the reason for the laparostomy exists no more?

- If non-absorbable material has been used as a TAC device, it must be removed. Leaving pieces of Marlex mesh in the depths of such a defect will result in a chronic mess of infected sinuses and even intestinal fistulas.
- Occasionally, when the defect is small it may be possible to close it completely. If the healthy surrounding skin comes nicely together forget about fascia and close the skin over the defect. Laterally placed “relaxation incision(s)” occasionally help to bring the midline together. The ensuing certain hernia is of minor importance

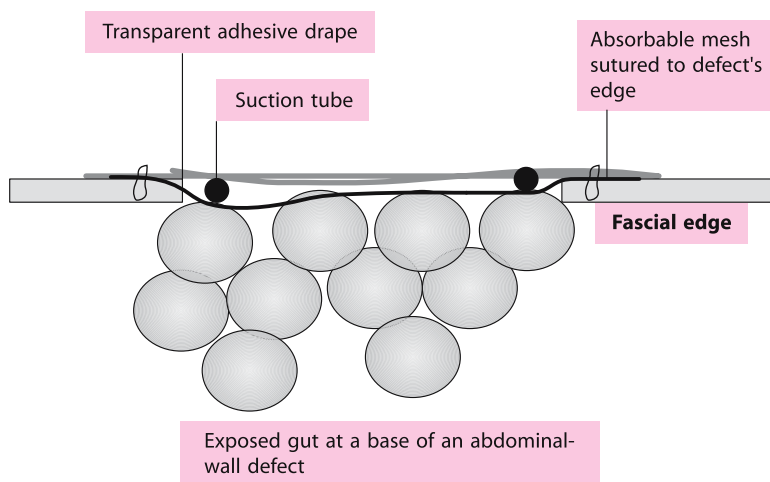


Fig. 46.2. The “sandwich technique” in the management of laparostomy

at this stage. In most patients recovering from multiple re-laparotomies and laparostomy the defect is too large, however, to allow primary closure of the fascia or skin. Here, the safest option is to let the defect granulate under and over the absorbable mesh. In a week or two after the last laparotomy, when a healthy layer of granulation tissue has covered the omentum and viscera and the patient’s recovery is well under way, split-skin grafts are easily applied to the granulation tissue. The resulting ventral hernia is usually wide-necked and well tolerated except for its cosmetic appearance. It can be repaired, if necessary and usually with great difficulty, at a much later stage.

- Now you understand why the use of an absorbable synthetic mesh (e.g. Vicryl or Dexon) as a “final” TAC device is advantageous. It can be left in situ to disintegrate rapidly within the granulating abdominal defect – and then be skin grafted.
- Whatever you do with the abdominal wall defect remember that your patient has just recovered from the immense stress of peritonitis and multiple operations – he cannot take much more at this stage.

Antibiotics

As mentioned in ◉ Chap. 42, in patients with severe intra-abdominal infection who deserve re-operations and/or laparostomy for additional source and damage control, prolonged courses of postoperative antibiotics may be justified. Antibiotics should be continued as long as the source, and residual infection, is “active”. Recent evidence suggests that, in this subgroup of patients, anti-fungal prophylaxis with

fluconazole may decrease the incidence of intra-abdominal superinfection with *Candida* species.

Is Laparostomy Beneficial?

Complications do occur with laparostomy, the most morbid being spontaneous enteric fistulas, and there is always the need for subsequent reconstruction of the abdominal wall. So is the risk–benefit ratio for laparostomy in these patients favorable?

The physiological benefits of a “decompressing” laparostomy for significant IAHT/abdominal compartment syndrome are well proven in trauma and general surgical patients (● Chap. 36). There is also a large body of experimental studies strongly suggesting that elevated intra-abdominal pressure promotes systemic absorption/translocation of peritoneal endotoxin and bacteria, thus increasing the mortality rate of peritonitis in small and large animals. Although the issue of raised intra-abdominal pressure and its treatment with laparostomy has not been studied specifically in the setting of peritonitis, it is clear that treating IAHT is beneficial. Although a borderline IAHT contributes to the overall morbidity, the risk–benefit ratio of *prophylactic* laparostomy in such situations is not clear as yet. **Therefore, in our practice we reserve laparostomy for patients with severe IAHT, those who “cannot be closed” or those whom we plan to re-explore.**

Conclusions

Re-laparotomy and *laparostomy* are therapeutic measures that are indicated in a minority of patients. They represent, for the time being, the heaviest weaponry in the surgeon’s mechanical armamentarium for the treatment of severe intra-abdominal infection and other postlaparotomy abdominal catastrophes. Remember that unnecessary re-laparotomies carry significant morbidity. An aggressive but selective policy of directed “on-demand” re-looks, supplemented by laparostomy, if necessary, is probably superior to a “blind” execution of planned re-laparotomies.

He who operates and runs away – may get to re-operate on the same patient another day.

Laparoscopic Abdominal Re-exploration¹

DANNY ROSIN

No surgeon likes to face a postoperative complication, but the need to treat such a complication by repeated surgery is even more distressing. Such complications may include conditions like intestinal obstruction, intra-abdominal bleeding, hollow viscus perforation or inadvertent bowel injury resulting in intra-abdominal infection. In some cases, such as mesenteric ischemia, a repeat operation is a planned “second-look” procedure.

The presence of a fresh abdominal wound makes it reasonable to re-explore through this same incision. However, re-opening of a recent incision, and re-exploration by laparotomy may contribute to increased short and long-term morbidity. Re-laparotomy is associated with pain, ileus and increased risk of abdominal infection. It may increase the risk of wound infection, and eventual wound dehiscence or later development of an incisional hernia. Overall, it may extend the recovery period of the patient, on top of the condition that prompted it, serving as a “second hit”.

Treatment of complications after laparoscopic surgery is frequently attempted by a repeat laparoscopy – trying to avoid a formal laparotomy. Indeed, complications such as bleeding or bile leak after laparoscopic cholecystectomy can be successfully approached by a second laparoscopy. Laparoscopy is also a valid treatment option in various acute surgical conditions (🔗 Chap. 51). Laparoscopy is frequently performed in the presence of abdominal scars and previous operations – adhesions, or moderately distended bowel, are no longer considered to be considerations for laparoscopic intervention. Given the morbidity associated with re-laparotomy, and the ability of trained laparoscopic surgeons to deal with acute abdominal conditions, **it naturally follows that acute surgical complications may be optimally handled by a minimal access approach.**

Postoperative Conditions Treated by Laparoscopy

— **Mesenteric ischemia** (🔗 Chap. 23). One of the earliest applications of laparoscopy after a recent laparotomy was to perform a “second-look” operation after treating acute mesenteric ischemia. The purpose of this procedure is to ascertain the viability of potentially ischemic segments of bowel, for example around the anas-

¹ We invited Dr. Danny Rosin to tell us how laparoscopy could be used for abdominal re-exploration – even following open procedures (and have added our own comments at the end of his section). – The Editors

tomosis after resection of gangrenous bowel. As the secondary intervention is a simple diagnostic procedure (unless further resection is necessary), it can readily be accomplished via laparoscopy. It has even been suggested that laparoscopic ports should be left in place at the end of the first operation to facilitate access at the second look, but we consider this approach as unnecessary and too risky. Possible injury can be caused by the port itself, which may also serve as a port of entry to bacteria.

- **Early postoperative small bowel obstruction** (⦿ Chap. 43) is an infrequent condition, as opposed to the common postoperative ileus. At times, it will require a second intervention. Laparoscopic management of bowel obstruction is an established procedure and we have successfully applied this approach in several cases of early postoperative obstruction after appendectomy, colectomy and laparotomy for trauma.

- **Peptic ulcer perforation** (⦿ Chap. 17) is another rare postoperative complication, not directly related to the specific procedure performed but possibly related to postoperative stress response or to ulcerogenic medications. We have treated such a case by laparoscopic omentopexy, just as in our standard approach to “primary” duodenal peptic perforations.

- **Intra-abdominal infections** (⦿ Chaps. 12, 43, and earlier in this chapter) may include established abdominal abscesses, and “septic” conditions associated with recent anastomoses. Most of the postoperative abscesses are amenable to percutaneous CT-guided drainage, but a few are not accessible and mandate surgical drainage. Unless treating a patient in extreme conditions of septic shock, laparoscopy can be used to access the abscess cavity, drain and irrigate it, and leave suction drainage in the area.

- **Anastomotic leak** (⦿ Chap. 45) is another dreaded postoperative complication. It may manifest as a free intestinal leak, or as an inflammatory condition (“perianastomosis”). Exteriorization and stoma creation is the usual treatment of the first condition, but the peritonitis leads to a high rate of wound infection, abdominal wall edema, and a risk of increased intra-abdominal pressure. The need for temporary abdominal closure is frequent. Laparoscopy may permit bowel exteriorization and abdominal toilet, without risking the original laparotomy wound. In addition, perianastomosis, although usually responding to antibiotic treatment, may be associated with the presence of free abdominal gas but without actual spillage of bowel contents. This is frequently treated by anastomotic takedown or a proximal diversion. We have a limited experience with three patients in whom laparoscopy revealed a localized inflammatory process, without actual spillage or generalized peritonitis, and, despite the presence of free gas drainage, alone led to full recovery.

Technique

Access to the abdominal cavity must be established by the open technique, using a Hasson cannula, as the bowel may be distended and adherent to the abdominal wall. The port is placed away from the previous incision, usually laterally in the abdominal wall, to avoid the inevitable adhesions to the fresh scar. Some of the adhesions can be separated bluntly by careful movements of the camera, as the bowel may be edematous and friable. Further trocars are placed as necessary, when enough space is established, to complete the space creation and permit abdominal exploration. Non-traumatic instruments should be used, and bowel handling should be kept to minimum, preferably manipulating the bowel by grasping its mesentery to avoid serosal tears and perforations. Although at times the pathology is evident, it is frequently hidden by adhesions of omentum and bowel loops. The abdomen may initially appear “benign”, but a thorough search in spaces such as the pelvis or retroperitoneum may reveal a compartmentalized process. Previous data obtained by a CT scan may help direct the exploration and prevent false-negative explorations and missed pathologies.

I believe that laparoscopic abdominal re-exploration has a definitive role in:

- **Persistent early postoperative intestinal obstruction**
- **“Second look” for mesenteric ischemia**
- **Perforated peptic ulcers**
- **Drainage of abscesses and collections (when percutaneous attempts fail)**
- **Drainage (with or without exteriorization) for anastomotic leaks**

Editorial Comment

We agree with Dr. Rosin that laparoscopic re-exploration in the hands of well trained and experienced laparoscopic surgeons may be advantageous compared with re-laparotomy. The patients must be well selected in terms of their physiology (you do not want to pump lots of gas into the distended belly of a moribund patient) and intra-abdominal pathology. In fact, in most instances the procedure would be “CT-guided laparoscopy” to compensate for the lack of manual exploration of blind spots. And what is true with any laparoscopic procedure should be *crucial* here: “Do not f**k around, do not damage anything – and for God’s sake – know when to stop and open up!”

“A surgeon...is like the skipper of an ocean-going racing yacht. He knows the port he must make, but he cannot foresee the course of the journey. At every stage he must have a plan, based on a working knowledge of his present position, that will allow him to make for the best of several available harbours should things go wrong, or if none is suitable he must know where to find temporary refuge under the lee of the land till he can resume his journey.” (William Heneage Ogilvie, 1887–1971)

MOSHE SCHEIN

The gut bursts out either because you did not close the tummy properly or it has no place inside . . .

When rounding on your patient, who 5 days ago had a laparotomy for intestinal obstruction, you find his wound dressings soaked in some clear-pinkish fluid. “Change the dressings more frequently”, you mutter to the intern. A day later, during lunch, you are paged by the head nurse on the floor: “Doctor, Mr. Hirsch’s intestines are spread all around his bed. Please come and help...!” How embarrassing.

Definitions

Abdominal dehiscence is either complete or partial, the latter being much more common.

- **Partial** (covert, latent) dehiscence is a separation of the fascial edges of the wound without evisceration or full exposure of the underlying viscera. It presents usually a few days after the operation with some sero-sanguinous peritoneal fluid seeping through the wound. When the skin edges are separated or if, as commonly occurs, wound infection is present, you may see the exposed fascia, loose fascial sutures, and occasionally a fibrin-covered loop of intestine
- **Complete** dehiscence is full a separation of the fascia and skin. Loops of intestine – if not glued in place by adhesions – commonly eviscerate “all over the place”.

Etiology

Multiple local, mechanical and systemic factors contribute to abdominal wound dehiscence: ileus, distention, deep wound infection, pulmonary disease, hemodynamic instability, ostomies in the wound, age >65, hypoalbuminemia, systemic infection, obesity, uremia, malignancy, ascites, corticosteroid use, and hypertension. These are factors that cause poor tissue healing or increased intra-abdominal pressure, and you’ll find a few of these in any patient who suffers a

dehiscence. Dehiscence, be it complete or partial, is associated with a significant mortality rate. The prevailing perception is that dehiscence is only a marker for these underlying local and systemic factors, and thus is not directly responsible for the associated morbidity and mortality. **However, the way dehiscence is managed also affects on the outcome, as you'll see below.**

How to Prevent Dehiscence?

You can prevent dehiscence by:

- Choosing a “correct” incision (⦿ Chap. 10)
- “Correctly” closing the abdomen (⦿ Chap. 38)
- Not closing abdomens that should be left open (⦿ Chaps. 36 and 46)

Generally, it appears that vertical incisions – especially the midline – are associated with a greater incidence of dehiscence than transverse incisions. In mechanical terms, **three main causes for dehiscence exist: the suture breaks, the knot slips, or the tissue breaks** (i.e. the suture cuts through the tissues). The last mentioned is the dominant one. Please re-read ⦿ Chap. 38 to ingrain in your brain how dehiscence can be prevented by correct abdominal closure. And remember that abdomens that are very likely to burst could be left open as discussed elsewhere in this book (⦿ Chaps. 36 and 46).

Note: to avoid intra-abdominal hypertension and subsequent fascial dehiscence you can leave the fascia unsutured but close the skin. This is what we do occasionally in high-risk situations, after, say, laparotomies for mesenteric ischemia or intestinal obstruction within a complex incisional hernia. We suture the subcutaneous layer with heavy absorbable suture and the skin with Nylon 2-0, which is left in situ for at least 2 weeks. **A planned hernia is much better tolerated than fascial dehiscence!**

Treatment

“Leading” surgical texts advocate an immediate surgical closure of the dehiscence. For example, Schwartz’s textbook recommends that “If the patient can tolerate the procedure, a secondary operative procedure is indicated”. What kind of a patient “cannot tolerate the procedure” is not stated. The guidelines published by the American College of Surgeons state that if “dehiscence is significant, an immediate operative re-closure is preferred”. A text devoted to complications in surgery suggests that “when a dressing is found soaked in salmon-pink fluid... a fascial defect or a loop of bowel palpated just below the skin... a binder must be applied and the




Fig. 47.1. “Doc, pull harder!”

patient sent promptly to the operating room”. In addition, “failure to repair dehiscence results in evisceration in most cases... re-closure, in contrast is strikingly successful”. Another recent text on re-operative general surgery emphasizes that “abdominal wound dehiscence is clearly a surgical emergency” requiring fascial re-closure (● Fig. 47.1).

Managed according to the above recommendations the patient is taken to the operating room where the abdomen is re-sutured with “retention sutures” (see ● Chap. 38). So why is the mortality so high? Many still think that “most deaths associated with dehiscence today are the result of ongoing primary disease rather than being a direct result of this complication”. There is a large body of data, however, to suggest that such hypothesis is not true. Instead, it appears that the “recommended” treatment of the dehiscence, re-closure, plays a significant role in the associated M & M (morbidity and mortality).

We believe that that forcing the distended intestines back into a cavity of limited size may kill the patient. The **fatal factor** leading to the high mortality rate associated with abdominal wound dehiscence is not the dehiscence itself but the emergency procedure to correct it, which produces intra-abdominal hypertension, which in turn adversely affects cardiovascular, respiratory, renal, and intestinal function, leading to multi-organ dysfunction and eventually to death. (● Chap. 36).

Recommended Approach to Dehiscence

Instead of routinely “pushing back” the bulging viscera into the limited space of the peritoneal cavity, be selective, using the following rationale:

- **Complete dehiscence mandates** an operation to reduce the eviscerated abdominal contents. You cannot leave the intestine hanging outside the bed. You may attempt a re-closure of the fascia when a faulty closure technique or a broken suture is the cause of the dehiscence and local circumstances permit – but only if the facial edges can be approximated without excessive tension. If this is not the case you should leave the abdomen temporarily open, using one of the temporary abdominal closure (TAC) methods described in ♦ Chap. 46. We avoid re-closure also when the abdominal wall is frail or if the cause of the evisceration – persistent intra-abdominal infection – is still present. **What is the use of re-suturing the abdomen if the factors causing the evisceration in the first place are still present?**

- **Partial dehiscence may be managed conservatively.** Many surgeons feel compelled to take the patient to the operating room and re-suture the fascia. But what’s the rush? In our experience this is not only unnecessary but may even complicate matters. The natural course of a partially dehisced wound is to heal by granulation and scarring with or without the formation of an incisional hernia. Re-suturing such a friable wound in a compromised patient entails the additive risks of anesthesia and abdominal re-entry while not preventing the eventual hernia. The latter, if symptomatic, can be repaired electively at a later stage. If the bowel were partially exposed we would approximate the skin to cover it. Otherwise, the wound is managed as any open wound (● Chap. 49) until healed.

In summary: Regard dehiscence as a **symptom rather than a disease**. Operate for complete dehiscence with evisceration; re-suture fascia or use a TAC device selectively. Most cases of partial dehiscence are best treated conservatively.

Commonly, dehiscence of the abdominal wound represents a spontaneous decompression of intra-abdominal hypertension, and thus could be defined as a “beneficial” complication.

LIRS, SIRS, Sepsis, MODS and Tertiary Peritonitis

MOSHE SCHEIN · JOHN MARSHALL

*The larger the operation – the greater the trauma
The greater the trauma – the stronger the SIRS
The stronger the SIRS – the sicker the patient
The sicker the patient – the higher the M & M*

Local and Systemic Inflammation, and Its Consequences

MOSHE SCHEIN

In the first paragraph of this book we alluded to your patient being **locally and systemically inflamed by his surgical disease, your treatment, and the complications of both**. In almost every subsequent chapter you have been reminded that the magnitude of the inflammation correlates with that of the disease process and the operation. You were told that the more inflammation there is – or that you create – the more likely is your patient to develop organ dysfunction or failure, and to die. In this chapter, we'll concentrate on the inflammation – both local and systemic – and its consequences. The biological events involved are immense and chaotic but let us maintain a simplistic attitude – you did not buy this book to read about cytokines, right?

Background

Matters were much simpler for us surgeons, only a few years ago. Post operative or post-traumatic fever, raised white cell count, deteriorating organ-system function, with or without shock, meant for us only one thing – “sepsis”. And “sepsis” meant “infection”, usually bacterial in nature, necessitating antibiotic therapy. So we administered the “strongest”, ever changing, antimicrobial agents available on the market; we looked for pus, draining it whenever present, and we prayed for the “infection” to subside. Some of our patients, however, continued to deteriorate, dying slowly from respiratory and/or renal failure. We buried them, blaming the death on an “intractable sepsis”, which in our minds always signified an infection “somewhere” in their blood, abdomen, urine or lungs. Look around you – isn't this the way many of your senior colleagues, mentors or teachers still think and practice?

Then, in the early 1980s, when our supportive care and re-operative efforts became more aggressive, resulting in prolonged survival, we began to note that many of our patients were dying a “septic” death in the absence of “infection”; we did not understand why. Towards the second half of the 1980s, the rapidly developing field of molecular biology produced a huge amount of data to explain that a lot of what we see in clinical practice is not “sepsis” or “infection” but **inflammation** – which in turn is fueled by pro-inflammatory mediators such as **cytokines**. This has totally changed the way we look at the surgical patient. We see him being **inflamed** by the disease and the operative trauma together with the postoperative complications and associated therapies. **In fact, most of our postoperative patients who die today do so from inflammation or infection – alone or in combination.** But before we go further, we need to clarify a few issues in terminology.

Terminology

Take a knife and cut your finger: sooner or later your finger will manifest the usual signs of inflammation – redness, swelling, warmth and pain, produced by locally generated inflammatory mediators. This is *LIRS or local inflammatory response syndrome*.

Now take a patient who has suffered multiple, and deeper, knife wounds to the soft tissues. In addition to the local inflammation he’ll experience signs of systemic inflammation: fever, tachycardia and even elevation of his white cell count. This is *SIRS or systemic inflammatory response syndrome*. SIRS occurs when the locally pro-inflammatory mediators of LIRS spill over to the systemic circulation, affecting the entire organism. In surgical practice most instances of SIRS are secondary to LIRS. Examples include acute pancreatitis, retroperitoneal hemorrhage, and acute cholecystitis. *Note that the pro-inflammatory cascades leading to SIRS are initially, at least, well compartmentalized locally, with the SIRS representing only the tip of the iceberg.*

LIRS and SIRS can be generated by sterile, non-infective causes (e.g., tissue trauma, necrosis, burn) as well as infective causes (e.g. acute appendicitis). The ensuing clinical manifestation are, however, indistinguishable.

— **Infection** is a microbiological phenomenon characterized by the invasion of normally sterile tissue by microorganisms. The host’s local response to the infection is LIRS, the systemic response is SIRS. And here we arrive at the term *sepsis*.

— **Sepsis is currently defined as the systemic response to infection** consisting of SIRS with microbiological evidence of infection. (*Sepsis = systemic inflammation (SIRS) ± infection*). In other words, SIRS and *sepsis* represent an identical host-determined response, the former in culture-negative patients and the latter when infection is documented. Both manifest a continuum of clinical and pathophysiologic severity.

According to current consensus SIRS may be diagnosed in any patient who manifests two or more of the following: temperature $>38^{\circ}\text{C}$ (100.4°F), heart rate $>90/\text{min}$, respiratory rate $>20/\text{min}$, white cell count $>12,000$ cells/ mm^3 . With such a low inclusion threshold, it appears that most of your emergency abdominal post-operative patients, and all your surgical intensive care unit patients, experience a degree of SIRS. (In fact, there was someone who said that even engaging in vigorous sex produces clinical SIRS).

The noxious stimuli, which incite *pro-inflammatory* mediators leading to LIRS and SIRS, induce in parallel potent anti-inflammatory mediators, to produce what the late Roger Bone (1943–1996, the “father” of SIRS) termed **CARS or compensatory anti-inflammatory syndrome**. CARS manifests clinically as immunodepression and an increased susceptibility to infection, so typical in the aftermath of major surgery and trauma. Conceptually, the balance between SIRS and CARS determines outcome. When CARS equalizes SIRS – homeostasis results. When SIRS is unopposed, organ dysfunction develops. When CARS is the winner, primary or secondary infections may take their toll.

As with many other essential things in life, too much may be harmful and too little may be not satisfactory. The same is probably true for the inflammatory and anti-inflammatory responses, which in a certain phase and magnitude are beneficial but when out of control are harmful. Understand, however, that these events are extremely complex, chaotic, non-linear and unpredictable; some severely traumatized patients do not progress from SIRS to organ failure and some do. Your grandmother may be right – *genes* play a role in everything.

This is of course a highly simplistic version of the reality, much of which we still do not understand, but didn't Ralph Waldo Emerson (1803–1882) say: “**It is proof of high culture to say the greatest matters in the simplest way?**”

From SIRS to Multi-organ Dysfunction Syndrome (MODS)

The same pro-inflammatory mediators that locally possess salutary actions, when over-produced and systemically spread, eventually damage the microcirculation, resulting in progressive damage to vital organs. The inflammatory mediators released by the circulating macrophages, which are activated by the disease or injury, result in widespread endothelial damage, causing capillary leak and coagulation and resulting in cellular damage and then organ dysfunction (lungs, kidneys, liver, gut...). The cytokines (e.g. interleukin-6) not only promote local coagulation but also suppress local fibrinolysis, a compensatory mechanism that attempts to lyse the forming clot.

Thus, your SIRS patient swells, he gains weight, his lungs become wet, the gastric mucosa bleeds, liver enzymes become elevated, renal dysfunction appears,

and so forth. He becomes autointoxicated with his own inflammatory mediators. **The more severe the damage to the organs, the more organs are involved and for a longer duration, and the less likely is your patient to recover.** When three organs fail the prognosis is grim; when the fourth organ joins in, the die is cast.

The Second-Hit Phenomenon

Imagine a boxer in a ring. Having just received a major blow he lifts himself back up to his feet where, almost erect, he receives a second hit, which is softer than the first one, but enough to send the boxer back onto the floor – a fatal knockout. Similarly, your SIRS patient is susceptible to a second hit; his inflammatory response, switched on by the primary hit, is easily amplified by additional, albeit relatively minor hits. Think of your patient as an aging boxer. The abdominal emergency plus your operation represent the first hit. From now on any additional procedure (or complication) constitutes a potential second hit, which greatly increases the magnitude of the inflammation.

Treatment of SIRS and MODS

The search for the magic bullet to arrest the cascades of LIRS, SIRS and to modulate CARS continues; but meanwhile is there anything we can do for these patients?

- First, we need to use terms accurately, distinguishing between local inflammation and infection, between SIRS and systemic sepsis. We must understand that LIRS and SIRS do not always mean infection and thus may not be an indication to administer antibiotics (➤ Chaps. 7 and 42).
- Second, we must restore and maintain perfusion of end organs to prevent an additional ischemic injury, which will contribute to the inflammation (⦿ Chap. 6).
- Third, we must avoid adding fuel to the inflammatory fire, appreciating that what we do, and how we do it does matter. A prolonged operation and rough handling of tissues means more inflammation, more LIRS and SIRS. Unnecessary and poorly timed re-interventions may produce a “second hit” in a previously primed host.
- Fourth, we should deal promptly with ongoing infective (e.g. an abscess) and non-infective (e.g. necrotic tissue) sources of LIRS and SIRS.
- Fifth, we should attempt to preserve the integrity of the mucosal layer of the gut (through early enteral feeding) in order to prevent translocation of bacteria and endotoxin, which may contribute to SIRS, sepsis and MODS (⦿ Chap. 41).

— Sixth, we should minimize iatrogenic contributors to LIRS and SIRS. The patient must not be continuously injured and crucified in bed with indiscriminate insertion of catheters, tubes and pipes. Blood products may be harmful and should be used judiciously (🔍 Chap. 40). Antibiotics are a double-edged sword and may in fact increase SIRS by various mechanisms.

It is impossible to prove that each of the above measures decreases SIRS and MODS, but proper management as a whole is the mainstay of prevention of this “horror autotoxicus”.

Tertiary Peritonitis

In 🔍 Chap. 12 you were introduced to the concepts of peritoneal contamination and infection and the terms **primary and secondary peritonitis**. In 🔍 Chap. 46 you read: “When peritonitis persists despite adequate source control and repeated re-operations, think about *tertiary peritonitis*”. What’s that?

The aggressive supportive and operative measures discussed in the previous chapter allowed for the initial salvage of patients who previously would have succumbed early to uncontrolled secondary peritonitis. This success, however, created a new subgroup of patients. Let us take one as an example:

A 75-year-old male underwent an emergency subtotal colectomy with an ileorectal anastomosis for an obstructing carcinoma of the sigmoid colon (🔍 Chap. 25). Six days later he was rushed for a re-laparotomy because of diffuse peritonitis and a documented free anastomotic leak. At operation his abdomen was found to be full of fecal material. It was cleansed and the anastomosis was dismantled; the rectum was closed as in a Hartmann’s procedure and the ileum exteriorized as an end ileostomy. The abdomen was left open as a “laparostomy” (🔍 Chap. 46). During a planned relaparotomy 48 hours later residual collections of “thin” pus were evacuated. The patient continued to be “septic” and developed MODS. CT of the abdomen showed fluid in the pelvis and gutters; diagnostic aspiration revealed the presence of fungi. An antifungal agent was added to the wide spectrum antibiotics the patient was already receiving. He continued to deteriorate; a re-laparotomy disclosed a few hundred milliliters of murky peritoneal fluid, which grew *Candida* and *Staph. epidermidis*. The antibiotic regimen was changed. MODS worsened leading to the patient’s demise 5 weeks after the first operation. The hospital bill was \$250,000.

You have seen similar patients, eh? Probably one of them is now fading away in your ICU. The term *tertiary peritonitis* was coined to describe this situation, which develops late in the postoperative phase, manifests clinically as SIRS with MODS, and is associated with a peculiar peritoneal microbiology consisting of yeasts and other commensals. These organisms, normally of low virulence, probably act as a *marker* of tertiary peritonitis and not its *cause*. Their presence also reflects

the global immunodepression of the affected patient, allowing superinfection of the re-explored abdomen with organisms resistant to the antibiotic regimen he is receiving. Further antimicrobial administration and operative interventions are futile and may contribute to the peritoneal superinfection. The usually fatal outcome of tertiary peritonitis, which conceptually falls within the SIRS-MODS complex, indicates that current antibiotic-assisted, mechanical answers to severe peritonitis have about reached their limits, and the patient is unsalvageable.

“Our ingenuity in developing terminology exceeds our abilities to take care of these patients once they have developed the syndrome of MOF. The solution to MOF or MODS or SIRS is prevention.” (Arthur E. Baue)

We asked John Marshall of Toronto, who originated many of the terms described above, to tell us more on how to prevent and treat SIRS, MODS and tertiary peritonitis. [The Editors]

Invited Commentary

JOHN MARSHALL

The world of the critically ill surgical patient is a strange one. Its genesis lies in the performance of feats of surgical daring that were almost unimaginable even half a century ago, and its progress reflects the expression of processes that have no precedent in evolutionary biology. Could Halsted or Kocher have anticipated an age when surgeons would sew the liver of a cadaver into a patient dying of cirrhosis, or salvage a patient who presents in cardiac arrest from a gunshot wound to the heart? The leading surgical minds of their era spoke of “shock” because they believed that wounded patients died of an overwhelming sense of fear, and it was not until the early years of this century that Alfred Blalock refined this view, and showed that shock arose not from the brain, but from a lack of circulating volume within the vascular tree. He set the stage for a bold and unprecedented conceit – that the clinician, through the correction of acute physiologic derangements and the support of fundamental physiologic functions – could prevent, or at least forestall, the inevitability of death from acute life-threatening illness.

The late John Border (1926–1996), a trauma surgeon who contributed so much to contemporary views of the pathogenesis of critical illness, captured this conceptual advance by allusion to a classical motif from American cinema. The scene is a battlefield during an unnamed war. Surgeons are operating desperately to save the life of the shy and handsome, but somehow anonymous, soldier who has been wounded. The urgency of their mission is underlined by rapid cinematic cuts

between the surgeons, and the rubber bag that moves in and out as the patient inhales the ether that provides him with pain relief. The situation becomes desperate. Beads of sweat appear on the brows of the operating surgeon, and the movement of the anesthetic bag becomes shallow... then stops. The surgeons bow their heads, and the camera pulls back to show a silent medical team, lost against the sullen sky of the enveloping evening. And Border opines: "They didn't realize that all you have to do is to squeeze the bag."

We have squeezed the bag, and much more, and the author of this chapter has beautifully articulated the consequences of that squeezing. It is both incomprehensibly complex, and very simple; let me just underline a few of the principles that I hope you will retain from these discussions.

First, patients no longer die of their primary diseases; rather they die of their response to that disease. Shock kills not because of a deficit of circulating intravascular volume (a state that we can readily correct with intravenous fluids), but because of the biologic processes that are activated during reperfusion of ischemic tissues. Infection kills not because of uncontrolled proliferation of microorganisms (a process we can easily avert with source control measures and systemic antibiotics), but because the host responds to the infecting microorganism. This concept was beautifully demonstrated in an animal study performed more than two decades ago by Michalek et al. (1980). Two strains of mice, one known to be sensitive to endotoxin, and the other resistant because of a point mutation in a single gene, were irradiated and then given bone marrow transplants from the other strain. The lethality of endotoxin, a bacterial product, was transferred to the resistant-strain animals who received bone marrow cells from their sensitive relatives. In other words, the lethality of bacterial endotoxin is not an intrinsic property of the molecule, but rather a function of the fact that the host responds. It is not uncommon to see a critically ill, immunosuppressed patient who survives a life-threatening infection, only to become gravely ill as the immunosuppression abates, and he or she is able to respond to the infection.

An important corollary of this principle is that interventions against infection will not alter the course of a disease process whose pathophysiology reflects the response to infection. Stated differently, surgical source control and systemic antibiotics are anti-infective measures whose objective is to reduce the size of the microbial inoculum with which the host must contend. Their utility is critically dependent on establishing a diagnosis by demonstrating that a focus of infection, or uncontrolled microbial proliferation, is present, and it is incumbent upon the surgeon to demonstrate conclusively that such is the case, for antibiotics kill not only the organisms responsible for the infection, but also the normal colonizing flora of the host. In doing the latter, they facilitate colonization, and ultimately superinfection, by antibiotic-resistant organisms, a state that is epitomized by the phenomenon of tertiary peritonitis, described above.

Equally, the injury experienced by the critically ill surgical patient reflects not only what happened to him or her prior to arrival at the hospital, but also the intervention of the surgeon and other clinicians who provided care. Contemporary critical illness is an intrinsically iatrogenic disorder, for it only arises in patients who in the absence of medical intervention would have died, but its evolution reflects the inadvertent consequences of the interventions used to resuscitate the patient and to sustain life. The challenge we face as clinicians is to apply new technologies, but even more importantly, to recognize the potential adverse consequences of these, and to know when to back off.

Yet another concept intrinsic to this discussion is that the “syndromes” of critical illness are not well-defined pathologic entities, but rather metaphors for a process that we only dimly understand. For example, more than a decade ago a group of intensivists met to try to achieve consensus on the definition of sepsis (Bone et al. 1992). They coined the phrase “systemic inflammatory response syndrome” out of a desire to assert that the clinical syndrome of sepsis can arise in patients who are not infected, and to recognize that we did not have terminology to describe such a state. However, this concept does not necessarily define a syndrome, if by a syndrome we are referring to a constellation of signs and symptoms caused by a discrete pathologic process (Marshall 1999), and the criteria proposed to delineate that supposed syndrome were both arbitrary and highly non-specific (Vincent 1997). SIRS implies a response, and a relatively significant one at that, but its diagnostic import is nothing more than that the clinician should consider looking for a cause of that response (Marshall et al. 2000). The notion that there are other syndromes designated as CARS (compensatory anti-inflammatory response syndrome) or MARS (mixed acute response syndrome) (Bone 1996) similarly overstates our basic understanding and descriptive capacity. It is a biological truism that an acute inflammatory response entails the release of both pro- and anti-inflammatory mediators (and even this distinction is simply a matter of conceptual convenience for a human intellect that insists on categorizing), but it far oversteps current understanding to suggest that we can identify discrete syndromes, or clinical manifestations that point to a particular pattern of mediator response. SIRS and CARS are useful as concepts, but entirely unhelpful as patterns of clinical manifestations that might guide the care of a particular patient, or even shape the design of a clinical trial.

Finally, despite Dr. Schein’s admonition that “you didn’t want to learn about cytokines”, let me try to convince you that, although the inflammatory response is complex (and sufficiently complex that no one really understands it in a comprehensive way), its basic principles are not only straightforward, but seductively appealing. Inflammation is mediated primarily by the *innate* immune system, in

contradistinction to the *adaptive* immune system that includes T cells and B cells. Innate immunity is highly conserved through evolution; the same principles that regulate innate immunity in the Pope, also regulate innate immunity in fruit flies and sea slugs, so they have to be simple. The innate immune system evolved to recognize danger both from microorganisms in the environment, and from injured tissues in the host. Cells of the innate immune system – principally neutrophils and macrophages – recognize molecular patterns that signify danger, e.g. complex lipids and carbohydrates that are found in bacterial, but not mammalian, cells, or molecules such as heat shock proteins or RNA that are normally found within the cell. Recognition occurs through a family of ten receptors called toll-like receptors (“toll” is the German word for “cool” – nothing sophisticated here) that bind these substances, and, in doing so, activate a series of intracellular cascades that lead the cell to express genes that encode inflammatory mediators, two of the most important being tumor necrosis factor (TNF) and interleukin-1 (IL-1). These mediators too, can activate cells, leading to the release of a complex mélange of cytokines, prostaglandins, and reactive intermediates of oxygen and nitrogen, and triggering the coagulation cascade.

But let's return to the world of clinical reality. We don't need fully to understand the inflammatory process to recognize that we need to minimize exposure of the innate immune system to danger signals, whether by draining an abscess to reduce the bacterial load, providing rapid resuscitation to prevent tissue ischemic injury, or taking steps to limit iatrogenesis through keeping ventilatory volumes low, and minimizing unnecessary exposure to vasoactive drugs and antibiotics. **Good clinical care is grounded in common sense and carefully considered intervention, not in esoteric renderings of biology.**

References

- Bone RC (1996) Sir Isaac Newton, sepsis, SIRS, and CARS. *Crit Care Med* 24:1125–1128
- Bone RC, Balk RA, Cerra FB, Dellinger RP, Fein AM, Knaus WA et al. (1992) Definitions for sepsis and organ failure and guidelines for the use of innovative therapies in sepsis. The ACCP/SCCM Consensus Conference Committee. *Chest* 101:1644–1655
- Marshall JC (1999) Rethinking sepsis: From concepts to syndromes to diseases. *Sepsis* 3:5–10
- Marshall JC, Baue AE (2000) SIRS and MODS: What is their relevance to the science and practice of critical care? *Shock* 14:586–589
- Michalek SM, Moore RN, McGhee JR, Rosenstreich DL, Mergenhagen SE (1980) The primary role of lymphoreticular cells in the mediation of host responses to bacterial endotoxin. *J Infect Dis* 141:55–63
- Vincent JL (1997) Dear SIRS, I'm sorry to say that I don't like you. *Crit Care Med* 25:372–374

MOSHE SCHEIN

The fate of the surgical wound is sealed during the operation; almost nothing can be done after the operation to modify the wound's outcome.

A minor complication is one that happens to somebody else.

All that is visible to the patient of your wonderful, life saving, emergency abdominal operation is the surgical wound (● Fig. 49.1). Wound complications, although not life-threatening are an irritating source of painful morbidity, which bothers the patient and his surgeon alike. It is no wonder then that throughout generations, surgeons developed elaborate rituals to prevent and treat wound complications. Now that you are reading one of the last chapters of this book you are, hopefully, sufficiently brain-washed to deplore elaborate gimmicks, and to demand pragmatic solutions instead.




Fig. 49.1. “I hope you are satisfied with the beautiful wound, eh?”

Definitions and the Spectrum

For practical purposes you do not need complicated definitions used by epidemiologists or infection-control nurses – the (usually ugly) creatures who tell you not to walk out of the operating room with your scrubs on...

- An **uncomplicated** wound is a sutured wound that heals by primary intention and uneventfully. Note that following emergency abdominal surgery, an entirely uncomplicated wound is an exception! You don't believe us? Start to document from now on all your wounds and see for yourself the number of weeping or red-swollen wounds your patients have.

- **Complicated** wounds. Those are extremely common after emergency surgery when prospectively assessed by *independent* observers. Conversely, when “reported” by surgeons they become “rare” or “minor” due to our natural tendency to suppress or ignore adverse outcomes.

The **spectrum of wound complications** is wide and encompasses infective and non-infective complications, minor and major.

- **Minor complications** are those irritating aberrations in the process of healing that, however, do not impede primary healing of the wound: a tiny hematoma, a little painful erythema, some serous discharge. The distinction between an infectious and non-infectious process is difficult and also unnecessary: why take swab-cultures from such a wound if it will not affect therapy?

- **Major complications** are those that interfere with the process of primary healing and require your intervention: a large hematoma or a wound abscess in need of drainage.

- **Wound infection** – for practical purposes this is a wound that contains pus and requires drainage. Usually such an infection represents a “walled-off” wound abscess, with minimal involvement of adjacent soft tissues or underlying fascia. Rarely, surrounding cellulitis is significant or the deep fascia is involved, denoting a (deep) **invasive** infection.

Prevention

Surgical technique and overall patient care are of great importance in minimizing the incidence of wound infection. Rarely is one aspect of management of singular importance but it is the sum of the parts that yields favorable results. Emergency surgery is particularly associated with wound problems for several reasons. Contamination of the wound may arise from intestinal bacteria released at the time of bowel resection or from the organisms present in the established infection that the surgery was performed to treat (➤ Chap. 12). Additionally, there is insufficient

time to pre-operatively reverse all conditions which may adversely affect wound healing such as shock, diabetes and malnutrition (🔗 Chap. 6).

Evidence suggests that **tissue hypoxia, hypothermia and poorly controlled blood sugar** predispose to wound complications. Thus try – the best you can in the few hours you have (if any at all) before operation – to oxygenate the patient better (yes, give him that oxygen mask!), warm him up and administer insulin if necessary.

Although a certain rate of wound complications is obligatory and inherent in the nature of this type of surgery, you should strive to keep it as low as possible. How?

Let us reiterate here the above-mentioned aphorism: **“The fate of the surgical wound is sealed *during* the operation; almost nothing can be done after the operation to modify the wound’s outcome”**. Whether your patient develops a wound hematoma or infection depends on your patient and on you, and is determined during the operation – not afterwards. We quote Mark Ravitch again: **“The likelihood of wound infections has been determined by the time the last stitch is inserted in the wound.”**

Meticulous technique as described in 🔗 Chap. 38 is paramount. Here, a few preventive points are re-emphasized:

- Operate efficiently and carefully; avoid “masturbating” the tissues.
- Do not strangulate the fascia with interrupted-figure-of-eight sutures of wire, Ethibond or Vicryl; instead, use low-tension continuous spring like monofilament closure – letting the abdominal wall breathe (🔗 Chap. 38).
- Do not barbeque the skin and underlying tissues with excessive use of diathermy.
- Do not bury tons of highly irritating chromic (or anything else) in the subcutaneous fat.
- Do not close the skin with the even more noxious silk.
- Do not terminate contaminating colostomies in the main abdominal wound.
- Do not leave useless drains in the wound (or anywhere else). Don’t forget that drains increase the risk of wound infections.

Transfer your meticulous technique to the ward also. Nosocomial (hospital-acquired) infection is a menace to our patients. We have already mentioned the contribution that indiscriminate use of non-indicated antibiotics makes to the emergence of resistant organisms. The prevalence of these germs as colonizers of our patients is increasing, and spread from patient to patient is a major problem. Doctors are a major vector in this spread. Wash your hands every time you touch a patient. It seems astonishing that this message has to be repeated nowadays,

but studies have shown time and again that nurses are much more meticulous in their approach to this issue than MDs. This act of handwashing after each patient contact should be so ingrained that you have a sense of incompleteness until it is performed.

Antibiotics

Antibiotic prophylaxis reduces the wound infection rate; its anti-infective effects are in fact more pronounced in the surgical wound than within the peritoneal cavity (▶ Chap. 7). Intra-incisional antibiotics have an additional preventive role (⊙ Chap. 38); this makes sense if you consider that the wound's defense mechanisms are much weaker than those of the peritoneal cavity. Many years ago it was shown that systemic antibiotics are effective in preventing wound infections only if given within 3 hours of bacterial contamination – the “effective period”. **Post-operative antibiotics cannot change the fate of the wound**, as they won't penetrate the area. Despite what you have been told hitherto by your local infectious disease specialists or surgical “gurus”, adequate peri-operative antibiotic coverage is as effective in preventing wound infection as 7 days of post-op administration (⊙ Chap. 42).

Non-closure or Delayed Closure of the Wound

Leaving the skin and subcutis completely or partially open following contaminated or “dirty” procedures is still advocated by some “authorities”. True, it may prevent wound infection in the minority of patients who are bound to develop one. At the same time leaving these wounds open condemns the majority, whose wounds are destined to heal more or less uneventfully, to the morbidity of open wounds, the associated problems of management, and the risk of superinfection. Look at ▶ Chap. 38 for more details on this controversial issue.

Management

The Uncomplicated Wound

Throughout history surgeons were fascinated with the treatment of wounds because all they could do was to manage external post-traumatic wounds. For hundreds of years surgical leaders advocated simplicity in the management of wounds:

Felix Wurtz (1518–1574) wrote: “**Keep them as neat and clean as possible, and disturb them as little as you can; so far as may be practicable, exclude the air; favor healing under the scab; and... feed him as you would a women recovering from her confinement.**”

The great Joseph Lister (1827–1912) said: “**Skin is the best dressing.**” The renowned physician William Osler (1849–1919) maintained: “**Soap and water and common sense are the best disinfectants.**”

But most surgeons took literally the famous adage by Ambroise Paré (1510–1590): “**I dressed him and God healed him,**” and practice unnecessarily elaborate wound-management policies.

The uncomplicated primarily closed surgical wound needs almost no care. A day after the operation it is well sealed away from the external environment by a layer of fibrin. It can be left exposed. Isn't it ridiculous to see gloved and masked nurses changing sterile dressings on routine surgical wounds? Some patients demand their wounds be covered; cheap dry gauze is more than adequate for this purpose. The chief aim of elaborate “modern” dressing material such as antibiotic impregnated gauze is to enrich the medical-industrial complex. Patients with uncomplicated wounds can shower or bath any time.

The Complicated Wound

Here the punishment should fit the crime. Minor non-specific complications should be observed – the majority will resolve spontaneously. Again, starting antibiotics because a wound weeps a little serous discharge is not going to change anything; if the wound is destined to develop an infection it will, with or without antibiotics! Major wound hematomas require evacuation but this is extremely rare following abdominal surgery.

Wound Infections

Wound infection following an emergency abdominal operation is usually caused by endogenous bacteria – the resident bacteria of the abdominal organs breached during the operation or the bacteria which caused the intra-abdominal infection in the first place. Following non-contaminated operations (e.g., blunt splenic trauma) the bugs causing wound infections are exogenous-skin residents, usually a *Staphylococcus*.

A *Streptococcal* wound cellulitis may develop a day after the operation with pain, swelling and erythema and elevated temperature. This is mentioned in all textbooks but we have never seen one; we have also never met anyone who observed

such an early *Strep* wound infection. Wound infections also may present in your private office even weeks after the operation, skewing your hospital infection-control data (which are collected only to pay lip service to the administration's need to produce statistics). When in doubt, do not rush to poke in or open the wound – creating complications in wounds that would otherwise heal. Instead, be patient, wait a day or two, let the infection mature and declare itself.

Remember: a “hot red” surgical wound with surrounding erythema does not mean “cellulitis”. It means that there is pus within the wound that has to be drained. As a rule, removing a few skin sutures and draining the pus treats most wound infections. You do not need a CT scan to diagnose a wound infection (this is not a joke...this is what “modern medicine” is educating people to do). All you need is to remove a suture or two and probe the wound.

Aftercare

Aftercare should be simple. Shallow wounds are covered with dry gauze and cleaned twice daily with water and soap. There is nothing better for an open wound than a shower or bath! Deeper wounds are **loosely** packed with gauze to afford drainage and prevent premature closure of the superficial layers. Antibiotics are not necessary. Do you give antibiotics after the incision and drainage of a peri-anal abscess? Of course not. So why treat wound infections with antibiotics? A short course of antimicrobials is indicated when severe cellulitis is present or the abdominal fascia is involved, indicating invasive infection.

Wound swabs? Wound cultures? Gram stains? What for? As you know by now, the causative bacteria are predictable (👁 Chap. 12) and, besides, how could the microbiological results change the therapy outlined above?

Nurses and for-profit home-care agencies push elaborate and expensive wound care methods in order to justify their continued involvement. Local application of solutions or ointments of antiseptics or antibiotics destroy microorganisms and human cells alike, induce allergy and encourage bacterial resistance. **Expensive forms of wound coverage are a gimmick. Simple is beautiful. Use soap, water and did you ever try honey?**

“Dressings on undrained wounds serve only to hide the wound, interfere with examination, and to invite adhesive tape dermatitis.” (Mark M. Ravitch, 1910–1989)

“A surgeon should not wear a long tie that could dangle embarrassingly and dangerously down into a wound or incision while he leans over the patient.” (Francis D. Moore, 1913–2001)

Postoperative Bleeding

BARRY ARMSTRONG

*“The wounded surgeon plies the steel
That questions the distempered part;
Beneath the bleeding hands we feel
The sharp compassion of the healer’s art...”*
(East Coker, T.S. Eliot, 1888–1965)

Every stroke of the scalpel opens capillaries or larger vessels, shedding precious blood. Blood – the iconic image of surgery – is a sign of the surgical sacrifice made by the patient through the ministration of the surgeon. This sacrifice has an inverse benefit – **the greater the bloodshed, the worse will be the outcome**. The scalpel’s bloody harvest must be limited by the joint action of the surgeon’s technique and the patient’s natural hemostasis. This interplay of patient factors and surgical technique determines the amount of bleeding during and after surgery. If the patient’s hemostasis is weak, then the surgical control of bleeding must be “strong” and complete.

Bleeding complications are responsible for at least a tenth of surgical deaths. They usually occur in trauma patients, but few types of operations escape the occasional complication due to a postoperative bleed. The bleeding may have started before the operation or during the operation, or it may have commenced following the procedure.

Whenever natural hemostasis fails, the surgeon eventually learns about the hematoma, a falling blood count, or unexpected shock. Depending upon the size of the bleeding vessel, the quality of the nursing care and the cooperation of the patient, things might deteriorate slightly or seriously, before the surgeon is called. Detecting bleeding and notifying the surgeon is one of the key functions of postoperative nursing care.

Bleeding in the first day or two after surgery is called “*reactionary hemorrhage*”. If the hemostasis was good when the wound was closed then this reactionary bleeding is due to a displaced or lysed clot, a failed suture or a slipped clip. But in truth, in many instances it represents continued oozing that started during the operation.

“*Secondary hemorrhage*” arises more than a week after surgery. This is usually associated with an infection or inflammatory process. An example would be bleeding from the pancreatic bed after necrosectomy for infected pancreatic necrosis (🔗 Chap. 18).

Table 50.1. The 12 Ps of surgical hemostasis: what to do if the patient is still bleeding? (Developed by Ahmad Assalia)

First	Then consider
Apply PRESSURE... with PACKS or PADS Have PATIENCE Suture with PROLENE (or whatever)	Giving PLATELETS, Fresh frozen PLASMA, PROTAMINE (to reverse heparin), and PACKED CELLS (if still bleeding) Call PROFESSOR for help... If he can't help – PRAY... ...that you will not meet your patient at the POSTMORTEM

Preventing Hematomas and Postoperative Bleeding

- Technical factors: check the wound hemostasis after opening. Major “pumpers” are controlled as they are encountered. Minor bleeders and ooze should stop spontaneously. Remember that natural hemostasis of minor bleeders (“bleeding time”) takes about 5–7 minutes. Double-check wound hemostasis in mid-operation and at closing. Don't let your assistant wipe the wound with a sponge since this may strip away the beneficial platelet plugs. Teach him to gently daub at bleeders, rather than wiping.
- Patient factors: you surely do not want us to bore you with yet another lecture on hemostasis. So just remember the 12 Ps – a mnemonic that may help your patient clot and prevent him from bleeding – presented in [Table 50.1](#).

For details on coagulation testing log on to: <http://www.anaesthetist.com/icu/organs/blood/test.htm>

Postoperative Wound Hematomas

The most important clotting factor is the surgeon.

Fallacy 1: “The wound was dry when we closed.” (👉 Fig. 50.1)

Fact: Careful surgical technique will minimize the risk of post-op bleeding. A single look, as the abdomen is closed, may miss an important bleeder that is temporarily in spasm. Hypotension, surgical retractors and/or a pressurized pneumoperitoneum can also mask bleeders. The wise surgeon will check for hemostasis a few times over the last 10–15 minutes of the operation. He will relax the pneumoperitoneum or reposition the retractors and sponges to spot hidden bleeders.

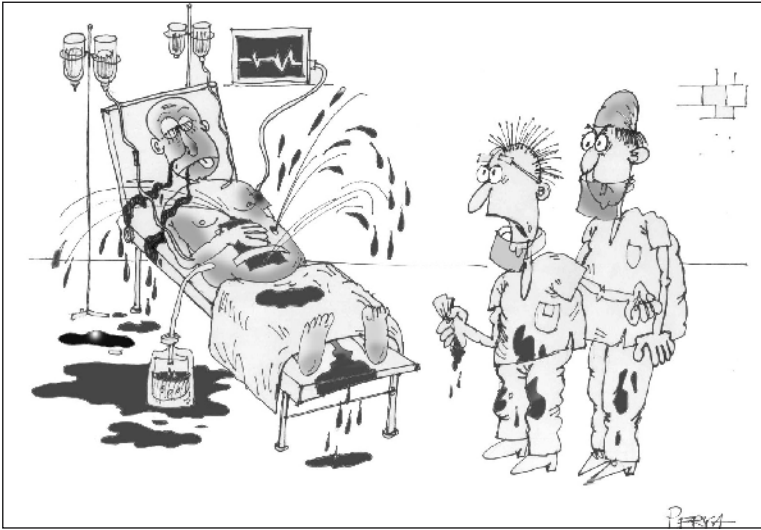


Fig. 50.1. “When we closed it was dry...”

If postoperative **wound** bleeding continues despite local pressure, then the wound should be re-explored. Often this can be done with local anesthetic using sterile technique in a well-lit minor-surgery room, evacuating clots and controlling the bleeding points. Give a dose of intravenous prophylactic antibiotic first, as re-exploration for bleeding boosts the risk of infection. But if you think the wound hematoma arises from a major vessel, a return to the operating room will be best. For example, a rapidly expanding hematoma at the epigastric trocar site after laparoscopic cholecystectomy typically originates from an injured inferior epigastric artery. Awaiting natural hemostasis of the inferior epigastric will usually not kill your patient, but it will result in a large, uncomfortable and ugly hematoma and bruise, which will take weeks to subside.

Postoperative Abdominal Bleeding

The three words most often associated with re-operation for hemorrhage are: “It will stop.”

Fallacy 2: If the patient is bleeding and hypotensive, then you should start two large-bore IVs, and give Ringer’s lactate quickly, at least 2 l.

Fact: evidence of the truth is mounting – vigorous fluid resuscitation might restore blood pressure and pulse, but mortality and morbidity are increased. In the

presence of uncontrolled bleeding, rapid fluid resuscitation will dilute clotting factors, increase the rate of blood flow from an actively bleeding site and can “pop the clot” (Ken Mattox), opening new bleeders. Animal and human data show the benefits of restricting intravenous fluids when there is uncontrolled bleeding.

Permissive hypotension and small volume intravenous therapy is the best strategy for supporting the patient’s hemostatic mechanisms.

While any bleeding from or into a superficial surgical wound is obvious to the eye, postoperative bleeding into the abdominal cavity is “hidden” and, thus, more difficult to diagnose. Postoperative abdominal bleeding represents an *iatrogenic surgical trauma* posing diagnostic and therapeutic considerations not dissimilar from those arising in the management of penetrating and blunt abdominal trauma (Chaps. 34 and 35).

— **Is the patient bleeding into the abdomen?** Tachycardia, hypotension, confusion, sweating, increased pain in the incision or the abdomen, abdominal distension, oliguria, dropping hematocrit, or a positive bedside ultrasound scan are usually diagnostic. Remember, however, that hypotension after surgery is not always due to blood loss. The persisting effects of anesthetics and narcotics may cause the blood pressure to drop. Postoperative epidural pain relief is a common cause of hypotension but beware of missing hemorrhage in this situation. Fluid resuscitation during the first operation may have been inadequate to compensate for the fluid losses and “third space” sequestration. The patient may have lost fluids from diarrhea or vomiting. In the elderly, or those chronically taking steroids, an Addisonian crisis may provoke hypotension with a rapid response to corticosteroids.

— **Should I rush him to the OR?** With profound shock and full blown abdominal compartment syndrome caused by the expanding hemoperitoneum you should run to the operating room and open the abdomen. Otherwise, think about the following steps.

— **Should I image the abdomen?** In a stable patient CT scan would confirm the size of the hematoma (e.g. in the gallbladder bed) and help estimate the volume of the hemoperitoneum. As the case with blunt abdominal trauma CT diagnosis and follow-up would allow safe non-operative management. A CT “blush” – extravasating contrast – may mark the source of active bleeding. In specific situations (e.g. after operations for hepatic trauma) *angiography* could localize and treat the bleeding.

— **Should I treat the patient non-operatively?** Today, with most blunt abdominal trauma patients managed successfully without an operation we tend to apply the lessons learned to the postoperative abdominal bleeders. Patients who *continue* to exhibit signs of hypovolemia after “gentle” resuscitation should be returned to the operating room. Also, you should avoid the old dogma of treating hemoperitoneum by tamponade, waiting for the intraperitoneal pressure to exceed that of the bleed-

ing source. Such outdated practice will only produce abdominal compartment syndrome necessitating abdominal decompression. Stable patients could be watched under close hemodynamic observation and with serial measurement of their hematocrit. The initial need for blood transfusions is not a contra-indication to conservative approach; we seldom know how much of the hemoglobin was shed during the operation and how much after – and how much of the drop is caused by hemodilution.

— **Is my conservative approach failing?** Continuing blood loss reflected by the need for more blood would indicate that the conservative approach has failed. *Continued* transfusion is associated with increased mortality, more infections, and increased length of stay – independent of the severity of shock. In patients who cannot be transfused because of religious objections (Jehovah Witnesses) consider more liberal indications for radiologic or surgical intervention. Also, be quicker to intervene in pregnant patients, since even early and mild maternal shock can cause uteroplacental vasoconstriction and severe fetal shock.

— **Is it safe to leave a large hematoma or blood clots within the abdomen?** Surely it is better to have a perfectly clean abdomen than blood and its products of degradation floating around? And of course, blood and its metabolizing hemoglobin offer a perfect breeding ground for abscess-forming bacteria. Moreover, the by-products of old blood have been shown to contribute to the systemic inflammatory response syndrome (SIRS; ● Chap. 48). Re-laparotomy, on the other hand, is associated with its own early and late morbidity (and mortality). While it is the perfect tool to stop the hemorrhage from an actively bleeding artery, it may only increase generalized surface oozing associated with coagulopathy. Remember that large residuals clots can be washed and removed by an elective laparoscopy days after the bleeding has stopped.

— **Is my patient clotting adequately?** This should be one of your concerns irrespective whether you decide to wait or to operate. Severe acquired coagulopathy may develop intra-operatively or in the immediate post-op period. This “disseminated intravascular coagulation” (DIC) syndrome is secondary to a serious insult, such as sepsis, embolism of air, fat or amniotic fluid, shock, blood transfusion mismatch, extensive cancer, or severe trauma. Recovery requires rapid correction of the primary cause and treatment of the coagulopathy that is consuming both the platelets and coagulation factors, and destroying fibrin and fibrinogen through fibrinolysis. Multiple component blood therapy will be needed, and possibly specialized treatment such as recombinant activated factor VII. Platelet transfusions may be useful when the absolute platelet count is <50,000 and the patient is bleeding. Alert the blood bank immediately and consider hematology consultation, if there is DIC.

— **Consider the specific index operation.** You did the first operation so you are the one to know best what went – or could go – wrong. Factor it into your decision-making.

Life-Threatening Abdominal Bleeding

“Bleeding started in the rectal area and continued all the way to Los Angeles.”
(A patient chart, reproduced in *Details in Professional Liability*, January 27, 1999)

When a patient is compensating for blood loss his blood pressure may be a third below normal but central organs remain perfused. He is awake and cooperative, making 0.5 ml/kg urine each hour and has palpable pulses in the wrists and ankles. However, ongoing hemorrhage or sudden severe bleeding can overwhelm such a steady state. The history (e.g. soaked bed sheets or bandages, a “bloody” primary operation) combined with physical findings will tell you that you must intervene urgently.

Medical hemostasis through rapid correction of coagulation abnormalities is useful, but mechanical hemostasis is critical in this urgent situation. Re-intervention for mechanical hemostasis usually means a re-laparotomy but could selectively (in a stable patient) be accomplished laparoscopically, through gastrointestinal endoscopy or by the interventional radiologist.

Re-laparotomy for Hemorrhage

In the operating room, you will want as many “aces” in your hand as possible. These multiple options will increase your confidence as you answer the question, “What practice will stop the hemorrhage?”

- Until now you restricted volume resuscitation and allowed permissive hypotension. Now, immediately before induction of anesthesia hypovolemia must be aggressively corrected to avoid cardiovascular collapse. Such a collapse is often caused by sudden decrease in peripheral resistance – a result of muscle paralyzing agents and sudden decompression of high intra-abdominal pressure – leading to peripheral pooling and decreased venous return.

- You will want an adequate blood bank, a capable anesthetist, the means to keep the patient warm during surgery, good assistants (including a senior colleague), adequate lighting (consider extra lamps or headlights), good retraction and visualization (possibly magnification or video-laparoscopy) to allow for rapid exposure of the bleeding site, plus dissection of any major bleeding vessel with proximal and distal control.

- Prepare your equipment. Mechanical hemostasis at re-operation might mean the surgeon’s pinching finger, sutures, staples, clips, electrocautery (bipolar or monopolar with or without autologous muscle fragment “welding” for retroperitoneal venous oozing), ultrasonic energy, laser, argon-beam, heat-gun, proximal vessel ligation, injection sclerotherapy, or the application of topical hemostatic

agents (gauze packs, sponge balls, gelatin foam, cellulose pads, collagen fleece, topical thrombin, or fibrin sealants). Omentoplasty has been used to cover diffusely oozing surfaces, but topical energy or hemostatic agents can be effective.

If the bleeding has been heavy, you should consider harvesting the shed blood for *autologous autotransfusion*.

Often, the emergency nature of the procedure and the serious state of the patient will have you and the team on edge. The wise surgeon will tell a little humorous personal story or a non-offensive joke to relax the team. This breaks the emotional ice and will often increase the effectiveness of your team's performance.

Patience is required in order not to damage adjacent structures and also to arrest the hemorrhage. We were educated on the story of a famous British surgeon who was called to operate on a patient who bled after cholecystectomy. At surgery a large “pumper” – probably the stump of the cystic artery – was visualized in the depths of the triangle of Calot. The surgeon did not rush to apply clamps endangering the nearby bile duct. Instead he calmly placed a large gauze pack into the gallbladder bed and said: “Chaps, I am leaving for a cup of tea. Call me in 30 minutes.” When he returned everything was dry. [The Editors]

Most probably the source of blood will be what you expected it to be – something at the site of your previous butchery. If this is not the case, search elsewhere; pulling on the omentum during colectomy may have torn the spleen, retracting on the liver to expose the duodenum may have damaged it, eviscerating edematous small bowel may tear its mesentery and so forth. It is not unusual, though somewhat disconcerting, to find at exploration only blood clots with no evidence of the actual source of bleeding – by now contracted and thrombosed.

Most sources of bleeding will be controlled by the basic Ps (see Table 50.1). If not, try one of the hemostatic gimmicks available to you. Make yourself familiar with “speciality maneuvers” (e.g., use of thumb tacks to control pre-sacral bleeding). **And do not forget the principles of “damage control” you learned in trauma (▶ Chap. 35): do not hesitate to pack stubborn surface ooze or venous bleeding and come back another day (or after a cup of tea!).**

“The only weapon with which the unconscious patient can immediately retaliate upon the incompetent surgeon is hemorrhage.” (William Stewart Halsted, 1852–1922)

PIOTER GORECKI

The world might look brighter through the (laparoscopic) camera – but not everything bright is gold.

Laparoscopic options were mentioned *en passant* in the preceding chapters but a promise was made to elaborate further on the role of laparoscopy in abdominal emergencies. To do so we had to summon help from a surgeon who is more enthusiastic than we are. [The Editors]

Key Points

- Laparoscopic evaluation of the peritoneal cavity enables magnified visualization of peritoneum and intra-abdominal organs with less tissue trauma than with laparotomy.
- Laparoscopy detects the presence of pus, feces, bile or blood (facilitating the detection of the source of intra-abdominal pathology) and estimates its severity.
- Whether the therapeutic procedure is laparoscopic or conventional depends on the findings, the patient's condition, and the complexity of the planned procedure.
- Advantages of laparoscopy compared to laparotomy are: reduced peri-operative pain, shorter hospital stay, quicker recovery and decreased wound complications such as wound infection and incisional hernias. In addition, laparoscopic procedures result in improved cosmesis and greater patient satisfaction.

Overview

Diagnostic laparoscopy was used for many decades by gynecologists to investigate acute pelvic disorders. In light of the recent boom in basic and advanced laparoscopic techniques it is no wonder that enthusiasts started to explore the role of laparoscopy in the diagnosis and treatment of almost any abdominal emergency.

Table 51.1. Laparoscopic applications in emergency abdominal surgery. Numbers in parentheses refer to the chapters dealing with the topic

Clear indications for laparoscopy	Potential and controversial indications for laparoscopy	Contra-indications to laparoscopy
Acute cholecystitis (19)	Perforated diverticulitis (27)	Unstable patient
Acute appendicitis (28)	Colonoscopic perforation (30)	Presence of abdominal hypertension
Perforated ulcer (17)	Intestinal obstruction (21)	Severe established peritonitis
Diagnostic laparoscopy in acute pain of unknown etiology	Intestinal ischemia (23)	Lack of experience
Acute gynecological pathology (31)	Acute abdominal pain in a pregnant patient (31)	Elevated ICP (head trauma patient)
Thoraco-abdominal trauma in stable patient (to evaluate diaphragmatic integrity) (34)	Second look laparoscopy (46) Bleeding peptic ulcer (16) Drainage of intra-abdominal abscess (44) Rule out intra-abdominal source of sepsis in ICU patient (46) Diagnostic laparoscopy in stable trauma patient with no urgent indications for laparotomy (34 & 35)	

ICU intensive care unit; ICP intracranial pressure.

The rationale is simple – laparoscopy may offer an organ-specific diagnosis and, at the same time, provide treatment, thereby avoiding the need for laparotomy. This would minimize morbidity and patient discomfort, shorten the hospital stay, accelerate recovery, and improve patient satisfaction.

Laparoscopy has been used in both acute non-traumatic and traumatic abdominal situations. Master laparoscopists – great aficionados – claim to be able to do “anything” through the laparoscope. Our conservationists [Dr. Gorecki probably refers to us. – The Editors], on the other hand, almost totally reject laparoscopy, ex-

cept perhaps for very selected indications – such as acute cholecystitis (◉ Chap. 19), acute appendicitis (◉ Chap. 28), gynecological emergencies (◉ Chap. 31) and left thoraco-abdominal trauma (◉ Chap. 34). The following, we hope, is an enlightened and modern but balanced view.

◉ Table 51.1 provides an overview of possible laparoscopic applications in emergency abdominal surgery

Non-traumatic Abdominal Emergencies

Let us start by emphasizing that laparoscopy is absolutely contraindicated in critically ill hemodynamically unstable patients. Simply put, laparoscopy takes more time, and in severely compromised patients you need to find the source of the problem and deal with it immediately. In addition, pneumoperitoneum elevates intra-abdominal pressure, which is deleterious in unstable, “septic” and ill patients, as discussed also in ◉ Chap. 36. A sure way to induce a cardiac arrest would be to take a hypovolemic patient, anesthetize him, and then pump up his abdomen with gas (CO₂).

Laparoscopy can be performed either as part of a diagnostic process, or as a therapeutic procedure, or both. Its application and availability largely depend on the surgeon’s experience and prompt access to laparoscopic instrumentation. Diagnostic laparoscopy (DL) can be performed expeditiously and even outside the operating room – in the emergency room or surgical intensive care unit – and under local anesthesia. The morbidity from negative DL, as compared to a negative or non-therapeutic laparotomy is reduced. The use of mini-laparoscopy (instruments smaller than 3 mm in diameter) is gaining popularity and may further diminish the morbidity of the procedure.

DL assesses the presence and amount of intraperitoneal blood, bowel contents or pus, and establishes its source. A decision is then made whether control of the source is necessary, and if it is, whether to do so via laparoscopy or laparotomy (see ◉ Fig 51.1).

Editorial Comment

The role of laparoscopy in the diagnosis and treatment of non-traumatic abdominal emergencies is evolving. So far, it has reached wide acceptance in acute cholecystitis and gynecological conditions. There is some rationale to embark on laparoscopy when the source of right lower quadrant pain is questionable – especially in a female patient. However, in most of these patients rational use of abdominal imaging establishes the diagnosis without resorting to laparoscopy, which can be viewed as “controlled penetrating abdominal trauma.” As to diagnostic laparoscopy under *local anesthesia* – we would wish such an experience only on our enemies.

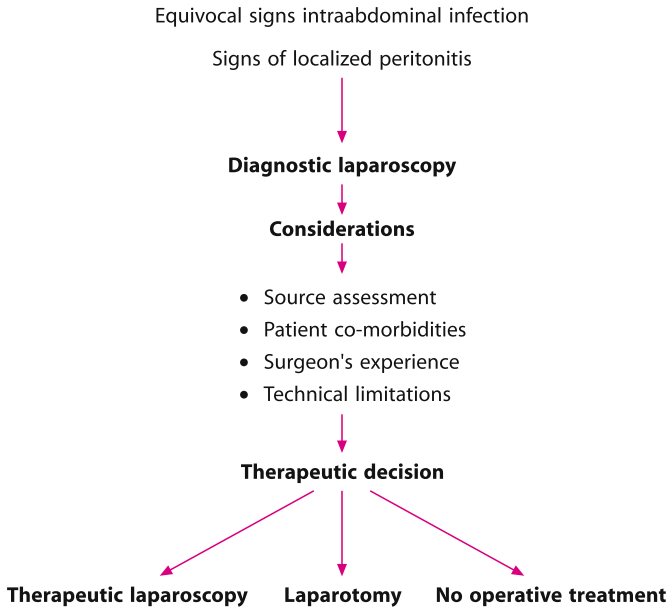


Fig. 51.1. Laparoscopy in abdominal emergency – decision making algorithm

Many surgeons do favor laparoscopic appendectomy; however, its benefits are marginal. “Lap-appy”, though, may be an attractive alternative in the very obese patient, significantly reducing the wound complications. In order to be able to tackle confidently other conditions through the laparoscope you must be able to explore laparoscopically the various spaces and corners of the peritoneal cavity. You must be skilled in advanced laparoscopic and intracorporeal suturing techniques if you wish to deal with more complicated situations such as perforated peptic ulcer.

Remember: The acutely ill patient is in desperate need of immediate intervention. The sicker the patient, the more diffuse his peritonitis – the less suitable a candidate he is for your magic lenses and trocars. Be selective and use your best judgment.

Laparoscopy for Abdominal Trauma

You may remember that in [Chaps. 34 and 35](#) the author was not too keen on the role of laparoscopy in the trauma patient. Let us hear, however, the siren song of the enthusiast ([Fig. 51.2](#)). – The Editors

[Fig. 51.3](#) shows the potential applications for laparoscopy in trauma.



Fig. 51.2. “I love to play with it!”

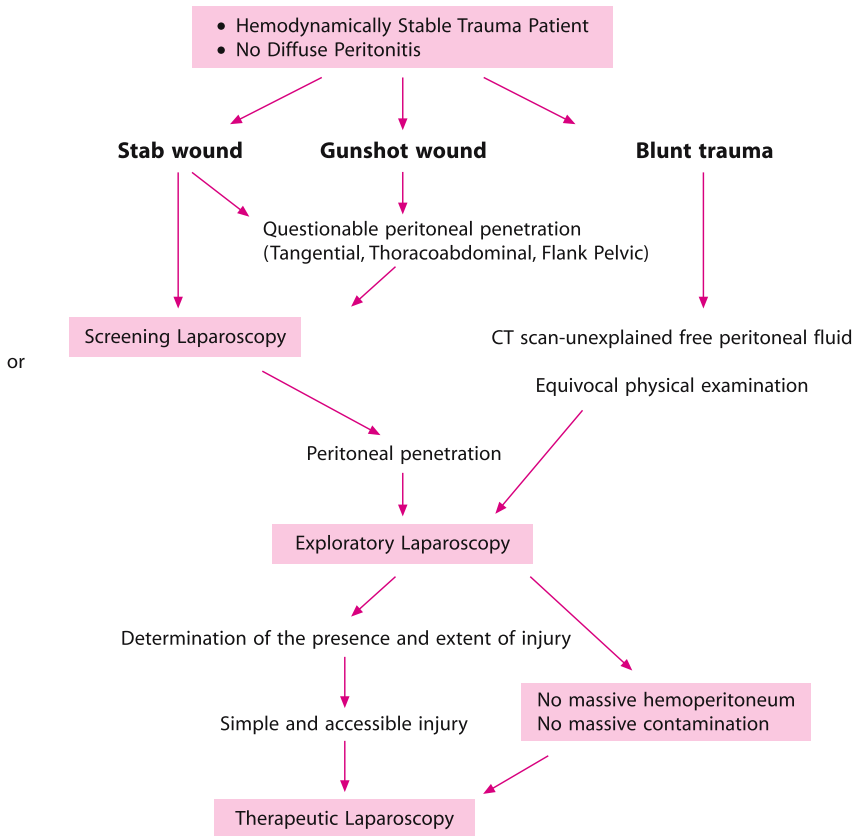


Fig. 51.3. Potential applications for laparoscopy in trauma

Blunt Trauma

Management decisions in blunt abdominal trauma are based on the patient's hemodynamic status and physical findings, and the selective and complementary use of diagnostic ultrasonography, CT, and diagnostic peritoneal lavage (DPL). So where does laparoscopy fit in?

Its main role is to assist in the avoidance of non-therapeutic laparotomy, thereby reducing postoperative morbidity and hospital stay. But first, let's recall the contraindications: *laparoscopy should be performed only in the hemodynamically stable patient with no urgent indication for laparotomy.*

The good candidate for DL is a stable patient with equivocal findings on physical examination, CT or DPL. DL can achieve organ specific diagnosis, identify and quantify the presence of peritoneal blood, bile or intestinal content, grade the severity of injury to the liver and spleen, assess whether there is active bleeding and its rate, and rule out diaphragmatic injury. In selected patients with minimal injury laparoscopy may become therapeutic, for example, evacuating blood or achieving hemostasis of a small hepatic tear.

Penetrating Trauma

— *Stab wounds*: patients with clinical indications for a laparotomy, e.g., peritonitis or shock should be managed with immediate laparotomy. DL has a potential role when clinical findings are equivocal, and especially in thoracoabdominal wounds, to rule out diaphragmatic penetration. Laparoscopy may become therapeutic when injury is minimal.

— *Gunshot wounds (GSW)*: The vast majority of the GSW are managed with immediate laparotomy. However, a few patients with stable vital signs and no peritonitis are candidates for DL to exclude abdominal penetration or prove that the injury is minimal and does not require laparotomy. Again, with thoracoabdominal GSW diaphragmatic injury has to be excluded.

Editorial Comment

“Selective conservatism” based on clinical assessment (↻ Chap. 34) is a well-tested, safe and cheap approach in patients with stab wounds to the abdomen. The advantages of performing invasive DL in such patients is unsubstantiated and difficult to justify. True, there are instances where DL is the most sensitive method to diagnose an occult penetration of the left diaphragm, which is commonly associated with left thoracoabdominal wounds, but the natural history of this entity,

if left untreated, is unknown. With gunshot wounds, selective conservatism is also possible in the minority of patients but adopted reluctantly by surgeons. In stable patients with borderline abdominal signs however, DL may prove that the GSW was extra-peritoneal-tangential.

A crucial limitation of laparoscopy is that it cannot adequately assess retro-peritoneal structures such as the colon, duodenum, kidneys and vessels. It confirms or excludes peritoneal penetration but in terms of assessing damage a CT is more sensitive and less invasive. Be aware of the risk of tension pneumothorax when performing a DL in patient with diaphragmatic penetration. Deflating the pneumoperitoneum and the insertion of a chest tube can reverse it. Gas embolism is a potential complication when major venous injuries are present but as our expert points out, it has never been reported after thousands of cases. It appears that the role of laparoscopy in the injured patient is limited, but laparoscopic aficionados claim that growing experience and developing instrumentation will expand its role in the future.

“We are looking at a glass of beer. Open surgery is the beer; laparoscopy is the foam.” (Herand Abcarian)

Technical Considerations

The patient is placed on the operating table in a supine position and general endotracheal anesthesia is given. If no abdominal distention or previous operation is evident, a Veres needle is inserted in the umbilicus and pneumoperitoneum is obtained. A 5-mm 30-degree angled laparoscope is introduced via a 5-mm umbilical port. An initial brief visualization of the peritoneal cavity is done to rule out massive hemoperitoneum or obvious complex injuries. Two other 5-mm ports are placed in the right upper and left lower paramedian sites as shown (● Fig. 51.4).

The surgeon's initial position is on the patient's left side with the patient in the Trendelenburg tilt, which allows inspection of the pelvic structures, rectosigmoid, urinary bladder, both groins and the iliac regions (● Fig. 51.5). Subsequently the ileocecal junction is identified and the right colon is inspected. Complete inspection of the small bowel is performed utilizing a “hand-to-hand” technique to run the bowel with a pair of atraumatic bowel graspers from the ileocecal valve to the middle of its length. “Flipping” the bowel back and forth as it is run proximally permits visualization of both mesenteric surfaces of each inspected segment (● Fig. 51.6). The surgeon then changes his position to the patient's right to facilitate inspection of the small bowel from its middle length to the ligament of Treitz (● Fig. 51.7). The descending colon is also inspected from this position. Tilting the table laterally improves visualization of the flanks and mobilization of the colon as needed for

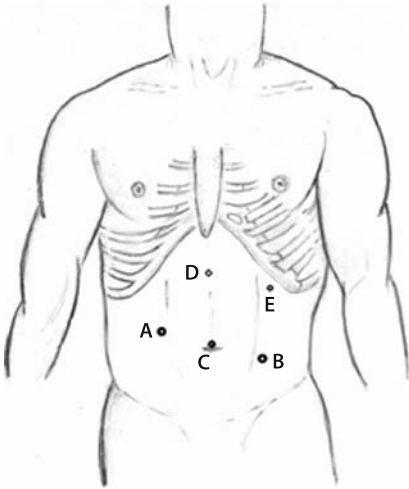


Fig. 51.4. Position of trocars during exploratory laparoscopy. *A,B* operative ports, *C* camera, *D,E* optional trochars facilitating exploration and therapeutic interventions in the upper abdomen

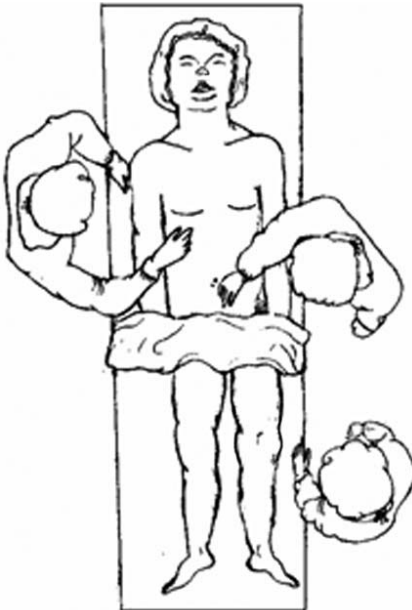


Fig. 51.5. Patient in the Trendelenburg position. Surgeon on the patient's left. Exploration of the pelvis, right colon and small bowel from the ileocecal valve to mid-jejunum is performed

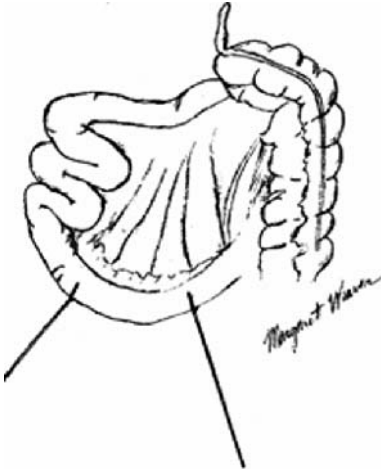


Fig. 51.6. Bowel is run in a “hand-to-hand” fashion. “Flipping” the segments of the intestine back and forth as it is run towards the ligament of Treitz allows the inspection of both sides of the bowel with its mesentery

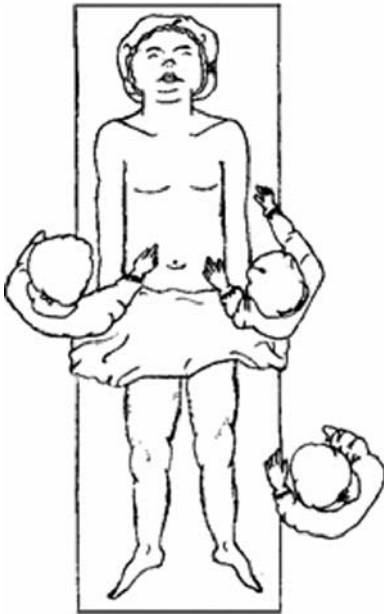


Fig. 51.7. Patient in the reversed Trendelenburg position. The surgeon on the patient’s right. Inspection of the small bowel (from mid-jejunum to the ligament of Treitz), spleen, liver, stomach, diaphragm, transverse, and left colon. The addition of two other ports in the upper abdomen facilitates exploration of the diaphragm, proximal stomach and lesser sac

complete exploration. Rotating the table into reversed Trendelenburg position allows easy access to the upper abdomen, the diaphragm, the spleen, the stomach, both lobes of the liver, and the transverse colon with its flexures. Inspection of the area of the gastroesophageal junction, posterior wall of the stomach and the lesser sac including the pancreas requires placement of two additional ports for retraction and grasping by the assistant surgeon (◉ Fig. 51.4). If no complex injuries are found and hemodynamic stability is assured, a focused therapeutic laparoscopy can follow or a strategically placed incision can be made depending on the nature of the injury and the surgeon's experience in advanced laparoscopic techniques.

Know your limitations and do not compromise the principles of exploration for trauma.

— “If you are too fond of new remedies, first you will not cure your patients; secondly, you will have no patients to cure.” (Astley Paston Cooper, 1768–1841)

In the Aftermath and the M & M Meeting

MOSHE SCHEIN

A 'big' operation in a fit patient may be 'small'

A 'small' operation in a sick patient may be 'big'

A 'big' surgeon knows to tailor the operation and its trauma to the patient and his disease

"Again and again I find that there are few things so quickly forgotten by the surgical system as a dead patient." (P.O. Nyström)

Let us hope that your patient survives his emergency abdominal operation and his postoperative course is uneventful. Unfortunately, the overall mortality of such procedures is still far from negligible and the morbidity rate is generally high. Now, after the storm has abated, it is the time to sit down and reflect on what went wrong. As Francis D. Moore (1913–2001) said: **"You want a surgical team that faces each error, each mishap, straight up, names it, and takes steps to prevent its recurrence."**

The Mortality & Morbidly Meeting

At any place where a group of surgeons is working it is crucial to conduct a regular M & M Meeting (MMM). This is the venue where you and your colleagues should *objectively* analyze and discuss – in retrospect – all the recent mortalities and complications. You are familiar with the cliché that "some surgeons learn from their own mistakes, some learn from those of others, and some never learn". The aim of the MMM is to abolish the last entity.

Do you have a regular M & M meeting in your department? If you are associated, as a resident or a qualified surgeon, with a teaching department in the USA, you must have a weekly MMM, because without a routine MMM the department's residency program cannot be accredited. We know that in many corners around the world MMMs are not conducted; all blunders and failures are swept under the carpet. Elsewhere still, MMMs are conducted in name only, being used to present "interesting cases" or the latest "success stories". This is wrong. The MMM exists to analyze objectively your mistakes and complications, not to punish or humiliate anyone, but to educate and improve results. You do not want to repeat the same error twice. See to it that proper MMMs are conducted wherever you provide surgical care.

Optimal Format for the MMM

- A routine hour should be dedicated to the MMM each week.
- ALL interns, residents and surgeons should attend – regularly.
- ALL complications and deaths that occurred in any patient treated by any member of the department should be presented.
- “A complication is a complication” – irrespective of whether the outcome was a triumph or tragedy. All must be presented.
- The MMM is a democratic forum. The boss’s blunder or that goof by the “local giant” is as “interesting”, if not more so, as that caused by a junior resident.

The resident-team that was involved with the case should present it. They should know all details and rehearse the presentation in advance. The patient’s chart and X-rays should be readily available. If you are the presenting resident, be objective and neutral. Your task is to learn and facilitate the learning of others, not to defend or cover up for the involved surgeon; you are not his or her lawyer. Understand that the majority of those who are present are not stupid – they sense immediately when truth is deserted.

The Assessment of Complications

After the case has been presented, the person who presides over the meeting has to initiate and generate a discussion with the intent of arriving at a consensus. An easy way to break the commonly prevailing and embarrassing silence is to point at one of the senior surgeons and ask “Dr. X, please tell us, had this patient been under *your* care from the beginning, would the outcome be the same?” This technique usually manages to break the ice, prompting a sincere and complete response.

The questions to be answered during the discussion are:

- **Was it a “real complication”?** Some surgeons may argue that blood loss, which required transfusion, is not a complication but a technical mishap, which simply “can happen”.
- **Assess the cause:** was it an error of **judgment** or a **technical** error? Operating on a dying terminal cancer patient reflects poor judgment; having to re-operate for hemorrhage from the gallbladder’s bed marks a technical error – poor hemostasis at the first operation. **The two types of errors are often combined and inseparable**, the patient with acute bowel ischemia died because his operation was “too late” (poor judgment) and the stoma, which was performed, has retracted, leaking into the peritoneal cavity (poor technique). Often it is impossible to define whether a “technical complication” (e.g. anastomotic leak) is caused by poor technique (technical error) or patient-related factors, such as malnutrition or chronic steroid intake.

— Another possibility is to look at the error as either an error of **commission** or **omission**. One either operates too late or not at all (**omission**) or operates too early or unnecessarily (**commission**). One either misses the injury or resects too little (**omission**) or does too much (**commission**). After the operation one either fails to re-operate for the abscess (**omission**) or operates unnecessarily when percutaneous drainage was possible (**commission**). Note that the surgical community considers errors of omission more gravely than those of commission; the latter are looked at with understanding: “we did all we could but we failed”.

— **Was there negligence? A certain rate of mistakes (hopefully low) is an integral part of any surgical practice as only those who never operate commit no errors, but negligence is deplorable.** The operation was delayed because the responsible surgeon did not want to be disturbed over the weekend or the surgeon operated under influence of alcohol; this is clearly “negligence”. When an individual surgeon repeats errors over and over again, a *paradigm* is exhibited, which in itself may constitute negligence.

— **Was the complication/death preventable or potentially preventable?** We encourage our residents to report the physiologic score of acute disease – APACHE II (◊ Chap. 6) of the presented patient. Low pre-operative scores (e.g., below 10) mean that the patient’s predicted operative mortality was very low, suggesting a preventable death such as anesthetic mishap. A very high score (>20) does not imply, however, that the patient was unsalvageable. High-risk patients are those who require superb judgment and technical skills; these are the patients who do not tolerate even the smallest error.

— **Who was responsible?** The MMM is not a court (◊ Fig. 52.1). Culpability is not the issue, but at the end of the presentation it should be clear to all present how things might have been done better. Blame is to be avoided at all costs (except in the most extreme cases, and then the MMM is not the forum to deal with them) because any system that aims to apportion blame as part of the quality control processes will fail; the truth will be hidden and confrontation avoided. Such is human nature. The sad truth, however, is that in many instances complications and mortality are caused by “**system failure**” – which in purely surgical terms means that the hospital is a “s***hole” with a malfunctioning chain of command, organization, supervision, education and morals. For example, the old man was gasping unattended 6 hours in the emergency room before you were called to assess his acute abdomen. You decided on an emergency laparotomy but no operating room was available for 2 hours. Because the orderlies went for dinner another half-an-hour was lost until you decided to fetch the patient yourself. Only then did you realize that the antibiotics and intravenous fluids you ordered had not been given. A clueless anesthetist then struggles with the intubation producing prolonged hypoxia... and so on and so on... how much damage can an old man take? System failures are much more common than you think, just look around your own environment...



Fig. 52.1. “You killed the patient!”

— **Was the standard of care met?** As you surely know, the “standard of care” means different things to different people. (“**The good thing about standard of care is that there are so many to choose from**”). It has a spectrum, which should be well represented and assessed by a group of well-informed practicing surgeons. Take, for example, a case of perforated sigmoid diverticulitis with local peritonitis (● Chap. 26); any operation ranging from a Hartmann’s procedure (the conservative surgeon) to a sigmoid resection with anastomosis (the modern surgeon) would fall within the accepted standard of care. Primary closure of the perforation would not. Easy to assess – “anyone who would attempt closing the perforation please raise your hand”. No hand is raised; the responsible surgeon is left lonely to understand that what he did is not acceptable and is outside the practiced standard **in his community**. The responsible surgeon may, however, present published literature to support that what he did is acceptable elsewhere. Local surgeons may, however, be dogmatic and wrong!

— **Evidence-based surgery.** At the end of the presentation the resident should present literature to pinpoint the “state of the art” and the associated controversies, emphasizing “what could have been done, and should be done when we see a similar case in the future”.

— **The surgeon in whose patient the complication arose.** At the end of the discussion the most senior surgeon involved in the care of the concerned patient should offer a statement. He may choose to present additional evidence from the published literature to show that what was done is acceptable elsewhere. The most graceful way

to deal with the situation is to discuss the case scenario frankly and humbly admit any mistakes one may have made. If you had another chance with the same patient how would you manage him? By standing up and confessing you gain the respect of all present. When you lie, cover-up and refuse to accept the verdict of the gathering, you evoke silent contempt and disdain, (or perhaps sympathy from obsessive liars). So stand up and fess up!

Conclusions and Corrective Measures

Finally the person in the chair has to conclude – was there an error? Was the standard of care met? And what are the future recommendations and the corrective measures? If you are that chairman, and you may be some day, don't be wishy-washy. Be objective and definitive, for the audience is not stupid. Essentially, in any department of surgery the face of the MMM, its objectivity and practical value, reflects the face of the department's chairman or director.

Financial Morbidity

In this day and age of growing costs and limited resources we must not ignore the *financial morbidity* – the excessive spending on unnecessary procedures, even if they were not associated with an immediately visible physical morbidity (◉ Fig. 52.2). When discussing the case, ask the presenter to justify the Swan-Ganz catheter that has been inserted, or the reason antibiotics were continued for 7 days, or why the patient was “observed” in the SICU after an uneventful laparotomy? A useful educational exercise is to randomly present a detailed summary of the hospital bill of a presented patient. If you are confronted with what your patient's care, your superfluous acts, and the complications you created actually cost in dollars or euros, you may become a more careful surgeon.

The SURGINET

An ideal and objective MMM as featured above is not conducted in many places because of local sociopolitical constraints. If this is the case in your neck of the woods, it may be damaging to your own surgical education; how would you know what is right or wrong? Books and journals are useful but cannot replace a thorough analysis of specific cases by a group of learned surgeons. Well, if you have a PC and e-mail access you can subscribe to SURGINET, an international forum of surgeons, who would openly and objectively discuss any case or complication you present to



Fig. 52.2. "How much money can he bill for sending this guy to his grave?"



Fig. 52.3. "SURGINET - please help me!"

them (• Fig. 52.3). Should you want to take part in this “international MMM” send an e-mail message to Dr. Tom Gilas of Toronto, tgilas@sympatico.ca, or to one of the editors of this book: mschein1@mindspring.com.

Conclusions

As you know, there are many ways to skin a cat, and it is easy to be a smart-ass looking at things through the “retroscope”. Our sick patients and the events leading to the MMM are very complex. But behind this chaos there is always an instructive truth which should be and can be disclosed and announced. As Winston Churchill said, success is **“the ability to go from failure to failure without losing your enthusiasm”**.

— “It is usually the second mistake in response to the first mistake that does the patient in.” (Clifford K. Meador)

— “The two unforgivable sins of surgery. The first great error in surgery is to operate unnecessarily; the second, to undertake an operation for which the surgeon is not sufficiently skilled technically.” (Max Thorek, 1880–1960)

We hope you enjoyed our little book. Let us wish you farewell using this memorable quotation from Winston Churchill’s broadcast (1949) to the people of conquered Europe.

“Good night then: Sleep to gather strength for the morning. For the morning will come. Brightly will it shine on the brave and the true, kindly on all who suffer for the cause, glorious upon the tombs of heroes. Thus will shine the dawn.”

You – the emergency surgeons – are the heroes of medicine. For you the dawn will shine!

The Editors

Subject Index

A

Abcarian, Herand 445

abdominal

- aortic aneurysms (AAA) 19, 46, 329
- aortic emergency 329
 - - incision 331
 - - infra-renal aortic control 332
 - - operation 331
 - - preparation 331
 - - proximal control 332
 - - subdiaphragmatic aortic control 332
- apoplexy 19, 88
- bleeding
 - - life-threatening 436
- closure 334, 337, 340
 - - high risk 340
- compartment syndrome 155, 319, 321
- contamination 96, 97
- CT 372
 - - reviewing 42
- decompression 326
- emergency
 - - non-traumatic 441
- exploration 87
- imaging 33
- pain 19, 292
- re-entry 85
- sepsis 96
- trauma 9
 - - laparoscopy 442
- ultrasound (US) 28
 - - wall 53
 - - defect 390
 - - hernia 191
 - - wall dehiscence 411

- - complete 411

- - etiology 411

- - partial 411

- - prevention 412

- - treatment 412

- X-ray 21, 28, 33

abnormal

- gas pattern 33

- opacity 37

abscess

- complex form 382

- intra-abdominal 101, 211, 377

- - conservative treatment 381

- perianal 258, 261

achalasia 113

acidosis

- lactic 56

- metabolic 56

acquired biliary strictures 173

active bleeding 87

acute

- abdomen 10, 17

- abdominal pain

- - in the fertile woman 276

- anal fissure 263

- appendicitis 21, 29, 44, 68, 210, 230, 245, 281, 285, 293,

- cholangitis 173

- cholecystitis 21, 29, 163, 236, 281, 295

- colitis 208

- diverticulitis 21, 229

- gastric mucosal lesion 125

- gastroenteritis 37

- incarcerated full-thickness rectal prolapse 261

- acute
- mesenteric ischemia 19, 30, 197
 - pancreatitis 19, 27, 95, 144, 175
 - perianal hematoma 263
- adhesion 179, 370
- post-operative 13
- adjunctive
- diagnostic test 306
 - imaging 299
 - vascular procedures 202
- adnexal pathology 251
- AIDS 22, 291
- albumin 31
- anal
- canal injuries 257
 - fissure 2612, 263
- anastomosis 220, 233
- colocolic 220
 - colonic 107
 - colorectal 220, 227
 - testing 106
- anastomotic
- leak 387, 408
 - - non-operative management 388
 - - operative management 388
 - obstruction 373, 375
 - technique 104
- angiodysplasia 240
- anorectal emergency 255
- antibiotics 105, 150, 176, 184, 249, 381, 405, 428
- acute cholecystitis 171
 - duration of postoperative administration 364
 - minimal administration 364
 - postoperative use 363
 - pre-operative use 67
 - prophylaxis 67, 219
 - therapeutic 67
- anti-*Helicobacter pylori* 144
- anti-reflux procedure 124
- antrectomy 135
- aorta 315
- aortic
- occlusion 336
 - replacement 333
 - thrombosis 335
- APACHE II 88, 154
- apoplexy 88
- appendectomy 250
- appendiceal
- abscess 252
 - mass 252
 - phlegmon 21
- appendicitis 11, 284
- acute 21, 29, 44, 68, 210, 230, 245, 281, 285, 293
 - - abdominal imaging 247
 - - laparoscopic approach 250
 - - open approach 250
 - - technical points 250
 - perforated 20
- appendicular fecaliths 37
- Arderne, John* 264
- arterial blood gas 56
- ascites 40
- aspiration 59
- associated
- jaundice 164
 - lesion 113
- atelectasis 348
- autopsy
- in vivo 95
 - under anaesthesia (AUA) 75
-
- B**
- Bacteroides fragilis* 69
- balloon control 333
- Balzac, Honore de* 8
- barium 30
- base excess 56
- Battle, William* 13
- Baue, Arthur E.* 420
- BcBurney, Charles* 249
- Belloste, A.* 297
- Bernays, Augustus Charles* 196
- best management 3
- bezoar 22
- bile duct 50, 170
- biliary colic 163
- Billroth I
- gastroduodenostomy 135
 - partial gastrectomy 136
- Billroth, Theodor* 75
- bladder 79, 315

- Blaisdel, F. William* 304
Blalock, Alfred 60
 bleeding 270
 - duodenal ulcer 240
 - postoperative 240, 431
 - sources 239
 - varices 140
 blood
 - intraperitoneal 88
 - product 62
 - test 31
 blood-brain barrier 90
 blood-product transfusion 251
 blunt 119
 - abdominal trauma 29, 44, 305
 - trauma 68, 444*Boerhaave, Herman* 111, 116
 Boerhaave's syndrome 28
Borchardt, Moritz 121
Border, John 420
 bowel
 - edema 107
 - irrigation
 - - on-table 221*Bryant, Thomas* 13
Burke, Edmund 161
-
- C**
 Candida species 153
 capillary refill 60
 captain of the ship 24
 carcinomatosis 188
 cardiac
 - index 62
 - output 62
 care continuity 24
 CARS (compensatory anti-inflammatory syndrome) 6, 417
 Catell-Braasch maneuver 92
 catheter drainage 383
 CD4+ count 291
 cecal
 - carcinoma 187
 - diverticulitis 236
 - lesion 224
 cecopexy 228
 cecostomy 224
 celiac artery 316
 cellular hypoxia 56
 central
 - venous catheter 61
 - venous pressure (CVP) 61*Chalmers Da Costa, J.* 27
Charcot, Jean Martin 174
 Charcot's triad 174
 checklist 78
 - pre-operative 77*Cheselden, William* 10
 chest X-ray 27
Child, Charles Gardner III 139
 Child-Pugh classification 139
 cholangitis 31
 - acute 173
 - ascending 156
 cholecystectomy
 - delayed 164, 165
 - early 165
 - open tube 171
 - percutaneous, transhepatic 171
 - subtotal (partial) 168, 171
 - with common bile duct exploration 176
 cholecystitis 31, 50, 295
 - acalculous 170
 - acute 21, 29, 163
 - - antibiotics 171
 - - in cirrhotic patients 167
 - - non-operative management 164
 - - surgical management 165
 - acute calculous 163
 cholecysto-enteric fistula 34
 cholecystostomy 169
 choledocholithiasis 169
 cholelithiasis 154
 chronic
 - abdominal compartment syndrome 280
 - duodenal ulcer 125
 - gastric ulcer 130
 - megacolon 22
 - steroid intake 107*Churchill, Winston* 5, 455
 cirrhosis 138
 clinical pattern 19
 Clostridium difficile
 - colitis 211, 367
 - enterocolitis 27

colectomy
 – subtotal 219–221
 – total abdominal 221
 colitis 46, 205
 – acute
 – – operation 208
 – complications 207
 – severe 34
 Collis gastroplasty 113
 colloids 60
 colon 314
 – obstruction 22
 – perforation 34
 colonic
 – anastomosis 107
 – obstruction 37, 217
 – – preoperative diagnosis 217
 – pandiverticulosis 236, 240
 – pseudoobstruction 22, 223
 colonoscopic decompression 227
 colonoscopy 218, 223
 – complications 270
 colorectal anastomosis 227
 colostomy 221, 222, 260
 – decompressive 221
 – double-barreled 12
 – transverse 12
 common
 – bile duct stones 173
 – iliac artery 316
 compartment
 – infracolic 91
 – supracolic 91
 – syndrome 79
 compensatory anti-inflammatory
 syndrome (CARS) 6
 computed tomography 40, 184, 199, 306,
 307
 – contrast-enhanced dynamic 154
 – interpretation of the scan 41
 – methodology 41
Condon, Robert E. 161
 conservative treatment 131
 contamination 91, 95
 – abdominal 96
 contrast
 – enema 218
 – study 30

control continuing exploration 87
Cooper, Astley Paston 44, 265
Cope, Zachary 17, 33, 99, 225, 228
 Crohn's disease 51, 187, 205
 – emergency surgery 209
 crystalloids 60
 culdocentesis 276
Cullen, William 11
 Curtis-Fitz-Hugh syndrome 279
 cytomegalovirus 294
Czerny, Vincent 12

D

damage control 97
 decompression 219
 decubitus ulcer 348
 deep vein thrombosis (DVT) 79, 348
 diabetic ketoacidosis 22
 diagnostic
 – body 32
 – peritoneal lavage 29, 306, 307
 diaphragm 300, 311
 – free air 27
 – procedures 27
 – rupture 119
 diaphragmatic
 – emergency 119
 – hernia
 – – acquired 120
 – – congenital 119
 – – left 120
 diathermy 85
 Dieulafoy's lesion 137
 diverticulitis 46, 53, 240
 – acute 229
 – – approach 230
 – – clinical features 230
 – – conservative treatment 231
 – – controversies 236
 – – diagnosis 230
 – – newer concepts 235
 – – operation 232
 – – severe attack 232
 – – surgical pathology 229
 – complicated 231
 – – approach 232
 – phlegmonous 231

diverticulitis-sigmoiditis 220
 documentation 74
 drain 98, 349, 384, 400
 drainage 381
 – percutaneous 382
 duodenal ulcer 134
 – postbulbar 135
 duodenotomy 134
 duodenum 314
 – perforation 34

E

ectopic pregnancy 19, 276, 277
 edematous bowel 105
 electrolyte 182
 – imbalance 56
 elevated white cell count 31
 Eliot, T.S. 431
 emergency
 – cholecystectomy 165
 – during pregnancy 280
 – endoscopy 130
 – re-laparotomy 389
Emerson, Ralph Waldo 417
 endometrioma 276
 endoscopic
 – management 130
 – retrograde cholangiopancreatography (ERCP) 176
 – – preoperative 176
 – – with common duct clearance 176
 – sphincterotomy 156
 – stenting 224
 endoscopy
 – emergency 133
 – intra-operative 133
 endotoxin 68
 endotracheal intubation 59
 enteral nutrition 357
 enterotomy 85
 epigastric vessel 86
 EPSO following laparoscopy 374
 Escherichia coli 69
 esophageal
 – emergency 109
 – perforation 111, 266

– spontaneous perforation 28
 – varices 125, 138
 ethical problem solving 73
 ethics 71
 evidence 7
 evidence-based surgery 452
 exploration 87
 exploratory laparotomy 155, 384
 external bowel fistula 85
 extraperitoneal rectum injuries 256
 extreme fracture 317

F

Fabian, Timothy 313
 falciform ligament 86
 family 71, 73
 – difficult family 73
 FAST (focused abdominal sonography for trauma) 29
 fecal fistula 9
 fecology 234
 feculent vomiting 180
 femoral hernia 22, 194
 financial morbidity 453
Fine, Pierre 12
 fistula 387
 – external bowel 85
 – non-operative 388
 – operative management 388
 – type IV-A 391
 – type IV-B 391
Fitz, Reginald 11
 fluconazole 155
 fluid 182
 focused abdominal sonography for trauma (FAST) 306, 307
 foreign body ingestion 109
 Fournier's gangrene 259
 free fluid 44

G

gallbladder 50
 gallstone 37
 – ileus 22, 34, 189
 gas within the bowel 37
 gastrectomy 124

- gastric
 - emptying 375
 - mucosal lesion 125
 - outlet obstruction 31
 - ulcer 125, 136
 - – riding variant 136
 - volvulus 121
- gastroduodenostomy 135
- gastroenteritis 37
- gastroenterostomy, posterior 135
- gastroesophageal reflux 113
- gastrografin 31, 183
 - challenge 371
- gastropexy 124
- gastrostomy 357
- George II* 10
- Gilas, Tom* 455
- gimmicks 390
- gunshot wound 297, 444
 - to the abdomen 300
- gynecological emergency 275

H

- H₂ antagonist 125
- Halsted, William Stewart* 385, 437
- Hancock, Henry* 11
- Hardman criteria 330
- Hartmann's procedure 220, 221, 227
- Heinke-Mikulicz pyloroplasty 135
- Heister, Lorenz* 11
- Helicobacter pylori* 134
- HELLP syndrome 281
- hematemesis 126
- hematochezia 126, 240
- hematocrit 31
- hematoma
 - postoperative wound 432
 - prevention 432
- hemicolectomy 228
- hemoconcentration 56
- hemoperitoneum 89, 92
- hemorrhage 268, 436
 - adrenal 89
 - anti-coagulation 89
 - gynecological 89
 - kidney 89
 - liver 89
 - pancreatitis 89
 - recurrent 132
 - re-laparotomy 436
 - spleen 89
 - spontaneous intra-abdominal 89
 - trauma 89
 - upper gastrointestinal 125
 - vascular 89
- hemostasis 85
- heparin 334
- hepatic ligament 86
- hepatobiliary radio-isotope 170
- hernia 179
 - acute groin 191
 - diaphragmatic 119, 120
 - femoral 194
 - femoral 2
 - inguinal 193
 - irreducible inguinal 288
 - of the abdominal wall 191
 - paraesophageal 120
 - strangulated 10
- Heusner, Ludwig* 13
- highly selective vagotomy 135
- Hippokrates* 10, 355
- Hirshberg, Asher* 168
- history 9
- hollow organ 44
- hostile abdomen 85, 374
- Hunter, John* 8
- Hutchinson, Jonathan* 13
- hyperamylasemia 164
- hyperbaric oxygen 260
- hypertension
 - intra-abdominal 90
- hypertensive gastropathy 125
- hypertonic saline 60
- hypothermia 79
- hypovolemia 56
- hypovolemic shock 127

I

- iatrogenic intestinal injury 185
- ileus 37, 369
- iliac vein 316
- imaging study 78
- imipenem 155

Imrie, Clement 154
 incision 83
 – linea alba midline 83
 – lower midline 86
 – midline 84
 – subcostal 83
 – thoracoabdominal 85
 – transverse 83
 incisional hernia 83, 195
 infection 95, 366, 416
 – intra-abdominal 96
 – resectable 97
 inferior vena cava 88
 inflammatory
 – bowel disease 37, 205, 240
 – mediators 6
 informed consent 71, 74
 infracolic compartment 91
 inguinal hernia 193
 inotropic agent 62
 internal
 – acute strangulated hemorrhoids 260
 – hernia 370
 intestinal
 – anastomosis 103
 – distension 27
 – obstruction 12, 21, 281, 284, 369
 – – early postoperative mechanical 370
 intra-abdominal
 – abscess 101, 211, 381, 384
 – – surgical management 384
 – infection 408
 – vascular injury 315
 intra-hepatic abscess 49
 intra-operative endoscopy 133
 intraperitoneal
 – contamination 91
 – rectum 256
 – – injury 256
 intravenous contrast medium
 – contra-indications 42
 intussusception 12, 187, 286
 invasive monitoring 61
 irreducible inguinal hernia 288
 ischemic colitis 214

J
 jaundice 164, 175
 jejunal diverticulosis 236
 jejunostomy 358
Jones, Peter F. 17
 juxtarenal neck 332

K
Keeney, Arthur H. 86
Kelsey Fry, William 32
 kidney 89, 312
King Edward 11
 kissing ulcer 135, 149
 knife 85
Kocher, Theodor 85
 Kocherization 133
 Kocher's maneuver 92
 – left-sided 92
Kommer, Tid 64

L
 La Rocque's maneuver 194
 laboratory 62
 lactic acidosis 56
Lane, Arbuthnot 12
Lange, William A. 255
 laparoscopic
 – cholecystectomy 168, 171, 176
 – necrosectomy 160
 laparoscopy 439
 – technical considerations 445
 laparostomy 99, 100, 301, 395, 402, 406
 – abdominal re-exploration 407
 – indications 402
 – Sandwich technique 404
 – technical considerations 403
 – terminating 404
 – unnecessary 297
Larrey, Jean 310
 leak 31
 leakage 104
 leaking
 – anastomosis 107
 – intestine 100
 left colon 219

- ligament
 – falciform 86
 – round hepatic 86
 linea alba midline incision 83
 LIRS (local inflammatory response syndrome) 415, 416
Lister, Joseph 429
 Littre's inguinal hernia 287
 liver 49, 86, 89, 310, 311
 – function test 31
 – panel 175
 local inflammation 415
Lockwood, John S. 77
 lower midline incision 86
 lung window 43
-
- M**
- MacEwen, William* 101
 major trouble 92
 Mallory-Weiss 128, 130
 malnutrition 107
 management
 – algorithm 372
 – options 18
 mass closure 338
 massive
 – hemoperitoneum 90
 – lower gastrointestinal bleeding 239
 – – operation 242
 Mattox maneuver 92
Maugham, W. Somerset 275
Mayo, Charles H. 9, 125
McBurney, Charles 11
 McBurney's point 11
McDowell, Ephraim 13
Meador, Clifford 455
 mechanical ventilation 59
 Meckel's diverticulitis 51, 52, 251, 287
 medial
 – infection 366
 – visceral rotation 92
 median sternotomy 85
 medical cause 22
 medicolegal
 – consideration 73
 – issue 71
 megacolon 22
 – chronic 22
 melena 126
 mesenteric
 – angina 198
 – angiography 30, 199, 242
 – ischemia 30, 34, 107, 407
 – lymphadenitis 251
 – tears 88
 – venous thrombosis 203
 – acute ischemia 197
 – – non-operative treatment 200
 – – operative treatment 200
 – – second-look operation 203
 metabolic acidosis 56
 microbiology 379
 midline incision 84
Mikulicz-Radecki, Johannes von 12, 13, 143
 minor trouble 92
 misadventure 104
 missed abdominal injury 91
 mittelschmerz 276
 MODS (multi-organ dysfunction syndrome) 415, 417
 – treatment 418
Molière 67
Mondor, Henry 277
 monitoring 348
Moore, Francis D. 64, 79, 125, 353, 430, 449
 morbid obesity 323
 morbidity 75
 Morgagni hernia 119
Morrison, Rutherford 279
Morse, Thomas 13
 mortality 75
 – risk of 72
Morton, Thomas 11
Moynihan, Berkeley 10
 Murphy's sign 174
Murphy, John Benjamin 11, 174
Murray, Humphrey George 87
 myocardial infarction 22
-
- N**
- nasoenteric 357
 nasogastric 357
 – tube 59, 128, 349
 – aspiration 182

necrosis non-infected 157
 neoplasm 240
 neostigmine 223
 neutropenic enterocolitis 213
 non-resectable IAI 96
 non-specific abdominal pain (NSAP)
 18
 nutrition 355
 – parenteral 359
Nyström, P.-O. 73

O

obesity 86
 obstruction 31
 – closed-loop 180
 – complete 180
 – partial 180
 – simple 180
 – strangulation 180
Ogilvie, William Heneage 223, 352, 362,
 410
 Ogilvie's syndrome 223
Oliver, Matt 341
 omental flap 147
 omentopexy 146, 148
 omentum 10
 open management 99
 operation, indication 132
 operative management 132
 optimization 55
 – goals 56
 oral feeding 361
 organ dysfunction 396
Osler, William 429
 ovarian
 – cyst 51, 277
 – torsion 46
 oxygen delivery 58
 oxygenation 59

P

Pack, George T. 75
 pain treatment 348
 pancreas 313
 pancreatectomy 154
 pancreatic

– abscess 151, 153, 158
 – calcification 37
 – – infected 34
 – carcinoma 173
 – necrosis 51, 91, 151
 pancreatitis 46, 89, 95, 267, 451
 – acute 144, 175
 – – classification 151
 – – infection 153
 – – inflammation 151
 – – natural history 151
 – – necrosis 152
 – – operative approach 158
 pandiverticulitis 236
 – colonic 236
 paralytic ileus 348
Paré, Ambroise 429
 parenteral nutrition
 patient
 – asymptomatic 298
 – general status 208
 – high risk 166
 – unstable 107
Paul, Frank Thomas 12
 PC drain 383
Péan, Jules 11
 pediatric abdominal
 – injury 289
 – pain 283
 pelvic
 – hematoma 317
 – inflammatory disease 276, 278
 penetrating trauma 119, 444
Penn, William 161
 peptic ulcer 95
 – definitive procedure 145
 – diagnosis 144
 – natural history 143
 – perforation 13, 27, 408
 – simple closure 146
 percutaneous
 – aspiration 383
 – drainage 158
 perenal azotemia 56
 perforated
 – appendicitis 20
 – cecal diverticulitis 251
 – peptic ulcer 27

- perforated
 – ulcer 20
 – – laparoscopic management 149
 – – non-operative management 149
 perforation 269,271
 – esophageal 112
 – in the chest 112
 – in the neck 112
 – spontaneous 113
 – time of 116
 periampullary carcinoma 173
 perianal
 – abscess 258,261
 – hematoma 261
 – sepsis 295
 pericolic abscess 232
 perineal infection 259
 periodic re-evaluation 248
 peripheral parenteral nutrition 360
 peritoneal
 – cavity
 – – radical debridement 98
 – cultures 101
 – irrigation with antibiotics 98
 – lavage
 – – intra-operative 98
 – – postoperative 98
 – sign 20
 – toilet 97,251
 peritonitis
 – contamination 95
 – diffuse established 53,107
 – generalized 20,396
 – infection 95
 – localized 21
 – postoperative 103
 – primary 91,95
 – secondary 91,95
 – tertiary 95,415,419
 philosophy 3
 phlegmonous diverticulitis 231
 plain abdominal X-ray 218
 pneumatosis intestinalis 34,44
 pneumobilia 34
 pneumonia 348
 – lower lobe 28
 pneumoperitoneum 33
 pneumothorax 42
 portal
 – hepatic injury 312
 – hypertension 125,138
 – vein gas 34
 position 78
 post partum period 282
 post-endoscopy decision making 131
 postoperative
 – abdominal bleeding 433
 – bleeding 431
 – care 347
 – ileus 369
 – peritonitis 396
 – test 350
 postural hypotension 60
 pregnancy 323
 – emergencies 280
 pregnant woman 279
 presacral drainage 256
 prevention 326
 primary
 – peritonitis 91
 – survey 90
 proctocolectomy 209
 pro-inflammatory mediator 152,
 417
 protein sparing hydration 359
 proton pump inhibitor 125
 proximal fecal diversion 256
 pseudocyst 151,157
 – infected 151,153
 pseudo-obstruction 37,218
 pulse oximetry 59
 pyelophlebitis 34
 pyrexia 365
-
- Q**
Queen Caroline 10
-
- R**
 radiation
 – enteritis 188
 – exposure 41
 – proctitis 240
 radionuclide 163
Ranson, John C. 154

- Ravitch, Mark M.* 69, 249, 254, 353, 362, 397, 430
 rebound tenderness 20
 rectal
 – examination 128
 – foreign body 257
 – prolapse 261
 – washout 256
 rectoscopy 241
 rectum 315
 re-imaging 383
 re-laparotomy 395
 – on demand 395, 396
 – planned 99, 100, 395
 – – indications
 – timing of re-look 400
 renal vein thrombosis 51
 re-operation 72
 resectable
 – IAI 96
 – infection 97
 resection 220
 resting the pancreas 155
 restorative procedure 209
 retention sutures 340
 retrohepatic caval injury 312
 retroperitoneal hematoma 316
 retroperitoneum 53
 Reynold's pentad 175
Reynolds, B.M. 175
Richardson, David J. 116
 Richter's hernia 192
Riegner, Oskar 12
Roscoe, R. Graham 150
Roth, Philip 71
 round hepatic ligament 86
 routine exploration 87
 ruptured ovarian cyst 276
 – survey 90
 selective conservatism 303
 sepsis 56, 96, 416
 serum
 – albumin 356
 – amylase 20
 severity
 – of illness 58, 153
 – of injury 92
 shock 19
 sigmoid 219
 – diverticulitis 91
 – volvulus 225
 – – non-operative approach 225
 sigmoidopexy 227
Sims, James Marion 163
 SIRS 6, 348, 415, 416
 – treatment 418
 small bowel 107, 314
 – mesentery 53
 – obstruction 22, 37, 44, 192, 210
 – – conduct of the operation 185
 – – decompression 186
 – – early postoperative 370
 – – immediate operation 183
 – – laparoscopic approach 186
 – – non-operative approach 182
 solid organ 44
 – injury
 – non-operative management 309
 source control 97
 speed 104
 spleen 50, 89, 10, 310, 311
 – ruptured 11
 splenectomy 11
 splenic abscess 295
 spontaneous hemoperitoneum 92
 stab wound 297, 444
 – to the abdomen 298
 steak house syndrome 110
 sterile necrosis 153
 stoma 85
 – high small bowel 107
 stomach 314
 stomal ulcer 137
 strangulation 181
 stratification 129, 139
 stricture 104
-
- S**
 saddle embolus 335
Saint, Charles F.M. 79
Sampson, H.H. 303
 seat belt sign 306
 second lumbar vertebrae 306
 secondary
 – peritonitis 91

- stump appendicitis 252
 subcostal incision 83
 subcutaneous space 339
 superficial
 – acute mucosal lesion 137
 – lesion 130
 superior mesenteric
 – artery 316
 – vein 316
 supracolic compartment 91
 surgical
 – acrobatics 5
 – drainage 382, 384
 – infection 366
 – management
 – philosophy 134
 – ostrich 350
 SURGINET 453
 survey
 – primary 90
 – secondary 90
 suture material 104, 337
 Swan–Ganz pulmonary artery flotation
 catheter 62
Sydenham, Thomas 204
 systemic
 – inflammation 415
 – inflammatory response syndrome (SIRS)
 6, 56, 152, 170
-
- T**
Tait, Robert Lawson 11, 14
 team approach 24
 technetium-labeled erythrocyte scan 242
 temperature 351
 temporary abdominal closure 100
 tertiary peritonitis
 testicular torsion 288
 thoracoabdominal incision 85
Thorek, Max 168, 455
 total
 – abdominal colectomy 208
 – body CT scanner 32
 – parenteral nutrition 360
 trans-atrial vena cava shunt 85
 transnasal 357
 – intubation 357
 – transverse incision 83
 – trauma 89
 – in pregnancy 282
 – to the rectum and the anus 255
 – treatment
 – effectiveness 60
 – philosophy 145
Trendelenburgh, Friedrich 12
Treves, Frederick 179
 triangle of death 90
 triple regimen 69
 trouble
 – major 92
 – minor 92
 truncal vagotomy 134
 tube
 – cholecystectomy 167
 – gastrostomy 124
 tubo-ovarian abscess 46, 51
-
- U**
 ulcer
 – chronic duodenal 125
 – chronic gastric 130
 – duodenal 134
 – gastric 125, 136
 – perforated 20
 – pre-pyloric 136
 – stomal 137
 ulcerative colitis 205
 – grading 207
 ultrasonographic finding 164
 ultrasonography 170, 184
 ultrasound 154, 247
 unnecessary test 31
 upper gastrointestinal
 – bleeding
 – post EGD 266
 – endoscopy 266
 – complications 266
 ureter 312
 ureteric
 – calculi 41
 – stone 29, 37
 urinary
 – bladder 86
 – catheter 79

- urine
- analysis 56
- output 61

V

- Valentino appendix 252
- Valentino, Rudolph* 252
- varices 130, 140
- vena cava 315
 - infrahepatic 315
- Vesalius* 10
- virgin abdomen 187
- visible vessel 130
- volvulus 37
 - mesenteroaxial 121
 - of the cecum 227
 - of the colon 224
 - organoaxial 121

W

- water-soluble contrast 30
- Way, Lawrence W.* 167
- white
 - appendix 251

- cell response 365
- Wittmann, Dietmar* 398
- World War II 107
- wound
 - closure
 - - delayed 428
 - dehiscence 83
 - infection 426, 429
 - - prevention 426
 - management 425
 - - aftercare 430
 - - complicated wound 426, 429
 - - major complications 426
 - - minor complications 426
 - - uncomplicated wound 425, 428
 - - wound infection 426
 - non-closure 428
 - Wurtz, Felix* 429

X

- X-ray
 - abdomen 21
 - chest 27
 - plain abdominal 28, 33